


Orthopaedic Nursing 101

- Lacey Roberts, RN
- January 22, 2014



Objectives

- Describe assessment of an orthopaedic patient
 - Demonstrate use of orthopaedic splints and braces
 - Identify skin care issues in the orthopaedic patient
 - State signs and symptoms of orthopaedic complications
- 



Assessment


- ABC's
 - Monitor VS; circulation, motor, sensory checks (CMS checks) specifically to affected extremity
- Level of Consciousness
- Lung Sounds, respirations, oxygen saturations, need for supplemental oxygen

Assessment Cont.

- Bowel sounds, last BM, urinary complications
- Incision area : drainage, ecchymosis, edema
- Appetite, Nausea, Vomiting
- Activity Tolerance (muscle strength, movement, atrophy, contracture)
- Sleep

Assessment Cont.


- Pain
 - where is the pain?
 - when did the pain begin?
 - what makes it worse?
 - what relieves the pain? (positioning, ice, analgesics, mobility)
 - describe the pain and rate intensity



Pain control is a key factor in improving a patient's recovery. Adequate pain control promotes earlier mobilization and improves circulation.



Fractures

- CMS checks:
 - pulses distal to injury (palpable or need doppler)
 - capillary refill
 - color
 - motor function distal to fracture
 - sensory function distal to fracture
- 

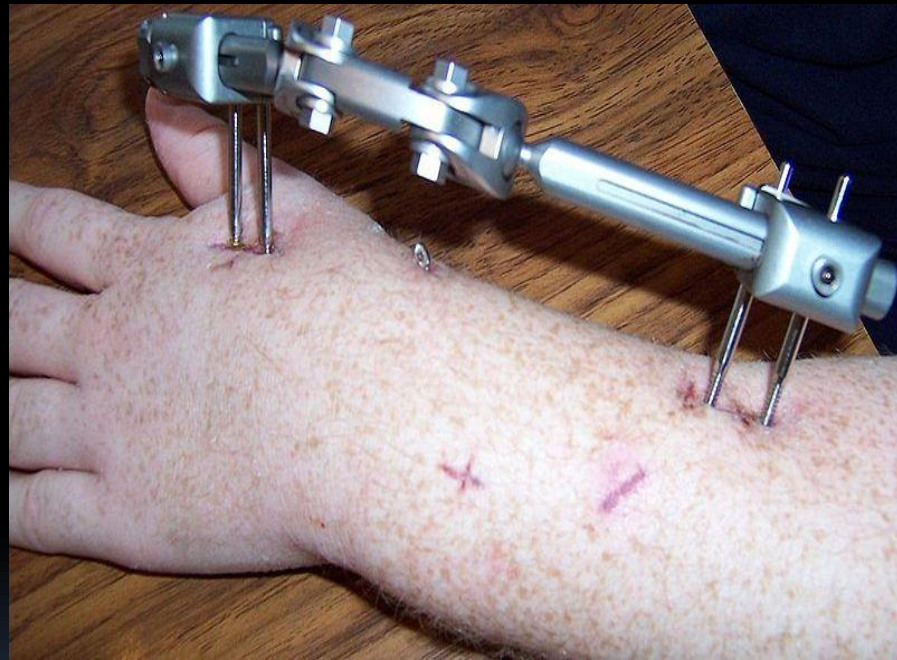

Fractures Cont.

- Open fracture- high concern for infection (osteomyelitis, sepsis)
- Closed fracture
- Close monitoring of patients with unstable pelvis fractures
 - increased risk for hypovolemic shock


External Fixator

- proper pin site care
- monitor for signs of infection.





Uses of Splints and Braces

- Acute injuries
 - Chronic conditions
 - Prevention of injury
 - Pain reduction by giving support to a joint
 - Immobilizer
 - Rehabilitative knee brace
- 

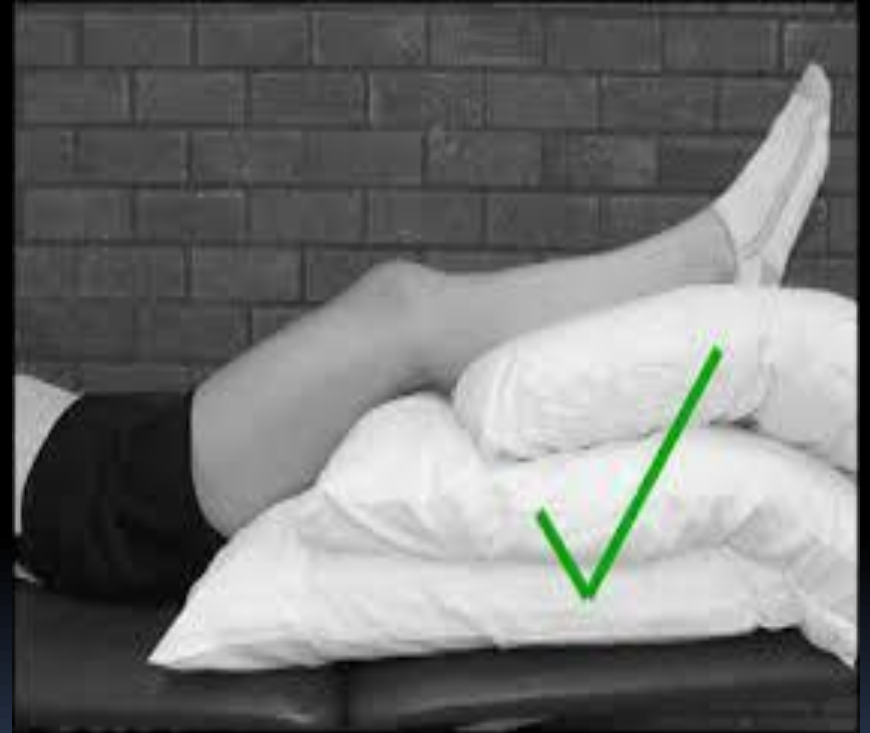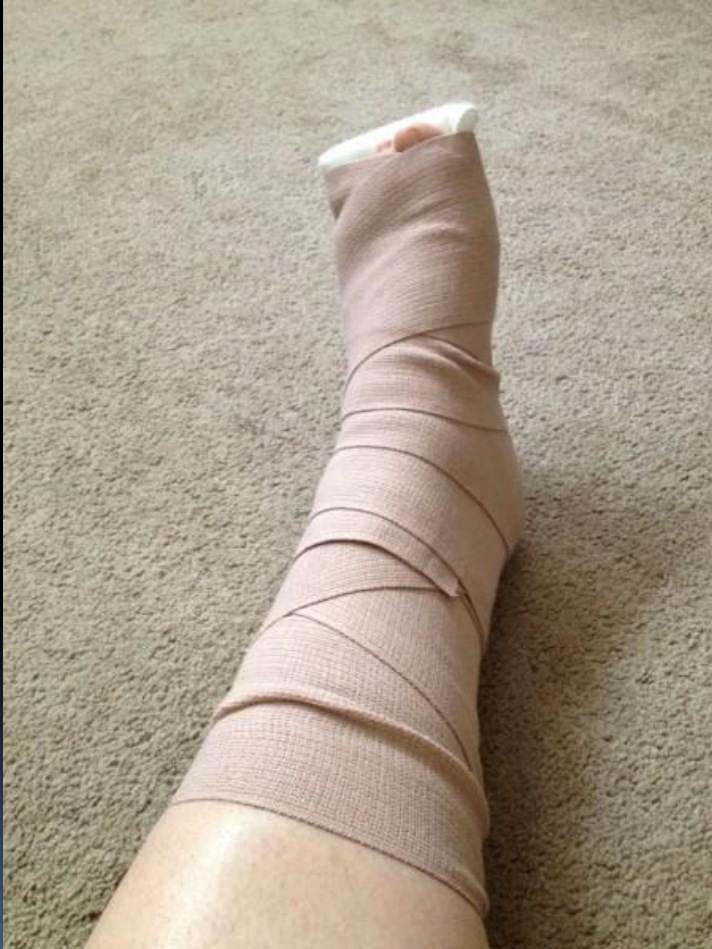Examples of Splints and Braces

- wrist splint for carpal tunnel syndrome
- Semi-rigid ankle brace for ankle sprain
- Knee brace after ACL surgery or total knee replacement
- Quadriceps rupture, patellar fracture or dislocation
- MCL rupture
- After ACL surgery

Splints and Braces Cont.

- Keep swelling down it can create pressure under splint, brace or cast
 - elevate affected extremity
 - exercise joints above and below the splint, brace or cast
 - ice the affected area
 - splint should be well padded

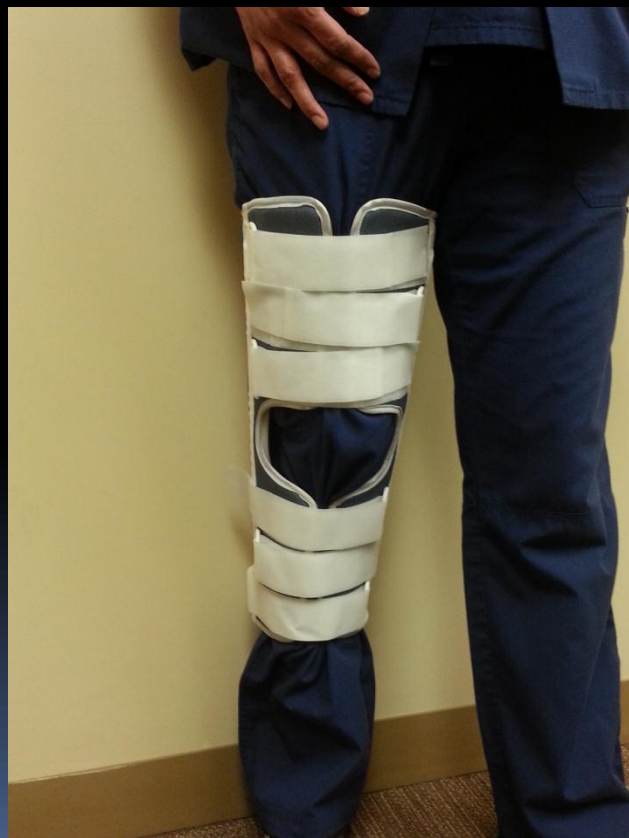Splints and Braces Cont.



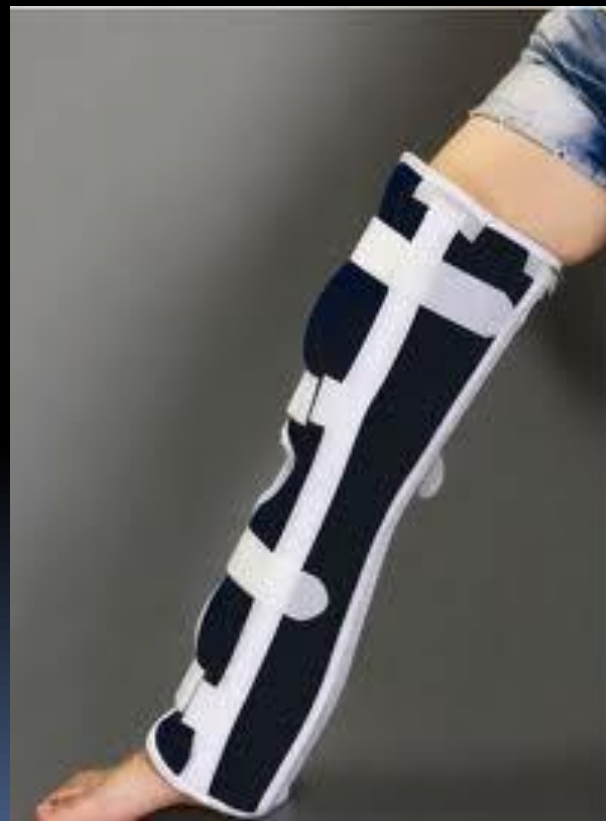Splints and Braces Cont.

Knee Immobilizer

Correct way to wear

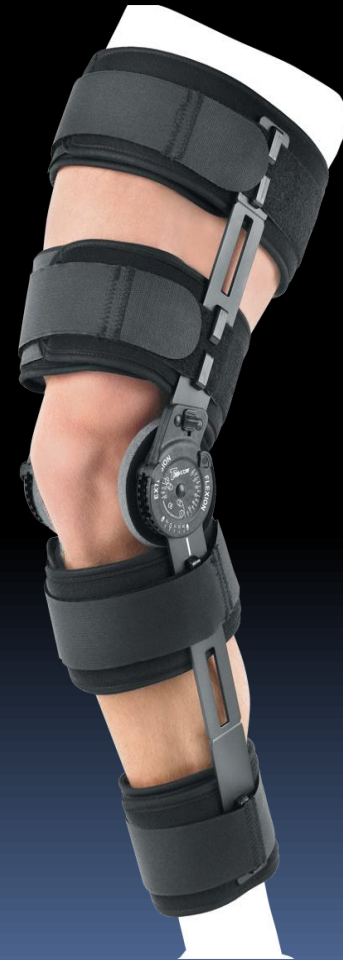
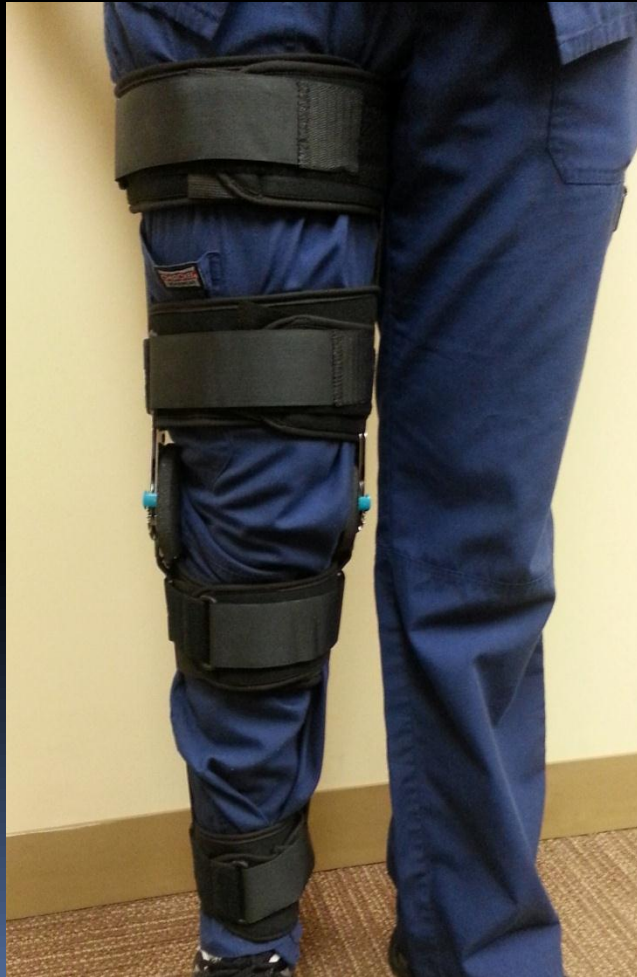
Wrong way to wear



Splints and Braces Cont.

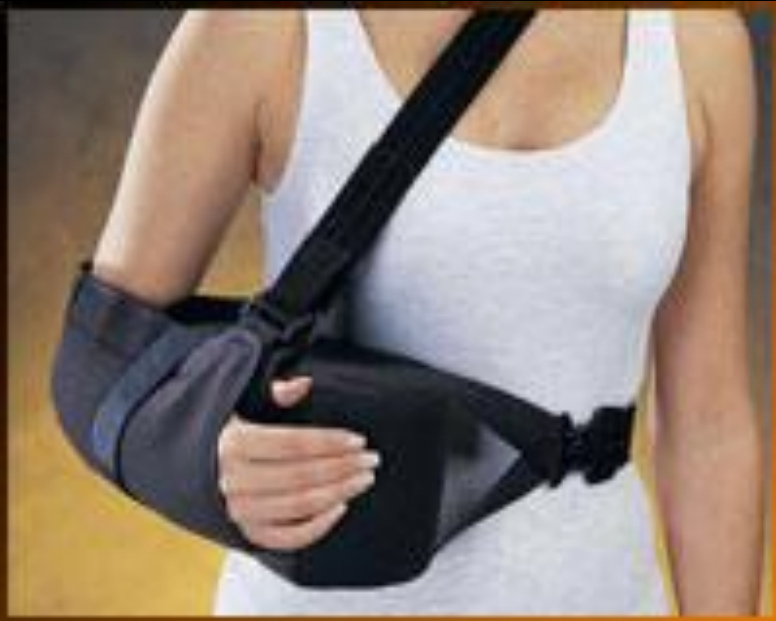T-ROM Brace



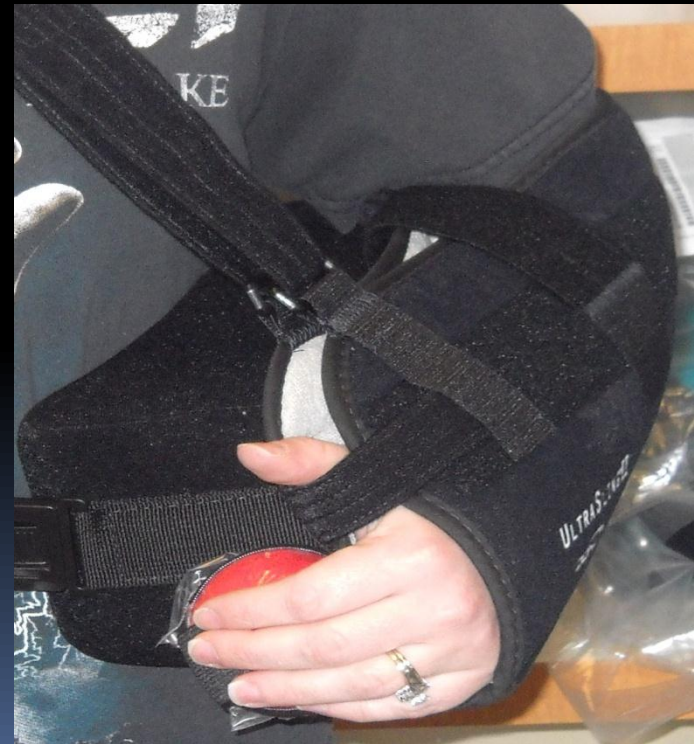Splints and Braces Cont.

Abduction pillow shoulder sling

Correct way to wear



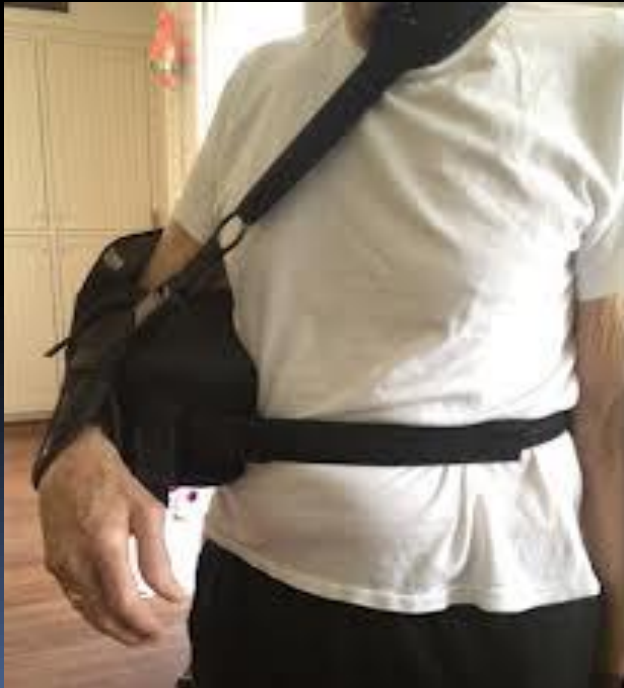Correct way to wear



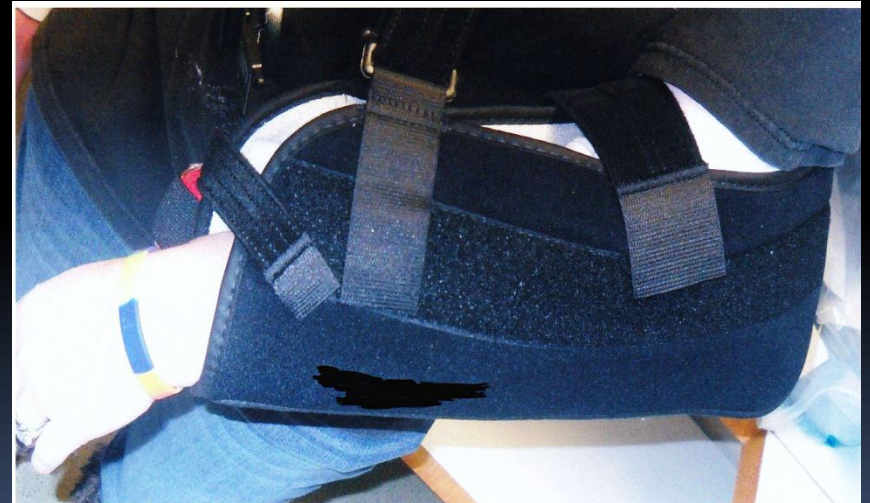Splints and Braces Cont.

Abduction pillow shoulder sling

Wrong way to wear



Wrong way to wear



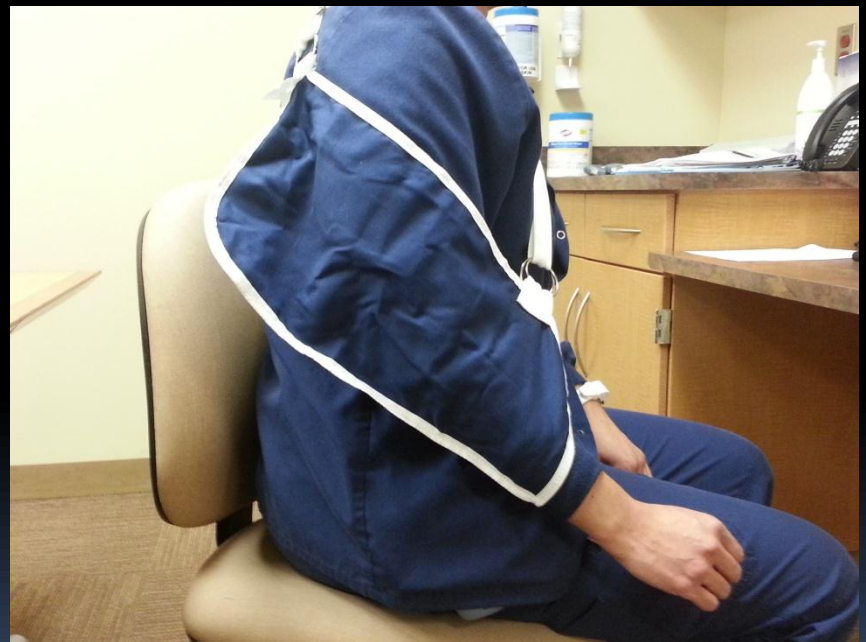Splints and Braces Cont.

Arm sling

Correct way to wear



Wrong way to wear






Cold Compression

- Routinely used immediately after acute injury or following surgery
- Cold can help reduce pain by reducing inflammation and swelling



Skin Care Issues

Pressure ulcer is localized injury to the skin and/or underlying tissue usually over a bony prominence, as a result of pressure, or pressure in combination with shear and/or friction.




Skin Care Issues Cont.

- Obesity and low body weight individuals tend to be at greater risk for developing pressure ulcers
- Orthopaedic patients tend to be more immobile initially post-op, particularly the elderly, which increases the risk of friction and shearing



Skin Care Issues Cont.

- Use of Braden Scale to identify the risk of skin and pressure issues for your patient.
 - Use interventions to help decrease your patient's risk (proper transfers, frequent repositioning, use of air mattress, mobilize, protective dressings)
- 

Tissue tolerance for pressure

Influenced by intrinsic factors:

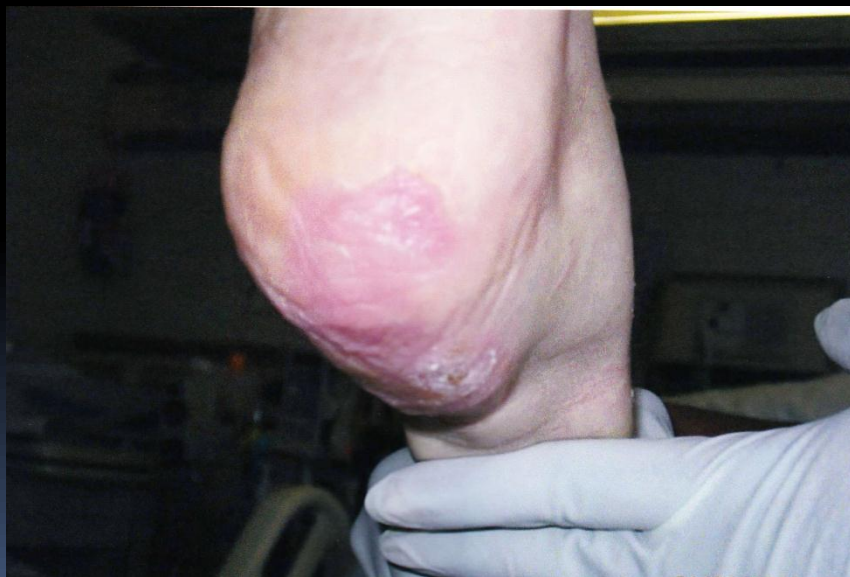- Nutritional status
- Age
- Low arteriolar pressure

Influenced by extrinsic factors:

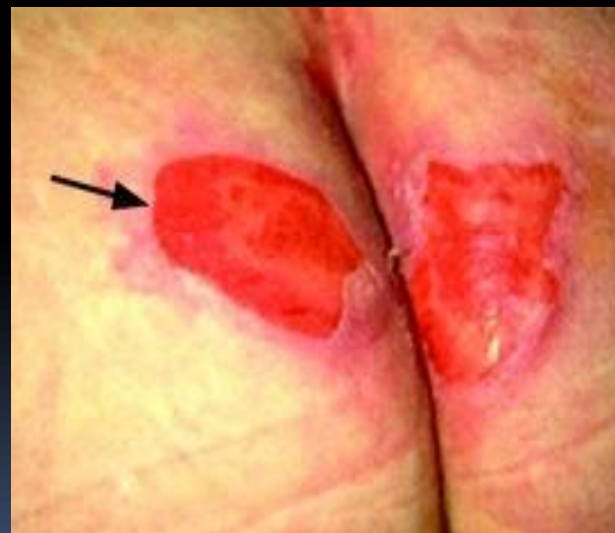- Skin moisture
- Friction
- Shear

Skin Care Issues Cont.

Stage 1 Pressure Ulcer




Stage 2 Pressure Ulcer



Pressure Ulcer

- Off load heels
- Keep skin dry
- Reposition
- Get out of bed
- Monitor bony prominences
- Straight linens
- Monitor where tubing lays (oxygen tubing on ears)



Orthopaedic Complications

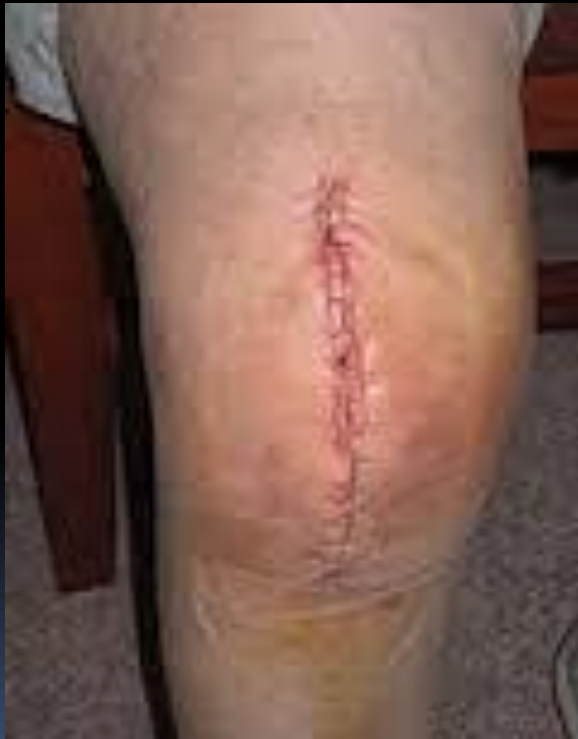

Surgical Site Infection

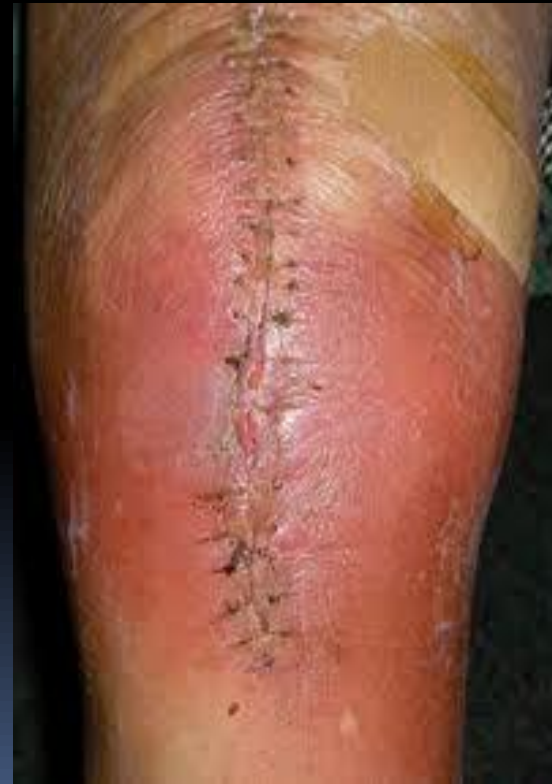- Redness
- Delayed healing
- Fever
- Pain
- Tenderness
- Warmth
- Errythema
- Swelling
- Purulent discharge
- Drainage
- Increased pain

Surgical Site Infection Cont.

Non-infected




Infected






Surgical Site Infection Cont.

- Make sure all appropriate doses of antibiotics are given post-op
 - Monitor vital signs, watch lab work
 - Good nutrition, use of supplements if needed
- 



Surgical Site Infection Cont.

- Monitor blood glucose in diabetic patients
 - Incision care
 - Educate patients
- 

Surgical Site Infection Cont.

HAND

HYGEINE

COMPLIANCE!!!






Compartment Syndrome

A condition in which there is increased pressure in a closed compartment preventing blood flow and oxygen from reaching muscles and nerves causing damage.



Compartment Syndrome Cont.

If not identified and treated immediately

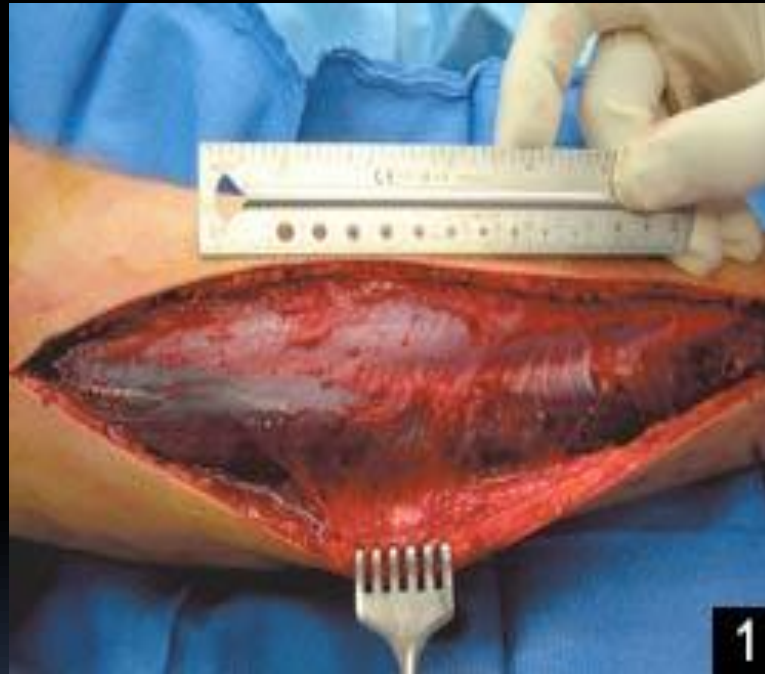
- Permanent nerve damage
 - Tissue necrosis
 - Muscle death
 - Amputation
- 

Compartment Syndrome Cont.

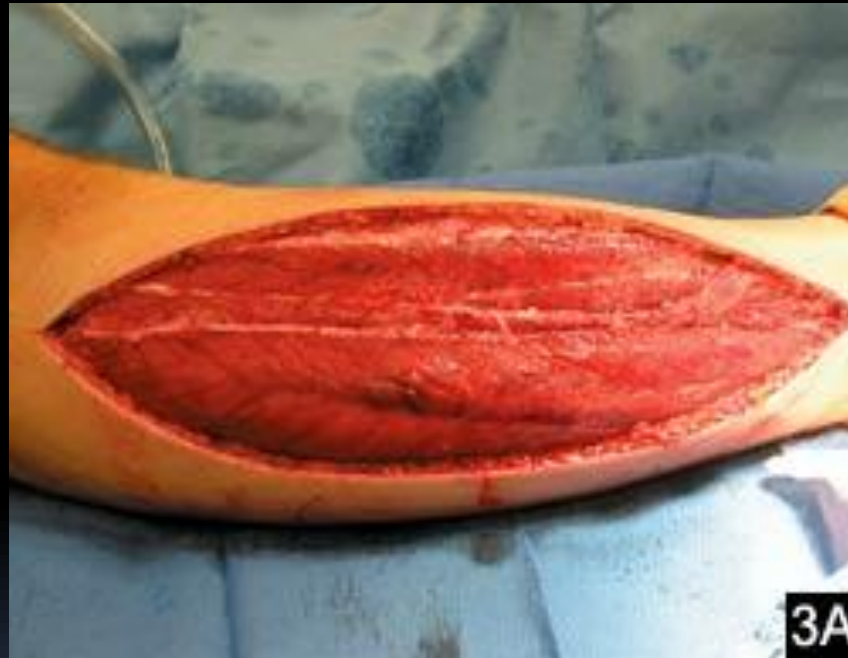The 5 p's of compartment syndrome

1. Pain – early sign
2. Pallor
3. Paresthesia
4. Paralysis
5. Pulselessness- late sign

Compartment Syndrome Cont.



Compartment Syndrome Cont.



Compartment Syndrome Cont.

- Notify MD ASAP, compartment syndrome is an EMERGENCY, muscle necrosis can occur within 4 hours
- Avoid hypotension, you want as much capillary perfusion pressure as possible to the limb
- Remove bandages, splint, cast if possible
- Maintain extremity at heart level, elevating will reduce capillary perfusion


Compartment Syndrome Cont.

Do not apply ice to suspected site, this can constrict blood flow causing more damage





Fat Embolism


- Rare clinical condition in which fat emboli lead to multisystem dysfunction
 - respiratory dysfunction
 - cerebral dysfunction
 - petechial rash
- 

Fat Embolism Cont.

- Manifestations can develop 24-72 hrs after trauma especially long bone fractures
- Pulmonary dysfunction is the earliest to manifest
 - Leads to respiratory failure in 10% of cases
 - tachypnea, dyspnea, cyanosis, hypoxemia



Fat Embolism Cont.


- Cerebral dysfunction
 - acute confusion, drowsiness, rigidity, convulsions, coma
- 

Fat Embolism Cont.

- Skin dysfunction
 - nondependent areas
 - nonpalpable petechial rash in chest, axilla, conjunctiva, and neck
 - rash can appear 24-36 hrs and disappear in 1 week



Fat Embolism Treatment

- High flow rate of oxygen to support good arterial oxygenation
 - IV fluids to help prevent shock that can exacerbate lung injury
 - Albumin- restores blood volume and binds with fatty acids that can decrease injury to the lung
- 



Deep Vein Thrombosis

- DVT is the formation of a thrombus within a deep vein, most commonly in the thigh or calf
- More common in thigh after hip surgery
- More common in calf after knee surgery

Deep Vein Thrombosis Cont.

- Thrombin forming in the thigh are more likely to break free and cause a Pulmonary Embolism (PE)
- Without preventative measures about 80% of orthopaedic surgical patients would develop a DVT and 10-20% would develop PE
- Prevention: early mobilization, anticoagulant, pneumatic compression device

Deep Vein Thrombosis Cont.

- Lower extremity DVT can be symptomatic or asymptomatic
 - positive Homan's sign
 - erythema/discoloration
 - swelling
 - pain when standing or walking
 - tenderness
 - warmth

Testing: D-dimer lab, venous ultrasonography,
MRI

Deep Vein Thrombosis Cont.


Risk for DVT extends for at least 3 months after a joint replacement surgery. Greatest risk is days 2-5 postoperatively with second peak period about 10 days postoperatively.

Treatment:

- Anticoagulants
- Thrombolytics



Pulmonary Embolism

- Blockage in one or more arteries in the lung commonly caused by blood clots traveling to the lungs from another part of the body (legs)
 - Knee and hip replacement surgery are one of leading problems for blood clots.
- 



Pulmonary Embolism Cont.

Common signs/symptoms

- SOB- sudden onset, worse with exertion
- Chest pain- worse with deep breath, worse with exertion no relief with rest
- Cough- hemoptysis



Pulmonary Embolism Cont.

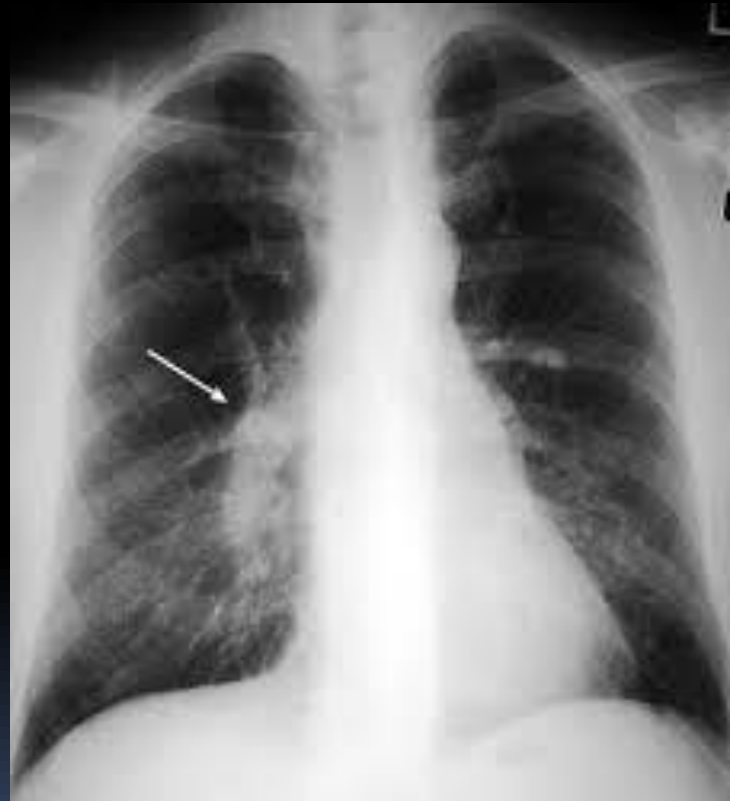Other signs/symptoms

- Clammy or cyanotic skin
- Leg pain and/or swelling
- Anxiety
- Excessive sweating
- Tachycardia, tachypnea, palpitations
- Lightheadedness or dizziness

Pulmonary Embolism Cont.

Tests:

- D-dimer lab
- CXR
- Spiral CT scan
- Ultrasound

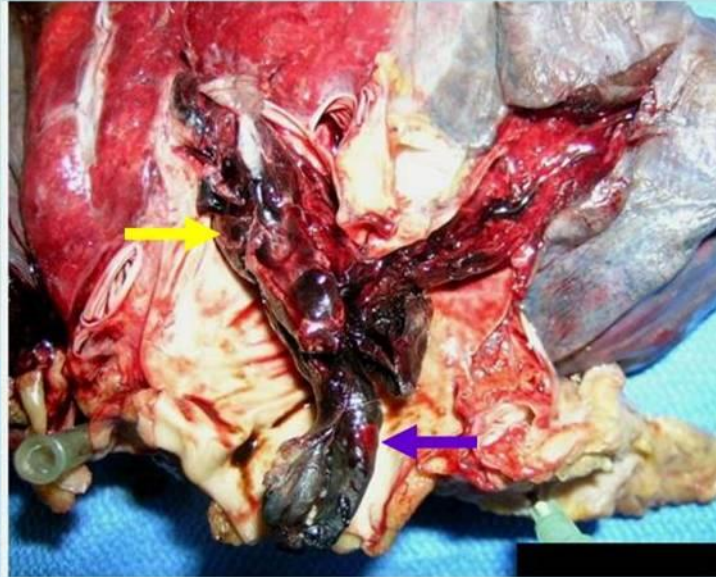
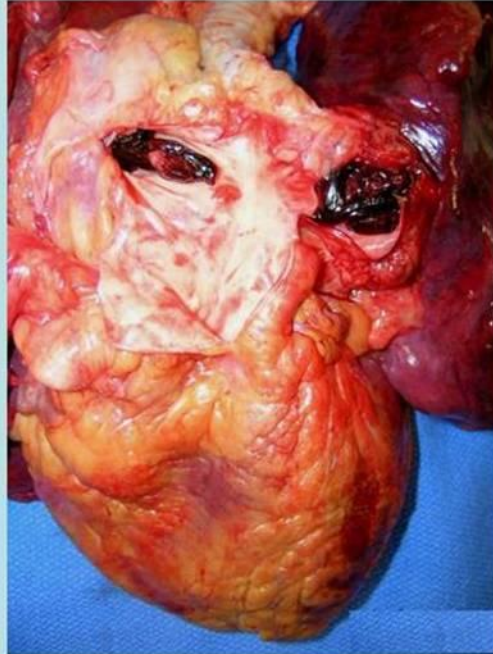


Pulmonary Embolism Cont.

- Treatment


- Anticoagulants
- Thrombolytics
- Embolectomy
- Placement of IVC filter

Pulmonary Embolism Cont.





Other Complications

- Atelectasis
 - Pneumonia
 - Bowel Obstruction
 - Urinary Retention
 - Hip Dislocation
- 



QUESTIONS?

References

1. Pulmonary embolism - Disease and Conditions - Mayo Clinic, (1998-2014). Retrieved from <http://www.mayoclinic.org/diseases-conditions/pulmonary-embolism/basics/definition/>
2. American Academy of Orthopaedic Surgeons, (2009). Deep vein thrombosis. Retrieved from <http://orthoinfo.aaos.org/topic.cfm?topic=A00219>
3. Emeka Kesieme, Chinenye Kesieme, Nze Jebbin, et al. Deep vein thrombosis: a clinical review. *Journal of Blood Medicine* 2011;2 59-69.
4. Michael S. Bongiovanni, MD, FACS; Susan L. Bradley, MSN, FNP; Dorothy M. Kelley, MSN, RN, CEN. Orthopedic Trauma. *Critical Care Nursing*, 2005, Vol. 28, No 1. pp 60-71.
5. American Academy of Orthopaedic Surgeons, (2011). Care of casts and splints. Retrieved from <http://orthoinfo.aaos.org/topic.cfm?topic=a00095>.
6. Wai Shan Chan, Samantha Mei Che Pang and Enid Wai Yung Kwong. Wound care and pressure ulcers. *Journal of Clinical Nursing*, (2009). 18, 1565-1573
7. Emergency management of fat embolism syndrome. *Journal of Emergencies, Trauma, and Shock*, (2009). Jan-Apr; 2(1): 29-33. Retrieved from <http://www.ncbi.nlm.nih.gov/pmc/articles/PMC2700578/>

References Cont.

8. Shawn Mangan Pierce, MSN, RN, CRNP. Acute lower extremity compartment syndrome. Advance Healthcare Network for NPs and PAs, (2013). Retrieved from <http://nurse-practitioners-and-physician-assistants.advanceweb.com/Editorial/Content/>
9. Jon E Block, PhD. Cold compression in the management of musculoskeletal injuries and ortopedic operative procedures: a narrative review. Open Access Journal of Sports Medicine 2010:1 105-113.
10. Gravely, J.R. & Van Durme, D.J. (2007). Braces and splints for musculoskeletal conditions. American Family Physician. Retrieved from <http://www.aafp.org/afp/2007/0201/p342.html>
11. Thompson, M. & Magnuson, B. (March 2012). Management of Postoperative Ileus. Retrieved from <http://www.healio.com/orthopedics/journals/ortho/%7Bc1b4c8do-3aea-45e2-9dca-af6b98446f71%7D/>
12. T. Balderi, F.Carli. Urinary retention after total hip and knee arthroplasty. Minerva Anesthesiol, 2010-prohipdk.elyk.dk
13. American Academy of Orthopaedic Surgeons, (2011). Total Hip Replacement. Retrieved from <http://orthoinfo.aaos.org/topic.cfm?topic=a00377>