

**STANDARD TREATMENT
GUIDELINES
OPHTHALMOLOGY**

**Ministry of Health & Family Welfare
Govt. of India**

Contents

S.No.	Topic	Page No.
1	REFRACTIVE ERRORS	4
2	STRABISMUS AND AMBLYOPIA	23
3	CONJUNCTIVITIS	35
4	MICROBIAL KERATITIS	45
5	CATARACT	57
6	DIABETIC RETINOPATHY	68
7	AGE RELATED MACULAR DEGENERATION (AMD)	81
8	GLAUCOMA	88
9	ANGLE CLOSURE DISEASE	89
10	PRIMARY OPEN ANGLE GLAUCOMA	103
11	INFECTIVE ENDOPHTHALMITIS	113
12	CHRONIC DACRYOCYSTITIS	124
13	RETINOBLASTOMA	133

Group Head Coordinator of Development Team

Dr. Venkatesh Prajna

Chief- Dept of Medical Education,

Aravind Eye Hospitals, Madurai

NAME OF CONDITION: REFRACTIVE ERRORS

I. WHEN TO SUSPECT/ RECOGNIZE?

a) Introduction:

An easily detectable and correctable condition like refractive errors still remains a significant cause of avoidable visual disability in our world. A child, whose refractive error is corrected by a simple pair of spectacles, stands to benefit much more than an operated patient of senile cataract – in terms of years of good vision enjoyed and in terms of overall personality development. In developing countries, like India, it is estimated to be the second largest cause of treatable blindness, next only to cataract. Measurement of the refractive error is just one part of the whole issue. The most important issue however would be to see whether a remedial measure is being made available to the patient in an affordable and accessible manner, so that the disability is corrected. Because of the increasing realization of the enormous need for helping patients with refractive error worldwide, this condition has been considered one of the priorities of the recently launched global initiative for the elimination of avoidable blindness: VISION 2020 – The Right to Sight.

b) Case definition:

- i. **Myopia** or Short sightedness or near sightedness
- ii. **Hypermetropia** or Long sightedness or Far sightedness
- iii. **Astigmatism**

These errors happen because of the following factors:

- a. **Abnormality in the size of the eyeball** – The length of the eyeball is too long in myopia and too short in hypermetropia.
- b. **Abnormality in the curvature of the cornea** – The curvature of the cornea is too steep in myopia and too flat in hypermetropia. In addition, irregularity of the corneal surface may give rise to astigmatism.
- c. **Abnormality in the refractive index** – Light passes through the major refracting surfaces like the cornea and lens, before impinging on the retina. A high refractive index may cause myopia, while a low refractive index may cause hypermetropia.

Of all these factors, the abnormality of the size of the eyeball is most common in producing refractive errors.

Myopia

Myopia is a form of refractive error, wherein parallel rays of light come to a focus in front of the retina, when the eye is at rest.

It is the commonest cause of refractive error and usually detected in the younger age group.

It consists of two main types:

Simple myopia: is just a variant of the normal and is not a major problem. Apart from the refractive error, no anatomical or functional complications of the ocular structures occur. The progression of myopia, more commonly happens during the growing phase of one's life. The maximum growth happens between the ages of 12 and 20 years. Frequent change of glasses maybe required during these years and the myopic error usually stabilizes after the age of 20. Hence permanent surgical procedures like laser surgery have to be performed only after documented stabilization of the myopia.

Pathological (or progressive) myopia: also called as degenerative myopia, as the name suggests is of a more serious nature a type of severe, progressive nearsightedness characterized by changes in the fundus of the eye, posterior staphyloma, and deficient corrected acuity. Refractive error is greater than -8.00 diopters, and axial length is greater than 32.5 mm. In pathological myopia the retina becomes very thin and is stretched at the periphery. The peripheral retina is at risk of developing tears or holes.

Hypermetropia

Hypermetropia is a form of refractive error, wherein parallel rays of light come to a focus behind the retina, when the eye is at rest.

In this condition, the person is unable to see near objects well. The eye tries to focus the images by increasing the refractive index of the lens (by making it thicker) - the process is called Accommodation.

Astigmatism

In this condition the eye is unable to form a point focus of light upon the retina. Instead of a single focal point of the image being formed, there are two foci that are separated by a distance. Hence the person is unable to see an image clearly in one meridian when he is focusing on another meridian.

- In regular astigmatism, the refractive power varies successively from one meridian to the next, and each meridian has a uniform curvature at every point across the entrance pupil. The meridians of greatest and least power, the so-called principal meridians, are always located at meridians 90 degrees apart.
- In irregular astigmatism, which can be clinically significant in conditions such as keratoconus and other corneal ectasias; corneal basement membrane and stromal dystrophies; corneal scarring; and post-surgical corneas (e.g., following penetrating

keratoplasty, radial keratotomy (RK), complicated refractive surgery), the magnitude and the axis of astigmatism vary from point to point across the entrance pupil.

In addition to these refractive errors, there is another condition called as presbyopia which occurs in all people, usually above the age of 40 years.

Presbyopia

In this condition, the eye is unable to focus near objects. The problem in presbyopia is the aging of the lens and the accommodating system, which fail to focus near objects on the retina. Although not truly a refractive error, presbyopia will be considered in this document because its correction has similarities to the correction of refractive errors.

II. INCIDENCE OF THE CONDITION IN OUR COUNTRY

With blindness defined as presenting distance visual acuity $<3/60$ in the better eye, the prevalence of blindness due to refractive error has been reported to be as high as 0.2% in India, for all age groups in the population considered together. A recent survey shows an increase in the incidence of refractive errors as a cause of social blindness from 12% to 15%, whereas the burden of cataract has actually decreased from 80% to 62% (Source: National Survey of Blindness 1986-89 and 2001-02).

III. DIFFERENTIAL DIAGNOSIS:

Patients with refractive errors often complain of defective vision, tiredness of eyes and headache. Even though refractive errors is the most common causative factor for defective vision, other organic causes such as the following should be examined and ruled out by a comprehensive eye examination.

- i. Cataract
- ii. Retinal disorders
- iii. Optic nerve pathology
- iv. Glaucoma
- v. Other media opacities

It should be once again emphasized that estimation of refractive errors should be a part of a complete ophthalmic evaluation. In addition, other causes of headache like sinusitis or migraine should be suspected especially when there are complaints of recurrent headache in the setting of a normal refractive status.

IV. PREVENTION AND COUNSELING

For all practical purposes, there are no strategies which are effective in preventing this condition from occurring. However, counseling on the importance and compliance to treatment optimizes visual performance and prevents further deterioration of the functioning of the eye. Most myopic refractive errors develop and progress during childhood and adolescence, which corresponds to their general physical development. The

importance of school teachers in suspecting this condition cannot be over emphasized. They can be trained for screening of this condition and experience has shown that this system is very useful to identify children who need ophthalmic care and support at the school going level. The positive effect of outdoor activity for reducing myopic progression has been documented in numerous studies. Physical activity, sports, and low accommodative demands have been postulated as the cause of this protective effect.

V. OPTIMAL DIAGNOSTIC CRITERIA, INVESTIGATIONS, TREATMENT & REFERRAL CRITERIA

Situation 1: At Secondary Hospital/ Non-Metro situation: Optimal Standards of Treatment in Situations where technology and resources are limited

a) Clinical Diagnosis:

A proper history taking remains a cornerstone of the diagnosis of this condition. A child with uncorrected refractive error is restricted to the limits of its vision. Those who are not so eloquent with their complaints would tend to read their books very close to their face and sit closer to the black board or the television. The frustrated child becomes an introvert, keeping away from other children of his age and avoids outdoor activities.

The myope's main complaint is that he /she don't see distant objects clearly. The defect may also manifest as headache, watering from eyes and constant itching of the eyes – all these symptoms are a result of the eyestrain induced by the refractive error. Conditions like pathological myopia, if not diagnosed early and followed up regularly can result in permanent loss of vision due to retinal scarring or retinal detachment. The progression of myopia happens more often in the growing phase of a person's life. The maximum growth happens between the ages of 12 and 20. Frequent changes of spectacles may be required during these years, and the myopic error usually stabilizes after the age of 20.

The hypermetropes complain that they are unable to do near work very well. Headache and eyestrain following any prolonged near work like desk jobs or sewing can be accompanying symptoms. These symptoms are collectively termed asthenopia. Although hypermetropia can be detected at any age, it generally manifests more with increasing age. Presbyopes are usually people in their fourth decade, who find it increasingly difficult to read the newspaper at their usual working distance in dim light and tend to keep it at a distance to make out the letters. Simple tasks like threading a needle, putting one's signature on a document or making out the fine print on a visiting card become increasingly difficult and sometimes embarrassing. For artists and artisans who depend on their near vision for livelihood, it can even become economically crippling. Headaches and eye – strain may occur after long hours of near work. The uncorrected disability hampers his/her financial productivity and compromises their occupational skills. Left uncorrected, he/she

loses interest in performing near work like reading and writing leading to a compromise in quality of life.

The evaluation of refractive errors requires an assessment of both the refractive status of the eye, the patient's current mode of correction, symptoms, and visual needs. As emphasized repeatedly, refraction is often performed in conjunction with a comprehensive ophthalmic evaluation. A thorough history with a special focus on the vocational needs of the patient should be asked for and kept in mind before finalizing the prescription. The examination should include both undilated and dilated evaluations. While pupillary reactions, ocular alignment and movements, visual field evaluation (in indicated cases) and dynamic refraction can be performed on a reactive pupil, posterior segment evaluation and cycloplegic retinoscopy and refraction can be done after dilating the pupil.

b) Investigations:

1. Visual acuity testing

Distance visual acuity is usually measured in a dimly lit room as the patient looks at a chart of high-contrast characters. It should be measured separately for each eye with current correction. For clinical purposes it is desirable that test chart luminance not be less than 80 cd/m². It is desirable that the luminance level employed be specifiable. visual acuity testing conditions should be standardized in each examination room and at each visit, so that the same viewing distance and lighting conditions are used. Near acuity is usually measured while the patient looks at a well-lit reading card of high-contrast characters held at a specified near working distance, typically 14 inches or 30 cm

Nonverbal child (upto 1 year)

Estimating visual acuity in a non verbal child is a challenge. It should comprise of assessing the following parameters.

1. The assessment for this age involves evaluation of ocular fixation and following to appropriate visual stimuli: for an infant under 4 months of age, the examiner's face or the parent's face is used as a target. For older infants, appropriate toys can be used to induce fixation. Attempts should be made to assess the quality of the fixation response (central, eccentric, steady, unsteady, maintained) to the targets used. Even a subtle difference in the ocular fixation response of an infant with an otherwise normal eye examination requires monitoring to evaluate the presence or development of amblyopia.
2. Ability to fixate a light held at 33cm.is assessed
3. Blink reflex in response to sound is observed.

Verbal but preliterate child (1 to 5 year)

Preschool going children can be assessed by either of the following methods.

1. Ability to locate small objects (cake decorations).
2. Marble game test; in which child is asked to place marbles in holes of a card.
3. Illiterate E-card test.
4. Sheridan Gardiner (S-G) test.

Literate child (>5 year) and adults

These patients can be checked using a regular Snellen's visual acuity chart. In illiterate people, Landolt C chart or a tumbling E chart may be used. Near vision testing can be performed using a Jaeger chart.

2. Refraction:

Each eye should be evaluated independently. A dynamic refraction is done first for all adults followed by a cycloplegic refraction if necessary. Presbyopic correction is determined before applying dialating drops. All children, below the age of 15 years should be refracted only after applying cycloplegics to neutralize the effects of accommodation, to identify accommodative spasm and to diagnose strabismus of accommodative aetiology. An objective retinoscope followed by a subjective refinement of refraction is preferred. Distance refraction should be performed with accommodation relaxed using manifest (noncycloplegic) refraction with fogging or other techniques to minimize accommodation with care not to provide excess minus power correction to the patient. The common dialating agents are tropicamide and cyclopentolate. Tropicamide provides a more rapid onset of action and a shorter duration of effect while cyclopentolate provides greater cycloplegia that can allow a more accurate refraction but a longer duration of effect. A significant difference between manifest and cycloplegic refraction is frequent in children; In adults, a substantial difference between manifest and cycloplegic refraction may require a post-cycloplegic dynamic refraction on a subsequent day where the cycloplegic refraction is used to guide the final manifest prescription. The post-cycloplegic refraction is performed when full accommodation has returned.

3. Measurement of interpupillary distance (IPD) to determine the distance in millimeters between the centre of the pupils of the two eyes for a given viewing distance with a ruler. IPD is to be measured for both distance and near.

4. Determination of vertex distance and precise astigmatic axis is especially important in patients with high refractive errors.

5. Determination of Muscle Balance

This is done for people complaining of asthenopic symptoms

C) Treatment:

Spectacle Correction:

- 1. Myopia:** Full correction can be given to patients who are having visually demanding activities so that they can have a good distance vision. Over correcting myopic patients will cause excessive accommodation, which may create symptoms. Some patients may become symptomatic from increasing myopia at low levels of illumination. These patients may require increased correction for clear vision at night.
- 2. Hypermetropia:** Slight under correction may be desirable in young and middle aged hypermetropes because there is some physiological accommodative tone. With the onset of presbyopia as the patient ages, full correction may be necessary to minimize difficulties with near vision.
- 3. Astigmatism:** Full correction may not be needed for individuals with regular astigmatism. Adults with astigmatism may not accept full cylindrical correction in their first pair of spectacles, or in subsequent spectacles if their astigmatism has been only partially corrected or its oblique axis astigmatism.
- 4. Presbyopia:** In presbyopic patients, accommodative amplitudes are measured to determine if the available accommodation is sufficient for the near task. It is suggested that half of the accommodative amplitude be held in reserve for comfort. Individuals with myopia must exert more accommodative effort when using contact lenses, or after refractive surgery, than when using eyeglasses. Individuals with hyperopia must exert more accommodative effort when using eyeglasses than contact lenses.

A brief note of the basics of spectacle fitting is given below:

Frames

The types of frames can be broadly classified into Metal and Plastic Frames.

Metal Frames

Alloys of varying constituents and consistencies are used to make frames. The most commonly used Nickel alloys, are cheap, strong and are tensile but may cause allergic reactions in the skin and so are not advisable. Stainless steel is a good alternative as it is inert, less allergenic and lightweight at the same time. Aluminium is lightweight but soft, and is less allergenic. Metals such as Titanium are also becoming popular, as it is very strong but lightweight.. The color and protective coatings given to the frame are just as important as the base material. Electroplating is a sturdy and reliable way to coat the frames. Cheaper frames are usually dipped or spray-painted – these coats usually peel off fast and may not be uniform. Powder coats on frames have a longer life as the coat is fused with the base metal. A final protective lacquer coat on top of the colour coat adds lustre and binds the color coat to the frame.

Plastic Frames

Most 'plastic' frames are actually all natural. The common constituent of this frame is Cellulose acetate, which is derived from treated wood pulp. These are sometimes called "shell" frames since the tortoise shell was initially used to make frames and later bone and animal horns were also used. Though this practice no longer exists, the name has remained.

All these shell frames are less allergenic, flexible and elastic – so they last longer. However, low-grade plastic frames which are more thermosetting (become rigid with heating) tend to become brittle and cannot be reused. Thermoplastic frames on the other hand become pliable on heating and can be reused when one wants a change of lenses.

Rimless Frame

These frames are actually disjointed three parts of a frame – the two temples of the frame and the nose bridge. These are then attached to the lenses and held in place by screws.

These are available in both metal and shell frames. The advantage here is that the lens shape can be free form. However, these must be handled carefully as the lenses have no protection.

Half-Rimless Frames

These frames appear to have the frame rim running only along one side of the frame, but if at a closer look one can see a clear nylon wire running along a groove holding the lens in place. These are quite fashionable and are more reliable than rimless frames.

Lenses

Once the frame is chosen the lenses need to be selected. Lenses are available in three basic materials:

Glass Lenses

Traditionally lenses were made out of glass. These had very high clarity and were easy to produce and fit into frames. Alternatives for lens materials were sought because glass was heavy and broke easily. This was a cause for concern where wearers had an active lifestyle.

Plastic Lenses

Lenses made of plastic are lightweight and do not break easily. However, as plastic is softer than glass, it tends to scratch easily. But today with the developments of high quality scratch resistant coatings plastic is fast replacing glass in the market. Plastic lenses weight only 40% as much as glass and are especially suitable for an active lifestyle or a high refractive error. It is especially safe for children, as it does not shatter like glass lenses.

Polycarbonate Lenses

These are called "bulletproof" lenses and for good reason too. They are impact resistant, that makes them long lasting and lightweight. They have a very high refractive index, which means that these lenses are very thin even for very high powers. Polycarbonates are usually used for sports eyewear. But their lightweight, longevity combined with a good scratch resistant coating make them one of the best choices.

Hi Index Lenses

For a high myope heavy, thick ringed lenses make their eyes seem small and unsightly. An excellent alternative are hi-index lenses that give the same refractive power at half the thickness of the normal glass lens. These are available in both plastic and glass lenses.

Lenses admit most of the light through them – but some of the incident rays are reflected off the surface of the lens. This causes glare, which is disturbing when driving in the night with glasses on or while using the computer.

Anti-Reflection Coatings (or ARC) that is applied onto the lens ensures that the lens admits up to 99% of the light. This not only gives clearer vision to the wearer, it is a cosmetically better choice as the ugly reflections on the lens surface are avoided and the eyes are visible to the onlooker.

Correction for Presbyopia

Presbyopes require glasses called **bifocal** lenses (two focal lengths); their main disadvantages being discomfort if line of sight falls at the division in the lens; and being able to see clearly only at two focal lengths.

To help them focus at all distances new lenses have been designed called '**varifocals**'. These are designed by increasing the focal power gradually (so also called **Progressive Addition Lenses**). They eliminate the discomfort caused by segments in the lenses and improve the quality of vision.

Safety Lenses

These are special eyewear systems designed for protecting the eye from excessive heat, dust, light, harmful rays, or impact. This eyewear is suitable for people working in extremes of environment like welders, bikers, those living in extremes of weather, those handling harmful chemicals etc.

Polarized lenses have long been known and proven to enhance visibility and reduce glare under all conditions. The lenses provide a sharper vision under any environmental condition. Polarized lenses are the only lenses that provide visibility below the surface of the water in a marine environment. A polarized lens filters and eliminates annoying glare and transmits only efficient light to the eye. Wherever there are horizontal surfaces producing glare, the use of polarizing lenses is recommended because it reduces eye fatigue and maintains the health of your eyes while exposed to the sun.

Ultra Violet Protection

UV Filter capacity of a lens is measured and certified. Lenses marked UV400 mean that they block 100% of UVA & UVB. As a result, your eyes are not subjected to any harmful rays. All sunglasses offer UV protection to some extent but not 100%. Exposure to UV rays accelerates development of cataract, degeneration of cornea and retina. It can also cause tumors of the eyelid.

Standard Operating procedure

a. Inpatient

Not applicable

b. Out Patient: All patients are treated as outpatients.

c. Day care

Not applicable

d) Referral criteria:

The following patients can be referred to a higher centre for the following reasons:

- Pathological Myopia
- Refractive Error with associated Strabismus
- Visual Acuity not improving with glasses
- Oblique Astigmatism
- Sudden refractive change
- Amblyopia

Those patients who desire contact lenses and refractive surgeries

***Situation 2: At Super Specialty Facility in Metro location where higher-end technology is available**

a) Clinical Diagnosis:

Apart from the regular history and examinations, measured above, special emphasis on evaluating the visual expectations should be performed on patients seeking refractive surgery.

b) Investigations:

While regular patients seeking spectacle correction go through the same investigations mentioned above, patients with special needs such as contact lenses and laser refractive surgeries have to undergo special procedures. The refraction may be done objectively by retinoscopy, with an autorefractor, or with a wavefront analyzer; or it may be done subjectively. In cooperative patients, subjective refinement of refraction using a phorometer or trial lens set is preferred

c) Treatment:

Contact Lenses:

An attractive alternative to spectacles for correcting refractive errors, contact lenses are also used for various therapeutic, pharmacological and cosmetic procedures. Modern contact lenses are polymers which are relatively safe, non-toxic and non-allergic. Since the cornea derives its oxygen supply mainly from the atmosphere, placing a lens on its surface can compromise its intake starving the cornea of oxygen. Newer lenses however, allow oxygen to pass through them to the cornea.

There are basically three types of contact lenses:

Soft contact lens: These are well flexible lenses made of a polymer called HEMA (Hydroxy Ethyl Metha Acrylate). They are very comfortable to wear and permit oxygen to reach the cornea.

Semi soft lenses or Rigid Gas Permeable Lenses: These lenses are made from special materials like Cellulose or Silicon acrylate. They are less flexible than soft contact lenses but allow some oxygen to pass through the cornea. Though less comfortable than soft lenses, they can be used to correct steep corneas and high astigmatism.

Hard contact lenses: Made of a polymer called PMMA (Poly Methyl Metha Acrylate), hard lenses are least flexible and permit almost no oxygen to pass through to the cornea. The advantage of a hard contact lens is its durability.

Advantages of a contact lens:

- A contact lens provides a larger field of vision than spectacles and a better range of mobility. Hence it is ideally suited for sportspersons and people engaged in outdoor physical activities.
- In people with high refractive error in one eye alone, spectacles will produce double vision due to the image size discrepancy. Contact lenses can be used for such people.
- Cosmetically, they offer an advantage over spectacles.
- Apart from correcting refractive errors, contact lenses are also used to deliver drugs to the eyes and to treat corneal diseases.
- Nowadays contact lenses are also available in various colors and can be used by people even with normal vision for the cosmetic appeal.

Precautions

With all these advantages, there are also some precautions to be taken before opting for contact lenses.

- An ophthalmologist should examine the eyes to rule out infections and other disorders of the eye.
- A qualified contact lens specialist alone should do the contact lens fitting. This includes measuring the corneal curvature and diameter and issuing a suitable pair of contact lens. After wearing them, the specialist examines the eyes for a good, comfortable fit on the eyes.
- Hand washing with soap before inserting and removing the contact lens from the eye is mandatory.
- Proper maintenance of the contact lens by cleansing it with the appropriate lens fluid is necessary.
- If the eyes are red or there is a white discharge from the eyes, the contact lens should not be used and the eye care professional should be contacted for further instructions.

- One should not sleep overnight with the regular daily wear contact lens on. The oxygen supply to the cornea is totally cut off during sleep by the contact lens. The oxygen deprived cornea is liable to damage and ulceration.
- The eyes should be periodically examined by an eye care professional to look for any infections or corneal damage, possible due to contact lens wear.

The latest innovation in the field is extended wear contact lenses which can be used over a longer period of time. Wearing of contact lenses during waking and sleeping hours, i.e., continuous 24 hour wear for a specified number of days. NOTE: The FDA recommends no longer than six (6) consecutive nights wear for traditional extended-wear lenses. These lenses allow free passage of oxygen through them to the cornea, but even they must be used with care.

Refractive Surgery for Myopia, Astigmatism and Hyperopia

Refractive surgery may be considered when a patient wishes to be less dependent on eyeglasses or contact lenses, or when there are occupational or cosmetic reasons not to wear eyeglasses.

Patient expectation will be the main pillar around which all the other structures of the preoperative examinations should be built. The motives for desiring refractive surgery should be carefully discussed with the patient by the surgeon. Individuals who expect only 6/6 and nothing less should be discouraged from having refractive surgery, while patients motivated by a desire to reduce their dependence on glasses or contact lenses, will be good candidates.

Keratorefractive surgery can be applied to a broad range of refractive errors, but in some circumstances, the surgeon may consider an intraocular procedure like the placement of an intraocular lens (IOL) implant, either in front of the crystalline lens (phakic IOL) or in place of the crystalline lens (refractive lens exchange).

Preoperative evaluation

1. Patients to discontinue contact lenses at least 1 week before surgery because of the possibility of contact lens induced corneal warpage. Toric soft contact lenses and rigid contact lenses should be discontinued for a longer period (atleast 2 weeks) because they are associated with a greater potential for corneal warpage and refractive instability.
2. Visual acuity without correction
3. Manifest, and where appropriate, cycloplegic refraction: The stability of the refraction should be well documented. If the patient is seen for the first time, it may be prudent to ask for his previous refraction powers and compare with the present
4. Detailed anterior and posterior segment evaluation: A thorough anterior segment evaluation before and after pupillary dilation is crucial. Potential anatomical problems like a prominent brow, narrow palpebral fissure and peripheral vascular pannus should be looked for, since these may pose problems during microkeratome operation. As the

cornea is evaluated, close attention should be paid to any anterior membrane dystrophy, stromal scarring or vascularization that may influence the type of surgery or whether it should be done at all. Any variation in stromal thickness, as in pellucid or Terrien's degeneration, keratoconus or stromal dystrophies should alert the surgeon to reconsider performing a refractive procedure. The crystalline lens should be examined in detail after full dilatation, especially in patients above the age of 40 years. A progressive myopia, during middle age should alert the clinician about the early stage of immature cataract. In case of doubt, an axial length measurement can be estimated and if there is any discrepancy, further testing can then be ordered. A baseline intraocular pressure measurement, like the preoperative keratometry reading, serves as an useful adjuvant, since post lasik intraocular pressure measurement using Goldman's applanation tonometry is less than accurate.

A detailed indirect ophthalmoscopic evaluation with and without indentation should be an integral component of the whole screening processes. Lattices with multiple holes and horse shoe tears can be subjected to barrage laser and laser surgery can be performed after a period of 1 month. Round atrophic holes and simple lattice degenerations need not be treated as a routine. Even as there is no proof of increased occurrence of retinal detachment following refractive surgery, it will be prudent to treat any predisposing condition first.

5. Evaluation of tear film: The level of tear meniscus and the quality of the tear film should be assessed before any instrument touches the eye. Although mild dryness due to intolerance of contact lens wear may be an indication for refractive surgery, more significant dryness may pose a threat to successful epithelial healing.
6. Evaluation of ocular motility and alignment
7. Topography: for evidence of irregular astigmatism, corneal warpage, or abnormalities suggestive of keratoconus or other corneal ectasias, because all may be associated with unpredictable refractive outcomes and latter with progressive ectasia following surgery. The detection of the posterior corneal elevation adds an extra safety dimension before Lasik procedure.
8. Pachymetry: To identify unusually thin corneas and estimate residual stromal bed thickness. Corneas with central corneal thickness values less than 500 μm should be considered potentially abnormal.

Excimer Laser Systems

Laser assisted in situ keratomileusis (LASIK) is the most commonly performed refractive surgery worldwide. Good visual results, quick rehabilitation and negligible complication rates have been the main reasons for the widespread acceptance rate of this procedure. Technological advancements have brought in many evolutions from the initial era of broad beam lasers to the more recent ones using flying spot technology. These refinements have helped the new generation lasers to have more accurate predictability than the earlier

ones. A recent addition in this field is the area of customized correction, by lasers using wave front technology. Even though the customized correction procedures are becoming popular by the day, controversies still surround many of its presumed theoretical advantages. Since conventional LASIK surgery by itself is a highly accurate procedure, it becomes all the more difficult to establish the superiority of the customized correction over the conventional one.

Conventional

By varying the ablation pattern, the excimer laser can alter the anterior corneal curvature to modify a particular refractive error described by sphere and cylinder. The laser delivery methods currently being utilized to achieve the ablation pattern are broad beam, scanning slit, or flying spot systems. Eye-tracking technology is integrated into the current commercially available excimer laser systems and permits the ablation to remain centered on the pupil in the presence of small ocular movements.

Potential advantages of customized treatment

Wave front based aberrometry has certain theoretical advantages, the notable one being the evaluation of whole eye optics. In certain instances, visual symptoms can be correlated with certain higher order aberrations. However the measurements of these aberrations are not reproducible. For example, it has been shown that Postoperative wavefront aberrations do not always correlate with contrast sensitivity measurements. The magnitude of higher order aberrations have been documented to increase with increasing pupillary size. Hence there is a theoretical beneficial effect of correcting higher order aberrations in people with large pupils, who have to work mainly in dim light conditions.

Potential disadvantages of customized treatment

- 1. All aberrations are not treated:** The aberrometer generates a lot of data from a human eye. Not all of these are treatable using customized LASIK procedure. In fact, customized LASIK has been demonstrated to induce additional higher order aberrations as well. This again brings us to the notion that the significance of these aberrations is still not well understood at this point of time and further refinements are yet to be done in this field.
- 2. All aberrations are not reproducible:** The aberrations generated from a human eye are not reproducible and this is one of the major draw backs. Daily fluctuations in wave front aberrations have been noted in several studies and are attributed to accommodation, tone of the pupil and tear film distribution.
- 3. Wave front changes with age:** The wave front measurements of the eye alter with age, because of changes that occur in the lens and cornea with age. Hence even if one performs customized corneal ablation, it will be interesting to watch whether these changes would be permanent.
- 4. Pupillary size:** Pupillary alterations happen almost on a continuing basis in our day to day routine. The output of the wave front images changes with minute changes in the

papillary size. If this be the case, it is interesting to speculate whether the treated area corrects the aberrations, over the entire spectrum of papillary dilatation and constriction, which happens during our day to day activities.

5. **Limitation of the retina:** Even if we correct all the aberrations of the eye, there is a biological limitation of the retina to see beyond approximately 6/3 vision. It is not clear whether the neural retina will be able to interpret the improved image.
6. **Depth of field:** Removing the eye's higher order aberrations increases optical quality for objects that lie at the best focus. However, it reduces optical quality for objects that are far out of best focus. Exactly how this benefits and cost tradeoff functions in everyday vision has not yet been carefully studied.
7. **Change in posture:** It has to be understood that the wave front measurements are taken with the patient in a sitting position, while the treatment is performed in a patient in a supine position. Since the wave front changes with these postural alterations, this factor needs to be studied in detail.

Contraindications

- Unstable refraction
- Certain abnormalities of the cornea (e.g., keratoconus or other corneal ectasias, thinning, edema, interstitial or neurotrophic keratitis, extensive vascularization)
- Insufficient corneal thickness for the proposed ablation depth
- Visually significant cataract
- Uncontrolled glaucoma
- Uncontrolled external disease (e.g., blepharitis, dry eye syndrome, atopy/allergy)
- Uncontrolled connective tissue or autoimmune disease
- Unrealistic patient expectations

Relative Contraindications

- Functional monocularity
- Ocular conditions that limit visual function
- Excessively steep or flat corneas
- Abnormal corneal topography suggestive of forme fruste of keratoconus, keratoconus, or other corneal ectasias
- Significant irregular astigmatism
- Corneal stromal or endothelial dystrophies
- History of herpes simplex virus (HSV) or varicella zoster virus (VZV) keratitis
- Significant dry eye syndrome
- Prior incisional or lamellar keratorefractive surgery
- Glaucoma
- Diabetes mellitus
- Pregnancy or lactation
- Connective tissue or autoimmune diseases

- Certain systemic medications (e.g., isotretinoin, amiodarone, sumatriptan, levonorgestrel implants, colchicine)
- Under 21 years of age (FDA labeling should be consulted for each laser)

Surface Ablation Techniques

Photorefractive Keratectomy

In PRK, the central corneal epithelium is removed and the excimer laser is used to ablate Bowman's membrane and superficial corneal stroma over the entrance pupil.

Laser Epithelial Keratomileusis and Epi-LASIK

Laser epithelial keratomileusis (LASEK) is a modification of PRK that attempts to preserve the epithelium. After alcohol is applied to the corneal epithelium, an epithelial trephine and spatula are used sequentially to score, loosen, and roll up the epithelium, which remains attached at a nasal or superior hinge. Photoablation is then performed, and the epithelium is unrolled back over the central corneal stroma. A bandage contact lens is used for several days until the surface re-epithelializes.

An alternative surface ablation procedure to LASEK is epi-LASIK. Instead of using alcohol to loosen the epithelium, an epikeratome is used to dissect an epithelial sheet from Bowman's membrane. The epikeratome is similar in design to a mechanical microkeratome used for LASIK. Instead of using an oscillating sharp blade to incise the cornea beneath Bowman's membrane, the epikeratome uses a blunt oscillating separator that moves across the cornea held under high pressure with a suction ring. This separator lifts a sheet of epithelium from Bowman's membrane. The laser ablation is then performed and the epithelial sheet is either replaced or discarded. Visual recovery and discomfort with LASEK and epi-LASIK are similar to PRK and are prolonged relative to LASIK.

Alternatives for patients who are Lasik Rejects:

For eyes with THIN CORNEA

- PRK / LASEK / EPI-LASIK
- SBK (Sub Bowman's Keratomileusis)
- Intra corneal Rings
- Phakic IOL (ICL)

For eyes with ABNORMAL SHAPE

- Intra corneal Rings (INTACS, Kera rings)
- Phakic IOL

Phakic IOLs

Phakic IOLs fall into three broad categories:

- Anterior chamber angle-fixated lenses, originally introduced by Baikoff and Joly
- Anterior chamber iris-fixated lens, introduced by Fechner and Worst

- Posterior chamber sulcus- fixated lens introduced by Fyodorov and subsequently modified by other companies.

Indications for phakic IOLs:

- Correction of myopic errors of -8.00 D or more.
- In eyes contraindicated for LASIK:
 - Relatively thin corneas,
 - Stable keratoconus;
 - Corneas steeper than 48.00 D or with expected post-LASIK keratometry readings flatter than 35.00 D.
 - in eyes with **residual refractive errors** after LASIK, corneal transplant, intrastromal corneal ring segment (ICRS) implantation, corneal collagen crosslinking (CXL), and pseudophakia.

Contraindications:

- Unstable refraction
- Visually significant cataract in the case of phakic IOLs
- Corneal endothelial disease, including Fuchs dystrophy
- Uncontrolled glaucoma
- Uncontrolled external disease
- Uncontrolled connective tissue or autoimmune disease
- Unrealistic patient expectations

Standard operating procedure

- a. **In patient:** Not applicable
- b. **Out Patient:** Not applicable
- c. **Day care:** Refractive surgeries are done as day care procedures.

d) Referral criteria:

Not applicable

VI. WHO DOES WHAT? And TIMELINES

a. Doctor

1. History taking with examination of the patient
2. To carry out the necessary investigations
3. To satisfy the patient as per his/her needs

b. Technician/Nurse

Role of Ophthalmic Assistants is to

1. Test vision, conduct refraction and prescribe corrective lenses.

2. Assist medical officers in providing primary care including treatment for trachoma, ocular injuries, and conjunctivitis etc.
3. Assist in conducting eye camps at the primary health centre.
4. Help in organizing vision-screening programmes in schools.
5. Carry out eye health education activities.
6. Maintain the dark room and ophthalmic equipment in primary health centre.

VII. FURTHER READING / REFERENCES

1. Caster AI, Hoff JL, Ruiz R. Conventional vs wavefront-guided LASIK using the LADARVision4000 excimer laser [Internet]. *Journal of Refractive Surgery* (Thorofare, N.J.: 1995). 2005 ;21(6):S786-791. Available from: <http://www.ncbi.nlm.nih.gov/pubmed/16329381>
2. Frick KD, Riva-Clement L, Shankar MB. Screening for refractive error and fitting with spectacles in rural and urban India: cost-effectiveness [Internet]. *Ophthalmic Epidemiology*. 2009 ;16(6):378-387. Available from: <http://www.ncbi.nlm.nih.gov/pubmed/19995203>
3. Jose R, Sachdeva S. School eye screening and the National Program for Control of Blindness [Internet]. *Indian Pediatrics*. 2009 ;46(3):205-208. Available from: <http://www.ncbi.nlm.nih.gov/pubmed/19346567>
4. Limburg H, Kansara HT, d'Souza S. Results of school eye screening of 5.4 million children in India--a five-year follow-up study [Internet]. *Acta Ophthalmologica Scandinavica*. 1999 ;77(3):310-314. Available from: <http://www.ncbi.nlm.nih.gov/pubmed/10406152>
5. McLeod SD, Chuck RS, Hamilton DR, Katz JA, Rutzen AR, Vukich JA, et al. Prepared by the American Academy of Ophthalmology Refractive Management/Intervention Panel Refractive Management/Intervention Panel Members. 2007 ;
6. Pararajasegaram R. VISION 2020-the right to sight: from strategies to action [Internet]. *American Journal of Ophthalmology*. 1999 ;128(3):359-360. Available from: <http://www.ncbi.nlm.nih.gov/pubmed/10511033>
7. Shah S. LASIK--the Indian eye controversy [Internet]. *Indian Journal of Ophthalmology*. 2002 ;50(4):259-260. Available from: <http://www.ncbi.nlm.nih.gov/pubmed/12532489>
8. Contact lenses: Edited by James V. Aquavella, M. D., and Gullapalli N. Rao, M.D., with 15 contributors. Philadelphia: J.B. Lippincott Company, 1987. Pp. 278. \$42.50 [Internet]. Available from: [http://www.journals.elsevierhealth.com/periodicals/cev/article/0953-4431\(89\)90035-0/abstract](http://www.journals.elsevierhealth.com/periodicals/cev/article/0953-4431(89)90035-0/abstract)

RESOURCES REQUIRED

Situation	HUMAN RESOURCES	INVESTIGATIONS	DRUGS & CONSUMABLES	EQUIPMENT
1) Secondary level	1) Doctor 2) Nurse 3) Ophthalmic Assistant	1) Refraction 2) Kerotometry	1) Mydriatics and 2) Cycloplegics 3) Spectacle frames and lenses 4) Antibiotic and steroid eye drops	1) Retinoscope 2) Trial set 3) Indirect ophthalmic with 20D lens 4) Slit Lamp Biomicroscope with 5) Visual acuity charts 6) Keratometry
2) Tertiary level	1) Doctor (with a refractive surgeon) 2) Nurse - 1 3) Ophthalmic Assistant - 1 4) OT Nurse - 1	1) Refraction 2) Kertometry 3) Pachymetry 4) Topography	1) Mydriatics and 2) Cycloplegics- 3) Spectacle frames and lenses 4) Antibiotic and steroid eye drops 5) Phakic IOL INTACS	1) Retinoscope 2) Trial set 3) Autorefractometer 4) Slit Lamp Biomicroscope 5) Keratometer 6) Pachymeter 7) Topography 8) Indirect ophthalmic with 20D lens 9) Operating microscope 10) Visual acuity charts 11) Laser equipment

NAME OF CONDITION: STRABISMUS AND AMBLYOPIA

I. WHEN TO SUSPECT/ RECOGNIZE?

a) Introduction:

Strabismus or amblyopia or both together may lead to failure to develop binocular vision which may prevent individual pursuing specific occupations. The associated cosmetic disorder may interfere with social and psychological development with potentially serious effects on individuals. Timely diagnosis and appropriate treatment of children with strabismus and/or amblyopia is likely to reduce the prevalence of persistent amblyopia and ocular misalignment in adults.

Rarely, strabismus and/or amblyopia may be the presenting symptom in children with a serious eye disease or systemic condition (e.g. retinoblastoma or hydrocephalus) when urgent referral to a specialist may be necessary. Amblyopia is the most common visual disability in children. It can present as early as 3 months of age. Its progression and reversibility both are inversely proportional to child's age. It is commonly unilateral. Nearly all amblyopic visual loss is preventable or reversible with timely detection and appropriate intervention.

b) Case definition:

Strabismus is a misalignment of the eyes in which the visual axes deviate from bifoveal fixation.

Amblyopia is a unilateral or, less commonly, bilateral reduction of best-corrected visual acuity that cannot only and directly be attributed to the effect of a structural abnormality of the eye or the visual pathways.

For practical purposes, amblyopia is defined as at least 2 Snellen lines difference in visual acuity between the eyes, but amblyopia is truly a spectrum of visual loss, ranging from missing a few letters on the 6/6 (20/20) line to hand motion vision. It is a diagnosis of exclusion. Amblyopia is caused by abnormal visual experience early in life resulting from one of the following:

- Strabismus
- Anisometropia or high bilateral refractive errors (isometropia)
- Visual deprivation

With timely intervention, the reduction in visual acuity caused by amblyopia can be completely or partially reversed.

II. INCIDENCE OF THE CONDITION IN OUR COUNTRY

There are not many reports available from India about the prevalence of strabismus. One population based study from South India reported the prevalence as 0.43% among children. Another study in North India among school children reported it as 2.5%. The presence of strabismus is not a cosmetic issue only. Its presence says that the child is unable to use both eyes together and there could be some other ocular problem that is undetected.

Different studies from developed countries on amblyopia have an estimated prevalence in childhood of 1.2% to 4.4% depending on the defining criteria.

III. DIFFERENTIAL DIAGNOSIS

Strabismus

- Pseudostrabismus
- Nystagmus
- Facial asymmetry

Amblyopia

- Nutritional/Toxic optic neuropathy
- Malingering
- Cortical blindness

IV. PREVENTION AND COUNSELING

Recent studies have shown that early detection and treatment of amblyopia are highly cost effective when compared with other interventions in health care. The earlier amblyopia is detected and properly treated, the higher the likelihood of visual acuity recovery. Starting treatment at a young age also may increase the likelihood of compliance and the rate of vision recovery. The Amblyopia Treatment Study demonstrated that more than 75% of amblyopic children younger than 7 years can have significant improvement in the amblyopic eye (to 20/30 or better) as the result of treatment. The purpose of periodic eye and vision screening is to detect pediatric eye disorders, especially amblyopia, at a sufficiently early age to allow effective treatment. All children should undergo eye and vision screening, because screening is most effective when performed periodically throughout childhood.

In addition, children with risk factors for amblyopia should have a comprehensive ophthalmic evaluation. Some risk factors include family history of amblyopia or strabismus, childhood cataract or glaucoma, premature birth of less than 30-week gestation or 1,500 grams, and delayed visual or neurologic maturation of unclear etiology. Reduction or prevention of risk factors such as premature birth and detrimental prenatal environmental

influences such as alcohol abuse and smoking can result in a decrease in the incidence of amblyopia.

V. OPTIMAL DIAGNOSTIC CRITERIA, INVESTIGATIONS, TREATMENT & REFERRAL CRITERIA

***Situation 1: At Secondary Hospital/ Non-Metro situation: Optimal Standards of Treatment in Situations where technology and resources are limited**

a) Clinical Diagnosis:

The initial strabismus and amblyopia evaluation (history and physical examination) includes all components of the comprehensive pediatric ophthalmic evaluation, with special attention to the potential risk factors for amblyopia, such as a positive family history for strabismus, amblyopia, or media opacity.

The examination of a patient who has childhood-onset strabismus includes all components of the comprehensive pediatric or adult ophthalmic evaluation in addition to the sensory, motor, refractive, and accommodative functions.

History

Although a thorough history generally includes the following items, the exact composition varies with the patient's particular problems and needs:

- The chief complaint and reason for the eye evaluation
- Current eye problems
- Ocular history, including prior eye problems, diseases, diagnoses, and treatments
Systemic history: birth weight, prenatal (e.g., alcohol, tobacco, and drug use during pregnancy), and perinatal history (e.g. birth asphyxia, trauma) that may be pertinent, past hospitalizations and operations, general health and development.
- Pertinent review of systems, including history of head trauma and relevant systemic diseases
- Current medications and allergies
- Family history of eye conditions and relevant systemic diseases
- Review of systems

Examination

The eye examination consists of an assessment of the physiological function and the anatomic status of the eye and visual system. Documentation of the child's level of cooperation with the examination can be useful in interpreting the results and in making comparisons among the examinations over time. In general, the examination may include the following elements:

- Assessment of visual acuity and fixation pattern
- Ocular alignment and motility for near and distance
Extraocular muscle function (ductions and versions including incomitance, such as A and V patterns)
- Detection of nystagmus
- Sensory testing
- Red reflex or binocular red reflex (Brückner) test
- Pupil examination
- External examination
- Anterior segment examination
- Cycloplegic retinoscopy/refraction
- Funduscopy examination
- Binocularity/stereoacuity testing

Assessment of Visual Acuity and Fixation Pattern

The method of evaluating visual acuity varies according to the child's age and level of cooperation. Preverbal children should be checked for objection to cover and the presence of a fixation preference. When possible, monocular distance visual acuity should be determined utilizing a recognized optotype, such as the tumbling-E, Lea figures, or Snellen letters.

Anomalous head posture is suggestive of peeking around the occluder. An occlusive patch over the non-tested eye can distinguish between peeking and possible eccentric fixation. Monocular visual acuity testing for patients with nystagmus may require blurring of the contralateral eye with a high plus lens (+4.00 D to +5.00 D). Binocular and monocular testing also should be performed for patients with nystagmus.

Testing visual acuity with isolated targets (figures or letters) is the quickest way to assess the vision in preverbal children, but it does lead to falsely elevated visual acuities. Isolated acuities should be compared with visual acuities taken with linear targets or crowding bars. The difference between linear and isolated acuities should be noted at each visit, if possible. This difference is a way of quantifying the depth of amblyopia from visit to visit.

Under ideal circumstances, visual acuity testing conditions should be standardized in each examination room and at each visit, so that the same viewing distance and lighting conditions are used. Some children are more amenable to testing at shorter distances.

Young children sometimes benefit from shorter testing distances, especially when a visual or attention deficit is suspected. The testing distance, type of optotype, and whether the optotype is presented a line at a time or isolated, should be documented. Patients should be encouraged to learn optotype-equivalent tests at the earliest possible age.

Ocular Alignment and Motility

Ocular alignment is assessed by using the corneal light reflection, the binocular red reflex (Brückner) test, or the cover test. Cover/uncover and alternate cover tests in primary gaze at distance and near accommodative targets are utilized when feasible; these tests require the patient's cooperation and interaction with the examiner in addition to sufficient vision to fixate on the target. Ocular versions and ductions should be tested even in the young infant. In the inattentive or uncooperative patient, eye movements may be tested using the oculocephalic rotations maneuver (doll's head) or assessed by spontaneous eye movements. Evaluating oblique muscle function in young children is important when examining a child with strabismus, but it may be difficult. When strabismus is suspected or revealed, a strabismus evaluation is warranted).

Red Reflex / Binocular Red Reflex (Brückner) Test

The red reflex and/or binocular red reflex test should be performed to identify opacities of the ocular media.

The red reflex of each eye is assessed by looking at each eye with a direct ophthalmoscope from a distance of about 18 inches. The examiner should answer three questions:

1. Is there a red reflex from each eye?
2. Are the red reflexes from each eye symmetrical?
3. Is the quality of the red reflex normal for the individual child (taking into account skin tone and race or ethnicity)?

The binocular red reflex (Brückner) test allows an assessment of the clarity of the visual axis and an indirect assessment of ocular alignment as well as large and/or asymmetric refractive errors. The binocular red reflex test is performed in a dimly lit room with the examiner at a distance of about 30 inches (0.75 meter) from the child. The examiner overlaps both pupils simultaneously, creating a binocular red reflex with the largest circular light of a direct ophthalmoscope set to focus on the ocular surface, usually at zero. The examiner then assesses the quality of the redness seen within the child's pupils. Normally, the red reflex from each eye should be of the same color and brightness.

Abnormalities include asymmetric reflexes when one reflex is duller or a different color, a white reflex, a partially or totally obscured reflex, or crescents present in the reflex.

Extraocular Muscle Function

Versions and ductions should be evaluated and any over- or underactions of extraocular muscles assessed and recorded. Inferior oblique muscle dysfunction, A or V patterns, or dissociated vertical or horizontal deviations may develop over time. The examiner should note any limitations in versions or ductions. The oculocephalic rotations maneuver (doll's head) is particularly valuable in infants and young children and often reveals clinically normal ductions that cannot otherwise be documented, even with patch testing.

Detection of Nystagmus

Nystagmus in the patient with esotropia may be manifest or latent. Manifest nystagmus is constantly present and may be horizontal, vertical, or torsional. It is typically symmetrical, although it may vary in magnitude, speed, and wave form, depending on the direction of gaze and other specific viewing conditions. Latent nystagmus (sometimes called occlusion nystagmus) is conjugate, predominantly horizontal, jerk oscillations of the eyes that are produced or exacerbated by monocular viewing. It is characterized by a slow drift away from the fixating eye, with rhythmic jerk redress movements to re-establish central fixation. The nystagmus is described as latent because it is typically perceptible or accentuated when one eye is occluded. Both manifest and latent nystagmus may coexist in the same patient.

Sensory Testing

The binocular sensory status should be assessed when feasible using Worth 4-dot testing and stereoacuity tests. Reliable data may be difficult to obtain in younger children. In the older strabismic (especially esotropic) patient, more detailed sensory testing is occasionally useful, especially if there is a history of diplopia. An orthoptic evaluation may be useful to further define the sensory status of the child.

Pupil Examination

Even in small infants, the pupils should be assessed for direct and consensual response to light and for the presence of a relative afferent defect. This can be done with a penlight, a direct ophthalmoscope, or a transilluminator. Pupil evaluation in infants and children may be difficult due to active hippus or shift in the patient's fixation and accommodative status. In general, amblyopia is not associated with a detectable afferent pupillary defect. If an afferent pupillary defect is present, the examiner should thoroughly review etiologic causes for asymmetric optic nerve function rather than attribute the finding to amblyopia.

External Examination

External examination involves assessment of the eyelids, eyelashes, lacrimal apparatus, and orbit. The anatomy of the face (including the lids, interocular distance, and presence or absence of epicanthal folds), orbital rim, and presence of oculofacial anomalies should be noted. The position of the head and face (including head tilt or turn) should be noted. Children with prominent epicanthal folds and normal ocular alignment may appear to have an esotropia (pseudo-esotropia). Distinctive features unusual for the family may suggest the presence of a congenital anomaly and merit an assessment of other physical abnormalities (e.g., ears, hands).

Anterior Segment Examination

To evaluate further opacities of the ocular media, the cornea, anterior chamber, iris, and lens should be evaluated with slit-lamp biomicroscopy if possible. Slit-lamp biomicroscopic

evaluation is easily performed for older children or for younger children who are cooperative. In infants and young children, a hand-held slit-lamp biomicroscope may be helpful. Some children may need to be restrained, sedated, or undergo an eye examination under general anesthesia when apparent abnormalities warrant a detailed examination.

Cycloplegic Retinoscopy/Refraction

Determination of refractive errors is important in the diagnosis and treatment of amblyopia or strabismus. Patients should receive an accurate cycloplegic refraction either by retinoscopy or by subjective refraction. Prior to cycloplegia, dynamic retinoscopy provides a rapid assessment of accommodative function and may be helpful in evaluating a child with high hyperopia or possible accommodative insufficiency.

Cycloplegia is necessary for accurate refraction in children. Cyclopentolate is useful because it has a rapid onset and produces cycloplegia that approximates the effect of topical ophthalmic atropine but with a shorter duration of action. Cyclopentolate 1% is more frequently used; cyclopentolate 2% is also available. The strength of cyclopentolate should be determined based on the child's weight, iris coloration, and dilation history. In eyes with heavily pigmented irides, adjunctive agents such as tropicamide and/or phenylephrine hydrochloride may be necessary to achieve adequate dilation. In rare cases, topical ophthalmic atropine may be necessary to achieve maximal cycloplegia. The use of topical anesthetic prior to the cycloplegic makes the cycloplegic sting less and promotes its penetration into the eye.

Funduscopy Examination

Posterior segment structures should be examined, preferably with an indirect ophthalmoscope. The optic disc, macula, retina, vessels, and the choroid of the posterior regions should be examined. Examination of the peripheral retinal and scleral indentation, if indicated, may require sedation or general anesthesia (e.g., evaluation for retinoblastoma).

Binocularity / Stereoacuity Testing

Testing for binocular fusion (e.g., Worth 4-dot test) or the presence of stereopsis (e.g., Random-Dot E test or Stereo Fly test) may be useful in detecting ocular misalignment or amblyopia. Fusion and stereoacuity testing at distance (20 feet or 6 meters) as well as near (13 inches or 0.33 meter) may also be helpful.

b) Investigations:

Strabismus and Amblyopia are mostly clinically diagnosed and treatment is planned based on routine examination and orthoptic check up. B scan ultrasonogram may be needed for associated media opacity and intra ocular tumors. Rarely CT scan and Electrophysiological tests are needed for assisting diagnosis.

c) Treatment:

Amblyopia:

Choice of Therapy

The following therapies are used alone or in combination as required to achieve the therapeutic goal.

- **Optical correction:** The amblyopic eye must have the most accurate optical correction possible. This should occur prior to any occlusion therapy because vision may improve with spectacles alone. Full cycloplegic refraction should be given to patients with accommodative esotropia and amblyopia. In other patients, a prescription less than the full plus measurement that was refracted may be prescribed given that the decrease in plus is symmetric between the two eyes. Because accommodative amplitude is believed to be decreased in amblyopic eyes, one needs to be cautious about cutting back too much on the amount of plus. Refractive correction alone has been shown to improve amblyopia in up to 77% of patients.
- **Occlusion:** Patching may be full-time or part-time. Standard teaching has been that children need to be observed at intervals of 1 week per year of age, if undergoing full-time occlusion to avoid occlusion amblyopia in the sound eye. In addition to adhesive patches, opaque contact lenses, occluders mounted on spectacles, and adhesive tape on glasses have been used
- **Penalization:** Penalization therapy was reserved for children who would not wear a patch or in whom compliance was an issue. The Amblyopia Treatment Studies, however, have demonstrated that atropine penalization in patients with moderate amblyopia (defined by the study as visual acuity better than 20/100) is as effective as patching. The Amblyopia Treatment Studies were performed in children aged 3-7 year
- **Surgery to treat the cause of the amblyopia**

In general, occlusive adhesive patches should be used during the initial therapy in many cases of amblyopia; however, in mild to moderate amblyopia, penalization with atropine drops has been shown to be an effective alternative

Strabismus:

Ocular alignment should be established as soon as possible, especially in young children, to maximize binocularity, prevent or facilitate treatment of amblyopia, and normalize appearance. In almost all cases, clinically important refractive errors should be corrected. Amblyopia treatment is usually started before surgery, because this may reduce the angle of strabismus or increase the likelihood of good postoperative binocularity.

The following treatment modalities are used alone or in combination as required to achieve the therapeutic goal:

- Correction of refractive errors
- Bifocals
- Miotics

- Prism therapy
- Amblyopia treatment
- Extraocular muscle surgery: Except few conditions (like, accommodative esotropia), strabismus is corrected with surgery.

Treatment plans are formulated in consultation with the patient and parents. The plans should be responsive to their expectations and preferences, including the family's perception of the existing alignment, which may differ among ophthalmologist's, and what they hope to achieve with treatment. It is important that the family and ophthalmologist agree on the goals of treatment before surgery is performed. A particularly challenging situation can arise when the surgical intervention might worsen the appearance of the child. In patients for whom the potential for binocularity is poor, surgery to normalize appearance is still appropriate treatment.

The amount of surgery and the choice of surgical technique may vary (e.g., methods of suture placement in the muscle and sclera, or measurement of recession or resection). Although two-muscle surgery is most frequently performed, sometimes three- or four-horizontal-muscle surgery may be required for large-angle deviations.

Results may be similar with different procedures; one method may be chosen over another on the basis of preoperative diagnosis, angle of deviation, technical ease, anatomical exposure, the need for an assistant, presence of scar tissue, and other factors such as physician preference and experience. Bilateral medial rectus muscle recessions are commonly performed as the initial surgical procedure. Most surgeons prefer unocular surgery (single-muscle recession or recession/resection) for patients with irreversible amblyopia or substantially reduced vision in one eye on an anatomic basis. Operating on both eyes may be preferable in specific clinical circumstances, such as V pattern esotropia with inferior oblique-muscle overaction or null-point nystagmus with compensatory face turn.

Standard Operating procedure

a. In Patient

- Patients preferring hospital stay for surgery because of distance and better care
If decided by the anaesthesiologist
- Patients needing some adjustment of sutures on the next day
- Patients with post operative complications that need institutional care

b. Out Patient

Non surgical treatment

Pre operative investigations

Follow up

c. Day Care

If patients prefer and are able to reach the clinic easily if required

d) Referral criteria:

- Cases needing specialized investigations (e.g USG B-Scan, Electrophysiological tests)
- Cases not manageable by the facilities available .
- Seeking second opinion
- Complications needing specialized intervention.
- Complex cases like torsional deviation, DVD, Duanes retraction syndrome etc.,needs referral

***Situation 2: At Super Specialty Facility in Metro location where higher-end technology is available**

- a) **Clinical Diagnosis:** Same as situation 1 plus better orthoptic examination.
- b) **Investigations:** Same as situation 1. In addition, USG B Scan and electrophysiological tests are done if needed. Paediatric and neurological consultation back up and facility for relevant systemic investigations is required in indicated patients.
- c) **Treatment:**

Same as situation 1. In addition, the ophthalmologist should be able to take up complex surgeries. Interdisciplinary referral between the anterior and posterior segment specialists is required in certain cases. Low vision aids may be required in some individuals

Standard Operating procedure

a. In Patient

- Patients preferring hospital stay for surgery because of distance and better care
If decided by the Anaesthesiologist
- Patients needing some adjustment of sutures on the next day
- Patients with post operative complications that need institutional care

b. Out Patient

Non surgical treatment; Pre operative investigations; Follow up

c. Day Care

If patients prefer and are able to reach the clinic easily if required

d) Referral criteria:

Does not apply

VI. WHO DOES WHAT? and TIMELINES

a. Doctor

- Patient History is taken and a Clinical Examination performed
- Documenting the medical record
- Plan treatment guidelines and counsel patients
- Perform surgery. Explain and assure patients if complications occur.
- Follow up
- Referral in needed.
- Monitoring the functional improvement and if needed guide parents in rehabilitation

b. Nurse / Technician

- Receive the patients and assist in clinical examination
- Refraction
- Orthoptic check up
- Counseling whenever patients/ parents
- Prepare the patients for surgery
- To monitor the patients who are admitted regarding pre and post operative care
- To maintain separate inpatient and outpatient record
- To maintain lab reports
- Explain discharge advice to patients
- Proactively ensure follow up through counseling.

VII. FURTHER READING / REFERENCES

1. Madhu Gupta, Bhupinder P Gupta, Anil Chauhan, and Ashok Bhardwaj Ocular morbidity prevalence among school children in Shimla, Himachal, North India Indian J Ophthalmol. 2009 Mar–Apr; 57(2): 133–138
2. Nirmalan PK, Vijayalakshmi P, Sheeladevi S, Kothari MB, Sundaresan K, Rahmathullah L.,The Kariapatti pediatric eye evaluation project: baseline ophthalmic data of children aged 15 years or younger in Southern India. Am J Ophthalmol. 2003 Oct;136 (4):703-9.

RESOURCES REQUIRED

Situation	HUMAN RESOURCES	INVESTIGATIONS	DRUGS & CONSUMABLES	EQUIPMENT
1] Secondary level	1) Ophthalmologist - 1 2) OP Nurse - 1 3) Ophthalmic Assistant / 4) Optometrist trained in orthoptics 1	1) Refraction 2) Orthoptic check up	1) Cycloplegics 2) Local Anaesthetics 3) Antibiotics eye drops	1) Torch light 2) Trial set 3) Prism set 4) Retinoscope 5) Slit lamp - biomicroscope 6) Direct Ophthalmoscope 7) +90 D lens 8) Indirect Ophthalmoscope with +20 D lens
2] Tertiary level	1) Experienced Ophthalmologist - 1 2) OP Nurse - 1 3) Ophthalmic Assistant / 4) Optometrist -1 5) Orthoptist -1 6) Anaesthesiologist -1 7) Assisting Nurse -1 8) Counsellor - 1	1) Refraction 2) Strabismus assessment 3) Biometry 4) USG B- Scan 5) Examination under short GA	1) Local anaesthetics 2) Antibiotics eye drops 3) Mydriatics 4) General 5) Anaesthetic medications	1) Torch light 2) Trial set 3) Prism set 4) RAF Rule 5) Synoptophore 6) Hess's screen 7) Retinoscope 8) Slit lamp - biomicroscope 9) Direct Ophthalmoscope 10) +90 D lens 11) Indirect Ophthalmoscope 12) Applanation tonometer (Perkin's) 13) Gonioscope with +20 D lens 14) A-Scan Keratometer 15) USG B- Scan 16) Boyle's apparatus 17) Pulse oxymeter

NAME OF CONDITION : CONJUNCTIVITIS

I. WHEN TO SUSPECT/ RECOGNIZE?

a) Introduction:

Conjunctivitis is a highly contagious disease which occurs world wide both sporadically and epidemically. Most varieties of conjunctivitis are self limited, but some may progress and cause severe ocular and extra ocular complication. Even in self limited conditions, it causes a significant period of ocular morbidity and loss of work place efficiency. It affects all ages and all social strata. Approximately 2% of all primary case visit and 1% of all emergency room visit are related to conjunctivitis. Appropriate prevention strategies are required to prevent this condition to spread and affect large number of people.

b) Case definition:

Conjunctivitis is a general term that refers to a diverse group of disorder, characterized by inflammation of the conjunctiva, as typified by congestion, pain, discharge, lid edema and gritty sensation of the eye.

INCIDENCE OF THE CONDITION IN OUR COUNTRY

Conjunctivitis is considered extremely common in developing countries. Although there are no reliable figures that document the incidence or prevalence of conjunctivitis, this condition has been cited as one of the most frequent causes of patient self-referral. Adenoviral conjunctivitis is the most common cause of epidemic conjunctivitis accounting for 70% . It is highly seasonal, often following monsoons. It often assumes epidemic proportions in certain years. The morbidity is directly linked to the virulence of the infecting virus. Rarely, chlamydia is the causative organism in 2% of cases of acute conjunctivitis and is the most common cause of chronic follicular conjunctivitis. Ophthalmia neonatorum, which denotes purulent conjunctivitis caused by gonococcus in infants, is a relatively rare phenomenon nowadays.

II. DIFFERENTIAL DIAGNOSIS

Conjunctivitis is a general term that refers to a diverse group of disorder, classified as infectious and non infectious affecting the conjunctiva primarily. The cause of

infectious conjunctivitis include viral and bacterial while noninfectious conjunctivitis are allergic,mechanical/toxic/irritative,immune mediated, and neoplastic.

Ophthalmia neonatorum [neonatal conjunctivitis]is often defined separately as it is caused by different group of organisms. It is important to understand that all red eyes are not necessarily due to conjunctivitis and hence the role of an ophthalmologist is to differentiate from other important serious conditions like

1. Scleritis
2. Angle closure glaucoma
3. Keratitis
4. Acute anterior iritis
5. Masquerade syndromes like ocular squamous surface neoplasia,ocular cicatricial pemphigoid.

III. PREVENTION AND COUNSELING

The ophthalmologist plays a critical role in breaking the chain of transmission of epidemic conjunctivitis, primarily by educating the patient and family about proper hygiene. Infected individuals should be counseled to wash hands frequently along with washing their eyes and use separate towels, and to avoid close contact with other family members during the period of contagion. Health care facilities have occasionally been associated with epidemic outbreaks of adenoviral keratoconjunctivitis. Paradoxically, eye hospitals may be a source of the disease transmission and hence steps have to be taken to prevent such instances from happening. Hand-washing procedures with antimicrobial soap and water and disinfecting ophthalmic equipments in between every procedure may reduce the risk of transmission of viral infection. Exposed surfaces on equipment like the applanation tonometers can be decontaminated by wiping with sodium hypochlorite (a 1:10 dilution of household bleach) or with 70% isopropyl alcohol. Prevention of allergic conjunctivitis is possible by changing the environment of the patient or by avoiding exposure to allergen causing the allergy e.g., pollen, animal fur. Ophthalmia neonatorum can be prevented by prenatal screening and treatment of the expectant mother suffering from sexually transmitted diseases and prophylactic treatment of the infant at birth by using 0.5% erythromycin or 1% tetracycline ointment .

IV. OPTIMAL DIAGNOSTIC CRITERIA, INVESTIGATIONS, TREATMENT & REFERRAL CRITERIA

***Situation 1: At Secondary Hospital/ Non-Metro situation: Optimal Standards of Treatment in Situations where technology and resources are limited**

a) Clinical Diagnosis:

History taking, comprehensive evaluation of the eye and understanding of the general epidemic prevalence of this condition in the society is crucial to establish a diagnosis . Patients usually come with typical history of matting of eye lashes on waking, copious purulent discharge, redness, gritty foreign body sensation, itching and rarely may even present with distortion of vision, photophobia and coloured haloes.

Examination: The ocular examination includes recording visual acuity, an external eye examination and slit-lamp biomicroscopy.

Visual acuity measurement: Due to acute infection of the involved eye, it is difficult to record visual acuity accurately. Although visual acuity is normal in patients with conjunctivitis, discharge sliding across the eye may cause visual disturbance vision colored haloes resulting in under estimation of true visual potential.

External examination:

The following points should be looked for:

1. Abnormalities of skin like signs of eczema, roseacea, seborrhea.
2. Look for regional enlargement of lymph nodes (pre auricular).
3. Abnormalities of eye lid and adnexa like swelling, ulceration and discolouration and laxity.
4. Examination of conjunctiva to look for chemosis, sub conjunctival hemorrhage, discharge cicatricial changes and symblepharon.

Slit-lamp Biomicroscopy:

Should include evaluation of the following:

1. Eye lid margins: To look for inflammation, ulceration, nodules, vesicles and keratinization.
2. Eye lashes: loss of eye lashes, crusting, scurf, nits and lice.
3. Lacrimal puncta and canaliculi for pouting and discharge
4. Tarsal and forniceal conjunctiva for presence and size of papillae and follicles, membranes, pseudo membranes, ulceration, masses, hemorrhages and cicatricial changes like foreshortening and symblepharon.

5. Bulbar conjunctiva and limbus for follicles, edema, nodules, chemosis, laxity, papillae, ulceration, scarring, phlyctenules, hemorrhages, foreign material, keratinization.
6. Cornea for coarse punctate keratitis, epithelial defects, filaments, ulceration, infiltrations including sub epithelial infiltrates and phlyctenules.

Specific helpful clues in differentiating the causes of conjunctivitis are listed below.

1. Bacterial conjunctivitis
 - Preauricular adenopathy sometimes occurs; chemosis (thickened, boggy conjunctiva) is common.
 - Discharge is copious; discharge quality is thick and purulent. Conjunctival injection is moderate or marked.
2. Viral conjunctivitis
 - Preauricular adenopathy is common in epidemic keratoconjunctivitis and herpes; chemosis is variable.
 - Discharge amount is moderate, stringy, or sparse; discharge quality is thin and seropurulent. Conjunctival injection is moderate or marked.
3. Chlamydial conjunctivitis tends to be chronic with exacerbation and remission.
 - Preauricular adenopathy is occasional; chemosis is rare.
Discharge amount is minimal; discharge quality is seropurulent. Conjunctival injection is moderate
4. Allergic conjunctivitis is characterized by acute or subacute onset, no pain, and no exposure history.
 - Pruritus is extremely common. Clear, watery discharge is typical with or without a moderate amount of mucous production.
 - An aggressive form of allergic conjunctivitis is vernal conjunctivitis in children and atopic conjunctivitis in adults. Vernal disease often is associated with shield corneal ulcers. Perilimbal accumulation of eosinophils (Horner-Trantas dots) typifies vernal disease. Vernal keratoconjunctivitis (VKC), usually affecting young boys, tends to be bilateral and occurs in warm weather. VKC is presumed to be a hypersensitivity to exogenous antigens and may be associated with or accompanied by keratoconus.
5. Giant papillary conjunctivitis resembles vernal disease.
 - This condition occurs mainly in contact lens wearers who develop a syndrome of excessive pruritus, mucous production, and increasing intolerance to contact use.
 - Bilateral disease typically is infectious or allergic.
 - Unilateral disease suggests toxic, chemical, mechanical, or lacrimal origin.
 - Intraocular pressure, pupil size, and light response are all normal.
 - Ciliary flush, corneal staining, and anterior chamber reaction is absent unless a significant amount of keratitis is associated (as seen in EKC).

6. Nummular keratitis gives a clue for diagnosis as it is often caused by adenovirus and HZV

b) Investigations:

Conjunctivitis usually is diagnosed by history and physical examination. A regular microbiological useful in patients with recurrent conjunctivitis and in some cases of epidemic conjunctivitis the material is obtained by taking conjunctival swabs from lower forniceal and upper tarsal conjunctiva after instilling a topical anesthetic agent (4% lignocaine). Two smears are initially prepared one with gram staining and the other with giemsa. Gram stain is considered the criterion standard for determining the bacterial cause of conjunctivitis. Eosinophils seen on Giemsa stain are indicative of allergic conjunctivitis but can be seen in parasitic causes also.

Giemsa staining is also performed to look for the inclusion bodies of Chlamydia trachomatis.

c) Treatment:

Treatment of conjunctivitis is ideally directed at the root cause. Indiscriminate use of topical antibiotics or corticosteroids should be avoided, because antibiotics can induce toxicity and corticosteroids can prolong adenoviral infections and worsen herpes simplex virus infections. A careful counselling of the dosages of the individual medicine should be adequately explained to the patient and an accompanying person so that it will be applied in the right manner. Regular irrigation of the eye with clean water remains the corner stone of the treatment for all forms of conjunctivitis. The following table shows various modalities of management in different types of conjunctivitis.

Type	Management
1] Bacterial conjunctivitis	<ul style="list-style-type: none"> • Chloramphenicol 0.5% eye drops (or) • Ciprofloxacin 0.3% eye drops <p>Intensive instillation every 15 to 30 min until symptoms and signs are reduced and gradually tapered.</p>
2] Viral conjunctivitis	<ul style="list-style-type: none"> • Advise the patient to clean the eye by washing with normal saline frequently. • Cold compression. • Topical anti-histaminics • Frequent application of preservative free artificial tears. • Topical antibiotics in cases of suspected secondary bacterial infection. • Severe inflammation, presence of sub-epithelial infiltrate,

	<p>presence of membranes and pseudo membranes may necessitate a short course of topical steroids.</p> <ul style="list-style-type: none"> • Herpetic conjunctivitis to be treated with topical acyclovir eye ointment.
3] Allergic conjunctivitis	<ul style="list-style-type: none"> • Cold compression and ocular lubricants. • Topical and systemic anti-histaminics. • Topical mast-stabiliser • Topical NSAIDs • Topical steroids in short pulses
4] Chlamydial conjunctivitis	<p>In Neonates</p> <ul style="list-style-type: none"> • Topical tetracycline 1% or erythromycin ointment twice daily for 2 months • Oral tetracycline 1.5-2gm daily in divided doses for 2 weeks or oral azithromycin single dose or erythromycin 50mg/kg in four divided doses for 2 weeks <p>In Adults</p> <ul style="list-style-type: none"> • Oral azithromycin 1g single dose or doxycycline 100mg BD for 7 days or tetracycline 250mg qid for 7 days or erythromycin 500mg qid for 7 days.
5] Gonococcal conjunctivitis	<p>In Neonates</p> <ul style="list-style-type: none"> • I M Ceftriaxone 25-50mg/kg single dose <p>In Adults</p> <ul style="list-style-type: none"> • I M Ceftriaxone 1g single dose • I M Spectinomycin 2g single dose. • Chloramphenicol 1% eye ointment • Use normal saline or cooled boiled water. Initially continuous irrigation will be needed.
6] Chemical conjunctivitis	<ul style="list-style-type: none"> • Stop instilling the substances that has caused the reaction. • Lubricant ointment can be soothing. • Mild topical antibiotics like chloramphenicol will prevent secondary bacterial infection.

standard operating procedure

a. In Patient :

- Admit patients if they develop complications secondary to conjunctivitis like orbital cellulitis, keratitis, scleritis, anterior uveitis, especially if the patient cannot come for frequent follow up and who are non compliant.
- Admit patients with hyperacute bacterial conjunctivitis if the entire cornea cannot be visualized, as there may be an early corneal ulceration.

- b. Out Patient:** All cases of simple conjunctivitis are almost exclusively treated on out patient basis.
- c. Day Care:** Not applicable.

d) Referral criteria:

- Infants diagnosed to have ophthalmia neonatorum due to gonococci, chlamydia and HSV are referred as they need systemic evaluation and appropriate systemic treatment and more importantly need for counseling the parents.
- Severe conjunctivitis, not responding to treatment to be referred for further laboratory evaluation in tertiary centre.
- When conjunctivitis appears to be a manifestation of auto immune systemic disease like Reiters ulcerative colitis etc., then patients should be referred for evaluation by an appropriate medical specialist.
- Prolonged persistent conjunctivitis with development of complication like cicatrization, lid abnormalities, and dry eye, symblepharon and punctal anomalies.
- Severe chemical conjunctivitis with limbal ischaemia and suspected intra ocular penetration of toxic substances to be referred for further management in higher centre.

***Situation 2: At Super Specialty Facility in Metro location where higher-end technology is available**

a) Clinical Diagnosis:

Apart from the regular history taking, care should be exercised to fully understand the treatment history of the patient, including all the medications along with the dosage schedules which were prescribed at the secondary centre. In fact, withdrawal of strong topical antibiotics may be warranted. A fresh comprehensive clinical examination, as detailed in the previous section should be performed without being biased by the referral report.

b) Investigation

As the patients are referred from a secondary centre for a non responsiveness to treatment or when diagnosis is uncertain or especially in neonatal conjunctivitis which needs exact etiological diagnosis for initiation of treatment , additional micro biological and immunological diagnostic tests may be required.

- **Culture:** Culture and sensitivity of conjunctival scrapings are indicated in all cases of suspected neonatal conjunctivitis, persons who are immunosuppressed, when *N gonorrhoeae* is under consideration as the etiology, recurrent or severe purulent conjunctivitis and in cases where the conjunctivitis has not responded to medication. When performed, collect

exudate from the lower conjunctival fornix with a calcium alginate swab moistened with saline. Sheep blood and mannitol agar plates routinely are used. Expect viral and chlamydial causes in culture-negative conjunctivitis.

- **Viral diagnostic tests:** Viral cultures are not routinely used to establish a diagnosis. A rapid, in-office immunodiagnostic test using antigen detection is available for adenovirus conjunctivitis. Immunodiagnostic tests may be available for other viruses. Polymerase chain reaction (PCR) may be used to detect viral deoxyribonucleic acid. RPS adenodetector is a new rapid diagnostic test for identifying adeno viral conjunctivitis.
 - **Chlamydial diagnostic tests:** Suspected cases of adult and neonatal chlamydial conjunctivitis can be confirmed by laboratory testing. Immunologically based diagnostic tests are available, including a direct immunofluorescent antibody test and enzyme-linked immunosorbent assay.
 - **Biopsy:** Conjunctival biopsy may be helpful in cases of conjunctivitis unresponsive to therapy. Because such eyes may harbor a neoplasm, directed biopsy may be both vision-saving and lifesaving. Conjunctival biopsy and immunofluorescent staining diagnostic tests may be helpful to establish the diagnosis of diseases such as ocular squamous surface neoplasia (OSSN), ocular mucous membrane pemphigoid (OMMP) and paraneoplastic syndromes. A biopsy of bulbar conjunctiva should be performed and a sample should be taken from an uninvolved area adjacent to the limbus in an eye with active inflammation when OMMP is suspected. In cases of suspected sebaceous gland carcinoma, a full-thickness lid biopsy is indicated. When considering a biopsy, a preoperative consultation with the pathologist is advised to ensure proper handling and staining of specimens.
- c) **Treatment:** The treatment strategies should be revisited to check for adequacy, appropriateness and affordability. If the culture and other tests show a different organism, then the treatment regimen should be modified.

Surgical procedure includes:

1. Symblepharon: treated by dividing the symblepharon and to prevent the reformation of scar tissue during healing period. The formation of scar tissue in raw area is prevented by single pedicle conjunctival graft, mucous membrane graft, split skin graft or by amniotic membrane transplantation.
2. Correction of lid abnormality like cicatricial ectropion, cicatricial entropion, trichiasis etc., by appropriate surgical procedure.
3. Chemical conjunctivitis with severe ocular surface abnormality treated by ocular surface reconstruction by limbal stem cell graft, conjunctival autografts,

fornix reconstruction, optical penetrating keratoplasty and keratoprosthesis surgeries.

STANDARD OPERATING PROCEDURE

a. In Patient :

- Infants diagnosed to have ophthalmia neonatorum due to gonococci chlamydia and HSV are admitted as they need systemic evaluation and appropriate systemic treatment.
- Prolonged persistent conjunctivitis with development of complication like cicatrization, lid abnormalities, dry eye, symblepharon and punctal anomalies.
- Severe chemical conjunctivitis with limbal ischaemia and suspected intra ocular penetration of toxic substances.

b. Out Patient: If the patient requires only modification of the topical anti-infectives, then he/she can be treated as an outpatient.

c. Day Care: not applicable.

d) Referral criteria: not applicable.

V. WHO DOES WHAT? AND TIMELINES

a. Doctor :

- Patient history is taken and a clinical examination performed
- Conjunctival infective material is obtained by scrapping and smear are prepared and also materials are inoculated directly onto culture media
- Documenting the medical record
- Plan treatment guidelines and perform surgery if necessary. Monitoring, publication and reporting to department of health if there is an epidemic conjunctivitis and if there is an emergence of drug resistance pathogen.
- He/she plays a critical role in breaking the chain of transmission of epidemic adenoviral conjunctivitis, primarily by educating the patient and family about proper hygiene.
- He/she should also ensure that needy patients receive necessary care directly or through referral to appropriate persons and facilities that will provide such care, and he or she supports activities that promote health and prevent disease.

b. Nurse/Technician:

- Prepare Slide, Media for smear and culture.
- To monitor the patients who are admitted.
- To maintain separate inpatient and outpatient record.
- To maintain lab reports.

VI. FURTHER READING / REFERENCES

1. Bersudsky V, Rehany U, Tendler Y, Leffler E, Selah S, Rumelt S. Diagnosis of chlamydial infection by direct enzyme-linked immunoassay and polymerase chain reaction in patients with acute follicular conjunctivitis [Internet]. Graefe's Archive for Clinical and Experimental Ophthalmology = Albrecht Von Graefes Archiv Für Klinische Und Experimentelle Ophthalmologie. 1999 ;237(8):617-620. Available from: <http://www.ncbi.nlm.nih.gov/pubmed/10459609>
2. Sambursky R, Tauber S, Schirra F, Kozich K, Davidson R, Cohen EJ. The RPS adeno detector for diagnosing adenoviral conjunctivitis [Internet]. Ophthalmology. 2006 ;113(10):1758-1764. Available from: <http://www.ncbi.nlm.nih.gov/pubmed/17011956>

Resources required

Situation	HUMAN RESOURCES	INVESTIGATION	DRUGS AND CONSUMABLES	EQUIPMENT
1) Secondary level	1)Ophthalmologist - 1 2)OP Nurse - 1 3)Refraction nurse - 1 (shared)	Smear test 1)Gram stain microscopy 2)Giemsa stain	1)Antibiotics eye drops 2)Anti viral eye ointment 3)Systemic antibiotics and anti virals 4) NSAID'S eye drops and steroids 5) Anti allergic eye drops. 6) Cycloplegics	1)Slit lamp - biomicroscopy -1 2)Light microscopy -1 3)15# blade/ conjunctival swabs - 1 4)Glass slide - 1 5)Basic stains - 1
2) Tertiary level	1)Cornea specialist - 1 2)Refraction nurse - 1 (shared) 3)OP Nurse - 1 4)lab technician - 1 5)Scrub nurse 1 6)OT nurse 1 7)Ward nurse - 1 8) Counsellor - 1	1)Smear test 2)Culture medium 3)Viral diagnostic tests like IF tests, PCR, RPS adeno detector. 4) Chlamydial diagnostic tests like IF tests,ELISA. 5) Conjunctival biopsy.	1)Antibiotics eye drops 2)Anti viral eye ointment 3)Systemic antibiotics and anti virals 4) NSAID'S eye drops and steroids 5) Anti allergic eye drops. 6) Cycloplegics	1)Slit lamp - biomicroscopy -1 2)Light microscopy -1 3)15NO blade /calcium alginate swabs 1 4)Glass slide - 1 5)Basic stains - 1 6)Cultures 7)OT microsurgical instruments - 1

NAME OF CONDITION: MICROBIAL KERATITIS

I. WHEN TO SUSPECT/ RECOGNIZE?

a) Introduction:

Microbial keratitis is an important cause of avoidable monocular blindness in India. Young adults in their prime working age group are most commonly affected and hence the loss of man years of productivity is extremely high. The therapeutic results are less than satisfactory even in the most optimistic situations. Even the so called successfully treated cases end up with a corneal scar which might impair vision. The cost of treatment is compounded by the long treatment schedules and frequent follow ups to the hospital. A significant percentage of patients fail medical treatment, and will require corneal transplantation. The availability of donor corneas in India is extremely low. Currently only 5% of the requirement is being met. Under these circumstances, it becomes very clear that adequate and appropriate therapy at all levels and more importantly preventive strategies at the primary level will go a long way in preventing this unnecessary catastrophe.

b) Case definition:

A theoretical definition of a corneal ulcer is a loss of the overlying epithelium with underlying infiltration. However, for all practical purposes, microbial keratitis includes any condition which causes suppurative infection of the cornea. Further progress of the disease can cause necrosis of the deeper stromal tissue, resulting in perforation and loss of intraocular contents.

II. INCIDENCE OF THE CONDITION IN OUR COUNTRY

It is an extremely common condition causing significant ocular morbidity in our country. In fact, an editorial in the British Journal of Ophthalmology called it as a silent epidemic. Gonzales et al found that the annual incidence of corneal ulceration in Madurai district in South India was 113 per 1,00,000 people. By applying the 1993 corneal ulcer incidence rate in Madurai district to whole of India, about 8,40,000 people are likely to develop a corneal ulcer in a year. Even this figure is quoted as an under estimation when compared to other SAARC countries. This figure is thirty times more than the number of corneal ulcers seen in the United States.

III. DIFFERENTIAL DIAGNOSIS

The term microbial keratitis is often reserved for conditions caused by microorganisms which results in suppuration. The common causative organisms can be bacteria, fungi or, parasites. Other conditions which can mimic a suppurative keratitis includes

- a. Viral keratitis

- b. Marginal keratitis caused by hypersensitivity reactions
- c. Ulcerative keratitis secondary to inherent connective tissue disorders
- d. Toxic keratitis
- e. Exposure and neurotrophic keratitis
- f. Corneal ulceration secondary to Vitamin A deficiency in children.

IV. PREVENTION AND COUNSELING

Avoiding exposure to predisposing factors may minimize the risk of microbial keratitis. The majority of corneal ulcers follow trivial corneal abrasions. The use of traditional eye medicines (TEMs) is an important risk factor for corneal blindness, since they are often contaminated and provide a vehicle for the growth of pathogenic organisms. The common TEM's used in our country includes breast milk, castor oil and leaf extracts. Training traditional healers in asepsis, banning harmful medicines and directing patients to appropriate health care facilities would be the first rewarding approach in preventing corneal blindness due to red eye and corneal injuries. Ocular surface disease such as Trachoma, dry eye, lagophthalmos and Vitamin A deficiency should be treated. Routine use of prophylactic topical antibiotics in this setting is controversial because their efficacy has not been established and may promote growth of resistant organisms. Even though keratomalacia is rare, still we see children going blind due to Vitamin A deficiency. Proper diet counseling and Vitamin A supplementation will totally eradicate keratomalacia from our country.

V. OPTIMAL DIAGNOSTIC CRITERIA, INVESTIGATIONS, TREATMENT & REFERRAL CRITERIA

***Situation 1: At Secondary Hospital/ Non-Metro situation: Optimal Standards of Treatment in Situations where technology and resources are limited**

a) Clinical Diagnosis:

An adequate history taking, coupled with a comprehensive evaluation goes a long way in establishing a clinical diagnosis which can then be confirmed by microbiological examination. Patients come with varying degrees of pain, photophobia, watering and redness of eyes and may also complain of defective vision, especially if the visual axis is involved.

History

Eliciting a proper history with regards to nature of trauma and use of TEM is crucial step in the management of microbial keratitis. Trauma with vegetable matter such as paddy husks or onions are more likely to cause a fungal keratitis. Contact with contaminated or brackish water is likely to produce *Acanthamoeba* keratitis. In cases of contact lens wearers, it is imperative to take history of wearing schedule and lens care.

Examination

The ocular examination includes recording visual acuity, an external eye examination and slit-lamp biomicroscopy of affected and normal eye.

Visual Acuity measurement

Due to acute infection of the involved eye, it is difficult to record visual acuity accurately. However, an approximate visual acuity with or without optical correction will give a baseline data to aid in the appropriate management strategy and also to monitor the healing process.

External Examination

An external examination should be performed with particular attention to the following:

- General appearance of the patient
- Facial examination
- Eyelids and lid closure
- Conjunctiva
- Nasolacrimal apparatus
- Corneal sensation

Slit-lamp Biomicroscopy

Should include evaluation of the following:

Eyelid margins: Inflammation, ulceration, eyelash, and abnormalities including trichiasis, irregularities, and lacrimal punctal anomalies.

Conjunctiva: Discharge, inflammation, morphologic alterations (e.g. follicles, papillae, cicatrization, keratinization, membrane, pseudomembrane, ischemia, and foreign bodies).

Sclera: Inflammation, (e.g. infectious, versus autoimmune), ulceration, scarring / thinning, nodules, ischemia.

Cornea:

Epithelium, including defects and punctate keratopathy, edema

Stroma, including ulceration, thinning, perforation, and infiltrate (location [central, peripheral, perineural, surgical, or traumatic wound], density, size, shape [ring], number [satellite], depth, character of infiltrate margin [suppuration, necrosis, feathery, soft, crystalline], color), edema

Signs of corneal dystrophies (e.g., epithelial basement membrane dystrophy)

Previous corneal inflammation (thinning, scarring, or neovascularization)

Signs of previous corneal or refractive surgery

Fluorescein (or, occasionally, rose bengal staining) of the cornea is usually performed and may provide additional information about other factors, such as the presence of dendrites, pseudodendrites, loose or exposed sutures, foreign body, and any epithelial defect.

Clinical features suggestive of bacterial keratitis include dense suppurative stromal infiltrate with distinct edges and edema. The symptoms are typically more prominent than the signs. Fungal keratitis presents with dry raised surface and feathery indistinct margins. Accompanying satellite lesions may be present in few cases. Acanthamoeba keratitis usually presents with a ring shaped stromal infiltrate, as a late clinical feature and commonly it is misdiagnosed as viral keratitis. It has to be emphasized however that all these features are only suggestive of the organism and microbiological confirmation should be sought for proper identification.

b) Investigations:

Microbiological investigations:

While characteristic clinical features have been described for ulcers caused by different microorganisms, it is difficult to confirm these, especially after the disease has become well established. Patients present late in our country and by this time, the clinical demarcation between the ulcers caused by bacteria and fungi are usually lost. Since bacteria and fungi cause an almost equal proportion of keratitis in our country, it is highly essential to perform at least a smear test before initiating the treatment. Corneal infective material is obtained by scraping after instilling a topical anesthetic agent (4% lignocaine) and using a flame sterilized platinum spatula, blade or other similar sterile instrument. The material is obtained from the advancing borders; ulcer base and edges. Two smears are initially prepared – one with Gram's stain (for identifying bacteria, fungi, and Acanthamoeba) and the other with 10% potassium hydroxide (for fungus).

Biochemical investigations:

A baseline evaluation for diabetes mellitus should be performed. Some of these patients have undiagnosed diabetes, which might hinder with the healing of the ulcer.

c) Treatment:

The treatment for suppurative keratitis is often prolonged. The importance of a regular follow up should be adequately emphasized to the patient before the initiation of the appropriate anti microbial therapy. A careful counseling of the dosages of the individual medicine should be adequately explained to the patient and an accompanying person so that it will be applied in the right manner. The treatment strategy should be guided by the microbiological investigations and the clinical appearance of the ulcer.

Bacterial Keratitis:

Topical antibiotics are capable of achieving high tissue levels and are the preferred route in most cases. Ointments may be useful in children and at bedtime. Routine subconjunctival antibiotics are not necessary unless the compliance of the patient is doubtful or poor.

For severe keratitis (ulcer more than 5mm and deep), a loading dose at every 5 to 15 minutes during the first hour, followed by applications every 15 minutes to 1 hour during waking hours is recommended. It is ideal to treat the patient as inpatient. For non-severe keratitis, a regimen with less frequent dosing is appropriate. Cycloplegic agents may be used to prevent synechia formation and to decrease pain. Small ulcers less than 2 mm and away from the visual axis do not need cycloplegics.

Gram positive cocci are the most important cause of bacterial keratitis in our country. Topical eye drops of Chloramphenicol (0.5%) and Cefazolin (5 to 10%) are ideal for gram positive cocci. *S. pneumoniae*, which is the most common bacterial isolate in our country, has variable susceptibility to fluoroquinolones and hence fluoroquinolones may not be the ideal antibiotic for monotherapy for gram positive organisms in our country .

Gram negative bacilli respond very well to fluoroquinolones and aminoglycosides. Single drug therapy using a fluoroquinolone has shown to be as effective as combination therapy utilizing topical antibiotics that are commercially available. But recent reports do not recommend this in view of more drug resistance. The following table gives the dosage schedule of commonly used antibacterial agents.

Table 1: Antibiotic Therapy of Bacterial Keratitis

Organism	Antibiotic	Topical Concentration	Subconjunctival Dose
No organism identified or multiple types of organisms	Cefazolin with	50 mg/ml	100 mg in 0.5 ml
	Gentamycin/ Tobramycin or	3-14 mg/ml	20 mg in 0.5 ml
	Fluoroquinolones	3 mg/ml	
Gram-positive cocci	Chloramphenicol	5 to 10 mg/ml	
	Cefazolin	50 mg/ml	100 mg in 0.5 ml
	Vancomycin	15-50 mg/ml	25 mg in 0.5 ml
Gram-negative bacilli	Gentamicin/ Tobramycin	3-14 mg/ml	20 mg in 0.5 ml
	Ceftazidime	50 mg/ml	100 mg in 0.5 ml
	Fluoroquinolones	3 mg/ml	
Non-tuberculous Mycobacteria	Gentamicin	14 mg/ml	20 mg in 0.5 ml
	Amikacin	10 mg/ml	
Nocardia	Amikacin	10 mg/ml	20 mg in 0.5 ml
	Trimethoprim/ Sulphamethoxazole	16 mg/ml	
		80 mg/ml	

Note: Systemic antibiotics are recommended only when the ulcer involves sclera or perforates. Fortified antibiotic therapy is a good armamentarium to treat bacterial keratitis. The preparation and the indication for such a therapy is described in the following paragraph

Preparation of fortified antibiotics:

Gentamicin and Tobramycin

Add 2 ml of injectable Gentamicin or Tobramycin to 5 ml commercial topical preparation in a sterile set up using disposable syringe.

5 ml commercial has - 15 mg
 Added drug - 80 mg
 Total in 7 ml - 95 mg

1 cc contains 13.5 mg or 1.35%

Cefazolin:

Add 5 ml or 10 ml of distilled water or sterile saline to 500 mg vial of cefazolin to obtain 10% or 5% solution. Use a dropper, which is available in the pharmacy or other source.

Vancomycin:

Add 10 ml distilled water or saline to 500mg vial of Vancomycin and obtain a 5% solution.

Amikacin:

1% would be sufficient. Add 10cc distilled water to 100mg of Amikacin. Use a sterile empty Xylocaine vial and place the cap for ready use.

All these solutions could be safely used for a week. If it is applied frequently as recommended it will not last more than a week.

The treatment of fungal keratitis remains as a challenge. All the available antifungal agents are fungistatic and not fungicidal. The penetration of the drugs is poor particularly when the epithelial defect is small. It leads to prolonged treatment, often leading to poor compliance with antifungal therapy. Natamycin (5%) and Amphotericin -B(0.15%-0.5%) are the most efficacious among the available topical antifungal agents against filamentous fungi. Voriconazole 1% is a recent addition in the treatment of filamentous fungi. A recently published randomized clinical trial demonstrated that the safety and efficacy of Natamycin and Voriconazole are comparable when used for fungal keratitis .Use of systemic anti-fungals like imidazoles and triazoles are reserved for deep keratitis associated with scleritis and endophthalmitis. The following table gives the dosage schedule of commonly used antifungal agents.

Table 2: Therapy of fungal Keratitis

<i>Organism</i>	<i>Antibiotic</i>	<i>Topical</i>	<i>Systemic</i>
Fusarium	a. Natamycin b. Amphotericin B	5% suspension 0.1 to 0.5 %	not available I.V.use rarely
Aspergillus	a. Amphotericin B b. Imidazole (Prepare the suspension) daily - orally	0.15% to 0.5% 1 ó 2 %	---- 200 mg to 400 mg
Candida (rare)	a. Fluconazole b. Nystatin ointment	0.3% 1,00,000 µ	

Other Drugs

- ◆ Itraconazole ó oral ó 300 mg daily (only 55 to 60 % efficacy)

Several clinical features suggest the response to antimicrobial therapy.

- Decreased pain.
- Consolidation and sharper demarcation of the periphery of the stromal infiltrate.
- Decreased density of the stromal infiltrate.
- Reduction of stromal edema and endothelial inflammatory plaque.
- Dilatation of the pupil.
- Re-epithelialization.

- Reduction in congestion of bulbar conjunctiva
- Visual improvement

Topical therapy is tapered according to the clinical response, taking into account the baseline clinical picture and the virulence of the pathogen.

Standard Operating Procedure

a. In Patient

- Severe keratitis (ulcer more than 5mm and deep)
- No response to initial management
- Doubtful compliance

b. Out Patient

- Small ulcers
- Patients who can come for frequent follow up and those who understand the importance of compliance

c. Day Care

- Not applicable

d) Referral criteria:

Immediate referral on presentation if there is

- Immediate threat to vision
- Ulcer involved in the only seeing eye
- Pediatric patients needing anesthesia
- Impending or actual perforation

Referral following initial treatment if,

Non healing or progressive ulcer inspite of adequate and appropriate anti microbial therapy, apart from all the points mentioned above.

***Situation 2: At Super Specialty Facility in Metro location where higher-end technology is available**

a) Clinical Diagnosis:

Apart from the regular history taking, care should be exercised to fully understand the treatment history of the patient, including all the medications along with the dosage schedules which were prescribed at the secondary centre. This will avoid unnecessary wastage of medicines and help in formulating an ideal treatment strategy. A fresh comprehensive clinical examination, as detailed in the previous section should be performed without being biased by the referral report.

b) Investigations:

Microbiology: Since the patient has been referred for a potentially serious condition, a comprehensive microbiological evaluation including additional culture, antibiotic sensitivity testing and if necessary, a corneal biopsy should be performed. A repeat smear examination should be ordered for and carefully looked for mixed organisms.

Routine culture examinations are useful for the following reasons

- i. Gold standard that confirm gram stain microscopy (GSM)
- ii. Provide sensitive data, including antibiotic sensitivity measurement to enable modification of initial therapy
- iii. It will serve as an useful tool to understand the causative organisms prevalent in the region

The cultures should be selected to identify common organisms like fungi and bacteria. An ideal minimal culture tests would use blood agar and Sabouraud's dextrose agar. Special culture media such as non nutrient agar should be reserved for non responsive cases or cases which show clinical suspicion of Acanthamoeba. Ocular bacterial cultures usually grow within 48 hours while the fungi from the ocular specimens grow within 7 days.

Recommended Stains and Culture media for Microbial Keratitis

Suspected Organisms	Stain	Media
Aerobic bacteria	Gramø	Blood agar Chocolate agar Thioglycollate broth
Anaerobic bacteria (Rarely involved)	Gramø	Anaerobic blood agar Thioglycollate broth
Mycobacteria	Gramø Acid fast	Blood agar Lowenstein ó Jenson
Fungi	10 % KOH Gramø Calcofluorwhite	Blood agar Sabouraudø dextrose agar Brain heart infusion
Acanthamoeba	10 % KOH Gramø Giemsa Calcofluorwhite	----- Non-nutrient agar with E.coli

Note: Acridine orange ó GMS ó if facilities available, use it.

Corneal biopsy:

It may be performed in the following conditions

- i. Deeper stromal lesions which are non accessible to routine corneal scrapings
- ii. Ulcers which show a negative culture, probably because of inadequate specimen.

C) Treatment:

The treatment strategies should be revisited to check for adequacy, appropriateness and affordability. If the culture grew a different organism, then the treatment regimen should be modified appropriately as recommended in the previous table. If the ulcers continue to worsen in spite of correct treatment, then surgical options should be considered.

Surgical Procedure may include:

1. Ulcer Debridement :
 - Enhance penetration of topical medication
 - Debulking of infective material
2. Tissue adhesive
 - Microperforation
 - Peripheral corneal ulcer with descemetocoele
3. Dacryocystectomy if lacrimal sac infection in same eye
4. Penetrating Keratoplasty

Therapeutic keratoplasty has to be performed when the ulcer progresses despite specific anti-microbial therapy leading to descemetocoele or perforation. The microperforation could be diagnosed by noticing a decrease in the size of the hypopyon, radial folds from the base of the ulcer and relief from pain. Sometimes it may seal spontaneously and healing will be faster. If the anterior chamber is formed within 48 hours with bandage or other supportive therapy therapeutic keratoplasty could be avoided or postponed. The goals of the therapeutic keratoplasty are to eliminate the infection and restore the integrity of the globe. The size of the graft should be decided on the basis of the size of the ulcer and should include the infected edges. Fresh donor corneas give better results in Phakic eyes. Steroid in any form should be avoided post operatively in fungal ulcers.

5. Tarsorrhaphy: can be considered in neurotrophic and exposure keratitis

Standard Operating Procedure

a. In Patient

- i. Immediate threat to vision
- ii. Ulcer involved in the only seeing eye
- iii. Pediatric patients needing anesthesia
- iv. Impending or actual perforation
- v. Any patients requiring surgery

b. Out Patient

- i. If the patient requires only modification of the topical antibiotics, then he/she can be treated as outpatients.

c. Day Care

Not applicable

D) Referral criteria:

Not applicable

VI. WHO DOES WHAT? AND TIMELINES

a. Doctor

- Patient History is taken and a Clinical Examination performed
- Corneal infective material is obtained by scrapping and smear are prepared and also materials are inoculated directly onto culture media
- Documenting the medical record
- Plan treatment guidelines and perform surgery if necessary.
- Monitoring, publication and reporting to department of health if there is an epidemic of drug resistant pathogen and iatrogenic corneal ulcer (Contact lens, refractive Surgery related)

b) Nurse/Technician

- Prepare Slide, Media for smear and culture
- To monitor the patients who are admitted regarding application of eye drops and ensure compliance
- To maintain separate inpatient and outpatient record
- To maintain lab reports

VII. FURTHER READING / REFERENCES

1. Garg P, Sharma S, Rao GN. Ciprofloxacin-resistant Pseudomonas keratitis [Internet]. Ophthalmology. 1999 ;106(7):1319-1323. Available from: <http://www.ncbi.nlm.nih.gov/pubmed/10406614>
2. Prajna NV, Mascarenhas J, Krishnan T, Reddy PR, Prajna L, Srinivasan M, et al. Comparison of natamycin and voriconazole for the treatment of fungal keratitis [Internet]. Archives of Ophthalmology. 2010 ;128(6):672-678. Available from: <http://www.ncbi.nlm.nih.gov/pubmed/20547942>
3. Srinivasan M, Gonzales CA, George C, Cevallos V, Mascarenhas JM, Asokan B, et al. Epidemiology and aetiological diagnosis of corneal ulceration in Madurai, south India

[Internet]. The British Journal of Ophthalmology. 1997 ;81(11):965-971.Available from: <http://www.ncbi.nlm.nih.gov/pubmed/9505820>

4. Whitcher JP, Srinivasan M. Corneal ulceration in the developing world--a silent epidemic [Internet]. The British Journal of Ophthalmology. 1997 ;81(8):622-623.Available from: <http://www.ncbi.nlm.nih.gov/pubmed/9349145>

RESOURCES REQUIRED

Situation	HUMAN RESOURCES	INVESTIGATION	DRUGS AND CONSUMABLES	EQUIPMENT
1) Secondary level	1)Ophthalmologist - 1 2)OP Nurse 1 3)Refraction nurse - 1(shared)	1) Smear test 2) Gram stain microscopy 3) KOH smear 4) Blood sugar 5) Lacrimal syringing	1) Antibiotics eye drops 2) Antifungal eye drops 3) Systemic antibiotics and anti fungal 4) Vitamin A 5) Cyclopiegics	1)Slit lamp - biomicroscope -1 2)Light microscope -1
2) Tertiary level	1)Cornea specialist - 1 2)Refraction nurse - 1(shared) 3)OP Nurse - 1 4)lab technician – 1 5)Scrub nurse 1 6)OT nurse 1 7)Ward nurse - 1	1) Smear test 2) Culture medium 3) Antibiotic sensitivity 4) Corneal biopsy 5) AC tap 6) PCR 7) Blood sugar 8) Lacrimal syringing	1) Antibiotics eye drops/ointment 2) Antifungal eye drops/Ointment 3) Systemic antibiotics and anti fungal 4) Vitamin A 5) Topical and systemic steroids 6) Suture materials 7) Needles and syringes	1)Slit lamp - biomicroscope -1 2)Light microscopy -1 3)Confocal microscope -1 4)Specular microscope -1 5) OT microsurgical instruments including trephines. 6)Well equipped microbiological laboratory for smear, culture and PCR) 7)Eye Bank equipment

NAME OF CONDITION: CATARACT

I. WHEN TO SUSPECT/ RECOGNIZE?

a) Introduction:

Cataract is the commonest cause of blindness and visual impairment in India. It affects a significant number of elderly people's quality life and economic productivity. This age related condition usually presents with gradual dimness of vision in both eyes. In the earlier stages, patients may experience glare, especially while driving at night. There may be monocular diplopia or polyopia, reduced contrast sensitivity and altered colour perception. Over a period of time, the cataracts can advance and can cause total blindness.

Very rarely, children can also have cataract. These children are born with this disorder or develop it at a very early age. The definitive treatment is always surgery with a very favourable risk reward ratio. In fact, cataract surgery is one of the most cost-effective public health interventions worldwide.

b) Case definition:

A cataract is any opacity of the crystalline lens or its capsule leading to degradation of its optical quality, thereby causing decreased quality of vision.

II. INCIDENCE OF THE CONDITION IN OUR COUNTRY

In India cataract has been reported to be responsible for 50-80% of the bilaterally blind in the country .Data from a population based longitudinal study of randomly selected communities in Central India have for the first time provided direct estimates of age specific incidence of blindness from cataract. It estimated that 3.8 million persons become blind from cataract each year in India. The absolute number of cataract blind which was 7.75 million in 2001 is likely to reach 8.25 million in 2020 due to a substantial increase in the population above 50 years in India over this period.

The 60+ population which stood at 56 million in 1991 will double by 2016.This increase in population means that the population 'at-risk' of blinding cataract will also increase tremendously. The economic loss due to blindness and visual disability from cataract is enormous. Cataract blind people are unable to work and thus due to lack of productivity, the economic impact is a staggering 4.5 million rupees per year of every million population. Cataract in children, although rare, can still happen. The prevalence of blindness among children in different regions varies from 0.2/1000 children to over 1.5/1000 children with a global figure estimated at 0.7/1000. In India this figure is approximately 1 per 1000 children. The proportion of blindness in children due to cataract varies considerably between regions from 10%-30%. Children who are blind have to overcome a lifetime of

emotional, social and economic difficulties which affect the child, the family and society. Timely recognition and intervention can eliminate blind-years due to childhood cataract, as the condition is treatable.

III. DIFFERENTIAL DIAGNOSIS

Cataract presents as a white reflex in the central part of the pupil. There are some other common conditions of the eye that show white reflex in the pupillary area and mimic cataract.

- Endophthalmitis
- Old Retinal Detachment
- Intra ocular tumour
- Persistent hyperplastic primary vitreous

IV. PREVENTION AND COUNSELING

Cataract is mostly age related and there is no effective way of preventing this condition. However there are certain secondary types of cataract which can be prevented.

- **Traumatic cataract** is very common in India especially among younger adults and children. Education about occupational safety and avoiding dangerous games (e.g. Bow and arrow) can reduce incidence of traumatic cataract.
- **Drugs**, commonly corticosteroids (either local or systemic) can produce cataract after prolonged use. This can be prevented by judicious application of the medicine.
- **Heredity** plays a role in some families. Multiple children in a family are either born with cataract or develop cataract at a very young age. Genetic counseling has some role in prevention. Early eye check up for all the children in those families can be advocated.
- **Maternal infections** during pregnancy, most commonly rubella, can give rise to congenital cataract. This can be prevented by immunizing the target age group of women.
- **Smoking** is known to be associated with nuclear cataract and hence preventing smoking is thought to be beneficial.
- **Ultraviolet-B radiation** has been associated with lens opacities and hence protecting eyes from sun has some role in prevention.
- **Diabetes mellitus** has a higher risk for cataract formation, and behavior modification to reduce the risk of developing type 2 diabetes may be effective.

V. OPTIMAL DIAGNOSTIC CRITERIA, INVESTIGATIONS, TREATMENT & REFERRAL CRITERIA

***Situation 1: At Secondary Hospital/ Non-Metro situation: Optimal Standards of Treatment in Situations where technology and resources are limited**

a) Clinical Diagnosis:

History:

Cataracts is an extremely common occurrence in the elderly. However, the key is to determine whether the cataract is the cause of functional disability for an individual. Careful history taking is important for assessing the quality of the visual impairment due to this disability. Occupational and functional needs of the patients should be taken into consideration before planning for surgical intervention.

History should also include ocular and systemic medications currently and previously used. Medical history about systemic diseases is important. Patients should be asked about any allergy to any food or medicine.

Ocular examination:

- i. Presenting Visual acuity** with and without present correction (if spectacle is available, the power of the present correction should be recorded) is determined
In advanced and mature cataract, perception and projection of light should be tested in all the four quadrants to rule out gross retinal problems.
- ii. Measurement of best-corrected visual acuity (with refraction when indicated).**
- iii. External examination** (lids, lashes, lacrimal apparatus, orbit).
Pressure should be applied over the sac to look for any regurgitation. If regurgitation is positive or dacryocystitis is suspected syringing of naso-lacrimal duct should be carried out. If duct is not free, with mucus or purulent discharge, dacryocystectomy or dacryocystorhinostomy is done and cataract surgery is done after one month.
- iv. Examination of ocular alignment and motility.**
- v. Assessment of pupillary shape, size and reaction:** This is a very important step and should be done very carefully, since it will help in determining the prognosis.
- vi. Slit-lamp biomicroscopy** of the anterior segment : Special emphasis should be made to examine the corneal endothelium for any guttata, pupil for pseudoexfoliation and the lens for any preoperative compromises on stability.
- vii. Dilated Examination** of the lens opacity may reveal the extent of visual impairment. For example, opacity in the visual axis may cause more functional visual deficit than a peripheral cataract posterior sub-capsular opacity may cause more symptoms of glare than a nuclear cataract. It helps in grading nuclear sclerosis and reveals any subluxation. Measuring amount of maximal dilation helps in planning the surgery.

- viii. Dilated examination of the fundus including, optic disc, macula and vitreous. If clarity of media allows then the peripheral retina should be examined. This helps in planning the prognosis of the surgical intervention.
- ix. **Indirect ophthalmoscopy** is indicated for known myopes, eyes with past history of trauma or retinal detachment in other eye.

b) Investigations:

- i. Measurement of intraocular pressure (preferably by Applanation tonometry)
- ii. Gonioscopy is not done as a routine. It can be performed if anterior chamber appears shallow, IOP is raised, presence of any sign that can be related to secondary glaucoma (e.g. pseudoexfoliation) or known cases of glaucoma.
- iii. Keratometry and A scan biometry: It should be performed in both eyes. It should be repeated if needed for unusual powers of IOL. Appropriate formula should be used according to cases. In case of scarred cornea and irregular surface of cornea, the K reading will not be possible. In this case the other eye should be taken into consideration.
- iv. Ultrasonogram of the posterior segment is indicated in traumatic cataracts, complicated cataracts and unilateral mature cataracts.
- v. Blood pressure
- vi. Screening for diabetes mellitus
- vii. Physician fitness is mandatory for cardiac patients and those with advanced systemic problems.
- viii. Patients who require general anesthesia need to undergo preanesthetic check up

c) Treatment:

Nonsurgical management

Patients with early cataract and all stages of nuclear cataracts may sometimes benefit by spectacles. If they do benefit, then subsequent follow ups can be planned to determine the timing of surgery, if required.

Management of a visually significant cataract is primarily surgical.

Indications for Surgery

An individual who is unable to carry out his/her desired activities due to dimness of vision for which cataract surgery is likely to restore the visual function is the prime indication for surgery. The other reasons for a cataract removal include the following:

- i. Clinically significant anisometropia in the presence of a cataract where cataract surgery is likely to facilitate binocularity.
- ii. Conditions in which the lens opacity is dense enough to interfere with evaluation and management of posterior segment conditions.
- iii. Lens induced ocular inflammation

iv. Lens induced glaucoma

Prognosis of surgery should be clearly explained to the patient in an understandable language.

Contra-indications for surgery:

- i) Patient not convinced about surgery
- ii) Patient has satisfactory functional vision either with or without visual aids
- iii) Cataract surgery is unlikely to improve vision
- iv) Patient is medically unfit

Anesthesia

Cataract surgery may be performed using a variety of anesthesia techniques that include general and local (regional) anesthesia (e.g., retrobulbar, peribulbar, periocular, sub-Tenons injection, topical, and intracameral). Local (regional) anesthesia is generally used, with or without sedation/analgesia. Traditionally, a retrobulbar or peribulbar anesthesia is used for most of the extracapsular cataract surgeries. Topical anesthesia can be used for patients undergoing clear corneal phacoemulsification. General anesthesia may be utilized if needed for children and patients with medical, psychosocial, or surgical indications. The planned mode of anesthesia should be decided after interaction between patient and the doctor. The process should be discussed with the patient so that he/she will know what to expect in terms of pain, discomfort, consciousness level, visual experiences, and complications.

Infection Prophylaxis

Greatest concern of an ophthalmologist after successful surgery is the endophthalmitis because of its serious consequences. Prevention remains the best measure to avoid it. Risk for endophthalmitis can be lessened by reducing the number of microorganisms on the ocular surface.

Prophylactic strategies that are commonly practiced include using topical antibiotic eye drops before surgery, applying 5% povidone iodine to the conjunctival cul de sac, preparing the periocular skin with 10% povidone iodine, careful sterile draping of the eyelid margins and eyelashes, and applying topical antibiotic eye drops after surgery.

Taking care of personal hygiene of the patient is very important. A thorough face washes before surgery is recommended. A surgeon should stick to strict aseptic techniques of surgeries.

Wound construction and closure should be meticulous. The surgery should end with a water tight incision and the surgeon should not hesitate to put sutures for security.

Surgical Techniques

The preferred method to remove a cataract is extracapsular extraction by either of the following techniques:

- a. Manual small incision cataract surgery
- b. Conventional extracapsular cataract extraction.

c. Phacoemulsification.

Visual results can be improved in all these types of surgeries by adhering to these common guidelines.

- A well planned incision that minimizes surgically-induced astigmatism.
- Safe and secure incision.
- Ensuring minimal loss of the corneal endothelial cells
- An appropriate posterior chamber IOL placed in the capsular bag.
- Avoiding trauma to iris, and other ocular tissues.

Incision location, size, and design may depend on several factors, including the patient's orbital anatomy, the type of IOL to be implanted, the role of the incision in astigmatism management, and surgeon preference and experience.

Manual small incision cataract surgery: This surgery is known to be extremely cost effective and visual improvements are comparable to other technique like phacoemulsification. This can be performed through superior incisions or temporal incisions. While superior incisions would be relatively safer with regard to the occurrence of endophthalmitis (since the incision is protected by the lids), it causes a higher astigmatism than the temporal incision. If temporal incisions have to be performed because of excessive preoperative astigmatism, care should be taken to fashion a longer internal corneal valve and the tunnel may be secured with a couple of nylon sutures. While any type of anterior capsular opening techniques can be used alongside this procedure, capsulorrhexis is preferred for better centration of the intraocular lenses and reduced inflammation. The cataractous lens can be taken out by irrigating vectis or by viscoexpression. Rigid or foldable lenses can be used as per the needs of the individual patient.

Extra capsular cataract surgery:

This surgery can be performed on hard cataracts, shallow anterior chambers or a bulky nucleus which may be difficult to express through a smaller incision. The decision to perform this surgery has to be decided upon by the needs of the patients along with the comfort level of the surgeon. The main drawback of this surgery is the increased need for postoperative follow ups which may be necessitated due to problems associated with sutures. Astigmatism can also be a significant issue which may warrant a suture removal, in order to optimize good uncorrected visual acuity.

Phacoemulsification: This surgery can be performed on early to intermediate level of hardness of cataract and produces rapid visual recovery. It also eliminates the risk of regional anesthesia since it may be performed topically. There is a learning curve for surgeons and once it is mastered, it can be employed in a significant number of cases. Harder cataracts may require an experienced surgeon and a machine with good fluidics.

However, this procedure is expensive and sometimes may be difficult to perform in certain types of cataracts.

In all these types of surgeries, there are chances of intraoperative complications. The most common causes are posterior capsular rupture and zonular dialysis. If this happens, the management of vitreous loss is crucial and should be managed by automated vitrectomy.

Intraocular Lenses

Posterior chamber IOLs (PC IOL) are the best choice unless contra-indicated. Other less commonly used lenses are Anterior Chamber and Scleral Fixated IOLs.

There is a wide range of PC IOLs with various value added optical and non optical characteristics. The most common materials used are polymethyl methacrylate (PMMA) and acrylic lenses. Even though they have comparable visual acuity outcomes, the rates of posterior capsular opacification (PCO) is lower in acrylic than PMMA. In patients, where there is more chance of posterior capsular opacification, as in children or diabetics or others, acrylic lenses may be preferred. Acrylic lenses can be hydrophobic or hydrophilic. Another parameter which has been thought to influence PCO occurrence is the design of the intraocular lenses. Square edged lenses are known to cause a lower incidence of PCO.

The ophthalmologist can choose any of these PC IOLs according to clinical indications, patient's visual need and affordability.

Anterior chamber lenses if used at all, should preferably be single-piece flexible open-loop. Effective and safe use of an anterior chamber lens depends on appropriate sizing. Anterior chamber IOLs are used most often when there is inadequate capsule support for a posterior chamber IOL. Placement of an anterior chamber lens requires a peripheral iridectomy and proper anterior vitrectomy.

The surgeon should have access to a variety of lens styles to select an appropriate IOL for an individual patient. Variations in the preoperative state of the eye, the surgical technique, patient expectation, and surgeon experience and preference affect the decision.

Post Operative Medication:

- i) Topical corticosteroid in a tapered fashion for 4 to 6 weeks.
- ii) Topical broad spectrum antibiotics for two weeks.
- iii) Cycloplegic drops, NSAID and anti glaucoma medications according to ophthalmologist's clinical decision.

Outcomes of cataract surgeries should be carefully monitored and results used for improvement of service. Presenting visual acuity, rather than best corrected visual acuity should be taken as the standard for assessing visual success.

Complications of Cataract Surgery should be carefully documented clearly explained to the patient in their own language and appropriate care given.

Standard Operating procedure

a. In Patient

- i. Patients coming from a long distance
- ii. Traumatic cataracts
- iii. Cataracts with intraoperative complications:
- iv. Pediatric patients requiring anesthesia.
- v. Mono ocular patients.

b. Out Patient

Pre operative investigations

Follow up

C. Day Care

Cataract surgery is ideally done as a day care procedure.

d) Referral criteria:

Cases needing specialized investigations before surgery (Specular microscopy)

Cases not manageable by the facilities available

Seeking second opinion

Complications needing specialized intervention (e.g. posterior vitrectomy)

Detection of posterior segment disorder after cataract removal

***Situation 2: At Super Specialty Facility in Metro location where higher-end technology is available**

a) Clinical Diagnosis: Same as situation 1

b) Investigations: Same as situation 1. Some additional investigations help in explaining prognosis and planning the surgery.

- b. Corneal topography, corneal pachymetry and , specular microscopy for associated corneal disease. Specular microscopy is helpful for planning surgery in hard cataracts and in patients with suspected compromised corneas.
- c. Fluorescein angiography is helpful in vascular retinopathies and maculopathies if clarity of media permits.
- d. An automated field analyzer evaluation may be helpful in preoperative diagnosis of co-existing glaucoma.
- e. Conjunctival swab culture for suspected infections
- f. Additional investigations for paediatric cataracts according to systemic conditions.

c) Treatment: Same as situation 1. Difficult cases should get individualized attention according to the merit of the case. Correction of pre-existing astigmatism can be taken either with selection of the incision sites, using toric intraocular lenses or by limbal relaxing incision. Patients desiring multifocal lenses should be counseled appropriately and then taken for surgery. Paediatric cataracts should be appropriately managed by trained surgeons.

Standard Operating procedure

a. In Patient

Patients preferring hospital stay for surgery because of distance and better care

Children undergoing cataract surgery

Patients with post operative complications that need institutional care

g. Out Patient

Pre operative investigations

Follow up

h. Day Care

Ideal for cataract surgery.

d) Referral criteria: Does not apply

VI. WHO DOES WHAT? AND TIMELINES

a. Doctor

Patient History is taken and a Clinical Examination performed

Documenting the medical record

Plan treatment guidelines and counsel patients

Advise and Perform surgery. Explain and assure patients if complications occur.

Follow up

Referral in needed.

Monitoring the infection control process

Monitoring outcome and share the results with the team

b. Nurse / Technician

Receive the patients and assist in clinical examination

Prepare the patients for surgery

Counseling whenever necessary

To monitor the patients who are admitted regarding application of eye drops and ensure compliance

To maintain separate inpatient and outpatient record

To maintain lab reports

Explain discharge advice to patients

VII. FURTHER READING / REFERENCES

1. Minassian DC, Mehra V. 3.8 million blinded by cataract each year: projections from the first epidemiological study of incidence of cataract blindness in India [Internet]. The British Journal of Ophthalmology. 1990 ;74(6):341-343. Available from: <http://www.ncbi.nlm.nih.gov/pubmed/2378840>
2. Murthy G, Gupta SK, John N, Vashist P. Current status of cataract blindness and Vision 2020: the right to sight initiative in India [Internet]. Indian Journal of Ophthalmology. 2008;56(6):489-494. Available from: <http://www.ncbi.nlm.nih.gov/pubmed/18974520>
3. Schein OD, Katz J, Bass EB, Tielsch JM, Lubomski LH, Feldman MA, et al. The value of routine preoperative medical testing before cataract surgery. Study of Medical Testing for Cataract Surgery [Internet]. The New England Journal of Medicine. 2000 ;342(3):168-175. Available from: <http://www.ncbi.nlm.nih.gov/pubmed/10639542>
4. Tseng VL, Greenberg PB, Scott IU, Anderson KL. Compliance with the American Academy of Ophthalmology Preferred Practice Pattern for Diabetic Retinopathy in a resident ophthalmology clinic [Internet]. Retina (Philadelphia, Pa.). 2010 ;30(5):787-794. Available from: <http://www.ncbi.nlm.nih.gov/pubmed/20168268>
5. Childhood cataract: magnitude, management, economics and impact [Internet]. Community Eye Health / International Centre for Eye Health. 2004 ;17(50):17-18. Available from: <http://www.ncbi.nlm.nih.gov/pubmed/17491800>
6. Preferred Practice Patterns : American Academy of Ophthalmology [Internet]. Available from: <http://one.aao.org/CE/PracticeGuidelines/PPP.aspx?sid=17ec4816-d6f4-4af7-81fc-64919982bac4>

RESOURCES REQUIRED

Situation	HUMAN RESOURCES	INVESTIGATIONS	DRUGS & CONSUMABLES	EQUIPMENT
1) Secondary level	1) Ophthalmologist - 1 2) OP Nurse - 1 3) Ophthalmic Assistant / 4) Optometrist 1 5) OT Nurse 6) Ward Nurse - 1 7) Counsellor - 1	1) B.P. recording 2) Tonometry 3) Sac syringing (if indicated) 4) Refraction 5) Biometry 6) USG B scan	1) Local anaesthetics 2) Antibiotics eye drops 3) Steroid eye drops 4) Mydriatics Miotics 5) Viscoelastics 6) Irrigating fluids 7) Intraocular lenses in various powers 8) Dyes to stain the capsule 9) Needles and syringes 10) Suture materials	1) Torch light 2) Trial set 3) Retinoscope 4) Slit lamp - biomicroscope -1 5) Direct Ophthalmoscope 6) +90 D lens 7) Indirect Ophthalmoscope with +20 D lens 8) A-Scan 9) Keratometer 10) BP apparatus 11) Schiotz Tonometer/ Applanation tonometer 13) Gonioscope 14) Operating microscope 15) Phacoemulsification machine 16) Anterior vitrectomy machine 17) Ultrasonogram 18) Microsurgical instruments 19) Nd: YAG laser machine (for capsulotomy)
2) Tertiary level	1) Experienced Ophthalmologist - 1 2) OP Nurse - 1 3) Ophthalmic Assistant / 4) Optometrist 1 5) OT Nurse 6) Ward Nurse - 1 7) Counsellor - 1	1) B.P. recording 2) ECG 3) Sac syringing (if indicated) 4) Refraction 5) Biometry 6) USG B- Scan 7) Specular microscopy 8) Pachymetry 9) FFA 10) HFA	Similar	Similar. In addition, a specular microscope and an automated field analyzer and equipments for documenting fundus pathologies.

NAME OF CONDITION: DIABETIC RETINOPATHY

I. When to suspect/ recognize?

a) Introduction:

Diabetes Mellitus (DM) has established itself as a pandemic disease, projected to affect 438 million people by 2030 AD.. The exponential growth in the incidence and identification of systemic diabetes has projected diabetic retinopathy as one of the leading causes of visual loss globally.

Diabetic retinopathy (DR) is one of the most frequent causes of blindness worldwide. In India DR which was the 17th cause of blindness but has now ascended to the 6th position. Diabetic retinopathy screening is directed towards improving health care services for persons with diabetes and diabetic retinopathy. It is symptomless in its early stage; screening is the only way to identify these patients to prevent them from going blind. The number of DR patients' increase with increase in the diabetic population, especially in developing countries where there is resource scarcity. Timely treatment can prevent vision loss which means that all of the diabetics have to be regularly examined for DR.

b) Case definition:

Diabetic Retinopathy is primarily a microvascular disease. For all practical purpose fundus changes like micro aneurysms, hard exudates and hemorrhages in diabetic patients are to be considered as diabetic retinopathy until proved otherwise. The most common cause of visual loss in diabetic patients is due to macular edema (DME) and advanced diabetic retinopathy (Vitreous hemorrhage and Retinal detachment).

II. Incidence of the condition in our country

Diabetic retinopathy is the leading cause of blindness among adults in the developing countries and is emerging as an important cause of blindness in the developing countries next to cataract. The longer the duration of diabetes higher is the incidence of developing diabetic retinopathy. In India, there is a paucity of data on the prevalence of DR in type 1 diabetes mellitus, as a registry for prevalence of type 1 diabetes is only recently being set up in the country. The prevalence of diabetic retinopathy in India, according to various population based studies is in between 17.6% to 34.1%. An earlier study done in a clinic-based population reported an overall prevalence of 14 per cent of DR in a diabetic population examination. Of these, non proliferative diabetic retinopathy (NPDR) accounted for 6 per cent, macular oedema accounted for 4 per cent and proliferative diabetic retinopathy accounted for rest of the 4 per cent.

III. DIFFERENTIAL DIAGNOSIS

Diabetic retinopathy may present like or coexist with other conditions and hence one needs to be careful with making a diagnosis. The following disorders may also present similarly and hence they have to be ruled out.

1. Hypertensive retinopathy
2. Vascular occlusive disorders
3. Inflammatory chorio retinopathy
4. Radiation retinopathy
5. Age related macular degeneration

IV. PREVENTION AND COUNSELLING

- All the diabetic patients are the potential candidates for vision impairment. Strict control of blood glucose level and other risk factors like hypertension, hypercholesterolemia, anaemia will retard the development and progression of DR..
- Screening of all “known diabetic patients” for DR at their primary point of contact, by physicians/diabetologists as most of the diabetic patients come to the ophthalmologists only after experiencing considerable vision loss will detect early cases.
- All pregnant women with diabetes should have dilated eye examinations during each trimester of their pregnancy to check for retinopathy
- Educating the community for regular eye check up and having good healthy diet, exercises and avoiding smoking goes a long way in preventing progression of diabetic retinopathy.

v. OPTIMAL DIAGNOSTIC CRITERIA, INVESTIGATIONS, TREATMENT & REFERRAL CRITERIA

***Situation 1: At Secondary Hospital/ Non-Metro situation: Optimal Standards of Treatment in Situations where technology and resources are limited**

a) Clinical Diagnosis:

History taking: Diabetic retinopathy often has no early warning signs. Patients usually presents with painless loss of vision. A thorough and complete history taking regarding past duration of diabetes, treatment history, family history and history of

associated risk factors is essential. Waiting for the diabetic to present with visual problems is not a good strategy. Many patients retain normal eyesight or experience a minimal (and sometimes unnoticeable) reduction of vision even in the presence of sight-threatening disease (diabetic maculopathy, proliferative disease). It is for this reason that screening for DR is mandatory. Sometimes, the patients may become aware of a problem (whether or not they are known diabetics) as in :

- A painless gradual reduction of central vision may be associated with any of the types of DR. The most common cause is diabetic macular oedema. Painless and gradual **visual loss** is also associated with coexistent cataract formation (diabetic or otherwise).
- Haemorrhages result in the sudden onset of dark, painless **floaters** which may resolve over several days.
- Severe vitreous haemorrhage may obscure the vitreous altogether resulting in a painless visual loss.
- An acute attack of glaucoma precipitated by rubeosis iridis is the one situation where the patient will present with acute pain; urgent referral is essential.

Examination: a complete and comprehensive examination using a direct ophthalmoscope, indirect ophthalmoscope and slit lamp with 90 dioptre lens is essential for diagnosing and staging diabetic retinopathy. Careful staging and appropriate management goes a long way in preventing visual loss due to diabetic retinopathy.

International clinical diabetic retinopathy disease severity scale

5 levels for Diabetic Retinopathy – none, mild, moderate, severe and proliferative

<i>Proposed Disease Severity Level</i>	<i>Findings Observable upon Dilated Ophthalmoscopy</i>
No Apparent retinopathy	<ul style="list-style-type: none"> • No abnormalities
Mild non-proliferative diabetic retinopathy	<ul style="list-style-type: none"> • Microaneurysms only
Moderate non-proliferative diabetic retinopathy	<ul style="list-style-type: none"> • Microaneurysms . dot shaped haemorrhages and hard exudates but less than severe NPDR
Severe non-proliferative diabetic Retinopathy	<p>Any of the following :</p> <ul style="list-style-type: none"> • More than 20 intra-retinal hemorrhages in each of 4 quadrants • Definite venous beading in 2+quadrants • Prominent IRMA in 1+ quadrant

And no signs of proliferative retinopathy

Proliferative diabetic retinopathy

One or more of the following:

- Neovascularization of the Disc or else where
- Vitreous / preretinal hemorrhage

International clinical diabetic retinopathy disease severity of diabetic macular edema

2 Major levels, with subcategories for diabetic macular edema

Proposed Classification	Findings Observable upon Dilated Ophthalmoscopy
Diabetic Macular Edema Absent	No retinal thickening or hard exudates in posterior pole
Diabetic Macular Edema Present	Some retinal thickening or hard exudates in posterior pole

Diabetic macular edema is classified into three types based on FFA findings:

- Focal exudative maculopathy
- Diffuse exudative maculopathy
- Ischaemic maculopathy.

Term clinically significant macular edema(CSME) is considered ,if one of the following criteria are present on :

- ✓ Retinal edema or Thickening of the retina at or within 500 μ of the centre of the fovea.
- ✓ Hard exudates at or within 500 μ of the centre of fovea associated with adjacent retinal thickening
- ✓ Retinal thickening of size 1DD, at least a part of which is within 1DD of the foveal centre.

Advanced diabetic eye disease.

- ✓ Vitreous and preretinal haemorrhages occur as new vessels grow forward from the retina and enter the vitreous where they bleed easily.
- ✓ Haemorrhages appear as reddish/dark opacities; preretinal or subhyaloid haemorrhages.
- ✓ Retinal detachment.
- ✓ Rubeosis iridis .

b) Investigations:

Visual acuity test: This is done as a baseline investigation. Amsler's grid evaluation is also useful to monitor macular disease

Fundus examination with direct and indirect ophthalmoscope. The direct ophthalmoscope examination is essential for both community setting and general physicians. Indirect ophthalmoscopy is done in case of advanced diabetic retinopathy.

Slit lamp biomicroscopy with 78D or 90D is gold standard for diagnosis of diabetic maculopathy.

Fundus photography and Digital Retinal Screening Programs: Systematic programs for the early detection of eye disease including diabetic retinopathy are becoming more common, where all people with diabetes mellitus are offered retinal screening at least annually. This involves digital image capture and transmission of the images to a digital reading center for evaluation and treatment referral.

Fluorescein Angiography

This is a magnified photography of the retina involving the use of an injectable dye. It helps to classify the condition and to record changes in the retinal blood vessels. It is also useful to rule out the ischemia of the macular region. The first angiogram is usually done during the first evaluation. Subsequent angiograms may be done to assess the progression of diabetic retinopathy and to decide on the mode of treatment

C. Treatment:

Medical Care

Glucose control: One of the clinical trials, the Diabetes control and complications trial (DCCT) has found that intensive glucose control in patients with insulin dependent diabetes mellitus (IDDM) has decreased the incidence and progression of diabetic retinopathy. Glycosylated hemoglobin levels of 6- 7% are ideal to prevent or at the very least to minimize the long-term complications of DM, including DM retinopathy.

Surgical Care

Laser photocoagulation is the standard technique for treating diabetic retinopathy. In general, it is advised for patients with high-risk PDR, CSME, or neovascularization of the anterior chamber angle. Either argon or diode laser can be used for photocoagulation. Laser photocoagulation techniques can be classified as panretinal, focal, or grid. Panretinal photocoagulation, also referred to as scatter

photocoagulation, is used for the treatment of proliferative diabetic retinopathy. It may be done in more than one session. Focal and grid photocoagulation are used for the treatment of diabetic macular edema.

DIABETIC MACULOPATHY:

Argon laser photocoagulation:

Indications:

- All eyes with CSMO should be considered for laser photocoagulation irrespective of the level of visual acuity because treatment reduces the risk of visual loss by 50%.
- Pre-treatment FFA is useful to delineate the area of leakage and to detect ischaemic maculopathy which carries a poor prognosis.

Focal treatment – burns are applied to microaneurysms and microvascular lesions in the centre of rings of hard exudates located 500 -3000µm from the centre of macula .The spot size is 50 - 100 µm , exposure time 0.1 sec with sufficient power to obtain gentle whitening or darkening of the lesions.

Grid treatment – burns are applied to areas of diffuse retinal thickening more than 500 µm from the centre of the macula and 500 µm from the temporal margin of the optic disc.the spot size is 100 µm and exposure time is 0.1 sec giving a very light intensity burn.

PROLIFERATIVE DIABETIC RETINOPATHY:

Panretinal photocoagulation:

Laser treatment is aimed at inducing involution of new vessels and preventing visual loss.

Indications:

- PDR with HRCs
- Neovascularisation of irids
- Severe NPDR associated with :
 - Poor compliance for follow up
 - Before cataract surgery/YAG capsulotomy
 - Renal failure
 - Pregnancy
 - One-eyed patient

The recommended therapy is 1200-2000 burns 500µm in diameter delivered through the goldmann lens or the same number of 200 µm burns delivered through volk lens. The burns should be intense enough to whiten the overlying retina,which usually requires a power of 200 – 600mW and duration of 0.1 second.

Treatment of Diabetic Retinopathy

	Proliferative Retinopathy	Clinically Significant Macular Oedema Retinal microaneurysms	Clinically Significant Macular Oedema Retinal thickening & areas of non-perfusion
Type of laser	Argon green	Green or yellow (577) argon laser	Green or yellow (577) argon laser
Spot size	200-500µm	50 - 100µm	100µm
Power	0.2 - 0.8 watts	0.1 - 0.3 watts	0.1 - 0.3 watts
Duration	0.2 seconds	0.1 seconds	0.05 - 0.1 seconds
End point	Faint white burn at level of retinal pigment epithelium (RPE)	Faint whitening of RPE or darkening of microaneurysm	Very faint white burn at level of retinal pigment epithelium (RPE)
How to treat	Do not overlap burns Do not treat within temporal arcades Do not treat within one disc diameter of optic disc Do not treat within two disc diameters temporal to fovea	Apply burns directly to microaneurysms	Place burns at least one burn width apart, to make a grid which includes the area of retinal thickening Do not treat within 500m of fovea at first session
Number of burns	Approximately 2,000	Variable	Variable
Number of sessions	Two sessions. Treat the lower half of the retina first (1,000 burns)	One	One
Other	Topical steroids and mydriatic after treatment		
Signs of resolution	New vessels regressing Reduced blood flow in new vessels More fibrous tissue Less beading of retinal veins	Less retinal thickening/exudate	Less retinal thickening

Indications for retreatment	Fresh new vessels on the optic disc or elsewhere in the fundus Failure of new vessels to regress	Significant macular oedema after 3 months	Significant macular oedema after 3 months
Retreatment	Between previous burns, avoiding retinal vessels	Do not retreat areas lying in the macular-papular bundle	Treat to within 100m of the edge of the foveal avascular zone

Standard Operating procedure

- a. In Patient – No need
- b. Day Care – Not applicable
- c. Out Patient Procedure:
 - Screening, diagnosis and disease management.
 - Providing treatment for diabetic retinopathy with lasers and other medical treatment.

d) Referral criteria:

If the patients are requiring further investigations/treatment such as vitrectomy, Retinal detachment surgery is referred to the tertiary level eye care provider.

***Situation 2: At Super Specialty Facility in Metro location where higher-end technology is available**

- a) **Clinical Diagnosis:** Same as situation 1
- b) **Investigations:** Same as situation 1. Some additional investigations help in explaining prognosis and planning the surgery (example Optical Coherence Tomography(OCT))
- c) **Treatment:**

General Management Recommendations:

Level of Retinopathy	Evaluation	Treatment Strategies		
	Fluorescein Angiography	PRP	Focal	Follow-up (months)
Mild NPDR				
No macular edema	No	No	No	12
Macular edema	No	No	No	4-6

CSME	Yes	No	Yes	2-4
Moderate NPDR				
No macular edema	No	No	No	6-8
Macular edema (not CSME)	No	No	No	4-6
CSME	Yes	No	Yes	2-4
Severe NPDR				
No macular edema	No	Rarely	No	3-4
Macular edema (not CSME)	No	Occasionally after focal	Occasionally	2-3
CSME	Yes	Occasionally after focal	Yes	2-3

Standard Operating procedure:

The operating procedures like vitrectomy, retinal detachment surgeries and other intravitreal medications are done for those cases of advanced retinal detachment which have been referred from secondary eye care.

Surgical treatment in advanced diabetic eye disease:

Laser photocoagulation allows effective treatment of moderate to severe PDR .Some eyes can progress to tractional retinal detachment and vision loss. Standard laser cannot be performed in eyes with vitreous hemorrhage precluding visualization of the retina.

Pars plana vitrectomy is the main method of treating severe complications of PDR. The diabetic retinopathy vitrectomy study (DRVS) showed that early vitrectomy was beneficial for patients with visual acuity of 6/120 or better and having one of the following: (1) severe neovascularization and fibrous proliferation; (2) fibrous proliferation and moderate vitreous hemorrhage; or (3) moderate neovascularization, severe fibrous proliferation, and moderate vitreous hemorrhage.

Role of vitrectomy:

The most common indications for diabetic vitrectomy are :

1. Severe nonclearing vitreous haemorrhage,
2. Traction retinal detachment recently involving the macula,
3. Combined traction and rhegmatogenous detachment,
4. Progressive fibrovascular proliferation,
5. Rubeosis iridis and vitreous haemorrhage, with opacity preventing adequate laser.

The DRVS study concluded that:

1. Early vitrectomy provides a greater chance for prompt recovery of visual acuity in eyes with recent severe vitreous haemorrhage.
2. For patients with IDDM, in whom severe vitreous haemorrhage occurred after a shorter duration of diabetes, early vitrectomy provides a greater chance of recovering good visual acuity
3. DRVS findings support early vitrectomy in eyes known or suspected to have very severe PDR as a means of increasing the chance to restoring or maintain good vision.
4. Vitrectomy for traction retinal detachment or macular traction: Progressive tractional RD threatening or involving the macula must be treated without delay.

Other medications that are being used in clinical practice and in clinical trials include intravitreal bevacizumab (Avastin) and ranibizumab (Lucentis), These medications are VEGF antibodies and antibody fragments, respectively. They can help to reduce diabetic macular edema and also neovascularization of the disc or retina

a. Out Patient

Diagnosis and disease management

- a. Investigations for diabetic retinopathy
- b. Fluorescein angiography
- c. Photography-scan ultrasonography
- d. Lasers for diabetic retinopathy

b. In Patient:

- Advanced diabetic retinopathy
- Patient who need surgical treatment
- Patient with neovascular glaucoma, complicated cataract and other ocular complication secondary to diabetes has to be admitted for further management.

c. Day care

d) Referral criteria:

Not applicable

VI. Who does what? And timelines

Doctor

- history taking, clinical examination ,treatment plan
- Follow up schedule
- Need additional skills in indirect ophthalmoscopy,
- Interpretation of Fluorescein angiography.
- Handling retinal laser photocoagulation
- Surgical management of DR.

Nurse

- Assist in conducting diagnosis and examination of patient and preparing them for treatment.
- Attend and assist in diabetic retinopathy screening camps.

Technician

- Undergo additional training in fundus photography and fluorescein angiography
- FFA - Indications, technique complications -Basic ultrasonography

VII. FURTHER READING / REFERENCES

1. Alfaro DV, Liggett PE, Mieler WF, Quiroz-Mercado H, Jager RD, Tano Y. Age-Related Macular Degeneration: A Comprehensive Textbook [Internet]. 1 ed. Lippincott Williams & Wilkins; 2005. Available from: <http://www.amazon.com/dp/0781738997>
2. Kempen JH, O'Colmain BJ, Leske MC, Haffner SM, Klein R, Moss SE, et al. The prevalence of diabetic retinopathy among adults in the United States [Internet]. Archives of Ophthalmology. 2004 ;122(4):552-563. Available from: <http://www.ncbi.nlm.nih.gov/pubmed/15078674>
3. Roy MS, Klein R, O'Colmain BJ, Klein BE, Moss SE, Kempen JH. The prevalence of diabetic retinopathy among adult type 1 diabetic persons in the United States [Internet]. Archives of Ophthalmology. 2004 ;122(4):546-551. Available from: <http://www.ncbi.nlm.nih.gov/pubmed/15078673>
4. Silva PS, Cavallerano JD, Sun JK, Aiello LM, Aiello LP. Effect of systemic medications on onset and progression of diabetic retinopathy [Internet]. Nature Reviews. Endocrinology. 2010 ;6(9):494-508. Available from: <http://www.ncbi.nlm.nih.gov/pubmed/20664533>
5. Wild S, Roglic G, Green A, Sicree R, King H. Global prevalence of diabetes: estimates for the year 2000 and projections for 2030 [Internet]. Diabetes Care. 2004 ;27(5):1047-1053. Available from: <http://www.ncbi.nlm.nih.gov/pubmed/15111519>
6. Grading diabetic retinopathy from stereoscopic color fundus photographs--an extension of the modified Airlie House classification. ETDRS report number 10. Early Treatment Diabetic Retinopathy Study Research Group [Internet]. Ophthalmology. 1991 ;98(5 Suppl):786-806. Available from: <http://www.ncbi.nlm.nih.gov/pubmed/2062513>

RESOURCES REQUIRED

Situation	HUMAN RESOURCES	INVESTIGATIONS	DRUGS & CONSUMABLES	EQUIPMENT
1 Secondary level	1) Ophthalmologist – 1 2) Nurse - 1 3) Technician - 1 4) Counsellor - 1 5) Field coordinator - 1	1) FFA 2) USG 3) Blood sugar	1) Fluorescing dye 2) Antiangiogenic injections 3) Mydriatics 4) Neeles and syringes	1) FFA including retinal camera & imagenet - 1 2) Ultrasonography 3) Indirect ophthalmoscope with 20D lens-1 4) Frequency double YAG laser with endolaser probe/slit lamp delivery with all accessories- 1
2. Tertiary level	1) Ophthalmologist – 2 2) Retina specialist - 2 3) Nurse - 3 4) Technician – 1 5) Counsellor - 2 6) Field coordinator - 1	1) FFA 2) USG 3) OCT 4) Blood sugar	1) Fluorescing dye 2) Antiangiogenic injection 3) Irigating solution 4) Intraocular gas and silicon oil 5) Mydriatics 6) Needle s and syringes 7) Suture materials	1) FFA including retinal camera & imagenet - 1 2) Ultrasonography-1 3) Indirect ophthalmoscope with 20D lens -1 4) Frequency double YAG laser with endolaser probe/slit lamp delivery with all accessories- 1 5) OCT – 6) ERG – 1 Surgical equipment: <ol style="list-style-type: none"> 1. Vitrectomy console 2. VR surgical instrument 3. Surgical operating microscope with CCTV attachment and observerscope–1

NAME OF CONDITION: AGE RELATED MACULAR DEGENERATION (AMD)

I. WHEN TO SUSPECT/ RECOGNIZE?

a) Introduction:

Age related macular degeneration (AMD) is one of the leading causes of low vision in developed countries. However, this condition is being increasingly recognized in our country in recent times. It has been found to have significant impact on the individual's quality of life. As the geriatric population of the country increases, courtesy of improved medical services, the number of people afflicted with AMD will proportionately, increase. Understanding the epidemiology, risk factors and treatment modalities of AMD is essential to improve the overall ocular health of the individual.

b) Case definition:

Age-related macular degeneration is defined as a degenerative disease characterized by the presence of the following: drusen; retinal pigment epithelium (RPE) abnormalities; RPE and associated neurosensory detachment; retinal haemorrhages; choroidal neovascularization; geographic atrophy, or retinal fibrous scarring in the absence of other retinal disorders.

- Drusen are localized, discrete whitish-yellow deposits lying between the basement membrane of the RPE and Bruch's membrane.
- Abnormalities of the RPE include hyperpigmentation or hypopigmentation, without any visibility of the choroidal vessels as associated with drusen.
- Geographic atrophy is defined as sharply delineated, confluent areas of hypopigmentation or depigmentation or apparent absence of the RPE in which choroidal vessels are more visible than in surrounding areas.
- Choroidal neovascularization is the growth of new blood vessels from the choroid, characterized morphologically by greenishgrey subretinal tissue, with or without subretinal haemorrhage or exudates.
- Dry AMD is defined as the presence of drusen and RPE abnormalities, including geographic atrophy.
- Wet AMD is defined as the presence of any of the following: RPE detachments or serous detachment of the sensory retina; subretinal or sub-RPE neovascular membranes; subretinal haemorrhages, and epiretinal, subretinal, intraretinal or sub-pigment epithelial scar or glial tissue or fibrin-like deposits.

Several classification systems have evolved over the years to define this entity and describe the various stages. The commonest ones used in epidemiological studies is

the Wisconsin ARMD grading system. The stages as defined by the Wisconsin group are:

Category 1: No AMD

No or a few small drusen(<63 microns in diameter)

Category 2: Early AMD

Many small drusen or a few intermediate sized drusen(63-124 microns in diameter) or macular pigmentary changes

Category 3: Intermediate AMD

Extensive intermediate drusen or at least one large drusen(≥ 125 microns), or geographic atrophy not involving the foveal center.

Category 4: Advanced AMD

Geographic atrophy involving the foveal center (atrophic or dry AMD)

Choroidal neovascularisation (wet AMD) or evidence for neovascular maculopathy (Sub retinal haemorrhage, serous retinal or RPE detachments, lipid exudates or fibrovascular scar).

II. INCIDENCE OF THE CONDITION IN OUR COUNTRY:

Several incidence and prevalence studies have been undertaken in various parts of India. These studies show an overall prevalence of AMD in India for early AMD is similar to that seen in western countries. However, the incidence of late AMD is found to be comparatively less. The prevalences of early and late age-related macular degeneration were 2.7% (95% CI, 2.2%-3.2%) and 0.6% (95% CI, 0.4%-0.8%), respectively (ACES 2004). Another study found the overall prevalence of AMD in south India to be 1.87% (APEDS 2005). Most recent data show a prevalence of blindness in late AMD of 1.8% (INDEYE study). This data indicates that the condition is rapidly increasing or is being increasingly recognized and is a significant health hazard and cause for blindness in our country.

III. DIFFERENTIAL DIAGNOSIS

The widely variable clinical presentation and sometimes unpredictable natural history are important confounding features in the correct diagnosis of AMD. Variable degenerative and dystrophic diseases of the retina and RPE, in which pigmentary mobilization or lipofuscin accumulation are major findings, share fundamental clinical features with the dry form of the disease.

The common differential diagnoses for dry AMD are

- Bests disease
- Pattern dystrophies of RPE
- Cuticular drusen, pseudo vitelliform detachment
- Stargardts disease.
- Central serous retinopathy.
- Chloroquine toxicity

- Dominant drusen
- Membranoproliferative glomerulonephritis Type II

Wet AMD has to be differentiated from

- Angioid streaks
- Sub retinal neovascular membranes
- Myopic CNVM
- Choroidal melanoma
- Choroidal rupture
- Parafoveal telangiectesia.

IV. PREVENTION AND COUNSELLING

- Prospective, randomized, controlled clinical trials support the use of antioxidant vitamins and minerals in patients with intermediate-risk AMD to reduce the rate of progression to advanced AMD.
- The role of antioxidant supplements in the prevention of AMD or in slowing progression of AMD for those with the early stages of the disease has not been adequately answered in randomized controlled trials.
- Patients with intermediate AMD in one or both eyes and patients with advanced AMD in one eye only or vision loss due to AMD in one eye should consider taking antioxidants with zinc on a daily basis
- Self screening by the use of Amslers grid should be taught to the patients, specially those in stage of intermediate AMD. The warning signs have to be explained to them in order to recognise the shift to wet AMD earlier.
- Regular follow up of the patients is essential. The interval depends on the stage of AMD.
- Rehabilitation of the patients who are already in the stage of advanced AMD by use of low vision aids should form an important part of AMD management protocol. .

V.OPTIMAL DIAGNOSTIC CRITERIA, INVESTIGATIONS, TREATMENT & REFERRAL CRITERIA

***Situation 1: At Secondary Hospital/ Non-Metro situation: Optimal Standards of Treatment in Situations where technology and resources are limited**

The role of secondary level in diagnosis and treatment of AMD include:

- Early diagnosis
- Treatment
- Prevention of progression

- Rehabilitation
- Patient education
- Human resource development
- Documentation.

a) Clinical Diagnosis:

Diagnosis is mostly clinical. It requires good ophthalmic examination set up with basic instruments such as slit lamp, 90D lenses, Indirect ophthalmoscope.

In its earliest stages, macular degeneration may cause the following symptoms:

- ☐ Blurry distance and/or reading vision;
- ☐ Distorted vision - straight lines will appear bent, crooked or irregular;
- ☐ Dark gray spots or blank spots in vision;
- ☐ Size of objects may appear different for each eye;
- ☐ Colours do not look the same for each eye.

The disease can be classified according to the stages mentioned earlier and steps for prevention, treatment, rehabilitation or referral as required can be done.

b) Investigations:

Diagnostic tools such as slit lamp, indirect ophthalmoscope; procedures such as fluorescein angiography, Indocyanine green angiography, autofluorescence and optical coherence tomography are used to obtain optimal diagnosis.

- 1. Amsler's grid:** is used to check macular vision and to detect any damage or disease to the macula, which is located at the center of the retina. Basically, it is a grid that consists of evenly spaced vertical and horizontal lines, resembling a piece of graph paper, with a large dot in the middle. While staring or focusing at the dot, patient will be asked if he sees any wavy lines or missing spaces. Any distortion in the perception of the grid could indicate the presence of macular disease or degeneration.
- 2. Fundus Fluorescein Angiography (FFA):** This is a test involving photography of retina after injecting fluorescein dye. This is usually performed to detect wet AMD. It helps to decide the mode of treatment.
- 3. Indocyanine Green Angiography (ICG):** This is another test done using injectable dye. The helps to highlight the choroidal features well. As there is development of choroidal neovascular membrane in AMD, ICG angiography has good diagnostic value.
- 4. Optical Coherence Topography (OCT):** OCT is a non-invasive, fast, non-contact imaging technique which readily displays intra-retinal, subretinal and sub-RPE fluid, but is limited in its imaging of the choroid due to poor penetration. Its role in CNV detection has a good sensitivity and specificity.

c) Treatment:

Laser photocoagulation: laser photocoagulation is usually reserved for CNV outside the fovea and for treatment of the variants of exudative AMD, including retinal angiomatous proliferation (RAP) and polypoidal choroidal vasculopathy.

Photodynamic therapy (PDT)

Indications:

1. Sub foveal predominant classic CNVM (classic CNVM >50% of the area of entire lesion)
2. Small pure occult CNVM
3. Large occult CNVM with definitive decrease in visual acuity.
4. Mixed lesions

Technique : vertiporfirin (6 mg/kg BW) is infused intravenously over 10 minutes. non thermal laser is applied for CNVM for 83 sec ,spot size 1000µ larger than greater linear dimension of the lesion to ensure complete closure.

Trans pupillary thermotherapy: uses infra red laser beam to induce neovascular tissue regression by hyper thermia but not coagulation.

Technique : over lapping one minute application of 3mm diode laser beam over the area of neovascular tissue ,adjust the power so that retinal blanching does not develop before 45 seconds.

Anti angiogenic agents:

- (i) Bevacizumab
- (ii) Ranibizumab
- (iii) Pegatinib sodium.

These medications are VEGF antibodies and antibody fragments, respectively. They can help to induce regression of new vessel.

- Regular follow up once in 6 months if patient is in dry AMD stage. No specific treatment. Patient is taught about Amsler grid and its use in this stage.
- Anti oxidant and Zinc supplementation if patient is in intermediate AMD stage.
- Referral to higher centre for treatment if patient is in exudative AMD stage.
- Rehabilitation with low vision aids if there is atrophy or scarring.

Standard Operating procedure

- a. **In Patient:** Not necessary
- b. **Out Patient:** Yes. For investigations and diagnosis.
- c. **Day Care:** Yes. For treatment.

d) Referral criteria:

- ☐ Exudative AMD
- ☐ Difficulty in diagnosing with FFA

***Situation 2: At Super Specialty Facility in Metro location where higher-end technology is available**

a) Clinical Diagnosis:

Using slit lamp, 90 D lens and indirect ophthalmoscope.

b) Investigations:

FFA

OCT

ICG angiography

c) Treatment:

- Laser
- PDT
- TTT
- Anti VEGF therapy: Intra vitreal bevacizumab
Intravitreal ranibizumab
Intravitreal pegatanib sodium.

Standard Operating procedure

- a. **In Patient:** Not necessary
- b. **Out Patient:** This is the standard operating procedure for diagnosis and treatment such as laser, PDT.
- c. **Day Care:** This is required if intra vitreal injections are to be the mode of treatment.

V. WHO DOES WHAT? AND TIMELINES

Designation	Role
Doctor	Diagnosis of AMD Interpretation of investigations Treatment: Requires skills in Intra vitreal injection and laser delivery.
Nurse	Vision recording Counselling for treatment and prevention Maintaining proper follow up
Technician	Fundus photography for documentation Performing FFA, ICGA,OCT .

VI. FURTHER READING / REFERENCES

1. Bird AC, Bressler NM, Bressler SB, Chisholm IH, Coscas G, Davis MD, et al. An international classification and grading system for age-related maculopathy and age-related macular degeneration. The International ARM Epidemiological Study Group [Internet]. Survey of Ophthalmology. 1995 ;39(5):367-374. Available from: <http://www.ncbi.nlm.nih.gov/pubmed/7604360>
2. Krishnaiah S, Das T, Nirmalan PK, Nutheti R, Shamanna BR, Rao GN, et al. Risk factors for age-related macular degeneration: findings from the Andhra Pradesh eye disease study in South India [Internet]. Investigative Ophthalmology & Visual Science. 2005 ;46(12):4442-4449. Available from: <http://www.ncbi.nlm.nih.gov/pubmed/16303932>
3. Nirmalan PK, Katz J, Robin AL, Tielsch JM, Namperumalsamy P, Kim R, et al. Prevalence of vitreoretinal disorders in a rural population of southern India: the Aravind Comprehensive Eye Study. [Internet]. Archives of ophthalmology. 2004 ;122(4):581-6. Available from: <http://www.ncbi.nlm.nih.gov/pubmed/15078677>

RESOURCES REQUIRED

Situation	HUMAN RESOURCES	INVESTIGATIONS	DRUGS & CONSUMABLES	EQUIPMENT
1) Secondary level	1) Ophthalmologist - 1 2) OP Nurse 1 3) Refraction nurse - 1 4) FFA technician-1 (optional)	1) Amsler grid 2) Fundus fluorescein angiography	1) Dilating drops 2) Fluorescein dye 3) Needles and syringes	1) Slit lamp 2) 90 D lens 3) 20 D lens 4) Indirect 5) Ophthalmoscope Fundus camera
2) Tertiary level	1) Ophthalmologist - 1 2) OP Nurse 2 3) Refraction nurse - 1 4) FFA technician-1	1) FFA 2) OCT 3) ICGA	1) Dilating drops 2) Fluorescein dye ICG dye 3) Anti VEGF injections 4) Needles and syringes 5) Suture materials	1) Slit lamp 2) 90 D lens 3) 20 D lens 4) Indirect 5) Ophthalmoscope 6) Fundus camera 7) OCT machine 8) Laser equipment 9) Operating microscope

NAME OF CONDITION: GLAUCOMA

Glaucoma is a group of eye diseases with multi-factorial etiology characterized by an acquired loss of retinal ganglion cells manifesting as progressive optic neuropathy with morphological abnormalities in the optic nerve head and retinal nerve fiber layer and visual field effects in which intraocular pressure (IOP) is a major risk factor. In short, it is a pressure sensitive optic neuropathy. It is estimated there are more than 60 million glaucoma cases worldwide of which 12 million are in India. With a rapidly growing ageing population in India, this figure will increase to 16 million by 2020 and population-based studies in India suggest that more than 90% of glaucoma cases in our country remain undiagnosed. Hence glaucoma is a significant public health problem of our country and requires a concerted effort on part of the health care community to counter irreversible blindness caused by the disease.

There are three major theories regarding the pathogenesis of glaucoma: -

- Mechanical (IOP related damage),
- Vascular (decrease in blood supply to optic nerve head) and
- Biochemical (decrease in neurotrophic factors / increased levels of neurotoxins)

Therefore the three possible therapeutic options would be to decrease IOP, increase perfusion to the optic nerve head and provide neuro-protection to retinal ganglion cells. As of today the only option available to us is to decrease IOP and treat systemic conditions which may compromise the vascular supply to the optic nerve head decreasing the perfusion pressure.

Compliance to therapy, affordability of treatment and family history should be ascertained and all siblings of a glaucoma patient encouraged to get their eye checked up.

The following table gives the guidelines of glaucoma management in general:

Goals for Glaucoma Management

To achieve target IOP and reduce IOP fluctuations with minimal possible medications
To administer glaucoma medication which have the least side effects on the quality of life of the patient
To achieve this treatment at an affordable and sustainable cost for the patient
Monitor the structure and function of the optic nerve for further damage and adjust the target IOP to a lower level if deterioration occurs.
To treat non-IOP dependant systemic factors (systemic hypertension, low diastolic perfusion pressures [diastolic blood pressure minus IOP], diabetes, hyperlipidemia, vasospasm) which may contribute to the development and worsening of glaucomatous optic neuropathy.
To educate and involve the patient and his family in the management of the disease process

NAME OF CONDITION: ANGLE CLOSURE DISEASE

I. WHEN TO SUSPECT/ RECOGNIZE?

a) Introduction:

'Angle closure' implies either appositional or synechial closure of the anterior chamber angle. This iridotrabecular contact (ITC) may or may not be associated with raised intraocular pressure (IOP) or glaucomatous optic neuropathy. Various mechanisms are postulated in pathogenesis of primary angle closure (PAC), of which pupillary block constitutes a key element. This results in obstruction of aqueous flow from posterior chamber of eye to the anterior chamber, resulting in anterior bowing of iris and consequent crowding of the chamber angle. Prolonged apposition may lead to mechanical or functional obstruction to trabecular meshwork outflow and may result in formation of peripheral anterior synechiae (PAS), causing raised intraocular pressure and glaucomatous optic neuropathy. There are various other causes of ITC including position and thickness of ciliary body, iris thickness, lens position and thickness. Secondary angle closure can also occur in neovascularization, inflammation and gas or oil tamponade of posterior chamber besides other causes.

b) Case definitions:

Angle closure disease had been classified earlier on the basis of presence or absence of symptoms into three subtypes as acute, intermittent and chronic angle closure. Intermittent and chronic angle closure have since then been reclassified into PAC and PACG as described above.

In recent years, there has been an effort to standardize diagnostic definitions of angle closure glaucomas based on suggestions by International Society of Geographical and Epidemiological Ophthalmology (ISGEO).¹ More emphasis is placed on structural (optic nerve head) and functional (visual field) changes to diagnose glaucoma. The amount of ITC (apposition between iris and posterior trabecular meshwork) required to define primary angle closure has been debated. By consensus, an eye with 180 degrees or more of ITC in dim illumination and non compressive gonioscopy is classified as one having primary angle closure disease.² Based on associated findings this is further subclassified as:

Primary Angle Closure Suspect (PACS)

An angle where more than 180° of the posterior trabecular meshwork cannot be seen under dim illumination, which, in the presence of normal intraocular pressure and no disc/ field changes suggestive of glaucoma and no peripheral anterior synechiae is classified as primary angle closure suspect.

Primary Angle Closure (PAC)

An eye with PACS having peripheral anterior synechiae and/or raised intraocular pressure with no glaucomatous optic neuropathy is classified as primary angle closure.

Primary Angle Closure Glaucoma (PACG)

An eye with PACS having evidence of glaucomatous damage in the form of glaucomatous disc changes and/or visual field changes is classified as primary angle closure glaucoma. It is not mandatory to have raised intraocular pressure or peripheral anterior synechiae.

Secondary Angle Closure

Secondary angle closure occurs from known causes which may or may not be associated with pupillary block.

Etiology:

Secondary angle closure with pupillary block:

- Swollen lens induced (Phacomorphic)
- Anterior lens subluxation/ dislocation
- Trauma, laxity of zonules, Marfan's syndrome
- Miotic induced secondary closure
- Miotics relax the ciliary muscle, causing forward movement of iris-lens diaphragm and may precipitate angle closure.
- Synechiae between iris and crystalline lens/ intraocular lens/cornea/ vitreous
- These cause a physical obstruction to flow of aqueous from the posterior to anterior chambers and may result in 'iris bombe'.
- Aphakic pupillary block

Secondary angle closure with anterior pulling mechanism without pupillary block

- Neovascular glaucomas
- Iridocorneal endothelial syndromes
- Inflammation
- Post penetrating keratoplasty
- Epithelial downgrowth
- Aniridia

Secondary angle closure with posterior pushing mechanism without pupillary block

- Ciliary block glaucoma
- Iridociliary cysts

- Intravitreal silicon oil/ gas induced
- Ciliochoroidal effusions
- Suprachoroidal haemorrhage
- Scleral buckling

II. INCIDENCE OF THE CONDITION IN OUR COUNTRY

Reported prevalence differences between studies occur due to differing methodology and classification of angle closure in these studies. The estimates of number of people with angle closure glaucoma in 2010 were 15.4 million for the world with India accounting for 3.7 million cases. Estimates of angle closure glaucoma in 2020 will rise to 21 million for the world and above 5 million for India.

The reported prevalence for PACG in Vellore eye study (VES) was 4.32%. In Andhra Pradesh Eye Disease Study (APEDS), the reported prevalence for PACG was noted to be 1.08% with another 2.21% having 'occludable angles'. The criteria for occludability was different between the studies-the VES considered one half or more angle to be narrow to be considered occludable while APEDS had a criteria of three quarters or more. Moreover, VES incorporated PAC and PACG together into PACG. The actual prevalence of PACG would have been 0.5% alone. A similar prevalence of 0.5% for PACG was reported by Aravind Comprehensive Eye Survey (ACS).

The Chennai Glaucoma Study (CGS), using the current ISGEO criteria reported higher rates for PACS, PAC and PACG in the urban cohort as compared to rural one. The prevalence of PACG was noted to be 0.87% in rural and 0.88% in urban cohorts. Besides this, 6.3 % were classified as PACS and 0.7% as PAC in the rural cohort as compared to 7.2 and 2.8% in urban cohorts.

The prevalence of PACS has been noted to be higher than PAC and PACG in these, implying that all patients of PACS do not necessarily progress to PAC and PACG and the slow rate of conversion for the same.

III. DIFFERENTIAL DIAGNOSIS

- Secondary pupillary block due to uveitis with iris bombe
- Malignant glaucoma
- Lens induced angle closure-phacomorphic/ subluxation/ dislocation
- Neovascular glaucomas

IV. PREVENTION AND COUNSELING

The majority of patients are asymptomatic. Vision lost in glaucoma cannot be restored. The purpose of therapy is to preserve existing vision. Diagnosis of angle closure needs a detailed slit lamp examination, intraocular pressure assessment, indentation gonioscopy, optic nerve head assessment and investigations as required. Since cataract and glaucoma can coexist and the patient may attribute their vision loss to the former, it is essential to have a comprehensive eye examination above the age of 40 years at least annually or biannually. Being a progressive blinding disorder, if glaucoma is detected in a patient, the patient is counseled and explained the need for regular eye examinations throughout life. The need to screen close family members of the patient with angle closure disease is stressed as glaucomas at times may be heritable and may show familial predisposition.

V. OPTIMAL DIAGNOSTIC CRITERIA, INVESTIGATIONS, TREATMENT & REFERRAL CRITERIA

***Situation 1: At Secondary Hospital/ Non-Metro situation: Optimal Standards of Treatment in Situations where technology and resources are limited**

a) Clinical Diagnosis:

History:

Most primary angle closure glaucoma in Indian eyes is asymptomatic. A patient may present with intermittent attacks of redness or pain with halos and blurred vision in eyes or may present with acute onset of such symptoms. Previous or concomitant use of steroids in any form should be noted. Drugs likely to precipitate angle closure such as such as adrenergic and anticholinergic agents, tri and tetracyclic antidepressants, MAO inhibitors and sulfa based such as topiramate to be recorded along with any history of angle closure in family.

IOP:

Intraocular pressure is preferably assessed with Goldmann's applanation tonometer.

Gonioscopy:

A carefully done gonioscopy for diagnosis of angle closure is crucial and helps in follow up and management of these patients. Preferably, indentation gonioscopy is done in patients suspected for angle closure to differentiate appositional from synechial closure. It is first done in dim illumination with a short slit beam avoiding the pupil and then on indentation with a bright light. Excessive compression on the gonioscope and/ or excess light entering the pupil may artifactually open up the angle. Careful assessment of the angle structures with their exact anatomic documentation along with iris contour, iris processes, areas of peripheral anterior synechiae with pigmentation of the angle should ideally be done.

Optic nerve head and visual fields assessment:

Undilated disc assessment (if possible prior to laser peripheral iridotomy) with a +78/90 Dioptre lens under a slit lamp biomicroscope along with a dilated fundus examination with nerve fiber layer and optic nerve head assessment.

b) Investigations:

Automated perimetry (preferably Humphrey 24-2 SITA Standard/ Octopus G1 test) form the gold standard tests for the diagnosis and follow up of the glaucoma patient. In patients with advanced visual field losses 10-2 or macular threshold test on Humphrey may be required. Since visual fields may have a learning curve, it is preferable to have two visual fields with replicable defects to establish a reliable baseline. Serial stereoscopic disc photographs/disc drawings also form an important additional modality to follow up a patient.

c) Treatment:

Guidelines to therapy:

Treatment for angle closure revolves around intraocular pressure control, assessment and therapy directed to the control of the angle and angle closure, prevention and treatment for acute primary angle closure, preventing progression of glaucoma and thus aiming to preserve a patient's vision and quality of life.

(1) Control of intraocular pressure:

Antiglaucoma medications are prescribed to control IOP for short term either before definitive therapy by laser or surgery and following the same for residual IOP elevation in the long term. All major classes of drugs can be used as for open angle glaucomas such as beta blockers, alpha agonists, carbonic anhydrase inhibitors, prostaglandin analogues, cholinergic agents and hyperosmotic agents can be used depending on their tolerability, side effects and contraindications. However Pilocarpine is usually contraindicated in lens induced and retro lenticular mechanisms as it may cause forward movement of iris lens diaphragm and shallowing of chamber angle. At low doses, Pilocarpine can be used for relieving residual appositional closure after laser iridotomy or iridoplasty in plateau iris and angle closure patients.

2) Angle control:

Laser peripheral iridotomy/ Surgical iridectomy

Preferably, a laser peripheral iridotomy (LPI) is done to alleviate pupillary block. It allows the aqueous to bypass the pupil, providing an alternative route for outflow from posterior to anterior chambers of the eye. Surgical iridectomy may rarely be needed in case of failures of laser iridotomy.

Laser peripheral iridotomy: Technique

The role and limitations and possible complications of laser iridotomy are explained to the patient. To reduce the risk of post laser IOP spike and inflammation, apraclonidine 1% or brimonidine 0.15/ 0.2% can be used either before or after the procedure. Alternatively, oral/ topical carbonic anhydrase inhibitors or topical glycerine (in case of corneal epithelial edema secondary to raised IOP) can be used in selected patients. It is preferable to reduce IOP to a safe level prior to the procedure. To reduce the risk of bleeding, selected patients on oral anticoagulants for systemic diseases should be counseled and may be asked to stop their anticoagulants for a few days prior to the procedure. Usually iridotomy is recommended between 11-1 o' clock beneath the eyelids avoiding the 12 o' clock position. However, others prefer 3 and 9 o' clock positions. PI is avoided at lid margins to reduce symptoms of glare formed by tear meniscus. Successful penetration is seen with a gush of pigments in anterior chamber with a visible deepening of anterior chamber. A minimum opening of 150-200 microns is aimed to ensure patency.

Parameters (Nd-YAG laser)

Energy: 2-5 mJ, 1-3 pulses/ burst

It is preferable to choose a thin area of iris or an iris crypt to reduce the amount of energy and associated complications with the procedure. Pre treatment with pilocarpine to stretch and thin the peripheral iris is helpful. Use of Abraham or Wise lenses with coupling agents is preferred to enhance magnification and focusing of the laser beam.

Complications and follow up after LPI: Possible complications can include IOP spike, blurred vision, bleeding, damage to corneal epithelium or endothelium and rarely damage to lens capsule or the retina. Late complications include progression of cataract and iridotomy closure. Post laser IOP check is done within 1-6 hours and patient is advised tapering dose of topical steroids with antiglaucoma medications as needed. Reassessment of the angle after pilocarpine effect wears off with documentation of areas of synechial and appositional closure is done.

(3) Surgery: Surgery is usually considered in case of failure of medical/ laser management for IOP control or progression of glaucoma despite maximum medical management.

Trabeculectomy alone or combined with cataract surgery

Cataract surgery alone-helps to reduce crowding of the angle and relative pupillary block.

Treatment of primary angle closure disease:

PACS

As noted, not all patients of PACS progress to PAC or PACG. The treatment needs to be individualized in regards to laser iridotomy or a close follow up. An iridotomy may be considered to reduce the risk of angle closure in future or alternatively the patient may be monitored for IOP elevation and PAS over time. However an iridotomy can be considered in the following situations:

- Fellow eye of an eye with primary angle closure
- Confirmed family history of angle closure glaucoma
- Eyes requiring frequent dilation for retinal examination
- When follow up is impractical or a poorly compliant patient
- Symptomatic patient
- Difficulty in opening the angle with compression, with areas of patchy trabecular meshwork pigmentation

In case iridotomy is deferred, patients are warned about symptoms of angle closure and are counseled for regular check ups. The possible risk of angle closure by medications such as decongestants and motion sickness is warned.

PAC and PACG

Laser peripheral iridotomy to relieve pupillary block is recommended as first line therapy. Appositional or synechial closure of the angle with concomitant damage to trabecular meshwork can cause rise in IOP. However, medical treatment should not be used as a substitution of laser in cases of PAC and PACG.

After component of pupillary block has been removed, further management on lines of open angle glaucomas is done to prevent pressure induced glaucomatous optic neuropathy and visual field progression by topical hypotensive agents and/or surgery.

Plateau Iris Configuration/ Syndrome

Elimination of element of pupillary block by LPI is recommended as first line of treatment. Iridoplasty helps opening up non synechial areas of the angle in selected patients. Chronic use of low dose miotic therapy may prevent further closure of the angle.

Acute Primary Angle Closure

Initial treatment is medical to lower IOP to a level when definitive therapy by LPI can be performed.

Medical therapy includes topical hypotensive agents and systemic agents to reduce IOP rapidly. However, topical mioics may not be effective at times in an ischemic pupillary

sphincter. Indentation with a 4 mirror gonioscope or a cotton tipped applicator has been used to break the acute attack. Laser iridectomy of the affected eye is the definitive management. It is done along with prophylactic iridectomy of the fellow eye, if narrow. This is done as nearly 50% of fellow eyes have been reported to develop acute closure within 5 years of the fellow eye. Following LPI, reassessment of the angles by gonioscopy is done to determine extent of synechial closure. IOP is controlled by antiglaucoma medications and optic nerve head damage and visual field assessment is done to outline further management. In case of extensive synechial closure, incisional surgery for glaucoma can be considered for IOP control, although it carries a high risk of post operative complications such as shallow anterior chamber and malignant glaucoma.

Treatment of secondary angle closure glaucomas:

The treatment of secondary glaucomas is directed to the primary event causing angle closure which is based on the underlying mechanism of angle closure—pupillary block, or non pupil block (anterior pulling/ posterior pushing) mechanisms.

Thus, treatment of secondary glaucomas may require relief of pupil block (iris bombe/ lens induced) with YAG peripheral iridectomy and treatment of underlying inflammatory disorder. Raised IOP is treated with topical/ oral antiglaucoma medications as needed.

Standard Operating procedure

a) In Patient

- ☐ Acute primary angle closure unresponsive to medical therapy/lasers
- ☐ Lens induced (Phacomorphic glaucoma)
- ☐ Symptomatic secondary angle closure requiring hyperosmotics for IOP control

b) Out Patient

- ☐ PACS, PAC, PACG, Secondary glaucomas
- ☐ Acute primary angle closure (following laser iridotomy and the patient is asymptomatic)

c) Day Care

- Not applicable

d) Referral criteria:

immediate referral on presentation if there is

Acute primary angle closure with uncontrolled IOP on maximum therapy and facilities for laser peripheral iridotomy are not available

Facilities for cataract surgery not available in lens induced glaucomas (phacomorphic)

Children (acute intraocular pressure lowering measures initiated prior to referral; laser or surgical therapy to be done at higher centres)

Referral following initial treatment if,

- ☐ Secondary glaucomas without facilities to treat the underlying cause (for example laser iridotomy for pupil block/ surgery (ex. in microspherophakia or lensectomy for subluxated crystalline lens)
- ☐ Nanophthalmos requiring surgery
- ☐ Previous failed trabeculectomy uncontrolled on maximum antiglaucoma therapy
- ☐ Patients requiring tube implants
- ☐ Only seeing eye
- ☐ Post congenital cataract surgery with uncontrolled IOP on therapy
- ☐ Complications of filtration surgery requiring surgical intervention
 - ✓ Failing bleb
 - ✓ Large choroidal haemorrhage/ effusions
 - ✓ Bleb leaks
 - ✓ Blebitis and endophthalmitis

***Situation 2: At Super Specialty Facility in Metro location where higher-end technology is available**

The clinical diagnosis and management is done on the same general guidelines as given above.

a) Clinical Diagnosis:

A Perkins tonometer or Tonopen (especially in case of corneal scarring precluding the use of a Goldmann's tonometer) may be used for IOP measurement.

b) Investigations:

Ancillary investigations which may aid clinical diagnosis and management include

Imaging of anterior segment:

A carefully done gonioscopy remains the gold standard for diagnosis of angle closure. There are various imaging tools to help evaluate the anterior segment of the eye. Anterior segment optical coherence tomography and ultrasound biomicroscopy play a key role in selected patients with angle closure. Both allow qualitative and quantitative assessment of anterior segment of the eye, although AS-OCT is unable to assess structures posterior to the iris.

Biometry To assess the axial length, lens thickness and anterior chamber depth (Refer 'Risk factors' above)

Imaging of optic disc and nerve fibre layer

Use of HRT, GDx and OCT (Retinal nerve fiber layer assessment) (if available)

C)Treatment:

- (1) Control of IOP as outlined above
- (2) Angle control

Laser peripheral iridotomy

Both Argon and Nd-YAG lasers can be used either alone or sequentially to achieve an iridotomy. Use of Nd-YAG laser for iridotomy has been described above. In sequential use, photocoagulative effects of argon laser are combined with photodisruptive effects of Nd-YAG laser. This is especially useful in cases of thick irides and to reduce the risk of bleeding. Argon laser is used first to thin the iris and then the Nd-YAG laser is used for penetration.

Parameters (Argon laser)

Stretch Burns:

Spot size:	200-500 μm
Exposure time:	0.2-0.5 sec
Power:	200-600 mW

Penetration burns:

Spot size:	50 μm
Exposure time:	0.02 sec
Power:	800-1000 mW

Argon laser peripheral iridoplasty.

(3) Surgery

Trabeculectomy alone or combined with cataract surgery

Cataract surgery alone-helps to reduce crowding of the angle and relative pupillary block.

Tube implant surgery

Management of complications of glaucoma surgery causing secondary closure of angle

Malignant glaucoma

- Aqueous suppressants/ cycloplegics (miotics are contraindicated)
- Nd-YAG hyaloidotomy along with posterior capsulotomy in pseudophakics
- -Pars plana vitrectomy_

Secondary closure choroidal effusion

- Topical steroids/ cycloplegics with or without systemic steroids
- Choroidal drainage if conservative measures fail

Acute primary angle closure

Other modalities attempted include iridoplasty and paracentesis for temporary lowering of IOP. In case LPI is not possible, iridoplasty or surgical iridectomy can be attempted. Cataract surgery alone or combined with goniosynechiolysis have been reported with varying success rates. This approach may be attempted in eyes not amenable to laser iridotomy or surgical iridectomy, however the risks and benefits should be weighed beforehand.

Genetic counseling: This forms an important tool to educate and inform patients about higher risk of glaucoma in close relatives and children.

Standard Operating procedure

a. In Patient

- Patients requiring surgical intervention
- Acute primary angle closure with uncontrolled IOP on maximum therapy/laser peripheral iridotomy not complete (symptomatic patient)
- Lens induced glaucomas (phacomorphic)
- Blebitis and Endophthalmitis
- Malignant glaucoma refractory to medical management

b. Out Patient

- PACS, PAC, PACG, Secondary glaucomas

c. Day Care

- Not applicable

d)Referral criteria:

- Not applicable

VI .WHO DOES WHAT? and TIMELINES

a. Doctor

- Clinical history and examination
- Visual acuity
- Intraocular pressure measurement
- Gonioscopy
- Undilated/ dilated fundus examination
- ASOCT/ UBM
- YAG peripheral iridotomy/ Iridoplasty
- Surgery if indicated

b. Nurse/Technician

- Preparing the patient for laser treatment
- Ancillary tests-Pachymetry, Visual fields, Disc photography
- Compliance to therapy for inpatients

VII FURTHER READING / REFERENCES: Please refer at the end of the chapter

RESOURCES REQUIRED:

Situation	HUMAN RESOURCES	INVESTIGATIONS	DRUGS & CONSUMABLES	EQUIPMENT
1) Secondary level	1) Ophthalmologist -1 2) Optometrist/ Technician -1 3) OP Nurse -1	1) Visual fields 2) Pachymetry 3) Disc photographs (desirable)	1) Antiglaucoma medications 2) Topical steroids 3) Irrigating Solutions 4) Viscoelastic agents 5) Mydriatics & Cycloplegics 6) Antibiotic eye drops 7) Intraocular lenses 8) Needle and syringes 9) Suture materials	1) Slit lamp biomicroscope-1 2) Goldmann applanation tonometer -1 3) Indentation gonioscope -1 (preferable Sussman/ Posner/ Zeiss) 4) 90D/ 78 D lens-1 5) Indirect ophthalmoscope-1 6) Operating Microscope 7) Microsurgical Instruments 8) Pachymeter 9) Nd-YAG laser 10) Lenses for PI-1 (Abraham/ Wise) 11) Automated perimeter-1 (preferably 12) Humphrey/ Octopus)

2) Tertiary level	1) Glaucoma specialist-1 2) Optometrist/ Technician -1 3) OP Nurse -1 4) Scrub nurse -1 5) OT nurse -1	1) Visual fields 2) Pachymetry 3) Biometry 4) ASOCT (desirable) 5) UBM	1) Antiglaucoma medications 2) Topical/Systemic steroids 3) Irrigating Solutions 4) Viscoelastic	1) Slit lamp biomicroscope-1 2) Goldmann applanation tonometer-1 3) Indentation gonioscope-1 (preferable Sussman/ Posner/ Zeiss)
-------------------	--	--	---	--

	<p>6) Ward nurse - 1</p> <p>7) Counsellor - 1</p>	<p>6) Ultrasound</p> <p>6) Disc photographs</p>	<p>agents</p> <p>5) Mydriatics & Cycloplegics</p> <p>6) Antibiotic eye drops</p> <p>7) Antimetabolites</p> <p>8) Ologen</p> <p>9) Glaucoma Drainage Devices</p> <p>10) Intraocular lenses</p> <p>11) Needles & Syringes</p> <p>12) Suture materials</p>	<p>4) 90D/ 78 D lens-1</p> <p>5) Indirect ophthalmoscope-1</p> <p>6) Pachymeter</p> <p>7) Ultrasound-1</p> <p>8) Disc photography-1</p> <p>9) A Scan-1</p> <p>10) Diode laser with laser delivery system / Cryo-1 (recurring supplies required for G probe for Diode)</p> <p>11) Nd-YAG laser-1</p> <p>12) Automated perimeter-1 (preferably Humphrey/ Octopus)</p> <p>13) ASOCT-1</p> <p>14) UBM-1</p> <p>15) Lenses for PI / Iridoplasty -1</p> <p>16) Operating Microscope</p> <p>17) Microsurgical Instruments</p>
--	---	---	---	--

PRIMARY OPEN ANGLE GLAUCOMA

I. WHEN TO SUSPECT/ RECOGNIZE?

a) Introduction:

POAG is most common form of glaucoma world wide. It is estimated that 45 million people worldwide have POAG. With the exception of Asia, Primary open angle glaucoma (POAG) is far more common than Primary angle-closure glaucoma (PACG) worldwide.

b) Case definition:

Definition: It is a chronic progressive anterior optic neuropathy characterised by acquired loss of retinal ganglion cell loss, visual field loss, open angles with no obvious causative ocular or systemic condition.

II. INCIDENCE OF THE CONDITION IN OUR COUNTRY

In India, Primary open angle glaucoma is estimated to affect 6.48 million persons. Aravind comprehensive eye survey found a prevalence (95% confidence interval) of POAG it was 1.7% (1.3, 2.1) in rural population. The prevalence of POAG in rural south Indian population as evaluated by Chennai glaucoma study group 1.62%. The prevalence increased with age, and 98.5% were not aware of the disease. Vellore eye study found a prevalence (95% CI) of POAG 4.1 (0.08-8.1) in urban south Indian population. Andhra Pradesh eye disease study found a prevalence (95% confidence interval) of 1.62% (0.77%-2.48%) in urban south Indian population. Studies comparing the prevalence in urban and rural population – Chennai glaucoma study found prevalence of POAG in south Indian urban population was 3.51%, higher than that of the rural population. Andhra Pradesh eye disease study also found the prevalence to be greater in urban population (4% vs 1.6%; $P < 0.001$).

III. DIFFERENTIAL DIAGNOSIS

- Optic nerve anomalies: coloboma, pits, oblique insertion
- Primary optic atrophy
- Past history of steroid usage
- Past history of trauma or surgery
- Ischemic optic neuropathy (arteritic/non arteritic)

IV. PREVENTION AND COUNSELING

Once the blindness of glaucoma has occurred there is no treatment that will restore the lost vision. In nearly all cases blindness from glaucoma is preventable, which requires early diagnosis and proper treatment. Detection depends on the ability to recognize the early clinical manifestations of various glaucomas. Appropriate treatment requires an understanding of the pathogenic mechanisms involved, detailed knowledge of drugs and operations that control IOP. Infact sometimes, a patient needs to be followed up for an extended period of time before a decision to treat can be made. Retinal nerve fiber layer loss precedes measurable optic nerve head and conventional white on white perimetry changes in early glaucoma.Hence patients should be counseled regarding the asymptomatic nature of the disease, importance of treatment, correct technique of eye drop application and regular follow up. Each patient should be educated about different modalities of treatment.

V. OPTIMAL DIAGNOSTIC CRITERIA, INVESTIGATIONS, TREATMENT & REFERRAL CRITERIA

***Situation 1: At Secondary Hospital/ Non-Metro situation: Optimal Standards of Treatment in Situations where technology and resources are limited**

Clinical Diagnosis:

Diagnosis: based on comprehensive initial ophthalmic evaluation-

- History (ocular and systemic)
- Family history of Glaucoma (Severity and Outcome)
- IOP recording by applanation tonometer.
- Larger diurnal variation in IOP either by daytime phasing or 24 hour diurnal phasing.
- Gonioscopy to exclude angle closure disease and causes of secondary open angle glaucoma
- Steroscopic ONH evaluation (Preferably through dilated pupil) with pictoric fundus diagram.

Investigations:

- Pachymetry : central corneal thickness affects IOP measurements with higher IOP in thick corneas and lower IOP in thin corneas.
- Fundus photography aids in documentation of optic nerve head at baseline and follow up visits.
- Visual field analysis

Treatment:

Management Goals:

- Stable ONH and RNFL status
- Controlled IOP
- Stable visual fields

Standard Operating procedure

a. In Patient :Surgical treatment is indicated

- IOP not controlled with maximal medical therapy
- Contraindication to medical therapy
- Poor compliance

Surgical options: Trabeculectomy and combined glaucoma and cataract surgery.

b. Out patient : Medical management : Most appropriate medication with greatest chance of reaching target IOP, with good safety profile, convenient dosing and affordable medication should be chosen. Details of the medications, dosage, its adverse effects and follow up schedule are mentioned below.

c.Day Care

Not applicable

VI. Referral criteria:

- 1.High suspicion of secondary glaucoma is present requiring evaluation for secondary causes
- 2.For optimal investigations and treatment
- 3.For management of difficult cases and Post-operative complications

***Situation 2: At Super Specialty Facility in Metro location where higher-end technology is available**

- a) Clinical Diagnosis:** Comprehensive ophthalmic evaluation including
- History special attention to factors including systemic diseases that influence diagnosis, course and treatment of POAG.
 - Evaluation of visual function: with respect to difficulties in night driving, nearvision and outdoor mobility.
 - Visual acuity measurement
 - Pupil examination: to detect Relative afferent pupillary defect, which is a function of optic nerve
 - Anterior segment examination by Slit lamp biomicroscopy
 - Intraocular pressure measurement by Goldmann applanation tonometry
 - Gonioscopy:
 - Is pre-requisite for diagnosis of glaucoma to rule out secondary causes like angle closure, angle recession, pseudoexfoliation, pigment dispersion, peripheral anterior synechiae, new vessels, blood in schlemm's canal and inflammatory precipitates.
 - Optic nerve head and retinal nerve fiber evaluation by 90D stereoscopic examination:
 - ✓ Disc size.
 - ✓ Neuroretinal rim
 - ✓ Disc haemorrhage
 - ✓ Nerve fiber layer defect.
 - ✓ Peripapillary atrophy.
 - ✓ Vascular pattern.
 - Central corneal thickness measurement (CCT)
Thicker CCT overestimates IOP readings and thinner CCT underestimates. There is no generally accepted correction formula. Thinner CCT is independent risk factor for conversion of ocular hypertensive to POAG as proven in Ocular Hypertensive Treatment Study.
 - Visual field evaluation: characteristics of glaucomatous visual field defects
 - ✓ Asymmetrical across horizontal midline.
 - ✓ Located in midperiphery.(5-25 degrees from fixation).
 - ✓ Reproducible.
 - ✓ Not attributable to other pathology.
 - ✓ Clustered in neighbouring test points.
 - ✓ Defect should correlate with the ONH damage.
 - Optic nerve head and retinal nerve fiber layer analysis
 - ✓ Slit lamp indirect ophthalmoscopy using 90 D and 78 D lenses.
 - ✓ Fundus diagrams.
 - ✓ Stereoscopic disc photographs.

 - ✓ Red free fundus photography.

- ✓ Confocal scanning laser ophthalmoscopy.(HRT)
- ✓ Scanning laser polarimetry (GDx)
- ✓ Optical coherence tomography.

POAG is chronic progressive optic neuropathy that is bilateral and asymmetric in presentation

- Evidence of Optic Nerve Head damage
- Optic disc and retinal nerve fiber layer damage
 - Diffuse thinning, focal narrowing or notching of neuroretinal rim (NRR) especially at inferior or superior poles
 - Progressive thinning of NRR with increased cupping
 - Diffuse or focal peripapillary nerve fiber layer defects especially at poles
 - Peripapillary splinter hemorrhages
- Reliable and reproducible visual field abnormality
 - Visual field defects corresponding to retinal nerve fiber layer damage (nasal step, arcuate scotoma, paracentral scotoma)
 - Adult onset (more than 18yrs of age)
 - Elevated Intraocular pressure > 22 mm Hg in majority of cases on two successive occasions
 - Diagnosis of exclusion (to exclude pigment dispersion, pseudoexfoliation and other secondary open angle glaucomas)

Severity of glaucoma:

- **HAP Visual Field Severity Score** (Based on visual field damage)
 - Criteria for early defect**
 - Mean deviation no worse than -6 dB
 - On pattern deviation plot, _25% of points depressed below the 5% level and _15% of points depressed below the 1% level
 - No point within central 5° with sensitivity _15 dB
 - Criteria for moderate defect**
 - Mean deviation worse than -6 dB but no worse than -12 dB
 - On pattern deviation plot, _50% of points depressed below the 5% level and _25% of points depressed below the 1% level
 - No point within central 5° with sensitivity _0 dB
 - Only 1 hemifield containing a point with sensitivity _15 dB within 5° of fixation
 - Criteria for severe defect**
 - Mean deviation worse than -12 dB
 - On pattern deviation plot, _50% of points depressed below the 5% level or _25% of points depressed below the 1% level
 - Any point within central 5° with sensitivity _0 dB
 - Both hemifields containing point(s) with sensitivity _15 dB within 5° of fixation

b) Investigations:

- ❏ Pachymetry

- ❑ Visual field
- ❑ Optic nerve head and retinal nerve fiber layer analysis
- ❑ Slit lamp indirect ophthalmoscopy using 90 D and 78 D lenses.
- ❑ Fundus diagrams.
- ❑ Stereoscopic disc photographs.
- ❑ Red free fundus photography.
- ❑ Confocal scanning laser ophthalmoscopy.(HRT)
- ❑ Scanning laser polarimetry (GDx)
- ❑ Optical coherence tomography.
- ❑ Additional Investigations to rule out secondary causes:
- ❑ B scan, UBM
- ❑ Fluorescein angiography

c) Treatment:

Standard Operating procedure

a. In Patient

Surgical treatment when

- ✓ target IOP not achieved with medical therapy
- ✓ Any contraindication to medical therapy exists.
- ✓ Has an edge over medical therapy in advanced glaucomas.
- ✓ Poor compliance

Surgical options:

Trabeculectomy, Combined cataract and glaucoma surgery, non penetrating glaucoma surgeries and aqueous drainage devices.

b. Out Patient:

Medical and laser therapy :

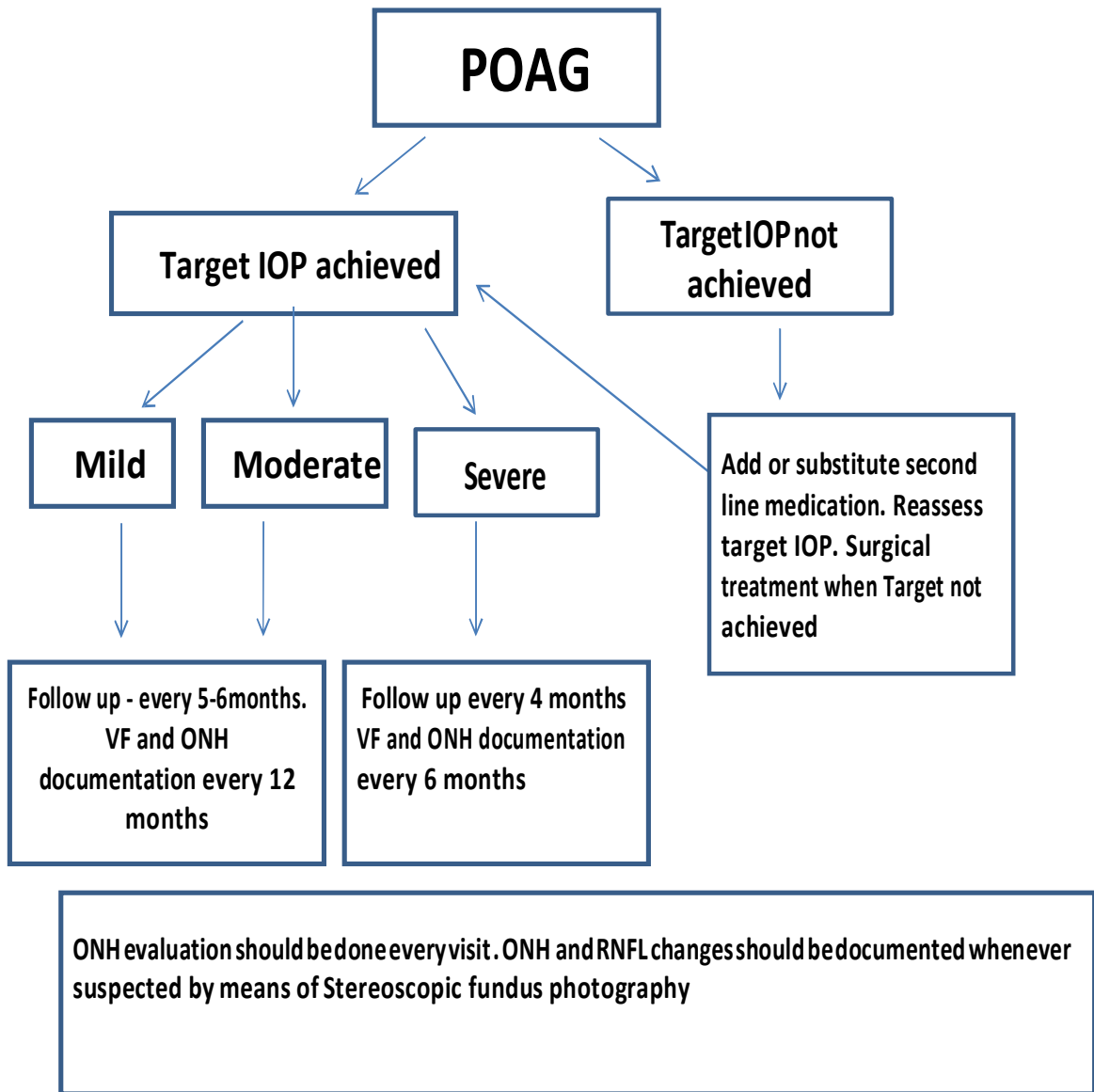
Medical therapy.

- ✓ Effective for majority of patients.
- ✓ Most widely acceptable
- ✓ Widely available.
- ✓ Most appropriate medication with greatest chance of reaching target IOP, with good safety profile, convenient dosing and affordable medication should be chosen

Drug	Methods of action	IOP	Side- effects	Contraindications

Prostaglandins	Increased uveoscleral outflow	25-33%	Cystoids macular edema conjunctival injection periocular hyperpigmentation eyelash growth iris colour change, uveitis possible herpes virus reactivation	Macular edema history of herpes keratitis
Beta-blockers	Decreased aqueous production	20-25%	Corneal toxicity allergic reactions congestive heart failure bronchospasm bradycardia depression impotence	COPD, asthma, bradycardia, first degree heart block, Myasthenia gravis CHF, hypotension
Alpha-adrenergic agonists	Non-selective: improve aqueous outflow Selective: decrease aqueous production, decrease episcleral venous pressure, increase uveoscleral outflow	20-25%	Conjunctival injection, allergic reaction, somnolence, fatigue, headache	Monoamino oxidase inhibitor therapy infants and children <2 yrs
Carbonic anhydrase inhibitors	Decrease aqueous production	15- 20%	Topical use: metallic taste Corneal edema, allergic dermatitis Systemic use: Steven Johnson syndrome, aplastic anemia, thrombocytopenia, renal calculi, metallic taste, malaise, anorexia, gastric irritation, depression, serum electrolyte disturbance	Sulfonamide allergy, aplastic anemia, Renal calculi and Renal failure, sickle cell disease
Parasympathetic agents	Increased trabecular outflow	20-25%	Myopia, brow ache, decreased vision, cataract, corneal toxicity, dermatitis, uveitis, development of peripheral anterior synechiae.	Neovascular glaucoma, malignant glaucoma, periodic retinal evaluation

Laser therapy: Selective Laser Trabeculoplasty by Frequency doubled Nd:YAG laser for outflow enhancement and Diode Cyclophotocoagulation for end stage glaucoma



c. Day Care

Trabeculectomy, combined cataract and glaucoma surgeries, laser therapy, can be done on day care basis ensuring regular follow up.

d) Referral criteria:

Not applicable.

VII. WHO DOES WHAT? and TIMELINES

a. Doctor :

- Detailed history pertaining to ocular, systemic, past treatment should be obtained.
- Visual acuity and refraction should be reviewed.
- Detailed slit lamp evaluation with IOP recording, gonioscopy and stereoscopic optic nerve head evaluation should be performed.
- Interpretation and clinical correlation of the investigations requested.
- Accurate treatment as applicable and monitoring the follow up.

b. Nurse / Technician

- Brief ocular history with respect to chief complaints, treatment, compliance should be obtained.
- Visual acuity and refraction should be performed at each visit.
- Should be trained in obtaining fundus photographs, perimetry and imaging.

VIII. FURTHER READING / REFERENCES

1. Jacob A, Thomas R, Koshi SP, Braganza A, Muliyl J Prevalence of primary glaucoma in an urban south Indian population, Indian J Ophthalmol. 1998 Jun;46(2):81-6
2. Ramakrishnan R, Praveen NK, Krishnadas R, et al. Glaucoma in a rural population of southern India: the Aravind Comprehensive Eye Survey. Ophthalmology.2003;110:1484-1490.
3. Lingam Vijaya, Ronnie George, M. Baskaran, Hemamalini Arvind, Prema Raju, S.Ve Ramesh, Govindasamy Kumaramanickavel, Catherine McCarty. Prevalence of Primary Open-angle Glaucoma in an Urban South Indian Population and Comparison with a Rural Population: Ophthalmology Volume 115, Issue 4 , April 2008, 648-654.
4. Vijaya. L, George.R, Paul P, et al prevalence of open angle glaucoma in rural south Indian population. Invest Ophthalmol vis sci.2005;46:2261-4467.
5. Dandona L, Dandona R, Mandal P et al. Angle-closure glaucoma in an urban population in southern India. The Andhra Pradesh eye disease study. Ophthalmology. 2000 Sep;107(9):1710-6.

RESOURCES REQUIRED FOR ONE PATIENT / PROCEDURE (PATIENT WEIGHT 60 KGS)
(Units to be specified for human resources, investigations, drugs and consumables and equipment. Quantity to also be specified)

Situation	HUMAN RESOURCES	INVESTIGATIONS	DRUGS & CONSUMABLES	EQUIPMENT
1	Ophthalmologist -1 Optometrist/ Technician-1 OP Nurse-1	Visual fields Pachymetry Disc photographs (desirable)	Antiglaucoma medications Topical steroids Topical anaesthetics Fluorescien strips.	Slit lamp biomicroscope-1 Goldmann applanation tonometer-1 Indentation gonioscope-1 (preferable Sussman/ Posner/ Zeiss) 90D/ 78 D lens-1 Indirect ophthalmoscope-1 Pachymeter Automated perimeter-1 (preferably Humphrey/ Octopus)
2	Glaucoma specialist-1 Optometrist/ Technician-1 OPNurse-1 Scrub nurse OT nurse Ward nurse	Visual fields Pachymetry OCT/GDX/HRT Fundus camera	Antiglaucoma medications Topical/Systemic steroids Topical anaesthetics. Fluorescein strips Anti – metabolites.	Slit lamp biomicroscope-1 Goldmann applanation tonometer-1 Indentation gonioscope-1 (preferable Sussman/ Posner/ Zeiss) 90D/ 78 D lens-1 Indirect ophthalmoscope-1 Pachymeter Disc photography-1 Automatedperimeter -1 (preferably Humphrey/ Octopus) Q switched frequency doubled Nd-Yag laser. Argon laser Diode laser. Glaucoma drainage devices

NAME OF CONDITION: INFECTIVE ENDOPHTHALMITIS

I. WHEN TO SUSPECT/ RECOGNIZE?

a) Introduction:

Exogenous Endophthalmitis is a devastating complication, usually following intraocular surgery or open globe injury. Rarely, a hematogenous dissemination into the eye from a distant focus of infection within the body may be a cause and this form is termed as endogenous endophthalmitis. In this condition, the internal structure of the eye are invaded by replicating microorganisms, resulting in an inflammatory response that ultimately may involve all tissues of the eye. This serious condition can be effectively treated if diagnosed early and treated comprehensively.

b) Case definition:

Endophthalmitis is defined as a serious intraocular inflammation resulting from infection of the vitreous cavity. Exogenous endophthalmitis occurs when infective organisms gain entry into the eye by direct inoculation, such as from intraocular surgery, intravitreal injections, penetrating trauma, or contiguous spread from adjacent tissues. Endogenous endophthalmitis occurs when infectious agents are hematogenously disseminated into the eye from a distant focus of infection. Initial intraocular signs and symptoms may include decreased visual acuity, afferent pupillary defect, pain, hypopyon, fibrinoid anterior chamber response, corneal edema, corneal/wound infiltrate, vitreous inflammation, retinitis, and/or retinal periphlebitis. External signs of inflammation, such as ciliary injection, chemosis, and lid edema, may be present. If the infection has spread to orbit, restriction of extraocular motility and proptosis may occur.

INCIDENCE OF THE CONDITION IN OUR COUNTRY

The national survey on blindness and visual outcome after cataract surgery in 2001, carried out by the ministry of health, Government of India, found an incidence of 0.6%. In a study conducted by a major tertiary care centre, the incidence of post operative endophthalmitis was found to be 0.09%. Traumatic endophthalmitis accounts for approximately 7% of open globe injuries and nearly a quarter of all endophthalmitis cases. Endogenous endophthalmitis accounts for 2.6% of all culture positive endophthalmitis.

III. DIFFERENTIAL DIAGNOSIS:

The following are the differential diagnosis

- a) Sterile uveitis
- b) Phacoanaphylactic endophthalmitis
- c) Sympathetic ophthalmia

Sterile inflammation may result from retained intraocular foreign material like cotton fibers, from toxic reaction to drugs or irrigating fluids, from operative trauma, from exacerbation of preexisting uveitis, and from other conditions like phacoanaphylactic endophthalmitis and sympathetic ophthalmia. Post trauma or post cataract surgery severe inflammation with true hypopyon can result from retained lens fragments.

Ultrasonography may be helpful in establishing the diagnosis. The clinical presentation depends on cause, therefore the history may be helpful, and should include the details of recent surgery, allergy history and uveitis history.

IV. PREVENTION AND COUNSELING

The mainstay of prevention of post operative endophthalmitis is maintenance of strict surgical asepsis during any intraocular surgery. The ocular surface and adnexa are the primary sources of microbes in culture positive cases of post operative endophthalmitis. The use of topical 5% povidine iodine solution in the conjunctival fornices before performing intraocular surgery reduces the bacterial load and decreases the incidence of this condition. The second line of prevention is use of broad spectrum and bactericidal topical / periocular/ intracameral antibiotics. Numerous surgical studies have confirmed that prophylactic antibiotics are maximally effective preoperatively and less effective postoperatively in preventing endophthalmitis. In case of post operative endophthalmitis, prompt referral to a tertiary care centre in case of slightest doubt is mandatory. Investigations have to be immediately performed to rule out any intra ocular foreign body.

V. OPTIMAL DIAGNOSTIC CRITERIA, INVESTIGATIONS, TREATMENT & REFERRAL CRITERIA

***Situation 1: At Secondary Hospital/ Non-Metro situation: Optimal Standards of Treatment in Situations where technology and resources are limited**

a) Clinical Diagnosis:

The diagnosis of endophthalmitis is based on the clinical presentation, be it postoperative, post-trauma or endogenous. Any eye with inflammation greater than the usual postoperative or post-trauma clinical course should be suspected of having endophthalmitis. Symptomatically, typically the patient notes a sudden increase in pain and

decrease in vision which may manifest after a variable time period after an intraocular surgery or open globe injury. Examination demonstrates conjunctival chemosis and

increased injection. The upper lid becomes edematous and the cornea shows variable degree of edema. The anterior chamber shows increased flare and cells, and hypopyon is often present in the inferior angle. Fundus view is obscured by focal or diffuse vitritis which manifests as a yellow glow. In more extreme cases the anterior chamber is filled with exudates and the cornea is white. If the infection has spread to orbit, restriction of extraocular motility and proptosis may occur.

b) Investigations:

- i) When measuring **visual acuity**, the technique of differentiating light perception from hand motions vision is most important, since this is a major factor in determining candidates most likely to benefit from vitrectomy in postoperative endophthalmitis. Hand motions vision should be determined no closer than 2 feet from the patient with light illumination originating from behind the patient.
- ii) A diligent **clinical examination** with slit lamp biomicroscopy should be done to look for certain risk factors which influence the management. These include wound leak or dehiscence, suture abscess and vitreous incarceration in the wound in postoperative endophthalmitis. Additionally, presence of intraocular foreign body and lens disruption should be recognized in post-trauma endophthalmitis.
- iii) **Ultrasound evaluation** of the globe should be performed if significant media opacification prevents an adequate view of the fundus. Findings consistent with endophthalmitis include dispersed vitreous opacities from associated vitritis and in advanced cases, chorioretinal thickening. The ultrasound examination should rule out associated retinal or choroidal detachment, dislocated lens material, or intraocular foreign bodies.
- iv) Ocular samples should be obtained for **microbial identification**. As there are no significant differences in yield of positive cultures among the needle tap, vitreous biopsy, or pars plana vitrectomy techniques, the surgeon may decide the best possible sampling method based on the resources available. Retrobulbar anesthesia may be necessary but must be administered cautiously in the presence of recent ocular surgical wound or open globe injury. The eye is surgically prepared with povidone iodine 5% solution and rinsed thoroughly with sterile balanced salt solution or normal saline to remove residual antiseptic from the ocular surface. A surgical drape, lid speculum and operating microscope may be used. A 30 gauge needle attached to a tuberculin syringe is inserted through the limbus into the anterior chamber and an aqueous specimen is aspirated without collapsing the anterior chamber. A quantity of approximately 0.1ml can usually be obtained. A vitreous specimen may be obtained either by vitreous needle tap or by vitreous biopsy with a vitreous cutter. After conjunctival incision, a vitrectomy probe attached to a tuberculin syringe is inserted into the vitreous cavity through a sclerotomy incision placed 3mm posterior to the

limbus. Approximately 0.1-0.3ml of vitreous is removed from the anterior vitreous cavity by using the automated cutting mechanism of the probe and slow, manual

aspiration into the syringe. The alternative method, vitreous needle tap, is performed by inserting a 27 to 23 gauge needle attached to a tuberculin syringe into the vitreous cavity through the pars plana, and slowly aspirating a similar volume of fluid vitreous. Samples collected should be sent immediately for Gram and KOH staining. It is ideal to inoculate the samples for culture (aerobic, anaerobic and fungal) within minutes of obtaining them to maximize the culture yield.

c) Treatment:

- i) **Postoperative endophthalmitis:** the main treatment is in the form of intravitreal antibiotics since it is the best way to achieve therapeutic concentration in the eye. An empirical treatment with broadspectrum antibiotics is initiated concomitantly with the ocular fluid biopsy or core vitrectomy. The recommended combinations of antibiotics for empirical therapy are Vancomycin 1.0mg/0.1ml and Ceftazidime 2.25mg/0.1ml. Amikacin 400 microgm/0.1ml can be considered in exchange for ceftazidime in beta-lactam sensitive patients. In cases of suspected fungal endophthalmitis intravitreal antifungal agents should be administered.

In addition to eradication of viable organisms from the eye and sterilization of the vitreous cavity, control of intraocular inflammation is an important therapeutic goal. Inflammation can increase even when microbes are no longer viable. Corticosteroid administration at the appropriate time - no matter what route is chosen - is to be administered to reduce the ocular inflammation and maintain the structural integrity of the globe.

Immediate vitrectomy should be reserved for severe endophthalmitis with a presenting vision of perception of light. Such cases carry a significant, threefold improved chance of obtaining 6/12 vision in comparison to vitreous tap or biopsy according to endophthalmitis vitrectomy study. However, the procedure is not without risks such as vitreous haemorrhage, retinal tears and retinal detachment. Hence a limited vitrectomy of the core of the vitreous is advocated by various investigators. Improved viewing systems and instrumentations have enabled surgeons to perform complete vitrectomies with claims of better visual results and fewer complications. It is highly recommended to choose the right amount of vitreous debulking depending on the visibility of the fundus structures and severity of the inflammation. The best way to avoid complications is to keep intraocular pressure at a constant level during the entire procedure, thereby preventing hypotony.

Post surgery management includes use of topical antibiotics based on the culture sensitivity. In situations where no organisms are grown on culture, a combination of antibiotic or a broad spectrum antibiotic should be chosen to cover both the gram

negative and gram positive spectrum of causative organisms. Role of systemic antibiotics are debatable considering its low intraocular bioavailability.

After initial treatment of endophthalmitis a fraction of patients would require further treatment, mainly for worsening ocular infection or complication from the initial procedure. It typically requires more than 48hrs to observe an improvement in the clinical appearance after initial treatment. But one needs to keep in mind that the treated eyes look somewhat worse 1 day after treatment before improving subsequently.

- ii) **Traumatic endophthalmitis:** When the diagnosis of traumatic endophthalmitis is established, aqueous and vitreous specimen should be obtained for culture and Gram stain. Intravitreal injection with appropriate antimicrobial agent may be given as an initial treatment. But the guidelines for postoperative endophthalmitis treatment may not be applicable for traumatic endophthalmitis because of the diversity of the organisms encountered. Early closure of the wound, removal of foreign body and Vitrectomy in patients with severe vitritis should be the standard of care in all cases of traumatic endophthalmitis where the injury involves a rupture of ocular coats, or rupture of lens. Patients who do not respond after 48hrs or rapidly deteriorate in the first 24hrs following intravitreal antibiotics should also be treated with vitrectomy. Just like postoperative endophthalmitis, the exact role of systemic antimicrobial therapy for traumatic endophthalmitis is unclear.

Endogenous endophthalmitis: In contrast to postoperative endophthalmitis and traumatic endophthalmitis, systemic antibiotics are central to treatment of the endogenous endophthalmitis, since the source of infection is often remote to eyes. A detailed systemic workup including a general physical examination with special attention to the heart, skin and extremities should be carried out to look for the source of origin of the infection. When the source of infection is not apparent, special diagnostic studies like echocardiogram, abdominal ultrasonography, culture of blood and urine should be done. Cases of endogenous endophthalmitis with mild inflammation (e.g., focal metastatic abscesses in the anterior or posterior segment) may be treated initially with topical and systemic therapy, using nonocular cultures to guide treatment. Intravitreal antibiotic injection may be indicated if: 1) the inflammatory focus is in the anterior segment, and the eye is aphakic, or there is a dehiscence in the posterior capsule; or 2) the inflammatory focus is in the posterior segment, and there is significant vitritis. If no improvement is seen within a reasonable length of time or if nonocular cultures are negative, biopsy is indicated. Unlike cases of postoperative or posttraumatic endophthalmitis, the vitreous may not be the principal

site of infection in endogenous endophthalmitis. For this reason, biopsies should be taken from the area that is the primary site of ocular inoculation/inflammation.

List of commonly used antibiotics with recommended doses:

Antibiotic	Topical	Subconjunctival	Intravitreal
Amikacin	20mg/ml	40mg/ml	400micgm
Amphotericin B	0.15-0.5%	-	5-10micgm
Ampicillin	50mg/ml	100mg	5mg
Cefazoline	50mg/ml	100mg	2.25mg
Ceftazidime	50mg/ml	100mg	2.25mg
Ciprofloxacin	0.3%	1mg	100-500micgm
Clindamycin	-	30mg	250micgm
Fluconazole	0.2%	2%-1ml	10-100micgm
Gatifloxacin	0.3%	-	400micgm
Gentamicin	10-20mg/ml	20mg	200micgm
Levofloxacin	0.5%	-	625micgm
Miconazole	10mg/ml	5mg	25micgm
Moxifloxacin	0.5%	-	400micgm
Tobramycin	8-15mg/ml	20mg	200micgm
Vancomycin	50mg/ml	25mg	1mg
Voriconazole	1-2%	-	100micgm

Standard Operating procedure

a. In Patient

All patients with endophthalmitis should be admitted and treated as in patients

b. Out Patient

Not applicable

c. Day Care

Not applicable

d) Referral criteria:

- i) Postoperative endophthalmitis with presenting vision of light perceptions.
- ii) Severe postoperative endophthalmitis
- iii) Traumatic endophthalmitis with lens rupture and intraocular foreign body.
- iv) Endogenous endophthalmitis worsening in spite of maximum treatment
- v) Endophthalmitis in the only seeing eye
- vi) Paediatric patients needing general anaesthesia

***Situation 2: At Super Specialty Facility in Metro location where higher-end technology is available**

a) Clinical Diagnosis:

The surgeon at the tertiary care center should elicit the history of the disease afresh to plug the missing links if any, especially in endogenous endophthalmitis. Postoperative and traumatic endophthalmitis history is generally straight forward. A detailed treatment history and the culture results if any should be noted. In culture negative cases fresh investigations should be initiated to rule out phacoanphylactic endophthalmitis or retained intraocular foreign body.

b) Investigations:

Meticulous ultrasonogram of the eye may detect retained lens matter. Computerised tomography may detect occult intraocular foreign bodies in traumatic endophthalmitis. Special investigations like polymerase chain reaction of the vitreous or aqueous samples may be an useful additional diagnostic tool in culture negative cases. A repeat smear and culture of ocular fluids is mandated. The commonly used stains and culture media are mentioned below.

Presumed organisms	Stain	Media
Aerobic bacteria	Gram	Blood agar
	Giemsa	Chocolate agar
Anaerobic bacteria		Thioglycolate broth
	Gram	Anaerobic blood agar
		Thioglycolate broth
Fungi	10%KOH	Blood agar
	Gram	Saboraud dextrose agar
	Calcofluor white	Brain heart infusion

c) Treatment:

The culture sensitivity results help in choosing appropriate antibiotics for treatment.

1. Vancomycin and ceftazidime with or without dexamethasone stand as the preferred combinations of intravitreal drugs if no organisms are isolated.

2. A combination of vancomycin with amikacin is advocated as the empirical treatment in traumatic endophthalmitis.

3. In Soil contaminated foreign body injuries where bacillus caerus is suspected, combination of gentamicin with clindamicin in an option.

4. Pars plana vitrectomy remains the treatment of choice in severe endophthalmitis and in cases where the disease progression is noted in spite of the initial antibiotic treatment.

The first technical problem that confronts the surgeon is placement of the infusion cannula. Because the media is almost always too cloudy for the surgeon to be able to visualize a pars plana port, this infusion cannot be used for the initial stages of the operation. Because the incision and placement of the infusion port are easier in a firm eye, it is often worthwhile placing an inferotemporal port with sutures, reserving its use for later in the procedure, once the location of the tip in the vitreous cavity can be verified.

The presence of the crystalline lens or a pseudophakos will determine placement of the canula (3.5mm from limbus in pseudophacos, 4mm in phakic eyes). If light is not needed during the initial portion of the procedure, a bent needle or other blunt infusion canula can be positioned in the center of the pupillary space, where its position can be monitored. This infusion can be turned on at this stage so that the incision through the pars plana for the cutting instrument may be made in a firm eye. The anterior chamber often contains significant amounts of fibrin and hypopyon. Because the cornea invariably has some combination of epithelial edema, folds, and cells deposited on the posterior surface, the iris and central anterior vitreous are often impossible to visualize adequately. Initial incisions may be made in the limbus at approximately the 9.30 and 2.30 clock positions, modifying the location as necessary depending on the condition of the previous surgical wound and on the presence of a filtering bleb. Fluid is infused into the anterior chamber as inflammatory debris is removed with the suction and cutting instrument. If an inflammatory membrane extends over the iris surface and the lens, a bent needle can be used to gently peel it off the surface. The vitrectomy is now progressively carried posteriorly. The vitreous removal is performed initially in the center of the vitreous cavity. Pockets of more heavily infiltrated vitreous are sometimes located; in the aphakic eye, peripheral depression may be used to bring these into view. Aggressive removal of all infiltrated vitreous in the basal area should not be attempted because this often results in retinal tears. The presence of a posterior vitreous detachment, on the other hand, allows more complete vitreous removal. If the vitreous is still attached, a judgment must be made about the amount of vitreous to be removed. The cutting of vitreous adjacent to inflamed or necrotic retina will often cause retinal breaks; these are difficult to seal and may result in failure of the case. In eyes with posterior vitreous detachment, a white mound of inflammatory debris may be visible over the posterior pole. This should be approached with care and may be gently aspirated into the cutting port. If the mound proves to be solid and adherent, small amounts can usually be removed, but in most cases it is unwise to attempt to remove large portions. In some instances the material is flocculent and equivalent to an unorganized hypopyon; this can be gently sucked up with vacuum techniques. The procedure is completed by closing all incisions in a watertight manner and injecting intraocular antibiotics. After closure of the conjunctival incisions, subconjunctival antibiotics are often injected.

Standard Operating procedure

a. In Patient

- i) Postoperative endophthalmitis
- ii) Traumatic endophthalmitis
- iii) Endogenous endophthalmitis

b. Out Patient

Not applicable

C. Day Care

Not applicable

c) Referral criteria:

Not applicable

VI. WHO DOES WHAT? AND TIMELINES

a. Doctor

- Elicits patient history and performs clinical Examination
- Collects ocular fluid sample and inoculates for smear and culture
- Maintains medical records
- Plans the appropriate treatment
- Performs surgery
- Monitors, publishes and reports to department of health any emergence of drug resistant strains of microbes.

b. Nurse

- Maintains separate inpatient and outpatient record
- Prepares the patient for operative procedures
- Monitors the inpatients to ensure compliance

c. Technician

- Prepares slide, media for smear and culture
- Maintains lab records
- Performs ultrasonography when necessary and maintains records

FURTHER READING / REFERENCES

1. Brinton GS, Topping TM, Hyndiuk RA, Aaberg TM, Reeser FH, Abrams GW. Posttraumatic endophthalmitis [Internet]. Archives of Ophthalmology. 1984 ;102(4):547-550. Available from: <http://www.ncbi.nlm.nih.gov/pubmed/6704010>
2. Doft BH, Kelsey SF, Wisniewski SR. Additional procedures after the initial vitrectomy or tap-biopsy in the Endophthalmitis Vitrectomy Study [Internet]. Ophthalmology. 1998 ;105(4):707-716. Available from: <http://www.ncbi.nlm.nih.gov/pubmed/9544646>
3. Jackson TL, Eykyn SJ, Graham EM, Stanford MR. Endogenous bacterial endophthalmitis: a 17-year prospective series and review of 267 reported cases [Internet]. Survey of Ophthalmology. 2003 ;48(4):403-423. Available from: <http://www.ncbi.nlm.nih.gov/pubmed/12850229>
4. Sternberg P, Martin DF. Management of endophthalmitis in the post-endophthalmitis vitrectomy study era [Internet]. Archives of Ophthalmology. 2001 ;119(5):754-755. Available from: <http://www.ncbi.nlm.nih.gov/pubmed/11346404>
5. Results of the Endophthalmitis Vitrectomy Study. A randomized trial of immediate vitrectomy and of intravenous antibiotics for the treatment of postoperative bacterial endophthalmitis. Endophthalmitis Vitrectomy Study Group [Internet]. Archives of Ophthalmology. 1995 ;113(12):1479-1496. Available from: <http://www.ncbi.nlm.nih.gov/pubmed/7487614>

RESOURCES REQUIRED

Situation	HUMAN RESOURCES	INVESTIGATION	DRUGS AND CONSUMABLES	EQUIPMENT
1) Secondary level	1)Ophthalmologist - 1 2)OP Nurse 1 3)Refraction nurse - 1(shared)	1)Smear test 2)Gram stain microscopy 3)KOH smear	1)Antibiotics eye drops 2)Antifungal eye drops 3)Systemic antibiotics steroids and anti fungals 4) Mydriatic cyclopigic 5) Needles and syringes 6) Basic stains	1)Slit lamp - biomicroscope -1 2)Light microscope -1 3)Disposable needles 4)Tuberculin syringe- 5 5)Glass slide - 1 6)Basic stains - 1
2) Tertiary level	1) Retina specialist - 1 2)Refraction nurse - 1(shared) 3)OP Nurse - 1 4) Lab technician - 1 5)Scrub nurse - 1 6)OT nurse - 1 7)Ward nurse -1 8) Counsellor - 1	1)Smear test 2)Culture medium 3)Antibiotic sensitivity plates 4)Corneal biopsy 5)PCR	1)Antibiotics eye drops 2)Antifungal eye drops 3)Systemic antibiotics and anti fungal 4) Topical and systemic steroids 5) Mydriatic and cyclopigic 6) Irrigating solutions 7) Needles and syringes 8) Basic stains	1)Slit lamp - biomicroscope -1 2)Light microscop -1 3)Ultrasonogram -1 4)Vitrectomy equipment -1 5)OT microsurgical instruments -1 6)PCR instruments -1

NAME OF CONDITION: CHRONIC DACRYOCYSTITIS

I. WHEN TO SUSPECT/ RECOGNIZE?

a) Introduction:

Chronic dacryocystitis is an inflammatory condition of the lacrimal sac most commonly associated with partial or complete obstruction of the nasolacrimal duct . Most chronic dacryocystitis present with watering and discharge, but some may progress and cause severe ocular and extra ocular complication. Even in mild conditions, it may cause a significant ocular morbidity and loss of work place efficiency because watering can blur the vision momentarily, prevent a person from concentrating on some work and can be socially embarrassing. It affects all ages and all social strata but women are more likely to develop dacryocystitis because of their nasolacrimal ducts are anatomically narrower as compared to males. Approximately 3% of all the ophthalmic clinical visits and 1% of all emergency room visits are related to dacryocystitis. The underlying etiology, typical infectious organisms and preferred treatments are important issues to understand in the management of this common disorder.

b) Case definition:

Dacryocystitis is defined as inflammation of the lacrimal sac. The sac is a part of the lacrimal excretory system whose function is to transport the tears from the eyes to the nose.

II. INCIDENCE OF THE CONDITION IN OUR COUNTRY

Chronic dacryocystitis is a common ophthalmic problem. Although there are no reliable figures that document the incidence or prevalence of chronic dacryocystitis, large studies from the west have documented it to be around 3% of all the clinical ophthalmic visits. Since the lacrimal system is prone to infections as it is contiguous with both conjunctiva and nasal mucosa, dacryocystitis is considered much more common in developing countries like India. The morbidity is much more than expected because of its chronic nature, social factors as discussed already, tendency for acute painful exacerbations and its complications.

III. DIFFERENTIAL DIAGNOSIS

Although chronic dacryocystitis is not very difficult to diagnose, there could still be certain atypical cases which may masquerade in a similar fashion and needs to be kept in mind. They include bacterial conjunctivitis, pre-septal cellulitis,

miebomitis, blepharitis and canaliculitis. Points that differentiate and favour bacterial conjunctivitis included sudden onset redness with discharge and diffuse conjunctival congestion. Pre-septal cellulitis is an acute inflammation involving the eyelid, not associated with discharge or long standing epiphora. Meibomitis and blepharitis are usually bilateral associated with irritation of the lid margins and burning sensation. Canaliculitis can be differentiated by focal swelling of the canalicular portion of the eyelid margin with pouting puncta and inspissated discharge.

IV. PREVENTION AND COUNSELING

There are no known preventive measures for chronic dacryocystitis. Infections and inflammations are the major known causes for it. Therefore a good hygiene can at least prevent secondary infections of the lacrimal sac from the conjunctiva and nasal mucosa.

V. OPTIMAL DIAGNOSTIC CRITERIA, INVESTIGATIONS, TREATMENT & REFERRAL CRITERIA

***Situation 1: At Secondary Hospital/ Non-Metro situation: Optimal Standards of Treatment in Situations where technology and resources are limited**

a) Clinical Diagnosis:

History taking, comprehensive evaluation of the eye and understanding of the general epidemic prevalence of this condition in the society is crucial to establish a diagnosis . Patients usually come with typical history of chronic watering, matting of eye lashes on waking, discharge and redness of the eye.

Examination: The ocular examination includes recording visual acuity, an external eye examination and slit-lamp biomicroscopy.

Visual acuity measurement: Although visual acuity is normal in patients with dacryocystitis, discharge sliding across the eye may cause visual disturbances.

External examination:

The following points should be looked for:

1. Increased tear lake
2. Visible or palpable enlargement of the lacrimal sac
3. Discharge which at times may be copious.
4. Regurgitation on pressure over the lacrimal sac or ROPLAS test is a simple confirmatory test, which if positive is diagnostic of nasolacrimal duct obstruction and usually does not require further investigations.
5. Abnormalities of skin like crusting or eczematous lesions suggest chronic changes caused by watering. Skin may also show a lacrimal fistula or a scar of past acute dacryocystitis or lacrimal abscess.

Slit-lamp Biomicroscopy:

Should include evaluation of the following:

1. Increased tear film height.
2. Matted lashes.
3. Lacrimal puncta and canaliculi for pouting and discharge
4. Variable types of discharge like clear, mucoid or muco-purulent.
5. Micro regurgitation with ROPLAS test as described earlier can be useful in cases where there is no frank regurgitation.
6. Conjunctival congestion

Fluorescein Dye Disappearance test

This is a very useful physiological test which is based on the principle of evaluation of residual fluorescein in the eye following instillation of one drop of fluorescein in unanesthetized conjunctival sac. This is a useful functional test specifically in children as it is easy to obtain results.

STANDARD PROCEDURE:

1. One drop of 1-2% fluorescein is instilled into the lower fornix of each eye.
2. After 5 minutes the thickness of the fluorescent tear meniscus is measured with the help of cobalt blue filter.
3. Children should be held upright during the test.
4. The tears normally drain down in 5 minutes. The test is positive if residual fluorescein is present.
5. The residual fluorescein is graded as Grade 0- No fluorescence , Grade 1- Thin strip of fluorescence, Grade 2- Between grade 1 and 3, and Grade 3- Wide, brightly fluorescence strip.

Diagnostic Probing and Syringing

This is a very simple clinical method which when employed appropriately give useful clues that helps the physician in knowing the presence, location and the form of

obstruction in the lacrimal excretory system. The test qualitatively establishes the patency or stenosis or complete obstruction of the canaliculi, lacrimal sac or nasolacrimal duct but does not give any information on functional insufficiencies.

STANDARD PROCEDURE:

1. Place a drop of topical anesthetic in the conjunctival cul-de-sac.
2. The punctum and the ampulla are dilated with a punctal dilator.
3. A blunt lacrimal canula is placed in the inferior canaliculus and the lower eyelid is pulled down and laterally to straighten the lower canaliculus and evert the punctum away from the ocular surface.
4. The tip is placed first vertically and then horizontally with the eyelid on stretch. The tip is advanced 6-7 mm into the canaliculi and sterile water is used as an irrigant. The irrigation should begin in the canaliculi so that the incoming passages are dilated and the mucosa is less traumatized.
5. Irrigation should be preferred when the tip is in the lacrimal sac. Simultaneous probing can also be done with the same tip of the canula. A hard stop rules out canalicular obstruction whereas a soft stop is indicative of such obstructions.
6. Irrigation should now be interpreted. In a normal passage the saline is felt in the nose or the throat by the patient. Regurgitation through the opposite punctum with a hard stop suggests a nasolacrimal duct obstruction. Regurgitation through the opposite punctum with a soft stop suggests a common canalicular block. In cases of upper or lower canalicular block, regurgitation is seen through the same puncta. Partial regurgitation is associated with partial blocks respectively.

b) Investigations:

Chronic dacryocystitis is usually diagnosed by history, physical examination and simple investigations where needed.

Microbiological work up: A regular microbiological examination is not necessary unless there are recurrent attacks of acute dacryocystitis, lacrimal abscess or any associated canaliculitis. If additional microbiological work up is needed or other imaging modalities like computed tomography or dacryocystography is the felt need than a referral to higher center must be thought of.

c) Treatment:

The treatment of choice in chronic dacryocystitis is dacryocystorhinostomy (DCR). Additional procedures along with dacryocystorhinostomy like intubation, use of adjunctive pharmacotherapy like mitomycin-C and canalicular trephining depends upon multiple factors like presence of canalicular obstructions, intra-sac synechiae or

repeat surgeries. Dacryocystorhinostomy is a bypass procedure that creates an anastomosis between the lacrimal sac and the nasal mucosa via a bony ostium. It may be performed through an external skin incision or endo-nasally with or without endoscopic visualization or via the transcanalicular approach. The most commonly done approach is the External DCR which is still considered as a gold standard in management of chronic dacryocystitis.

Standard procedure

1. Adequate nasal decongestion and nasal packing preoperatively is helpful.
2. Anesthesia can be local or general. Local anesthesia includes topical in conjunctival cul-de-sac, infratrochlear block and local infiltration.
3. Skin incision either straight or curvilinear can be used.
4. Periosteum over the anterior lacrimal crest is raised and the lacrimal sac is reflected laterally.
5. A large bony osteum is created respecting the anatomic boundaries.
6. Flaps of nasal mucosa and lacrimal sac raised. Posterior flaps are excised.
7. Adjunctive pharmacotherapy or intubation is done if needed.
8. Anterior flaps are sutured with 6-0 vicryl and skin is sutured with 6-0 silk or prolene.
9. Nasal packing is done to soak the blood and hemostasis.

Standard Operating Procedure

a. In Patient :

- Admit patients after the surgical procedure to monitor the vitals and signs of bleeding especially if they are from far off places.
- Admit patients with complications like orbital cellulitis or severe acute dacryocystitis for intravenous antibiotics.

b. Out Patient: Not applicable.

c. Day Care: Patients after the surgical procedure are kept under observation for 4-5 hours for any bleeding and then can be discharged if they are stable.

d) Referral criteria:

- Lacrimal obstruction at multiple sites.
- Failed Dacryocystorhinostomy.
- Complications of chronic dacryocystitis like recurrent acute exacerbations or orbital cellulitis.
- Chronic dacryocystitis associated with systemic diseases like sarcoidosis or Wegener's granulomatosis.

- Chronic dacryocystitis associated with suspected dacryolithiasis.
- Chronic dacryocystitis where there is a suspicion of a lacrimal sac tumor.

***Situation 2: At Super Specialty Facility in Metro location where higher-end technology is available**

a) Clinical Diagnosis:

Apart from the regular history taking, care should be exercised to fully understand the treatment history of the patient, including all the medications along with the dosage schedules which were prescribed at the secondary centre. In fact, withdrawal of strong topical antibiotics may be warranted. A fresh comprehensive clinical examination, as detailed in the previous section should be performed without being biased by the referral report.

DIAGNOSTIC NASAL ENDOSCOPY:

Nasal examination especially nasal endoscopy is obligatory for every lacrimal patient. An endoscopy provides a clear diagnostic look for nasal anatomical variations, nasal polyps, deviated nasal septum or tumors of the lacrimal sac. It is a very important for clinical evaluation in postoperative patients and after failed lacrimal surgery. The procedures are performed through rigid or flexible 2.7mm or 4mm endoscopes.

STANDARD PROCEDURE

1. Nasal mucosa is decongested and anesthetized with topical medications.
2. The patient either sits or lies in a relaxed position.
3. Nasal vestibule, inferior meatus, floor of the nose and nasopharynx are examined.
4. Middle turbinates and meatus is examined and then the scope is directed postero-superiorly to evaluate the sphenoid-ethmoidal recess and superior meatus.

b) Investigation

As the patients are referred from a secondary centre for a non responsiveness to treatment or when diagnosis is additional microbiological and imaging studies may be required.

- **Culture:** Culture and sensitivity of the discharge is indicated specially in cases of orbital cellulitis or recurrent lacrimal abscess. When performed, collect discharge with a calcium alginate swab moistened with saline. Apart from smears for gram and giemsa staining, culture onto blood and chocolate agar is

taken.

- Imaging: CT Scans are useful in elucidating facial skeletal anomalies, fractures or foreign bodies as the cause of lacrimal disorder. It is also useful rule out occult malignancy or mass as a cause of dacryocystitis. Dacryocystography(DCG) with subtraction or CT-DCG is very sensitive to study the anatomy of the lacrimal sac and surrounding structures. Dacryoscintigraphy (DSG) is done with the help of Technetium 99 and gamma camera and is useful in providing certain insights into the functional causes of epiphora.

c) Treatment: The treatment strategies should be revisited to check for adequacy, appropriateness and affordability. If the culture and other tests show a different organism, then the treatment regimen should be modified.

Surgical procedure includes:

1. External Dacryocystorhinostomy or repeat external DCR as described in the earlier section.
2. Endoscopic endonasal revision of past DCR.
3. Endoscopic guided secondary intubations
4. Canalicular trephining and use of monoka stents
5. Laser assisted DCR or Laser assisted revision of a failed DCR.
6. Conjunctival DCR with Jones tubes.
7. Balloon assisted DCR revision.
8. Balloon dacryoplasty and canaliculoplasty.

STANDARD OPERATING PROCEDURE

a. In Patient :

- All procedures planned under general anesthesia.
- Revision DCR's as there is more tendency to bleed in postoperative period.
- Patients with complications like orbital cellulitis on referral or postoperative severe bleeding.

b. Out Patient: Not applicable.

c. Day Care: Patients after the surgical procedure are kept under observation for 4-5 hours for any bleeding and then can be discharged if they are stable.

d) Referral criteria: not applicable.

VI. WHO DOES WHAT? AND TIMELINES

a. Doctor :

- Patient history is taken and a clinical examination performed.
- Infective material is obtained from discharge and smear are prepared and also materials are inoculated directly onto culture media
- Documenting the medical record
- Plan treatment guidelines and perform surgery if necessary .
- He/she should also ensure that needy patients receive necessary care directly or through referral to appropriate persons and facilities that will provide such care, and he or she supports activities that promote health and prevent disease.

b. Nurse/Technician:

- Prepare Slide, Media for smear and culture.
- To monitor the patients who are admitted.
- To maintain separate inpatient and outpatient record.
- To maintain lab reports.

VII. FURTHER READING / REFERENCES

1. Mills DM, Bodman GM, Meyer DL, et al. The microbiological spectrum of dacryocystitis: A national study of acute versus chronic infection. *Ophthal Plast Reconstr Surg* 2007;23:302-306.
2. Chaudhry IA, Shamsi FA, Rashed WA. Bacteriology of chronic dacryocystitis in a tertiary care center. *Ophthal Plast Reconstr Surg* 2005;21:207-210.
3. Kotlus BS, Rodgers R, Udell IJ. Dacryocystitis caused by community onset methicillin resistant staphylococcus aureus. *Ophthal Plast Reconstr Surg* 2005;21:371-375.
4. Linberg JV, McCormick SA. Primary acquired nasolacrimal duct obstruction: A clinico-pathological report. *Ophthalmology* 1986;93:1055-1062.
6. Bartley GB. Acquired lacrimal drainage obstructions: An etiologic classification system, case reports and review of literature. *Ophthal Plast Reconstr Surg* 1992;8:237-249.

6. Rosen N, Mordechai S, Moverman DC et al. Dacryocystorhinostomy with silicone tubes: Evaluation of 253 cases. *Ophthalmic Surg* 1989;20:115-119.

7. Dresner SC, Klussman KG, Meyer DR. Outpatient dacryocystorhinostomy. *Ophthalmic Surg* 1991;22:222-224.

8. Emmerich KH, Busse H, Meyer-Rusenberg HW. Dacryocystorhinostomia externa. *Ophthalmologie* 1994;91:395-39

Resources required

Situation	HUMAN RESOURCES	INVESTIGATION	DRUGS AND CONSUMABLES	EQUIPMENT
1) Secondary level	1)Ophthalmologist - 1 2)OP Nurse - 1 3)Refraction nurse - 1 (shared) 4) OT Nurse -1 5) Scrub Nurse -1 6) Ward Nurse -1 7) Counselor -1	Smear test 1)Gram stain 2)Giemsa stain	1)Antibiotics eye drops and ointment 2)Steroid eye drops 3)Systemic antibiotics and NSAIDS 4) Nasal decongestant drops 5) Nasal steroid spray. 6) Betadine 5%	1)Slit lamp - biomicroscopy -1 2)Light microscopy -1 3)Alginate swabs – 1 4)Glass slide - 1 5)Basic stains - 1 6) OT Headlight -1 7) Suction mach -1 8) Cautery -1 9) DCR SETS -2
2) Tertiary level	1)Ophthalmic plastics specialist - 1 2)Refraction nurse - 1 (shared) 3)OP Nurse - 1 4)lab technician – 1 5)Scrub nurse 1 6)OT nurse 1 7)Ward nurse - 1 8) Counselor - 1	1)Smear test 2)Culture medium 3)Drug sensitivity 4)Nasal endoscopy 5) CT Scan 6) DCG/DSG	1)Antibiotics eye drops and ointment 2)Steroid eye drops 3)Systemic antibiotics and NSAIDS 4) Nasal decongestant drops 5) Nasal steroid spray. 6) Betadine 5%	1)Slit lamp - biomicroscopy -1 2)Light microscopy -1 3)Alginate swabs – 1 4)Glass slide - 1 5)Basic stains - 1 6) OT Headlight -1 7) Suction mach -1 8) Cautery -1 9) DCR SETS -2 10)Nasal endoscope - 1

NAME OF CONDITION : RETINOBLASTOMA

I. WHEN TO SUSPECT/ RECOGNIZE?

a) Introduction:

Retinoblastoma is the most common intraocular malignancy of childhood. It is second only to uveal melanoma in the frequency of occurrence of malignant intraocular tumors. Although it is highly malignant, it is eminently curable. The recent advances such as identification of genetic mutations, replacement of external beam radiotherapy by chemoreduction as the primary management modality, use of chemoreduction to minimize the size of regression scar with consequent optimization of visual potential, identification of histopathologic high-risk factors following enucleation and provision of adjuvant therapy to reduce the incidence of systemic metastasis, protocol-based management of retinoblastoma with accidental perforation or intraocular surgery and aggressive multimodal therapy in the management of orbital retinoblastoma have contributed to improved outcome in terms of better survival, improved eye salvage and potential for optimal visual recovery. Life salvage has improved from 30% in the 1930s to nearly 95% now. Early diagnosis and appropriate referral are the keys to better outcome.

b)Case definition:

Retinoblastoma is a malignant tumor arising from the retinal progenitor cell or the retinal stem cell during the period of retinal development and occurs predominantly in children under 3 years of age.

II. INCIDENCE OF THE CONDITION IN OUR COUNTRY

The reported incidence of retinoblastoma ranges from 1 in 10,000 to 1 in 20,000 live births. There are no good epidemiological studies that provide the accurate data on incidence of retinoblastoma in India. It is estimated that 1500 new cases of retinoblastoma occur in India every year. The ICMR Indian Retinoblastoma Registry has recorded 1019 cases from 8 treatment centers between April 2009 to December 2010. There is no racial or gender predisposition in the incidence of retinoblastoma. Retinoblastoma is bilateral in about 25 to 35% of cases. The average age at diagnosis is 18 months, unilateral cases being diagnosed at around 24 months and bilateral cases before 12 months.

III. DIFFERENTIAL DIAGNOSIS

The typical clinical manifestation of retinoblastoma is leucocoria. There are several other causes for leucocoria in children that may clinically mimic retinoblastoma in children. Some of the common differential diagnosis are:

1. Coats' Disease
2. Persistent Hyperplastic Primary Vitreous
3. Toxocara Retinal Granuloma
4. Congenital or Developmental Cataract
5. Endogenous Endophthalmitis
6. Retinal Dysplasia
7. Astrocytic Hamartoma

A good history regarding the time of onset and course of the disease, comprehensive ophthalmic examination often under anesthesia, ultrasonography B-scan and computed tomography scan can reliably help differentiate retinoblastoma from pseudoretinoblastomas.

IV. PREVENTION AND COUNSELING

Out of the newly diagnosed cases of retinoblastoma only 6% are familial while 94% are sporadic. Bilateral retinoblastomas involve germinal mutations in all cases. Approximately 15% of unilateral sporadic retinoblastoma is caused by germinal mutations affecting only one eye while the 85% are sporadic.

Genetic counseling is an important aspect in the management of retinoblastoma. In patients with a positive family history, 40% of the siblings would be at risk of developing retinoblastoma and 40% of the offspring of the affected patient may develop retinoblastoma. In patients with no family history of retinoblastoma, if the affected child has unilateral retinoblastoma, 1% of the siblings are at risk and 8% of the offspring may develop retinoblastoma. In cases of bilateral retinoblastoma with no positive family history, 6% of the siblings and 40% of the offspring have a chance of developing retinoblastoma. The families are counseled to have every future sibling screened for retinoblastoma within 3 weeks after birth and periodically thereafter until at least 3 years of age. Apart from empiric genetic counseling as described above, the current trend is to identify the mutation and compute specific antenatal risk.

The most important aspect in the management of retinoblastoma is early diagnosis. Early diagnosis can be achieved by increasing public awareness about the most common obvious signs (white reflex as seen externally or on a photograph of the child or squint) of retinoblastoma so that the parents bring the child to medical attention. Concurrent sensitization of the medical community, specifically the pediatricians, pediatric health care workers and general ophthalmologists about the possible signs of retinoblastoma and the need for early initiation of management can not be overemphasized.

V. OPTIMAL DIAGNOSTIC CRITERIA, INVESTIGATIONS, TREATMENT & REFERRAL CRITERIA

Situation 1: At Secondary Hospital/ Non-Metro situation: Optimal Standards of Treatment in Situations where technology and resources are limited

a) Clinical Diagnosis:

A good history eliciting specific symptoms and also a family history of retinoblastoma are essential. Leucocoria is the most common presenting feature of retinoblastoma, followed by strabismus, painful blind eye and loss of vision. The clinical presentation of retinoblastoma depends on the stage of the disease. Early lesions are likely to be missed, unless an indirect ophthalmoscopy is performed. The tumor appears as a translucent or white fluffy retinal mass. The child may present with strabismus if the tumor involves the macula or with reduced visual acuity.

Moderately advanced lesions usually present with leucocoria due to the reflection of light by the white mass in the fundus.

Advanced tumors manifest with proptosis secondary to optic nerve extension or orbital extension and systemic metastasis. Retinoblastoma can spread through the optic nerve with relative ease especially once the lamina cribrosa is breached. Orbital extension may present with proptosis and is most likely to occur at the site of the scleral emissary veins. Systemic metastasis occurs to the brain, skull, distant bones and the lymph nodes.

Some of the atypical manifestations of retinoblastoma include pseudohypopyon, spontaneous hyphema, vitreous hemorrhage, phthisis bulbi and preseptal or orbital cellulites.

Examination: The ocular examination includes estimation of vision by age-appropriate means, an external examination, distant direct ophthalmoscopy, examination of the eye under good illumination and magnification, direct ophthalmoscopy and indirect ophthalmoscopy. A child with suspected retinoblastoma necessarily needs examination under anesthesia. The intraocular pressure is measured and the anterior segment and fundus are examined. Direct visualization of the tumor by an indirect ophthalmoscope is diagnostic of retinoblastoma in over 90% of cases.

Visual acuity measurement: Visual acuity assessment in children is difficult. A 3-12 month old child can only be assessed by fixation and following responses and by determining if one eye is preferred. A child in the age range of 12 months to 36 months can be dynamically assessed using familiar toys. An older verbal child can be assessed by using picture chart and alphabets.

External examination

1. Regional enlargement of lymph nodes
2. Eyelid and periocular edema
3. Proptosis and displacement

Slit-lamp Biomicroscopy (Handheld slit-lamp in younger children) or Examination under illumination and magnification

1. Conjunctival congestion, circumciliary congestion
2. Anterior extraocular extension
3. Corneal horizontal diameter and clarity
4. Depth of anterior chamber, presence of tumor hypopyon
5. Iris neovascularization
6. Cataract

Fundus Evaluation

1. Bilateral fundus examination with 360 degree scleral depression
2. Tumor location, size, morphology, vascularity
3. Extent and location of subretinal fluid, subretinal seeds and vitreous seeds

b) Investigations:

Ultrasonography B-scan helps in confirming the clinical diagnosis when in doubt or if the tumor is not directly visible because of media haze. CT-scan is reserved only to rule out suspected extraocular extension and MRI to rule out optic nerve or intracranial extension and pinealoblastoma. Fundus fluorescein angiography is rarely performed. Bone marrow biopsy is performed to rule out systemic metastasis in cases with clinical or histopathological risk factors and CSF cytology to rule out intracranial extension or CNS metastasis.

Management:

Classification

International Classification of Intraocular Retinoblastoma

Group A	Small tumors (< 3 mm) outside macula
Group B	Bigger tumors (> 3 mm) or any tumor in macula or any tumor with subretinal fluid
Group C	Localized seeds (subretinal or vitreous)
Group D	Diffuse seeds (subretinal or vitreous)
Group E	Tumor touching the lens, Neovascular glaucoma, Tumor anterior to anterior vitreous face involving ciliary body or anterior segment, Diffuse infiltrating retinoblastoma, Opaque media from hemorrhage, Tumor necrosis with aseptic orbital cellulitis, and Phthisis bulbi

International Staging System for Retinoblastoma

Stage 0	No enucleation (one or both eyes may have intraocular disease)
Stage I	Enucleation, tumor completely resected
Stage II	Enucleation with microscopic residual tumor
Stage III	Regional extension A Overt orbital disease B Preauricular or cervical lymph node extension
Stage IV	Metastatic disease A Hematogenous metastasis 1 Single lesion 2 Multiple lesions

- B CNS Extension
- 1 Prechiasmatic lesion
- 2 CNS mass
- 3 Leptomeningeal disease

C)Treatment

- A. Intraocular tumor, International Classification Group A to C, Unilateral or Bilateral
Refer to retinoblastoma treatment center
- B. Intraocular tumor, International Classification Group D, Unilateral or Bilateral
Refer to retinoblastoma treatment center
- C. Intraocular tumor, International Classification Group E, Unilateral or Bilateral
 - 1. Primary enucleation with PMMA orbital implant
Special considerations for enucleation in retinoblastoma
 - Minimal manipulation
 - Avoid perforation of the eye
 - Harvest long (> 15 mm) optic nerve stump
 - Inspect the enucleated eye for macroscopic extraocular extension and optic nerve involvement
 - Harvest fresh tissue for genetic studies
 - Avoid biointegrated implant if postoperative radiotherapy is necessary
 - 2. Send specimen for histopathology and high risk factors predictive of metastasis
 - Anterior chamber seeding
 - Iris infiltration
 - Ciliary body infiltration
 - Massive choroidal infiltration
 - Invasion of the optic nerve lamina cribrosa
 - Retrolaminar optic nerve invasion
 - Invasion of optic nerve transection
 - Scleral infiltration
 - Extrascleral extension
- D. High risk factors on histopathology, International Staging, Stage II
Refer to retinoblastoma treatment center

- E. Extraocular tumor, International Staging, Stage IIIA
Refer to retinoblastoma treatment center
- F. Regional Lymph Node Metastasis, International Staging, Stage IIIB
Refer to retinoblastoma treatment center
- G. Hematogenous or Central Nervous System Metastasis, International Staging, Stage IV
Refer to retinoblastoma treatment center

Standard Operating Procedure

- a. In-Patient :Admit patients for enucleation
- b. Out Patient: All older children who can cooperate for examination
- c. Day Care: All children undergoing examination under anesthesia

c) Referral criteria:

- a) Intraocular tumor, International Classification Group A to C, Unilateral or Bilateral
- b) Intraocular tumor, International Classification Group D, Unilateral or Bilateral
- c) High risk factors on histopathology, International Staging, Stage II
- d) Extraocular tumor, International Staging, Stage IIIA
- e) Regional Lymph Node Metastasis, International Staging, Stage IIIB
- f) Hematogenous or Central Nervous System Metastasis, International Staging, Stage IV

Situation 2: At Super Specialty Facility in Metro location where higher-end technology is available

a) Clinical Diagnosis:

A good history eliciting specific symptoms and also a family history of retinoblastoma are essential. Leucocoria is the most common presenting feature of retinoblastoma, followed by strabismus, painful blind eye and loss of vision. The clinical presentation of retinoblastoma depends on the stage of the disease. Early lesions are likely to be missed, unless an indirect ophthalmoscopy is performed. The tumor appears as a translucent or white fluffy retinal mass. The child may present with strabismus if the tumor involves the macula or with reduced visual acuity.

Moderately advanced lesions usually present with leucocoria due to the reflection of light by the white mass in the fundus. As the tumor grows further, three patterns are usually seen:

- Endophytic, in which the tumor grows into the vitreous cavity. A yellow white mass progressively fills the entire vitreous cavity and vitreous seeds occur. The retinal vessels are not seen on the tumor surface.
- Exophytic, in which the tumor grows towards the subretinal space. Retinal detachment usually occurs and retinal vessels are seen over the tumor.
- Diffuse infiltrating tumor, in which the tumor diffusely involves the retina causing just a placoid thickening of the retina and not a mass. This is generally seen in older children and usually there is a delay in the diagnosis.

Advanced tumors manifest with proptosis secondary to optic nerve extension or orbital extension and systemic metastasis. Retinoblastoma can spread through the optic nerve with relative ease especially once the lamina cribrosa is breached. Orbital extension may present with proptosis and is most likely to occur at the site of the scleral emissary veins. Systemic metastasis occurs to the brain, skull, distant bones and the lymph nodes.

Some of the atypical manifestations of retinoblastoma include pseudohypopyon, spontaneous hyphema, vitreous hemorrhage, phthisis bulbi and preseptal or orbital cellulites.

Examination: The ocular examination includes estimation of vision by age-appropriate means, an external examination, distant direct ophthalmoscopy, examination of the eye under good illumination and magnification, direct ophthalmoscopy and indirect ophthalmoscopy. A child with suspected retinoblastoma necessarily needs examination under anaesthesia. The intraocular pressure is measured and the anterior segment and fundus are examined. Direct visualization of the tumor by an indirect ophthalmoscope is diagnostic of retinoblastoma in over 90% of cases.

Visual acuity measurement: Visual acuity assessment in children is difficult. A 3-12 month old child can only be assessed by fixation and following responses and by determining if one eye is preferred. A child in the age range of 12 months to 36 months can be dynamically assessed using familiar toys. An older verbal child can be assessed by using picture chart and alphabets.

External examination

1. Regional enlargement of lymph nodes
2. Eyelid and periocular edema
3. Proptosis and displacement

Slit-lamp Biomicroscopy (Handheld slit-lamp in younger children) or Examination under illumination and magnification

1. Conjunctival congestion, circumciliary congestion
2. Anterior extraocular extension
3. Corneal horizontal diameter and clarity
4. Depth of anterior chamber, presence of tumor hypopyon
5. Iris neovascularization
6. Cataract

Fundus Evaluation

1. Bilateral fundus examination with 360 degree scleral depression
2. Tumor location, size, morphology, vascularity
3. Extent and location of subretinal fluid, subretinal seeds and vitreous seeds

b) Investigations:

Ultrasonography B-scan helps in confirming the clinical diagnosis when in doubt or if the tumor is not directly visible because of media haze. CT-scan is reserved only to rule out suspected extraocular extension and MRI to rule out optic nerve or intracranial extension and pinealoblastoma. Fundus fluorescein angiography is rarely performed. Bone marrow biopsy is performed to rule out systemic metastasis in cases with clinical or histopathological risk factors and CSF cytology to rule out intracranial extension or CNS metastasis.

Management:

- A. Intraocular tumor, International Classification Group A to C, Unilateral or Bilateral
1. Focal therapy (cryotherapy or transpupillary thermotherapy) alone for smaller tumors (< 3mm diameter and height) located in visually noncrucial areas
 2. Standard 6 cycle chemoreduction and sequential aggressive focal therapy for larger tumors and those located in visually crucial areas
 3. Defer focal therapy until 6 cycles for tumors located in the macular and juxtapapillary areas. Transpupillary thermotherapy or plaque brachytherapy for residual tumor >6 cycles.
 4. Focal therapy for small residual tumor, and plaque brachytherapy/external beam radiotherapy (>12 months age) for large residual tumor if bilateral, and enucleation if unilateral.

- B. Intraocular tumor, International Classification Group D, Unilateral or Bilateral
 - 1. High dose chemotherapy and sequential aggressive focal therapy
 - 2. Periocular carboplatin for vitreous seeds
 - 3. Consider primary enucleation if unilateral specially in eyes with no visual prognosis

- C. Intraocular tumor, International Classification Group E, Unilateral or Bilateral
 - 1. Primary enucleation with PMMA orbital implant
Special considerations for enucleation in retinoblastoma
 - Minimal manipulation
 - Avoid perforation of the eye
 - Harvest long (> 15 mm) optic nerve stump
 - Inspect the enucleated eye for macroscopic extraocular extension and optic nerve involvement
 - Harvest fresh tissue for genetic studies
 - Avoid biointegrated implant if postoperative radiotherapy is necessary

 - 2. Send specimen for histopathology and high risk factors predictive of metastasis
 - Anterior chamber seeding
 - Iris infiltration
 - Ciliary body infiltration
 - Massive choroidal infiltration
 - Invasion of the optic nerve lamina cribrosa
 - Retrolaminar optic nerve invasion
 - Invasion of optic nerve transection
 - Scleral infiltration
 - Extrascleral extension

- D. High risk factors on histopathology, International Staging, Stage II
 - 1. Standard 6 cycle adjuvant chemotherapy
 - 2. High dose adjuvant chemotherapy and orbital external beam radiotherapy in patients with scleral infiltration, extraocular extension, and optic nerve extension to transection.

- E. Extraocular tumor, International Staging, Stage IIIA
 - 1. Baseline systemic evaluation for metastasis

2. High dose chemotherapy for 3-6 cycles, followed by enucleation or extended enucleation, external beam radiotherapy, and continued chemotherapy for 12 cycles
- F. Regional Lymph Node Metastasis, International Staging, Stage IIIB
1. Baseline evaluation for systemic metastasis
 2. Neck dissection, high dose chemotherapy for 6 cycles, followed by external beam radiotherapy, and continued chemotherapy for 12 cycles
- G. Hematogenous or Central Nervous System Metastasis, International Staging, Stage IV
- Palliative therapy in discussion with the family

Standard Operating Procedure

a. In-Patient :

- Admit patients for surgery and chemotherapy
- Admit patients with complications following chemotherapy

b. Out Patient: All older children who can cooperate for examination

c. Day Care: All children undergoing examination under anesthesia and focal treatment.

c) Referral criteria: not applicable

VI. WHO DOES WHAT? AND TIMELINES

a. Doctor :

- Patient history is taken and a clinical examination performed
- Documenting the medical record
- Plan treatment guidelines and perform surgery if necessary.
- Awareness of public and medical personnel

b. Nurse/Technician:

- Perform lab tests
- To monitor the patients who are admitted
- To maintain separate inpatient and outpatient record

- To administer medications as prescribed by the Physician

VII. FURTHER READING / REFERENCES

1. Shields JA, Shields CL. Intraocular tumors – A text and Atlas. Philadelphia, PA, USA, WB Saunders Company, 1992.
2. Shields CL, Honavar SG, Shields JA, Demirci H, Meadows AT, Naduvilath TJ. Factors predictive of recurrence of retinal tumors, vitreous seeds, and subretinal seeds following chemoreduction for retinoblastoma. *Arch Ophthalmol.* 2002;120:460-4.
3. Shields CL, Honavar SG, Meadows AT, Shields JA, Demirci H, Singh A, Friedman DL, Naduvilath TJ. Chemoreduction plus focal therapy for retinoblastoma: factors predictive of need for treatment with external beam radiotherapy or enucleation. *Am J Ophthalmol.* 2002;133:657-64.
4. Shields CL, Honavar SG, Meadows AT, Shields JA, Demirci H, Naduvilath TJ. Chemoreduction for unilateral retinoblastoma. *Arch Ophthalmol.* 2002;120:1653-8.
5. Murthy R, Honavar SG, Naik MN, Reddy VA. Retinoblastoma. In: Dutta LC, ed. *Modern Ophthalmology*. New Delhi, India, Jaypee Brothers; 2004:849-859.
6. Honavar SG, Singh AD. Management of advanced retinoblastoma. *Ophthalmol Clin North Am.* 2005;18:65-73.
7. Vemuganti G, Honavar SG, John R. Clinicopathological profile of retinoblastoma in Asian Indians. *Invest Ophthalmol Vis Sci* 2000; 41(S):790.
8. Abramson DH, Frank CM, Susman M, Whalen MP, Dunkel IJ, Boyd NW 3rd. Presenting signs of retinoblastoma. *J Pediatr.* 1998; 132:505-8.
9. Ellsworth RM. The practical management of retinoblastoma. *Trans Am Ophthalmol Soc* 1969; 67: 462-534.
10. Shields CL, Shields JA. Basic understanding of current classification and management of retinoblastoma. *Curr Opin Ophthalmol.* 2006;17:228-34.
11. Chantada G, Doz F, Antoneli CB, et al A proposal for an international retinoblastoma staging system *Pediatr Blood Cancer* 2006;47;801-805
12. Hungerford JL, Toma NMG, Plowman PN, Kingston JE. External beam radiotherapy for retinoblastoma: I, whole eye technique. *Br J Ophthalmol.* 1995; 79: 112-117.
13. Ferris FL, 3rd, Chew EY. A new era for the treatment of retinoblastoma. *Arch Ophthalmol* 1996; 114:1412.

14. Kingston JE, Hungerford JL, Madreperla SA, Plowman PN. Results of combined chemotherapy and radiotherapy for advanced intraocular retinoblastoma. Archives of Ophthalmology 1996; 114:1339-43.
15. Gallie BL, Budning A, DeBoer G, Thiessen JJ, Koren G, Verjee Z, et al. Chemotherapy with focal therapy can cure intraocular retinoblastoma without radiotherapy. Arch Ophthalmol 1996; 114:1321-8.
16. Murphree AL, Villablanca JG, Deegan WF, 3rd, Sato JK, Malogolowkin M, Fisher A, et al. Chemotherapy plus local treatment in the management of intraocular retinoblastoma. Arch Ophthalmol 1996; 114:1348-56.
17. Shields CL, De Potter P, Himelstein BP, Shields JA, Meadows AT, Maris JM. Chemoreduction in the initial management of intraocular retinoblastoma. Arch Ophthalmol 1996; 114:1330-8.
18. Singh AD, Shields CL, Shields JA. Prognostic factors in retinoblastoma. J Pediatr Ophthalmol Strab 2000; 37:134-41.
19. Honavar SG, Singh AD, Shields CL, Demirci H, Smith AF, Shields JA. Post-enucleation prophylactic chemotherapy in high- risk retinoblastoma. Arch Ophthalmol 2002; 120:923-31.

Resources required

Situation	HUMAN RESOURCES	INVESTIGATION	DRUGS AND CONSUMABLES	EQUIPMENT
1) Secondary level	<ul style="list-style-type: none"> • 1 Ophthalmologist • 1 OP Nurse • 1 IP Nurse • 1 Medicosocial worker 	<ul style="list-style-type: none"> • Ultrasound B-scan 	<ul style="list-style-type: none"> • Surgical set for enucleation • Facility for general anesthesia • Topical antibiotics, topical steroids, oral anti-inflammatory drugs, oral antibiotics 	<ul style="list-style-type: none"> • Slit-lamp • Perkins applanation tonometer • Direct ophthalmoscope • Indirect ophthalmoscope
2) Tertiary level	<ul style="list-style-type: none"> • 3 Ocular Oncologist or Ophthalmic Plastic Surgeon or Retinal Surgeon • 3 OP Nurse • 3 IP Nurse • 2 Medicosocial worker 	<ul style="list-style-type: none"> • Ultrasound B-scan • CT-scan • MRI • Pathology Laboratory 	<ul style="list-style-type: none"> • Surgical set for enucleation and orbital exenteration • Cryotherapy • Transpupillary Thermotherapy • Plaque Brachytherapy • EBRT • Facility for Chemotherapy • Facility for general anesthesia • Topical antibiotics, topical steroids, oral anti-inflammatory drugs, oral antibiotics 	<ul style="list-style-type: none"> • Slit-lamp • Perkins applanation tonometer • Direct ophthalmoscope • Indirect ophthalmoscope • Wide-field fundus imaging • Fundus fluorescein angiography