



EYE EMERGENCY MANUAL

An Illustrated Guide

Second Edition

LOCAL EMERGENCY NUMBERS:

FOR URGENT REFERRAL PLEASE CALL THE OPHTHALMOLOGIST ON
CALL FOR YOUR HOSPITAL:

NAME: _____ NO: _____

FOR REFERRAL TO LOCAL OPHTHALMOLOGIST/S PLEASE PHONE:

NAME: _____ NO: _____

NAME: _____ NO: _____

IF OPHTHALMOLOGIST UNAVAILABLE LOCALLY, RING SYDNEY
HOSPITAL & SYDNEY EYE HOSPITAL ON **(02) 9382 7111**

OTHER IMPORTANT NUMBERS:

NAME/POSITION: _____ NO: _____

NAME/POSITION: _____ NO: _____

Disclaimer

This manual is designed for use by all medical and nursing staff in Emergency Departments across New South Wales. It is intended to provide a general guide to recognizing and managing the specified injuries, subject to the exercise of the treating clinician's judgment in each case. The GMCT (NSW Statewide Ophthalmology Service) NSW Health and the State of New South Wales do not accept any liability arising from the use of the manual. For advice about an eye emergency, please contact the ophthalmologist affiliated with your hospital in the first instance. If unavailable contact Sydney Hospital/Sydney Eye Hospital on (02) 9382 7111.

Copyright

© NSW Department of Health
73 Miller St NORTH SYDNEY NSW 2061
Phone (02) 9391 9000 Fax (02) 9391 9101 TTY (02) 9391 9900
www.health.nsw.gov.au

This work is copyright. It may be reproduced in whole or in part for study training purposes subject to the inclusion of an acknowledgement of the source. It may not be reproduced for commercial usage or sale. Reproduction for purposes other than those indicated above, requires written permission from the NSW Department of Health.

SHPN: (GMCT) 060125
ISBN: 0 7347 3988 5

For further copies please contact:

Better Health Centre
Phone: +61 2 9887 5450
Fax: +61 2 9887 5879

First Edition February 2007

Second Edition May 2009

Acknowledgements

The Statewide Ophthalmology Service (SOS) Provision of Hospital Services Subcommittee in conjunction with the SOS Nurse Standing Committee proposed this manual and asked Dr Weng Sehu to develop it based on his existing education material.

Dr Sehu as principal author and editor would like to thank Dr Brighu Swamy, Ms Ellen Moore, and Ms Jill Grasso, from Sydney Hospital/Sydney Eye Hospital, Dr James Smith, from Royal North Shore Hospital, Ms Kathryn Thompson from the School of Applied Vision Sciences, University of Sydney, and Ms Annie Hutton from the SOS for all the time and effort they put into developing the first edition of this useful tool for non-ophthalmic clinicians.

A special thank you to Drs Con Petsoglou, Peter Martin and Alex Hunyor for providing some of the images in this manual, Ms Louise Buchanan for layout and graphic design, and Mr Glenn Sisson, from NSW Institute of Trauma and Injury Management (ITIM) for assistance with desktop publishing.

Acknowledgements for the Second Edition

Review of the first edition of the Eye Emergency Manual (EEM) has been oversighted by the EEM Steering Committee chaired by Dr Ralph Higgins and including the principal author Dr Weng Sehu. Louise Buchanan again provided layout and graphic design services.

The consensus clinical guidelines published in the EEM have been introduced into 24 NSW Emergency Departments as part of a funded project to improve eye emergency care and evaluate the manual's use. Carmel Smith as SOS project officer facilitated feedback from emergency clinicians involved in the project. The majority of amendments provided have been incorporated into this second edition.

The SOS would like to thank the Steering Committee, emergency clinicians who have given so freely of their time, and Carmel Smith and Jan Steen SOS Executive Director for coordinating everyone's contributions. As well special thanks to Sydney Hospital/ Sydney Eye Hospital Ophthalmic Nurse Educator, Cheryl Moore for her contribution to the discussion about clinical practice.

Eye Emergency Manual (EEM) Steering Committee

Ralph Higgins OAM (Chair)	Ophthalmologist	Sydney & Sydney Eye Hosp, SESIAHS
Jan Steen	Executive Director	NSW SOS
Carmel Smith	Project Officer / ED RN	NSW SOS
Weng Sehu	Principal Author / Ophthalmologist	Sydney & Sydney Eye Hosp, SESIAHS
Peter McCluskey	Professor of Ophthalmology	University of Sydney
Jill Grasso	Clinical Nurse Consultant	Sydney & Sydney Eye Hosp, SESIAHS
Alwyn Thomas AM	Consumer Participant	
Sue Silveira	Head Orthoptist	Children's Hospital Westmead
Michael Golding	Emergency Physician	Australasian College of Emergency Medicine
Brighu Swamy	Trainee Ophthalmologist	
Liz Cloughessy	Executive Director	Australian College of Emergency Nursing (ACEN)
Subhashini Kadappu	Ophthalmology Research Fellow	Children's Hospital Westmead
Merridy Gina	A/Executive Manager	Institute of Trauma Education & Clinical Standards (ITECS)
James Smith	Head of Ophthalmology Department	RNSH, NSCCAHS
Annette Pantle	Director of Clinical Practice Improvement Projects	Clinical Excellence Commission (CEC)
Joanna McCulloch	Transitional Nurse Practitioner (Ophthalmology)	Sydney & Sydney Eye Hosp, SESIAHS
Janet Long	Community Liaison CNC (Ophthalmology)	Sydney & Sydney Eye Hosp, SESIAHS

Sponsors & Endorsements

This manual is sponsored by the SOS and the Greater Metropolitan Clinical Taskforce (GMCT), a Health Priority Taskforce of the NSW Department of Health. It is endorsed by the NSW Faculty of the Australasian College of Emergency Medicine (ACEM); the Australian College of Emergency Nursing (ACEN); the Royal Australian and New Zealand College of Ophthalmologists (RANZCO) and the 'Save Sight Institute,' University of Sydney.

Table of Contents

Introduction	7
Chapter One Anatomy.....	9
Chapter Two Ophthalmic Workup	13
History.....	15
Important points	15
Examination	15
Visual acuity.....	16
Slit-lamp.....	17
Fundus examination: direct ophthalmoscopy.....	20
Pupil examination.....	21
Paediatric examination.....	22
Treatment.....	25
Everting eyelids.....	25
Eyedrops.....	26
How to pad an eye.....	27
Types of Ocular Drugs.....	28
Common Glaucoma Medications.....	29
Chapter Three Common Emergencies	31
Trauma.....	33
Lid laceration.....	33
Ocular trauma	34
Blunt.....	34
Sharp (penetrating)	35
Corneal foreign body.....	36
Technique for the removal of corneal foreign bodies	37
Chemical Burns.....	38
Eye irrigation for chemical burns.....	38
Flash Burns	39
Orbital	40
Blow-out Fracture.....	40
Acute red eye	42
Painless.....	43
Diffuse.....	43
Localised	44
Painful.....	45
Cornea abnormal	45
Eyelid abnormal.....	46
Diffuse conjunctival injection.....	47
Acute angle closure glaucoma.....	48
Ciliary injection/scleral involvement.....	49
Anterior chamber involvement	49
Acute visual disturbance/Sudden loss of vision	50
Transient Ischaemic Attack (Amaurosis Fugax)	51
Central Retinal Vein Occlusion (CRVO)	52
Central Retinal Artery Occlusion	52
Optic neuritis.....	53
Arteritic Ischaemic Optic Neuropathy (AION)/Giant Cell Arteritis (GCA)	53
Retinal Detachment.....	54
Chapter Four Emergency Contact Information.....	55


Introduction

This manual is designed for use by all medical and nursing staff in Emergency Departments across New South Wales. It allows a quick and simple guide to recognising important signs and symptoms, and management of common eye emergencies. The manual will also be of assistance in triaging patients to appropriate care within the health system.

These guidelines have not undergone a formal process of evidence based clinical practice guideline development, however they are the result of consensus opinion determined by the expert working group (Provision of Hospital Services Subcommittee & Nurse Standing Committee). They are not a definitive statement on the correct procedures, rather they constitute a general guide to be followed subject to the clinician's judgment in each case. The consensus opinion provided is based on the best information available at the time of writing.

To help with ease of use, this manual has a high graphic content, and is subdivided into basic ophthalmic diagnostic techniques/treatment, and management of common eye presentations. Each of the presenting conditions is subdivided into the following sections:

- Immediate action (if any)
- History
- Examination
- Treatment
- Follow-up - When to refer?

 Each section has red flagpoints that are used to increase the triage weighting or indicate urgent ophthalmic referral with an explanation of its relevance. Recommended Australasian Triage Scale (ATS) categories have been included where possible.

Urgency hierarchy - referral to ophthalmologist

- 1 Urgent referral - immediate consult by phone
- 2 Urgent referral - see ophthalmologist within 24 hours
- 3 Non-urgent referral - patient to see ophthalmologist within 3 days
- 4 Non-urgent referral - contact ophthalmologist for time frame

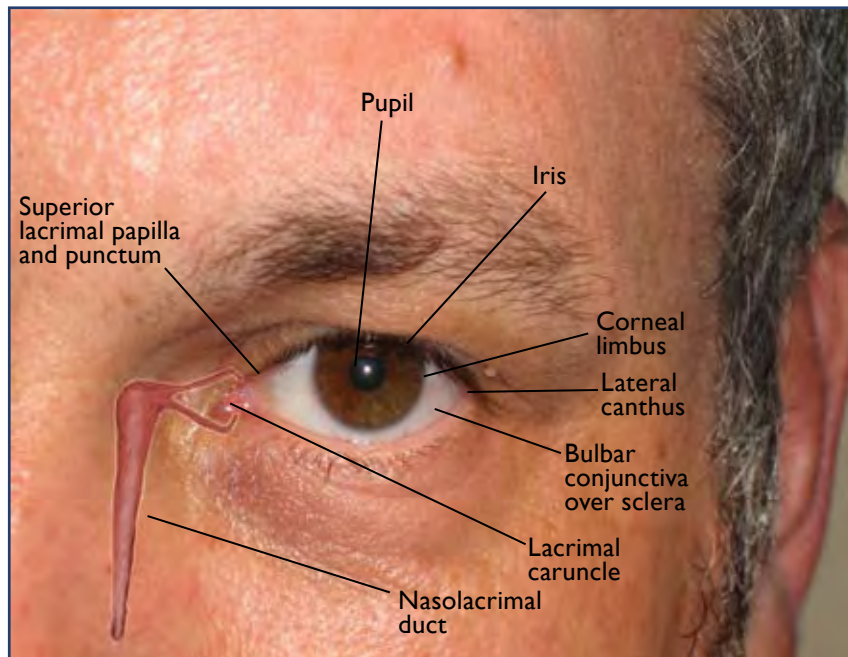
Information included in this manual is also available at the GMCT website at http://www.health.nsw.gov.au/resources/gmct/ophthalmology/eye_manual_pdf.asp

Listed on p56 are emergency contact numbers and relevant information which will give all medical and nursing staff 24 hour support.

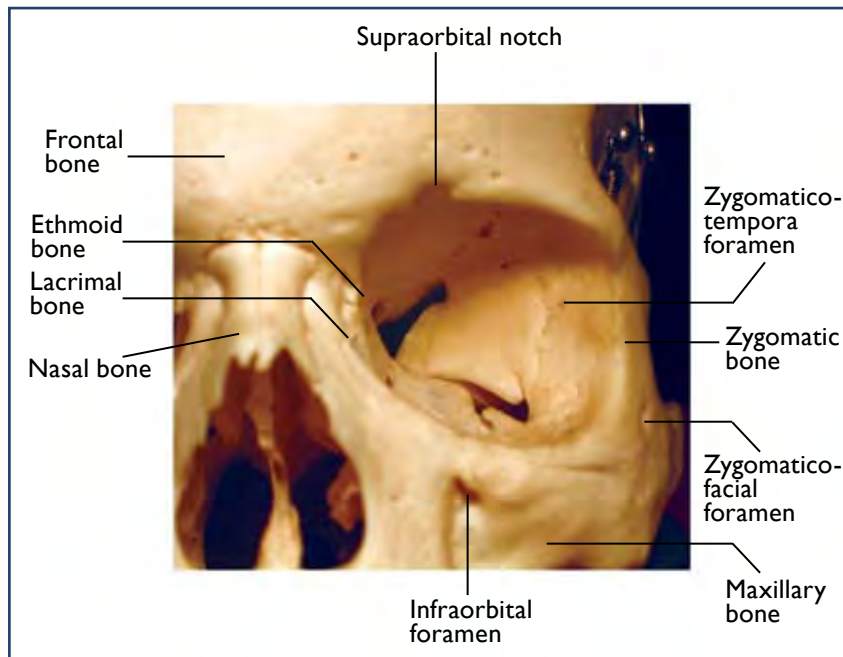
Chapter One

Anatomy

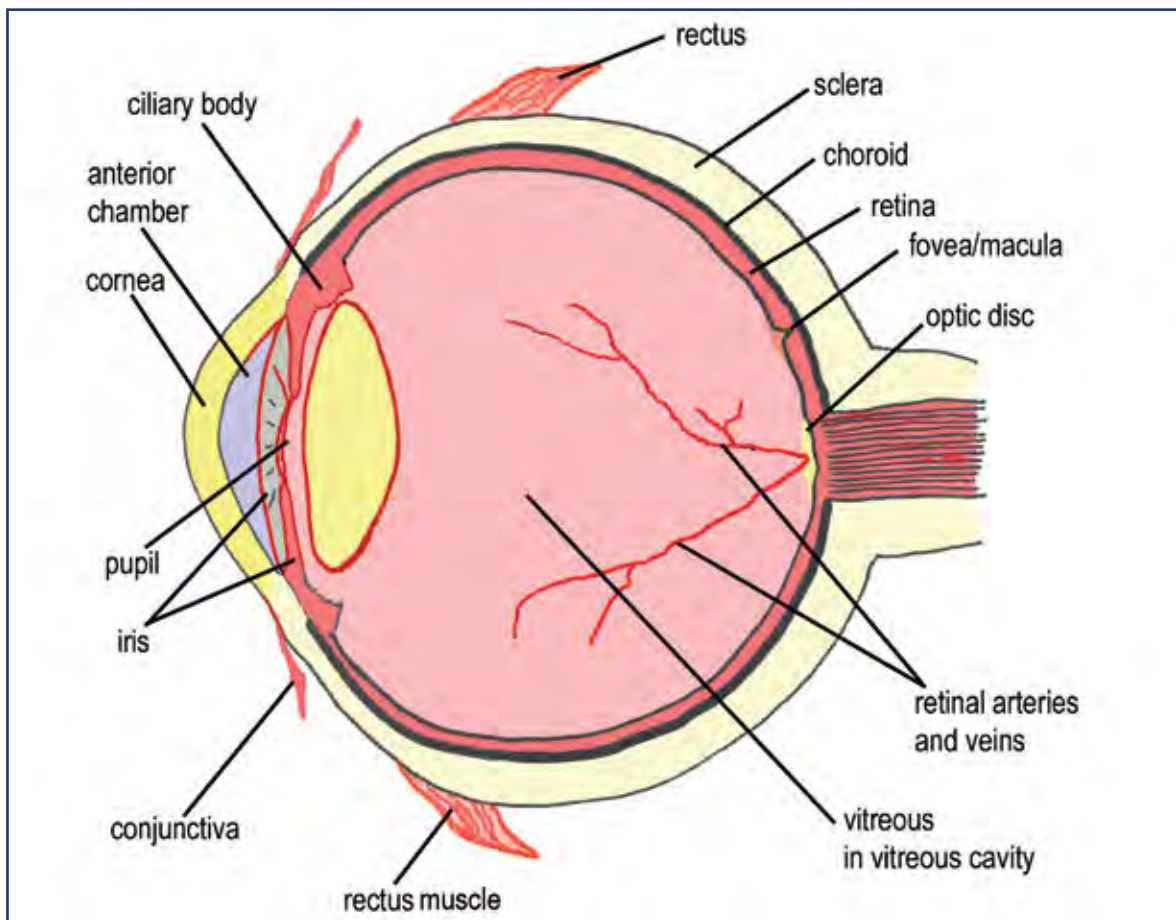
Anatomy



Anterior surface view



Bony structure – orbit and facial bones

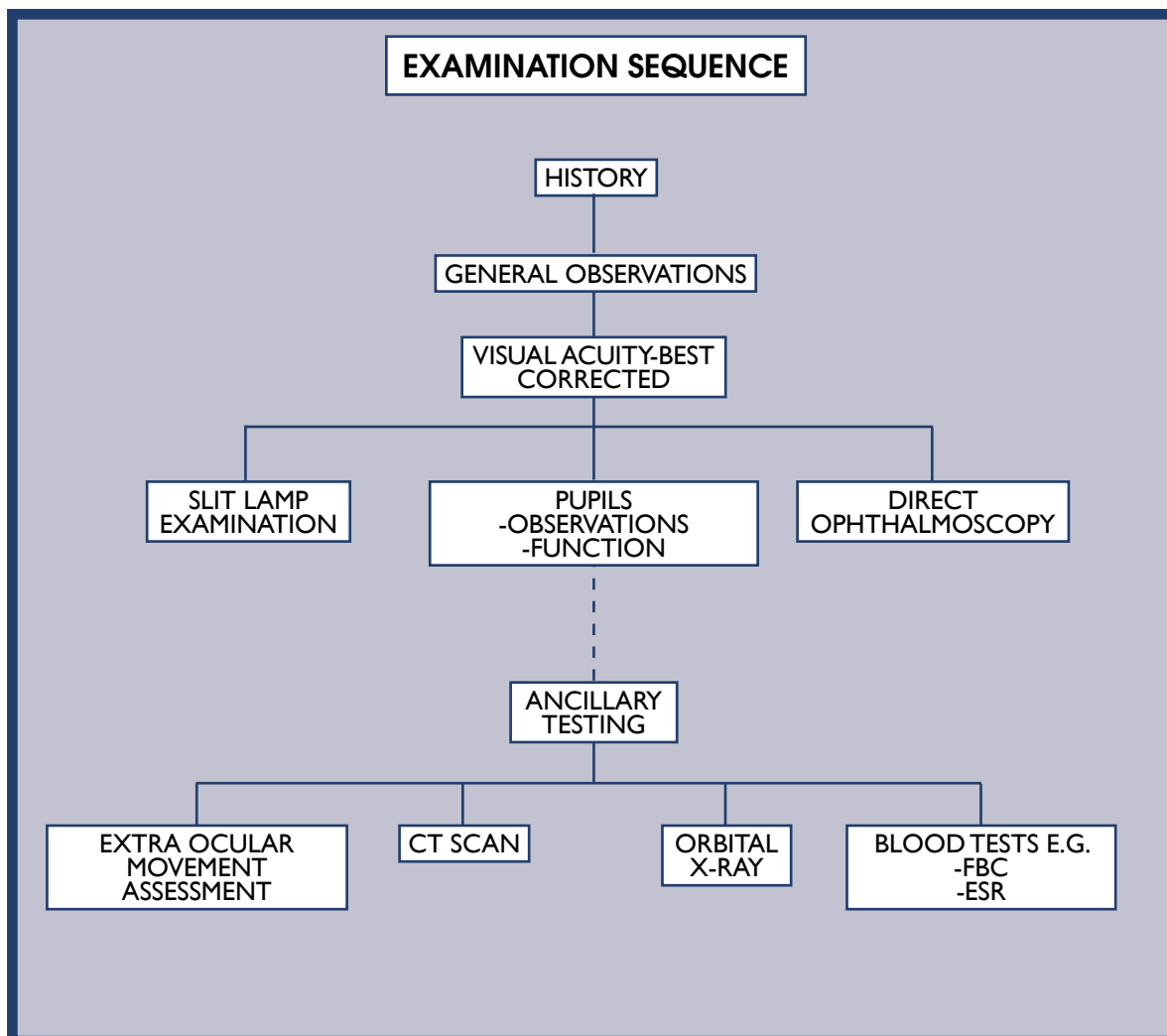


Horizontal section of a schematic eye

Chapter Two

Ophthalmic

Workup




Ophthalmic Workup

History


Important points

The suggested keypoints in the chapters on management are not intended to be the sole form of history taking but rather as an aid to prioritisation and referral.

The suggested questions to be asked when obtaining the history are common to both triage nursing (for urgency weighting) and medical staff.

 **Red flags are used to indicate potentially serious eye problems and should be noted to increase the triage weighting and to indicate whether urgent attention by an ophthalmologist is required.**

TAKING A GOOD HISTORY IS IMPORTANT
e.g. previous ocular history including contact lens wear, eyedrops and surgical procedures.

 **If the patient has one good eye only and presents with symptoms in the good eye, referral to an ophthalmologist for review is required.**

Always consider the systemic condition and medications.

Good documentation is essential not only for effective communication but is of medicolegal importance.

Examination

Sophisticated instruments are not a prerequisite for an adequate eye examination:

1. Small, powerful torch.
2. Visual acuity chart to measure visual acuity eg Snellen or Sheridan-Gardiner (see section on visual acuity, p16).
3. Magnification – handheld magnifying glass/simple magnification loupes. A slit lamp is preferred if available (see p17 for instructions) and is useful to visualise in detail the anterior structures of the eye.
4. Cotton bud – for removal of foreign bodies or to evert the eyelid.
5. Fluorescein – drops or in strips. A blue light source is required to highlight the fluorescein staining (see section on instillation of drops, p26) either from a pen torch with filter or slit lamp (see p19).
6. Local anaesthetic drops e.g. Amethocaine.
7. Dilating drops (Mydriatics) e.g. Tropicamide 1.0% (0.5% for neonates).
8. Direct ophthalmoscope – to visualise the fundus.

STANDARD PRECAUTIONS

It is important that Standard Precautions be observed in all aspects of examination:

- Hand hygiene - wash hands between patients
- Wear gloves if indicated
- Protective eye wear, mask and gown should be worn if soiling or splashing are likely
- NB Tears are bodily fluids with potential infective risk
- Clean the slit lamp using alcohol wipes
- Current NSW Infection Control Policy - for specific cleaning & disinfection see p56 for web site details

In patients with a red eye:

- Use single dose drops (minims)
- Use separate tissues and Fluorescein strips for each eye to reduce risk of cross contamination - NB Viral conjunctivitis

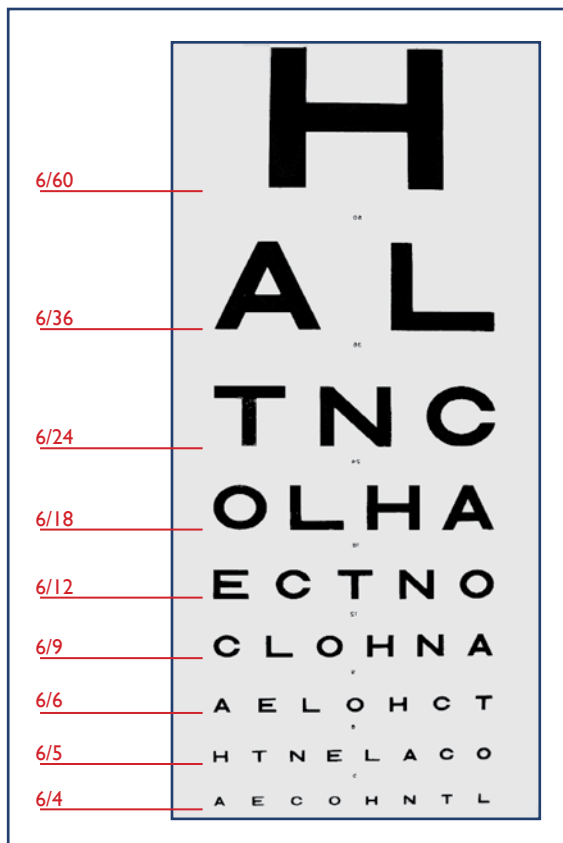


Fig 1 Snellen chart - 6m eye chart (visual acuity ratio in red)



Fig 2 Pinhole occluder

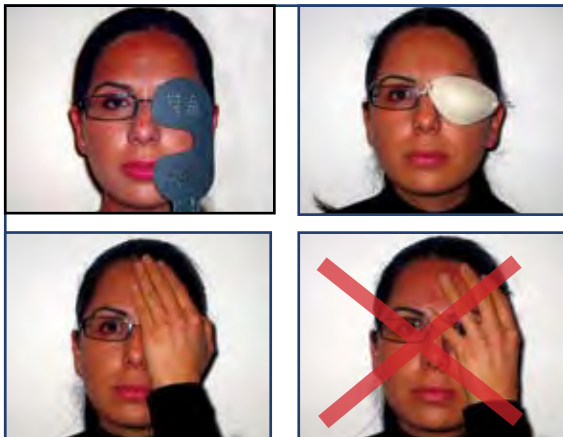

Fig 3 Examination of each eye

Visual acuity

It is important to test the visual acuity (VA) in all ophthalmic patients as it is an important visual parameter and is of medicolegal importance. **A visual acuity of 6/6 does not exclude a serious eye condition.**

The patient should be positioned at the distance specified by the chart (usually 3 or 6m).

Visual acuity is a ratio and is recorded in the form of x/y , where x is the testing distance and y refers to the line containing the smallest letter that the patient identifies, for example a patient has a visual acuity of 6/9 (see Fig 1).

Test with glasses or contact lenses if patient wears them for distance (TV or driving).

Pinhole

- If an occluder (see Fig 2) is unavailable, it can be prepared with stiff cardboard and multiple 19G needle holes.
- If visual acuity is reduced check vision using a "pinhole".
- If visual acuity is reduced due to refractive error, with a "pinhole" visual acuity will improve to 6/9 or better.

Test each eye separately (see below for technique)

- Check if the patient is literate with the alphabet (translation from relatives is often misleading). Otherwise consider numbers, "illiterate Es" or pictures.
- It is legitimate to instil local anaesthetic to facilitate VA measurement.
- If acuity is less than 6/60 with the "pinhole", then check for patient's ability to count fingers, see hand motions or perceive light.

Examine each eye (Fig 3)

- Requires proper occlusion. Beware of using the patient's hand to occlude vision as there are opportunities to peek through the fingers. Use palm of hand to cover the eye.
- Beware of applying pressure to ocular surfaces.

Slit-lamp

Guidelines in using a Haag-Streit slit lamp

- The patient's forehead should rest against the headrest with the chin on the chinrest (see Fig 1).
- Adjust table height for your own comfort and that of the patient when both are seated.
- Position patient by adjusting chinrest so that the lateral canthus is in line with the black line (see Fig 2).
- Set eyepieces to zero if no adjustment for refractive error is required.
- Set the interpupillary distance on the binoculars (see Fig 3).
- Magnification can be adjusted by swinging the lever (see Fig 4). Some models differ.
- Set heat filter if required (see Fig 5).
- Use the neutral density filter to reduce discomfort for the patient caused by the brightness of the wide beam.

continued...

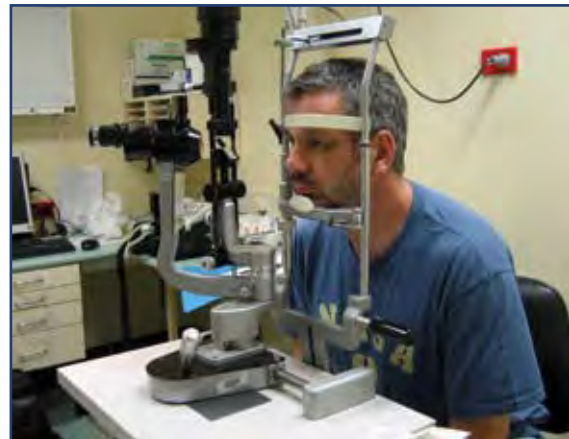

Fig 1 Position patient comfortably

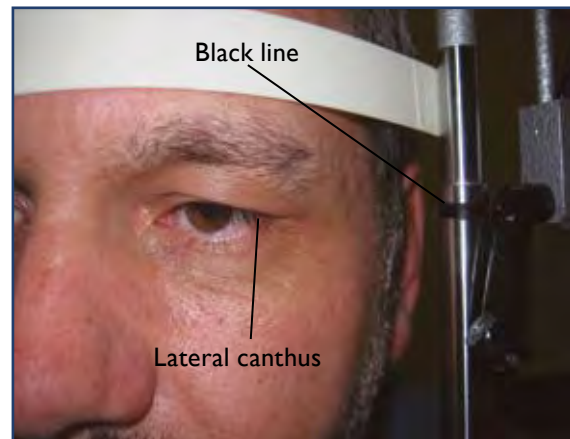


Fig 2 Left lateral canthus in line with black line



Fig 3 Setting interpupillary distance




Fig 5 Setting heat filter




Fig 4 To adjust magnification, swing lever




Fig 1 Length of beam 1




Fig 2 Length of beam 2




Fig 3 Width of beam

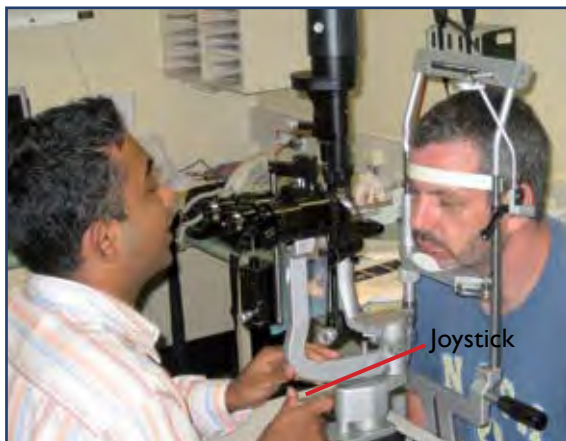

Fig 4 Preparing to position the joystick

- Ask the patient to look at your right ear when examining the right eye and vice versa.
- Turn on the control box, switching power to its lowest voltage.
- Adjust the slit aperture on the lamp housing unit, both the length and width of the beam can be adjusted (see Figs 1-3).
- The angulation of the slit beam light can also be adjusted.
- Focussing of the image is dependent upon the distance of the slit lamp from the subject (eye). Hint: obtain a focussed slit beam on the eye before viewing through the viewfinder.
- Push the joystick forward, toward the patient, until the cornea comes into focus (see Fig 4). If you cannot focus check to see if the patient's forehead is still on the headrest, or use the vertical controls at the joystick.
- Try to use one hand for the joystick and the other for eyeball control, such as to hold an eyelid everted (see p25).

Examine the eye systematically from front to back:

- Eyelashes.
- Eyelid – evert if indicated (see p25).
- Conjunctiva.
- Sclera.
- Cornea – surface irregularities, transparency and tearfilm.
- Anterior chamber.
- Iris/pupil.
- Lens.
- Remember to turn off the slit lamp at the end of examination.
- For slit lamp cleaning procedure see p19.

- Direct beam slightly out of focus. Useful for gross alteration in cornea. Can view lids, lashes and conjunctiva (see Fig 1).

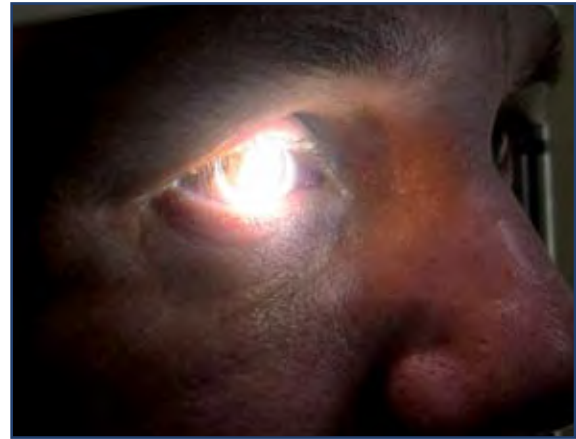

Fig 1 Direct beam illumination

- The cornea, anterior chamber, pupils and lens are best examined with a narrow width beam. Light beam is set at an angle of 45 degrees (see Fig 2).



Fig 2 Narrow beam illumination

- Optional **cobalt blue light** for Fluorescein. Do not use green light filter (see Fig 3).

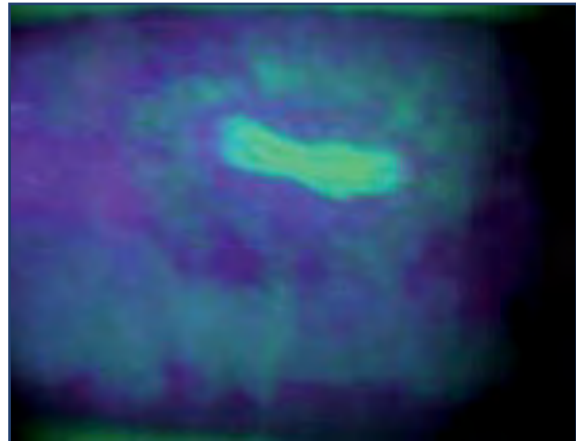


Fig 3 Corneal abrasion with Fluorescein

Cleaning Procedures

Remove chinrest paper if used.

Alcohol wipe over forehead rest, chinrest, joystick and handles.





Fig 1 Dioptic correction to zero

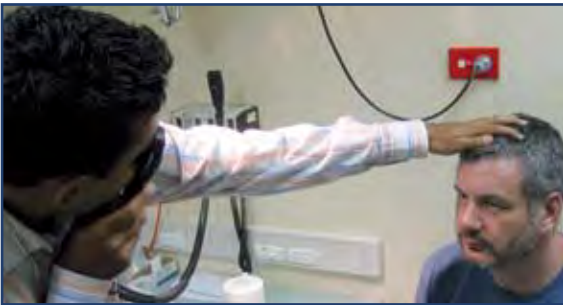

Fig 2 Testing for red reflex

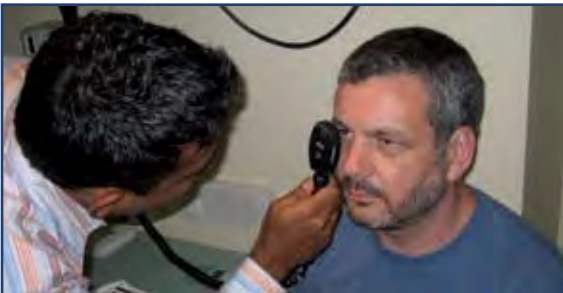

Fig 3 Examiner too far away from ophthalmoscope

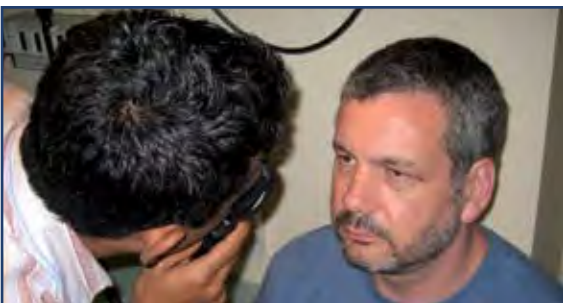

Fig 4 Patient too far away from ophthalmoscope

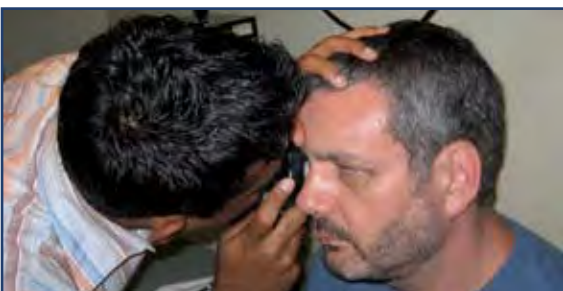

Fig 5 Just right!

Fundus examination: direct ophthalmoscopy

- Use a dim room for optimum examination.
- Examine pupil and iris before dilatation.
- Dilate pupil if possible using a mydriatic (see p28).
- **Do not dilate pupil if suspected head injury or iris trauma.**
- Maximise brightness/no filter.
- Set dioptic correction to zero (see Fig 1).
- Have the patient fixate (e.g. the 6/60 letter on the wall chart taking care that your head is not in the way!)
- Test for red reflex (see Fig 2) while viewing from a distance, approximately at an arm's length.
- View fundus – your right eye for the patient's right eye or vice versa.
- Proper positioning of both the examiner and patient is the key to a successful view. Hint: locate a blood vessel, following the vessel will lead to the optic disc (see Figs 3-5).
- Systematic examination (see Figs 6 & 7).
 - Optic disc - size, colour, cupping and clarity of margins.
 - Macula.
 - Vessels.
 - Rest of retina both central and peripheral.

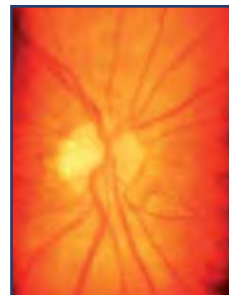

Fig 6 Appearance of the normal optic disc as viewed through the direct ophthalmoscope

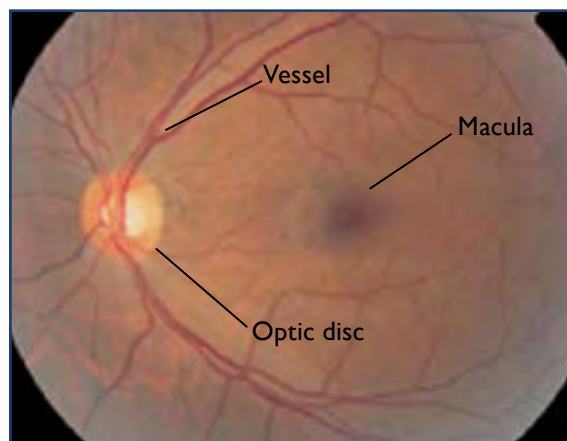


Fig 7 Photograph of a normal fundus

Pupil examination

- The pupil examination is a useful objective assessment of the afferent and efferent visual pathways.
- Direct/consensual/afferent pupillary defect.

Terminologies used in pupil examination

- Direct - When one eye is stimulated by light, the eye's pupil constricts directly (see Fig 2).
- Consensual - When one eye is stimulated by light, the other eye constricts at the same time (see Fig 2).
- Relative Afferent Pupillary Defect (RAPD): exists when one eye apparently dilates on direct stimulation after prior consensual constriction and is a result of reduced transmission in the affected optic nerve, regardless of cause. It is tested by the swinging torch test (see Fig 3). Hint: use a powerful torch, minimise the transition time between eyes however allow sufficient time for light stimulation (count to 3).

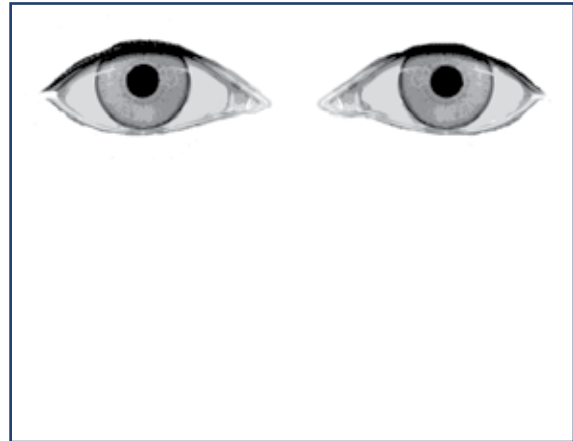


Fig 1 Normal Pupils

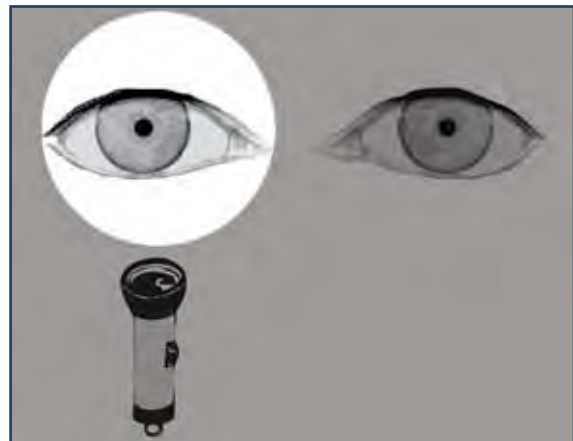


Fig 2 Direct Light Reflex

Consensual Light Reflex

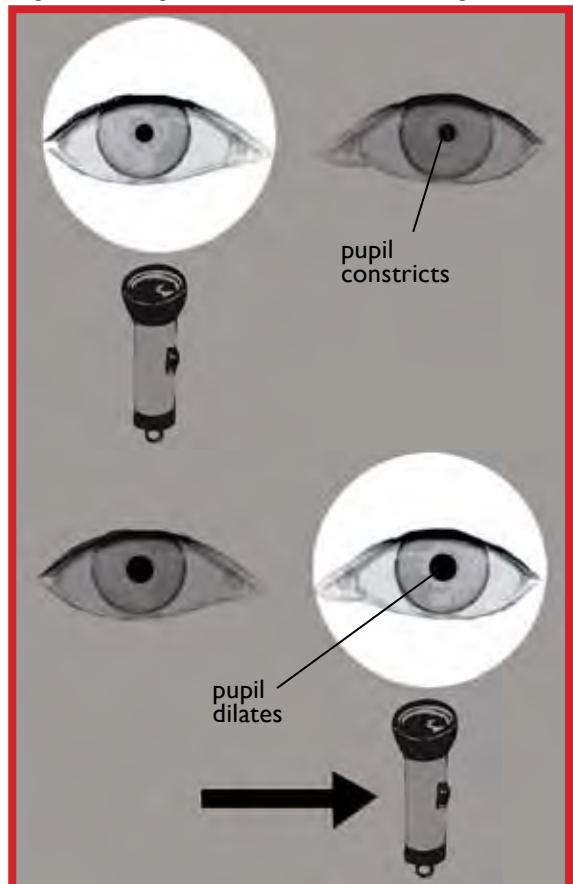


Fig 3 Swinging Torch test - demonstrating a left relative afferent pupillary defect where the left pupil apparently dilates after prior consensual constriction with direct light stimulation of the right eye



Fig 1 Small plastic figurines are useful in obtaining attention and visual fixation in the child.

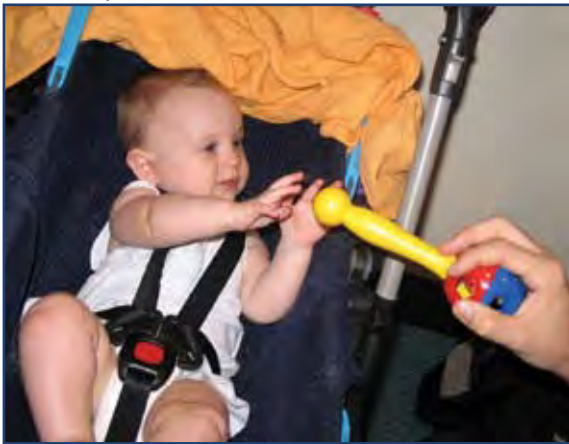

Fig 2 Small child fixing and reaching for a bright object.



Fig 3 "100's and 1000's" are commonly used to test fine vision in children

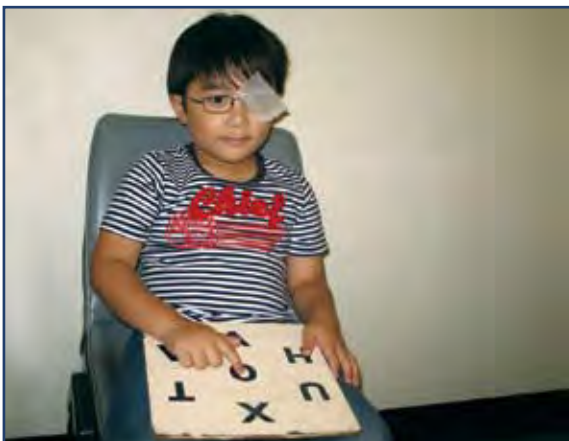

Fig 4 Monocular identification of letters of the alphabet by matching.

Paediatric examination

Paediatric Assessment

Assessing a child that may be injured or distressed can be difficult. The task should not be delegated to the most junior or inexperienced ED staff member.

Throughout the assessment it is not necessary to separate the child from its parent.

History

Obtain a detailed history from an adult witness.

If no such history is available, always suspect injury as a cause of the red or painful eye in a child.

Determine vaccination and fasting status.

Examination

This commences when the family is first greeted in the waiting room and continues throughout the history taking by simply observing the child.

Visual acuity **MUST** be assessed for each eye. For a preverbal child assess corneal reflections, the ability to steadily fixate upon and follow interesting toys (see Fig 1) or examiner's face, and their reaching responses for objects of interest (see Fig 2). A small child's vision is probably normal if the child can identify and reach for a small bright object at 1 metre e.g. a single "100 & 1000" (see Fig 3). Pupillary reactions should also be assessed. In a verbal child, acuity should be assessed monocularly using a Snellen chart, single letter matching at 3m or picture cards at 3m. A young child sitting on a chair or their parent's lap can identify the shape of the letters by matching, without knowing the alphabet (see Fig 4).

All drops will sting with the exception of plain Fluorescein. This should be used in all cases of red or sore eye in a child. Local anaesthetic will sting but may facilitate the child spontaneously opening the eye.

❗ **Never try to pry the eyelids of a child apart to see the eye. Inadvertent pressure on the globe may make a perforating injury worse.** Strong suspicion of such an injury (see p35) should be followed by placing a rigid shield on the eye and transporting the patient fasted to the appropriate facility for exploration under anaesthesia.

- A child less than two may require firm but gentle restraint (see Fig 1) for examination and treatment such as removal of a superficial foreign body. One such attempt should be made with a cotton bud before considering general anaesthetic.

Specific Conditions

❗ **Unexplained periorbital haemorrhage particularly in context with other injuries should arouse the suspicion of non-accidental injury (NAI) and the child protective services should be contacted.**

- Superglue closing an eye can usually be left to spontaneously open or treated by cutting the lashes. Fluorescein should be used as per corneal abrasion.

❗ **Purulent discharge within the first month of life (ophthalmia neonatorum) should be urgently investigated with microbiology for chlamydia and gonococcus. Systemic investigation and management in consultation with a paediatrician is mandatory. The parents must be referred to a sexually transmitted disease clinic.**

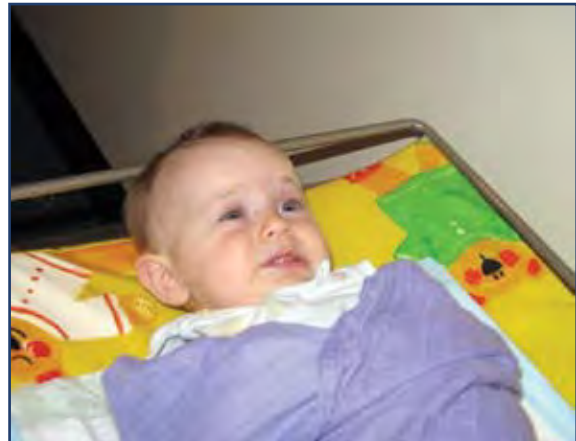

Fig 1 A small child can be gently restrained by swaddling.

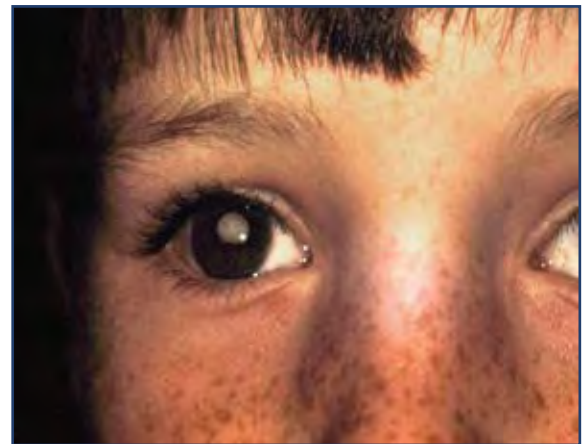

Fig 2 Child with Leukocoria

❗ **A red, swollen, tender eyelid in a febrile child should be assumed to be cellulitis and admitted to hospital. Cellulitis in the middle part of the face (the triangle of death) spreads by venous pathways into the cranial cavity.**

❗ **Leukocoria** - on occasion a parent will complain of seeing something in their child's pupil. A child with leukocoria (Fig 2) or a white pupil in one or both eyes may present to an emergency department. An attempt may be made to assess the child's vision, however **the presence of leukocoria warrants an urgent referral to see ophthalmologist within 24 hours.**

continued...

Specific Conditions continued

❗ A white blow-out fracture occurs with orbital injury with the findings of minimal periorbital haemorrhage, sunken globe and restricted eye movement in an unwell child (see Fig 1). Consider a head injury and refer urgently.

- An eyelid laceration is a penetrating injury until proven otherwise. The smaller the wound, the bigger may be the problem, particularly if the injury was not witnessed. For example a toddler walking with a pencil who falls forward and the pencil penetrates the eyelid and eye.
- Space penetrated may not only be the eye but also the adjacent cranial cavity.

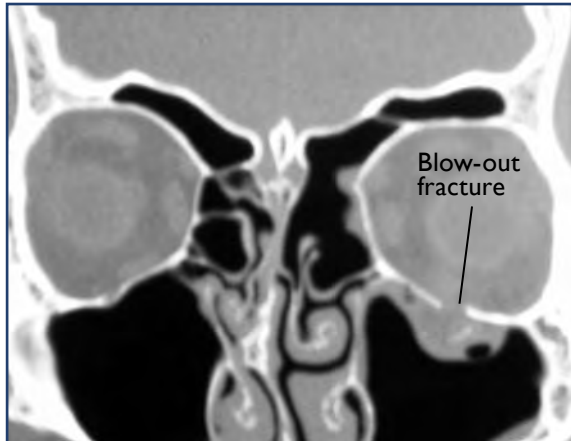


Fig 1 White blow-out fracture

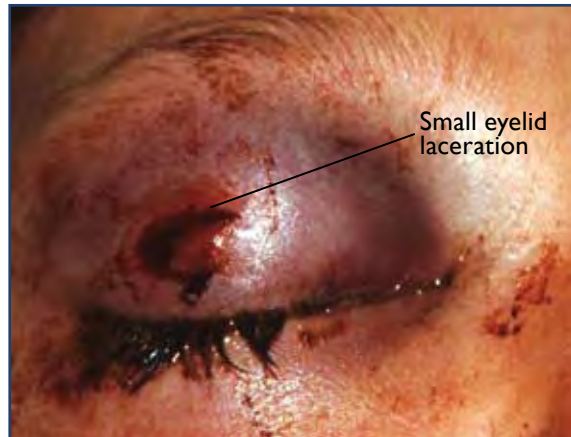

Fig 2 Small hole

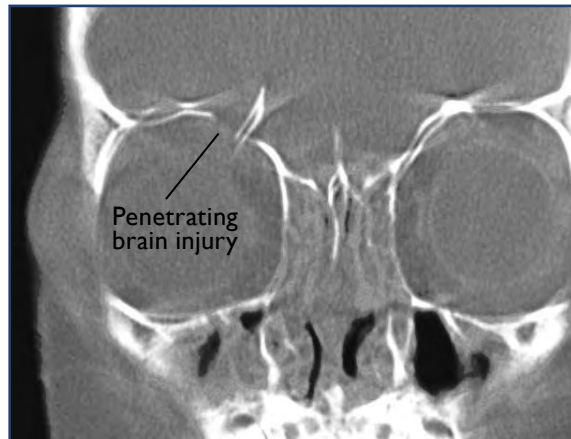


Fig 3 Big trouble - intact eyeball, with possible penetrating brain injury

Treatment

Everting eyelids

- Instruct the patient to keep looking downwards (see Fig 1).
- Place cotton bud at the lid crease (or 5mm from lid edge) and apply very light pressure (see Figs 1 & 2).
- Evert the eyelid over the cotton bud using the eyelashes to gently pull the lid away and upwards from the globe (see Fig 3).

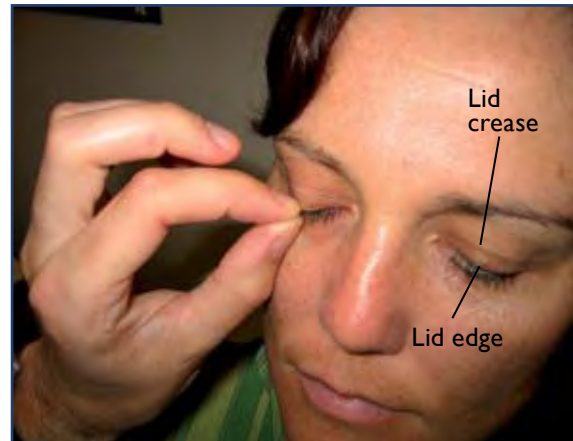


Fig 1

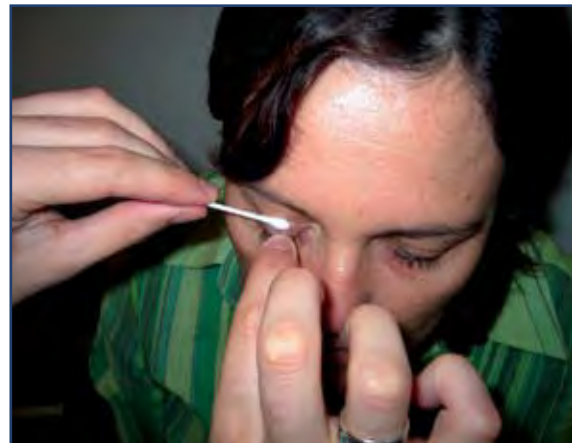

Fig 2

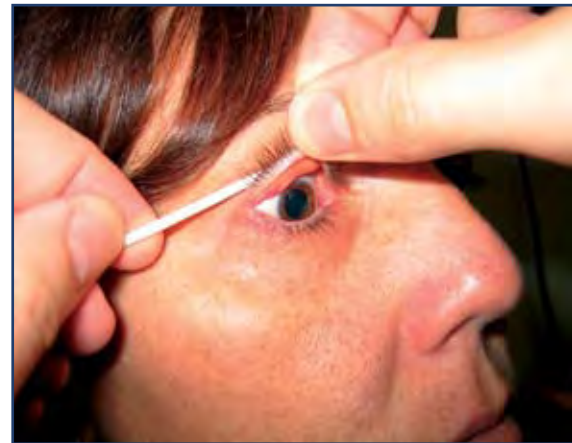

Fig 3

Eyedrops

How to instill drops

Self instillation (see Fig 1).

- Wash hands.
- Uncap the bottle/tube.
- Tilt head up.
- The hand on the opposite side holds the bottle resting on the bridge of the nose of the patient, taking care not to touch any surfaces with the bottle tip.
- Pull down the lower lid with the fingers of the same side so that a visible pocket forms at the space behind the lid.
- Gently squeeze bottle to deliver 1-2 drops.
- Shut eyelid for approximately 1 minute.
- Wipe away excess drops/ointment from face.
- Recap bottle.
- Wash hands.

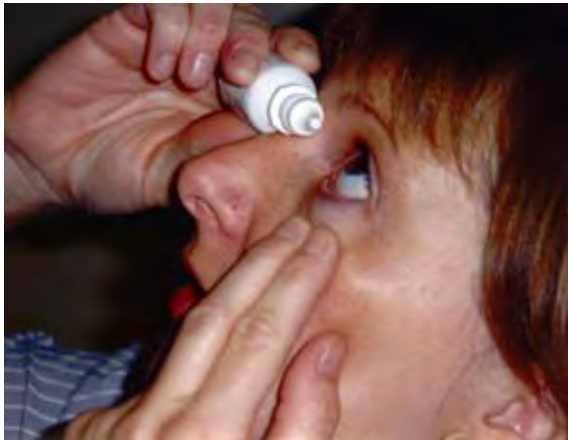

Fig 1 Self instillation of eyedrops

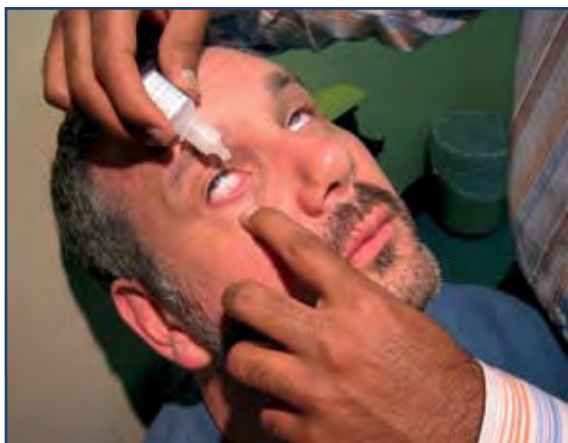

Fig 2 Drops administered by health care worker or family member

Assisted instillation (see Fig 2).

- Wash hands.
- Uncap the container or twist off tab.
- Pull lower eyelid gently down with forefinger to form a pocket.
- Tilt head slightly back and look up.
- Hold the bottle gently between the thumb and forefinger, gently squeeze the recommended number of drops into the pocket formed.
- Do not touch the eye with bottle tip.
- Shut eye and move eyeball from side to side to spread the medication.
- Wash hands.

How to pad an eye

- It is not necessary to pad an eye with minor corneal or conjunctival trauma.
- Drops are often preferred and are equally as effective as ointment.
- There are no indications for continued use of topical anaesthesia.
- Single eye pad (see Fig 1).
 - Secure with three tapes angled away from mouth.
 - Ensure eye is closed when padding the eye.
- Do not drive with eye padded.
- When to use an eye shield (see Fig 2).
 - Suspected perforation.
 - Protects eye from further compression.
 - A modified polystyrene cup can be used if an eye shield is unavailable (see Figs 3 & 4).
- There are no indications to pad the unaffected eye unless instructed by the ophthalmologist.

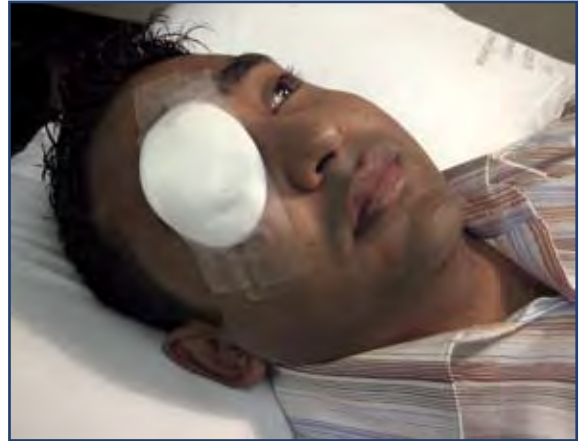

Fig 1 Single eye pad

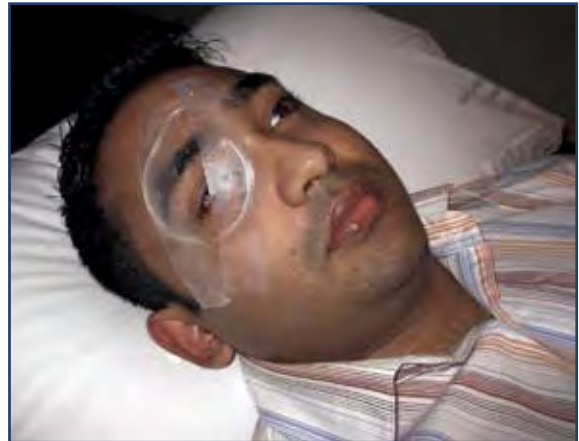

Fig 2 Eye shield




Fig 3 Shield made from a polystyrene cup

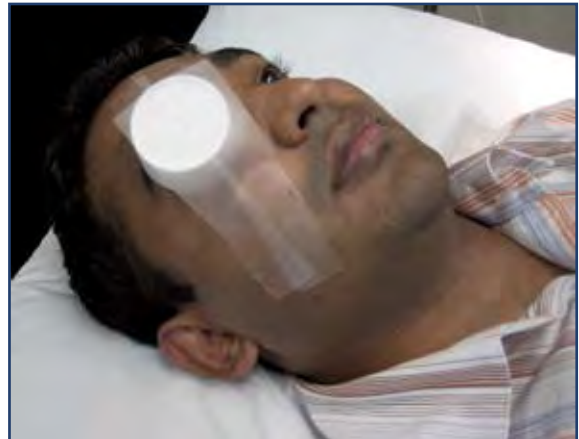

Fig 4 Polystyrene cup

Types of Ocular Drugs

Local anaesthetic

Use: Local anaesthetic drops are used as an aid to the examination of the eye (lasts 10-20 minutes). They are also useful in improving patient comfort in certain procedures such as irrigation of the eye following chemical trauma. **Never give patients anaesthetic drops to take home.** *Common preparations:* Amethocaine 0.5%, Benoxinate 0.4%, 1% Lignocaine from an ampule for injection is satisfactory if minims are unavailable. If required, additional medications such as Paracetamol and Codeine Phosphate (Panadeine Forte), topical Ketorolac or Homatropine may be used.

Fluorescein

Use: Topically to diagnose abrasions and foreign bodies in the cornea. A cobalt blue light is required to highlight these areas of increased Fluorescein uptake – available from either a torch light with a blue filter or the slit lamp. Fluorescein is also used in measurement of intraocular pressure and fundus angiography (specialist use). *Common preparations:* Impregnated paper strips or in drops.

Mydriatics

Use: To dilate the pupil to facilitate examination of the fundus. The relative contraindication to dilatation is in the eye with a shallow anterior chamber as dilatation may precipitate acute angle closure glaucoma. This is an uncommon occurrence and patients should be warned to report any acute eye discomfort following pupil dilatation (more common in oriental eyes). Vision may be affected so patients should also be instructed not to drive for a few hours following examination, or longer, if vision is blurred. It is normal for the drops to sting for a few seconds post instillation. *Common preparations:* Tropicamide 1.0% (0.5% for neonates). Pupils usually take 15 minutes to dilate and the drops may be repeated if dilation is unsatisfactory. Dark coloured irides may require multiple applications. Unless dilating the pupil mydriatics should only be used on the advice of the consulting ophthalmologist.

Basic antibiotics

Use: For treatment of acute bacterial conjunctivitis or as prophylaxis against bacterial infection following minor ocular trauma. Available in both drop and ointment preparations – there are no specific therapeutic differences between the two preparations in the acute situation and usage is based on the prescriber's preference. Usage is qid (4 times a day) and for 1 week unless directed by the ophthalmologist. *Common preparations:* Chloramphenicol drops (0.5%) or ointment (1.0%), Ciprofloxacin drops, Polymyxin B sulfate drops or ointment, Framycetin drops or ointment, Tobramycin drops or ointment.

Antiviral

Use: The most common viral condition is herpes simplex keratitis. This condition will require ophthalmology specialist follow-up. *Common preparations:* Acyclovir (Zovirax) ointment. Initial topical dosage of 5x per day.


Ocular lubricants – drops and gels

Use: In the treatment of the dry eye. This is a very common condition and is characterised by the multitude of products in the market. They are subdivided into drops and gels (longer lasting although may temporarily blur vision) and with or without preservatives (only indicated in severe conditions requiring more than qid dosage and would follow specialist assessment). *Common preparations (brands in brackets):* Hypromellose drops or gel (e.g. Genteal, Polytears, Tears Naturale, Refresh, Tears Plus, Optive), soft paraffin and lanolin (Lacrilube), Polyvinyl alcohol (Liquifilm, Murine), Carbomer (Polygel, Viscotears).

Glaucoma drops

Topical glaucoma medications are usually prescribed by the ophthalmologist, but it is important to have an appreciation of the possible systemic side effects of the medications (see Table p29).

Steroid drops

 **Steroids should only be used on the advice of the consulting ophthalmologist.**

Common Glaucoma Medications^{1,2}

Generic (Common Brand)	Mechanism of action	Contraindications or Precautions	Common Side effects
Apraclonidine (Iopidine) 0.5%	↓ production ↑ outflow Onset = 1 hr Duration = 3.5 hrs Stat or tds	Monoamine Oxidase Inhibitors Tricyclic Antidepressants Hypertension Cardiovascular Disease	Hypersensitivity Eye irritation Drowsiness Dry mouth Altered taste
Brimonidine (Alphagan) 0.2%	↓ production ↑ ↑ outflow Onset = 2 hrs Duration = 12 hrs bd	Monoamine Oxidase Inhibitors Tricyclic Antidepressants Severe Cardiovascular Disease	Hypersensitivity Eye irritation Drowsiness Dry mouth
Timolol 0.25%, 0.5%	↓ production Onset = 20 min Duration = 24 hrs bd or daily	Asthma Chronic Airways Limitation Bronchospasm Bradycardia Cardiac failure Heart block	Eye irritation Visual disturbances Cardiovascular and Respiratory effects Nausea Nightmares
Betaxolol (Betoptic) 0.25%, 0.5%	↓ production ↑ outflow Onset = 30 min Duration = 12 hrs bd	Bradycardia Cardiac failure Heart block Asthma Chronic Airways Limitation Bronchospasm	Eye irritation Visual disturbances Cardiovascular effects Nightmares Respiratory effects
Pilocarpine 0.5%, 1%, 2%, 3%, 4%, 6%	↑ outflow qid	Acute iritis	Miosis Hypersensitivity Reduction in visual acuity
Acetazolamide (Diamox) Oral tabs 250mg Injection 500mg	↓ production Variable dosage (diuretic)	Low Na/K Renal or hepatic disease Sulphonamide sensitivity Thirst	Hypersensitivity Electrolyte disturbance Paraesthesia Thirst Dizziness Drowsiness Confusion
Dorzolamide (Trusopt) Brinzolamide (Azopt 1%)	↓ production bd/tds	Sulphonamide-hypersensitivity Severe renal disease Impaired hepatic function	Sulphonamide-hypersensitivity Eye irritation Bitter taste Blurred vision
Latanoprost (Xalatan) 0.05% Bimatoprost (Lumigan) 0.03% Travaprost Travatan 0.004%	↑ episcleral outflow daily or nocte	Impaired renal function Impaired hepatic function	Eye irritation Blurred vision Brown colouration of iris Darkening of eyelid skin Growth of eye lashes

¹Included with the permission of Dr Weng Sehu.

²An increasing number of combined medications is available.



Chapter Three

Common Emergencies

AUSTRALASIAN TRIAGE SCALE (ATS)

The ATS reflects the potential of a vision threatening condition in this instance and does not reflect haemodynamic stability or pain intensity, which may require a higher triage score.

Common Emergencies

Trauma

Lid laceration (Figs 1 & 2)

ATS CATEGORY 3 (START TREATMENT WITHIN 30 MINS)

Any laceration other than superficial skin that involves the lid margin will need ophthalmological referral. (Check for tetanus immunisation status).

An eyelid laceration is a potential penetrating eye injury until proven otherwise.

History

Four basic questions are:

- which eye is injured?
- how did it happen?
- when did it happen?
- what are the symptoms?

Nature of injury – was there any possibility of penetration into the lid/orbit?

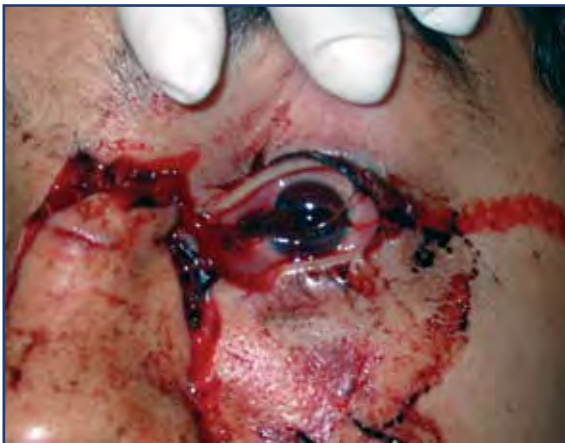

Fig 1 Exploration of an extensive lid laceration

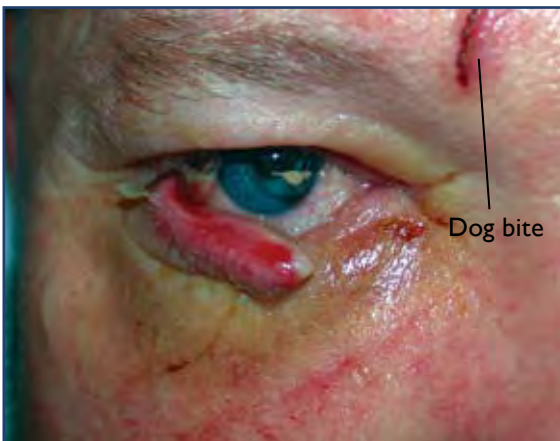


Fig 2 Torn eyelid with avulsed lower lacrimal canaliculus

Examination

- Wound examination – size and depth.
- **All wounds should be explored fully for extent of damage.**
- Visual acuity.
- Superficial ocular examination with magnification to assess for any corneal/ conjunctival laceration or penetration.
- Further ocular examination including dilated fundus examination as determined by history and examination findings.

Treatment/Investigation

- **Orbital X-Ray or CT if indicated for foreign bodies or orbital fracture.**
- If superficial laceration:
 1. Clean the area and surrounding skin with antiseptic such as Betadine.
 2. Subcutaneous anaesthetic with vasoconstrictor (2% Lignocaine with Adrenaline).
 3. Irrigate and debride the wound thoroughly with saline.
 4. Identify foreign bodies if applicable.
 5. Suture with a 6/0 non-absorbable suture.

When to refer?

- **Referral to an ophthalmologist:**
 1. If the eyelid laceration is associated with ocular trauma requiring surgery such as ruptured globe or intraorbital foreign body.
 2. If the laceration position is nasal to either the upper or the lower eyelid punctum, for the possibility of damage to the nasolacrimal drainage system.
 3. If there is extensive tissue loss or distortion of the anatomy.
 4. If there is full thickness laceration or the laceration involves the lid margin.
- **All wounds will require tetanus prophylaxis as indicated in current protocol. Broad spectrum systemic antibiotic cover will be required if there is significant risk of contamination, or debridement of necrotic tissue.**

Ocular trauma

History

- ▣ **Mechanism of trauma – any history suggestive of a penetrating trauma.**
 - The type of projectile and the likely velocity (e.g. low or high) should be documented.
- ▣ **Small projectiles at high velocities increase the likelihood of penetrating trauma. Symptoms include loss of vision, pain on movement and diplopia.**
 - Was the patient wearing eye protection?
 - Any previous history of ocular trauma or previous surgery is to be documented and may suggest reduced integrity of the wall of the globe.

Blunt

ATS CATEGORY 3 (START TREATMENT WITHIN 30 MINS)

Closed globe injury

Blunt trauma to the eye may result in considerable damage to the intraocular contents. Fracture of the orbital wall may occur due to the transfer of mechanical energy to relatively thin orbital bone.

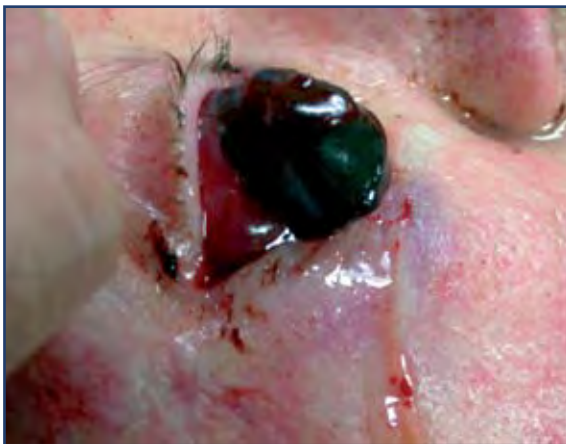

Fig 1 Ruptured globe

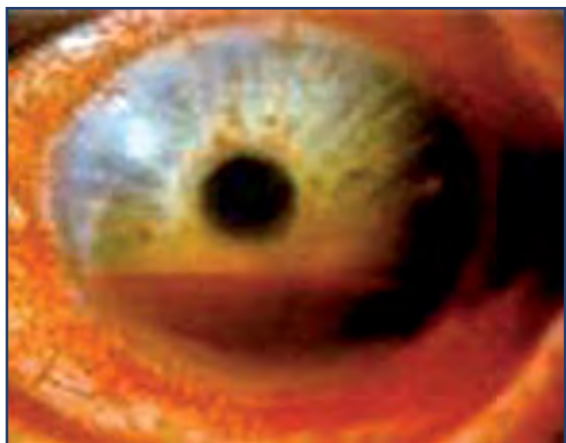


Fig 2 Hyphaema-blood in the anterior chamber

Ruptured globe (Fig 1)

ATS CATEGORY 2 (START TREATMENT WITHIN 10 MINS)

Trauma of sufficient force may result in globe rupture and typically occurs in the areas where the scleral wall is thinnest: at the limbus (which would be visible via the slit lamp) or behind the insertion of the rectus muscle (which would result in reduced ocular motility, loss of red reflex and vitreous bleeding).

Examination

- Visual acuity.
- Ocular movements – if there is considerable eyelid oedema, carefully lift up the lid while viewing the eye to ensure there is no obvious rupture.

▣ **Reduced movement may suggest ruptured globe or orbital wall fracture.**

- Slit lamp – looking for evidence of rupture (often at the limbus). Examine for blood in the anterior chamber (see Fig 2). Examine the eyelid for lacerations (see p33 for further management).
- Ophthalmoscopy – Red reflex (missing in intraocular haemorrhage or retinal detachment). Look for any retinal pathology (after dilating the pupil).

Investigations

- CT scan (axial and coronal) for orbital wall fracture if indicated (see p40).

Follow up - When to refer?

- Non-urgent referral within 3 days if the above findings are negative.

▣ **Urgent referral to ophthalmologist - immediate consult by phone if findings are suggestive of intraocular haemorrhage, ruptured globe or orbital wall fracture (also see p40).**

Treatment

- Topical antibiotic drops for superficial trauma (see p28).
- Suture any eyelid lacerations as indicated in eyelid trauma section (see p33).

Sharp (penetrating)

ATS CATEGORY 2 (START TREATMENT WITHIN 10 MINS)

- **All penetrating trauma require urgent referral to ophthalmologist - immediate consult by phone following appropriate pre-op workup.**

Examination

Examination may only need to be cursory if the trauma is obvious otherwise: –

- Visual acuity.
- Direct ophthalmoscopy – loss of red reflex may suggest retinal trauma or detachment.
- Slit lamp – looking for distorted anterior chamber structures or corneal/scleral breaks.

Treatment

- Ensure nil by mouth status. Strict bed rest. Injectable analgesia/antiemetic if required.
- CT scan of the orbit to exclude retained ocular/orbital foreign body after discussion with ophthalmologist (see Fig 2).
- Shield (not pad) the eye making sure not to increase the intraocular pressure with further loss of ocular contents. (See section on eye padding/shields, p27).
- No ointment for penetrating eye injury.
- Check for tetanus immunisation status as per current protocol.
- Commence broad spectrum IV antibiotics.

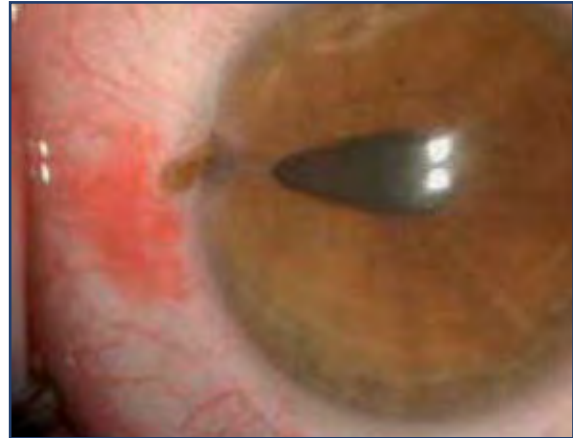

Fig 1 Distorted pupil with iris prolapse

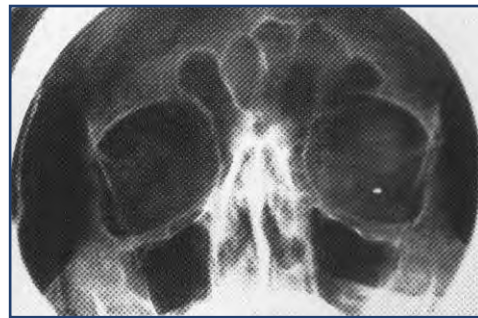

Fig 2 Intraocular foreign body

Corneal foreign body

ATS CATEGORY 4 (START TREATMENT WITHIN 60 MINS)

- Any foreign body penetration of the cornea or retained foreign body will require urgent referral to ophthalmologist - immediate consult by phone.

History

- What is the likely foreign body?
- Examples include dirt, glass, metal and inorganic material. (see Figs 1 & 2).
- Retained organic material may lead to infection; retained metallic foreign bodies may lead to the formation of rust rings that produce persistent inflammation and corneal epithelial defect.
- Velocity of impact?
- High speed motor drilling without eye protection may lead to a penetrating corneal/scleral injury.

Examination

- Visual acuity
- Slit lamp - assess for the size, site/s and nature of foreign body and the depth of penetration.
- Examine the cornea, anterior chamber, iris, pupil and lens for any distortion that may indicate ocular penetration (see p35, penetrating ocular trauma) and require urgent referral to an ophthalmologist. Evert the eyelids to exclude retained foreign bodies – remove if appropriate.

Treatment/Investigation

- Use topical anaesthesia.
- Foreign body removal under slit lamp as directed (see p37). If you are attempting the procedure for the first time, guidance and supervision are advised.
- Rust rings in the visual axis should be removed by an ophthalmologist, or suitably experienced emergency physician.
- Use Fluorescein to assess and measure the size of epithelial defect.
- Topical antibiotic (qid) and cycloplegic agent (such as Homatropine 2% bd) for comfort. Drops are often preferred and are equally as effective as ointment in a healing corneal wound. Oral analgesia as required.
- NB It is not necessary to pad an eye (see section on eye padding, p27). The advantage of not padding is that the patient is able to see with both eyes.
- There are no indications for continued use of topical anaesthetic drops.
- Daily visual acuity and slit lamp review until complete healing of defect. The defect should be measured (see section on slit lamp examination p17) and compared with previous findings.

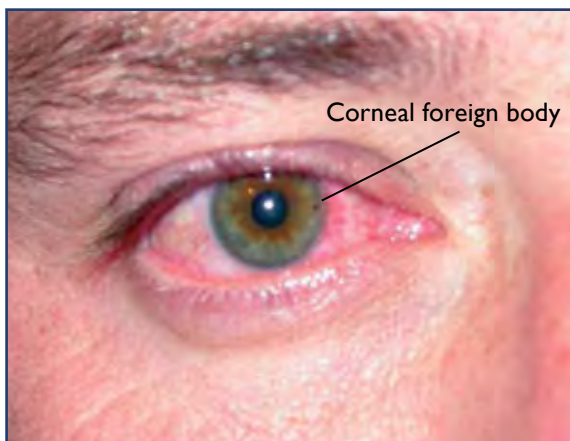


Fig 1 Corneal foreign body (macro)

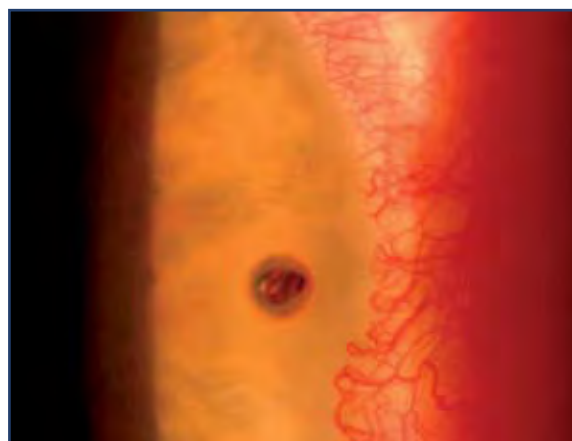


Fig 2 Corneal foreign body (micro)

Follow up - When to refer?

Follow-up and referral depend on the size and location of the abrasion:

1. **Urgent - within 24 hours - if foreign body is not completely removed.**
2. **Urgent - immediate consult - if the underlying surface defect is opaque and is indicative of an abscess.**
3. Non-urgent - within 3 days - if there is a persistent epithelial defect.

If the patient is a contact lens wearer, he/she should be advised to discontinue lens usage until the defect is fully healed and feels normal for at least a week.

Technique for the removal of corneal foreign bodies

Instruments

- Cotton bud (see Fig 1).
- 19-30 g needle (see Fig 1). Use the bevelled surface of instrument angled away from patient's eye. The head should rest against the slit lamp (see Fig 4).
- Optional: Motorised dental burr (see Fig 2). **Always obtain supervision if you are unfamiliar with the procedure.**

Procedure

1. Apply topical anaesthetic agent such as Amethocaine 1%.
2. Position patient at slit lamp (see Fig 4). Strap or hold head with the help of a colleague.
3. Focus slit lamp.
4. An oblique angular approach is very important (see Figs 3 & 4).

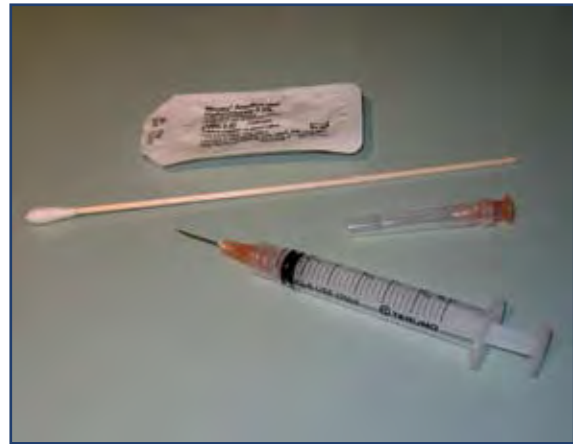

Fig 1



Fig 2

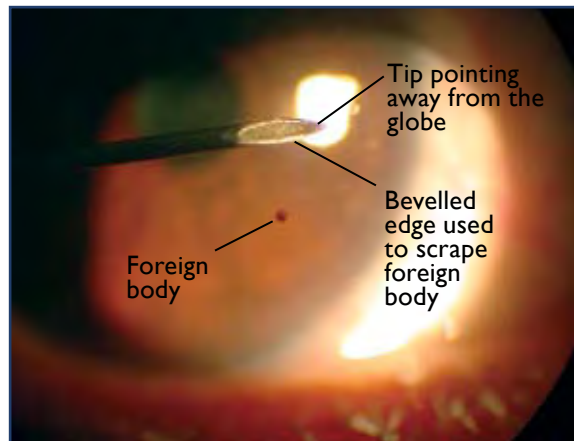


Fig 3 25G needle angled away from patient

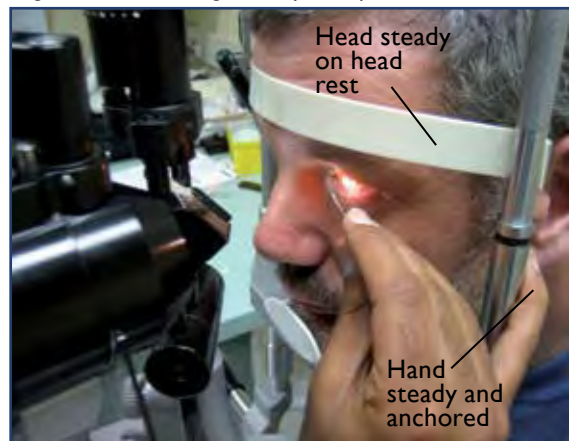


Fig 4 Corneal foreign body removal with 25G needle

Chemical Burns

ATS CATEGORY 2 (ASSESS & TREAT WITHIN 10 MINS)

IMMEDIATE - EYE IRRIGATION FOR CHEMICAL BURNS

1. Instil local anaesthetic drops to affected eye/eyes.
2. Commence irrigation with 1 litre of a neutral solution, eg N/Saline (0.9%), Hartmann's.
3. Evert the eyelid and clear the eye of any debris / foreign body that may be present by sweeping the conjunctival fornices with a moistened cotton bud.
4.
 - a. Continue to irrigate, aiming for a continuous irrigation with giving set regulator fully open.
 - b. If using a Morgan Lens, carefully insert the device now.
5. Review the patient's pain level every 10 minutes and instil another drop of local anaesthetic as required.
6.
 - a. After one litre of irrigation, review.
 - b. If using a Morgan Lens, remove the device prior to review.
7. Wait 5 minutes after ceasing the irrigation fluid then check pH. Acceptable pH range 6.5-8.5.
8. Consult with the senior medical officer and recommence irrigation if necessary.
9. Severe burns will usually require continuous irrigation for at least 30 minutes.

ALL CHEMICAL BURNS REQUIRE AN URGENT OPHTHALMOLOGY CONSULT BY PHONE

Refer to manufacturer's instructions if using Morgan Lens

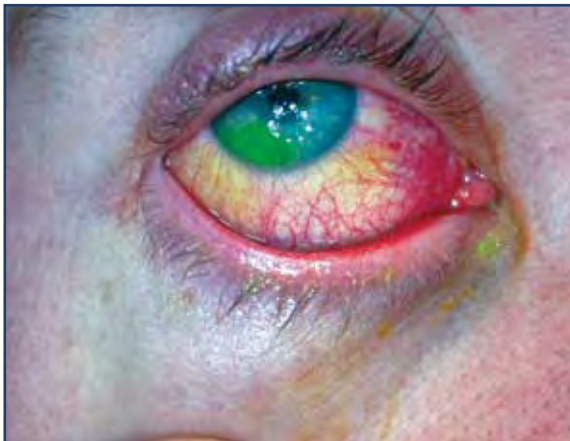

Fig 1 Acute alkali chemical injury: mild-moderate

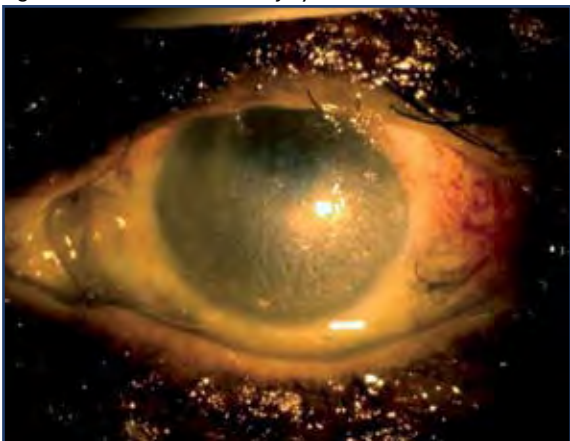


Fig 2 Acute alkali chemical injury: severe

History

- When did it occur?
- What is the chemical? (e.g. acid/alkali – alkalis are more harmful to the eye). Examples of acids include: toilet cleaner, car battery fluid, pool cleaner. Examples of alkalis include: lime, mortar & plaster, drain cleaner, oven cleaner, ammonia.
- Any first aid administered and how soon after the incident?

Examination

- Use topical anaesthesia.
- The degree of vascular blanching, particularly at the limbus, is proportional to severity of chemical burn (see Figs 1 & 2 for comparison).

Treatment

- Immediate treatment as indicated in the table on p38 - **Eye Irrigation for Chemical Burns** (see Fig 1).
- Measure pH using universal indicator paper to sample the forniceal space (see Fig 2).
- Test and record visual acuity.
- Contact poisons information or the chemical manufacturer for further information if required.

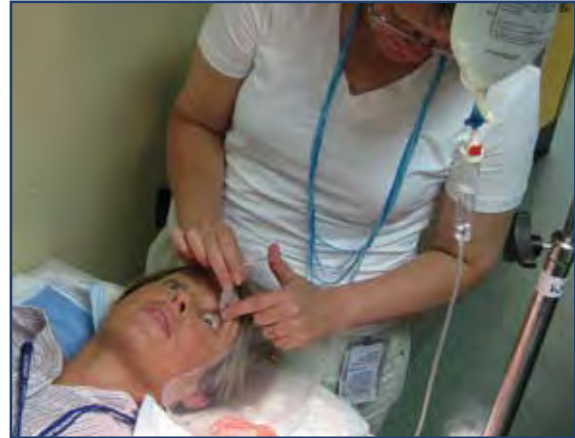

Fig 1 Irrigation with the eyelid everted

Flash Burns

ATS CATEGORY 4 (START TREATMENT WITHIN 60 MINS)
PAIN WILL INCREASE TRIAGE CATEGORY

History

- Electric arc welding or sun lamp without eye protection with symptoms appearing typically within several hours.
- Symptoms are usually intense pain, red eye, blepharospasm and tearing.

Examination

- Use topical anaesthesia in the examination.
- Visual acuity.
- Slit lamp – widespread superficial epithelial defects staining with Fluorescein, often bilateral. There may be also conjunctival injection.

Treatment

- Topical antibiotic (qid) and cycloplegic (e.g. Homatropine 2% bd) for comfort for 3 days. Oral analgesia as required. Patients are informed to re-present if symptoms have not improved appreciably after 24 hours.

Follow up - When to refer?

- Non-urgent - within 3 days.

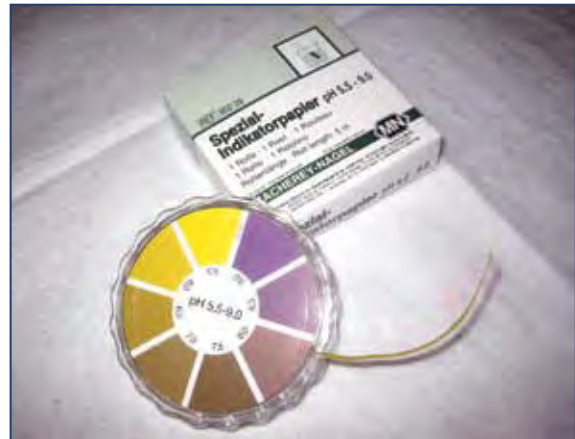

Fig 2 Universal Indicator Paper

Other**Unexplained Non-Accidental Injury (NAI)**

As well as an ophthalmological examination (fundus) and treatment, all children should be referred to the appropriate paediatric team as per hospital protocol.

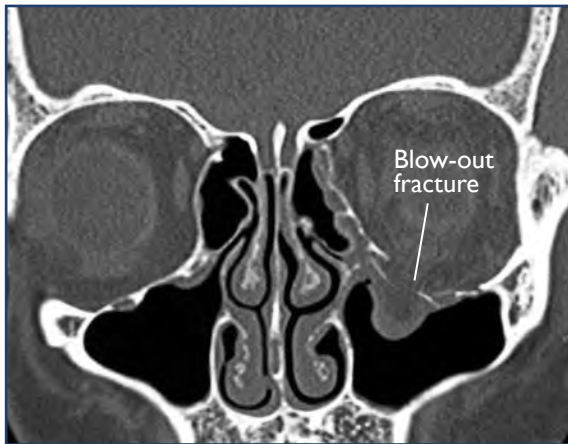


Fig 1 Coronal CT scan: Left blow-out fracture



Fig 2 Blow-out fracture - squash ball hits eye

Orbital

Blow-out Fracture (Figs 1-5)

ATS CATEGORY 4 (START TREATMENT WITHIN 60 MINS)

History

- Mechanism of injury - for example squash ball, punch with a fist.

Symptoms

- Pain (especially on vertical movement), local tenderness, diplopia, eyelid swelling and crepitus after nose blowing.
- A “white” blow-out fracture occurs with orbital injury with the findings of minimal periorbital haemorrhage, sunken (enophthalmic) globe, restricted eye movement in an unwell child.

Exlude head injury and refer urgently.

Signs

- Nose bleed, ptosis and localised tenderness.

Examination

- Complete ophthalmological examination.
- Sensation of affected cheek compared with that of the contralateral side.
- Infraorbital nerve involvement is demonstrated by anaesthetised upper teeth and gums on the affected side.
- Palpate eyelid for crepitus.

Investigation

- Computed tomography (CT) scan of the orbits and brain (axial and coronal views).

Treatment

- Nasal decongestants for 7-10 days.
- Broad spectrum oral antibiotics.
- Instruct patient not to blow his or her nose. (Avoid Valsalva manoeuvre).
- Ice pack to the orbit for 24-48 hours.

Follow up - When to refer?

- Non-urgent referral - contact ophthalmologist for time frame for all cases with:
 1. Suspected or documented orbital floor fractures.
 2. Evidence of ocular injury (see *Ocular Trauma*, p34).
- Patients should be seen within 1-2 weeks post trauma and evaluated for persistent diplopia or enophthalmos.
- Surgical repair if necessary is usually performed 7 to 14 days after trauma.

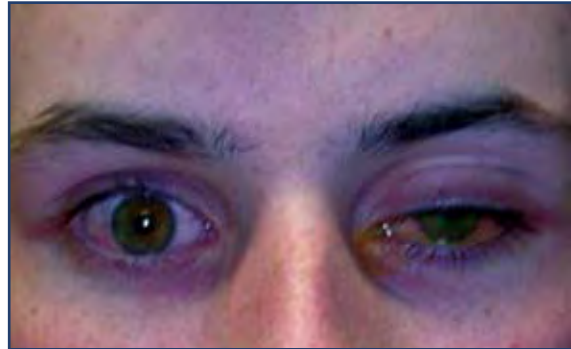


Fig 3 Left periocular ecchymosis and oedema with enophthalmos

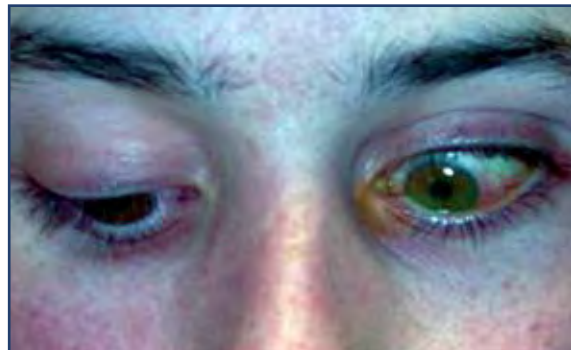


Fig 4 Ophthalmoplegia-typically in up- and down gaze (double diplopia)

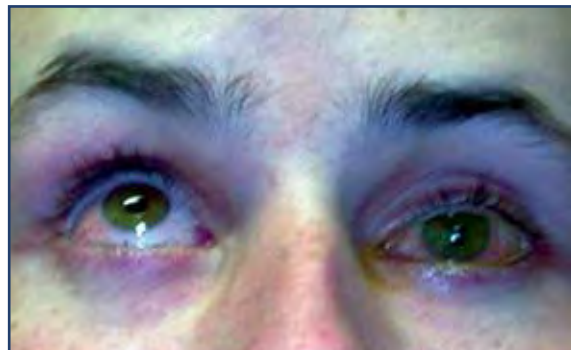

Fig 5 Ophthalmoplegia-typically in up- and down gaze (double diplopia)

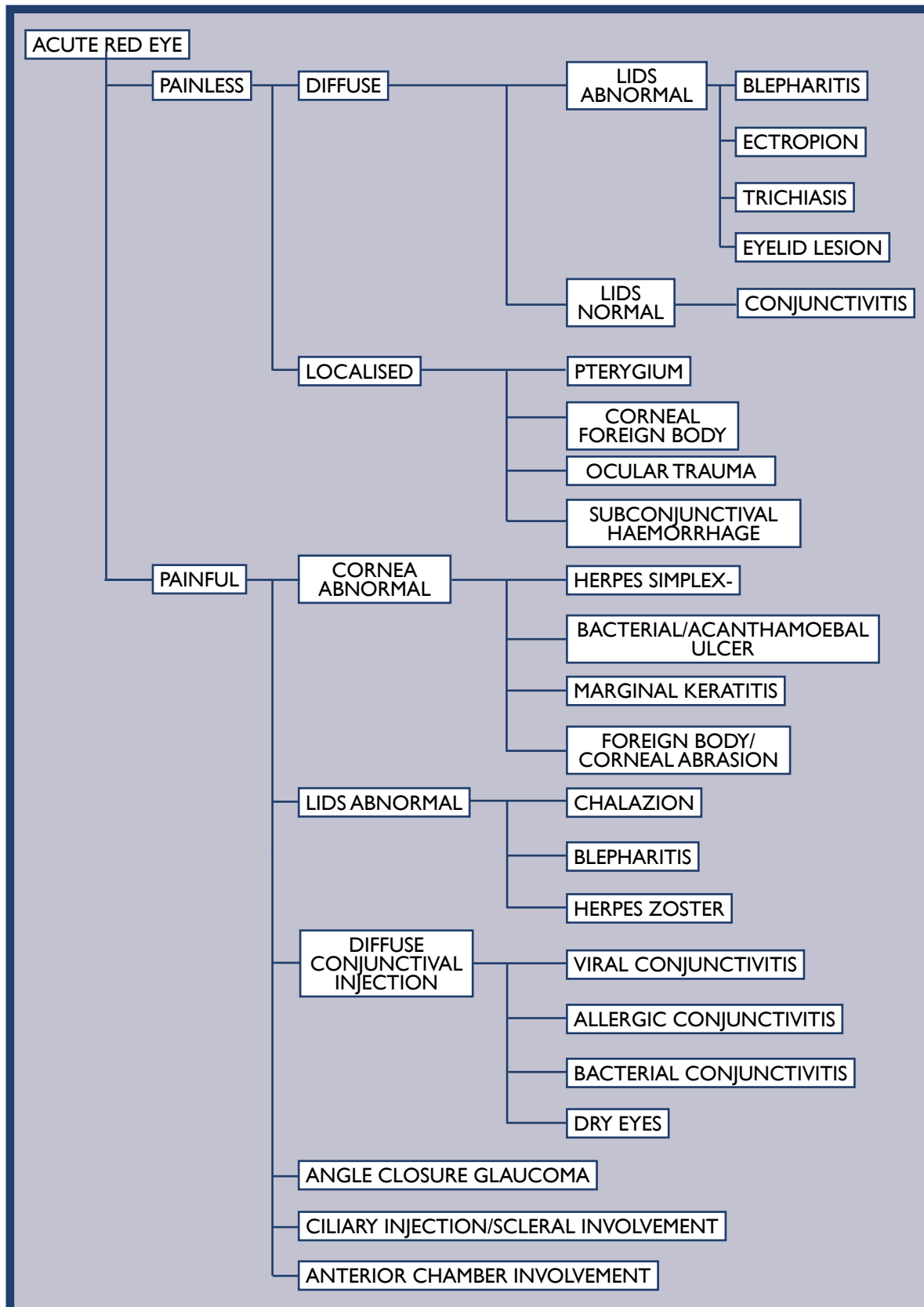
Acute red eye¹

There are many conditions that can lead to a patient presenting with a red eye. A useful distinguishing feature is whether the condition

is painful or painless, and with further slit lamp examination for specific features.



Beware in making the diagnosis of a monocular conjunctivitis until more serious eye disease is excluded.



¹Included with the permission of Dr Weng Sehu.

Painless

ATS CATEGORY 5 (START TREATMENT WITHIN 120 MINS)

It is rare for a painless red eye to require an urgent ophthalmological assessment.

Conjunctival redness can be diffuse or localised as follows:

Diffuse

ATS CATEGORY 5 (START TREATMENT WITHIN 120 MINS)

Lids abnormal

Blepharitis (Fig 1) - (non specific generalised inflammation of the eyelids). Treat with daily lid hygiene, lubrication as required with non-urgent referral - contact ophthalmologist for time frame.

Ectropion (Fig 2) - (lids turning outwards with exposure of conjunctival sac)—topical lubrication with non-urgent referral - contact ophthalmologist for time frame.

Trichiasis - epilate, lubricate with non-urgent referral - contact ophthalmologist for time frame

Entropion (Figs 3 & 4) - (lids turning inwards with eyelids abrading cornea)—check condition of cornea with fluorescein.

Intact cornea: lubrication with non-urgent referral - contact ophthalmologist for time frame.

Epithelial defect: tape back eyelid away from the cornea and manage as for corneal foreign body (see p36).

Eyelid lesion (Fig 5) - provided there is no overt eyelid infection/inflammation and no ocular involvement, non-urgent referral - contact ophthalmologist for time frame. Consider topical antibiotics.

Lids normal

Use Fluorescein to stain the corneal surface.

Conjunctivitis – most cases are painful (see p47).

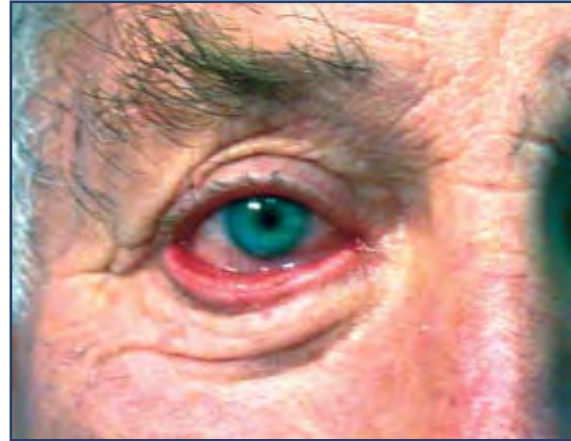


Fig 2 Ectropion

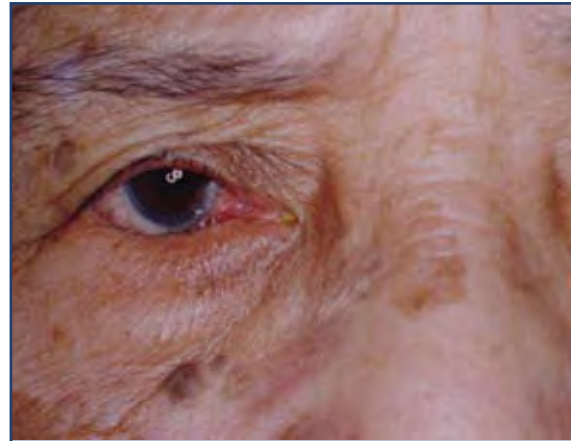


Fig 3 Entropion

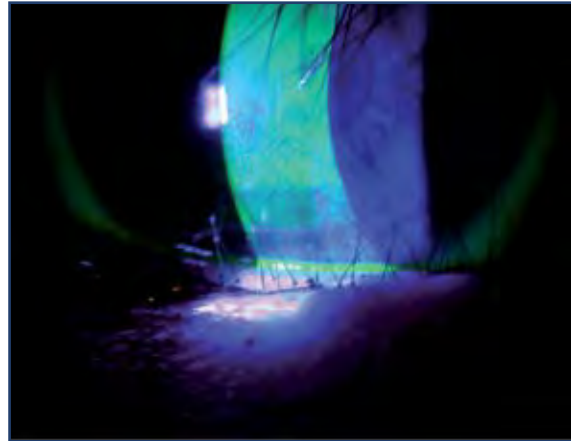


Fig 4 Entropion - Corneal abrasion

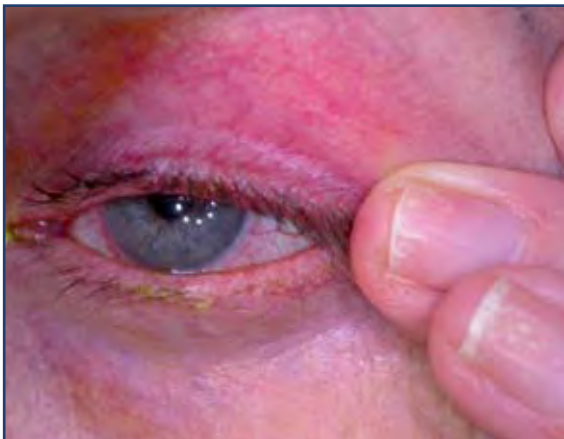

Fig 1 Blepharitis

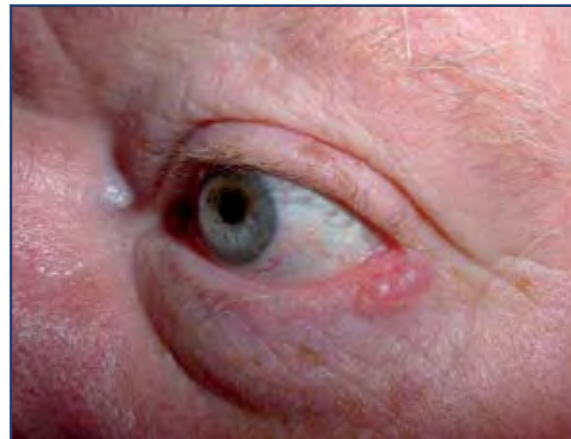


Fig 5 Lesion of left lower eyelid

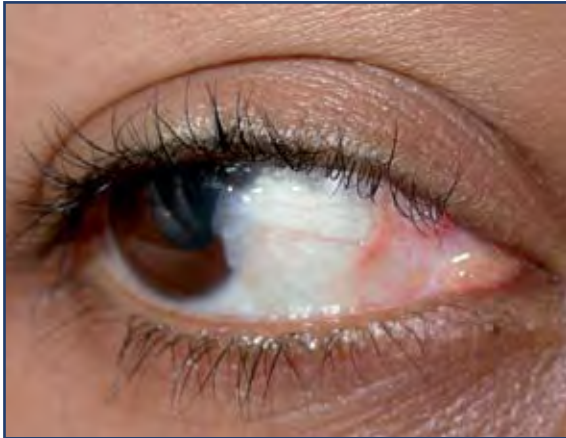

Fig 1 Pterygium

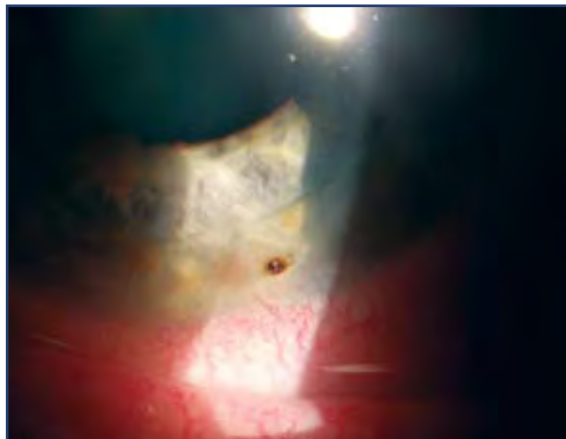


Fig 2 Corneal foreign body

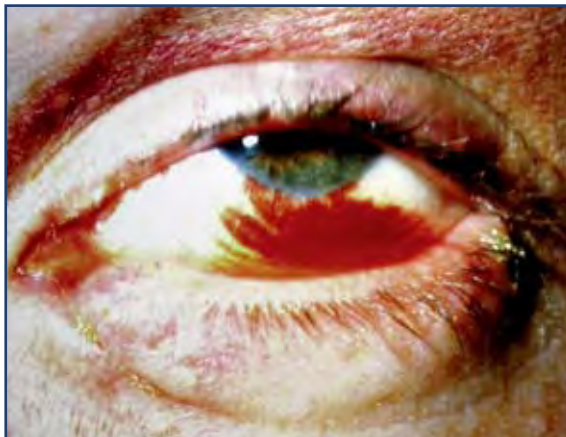

Fig 3 Subconjunctival haemorrhage

Localised

ATS CATEGORY 5 (START TREATMENT WITHIN 120 MINS)

Examine for specific conjunctival lesions.

Pterygium (Fig 1)

- A raised, yellowish fleshy lesion at the limbus that may become painful and red if inflamed.
- Treatment: lubrication and sunglasses.
- For further management - non-urgent referral - contact ophthalmologist for time frame.

Corneal foreign body (Fig 2)

- Remove foreign body and treat with topical antibiotics. (See section on corneal foreign body, p36).

Ocular trauma

- Treatment as for blunt or penetrating trauma (see p34). Topical antibiotics for superficial trauma.

Subconjunctival haemorrhage (Fig 3)

- Blood redness: unilateral, localised and sharply circumscribed.
- Underlying sclera not visible.
- No inflammation, pain or discharge.
- Vision unchanged.
- Possible association with minor injuries including rubbing.
- Common with use of antiplatelet agents and anticoagulants.

Treatment

1. Check and manage BP.
 2. If on Warfarin, check INR and manage.
 3. Use lubricating drops (see p28).
- Refer if condition worsens or pain develops.

Painful

Cornea abnormal

ATS CATEGORY 4 (START TREATMENT WITHIN 60 MINS)

Use Fluorescein to ascertain nature of any epithelial defect.

Herpes simplex infection (Figs 1, 2, & 3)

- Dendritic ulcers.
- Treat with topical Acyclovir (see p28).

Urgent referral - see ophthalmologist within 24 hours.

Bacterial or acanthamoebal ulcer (Fig 4)

- Often history of contact lens wear.
- Epithelial defect with an opacified base.

Urgent referral - immediate consult by phone, may require admission for microbiological investigation and intensive antibiotic treatment.

Marginal keratitis (Fig 5)

- Secondary to Blepharitis.
- Ulcer is situated at the corneal periphery.
- Requires discussion with ophthalmologist.
- Urgent referral - immediate consult by phone to confirm diagnosis.

Foreign body / Corneal abrasion

- As directed in the previous sections (see p19 Fig 3 (corneal abrasion with Fluorescein), p36 & p37).

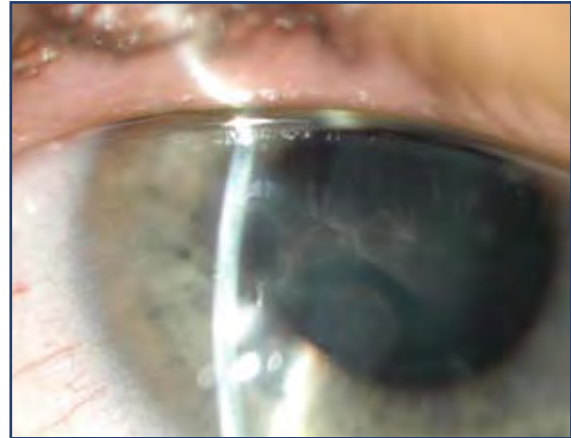


Fig 1 Herpes simplex keratitis

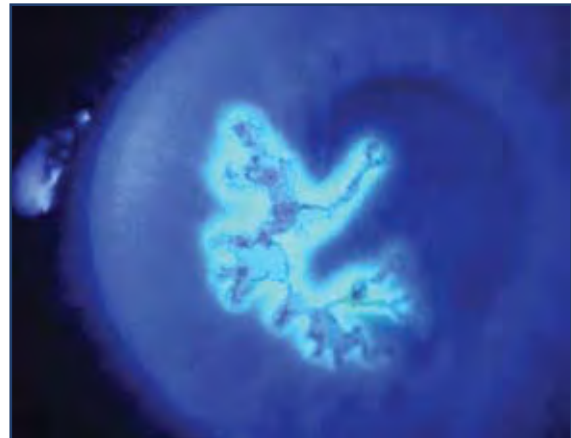


Fig 2 Herpes simplex keratitis dendritic ulcer with terminal bulbs

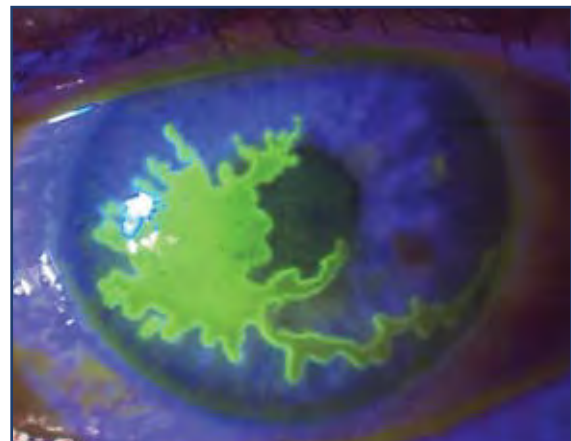


Fig 3 Herpes simplex keratitis- Steroid complication

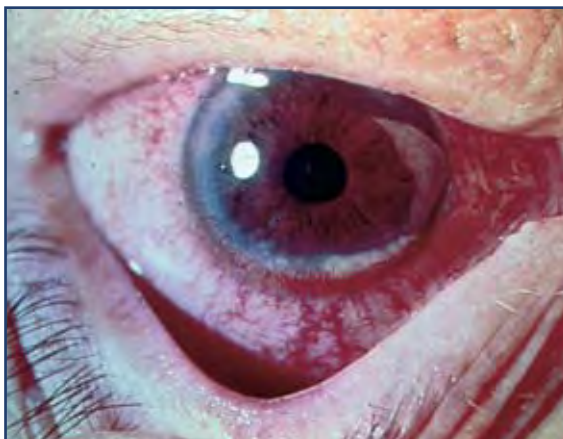


Fig 5 Marginal keratitis

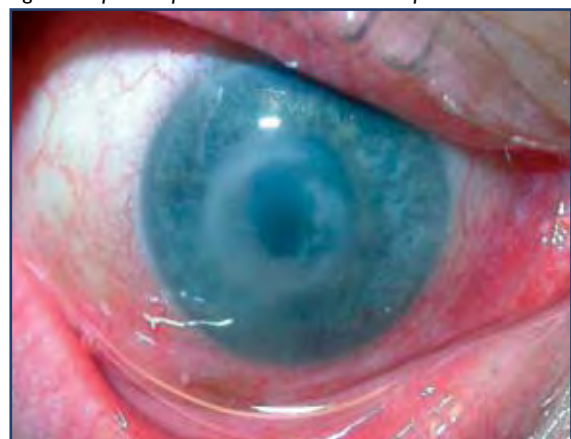

Fig 4 Bacterial ulcer

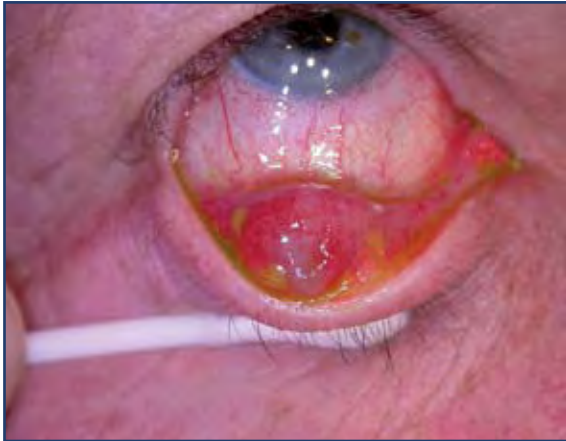

Fig 1 Chalazion

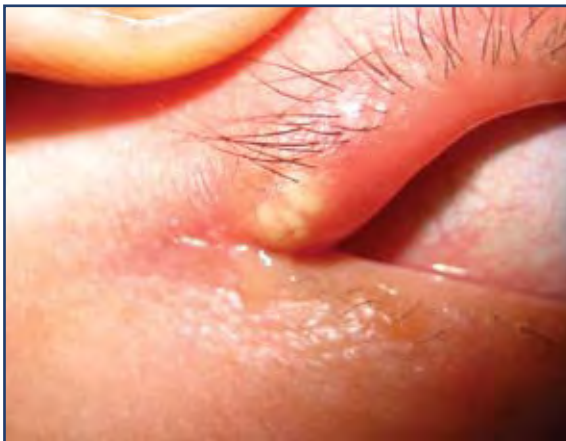


Fig 2 Sty

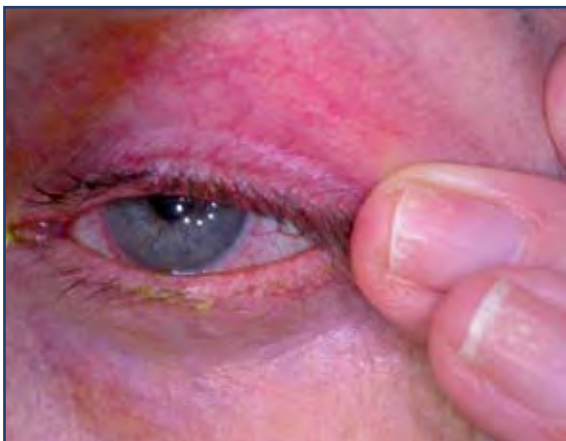

Fig 3 Blepharitis

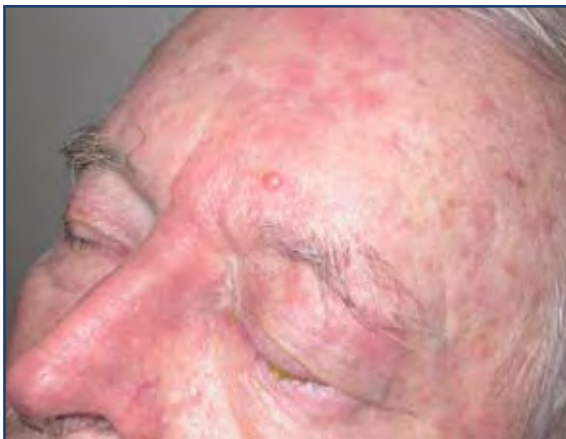

Fig 4 Herpes Zoster

Eyelid abnormal

ATS CATEGORY 4 (START TREATMENT WITHIN 60 MINS)

Chalazion (Fig 1), **Stye** (Fig 2)

- Localised eyelid inflammation with minimal ocular involvement.
- Treat with antibiotic ointment if indicated.
- If acutely inflamed treat with oral antibiotics (usual dosage and interval) and warm compresses (twice daily).
- Non-urgent referral - contact ophthalmologist for time frame.

Acute blepharitis (Fig 3)

- Localised eyelid inflammation with minimal ocular involvement (similar to Chalazion without cyst formation).
- Treat with antibiotic ointment if indicated.
- Non-urgent referral - contact ophthalmologist for time frame.

Herpes Zoster (Fig 4)

- Vesicular rash.
- Treat with oral antivirals within 72 hours of appearance of the rash.
- Non-urgent referral - contact ophthalmologist for time frame.

Diffuse conjunctival injection

ATS CATEGORY 5 (START TREATMENT WITHIN 120 MINS)

Viral conjunctivitis (Fig 1)

- Contact history with recent eye or upper respiratory tract infection symptoms (especially children).
- Burning sensation and watery discharge (different from purulent exudate in bacterial infections).
- Classically begins in one eye with rapid spread to the other.

🚩 **Highly contagious.** Observe Standard Precautions, (see p15). Refer to details of NSW Infection Control Policy, Fact Sheet for Epidemic Keratoconjunctivitis (EKC), and RANZCO Infection Control Guidelines (see p56).

Treatment

1. Wash hands and use separate tissues to avoid infection of the other eye or others.
 2. Cool compresses.
 3. Lubricants (preservative free) q 2 hrly (see p28).
 4. Antibiotic drops if indicated (see p28).
 5. Never steroids!
- Resolution may take weeks

When to refer?

- Photophobia and marked decrease in visual acuity.

🚩 **Urgent referral - see ophthalmologist within 24 hours.**

- Lasting longer than 3 weeks
 1. Chronic conjunctivitis.
 2. Consider other diagnosis.
 3. Chlamydia.
- Non-urgent referral - contact ophthalmologist for time frame.

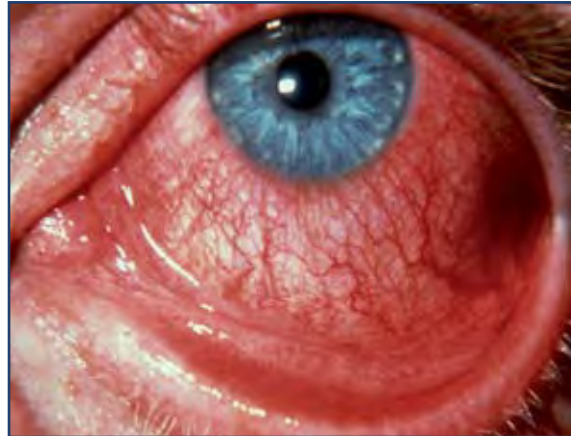

Fig 1 Viral conjunctivitis

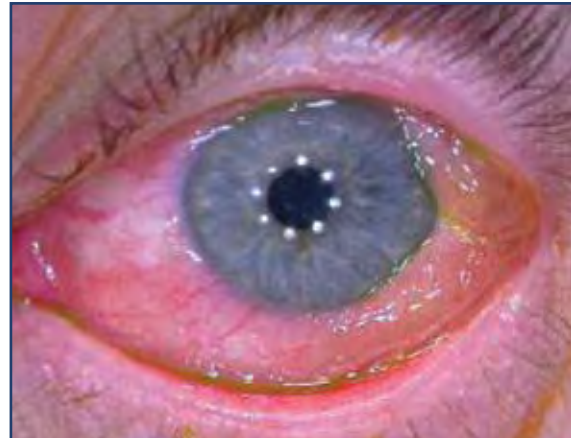


Fig 2 Allergic conjunctivitis

Allergic conjunctivitis (Fig 2)

- Itch!!!
- Atopic history: asthma, eczema, conjunctivitis.

Treatment

1. Cool compresses as required.
 2. Ocular lubricant (preservative free) qid - available over the counter (see p28).
- Non-urgent referral to ophthalmologist- within 3 days (if symptoms are not well controlled).

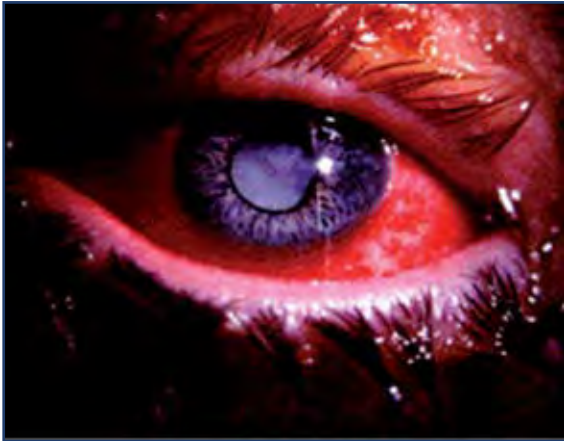

Fig 1 Bacterial conjunctivitis

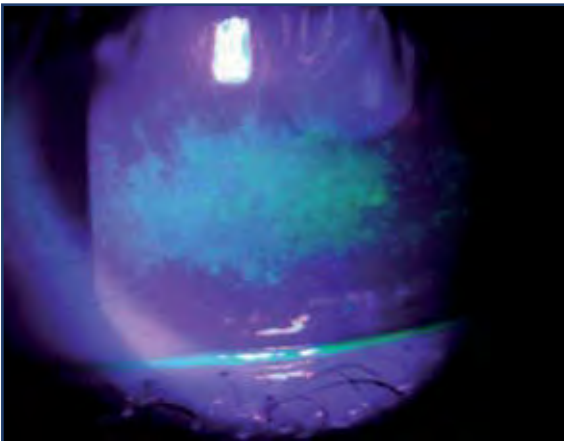


Fig 2 Dry eyes

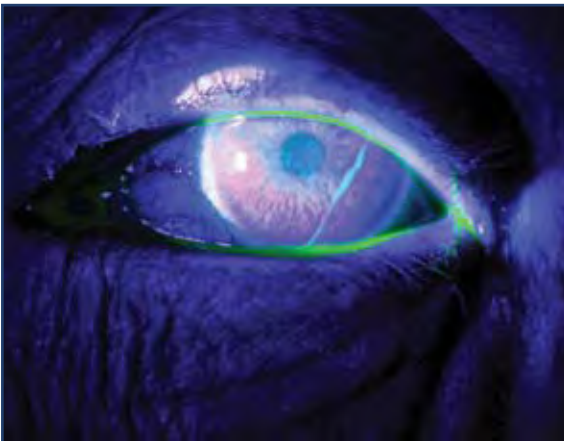

Fig 3 Dry eyes

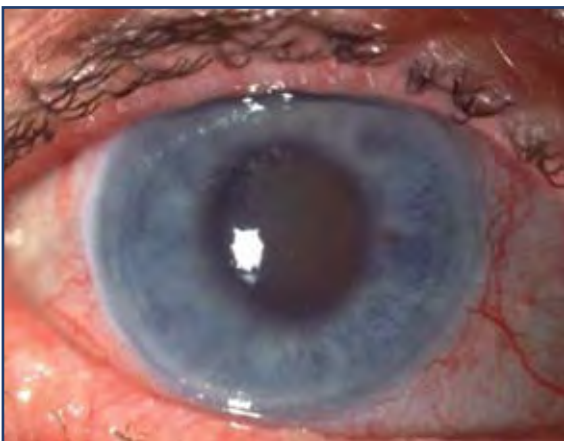

Fig 4 Acute angle closure glaucoma

Bacterial conjunctivitis (Fig 1)

- Tender inflamed conjunctiva with purulent discharge from the conjunctival sac. This condition is often bilateral.
- No corneal or anterior chamber involvement.
- Systemically well. Common in the elderly and children.

Treatment

1. Regular hygiene to minimise secretion buildup.
2. Wash hands and use separate tissues to avoid infection of the other eye or others.
3. Topical antibiotics qid for 5 days.

When to refer?

- If vision is affected.
- If condition does not improve with treatment after 2 days or worsens.
- If condition persists after treatment for 5 days.

Dry eyes (Figs 2 & 3)

- A common chronic ocular condition that is often caused by or coexists with other ocular diseases.
- Symptoms often worsen in the evening.

Treatment

1. Lubricants (see p28).
2. Non-urgent referral - contact ophthalmologist for time frame

Acute angle closure glaucoma

ATS CATEGORY 3 (START TREATMENT WITHIN 30 MINS)

- Cornea usually has hazy appearance (see Fig 4).
- Anterior chamber is shallow with irregular semidilated pupil.
- The affected eye is very tender and tense to palpation.
- Systemic symptoms include **headache, nausea and vomiting.**

Urgent referral to ophthalmologist - immediate consult by phone.

Ciliary injection/scleral involvement

ATS CATEGORY 4 (START TREATMENT WITHIN 60 MINS)

Scleritis (Fig 1)

- Vision may be impaired.
- Sclera is thickened and discoloured. The globe is tender to palpation.
- Associated history of life-threatening vascular or connective tissue disease – may require appropriate physician consult (NB look for medications involving systemic steroids, NSAIDs, antimetabolites).

Urgent referral - see ophthalmologist within 24 hours.

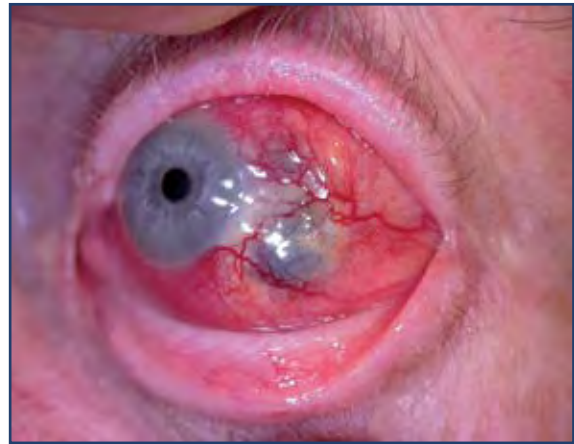

Fig 1 Scleritis

Anterior chamber involvement

ATS CATEGORY 4 (START TREATMENT WITHIN 60 MINS)

Acute Anterior Uveitis (Iritis)

- Pain, photophobia, and red eye.
- Anterior chamber appears cloudy from cells and flare.

Urgent referral - see ophthalmologist within 24 hours.

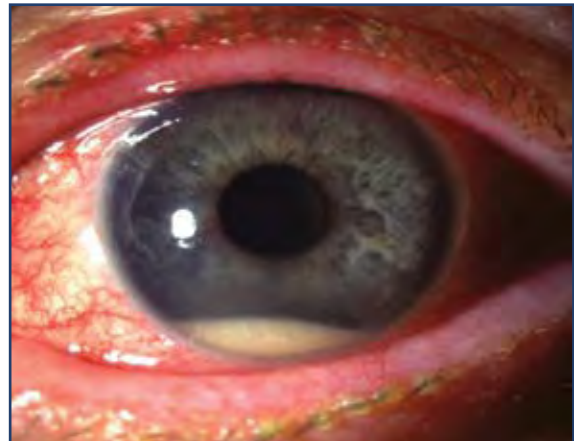


Fig 2 Hypopyon

Hypopyon (Fig 2)

Visible accumulation of white cells inferiorly seen in severe uveitis.

Urgent referral - immediate consult by phone - for investigation of infection, inflammation or ocular malignancy (Fig 3)

Hyphaema

- Usually trauma related but consider non-accidental injury in children and blood dyscrasias.
- Bed rest.

Urgent referral - see ophthalmologist within 24 hours.

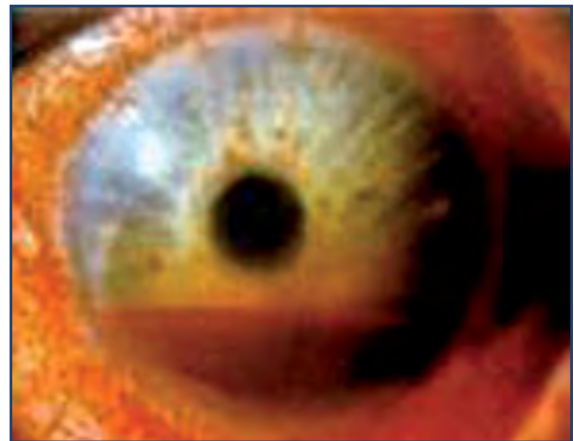
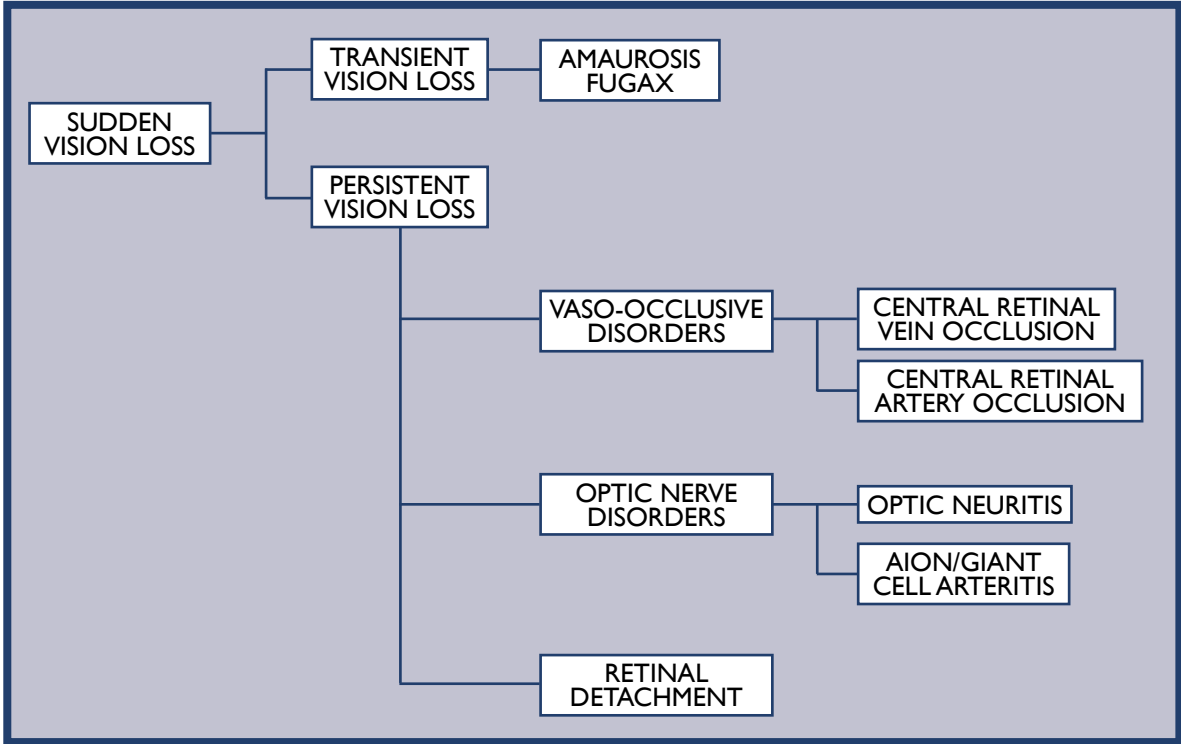


Fig 3 Hyphaema

Acute visual disturbance/Sudden loss of vision¹

ALL PRESENTATIONS OF SUDDEN PERSISTENT LOSS OF VISION REQUIRE AN URGENT OPHTHALMOLOGY CONSULT BY PHONE



¹Included with the permission of Dr Weng Sehu.

Transient Ischaemic Attack (Amaurosis Fugax) (Fig 1)

ATS CATEGORY 3 (START TREATMENT WITHIN 30 MINS)

Symptoms

- Monocular visual loss that usually lasts seconds to minutes, but may last 1-2 hours. Vision returns to normal.

Signs

- Essentially normal fundus exam (an embolus within a retinal arteriole is only occasionally seen (see Fig 1).
- Other neurological signs associated with ischemia of cerebral hemispheres.


Investigation

As per protocol but usually includes assessment of cardiovascular risk factors:

- Blood count/electrolytes/lipids/fasting blood sugar.
- Thrombophilia screen.
- Echocardiogram.
- Carotid doppler studies.

Management

- Commence aspirin.

 **Referral to neurology/cardiology or vascular surgery as appropriate. Patients with recurrent episodes of amaurosis fugax require immediate diagnostic and therapeutic intervention.**

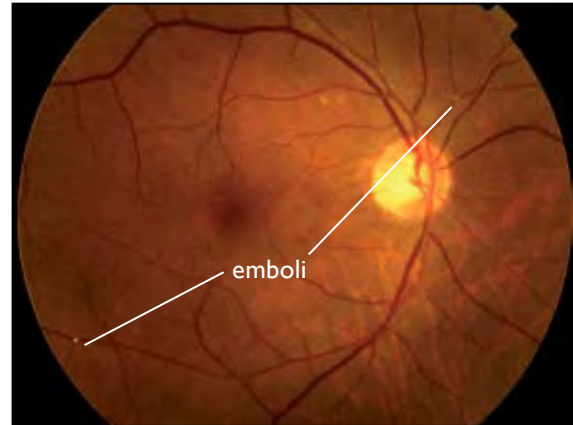


Fig 1 Transient ischaemic attack with visible emboli

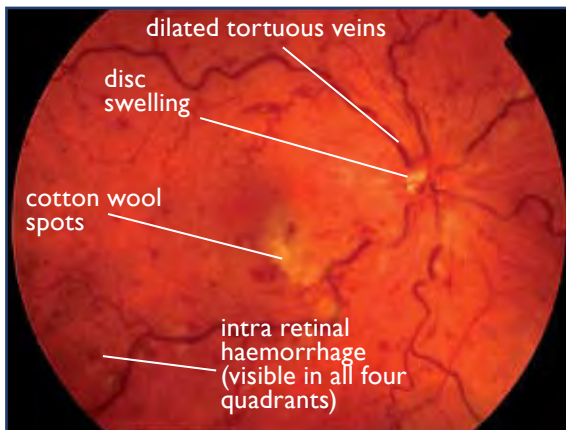


Fig 1 Non ischaemic CRVO (less severe)

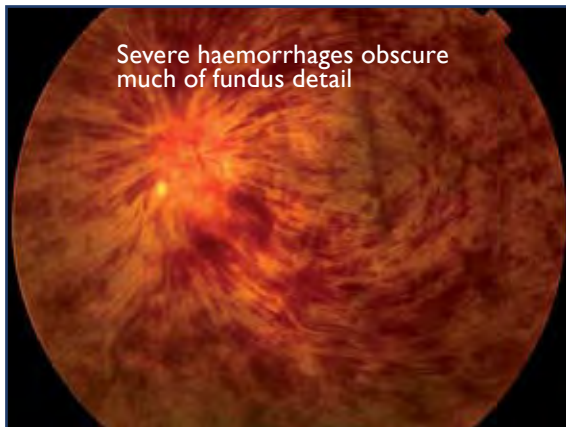


Fig 2 Ischaemic CRVO (more severe)

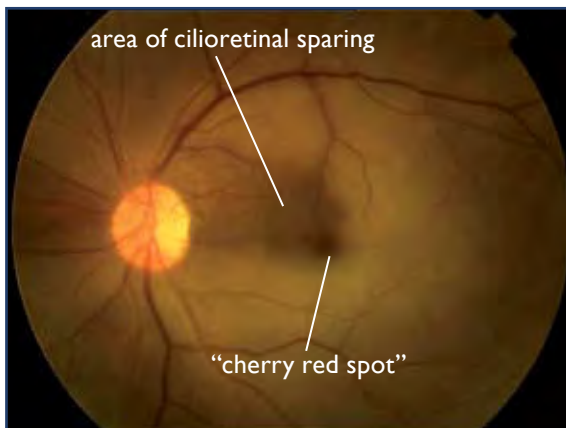


Fig 3 Central Retinal Artery Occlusion

Central Retinal Vein Occlusion (CRVO) (Figs 1 & 2)

ATS CATEGORY 3 (START TREATMENT WITHIN 30 MINS)

Symptoms

- Sudden and painless loss of vision.

Predisposing factors

- Increasing age.
- Hypertension.
- Diabetes.

Signs

- Visual acuity and presence of a Relative Afferent Pupillary Defect (RAPD) are variable depending on the severity and duration since the onset of the condition.
- Abnormal red reflex.
- Fundus examination shows large areas of haemorrhage.

Investigation and Management

- Screen for diabetes and hypertension.



Urgent referral to ophthalmologist
- immediate consult by phone

Central Retinal Artery Occlusion (Fig 3)

ATS CATEGORY 3 (START TREATMENT WITHIN 30 MINS)

Symptoms

- Sudden and painless loss of vision.

Signs

- Visual acuity < 6/60.
- Relative Afferent Pupillary Defect (RAPD) marked (see p21, Pupil Examination).
- Fundus examination: pale retinal (abnormal and asymmetrical red reflex), arteriolar and venular narrowing.

Investigation and Management



Urgent ESR and CRP to exclude Giant Cell Arteritis.



Urgent referral to ophthalmologist- immediate consult by phone.

- Workup as per Transient Ischaemic Attack (see p51).

Optic neuritis (Fig 1)

ATS CATEGORY 3 (START TREATMENT WITHIN 30 MINS)

Symptoms

- Painless loss of vision over hours to days. Vision loss can be subtle or profound.
- Reduced visual acuity, colour and contrast vision.
- Usually unilateral, but may rarely be bilateral.
- More often affecting females aged between 18-45.
- Orbital pain usually associated with eye movement.
- May have other focal neurological symptoms.

Signs

- Relative Afferent Pupillary Defect (RAPD)
- Decreased visual acuity.
- Decreased colour vision.
- +/- Patchy visual field defects.
- +/- Swollen optic disc.
- May have other focal neurological signs.

Investigation and Management

- Complete ophthalmic and neurological examination.
- Blood count/Erythrocyte Sedimentation Rate (ESR).
- 🚩 **Urgent referral to ophthalmologist - immediate consult by phone** - may be indicated for further MRI investigation and intravenous steroid treatment may be required.
- 🚩 **There are NO indications for oral cortico-steroids as initial treatment.**

Arteritic Ischaemic Optic Neuropathy (AION)/Giant Cell Arteritis (GCA) (Fig 2)

ATS CATEGORY 3 (START TREATMENT WITHIN 30 MINS)

- Transient visual loss may precede an ischaemic optic neuropathy or central retinal artery occlusion.
- Typically affects patients greater than 50 years.
- Raised Erythrocyte Sedimentation Rate (ESR) and C-Reactive Protein (CRP).

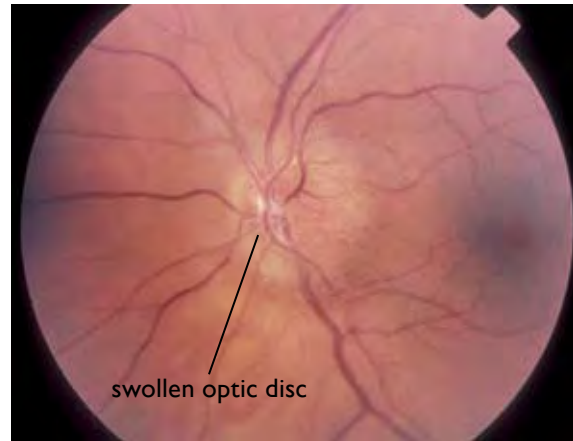


Fig 1 Optic neuritis

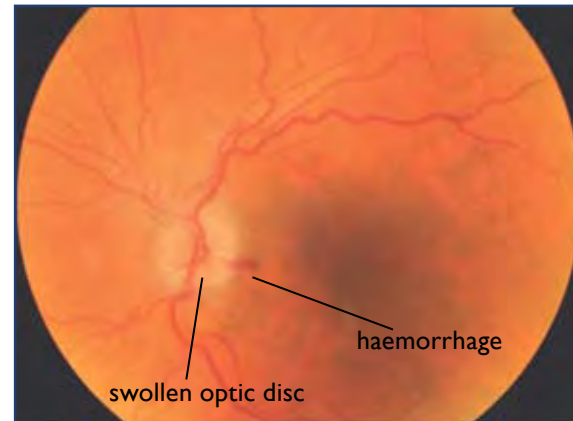


Fig 2 AION due to Giant Cell Arteritis

Symptoms

- Temporal headache.
- Scalp tenderness.
- Jaw claudication.
- Fever and night sweats.
- Generalised muscle pain and weakness.

Signs

May include any or all of the following:

- Afferent pupillary defect.
- Poor visual acuity, often VA count fingers.
- Palpable and tender non-pulsatile temporal artery.
- Swollen optic disc.

Investigation and Management

- Immediate ESR and CRP (NB not always raised in GCA).
- 🚩 **Urgent referral to ophthalmologist - immediate consult by phone** on the necessity of steroid treatment and/or temporal artery biopsy. Screen patient for risk factors and if indicated consult on call physician for complications of steroid treatment.

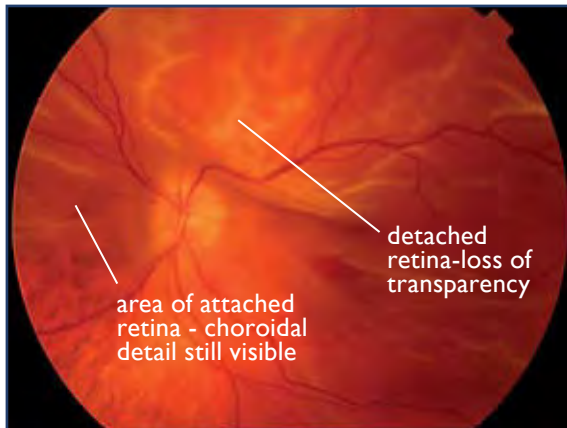


Fig 1 Retinal detachment (macula off)

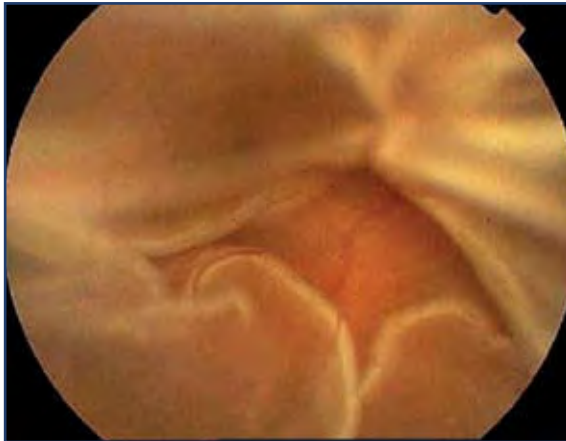


Fig 2 Retinal detachment

Retinal Detachment (Figs 1 & 2)

ATS CATEGORY 3 (START TREATMENT WITHIN 30 MINS)

- Separation of sensory retina from the retinal pigment epithelium.
- The most common aetiology of this condition is a predisposing retinal defect.

Symptoms


- Painless loss of vision. The patient may have encountered a recent history of increased number of visual floaters and/or visual flashes. There may be a “dark shadow” in the vision of the affected eye.
- Patients who are myopic (short sighted) or with previous trauma history have a higher risk of this condition.

Signs

- Reduced visual acuity (if the macula is detached).
- Abnormal red reflex - a mobile detached retina may be visible on ophthalmoscopy.

Investigation and Treatment

- Minimise activity - bed rest with toilet privileges.

 **Urgent referral to ophthalmologist - immediate consult by phone.**

- May require workup for surgery under general anaesthesia.

Chapter Four

Emergency Contact Information

Emergency contacts & further information

**Sydney Hospital & Sydney Eye
Hospital: (02) 9382 7111**

**NSW Poisons Information Centre:
131126**

**For current NSW Infection Control
Policies check NSW Health website:**

**[http://www.health.nsw.gov.au/policies/
pdf/2007/pdf/IPD2007_036.pdf](http://www.health.nsw.gov.au/policies/pdf/2007/pdf/IPD2007_036.pdf)**

**For Fact sheet for Epidemic
Keratoconjunctivitis (EKC) check NSW
Health website:**

**[http://www.health.nsw.gov.
au/factsheets/infectious/
keratoconjunctivitis.html](http://www.health.nsw.gov.au/factsheets/infectious/keratoconjunctivitis.html)**

**For RANZCO Infection Control
Guidelines check RANZCO website:**

**[http://www.ranzco.edu/aboutus/
ranzco-policies-and-procedures/policy/
Infection_Control_Guidelines.pdf/view](http://www.ranzco.edu/aboutus/ranzco-policies-and-procedures/policy/Infection_Control_Guidelines.pdf/view)**
