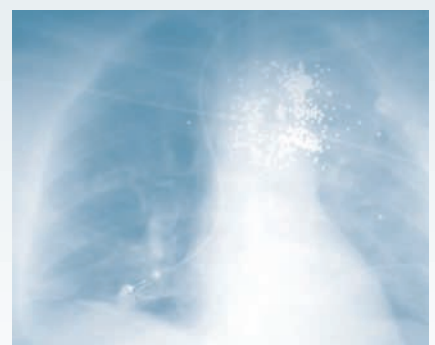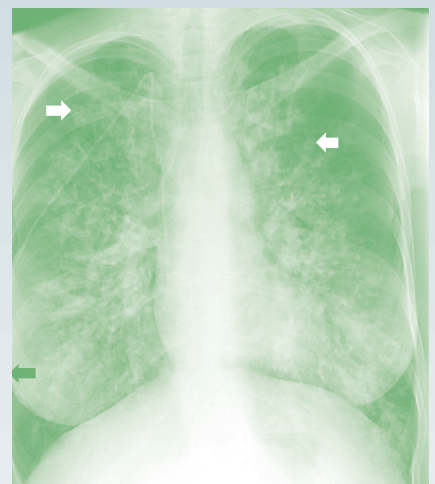
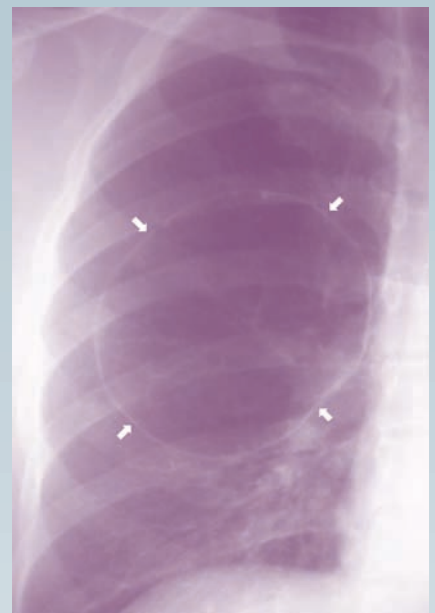
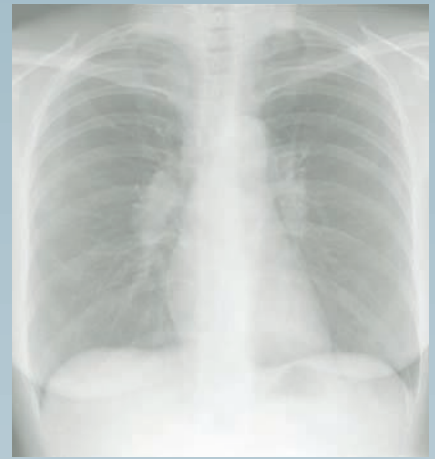


The WHO manual of diagnostic imaging

RADIOGRAPHIC
ANATOMY
AND INTERPRETATION
OF THE CHEST AND
THE PULMONARY
SYSTEM



The WHO manual of diagnostic imaging

Radiographic Anatomy and Interpretation
of the Chest and the Pulmonary System

Editors

Harald Ostensen
Holger Pettersson

Authors

Stephen M. Ellis
Christopher Flower



**Published by the World Health Organization
in collaboration with the
International Society of Radiology**

WHO Library Cataloguing-in-Publication Data

Ellis, Stephen M.

The WHO manual of diagnostic imaging : radiographic anatomy and interpretation of the chest and the pulmonary system / Stephen M. Ellis, Christopher Flower ; editors: Harald Ostensen, Holger Pettersson.

(WHO manuals of diagnostic imaging)

1.Radiography, Thoracic—methods 2.Lung—radiography 3.Manuals I.Flower, Christopher. II.Ostensen, Harald. III.Pettersson, Holger. IV.Title V.Series.

ISBN 92 4 154677 8 (NLM Classification: WF 975)

© World Health Organization 2006

All rights reserved. Publications of the World Health Organization can be obtained from WHO Press, World Health Organization, 20 Avenue Appia, 1211 Geneva 27, Switzerland (tel: +41 22 791 2476; fax: +41 22 791 4857; email: bookorders@who.int). Requests for permission to reproduce or translate WHO publications—whether for sale or for noncommercial distribution—should be addressed to WHO Press, at the above address (fax: +41 22 791 4806; email: permissions@who.int).

The designations employed and the presentation of the material in this publication do not imply the expression of any opinion whatsoever on the part of the World Health Organization concerning the legal status of any country, territory, city or area or of its authorities, or concerning the delimitation of its frontiers or boundaries. Dotted lines on maps represent approximate border lines for which there may not yet be full agreement.

The mention of specific companies or of certain manufacturers' products does not imply that they are endorsed or recommended by the World Health Organization in preference to others of a similar nature that are not mentioned. Errors and omissions excepted, the names of proprietary products are distinguished by initial capital letters.

All reasonable precautions have been taken by the World Health Organization to verify the information contained in this publication. However, the published material is being distributed without warranty of any kind, either express or implied. The responsibility for the interpretation and use of the material lies with the reader. In no event shall the World Health Organization be liable for damages arising from its use.

The named authors alone are responsible for the views expressed in this publication.

Printed in Singapore

Contents

Chapter 1	Introduction	1
Chapter 2	The normal CXR	3
	Technique	3
	Lateral	5
	Anatomy	7
Chapter 3	How to read a CXR	15
	The silhouette sign	15
	Suggested scheme for reading a frontal CXR	16
	Review areas	20
	Pitfalls	27
	Buttons	32
	ECG tabs	33
	Hair braids	34
	Film/screen artefacts	34
	Film kinking during processing	36
Chapter 4	Pattern recognition	37
	Collapse	37
	Consolidation	41
	Ground glass opacity	43
	Masses	43
	Nodules	46
	Lines	48
	Cavities	51
Chapter 5	Abnormalities of the thoracic cage and chest wall	53
	Pectus excavatum	53
	Kyphosis	55
	Tumours in bone	56
	Cutaneous nodules	58
	Soft tissue asymmetry	59
	Sickle cell disease	61
Chapter 6	Lung tumours	63
	CXR features of malignant tumours	63
	CXR features of benign tumours	67
	Bronchal carcinoma	68
	Non-mass like tumours	71
	Pleural tumours	71
	The solitary pulmonary nodule	72
	Further imaging	72

Chapter 7	Pneumonias	73
	Bacterial pneumonia	73
Chapter 8	Chronic airways disease	85
	Asthma	85
	Chronic bronchitis	86
	Emphysema	88
	Bronchiectasis	91
Chapter 9	Diffuse lung disease	95
	Fibrosis	95
	Lymphangitis carcinomatosa	97
	LAM	97
	LCH	98
	Pulmonary sarcoid	99
	Hypersensitivity pneumonitis (HP)	102
Chapter 10	Pleural disease	105
	Pneumothorax	105
	Effusion	109
	Empyema	113
	Haemothorax	114
	Pleural calcification	115
	Mesothelioma	117
Chapter 11	Left heart failure	119
	Cardiomegally	119
	Interstitial oedema	121
	Blood diversion	122
	Consolidation	123
	Septal lines	123
	Effusions	123
Chapter 12	Cardiac	125
	Coarctation of the aorta	125
	Fallot's tetralogy	126
	Cardiomegally	127
	Pericardial effusion	128
	Pericardial calcification	129
	Ventricular aneurysm	129
	Aortic aneurysm	130
Chapter 13	Pulmonary embolic disease	133
Chapter 14	Mediastinal disease	135
	Mediastinal tumours	135
	Hilar masses	137
	Lymphadenopathy	140
	Mediastinal haemorrhage	141
	Mediastinal abscess	142
Chapter 15	Trauma	143
	Further reading	147

Foreword

Modern diagnostic imaging offers a vast spectrum of modalities and techniques, which enables us to study the function and morphology of the human body in details that approaches science fiction.

However, it should be noticed that even in the most advanced imaging department in the economically privileged parts of the world, 70–80 % of all clinically relevant questions may be solved by using the two main *cornerstones* of diagnostic imaging, which are radiography (X-ray) and ultrasonography.

It should also be remembered that thousands of hospitals and institutions worldwide do not have the possibilities to perform even these fundamental imaging procedures, for lack of equipment and/or diagnostic imaging skills.

Therefore, WHO in collaboration with the International Commission for Radiologic Education (ICRE) of the International Society of Radiology (ISR) is creating a series of “WHO Manuals of Diagnostic Imaging”, developed under the umbrella of the Global Steering Group for Education and Training in Diagnostic Imaging. Among the members of this group are the major regional and global societies involved in diagnostic imaging, including the International Society of Radiology (ISR), the International Society of Radiographers and Radiological Technologists (ISRRT), and the World Federation for Ultrasound in Medicine and Biology (WFUMB).

The full series of manuals will primarily cover the examination techniques and interpretation of radiography, in a later stage also ultrasonography. It is meant for health care personnel who, in their daily work, are responsible for producing and interpreting radiographs, be it radiologists or other medical specialists, general practitioners, or radiological technologists working in rural areas.

The manuals are authored by experts in each field, covering the experience, knowledge and needs, which are specific for different regions of the world.

It is our sincere hope that the manuals will prove helpful in the daily routine, facilitating the diagnostic work up and hence the treatment, to the best benefit for the patient.

Geneva, Switzerland and Lund, Sweden, December 2005

Harald Ostensen

Holger Pettersson

Introduction

The following text aims to provide an aid to the interpretation of the chest radiograph (CXR). This is not a comprehensive account of all possible chest diseases but a descriptive text to help identify the way in which chest pathology is manifested and diagnosed on CXR. The initial chapters deal with interpretive skills and pattern recognition and the later chapters demonstrate specific pathologies.

This page was left blank by the publisher.

The normal CXR

Technique

The range of densities one is attempting to image on a chest radiograph (CXR) is larger than at any other site in the body, ranging from very dense bone to very low-density air filled lungs. As a result, the quality of the CXR is very dependent on the technique used in its production.

High kV

- In order to form an X-ray image, the tissue being imaged must absorb some X-rays but enough must pass through to expose the film.
- It was standard practice to produce a CXR using a tube voltage of 50–70 kV, such images have considerable contrast but fail to show up to a third of the lungs “hidden” behind the heart and diaphragm.
- Using 120–140 kV produces a spectrum of X-ray energies that are higher and therefore more penetrating. In this way a greater number of X-rays pass through the denser parts of the chest, i.e. the mediastinum, and therefore give more detail both of the mediastinum and the heart. Above 140 kV radiographic contrast becomes significantly reduced.

Air gaps

- X-rays are not only absorbed in the body they are also scattered. This process alters the direction of travel of the X-ray causing image un-sharpness; only X-rays passing in a straight line cast an accurate shadow of the chest on the X-ray film.
- Placing an air gap between the patient and the X-ray film increases the chance that the scattered X-rays will “miss” the X-ray film and therefore not affect image quality (Fig 2.1).

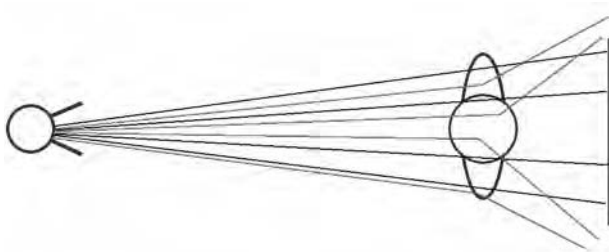


Figure 2.1

The X-ray beams originating from the X-ray source on the left are shown passing through a subject on the way to exposing the film on the right. The beams are scattered but miss the film due to the air gap.

- The amount by which the image of the chest is magnified on the X-ray film is dependent on how far the subject is from the film and how divergent the X-ray beams are. Therefore, when using an air gap technique the X-ray source should be around 3–4 m from the film.

Grid

- An alternative and more commonly used method of reducing scatter is the placement of a lead grid between the patient and the film.
- The grid is made up of many strips of X-ray absorbing lead placed closely together and angled in such a way that only the X-rays travelling in a particular direction, corresponding to that of a straight line between the X-ray tube and the film, are allowed through, scattered X-rays are absorbed by the lead strips. A fine vibration of the grid ensures that the strips of lead in the grid do not cast noticeable shadows on the film (Fig 2.2).

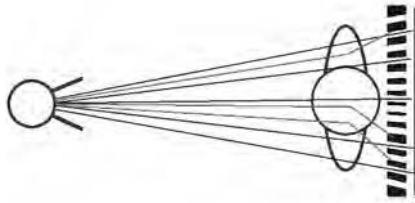


Figure 2.2

This time the subject is separated from the film by a grid that stops the scattered X-rays exposing the film.

- Using a grid enables the subject to be placed against the X-ray cassette so that the divergence of the X-ray beam is less significant and the X-ray source can be closer to the cassette, around 2 m, therefore not requiring a dedicated room. However, the air gap technique is felt to produce superior images.

PA/AP

- A CXR taken in the radiology department is taken with the patient standing erect in front of and facing the cassette containing the X-ray film.
- The X-ray tube is positioned behind the patient hence the X-rays pass from posterior to anterior (PA).
- For patients confined to bed or chair, the PA technique is not possible, therefore the X-ray film is placed behind the patient and the X-ray tube in front so that the X-rays pass from anterior to posterior (AP).
- In general, AP CXRs are taken with a shorter X-ray tube to film distance compared to a PA film due to practical limitations.
- There are marked differences in the CXR that can be attributed entirely to the technique used.
- The heart is an anterior organ in the chest and its size is magnified on an AP view due to both the increase in divergence of the incident X-rays (the X-ray source being closer to the film) and the increase in distance between the heart and the film when compared to the PA technique. This magnification may make numerous mediastinal structures appear abnormally enlarged.
- On AP films, the clavicles cast a broader shadow and typically overlay the apices making interpretation of these areas difficult (Fig 2.3).
- In general, the AP film should be interpreted with caution.

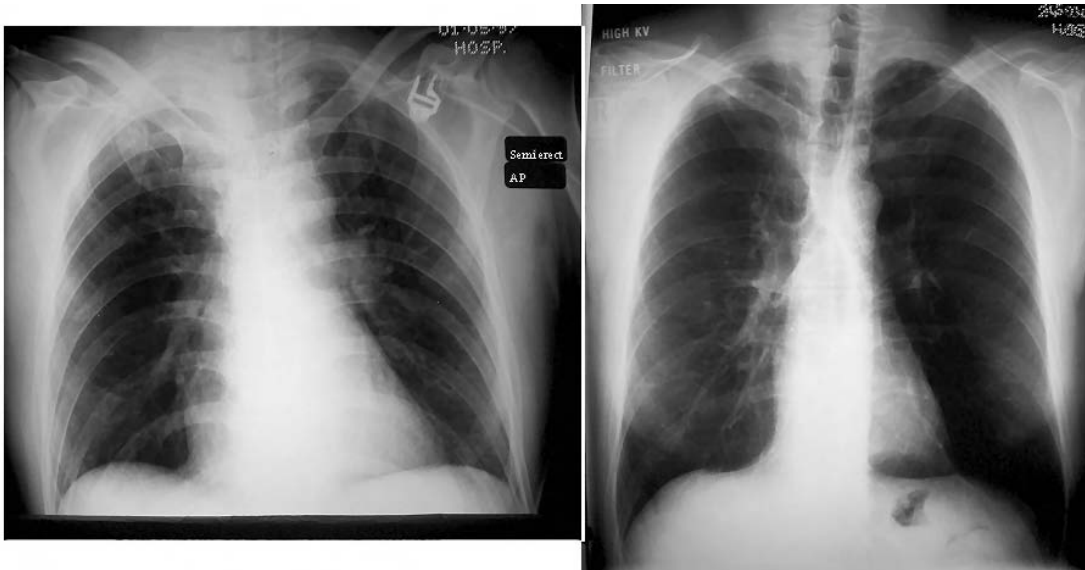


Figure 2.3
AP CXR (left image) and PA CXR (right image) of an adult male taken 1 day apart. Note the apparent difference in cardiac size and lung volumes and the loss of clarity in the apices.

Lateral

- The better visualization of the mediastinal structures due to a high kV technique reduces the necessity for routine lateral views.
- A lateral view provides clearer visualization of the area anterior to the mediastinum and posterior to the diaphragms and may help interpretation of an abnormality seen on a frontal view (Fig 2.4).

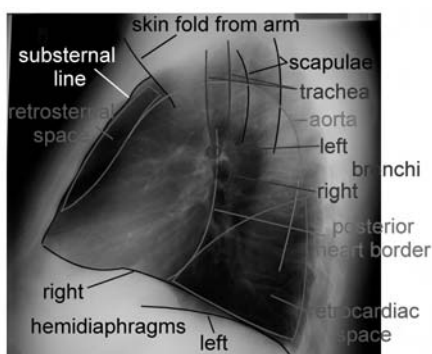


Figure 2.4
Annotated lateral CXR illustrating the anatomy.

- If a low kV technique is used a lateral is necessary to image the areas behind the heart and hemi-diaphragms.
- Other pathology better appreciated on the lateral CXR is right middle lobe or lingular collapse and/or consolidation, which may be missed on a frontal CXR due to the orientation of the X-ray beam (Fig 2.5).

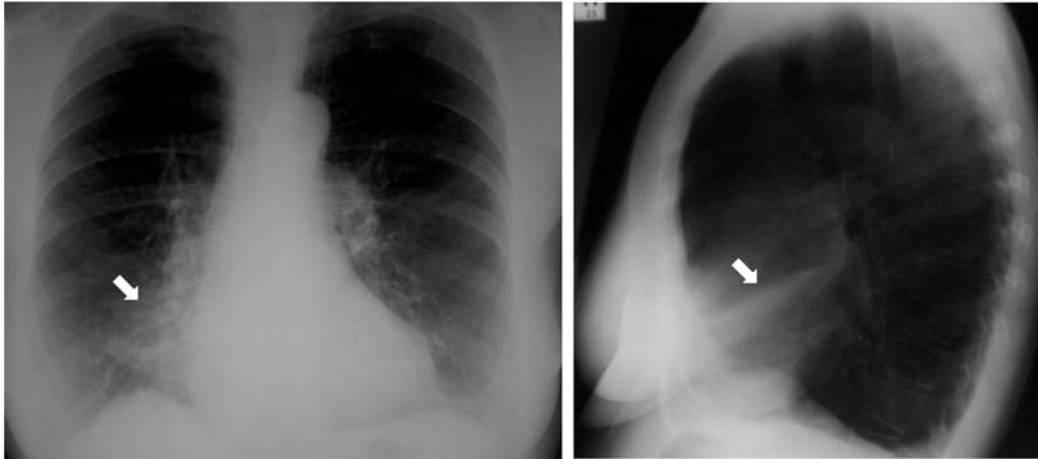


Figure 2.5

Frontal and lateral CXRs of an adult female with right middle lobe collapse. The white arrows indicate the areas of abnormal opacity. On the lateral view one can appreciate that the collapsed lobe is at an angle to the direction of the X-ray beam for the frontal view as the lobe collapses down onto the major fissure, the result is a vague increase in opacity on the frontal view.

- Conventional radiography uses a combination of a light sensitive film placed against an X-ray absorbing screen that converts X-ray photons to visible light (scintillation).
- Only around 5% of the CXR image is derived from the direct effect of X-rays on the film, the rest is due to the screen, which enhances the efficacy of the incident X-rays by producing many photons of light for each X-ray photon.
- The advantage of this combination is in a reduction of X-ray dose required to form an image.
- The disadvantage is that the light produced will spread out from the point at which the X-ray arrived and expose a larger area of the film creating some “un-sharpness” compared to an image derived entirely from incident X-ray exposure.
- This is one example of the many compromises made in radiology between radiation dose and image quality.
- The response of the film/screen combination to radiation exposure is not linear throughout the range of exposures. There is an approximate linear portion in the mid exposure range but very non-linear response at each end of the spectrum.
- As the range of tissue densities in the chest is so large the range of exposure that the film/screen combination has to depict is also large and regions of the CXR corresponding to exposures towards the end of the spectrum will have poor contrast.
- The CXR is taken such that as much information as possible is depicted in the mid range of exposure. A high kV approach generates a narrower spectrum of X-ray exposure but retains tissue distinction hence creating a better CXR.

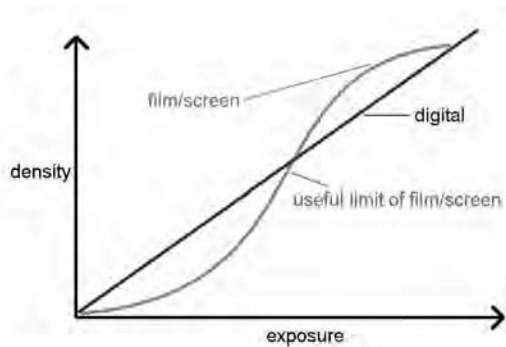


Figure 2.6

Graph of film density against exposure for digital and film/screen radiography. The curved line indicates the limited range over which film/screen radiography produces useful contrast.

- Digital radiography uses either a storage phosphor plate, which is read by a laser after the exposure, or by converting the incident X-ray directly into an electrical signal; both techniques have a linear relationship between optical density and exposure and therefore are not restricted in the same way as film/screen radiography (Fig 2.6).

kV, mA

- X-rays are produced when fast moving electrons impact on a tungsten target.
- The energy of the X-rays produced is dependent on the energy of the electrons.
- The energy is given to the electrons by accelerating them between the electron source (a piece of heated metal) and the target by applying a voltage across these two pieces of metal (the tube voltage).
- The electrons have a negative charge and are attracted to the positively charged target.
- The tube voltage determines the electron energy and thus the spectrum of X-ray energies produced, the higher the voltage the higher the X-ray energy.
- The amount of X-rays produced is dependent on both the kV and the mA.
- The mA is defined by the rate per second at which electrons hit the target in the X-ray tube. The product of tube current and exposure time mAs is used in the calculation of X-ray dose.
- Doubling the kV from 60 kV (low kV) to 120 kV (high kV) will increase the amount of X-rays produced four fold, therefore the mAs should be reduced to a quarter of its original value to leave the amount of X-rays produced, and thus the exposure, unchanged.

Anatomy

- A CXR is a two dimensional representation of a three-dimensional structure. As a result the CXR includes many overlapping structures.
- A thorough knowledge of the anatomy should enable you, on most occasions, to identify an abnormality and place it in the correct area of the chest.

Lobar anatomy on CXR (Fig 2.7)

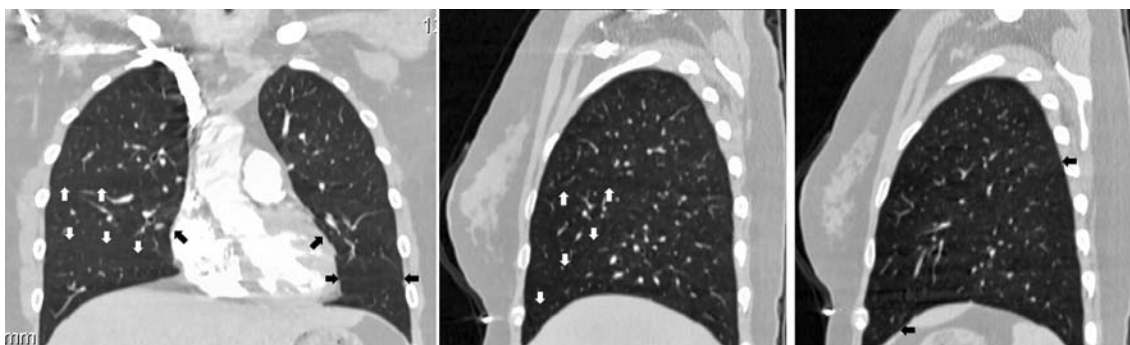


Figure 2.7

Coronal and sagittal reconstructions from a CT scan of the chest. The right minor fissure is marked by white arrows (vertical up), the right major fissure by white arrows (vertical down) and the left major fissure between the horizontal black arrows. Note on the coronal image the lung between the minor and major fissures, the right middle lobe, is adjacent to the right heart border. On the left the lung above the left oblique fissure, the left upper lobe or more specifically the lingular, lies adjacent to the left heart border. The lower lobes are adjacent to the hemidiaphragms.

Hilar points (Fig 2.8)

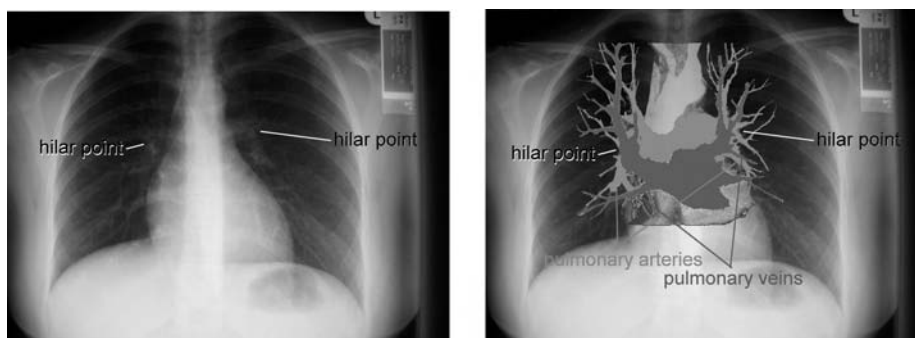


Figure 2.8

The hilar points are marked on the left image. On the right image the pulmonary arteries and pulmonary veins have been superimposed. The hilar point is formed by the outer margins of the upper lobe pulmonary veins and the lower lobe pulmonary arteries as they cross. Note the left main pulmonary artery loops over the left main bronchus therefore the left basal pulmonary artery crosses the left upper lobe pulmonary vein higher on the left than on the right and the hila point is also normally higher on the left.

Costophrenic and cardiophrenic angles (Figs 2.9, 2.10)

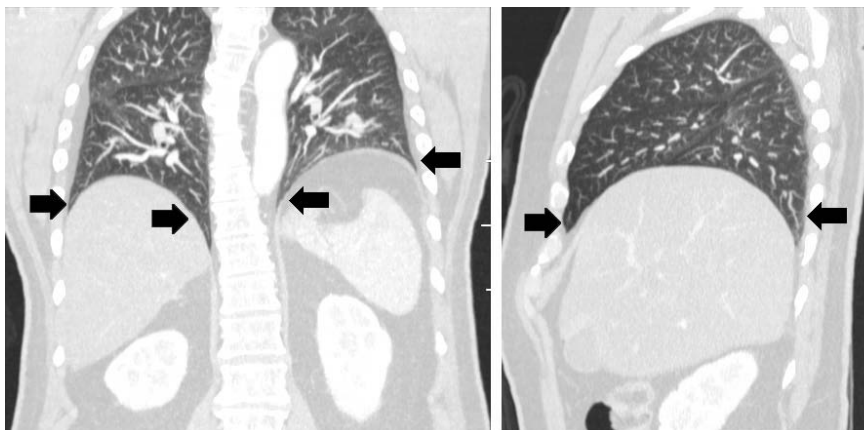


Figure 2.9

Coronal (left) and sagittal (right) reconstructions from CT scanning demonstrating the anatomy of the costophrenic angles (black arrows).

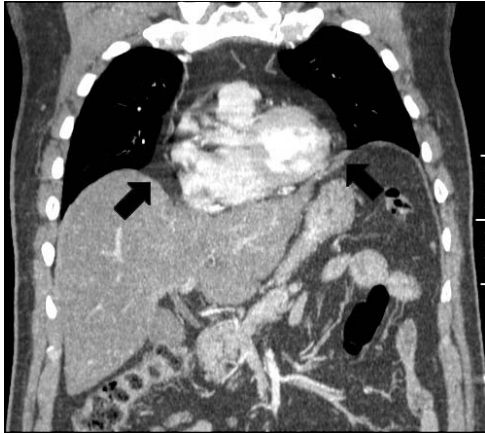

Figure 2.10
Coronal reconstruction from CT scanning demonstrating the anatomy of the cardiophrenic angles (black arrows).

Junctional lines (Fig 2.11)

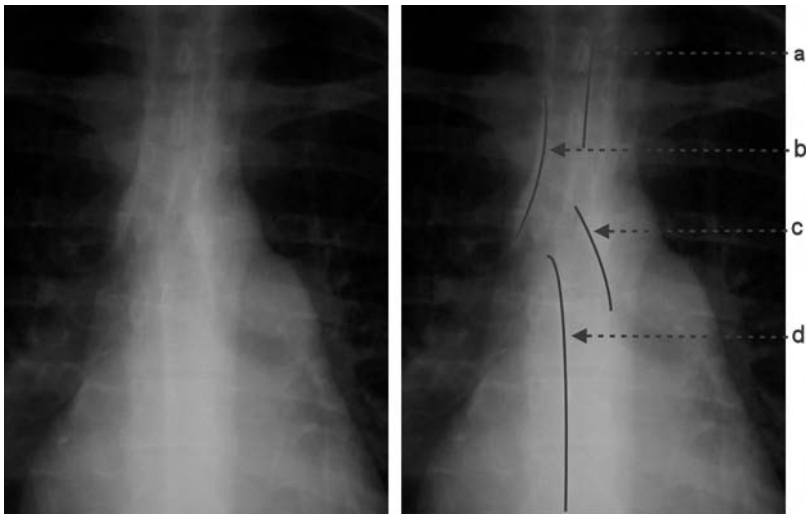


Figure 2.11
Mediastinal lines, **a**- posterior junctional line (where the lungs meet posteriorly-seen superior to the sternal notch), **b**- right paratracheal stripe (normally up to 5 mm with a bulge inferiorly where the azygos vein crosses the right main bronchus), **c**- anterior junctional line (where the lungs meet anteriorly- not present above the sternal notch), **d**- azygo-esophageal line formed where lung lies adjacent to the right margin of the oesophagus and extending up to the point where the azygos vein arches anteriorly over the right main bronchus to drain into the superior caval vein (SVC).

Mediastinal contour (Fig 2.12)

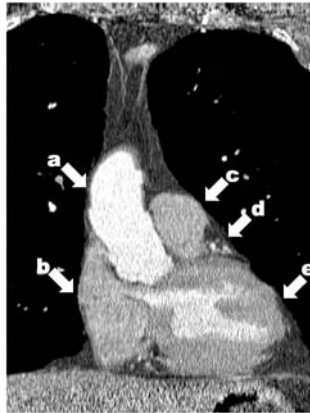
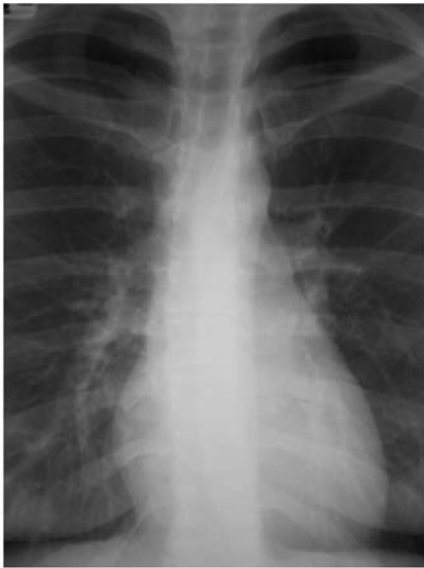
Figure 2.12

Left image shows mediastinal contours, the right image is a coronal reconstruction of the mediastinum from CT scanning; a- aortic outflow tract, b- right atrium, c- pulmonary artery outflow, d- left atrial appendage, e- left ventricle.

Paraspinal lines

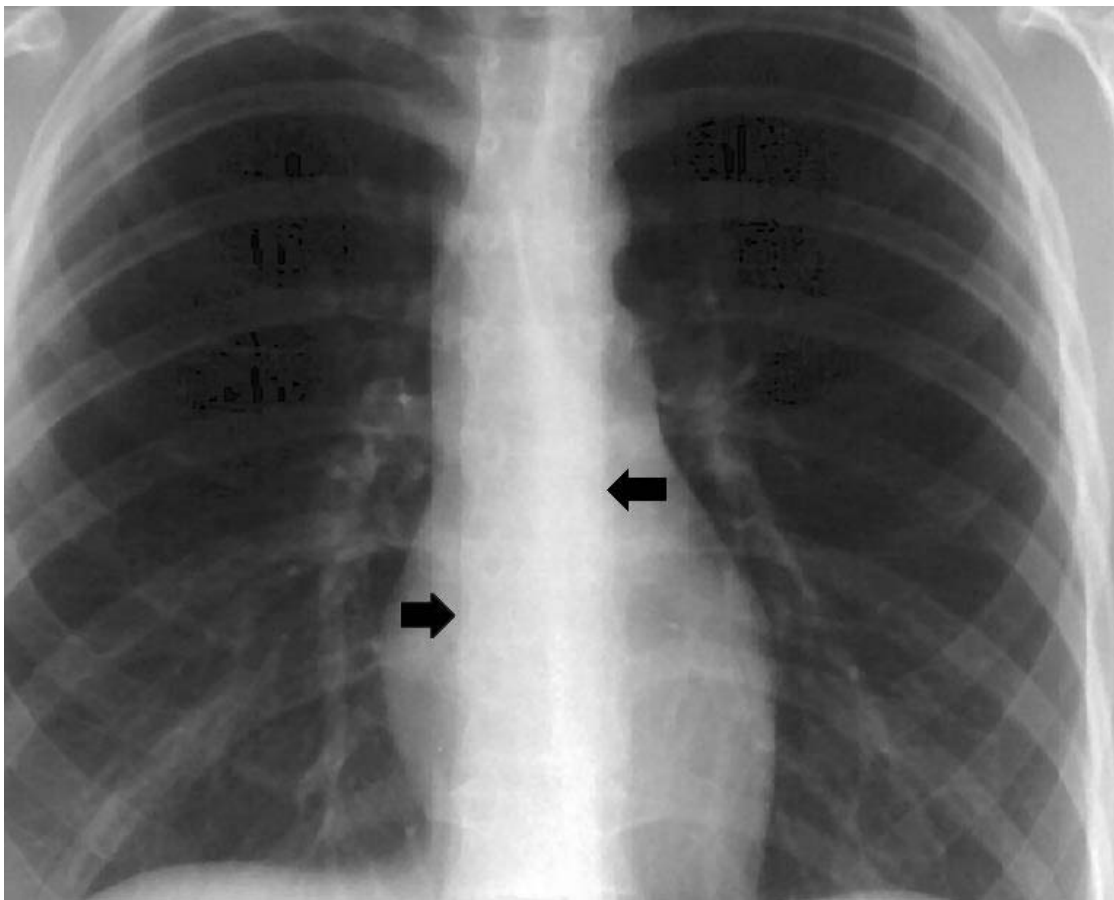


Figure 2.13

The arrows mark the paraspinal lines representing the soft tissue that lies adjacent to the spine. On the right there is very little soft tissue and the line is very close (~2 mm) from the spine. On the left the aorta courses down the anterior left aspect of the spine causing the paraspinal line to be further from the spine. The relevance of these lines is in the detection of paraspinal pathology such as tumours or spinal fracture causing haematoma. Bulging/widening of these lines suggests paraspinal pathology.

The upper abdomen is included on a CXR and the relevant anatomy is described. Upper abdominal pathology may be evident on a CXR (Fig 2.14).

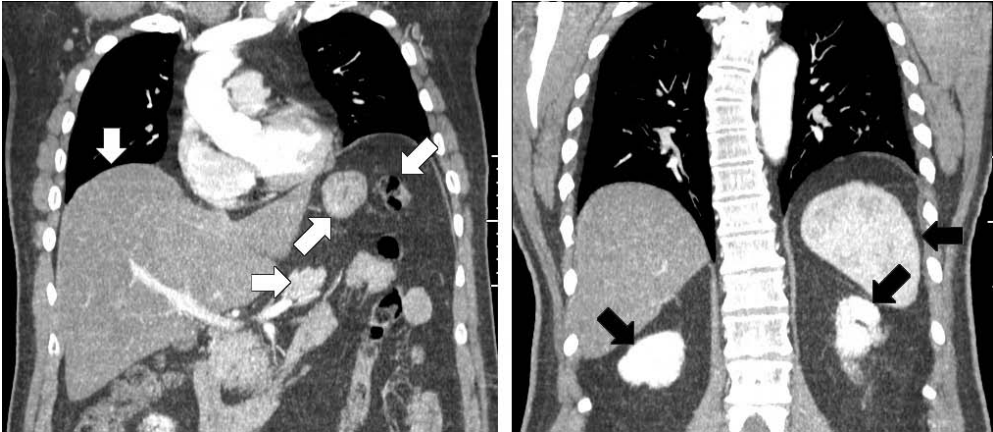


Figure 2.14
Coronal reconstruction from CT imaging demonstrating the abdominal anatomy included on a CXR. Note the liver (white arrow vertical down), the stomach (white arrow diagonally up), the splenic flexure of the colon (white arrow diagonally down), the pancreas (white arrow horizontal), the spleen (black arrow horizontal), the kidneys (black arrows diagonally down).

Normal variants

Accessory fissures (Fig 2.15).

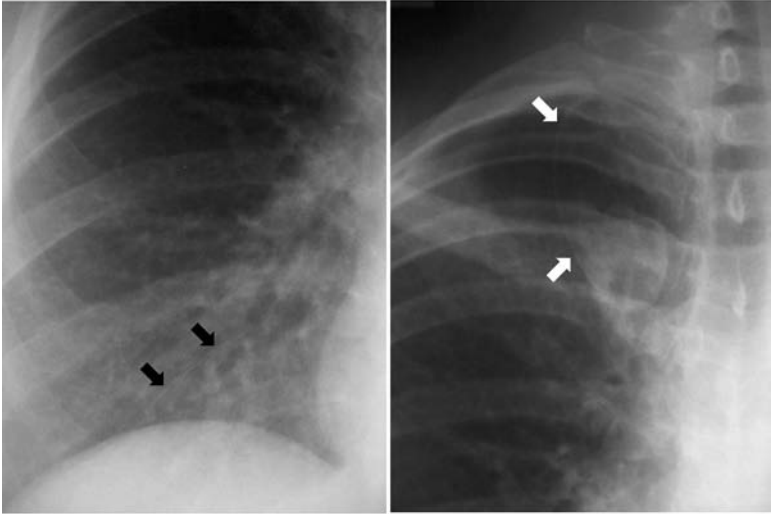


Figure 2.15
Right accessory fissure (black arrows) unlike the minor fissure this does not reach the hilum, azygos fissure (white arrows) formed during the migration of the azygos vein and contains 4 layers of pleura.

Right sided arch (Fig 2.16)

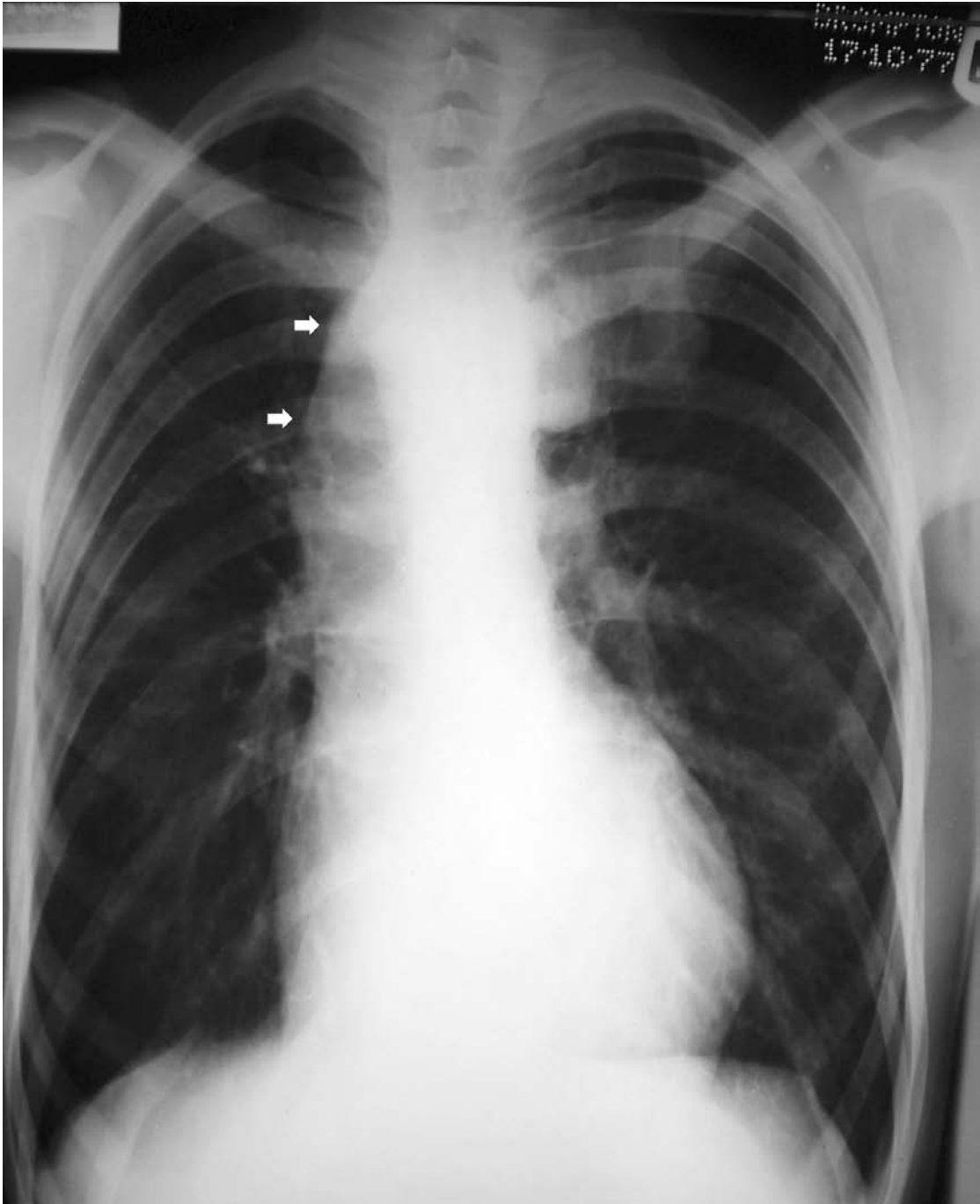

Figure 2.16
Frontal CXR of an adult with a right-sided aortic arch (white arrows). In this case associated with Fallot's tetralogy.

Dextrocardia (Fig 2.17)

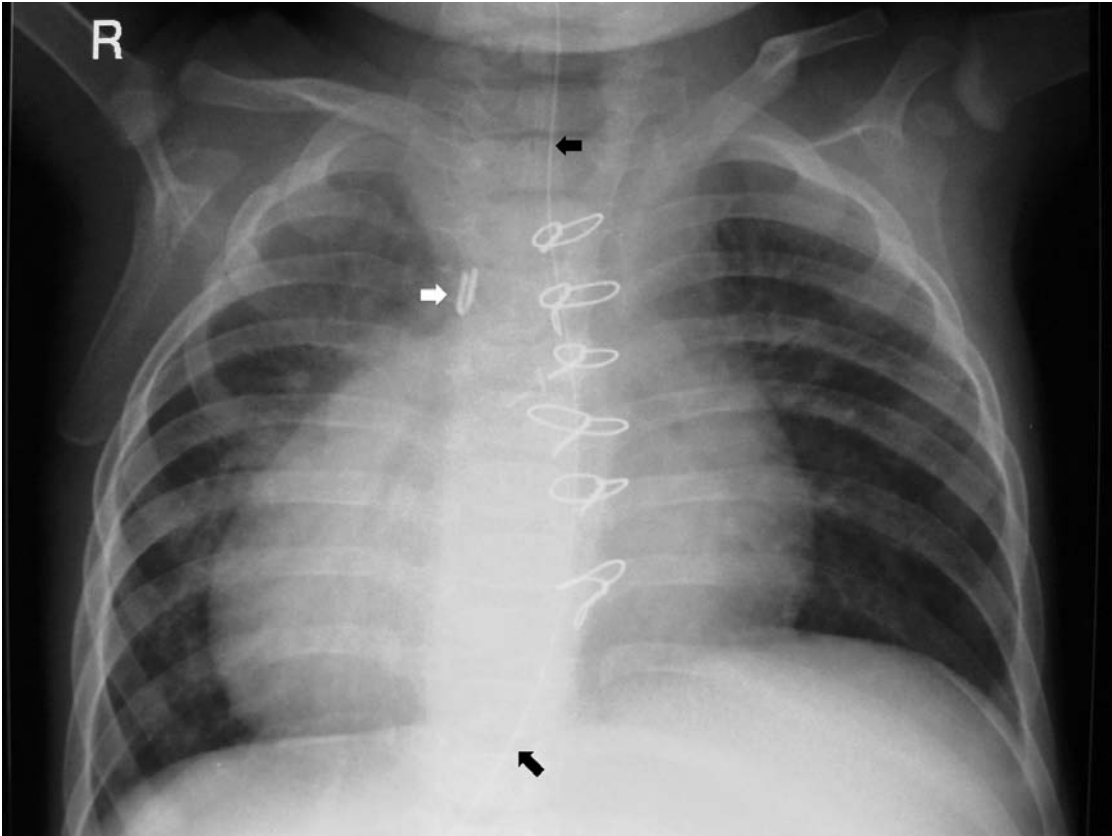


Figure 2.17
A child with dextrocardia and situs invertus (note the NG tube—black arrows), the clip (white arrow) is from repair of a patent ductus arteriosus found on the right in this child as such patients also have a right sided aortic arch.

Cervical ribs (2.18)

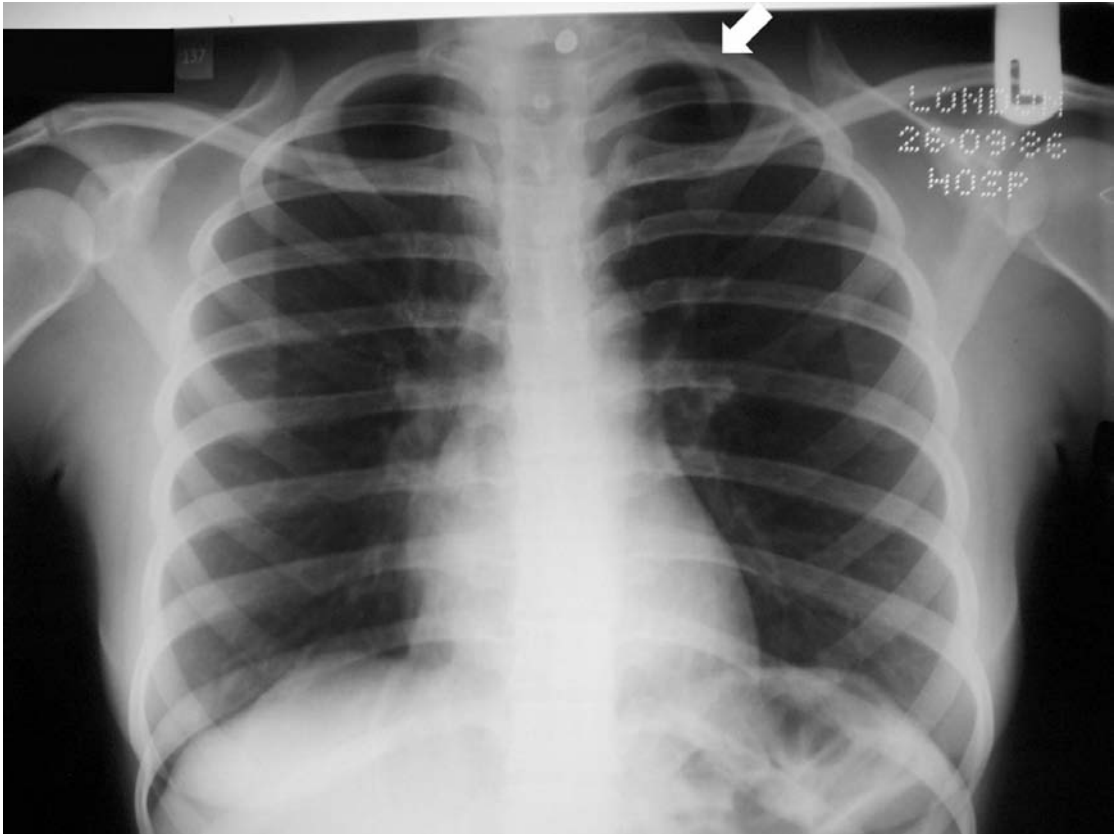


Figure 2.18

Cervical ribs, larger on the left (white arrow) can be distinguished from hypoplastic first ribs as they arise from the C7 vertebral body the transverse processes of which point downwards as opposed to those of the T1 vertebral body that point upwards.

How to read a CXR

- Air absorbs no X-rays and the lung contains mainly air. A deflated adult lung is about the size of a fist.
- Beyond the proximal airways the only structures visible in a normal lung on a CXR are the vessels due to the contrast between blood and air filled lungs; the lung interstitium and the walls of the bronchioles are too fine to be seen.
- Interpretation of the CXR depends to a great extent on determining how the visualization of the vessels has been altered.
- If the vessels are obscured the cause is opacification of the adjacent lung.
- If the vessels are of reduced calibre there is a reduction in blood flow.
- If the vessels are of increased calibre, an increase in blood flow or perhaps pressure may be the reason.
- The absence of vessels in aerated lung suggests lung destruction (e.g. emphysema).
- Spread out normal calibre vessels suggest overexpansion of the lung (e.g. accommodating collapse of another lobe).

The silhouette sign

- When there are tissues of different density next to each other there is a sudden change in the amount of X-rays passing through the body, this results in a sudden change in the density on the resulting X-ray film. In this way a silhouette of the more dense structure is created.



Figure 3.1

The simulated shadow cast by a 3D CT reconstruction of the mediastinum demonstrates the principal behind the silhouette of the mediastinal contours.

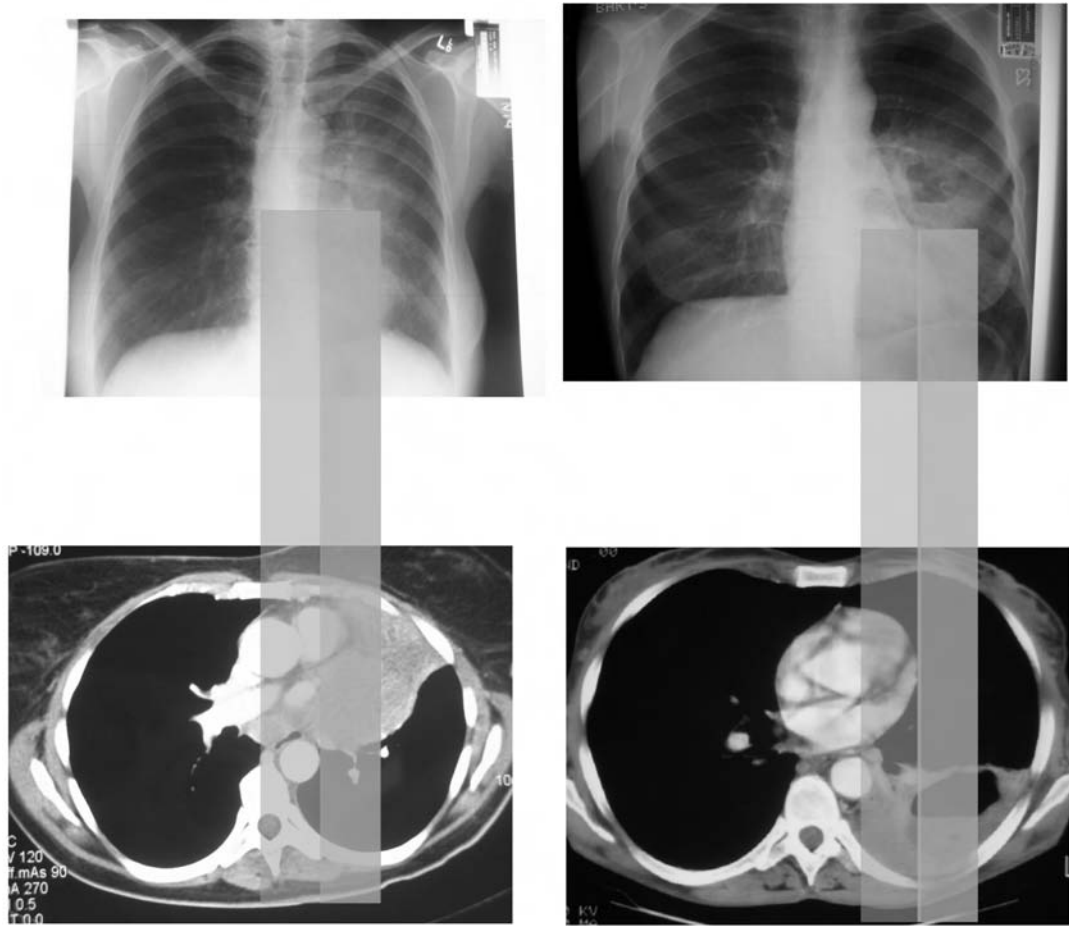


Figure 3.2

The bars depict the intensity of X-rays in relation to the edge of the descending aorta (image on left) and the left heart border (image on right). Note the resulting lines on the CXRs and the fact that these lines are visible overlying the other opacities (left upper lobe collapse—left image, left lower lobe abscess—right image).

- The presence of the silhouette enables the margins of a structure to be seen but, more importantly, the loss of a silhouette that should be visible indicates that the lower density tissue now has a higher density.
- In the lungs, the term silhouette sign refers to interfaces (boundaries) between soft tissue structures and aerated lung. When a silhouette is lost it means that either the lung in that region is no longer aerated, (e.g. consolidation/collapse) or that it has been replaced by different tissues such as a tumour.
- The position of the abnormality causing the loss of the silhouette can be localized if the origin of the silhouette is known, e.g. the aerated right middle lobe creates the silhouette of the right heart border and the lingual that on the left.

Suggested scheme for reading a frontal CXR

- Everyone should develop a scheme for reading the CXR. As there are many overlapping structures, many possible pathologies and significant blind spots, a thorough strategy is essential and with practice can be performed surprisingly quickly.
- We outline one strategy and explain the reasoning behind it. It highlights the areas of the CXR that require particular scrutiny and those that are often overlooked.
- As soon as a CXR is viewed a snapshot decision as to whether the film is normal or abnormal is made. If an abnormality is missed during this snapshot, it has in all likelihood been seen but incorrectly interpreted. All of this has happened in a few seconds and is not under conscious control.

- The eye is readily deceived and a CXR should be approached with as few preconceptions as possible.
- Even if a snapshot impression identifies an abnormality, other abnormalities may have been missed and the interpretation of a CXR should still be approached systematically.
- The following scheme covers the film but is not dependent on anatomical boundaries. You may develop your own scheme, but bear in mind the potential pitfalls detailed here.
- Check the name and date of the film.
- Check the film the correct way round (side marker).
- Is the film PA or AP (see earlier).
- Is the subject, erect, semi-erect or supine.

Begin in the top left hand corner of the film (patients right shoulder).

A. Scan from left to right

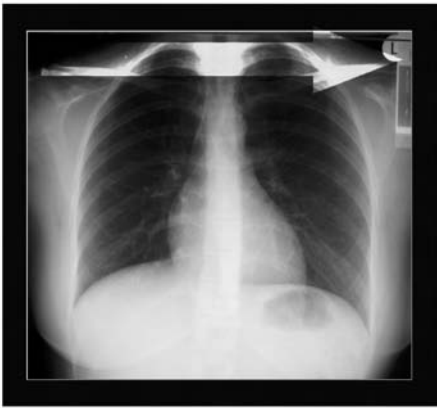

Figure 3.3

Check the soft tissues and bones of the shoulder girdle (clavicles, scapulae) and neck. Are there any bony lesions (fractures, deposits, cervical ribs, joint abnormalities, etc), soft tissue masses and is the trachea normal (position, calibre)? Compare the apices of the lung. Are they of the same density?

B. Return to the top left hand corner repeating the above observations.

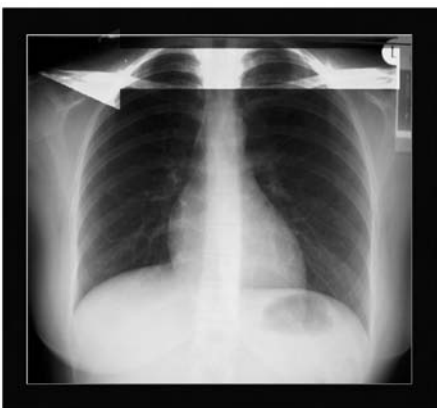

Figure 3.4

C. Scan from top left to bottom left

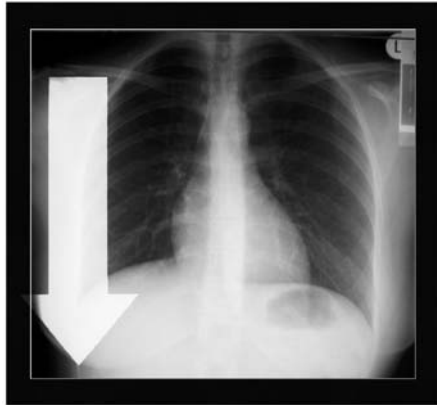


Figure 3.5

Check the soft tissues of the chest wall, the lateral aspect of the ribs, the peripheral lung, pleura and costophrenic angle.

D. Move to the mid right diaphragm and scan up to the right apex

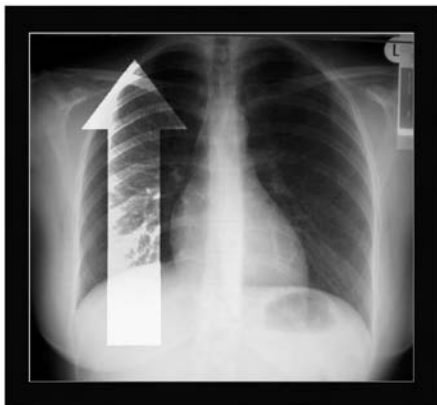


Figure 3.6

Check behind the diaphragm, there is enough space here to "hide" a 7–8 cm tumour. Observe the parenchyma of the right lung. Are the vessels visible and of normal calibre? If the vessels are obscured this suggests abnormal opacity in the adjacent lung.

E. From the right apex scan down the right mediastinal contour

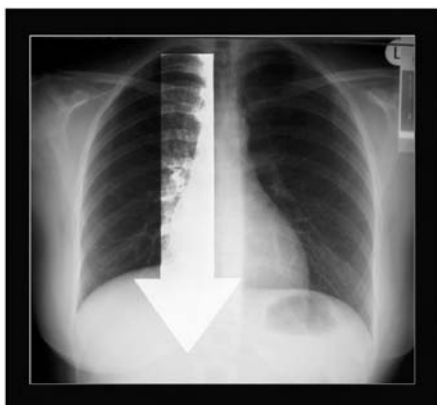


Figure 3.7

The right paratracheal stripe should be visible. Is the mediastinal contour visible? Check the position of the hilar point, which should be at the level of the lateral extent of the right 6th rib. End at the right cardiophrenic angle, the inferior vena cava lies here.

F. Scan up the centre of the film

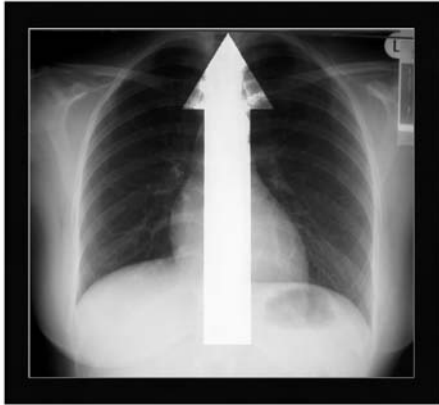


Figure 3.8

Note the structures that should be visible behind the heart, particularly the spine, paraspinal region and azygo-oesophageal line (often overlooked). Is the mediastinum central, the carina normal, the trachea normal in position and calibre?

G. Scan down the left mediastinal contour

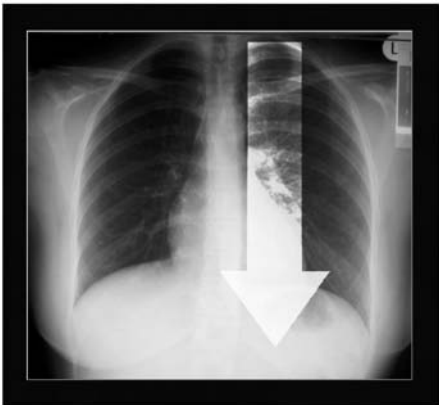


Figure 3.9

The aortic knuckle, aorto-pulmonary window, the left hilar point (slightly higher than the right hilar point) and the left contour of the heart (pulmonary outflow tract), left atrial appendage and left ventricle. End at the left cardiophrenic angle.

H. Now move to the mid left hemidiaphragm. The gastric fundus and the spleen are under the diaphragm.

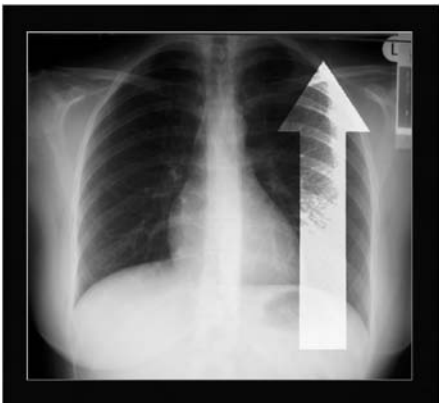

Figure 3.10

Scan up the film looking at the lung parenchyma ending in the left apex.

I. Move to the left shoulder and scan down the left periphery of the chest

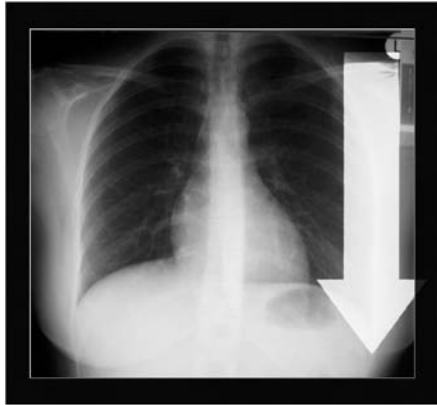


Figure 3.11

Concentrate on the peripheral lung, ribs and soft tissues of the chest wall.

J. Finally, compare the lung parenchyma left to right in the upper, mid and lower zones

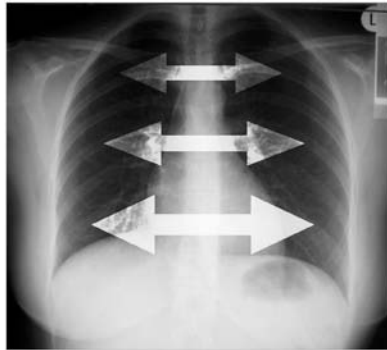


Figure 3.12

This scheme is easy to follow and includes the main areas in which abnormalities are missed.

Review areas

The review areas are those parts of the CXR in which an abnormality can easily be overlooked and therefore require particular attention (Fig 3.13).

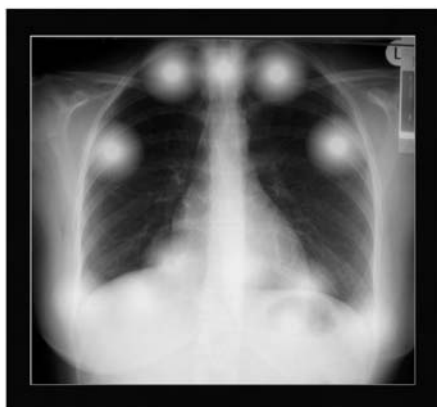

Figure 3.13

The review areas.

The apices

- At the apices of the lung there is little lung parenchyma compared to the amount of overlying soft tissue and bone.
- The anterior part of the first rib overlies the posterior parts of the first 3 to 4 ribs and all these relatively dense structures contribute to an overall increased opacity in the apex at the expense of definition of the lung parenchyma.
- At the extreme apex, it is not unusual to have a “cap” of pleural thickening that is of no clinical significance.
- The best way to approach the apices is by comparing the two sides. Is there a difference in opacity and if so, can this be explained by the overlying ribs?
- If not, then some parenchymal abnormality should be suspected and in the first instance, a lordotic view should be performed (Fig 3.14).

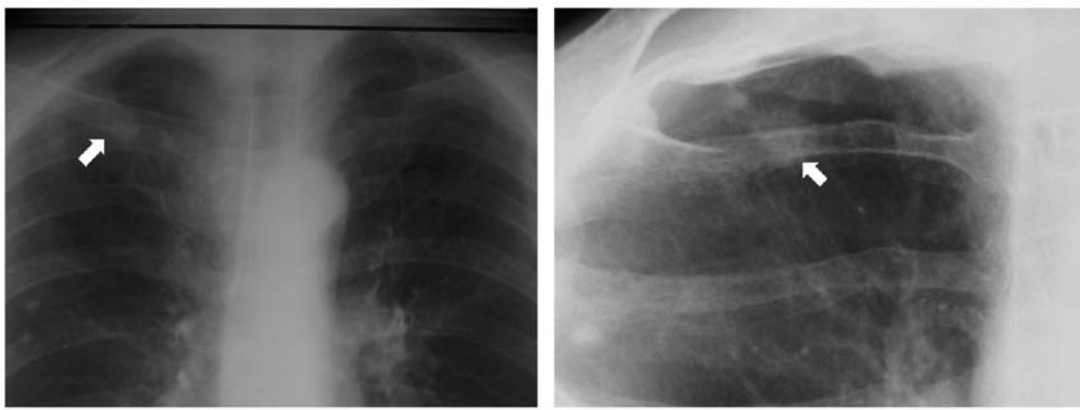


Figure 3.14

On the left image there is increased density in the right apex (white arrow) but this may be due to overlap of anterior 1st rib, clavicle and posterior 4th rib. The lordotic view (right image) projects the 1st rib and clavicle off the chest revealing the underlying nodule (white arrow), a carcinoma that was subsequently resected.

The thoracic inlet

- This is a review area because it is easily overlooked.
- The trachea dominates the thoracic inlet; the other structures in this area are the vessels arising from the aortic arch and the veins feeding into the superior vena cava.
- Abnormalities in the thoracic inlet are usually due to extra soft tissue such as lymphadenopathy or thyroid enlargement or intrinsic abnormality (narrowing or dilatation) of the trachea (Figs 3.15, 3.16).

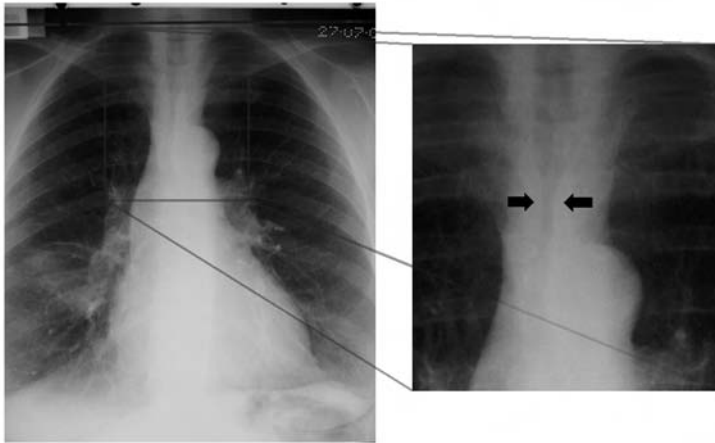


Figure 3.15
Frontal CXR on the left, on the right is a magnified view of the upper mediastinum. Note the tracheal stenosis secondary to prolonged intubation (black arrows).

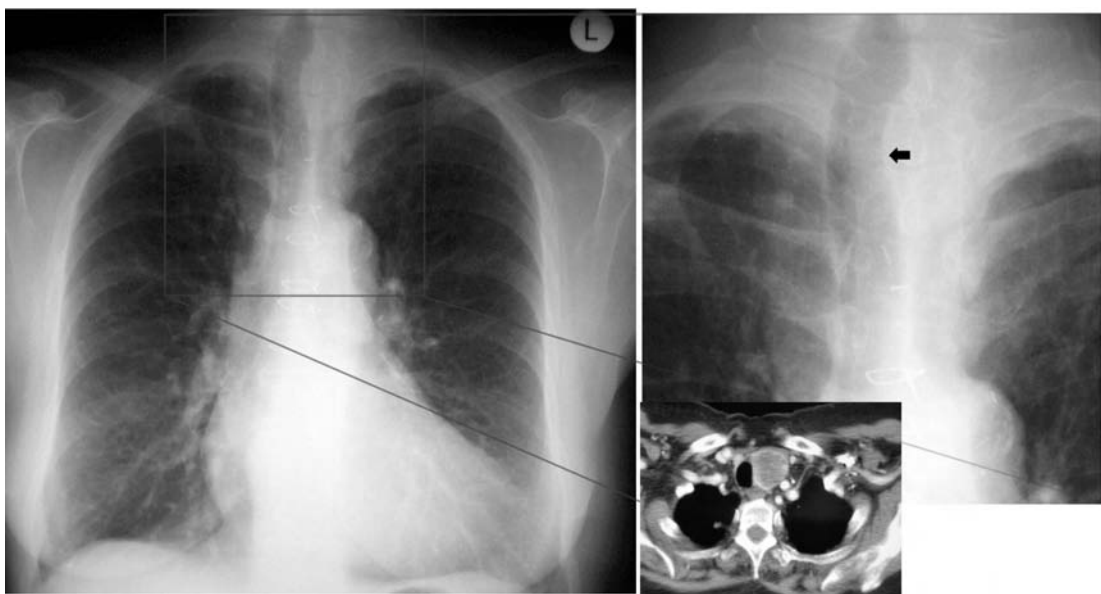


Figure 3.16
Frontal CXR of an adult female with a goitre. Note the deviation of the trachea (black arrow) marked on the magnified view. The CT image shows the enlarged left thyroid lobe causing deviation of the trachea.

Overlying the scapulae

- The region of lung overlying the scapula appears to be of slightly increased density, therefore subtle density changes such as soft tissue nodules unrelated to the scapulae could be overlooked (Fig 3.17).

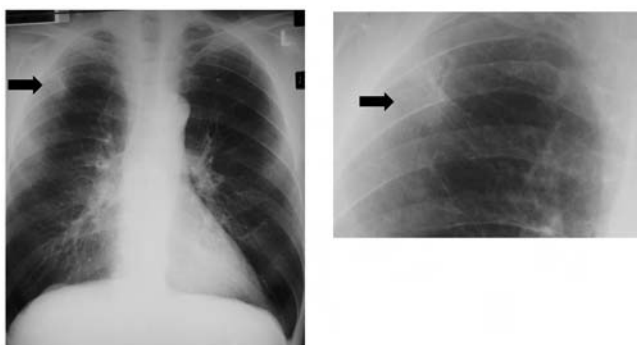


Figure 3.17
Frontal CXR demonstrates a soft tissue nodule (black arrow) projected over the medial border of the right scapula which can easily be overlooked.

Costophrenic angles

- The costophrenic angle should be “sharp”, i.e. the diaphragm should form an acute angle with the chest wall.
- “Blunting” of the costophrenic angle, indicates that there is soft tissue or fluid where the lowest limits of the lung should be. Usually this is due to pleural fluid or thickening (3.18).

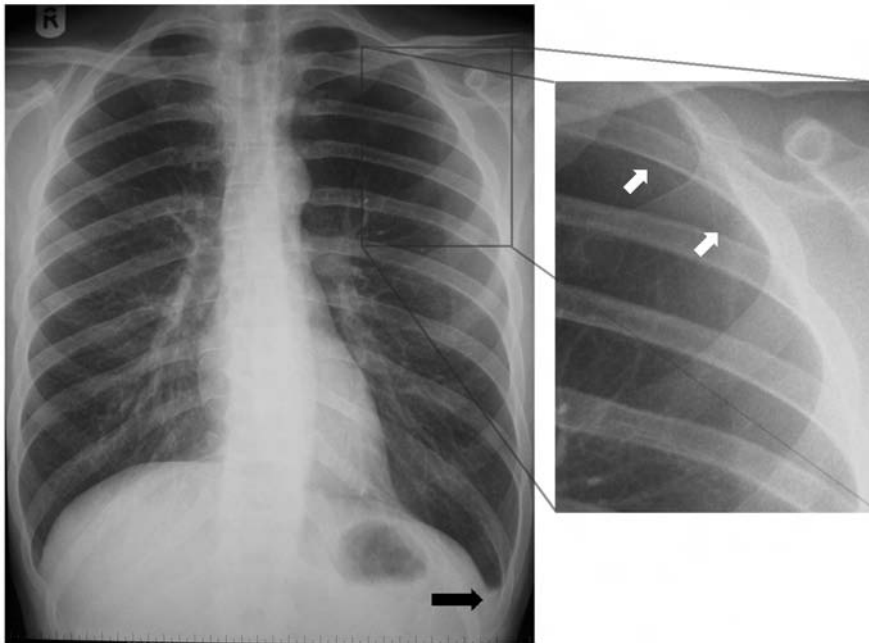


Figure 3.18

Blunting of the left costophrenic angle in a young man with a “long” chest indicates the possibility of a spontaneous pneumothorax. The subtle lung edge (white arrows) is marked on the magnified image.

- Septal lines (“Kerly B lines”) are best seen at the costophrenic angles and are easily overlooked; they indicate interstitial lung infiltrates, usually due to heart failure, but also consider lymphangitis carcinomatosa (see pattern recognition>lines).

Under the hemidiaphragms

- Lung lesions lying posteriorly in the lung bases are projected beneath the hemidiaphragms and may prove very difficult to see (Fig 3.19).

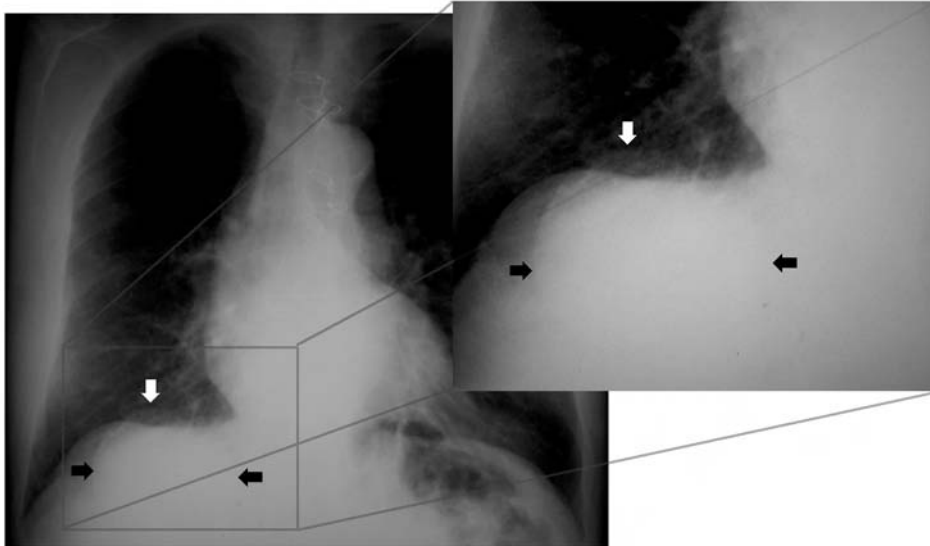


Figure 3.19
A large (7 cm) mass is sited posteriorly in the right lower lobe projected behind the right hemidiaphragm (margins marked by arrows).

- The liver lies under the right hemidiaphragm. Therefore lucency beneath this hemidiaphragm suggests the presence of free gas within the abdomen.
- The colon may interpose between the liver and the diaphragm mimicking free gas, but sharp medial and lateral extremities to the gas shadow would favour free gas, as that found within a tubular structure such as the colon, will not form these sharp margins (Fig 3.20).

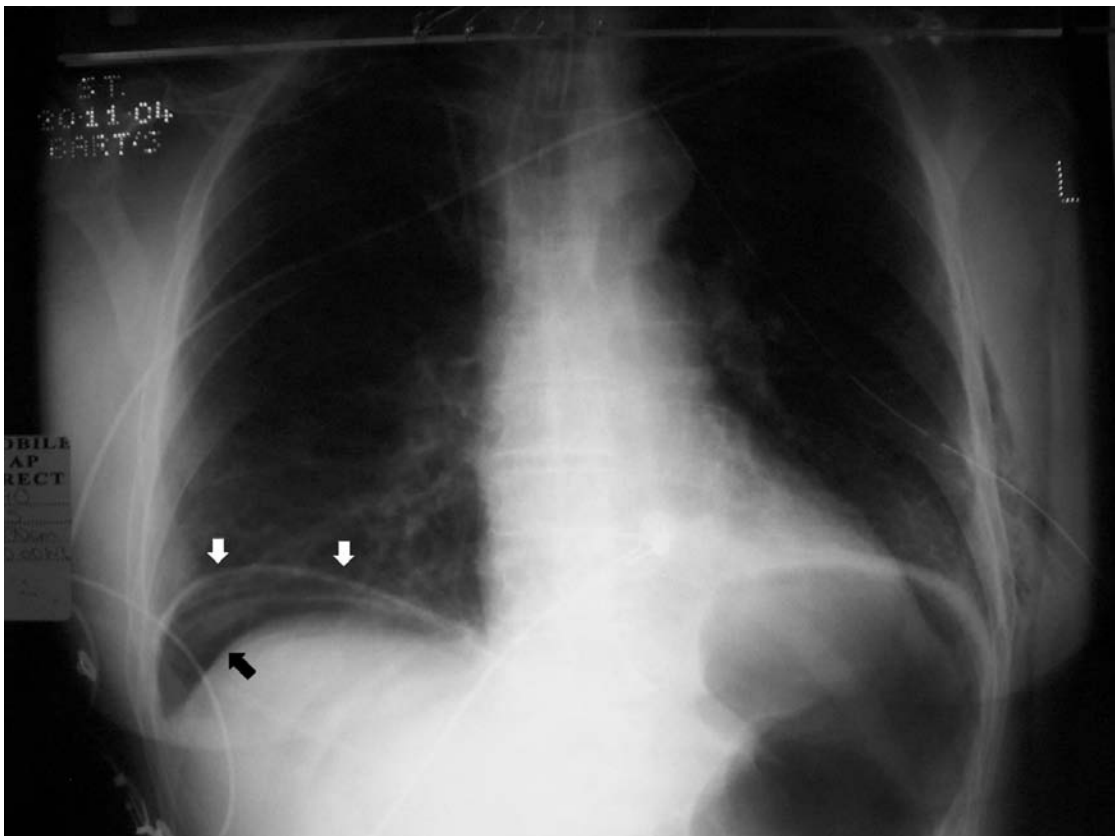


Figure 3.20
Frontal CXR of a post-operative patient. Note the visibility of both sides of the right hemidiaphragm (white arrows) due to free gas in the abdomen. As a result, the superior surface of the liver is visible (black arrow).

- On the left, the normally air filled gastric fundus lies beneath the diaphragm.
- If there is free gas on the left, only the diaphragm, about 3–4 mm thick, separates the free gas from the lung. Air in the gastric fundus is separated from the lung by the diaphragm and the gastric wall.
- Again, sharp margins to the gas shadow increase the likelihood of free gas.
- If uncertainty remains, a lateral decubitus AXR view should resolve the issue, as the free gas will travel to the least dependent area, i.e. the upper most lateral margin of the abdomen.

Behind the heart

- A well taken CXR will demonstrate the thoracic spine projected through the cardiac shadow. A “soft” or underexposed film where the spine is not visible should be read with caution as a significant portion of the thorax has not been adequately visualized.
- Abnormalities of the thoracic spine may be apparent, there may be masses or swelling related to the paraspinal lines (see anatomy).
- The descending aorta is projected behind the heart and the left edge of this should be visible.
- A hiatus hernia or oesophageal dilatation will be projected behind the heart and often contains gas (Fig 3.21).

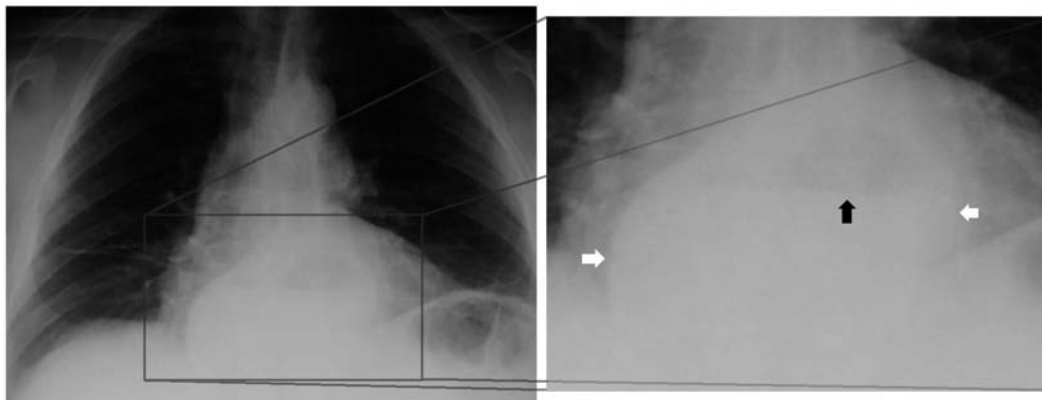


Figure 3.21

Hiatus hernia. Note on the magnified image the lateral margins of the hernia (white arrows) and the air fluid level (black arrow).

- The azygo-oesophageal line should be identified. An abnormal contour suggests a mediastinal mass, usually lymphadenopathy but also consider oesophageal pathology (Fig 3.22).

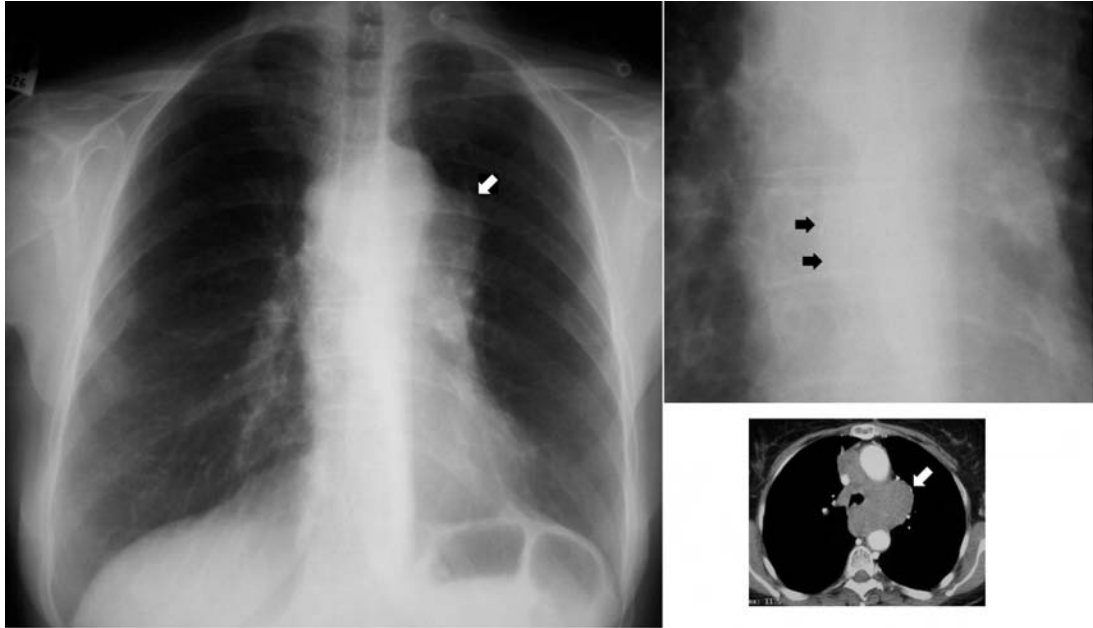


Figure 3.22

Frontal CXR of an adult female with lymphoma. Note the soft tissue mass in the aorto-pulmonary window (white arrow) also seen on the CT image (inset) and the bulging of the azygo-oesophageal line (black arrows) due to subcarinal lymphadenopathy.

- Left lower lobe collapse partially hidden behind the heart is often overlooked (Fig 3.23).

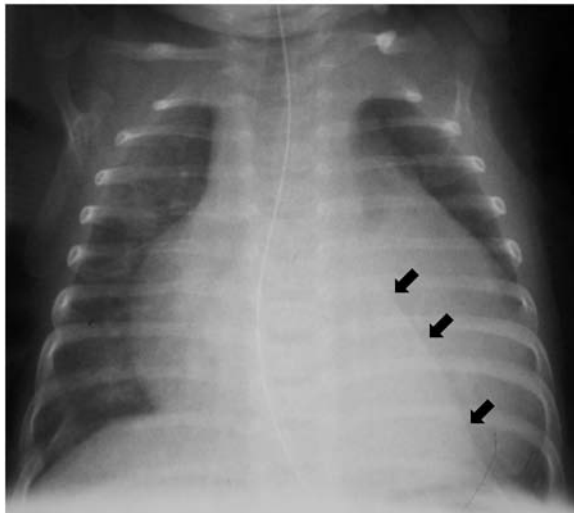


Figure 3.23

CXR of an infant demonstrates left lower lobe collapse. The lateral margin of the lobe is marked (arrows). Note the increased density behind the heart and the loss of the medial portion of the left hemidiaphragmatic silhouette.

The cardiophrenic angles

- A poorly defined opacity is often seen at the cardiophrenic angles due to pericardial fat pads.
- Abnormal soft tissue in the region is readily overlooked.
- A pericardial fat pad will not be separable from the cardiac outline, and being composed of fat, it should be of low density.
- The margins of the pericardial fat pad are usually indistinct, if at all discernable, such that opacity in the cardiophrenic angle with defined margins is unlikely to represent pericardial fat (Fig 3.24).

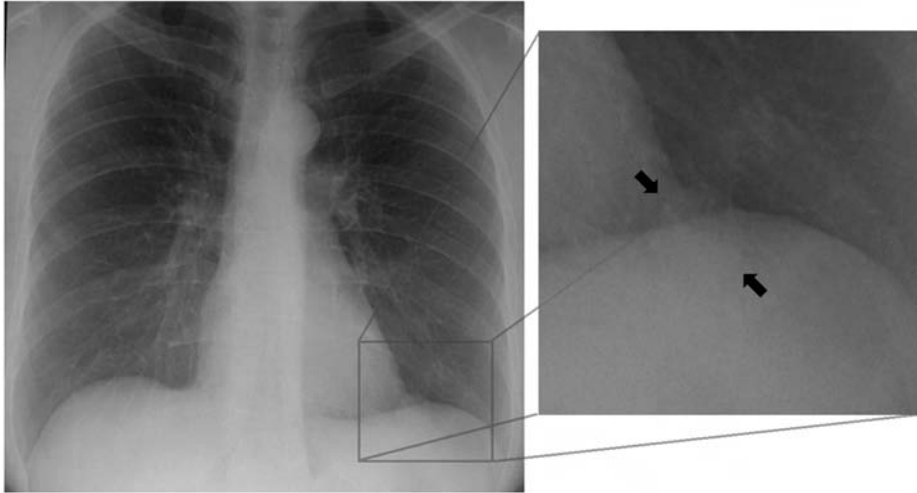


Figure 3.24
A 2 cm carcinoma projected over the left cardiophrenic angle. The margins of the nodule are marked by arrows in the magnified view.

Pitfalls

Pseudo-pneumothorax

- Folds in the skin can trap air creating a soft tissue/air interface and thus a line on the CXR which can mimic the lung edge of a pneumothorax.
- This is usually seen on AP films taken with the patient lying against the X-ray cassette.
- The key points are that there will be lung markings beyond the assumed lung edge and the line will cease more abruptly than a lung edge would (Fig 3.25).

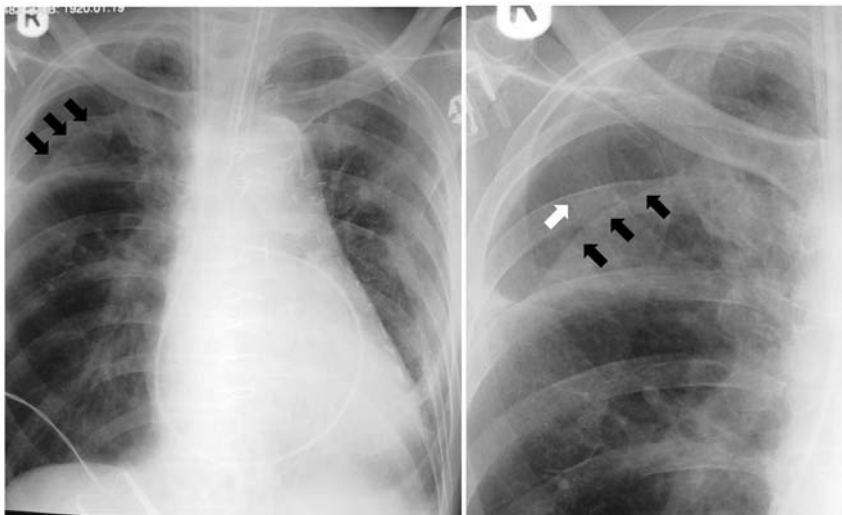


Figure 3.25
CXR taken in intensive care unit. Note endotracheal tube, internal jugular line, Swann Gantz catheter and a balloon pump in the aorta. An apparent lung edge is marked (black arrows) but careful scrutiny reveals lung markings beyond this edge (white arrow). The edge is formed by a fold of skin on the patients back as the patient is sitting semi-erect and the film cassette is against his back.

Patient rotation

- A correctly centred CXR will project the spinous processes of the thoracic spine mid way between the medial ends of the clavicles.
- As the clavicles are anterior structures and the spinous processes are posterior structures, any rotation of the patient, i.e. to the left or right, will result in the movement of the clavicles in relation to the spinous processes.
- As a result the projected distances between the medial ends of the clavicle and the spinous process will increase on the side to which the patient is rotated (Fig 3.26).

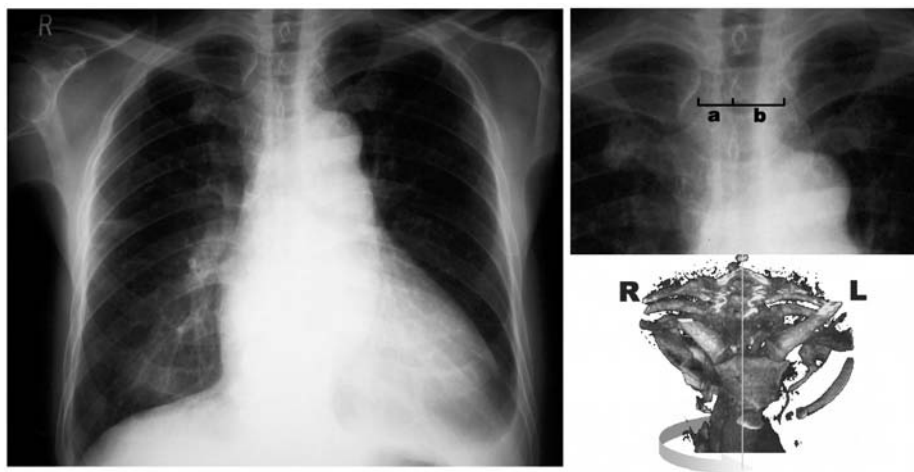


Figure 3.26

Frontal CXR with subject rotated to the left. Note an enlarged heart and small left pleural effusion. The left hemithorax is darker than the right due to the rotation. Note the distance between the medial end of the right clavicle and the spinous process of T2 (distance **a**) is less than the distance between the spinous process and the medial end of the left clavicle (distance **b**) indicating rotation to the left as demonstrated in the 3D reconstruction.

- Rotation may cause an increase in the transradiancy (blackness) of the lung on the side to which the patient is rotated, which should be taken into account when reading the film.
- Rotation will also alter the relative appearance on the hila and can mimic hilar asymmetry and the projection of the sternum over the hilum may be evident (Fig 3.27).

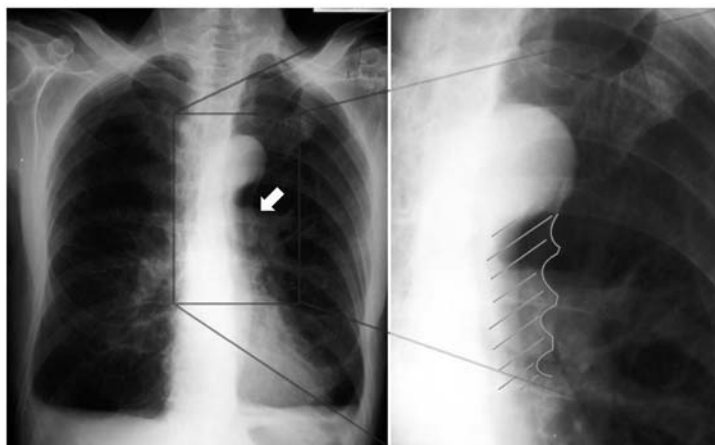


Figure 3.27

The subject is rotated to the left and as a result the sternum is projected over the left mediastinal contour (white arrow). The sternum is outlined on the magnified view.

Poor inspiration

- If there are less than 6 anterior ribs projected above the hemidiaphragms then the film has been taken with a poor inspiratory effort.
- The lower zone vessels become crowded and there is an overall increase in lower zone opacity.
- The hila are compressed and appear more bulky (Fig 3.28).

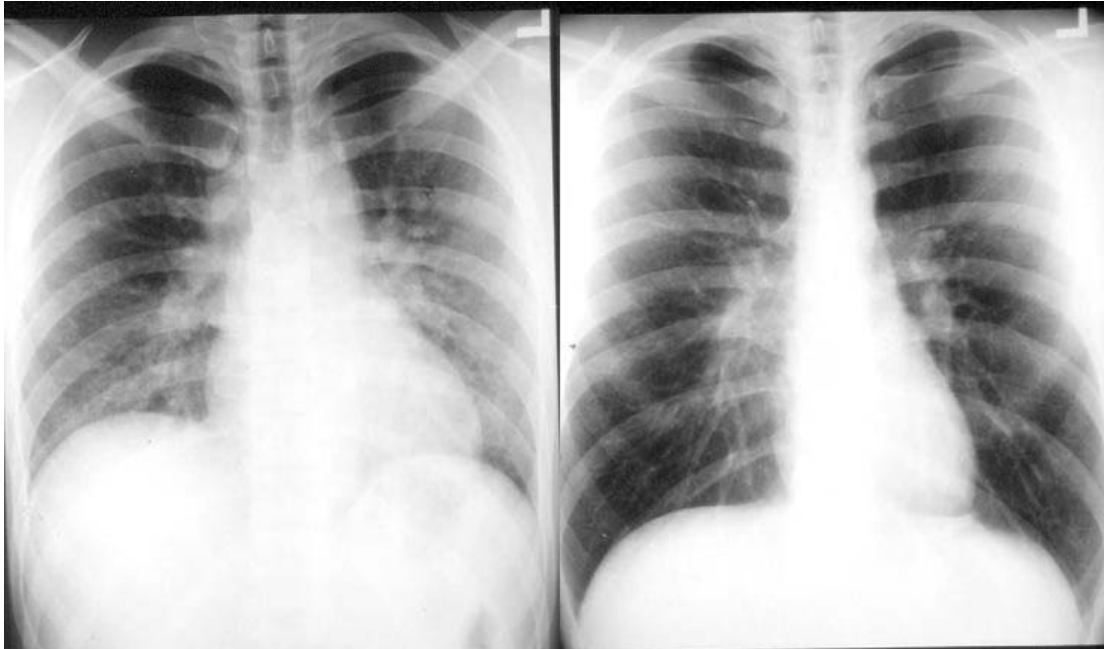


Figure 3.28

Two frontal CXRs of the same patient taken on the same day. For the CXR on the left the patient has made a poor inspiratory effort. Note the apparent bulkiness of the hila, increased density in the lower zones and the enlarged cardiac silhouette. The CXR on the right taken in full inspiration demonstrates that the patient's CXR is normal and previous apparent abnormalities were due to poor inspiratory effort (images courtesy of D M Hansell).

Nipple shadows

- When seen as symmetrical, nipple shadows rarely cause diagnostic difficulties.
- It is not uncommon that only one nipple is evident on a CXR.
- Features that suggest a shadow is due to a nipple are a position appropriate to the breast shadow and well-defined margins on only two sides usually inferior and lateral (Fig 3.29).

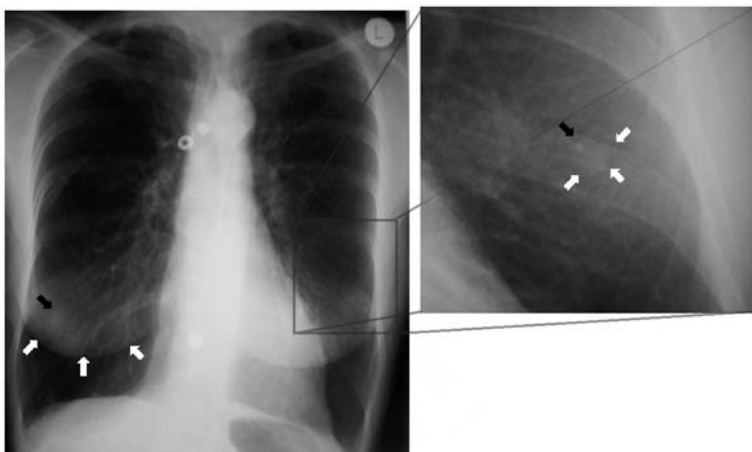


Figure 3.29

Left image-right nipple shadow marked (black arrow). Note relative position to right breast margin (white arrows). Right image is a magnified view of the left nipple shadow (white arrows). Note the indistinct superior medial margin (black arrow).

- If uncertainty remains, a repeat film with the nipples marked by something radio-opaque will resolve the issue (Fig 3.30).

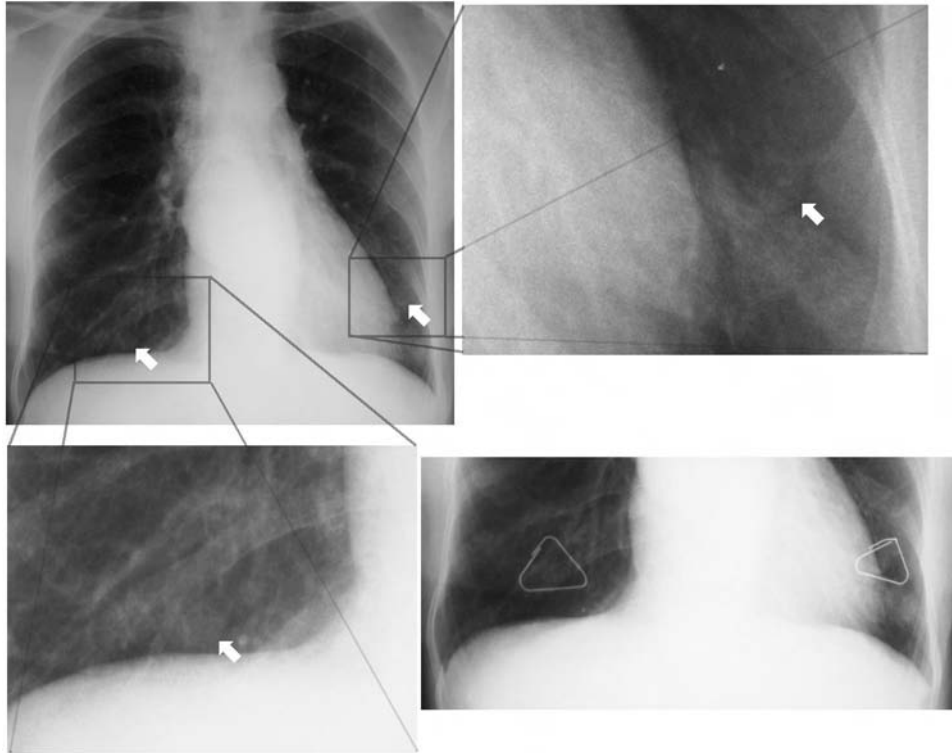


Figure 3.30

Top left image is a frontal chest radiograph, 2 areas magnified demonstrate possible nodules, the asymmetry on this image raises the possibility that at least one of the shadows represents a nodule. A repeat film bottom right with nipple markers resolves the issue demonstrating that both are nipples.

Pulmonary venous confluence

- Sometimes the pulmonary veins draining the right lung combine prior to entering the left atrium.
- The result is opacity visible behind the right side of the heart mimicking a mass (Fig 3.31).

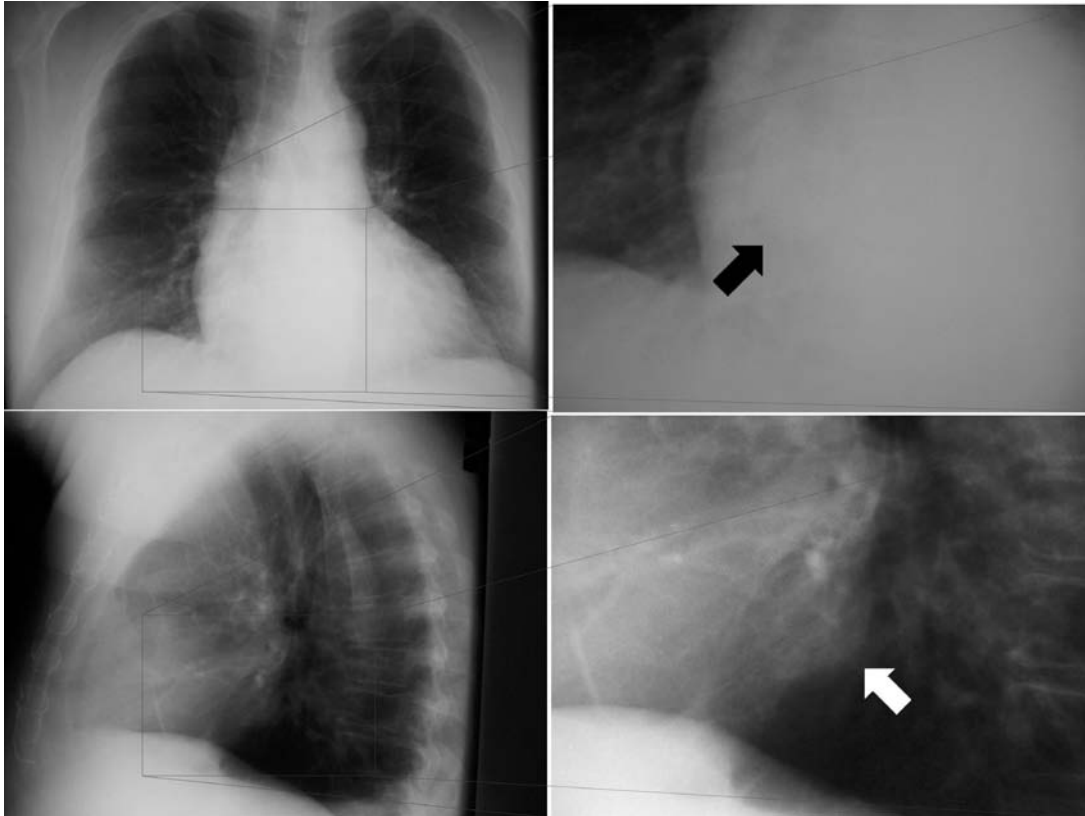


Figure 3.31

Frontal and lateral CXR of an adult male. The pulmonary venous confluence mimics a mass behind the right heart (white and black arrows).

- The clues to its identity are the absence of a medial margin, confluence with the left atrium and the draining pulmonary veins.
- Nevertheless the appearance can be quite compelling and a lateral CXR should help resolve the issue.

The azygos lobe

- During embryological development, the azygos vein may course through the upper developing lung on its way to taking its position, arching over the right main bronchus into the superior vena cava.
- A fold of pleura, azygos fissure, accompanies the vein and creates the azygos lobe as part of the upper lobe, which may have its own bronchus.
- The azygos fissure runs a curved course from the azygos knob to the apex and should not be confused with pathology.
- Pathology may be confined to the azygos lobe causing opacity with a very well defined lateral margin, which could easily be confused with right upper lobe collapse (Fig 3.32).

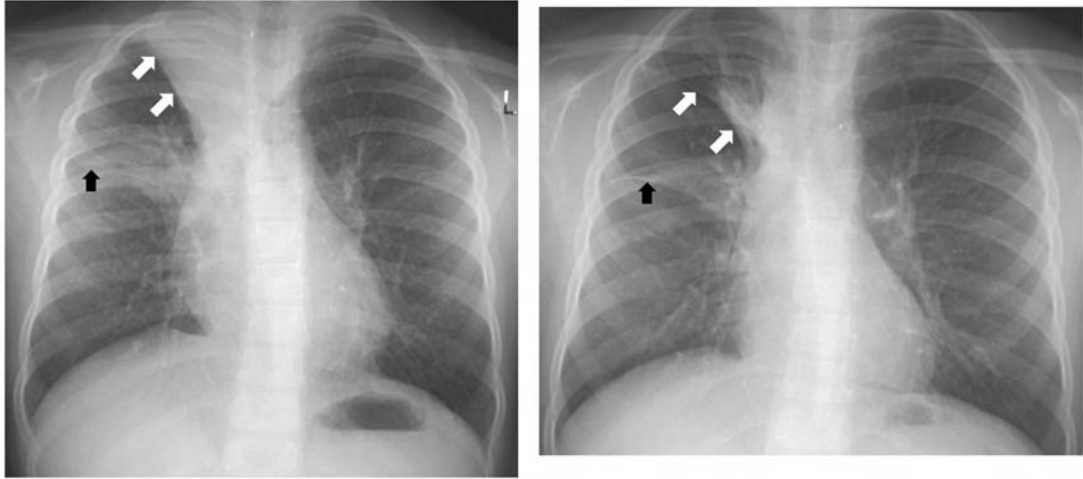


Figure 3.32

Left image shows opacity in the right apex with a well defined lower border (white arrows). This could easily be mistaken for a collapse right upper lobe but the minor fissure (black arrow) is visible. The left image follows bronchoscopic removal of a mucous plug in the airway leading to an azygos lobe. The azygos fissure (white arrows) and minor fissure (black arrow) are marked.

The manubrium sterni

- If the patient is slightly rotated, particularly to the right, the lateral margin of the manubrium becomes visible and may appear to represent para-tracheal lymphadenopathy.
- The appearances when carefully observed will reflect a well defined angular edge of appropriate shape (Fig 3.33).

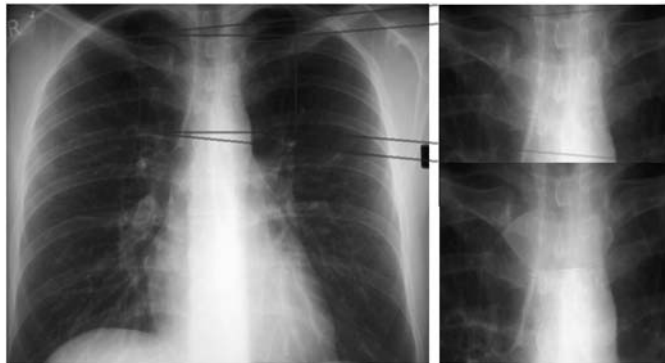


Figure 3.33

Left image suggests possible right paratracheal mass. The right images demonstrate the outline of the manubrium causing this appearance.

Artifacts

In general surface artefacts can be identified for what they are by careful scrutiny. However, if doubt remains a repeat film with all possible artefactual objects removed should resolve the issue.

Buttons

- When solitary, buttons can look convincingly like nodules particularly due to the soft tissue density they mimic.
- The presence of other nodules elsewhere of exactly the same size or outside the lung parenchyma are useful clues and most buttons will have discernable holes in a regular pattern (Fig 3.34).

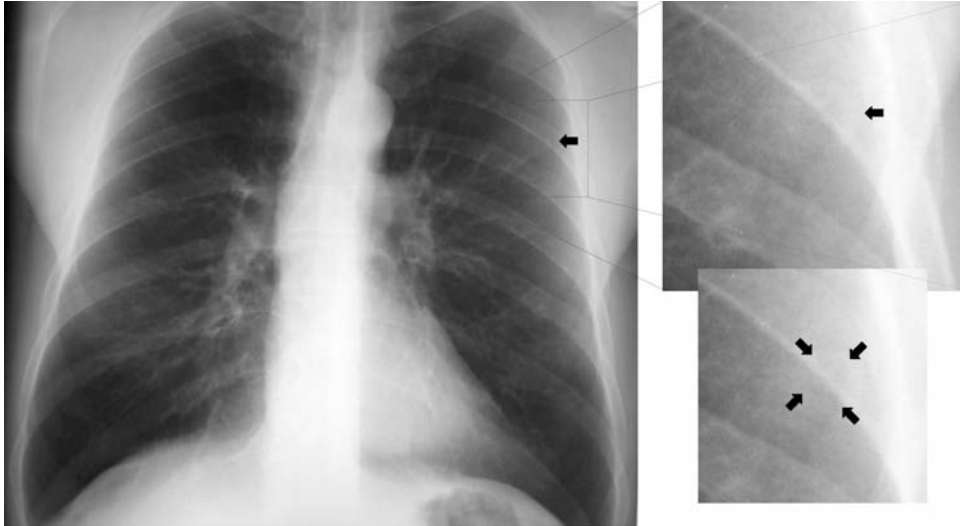


Figure 3.34
 Frontal CXR of an adult male with an apparent nodule in the left upper/mid zone (horizontal black arrows). On closer inspection, the regular shape of this “nodule” and the presence of four equally spaced holes (diagonal black arrows) confirms that this is a button.

ECG tabs

- Commonly left on the patient’s chest for days on end, these artefacts can appear to be consistent over a series of films and have a disconcerting soft tissue density appearance.
- As for buttons the appearance of these outside the lung is a useful clue and the well-defined curved corners are characteristic.
- Again, repeat film with tabs removed would resolve the issue (Fig 3.35).

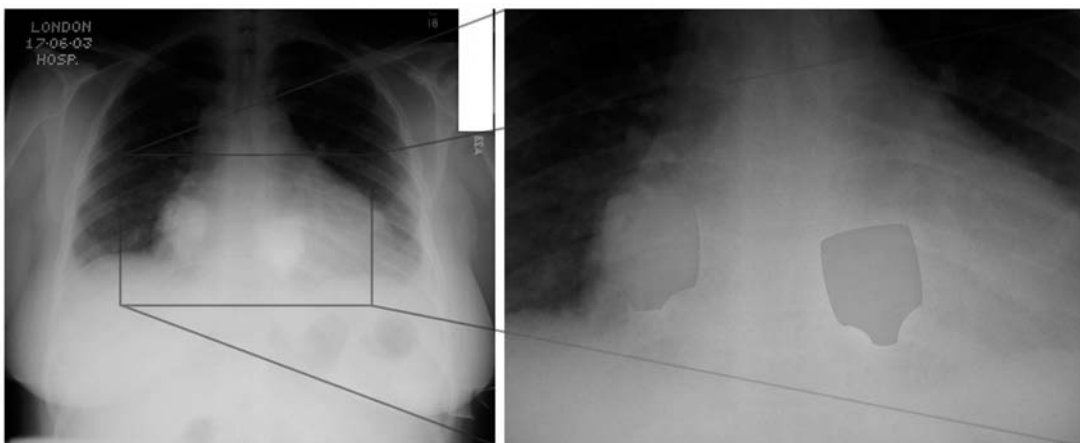


Figure 3.35
 Left image suggests 2 large soft tissue masses, the magnified image on the right shows these to be ECG tabs.

Hair braids

- When multiple, hair braids do not pose a diagnostic problem but single braids that are short or folded can overlay the apices giving the appearance of parenchymal opacity.
- The clue is in the extension of this opacity beyond the apex to overlay the neck where, unlike a true soft tissue mass, its margins will still be definable.
- In addition, the air trapped in a braid may be seen as radiolucent lines (Fig 3.36).

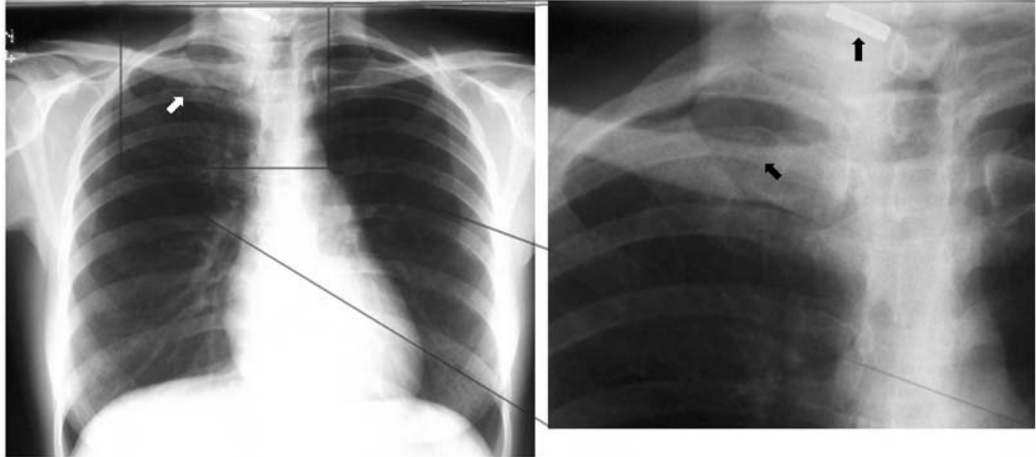


Figure 3.36

Left image shows increased opacity in the right apex (white arrow) in a subject being screened for TB. Right magnified image highlights the thin lucent lines within the hair braid (small black arrow) and the hair band (large black arrow).

Film/screen artefacts

- Foreign bodies such as dirt, dust and hair on the fluorescent screen will cast sharp shadows on the X-ray film as they are adjacent to the film compared to the structures in the lung that are further from the film and therefore have less sharp margins (Fig 3.37).

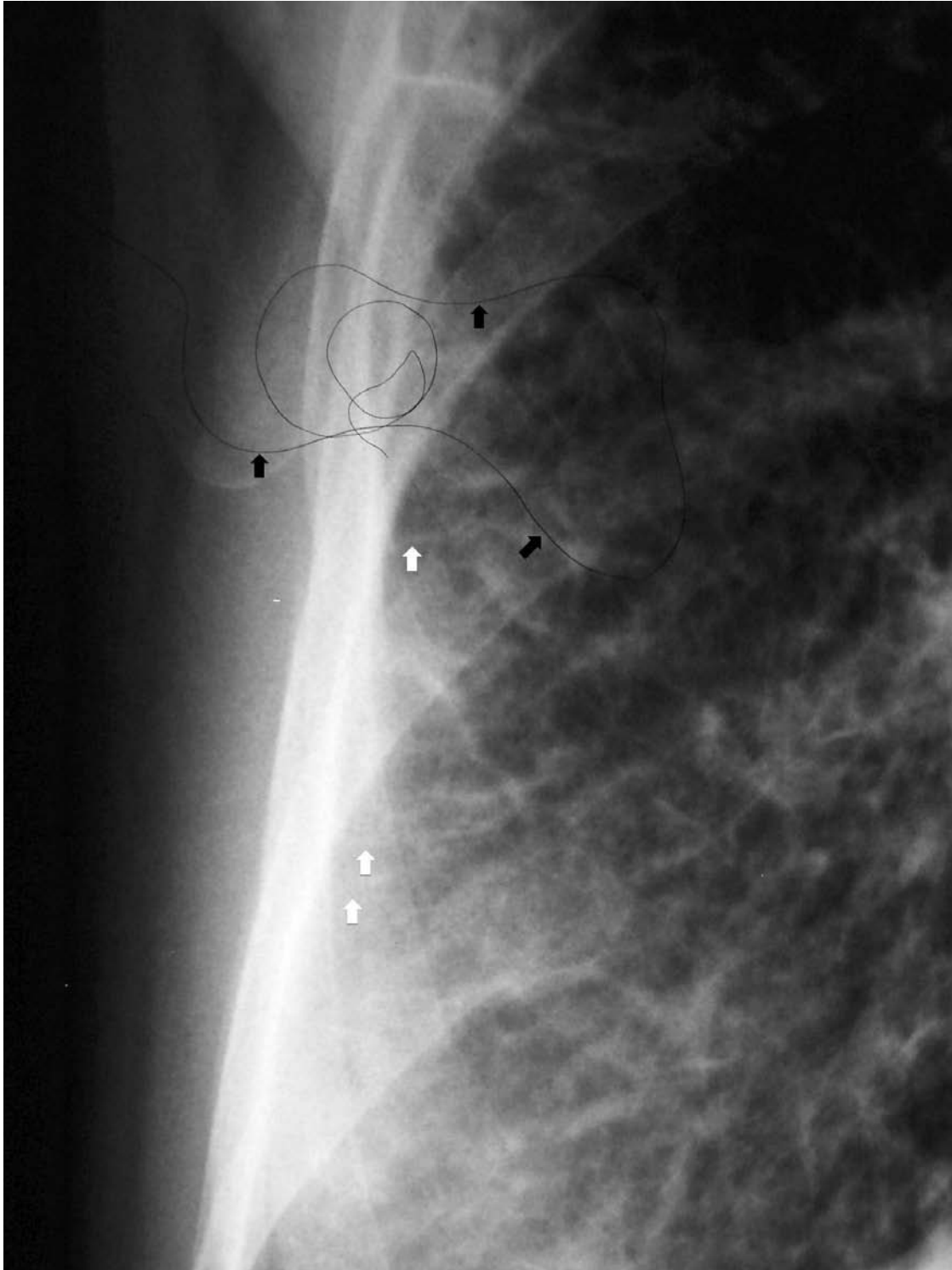


Figure 3.37

A magnified portion of a frontal CXR demonstrates the curvilinear opacity (black arrows) that appears far too sharply defined to represent an abnormality in the chest. Note the difference in sharpness between the artefact and the ribs. The artefact has been caused by a hair trapped between the film and the screen. Note also reticulation and septal lines (white arrows) due to lymphangitis carcinomatosa.

Film kinking during processing

- At the point at which a film is being gripped, particularly using the thumb and one finger, the film may become kinked. If this occurs prior to developing an artefact is created (Fig 3.38).

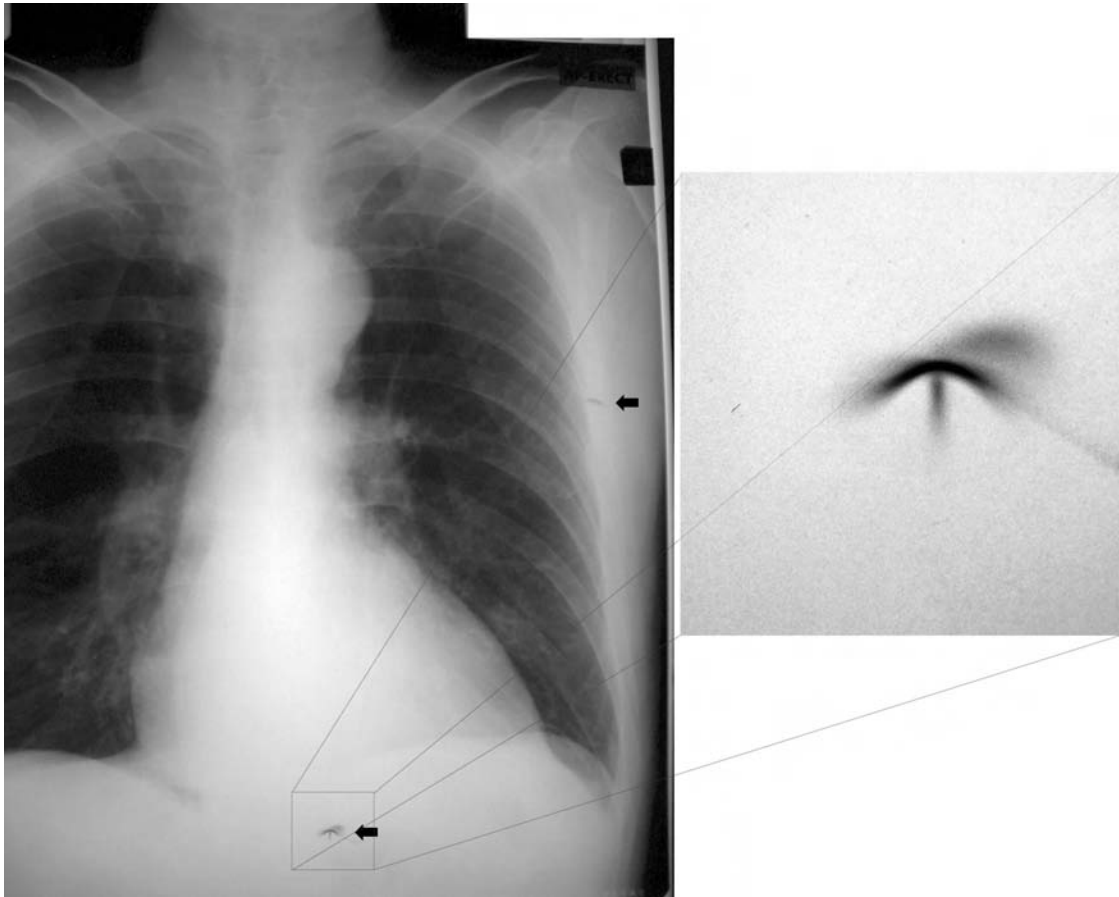


Figure 3.38

Frontal CXR of an adult male. The curved marks appearing on the film in two places (black arrows) are due to the film kinking when gripped between the thumb and fingers.

Pattern recognition

Collapse

Right upper lobe (RUL) collapse

- The RUL collapses forwards and the lower lobe expands to fill the space created, therefore, aerated lower lobe lies posterior to the collapsed RUL and extends to the apex.
- On a frontal CXR, RUL collapse is observed as an increase in density in the right upper zone with a lower margin defined by the horizontal fissure.
- If the cause of the collapse is a central mass obstructing the bronchus, a bulge at the hilum gives an “S” shape to the inferior margin of the collapse, the “Golden S sign” (Figs 4.1, 4.2).

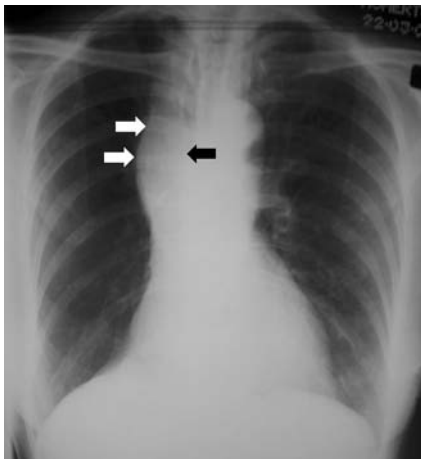


Figure 4.1

Complete right upper lobe collapse. The white arrows mark the minor (horizontal) fissure that separates the right upper lobe from the right middle lobe. As the upper lobe collapses medially and forwards the fissure also moves. The upper lobe comes to lie adjacent to the upper mediastinum causing widening of the right paratracheal stripe (black arrow) and deviation of the trachea to the right due to volume loss. Note the difference in transradiancy between the two hemithoraces as the lower lobe and middle lobe on the right have expanded to fill the space left by the upper lobe and the vessels are therefore more widely spread.

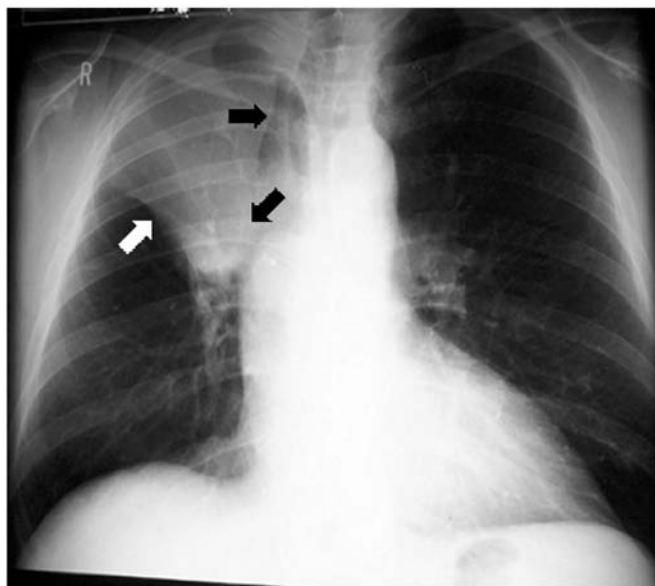


Figure 4.2

Right upper lobe collapse due to a central obstructing tumour mass. The minor fissure is raised (white arrow) indicating some collapse of the right upper lobe. There is increased opacity in the right apex and volume loss evident with deviation of the trachea to the right. The medial edge of the collapsed right upper lobe is seen (horizontal black arrow) and the cause for the collapse is the mass at the right hilum (diagonal black arrow). The combination of partial collapse and a central obstructing mass creates a curve to the minor fissure termed the “Golden S sign”.

Left upper lobe (LUL) collapse

- Like the RUL, the LUL collapses forwards, but in the absence of a horizontal fissure on the left, there is no clear inferior margin of the collapse.
- As on the right, the lower lobe expands to fill the space leaving a veil like opacity in the left upper zone.
- The lingula may be included in the collapse causing an increase in opacity over more than half of the left hemithorax with obscuration of the left heart border.
- Classically, LUL collapse obscures the silhouette of the aortic knuckle but this may not be apparent (Fig 4.3).

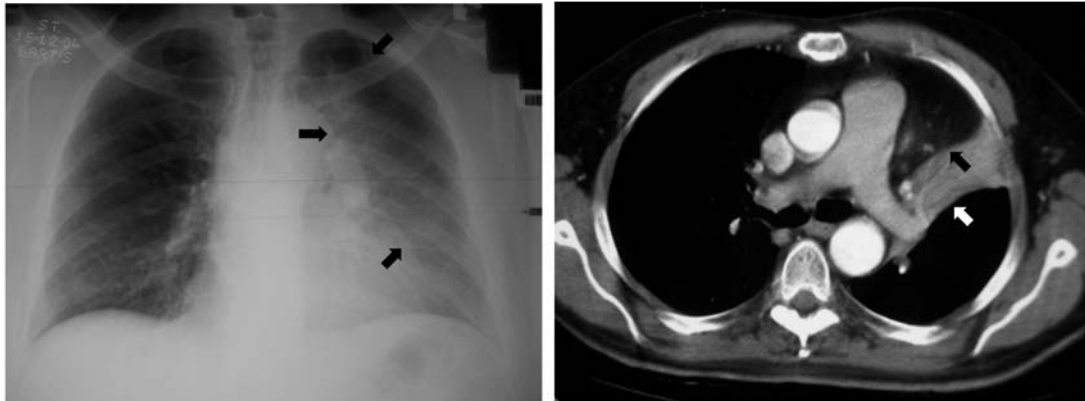


Figure 4.3

Left upper lobe collapse. Left image: Increased veil like opacity in the left mid and upper zone with almost normal translucency in the left apex (black arrow-diagonally down) as the left lower lobe expands to fill the space left by the collapsing upper lobe. Note loss of the left heart border due to lingular collapse (black arrow diagonally up). The collapse in this case is so complete that the aortic knuckle silhouette is preserved (horizontal black arrow); this is often obscured in LUL collapse. Right image: CT section demonstrates the interface between the collapsed LUL and the mediastinal fat (black arrow) and the major fissure (white arrow). Note the LUL collapses forwards leaving space posteriorly into which the left lower lobe expands.

Right middle lobe (RML) collapse

- The RML collapses inferiorly onto the oblique fissure causing depression of the horizontal fissure, which will no longer be apparent on the frontal CXR.
- There are no definable margins that relate to RML collapse making it a difficult sign to interpret.
- There is increased density adjacent to and obscuring the right heart border.
- A lateral CXR will demonstrate the collapse clearly and the appearances on the frontal CXR may be accentuated by taking a lordotic view (i.e. the X-ray beam angled upwards from the front or downwards from the back) (Fig 4.4).

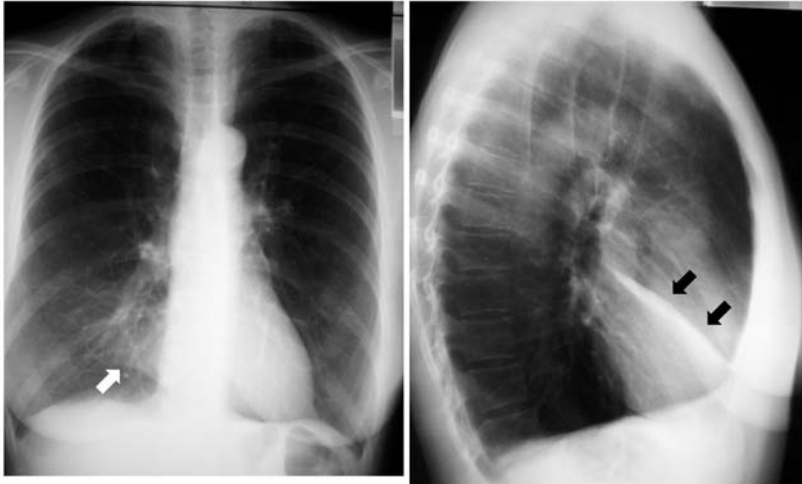

Figure 4.4

Right middle lobe collapse. Left image: Frontal CXR demonstrates an ill-defined opacity medially in the right lower zone (white arrow) obscuring the right heart border. Right image: Lateral CXR demonstrates a thin wedge shaped opacity that corresponds to the RML. Note the lobe collapses downwards, bringing the minor fissure (black arrows) close to the major fissure.

Right lower lobe (RLL) collapse

- The RLL collapses medially causing increased density behind and adjacent to, but not obscuring, the right heart border.
- Usually, the lateral margin of the collapse is well defined, demarcated by the oblique fissure, and there will be evidence of right lower zone volume loss with depression of the hila point on the right.
- The RUL expands to occupy the space (Fig 4.5).

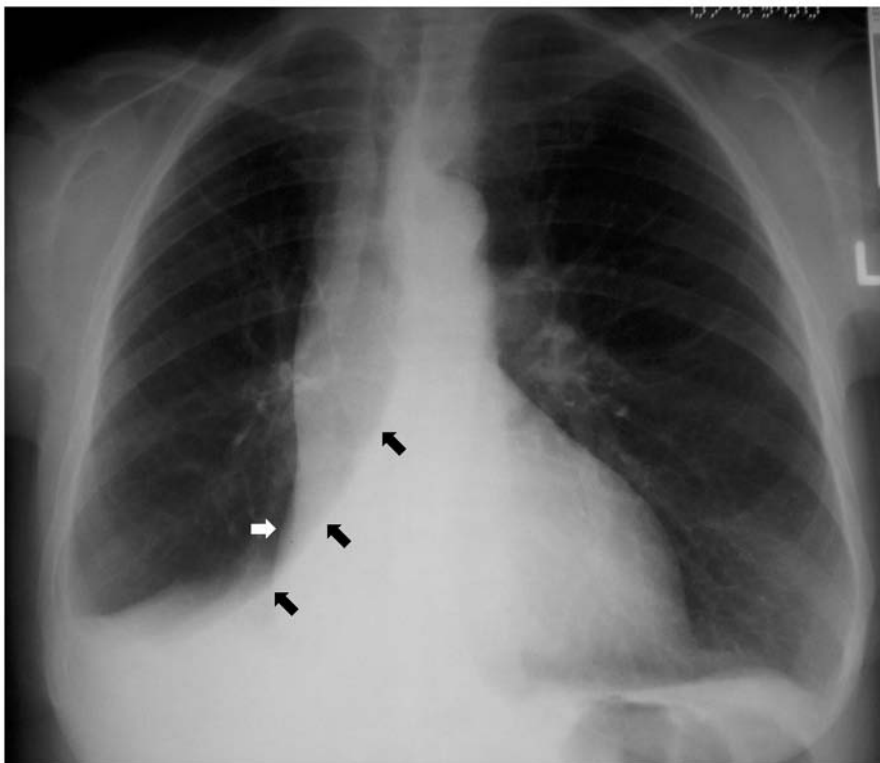


Figure 4.5

Right lower lobe collapse. The lateral margin of the collapsed RLL (black arrows) is formed by the major fissure, which has been pulled into the line of the X-ray beam by the RLL as it collapses posteriorly and medially. Note preservation of the right heart border (white arrow) and loss of the right diaphragmatic silhouette.

Left lower lobe (LLL) collapse

- Like the RLL the LLL collapses medially leaving a well-defined lateral margin, obscuring the medial aspect of the left hemi-diaphragmatic silhouette and causing increased density behind the heart.
- Volume loss results in depression of the left hilum, a more vertical course for the left main bronchus, shift of the mediastinum to the left and compensatory expansion of the LUL (Fig 4.6).

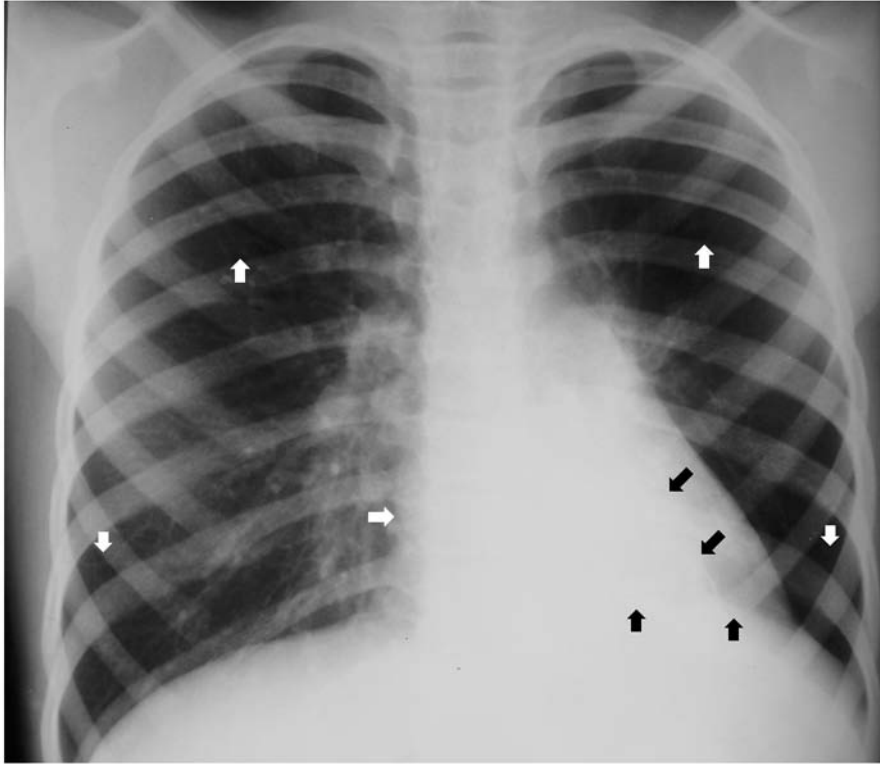


Figure 4.6

Left lower lobe collapse. The collapsed LLL creates a triangular density behind the heart with a straight lateral border (diagonal black arrows). Note the loss of the silhouette of the medial portion of the left hemidiaphragm (vertical black arrows), shift of the lower mediastinum to the left so that the right heart border overlies the spine (white horizontal arrow), reduction in the number of visible vessels on the left due to compensatory over-expansion of the left upper lobe (vertical white arrows).

Whole lung collapse

- An obstruction of the left or right main bronchus can cause collapse of an entire lung.
- The appearance is dramatic and mimics the “white out” seen in a very large pleural effusion but the presence of mediastinal shift to the side of the opacity indicates collapse as the cause rather than an effusion that is more likely to shift the mediastinum the opposite way (Fig 4.7).

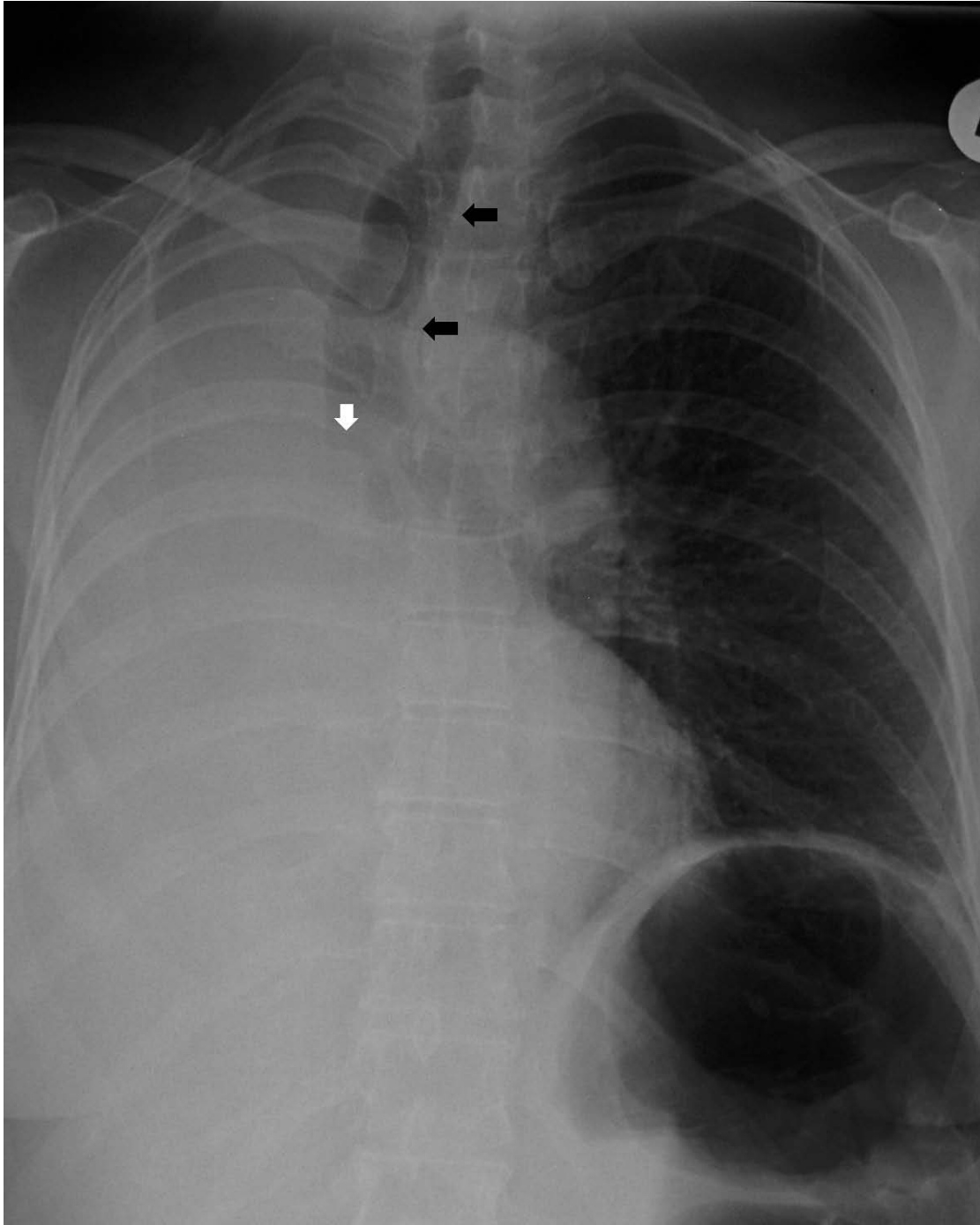


Figure 4.7

Complete collapse of the right lung secondary to an obstructing tumour in the right main bronchus (white arrow). Note the complete opacification of the right hemithorax combined with mediastinal shift to the right.

Consolidation

- Consolidation describes the filling of the air spaces of the lung with material other than air, namely, water, pus or blood.
- The CXR appearances reflect the loss of air, hence the increase in opacity.
- The vessels are no longer adjacent to the aerated lung and become invisible or indistinct.
- The small airways still containing air and surrounded by opacified lung become visible creating **air bronchograms** (Figs 4.8, 4.9).

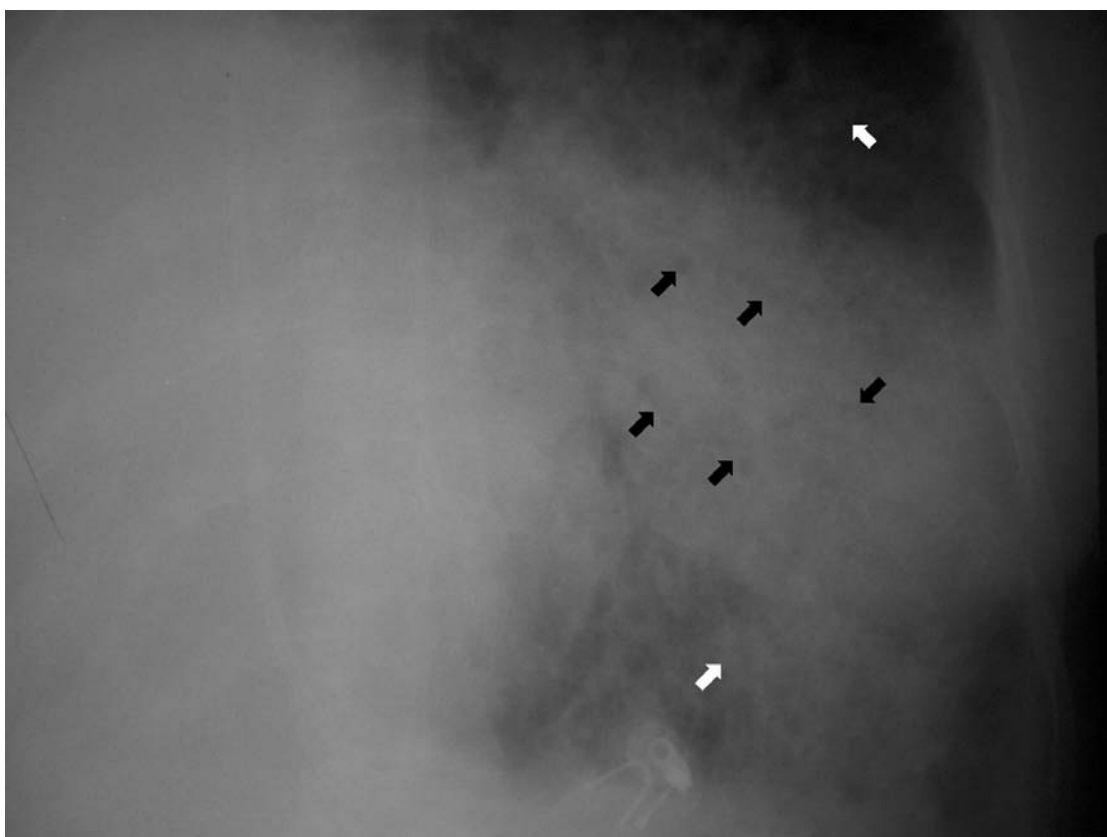

Figure 4.8

An area of consolidation in the lingula (note the loss of the left heart border silhouette) with air-bronchograms visible (black arrows) and pulmonary vessels marked (white arrows).

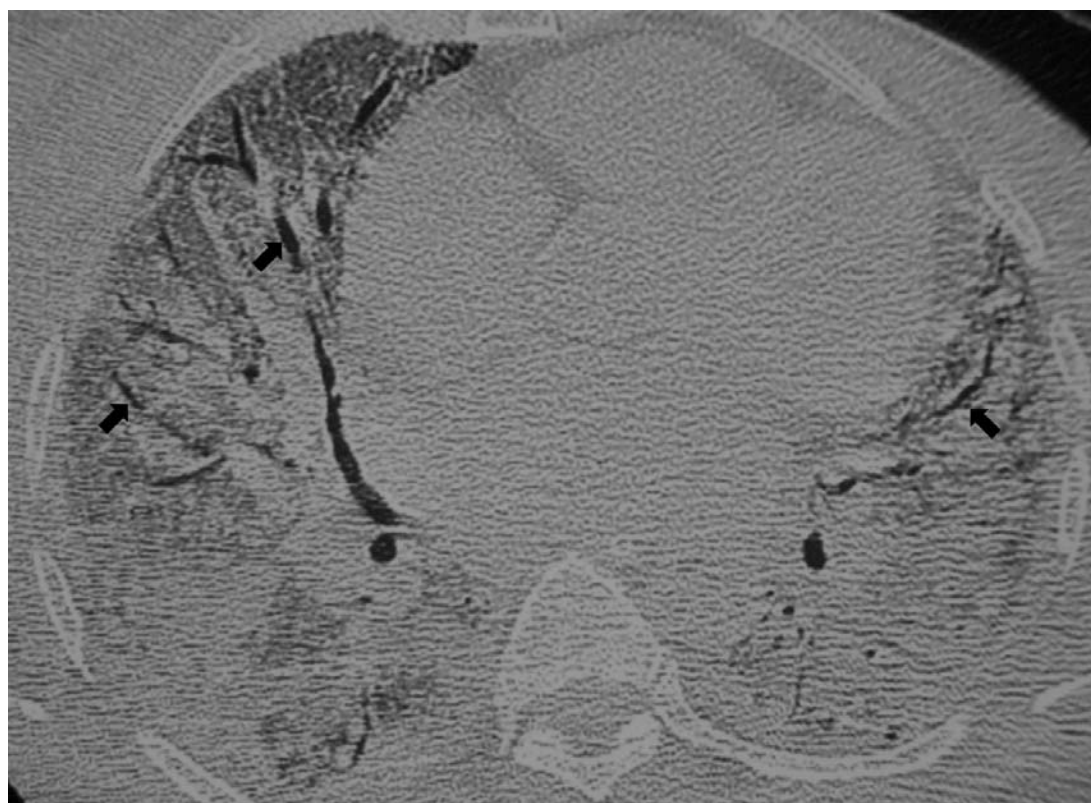


Figure 4.9

CT image demonstrating the creation of air bronchograms in consolidated lung. The walls of the smaller airways are too thin to see on CXR but with adjacent opacified lung, the tubular airway stands out clearly (black arrows).

Ground glass opacity

- As the lung tissue becomes filled with infiltrates, whether water, pus, blood or fibrosis, there is an increase in the density of that lung, which will appear on a CXR as an opacity.
- If there is insufficient alveolar filling to generate air-bronchograms or too much interstitial filling to display reticulation, the result is termed ground glass opacity.
- Areas of ground glass opacity on CXR are usually the result of an inflammatory process, such as infection, or due to developing pulmonary oedema.
- The pulmonary vessels become obscured but air bronchograms are not seen (Fig 4.10).

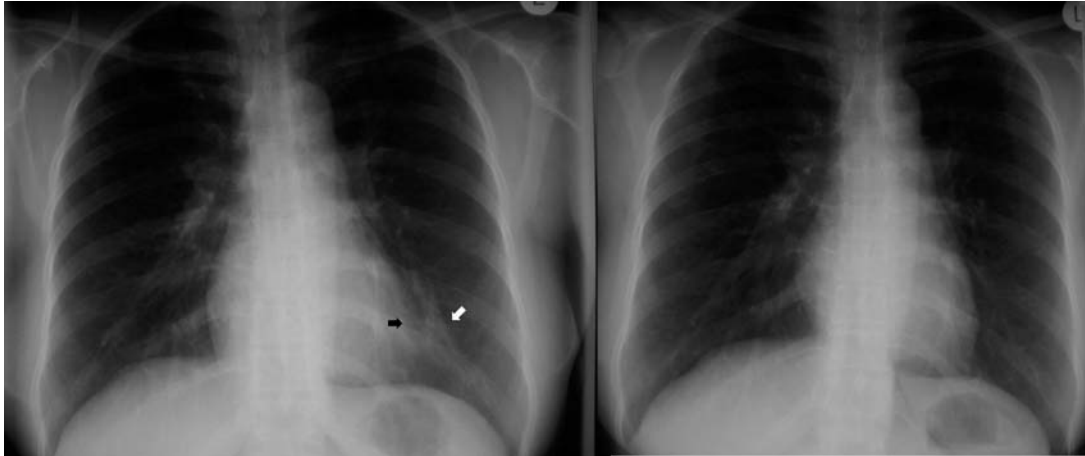


Figure 4.10

Left image demonstrates ground glass opacity in the lingula (white arrow) obscuring the left heart border (black arrow). The right image taken 6 weeks following antibiotic therapy, demonstrates resolution of what was pneumonia.

Masses

- A mass is defined as an opacity measuring 3 cm or more in diameter; an opacity less than 3 cm in diameter is called a nodule. A mass may destroy the adjacent lung as with invasive lesions, and have ill defined margins, or displace lung as it grows and have well defined margins.
- The identification of the margins of the mass depends upon the presence of adjacent aerated lung.
- If the mass is bounded by chest wall, consolidated lung or adjacent normal soft tissue structure, the relevant margin will be indistinct (Fig 4.11).

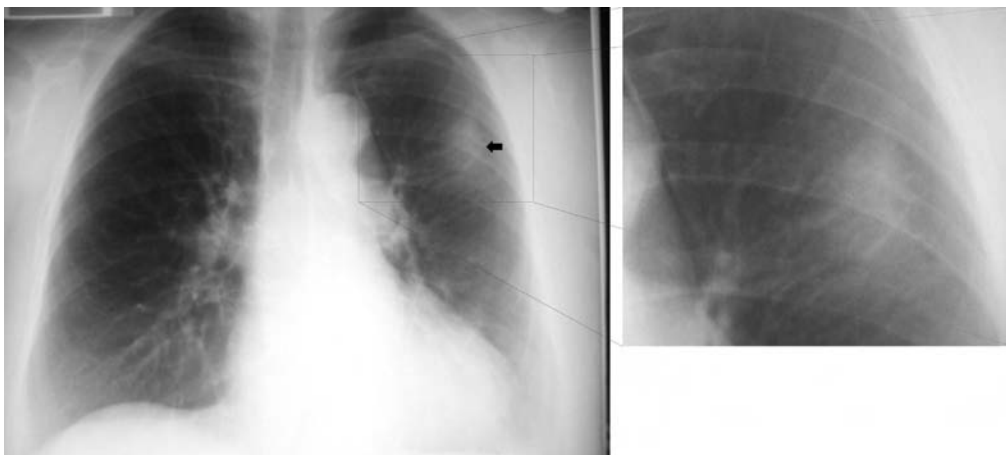


Figure 4.11

Frontal CXR of an adult male with an ill-defined mass in the left mid zone. Even on the magnified image, the margins are indistinct due to infiltration of this surrounding lung parenchyma by the primary adenocarcinoma.

- If the medial margin is visible, but the lateral margin is indistinct, the mass is probably pleural based (Fig 4.12).

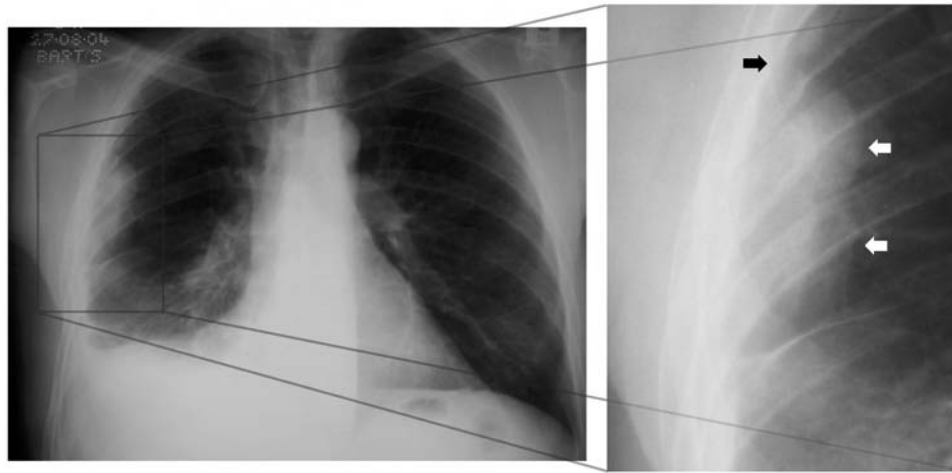


Figure 4.12

Left image demonstrates a pleural based mass, in this case mesothelioma. Note on the magnified image the well defined medial margin (white arrows) where the mass is adjacent to the lung and the merging of the upper border with the chest wall (black arrow).

- Pleural based masses at the front or back of the chest may only be visible as an increase in density on the PA CXR with preservation of the lung markings that would be obscured if the abnormality were within the lung (Fig 4.13).

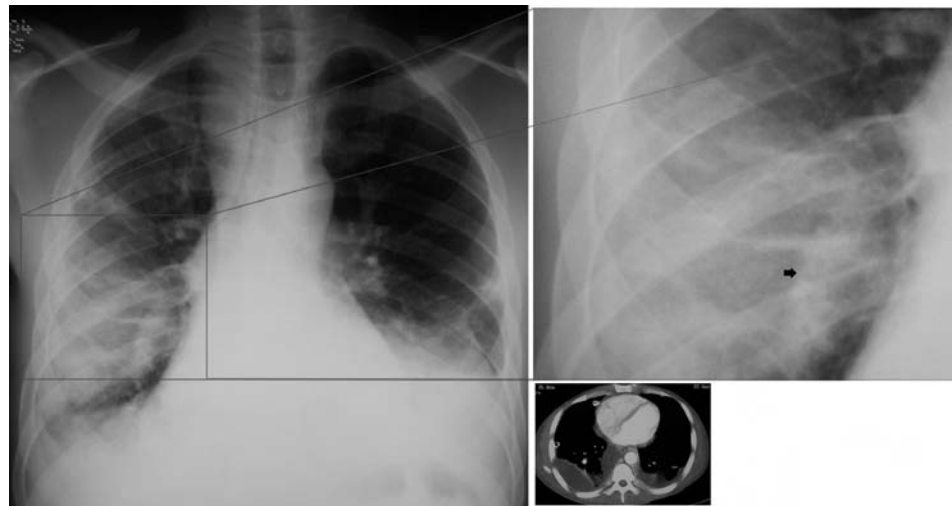


Figure 4.13

Frontal CXR of an adult with an empyema. Note the opacity in the right lower zone with preservation of vascular markings (black arrow). The CT image demonstrates the loculated collection causing the opacity.

- A mass arising from the mediastinum will have no definable medial margin but tends to have a well-defined lateral margin as it displaces adjacent lung (Fig 4.14).
- Masses may hide behind the diaphragm (Fig 4.15) in the posterior costophrenic recess, in the apices and in the para-spinal region projected behind the heart (Fig 4.16).

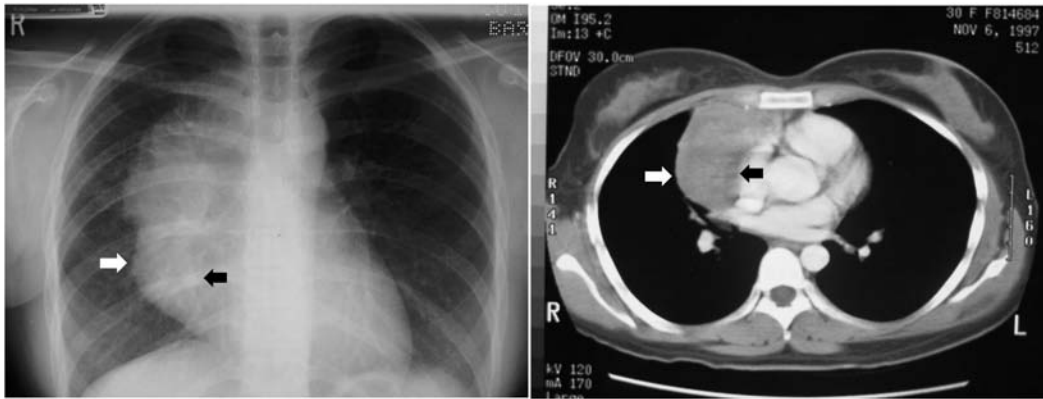


Figure 4.14 Left image is the frontal CXR and the right image a axial CT image of a large mediastinal mass, in this case lymphoma. Note the well-defined lobulated lateral margin and loss of the right heart border silhouette (black arrow). Also, note that the anterior position of this mass leaves the hilar vessels unobscured.

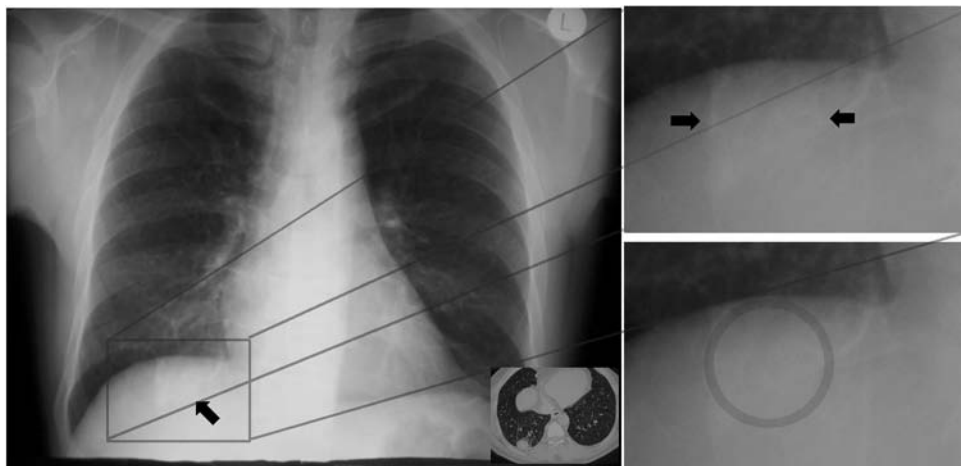


Figure 4.15 The left image is a frontal CXR where a 4cm mass lying in the right lower lobe is projected behind the right hemidiaphragm (black arrow) and easily overlooked. The inset demonstrates the lesion on a CT image and the magnified views highlight the outline of the mass on the CXR (black arrows/grey circle).

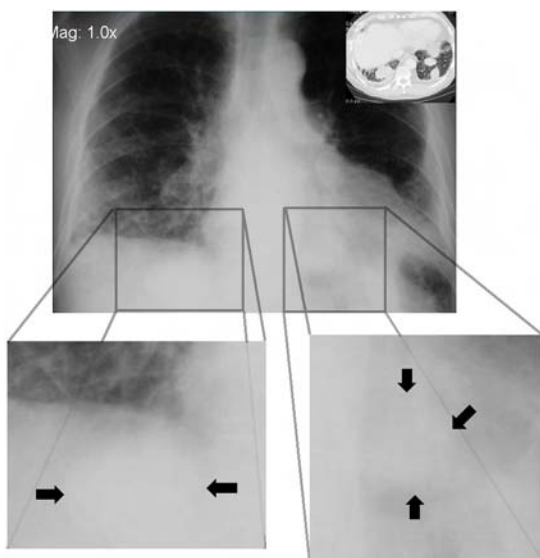


Figure 4.16 Two masses (colorectal metastases) are evident on the CXR, one projected behind the right hemidiaphragm (horizontal black arrows) and the other projected behind the heart (vertical/diagonal black arrows). The inset demonstrates the lesions on CT scanning.

Nodules

- Measuring less than 3 cm in diameter, nodules may be solitary or multiple.
- Multiple nodules have a wide differential depending on nodule size, density and the clinical state of the patient (Table 4.1).

Table 4.1 **Causes of multiple nodules**

Size	Density	Distribution	Disease
<2 mm	Soft tissue	Widespread	Miliary TB
		(more in bases)	Fungal infection
		Mid zones	Hypersensitivity pneumonitis
	High density	Mid zones	Coal miner's pneumoconiosis
		Basal	Sarcoid
		Widespread	Fibrosing alveolitis
2–5 mm	Soft tissue	Widespread	Haemosiderosis
			Siderosis
		Mid zones	Stannosis
	Soft tissue	Widespread and discrete	Alveolar microlithiasis
		Widespread and tend to confluence	Silicosis
		Basal and tend to confluence	Barytosis
>5 mm	Features	Distribution	Carcinomatosis
		Widespread	Lymphoma
		Widespread	Sarcoidosis
	Calcification, cavitation dependent on cell type	Widespread	Pneumonia (e.g.TB)
		Upper lobes	Pulmonary oedema
		Any	Hypersensitivity pneumonitis
Cavitation common	Widespread	Fat emboli	
	Any	Disease	
	Widespread	Metastases	
Cavitation and calcification	Widespread	Abscesses	
	Any	Coccidiomycosis	
	Widespread	Histoplasmosis	
Few in number, may calcify	Widespread	Wegener's	
	Lower zones, peripheral	Rheumatoid nodules	
	Any	Caplan's syndrome	
Cavitation, well defined	Cavitation, calcification, background pneumoconiosis	Any	Arterio-venous malformation
Well defined, lobulated			

- Nodules are particularly difficult to identify with certainty when they are of a similar diameter to the small vessels in the lung.
- Scrutiny of the periphery of the lung in the space bounded by the anterior and posterior ribs where there is no overlying rib and vessels are too small to be visible and should normally reveal no discernable anatomic structures.
- Nodules identified in this region are real (Figs 4.17, 4.18, 4.19).

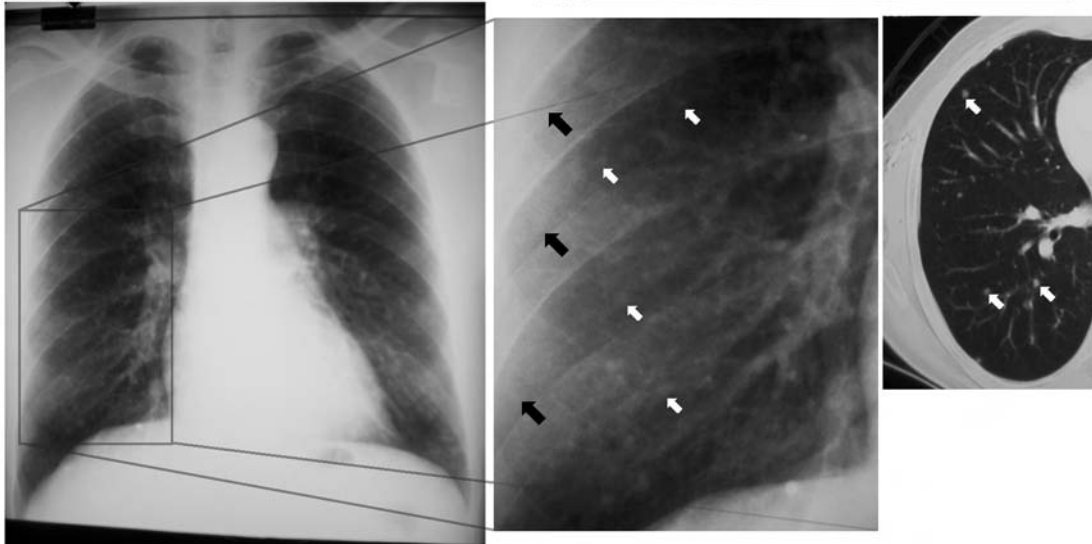


Figure 4.17

Multiple small nodules identified on frontal CXR are, at 2–3 mm similar in size to small vessels. Peripherally in the magnified view the nodules marked with white arrows could be confused for vessels but those marked with black arrows lie where vessels are not normally visible. The CT image confirms the presence of multiple small nodules, in this case a fungal infection in an immunocompromised patient.

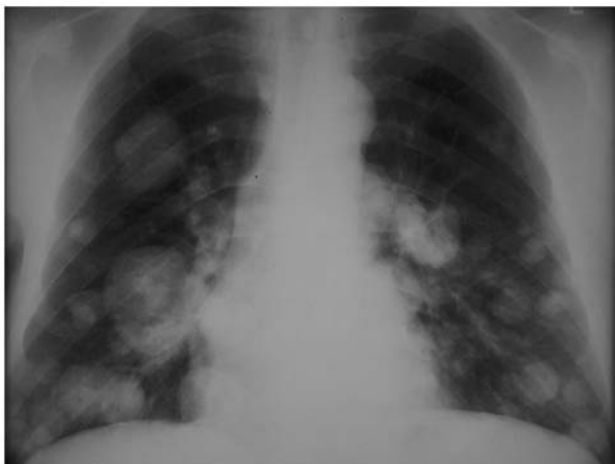


Figure 4.18

Frontal CXR demonstrating numerous nodules and masses. These are metastases from a seminoma and have clearly defined borders.

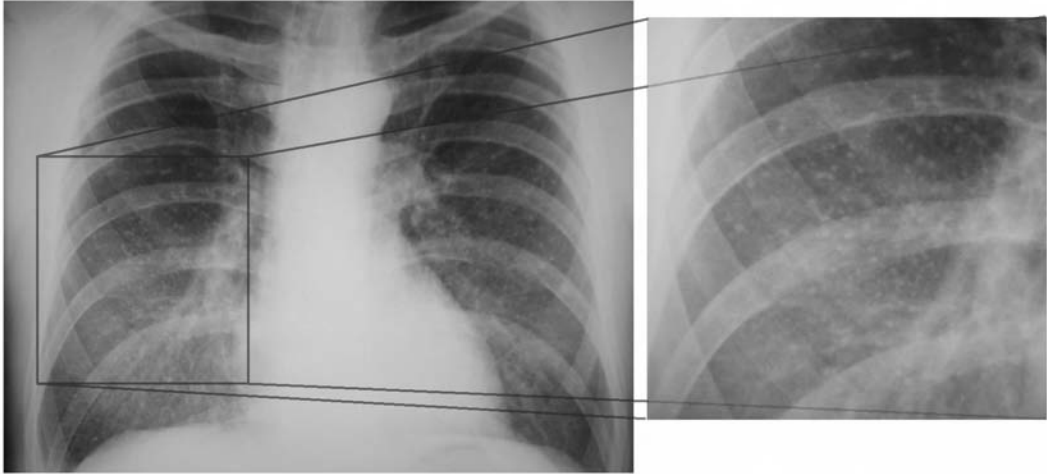


Figure 4.19

Frontal CXR of a case of previous chicken pox pneumonia. Note the multiple calcified nodules of varying size, very dense on CXR despite their small size.

Lines

There are four basic types of lines on the CXR.

Band shadowing

Band shadowing is usually 1–3 cm thick and 2–4 cm long and most commonly seen towards the lung bases. Parenchymal bands result from atelectasis (collapse) of a sub-segmental portion of lung usually found following focal pneumonia, pulmonary embolism or upper abdominal surgery (Fig 4.20).

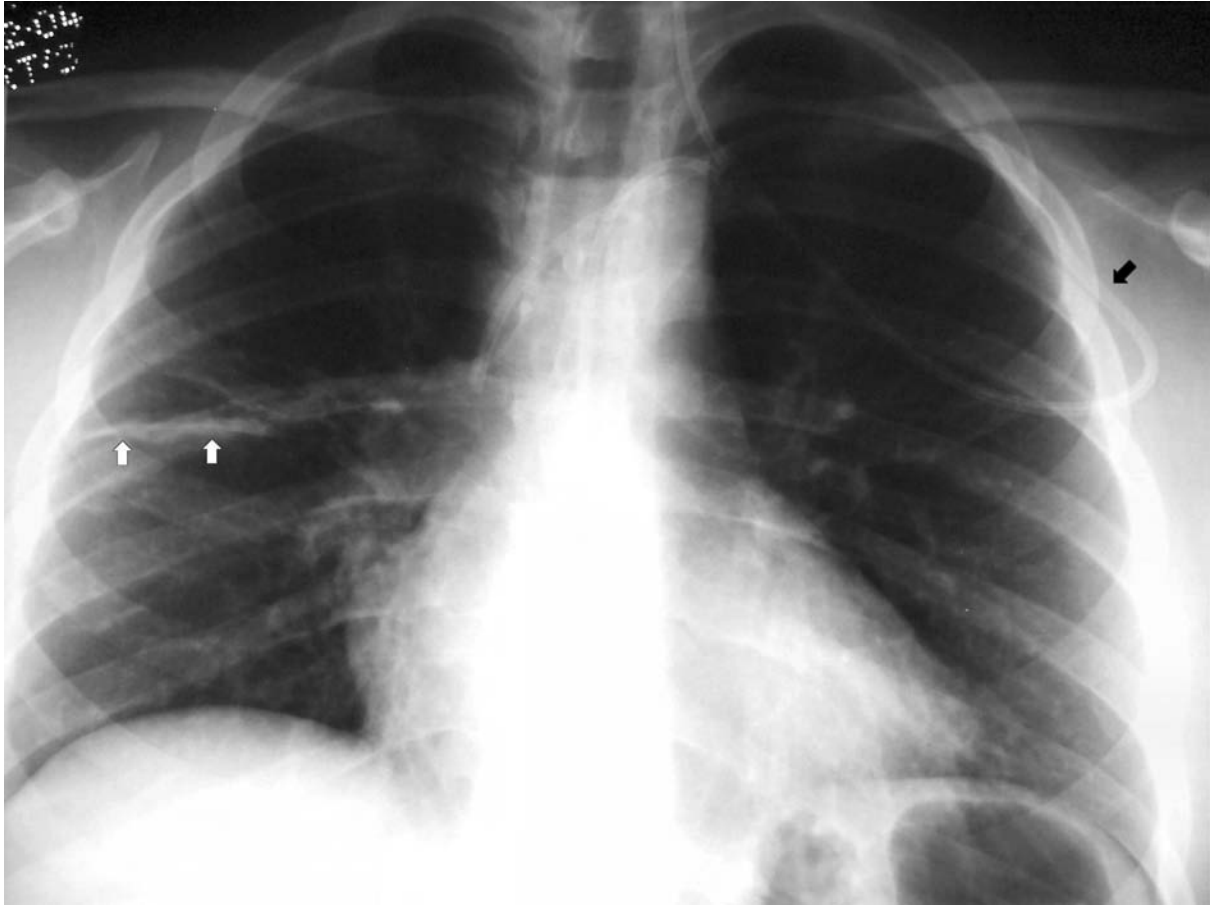


Figure 4.20
Frontal CXR of an adult male following recent abdominal surgery. Note the development of band atelectasis in the right mid zone (white arrows) and the subclavian intravenous line on the left (black arrow).

Curvilinear

Curvilinear lines are found in bullous emphysema. The entire margin of the bulla is rarely, if ever, seen but parts of the wall may cross the X-ray beam at the correct angle to create a line on the CXR (Fig 4.21).

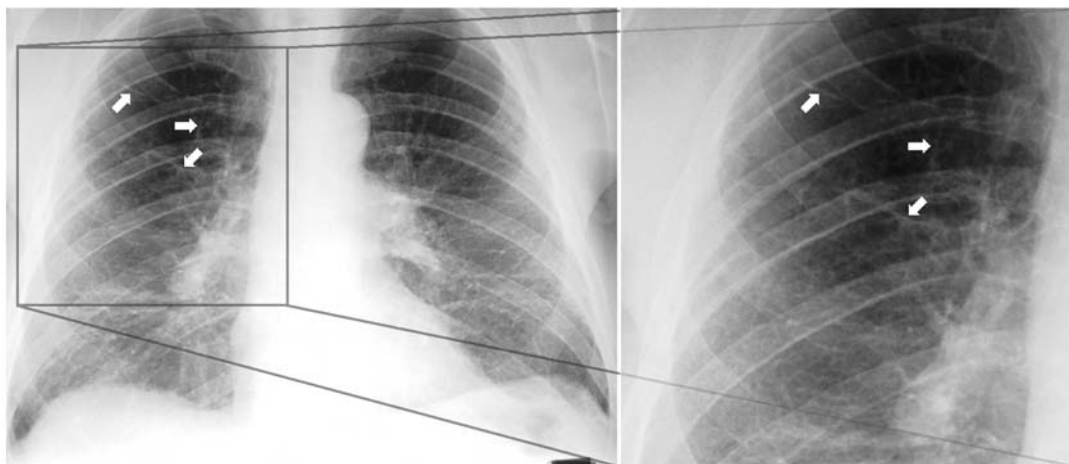

Figure 4.21
Frontal CXR of a patient with bullous emphysema. Note the curvilinear lines (white arrows) indicating the walls of the bullae.

Septal lines (Kerley A, B lines)

Septal lines are caused by the accumulation of fluid or other material in the interlobular septa. Kerley B lines are found at the periphery of the lung bases. They are 1–2 cm in length and extend at right angles from the pleural surface. The commonest causes are left heart failure (Fig 4.22) and lymphangitis carcinomatosa (Fig 4.23, Table 4.2).

Table 4.2 **Causes of septal lines**

Left ventricular failure
Pneumoconioses
Lymphangitis carcinomatosa
Sarcoid (rare)

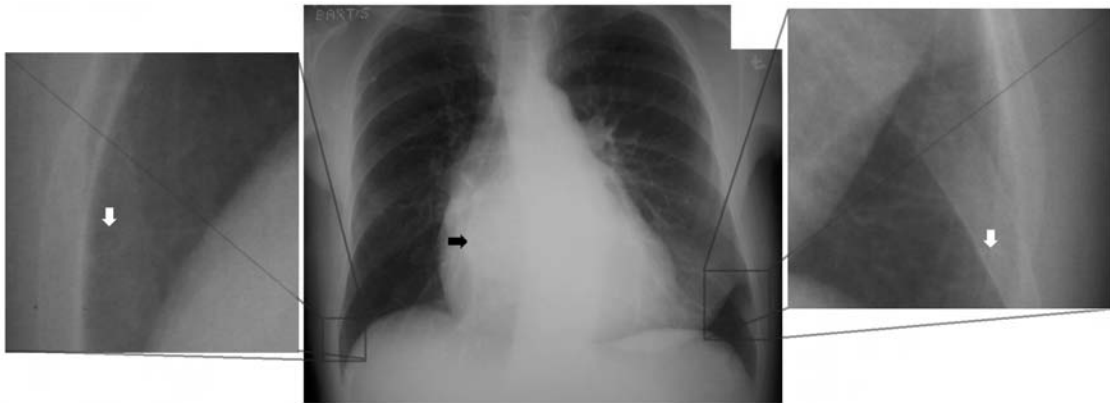


Figure 4.22

Frontal CXR of a patient with left heart failure. Note the double right heart border due to the right margin of the enlarged left atrium (black arrow). The 2 magnified views are of the costophrenic angles and septal lines are marked (white arrows).

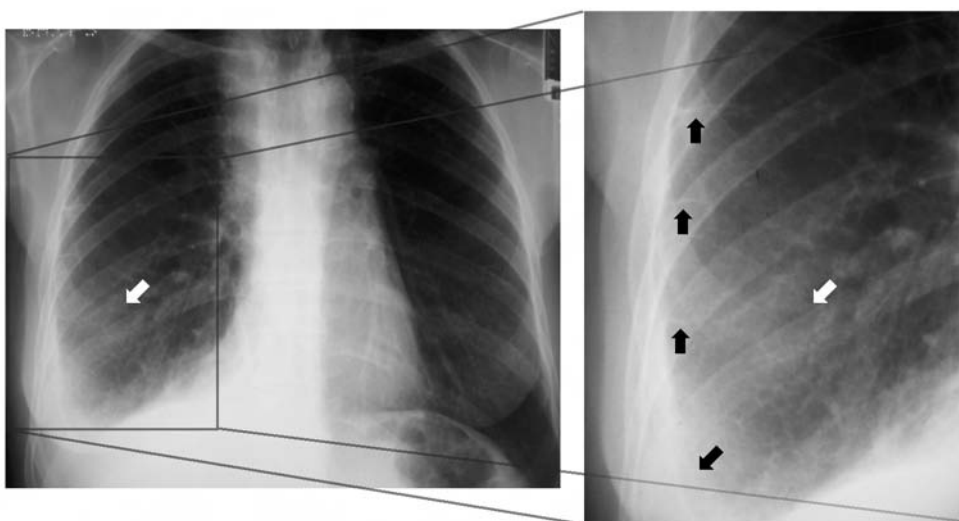


Figure 4.23

A patient with right lower lobe collapse secondary to primary lung carcinoma. There is mediastinal adenopathy and reticulation in the right lower zone (white arrow) indicating an interstitial infiltrate. In addition, there are numerous septal lines (vertical black arrows) and a small pleural effusion (diagonal black arrow) secondary to lymphangitic congestion from tumour infiltration.

Kerley A lines are longer and are seen in the mid zones. They reflect the same interstitial process extending into the more proximal interlobular septa.

Reticulation

Reticulation represents thickening of the lung interstitium and is difficult to identify with confidence on a CXR. The pattern consists of criss-crossing fine lines, which must be distinguished from the normal vascular pattern. Potential causes are fluid accumulation in the interstitium as in pulmonary oedema, or thickening due to cellular or fibrotic processes. As the interstitium extending to the surface of the lung is usually the first to become affected, reticulation is often better appreciated at the periphery of the lung on the CXR and the irregularity of the lung adjacent to soft tissue structures interferes with the silhouette sign resulting in a rough or ill-defined margin (Fig 4.24).

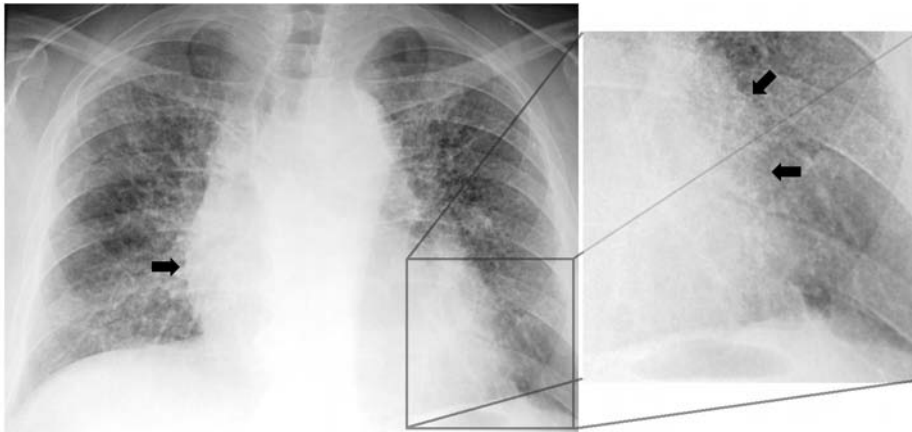


Figure 4.24
Frontal CXR of a patient with idiopathic pulmonary fibrosis (cryptogenic fibrosing alveolitis). Note the diffuse reticulation and the loss of clarity of the heart borders (black arrows).

Cavities

A cavity is the development of an air space within solid tissue whether a mass (Fig 4.25) or consolidated (Fig 4.26) /infarcted lung and therefore tends to have a thicker wall than found in cysts or bullae.

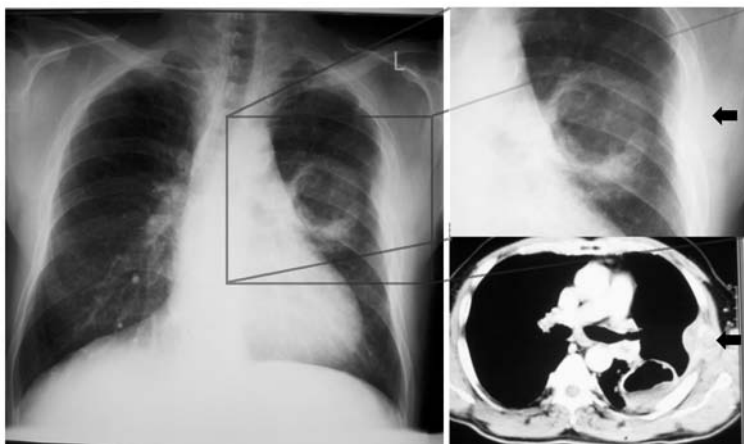


Figure 4.25
Large cavitating lesion (squamous cell carcinoma) in the left mid zone with an associated chest wall mass (black arrow – rib metastasis).

Cavities may contain air fluid levels and cavitation within consolidated lung may be obscured by the adjacent abnormal lung parenchyma.

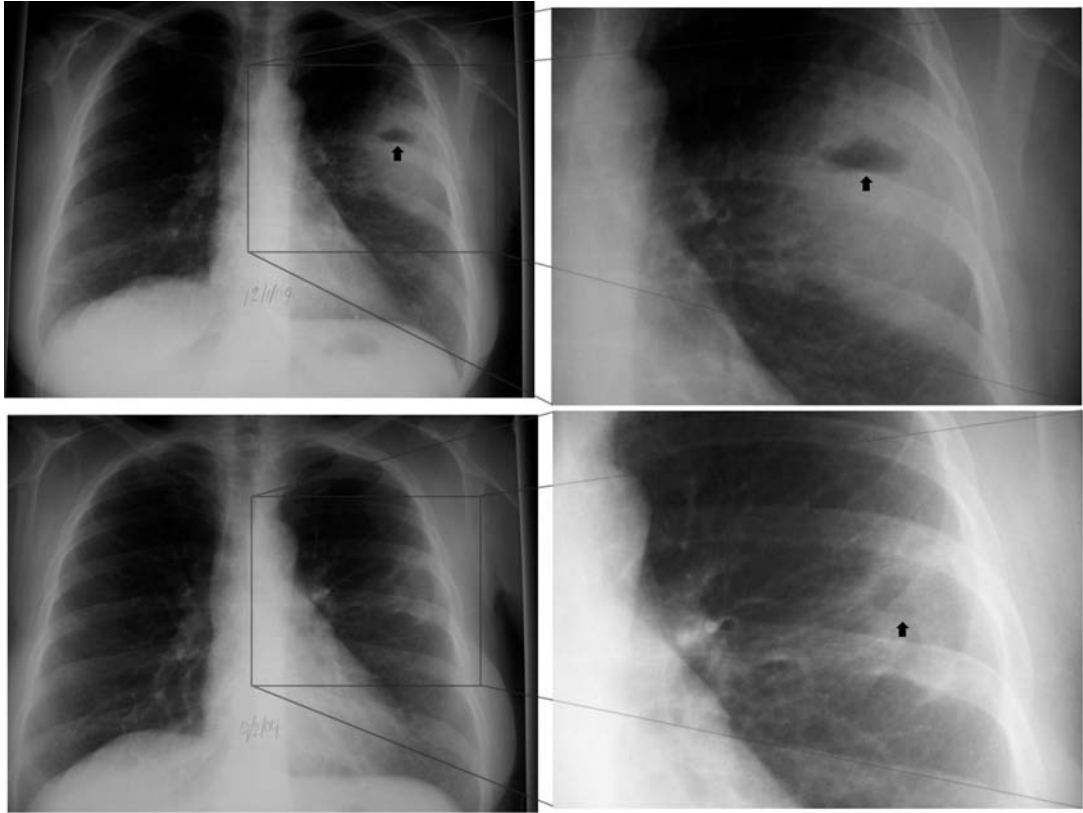


Figure 4.26

An adult female patient with a cavitating pneumonia. Note the fluid level within the cavity (black arrow). The top CXR was that at presentation, and the bottom CXR was taken 1 month later, following antibiotic therapy.

Abnormalities of the thoracic cage and chest wall

Pectus excavatum

- Pectus excavatum is a developmental abnormality that results in backward displacement of the sternum and a resulting reduction of the antero-posterior diameter of the chest in the mid line. This causes a shift of the heart to the left and an abnormal angle to the ribs adjoining the sternum.
- On the CXR, the posterior aspects of the ribs are more horizontal than usual and the anterior ribs are more vertical giving a figure “7” appearance.
- A change in the orientation of the anterior chest wall and the shifting of the heart to the left result in the loss of clarity of the right heart border and an unusually straight edge to the left heart border (Fig 5.1).
- Pectus excavatum occurs as an isolated phenomenon but is also strongly associated with Marfan’s syndrome.

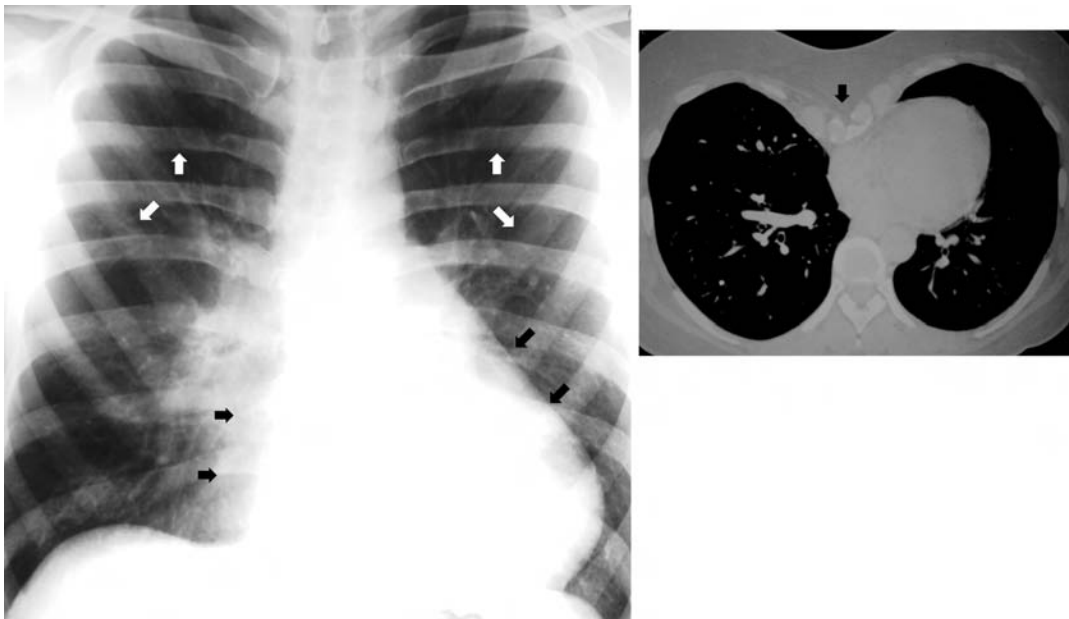


Figure 5.1

Frontal CXR of a patient with pectus excavatum. Note the shift of the lower mediastinum to the left and an unclear right heart border (horizontal black arrow), a straight left heart border (diagonal black arrow) and horizontal posterior ribs with more vertical anterior ribs the figure “7” sign (white arrows). The CT image is of a different patient with pectus excavatum demonstrating the depressed sternum (black arrow).

Scoliosis

- Scoliosis is curvature of the spine in the coronal plane.
- The normal spine is straight in the coronal plane but allows some degree of lateral flexion at each thoracic vertebral joint.
- The simplest form of scoliosis as seen on a CXR is physiological and related to the patient's position at the time of the CXR.
- This may be due to poor positioning by the radiographer but is also a normal response to unilateral chest pain where the scoliosis is due to flexion of the spine toward the side of the pain.
- Scoliosis may also be congenital or a result of spinal pathology such as vertebral fracture, tumour or infection.
- On a CXR, the spine should be visible, and swelling of a para-spinal line in association with a scoliosis indicates significant pathology (Fig 5.2).

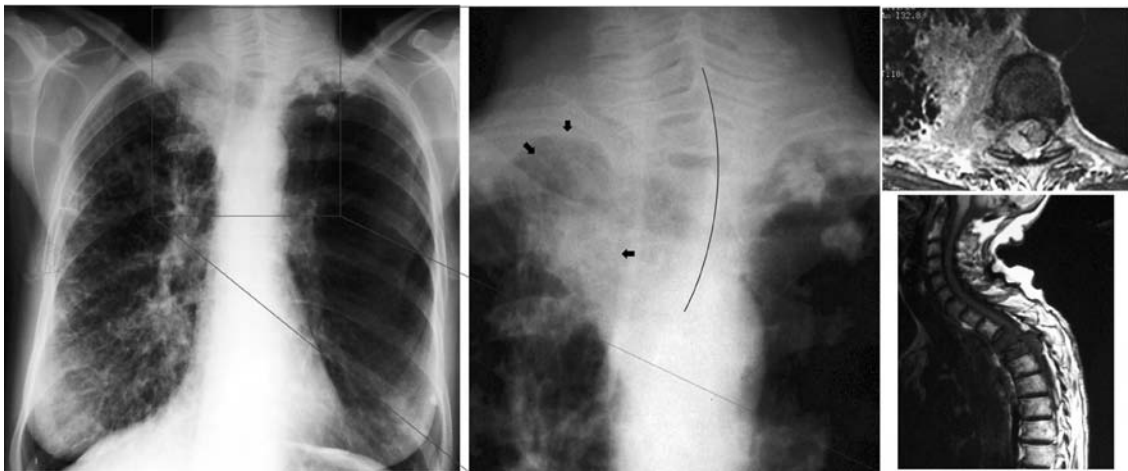


Figure 5.2

Frontal CXR of a patient with metastatic breast carcinoma. The presence of lymphangitis carcinomatosa is noted. The magnified image demonstrates the right para-spinal soft tissue mass (black arrows) and the resulting scoliosis is indicated with a thin dark line. The inset images are axial and sagittal images from a MRI of the same patient. Note the para-spinal soft tissue on the upper image and the change in signal in the vertebral bodies, evident in the sagittal view, confirming metastases.

Kyphosis

The spine in the sagittal plane is not straight but forms a double S shape. Mechanically, this enables the spine to absorb impacts along its length, e.g. whilst running, by minor degrees of flexion and extension at each intervertebral joint. The thoracic spine has a physiological kyphosis (Fig 5.3).

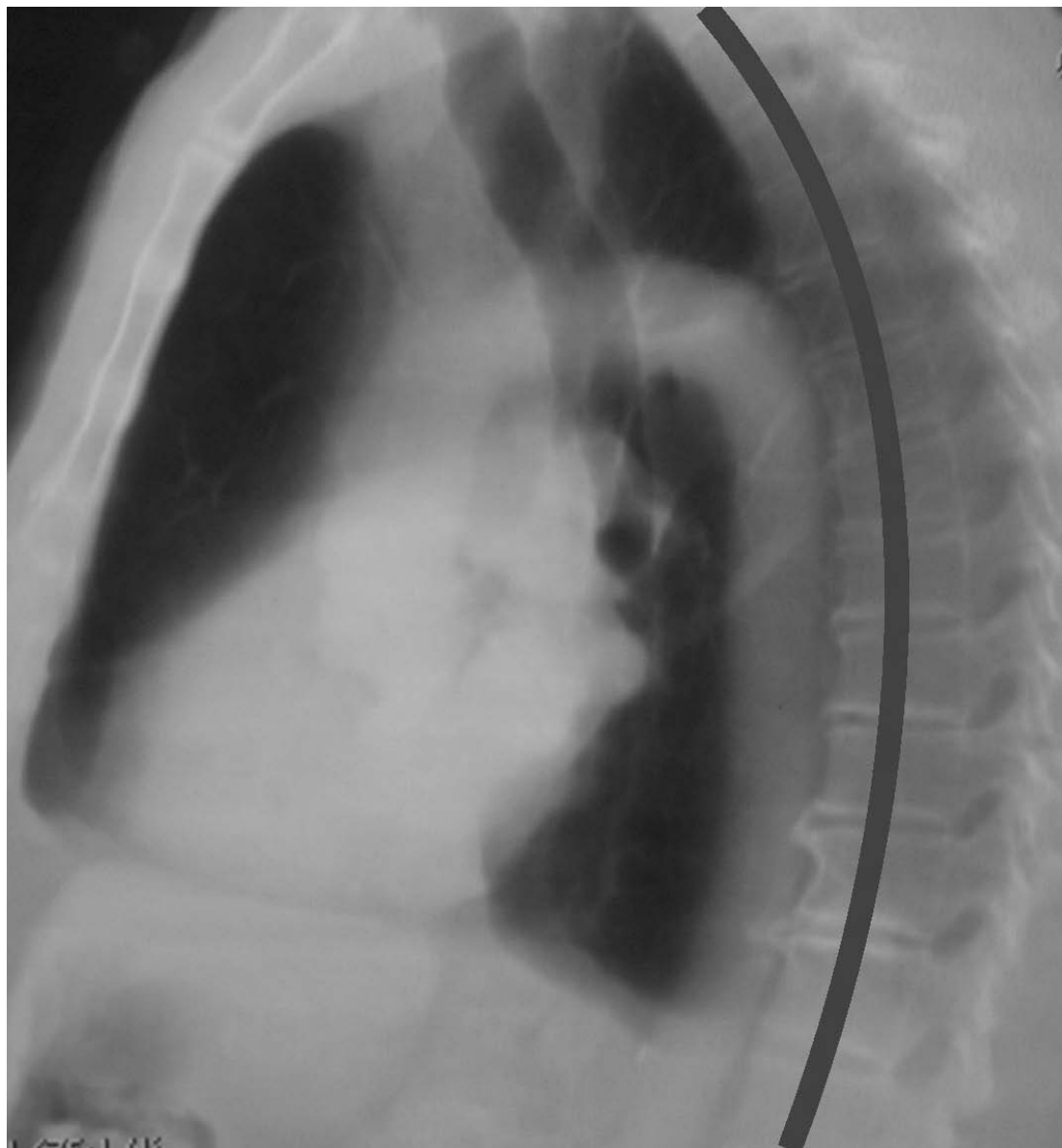

Figure 5.3

Sagittal reconstruction of the chest demonstrating the normal kyphotic curvature of the thoracic spine.

- Anterior wedge collapse of thoracic vertebrae causes accentuation of the thoracic kyphosis and is commonly found in the elderly.
- The significance to the patient is a restriction in chest expansion that may affect their respiratory function.
- On a frontal CXR, the kyphosis decreases the perceived size of the chest through reduction in the cranio-caudal dimension, and the mandible may come to overlay the upper chest.
- The lateral view is ideally suited to demonstrate the extent of kyphosis and the most likely cause is vertebral collapse.
- The lateral view reveals how erroneous the perception of a reduction in size of the chest may be, as the increase in antero-posterior diameter is not readily appreciated on the frontal CXR. (Fig 5.4)

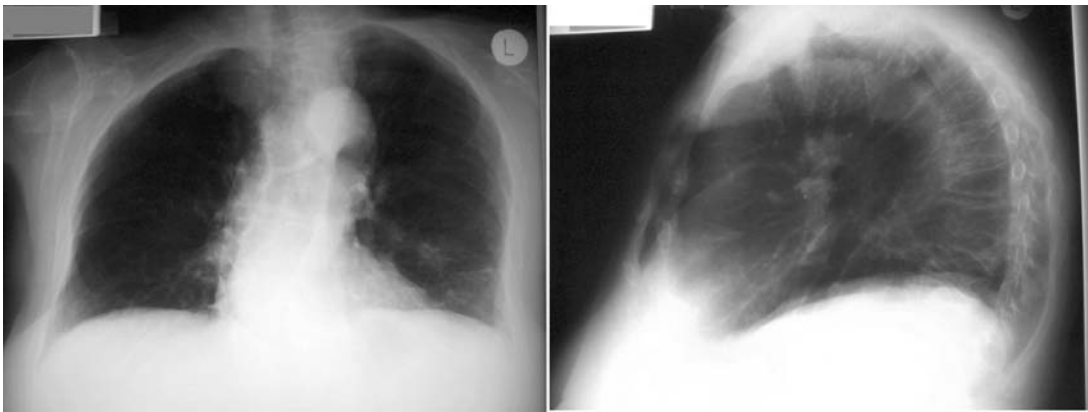


Figure 5.4

Frontal and lateral CXR of an adult female. Note the comparative small volume of lungs on the PA view due to an increase in the PA diameter of the chest.

Tumours in bone

- Primary tumours of the thoracic cage are rare; most bone tumours are metastases or multiple myeloma.
- Metastases may be sclerotic (producing increased density) (Fig 5.5) or lytic (when there is rarefaction and destruction of the bone) (Fig 5.6).
- Lytic bony lesions of the ribs may be difficult to appreciate on a CXR as superimposed lung vessels can readily give the impression of variations in density mimicking lytic deposits. The lateral aspects of the ribs not projected over lung and lucencies in the ribs at these sites indicate the presence of lytic lesions.
- The clavicles and scapulae are easier to scrutinise but are often overlooked (Fig 5.7).

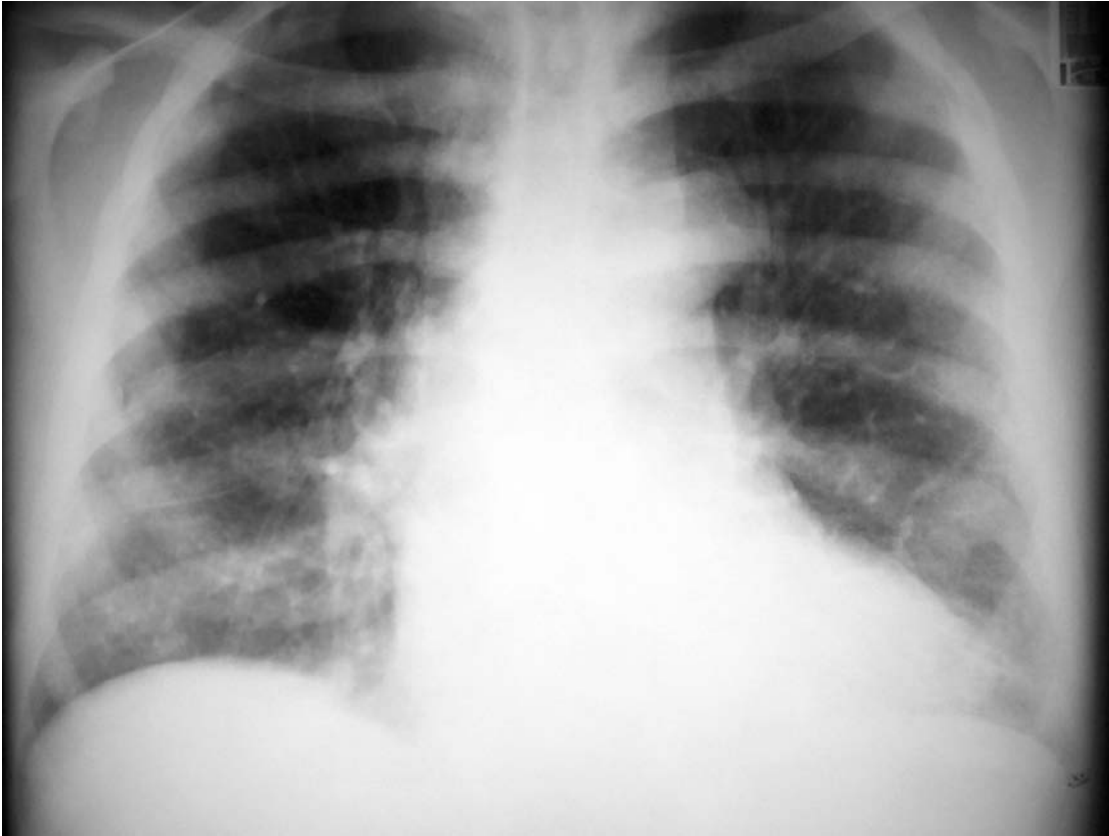

Figure 5.5
Frontal CXR of an adult male with metastatic prostatic carcinoma. Note the increased density of the ribs due to diffuse sclerotic metastases.

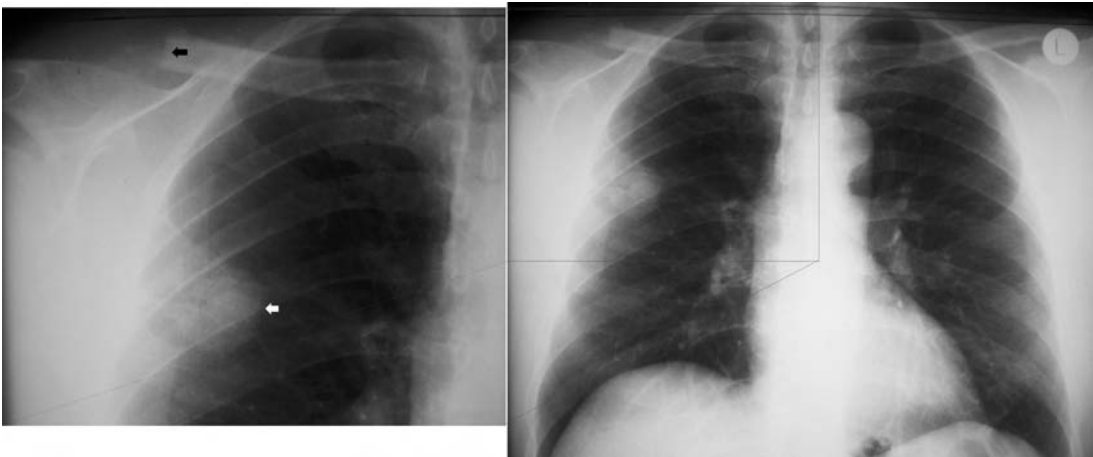


Figure 5.6
Frontal CXR of an adult male with a primary adenocarcinoma of the lung (white arrow) and a lytic clavicle metastasis (black arrow).

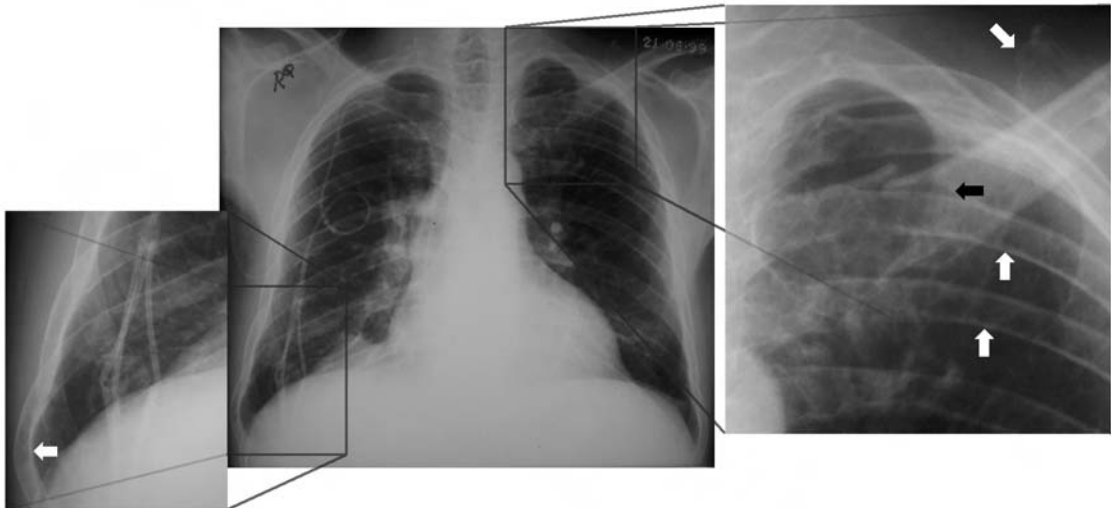

Figure 5.7

Frontal CXR of a patient with multiple myeloma. Note the lytic lesion seen in the lateral right lower rib (horizontal white arrow) in the left magnified view. In the right magnified view are a pathological fracture of the clavicle (black arrow), endosteal scalloping due to lytic lesions in the ribs (vertical white arrows) and a lytic lesion in the scapula (diagonal white arrow).

Cutaneous nodules

- Cutaneous nodules may be evident on a CXR as an increased area of density.
- As the nodule is likely to be outlined by adjacent air, its margins are typically very well defined.
- The true nature of these opacities is indicated by their presence outside the limits of the lungs.
- If this is not apparent, an inspection of the patient's chest wall should help explain the appearances (Fig 5.8).

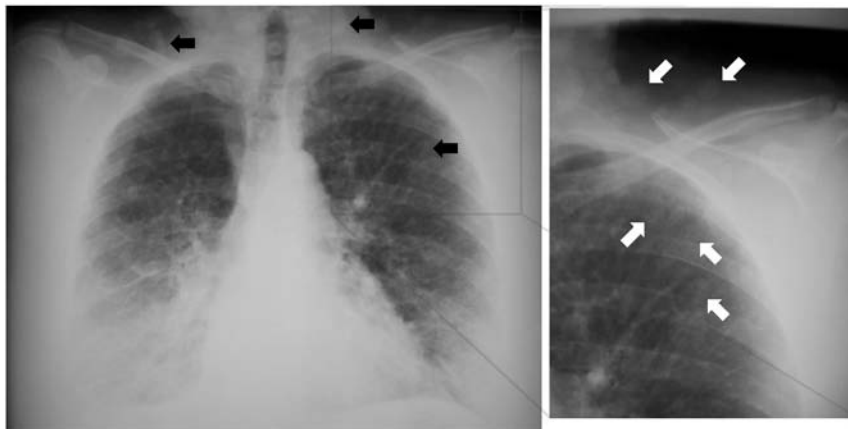


Figure 5.8

Frontal CXR of a patient with neurofibromatosis. Numerous cutaneous neurofibromas are marked. Note that those overlying the lungs appear like nodules in the lung but have very well defined margins. The presence of numerous opacities not projected over the lungs confirms their cutaneous origin.

Soft tissue asymmetry

- As the soft tissues of the chest wall contribute significantly to the absorption of X-rays during the production of the chest image, a change in the amount of soft tissue may have a marked effect on the exposure of the CXR.
- The reduction or absence of soft tissue results in an increase in X-ray exposure of the X-ray film, creating a darker area, e.g. mastectomy (Fig 5.9), Poland's syndrome (congenital absence of pectoralis muscle) and hemiplegia or polio causing muscle wasting.

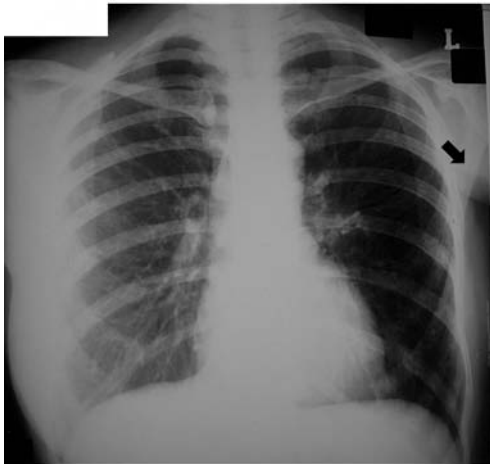


Figure 5.9

Frontal CXR of a patient who had had a left mastectomy. Note the difference in transradiancy (darker on the patient's left) making the underlying lung appear less vascular. Both left and right lung are actually normal. A further indicator of breast surgery is the deformity in the axilla (black arrow).

- An increase in soft tissue of the chest wall will absorb more X-rays, causing an increase in opacification of the X-ray film, e.g. tumour, haematoma, etc.
- Soft tissue tumours arising in the lateral chest wall should be apparent on the CXR through the resultant asymmetry in thickness and/or density (Fig 5.10, 5.11).

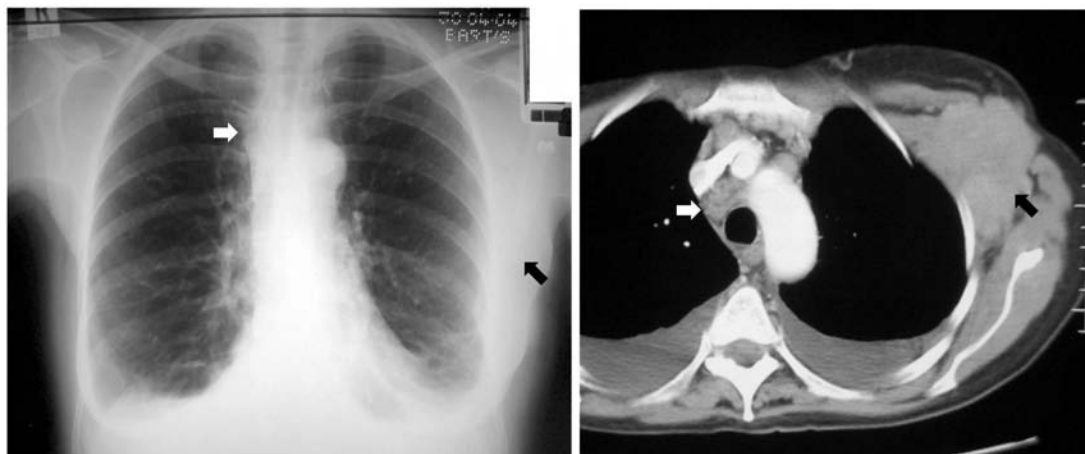


Figure 5.10

Frontal CXR and axial CT image of a patient with lymphoma. Note the asymmetry in the chest wall due to a large lymph node mass (black arrows), bilateral pleural effusions suggesting lung involvement and mediastinal lymphadenopathy is also apparent (white arrows).

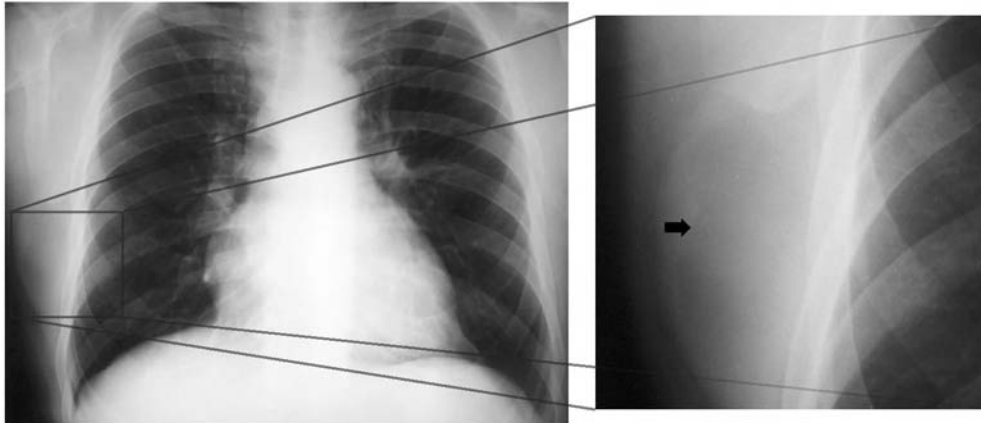


Figure 5.11
Frontal CXR of a patient with a lipoma of the chest wall. Note the asymmetry of the soft tissues and the low density (black arrow), indicating the presence of fat. (Case courtesy of Janet Dacey)

Care should be taken to compare the density of the right hemithorax with that of the left.

- An increase in axillary soft tissue may be due to lymphadenopathy (Fig 5.12) and an increase in the soft tissues of the lower neck may indicate a goitre (Fig 5.13) or lymphadenopathy.

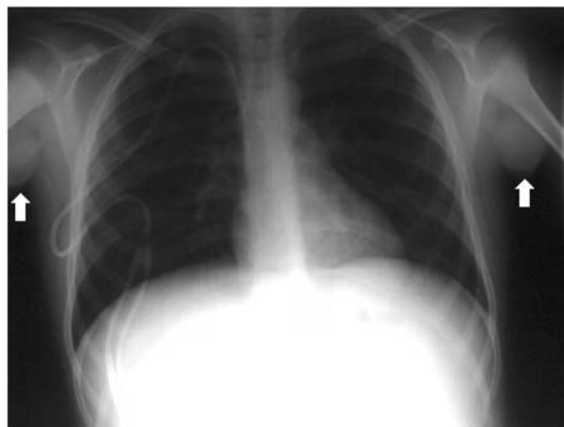

Figure 5.12
Frontal CXR of a young patient with lymphoma. Note the long-term central venous line for chemotherapy and bilateral axillary adenopathy (white arrows).

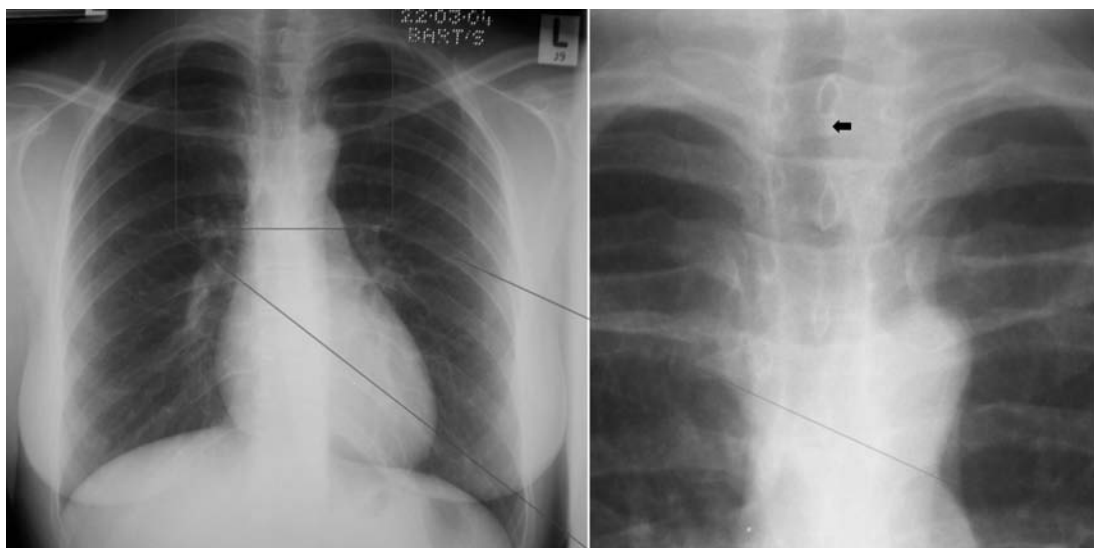


Figure 5.13
Frontal CXR of a patient with carcinoma of the left lobe of thyroid. Note the deviation of the trachea to the right (black arrow) and the increase in soft tissue opacity in the lower left neck.

Sickle cell disease

- Sickle cell disease is a hereditary condition that results in a biochemical abnormality of haemoglobin resulting in the crystallization of haemoglobin at low oxygen tension and a resulting change in the shape and flexibility of the red blood cells.
- The abnormal red blood cells are unable to traverse the capillary bed of organs, become stuck and therefore embolize the blood supply.
- Sickle cell disease has widespread implications causing tissue ischaemia and infarction.
- On a CXR, infarcted areas of lung may present as areas of atelectasis. The chronic sequel of pulmonary hypertension may be evident through dilated proximal pulmonary arteries.
- Cardiomegaly is often found and infarcts in the skeleton are evident as areas of sclerosis and end plate depression of the vertebral bodies.

CXR signs of sickle cell disease (Fig 5.14, 5.15).

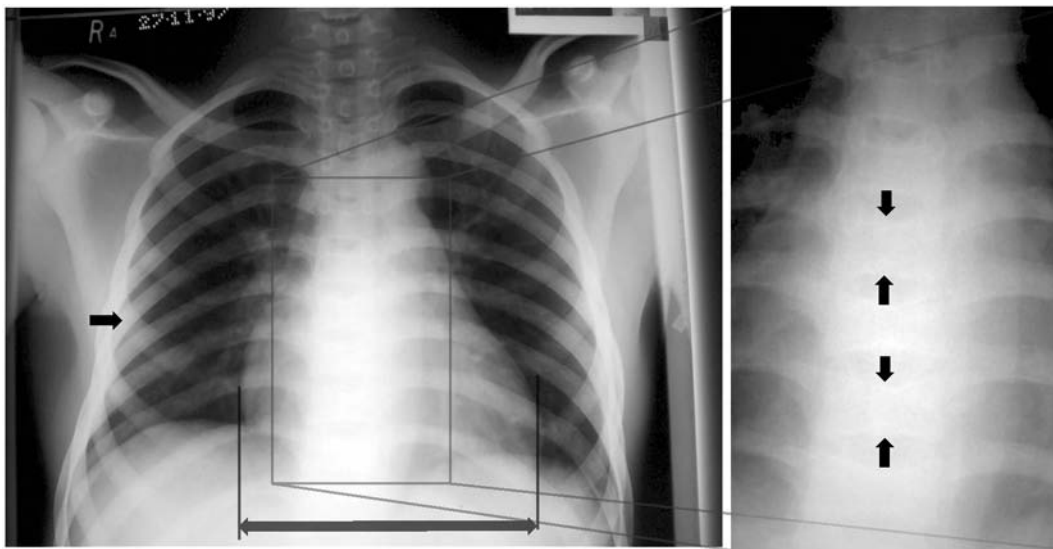


Figure 5.14

Frontal CXR of a patient with sickle cell disease. Note the cardiomegaly and sclerotic ribs due to small bone infarcts (horizontal black arrow). The magnified image demonstrates end plate depression (vertical black arrows) again due to bone infarcts.

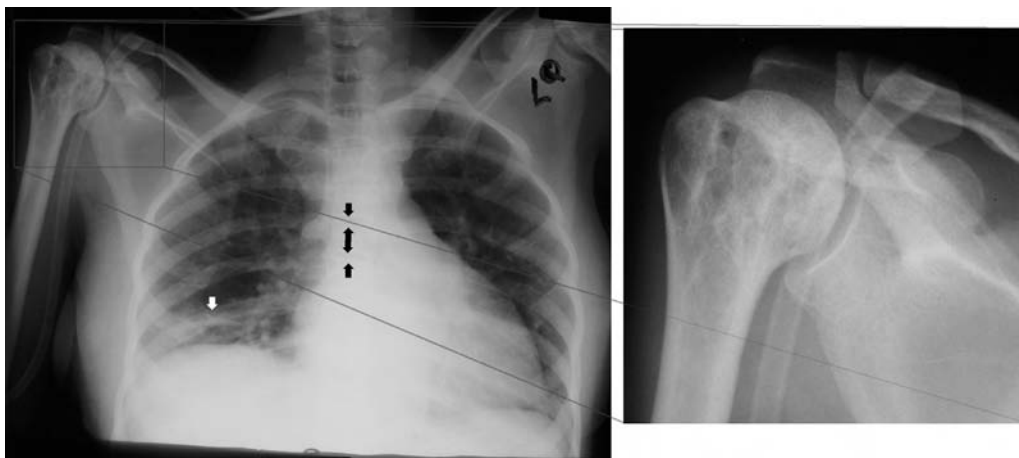


Figure 5.15

A second patient with sickle cell disease demonstrates cardiomegaly and end plate depression (black arrows). In addition to sclerotic ribs, there is focal sclerosis in the right humerus (magnified image) and band atelectasis in the right lung due to pulmonary infarction.

This page was left blank by the publisher.

Lung tumours

CXR features of malignant tumours

Ill-defined/spiculated margins

- A poor sign as pleurally based tumours may have ill-defined margins and malignant tumours that primarily metastasize via lymphatics and blood vessels may not have local invasion as a major component, and subsequently have well defined margins (Fig 6.1).

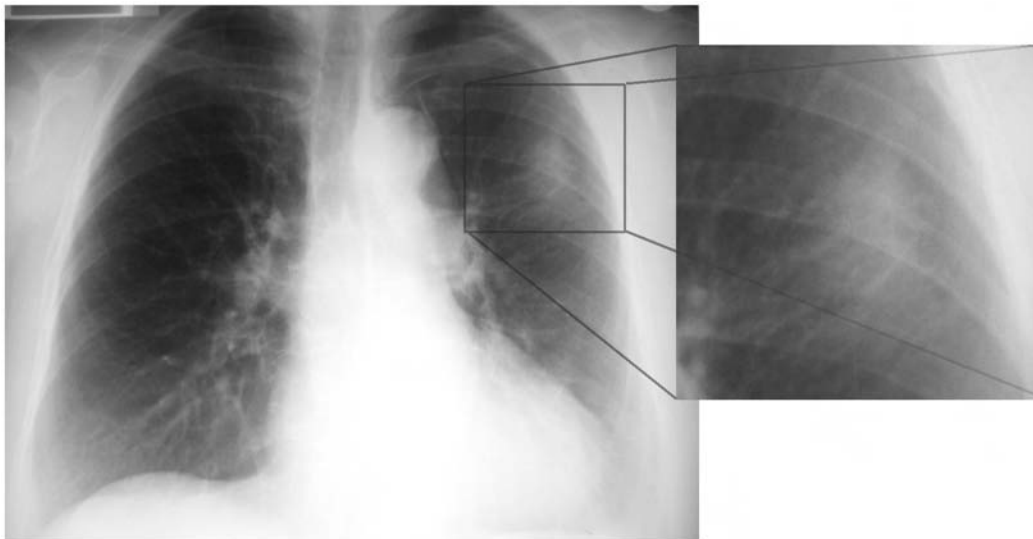


Figure 6.1

Frontal CXR of a patient with primary adenocarcinoma of the lung. Note in the magnified view, the poorly defined margins despite the size and intraparenchymal position of this tumour.

Rapid increase in size (Fig 6.2)

- A doubling of volume in less than 3 months is unlikely to be a neoplasm but more likely an infective or inflammatory process.
- Doubling times from 3 to 18 months are within the window for malignant lesions.

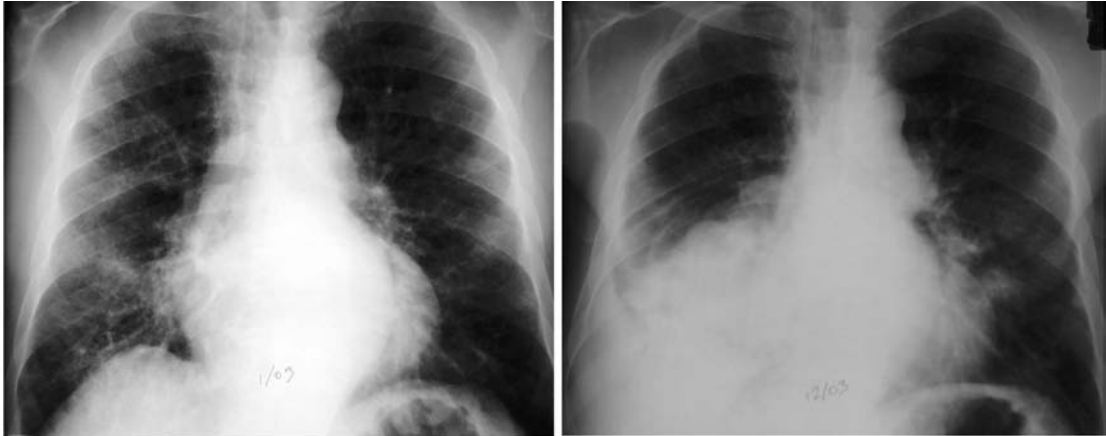


Figure 6.2
Frontal CXRs of an adult male taken 11 months apart. Note the rapid increase in size of the right lower lobe tumour.

Erosion of adjacent rib

- Erosion of an adjacent rib invariably indicates malignancy. Rarely, an infective process causing osteomyelitis could mimic this (Fig 6.3, 6.4).

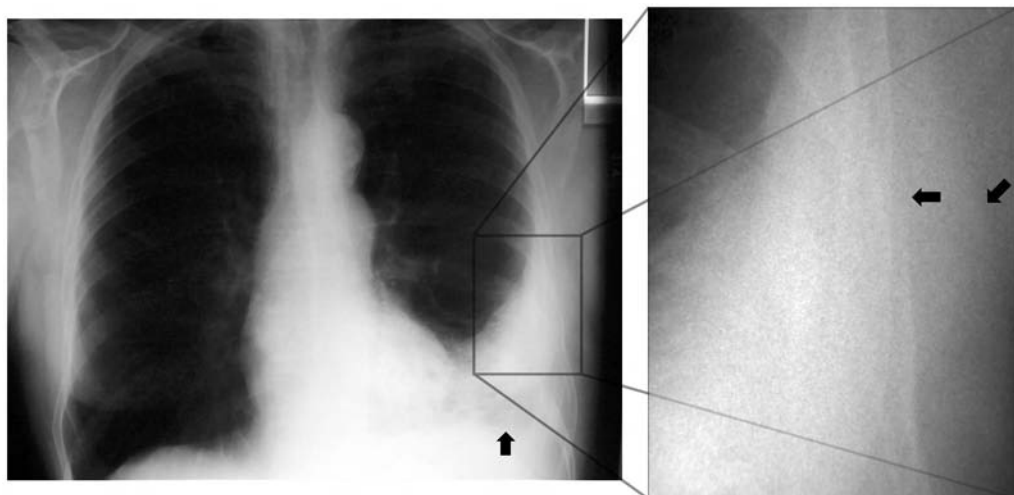


Figure 6.3
Frontal CXR of a patient with primary squamous cell carcinoma of the lung. Note the preservation of the diaphragmatic silhouette indicating that, although the increased opacity in the left lower zone has the appearance of a pleural effusion, this is not the case. Note on the magnified view, the erosion of an adjacent rib (horizontal black arrow) and a soft tissue mass extending outside the thoracic cavity (diagonal black arrow).

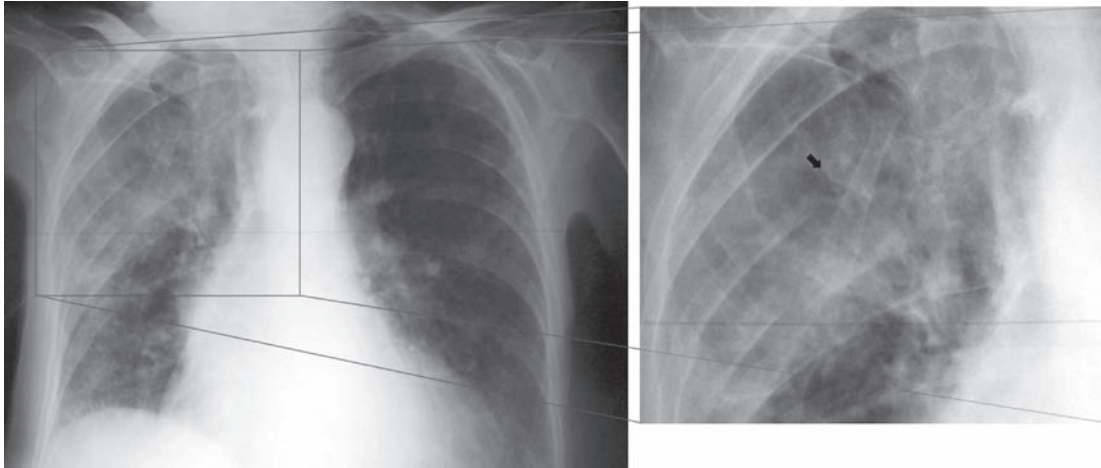


Figure 6.4

Frontal CXR of and adult male with primary adenocarcinoma of the right upper lobe. At first sight, the increased opacity in the right upper zone may be taken to represent developing consolidation. However, the presence of rib erosion (black arrow) reveals the underlying malignant pathology.

Presence of hilar/mediastinal adenopathy (Fig 6.5)

- The presence of hilar adenopathy on the same side as the lesion, or mediastinal adenopathy, increases the likelihood of a tumour, but equally many infections, particularly TB can present in this fashion.

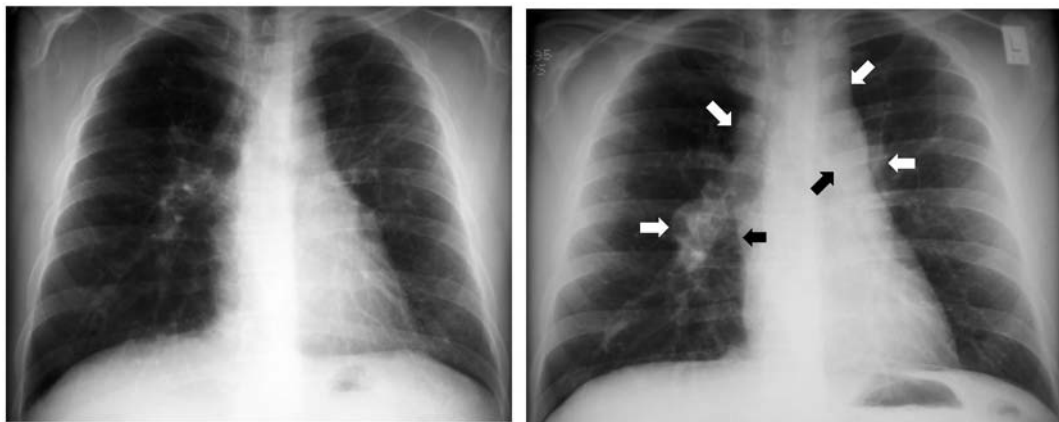


Figure 6.5

Two CXRs of the same patient with a bronchogenic carcinoma that is not readily seen on CXR. CXR at presentation – right hand image – demonstrates hilar adenopathy (horizontal white arrows), paratracheal adenopathy (diagonal white arrows), aorto-pulmonary window adenopathy (diagonal black arrow) and sub-carinal adenopathy, the right hand margin of which is just visible (horizontal black arrow). The left image is the CXR from a year previously, indicating that the diagnosis is new.

Presence of a pleural effusion on the side of the lesion (Fig 6.6)

- A poor sign as parapneumonic effusions are common and the solitary opacity may be a local pneumonia.
- However, in the context of possible malignancy, a malignant pleural effusion excludes surgical resection as a therapeutic option.

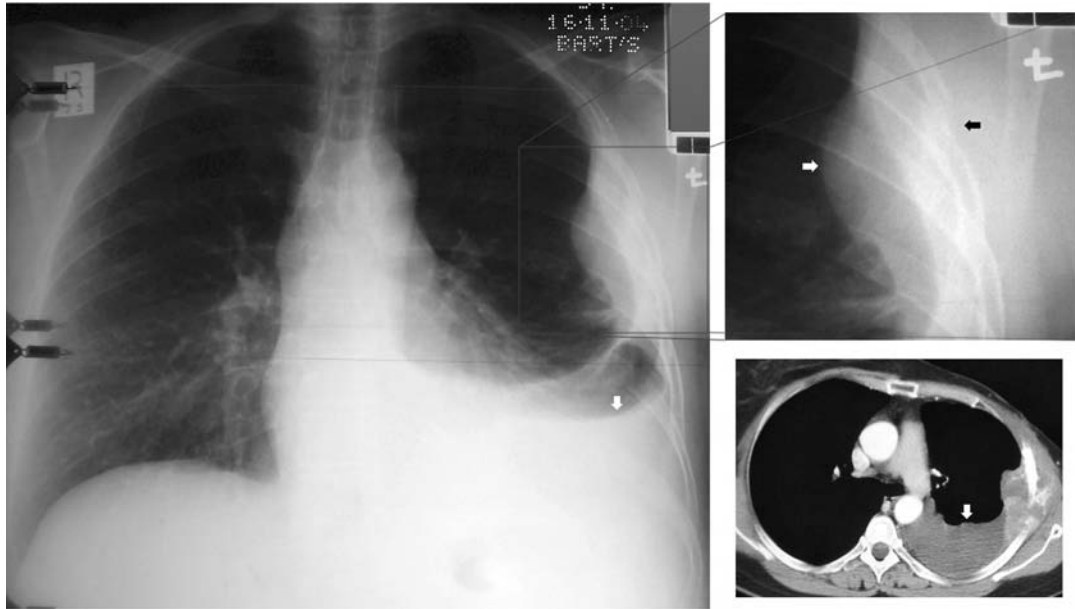


Figure 6.6

Frontal CXR of an adult female who has had a mastectomy and radiotherapy for a left breast carcinoma. She has now developed a sarcoma within the chest wall secondary to the radiotherapy (horizontal white arrow) and a reactive pleural effusion (vertical white arrow). Note the rib destruction to confirm the malignant nature of this lesion (black arrow).

Evidence of lymphangitis carcinomatosa (Fig 6.7)

- The radiologic finding of lymphangitis in relation to a solitary pleural opacity indicates lymphatic involvement by the tumour.

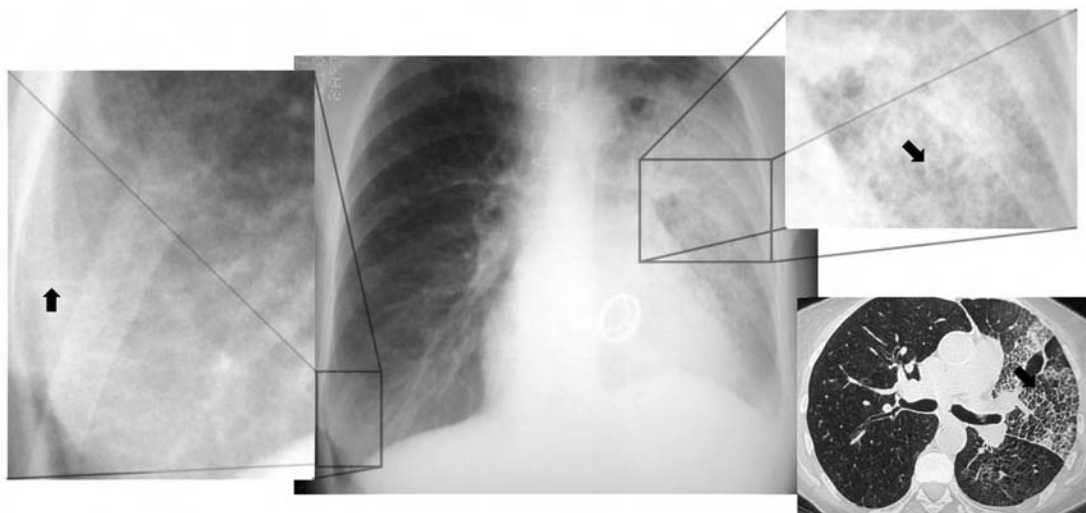


Figure 6.7

Frontal CXR of a patient with bronchogenic carcinoma. Note the consolidative appearance in the left upper zone, magnified image on the right and the corresponding section of the HRCT bottom right. The reticular pattern is due to secondary pulmonary lobules outlined by thickened septa congested with fluid and tumour cells. A similar process is beginning in the right lower zone left hand magnified image, where septal lines are evident (black arrow).

CXR features of benign tumours

Low density, high fat content

- The presence of fat within a lesion is a very strong indicator of a benign pathology, most likely a hamartoma.
- Low density may be difficult to appreciate on a plain CXR as surrounding soft tissue density will obscure the fat density. Plain film tomography may demonstrate fat within a lesion.

Calcification

- Calcification in small lesions (<2 cm) is a good indicator of a benign pathology but as lesion size increases, the likelihood of malignant tumour containing calcium, increases reducing the usefulness of calcification as a sign of benignity. When the calcification is marked with a “popcorn” like appearance the diagnosis of a hamartoma is usually correct (Fig 6.8).

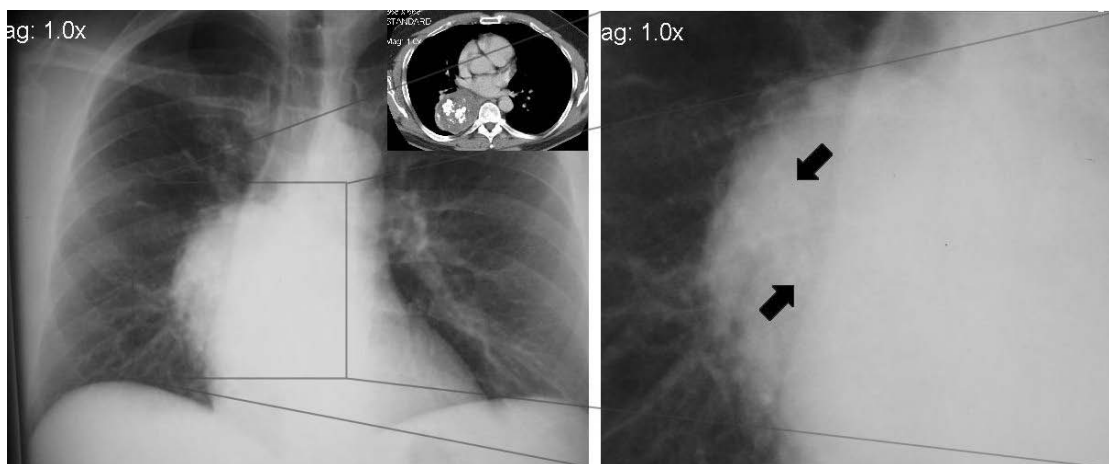


Figure 6.8
Frontal CXR of a patient with a large hamartoma. Note the popcorn calcification seen on the magnified view (black arrows) and the CT image (inset).

Slow or non-growing

- If a suspect lesion is seen to be static in growth over a period of 2 years, a benign pathology can be assumed; therefore previous imaging, if available, is invaluable.

Metastases

- Metastatic tumours may be single or multiple, but usually have well defined lobular margins with the primary mode of growth displacing rather than infiltrating the adjacent lung.
- Metastases may also be infiltrating in nature, resulting in less well-defined margins and, when solitary, can be difficult to distinguish from primary lung carcinoma.
- In the presence of two lesions, synchronous primary tumours are possible, but a primary plus a metastasis from that primary or two metastases, are far more likely.
- When there are three or more lesions, at least two will be metastases, unless the appearances are due to a benign cause of multiple nodules such as Wegener's, rheumatoid lung, sarcoidosis etc. (Fig 6.9).

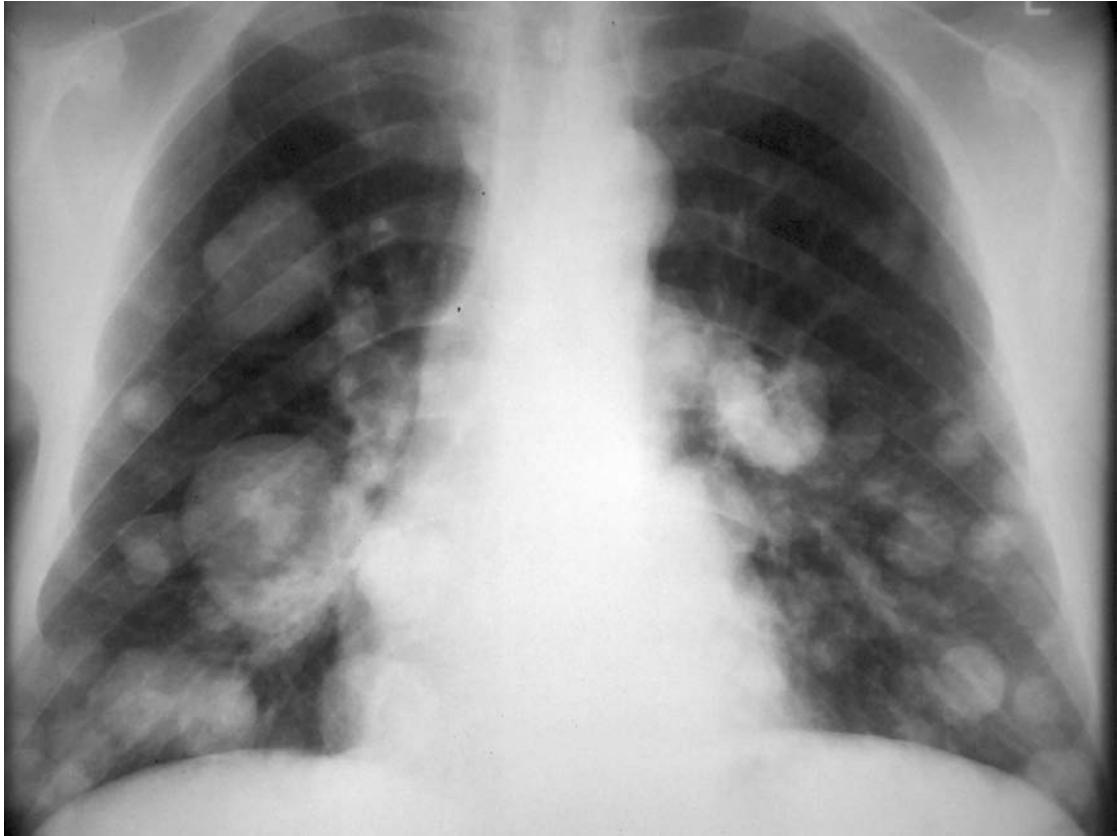

Figure 6.9
Frontal CXR of an adult male with metastatic renal cell carcinoma. Note the multiple well defined “cannon ball” metastases.

Bronchial carcinoma

For the purposes of treatment bronchogenic carcinoma can be conveniently divided into small cell lung cancer (SCLC) and non-small cell lung cancer (NSCLC).

Non-small cell lung cancer

- The NSCLCs are adenocarcinoma, squamous cell carcinoma and large cell carcinoma.
- When proximal, these tumour masses may cause obstruction of the airways resulting in distal collapse or consolidation (see Golden S sign earlier) (Fig 6.10).

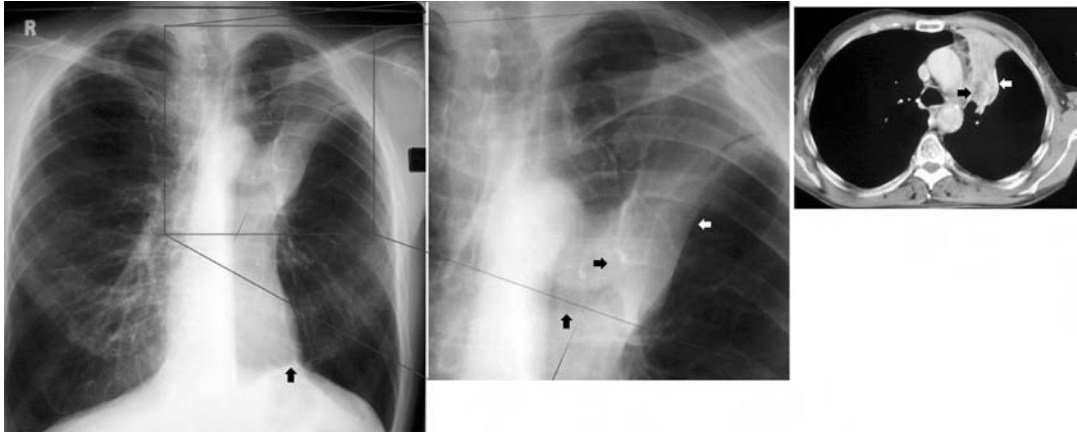


Figure 6.10

Frontal CXR of an adult male. The magnified view and CT image are marked to demonstrate a proximal soft tissue mass (horizontal black arrow) and the well defined lateral margin of the upper lobe collapse distal to the mass. Also note elevation of the left main bronchus and tenting of the left hemi-diaphragm (vertical black arrow) in keeping with upper lobe volume loss. Increased transradiancy of the left lower zone is due to compensatory over-expansion of the left lower lobe and note the preservation of the left heart border indicating the upper lobe collapse has not involved the lingula.

- Tumours less than 1 cm in diameter may not be visible on CXR.
- Cavitation is most likely to be found in squamous cell carcinoma. (Fig 6.11)

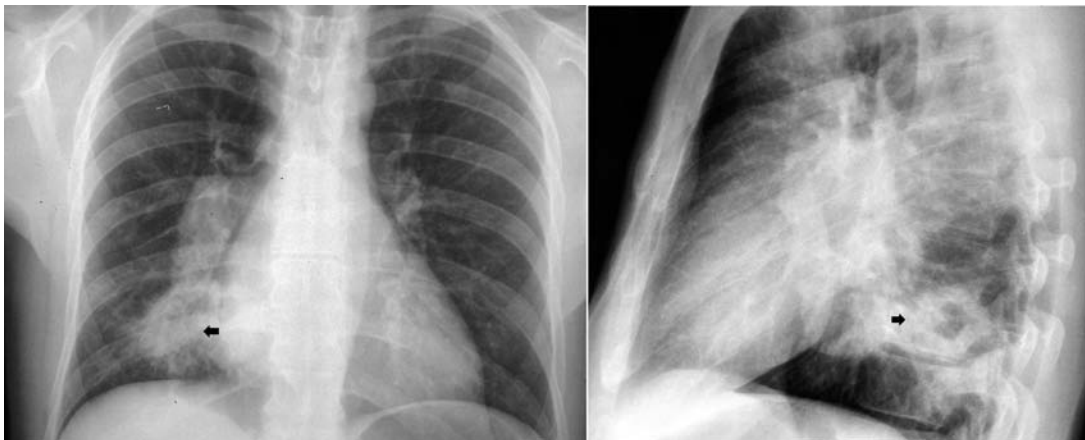


Figure 6.11

Frontal and lateral CXRs of an adult smoker with cavitating squamous cell carcinoma in the right lower lobe (black arrows).

- Synchronous primary lung cancers, although not common, are described. The less obvious of the two lesions may be missed due to satisfaction of search; when the observer stops looking once they find an abnormality (Fig 6.12).

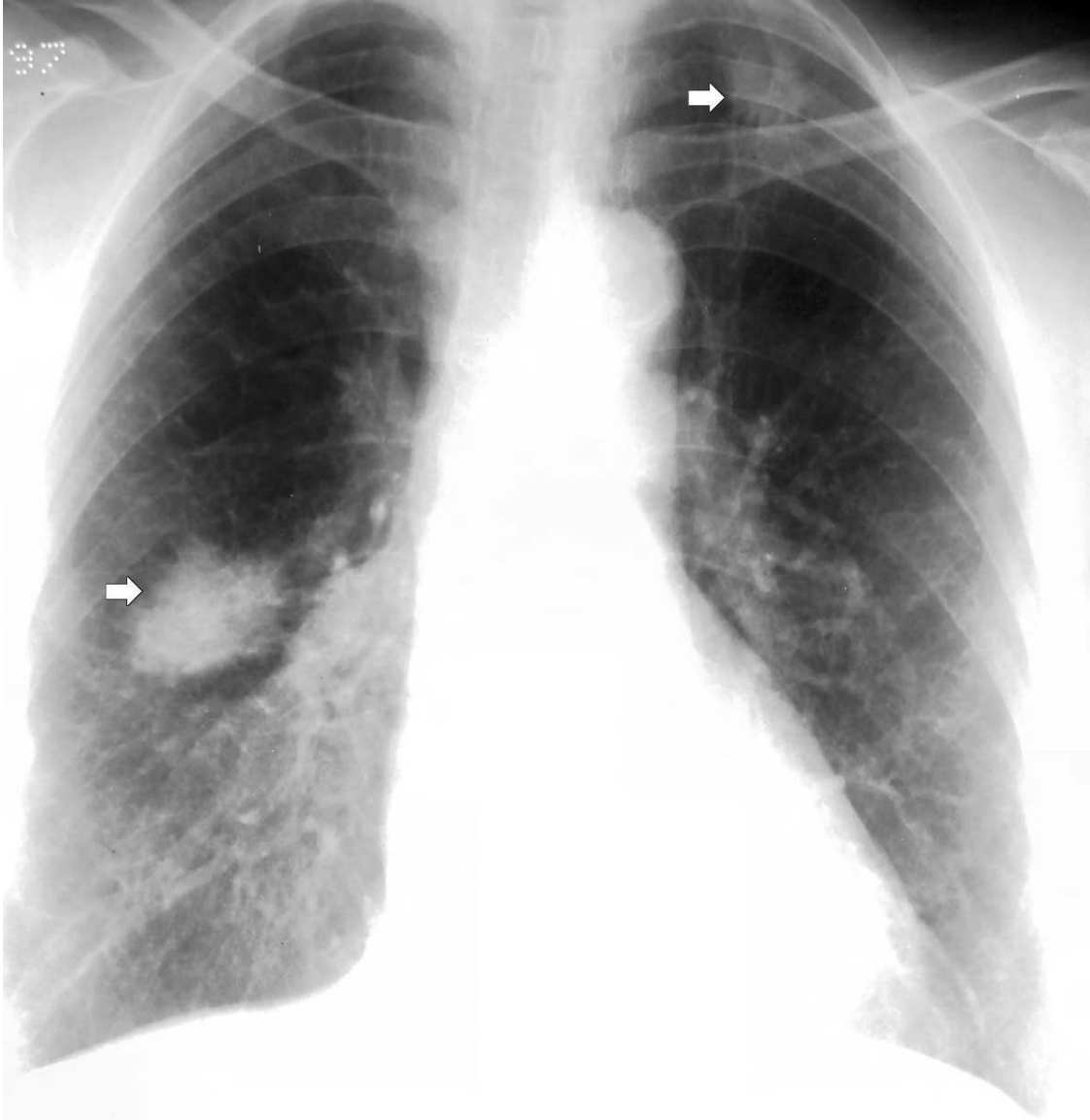


Figure 6.12

Frontal CXR demonstrating synchronous primary tumours (white arrows); an adenocarcinoma in the right lung and a squamous cell carcinoma in the left lung.

Small cell lung cancer

- SCLC tends to present with massive lymphadenopathy and/or distant metastases, CT brain is routine in the staging of this tumour.
- The primary tumour may not be identified despite large volume disease.
- On CXR, the distinction between NSCLC and SCLC is not possible, but gross mediastinal lymphadenopathy, out of proportion to the size of the primary tumour, should increase suspicion of a SCLC.

Non-mass like tumours

- Not all lung tumours present as nodules or masses.
- Alveolar cell carcinoma is an adenocarcinoma that may populate the airspaces causing the appearance of ground glass opacity and subsequently consolidation on CXR.
- The diagnosis should be considered in the presence of multi-focal consolidation or an area of consolidation that fails to resolve on appropriate antibiotic therapy (Fig 6.13).
- Lymphoma and metastatic adenocarcinoma are the other main tumours that may present in this fashion.

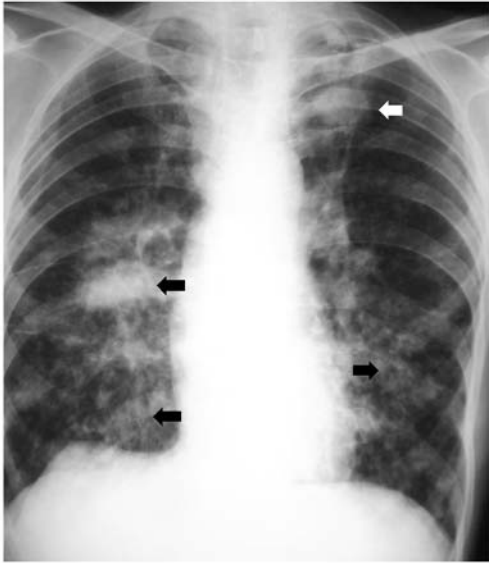


Figure 6.13

Frontal CXR of a patient with alveolar cell carcinoma demonstrates multifocal consolidation (black arrows) with a more mass like appearance in the left apex (white arrow).

Pleural tumours

- Tumours arising from the pleura characteristically have either ill-defined margins, or only defined margins on one side. The reason for this is the orientation of the edge of the mass with respect to the X-ray beam due to the contour of the pleura (Fig 6.14).

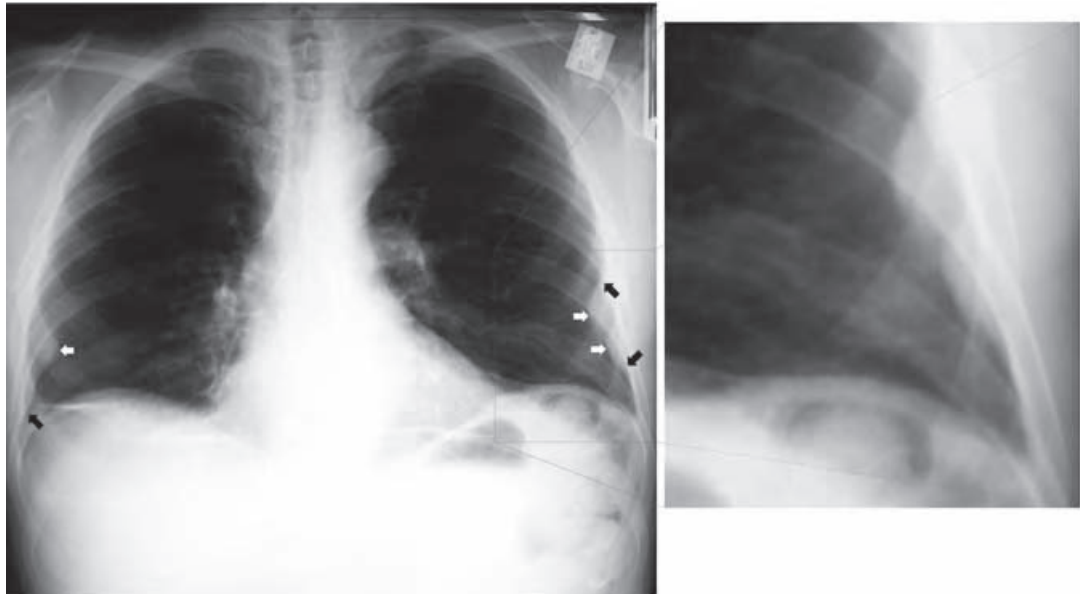


Figure 6.14

Frontal CXR of an adult male with pleural metastases. Note the well-defined medial margins (white arrows) and the angle the masses make with the internal chest wall (black arrows).

The solitary pulmonary nodule

- A soft-tissue, non-calcified nodule visible on a CXR will be at least 1 cm in diameter; smaller nodules are not readily seen.
- Numerous mimics of nodules, highlighted earlier under artefacts, should be excluded first.
- The likelihood that such a nodule represents a neoplasm is dependent on the patient's age, smoking history, underlying lung disease and history of other neoplasms, but patient history will not exclude a neoplasm.
- Ideally, the identification of the same nodule on a previous CXR showing no change in size over at least 18 months would confirm a benign aetiology.
- Heavy calcification in a solitary nodule indicates a benign aetiology.
- A watch and wait policy will attempt to identify significant growth, i.e. a volume doubling time of 3–18 months.
- A doubling in volume results in a 26% increase in diameter, i.e. a 1 cm nodule will measure 1.26 cm after doubling in volume, but this may take 18 months.
- In general, if facilities allow, solitary pulmonary nodules visible on a CXR and lacking any indication of a benign aetiology, should be imaged further with CT scanning.

Further imaging

- If an overlying rib obscures the suspected lesion, a lordotic view will project the ribs in a different place.
- A lateral film may be of benefit.
- In the absence of CT, plain film tomograms may identify benign type appearances, such as calcification or fat.

Pneumonias

Bacterial pneumonia

- Bacterial pneumonia is the growth of pathogenic bacteria within the lung.
- Centred on the air-spaces, a pneumonia initially causes a vague increase in lung parenchymal density (ground glass opacity). Then, as the air-spaces become filled with pus, consolidation results.
- Clues to the possible infecting organism may be gleaned from the distribution of the consolidation, the presence of cavitation and evidence of endobronchial spread.

Mycobacterial pneumonia

Pulmonary tuberculosis

- Pulmonary tuberculosis is caused by *M.tuberculosis*.
- The radiologic appearances depend upon whether it is a primary infection, re-activation or re-infection.
- Primary TB typically presents with consolidation, most commonly in the mid and upper zones. (Fig 7.1)

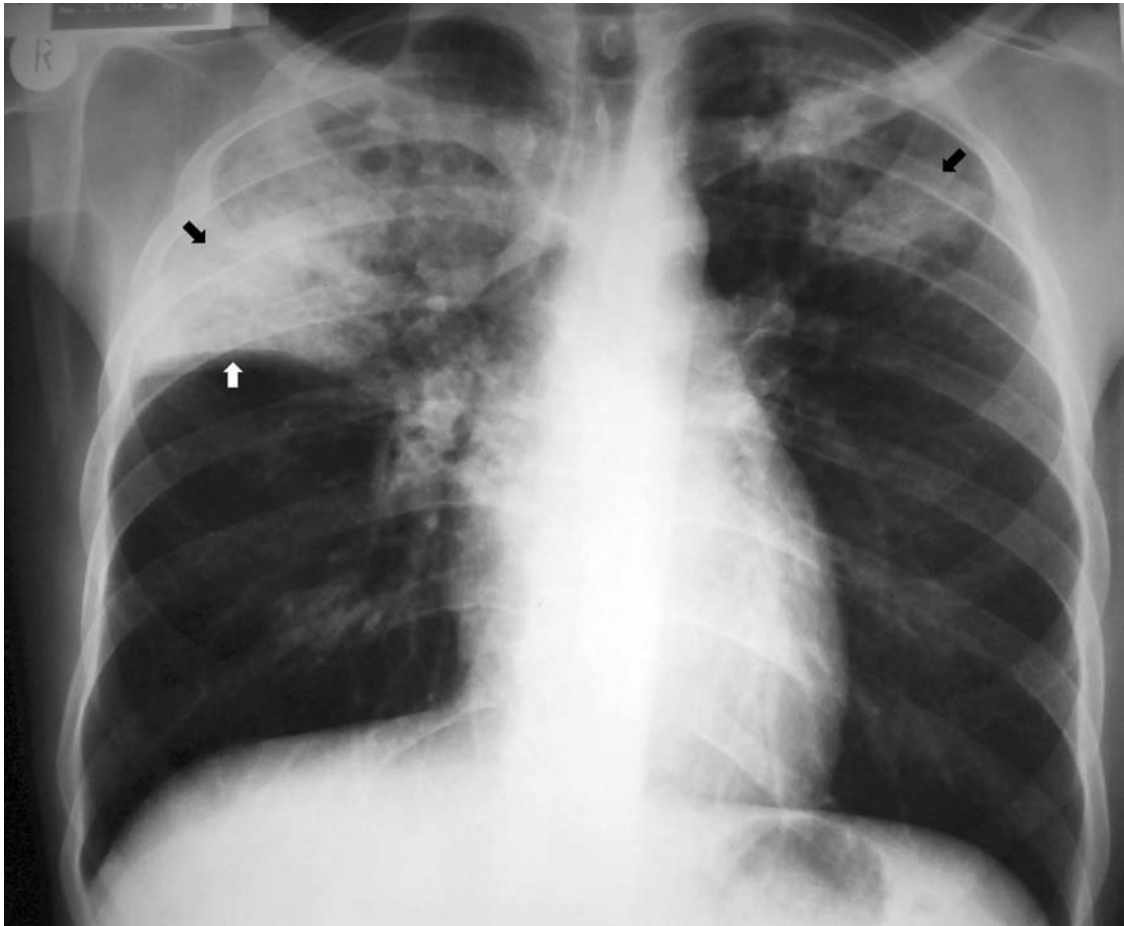


Figure 7.1

Frontal CXR of an adult male with primary, smear positive, pulmonary TB. There is bilateral upper lobe consolidation (black arrows) with the lobar distribution confirmed on the right by the demarcation of the minor fissure.

- Endobronchial spread may be the only radiologic manifestation and can be very subtle in degree, therefore careful scrutiny of the CXR of a TB contact should be routine practice (Fig 7.2).
- Lymphadenopathy is usually evident on CXR (Fig 7.3).

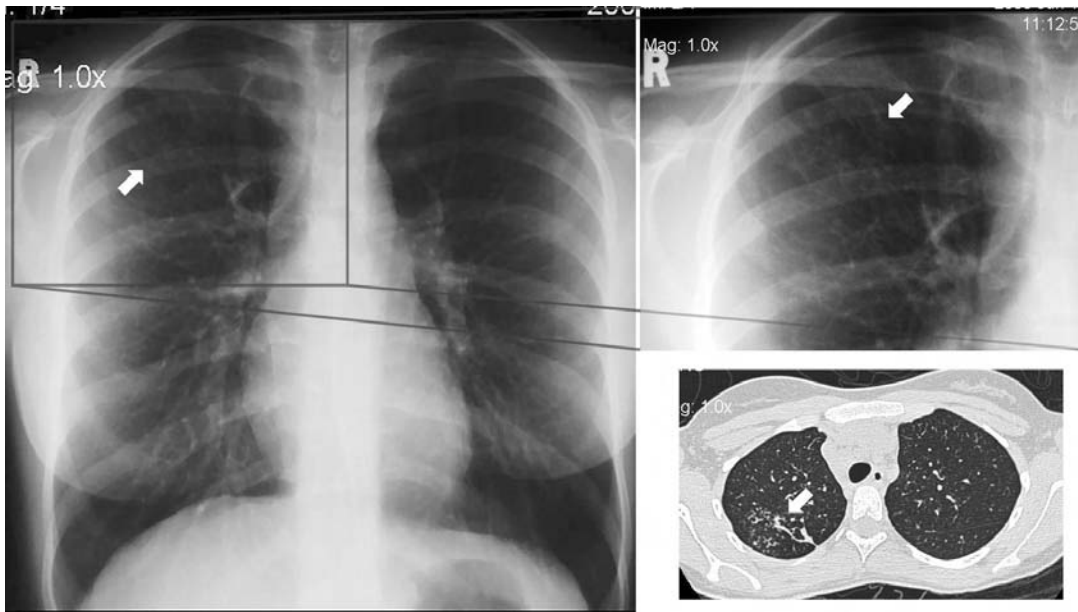


Figure 7.2

Frontal CXR of a young adult female who had been in contact with an index case of pulmonary TB. Note the asymmetry between the appearances of the upper zones. On the magnified image, the opacity in the right apex is mainly nodular. HRCT through that area confirmed a “tree in bud” pattern found when small airways are plugged and confirmed in this case to be due to TB.

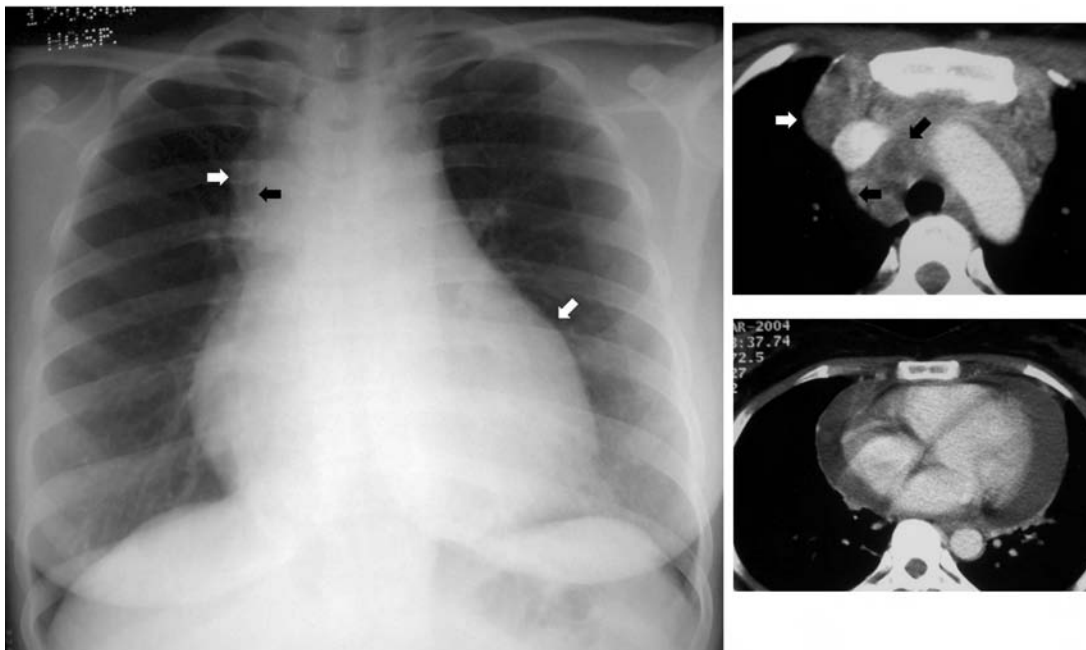


Figure 7.3

Frontal CXR of an adult female with tuberculosis. Note the widened paratracheal stripe (horizontal black arrow) and outside that the lateral margin of the superior mediastinal adenopathy (horizontal white arrow), the anatomy giving rise to these lines are marked on the upper CT image. Note also on the upper CT image the peripheral enhancement and central necrosis characteristic of TB lymphadenopathy (diagonal black arrow). This patient has an associated pericardial effusion (lower CT image) causing the loss of the normal concavity seen in the left heart border at the site of the left atrial appendage (diagonal white arrow) and an overall globular shape.

- The disease is usually self-limiting, but resolution takes 6–12 months and residual scarring is common (Fig 7.4).
- Post-primary TB results from re-activation or less commonly re-exposure.
- There is overlap with primary TB on CXR, but the absence of lymphadenopathy and more frequent cavitation are useful indicators (Fig 7.5).
- Haematogenous spread of TB may lead to miliary TB presenting with diffuse nodules throughout the lungs (Fig 7.6).

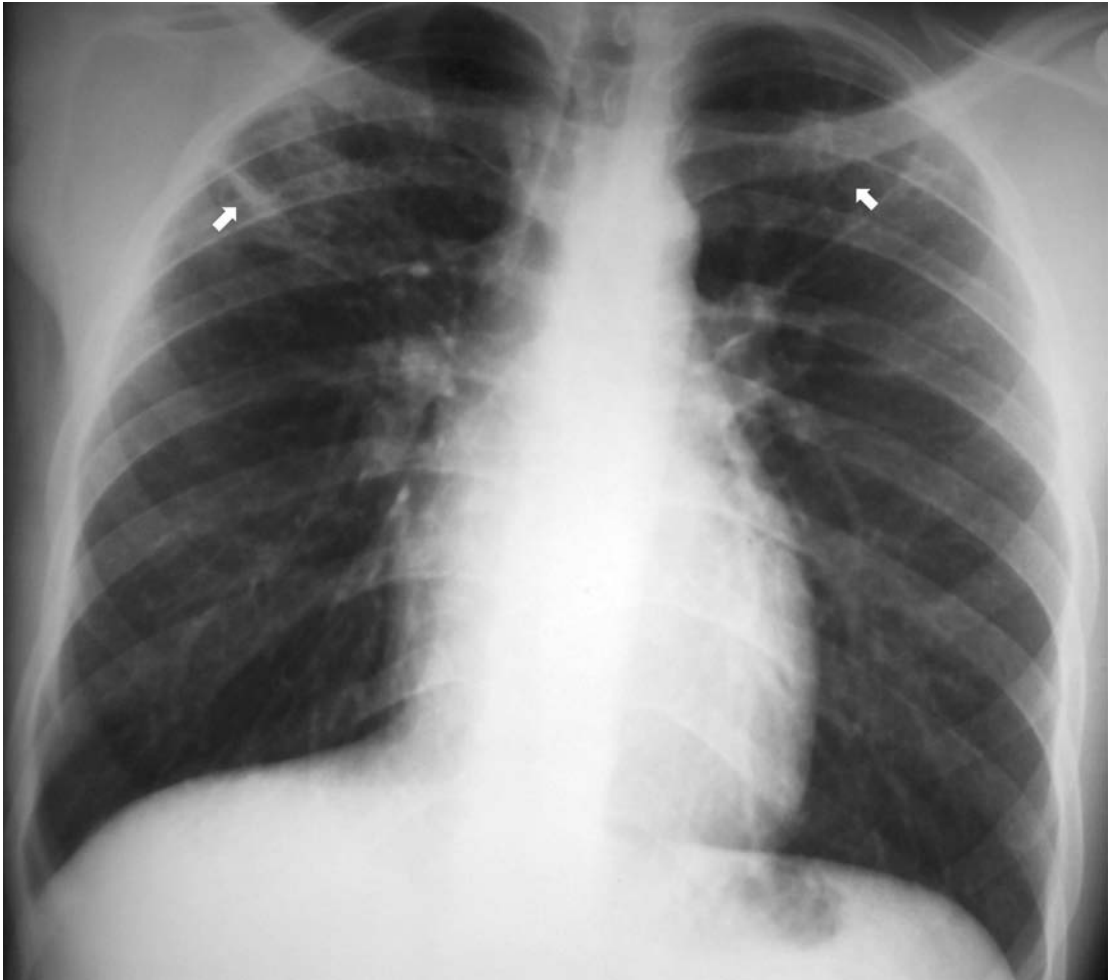

Figure 7.4

Frontal CXR of the same patient as above following treatment for TB. The consolidation has resolved, but residual fibrotic scarring remains in both apices (white arrows).

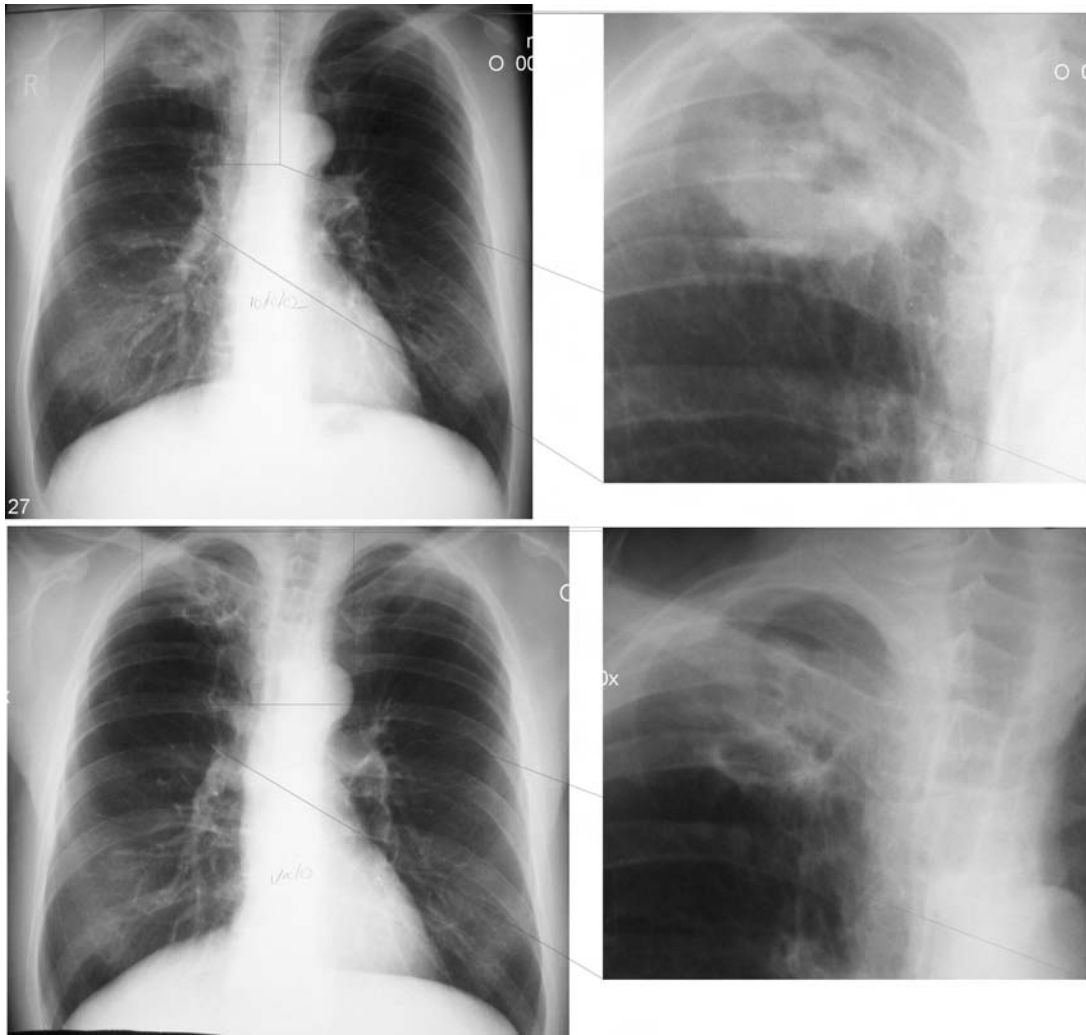


Figure 7.5

Frontal CXRs of an adult male with pulmonary TB. The upper image demonstrates a cavitating soft tissue lesion in the right apex, but no lymphadenopathy. The lower image was taken following 6 months of treatment. The lesion has almost completely resolved, but a residual cavity and adjacent scarring remain.

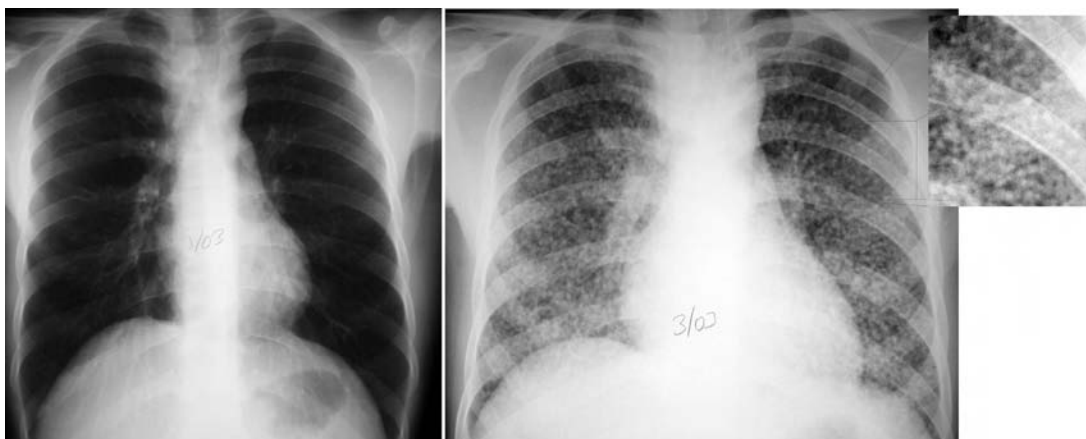


Figure 7.6

Frontal CXRs of an adult male. On the right hand image there are small nodules spread throughout the lungs all in the region of 2–3mm in size. The patient was culture positive for pulmonary TB. Note the left hand image of a CXR taken 2 months earlier, when the patient was developing symptoms of pulmonary TB, but there were no signs of this on the CXR.

Non-tuberculous mycobacteria (NTM)

- There are numerous NTMs that cause disease in humans; the commonest are listed in table 7.1

Table 7.1 **Most common species of NTMs that cause pulmonary disease in humans**

Species of mycobacterium

M.avium-intracellulare

M.kansasii

M.xenopi

M.fortuitum

M.chelonae

- *M.kansasii* and *M.xenopi* infections are indistinguishable from pulmonary TB (Fig 7.7).

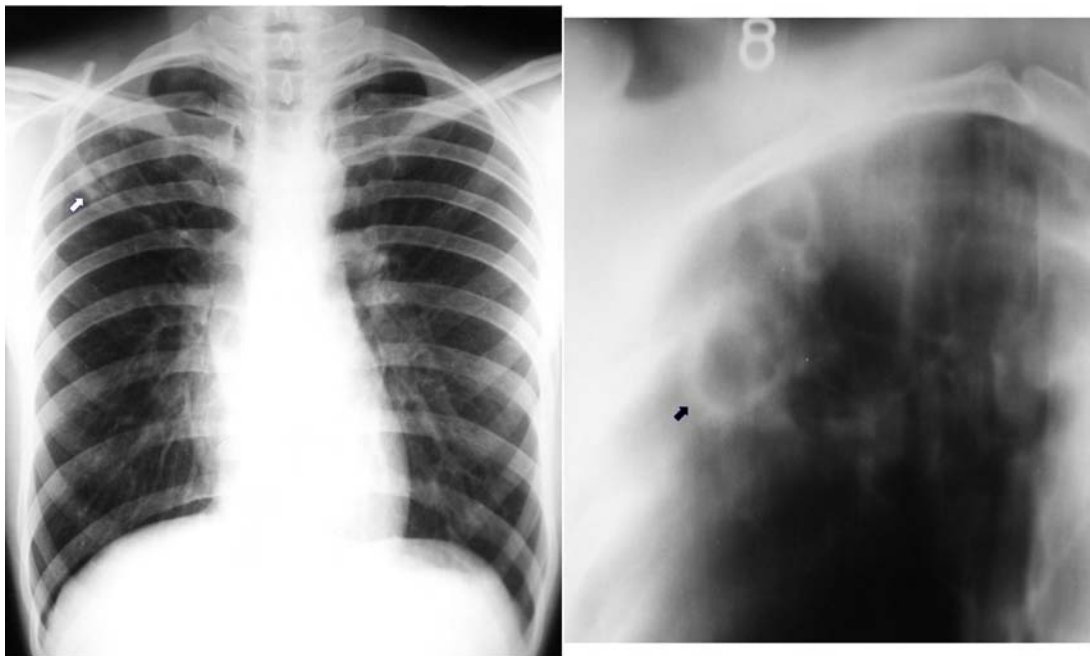


Figure 7.7

Frontal CXR and a plain tomogram of the chest of an adult male with *M.kansasii* infection in the right apex. Note the patchy parenchymal opacification and the thick walled (black arrow) cavitating lesions (white arrow) indistinguishable from pulmonary TB. (Images courtesy of Janet Dacey)

- *M.avium-intracellulare* may be found, but when pathological it tends to produce scattered nodularity and consolidation. Cavitation is a less frequent feature and there is often associated “tree in bud pattern”, but this is not readily appreciated on CXR (Fig 7.8).

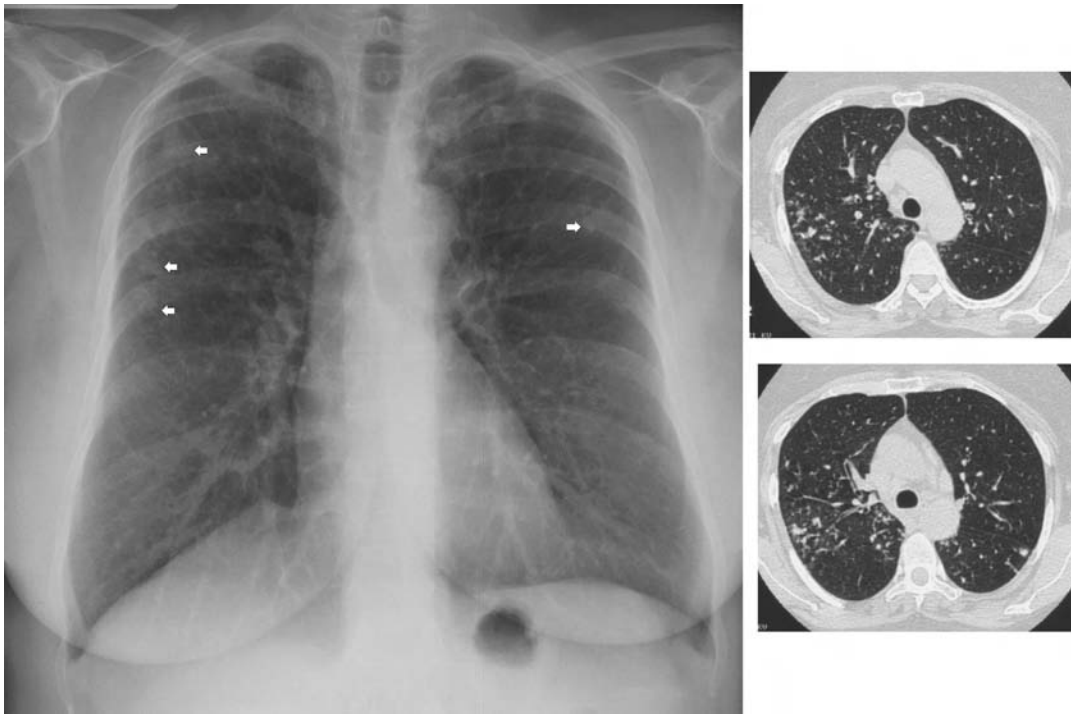


Figure 7.8

Frontal CXR of an adult female with culture confirmed *M.avium-intracellulare* infection. Note the ill defined nodularity in the mid zones (white arrows), which on the CT images are more evident and in places resolve into a “tree in bud” appearance indicating endobronchial disease.

- *M.fortuitum* appears to prefer an acidic environment and has been associated with aspiration, radiographically presenting with lower zone consolidation.

Pneumococcal pneumonia

- Pneumococcal pneumonia due to infection tends to give rise to lobar or segmental consolidation, often with an associated pleural effusion (Fig 7.9).

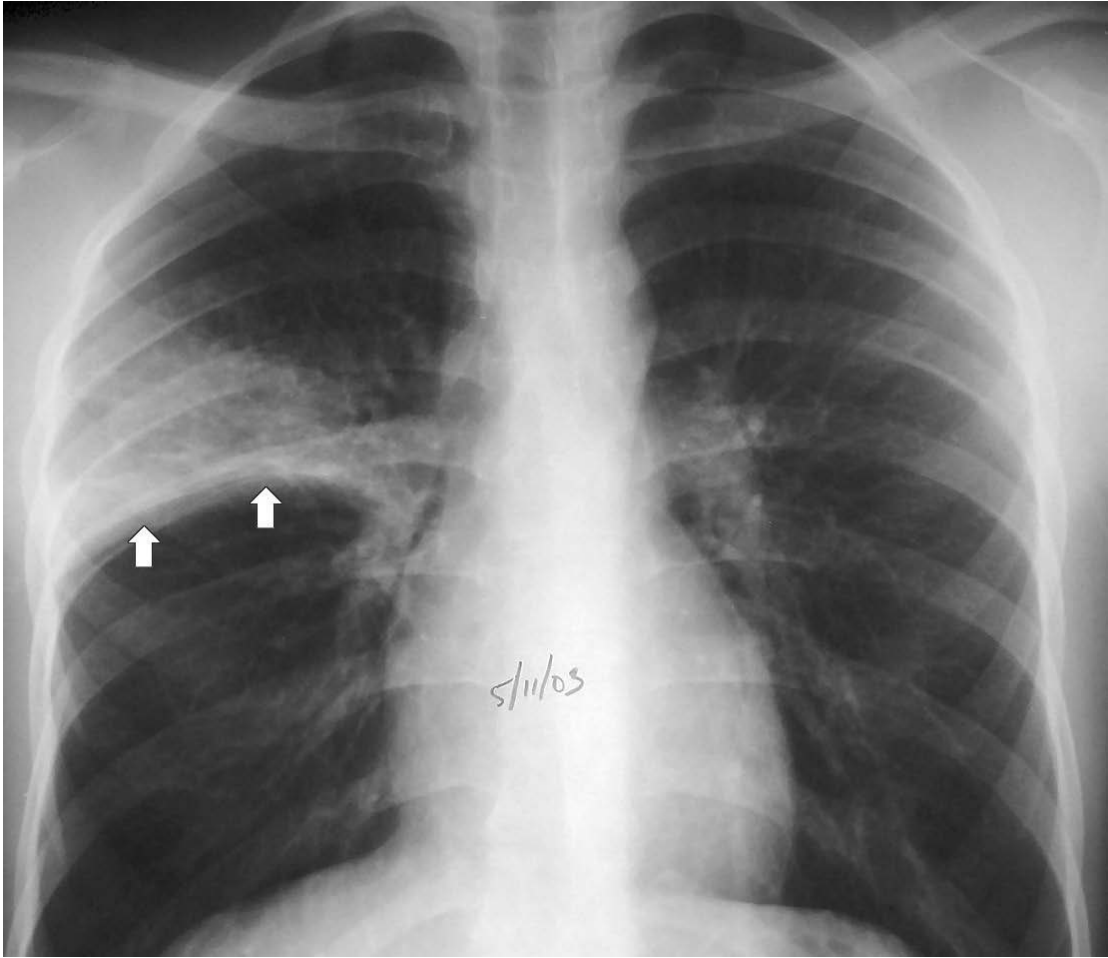


Figure 7.9
 Frontal CXR of an adult male with pneumonia confined to the anterior segment of the right upper lobe. Note the inferior demarcation by the minor fissure (white arrows).

Staphylococcal pneumonia

- Infection by *staphylococcus aureus* giving rise to consolidation not necessarily restricted to lobar or segmental anatomy.
- Complicated by abscess formation, cavitation, empyema and pneumothoraces. (Fig 7.10)

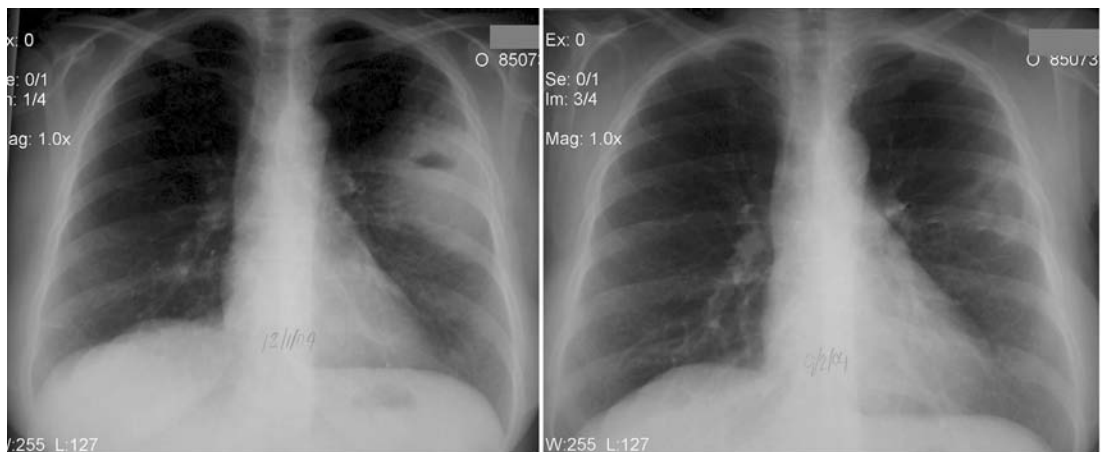


Figure 7.10
 Frontal CXRs of an adult female with a staphylococcal pneumonia taken 1 month apart. Note the cavitating consolidation in the left mid zone (left image) resolving on treatment (right image).

- A long-term sequel is a pneumatocele. The appearance is similar to that of a cavity, but thin walled with no adjacent lung parenchymal opacity to suggest active inflammation (Fig 7.11).

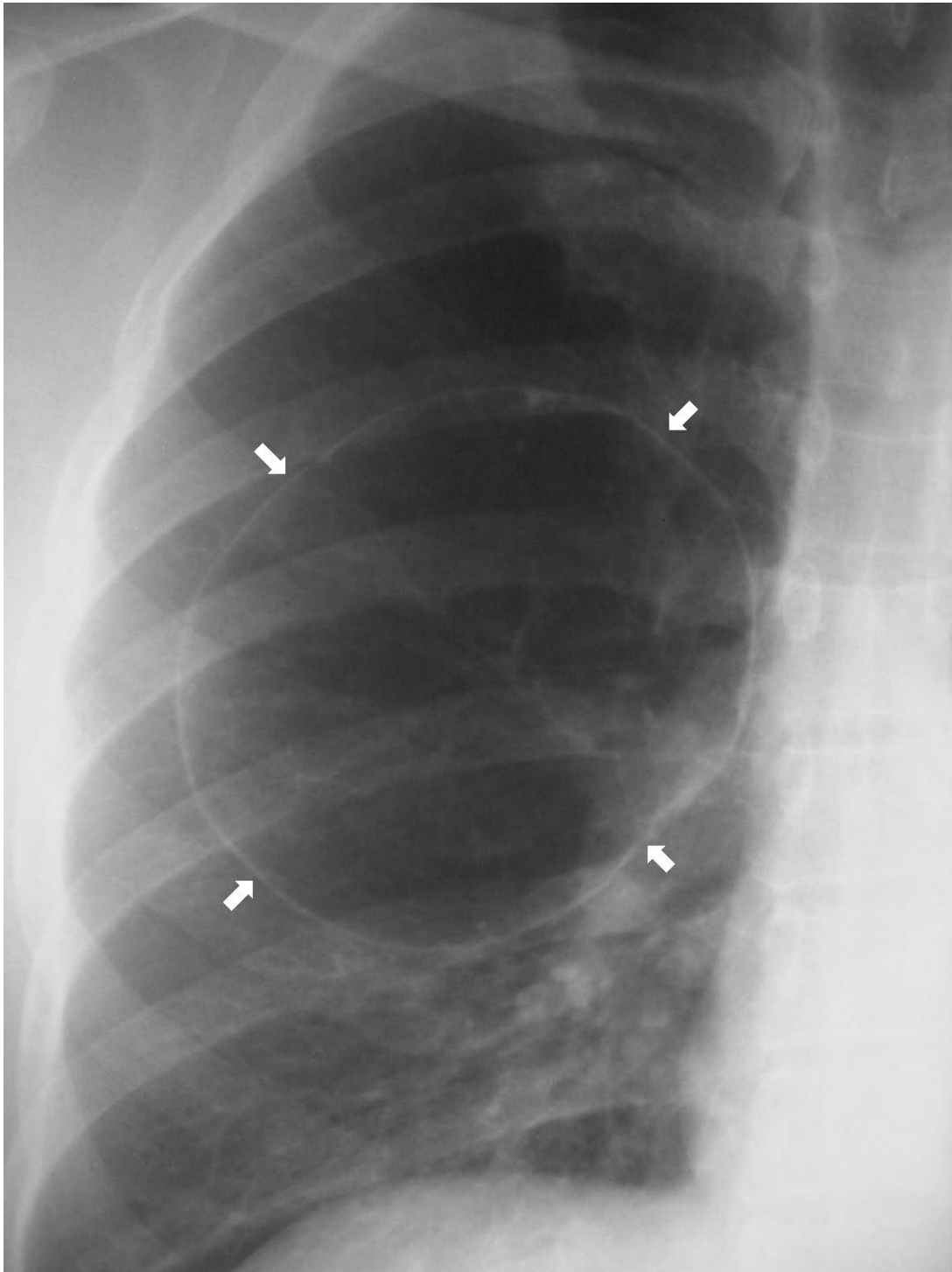


Figure 7.11

A pneumatocele in a patient who had had a staphylococcal pneumonia as a child. Note the thin wall, the entirety of which is visible (white arrows), unlike the wall of a bulla.

Klebsiella pneumonia

- *Klebsiella aeriginosa* causes a similar pneumonia to staphylococcus, favours the upper lobes, with a destructive inflammation, bulging of fissures, abscess formation and subsequent cavitation through fibrous resolution similar to pulmonary TB (Fig 7.12).

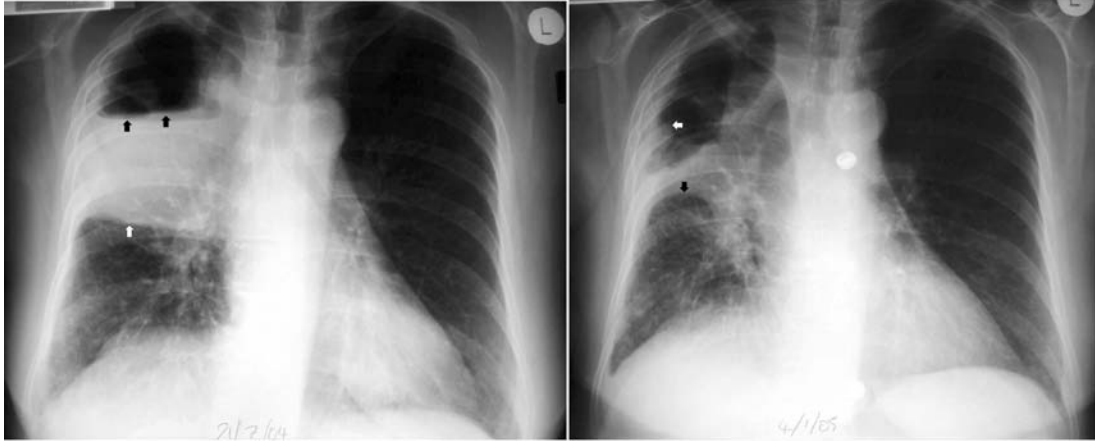


Figure 7.12

Frontal CXRs of an adult female taken 6 months apart. On the initial CXR (left) there is a large abscess within the right upper lobe (black arrows vertical up) and bulging of the horizontal fissure (white arrow vertical up). On the subsequent CXR (right) there remains a thick-walled cavity (horizontal white arrow) and upward bowing of the minor fissure (black arrow vertical down) indicating fibrosis.

Eosinophilic pneumonia

- Eosinophilic pneumonia describes the accumulation of eosinophil-rich material in the air-spaces resulting in consolidation.
- The characteristic finding is of flitting consolidation; the consolidation comes and goes over time in different areas of the lung (Fig 7.13).

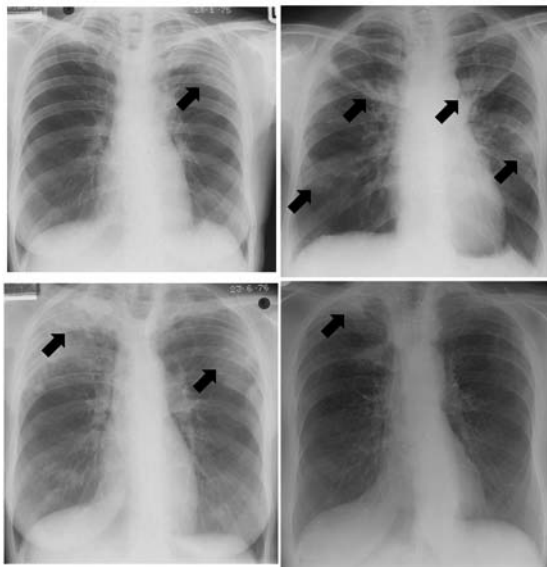


Figure 7.13

A sequence of 4 CXRs of a patient with eosinophilic pneumonia taken over a period of 18 months. Note how the areas of consolidation vary in site (black arrows). The flitting consolidation is typical of eosinophilic pneumonia.

Organizing pneumonia

- Organizing pneumonia is a non-infective entity. Inflammatory tissue growing into the distal air spaces and the interstitium causes consolidation (Fig 7.14).
- The associations of organizing pneumonia are given in Table 7.2.
- Usually, peripheral may be multifocal and/or flitting in nature.
- The distinction between organizing pneumonia and an infective pneumonia cannot readily be made on a plain CXR (or CT scanning) and the diagnosis is usually delayed as a result.

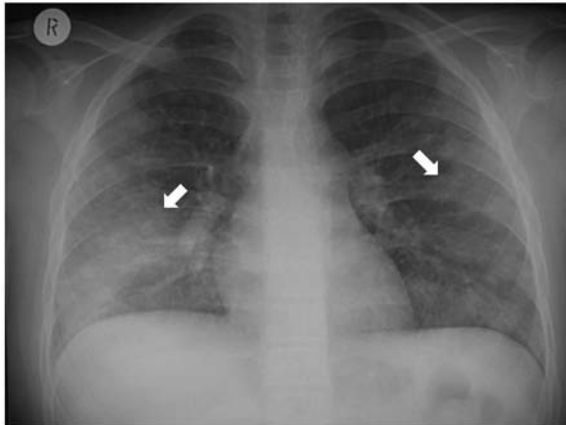


Figure 7.14

Frontal CXR of a patient with cryptogenic organizing pneumonia. The diagnosis was finally made on open lung biopsy following the failure of numerous courses of antibiotics. Note the patchy consolidation (white arrows).

Table 7.2 **Associations of organizing pneumonia**

INFECTION

Bacterial e.g. *streptococcus pneumoniae*, *legionella pneumophila*

Viral e.g. Adenovirus, CMV, Influenza, Parainfluenza, HIV

DRUGS

Antibiotics e.g. amphotericin B, cephalosporins, minocycline

Others e.g. sulfasalazine, bleomycin, amiodarone

CONNECTIVE TISSUE DISORDERS

e.g. systemic lupus erythematosus, rheumatoid arthritis, Sjogren syndrome

IMMUNOLOGICAL DISORDERS

e.g. common variable immunodeficiency syndrome, essential mixed cryoglobulinaemia

ORGAN TRANSPLANTATION

e.g. bone marrow, lung, renal

MISCELLANEOUS

e.g. inflammatory bowel disease, primary biliary cirrhosis, polyarteritis nodosa, haematological malignancies, radiotherapy.

The immunocompromised patient

- In the immunocompromised patient, the patterns of pneumonia already described, are less likely to assist in a diagnosis. Furthermore, normally non-pathogenic organisms may become pathogenic, increasing the range of possible infecting agents; in particular, pneumocystis jiroveci pneumonia (previously known as pneumocystis carinii pneumonia) (Fig 7.15) and fungal infections (Fig 7.16).

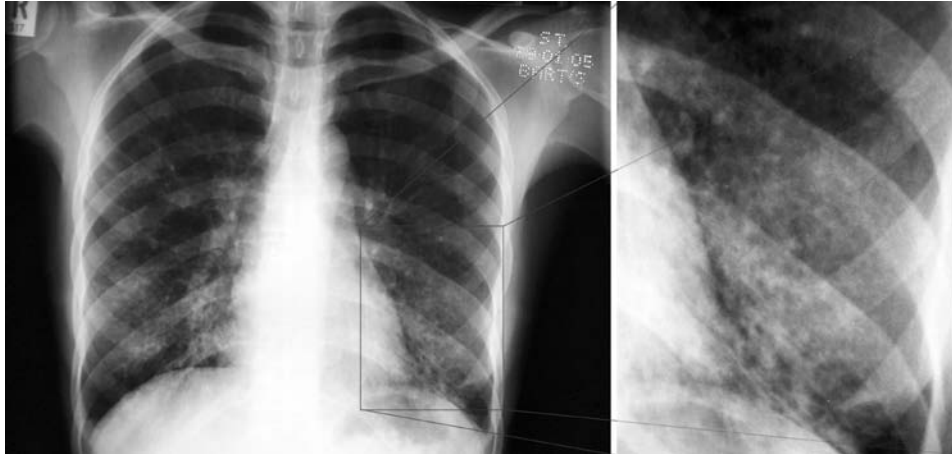


Figure 7.15

Frontal CXR of an immunocompromised patient with pneumocystis jiroveci pneumonia. Note in the magnified image a ground glass opacity with some nodular elements tending towards confluence/consolidation. The appearances are non-specific.

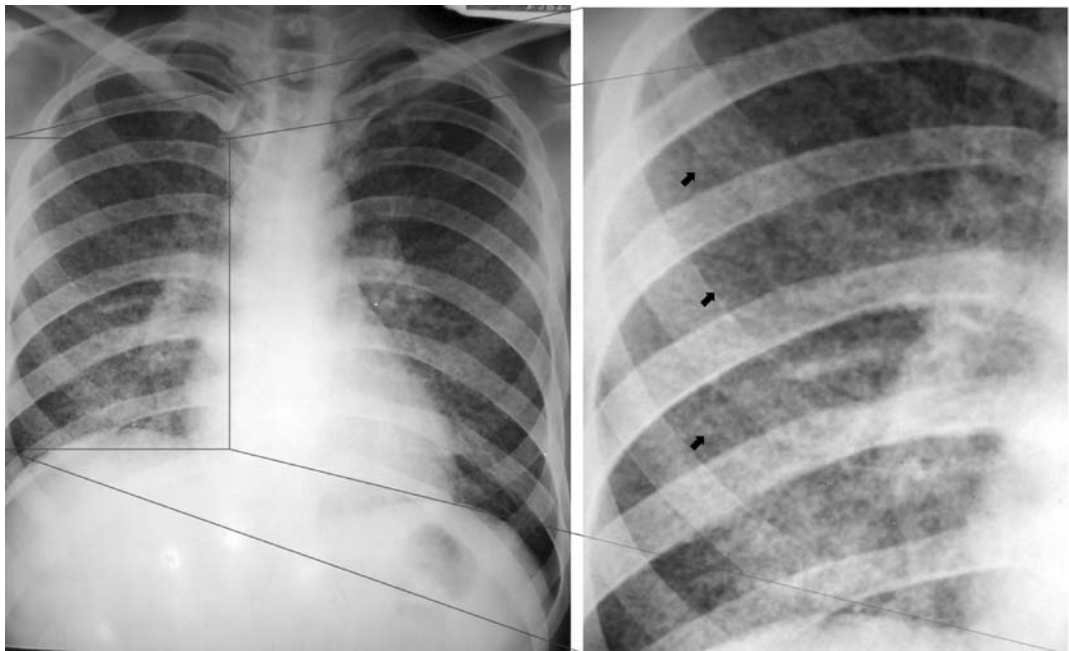


Figure 7.16

Frontal CXR of an immunocompromised adult patient with signs and symptoms of infection. Note the diffuse nodularity (black arrow) as a result of infection with histoplasmosis. (Images courtesy of Janet Dacey).

Chronic airways disease

Asthma

Most asthmatics have a normal CXR, but a few have large volume lungs.

Asthmatics are prone to spontaneous pneumothorax, pneumomediastinum (Fig 8.1) and mucous plugging which may cause lung opacification and collapse (Fig 8.2).

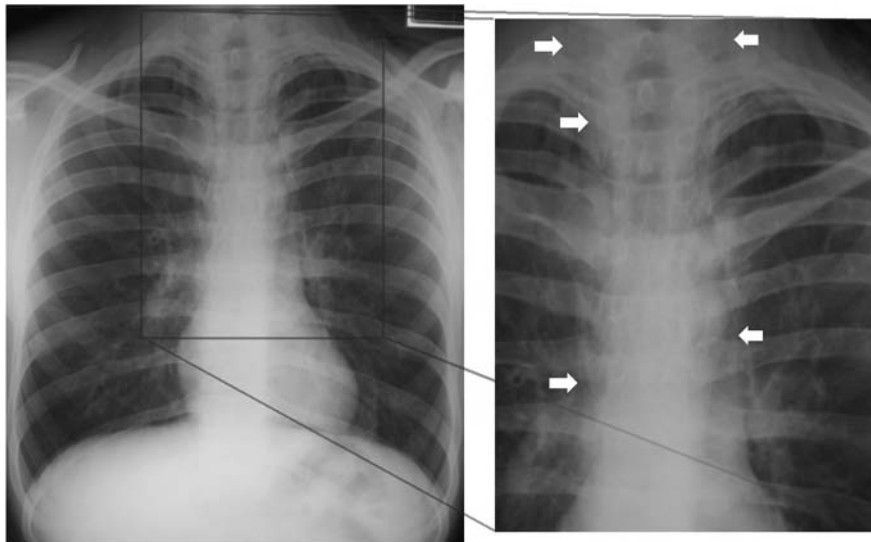


Figure 8.1

Frontal CXR of a patient with asthma who has developed a spontaneous pneumomediastinum. Note the air outlining the upper mediastinal structures and extending into the root of the neck (white arrows).

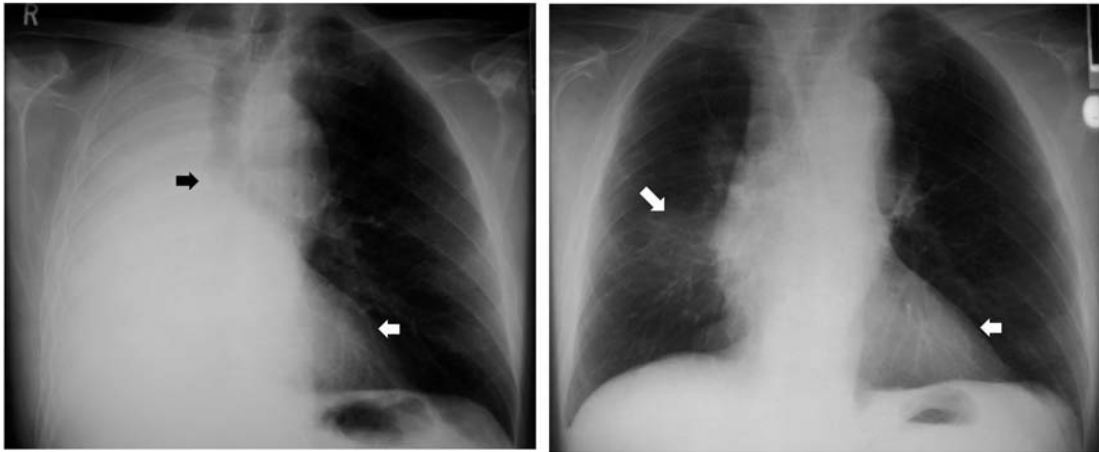


Figure 8.2

Two sequential frontal CXRs of a patient with asthma. Right image demonstrates complete opacification of the right hemithorax, but also mediastinal shift to the right (white arrow) indicating the cause is collapse of the lung and not a large pleural effusion, which would tend to shift the mediastinum the other way. The cause is a plug of mucous in the right main bronchus (black arrow) and following removal at bronchoscopy, there is re-expansion of the lung (left image) return of the mediastinum to a more central position (white arrow) and just a small residual area of consolidation (diagonal white arrow).

Chronic bronchitis

- Chronic bronchitis is a disease primarily associated with smoking and, when severe, may be evident on a CXR through the associated bronchial wall thickening, causing the bronchovascular markings to be more obvious and perceived further from the hila (Fig 8.3).

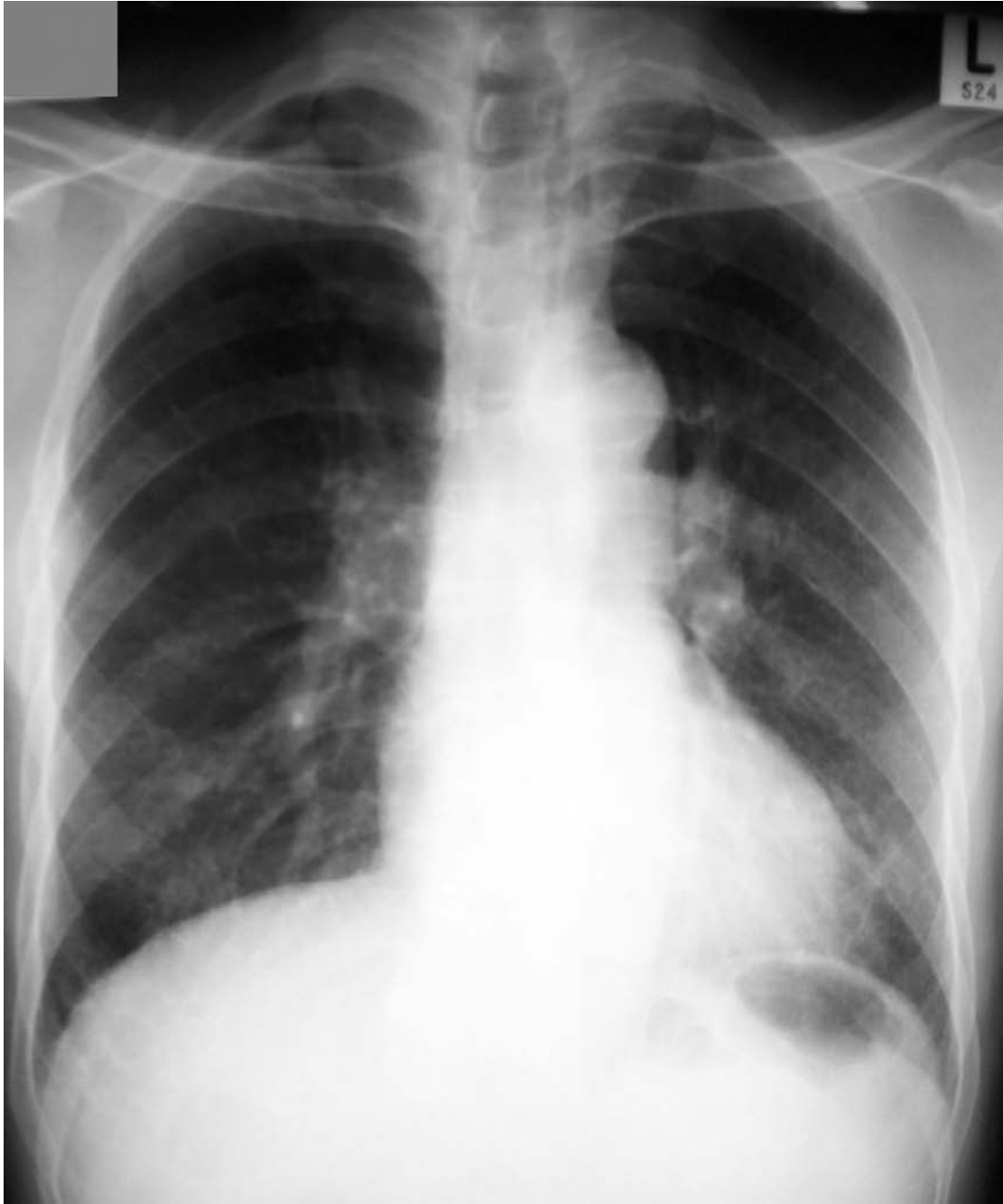

Figure 8.3

Frontal CXR of an adult male with a long history of cigarette smoking. Note the more obvious bronchovascular markings, large volume lungs, but lacking flattening of the hemidiaphragms or obvious signs of emphysema.

- Normally, the bronchi can be seen to segmental level, more peripherally, only the vessels are visible.
- In chronic bronchitis, the thickening of the bronchial wall results in extra lines adjacent to the vessels that increases the number of visible lung markings.
- As a disease of smokers, emphysema usually coexists with the chronic bronchitis and has the opposite effect on the appearance of the lungs on CXR.

Emphysema

Emphysema is divided into 4 overlapping presentations, centrilobular, bullous, paraseptal, and panacinar.

- Pathologically, there is destruction of lung tissue causing loss of the area over which gas exchange occurs and loss of the normal supporting structure of the lung.
- Destruction of lung tissue results in increased transradiancy, or a darker lung. In the area of emphysema, the vessels may be identifiably smaller and less numerous.
- The trapping of air has a space occupying effect in the thorax, which therefore holds a greater overall volume causing flattening of the diaphragms and expansion of the chest dimensions. Normal volume lungs extend over 6 anterior ribs. More than this suggests over-expansion (Fig 8.4), but flattening of the hemi-diaphragms should co-exist with pathological lung over-expansion.

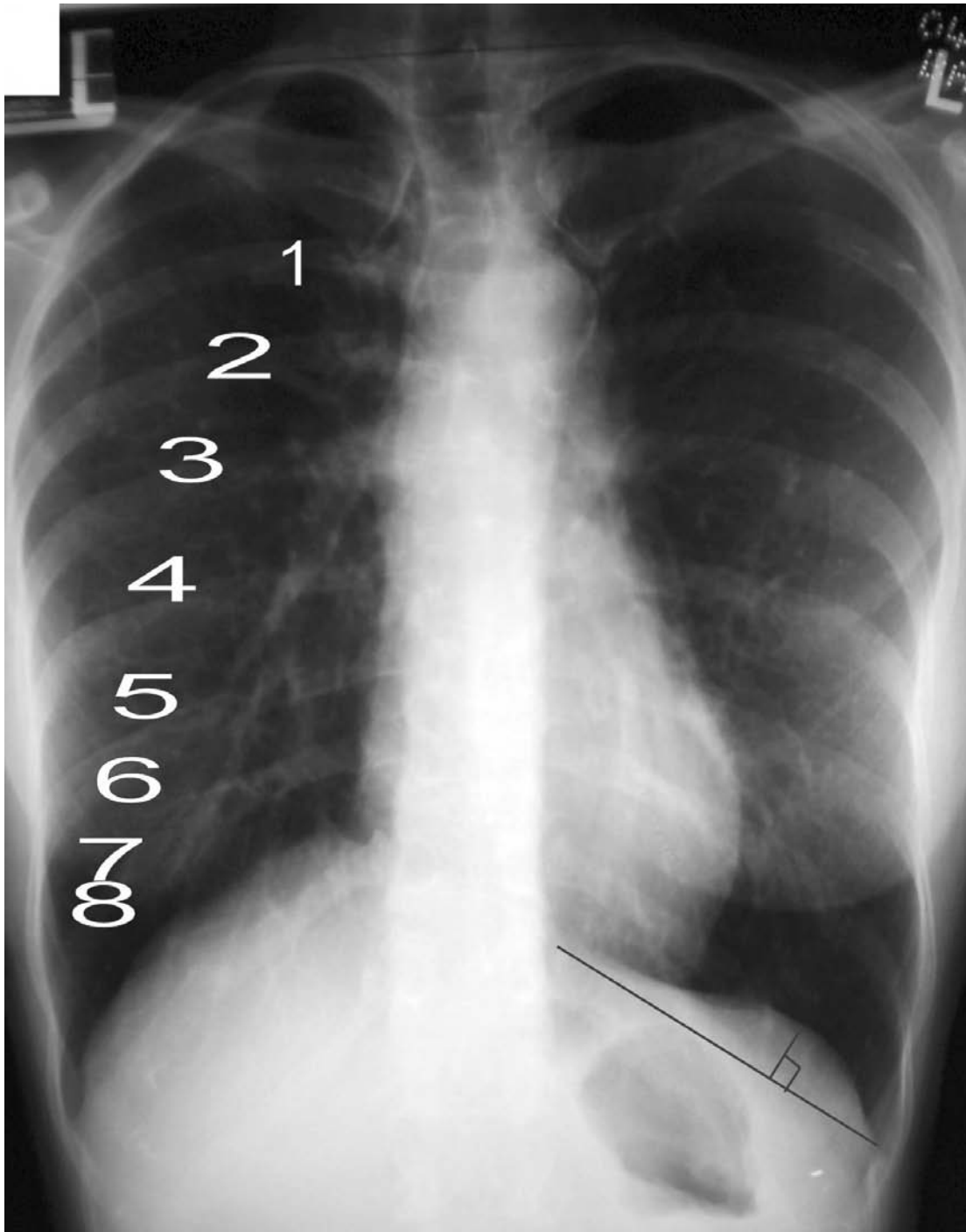


Figure 8.4

Frontal CXR of an adult male with a long history of cigarette smoking. Note the over-expanded lungs (8 anterior ribs above the hemi-diaphragm) due to emphysema. The flattening of the left hemi-diaphragm as judged by measuring the maximum perpendicular distance from a line drawn between the medial and lateral extents of the diaphragm to the diaphragmatic surface (appropriate line marked for left hemi-diaphragm). The measurement should be $>1.5\text{cm}$.

Centrilobular emphysema

- Centrilobular is the commonest form of emphysema and is a condition found in smokers, typically affecting the upper and mid zones.
- Centrilobular emphysema can be difficult to appreciate on a CXR as the lung destruction is at the centrilobular level and only quite extensive disease will result in sufficient lung destruction to be appreciated on CXR through a reduction in lung markings and over-expansion (Fig 8.5).

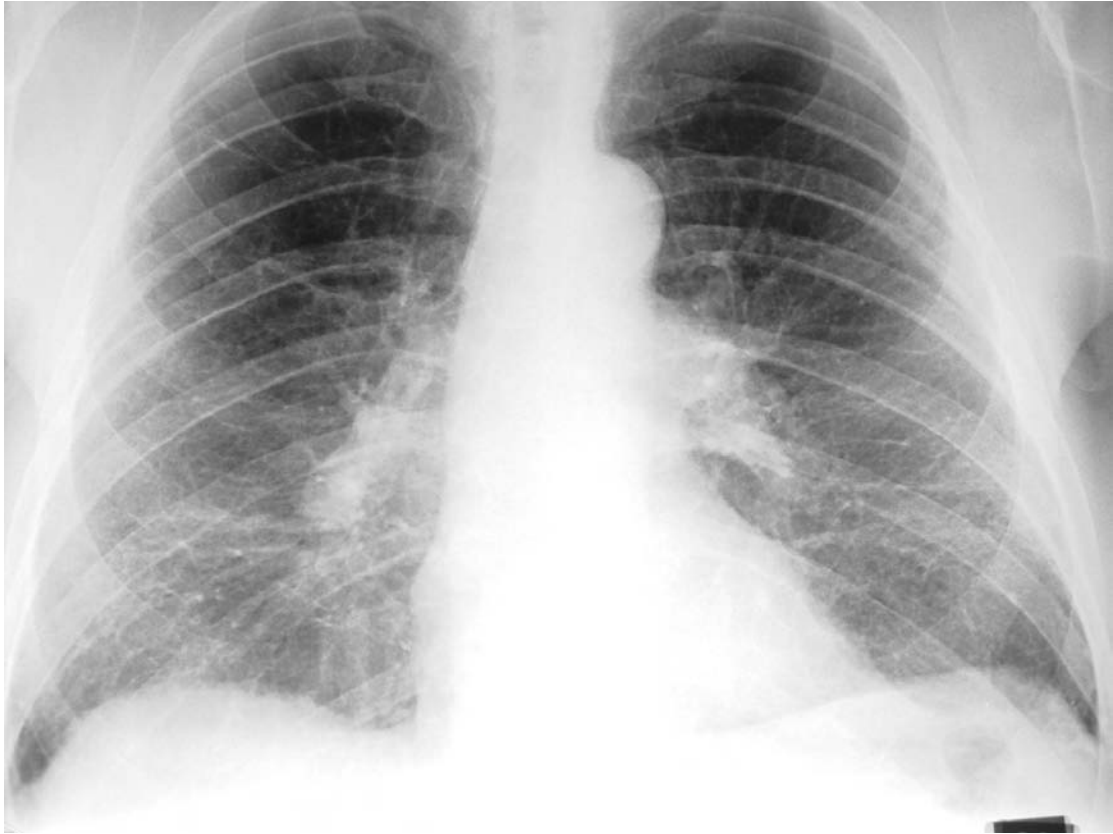

Figure 8.5

Frontal CXR of an adult male patient with a long history of cigarette smoking. Note the reduced lung markings in the upper zones due to centrilobular emphysema. High-resolution CT scanning confirmed this.

Bullous emphysema

- Bullous emphysema is characterized by bullae, which cause areas of absence or paucity of lung markings. Only a proportion of the wall of the bulla is usually visible creating thin curvilinear lines (see “pattern recognition”) (Fig 8.6).

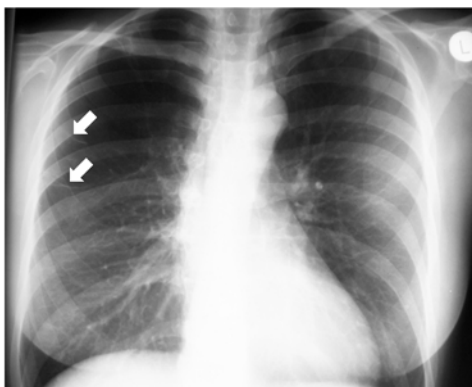


Figure 8.6

Frontal CXR of a patient with bullous emphysema. Note the curvilinear lines (arrows) formed by the walls of the bullae, but the entire wall is not visible.

Para-septal emphysema

- Para-septal emphysema is defined by distribution rather than by the type of lung destruction. The emphysematous destruction occurs in the subpleural regions and adjacent to the fissures.
- The appearances are those of both bullous and centrilobular emphysema and, as a pattern of disease para-septal emphysema, is not readily appreciated on CXR.

Panacinar emphysema

- On CXR, the distinction between panacinar and centrilobular emphysema is not possible, but the distribution may be revealing.
- Alpha-1 anti-trypsin deficiency, a relatively rare form of emphysema, causes panacinar emphysema and typically affects the lower zones of the lung rather than the upper/mid zone distribution of smoking related centrilobular emphysema (Fig 8.7).

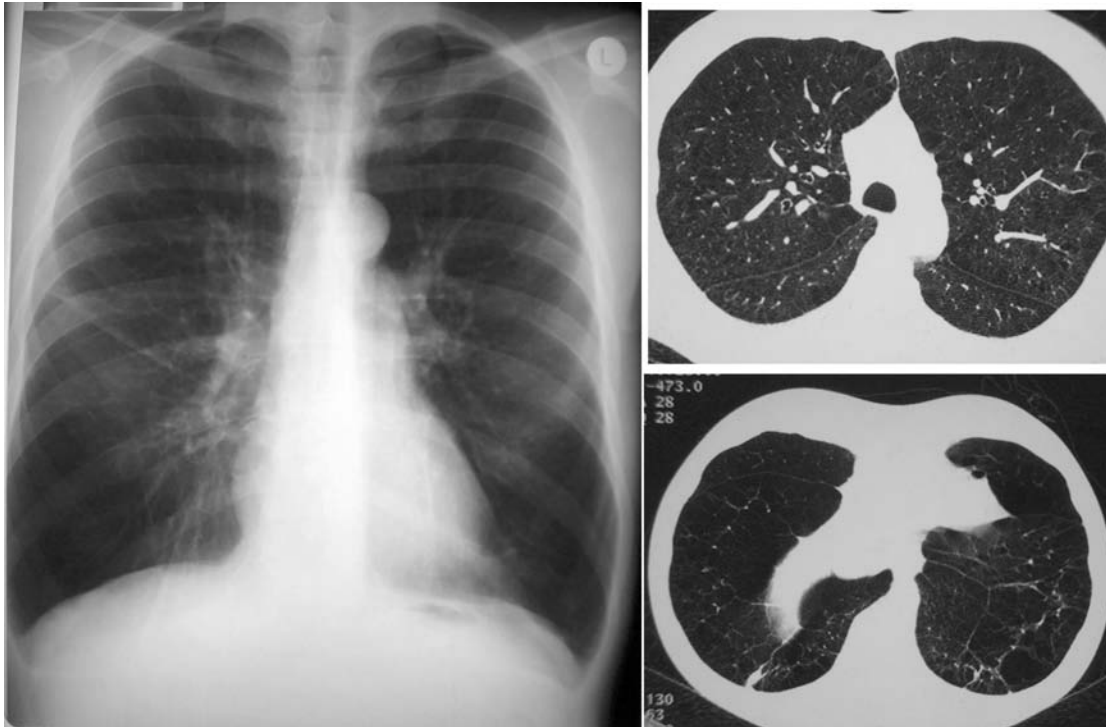


Figure 8.7

Frontal CXR of an adult male with alpha-1 antitrypsin deficiency. Note the reduced number and size of vessels in the lower zones compared to the upper and mid zones and over-expansion of the lungs with flattening of the hemidiaphragms. The inset HRCT images are from the mid zone (top image) and the lung base (bottom image) and display the difference in severity of the emphysematous destruction of the lung tissue.

Bronchiectasis

- Bronchiectasis is defined by the presence of dilated bronchi with thickened walls.
- CXR is insensitive for the detection of bronchiectasis with only severe disease being identified with any certainty.
- Bronchiectasis is descriptively divided into 3 types; cylindrical, varicose and cystic.

Cylindrical bronchiectasis

- Cylindrical bronchiectasis describes uniformly dilated, non-tapering airways.
- CXR reveals tramlines adjacent to lung vessels and rings when the dilated bronchi are seen end on (Fig 8.8).

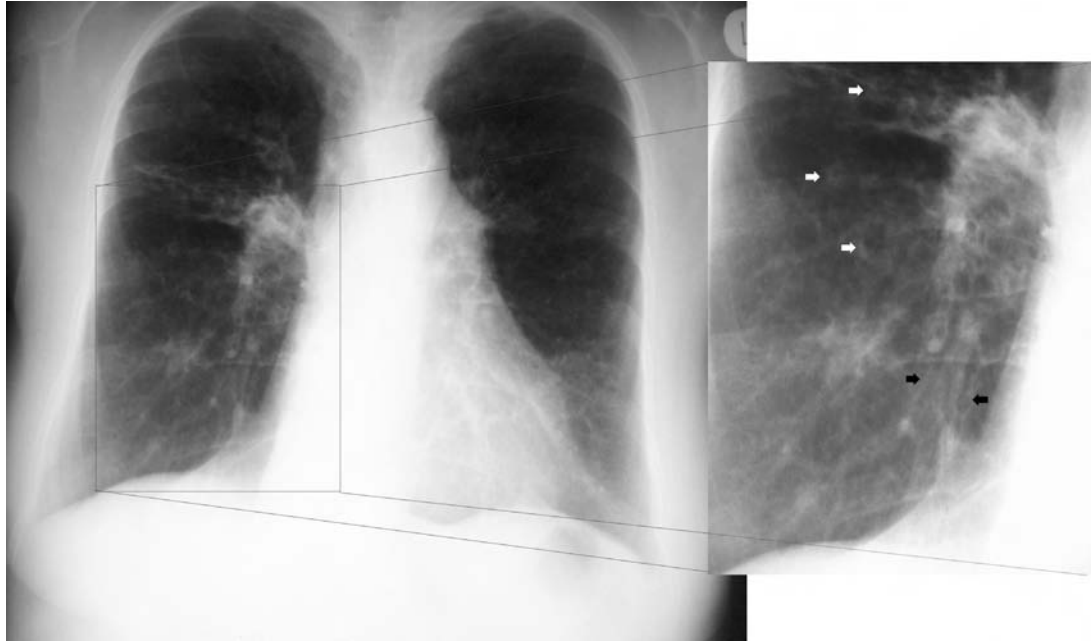

Figure 8.8

Frontal CXR of a patient with cylindrical bronchiectasis, on the magnified image are ring shadows (white arrows) and tram lines (black arrows), representing dilated bronchi end on and lengthways respectively.

Varicose bronchiectasis

- Varicose bronchiectasis describes a non-uniform dilatation of the bronchi forming multiple sequential bead-like dilatations which when viewed on a CXR, will appear cystic but in the plane of the CXR will have an undulating appearance.
- Varicose bronchiectasis is typically associated with allergic bronchopulmonary aspergillosis (ABPA) with a central mid and upper zone distribution (Fig 8.9).

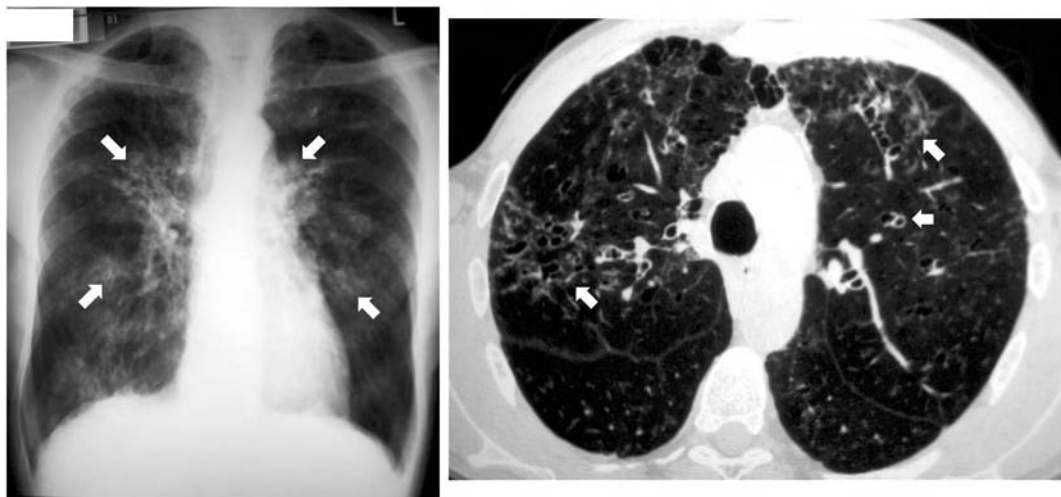


Figure 8.9

Left image is a frontal CXR of an asthmatic patient with ABPA. Note the patchy consolidation, bronchial wall thickening and bronchial dilatation (white arrows). The right image is an HRCT of the same patient demonstrating the bronchiectasis. The distribution is typically central in the mid and upper zones.

Cystic bronchiectasis

- Cystic bronchiectasis describes non-uniform dilatation of airways between which there are less dilated or even normal calibre airways (Fig 8.10).
- CXR reveals ring shadows that may contain fluid giving rise to air-fluid levels.

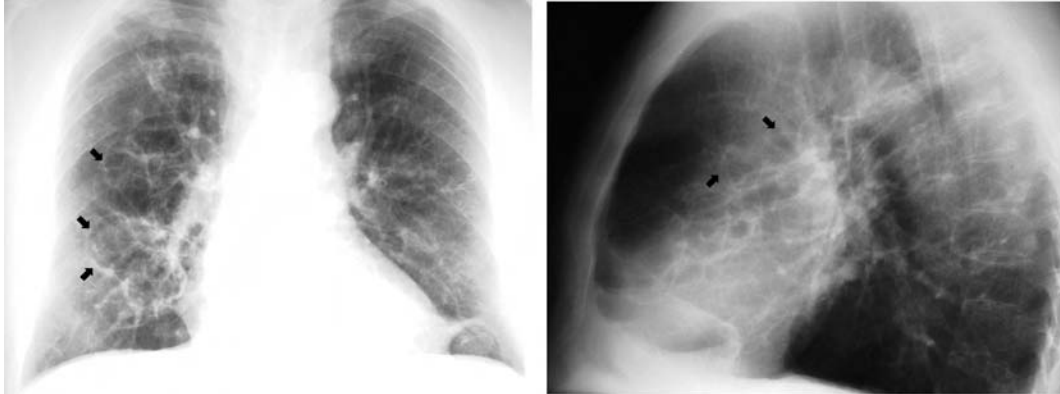


Figure 8.10

Frontal and lateral CXR of a patient with cystic bronchiectasis secondary to a childhood infection and confined to the right middle lobe. Note the "cysts" with thin walls (black arrows). The "cysts" are either focal dilatation of the bronchi or saccular out-pouchings from the bronchi.

- Cystic fibrosis is a congenital condition resulting in impaired ciliary motor activity and thickened secretions. In the lungs this results in bronchiectasis in a mid and upper zone distribution classically and the CXR is quite characteristic (Fig 8.11).

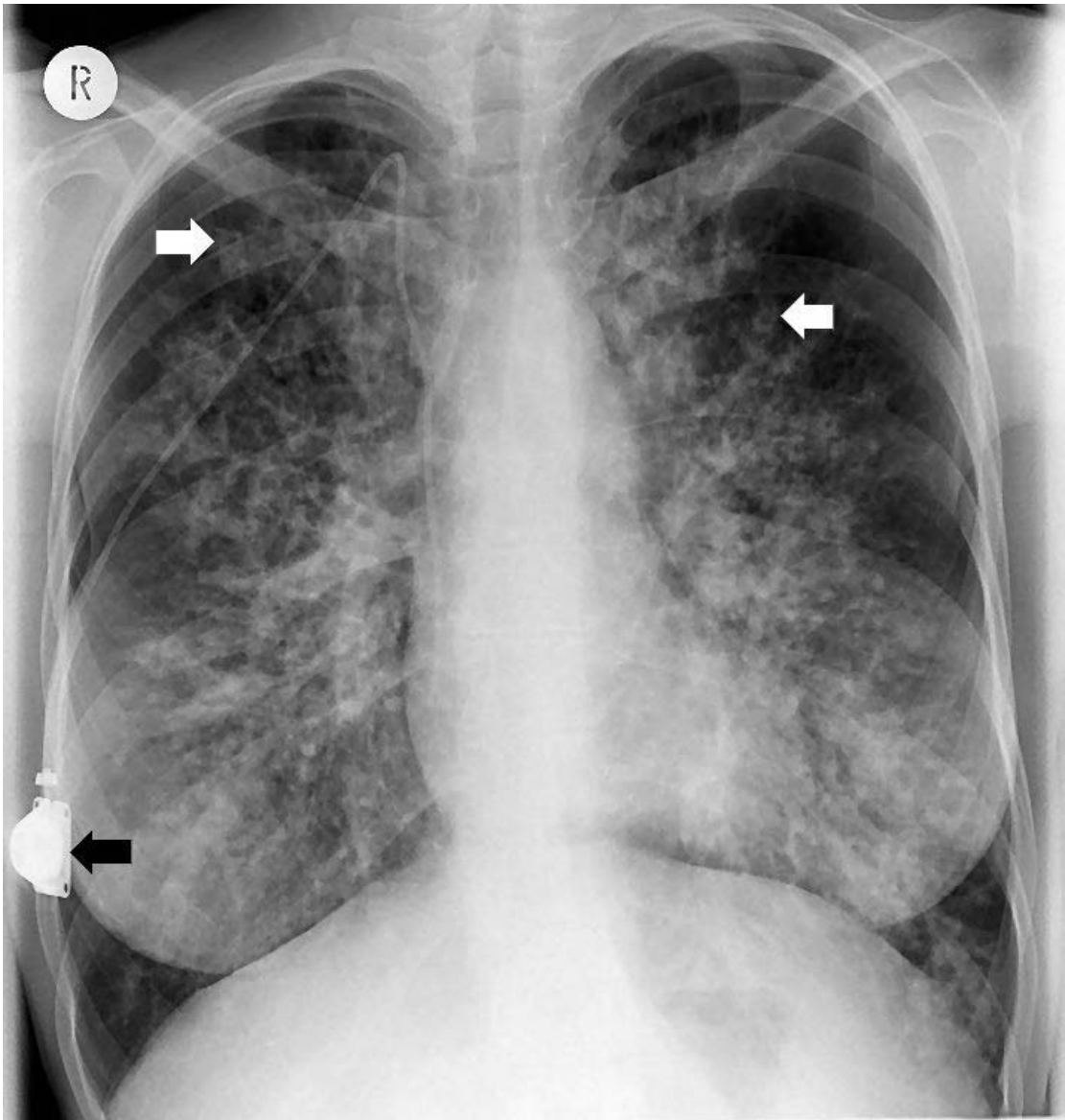


Figure 8.11

Frontal CXR of a young adult female with cystic fibrosis. Note the predominantly central bronchiectasis with ring shadows clearly evident (white arrows). The presence of a portocath (black arrow) indicates this patient is on long term intravenous medication like many cystic fibrosis patients are.

Diffuse lung disease

Fibrosis

- The CXR is an insensitive investigation for detecting pulmonary fibrosis.
- The advent of HRCT has demonstrated mild to moderate degrees of fibrosis that are not detected on CXR.
- When fibrosis is apparent on CXR the cardinal feature is reticulation, a fine network of lines, corresponding to fibrous thickening of the lung interstitium such that it becomes visible on CXR (Fig 9.1).

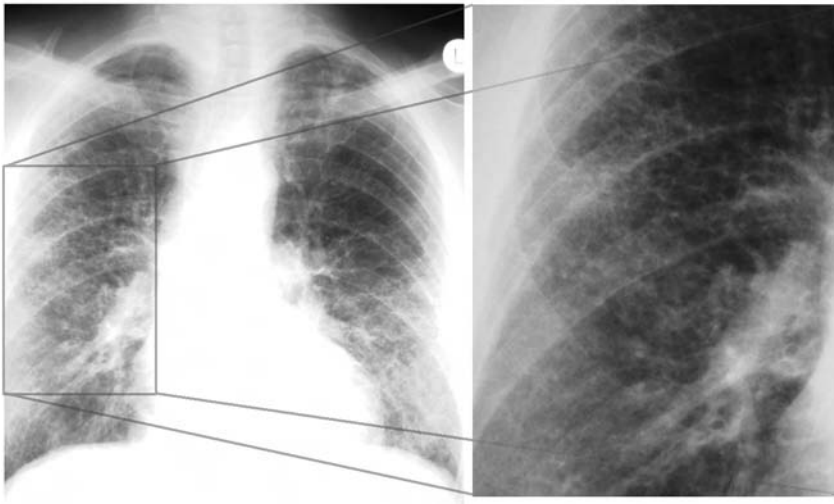

Figure 9.1

Frontal CXR of a patient with idiopathic pulmonary fibrosis. The magnified area demonstrates the interlacing network of lines described as reticulation, which represent the visible pathologically thickened interstitium, in this case due to fibrosis.

- To make a diagnosis of fibrosis the other conditions that thicken the interstitium such as interstitial oedema in heart failure, lymphangitis carcinomatosa and alveolar proteinosis, should be excluded or other evidence of fibrosis should be present.
- The presence of volume loss in the region of reticulation (Fig 9.2) and/or honeycomb destruction supports a diagnosis of fibrosis.
- Honeycomb destruction of the lung is primarily a feature of idiopathic pulmonary fibrosis, is characteristically peripheral and basal in site and may be seen on CXR if severe (Fig 9.3).

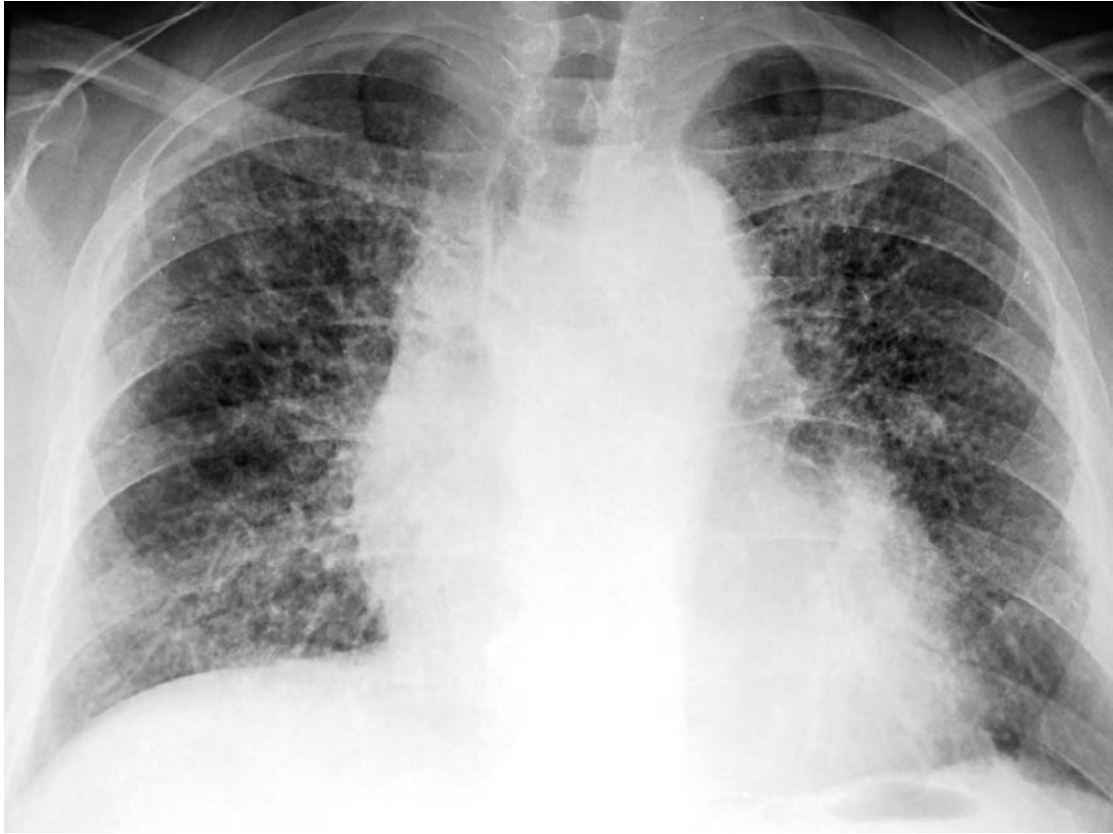


Figure 9.2

Frontal CXR of an adult male with diffuse lung fibrosis. As a result there is reduced lung expansion evident on this full inspiratory film.

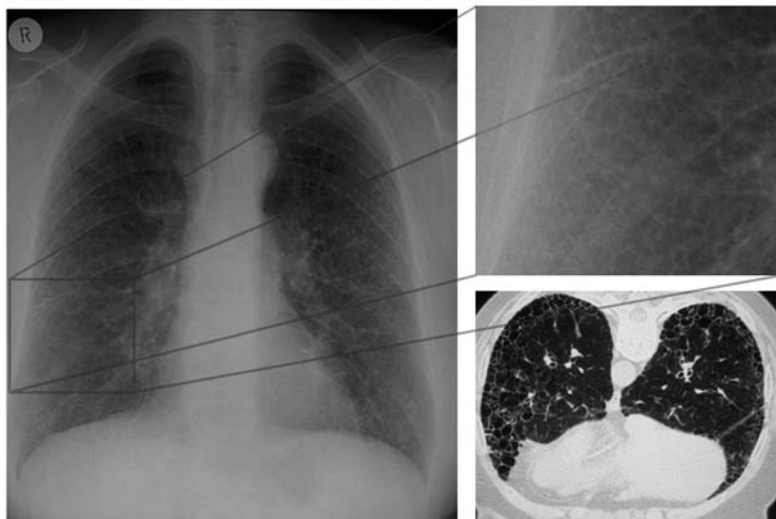


Figure 9.3

Frontal CXR of a patient with idiopathic pulmonary fibrosis. Note the "holes" in the periphery in the magnified section and the increased volume of the lungs, not expected in fibrotic lung, due to co-existent emphysema. The bottom right inset is from the high-resolution CT scan of the same patient demonstrating the peripheral/sub-pleural honeycomb destruction.

- Many patients with pulmonary fibrosis are also smokers and the presence of co-existent emphysema in the upper zones may mask significant lower zone volume loss due to fibrosis (Fig 9.4).

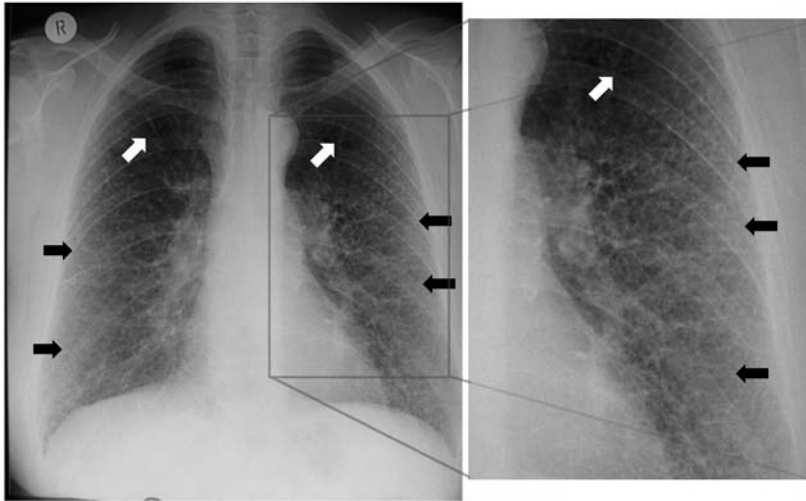


Figure 9.4
Frontal CXR of a patient with idiopathic pulmonary fibrosis and co-existent emphysema. Note the paucity of lung markings in the upper zones (white arrows) in conjunction with normal volume lungs and widespread reticulation extending from the lung bases.

Lymphangitis carcinomatosa

- Lymphangitis carcinomatosa describes the infiltration of the lymphatic vessels by tumour (Fig 9.5).
- The result is interstitial thickening causing reticulation.
- Clues to differentiate this cause of reticulation from fibrosis are the absence of volume loss, the asymmetrical nature, prominent septal lines, which are much less of a feature in fibrosis, and the identification of a primary tumour or mediastinal lymphadenopathy.

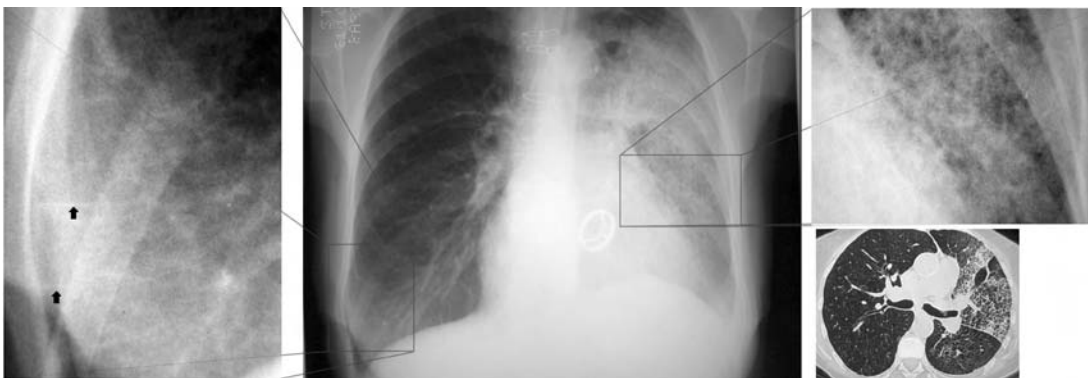


Figure 9.5
Frontal CXR of an adult female. Note in the magnified view on the left, there are prominent septal lines (black arrows) and on the right, note the reticulation (see inset HRCT). This patient has a left mid zone carcinoma of the bronchus with associated lymphangitis carcinomatosa. The cause for the right basal septal lines is uncertain. In the absence of obvious reticulation and the history of cardiac failure, note an enlarged heart and valve replacement, left heart failure is the more likely aetiology.

LAM

- Lymphangiomyomatosis is histologically identical to tuberous sclerosis in the lungs.
- A disease almost exclusive to women, this diagnosis should not be considered in male patients.
- The characteristic lesion is best appreciated on HRCT whereby there are numerous air filled cysts distributed throughout the lungs with normal lung parenchyma interspersed.

- On CXR, the walls of these cysts give the appearance of reticulation. A clue to the true nature is in the preservation of lung volumes and clarity of the mediastinal contours in the presence of what appears to be diffuse pulmonary fibrosis (Fig 9.6).

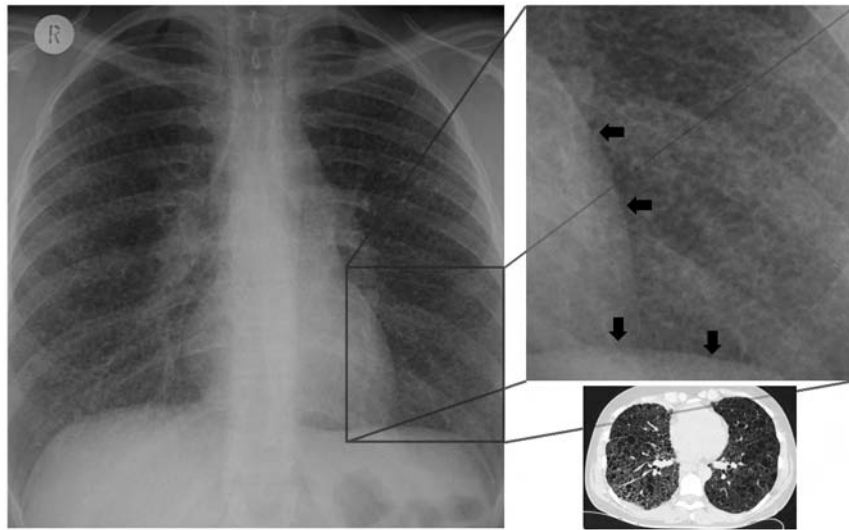


Figure 9.6

Frontal CXR of a patient with LAM. Again note the “holes” on the magnified view as for LCH but the absence of nodules is difficult to appreciate with the projection of so many overlapping cyst walls. The appearances could easily be mistaken for reticulation due to interstitial pathology but changes to this extent would involve and obscure the silhouette of the heart border and diaphragm and these are clearly intact (arrows).

LCH

- Langerhan’s cell histiocytosis is the main differential diagnosis along with LAM for diffuse air-filled cysts in the lung.
- The characterization of these cysts and distinguishing factors are only readily appreciated on HRCT.
- The numerous cysts give a reticulation type pattern on CXR as for LAM, but nodules that will subsequently develop into cysts may be seen.
- LCH is a smoking related disease and the distribution of disease tends to be in the upper and mid zones with sparing of the lung bases (LCH) (Figure 9.7).

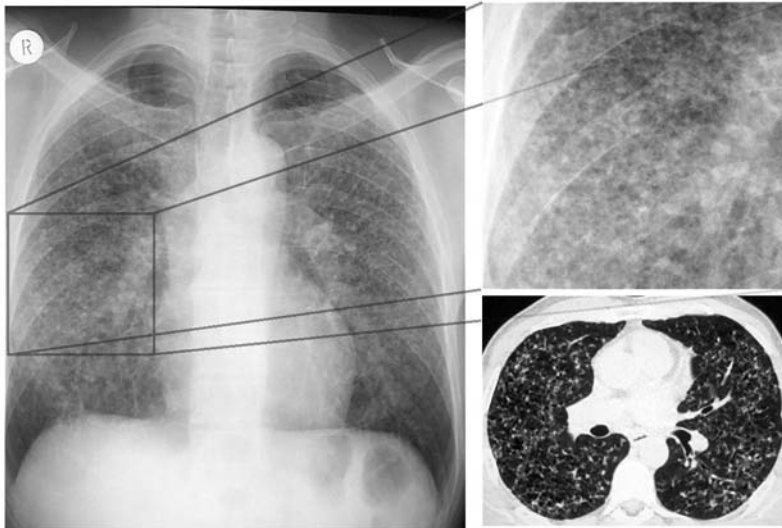

Figure 9.7

Frontal CXR of a patient with LCH. Note in the magnified region the combination of “holes” and nodules. The CT image (bottom right) demonstrates the irregular shape of the cysts giving rise to the CXR appearances and confirms the presence of nodules.

- In severe disease the distinction between LAM and LCH may not be possible radiologically, even on HRCT.

Pulmonary sarcoid

- Sarcoidosis is a systemic granulomatous condition.
- The spectrum of features found in the lung enable sarcoid to mimic the radiology of many other pulmonary pathologies.
- The characteristic presentation is of bilateral, symmetrical hilar adenopathy with or without mediastinal adenopathy and the main differential for this appearance is lymphoma (Fig 9.8).

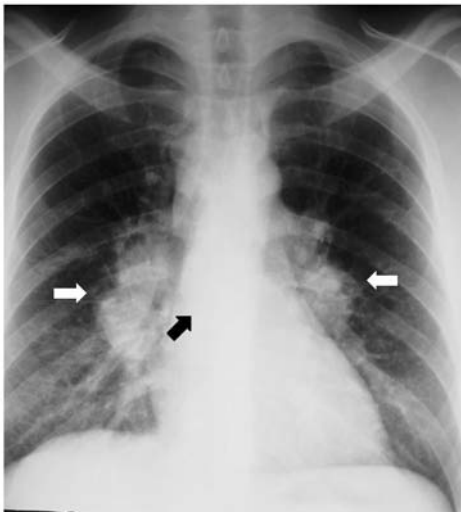


Figure 9.8

Frontal CXR of a patient with sarcoidosis. Note the bilateral hilar adenopathy (white arrows) and the likely paratracheal adenopathy. Furthermore, the azygo-oesophageal line is obscured (black arrow) suggesting subcarinal lymphadenopathy.

- Lung parenchymal involvement may present with fibrosis evident as reticulation, typically in the upper and mid zones (Fig 9.9).

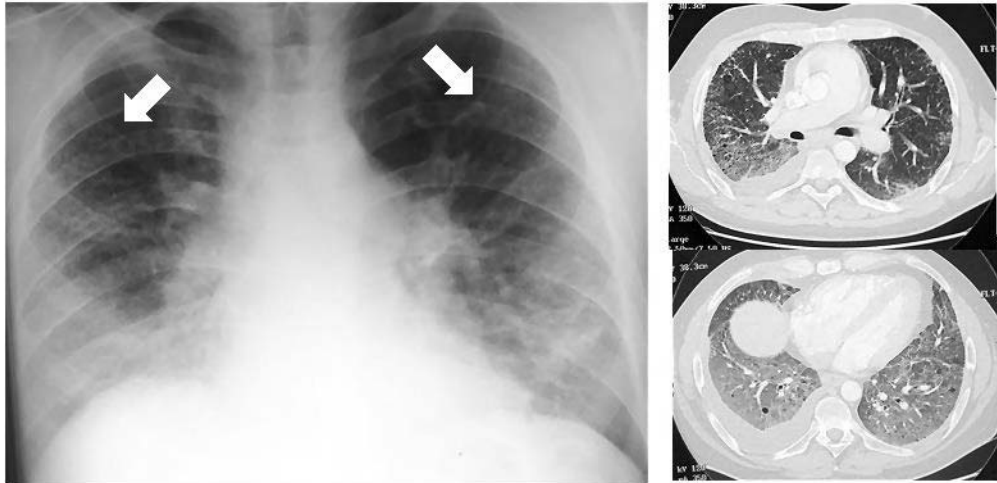


Figure 9.9

Frontal CXR of a patient with long standing sarcoidosis. The left image shows mid, and to a lesser extent, upper zone patchy opacity and peripheral nodularity (white arrows). CT imaging demonstrates the ground glass opacity caused by fibrosis. Note the dilated airways.

- Sarcoidosis may manifest as a nodular pattern similar in appearance to miliary TB (Fig 9.10) or consolidation (Fig 9.11), which tends to be peripheral and patchy.

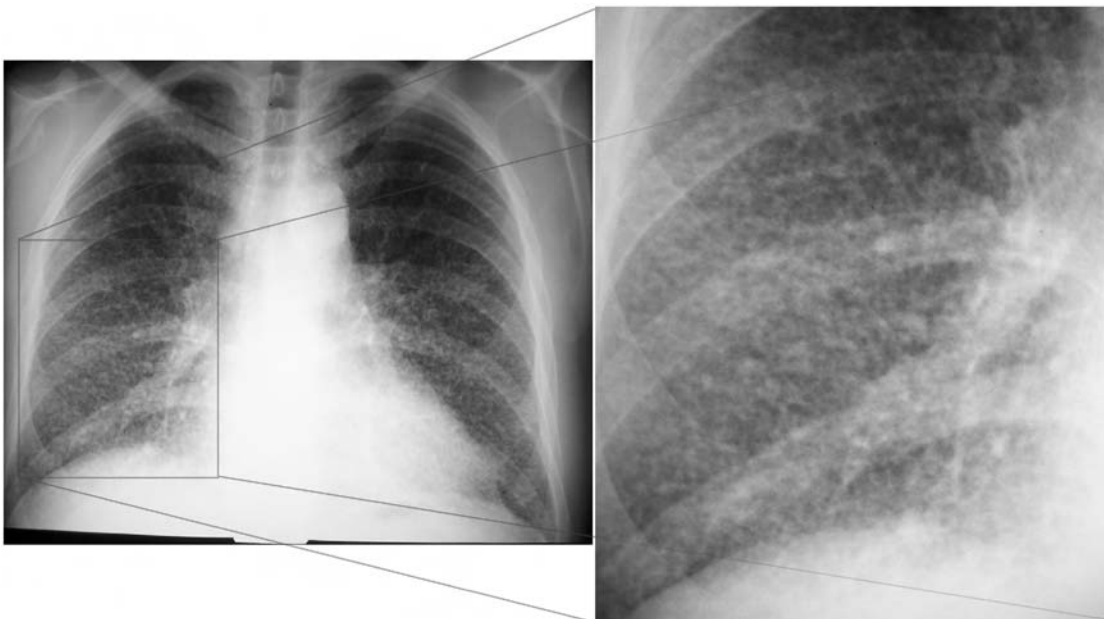


Figure 9.10

Frontal CXR of a patient with sarcoidosis presenting with multiple nodules, see magnified image. The appearance is difficult to distinguish from miliary TB radiologically, but clinically, patients with TB are very unwell whereas those with sarcoid may have no symptoms.

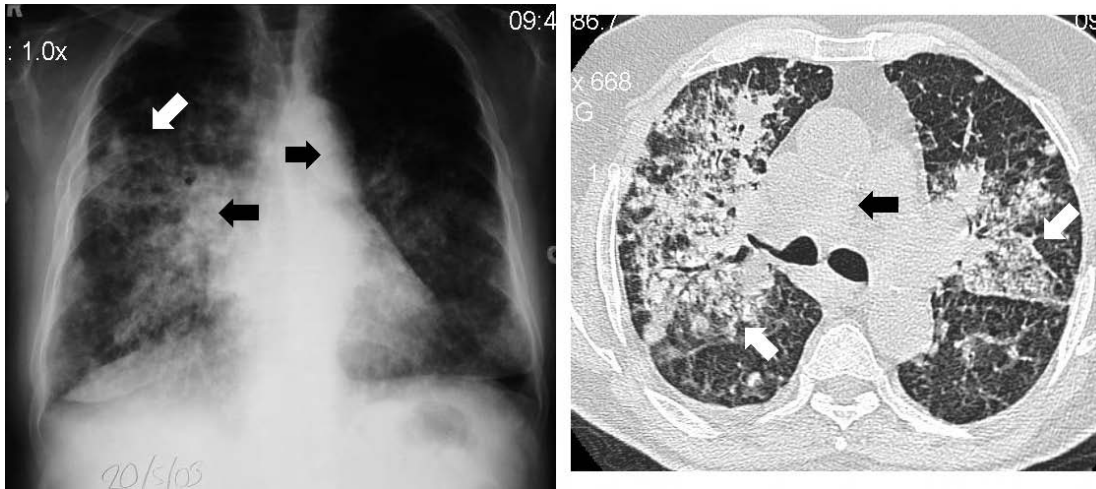


Figure 9.11
 Frontal CXR and HRCT image of a patient with sarcoidosis. Note the consolidation (white arrow) and marked mediastinal and hilar lymphadenopathy (black arrows).

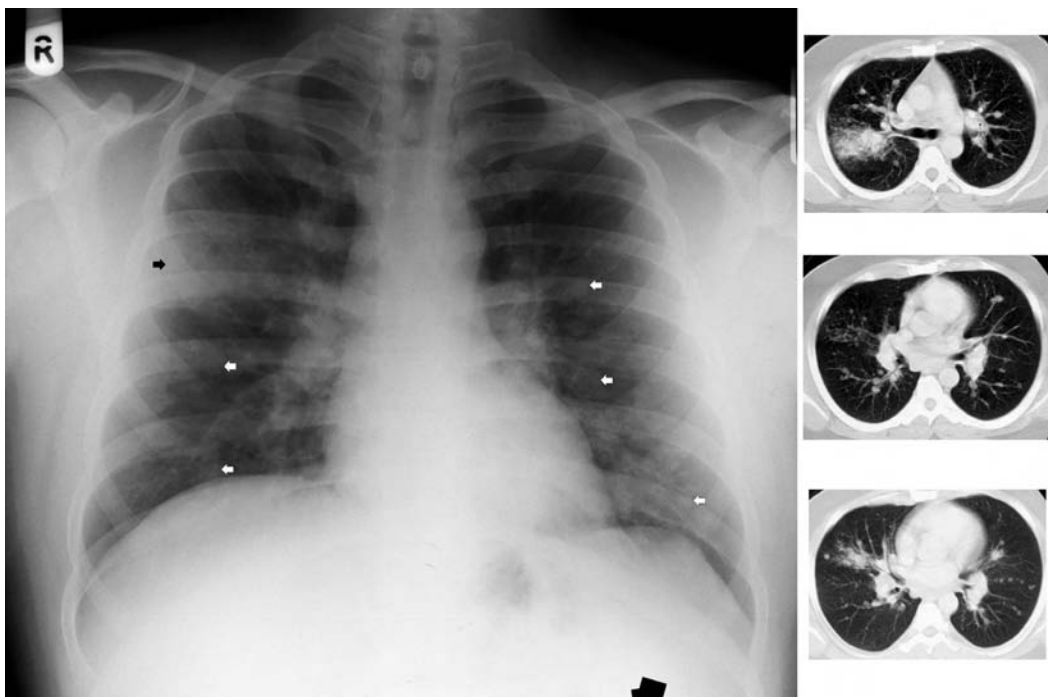


Figure 9.12
 Frontal CXR of a patient with sarcoidosis. Note the area of consolidation due to air space sarcoid (black arrow) and the numerous nodules (white arrows) that mimic metastases as they are larger than the nodules usually associated with sarcoid. The nodules also look like metastases on the CT images but note the lining up of the nodules along the left major fissure in the bottom CT image giving a clue to their true nature.

- In general, if the patient is clinically much better than their radiology would suggest, sarcoid should be considered as a possible diagnosis.

Hypersensitivity pneumonitis (HP)

- Hypersensitivity pneumonitis, previously known as extrinsic allergic alveolitis, results from type 2 and type 4 hypersensitivity reactions to inhaled organic allergens.
- HP can be divided into three types based on exposure, symptomatology and radiology.

Acute HP

- Acute HP presents as a transient viral like illness and rarely results in presentation to a doctor.
- On CXR in acute HP there may be ill-defined areas of ground glass opacity (Fig 9.13).

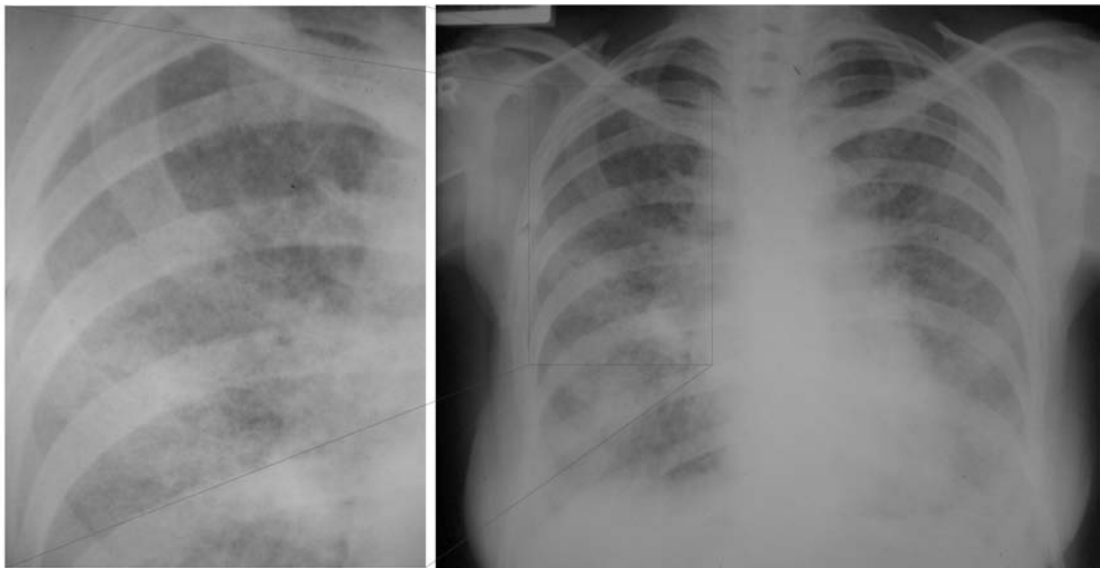


Figure 9.13

A frontal CXR of an adult female diagnosed with acute hypersensitivity pneumonitis. Note the patchy ground glass opacity.

Sub-acute HP

- Sub-acute HP results from repeated exposure to the allergen and presents with fevers, difficulty in breathing and “squeaks” on examination.
- The CXR again primarily shows ground glass opacity and possibly ill-defined nodularity (Fig 9.14).

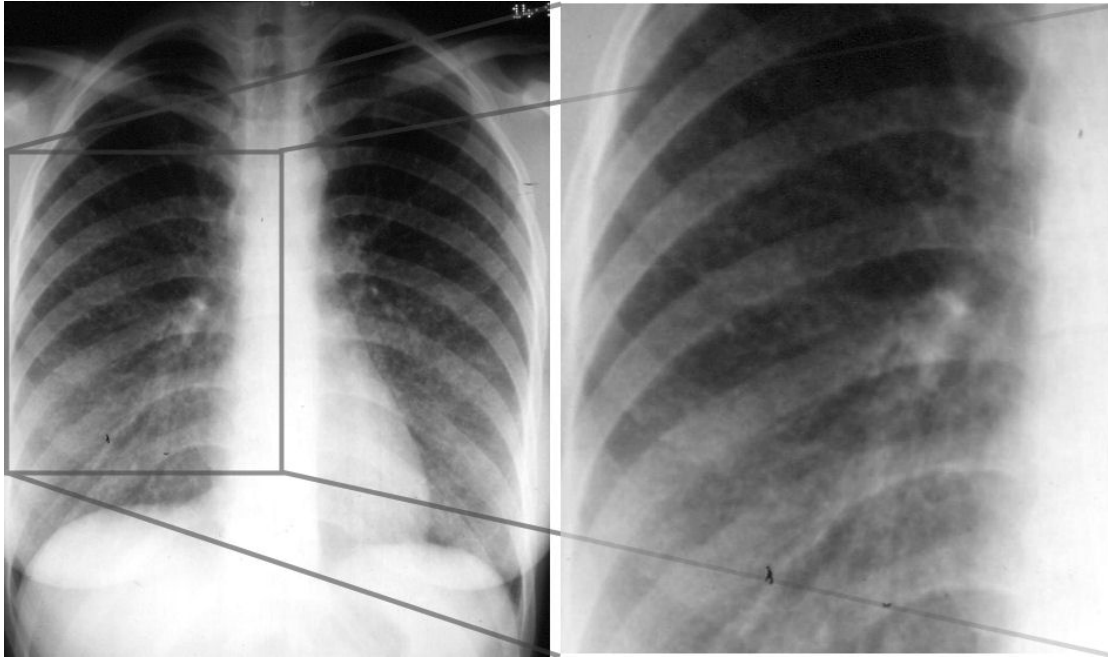


Figure 9.14
Frontal CXR of an adult female with sub-acute hypersensitivity pneumonitis. Note in the magnified view there are numerous small soft tissue nodules seen in the lung.

Chronic HP

- Chronic HP results from continued exposure to the allergen such that the inflamed lung becomes permanently damaged and fibrotic.
- The fibrosis tends to have an upper and mid zone predominance and is evident on CXR as fibrous bands and/or reticulation in the upper and mid zones with elevation of the hila indicating upper lobe volume loss (Fig 9.15).

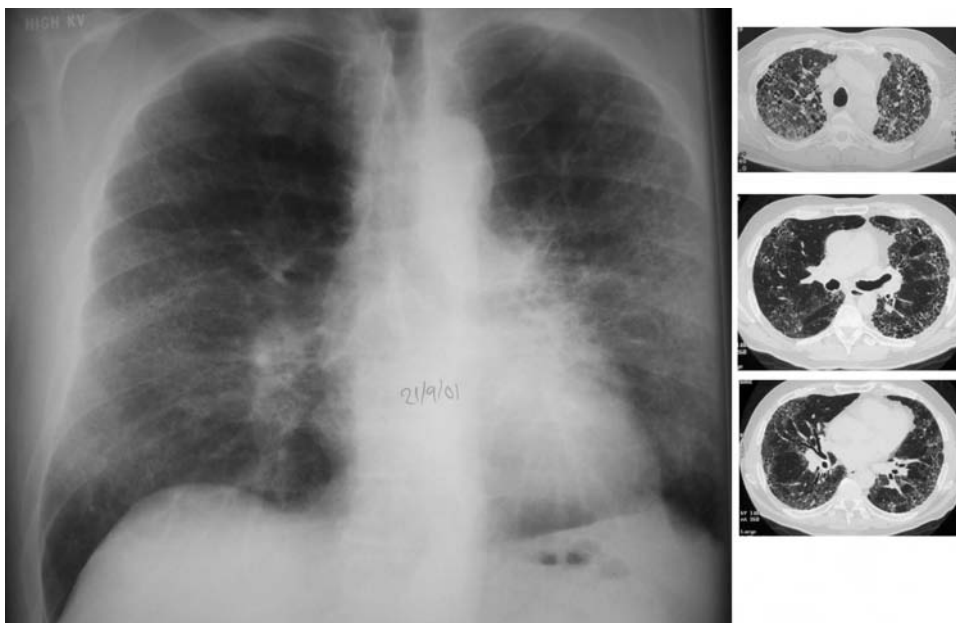


Figure 9.15
Frontal CXR of an adult male with chronic hypersensitivity pneumonitis. The inset images demonstrate the HRCT appearances in the upper, mid and lower zones. Note on the CXR the reticular pattern primarily in the mid and upper zones and elevation of the hila particularly on the left.

This page was left blank by the publisher.

Pleural disease

- The pleura is a thin membrane that may be likened to a sealed “bag” that is wrapped around the lung forming two layers, one against the lung, the visceral pleura, and one against the inside of the chest wall, the parietal pleura.
- Each lung has its own pleural “bag”.
- The parietal pleura is fixed to the inner chest wall and the potential space that lies between the two layers of pleura, the inside of the bag, is empty except for a small amount of fluid.
- The surface tension of the fluid is sticky enough to “glue” the two layers of pleura together such that as the chest wall expands the lung will expand with it.
- At the same time the layers of pleura allow the lung and chest wall to “slide against one another” such that in filling the thoracic cavity the lung does not have to match the movement of the chest wall.
- On inspiration the depression of the diaphragms has a significant impact on the increase in thoracic capacity and in filling this space the lungs elongate as well as expand laterally thus creating a shearing movement relative to the chest wall.
- This is facilitated by the two layer pleural design but as a result there is a potential space between the pleural surfaces and accumulation of air or fluid in this space will affect its function.
- Diseases that cause a loss of the ability of the pleural surfaces to slide over one another will have an impact on lung expansion and may present with chest wall pain related to breathing.

Pneumothorax

- Pneumothorax describes the presence of air in the pleural space.
- There are two main sources for this air, the lung or a breach of the chest wall, e.g. trauma or surgical procedure.
- In the absence of a chest wall breach the cause will be lung pathology, which at the simplest level may be a surface bleb, “bubble”, that has burst, a cause of spontaneous pneumothorax usually found in tall young men. Alternative causes include infections, particularly destructive abscesses, malignancy or internal traumatic damage to the major airways (Fig 10.1).

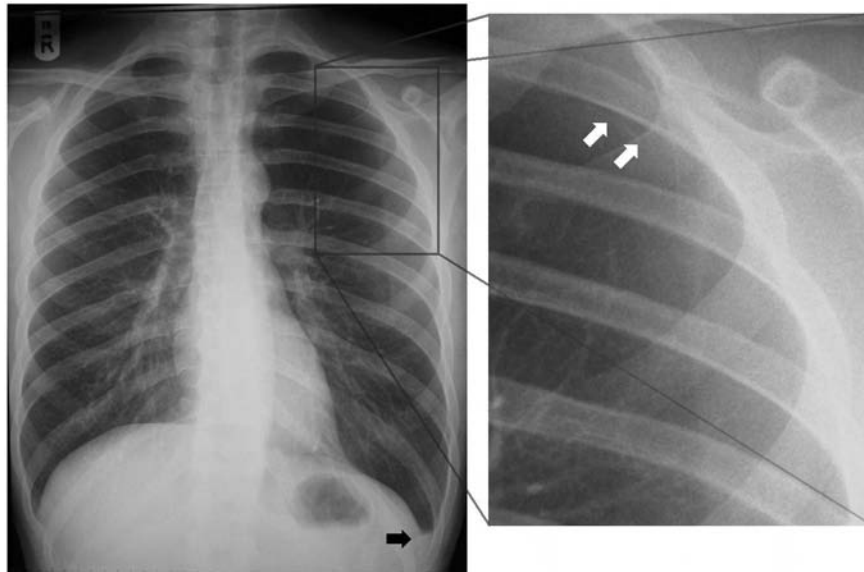


Figure 10.1

Spontaneous pneumothorax in a young tall male patient who presented with sudden onset of left sided chest pain. Note the subtle lung edge visible in the magnified view (white arrows) and the blunting of the left costophrenic angle where the fluid normally found in the pleural space has accumulated at the base (black arrow).

- Air in the pleural space breaks the water seal that sticks the two layers of pleura together allowing the lung to collapse through its inherent elasticity.
- A pneumothorax is evident on a CXR where there is an absence of lung markings and a defined edge to the lung (Fig 10.2).

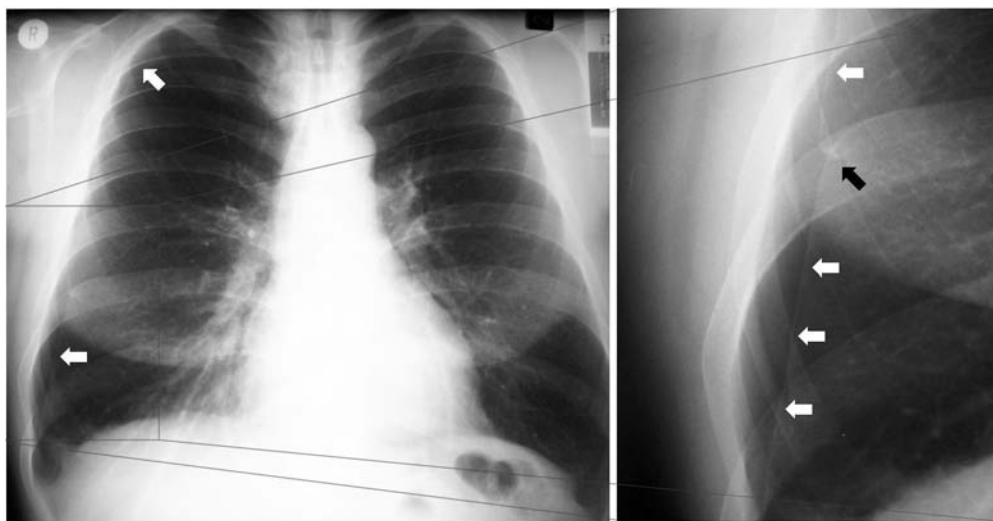


Figure 10.2

An adult male patient with a right-sided pneumothorax following percutaneous biopsy of an upper lobe tumour. Note the lung edge (white arrows) beyond which there are no lung markings. Note also the junction between the right middle and lower lobes, the major fissure (diagonal black arrow).

- The size of the pneumothorax will have an impact on how long it takes to spontaneously resolve a process that may be accelerated by high dose oxygen therapy.
- Aspiration or drainage with an underwater seal will dramatically speed up the resolution of the pneumothorax.
- If air is entering the pleural space but, due to a natural one-way valve, is unable to escape, the volume of air will continue to rise causing an increase in volume of the pleural space pushing the mediastinum to the opposite side.
- The result is termed a tension pneumothorax and is a life threatening condition.
- On CXR, the presence of mediastinal shift away from a large pneumothorax and flattening, even inversion, of the hemidiaphragm beneath the pneumothorax are signs of tension and urgent drainage is required (Fig 10.3).

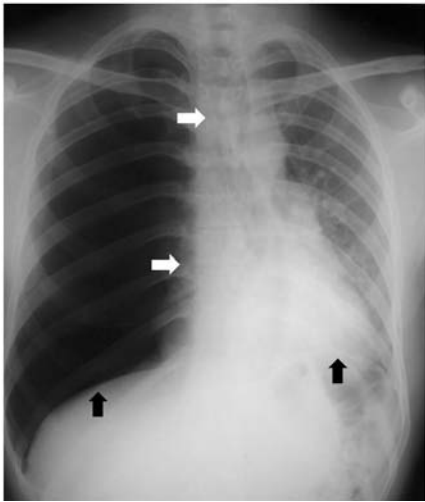


Figure 10.3

Frontal CXR of an adult patient with a tension pneumothorax. Note the comparison of the hemidiaphragms (black arrows), the right hemidiaphragm is flattened compared to the left, and the mediastinal shift away from the pneumothorax (white arrows).

- Soft tissue emphysema, the development of air in the soft tissues, may complicate a pneumothorax and can be found in the mediastinum, chest wall and neck.
- Soft tissue emphysema is readily apparent on CXR as lucent bubbles or lines in normally relatively opaque soft tissues (Fig 10.4).

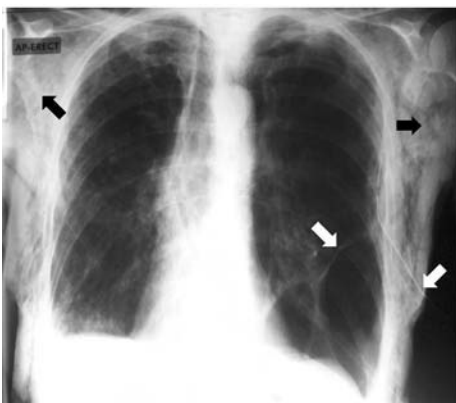


Figure 10.4

Frontal CXR of an adult with a tethered pneumothorax. There is a chest drain in-situ (white arrow) and soft tissue emphysema due to air leak around the drain (black arrows).

- On a CXR taken with the patient in a semi-erect or supine position, a pneumothorax may reside in the anterior part of the hemithorax.
- An anterior pneumothorax may cause no visible lung edge as this is not in the plane of the X-ray beam but across it.
- Clues to an anterior pneumothorax are very well defined mediastinal and diaphragmatic silhouettes, where air has replaced lung adjacent to the mediastinum and diaphragm (Fig 10.5) and reduced opacity overlying the diaphragm where the air has replaced the lung either in front of or behind the diaphragm and enlarged that space.

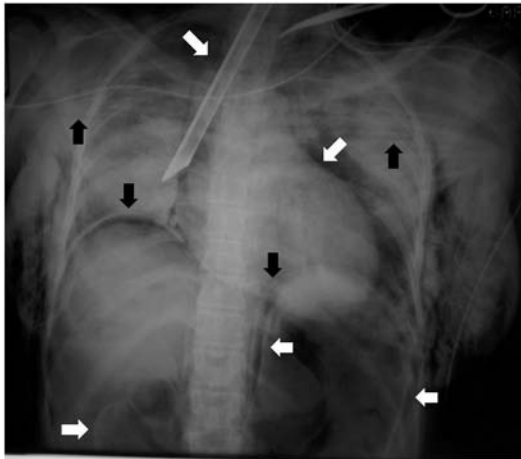


Figure 10.5

Frontal CXR of a post-thoracotomy patient who has developed bilateral pneumothoraces. Note the clarity of the mediastinal contours and the diaphragms (white arrows).

- A lateral CXR taken with the patient supine and the X-ray beam horizontally aligned may identify the lung edge in a suspected anterior pneumothorax.
- A skin fold may mimic the appearance of a lung edge but not the absence of lung markings (Fig 10.6).

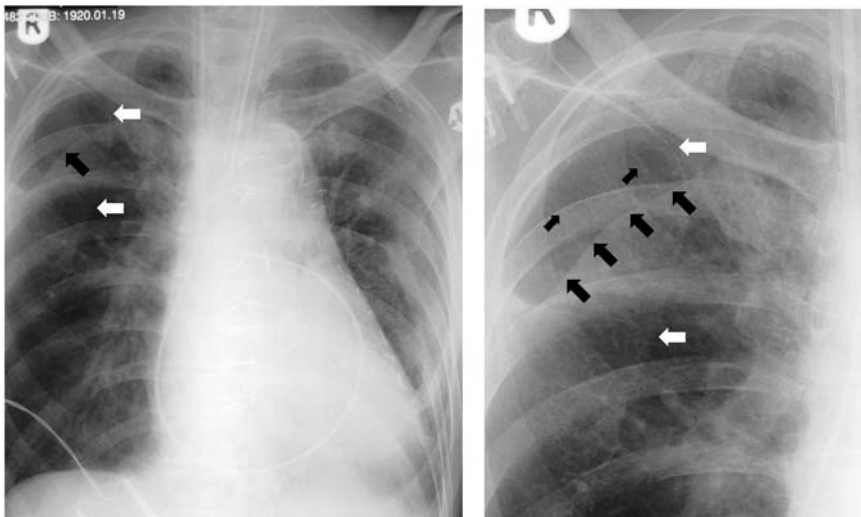


Figure 10.6

AP CXR taken on an intensive care ward appears to demonstrate a pneumothorax. An apparent lung edge is seen (large black arrows) but on closer inspection there are lung markings beyond the supposed lung edge (small black arrows). The margin of the scapula is also marked (white arrows).

- This appearance is more likely to occur on a portable CXR as the film cassette is placed behind the patient and in leaning back against the film a skin fold may be created especially if the patient has recently lost weight.

Effusion

- The pleural space normally has a small amount of fluid within it; this is evident in the blunting of the costophrenic angle on the side of a pneumothorax where this fluid has collected at the base (Fig 10.1).
- The physiological pleural fluid is constantly being replenished by the combination of accumulation and absorption. Accumulation in excess of absorption results in a pleural effusion and may therefore be caused by increasing accumulation, decreased absorption or both.

Table 10.1 **Causes of pleural effusions**

Intrathoracic

Left heart failure
Infection
Neoplasm
Pulmonary embolus, infarction
Collagen vascular disease
Trauma

Extrathoracic

Hepatic failure
Nephritic syndrome
Meig's syndrome (ovarian carcinoma)
Subphrenic abscess
Pancreatitis

Simple pleural effusion

- On an erect CXR, the fluid normally accumulates at the bases due to gravity with the upper margin defined by a meniscus (Fig 10.7).

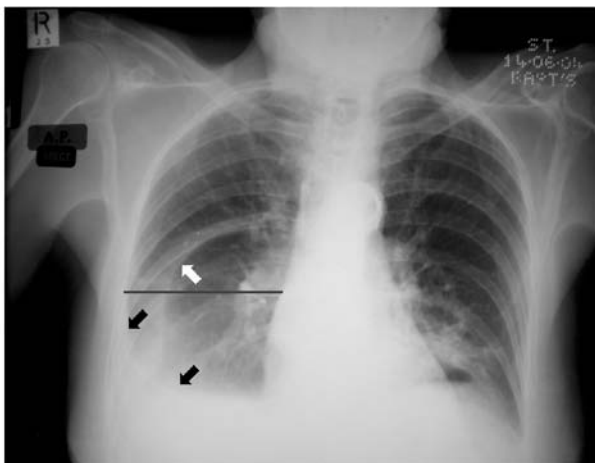


Figure 10.7

Frontal CXR of a patient with a simple pleural effusion. Note the curved margin of the meniscus (black arrows) but also the increased opacity in the right lower zone as the effusion also lies in front of and behind the lung up to the level marked by the faint line. There is also fluid tracking into the major fissure (white arrow).

- In the supine position, a simple pleural effusion will accumulate posteriorly in the chest and the above described meniscal effect is not seen.
- There is an overall increase in shadowing of the hemi thorax, which can be easily overlooked.
- If the effusion is large enough, there is apparent thickening of the pleura at the edges due to the displacement of lung from the chest wall by the fluid (Fig 10.8).

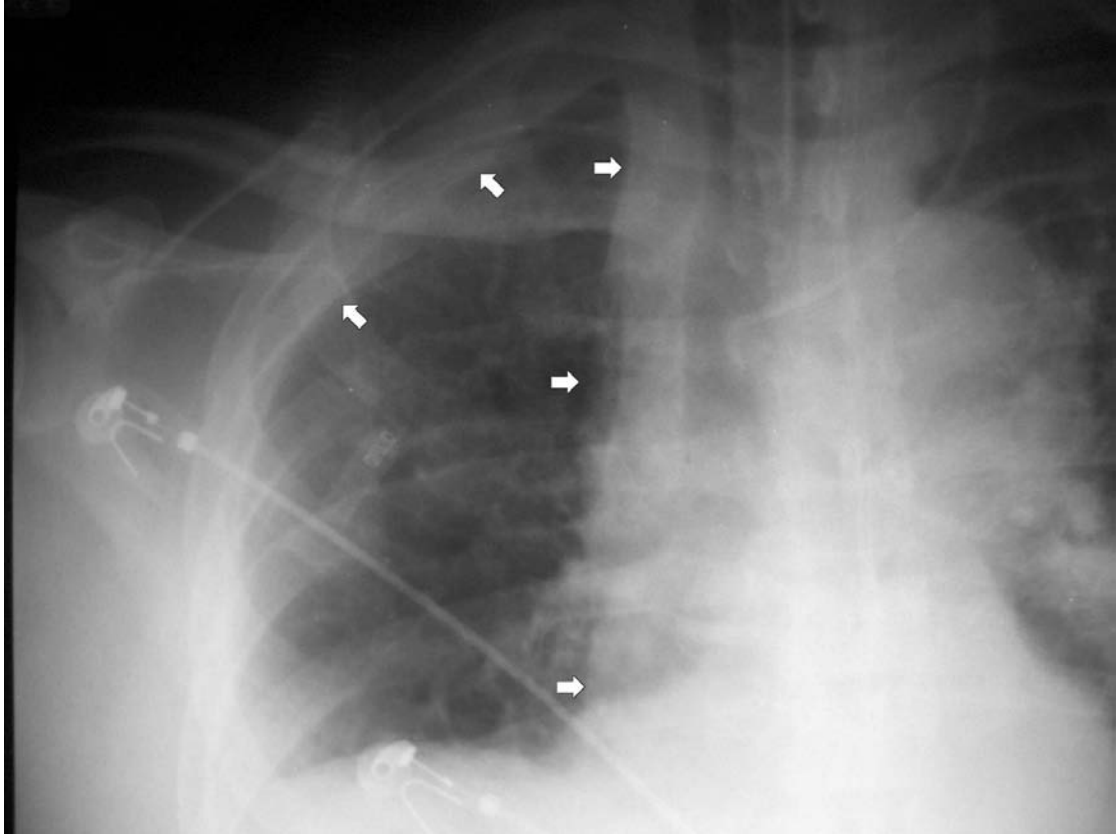


Figure 10.8

Supine CXR of an adult patient demonstrating a pleural effusion. Note the rim of opacity surrounding the lung (white arrows) due to fluid lying posterior and lateral where it separates the lungs from the chest wall.

- When the patient is semi-erect, the fluid will collect preferentially in the posterior costophrenic recess and posterior pleural space.
- The result is a vague increase in opacity in the lower zones with preservation of the diaphragmatic silhouette, no meniscus and even a normal costophrenic angle. Lobar collapse does not have the same dependence on patient position (Fig 10.9).

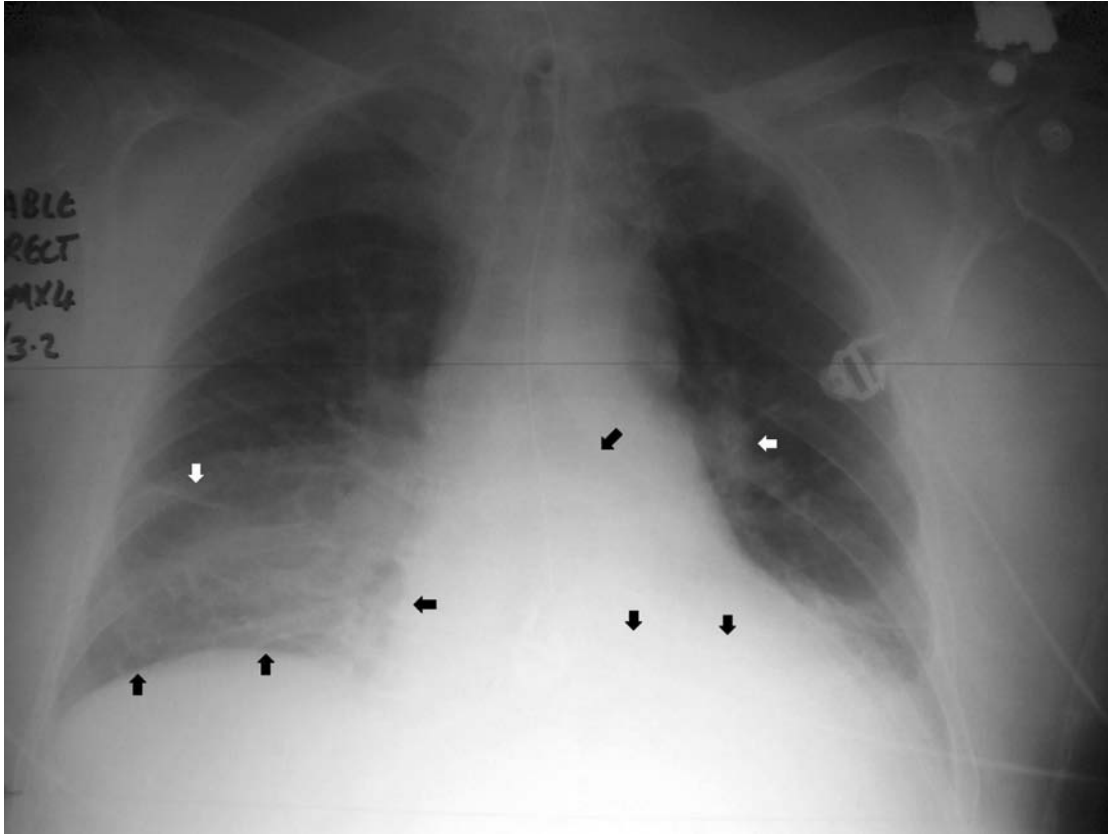


Figure 10.9

Semi-erect CXR of an adult in an intensive care unit. The patient has a large right pleural effusion causing increased opacity of the right lower zone with fluid tracking into the minor fissure but preserving the diaphragmatic (black arrows vertical up) and right heart border (black arrow horizontal) silhouettes due to the posterior position of the fluid. Note also on this CXR the loss of the left diaphragmatic silhouette (black arrows vertical down) due to left lower lobe collapse; the left hilum is depressed (white arrow), the left main bronchus is more vertical (black arrow diagonally down) and the right heart border overlies the spine (black arrow horizontal) all signs which are indicating left lower lobe volume loss.

Subpulmonic pleural effusion

- Sometimes pleural fluid collects beneath the lung with little or no component extending lateral to the lung.
- It can be difficult to identify on an erect chest; the diaphragm often appears to be high with the dome peaking more laterally than usual (Fig 10.10).
- Typically subpulmonic effusions are simple in nature and therefore the fluid is free flowing and becomes apparent when the patient is X-rayed in the supine position.

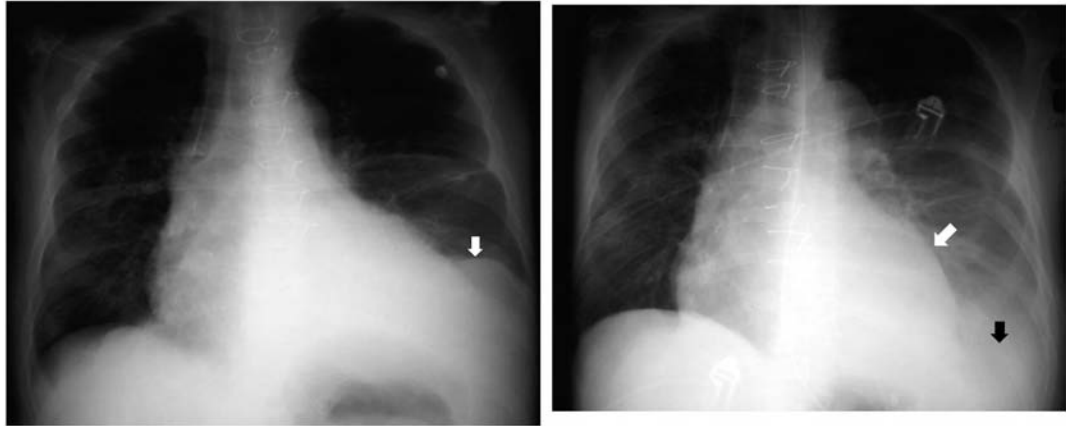


Figure 10.10

Subpulmonic pleural effusion. Left image – erect CXR demonstrates an apparently raised left hemi-diaphragm (white arrow). Note the diaphragm is peaking more laterally than usual. The right image is a supine CXR of the same patient. The subpulmonic fluid has redistributed in the posterior pleural space causing a vague increase in opacity, obscuring the left hemidiaphragmatic silhouette (black arrow) but preserving the left heart border as this lies anteriorly (white arrow).

Complex pleural effusion

- When the contour of the effusion is not meniscal as described above but straight or convex, this implies that the effusion is complex in nature containing viscous fluid and/or septations.
- Complex effusions do not necessarily occupy the dependent spaces and may therefore occur in isolation anywhere in the pleural space.
- A complex pleural collection raises the possibility of an empyema or haematoma but chronic simple effusions can become complex without a supervening infection and a simple pleural effusion in a complex pleural space may mimic these appearances i.e. after previous surgical intervention or infection (Fig 10.11).

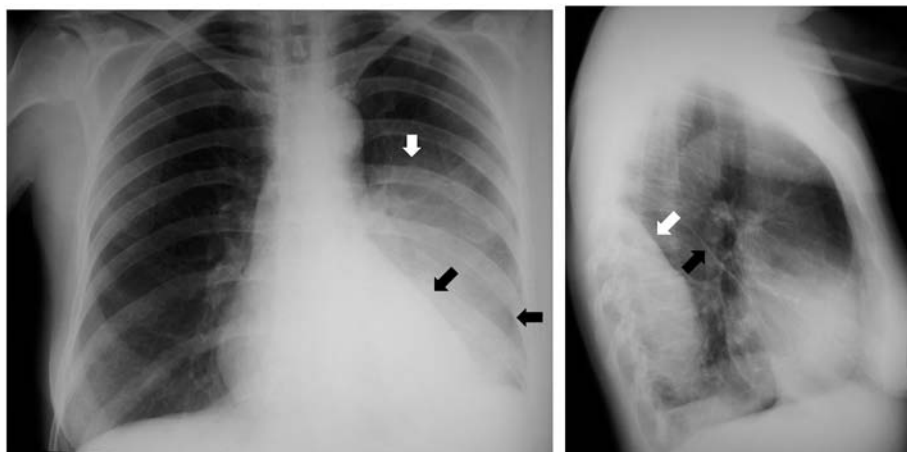


Figure 10.11

Left image: erect frontal CXR of a patient with a complex pleural effusion. Fluid aspirated was sterile. Note increased opacity but no meniscal appearance, a convex superior margin (white arrow) and relative preservation of the lateral subpleural region (horizontal black arrow) and left heart border (diagonal black arrow). Right image: lateral CXR demonstrates posterior loculated fluid collection with a convex anterior margin (white arrow) distinct from a normally positioned major fissure (black arrow).

Empyema

- An empyema is an infection in the pleural space. The fluid may vary from turbid to thick pus and can be very difficult to drain.
- On CXR an empyema presents as a complex pleural collection.
- Fibrous bands may create locules and the thicker fluid/pus may not be as mobile as the fluid of a simple pleural effusion, therefore failing to collect in the dependent areas (Fig 10.12).

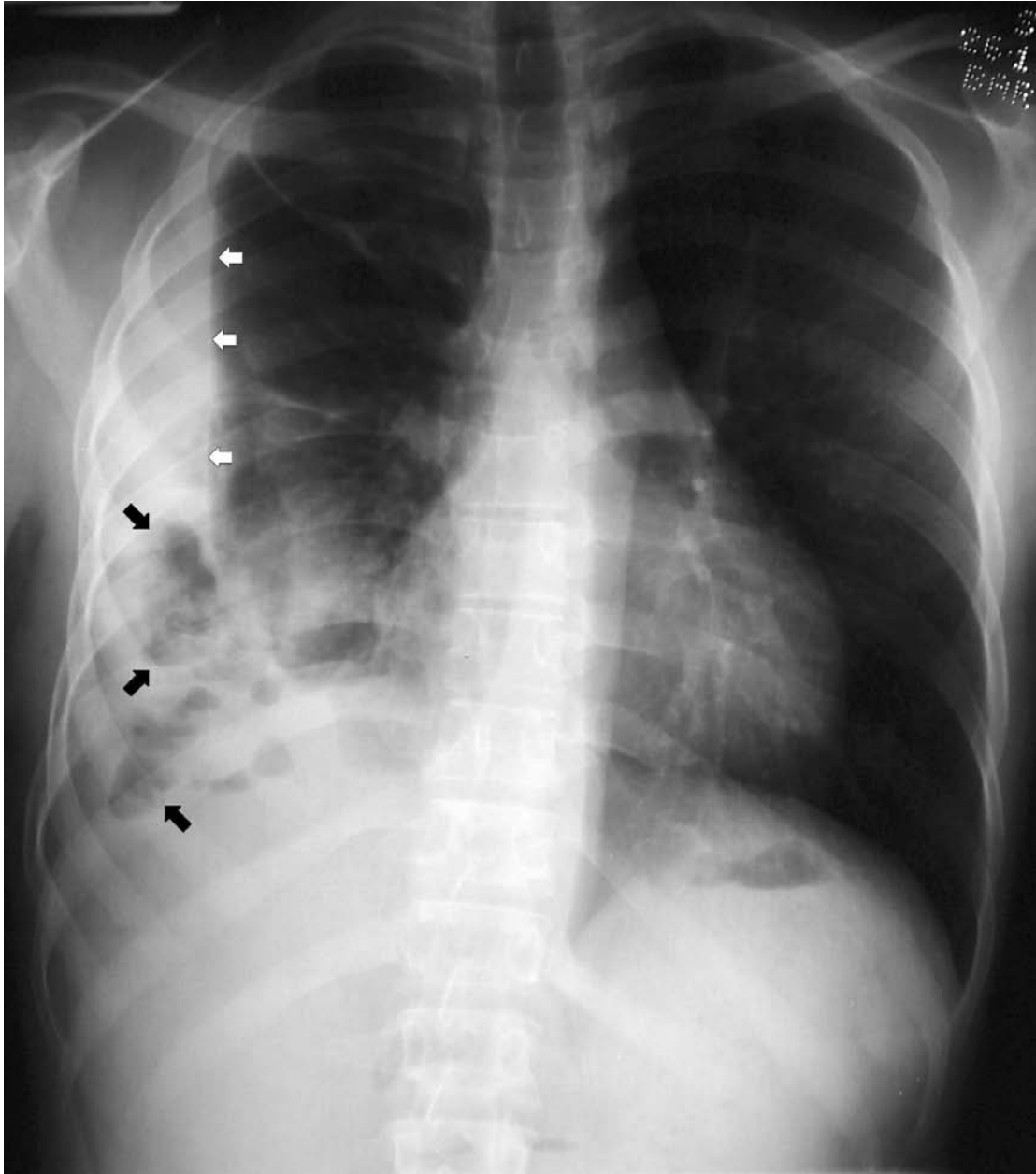


Figure 10.12

Frontal CXR of an adult with a right sided empyema. Note the pleural based opacity with a vertical (white arrows) rather than meniscal contour indicating a complex collection in this case including pockets of air (black arrows).

- The presence of pleural opacity that fails to conform to the meniscal appearance characteristic of a simple pleural effusion should alert the reader to the possibility of an empyema, or pleural tumour.
- Extension of an empyema outside the chest wall may mimic an invasive soft tissue mass (Fig 10.13).

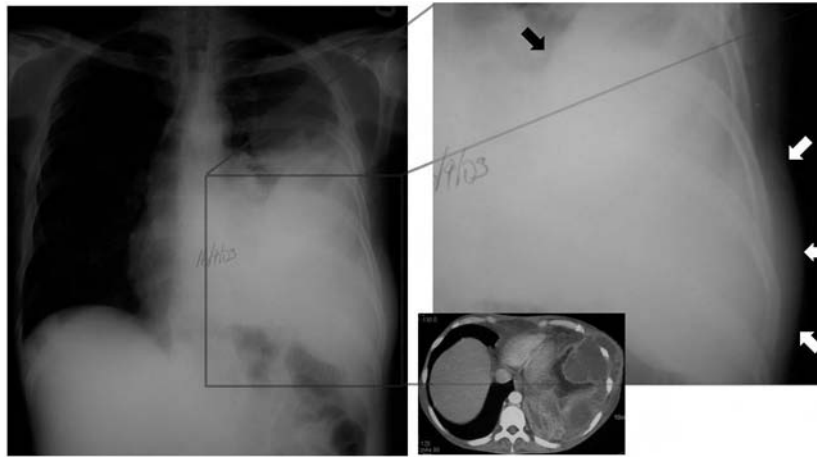


Figure 10.13

Frontal CXR of an adult male patient with TB empyema extruding through the chest wall. The magnified image demonstrates the increase in soft tissue of the chest wall (white arrows) and the convex upper margin of the empyema. The CT inset demonstrates the loculated nature of the collection.

- Simple percutaneous drainage should be attempted prior to surgical drainage.
- Residual pleural thickening is a common sequel of empyema and a base line CXR on resolution of symptoms will help interpret subsequent CXRs should further pleural problems arise.

Haemothorax

- A haemothorax is the presence of blood in the pleural space, which, as it becomes organized, behaves more like an empyema than a simple pleural effusion with undulating contours on CXR due to loculation and accumulation in non-dependent areas.
- The patient's history should contain a suitable cause such as recent trauma or surgery.
- Long term complications of a haemothorax are chronic pleural thickening and heavy pleural calcification (Fig 10.14).

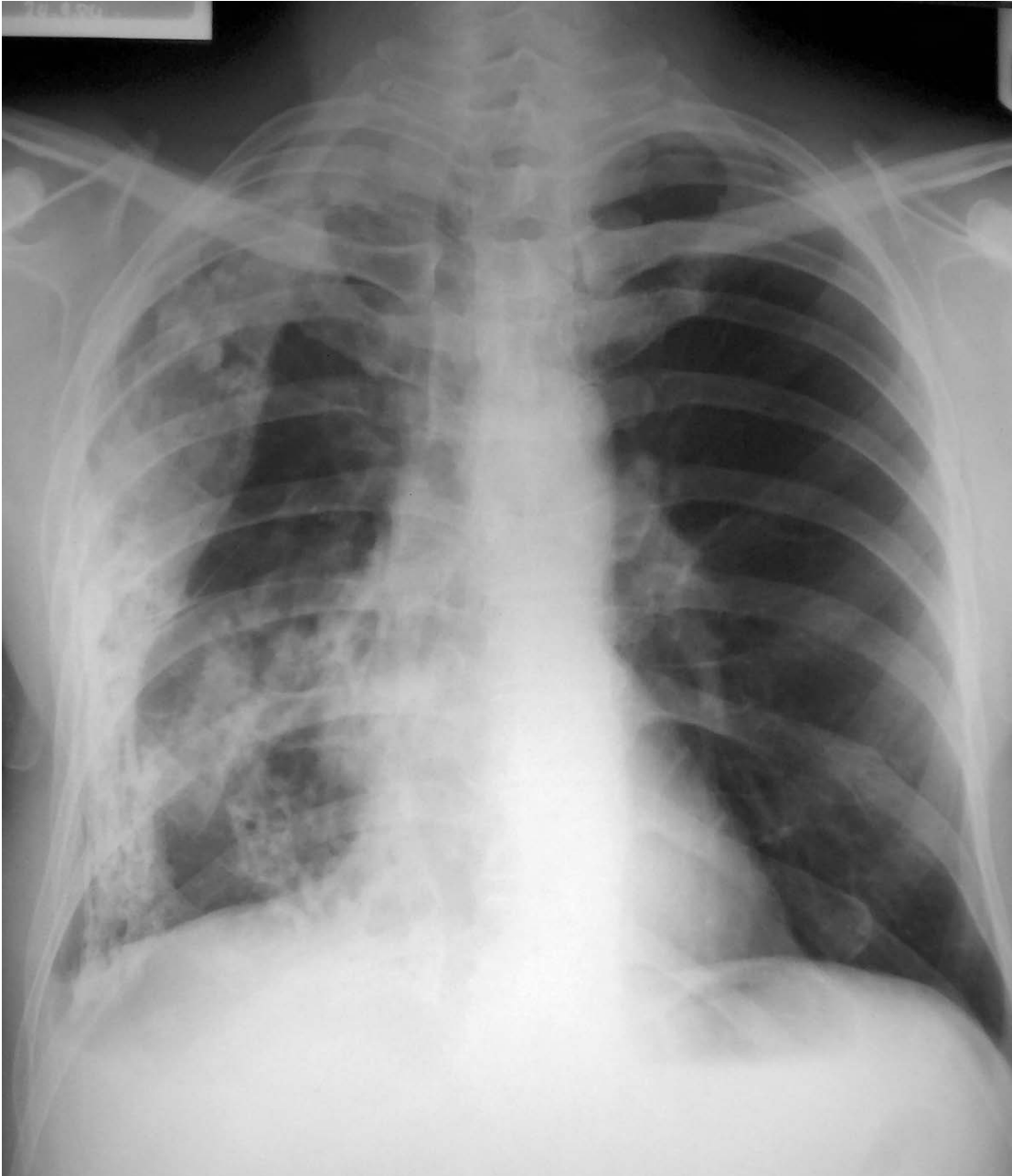

Figure 10.14

Frontal CXR of an adult male that developed pleural thickening and calcification following a right sided haemothorax. Note the dense pleural thickening with heavy calcification and loss of volume on that side of chest.

Pleural calcification

- Calcification of the pleura is readily seen on the CXR, in particular, where the pleural surface is in line with the X-ray beam, i.e. over the hemidiaphragms, the lateral margins of the chest and the apices (Fig 10.15).

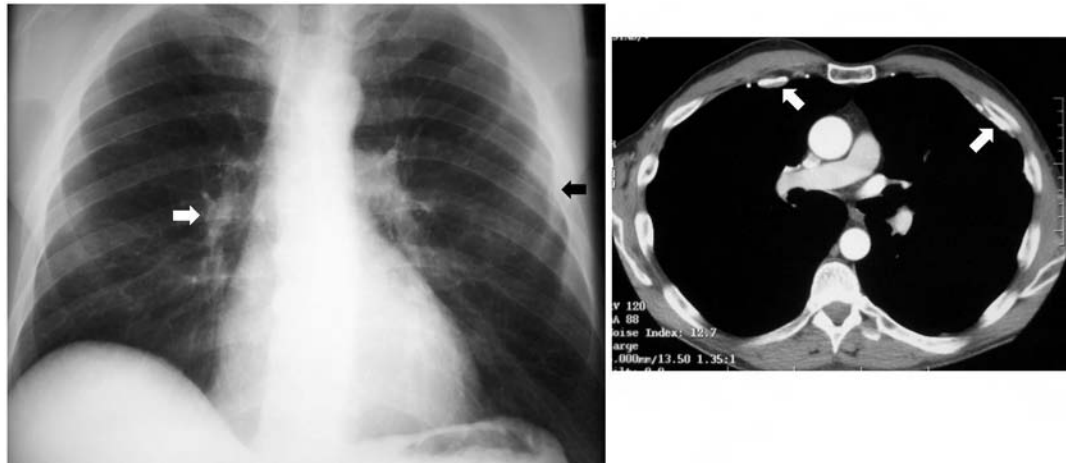


Figure 10.15

Frontal CXR and axial CT image of an adult male patient with a history of exposure to asbestos. Peripheral calcified pleural plaques are relatively easy to identify (black arrows) but calcified pleural plaques en face to the X-ray beam can convincingly mimic nodules, masses or in this case right hilar enlargement (white arrows).

- Pleural calcification on the mediastinal contour is unusual but pericardial calcification as a sequel of pericarditis may be observed.
- Difficulty may arise when the pleural calcification is en face, i.e. lies across the X-ray beam. The margins of the calcification may be visible but surround an area of density that may mimic a soft tissue mass (Fig 10.16). In such circumstances, the presence of other definite areas of pleural calcification may be reassuring but could equally be misleading (Fig 10.17).

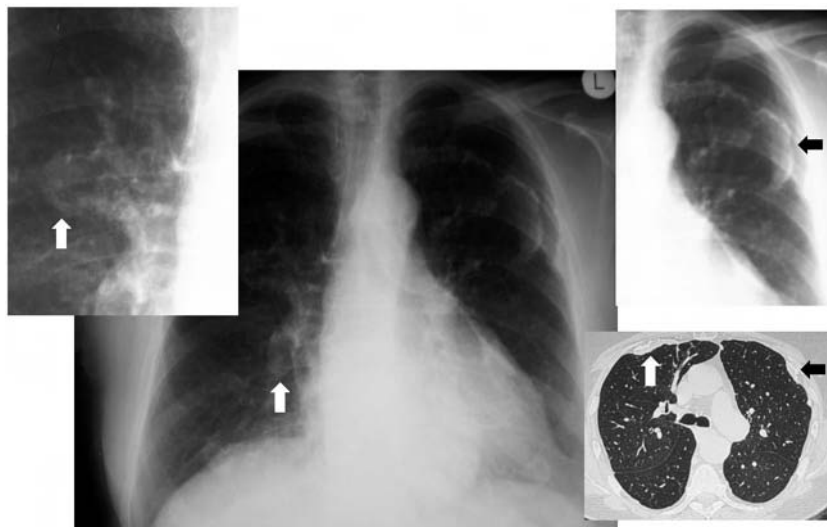


Figure 10.16

Frontal CXR and single axial HRCT image of an adult male patient with a strong history of previous asbestos exposure. Note the heavily calcified pleural plaques seen in the line of the X-ray beam that do not create any diagnostic difficulty (black arrows). The plaque seen en-face (white arrow) overlies the hilum and is not so readily diagnosed.

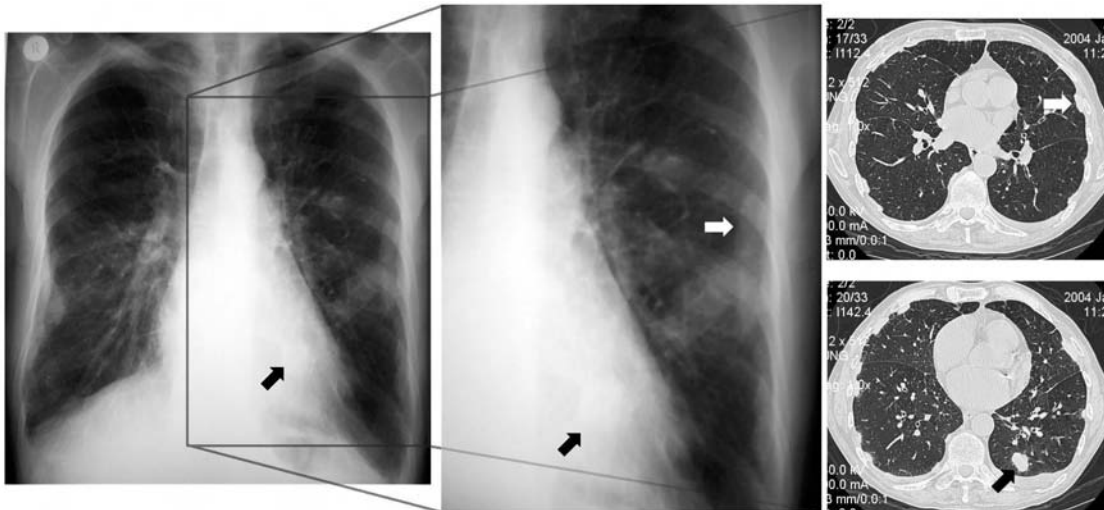


Figure 10.17

Frontal CXR of an adult male with asbestos related calcified pleural plaques (white arrows) clearer on HRCT but note the density projected behind the heart (black arrow). It could easily be discarded as a calcified plaque en face but as demonstrated on the HRCT image is clearly a soft tissue nodule. This distinction may have been possible with a lateral CXR.

- Possible causes of heavy pleural calcification include previous haemothorax or empyema (particularly tuberculous empyema) and exposure to asbestos (usually bilateral).

Mesothelioma

- Mesothelioma is a malignant tumour of the pleura divided into three types histologically, epitheloid, adenomatoid and mixed cellularity. It is most commonly a result of exposure to asbestos.
- The features that suggest malignant rather than benign pleural thickening are, thickness greater than 1 cm, nodular or undulating surface, involvement of the mediastinal pleura, encasement of the lung and evidence of chest wall invasion. All these features may be appreciated on a CXR depending on the size of the tumour (Fig 10.18).

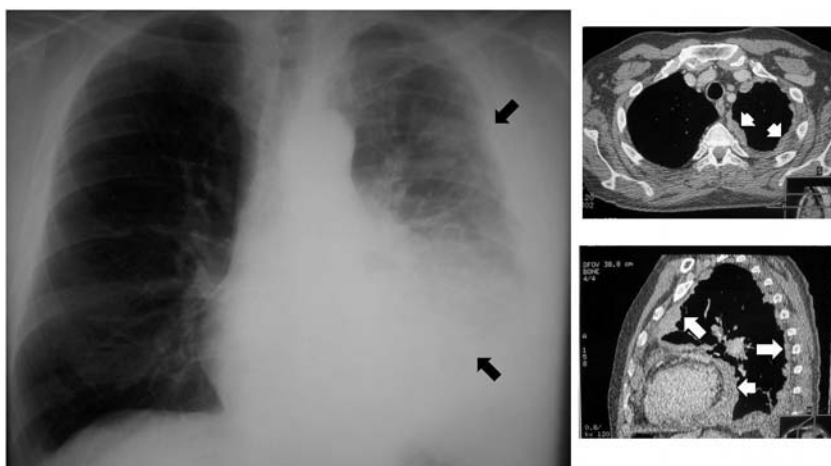


Figure 10.18

Frontal CXR of an adult male with mesothelioma following exposure to asbestos. Note the thickening of the pleura best seen laterally. At the left base the pleural thickening is such that the left heart border is obscured indicating the involvement of the mediastinal pleura, a reliable sign of malignancy. The axial and sagittal CT images demonstrate the encasement of the lung.

- An early sign of mesothelioma is loss of volume of the affected hemithorax.
- Other malignant pleural tumours to consider include metastases, and extension/spread of malignant thymoma. The distribution may be difficult to distinguish from mesothelioma but in the latter the originating malignant thymoma should be visible on CXR.
- Benign pleural tumours to consider are pleural fibroma (Fig 10.19), pleural lipoma and progressive massive fibrosis (PMF) (Fig 10.20). These tend to be focal in nature and in the case of PMF often multifocal and associated with diffuse pulmonary diseases such as interstitial fibrosis, silicosis etc.

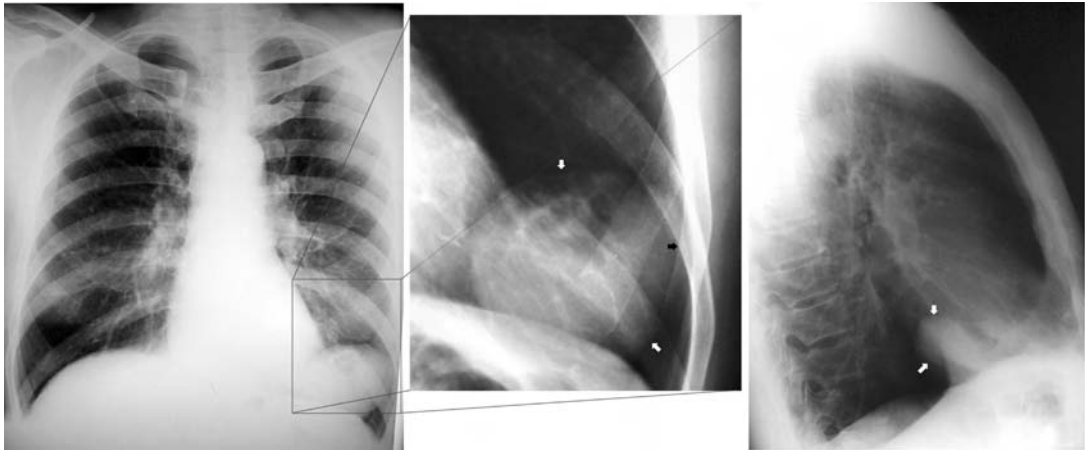


Figure 10.19

Frontal and lateral CXRs of an adult male with a left basal pleural fibroma. Note the clearly defined margins (white arrows) on all but the attachment to the chest wall (black arrow) which at surgery was found to be pedicular. (Images courtesy of Janet Dacey).

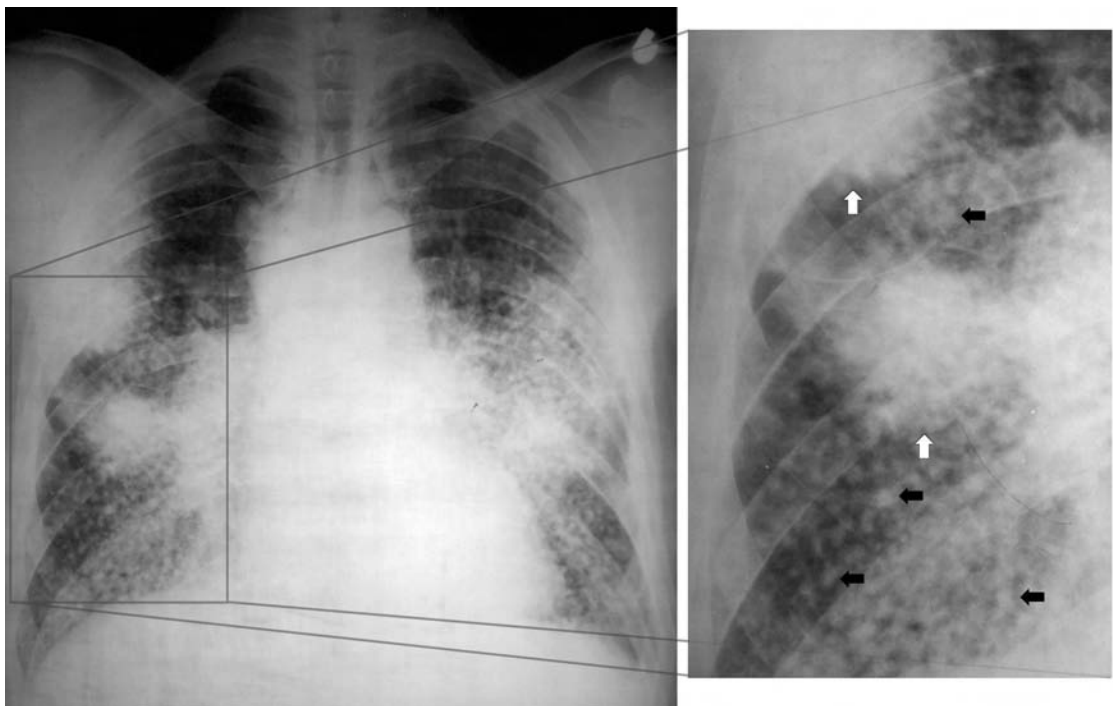


Figure 10.20

Frontal CXR of an adult male patient with silicosis. Note the diffuse nodules (black arrows) and progressive massive fibrosis (PMF), large patches of fibrotic lung causing focal dense opacities on the CXR (white arrows). (Image courtesy of Janet Dacey).

Left heart failure

Cardiomegally

- Long standing left heart failure results in a progressive enlargement of the left ventricle and left atrium, the latter particularly when mitral valve disease is present.
- Enlargement of the left ventricle, which forms the left heart border on a CXR, results in an increase in size of the cardiac silhouette (Fig 11.1).

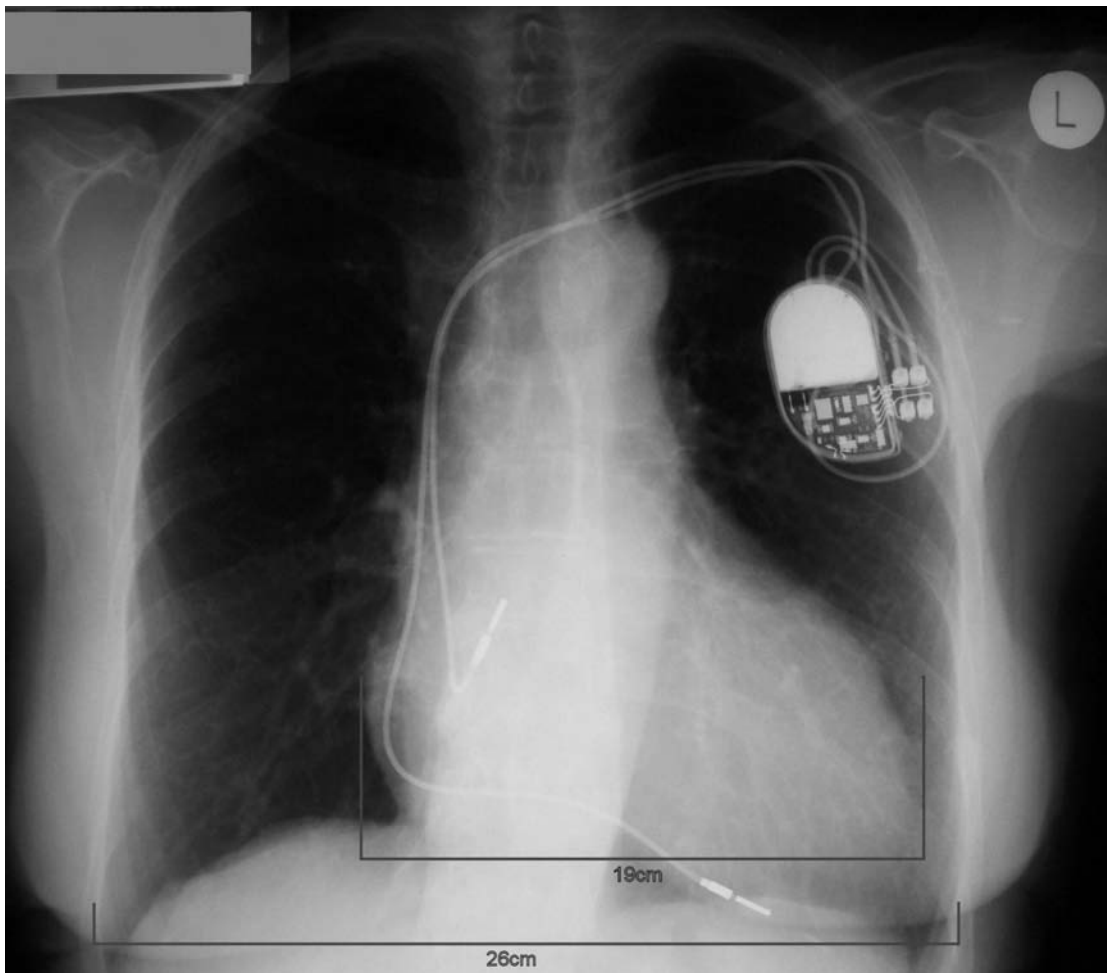


Figure 11.1
Frontal (PA) CXR of an adult female patient with a dual chamber pacemaker. The cardiac diameter is 19cm (normal up to 14.5cm) and the cardiothoracic ratio (CTR) is 19/26.

- The ratio of cardiac diameter to the maximum diameter of the thoracic cage (cardiothoracic ratio or CTR) gives a gauge of the amount of cardiac enlargement and is of most use on serial measurements.
- CXR evidence for enlargement of the left atrium includes (Fig 11.2, 11.3):
 - enlargement of the left atrial appendage affecting the left heart border
 - a double right heart border caused by the projection of the right wall of the left atrium behind the silhouette of the right atrium
 - widening of the carina

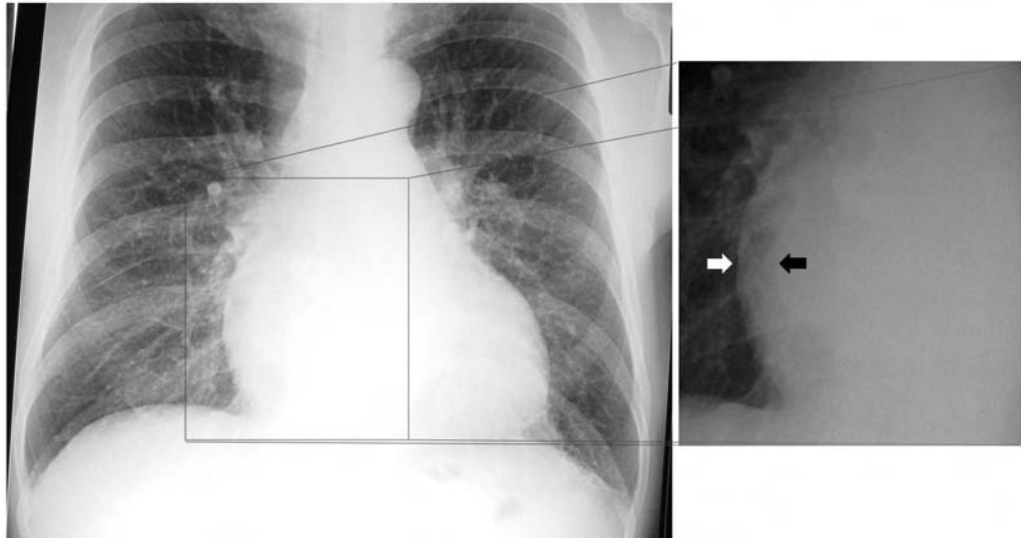


Figure 11.2

Frontal CXR of a patient with early left heart failure. The magnified view demonstrates the double heart border, right atrial wall (white arrow) and left atrial wall (black arrow).

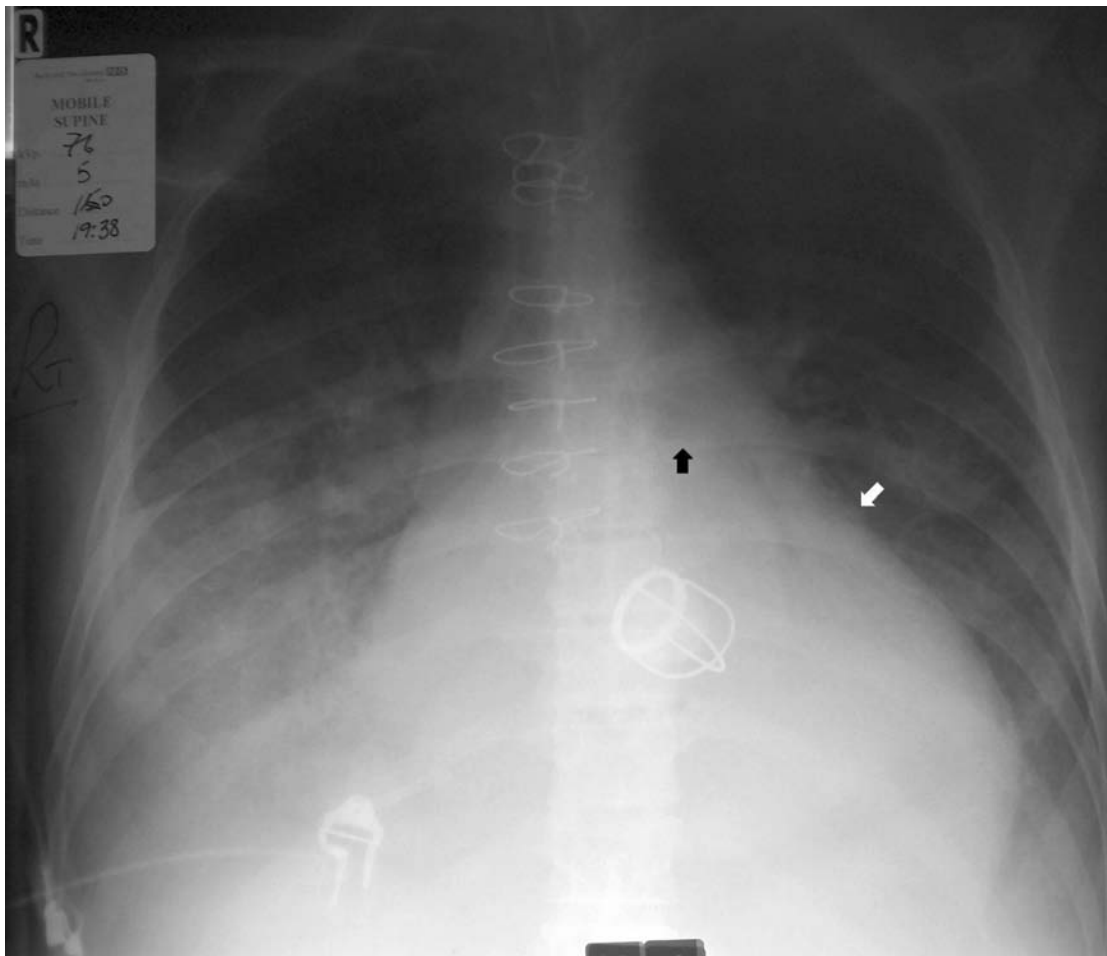


Figure 11.3

AP semi-erect CXR of an adult patient in heart failure. Note the prosthetic mitral valve and cardiomegaly. Elevation of the left main bronchus (black arrow) and loss of the normal concavity of the left heart border at the level of the left atrial appendage indicate left atrial enlargement.

Interstitial oedema

- In left heart failure, there is an increase in the pressure within the capillary bed of the lung resulting in the accumulation of fluid in the lung interstitium.
- On a CXR, this is visualized as reticulation and may be too subtle to detect with confidence (Fig 11.4).

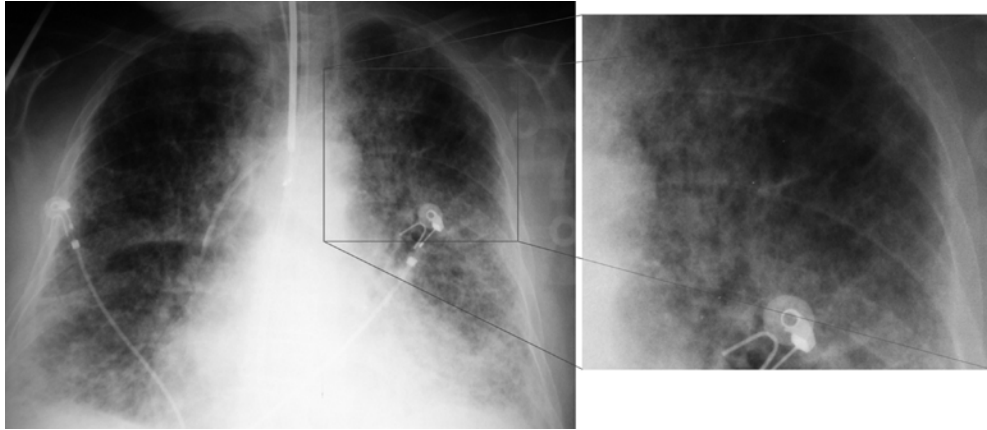


Figure 11.4

Semi-erect CXR of an adult patient developing severe left heart failure. Note the bilateral peri-hilar shadowing, which falls short of consolidation and has a reticular pattern. This is interstitial oedema and progressed to frank perihilar consolidation within hours.

Blood diversion

- The increase in pressure in the interstitium causes compression of the capillary bed; due to gravity the effect is more marked in the lower lobes causing shunting of blood into the upper lobes.
- The result is upper lobe blood diversion, enlargement of the upper lobe pulmonary veins, and lower lobe vasoconstriction such that the lower lobe pulmonary veins are smaller than those of the upper lobes, a reversal of the normal state (Fig 11.5).

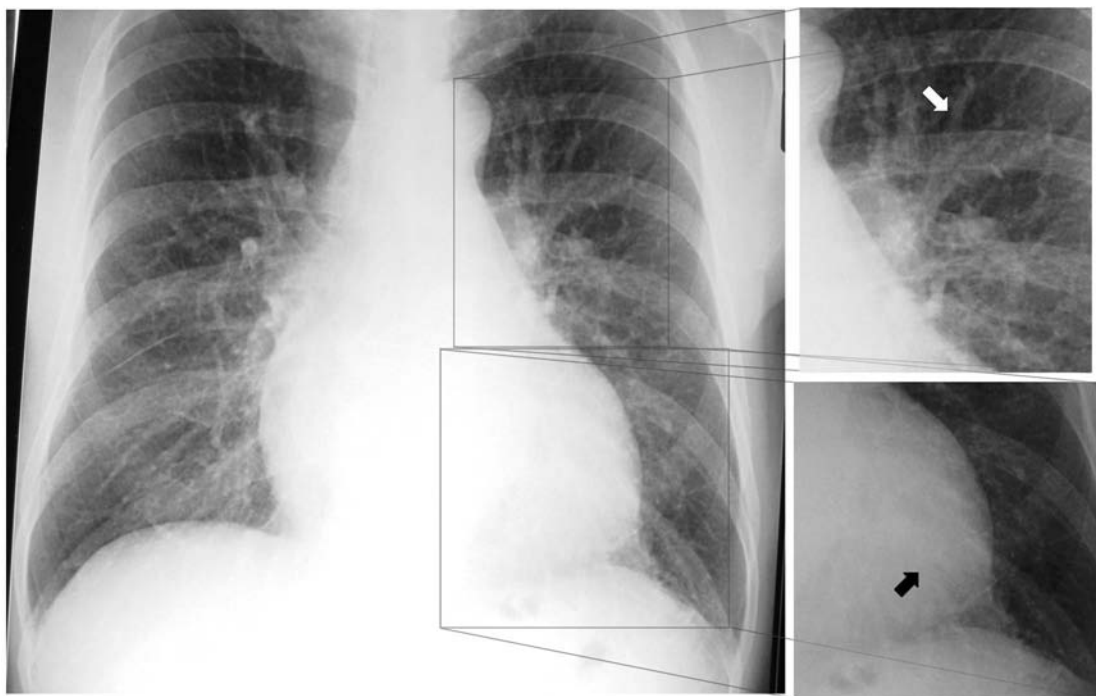

Figure 11.5

Frontal CXR of an adult patient with early left heart failure. The magnified views demonstrate dilated upper lobe veins (white arrow) and constricted lower lobe veins (black arrow).

Consolidation

- As the degree of interstitial oedema increases, fluid accumulates in the alveolar air spaces and interlobular septa initially causing ground glass opacity, an increase in lung opacity, progressing to consolidation/pulmonary oedema, where air-bronchograms may be seen.
- Pulmonary oedema classically has a bilateral perihilar distribution (Fig 11.6).

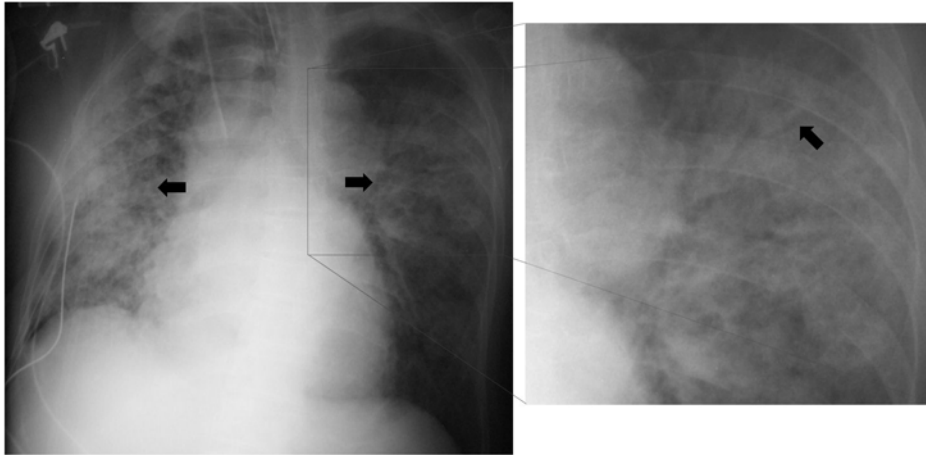


Figure 11.6
Frontal CXR of a patient with pulmonary oedema in a classic perihilar distribution (horizontal black arrows). The magnified view demonstrates air-bronchograms (diagonal black arrow).

Septal lines

- The accumulation of fluid in the interlobular septa, septal lines, may be difficult to distinguish from the interstitial reticulation or obscured by the air-space opacification.
- Septal lines are best seen at the costophrenic angles, where each diaphragm joins the chest wall. Septal lines are 2–3 mm in thickness around 10 mm in length and extend to the pleural surface where they contact it at 90 degrees.
- In more severe pulmonary oedema, more central septal lines may be found, which radiate from the hila.

Effusions

- Ultimately fluid accumulates in the pleural space causing a pleural effusion, which, in the earliest stages, may only be visible on an erect CXR through “blunting” of the costophrenic angle being the most dependent area of the pleural space (Fig 11.7).

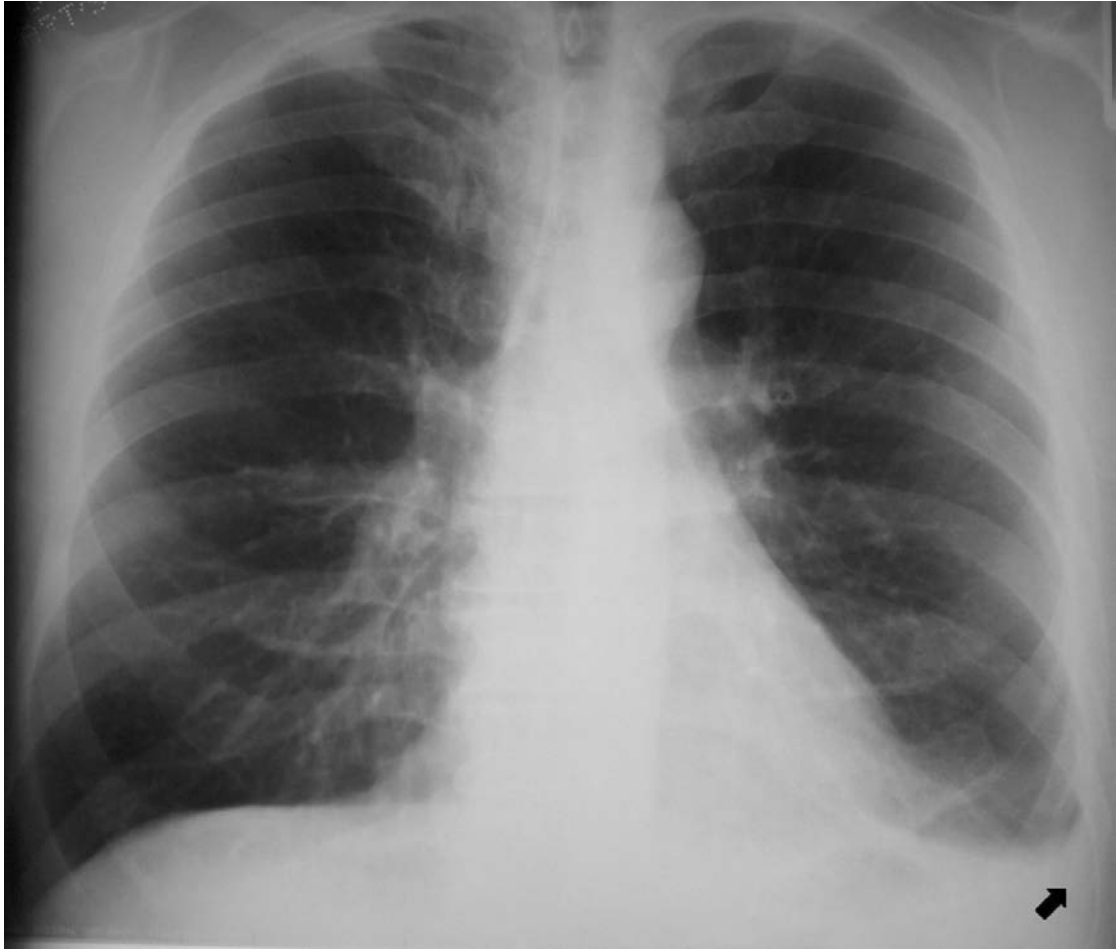

Figure 11.7

Frontal CXR of an adult male with a small left pleural effusion secondary to developing heart failure. Note the "blunting" of the costophrenic angle (black arrow).

- As the amount of fluid increases the pleural space gradually fills up causing increased opacity and obscuring the diaphragmatic silhouette.
- On a frontal CXR, the effusion will typically have a meniscal appearance.
- Effusions secondary to heart failure are usually bilateral, rarely symmetrical and can be unilateral, particularly in a patient who favours lying on one side.

Cardiac

Recognition of cardiac abnormalities on a CXR depends upon appreciating changes in the mediastinal silhouette and/or observing the effect of the abnormality on the lung vasculature.

Coarctation of the aorta

- Coarctation of the aorta typically occurs at the isthmus just distal to the arch.
- Present from birth, the coarctation may significantly reduce the vascular supply to the trunk and lower limbs such that collateral circulation develops via the intercostal arteries that originate from the aorta distal to the coarctation.
- On a CXR, the aortic knuckle will appear small and may demonstrate the characteristic reverse “3” appearance (Fig 12.1).

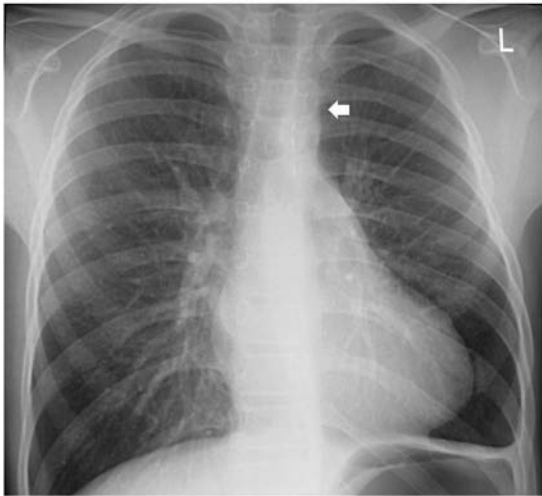


Figure 12.1

Frontal CXR of a young boy with coarctation of the aorta. Note the reversed “3” sign (white arrow), but due to the young age any intercostals collateral vessels are not of sufficient size to cause rib notching.

- The enlargement of the intercostal arteries, over time, causes erosion of the underside of the adjacent ribs, visible on a CXR as rib notching (Fig 12.2). In children the rib notching may not be apparent.

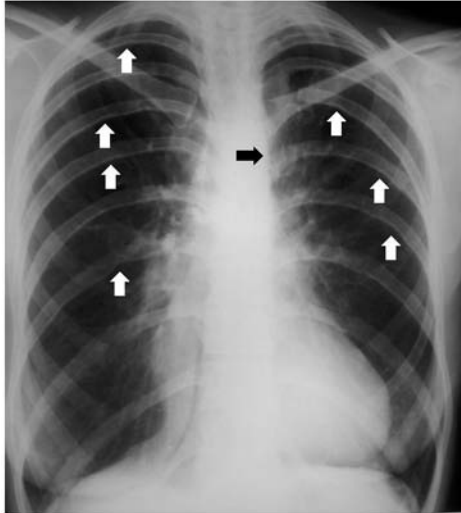


Figure 12.2
Frontal CXR of an adult male patient with corrected aortic coarctation. Note the small aortic arch (black arrow) and the numerous rib notches (white arrows).

Falot's tetralogy

- Falot's tetralogy describes the combination of four cardiac abnormalities; overriding aorta, ventricular septal defect, pulmonary stenosis and right ventricular hypertrophy.
- On a CXR, the classical appearances are of a boot shaped cardiac contour as a result of the right ventricular hypertrophy and a narrow cardiac root due to the overriding aorta (Fig 12.3).

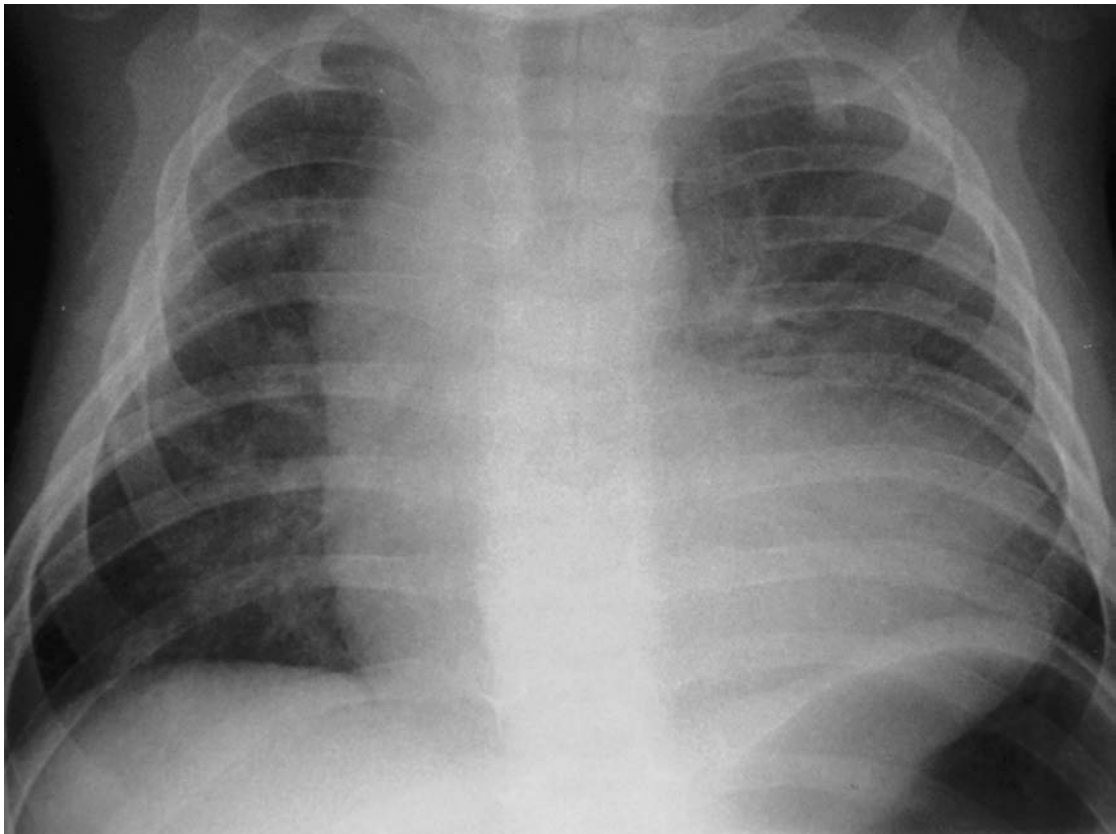


Figure 12.3
Supine CXR of an infant with Falot's tetralogy. Note the boot shaped heart due to right ventricular hypertrophy and an overriding aorta.

Cardiomegally

- Enlargement of the heart is assessed on a CXR by measuring its maximum diameter (Fig 12.4).

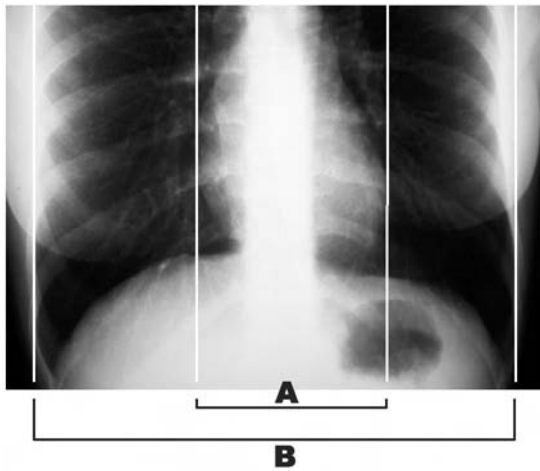


Figure 12.4
Demonstration of the cardiothoracic ratio (CTR).
A = cardiac size, B = thoracic diameter,
 $CTR = A/B$.

- Heart size will vary with body habitus making absolute lower limits meaningless, but reasonable upper limits for adults are 15.5 cm for females and 16 cm for males.
- Serial measurement of heart size is best determined by measuring cardiothoracic ratio.
- As the heart borders defining the mediastinal contours correspond to the left ventricle and right atrium, left atrial enlargement may be difficult to appreciate on a CXR. Useful signs are enlargement of the left atrial appendage, a double right heart border and widening of the carina. (Fig 11.2, 11.3).
- An enlarged fibrillating left atrium may develop mural thrombus, which can be identified if calcification of the thrombus occurs (Fig 12.5).

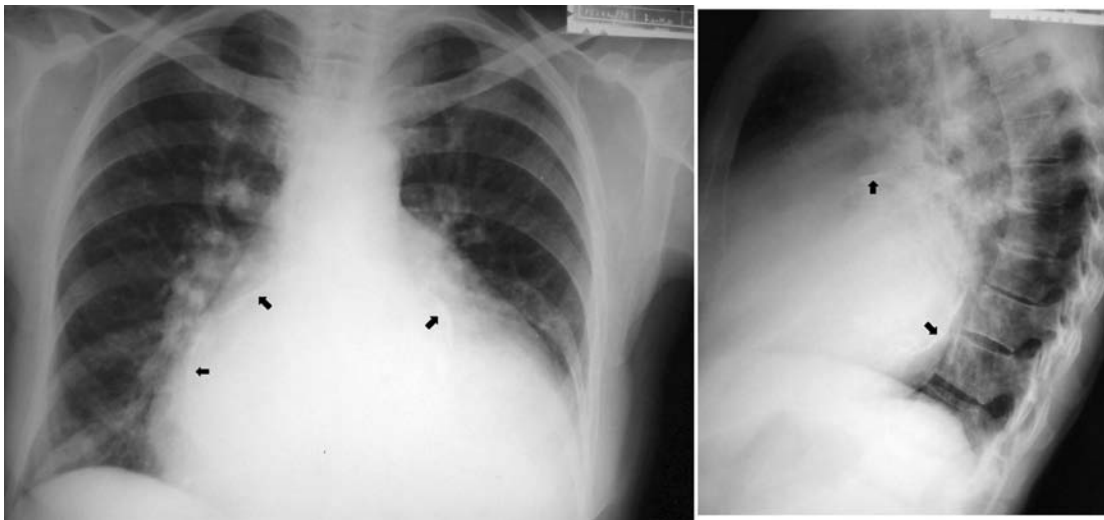


Figure 12.5
Frontal and lateral CXR of an adult with a grossly enlarged left atrium, in fibrillation with an extensive mural thrombus indicated by the curvilinear calcification following the contour of the atrium (black arrows). (Images courtesy of Janet Dacey).

Pericardial effusion

- A pericardial effusion is the accumulation of fluid, usually blood stained, in the potential space between the two layers of pericardium.
- The pericardium is enclosed such that the fluid is trapped and any increase in volume is compensated for by expansion of the pericardium or compression of the heart. As a result a pericardial effusion can have a profound impact upon cardiac function.
- Pericardial effusions are difficult to appreciate on CXR. The most obvious signs are a change in the shape of the heart to a more rounded contour (the globular heart) (Fig 12.6) and a rapid increase in size of the cardiac silhouette.

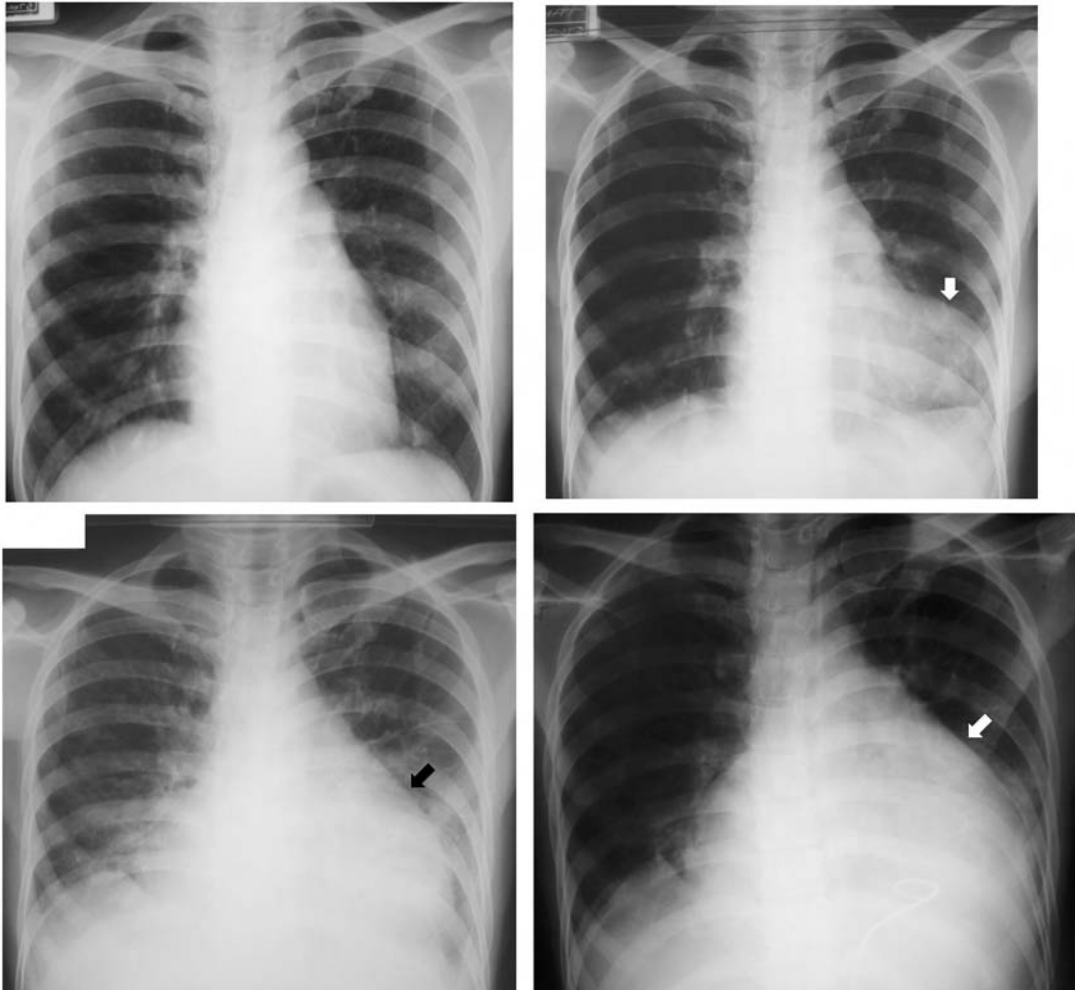


Figure 12.6

Four images demonstrating the evolution of a large pericardial effusion. Top left is the normal CXR, top right there is a change in the cardiac silhouette (white arrow) representing fluid accumulation around the left ventricle. Bottom left the concave margin relating to the left atrial appendage has filled in, giving a globular shape to the heart, and bottom right, there has been a further increase in heart size with a globular shape. Note the clearness of the left heart border (white arrow), the silhouette is now formed by a sack of fluid surrounding the heart and less blurred by cardiac motion.

Pericardial calcification

- Causes of pericardial calcification are listed in Table 12.1.

Table 12.1 **Causes of pericardial calcification**

Pericarditis (TB, rheumatic fever, viruses)
Post-traumatic
Uraemia

- On a CXR, there is curvilinear calcification on the surface of the heart.
- This should not be confused with calcification of a left ventricular aneurysm.
- Calcification en-face to the X-ray beam is difficult to appreciate but will be readily apparent on a lateral CXR (Fig 12.7).

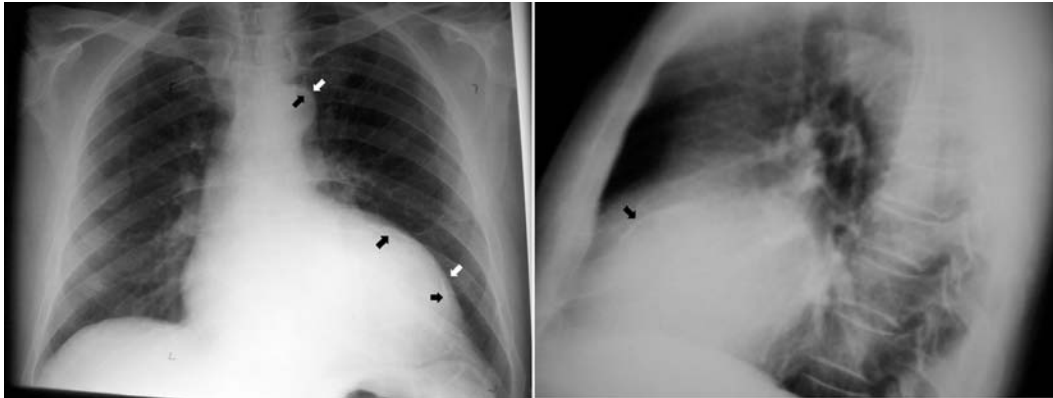

Figure 12.7

Frontal and lateral CXRs. There are two areas of curvilinear calcification (black arrows) that follow the contour of the aortic knuckle and left ventricle but do not lie on the surface of these structures (white arrows). The calcification is therefore inside the wall and due to calcified atherosclerosis in the aorta and calcified thrombus in a left ventricular aneurysm, not pericardial calcification.

Ventricular aneurysm

- A ventricular aneurysm is usually the sequel to a myocardial infarct, typically the left cardiac border changes shape and bulges.
- Mural thrombus is often present and may be visible if calcified (Fig 12.8).

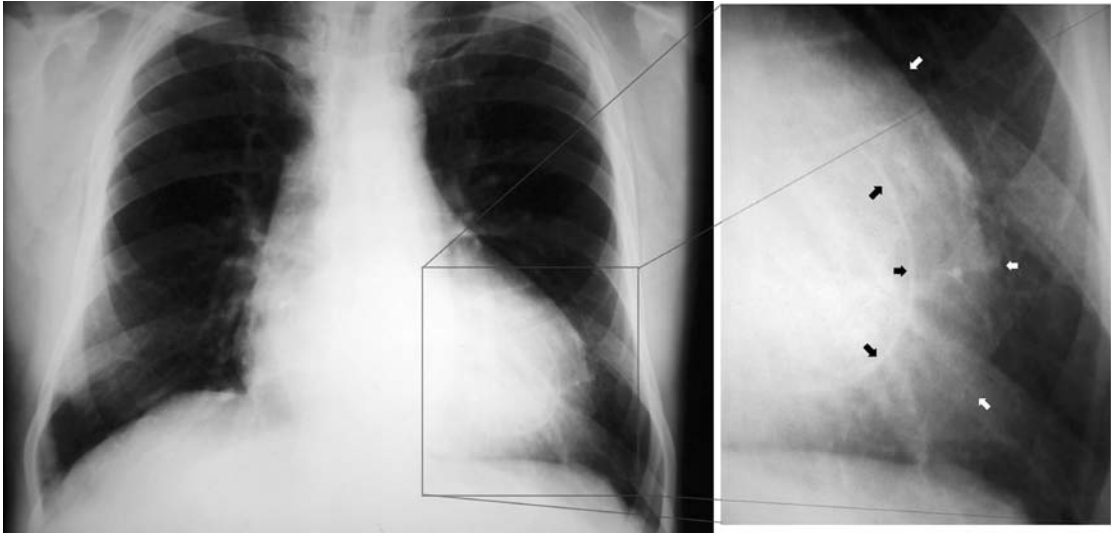


Figure 12.8

Frontal CXR of an adult with a large post myocardial infarct ventricular aneurysm. Note the bulging contour of the left ventricle (white arrows) and the curvilinear calcification (black arrows) due to mural thrombus formation. (Images courtesy of Janet Dacey).

Aortic aneurysm

- The appearance on a CXR of an aortic aneurysm depends upon the section of aorta involved.
- The ascending aorta forms part of the right mediastinal contour where aneurysmal dilatation of the ascending aorta may cause a bulge in the mediastinal silhouette (Fig 12.9).

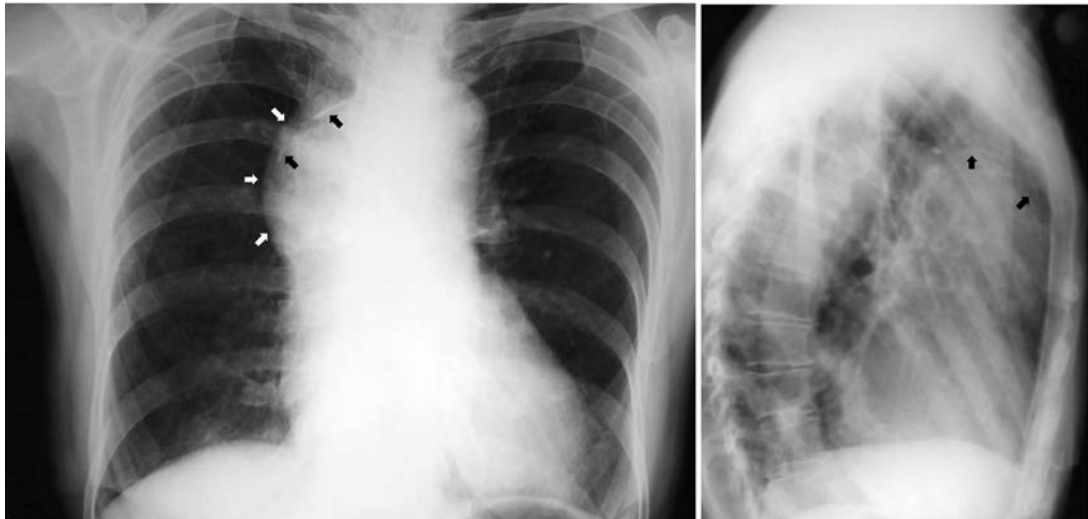

Figure 12.9

Frontal and lateral CXRs of an adult with aneurysmal dilatation of the ascending aorta. Note the rounded right mediastinal contour (white arrows) and the calcification within the wall of the ascending aorta (black arrows).

- Aneurysmal dilatation of the arch of the aorta will manifest as an enlargement of the aortic knuckle (Fig 12.10).

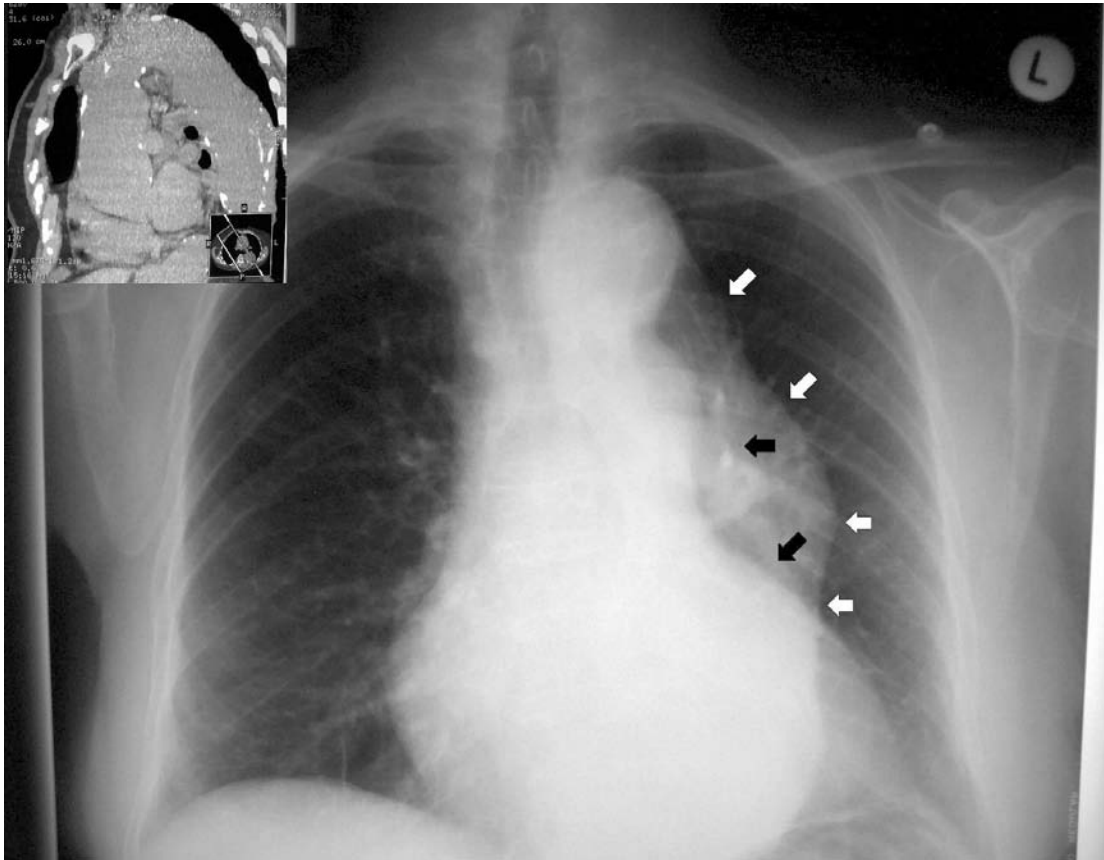


Figure 12.10

Frontal CXR of an adult male with a dissecting thoracic aortic aneurysm. Note the lateral margin of the aorta (white arrows) representing an aneurysmal dilatation of the descending aorta. The posterior placement of this abnormality is evident from the preservation of the hila point (horizontal black arrow) and the left heart border (diagonal black arrow). The inset image is a coronal CT reconstruction of this case.

- The descending aorta lies behind the heart not contributing to the mediastinal contours but its left border is visible lying adjacent to aerated lung. Bulging of this contour suggests aneurismal dilatation, but unfolding of the aorta may mimic the appearance (Fig 12.11).

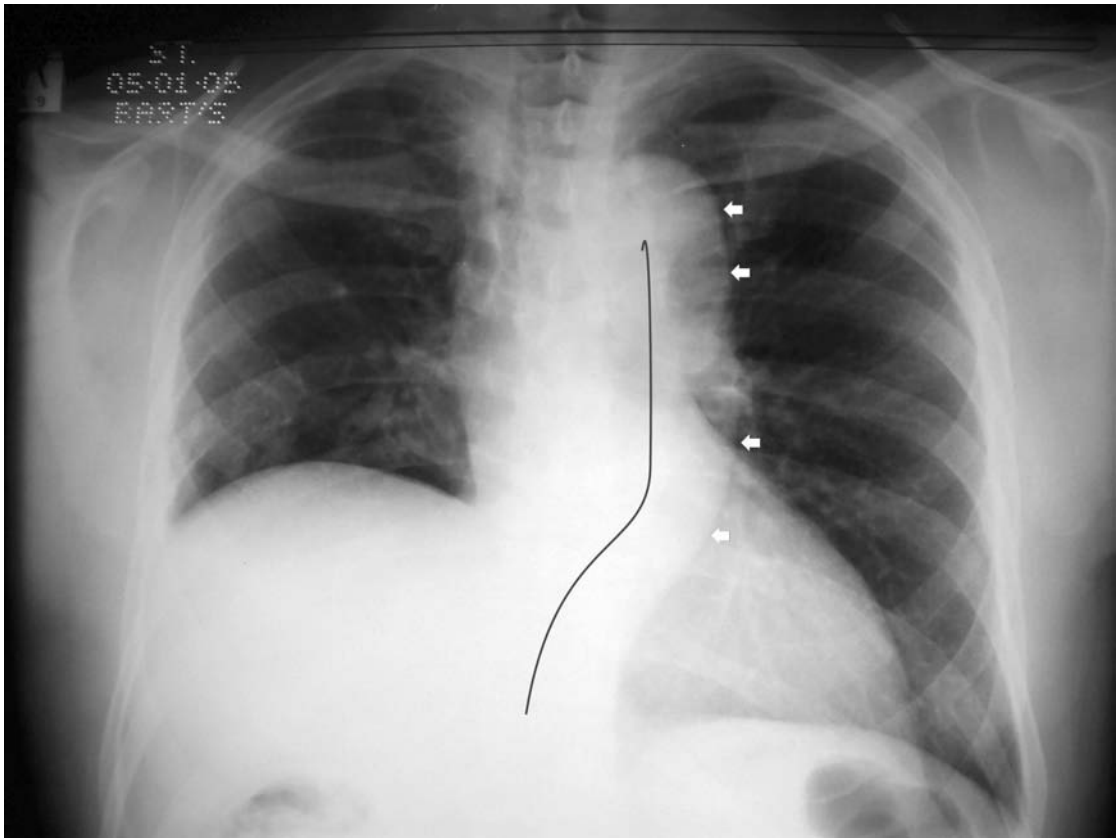


Figure 12.11

Frontal CXR of an adult female. The descending aorta appears dilated but is actually of a normal calibre. The right hand (medial) wall of the aorta is not seen, but is approximated by the grey line.

Pulmonary embolic disease

- The CXR in acute pulmonary embolus (PE) is often normal and its main value is in identifying other possible causes for the symptoms thought to be due to a PE.
- A CXR is required to accurately interpret a ventilation/perfusion scan if this is to be used to diagnose a PE.
- Some signs on the CXR that may indicate a PE are peripheral wedge-shaped opacities representing infarcted sub-segmental areas of lung that may cavitate (Fig 13.1), pleural effusion, atelectasis and paucity of vascular markings in the region of the PE.

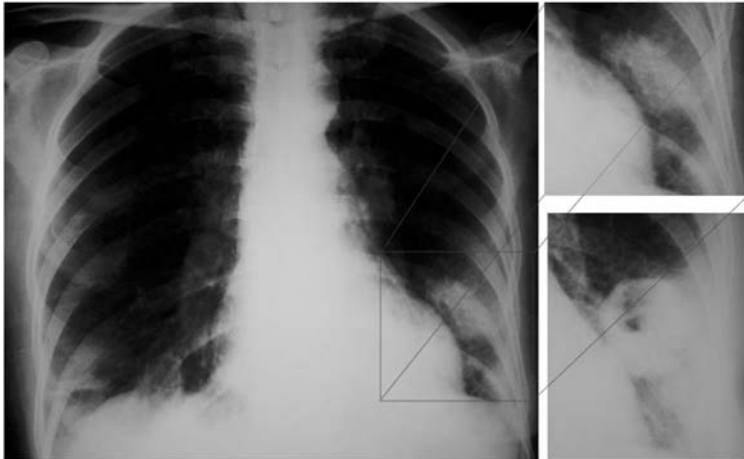


Figure 13.1
Frontal CXR of an adult male patient with a left lower lobe pulmonary infarct that subsequently cavitated (lower inset taken from CXR 3 weeks later).

- Chronic pulmonary embolic disease results from multiple small emboli to the lungs over a long period of time manifest in a gradual deterioration of pulmonary function.
- The signs associated with an acute PE are not a feature, but the development of pulmonary arterial hypertension may be evident with prominent proximal pulmonary arteries (Fig 13.2).

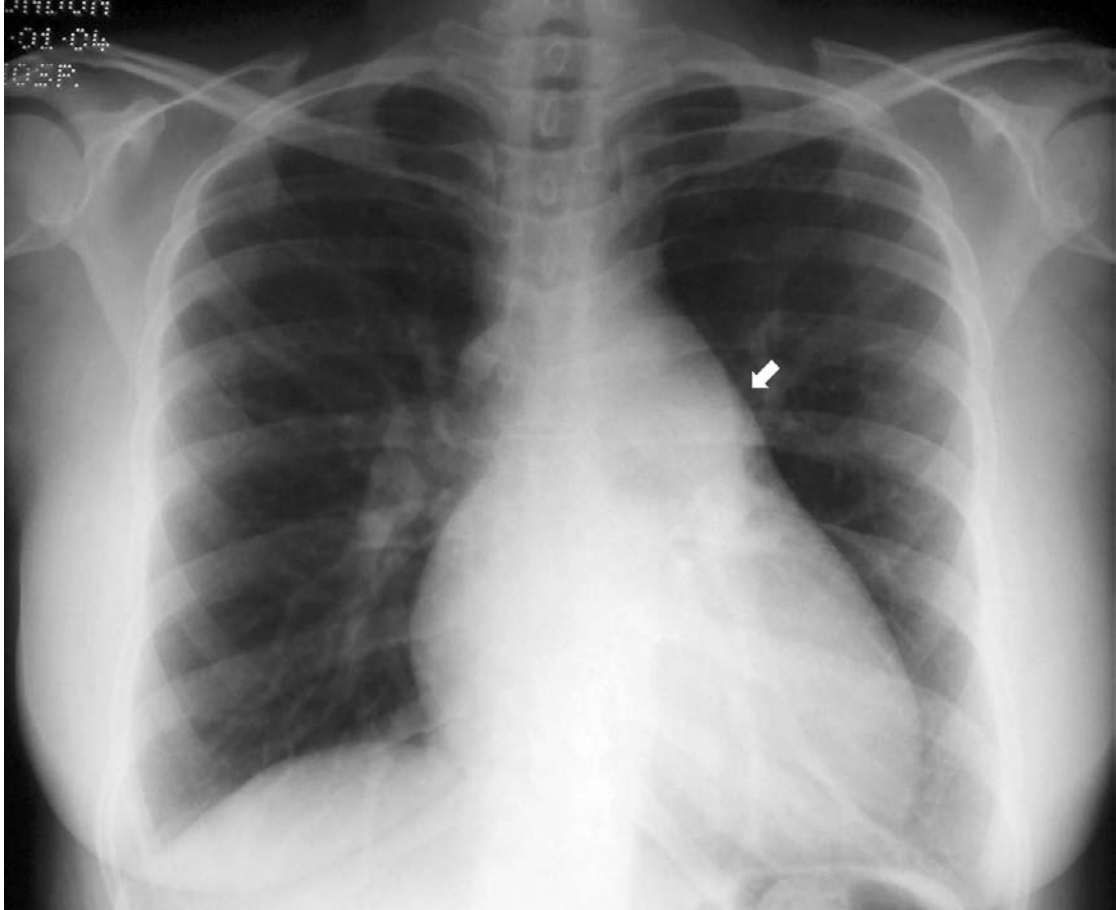

Figure 13.2

Frontal CXR of an adult male with pulmonary hypertension. Note the dilated pulmonary outflow tract causing an abnormal left mediastinal border (white arrow).

Mediastinal disease

- There is little natural contrast in the mediastinum with most adjacent structures of equivalent density and little low density fat in between.
- As a result, most of the interpretation of mediastinal pathology relates to the changes in the interface between the mediastinum and the lung, abnormalities that do not affect this contour or interface are not readily appreciated on a CXR.
- As a result, the extent of mediastinal disease may be underestimated on a frontal CXR.

Mediastinal tumours

- There are many soft tissues within the mediastinum all of which may give rise to tumours.
- In the interest of reducing the list of differential diagnoses for any given mediastinal mass, the site of the tumour is a useful discriminator.
- The mediastinum is most conveniently divided into three regions.
- This demarcation is based upon the structures that lie within each region and therefore define the likely nature of the pathology in the region, and can be described as follows (Fig 14.1):
 - Anterior mediastinum-heart, thymic region, pericardium
 - Middle mediastinum-SVC, descending aorta, hila, oesophagus, trachea
 - Posterior mediastinum-spine, nerve roots

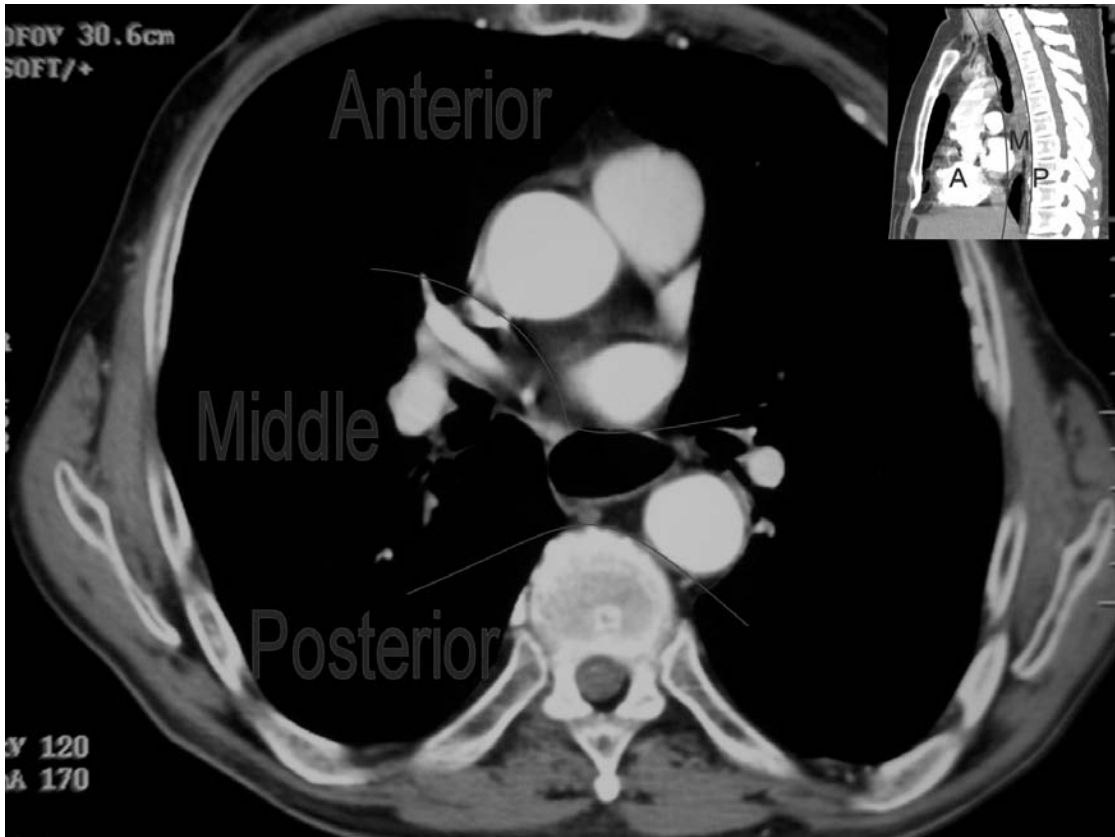


Figure 14.1

The division of the mediastinum into anterior, middle and posterior compartments is easiest to consider in terms of smooth curves drawn anterior to the spine and anterior to the trachea (inset image). However, the true demarcation is somewhat more complicated and governed primarily by the anatomical structures that reside in each compartment.

- Table 14.1 lists the most common tumours in each of those regions.

Table 14.1 Causes of mediastinal masses

Anterior mediastinum	Thymic tumour (thymoma, cyst, fat, etc.) Teratoma Thyroid (2/3 rd of retrosternal extension) Terrible lymph nodes (TB, lymphoma)
Middle mediastinum	Aneurysm of aorta, Tumour of trachea or main bronchi Duplication-bronchogenic cyst. Oesophageal lesions-achalasia/hiatus hernia.
Posterior mediastinum	Mass arising from spine—tumour, abscess etc. Neurogenic tumours Lateral thoracic meningocele Extramedullary haemopoiesis (e.g. thalassaemia) Bochdalek hernia, hiatus hernia

- On a frontal CXR, the site of a mediastinal mass can usually be determined from the loss or preservation of the various mediastinal contours and lines (see earlier).

Hilar masses

- The hilar point has been described earlier, at this site lie the hilar lymph nodes.
- Nodal enlargement increases the density and size of the hilum (Fig 14.2, 14.3).

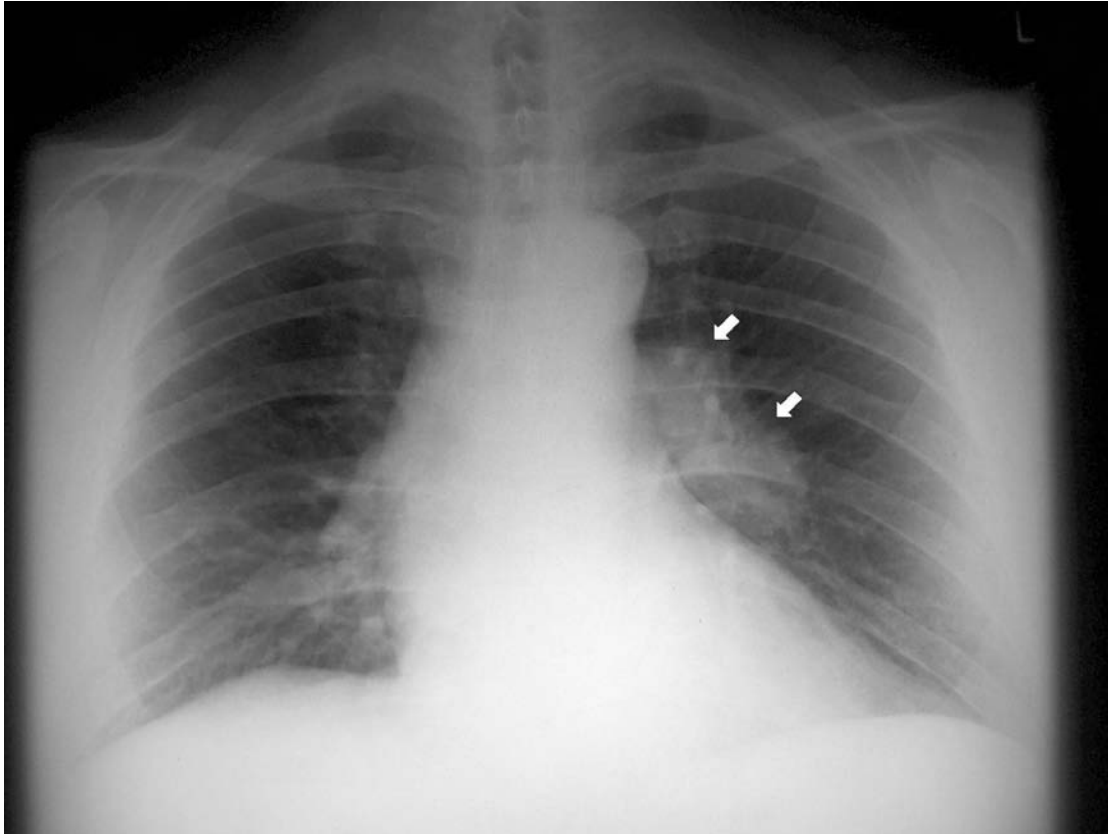


Figure 14.2
Frontal CXR of an adult male with left hilar adenopathy secondary to renal cell carcinoma. Note the increase in size and density of the left hilum (white arrows).

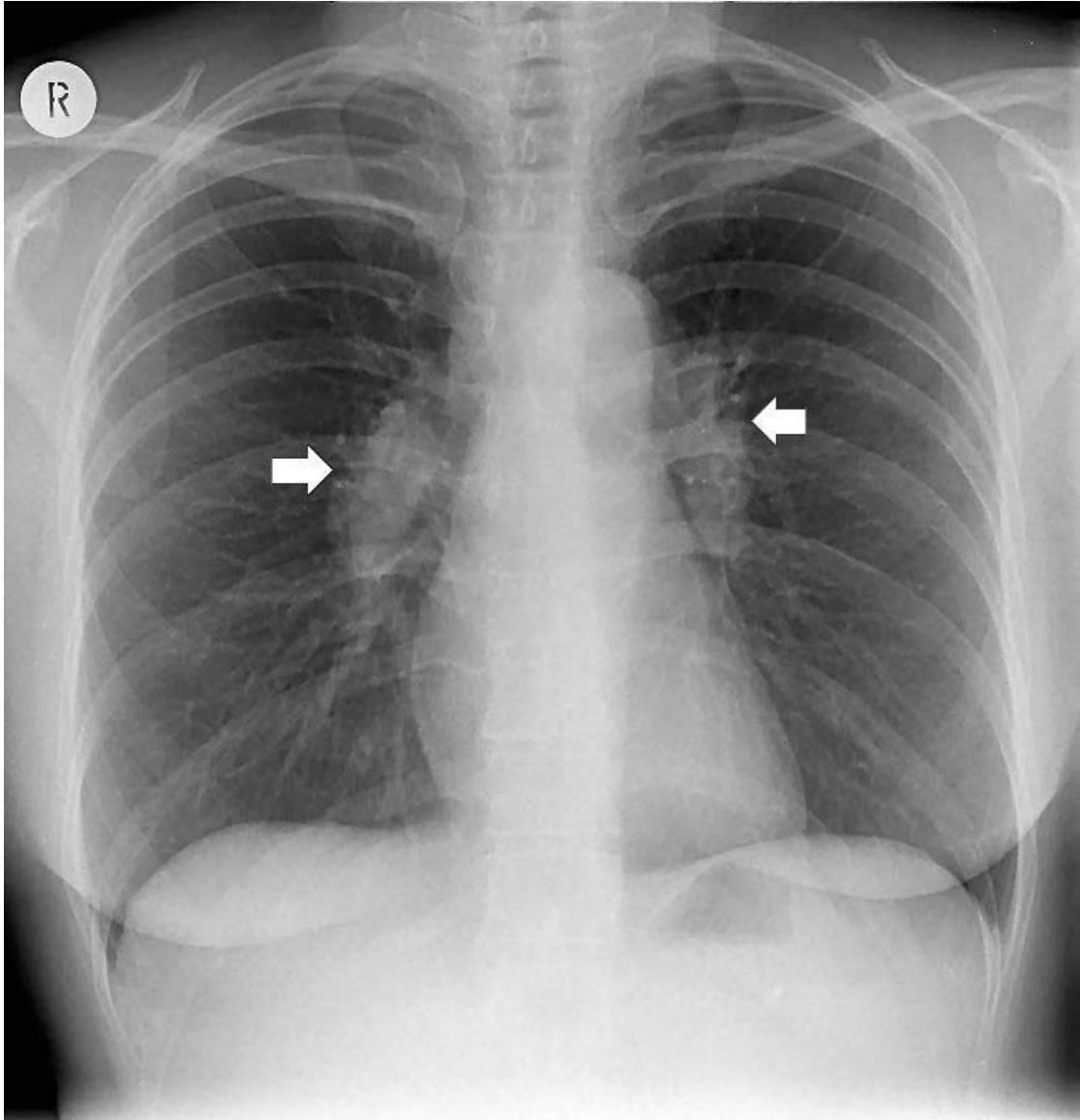


Figure 14.3
Frontal CXR of an adult female with sarcoidosis. Note the bilateral hilar adenopathy with filling in of the concavity normally associated with the hilar point (white arrows).

- Comparison between the hila may assist the observer in deciding whether the enlargement is genuine, but only if the abnormality is unilateral. One should beware of hilar discrepancy as a result of rotation of the patient (Fig 14.4).

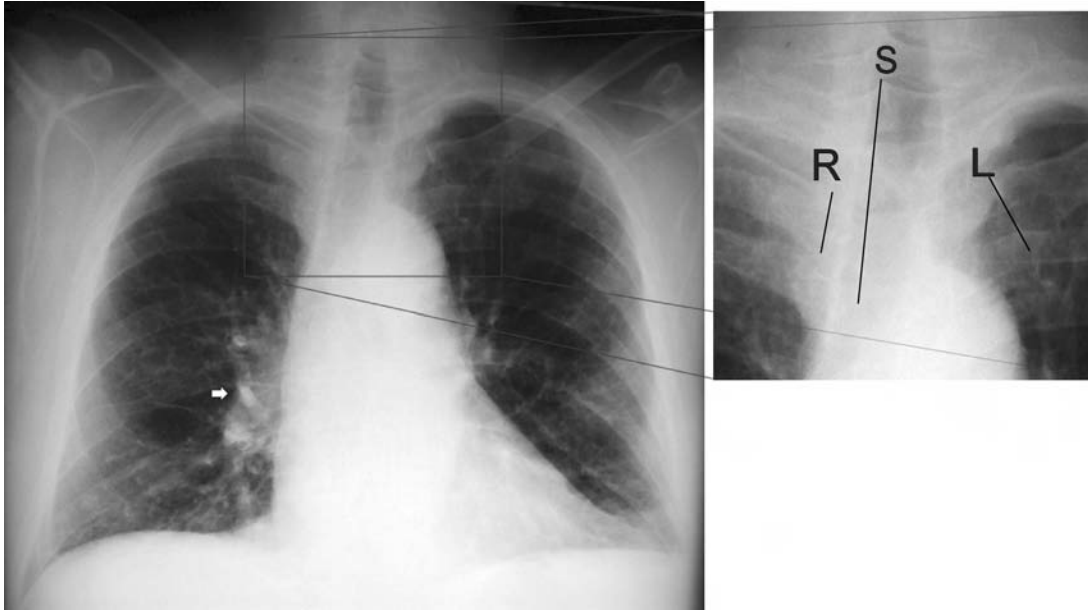


Figure 14.4

Frontal CXR of an adult. Note the apparent increase in the size and density of the right hilum (white arrow). The appearance is due to rotation of the patient to the left, which has partially obscured the left hilum making it look smaller than it is and revealing more of the right hilum, which when compared to the obscured left hilum appears enlarged. Note in the magnified image the relationship between the medial end of the right clavicle (R), the medial end of the left clavicle (L) and the spinous processes (S). The increased distance from S to L confirms left rotation.

Lymphadenopathy (Fig 14.5)

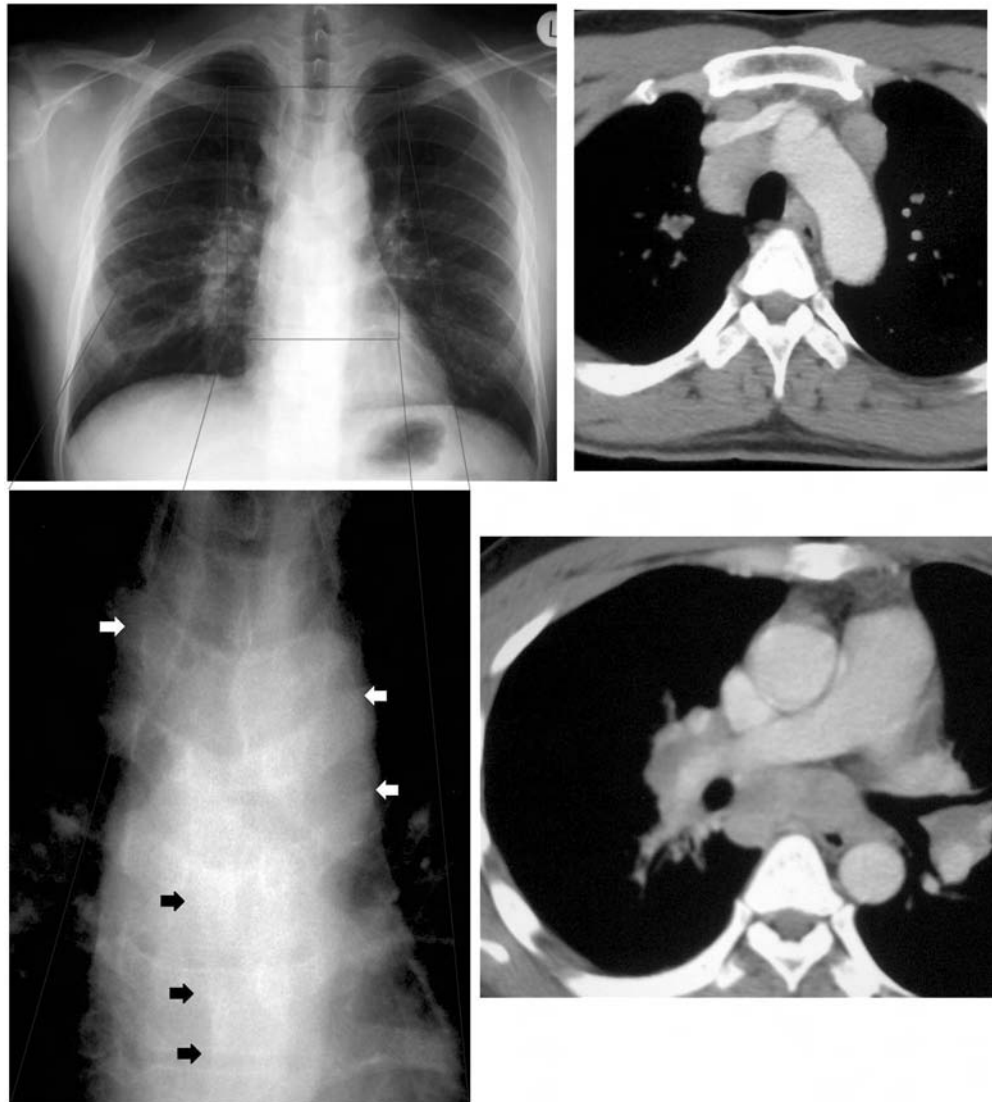


Figure 14.5

Frontal CXR of an adult male patient with lymphoma. Note the bilateral hilar adenopathy more evident on the right. The true extent of the mediastinal adenopathy is less readily appreciated. On the magnified view, the contours caused by the paratracheal and anterior mediastinal lymph nodes are marked (white arrows) and the appropriate CT section is included (top inset image). The sub-carinal lymphadenopathy has caused a subtle bulge of the azygo-oesophageal line (black arrows). The CT image at that level is the bottom inset image.

Mediastinal haemorrhage (Fig 14.6)

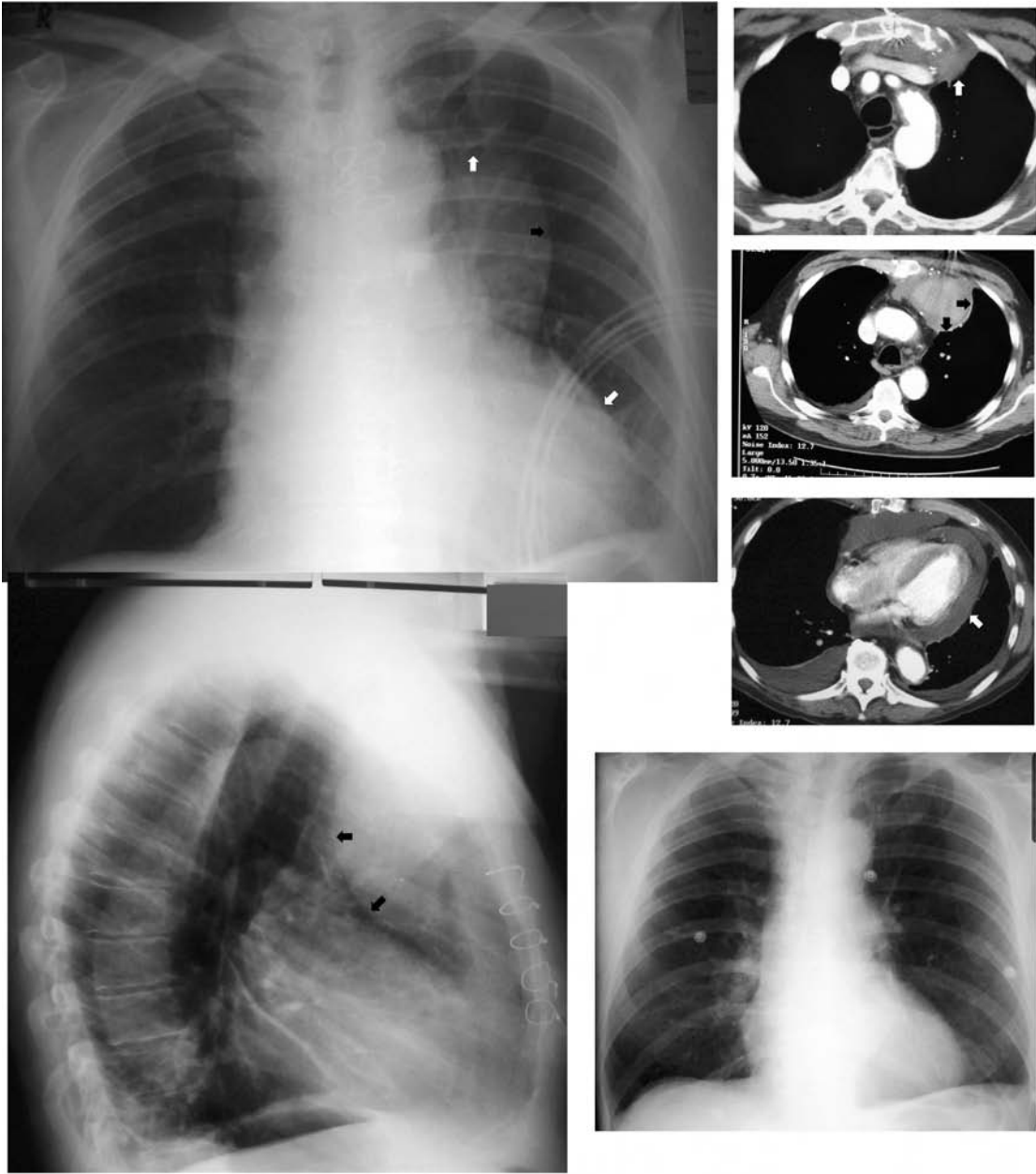


Figure 14.6 Top left: frontal CXR of an adult male following cardiac surgery; bottom left: lateral CXR taken at the same time; bottom right: pre-operative CXR; top right: three post-operative CT images. Note the clearly defined lateral and posterior margins of the mediastinal haematoma (black arrows, the position above the heart makes the posterior silhouette possible). The upper margin is ill-defined (vertical white arrows) as the haematoma merges with the normal tissues of the superior mediastinum at no point causing an abrupt change in tissue density as is found with the posterior and lateral margins. Note also the more globular shape to the heart post-operatively, compared to the pre-operative CXR, due to a pericardial effusion (diagonal white arrows).

Mediastinal abscess (Fig 14.7)

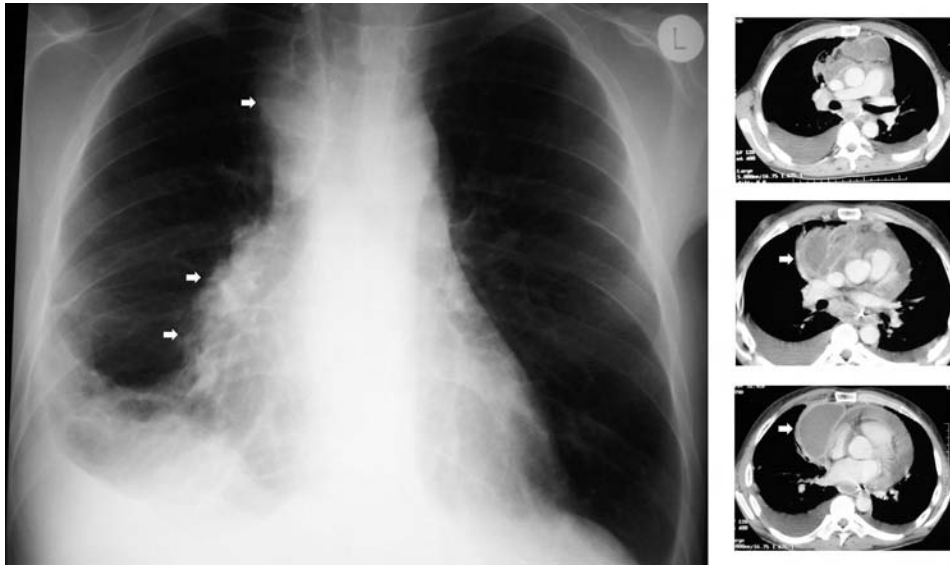


Figure 14.7

Frontal CXR and CT images of an adult male with extensive mediastinal abscesses, initially presenting with a parapharyngeal abscess, which was drained at surgery. Note the abnormal contour to the mediastinum (white arrows) as the only sign of mediastinal pathology. The CT images reveal, as for the case of lymphadenopathy earlier, how the CXR has underestimated the extent of the abscess. Note also the classic appearance of the pleural effusion.

Trauma

The chest X-ray in cases of trauma may reveal numerous significant complications of trauma. The mechanism of injury should always be considered when reading a chest X-ray in the context of trauma. The following signs may be identified:

- Fractures, potential cause of penetrating injuries and in some sites easily overlooked (e.g. the spine)
- Consolidation indicating lung contusion
- Pneumothorax, pneumomediastinum, pneumopericardium and surgical emphysema-indicating penetrating injury or airway rupture introducing air to these spaces either from the lung or from outside the chest
- Haemothorax.

The following cases demonstrate the various results of trauma:

Lung contusion/laceration/fractures (Fig 15.1)

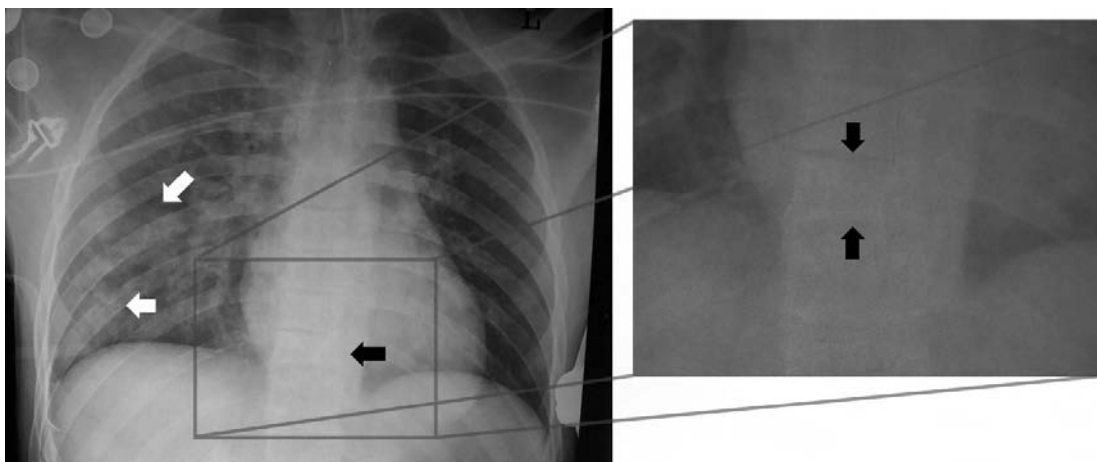


Figure 15.1

Frontal CXR of an adult male following a road traffic accident. Note the lung contusions (white arrows) but also the fracture of a lower thoracic vertebral body (black arrows).

Pneumothorax, surgical emphysema, pneumoperitoneum (Fig 15.2)

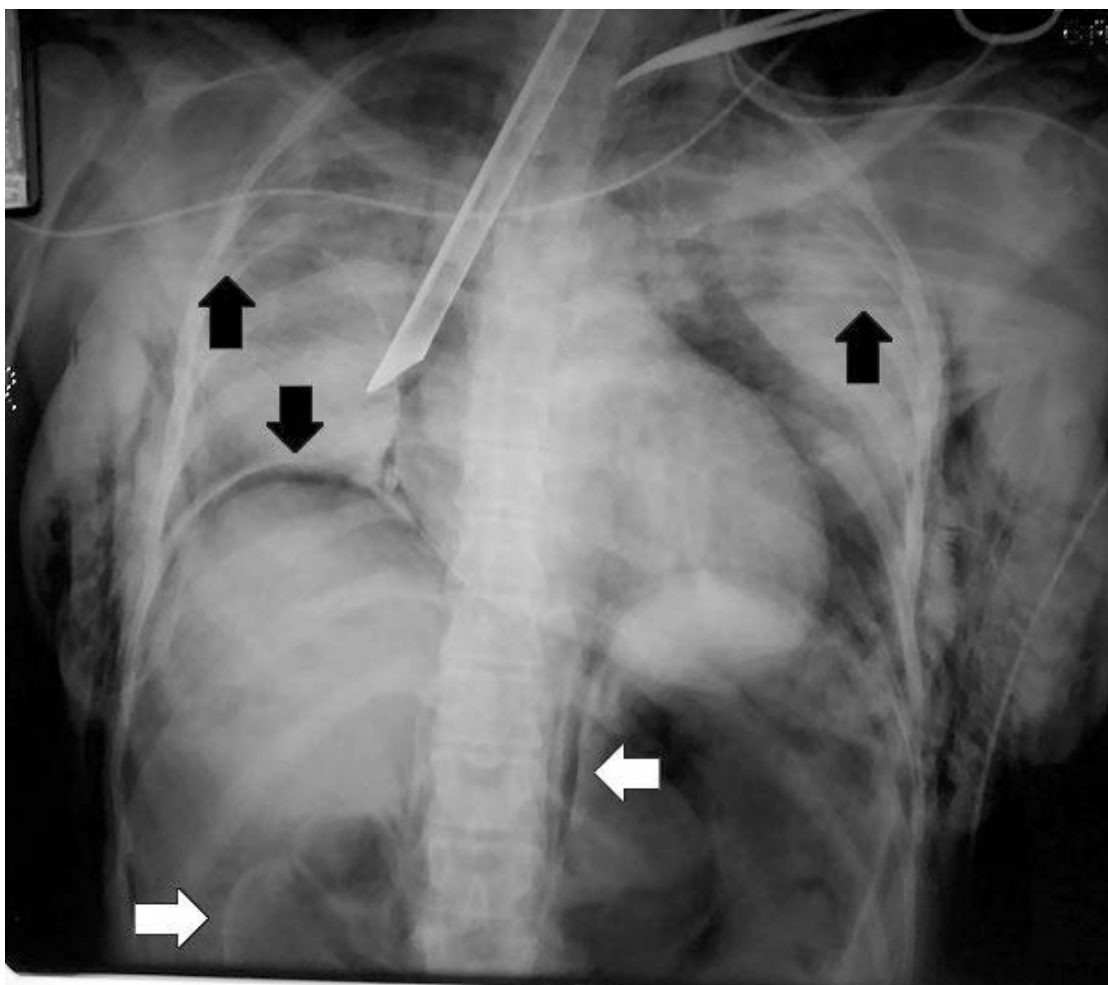


Figure 15.2

Supine CXR of an adult patient following a road traffic accident. Note the presence of air in the pectoral muscles (black arrows vertical up), pneumoperitoneum (horizontal white arrows), subdiaphragmatic air (black arrow vertical down). The left pneumothorax gives a sharp outline to the left heart border on this supine film.

Haemothorax (Fig 15.3, 15.4)

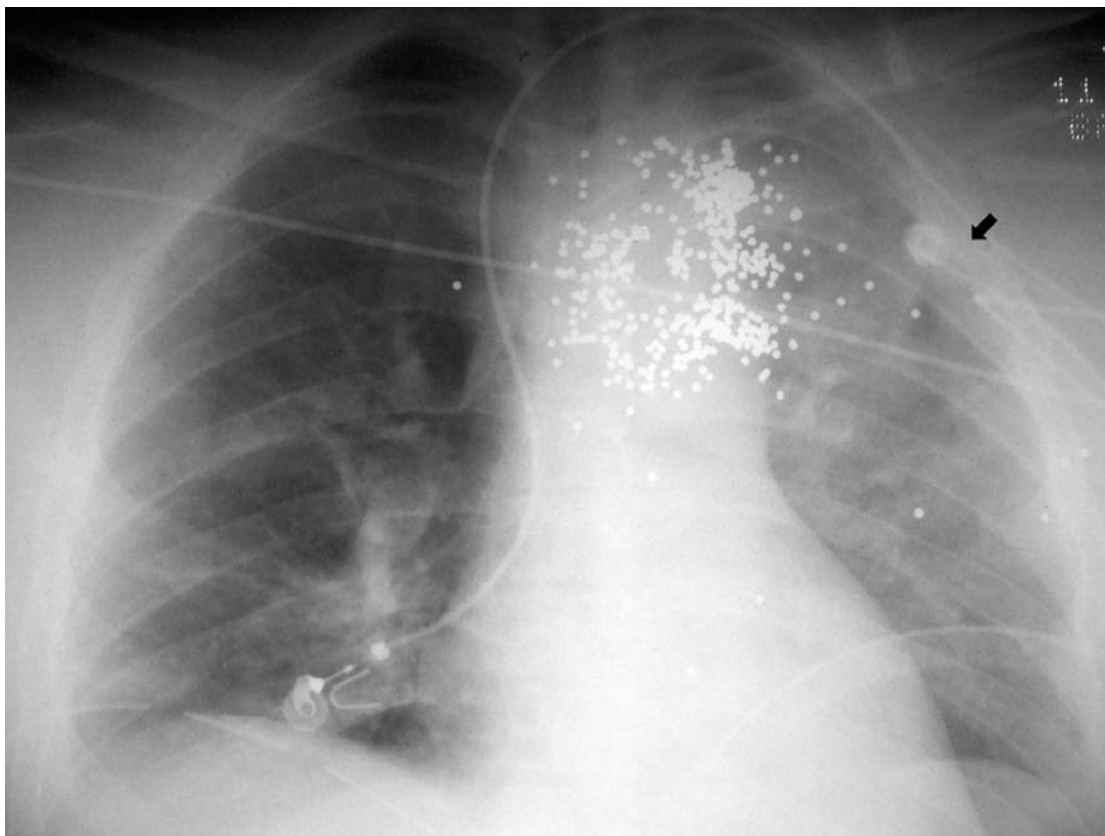


Figure 15.3

Supine CXR of an adult male who was shot in the chest with a shotgun. Note the radio-opaque shot. Of the three chest drains present, the marked drain (black arrow) was inserted to drain a haemothorax as a result of the trauma. Note the increased opacity in the left hemithorax due to haemorrhage into the upper and mid zone pleural space. The distribution indicates the non-simple nature of the fluid in this case blood.

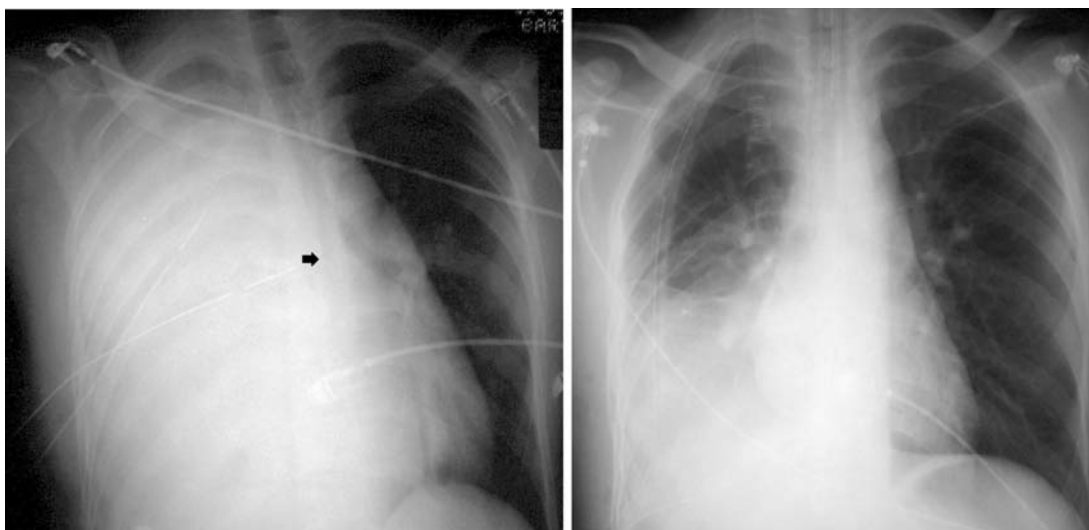


Figure 15.4

Frontal CXRs of an adult male victim of a stabbing. The complete opacification of the right hemithorax on the left CXR was due to a large haemothorax. Note the shift of the mediastinum to the left and deviation of the right main bronchus (black arrow). In the right hand image, the haemothorax has been partially drained and the mediastinal position has returned to normal.

Pneumopericardium and pneumomediastinum (Fig 15.5)

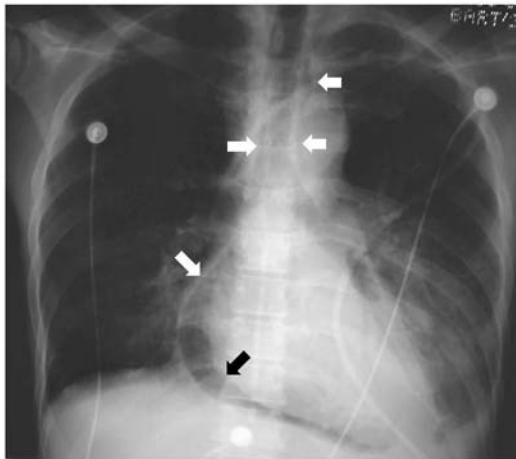


Figure 15.5

Frontal CXR of an adult male following a road traffic accident. Note the air tracking inferior to the heart (black arrow), the pericardium outlined by lung on one side and air on the other (white arrow diagonal down) and the mediastinal air (white arrows horizontal).

Bullet wounds (Fig 15.3, 15.6, 15.7)

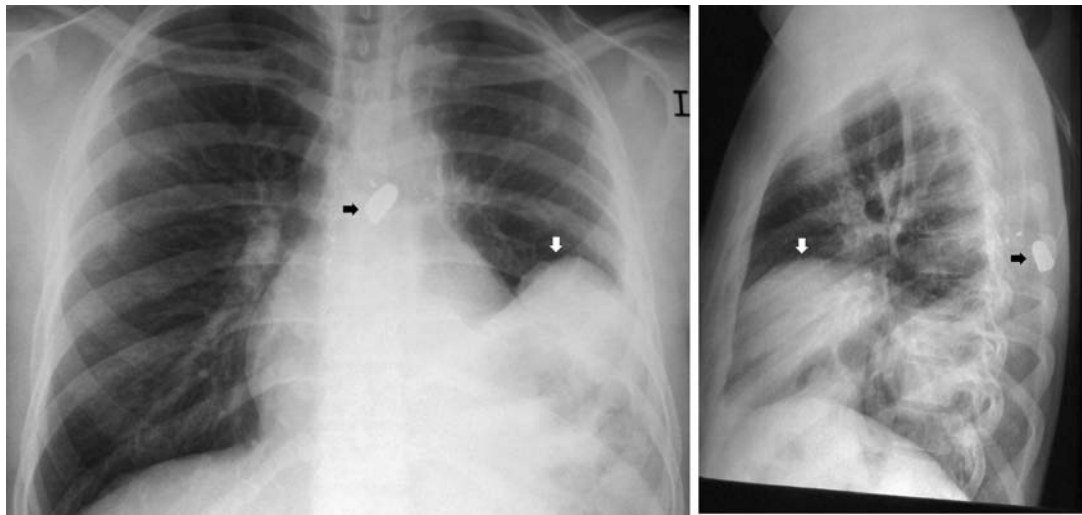


Figure 15.6

Frontal and lateral CXR of an adult male who was shot through the anterior left upper abdomen. The bullet traversed the diaphragm damaging the phrenic nerve causing diaphragmatic paralysis (white arrow), narrowly missed the heart and lodged in the posterior chest wall (black arrow).

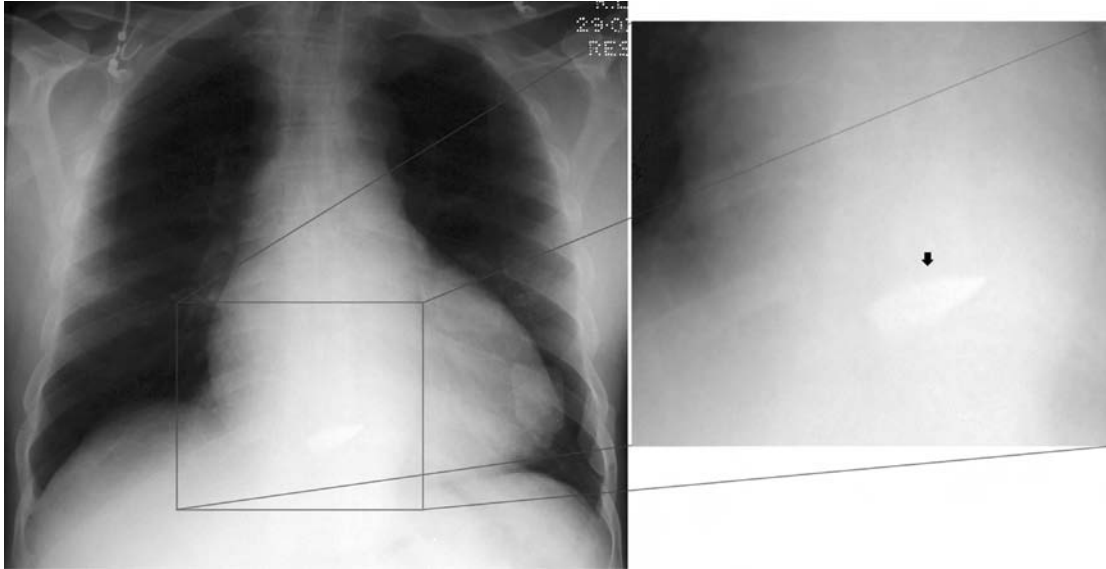


Figure 15.7

Frontal CXR of a patient shot in the abdomen 20 years earlier. The bullet has migrated via the IVC and right atrium to lodge in the right ventricle (black arrow).

The likelihood of any of these complications will depend upon the mechanism of injury, whether penetrating or blunt trauma, but all the possible complications should be considered in the context of a CXR for trauma.

Further reading

Hansell DM; Armstrong P; Lynch DA; McAdams HP, Imaging Diseases of the Chest 4th Edition (Mosby)

Wright FW, Radiology of the Chest and related conditions (Taylor and Francis)

Grainger RG; Allison DJ; Adam A; Dixon AK, Diagnostic Radiology, a textbook of medical imaging (Churchill Livingstone)

WHO in collaboration with the International Commission for Radiologic Education (ICRE) of the International Society of Radiology (ISR) and other members of the Global Steering Group for Education and Training in Diagnostic Imaging is creating a series of “Manuals of Diagnostic Imaging”. The full series of manuals will primarily cover the examination techniques and interpretation of conventional diagnostic X-ray procedures. These manuals will replace and update the *WHO Manual of Radiographic Interpretation for General Practitioners* and the *WHO Manual of Radiographic Technique*.

The present volume in the series, the manual *Radiographic Anatomy and Interpretation of the Chest and the Pulmonary System*, provides an exhaustive description of radiographic normal anatomy as well as the most common pathologic changes seen in the chest including trauma, tumours, congenital and developmental disorders.

Backed by high-quality reproduction of radiographs, this manual will prove essential reading to general practitioners, medical specialists, radiographers and radiologists in any medical settings, although focusing specifically on needs in small and mid-size hospitals.

ISBN 92 4 154677 8



9 789241 545556