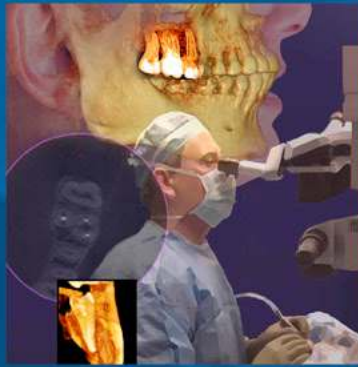

# ENDODONTICS

*Colleagues for  
Excellence*



Fall 2014

*The Standard of Practice in  
Contemporary Endodontics*



Published for the Dental Professional Community by the  
**American Association of Endodontists**  
and the **AAE Foundation**

[www.aae.org/colleagues](http://www.aae.org/colleagues)

As we approach the third decade of our advancing millennium, one of the realities of American dentistry is the expanding shift in the delivery of patient care. The private practice model is shrinking and giving way to corporate and group models promoting interdisciplinary treatment planning. This shift promises competence, reliability and cost control, all demanded by the corporate and industry structures that deliver the care (1).

As dental schools graduate novice practitioners trained and educated in a “generalist model” of care, many young practitioners will seek opportunities within these groups that provide patient services involving more and more complex endodontic procedures under an interdisciplinary umbrella. Thus, it is increasingly important for the generalist and the specialist to participate in concerted patient management with the overriding value of quality and patient safety at its core (2). A sustainable practice model that promotes high-quality, collaborative treatment has been a hallmark of American dentistry for decades, and newer practice models must maintain this high standard in order to provide value for patients and manage the complex dental problems that will regularly arise.

The practice of endodontics has concurrently experienced a shift in the delivery of services and the advancement of scientific discovery within the field. Emergent technologies in instrumentation, magnification and imaging aimed at treating and salvaging the natural dentition with consistent outcomes, are all hallmarks of contemporary endodontic practice.

### **Quality Care**

The movement towards evidence-based healthcare in medicine and dentistry has been gaining ground quickly over the past few decades. It has been fueled by clinicians, politicians, management and the public, all of whom are concerned about quality, consistency and costs. It has facilitated the development of guidelines for the delivery of care (3), which are defined in order to:

- Describe appropriate care based on the best available scientific evidence and consensus
- Reduce inappropriate variation in practice
- Provide a more rational basis for referral to specialists
- Provide a focus for continuing education
- Promote efficient use of resources
- Act as a focus for quality control

### **Standard of Practice in Contemporary Endodontics**

When we speak about standards in contemporary endodontic practice, there is often a misunderstanding of the terms used to describe these standards. In order to clarify these terms, they are listed here.

**Standard of Practice:** This is defined as the acceptable level of performance or an expectation for professional intervention, formulated by professional organizations based upon current scientific knowledge and clinical expertise. When improved technology offers clearly superior results, it no longer becomes a doctor-patient choice issue, but rather a requisite requirement to fulfill the standard of practice. The use of microscopy for apical surgery with ultrasonic tips for retrofilling (4, 5, 6) exemplifies improved technology and the current standard of practice in endodontics. Likewise, apical retrograde restorations should be performed with biocompatible materials such as mineral trioxide aggregate (MTA) and not with amalgam (7).

**Standard of Care:** There is no medical definition for standard of care, although the term is firmly established in law. In tort law, the standard of care is defined as “the caution and prudence that a reasonable person under a duty of care, in similar circumstances, would exercise in providing care to a patient.” Peer review and the courts recognize only one standard of practice in endodontics; that standard is determined by the endodontist.

**Best Practice:** This is defined as the recognized level of care provided by competent practitioners specifically trained in that area of specialization. Endodontics is recognized by the American Dental Association as a dental specialty. The American Board of Endodontics is the recognized certification board of the specialty. The American Association of Endodontists has developed and provided the dental profession and the public with information and education on endodontic best practices. Best practice is a dynamic model that progressively changes and improves, and is continually redefined by scientific discovery,

patient outcomes and the organized specialty.

In understanding these definitions we quickly see that the courts determine the standards of care and that the profession determines the standards for practice. This newsletter will focus on the standards of practice and best practices in contemporary endodontics.

### **Case Assessment**

The AAE's *Endodontic Case Difficulty Assessment Form and Guidelines* (8) provide a roadmap for when a generalist should treat or refer to an endodontist. The case assessment document specifically states that “technology, instruments and materials are not a replacement for clinical skill and experience, but rather adjuncts that a practitioner can employ to reach a desired goal.” The *Case Difficulty Assessment Form* is intended to assist practitioners with endodontic treatment planning, but can also be used to help with referral decisions and record keeping. The assessment form identifies three categories of considerations that may affect treatment complexity: patient considerations, diagnostic and treatment considerations, and additional considerations. Within each category, levels of difficulty are assigned based upon potential risk factors. The levels of difficulty are sets of conditions that may not be controllable by the dentist. They range from minimal to high difficulty. The form, and supporting information, is available at [www.aae.org/caseassessment](http://www.aae.org/caseassessment).

General dentists who render endodontic care are competent to treat minimal difficulty. Experienced general dentists may treat the moderate-difficulty cases, but should always consider referral of high-difficulty patients to endodontic specialists. As with any procedure, it is extremely important that any dental practitioner recognize the limits of his or her skill and expertise in order to protect patients and provide quality care. Patient considerations that may complicate treatment include medical complications, difficulties with anesthesia, behavioral management issues, limited opening and treatment complications. Additional considerations would include previous endodontic treatment, a history of trauma and periodontal-endodontic conditions (8).

Since endodontists set the standard of practice for conventional endodontics, if the endodontist's standard cannot be met—such as the need for microscopy, regenerative procedures, 3-D imaging for complex anatomy or the need for apical surgery—the generalist should seriously consider referral of the patient to an endodontist (9). As clinicians, we can ensure the highest-quality treatment with our ability to treatment plan for the patient in such a way that we accurately assess the difficulty of the case and our personal skill levels and formal training, and then determine whether to treat or refer.

### **Treatment Records**

#### ***Endodontic Records and Clinician Responsibilities***

Good clinicians keep good records. Records of endodontic treatment serve as important documentation to guide the clinician's objective data through the correct diagnostic and treatment paths. Documentation is essential to attaining an accurate log of events and decision making.

The dental record must contain sufficient information to identify the patient, support the diagnosis, justify the treatment, and document the course and result of treatment. Records are designed to protect the patient's welfare, and also are fundamental means of communication among health care professionals. A thorough and complete record should contain:

- A thorough review of the patient's medical and dental history
- Chief complaint(s), including onset, duration, frequency, type and intensity of any pain
- Radiographs of diagnostic quality
- Pulpal and periodontal diagnostic tests performed
- Objective clinical examination findings
- Differential diagnoses and final diagnosis
- The treatment plan and prognosis
- Documentation of the course of treatment

These are essential components of a quality record that support the doctor-patient interaction. When other factors affect the prognosis of any tooth diagnosed for endodontic treatment, such as the tooth's strategic value, restorability or proximity

to vital structures, the clinician should consider further consultation with an endodontist or other specialists, including a prosthodontist, periodontist or radiologist with 3-D imaging (10), before initiating endodontic treatment.

### **Informed Consent**

After an endodontic diagnosis is made, the benefits, risks, treatment plan and alternatives to endodontic treatment should be presented to the patient or the patient's guardian. This includes any patient refusal of recommended treatment and the consequences of refused treatment. This will document acceptance or rejection of treatment recommendations. The patient or guardian, along with a witness (who can be a staff member), should sign and date the consent form (11).

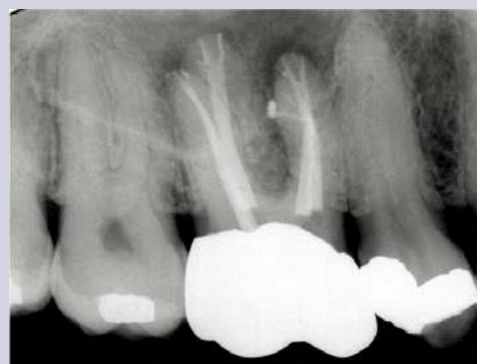An endodontic chart will help facilitate recording of information pertinent to the diagnosis, recommendations and treatment of the patient. Systematic acquisition and arrangement of data from the patient questionnaire, along with clinical and radiographic examinations and careful recording of treatment performed, expedites accurate diagnosis and maximizes clinician efficiency (11).

### **Dental Dam**

An example of a violation of the standard of practice includes any practicing dentists who do not use a dental dam for all root canal treatment. The 2010 *AAE Position Statement on Dental Dams* mandates that "tooth isolation using the dental dam is...integral and essential for any nonsurgical endodontic treatment." The dental dam also offers other benefits, such as aiding in visualization by providing a clean operating field and preventing ingestion or aspiration of dental materials, irrigants and instruments (12).

### **Anatomical Complexity**

The morphology of root canal systems is complex and contains many inaccessible areas such as apical canal ramifications, isthmus areas and canal wall irregularities (13) (Figure 1), where bacteria may be present in the form of biofilms (14). In some cases, root canals can be highly mineralized to an extent that they are very difficult to negotiate in a traditional manner. In addition, conventional radiographs only taken in a bucco-lingual direction reveal just part of the intricate root canal system. Overlying anatomical structures such as the zygomatic arch, maxillary sinuses, mylohyoid ridge or tori can make detection of additional canals or roots quite difficult. All of these potential circumstances as well as other case assessment issues require the clinician to ask themselves the question, "Do I possess the technical skills, training and equipment to deliver quality care in this case?"

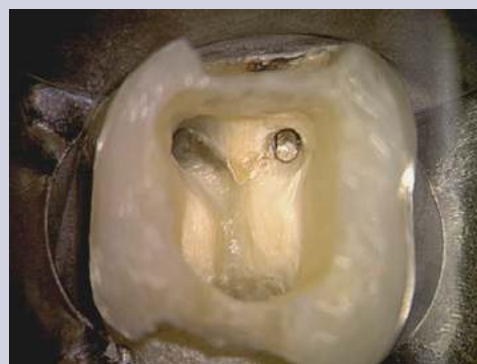

*Fig. 1.* A well-shaped, disinfected and obturated maxillary molar that reproduces the pulpal anatomy responsible for the existing pathosis. *Courtesy of Dr. Sherry Bloomfield.*

### **Magnification**

A 2007 survey of 1,091 endodontists indicated that 90 percent have access to and use the operating microscope in their practice, a dramatic increase from 52 percent in use in 1999 (15). The 2012 *AAE Position Statement on the Use of Microscopes and Other Magnification Techniques* is that the microscope is an integral and important part of the performance of modern endodontic techniques. The position statement describes procedures that benefit from the use of the microscope (15). They are:

- Locating canals obstructed by mineralization and/or reduced in size
- Removing materials such as solid obturation materials (silver points and carrier-based materials), posts or separated files
- Removing canal obstructions
- Assisting in access preparation to avoid unnecessary destruction of structural dentin (Figure 2)
- Repairing perforations



*Fig. 2.* Microscopic magnification at 16X of a lower molar retreatment. The ability to find and locate canals as well as a pre-existing silver point, while preserving maximum structural integrity, is a major advantage of enhanced lighting and magnification. *Courtesy of Dr. Clifford Ruddle.*

- Locating cracks and fractures that are not clinically visible or palpable with an endodontic explorer
- Facilitating all aspects of endodontic surgery, particularly in root-end resection and placement of retrofilling materials

Use of the microscope also enables enhanced photographic documentation and improved ergonomics for the clinician.

The modern approach to periradicular surgery is through magnification, illumination and microsurgery. It is documented that there is greatly improved prognosis when these techniques are employed (16). Use of magnifying loupes or similar devices that are adequate for coronal restorative procedures may prove inadequate for apical surgery or even conventional coronal endodontics when compared with microscopes. Microscopy provides a more detailed examination of the root apex and anatomic features such as isthmuses, unfound and accessory canals, fractures and crazing (Figure 3).

## 2-D and 3-D Radiographic Imaging

Preoperative radiographs are an indispensable part of diagnostic procedures in root canal treatment. A simple bitewing radiograph will always give the most accurate two-dimensional projection of the pulp chamber and its depth. However, recognition and diagnosis of periapical disease on conventional radiographs can be a challenge. Well-angulated periapical films should be taken with the cone directed straight-on, mesio-oblique and disto-oblique. This technique oftentimes reveals and clarifies the three-dimensional morphology of the tooth and identifies anatomic complexities. Digital radiography and other imaging technologies afford an enhanced variety of software features significantly augmenting radiographic diagnostics in identifying anatomical complexities. The clarity, color, contrast and brightness of a digital image can be easily modified affording a further ability to interpret hidden, mineralized or untreated canals.

When a radiographic examination is performed or required, the practitioner assumes the responsibility to make accurate interpretations from good, discernable images of diagnostic quality. It is a common understanding that both large and small pathoses as well as anatomic entities are routinely missed in 2-D radiographic surveys both by the operator and the limitations of the technology when encountering differences in anatomic variation (17). 3-D cone beam-computed tomography (CBCT) of teeth can image periapical lesions and other anatomical structures in the axial (transverse), coronal (anterior-posterior) and sagittal (left-right) sections. The scanning devices responsible for these “limited field” 3-D images have greatly advanced our understanding of the anatomic complexities in any given case, elucidating presurgical intricacies and unseen pathoses and canal complications (Figure 4).

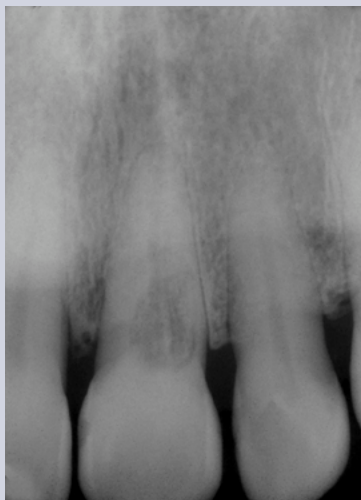


Fig. 5A. 2-D image of external resorption offering limited information for the clinician to understand the extent of the invasive process.

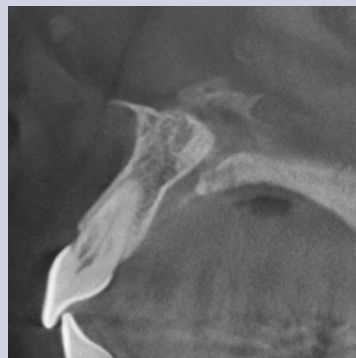

Fig. 5B. 3-D image in the sagittal view confirms the extensive and non-restorable invasive damage.

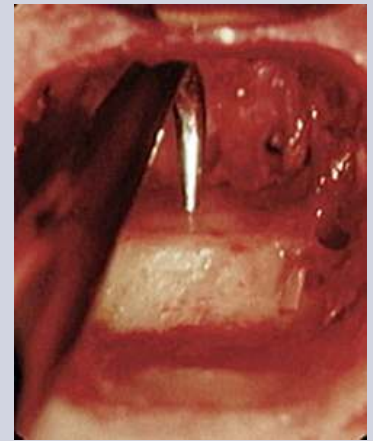

Fig. 3. Microscopic magnification at 20X of a retrograde surgical preparation with an ultrasonic instrument. Courtesy of Dr. Clifford Ruddle.

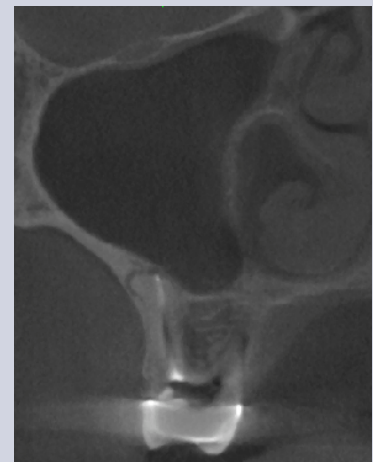

Fig. 4. CBCT coronal slice through the palatal root of a symptomatic molar demonstrating ledge and transportation of the original canal position, which could not be seen in any prior 2-D image.

When their utilization is indicated, the field of view can be limited to several teeth and the resulting CBCT scans can produce images with excellent contrast and clarity as well as relatively low radiation exposure to the patient (10, 18).

In instances of complex diagnosis such as internal or external resorption (Figure 5), a 3-D image defines very accurately the type and extent of disease. This information is critical to form a predictable treatment plan and associated prognosis. Assessment of periradicular lesions in multirouted teeth and differentiating these lesions from nonodontogenic pathoses is greatly facilitated by the use of focused

field CBCT. 3-D imaging also gives crucial information regarding the size and proximity of a lesion to vital structures. In addition to spatial relationships of root apices to anatomical structures, 3-D imaging can reveal accessory canals, the location of root canals and canal obstructions. The healing and repair of pathoses after nonsurgical and surgical endodontics can be observed in a far more predictable manner with 3-D technology (17).

### **Instrumentation**

Root canals are often depicted as smooth, hollow tubes that are more or less tapered in shape. These misleading images do not reflect the intricate anatomical structure and complexity of root canal systems. They are regularly asymmetrical or oval in cross section; they branch, dilacerate and divide, and the canal walls show concavities and convexities (13). Complex root canal anatomy should be considered one of the most significant challenges in debriding the canal system and creating root canal shapes that will support good obturation outcomes and leave sufficient remaining strength in the root (Figure 6).

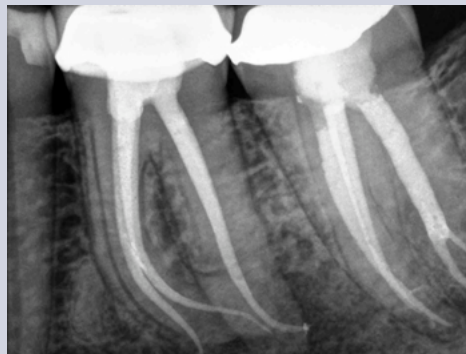Ultrasonic systems, in conjunction with magnification, eliminate the bulky head of the conventional handpiece, which frequently obstructs vision during difficult access procedures. The working ends of specific ultrasonic instruments are 5-10 times smaller than the smallest manufactured round burs, and their abrasive coatings allow them to precisely excavate dentin when exploring for mineralized canals or removing mineralized obstructions (19). On the contrary, a rotating bur in a dental handpiece is oftentimes difficult to see, because even a small handpiece head may block the line of sight.

After biomechanical instrumentation, the completed root canal shapes need to withstand the internal compressive forces of obturation, provide sufficient resistance form to contain softened and compressible filling materials, and retain enough strength for mastication and parafunction.

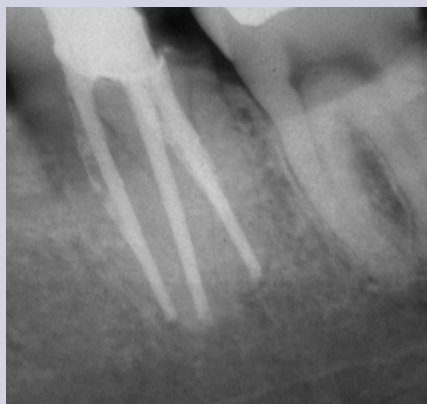Transportation, ledging, apical perforation and loss of the original canal position are all well-recognized shaping errors that often proceed to loss of working length and damage to the apical terminus followed by a weakening of the root structure at its most fragile levels (20).

There is now a large body of conclusive research quantifying the use of rotary and hand nickel-titanium instruments. They report that the use of this super-elastic metal alloy offers less straightening and better-centered preparations, compared to traditional stainless steel instruments, in preparing the wide range of anatomical variability seen in teeth (21) (Figure 7).

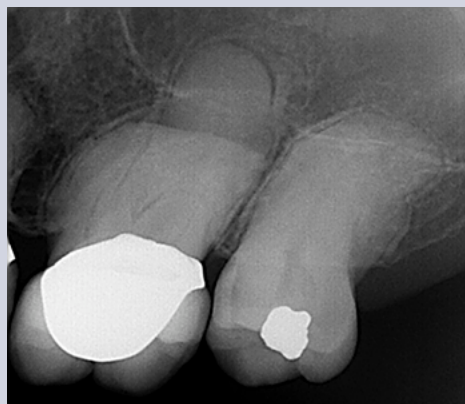
These studies have focused on the geometry of shape produced by these instruments alone, or in combination with stainless steel, including taper, flow and maintenance of original canal position. Collectively, these studies suggest that nickel-titanium technology in combination with the conservative use of stainless steel instruments provides shapes that are better centered, maintaining the original canal positions with greater conservation of dentin and offering safer radicular preparations (21).



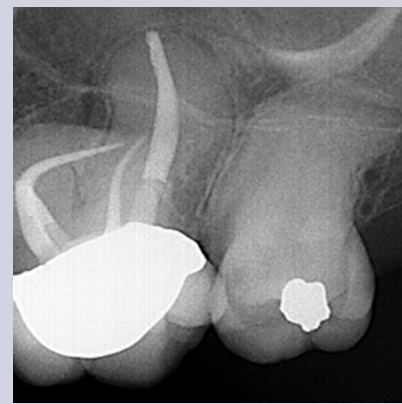
*Fig. 6.* Extremely long and narrow roots with tortuous canal systems make these molars high-difficulty challenges. *Courtesy of Dr. Jason West.*



*Fig. 7A.* Canals straightened and transported from their original positions reduce prognosis and often leave the patient symptomatic.



*Fig. 7B.* A preoperative image depicting vague root morphology and poorly visualized canals presents high difficulty.



*Fig. 7C.* Expert therapy reveals complex and challenging anatomy. *Courtesy of Dr. Wyatt Simons.*

Additionally, the use of electronic measuring devices, such as an electronic apex locator, is standard technology for accuracy when shaping and cleaning deep within the root canal system. Combined with diagnostic quality radiographs, an apex locator helps provide accurate length readings and corroboration with radiographs. Both are indispensable to rendering safe and accurate preparations.

## **Disinfection**

In order to address the microbiologic etiology of endodontic disease, *i.e.*, periapical inflammation, disinfection is and will always remain a key element of the overall treatment strategy. Current cleaning and shaping methods appear to be unlikely to predictably remove all bioburden from the root canal system. Two of the most common reasons for persistent infection are resistant organism populations protected in a biofilm, and canal space complexities that harbor infected necrotic tissues even after thorough mechanical instrumentation. This speaks to the fact that it is difficult to reach the most complex irregularities within the root canal space, and why thorough and copious irrigation with effective antimicrobials is such an important component of therapy. The use of antimicrobial irrigants during root canal treatment—whether they are delivered by passive irrigation, positive pressure irrigation via a side-vented needle, sonic or ultrasonic agitation, or negative pressure evacuation—meet the prevailing standards of practice for endodontic irrigation (22).

The key to adequate disinfection is the volume of solution that is used throughout the shaping process. Canal cleanliness is directly related to our ability to maintain a constant volume of fresh solution in the canals as the shaping takes place and the debris is evacuated. Sonic or ultrasonic activation of the irrigant further enhances the ability to remove the bioburden of the infected canal.

## **Obturation**

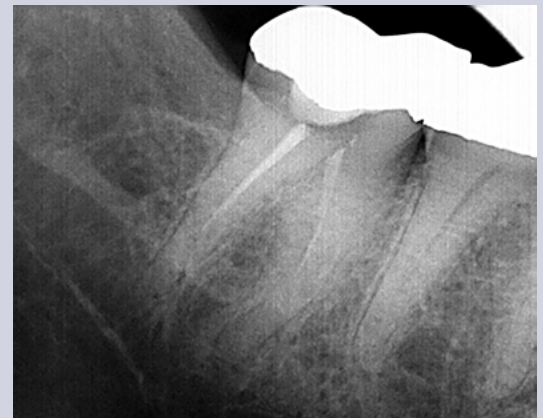### **Gutta-Percha**

The most common endodontic core material worldwide is gutta-percha. It has a history of usage in dentistry of well over a century, and is chemically considered a polyisoprene (a crystalline polymer). In its clinical formulations, gutta-percha comprises approximately 20 percent of total volume, with the remainder mostly zinc oxide and proprietary additives. Gutta-percha has a low degree of toxicity, compared to other components used in endodontic obturation, and has withstood the test of time in clinical usage. Obturation of root canal systems with this “medical-grade rubber” is possible with a host of potential applications. From lateral condensation with spreaders, to warm vertical technologies using heat generating devices; from custom single-cone techniques that fit a rotary file preparation, to gutta-percha carriers heated in an oven; all meet the requisite standards of practice when handled correctly and utilized appropriately (23) (Figure 8).

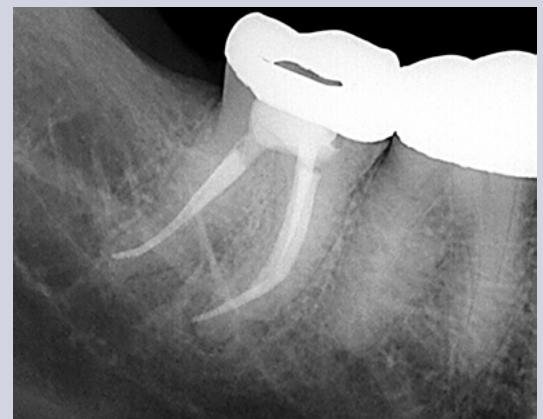
### **Silver Points**

Based on scholarly evidence for more than four decades, use of silver points in lieu of gutta-percha or other conventional endodontic filling materials is not the current standard of practice (24). This is because silver points corrode in time, and a well-fitting apical seal is difficult to achieve during initial placement and lost through corrosion.

The 2013 *AAE Position Statement on the Use of Silver Points* does not recommend the prophylactic retreatment of silver point obturation, unless there is clear evidence of endodontic pathosis or if the silver points complicate proper restoration of the tooth.



*Fig. 8A.* Lower molar with prior endodontic therapy that does not meet the standards of contemporary endodontic practice.



*Fig. 8B.* Endodontic retreatment provides a meaningful benefit to the patient. *Courtesy Dr. Robert Roda.*

### ***N2 (Sargenti Paste)***

Research has found that permanent neurologic injury can occur with overfilling using paraformaldehyde sealant (N2). N2 is cytotoxically unsafe and should be avoided (25). Accordingly, the use of such materials is below the standard of practice for endodontic treatment.

### **Coronal Seal**

Even the best and most meticulous endodontic treatment will become re-infected if the root canal system is contaminated by microorganisms coming from the oral cavity. Long-term seal of the root canal system is determined apically by the solid core and sealer, and coronally by the final restoration. Coronal leakage has been shown to be responsible for a constant source of microorganisms and nutrients that can initiate and maintain periradicular inflammation. Root-filled teeth should be permanently restored without undue delay to prevent leakage contamination of the previously obturated canal system, since varying canal shapes from round to oval preclude a perfect impenetrable seal (26). Leaking coronal restorations and their relation to root canal failure rates has been corroborated by investigations into the amount of time needed for bacteria in natural saliva to contaminate the entire length of sealed root canals exposed to the oral environment. Observed results showed that all root canals were recontaminated, on average, in less than 30 days (27). Bonded barriers (orifice plugs) covering the canal openings may be used to control any leakage after compaction until a permanent restoration is cemented. A leaking temporary or defective restoration will lead to contamination of an obturated root canal system over time, so the importance of keeping the temporary phase as short as possible, and restoring the root-filled tooth, cannot be overemphasized (28). The endodontic goal is to prevent bacterial contamination of the periradicular tissues by predictably providing adequately cleaned, shaped and filled root canal systems that are competently restored (29).

### **Mishaps**

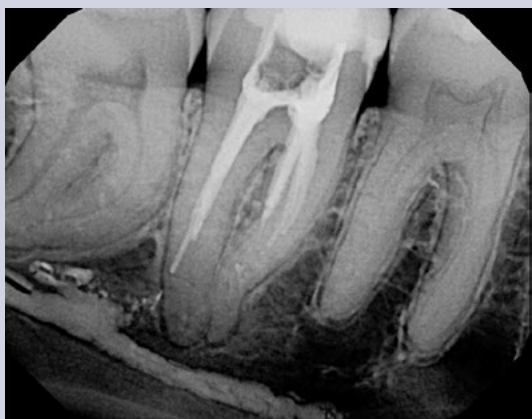#### ***Separated Instruments***

Risk reduction for separated files can be accomplished if all hand stainless steel and rotary nickel-titanium (NiTi) shaping files are discarded after single-use. Separation incidents increase sharply when hand or rotary shaping files are reused. Chair and staff time efficiency, along with improved patient safety, dictates single-visit use of files.

Today, separated instruments can quite often be removed due to technological advancements in vision, ultrasonic instrumentation, and microtube delivery methods (30). Specifically, the increasing integration of the dental operating microscope into clinical practice allows clinicians to visualize the coronal portion of most fractured instruments. If visualized, a strategy for removal is often possible.

#### ***Perforation***

If perforation occurs, early diagnosis and treatment are crucial. Belated intervention substantially increases the risk of chronic infection and failure. If a perforation is relatively small in size and promptly diagnosed at the time of the occurrence, immediate sealing of the perforation with intracanal sealants, such as MTA or bioceramic repair materials, have a high percentage success rate if placed properly with magnification and good illumination. However, delayed diagnosis and treatment (beyond 24 to 72 hours) will result in bacterial contamination of the area surrounding the perforation. Delayed repair can lead to periodontal or endodontic lesions and lateral periodontal breakdown making healing and a reasonable prognosis less likely.



**Fig. 9.** Poorly rendered therapy and a distal root perforation lead to a devastating overfill into the mandibular canal.

#### ***Overfill Into Neurovascular Anatomy***

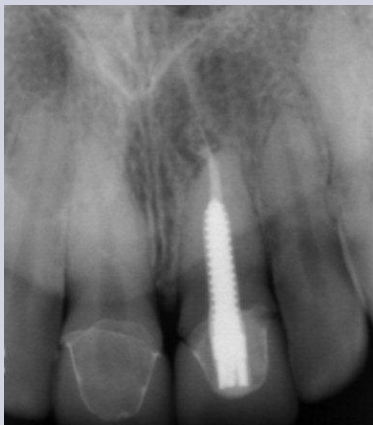
A clinician initiating root canal treatment on a mandibular posterior tooth should always be mindful of the vital neurovascular bundle containing the inferior alveolar nerve or mental nerve, which commonly approximates the ends of these roots. In the interest of patient safety, it is vitally important to procure a diagnostic-quality image that accurately demonstrates the



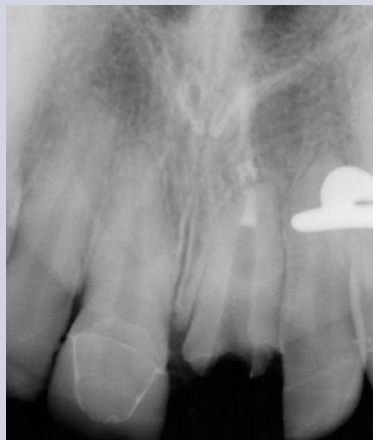
crestal borders of the inferior alveolar nerve canal (IANC). CBCT imaging aids in assessing the IANC location for planning implant placement, apical surgery or obturation in dangerous proximity of neurovascular anatomy. If endodontic treatment is performed without adequate diagnostic radiographs, the patient is placed at risk if there is anatomic variation, or if vital neural bundles lie in close proximity to these roots (31). Overfilling and/or over-instrumentation of the root ends can cause traumatic and/or chemical injury to the IAN bundle, resulting in potentially permanent alteration, or total loss of sensation from paresthesia (partial numbness), anesthesia and/or dysesthesia (burning pain). The eugenol or resin components of root canal sealers are known to be cytotoxic in their freshly mixed state. Consequently, endodontic overfill of the root apex into the IANC is capable of producing not only mechanical and compression damage, but also chemical injury (32) (Figure 9). Accordingly, if the patient demonstrates neuropathic symptoms in the first 24 hours, or in days subsequent to sealer entering the IANC, an expedient microsurgery referral to remove the injurious materials from the nerve space is warranted as a true neurologic emergency (33). Referral to a microsurgeon, whether that be an oral surgeon or endodontist, is time sensitive.

### **Ultrasonic Burns**

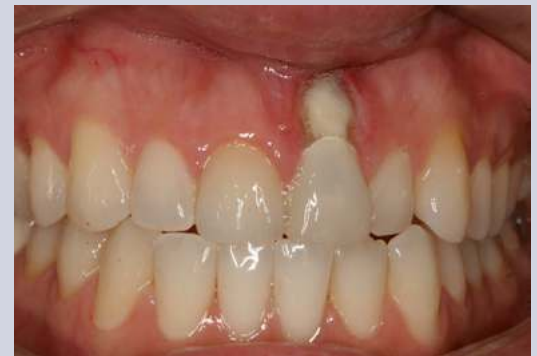Ultrasonic instrumentation has become an indispensable technology for removal of metallic obstructions within the root canal space, such as post removal for retreatment and separated instrument retrievals. Vibratory energy will loosen the cementation materials around posts, but the clinician must take precaution in such circumstances as large amounts of heat are generated deep within the root canal space. The clinician can avoid overheating a post and surrounding tissues by proceeding slowly with a concentrated water coolant, periodically stopping for cool down, and checking the post temperature periodically, to be reasonably certain overheating is not occurring (34). Figure 10 demonstrates a patient burn injury from an overheated tooth during the post removal attempt, causing tissue necrosis, bone loss and a poor prognosis for long-term retention.



*Fig. 10A.* Preoperative image of post to be removed for retreatment of root canal and esthetic restoration.



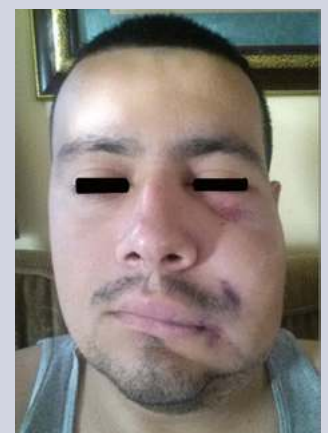*Fig. 10B.* Post removal.



*Fig. 10C.* Image of overheated tissue resulting in severe soft tissue and bone necrosis.

### **Bleach Injury**

Sodium hypochlorite still remains the endodontists' first choice of disinfection solutions. Prevention of sodium hypochlorite extrusion is accomplished by using syringes with safe, side-venting needles, and by constantly moving the syringe in small, vertical amplitudes to prevent hydrostatic build-up. Sodium hypochlorite can be extruded into the periapical tissues during root canal treatment if excessive pressure is placed on the irrigating syringe, resulting in an expression of sodium hypochlorite beyond the apex. Immediate, extreme pain and swelling is caused by the solution diffusing into the surrounding bone and soft tissues, causing tissue necrosis from the high alkalinity of the irrigant. Palliative treatment such as cold compresses, accompanied by reassurance that most symptoms will dissipate, is usually adequate. Occasionally, antibiotics are prescribed. Some patients have several days of increasing edema and ecchymosis, accompanied by tissue necrosis, paresthesia and secondary infection. Although most patients recover within one to two weeks, hospitalization, long-term paresthesia, chronic pain and surgical intervention have been reported (35,36) (Figure 11).



*Fig. 11.* Sodium hypochlorite accident requiring hospitalization associated with tooth #12. Four months later, the patient still demonstrated facial asymmetry, numbness in the upper left and vision impairment.

## **Conclusions, Future Directions**

A reasonable and prudent clinician must keep current with available advances that are generally accepted and embraced by the endodontist through research and evidence. Microsurgical endodontics is an example of improved endodontic technology. Use of magnifying loupes or similar devices may prove inadequate for apical surgery, accessing difficult canals while preserving tooth structure or fractured instrument retrieval, when compared with microscopes. It is incumbent upon the clinician to adopt proven technologies that improve the quality of endodontic care rendered and meet current accepted standards. CBCT imaging can be used to accurately locate the course of the mandibular nerve, the position of the mental foramen or the relationship of the maxillary sinus to adjacent root structures. This imaging can protect patients when anatomic proximity of these structures presents reasonable risk. As endodontics evolves in the future through science and technology, every clinician must understand how those advances will impact their own patient care. Clinicians deservedly earn patient trust and respect by providing safe and excellent quality care utilizing high standards of practice.

---

## **References**

1. Kao RT. Dentistry at the crossroads. *J Calif Dent Assoc* 2014;42:91-95.
2. Cooper MB. The perfect storm. *J Calif Dent Assoc* 2014;42:97-100.
3. Field MJ, Lohr KN (Eds). *Guidelines for clinical practice: from development to use*. Institute of Medicine, Washington, D.C: National Academy Press, 1992.
4. Kersten DD, Mines P, Sweet M. Use of the microscope in endodontics: results of a questionnaire. *J Endod* 2008;34:804-7.
5. Creasy JE, Mines P, Sweet M. Surgical trends among endodontists: the results of a web-based survey. *J Endod* 2009;35:30-4.
6. Tsesis I, Rosen E, Taschieri S, Telishevsky Strauss Y, Ceresoli V, Del Fabbro M. Outcomes of surgical endodontic treatment performed by a modern technique: an updated meta-analysis of the literature. *J Endod* 2013;39:332-9.
7. Parirokh M, Torabinejad M. Mineral Trioxide Aggregate: A comprehensive literature review—Part III: clinical applications, drawbacks, and mechanism of action. *J Endod* 2010;36:400-13
8. Law AS, Withrow JC. Endodontic Case Difficulty Assessment and Referral. *ENDODONTICS: Colleagues for Excellence Spring/Summer* 2005.
9. Goldman RP. Your duty to refer. *ADA Legal Adviser* 1998;2:6-7.
10. Cotton TP, Geisler TM, Holden DT, Schwartz SA, Schindler WG. Endodontic applications of cone-beam volumetric tomography. *J Endod* 2007;33:1121-32.
11. Zinman EJ. Endodontic records and legal responsibilities. In: Hargreaves KM, Cohen S. eds. *Pathways of the Pulp*. 10th ed. 2011; St. Louis; Mosby Elsevier;389-450.
12. Dental Dams. Position Statement of the American Association of Endodontists 2010.
13. Vertucci FJ. Root canal morphology and its relationship to endodontic procedures. *Endod Topics* 2005;10:3-29.
14. Svensäter G, Bergenholtz, G. Biofilms in endodontic infections. *Endod Topics* 2004;9:27-36.
15. Use of Microscopes and Other Magnification Techniques. Position Statement of the American Association of Endodontists 2012.

16. Tsesis I, Rosen E, Schwartz-Arad D. Retrospective evaluation of surgical endodontic treatment: traditional versus modern technique. *J Endod* 2006;32:412-6.
17. De Paula-Silva FWG, Wu M-K, Leonardo MR, Bezerra da Silva LA, Wesselink, PR. Accuracy of periapical radiography and cone beam computed-tomography scans in diagnosing apical periodontitis using histopathological findings as a gold standard. *J Endod* 2009;35:1009-12.
18. Peters CI, Peters OA. Cone beam computed-tomography and other imaging techniques in the determination of periapical healing. *Endod Topics* 2013;29:57-75.
19. Park E. Ultrasonics in endodontics. *Endod Topics* 2013;29:125-59.
20. Bürklein S, Schäfer E. Critical evaluation of root canal transportation by instrumentation. *Endod Topics* 2013;29:110–24.
21. Hülsmann M, Peters OA, Dummer PMH. Mechanical preparation of root canals: shaping goals, techniques and means. *Endod Topics* 2005;10:30–76.
22. Basrani B, Haapasalo M. Update on endodontic irrigating solutions. *Endod Topics* 2012;27:74-102.
23. Whitworth, J. Methods of filling root canals: principles and practices. *Endod Topics* 2005;12:2-24.
24. Use of Silver Points. Position Statement of the American Association of Endodontists 2013.
25. Paraformaldehyde-containing endodontic filling materials and sealers. Position Statement of the American Association of Endodontists 2013.
26. Ray HA, Trope M. Periapical status of endodontically treated teeth in relation to the technical quality of the root filling and the coronal restoration. *Int Endod J.* 1995;28:12-8.
27. Torabinejad M, Ung B, Kettering JD. In vitro bacterial penetration of coronally unsealed endodontically treated teeth. *J Endod* 1990;16:566-9.
28. Gillen BM, Looney SW, Gu L-S, Loushine BA, Weller RN, Loushine RJ, Pashley DH, Tay FR. Impact of the quality of coronal restoration versus the quality of root canal fillings on success of root canal treatment: a systematic review and meta-analysis. *J Endod* 2011;37:895–902.
29. Salehrabi R, Rotstein I. Endodontic treatment outcomes in a large patient population in the USA: an epidemiological study. *J Endod* 2004;30:846-50.
30. Suter B, Lussi A, Sequeira P. Probability of removing fractured instruments from root canals. *Int Endod J.* 2005;38:112-23.
31. Gluskin AH. Mishaps and serious complications in endodontic obturation. *Endod Topics* 2005;12:52-70.
32. Gluskin AH. Anatomy of an overfill: a reflection on the process. *Endod Topics* 2009;16:64-81.
33. Pogrel MA. Damage to the inferior alveolar nerve as the result of root canal therapy. *J Am Dent Assoc* 2007;138:65-9.
34. Gluskin AH, Ruddle CJ, Zinman EJ. Thermal injury through intraradicular heat transfer using ultrasonic devices: precautions and practical preventive strategies. *J Am Dent Assoc* 2005;136:1286-93.
35. Witton R, Henthorn K, Ethunandan M, et al. Neurological complications following extrusion of sodium hypochlorite solution during root canal treatment. *Int Endod J.* 2005;38:843-8.
36. Matthews J, Merrill RL. Sodium hypochlorite-related injury with chronic pain sequelae. *J Am Dent Assoc* 2014;145:553-5.



**This issue of *Colleagues* is supported by a grant from the AAE Foundation.**

The AAE Foundation is committed to excellence in endodontic research, education and patient care. It is the only organization that supports every accredited endodontic program in the United States and Canada. More than \$1 million annually is invested to advance this mission. Every dollar impacts:

- A resident's training
- An educator's development
- An endodontic department's success
- The specialty's future
- A patient's quality of care

For more information about the Foundation's grants and research visit [www.aae.org/foundation](http://www.aae.org/foundation).

The AAE wishes to thank Dr. Alan H. Gluskin for authoring this issue of the newsletter, as well the following article reviewers: Drs. Jeffrey S. Albert, Peter J. Babick, Linda G. Levin, Robert S. Roda and Kenneth W. Tittle.

**Exclusive Online Bonus Materials: Standard of Practice**

This issue of the *Colleagues* newsletter is available online at [www.aae.org/colleagues](http://www.aae.org/colleagues) with the following *exclusive bonus materials*:

- AAE Endodontic Case Difficulty Assessment Form
- Full-Text Article: Gluskin AH. Anatomy of an overfill: a reflection on the process. *Endod Topics* 2009;16:64-81.
- Full-Text Article: Peters CI, Peters OA. Cone beam computed-tomography and other imaging techniques in the determination of periapical healing. *Endod Topics* 2013;29:57-75.
- Full-Text Article: Gutmann JL. Surgical endodontics: past, present, and future. *Endod Topics* 2014;30:29-43.

LIVE LEARNING CENTER *Endodontic education online, on demand.*

Earn online CE credit when you enjoy two articles from *Colleagues for Excellence!*  
[www.aae.org/LiveLearningCenter](http://www.aae.org/LiveLearningCenter)

*Information in this newsletter is designed to aid dentists. Practitioners must use their best professional judgment, taking into account the needs of each individual patient when making diagnosis/treatment plans. The AAE neither expressly nor implicitly warrants against any negative results associated with the application of this information. If you would like more information, consult your endodontic colleague or contact the AAE.*

*Did you enjoy this issue of *Colleagues*? Are there topics you would like to cover in the future? We want to hear from you! Send your comments and questions to the American Association of Endodontists at the address below, and visit the *Colleagues* online archive at [www.aae.org/colleagues](http://www.aae.org/colleagues) for back issues of the newsletter.*





©2014, American Association of Endodontists  
211 E. Chicago Ave., Suite 1100  
Chicago, IL 60611-2691


Phone: 800/872-3636 (U.S., Canada, Mexico) or 312/266-7255

Fax: 866/451-9020 (U.S., Canada, Mexico) or 312/266-9867

Email: [info@aae.org](mailto:info@aae.org) Website: [www.aae.org](http://www.aae.org)

 [www.facebook.com/endodontists](http://www.facebook.com/endodontists)

 [@savingyourteeth](https://twitter.com/savingyourteeth)

 [www.youtube.com/rootcanalspecialists](http://www.youtube.com/rootcanalspecialists)