



Anatomy & Physiology of The Eye

2017-2018

Done By:

Abdullah M. Khattab

Abdullah AlOmair

Resources:
Team 433,
Doctors Notes,
Vaughan & Asbury's General ophthalmology.

433 Team
Important
Doctor's Notes
Extra

[Editing File](#)

Embryology of The Eye.....	2
• Defects:.....	2
Development of The Eye After Birth.....	3
• Refractive power depends on two factors:.....	3
The Orbit.....	4
• Seven bones contribute the bony orbit and surrounded by nasal sinuses.	4
• The orbital wall, pear-like shaped, formed by:	4
• Structures Passing Through the Optic Openings:.....	4
Extraocular Muscles.....	1
• Anatomy	1
• Notes:.....	1
• Field of action:.....	1
The Chambers of The Eye:	3
The Globe.....	4
Coats of the Eye:.....	4
A. Fibrous coat “outer protective coat - protective layer - external”:	4
B. Vascular pigmented coat “middle vascular coat” / Uveal tract:.....	4
C. Inner layer:.....	4
composed of the optic nerve and the retina.....	4
Conjunctiva	5
Transparent membrane covering sclera	5
1- Palpebral Conjunctiva (orbital cavity septum):.....	5
2- Bulbar Conjunctiva: covers the anterior part of the sclera	5
3- Forniceal Conjunctiva.	5
Cornea.....	6
Iris and Pupil:	7
The Lens:.....	8
Retina and Vitreous:	9
THE LACRIMAL APPARATUS- adnexa:.....	5
The Intraocular Pressure:.....	6
Optics of the Eye:.....	6
VISION:	6

Embryology of The Eye

The eye is an outgrowth from the brain (neural ectoderm). Started as Optic vesicle connected to the forebrain by Optic stalk.

The eye is derived from:

- 1- Ectoderm
 - a. Neuroectoderm of the forebrain
 - b. Surface ectoderm of the head
- 2- Mesoderm
- 3- Neural crest cells

Endoderm does not contribute in the eye embryology.

Neuroectoderm	Neural retina & Retinal pigmented epithelium (risk of detachment) Iris epithelium Conjunctiva epithelium
Surface ectoderm	Lens and corneal epithelium
Mesoderm	Extraocular muscles Vascular coat of the eye
Neural ectoderm	Everything else

During embryogenesis the lens and vitreous are supplied by **hyaloid vessels** that **disappears** at late stages of embryogenesis.

• Defects:

- **Persistent hyperplastic primary vitreous (phpv)**: persistent hyaloid vessels.
- **Congenital coloboma**: inferior nasal defect
- **Retinal detachment**. Between the neural retina and rpe

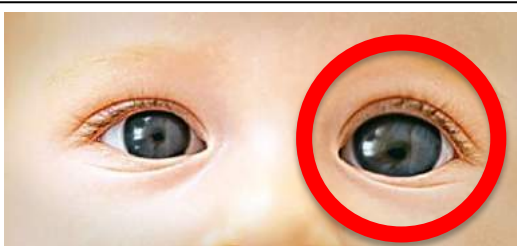Team 434 ladies:

patient who get affected by atopic dermatitis*¹ could have cataract . surface ectoderm derived structures such as cornea and lenses therefore, they're the only structures in eyes that can be implanted. surface ectoderm structures considered as the most painful structures in the eye because it causes epithelial defect.

¹ **Atopic dermatitis (AD)**, also known as **atopic eczema**, is a type of inflammation of the skin (dermatitis). It results in itchy, red, swollen, and cracked skin

Development of The Eye After Birth

- At birth, the eye is relatively large in relation to the rest of the body.
- The eye reaches full size by the age of **8 years**.
- Visual acuity developed until the age of **20 years**.
- The lens continues to enlarge **throughout the life**.
- The iris has a bluish color due to little or no pigment on the anterior surface.
- During early infant life, the cornea & sclera can be stretched by raised IOP → enlargement of the eye.
- Normal axial of the eye is 21-24mm (2.4cm)
 - Elevated intraocular pressure with onset in the first year of life it called congenital glaucoma.
 - Eye consist of globe (eyeball, extraocular muscles) and adnexa (lacrimal gland and sac).
- **Refractive power depends on two factors:**
 1. Surfaces: cornea and lens
 2. Axial length:
 - **Hyperopia:** image falls behind the retina due. Most common in children
 - **Myopia:** image falls in front of the retina.
 - **Emmetropia:** image falls on the retina. Risk of myopia with time.



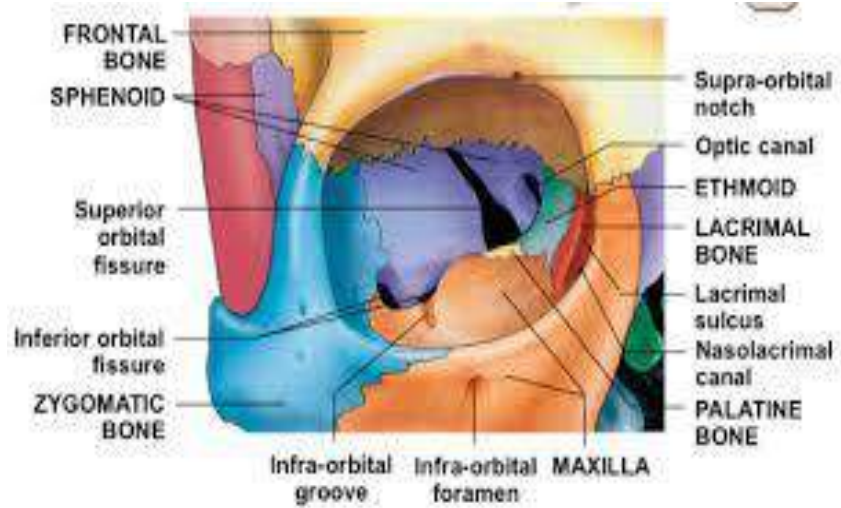
Parents came to the clinic complaining that their newborn has smaller right eyeballs. In fact, the left eye is enlarged due to increased ocular pressure.

Unilateral glaucoma in pediatric groups tend to clinic earlier than bilateral glaucoma.

The Orbit

• Seven bones contribute the bony orbit and surrounded by nasal sinuses.

1. Maxilla
2. Zygomatic
3. Frontal
4. Ethmoid
5. Lacrimal
6. Sphenoid
7. Palatine bone



• The orbital wall, pear-like shaped, formed by:

Floor	the orbital plate of the maxilla.
Lateral wall	1. zygomatic bone 2. greater wing of sphenoid
Medial wall	Dorsal to ventral: 1. frontal process of the maxilla, 2. lacrimal bone 3. orbital plate of ethmoid 4. body of sphenoid.

1. **Thinnest bone:** Lamina papyracea part of the ethmoid bone (medial wall).
2. **Weakest bone:** the floor (area of blowout fracture).
3. **Strongest bone:** zygomatic bone.

Any fracture of **orbital roof** tends to present with ptosis

Q. past Hx of sinusitis brought by Proptosis? that mean there is infection from the sinus to orbit through lamina papyracea.

• Structures Passing Through the Optic Openings:

Optic foramen (canal)	1. Optic nerve 2. Ophthalmic artery 3. Central retinal vein
Inferior orbital fissure	1. Infraorbital nerve (part of the maxillary nerve) 2. Inferior ophthalmic vein 3. Infraorbital artery & infraorbital vein 4. Zygomatic nerve, 5. Parasympathetic to lacrimal gland
Superior orbital fissure	Any structure that was not mentioned above including: III, IV and VI cranial nerves, lacrimal nerve, frontal nerve, nasociliary nerve, orbital branch of middle meningeal artery, recurrent branch of lacrimal artery, superior orbital vein, and superior ophthalmic vein.

Extraocular Muscles

● Anatomy

- **Six muscles:** Four recti & two oblique muscles.
- All are supplied by **III Oculomotor** nerve **except**
 - **Superior oblique** by **Trochlear (SO4)** -muscle of reading-
 - **Lateral rectus** by **Abducens (LR6)**

● The **recti** are attached **in front** of the equator, unlike the **obliques** attach **behind** the equator.

● Notes:

- 1- Superior oblique is the most superior muscle in the orbit.
- 2- Medial recti are strong muscles that keeps the eye in its normal position. During sleep, the eye tends to move laterally due to the relaxation of the medial recti. It's important that during preoperative assessment of a patient with strabismus. Check the angle of deviation before injecting anesthetic drugs; the eyes changes angles during sleep.
- 3- **Abducens nerve** is the **only** nerve passing through the **cavernous sinus**. A trauma at this structure will cause: **medial squint**

● Field of action:

A set of rules to help you understand the muscle action

Rule 1:

- Superior & inferior rectus or obliques have **1 primary action & 2 secondary** actions.
- Medial & lateral rectus have **only one action**.

Rule 2:

- All **recti muscles** are **adductors except lateral**
- All **oblique muscles** are **abductors**

Rule 3:

- **Superior** muscles: **intorsion action**
- **inferior** muscles: **extortion action**

Therefore: -

Muscles	Primary action	Secondary action
Superior rectus	Elevation	Adduction, Intorsion
Inferior rectus	Depress	Adduction, Extortion
Medial rectus	Adduct	-
Lateral rectus	Abduct	-
Superior oblique	Intorsion	Abduction, Depression
Inferior oblique	Extortion	Abduction, Elevation

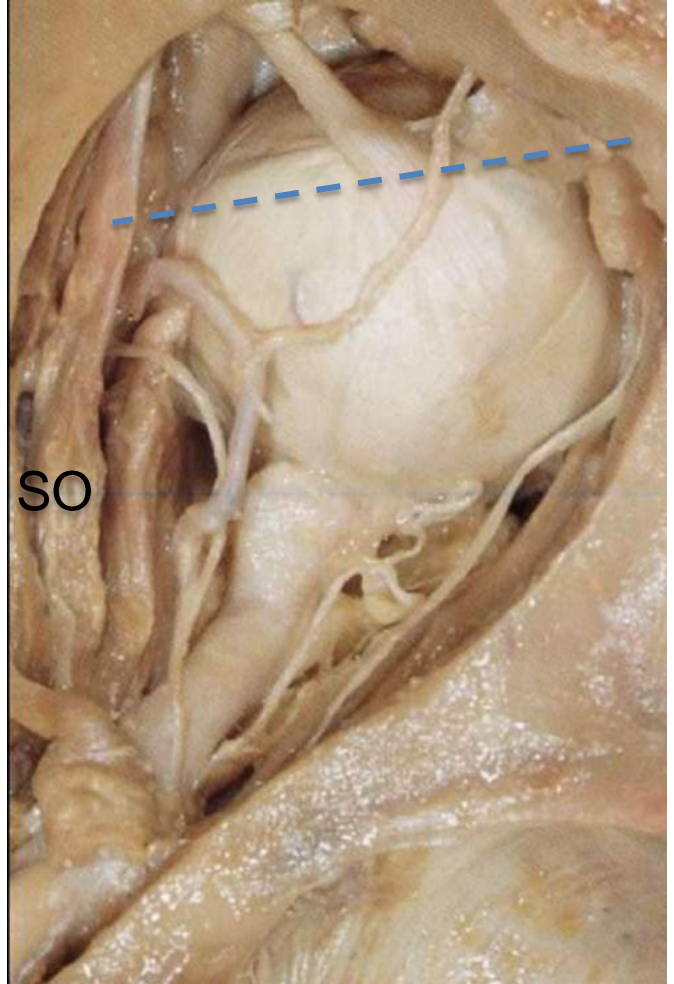
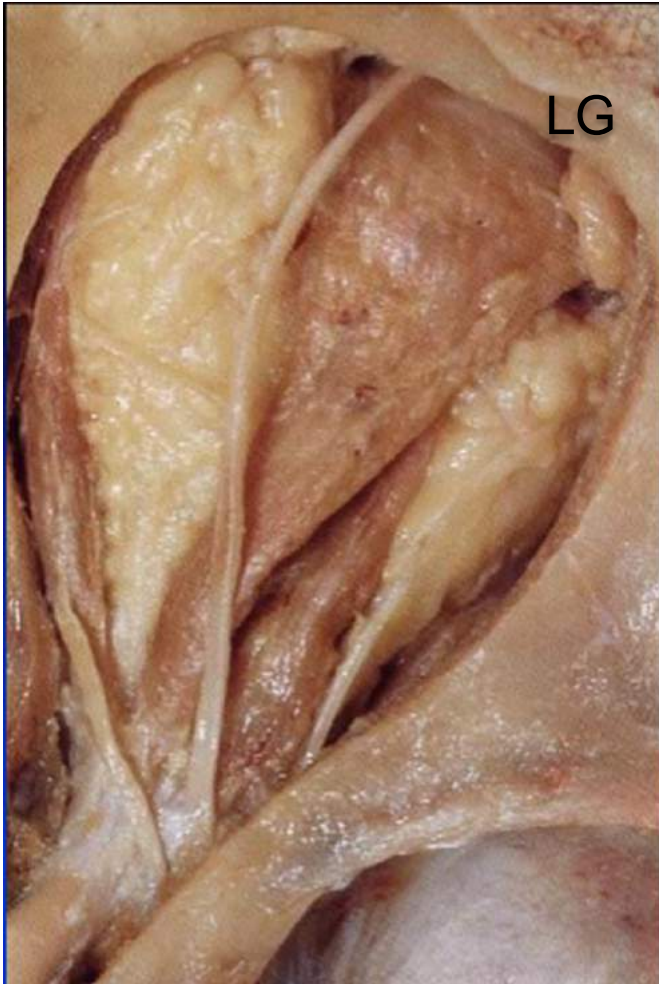To test superior oblique: downward on adduction because the *inferior rectus* will be restricted

To test inferior oblique: elevation on adduction because the *superior rectus* will be restricted

To test superior rectus: elevation on abduction because the *inferior oblique* will be restricted

To test inferior rectus: downward on abduction because the *superior oblique* will be restricted

For simplify: I can't use the superior oblique on abduction and use it for downward, I use inferior rectus muscle for eye downward because the axis restriction for superior oblique.



We are looking at the eye through the orbit roof.

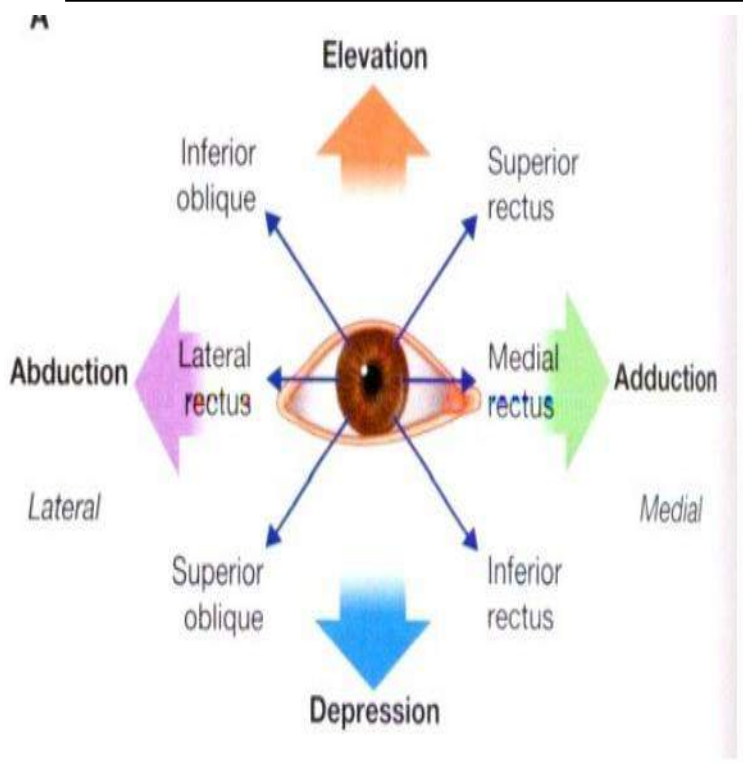
LPS: levator palpebrae superior. Function: raises eyelid.

SO: superior oblique. Notice in the right picture, the muscle is taking a turn and then attach to the eye.

SR: superior rectus: always straight.

ON: optic nerve

LG: lacriaml gland



Clinical Testing

Muscle tested

Movement

SR



Looks laterally and upwards

IR



Looks laterally and downwards

LR



Looks laterally

MR



Looks medially

IO



Looks medially and upwards

SO



Looks medially and downwards

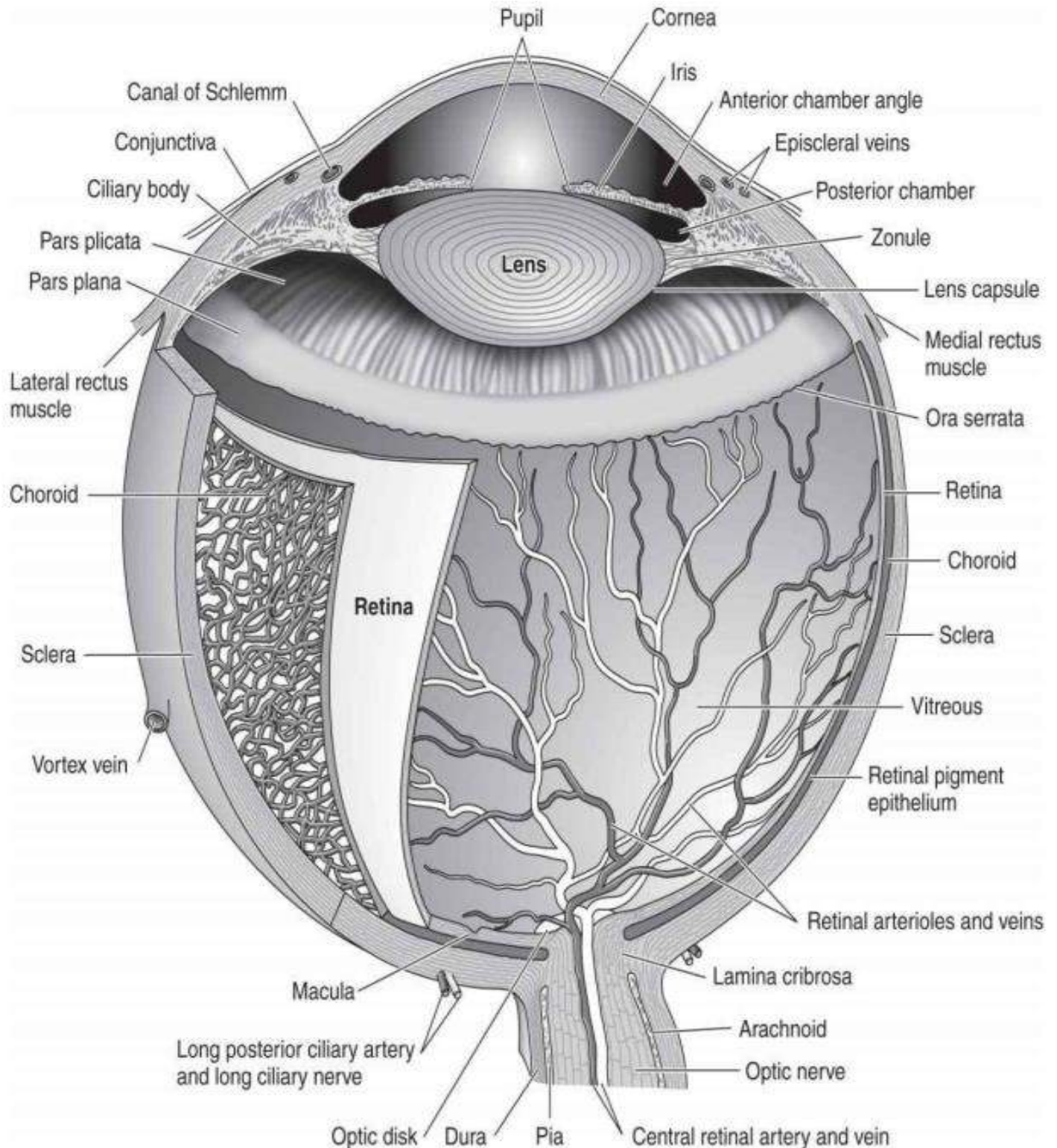
The Chambers of The Eye:

Consists of two chambers:

- The anterior chamber, in front of the iris
- The posterior chamber, immediately behind the iris.

These two chambers communicate through the pupil and are filled with clear aqueous humor. **The aqueous humor is secreted by the non-pigmented epithelium of the ciliary body and drained through the Schlemm's canal.**

- The vitreous cavity: filled by gel-like structure.



The Globe

Coats of the Eye:

A. Fibrous coat “outer protective coat - protective layer - external”:

- Made up of the **sclera (posterior opaque part)** and **the cornea (anterior transparent part)**. Both are formed of collagenous fibers with different arrangement.
- **Lamina cribrosa** (check the image above) is the area of the sclera that is **pierced by the nerve fibers of the optic nerve**.
- Cornea is in contact posteriorly with the aqueous humor.
- “the cornea is stronger than the sclera due to her special collagenous arrangement”

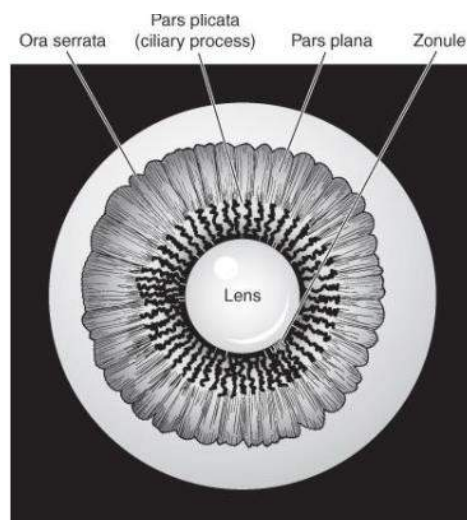
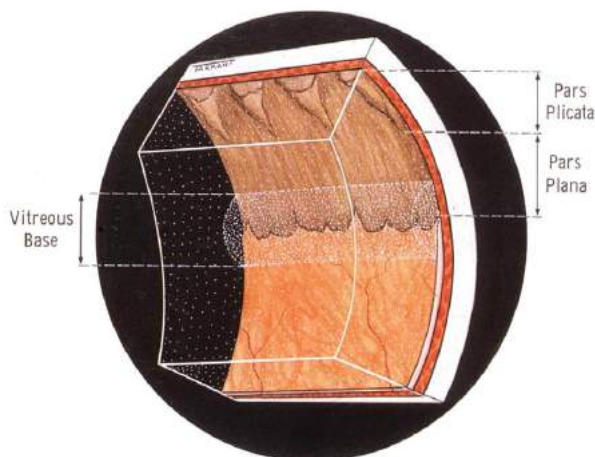
B. Vascular pigmented coat “middle vascular coat” / Uveal tract:

- Consists from behind forward, of the **iris, ciliary body and choroid**.
- **The choroid** is composed of an outer pigmented layer and an inner, highly vascular layer.
- **The ciliary body** is continuous posteriorly with the choroid, and anteriorly, it lies behind the peripheral margin of the iris.
- It is subdivided into three parts:

Ciliary muscle	<ul style="list-style-type: none"> ● Innervated by parasympathetic. ● Its zonules fibers attached to the lens. ● Responsible for changing lens thickness and curvature during accommodation. ● How it works (in layman explanation): ● Relaxed muscle → zonules pulled → thin lens (far sighted) ● Contracted muscles → zonules relax → thick lens (near sighted)
Ciliary process (pars plicata)	Two layers: <ol style="list-style-type: none"> 1- Pigmented outer layer 2- Non pigmented inner layer: section of aqueous humor.
Pars plana	Avascular space. Important area surgically to approach the vitreous space.

C. Inner layer:

- composed of the optic nerve and the retina.
- The retina extends forward to within 6 mm of the limbus.
- Lenses attached to ciliary body by zonular fibers about 70,000 in number.
- Power length in **cornea 42 db while in lens 18**.



Conjunctiva: (transparent membrane covering sclera) :

1. **Bulbar conjunctiva:** covers the scler

Conjunctiva

Transparent membrane covering sclera

1- Palpebral Conjunctiva (orbital cavity septum): covers the eye lid. It contains accessory gland which responsible for tear secretion while lacrimal gland a reflex secretion).

To see the palpebral conjunctiva: look down for suppressing the eye elevators for evaluating palpebral if the is foreign bodies

For the orbital cavity septum if there is infection behind it can cause **thrombosis the ophthalmic vein and will lead to cavernous sinus thrombosis**

2- Bulbar Conjunctiva: covers the anterior part of the sclera

3- Forniceal Conjunctiva.

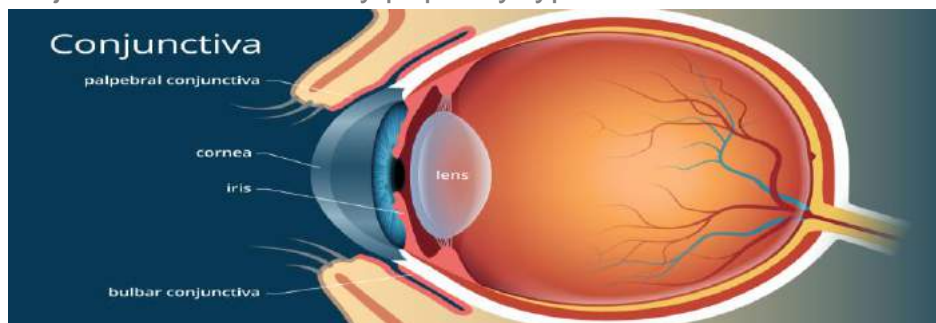
The conjunctival stroma is divided into:

1- **Adenoid layer.** Inflammation type: Follicular Conjunctivitis

2- **Fibrous layer.** Inflammation type: Papillary Conjunctivitis

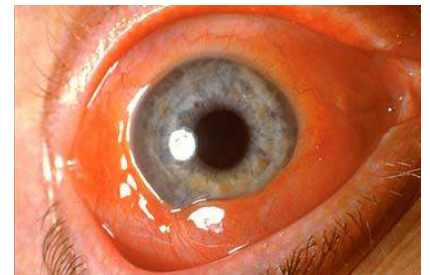The adenoid layer doesn't develop until 3 months after birth.

Newborn with conjunctivitis. Most likely papillary type

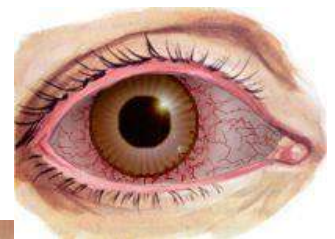


Diseases:

1- Chemosis: is the swelling of the conjunctiva due to **abnormally permeable capillaries**, it's a nonspecific sign of eye irritation and could be caused by conjunctivitis.



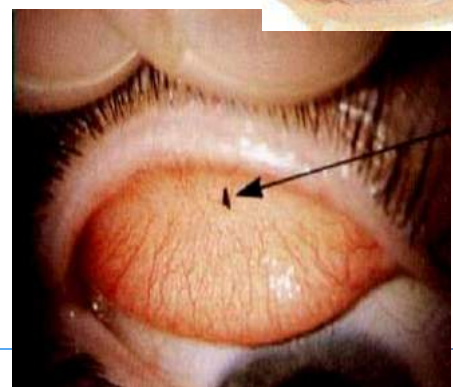
2- Ciliary injection: is peripheral hyperemia of the **anterior ciliary vessels** which produces a **deep red or rose color** of the corneal stroma



Causes of ciliary injection: keratitis , Uveitis & Acute glaucoma.

SAQ/Q. patient came complaining of tearing and pain when I exam the eye I found foreign body ?

- What is the diagnosis? Palpebral conjunctival foreign body - tarsal foreign body .
- What is the treatment? Removal and topical antibiotic.



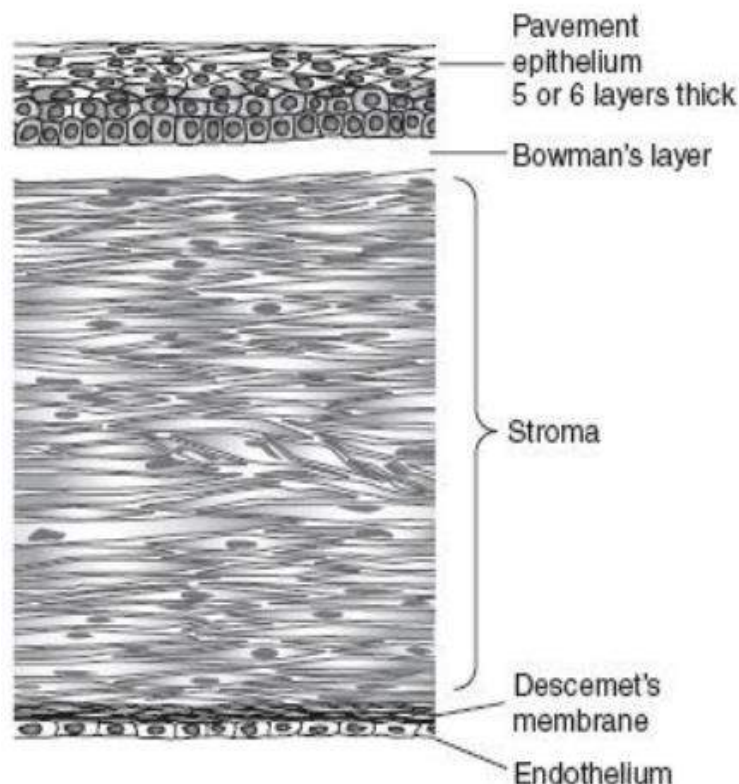
Cornea

It's a 500 – 530 micron thick transparent avascular tissue.

- The anterior cornea take the oxygen from direct exposure
- However most of the corneal take it from acquis fluid posteriorly

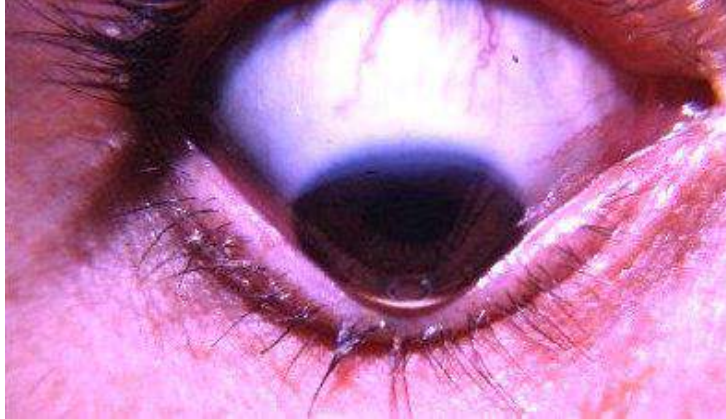It has 5 layers

Layer (anterior to posterior)		condition
Epithelium	<ul style="list-style-type: none"> ➤ continuation of the bulbar conjunctiva ➤ ectodermal origin 	Abrasion. Treatment by covering the eye for 24hrs and defect will heal without scarring . Never use topical anesthesia in this case.
Bowman's membrane	clear acellular layer	Abrasion. Risk of scarring
Stroma	contains collagen fibrils that accounts for around 90% thickness	
Descemet's membrane		Disturbance of this layer is common in congenital glaucoma. Management is surgical via keratoplasty
Endothelium	Single layer	It end in the angle, we have to know if it's open or closed which is about schwalbe's line , trabecular meshwork , scleral spur , ciliary body and iris if all structures are seen that mean open angle glaucoma while if all structures closed that mean closed angle.



The thickness of the cornea affects the IOP reading. After Lasik, the cornea becomes weak and a false low reading of IOP could occur which might miss the diagnosis of glaucoma.

- One possible risk of Lasik is **keratoconus**, which is central thinning and plugging of the cornea. This might end with corneal scarring and keratoplasty "corneal transplantation". The patient with keratoconus when he looks down, his lower eyelid becomes V shaped because of the plugging, and this is called **Munson's sign**. "important"

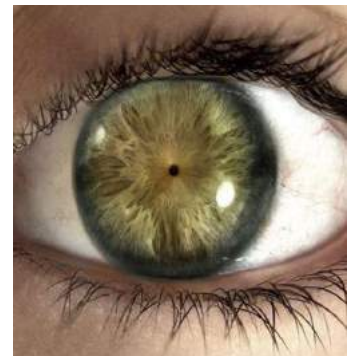
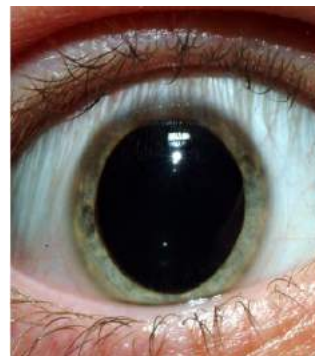
Iris and Pupil:

The iris is a thin, contractile, pigmented diaphragm with a central aperture, the pupil. It is positioned in front of the lens, dividing the anterior chamber from the posterior chamber, each of which contains aqueous humor that passes through the pupil. The iris has **two muscles**:

1. **Dilator pupillae**: **dilation** of pupil supplied by **sympathetic fibers**.
2. **Sphincter pupillae**: **constriction** of pupil supplied by **parasympathetic** fibers from the **oculomotor nerve**.

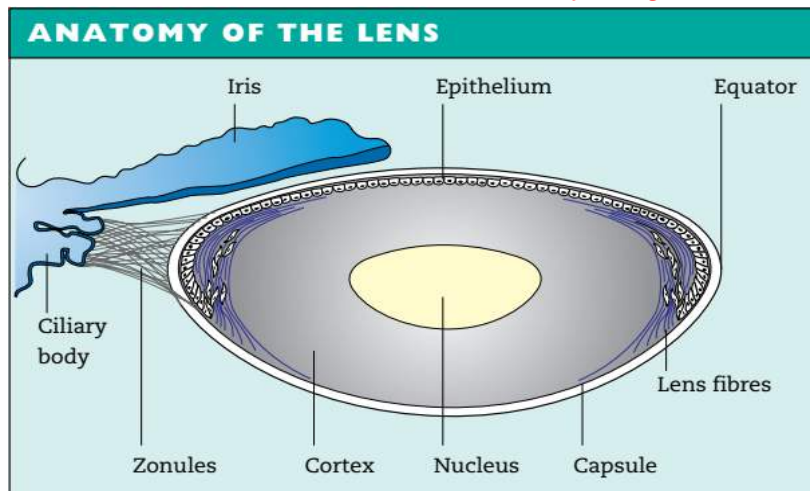
In patients with 3rd nerve palsy and spared pupil like in diabetes, or in patients with semi dilated fully dilated pupil and 3rd nerve palsy, what is the recommended investigation? The answer is MRA "magnetic resonance angiography" because the most common cause of surgical 3rd nerve palsy is aneurysm, which can be detected using MRA.



anisocoria: different size of the pupil . one supply by sympathetic and the other by parasympathetic.

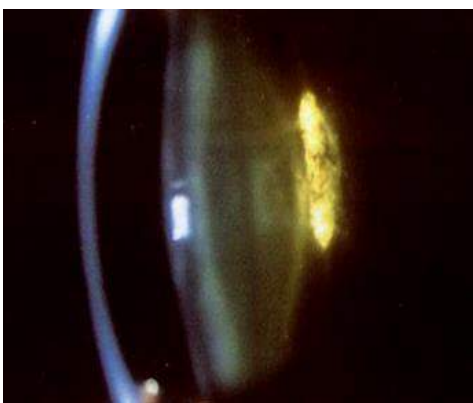
The Lens:

- The lens is a transparent, **avascular**, biconvex structure enclosed in a transparent capsule.
- It's encircled by the ciliary processes. Anterior to the lens is the aqueous and posterior to it is the vitreous.
- Crystalline lens is the only structure continuously grow throughout life. By the age of 40 the lens become less elastic (increase in refractive index) that could develop a condition called **nuclear sclerosis** which is an **early stage of cataract**.

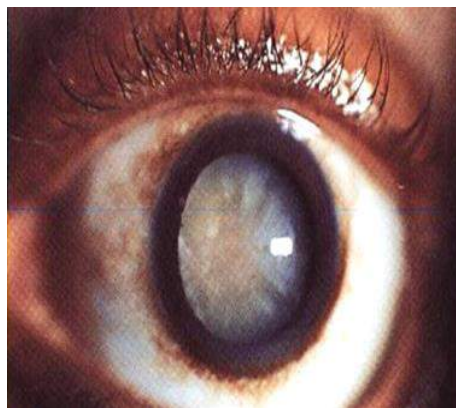

Posterior pole is more convex than anterior pole

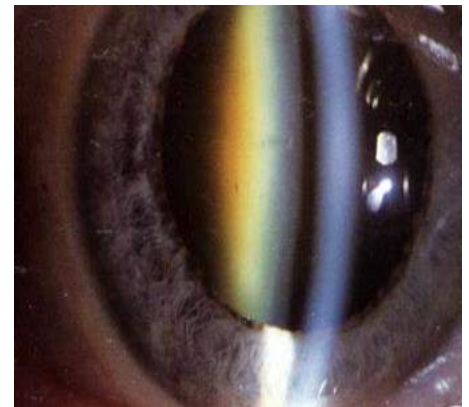
- The lens consists of an
 1. **Elastic capsule:** envelops the lens.
 2. **Cuboidal epithelium:** confined exclusively to the **anterior** surface of the lens.
 3. **Lens fibers**, which are formed from the cuboidal epithelium at the equator of the lens.



posterior subcapsular cataract Possible causes: steroids and trauma



cortical cataract



this is a nuclear sclerosis representing a manifestation of early stage cataract.

Retina and Vitreous:

- **Main function:** its responsible of changing photon power into action potential through photoreceptors

- **Blood supply:**

1. Inner one third from: the central retinal artery branch off the ophthalmic artery
2. Otter two third from: the choroid

- The retina consists of an **outer pigmented layer** and an **inner nervous layer**.

- The two layers of retina are prone to detachment

- Neural retina is attached with the choroid and the pigmented retina is in contact with the vitreous body.

- **Photoreceptors** is responsible of changing photon power into action potential.

- Photoreceptors is highly condensed at the Fovea

- Its extends anteriorly to the ciliary body and attach at a point called: ora serrata. Posteriorly it reaches the optic disc.

- At the center of the posterior part of the retina is an oval, yellowish area, the **macula lutea**, which is the area of the **highest visual acuity**.

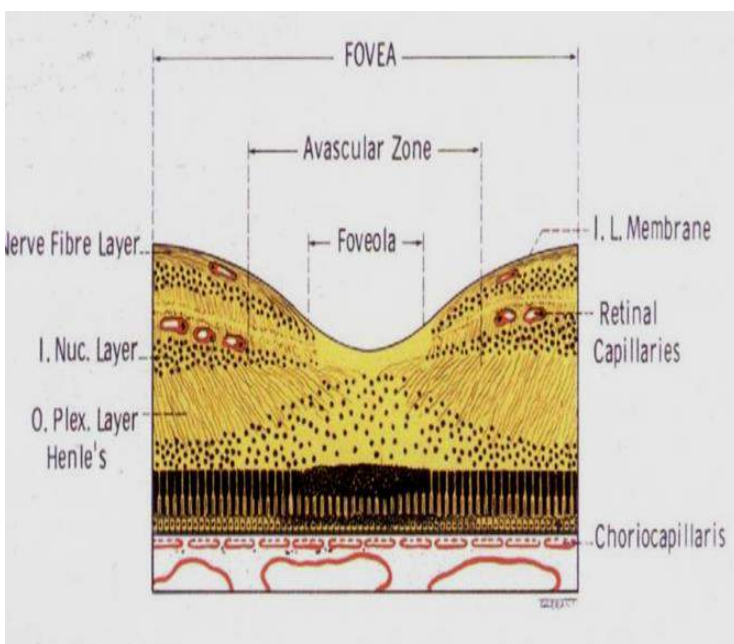
- **Fovea centralis (avascular zone)**, a central depression. **Any disturbance in the fovea will decrease the vision**.

- The fovea is condensed with cones and rods. Rods is used for night vision and cones for day vision.

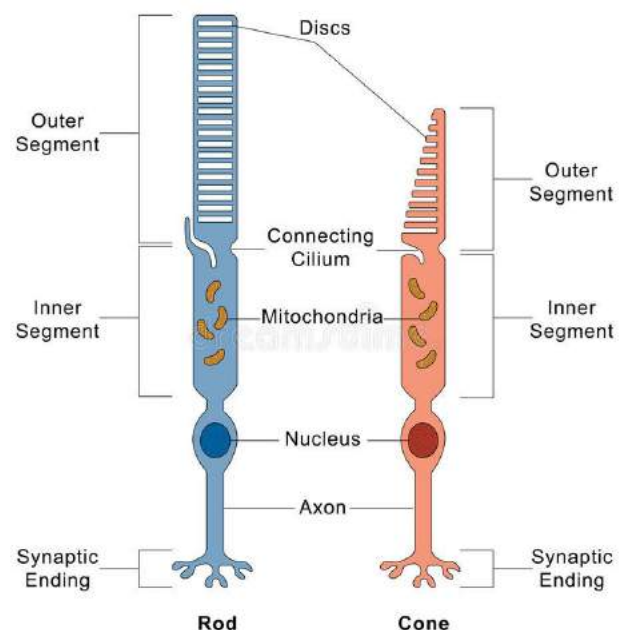
- The optic nerve leaves the retina about 3 mm to the **medial side (nasal)** of the macula lutea by the optic disc.

- The optic disc is slightly depressed at its center, where it is pierced by the central retina artery.

- The optic disc is referred as the **“blind spot”** due to lack of rods and cones

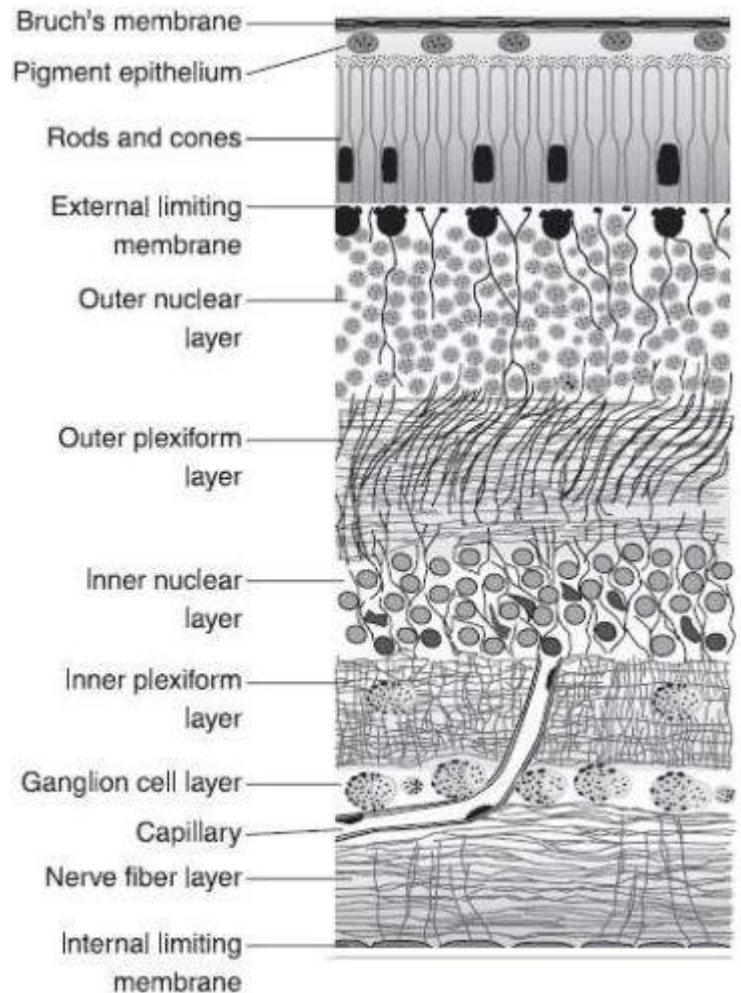


Rods: night vision
Cones: light vision



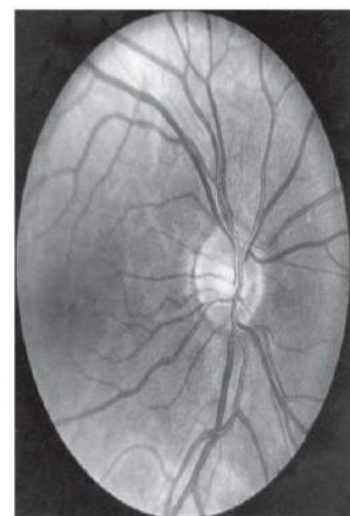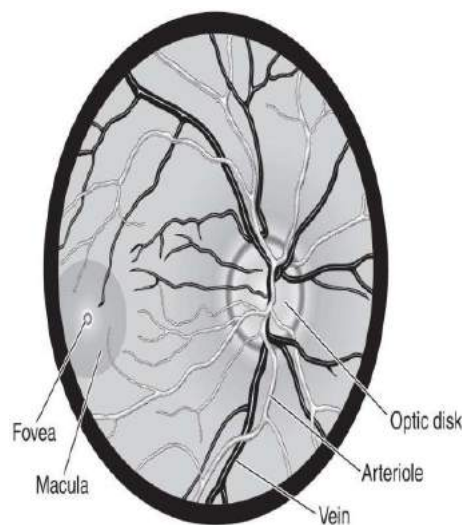
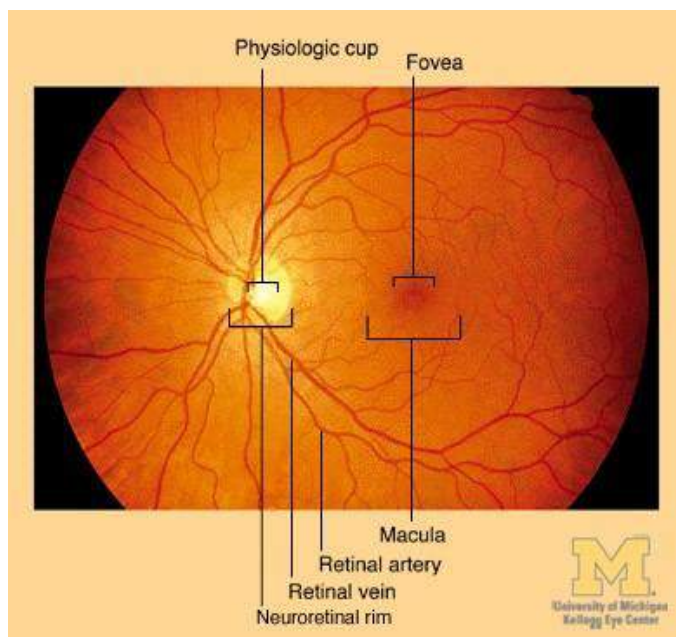
Layers of the retina (10 layers):

1. Retinal pigment epithelium
2. Photoreceptor layer
3. Outer limiting membrane
4. Outer nuclear layer
5. Outer plexiform layer inner
6. Inner nuclear layer
7. Inner plexiform layer
8. Ganglion cell layer
9. Nerve fiber layer
10. Internal limiting membrane



Types of retinal detachments clinic

- 1- Rhegmatogenous retinal detachment: tear, break in the retina
- 2- Tractional retinal detachment: like in DM
- 3- Exudative retinal detachment. Fluid accumulation under the retina without the presence of tear.



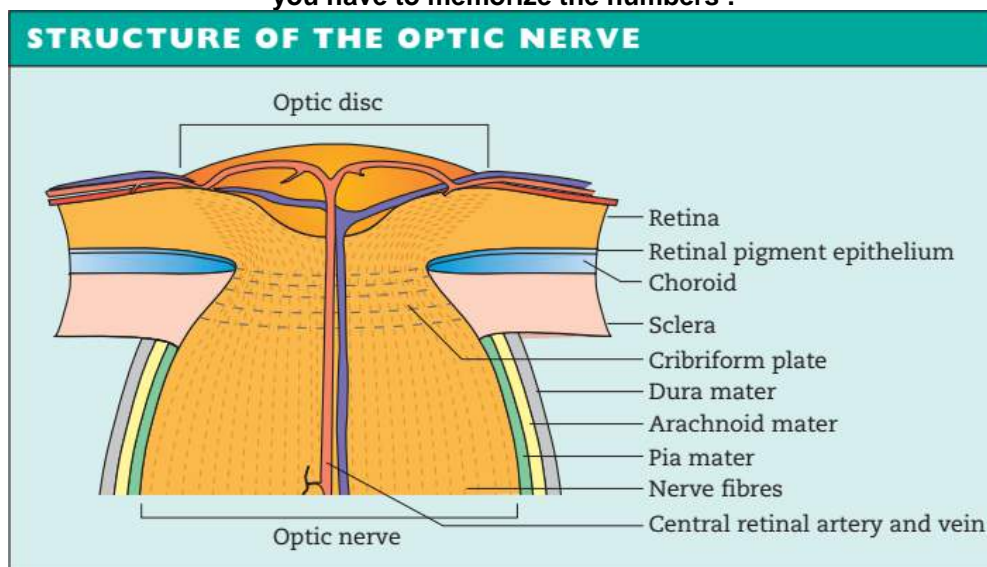
Optic Nerve: (optic nerve > optic disc > rim and cup (when increase is sign of glaucoma, or could be physiological and we differentiate two types by measuring IOP and visual field)).

- Contains around 1.2 million nerve fibers, which are axons of the retinal ganglion cells.

The length of optic nerve in these structures:

- 1 mm in the globe.
- 25 mm in the orbit.
- 9 mm in the optic canal.
- 16 mm in the cranial space
- Partial decussation occurs and about 53% of the fibers cross to form the optic tracts (if pt have carotid lesion will develop binasal hemianopia)
- The optic nerve leaves the retina about 3 mm to the **medial side** of the macula lutea by the optic disc. The optic disc is slightly depressed at its center, where it is pierced by the **central retinal artery**. At the optic disc, is a **complete absence** of rods and cons, so that the optic disk is insensitive to light and is referred to as the “blind spot”.
- **Optic disc:** the terminal part of the optic nerve where ganglion cells fibers leaves the eye.
- **Optic cup:** a central depression whethin the optic disc.
- The normally cup-disk ratio is **3/10**. Measurement is crucial to diagnose certain diseases like glaucoma.

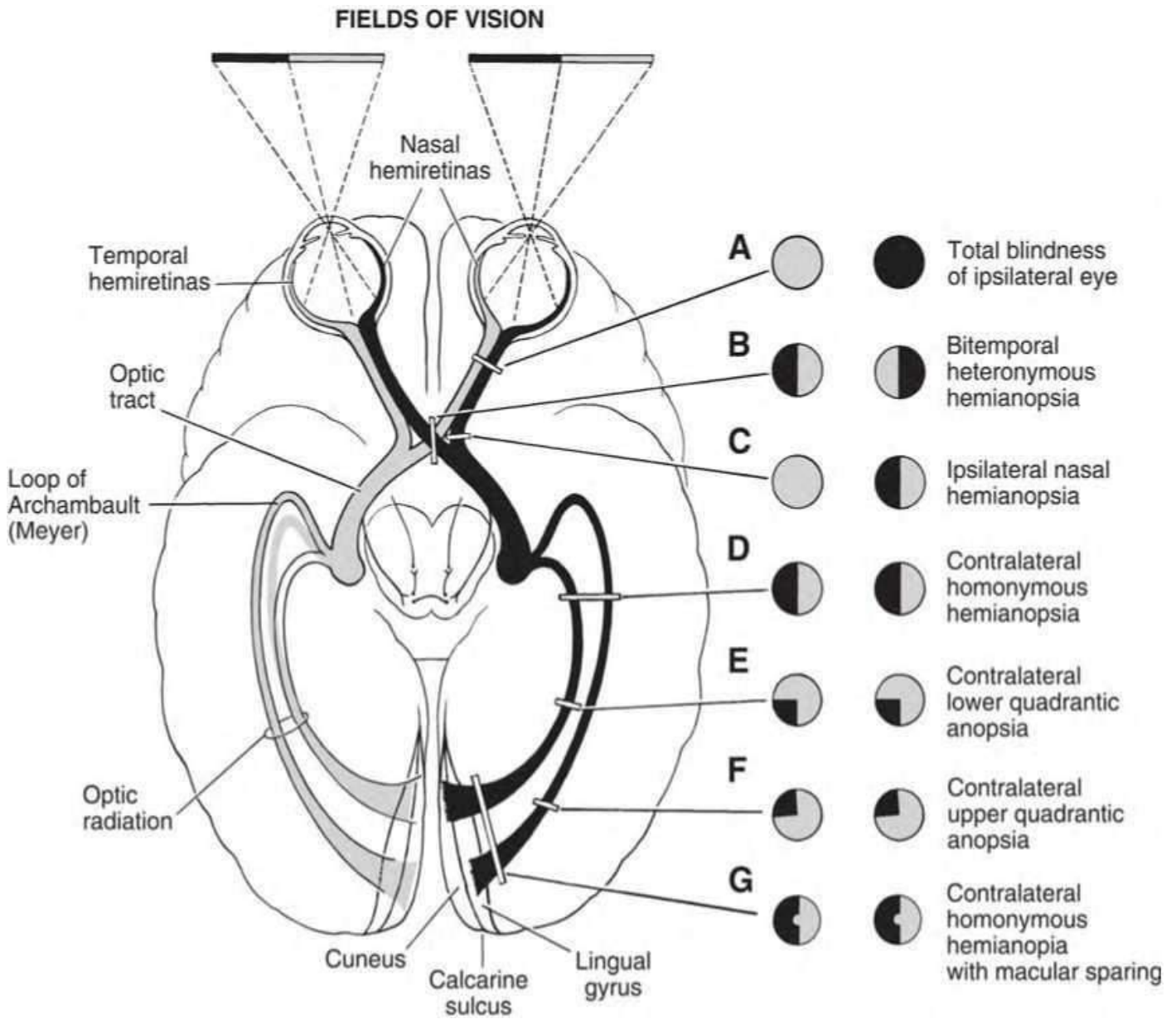
you have to memorize the numbers !



The Visual Pathway:

Formed by three neurons

1. Bipolar cell, lies within the retina.
2. Ganglion cell, synapse in lateral geniculate body.
3. Third neuron terminates in visual cortex.



Pituitary adenoma: bi temporal hemianopia

Optic chiasm: crossing of nasal fibers to the opposite optic tract and passage of temporal fibers to the ipsilateral optic tract.

- **Afferent pupillary defect:**

Related to pupillary light reflex (extra explanation)

normal anatomy:

what happen when you shine a light on the retina?

Afferent part: (via optic nerve)

Step1: small numbers of optic nerves fibers bypass lateral geniculate body and terminate at: Pretectal nuclei in the midbrain.

Step2: Pretectal nuclei will pass the signals to another nuclei in the midbrain called:

Edinger-Westphal nucleus which contain preganglionic parasympathetic fibers that supply both eyes

Efferent part: (via oculomotor)

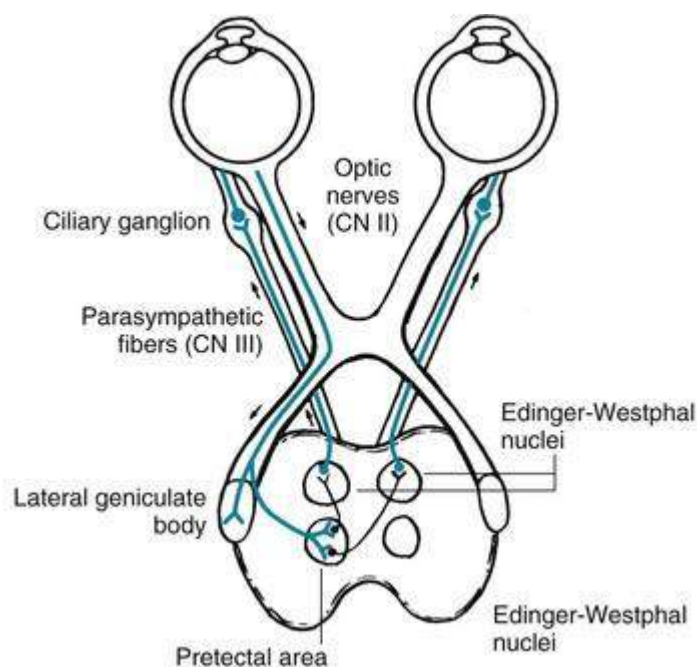
Step3: EWN send signals through the **oculomotor nerve** until it reaches the **ciliary ganglion**.

Step4: postganglionic parasympathetic fibers will terminate at **sphincter pupillae** muscles which responsible for both eyes constriction.

Doctor notes:

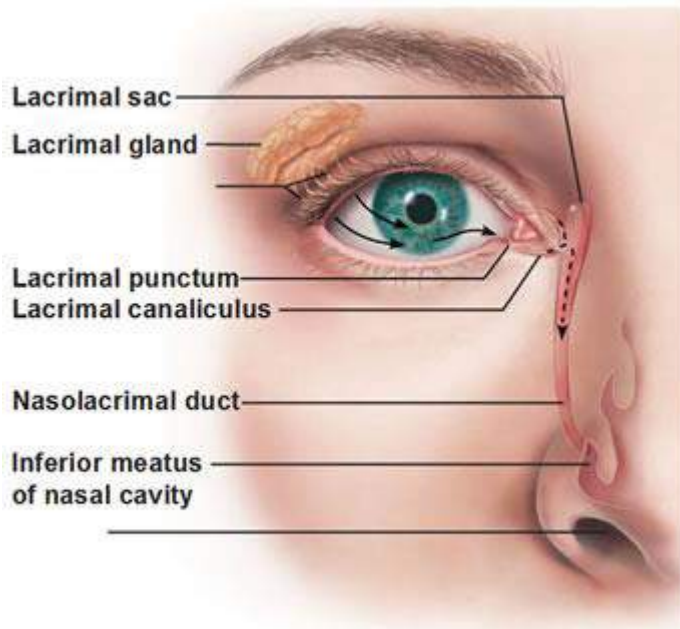
In case of cortex lesion, papillary reflex will not be affected. (accommodation reflex will be affected)

Lesions will only affect optic nerve until lateral geniculate nucleus.



THE LACRIMAL APPARATUS- adnexa:

- Lacrimal gland secretes tears into the upper fornix of the conjunctival sac which are spread over the surface of the cornea as a tear film by blinking of the lids.
- **The cascade:** Punctum → canaliculi → nasolacrimal sac → nasolacrimal duct → inferior meatus



Notes:

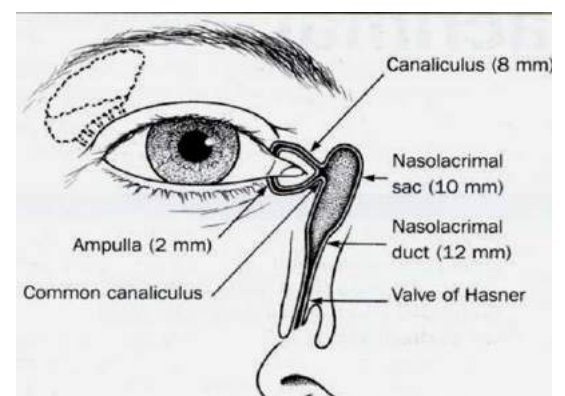
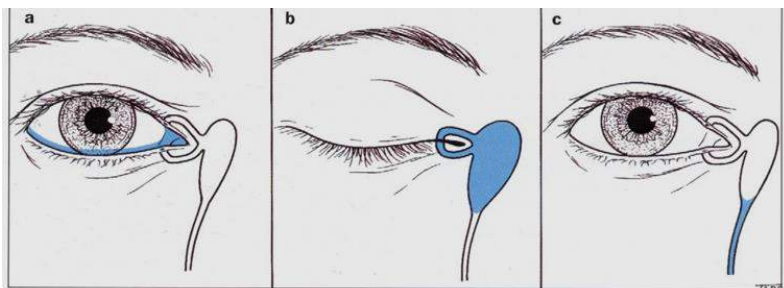
For the lacrimal gland, normally it's not palpable

The canaliculi connect the punctum to the **nasolacrimal sac** not the duct

Blinking help tear drainage into the system by creating **negative** pressure.

Tear film. 3 layers consist of:

- 1- Mucin gel layer: produced by conjunctival goblet cells
- 2- Aqueous layer: produced by lachrymal gland
- 3- Oil layer: Meibomian glands



The Intraocular Pressure:

- The pressure within the eye is maintained at a steady level by continuous formation & drainage of aqueous.
- Aqueous is secreted by the ciliary epithelium → posterior chamber → anterior chamber (through the pupil) → drained through the anterior chamber angle.
- The normal intra ocular pressure is from **10-21** must be higher than epi-scleral vein which is 9 to have the ability to drain from trabulcar meshwork.
- High IOP almost always due to an obstruction of aqueous outflow.
- **Ocular Hypertension:** high IOP with no optic disk damage.
- **Papilledema: bilateral disk edema with high ICP**

Optics of the Eye:

The eye is like a camera. Light must have a clearly pathway to be clearly focused on the sensory receptors of the retina, i.e., Clear cornea, anterior chamber, lens and vitreous cavity.

The Refractive power of the eye is **about 58 - 62 diopters**.

- The cornea is the major refracting element of the eye with a power of approximately 40 diopters. If the curvature is greater in one meridian than the other→ Astigmatism.
- The **refractive power** of the lens is about **17-21 diopters at rest**. Accommodation able to change the power of the lens markedly depends on age.(when near contraction of ciliary muscle , relaxation of zonular and bulging of the lens due to elastic lens capsule will occur while looking for far relaxation of ciliary muscle , contraction of zonular and lens will flatten)
- **Optic chiasm objective:**
 1. To visualize the object seen by the two eyes into a 3D image.
 2. Single image received by the two eyes to be transferred and translated by the visual cortex.

VISION:

The retina:

- The central retina contains yellow pigment, Xanthophyll, the so called macula lutea (yellow spot).
- It is divided into retinal pigment epithelium & neurosensory retina.
- **Photoreceptors** contains **visual pigment** which consists of a large protein (opsin) attached to retinal (vitamin A aldehyde).
 - Light splits the opsin from the retinal with initiation of a graded electrical potential → Transmitted through the visual pathway to be processed in the visual cortex (occipital lobe) → vision sense.(transform chemical to electrical symptoms)
 - **Visual Pathway:** Three neurons
 1. Bipolar cell, lies within the retina.
 2. Ganglion cell, synapse in lateral geniculate body.
 3. Third neuron terminates in visual cortex.

senario

mother came with her baby complaining of tearing eye ?

DDx: nasolacrimal duct obstruction and congenital glaucoma , how would you know which one is the Dx?

if there is nasal secretion that mean this is congenital glaucoma.

MCQs

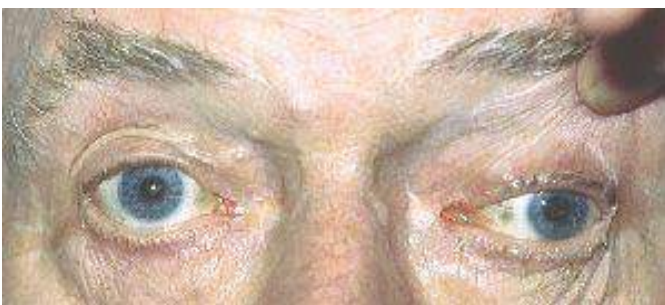1. The socket that contains the eye called? **ORBIT**
2. the orbit is formed by. **Seven Bones**
3. The optic nerve pass through. **Optic foramen or canal**
4. The eye hasExtraocular muscles. **Six(4 Recti and 2 obliques)**
5. All extraocular muscles are supplied by..... except and..... **Oculomotor nerve/SO4/LR6.**
6. When we test a patient 4th nerve we should ask him to lookand **Down/ in**
7. The space that lies behind the cornea & in front of the iris called. **Anterior chamber**
8. The fluid that fills the chambers of the eye called. **Aqueous humors**
9. The cavity that lies behind the lens called. **Vitreous cavity**
10. The main refractive structure in the eye is..... **The cornea**
11. The second refractive structure in the eye can change its power **The lens**
12. The structure that determines the color of the eye is... **The iris**
13. when the lens get opacified this condition called **cataract**
14. The central part of the retina called. **The macula**
15. The central part of the macula called **Fovea**
16. The central part of the fovea called **foveola**
17. The optic nerve lies in **Nasal** part of the retina
18. The percentage of the decussating fibers is **53%**

Q.Patient with a 3rd nerve palsy, how can you rule out 4th nerve palsy?

The clinical manifestations of 3rd nerve palsy:

- Ptosis.
- All muscles are paralyzed except the LR, so the eye will be abducted.
- The patient can not look downward because the IR is paralyzed.

To know if the 4th nerve is intact or not, ask the patient to look downward and if the 4th nerve is intact, then the eye will be intorted due to the action of SO muscle.



Q&A from: ophthalmology notes 11ed. Check the figures from the book

1. The cornea

- a Has an endothelial layer that regenerates readily.
- b Comprises three layers.
- c The endothelium actively pumps water from the stroma.
- d Is an important refractive component of the eye.
- e Has a stroma composed of randomly arranged collagen fibrils.

2. The retina

- a Is ten layers thick.
- b Has ganglion cells whose axons form the optic nerve.
- c Has three types of rods responsible for colour vision.
- d The neuroretina is firmly attached to the retinal pigment epithelium.
- e The RPE delivers vitamin A for rhodopsin production.

3. The lens

- a Grows throughout life.
- b Is surrounded by a collagenous capsule.
- c Cortical and nuclear fibres are nucleated.
- d Has a high refractive index owing to its protein content.
- e Changes in shape with accommodation.

4. The suspensory ligament of the lens (the zonule)

- a Attaches the lens to the ciliary body.
- b Is part of the iridocorneal angle.
- c Is composed of smooth muscle.
- d Transmits changes in tension to the lens capsule.

5. The posterior chamber

- a Is another name for the vitreous body.
- b Lies between the iris, lens and ciliary body.
- c Contains aqueous humour, secreted by the ciliary processes.
- d Is in communication with the anterior chamber.

6. The tear film

- a Is 100 μ m thick.
- b Is composed of four layers.
- c The mucin layer is in contact with the cornea.
- d Is important in the refraction of light entering the eye.
- e Contains lysozyme and secretory IgA.

7. The iridocorneal angle

- a Is the site of aqueous production.
- b Lies between the cornea and the ciliary body.
- c In primary open angle glaucoma there is a reduction in the number of cells covering the trabecular meshwork.
- d Fluid passes through the trabecular meshwork to Schlemm's canal.

8. The optic nerve

- a Axons leave the eyeball through the cribriform plate.
- b Is not bathed in CSF until it enters the cranial cavity.
- c Anteriorly is supplied by blood from the ciliary arteries.
- d Axons are not myelinated in its retrobulbar part.
- e Is formed by the nerve fibre layer of the retina.

9. The third, fourth and sixth cranial nerves

- a All originate in the midbrain.
- b A nuclear third nerve palsy will cause a contralateral palsy of the superior rectus.
- c The fourth nerve supplies the lateral rectus.
- d The sixth nerve has a long intracranial course.
- e The third nerve may be affected by aneurysms of the posterior communicating artery.

Answers

1. The cornea

- a False. The human endothelium does not regenerate; dead cells are replaced by the spreading of surviving cells.
- b True. The cornea has epithelial, stromal and endothelial layers.
- c True. The endothelial cells pump out ions and the water follows osmotically. Removal of water maintains corneal transparency.
- d True. The cornea is a more powerful refractive element than the natural lens of the eye.
- e False. The fine, equally spaced, stromal collagen fibrils are arranged in parallel and packed in an orderly manner. This is a requirement for transparency.

2. The retina

- a True. See Figure 1.7 .
- b True. The retinal ganglion cell axons form the retinal nerve fibre layer and exit the eye at the optic nerve head.
- c False. The rods are responsible for night vision and three cone types are responsible for daylight and colour vision.
- d False. The attachment is loose; the neuroretina separates in retinal detachment.
- e True. Vitamin A is delivered by the RPE to the photoreceptors and combined with opsin.

3. The lens

- a True. It does grow throughout life.
- b True. This is of great importance in cataract surgery.
- c False. The older, deep cortical and nuclear fibres lose their nuclei and other organelles.
- d True. The high protein content accounts for its high refractive index.
- e True. See page 10.

4. The suspensory ligament of the lens (the zonule)

- a True. Zonular fibres extend from the pars plicata of the ciliary body to the lens equator.
- b False. The zonule lies behind the iris and iridocorneal angle.
- c False. The ciliary muscle contains smooth muscle, not the zonule.
- d True. Contraction of the ciliary muscle relaxes the zonular fibres allowing the lens to increase its curvature and thus its refractive power (this is 'accommodation').

5. The posterior chamber

- a False. The vitreous body is quite separate.
- b True. See Figure 1.1
- c True. See page 2.
- d True. Communication is via the pupil, in the gap between iris and lens at the pupil margin. If this gap is narrowed or closed, pressure in the posterior chamber pushes the iris forward and may close the angle (acute closed angle glaucoma).

6. The tear film

- a False. The tear film is 3 μ m thick.
- b False. The tear film is composed of mucin, aqueous and oil layers.
- c True. The mucin layer is produced by goblet cells.
- d True. It provides a smooth interface for the refraction of light.
- e True. These account for the antibacterial properties of the tear film.

7. The iridocorneal angle

- a False. It is the site of aqueous drainage.
- b True. See Figure 1.9 .
- c True. This may reduce aqueous drainage.
- d True. The process is active.

8. The optic nerve

- a True. This sieve - like structure provides support for the optic nerve as it leaves the eye.
- b False. In the orbit, within its sheaths, the optic nerve is surrounded by subarachnoid CSF in continuity with that in the intracranial cavity.
- c True. This is a most important blood supply for the anterior optic nerve.
- d False. They are usually not myelinated within the eye.
- e True. It is made up from retinal ganglion cell axons.

9. The third, fourth and sixth cranial nerves

- a False. The nucleus of the sixth nerve lies in the pons.
- b True. The superior rectus is innervated by the contralateral nucleus.
- c False. It supplies the superior oblique.
- d True. This makes the sixth nerve susceptible to trauma, which may cause lateral rectus palsy.
- e True. It passes lateral to the artery.