

Cleaning and Shaping of Root Canal

The major biologic aim of endodontic therapy is to eliminate apical periodontitis by disinfection and sealing of root canal systems. Although “cleaning and shaping” accurately describes the mechanical procedures, it should be emphasized that enlarging canals directly facilitate the cleaning action of irrigants and the removal of infected dentin. Therefore, the objectives of root canal treatment could be divided into Mechanical and Biological. Schilder described 5 mechanical and 4 biological objectives for successful root canal therapy. The **Mechanical** objectives are:

1. The root canal preparation should develop a continuously tapering cone. This shape mimics the natural canal shape.
2. Making the preparation in multiple planes which introduces the concept of “flow”. This objective preserves the natural curve of the canal.
3. Making the canal narrower apically and widest coronally. To create a continuous tapers up to apical third which creates the resistance form to hold gutta-percha in the canal.
4. Avoid transportation of the foramen. There should be gentle enlargement of the foramen while maintaining its position.
5. Keep the apical foramen as small as possible. Since over-enlargement of the apical opening contributes to number of iatrogenic problems. Doubling the file size apically increases the surface area of foramen for four folds (πr^2).

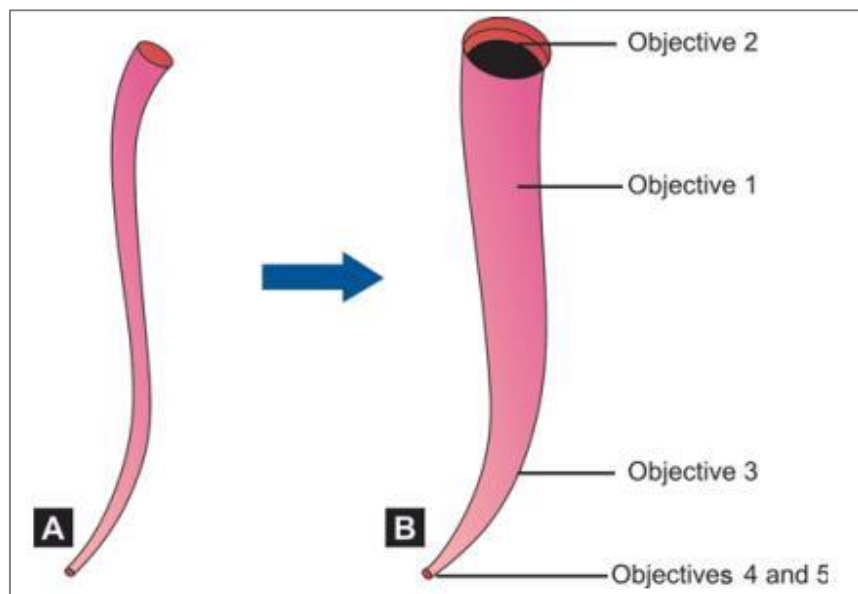


Diagram represents the mechanical objectives of root canal preparation.

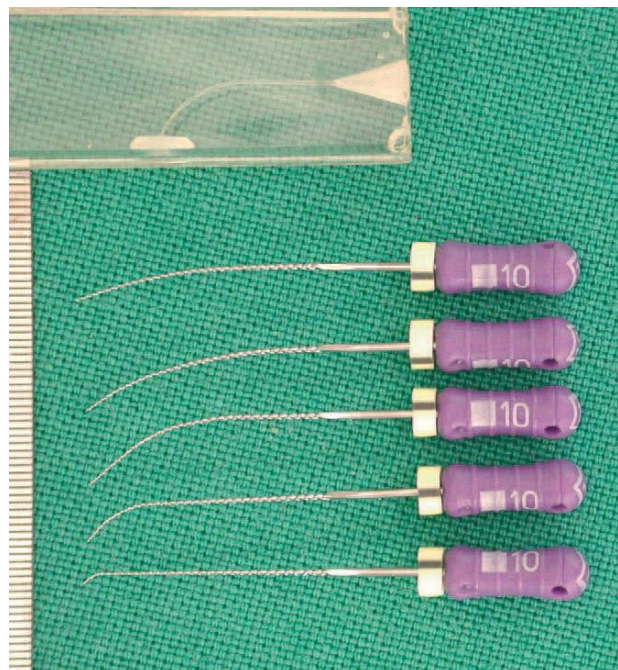
The **Biological** objectives are:

- 1- Confinement of instrumentation within the root canals only.
- 2- Ensure not to force necrotic or instrumentation debris beyond the apical foramen.
- 3- Optimum debridement of the root canal space.
- 4- Creation of sufficient space for intra-canal medicaments.

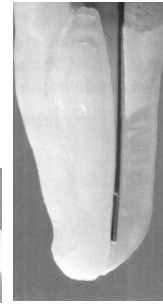
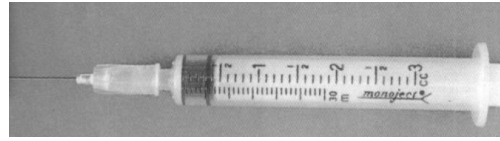
Aids in preparation of root canal

- 1- A Patency File (glide-path file): is a small K-file (usually a size #10 or #15) that is passively extended just through the apical foramen. This ensures opening of the canals and facilitate working length estimation.
- 2- Precurved instrument: In case of a curved canal, the instrument should be precurved to estimate the curvature of the canal. This is true only in case of stainless steel instrument, but nickel titanium instrument is flexible and cannot be curved.

Various precurved, stainless steel glide-path file. Compare the curves in the instruments to the ones in a plastic training block



- 3- The use of intracanal irrigation solutions that serve many advantages such as dissolving and flushing out of the debris from the root canal, lubricant for the cutting motion of the files within the canal, in addition to its antimicrobial activities. The most popular intra-canal irrigation solution is Sodium hypochlorite (NaOCl) 2.5-5.25%. This can be delivered inside the canal by using hypodermic syringe. (More details about irrigation and irrigant solutions will be discussed in the next lecture)



Hypodermic syringe and endodontic needle within root canal.

4- Examination of the instruments: Each instrument should be examined each time before insertion inside the root canal to verify the presence of any sign of fatigue, stress or damage, so any instrument showing such a sign should be discarded.

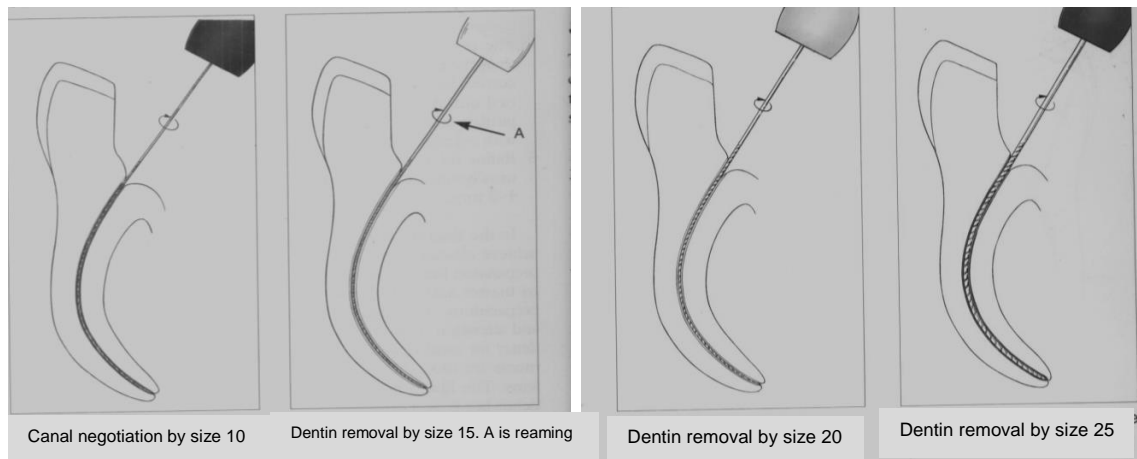
5- Use of instruments in sequential order: Root canal preparation is done gradually by using successively larger files (never skip any size of instrument) e.g. size 20 followed by size 25 then 30 and so on, but not size 20 then size 30.

Manual or Hand instrumentation techniques:

Several methods were developed for manual root canal preparation:

1- Standardized technique:

- This technique is developed by Ingle and uses the same working length (WL) definition for all instruments introduced into a root canal. Therefore, relies on the inherent shape of the instruments to impart the final shape of the canal. It is also called 'single-length technique'.
- In the beginning the canal is irrigated, then negotiation of fine canals is initiated with lubricated fine files in a so-called watch-winding movement until reaching to full WL. In watch winding motion, a gentle clockwise and anticlockwise rotation of file with minimal apical pressure is given.
- Canal preparation then continues with reaming or quarter-turn-and-pull motions until a next large instrument reached.
- This technique will produces a canal shape or taper that resembles the tapering of the final instrument which is called the master apical file (MAF).
- Creation of a true standardized tapered preparation is difficult in ideal straight canals and impossible in curved canals.
- A single match gutta percha point may then be used for root canal filling with inadequate space to do lateral compaction of gutta percha in such small canal tapering (0.02).



Disadvantages of Standardized technique:

- 1- Chances of loss of working length due to accumulation of dentin debris.
- 2- Increased incidences of ledging, zipping and perforation in curved canals.

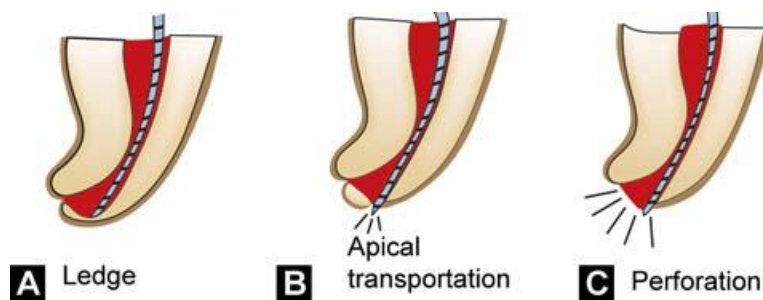


Diagram represent procedural errors

2- Step-back technique:

Realizing the importance of a canal shape larger than that produced with the standardized approach, the step-back technique was introduced by Clem and Weine in 1960. This technique relies on stepwise reduction of WL for larger files, typically in 1- or 0.5-mm steps, resulting in flared shapes with 0.05 and 0.10 taper, respectively. The final result is a preparation with small apical enlargement and marked taper from apical to coronal. The wide, less flexible instruments are avoided in the preparation of the apical portion of the canal. This will lessened the forces by these instruments on the canal walls, which in turn preserve the original shape of the canal. Filling with gutta-percha is made easier because more room space will be available for spreader &

plugger to penetrate more apically to get maximum condensation. The technique is as follow:

- After access of the pulp chamber and opening of the canal orifices, flood the pulp chamber with irrigant (Fig A and B).
- Establish the working length of each canal using path file which could be file # 10 (Fig C).
- Insert the next size file (# 15) into the full WL of the canal with a gentle watch-winding motion (for watch-winding motion see Fig D). Then start acting the file on the canal walls either with filling or quarter-turn-and-pull motion until the file becomes loosely moved within the canal.
- Remove the instrument and irrigate the canal.
- Place the next larger size files to the working length in similar manner and again irrigate the canal, until a clean white dentin will appear on the file tip. This file is called the MAF which is the final instrument that goes to the full working length (Fig E).
- Don't forget to recapitulate the canal with the previous smaller size instrument. This breaks up apical debris to be easily washed away with the irrigant.
- Next use a larger file, i.e. one size larger than MAF into 0.5 to 1 mm shorter than WL (Fig F). Then recapitulate the canal with MAF to full WL of the canal (Fig G) with irrigation to remove apical debris and maintain the WL.
- This process can be repeated to 3 or more, larger files until a good flaring and cleaning of the canal is obtained (Fig H, I and J). Furthermore, flaring of the coronal third of the canal can be more enlarged by using Gates Glidden rotary drills to obtain better canal cleaning coronally (Fig K and L).

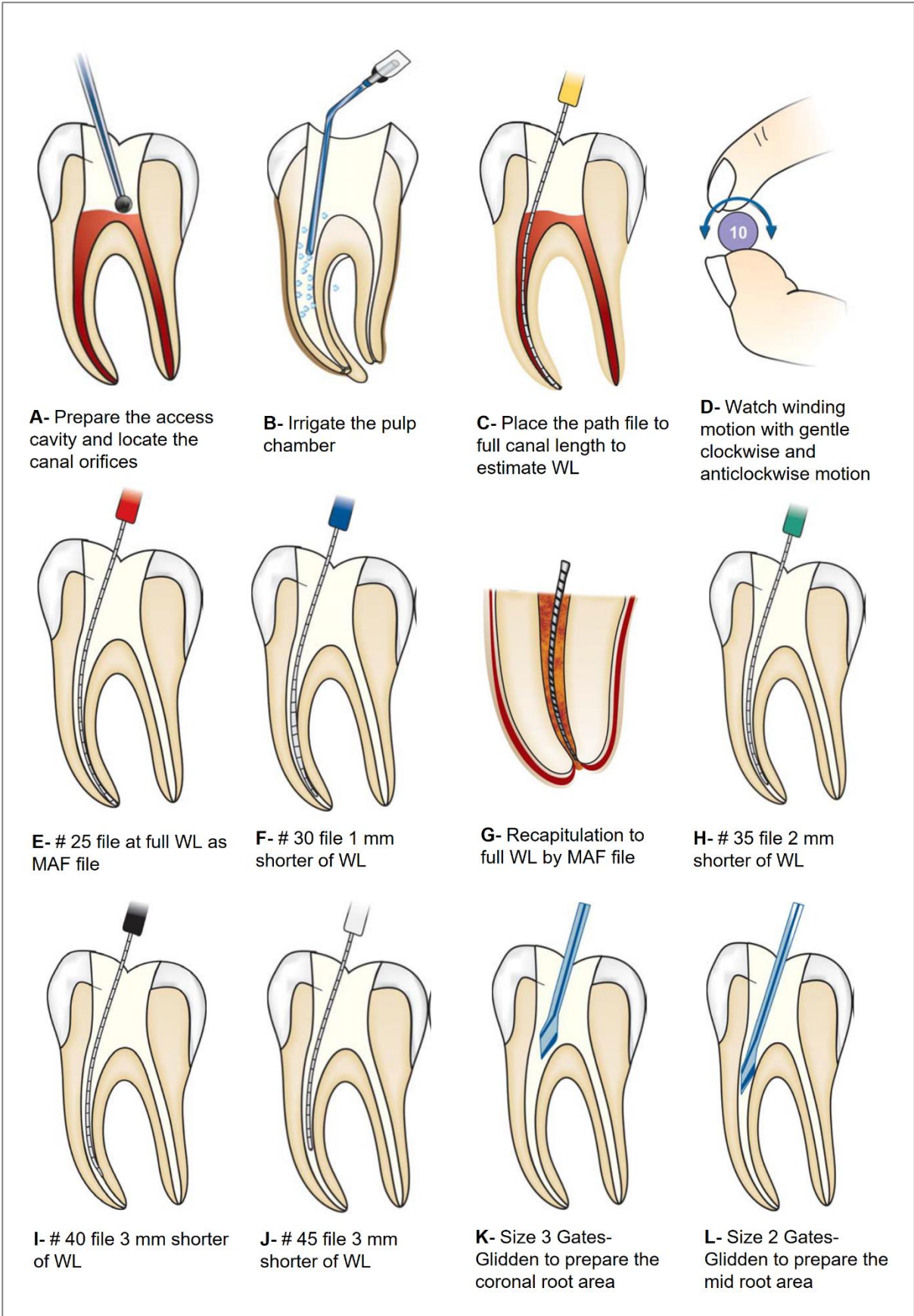


Diagram represent step-back root canal instrumentation technique.

Advantages of step-back technique:

More flare at coronal part of root canal with proper apical stop.

Disadvantages of step-back technique:

1. Difficult to irrigate apical region.
2. More chances of pushing debris periapically.
3. Time consuming.
4. Increased chances of iatrogenic errors for example ledge formation in curved canals.
5. Difficult to penetrate instruments in the canal.
6. More chances of instrument fracture.

Step-down technique:

This technique was developed to shape the coronal part (coronal preflaring) of the canal before instrumentation of the apical part.

The objectives of this technique is

- 1- To permit straight access to the apical region of the canal by eliminating coronal interference
- 2- To remove the bulk of necrotic tissue and microorganisms before apical shaping to minimize extruded debris through the apical foramen during instrumentation.
- 3- To allow deeper penetration of irrigant deeply into the apical part of the canal. In addition, it provide coronal escape way for debris extrusion from the apex.
- 4- The WL is less likely to change with less chance of zipping near the apical constriction.

Procedure:

- Preparation of two coronal root canal thirds using Hedstrom files of size #15, #20, and #25 to 16 to 18 mm or where they bind. These files are used with circumferential filing motion on the canal walls.
- Thereafter, increasing the coronal flaring of the canal by using Gates-Glidden drills size 2, 3, and 4, in sequential order and 1mm shorter length between each file.
- Followed by canal WL estimation, then instrumentation of the remaining apical part of the canal. This includes using small K-file # 15, 20 and 25 to prepare the apical seat.

- Combining the two parts, step-down and apical shape, by stepwise decreasing of WL of incrementally larger files. Frequent recapitulation with a #25 K-file to WL is advised to prevent blockage.

Balanced force technique:

This technique was introduced by Roane and Sabala in 1985, after the development of new file 'Flex-R file'. This file has "safe tip design" with a guiding land area behind the tip which allows the file to follow the canal curvature without binding in the outside wall of the curved canal. While the old K-type files have pyramidal tips with cutting angles which can be quite aggressive with clockwise rotation. This technique can be described as positioning and preloading an instrument through a clockwise rotation and then shaping the canal with a counterclockwise rotation.

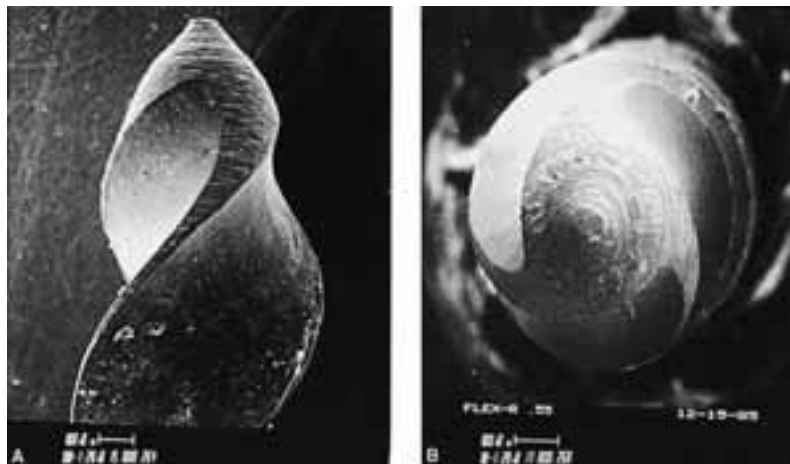


Fig shows Flex-R file with non-cutting tip.

Procedure:

1. In balanced force technique, preparation is completed in a step-down approach. The coronal and mid-thirds of a canal are flared with GG drills, beginning with small sizes as described previously.
- 2- After that, the balanced force hand instrumentation begins in the apical preparation by placing, cutting, and removing instrument using only rotation motion. First file which binds short of working length is inserted into the canal and rotated clockwise a quarter of a turn. This movement causes flutes to engage a small amount of dentin.
3. Now file is rotated counterclockwise with apical pressure at least one third of a revolution. It is the counterclockwise rotation with apical pressure which actually

provides the cutting action by shearing off small amount of dentin engaged during clockwise rotation.

4. Then a final clockwise rotation is given to the instrument which loads the flutes of file with loosened debris and the file is withdrawn.

5. Balanced Force instrumentation initiated from the belief that the apical area should be shaped to sizes larger than were generally practiced. The original Balanced Force concept then refers to apical control zones by, for example, first using sizes #15 and #20 files to the periodontal ligament (i.e., through the apical foramen) and then reducing the working depth by 0.5 mm for subsequent sizes #25, #30, and #35. The apical shape is then completed 1 mm short using sizes #40 and #45 under continuing irrigation with NaOCl.

Advantages of balanced force technique

Lesser chances of creating a ledge, blockage or canal transportation.

Crown-down (pressure-less) technique

The crown-down instrumentation concept based on the canal shaping technique moving from the crown toward the apical portion of the canal. This concept was the introductory for the most recent rotary instrumentation technology.

Procedure:

1. After preparing the access opening and locating the canal, flood the pulp chamber with irrigation solution and start preflaring of the canal orifices. This can be done by using hand instruments, Gates-Glidden drills or the nickle-titanium rotary instruments. After that a glide-path for each canal have to be obtained from the canal orifice till the apical foramen by using # 10 or 15 file.

2. Coronal preparation of the canal can be started with Gates-Glidden drills. The crown down approach begins with larger Gates-Glidden first (Fig A) (size 4 or 5), followed by smaller diameter Gates-Gliddens are worked into the canal with additional mm to complete coronal flaring. A care should be taken to avoid carrying all the Gates-Glidden drills to same level which may lead to excessive cutting of the dentin.

3. Frequent irrigation with sodium hypochlorite and recapitulation with a smaller file (usually No. 10 file) to prevent canal blockage.

4. After establishing coronal and mid root enlargement, explore the canal and establish the working length with small instruments (# 10 or 15 file) (Fig B).
5. Introduce larger files to coronal part of the canal and prepare it (Fig C and D). Subsequently introduce progressively smaller number files deeper into the canal in sequential order and prepare the apical part of the canal (Fig E).
6. Final apical preparation is prepared and finished along with frequent irrigation of the canal system.

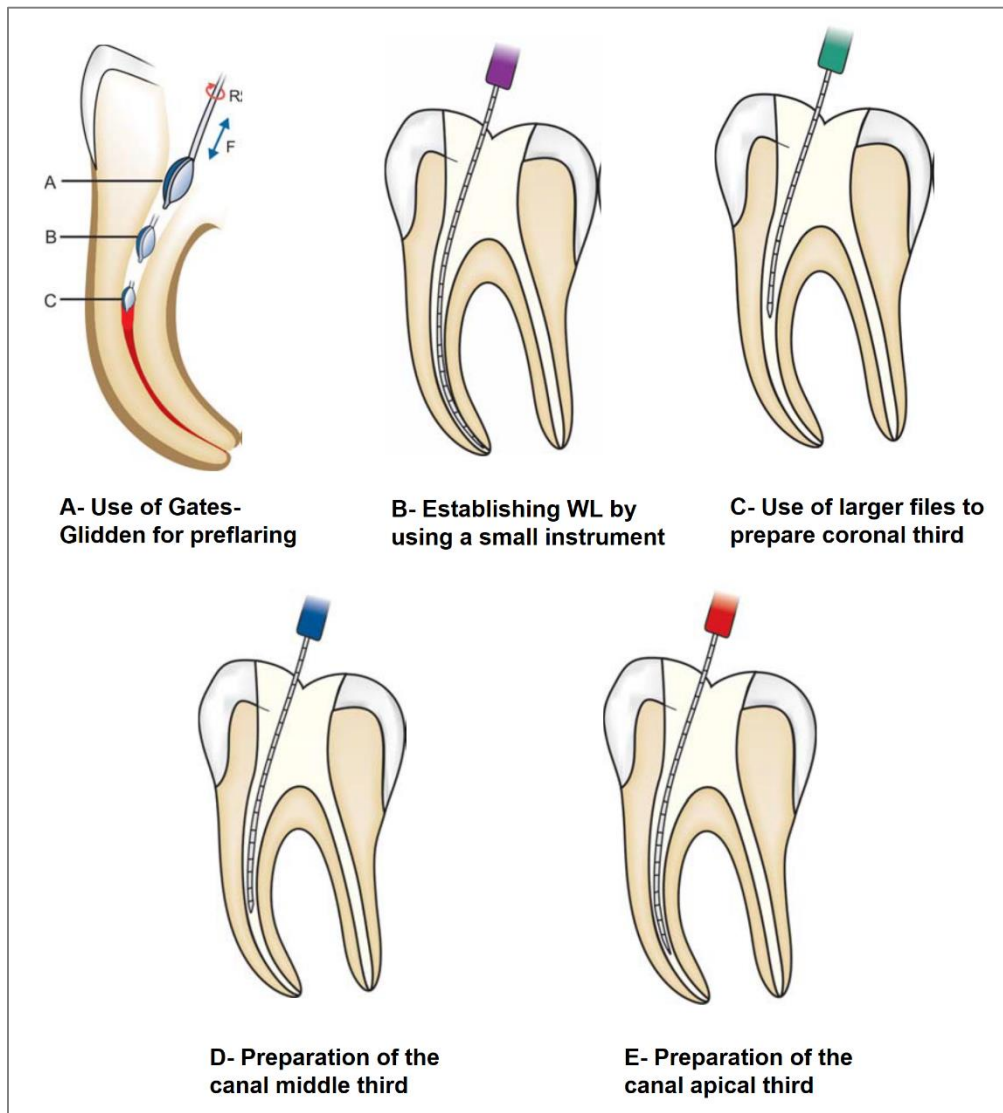


Diagram presenting Crown down (pressure-less) technique

Biological Advantages of crown down technique:

1. Removal of tissue debris coronally, thus minimizing the extrusion of debris periapically.

2. Reduction of postoperative sensitivity which could result from periapical extrusion of debris.
3. Greater volumes of irrigants can reach in canal irregularities in early stages of canal preparation because of coronal flaring.
4. Better dissolution of tissue with increased penetration of the irrigants.

Clinical advantages of crown down technique:

1. Enhanced tactile sensation with instruments because of removal of coronal interferences.
2. Flexible (smaller) files are used in apical portion of the canal; whereas larger (stiffer) files need not be forced but kept short of the apex. This decrease the chance for canal ledging, transportation and perforation.
3. Straight line access to root curves and canal junctions.
4. Provides more space for irrigants.
5. Enhance canal debridement and Decrease frequency of canal blockages.
6. Desired shape of canal can be obtained that is narrow apically and wider coronally. This provides better room for Gatta Percha condensation to obtain proper three dimensional obturation of the root canal.

References:

- 1- Garg N., Garg A. Textbook of Endodontics. Jaypee Brother Medical Publisher (P) LTD. 2nd Edition, 2010.
- 2- Hargreaves K M., Cohen S., Berman L H., Cohen's Pathways of the Pulp. Mosby. 10th Edition, 2011.
- 3- Hülsmann M., Peters O A., Dummer P MH. Mechanical preparation of root canals: shaping goals, techniques and means. Endodontic Topics. 2005; 10 (1): 30-76.
- 4- Ingle J I., Bakland L K., Baumgartner J C., Ingle's ENdodontics 6. BC Decker Inc Hamilton. 6th Edition, 2008.
- 5- Ruddle C J. Endodontic Access Preparation The Tool for Success. Just in Time Online Education, Dental Products Report. 2007: 1-9.
- 6- Vertucci F J., Fla G., Root Canal Anatomy of the Human Permanent Teeth. Oral surgery, oral medicine, oral pathology. 1984; 85 (5): 589-599.
- 7- West J., Endodontic Update 2006. Journal of Esthetic and Restorative Dentistry. 2006; 18 (5): 280- 300.