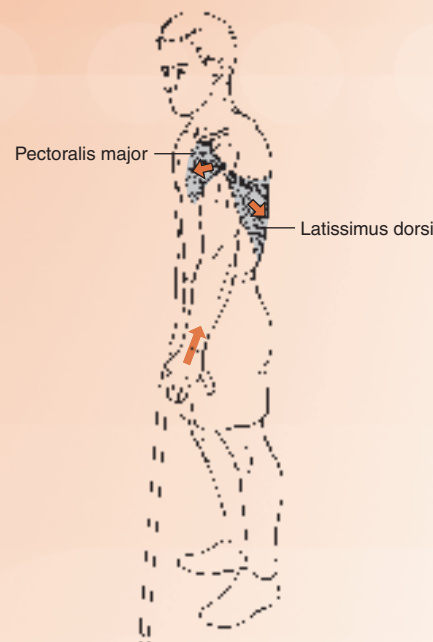


# ***Kinesiology of the Upper Extremity***



## ***UNIT 1: SHOULDER UNIT: THE SHOULDER COMPLEX***

- Chapter 8: Structure and Function of the Bones and Joints of the Shoulder Complex
- Chapter 9: Mechanics and Pathomechanics of Muscle Activity at the Shoulder Complex
- Chapter 10: Analysis of the Forces on the Shoulder Complex during Activity

## ***UNIT 2: ELBOW UNIT***

- Chapter 11: Structure and Function of the Bones and Noncontractile Elements of the Elbow
- Chapter 12: Mechanics and Pathomechanics of Muscle Activity at the Elbow
- Chapter 13: Analysis of the Forces at the Elbow during Activity

## ***UNIT 3: WRIST AND HAND UNIT***

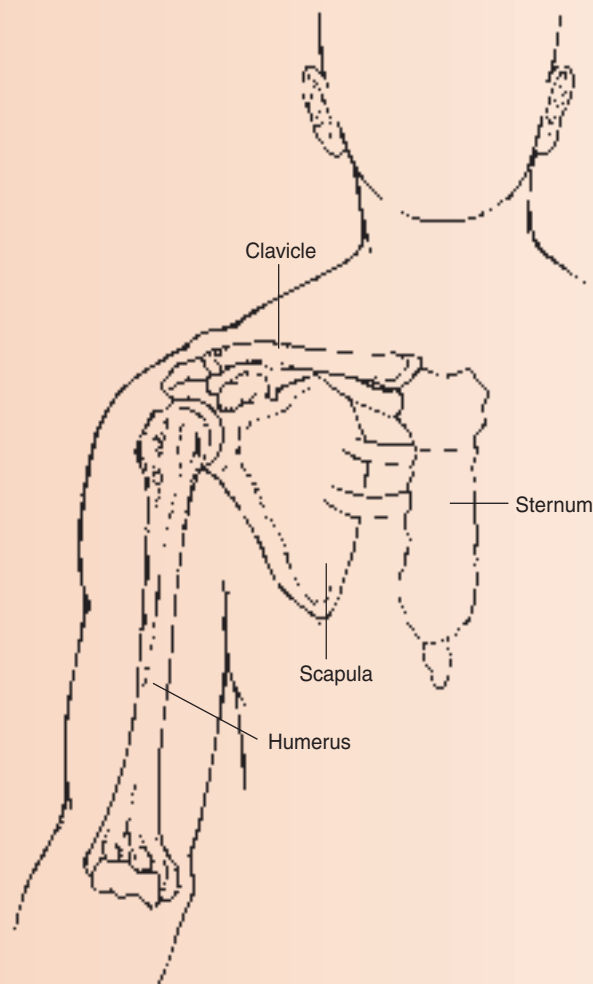
- Chapter 14: Structure and Function of the Bones and Joints of the Wrist and Hand
- Chapter 15: Mechanics and Pathomechanics of the Muscles of the Forearm
- Chapter 16: Analysis of the Forces at the Wrist during Activity
- Chapter 17: Mechanics and Pathomechanics of the Special Connective Tissues in the Hand
- Chapter 18: Mechanics and Pathomechanics of the Intrinsic Muscles of the Hand
- Chapter 19: Mechanics and Pathomechanics of Pinch and Grasp

## UNIT 1

## SHOULDER UNIT: THE SHOULDER COMPLEX

**T**he shoulder complex is the functional unit that results in movement of the arm with respect to the trunk. This unit consists of the clavicle, scapula, and humerus; the articulations linking them; and the muscles that move them. These structures are so functionally interrelated to one another that studying their individual functions is almost impossible. However, a careful study of the structures that compose the shoulder unit reveals an elegantly simple system of bones, joints, and muscles that together allow the shoulder an almost infinite number of movements (Figure). An important source of patients' complaints of pain and dysfunction at the shoulder complex is an interruption of the normal coordination of these interdependent structures.

The primary function of the shoulder complex is to position the upper extremity in space to allow the hand to perform its tasks. The wonder of the shoulder complex is the spectrum of positions that it can achieve; yet this very mobility is the source of great risk to the shoulder complex as well. Joint instability is another important source of patients' complaints of shoulder dysfunction. Thus an understanding of the function and dysfunction of the shoulder complex requires an understanding of the coordinated interplay among the individual components of the shoulder complex as well as an appreciation of the structural compromises found in the shoulder that allow tremendous mobility yet provide sufficient stability.



The shoulder complex. The shoulder complex consists of the humerus, clavicle, and scapula and includes the sternoclavicular, acromioclavicular, glenohumeral, and scapulothoracic joints.

**UNIT 1*****SHOULDER UNIT: THE SHOULDER COMPLEX***

This three-chapter unit on the shoulder complex describes the structure of the shoulder complex and its implications for function and dysfunction. The purposes of this unit are to

- Provide the clinician with an understanding of the morphology of the individual components of the complex
- Identify the functional relationships among the individual components
- Discuss how the structures of the shoulder complex contribute to mobility and stability
- Provide insight into the stresses that the shoulder complex sustains during daily activity

The unit is divided into three chapters. The first chapter presents the bony structures making up the shoulder complex and the articulations that join them. The second chapter presents the muscles of the shoulders and their contributions to function and dysfunction. The third chapter investigates the loads to which the shoulder complex and its individual components are subjected during daily activity.

## CHAPTER

## 8

# Structure and Function of the Bones and Joints of the Shoulder Complex

## CHAPTER CONTENTS

STRUCTURE OF THE BONES OF THE SHOULDER COMPLEX .....	121
Clavicle .....	121
Scapula .....	121
Proximal Humerus .....	125
Sternum and Thorax .....	126
STRUCTURE OF THE JOINTS AND SUPPORTING STRUCTURES OF THE SHOULDER COMPLEX .....	127
Sternoclavicular Joint .....	127
Acromioclavicular Joint .....	130
Scapulothoracic Joint .....	133
Glenohumeral Joint .....	135
TOTAL SHOULDER MOVEMENT .....	140
Movement of the Scapula and Humerus during Arm–Trunk Elevation .....	141
Sternoclavicular and Acromioclavicular Motion during Arm–Trunk Elevation .....	142
Impairments in Individual Joints and Their Effects on Shoulder Motion .....	143
SHOULDER RANGE OF MOTION .....	146
SUMMARY .....	146

**T**his chapter describes the structure of the bones and joints of the shoulder complex as it relates to the function of the shoulder. The specific purposes of this chapter are to

- Describe the structures of the individual bones that constitute the shoulder complex
- Describe the articulations joining the bony elements
- Discuss the factors contributing to stability and instability at each joint
- Discuss the relative contributions of each articulation to the overall motion of the shoulder complex
- Review the literature's description of normal range of motion (ROM) of the shoulder
- Discuss the implications of abnormal motion at an individual articulation to the overall motion of the shoulder complex

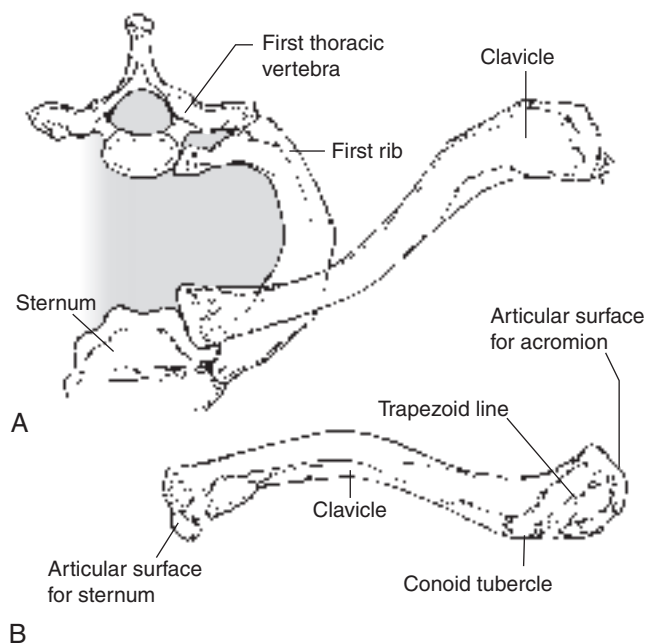
## STRUCTURE OF THE BONES OF THE SHOULDER COMPLEX

The shoulder complex consists of three individual bones: the clavicle, the scapula, and the humerus. Each of these bones is discussed in detail below. However, the complex itself is connected to the axiskeleton via the sternum and rests on the thorax, whose shape exerts some influence on the function of the entire complex. Therefore, a brief discussion of the sternum and the shape of the thorax as it relates to the shoulder complex is also presented.

### Clavicle

The clavicle functions like a strut to hold the shoulder complex and, indeed, the entire upper extremity suspended on the axiskeleton [84]. Other functions attributed to the clavicle are to provide a site for muscle attachment, to protect underlying nerves and blood vessels, to contribute to increased ROM of the shoulder, and to help transmit muscle force to the scapula [52,69]. This section describes the details of the clavicle that contribute to its ability to perform each of these functions. How these characteristics contribute to the functions of the clavicle and how they are implicated in injuries to the clavicle are discussed in later sections of this chapter.

The clavicle lies with its long axis close to the transverse plane. It is a crank-shaped bone when viewed from above, with its medial two thirds convex anteriorly, approximately conforming to the anterior thorax, and its lateral one third convex posteriorly (*Fig. 8.1*). The functional significance of this unusual shape becomes apparent in the discussion of overall shoulder motion.



**Figure 8.1:** Clavicle. **A.** View of the superior surface. **B.** View of the inferior surface.

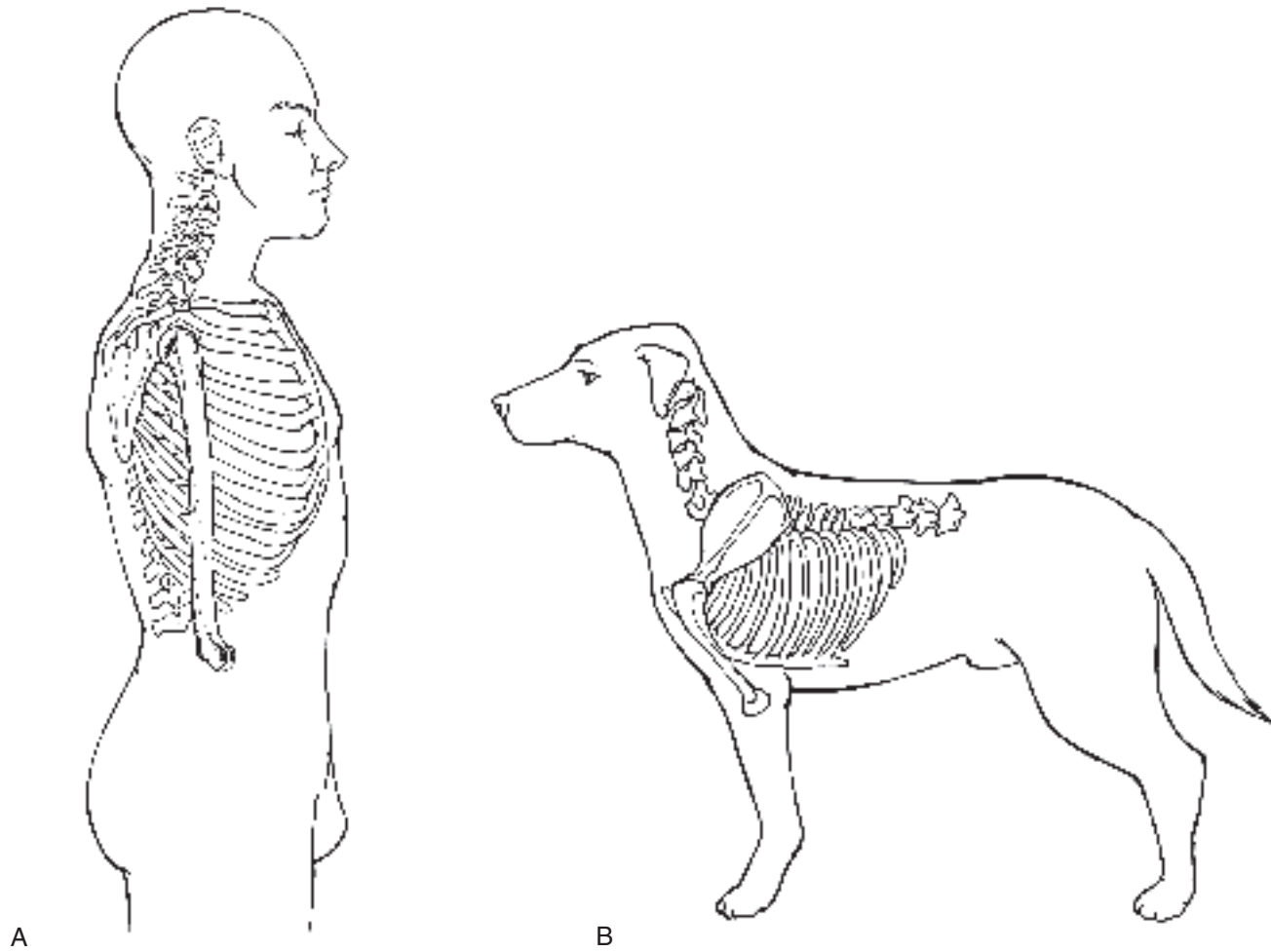
The superior surface of the clavicle is smooth and readily palpated under the skin. Anteriorly, the surface is roughened by the attachments of the pectoralis major medially and the deltoid laterally. The posterior surface is roughened on the lateral one third by the attachment of the upper trapezius. Inferiorly, the surface is roughened medially by attachments of the costoclavicular ligament and the subclavius muscle and laterally by the coracoclavicular ligament. The latter produces two prominent markings on the inferior surface of the lateral aspect of the clavicle, the conoid tubercle and, lateral to it, the trapezoid line.

The medial and lateral ends of the clavicle provide articular surfaces for the sternum and acromion, respectively. The medial aspect of the clavicle expands to form the head of the clavicle. The medial surface of this expansion articulates with the sternum and intervening articular disc, or meniscus, as well as with the first costal cartilage. The articular surface of the clavicular head is concave in the anterior posterior direction and slightly convex in the superior inferior direction [93,101]. Unlike most synovial joints, the articular surface of the mature clavicle is covered by thick fibrocartilage. The lateral one third of the clavicle is flattened with respect to the other two thirds and ends in a broad flat expansion that articulates with the acromion at the acromioclavicular joint. The actual articular surface is a small facet typically facing inferiorly and laterally. It too is covered by fibrocartilage rather than hyaline cartilage. The medial and lateral aspects of the clavicle are easily palpated.

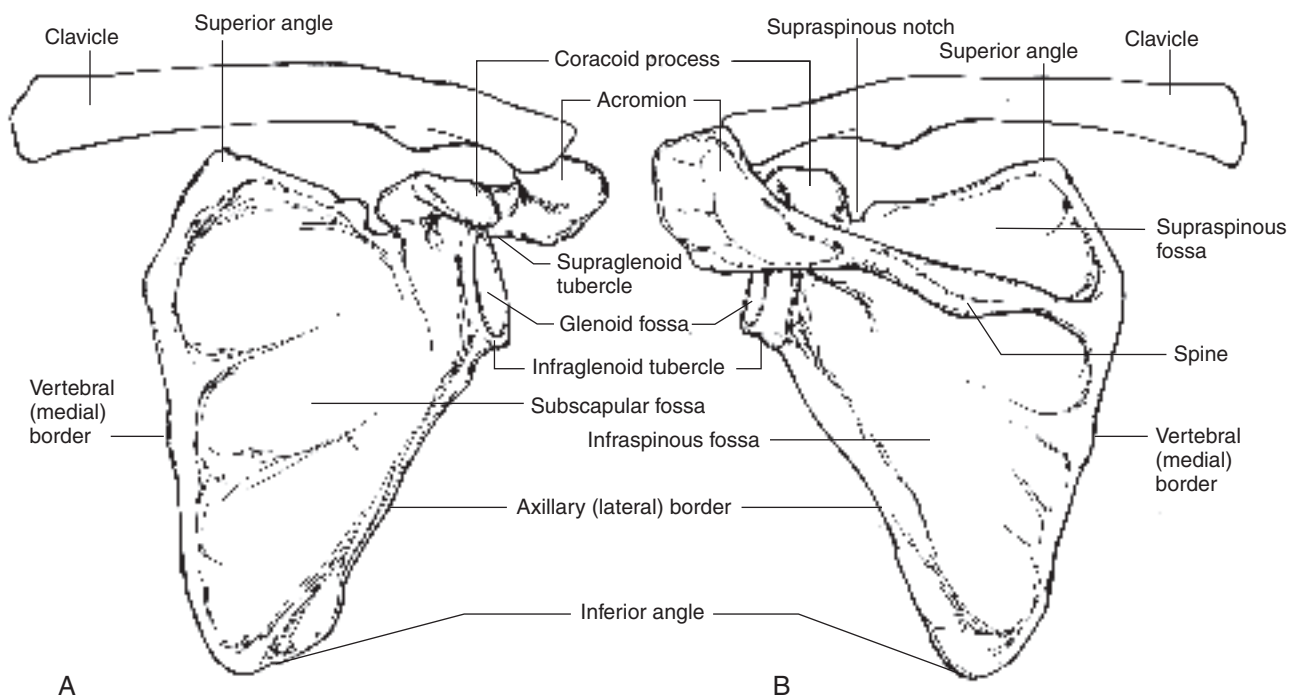
### Scapula

The scapula is a flat bone whose primary function is to provide a site for muscle attachment for the shoulder. A total of 15 major muscles acting at the shoulder attach to the scapula [58,101]. In quadrupedal animals, the scapula is long and thin and rests on the lateral aspect of the thorax. In primates, there is a gradual mediolateral expansion of the bone along with a gradual migration from a position lateral on the thorax to a more posterior location (*Fig. 8.2*). The mediolateral expansion is largely the result of an increased infraspinous fossa and costal surface that provide attachment for three of the four rotator cuff muscles as well as several other muscles of the shoulder [40,83]. These changes in structure and location of the scapula reflect the gradual change in the function of the upper extremity from its weight-bearing function to one of reaching and grasping. These alterations in function require a change in the role of muscles that now must position and support a scapula and glenohumeral joint that are no longer primarily weight bearing and instead are free to move through a much larger excursion.

The scapula has two surfaces, its costal, or anterior, surface and the dorsal, or posterior surface (*Fig. 8.3*). The costal surface is generally smooth and provides proximal attachment for the subscapularis muscle. Along the medial border of the anterior surface, a smooth narrow surface gives rise to the serratus anterior muscle.



**Figure 8.2:** Location of the scapula. **A.** In humans the scapula is located more posteriorly. **B.** The scapula is located on the lateral aspect of the thorax in quadrupedal animals.



**Figure 8.3:** Scapula. **A.** Anterior surface. **B.** Posterior surface.

The dorsal surface of the scapula is divided into two regions by the spine of the scapula, a small superior space called the supraspinous fossa and a large inferior space known as the infraspinous fossa. The spine is a large dorsally protruding ridge of bone that runs from the medial border of the scapula laterally and superiorly across the width of the scapula. The spine ends in a large, flat surface that projects laterally, anteriorly, and somewhat superiorly. This process is known as the acromion process. The acromion provides a roof over the head of the humerus. The acromion has an articular facet for the clavicle on the anterior aspect of its medial surface. Like the clavicular surface with which it articulates, this articular surface is covered by fibrocartilage rather than hyaline cartilage. This facet faces medially and somewhat superiorly. The acromion is generally described as flat. However Bigliani et al. describe various shapes of the acromion including flat, rounded, and hooked processes [4]. These authors suggest that the hooked variety of acromion process may contribute to shoulder impingement syndromes. Additional factors contributing to impingement syndromes are discussed throughout this chapter.

The scapula has three borders: the medial or vertebral border, the lateral or axillary border, and the superior border. The medial border is easily palpated along its length from inferior to superior. The medial border bends anteriorly from the root of the spine to the superior angle, thus conforming to the contours of the underlying thorax. It joins the superior border at the superior angle of the scapula that can be palpated only in individuals with small, or atrophied, muscles covering the superior angle, particularly the trapezius and levator scapulae.

Projecting from the anterior surface of the superior border of the scapula is the coracoid process, a fingerlike projection protruding superiorly then anteriorly and laterally from the scapula. It is located approximately two thirds of the width of the scapula from its medial border. The coracoid process is readily palpated inferior to the lateral one third of the clavicle on the anterior aspect of the trunk. Just medial to the base of the coracoid process on the superior border is the supraspinous notch through which travels the suprascapular nerve.

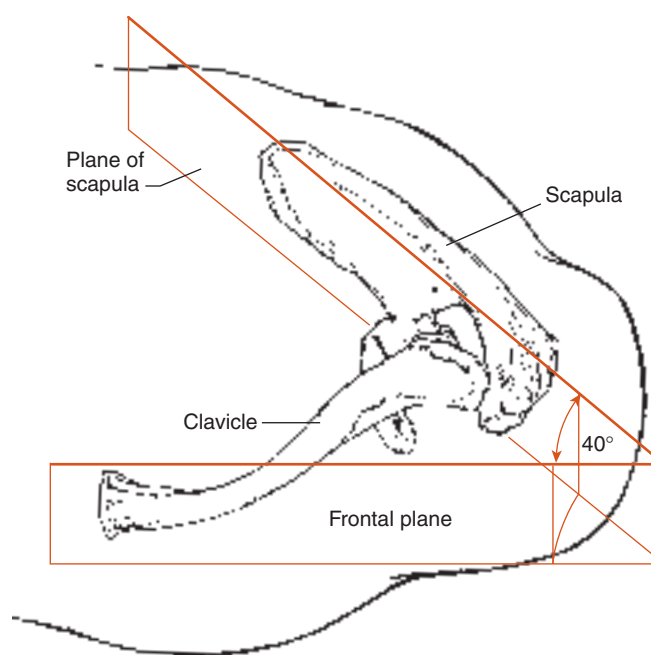
The medial border of the scapula joins the lateral border at the inferior angle, an important and easily identified landmark. The lateral border of the scapula is palpable along its inferior portion until it is covered by the teres major, teres minor, and latissimus dorsi muscles. The lateral border continues superiorly and joins the superior border at the anterior angle or head and neck of the scapula. The head gives rise to the glenoid fossa that provides the scapula's articular surface for the glenohumeral joint. The fossa is somewhat narrow superiorly and widens inferiorly resulting in a "pear-shaped" appearance. The depth of the fossa is increased by the surrounding fibrocartilaginous labrum. Superior and inferior to the fossa are the supraglenoid and infraglenoid tubercles, respectively.

The orientation of the glenoid fossa itself is somewhat controversial. Its orientation is described as

- Lateral [2]
- Superior [2]
- Inferior [80]
- Anterior [2,84]
- Retroverted [85]

Only the lateral orientation of the glenoid fossa appears uncontested. Although the differences in the literature may reflect real differences in measurement or in the populations studied, at least some of the variation is due to differences in reference frames used by the various investigators to describe the scapula's position. The reference frames used include one imbedded in the scapula itself and one imbedded in the whole body. The scapula-fixed reference frame allows comparison of the position of one bony landmark of the scapula to another landmark on the scapula. The latter body-fixed reference frame allows comparison of the position of a scapular landmark to other regions of the body.

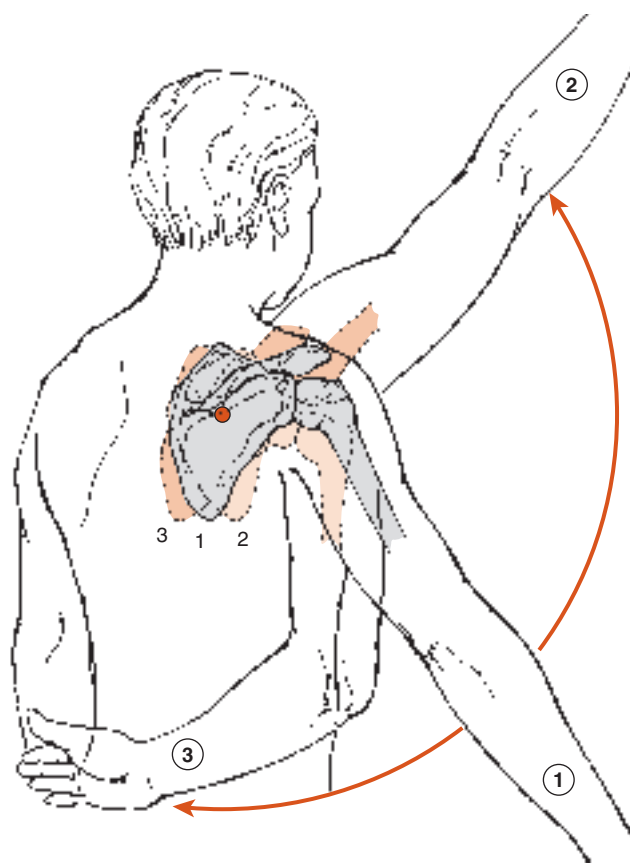
To understand the controversies regarding the orientation of the glenoid fossa, it is useful to first consider the orientation of the scapula as a whole. Using a body-fixed reference frame, the normal resting position of the scapula can be described in relationship to the sagittal, frontal, and transverse planes. In a transverse plane view, the scapula is rotated inwardly about a vertical axis. The **plane of the scapula** is oriented approximately 30–45° from the frontal plane (Fig. 8.4) [46,86]. This position directs the glenoid anteriorly with respect to the body. However, a scapula-fixed reference frame reveals that the glenoid fossa is retroverted, or rotated posteriorly, with respect to the neck of the scapula [14,85].



**Figure 8.4:** Plane of the scapula. A transverse view of the scapula reveals that the plane of the scapula forms an angle of approximately 40° with the frontal plane.

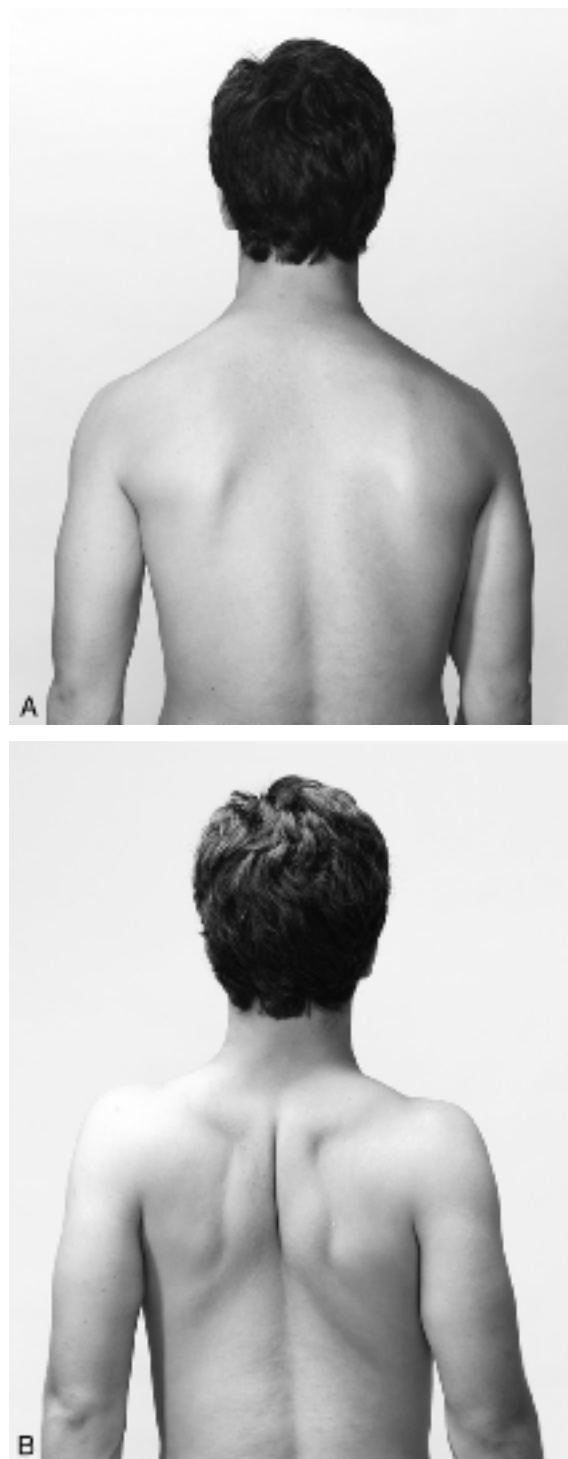
Thus the glenoid fossa is directed anteriorly (with respect to the body) and at the same time is retroverted (with respect to the scapula).

Rotation of the scapula in the frontal plane about a body-fixed anterior–posterior (AP) axis is also described (*Fig. 8.5*). This frontal plane rotation of the scapula is described by either the upward or downward orientation of the glenoid fossa or by the medial or lateral location of the scapula's inferior angle [2,25,80]. A rotation about this AP axis that tips the glenoid fossa inferiorly, moving the inferior angle of the scapula medially (i.e., closer to the vertebral column), is described as **downward** or **medial rotation** of the scapula. A rotation that tilts the glenoid fossa upward, moving the inferior angle laterally away from the vertebral column, is **upward** or **lateral rotation**. Two investigations report that the glenoid fossa is upwardly inclined in quiet standing [2,61]. Two other studies report a downward inclination of approximately 5° [25,80]. The posture of the studies' subjects may help to explain these reported differences. Perhaps subjects who demonstrate an upward inclination are instructed to pull their shoulders back into an "erect" posture while those who have a downward inclination of the glenoid fossa have slightly drooping



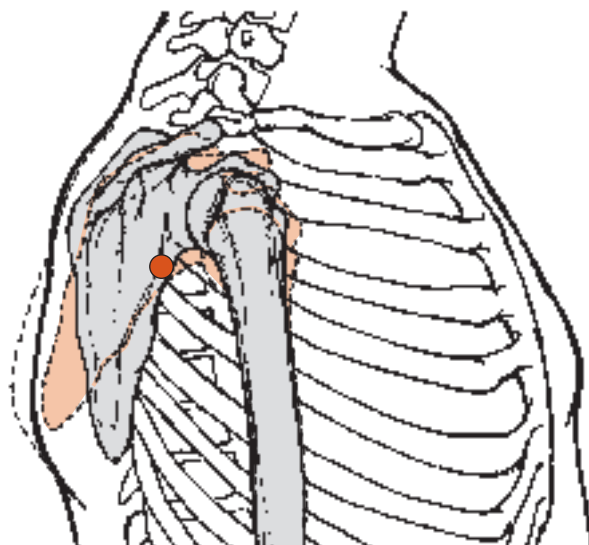
**Figure 8.5:** Scapular rotation. Rotation of the scapula about an anterior–posterior (AP) axis causes the glenoid fossa to face upward (2) or downward (3).

shoulders (*Fig. 8.6*). A final determination of the normal orientation of the scapulae in the frontal plane requires an accepted definition of normal postural alignment of the shoulder. That definition unfortunately is presently



**Figure 8.6:** Postural changes of the scapula. **A.** This individual is standing with drooping, or rounded, shoulders, and the scapulae are rotated so that the glenoid fossa tilts downward. **B.** This individual stands with the shoulders pulled back and the scapulae tilted upward.





**Figure 8.7:** Scapular rotation. Rotation of the scapula about a ML axis tilts the scapula anteriorly and posteriorly.

lacking. Therefore, the controversy regarding the orientation of the scapula and its glenoid fossa in the frontal plane continues.

Viewed sagittally, the scapula tilts forward from the frontal plane approximately  $10^\circ$  about a medial lateral axis (Fig. 8.7) [17]. This forward tilting is partly the result of the scapula's position on the superior thorax, which tapers toward its apex. Additional forward tilt of the scapula causes the inferior angle of the scapula to protrude from the thorax.

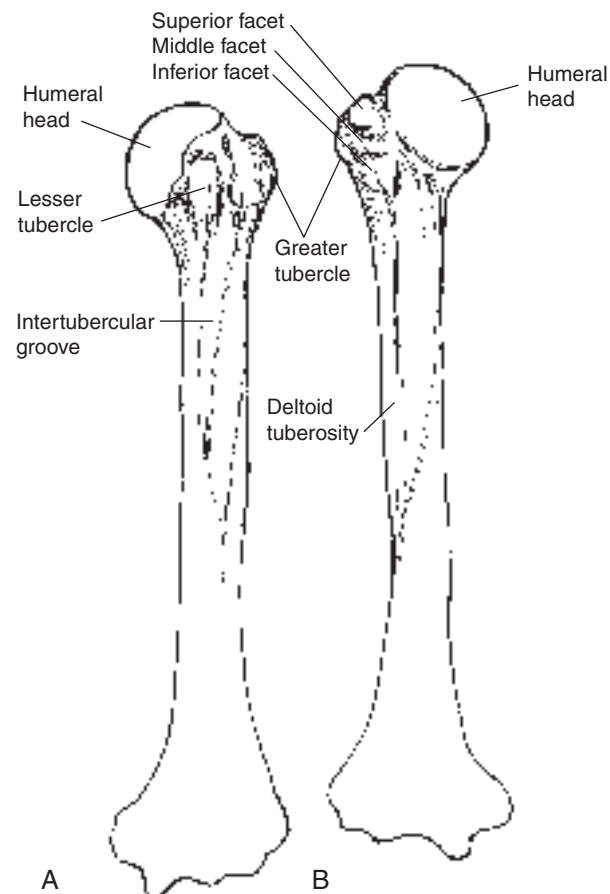
### Clinical Relevance

#### SCAPULAR POSITION IN SHOULDER DYSFUNCTION:

*Abnormal scapular positions have been implicated in several forms of shoulder dysfunction. Abnormal orientation of the glenoid fossa has been associated with instability of the glenohumeral joint [2,85,91]. In addition, excessive anterior tilting is found in individuals with shoulder impingement syndromes during active shoulder abduction [61]. Careful evaluation of scapular position is an essential component of a thorough examination of patients with shoulder dysfunction.*

### Proximal Humerus

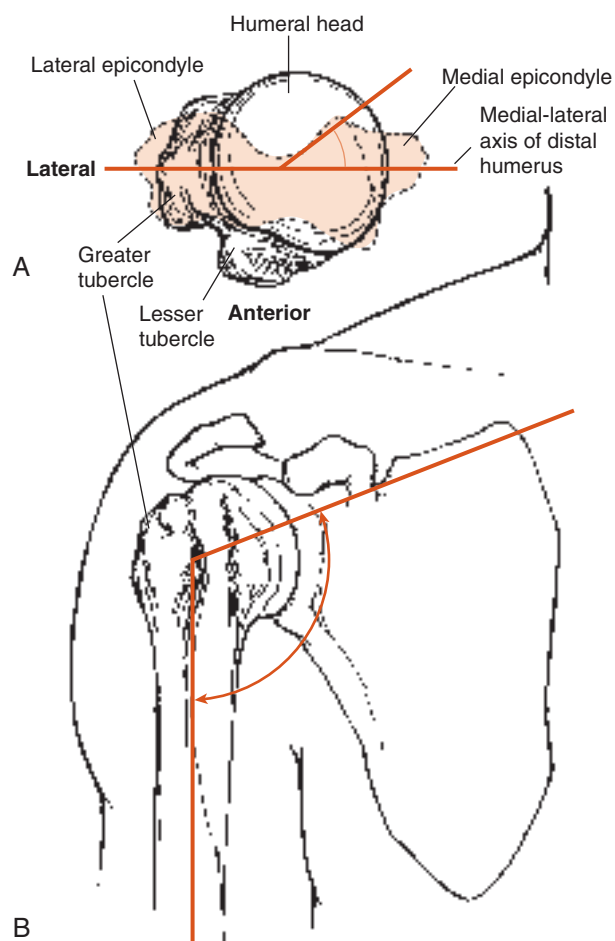
The humerus is a long bone composed of a head, neck, and body, or shaft. The body ends distally in the capitulum and trochlea. This chapter presents only those portions of the humerus that are relevant to a discussion of the mechanics and pathomechanics of the shoulder complex. The rest of the



**Figure 8.8:** Proximal humerus. A. Anterior view. B. Posterior view.

humerus is discussed in Chapter 11 with the elbow. The articular surface of the head of the humerus is most often described as approximately half of an almost perfect sphere (Fig. 8.8) [39,89,99,101]. The humeral head projects medially, superiorly, and posteriorly with respect to the plane formed by the medial and lateral condyles (Fig. 8.9) [40]. The humeral head ends in the anatomical neck marking the end of the articular surface.

On the lateral aspect of the proximal humerus is the greater tubercle, a large bony prominence that is easily palpated on the lateral aspect of the shoulder complex. The greater tubercle is marked by three distinct facets on its superior and posterior surfaces. These facets give rise from superior to posterior to the supraspinatus, infraspinatus, and teres minor muscles, respectively. On the anterior aspect of the proximal humerus is a smaller but still prominent bony projection, the lesser tubercle. It too has a facet that provides attachment for the remaining rotator cuff muscle, the subscapularis. Separating the tubercles is the intertubercular, or bicipital, groove containing the tendon of the long head of the biceps brachii. The greater and lesser tubercles continue onto the body of the humerus as the medial and lateral lips of the groove. The surgical neck is a slight narrowing of the shaft of the humerus just distal to the tubercles.



**Figure 8.9:** Orientation of the head of the humerus. **A.** In the transverse plane, the humeral head is rotated posteriorly with respect to the condyles of the distal humerus. **B.** In the frontal plane, the head of the humerus is angled medially and superiorly with respect to the shaft of the humerus.

### Clinical Relevance

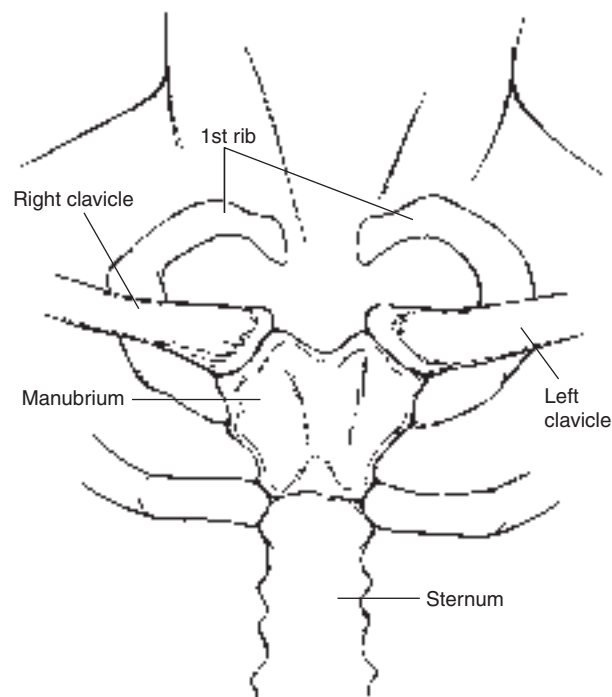
**THE DEPTH OF THE BICIPITAL GROOVE:** *The depth of the bicipital groove varies. A shallow groove appears to be a contributing factor in dislocations of the biceps tendon [56,58].*

Approximately midway distally on the body of the humerus is the deltoid tuberosity on the anterolateral surface. It provides the distal attachment for the deltoid muscle. The spiral groove is another important landmark on the body of the humerus. It is found on the proximal half of the humerus, spiraling from proximal to distal and medial to lateral on the posterior surface. The radial nerve travels in the spiral groove along with the profunda brachii vessels. The radial nerve is particularly susceptible to injury as it lies in the spiral groove.

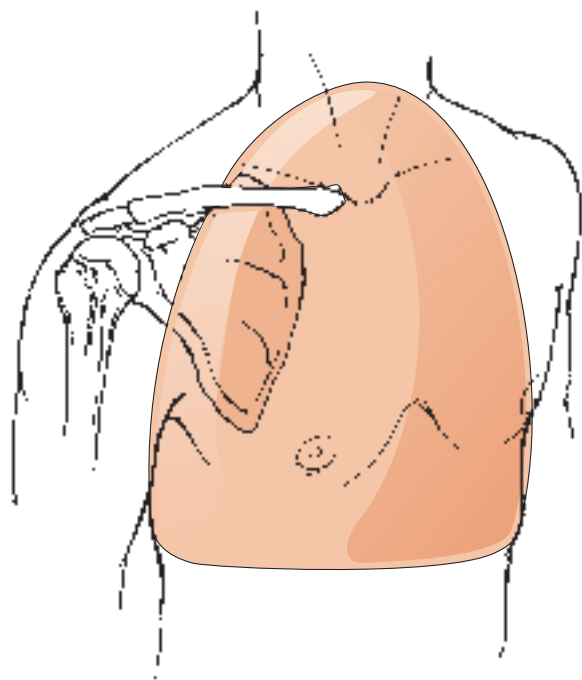
### Sternum and Thorax

Although the sternum and thorax are not part of the shoulder complex, both are intimately related to the shoulder; therefore, a brief description of their structure as it relates to the shoulder complex is required. Both the sternum and thorax are covered in greater detail in Chapter 29. The superior portion of the sternum, the manubrium, provides an articular surface for the proximal end of each clavicle (*Fig. 8.10*). The articular surface is a shallow depression called the clavicular notch covered with fibrocartilage like the clavicular head with which it articulates. Each notch provides considerably less articular surface than the clavicular head that articulates with it. The two clavicular notches are separated by the sternal or jugular notch on the superior aspect of the manubrium. This notch is very prominent and is a useful landmark for identifying the sternoclavicular joints. Another reliable and useful landmark is the angle formed by the junction of the manubrium with the body of the sternum, known as the sternal angle, or angle of Louis. This is also the site of the attachment of the second costal cartilage to the manubrium and body of the sternum.

The bony thorax forms the substrate on which the two scapulae slide. Consequently, the shape of the thorax serves as a constraint to the movements of the scapulae [97]. Each scapula rides on the superior portion of the thorax, positioned in the upright posture approximately from the first through the eighth ribs and from the vertebral bodies of about T2 to T7 or T8. The medial aspect of the spine of the scapula is



**Figure 8.10:** The sternum's articular surface. The sternum provides a shallow articular surface for the head of the clavicle.



**Figure 8.11:** Shape of the thorax. The elliptical shape of the thorax influences the motion of the scapula.

typically described as in line with the spinous process of T2. The inferior angle is usually reported to be in line with the spinous process of T7. It is important to recognize, however, that postural alignment of the shoulder and vertebral column can alter these relationships significantly.

The dorsal surface of the thorax in the region of the scapulae is characterized by its convex shape, known as a thoracic kyphosis. The superior ribs are smaller than the inferior ones, so the overall shape of the thorax can be described as ellipsoid (*Fig. 8.11*) [99]. Thus as the scapula glides superiorly on the thorax it also tilts anteriorly. An awareness of the shape of the thorax on which the scapula glides helps to explain the resting position of the scapula and the motions of the scapula caused by contractions of certain muscles such as the rhomboids and pectoralis minor [17,49].

In conclusion, as stated at the beginning of this chapter, the shoulder complex is an intricate arrangement of three specific bones, each of which is unique. These three bones are also functionally and structurally related to parts of the axioskeleton (i.e., to the sternum and the thorax). A clear image of each bone and its position relative to the others is



essential to a complete and accurate physical examination. The palpable bony landmarks relevant to the shoulder complex are listed below:

- Sternal notch
- Sternal angle
- Second rib
- Head of the clavicle
- Sternoclavicular joint

- Superior surface of the clavicle
- Anterior surface of the clavicle
- Acromion
- Acromioclavicular joint
- Coracoid process
- Vertebral border of the scapula
- Spine of the scapula
- Inferior angle of the scapula
- Axillary border of the scapula
- Greater tubercle of the humerus
- Lesser tubercle of the humerus
- Intertubercular groove of the humerus

The following section describes the structure and mechanics of the joints of the shoulder complex formed by these bony components.

### STRUCTURE OF THE JOINTS AND SUPPORTING STRUCTURES OF THE SHOULDER COMPLEX

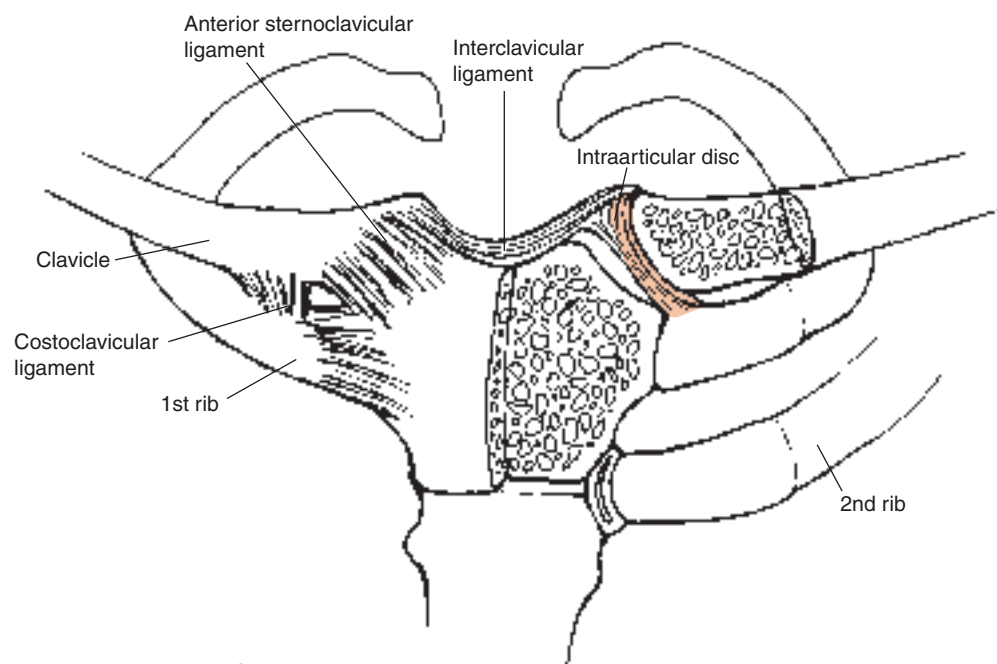
The shoulder complex is composed of four joints:

- Sternoclavicular
- Acromioclavicular
- Scapulothoracic
- Glenohumeral

All but the scapulothoracic joint are synovial joints. The scapulothoracic joint falls outside any traditional category of joint because the moving components, the scapula and the thorax, are not directly attached or articulated to one another and because muscles rather than cartilage or fibrous material separate the moving components. However, it is the site of systematic and repeated motion between bones and thus justifiably can be designated a joint. This section presents the structure and mechanics of each of the four joints of the shoulder complex.

#### Sternoclavicular Joint

The sternoclavicular joint is described by some as a ball-and-socket joint [84] and by others as a saddle joint [93,101]. Since both types of joints are triaxial, there is little functional significance to the distinction. The sternoclavicular joint actually includes the clavicle, sternum, and superior aspect of the first costal cartilage (*Fig. 8.12*). It is enclosed by a synovial capsule that attaches to the sternum and clavicle just beyond the articular surfaces. The capsule is relatively weak inferiorly but is reinforced anteriorly, posteriorly, and superiorly by accessory ligaments that are thickenings of the capsule itself. The anterior and posterior ligaments are known as the anterior and posterior sternoclavicular ligaments. These ligaments serve to limit anterior and posterior glide of the sternoclavicular joint. They also provide some limits to the joint's normal transverse plane movement, known as *protraction* and *retraction*.

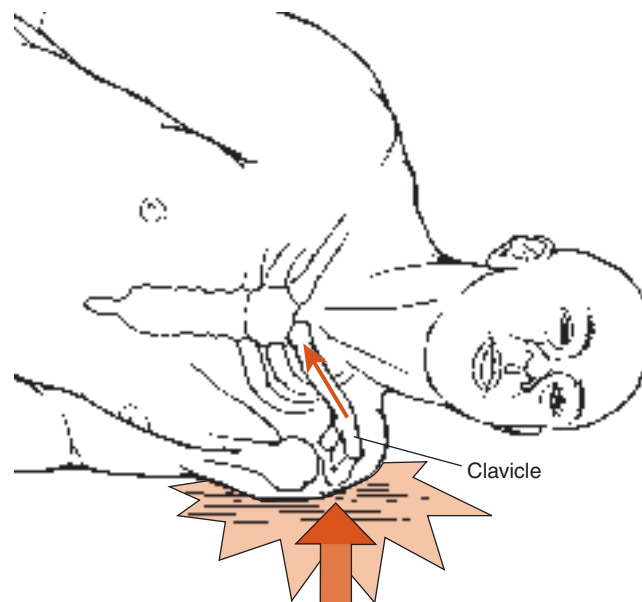


**Figure 8.12:** The sternoclavicular joint. The supporting structures of the sternoclavicular joint include the capsule, the intraarticular disc, the anterior and posterior sternoclavicular ligaments, the interclavicular ligament, and the costoclavicular ligament.

The superior thickening of the joint capsule comes from the interclavicular ligament, a thick fibrous band extending from one sternoclavicular joint to the other and covering the floor of the sternal notch. This ligament helps prevent superior and lateral displacements of the clavicle on the sternum. The capsule with its ligamentous thickenings is described as the strongest limiter of excessive motion at the sternoclavicular joint [3].

The capsule and ligaments described so far are the primary limiters of anterior, posterior, and lateral movements. However, other structures provide additional limits to medial translation and elevation of the clavicle. As noted in the descriptions of the bones, the articular surface of the clavicle is considerably larger than the respective surface on the sternum. Consequently, the superior aspect of the clavicular head projects superiorly over the sternum and is easily palpated. This disparity between the articular surfaces results in an inherent joint instability that allows the clavicle to slide medially over the sternum. Such migration can be precipitated by a medially directed force on the clavicle, such as those that arise from a blow to, or a fall on, the shoulder (*Fig. 8.13*). An intraarticular disc interposed between the clavicle and sternum increases the articular surface on which the clavicle moves and also serves to block any medial movement of the clavicle. The disc is attached inferiorly to the superior aspect of the first costal cartilage and superiorly to the superior border of the clavicle's articular surface dividing the joint into two separate synovial cavities. The specific attachments of the disc help it prevent medial migration of the clavicle over the sternum. A blow to the lateral aspect of the shoulder applies a

medial force on the clavicle, tending to push it medially on the sternum. The clavicle is anchored to the underlying first costal cartilage by the intraarticular disc resisting any medial movement of the clavicle. However a cadaver study suggests that the disc can be torn easily from its attachment on the costal cartilage [3]. Therefore, the magnitude of its role as a



**Figure 8.13:** Forces that tend to move the clavicle medially. A fall on the lateral aspect of the shoulder produces a force on the clavicle, tending to push it medially.

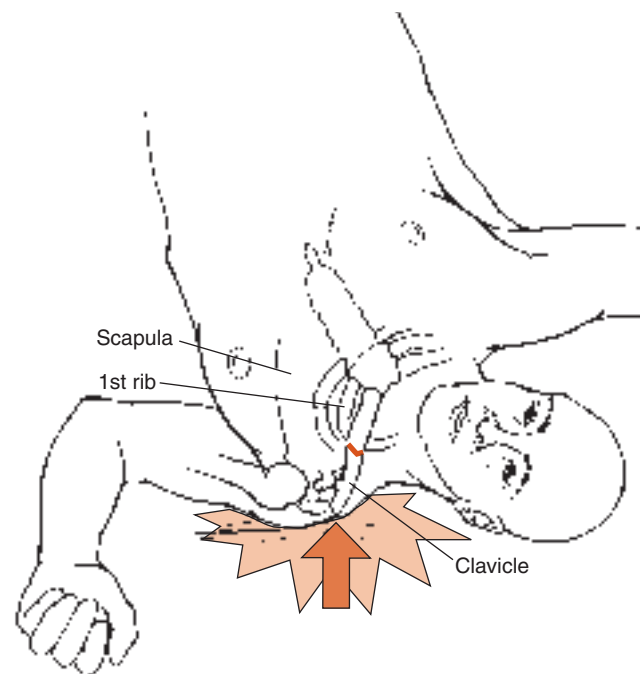
stabilizer of the sternoclavicular joint, particularly in limiting medial translation of the clavicle on the sternum, remains unclear. The disc may also serve as a shock absorber between the clavicle and sternum [50].

Another important stabilizing structure of the sternoclavicular joint is the costoclavicular ligament, an extracapsular ligament lying lateral to the joint itself. It runs from the lateral aspect of the first costal cartilage superiorly to the inferior aspect of the medial clavicle. Its anterior fibers run superiorly and laterally, while the posterior fibers run superiorly and medially. Consequently, this ligament provides significant limits to medial, lateral, anterior, and posterior movements of the clavicle as well as to elevation.

A review of the supporting structures of the sternoclavicular joint reveals that despite an inherently unstable joint surface, these supporting structures together limit medial, lateral, posterior, anterior, and superior displacements of the clavicle on the sternum. Inferior movement of the clavicle is limited by the interclavicular ligament and by the costal cartilage itself. Thus it is clear that the sternoclavicular joint is so reinforced that it is quite a stable joint [72,96].

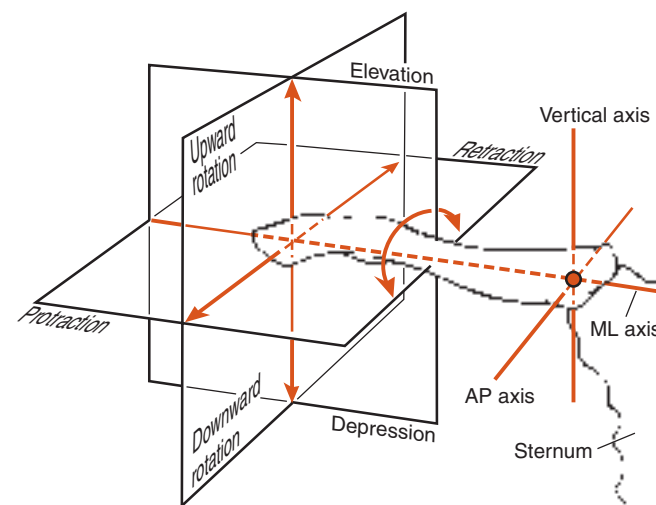
### Clinical Relevance

**FRACTURE OF THE CLAVICLE:** *The sternoclavicular joint is so well stabilized that fractures of the clavicle are considerably more common than dislocations of the sternoclavicular joint. In fact the clavicle is the bone most commonly fractured in humans [32]. Trauma to the sternoclavicular joint and clavicle most commonly occurs from forces applied to the upper extremity. Although clavicular fractures are commonly believed to occur from falls on an outstretched hand, a review of 122 cases of clavicular fractures reports that 94% of the clavicular fracture cases (115 patients) occurred by a direct blow to the shoulder [92]. Falls on the shoulder are a common culprit. As an individual falls from a bicycle, for example, turning slightly to protect the face and head, the shoulder takes the brunt of the fall. The ground exerts a force on the lateral and superior aspect of the acromion and clavicle. This force pushes the clavicle medially and inferiorly [96]. However, the sternoclavicular joint is firmly supported against such movements, so the ground reaction force tends to deform the clavicle. The first costal cartilage inferior to the clavicle is a barrier to deformation of the clavicle, and as a result, the clavicle is likely to fracture (Fig. 8.14). Usually the fracture occurs in the middle or lateral one third of the clavicle, the former more frequently than the latter [32]. The exact mechanism of fracture is unclear. Some suggest that it is a fracture resulting from bending, while others suggest it is a direct compression fracture [32,92]. Regardless of the mechanism, it is clear that fractures of the clavicle are more common than sternoclavicular joint dislocations, partially because of the firm stabilization provided by the disc and ligaments of the sternoclavicular joint [15,96].*



**Figure 8.14:** A typical way to fracture the clavicle. A fall on the top of the shoulder produces a downward force on the clavicle, pushing it down onto the first rib. The first rib prevents depression of the medial aspect of the clavicle, but the force of the fall continues to depress the lateral portion of the clavicle, resulting in a fracture in the middle third of the clavicle.

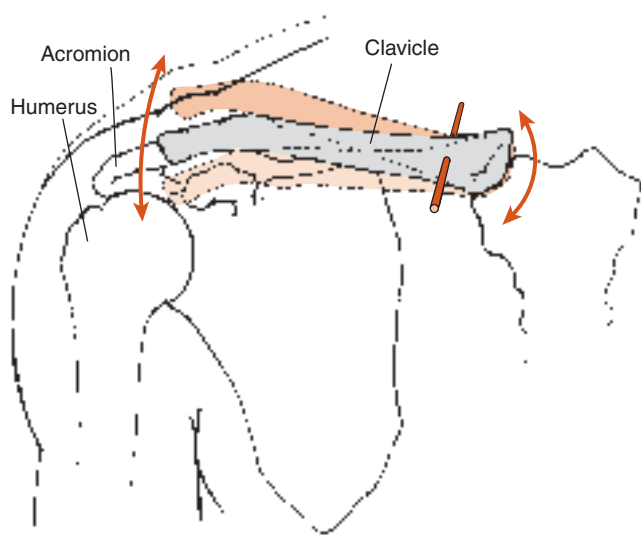
Whether regarded as a saddle or ball-and-socket joint, motion at the sternoclavicular joint occurs about three axes, an anterior–posterior (AP), a vertical superior–inferior (SI), and a longitudinal (ML) axis through the length of the clavicle (Fig 8.15). Although these axes are described as slightly



**Figure 8.15:** Axes of motion of the sternoclavicular joint. **A.** Elevation and depression of the sternoclavicular joint occur about an anterior–posterior axis. **B.** Protraction and retraction of the sternoclavicular joint occur about a vertical axis. **C.** Upward and downward rotation of the sternoclavicular joint occur about a medial–lateral axis.

oblique to the cardinal planes of the body [93], the motions of the clavicle take place very close to these planes. Movement about the AP axis yields **elevation** and **depression**, which occur approximately in the frontal plane. Movements about the SI axis are known as **protraction** and **retraction** and occur in the transverse plane. Rotations around the longitudinal axis are **upward (posterior)** and **downward (anterior)** **rotation**, defined by whether the anterior surface of the clavicle turns up (upward rotation) or down (downward rotation).

Although movement at the sternoclavicular joint is rotational, the prominence of the clavicular head and the location of the joint's axes allow easy palpation of the head of the clavicle during most of these motions. This palpation frequently results in confusion for the novice clinician. Note that retraction of the clavicle causes the head of the clavicle to move anteriorly on the sternum as the body of the clavicle rotates posteriorly (*Fig. 8.16*). Similarly in protraction the clavicular head rolls posteriorly as the body moves anteriorly. Likewise in elevation the body of the clavicle and the acromion rise, but the head of the clavicle descends on the sternum; depression of the sternoclavicular joint is the reverse. These movements of the proximal and distal clavicular surfaces in opposite directions are consistent with rotations of the sternoclavicular joint and are the result of the location of the axes within the clavicle itself. The exact location of the axes about which the movements of the sternoclavicular joint occur are debated, but probably the axes lie somewhat lateral to the head of the clavicle [3,82]. This location explains the movement of the lateral and medial ends of the clavicle in apparently opposite directions. With the axes of motion located between the two ends of the clavicle, pure rotation results in opposite movements of the two ends, just



**Figure 8.16:** Movement of the head of the clavicle. Rotation of the sternoclavicular joint about an axis causes the head of the clavicle to move in a direction opposite the motion of the rest of the clavicle just as the two ends of a seesaw move in opposite directions about a central pivot point.

as the two ends of a seesaw move in opposite directions during pure rotation about the pivot point.

Few studies are available that investigate the available ROM of the sternoclavicular joint. The total excursion of elevation and depression is reportedly 50 to 60°, with depression being less than 10° of the total [69,93]. Elevation is limited by the costoclavicular ligament, and depression by the superior portion of the capsule and the interclavicular ligament [3,93]. Some suggest that contact between the clavicle and the first rib also limits depression of the sternoclavicular joint [82]. Facets found in some cadaver specimens between the clavicle and first costal cartilage provide strong evidence for contact between these structures in at least some individuals [3,82].

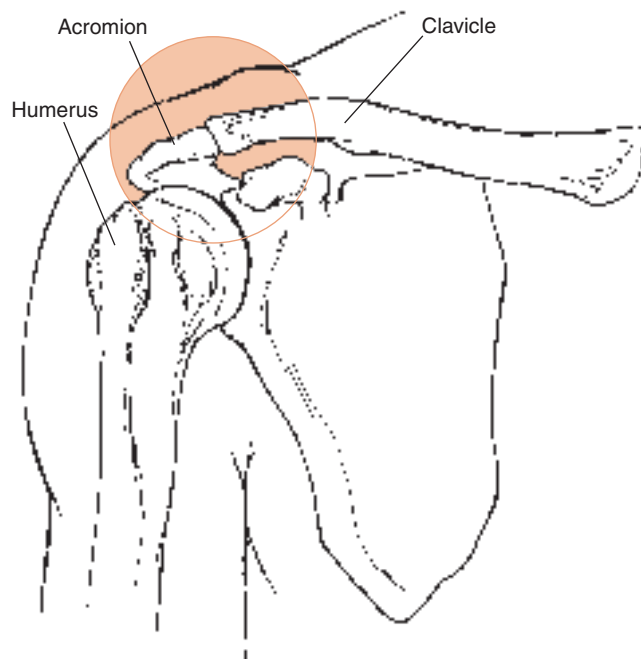
Protraction and retraction appear to be more equal in excursion, with a reported total excursion ranging from 30 to 60° [82,93]. Protraction is limited by the posterior sternoclavicular ligament limiting the backward movement of the clavicular head and by the costoclavicular ligament limiting the forward movement of the body of the clavicle. Retraction is limited similarly by the anterior sternoclavicular ligament and by the costoclavicular ligament. The interclavicular ligament assists in limiting both motions [3].

Upward and downward rotations appear to be more limited than the other motions, with estimates of upward rotation ROM that vary from 25 to 55° [3,40,82]. Although there are no known studies of downward rotation ROM, it appears to be much less than upward rotation, probably less than 10°. Regardless of the exact amount of excursion available at the sternoclavicular joint, it is well understood that motion at the sternoclavicular joint is intimately related to motions of the other joints of the shoulder complex. How these motions are related is discussed after each joint is presented.

## Acromioclavicular Joint

The acromioclavicular joint is generally regarded as a gliding joint with flat articular surfaces, although the surfaces are sometimes described as reciprocally concave and convex [93,101] (*Fig. 8.17*). Both articular surfaces are covered by fibrocartilage rather than hyaline cartilage. The joint is supported by a capsule that is reinforced superiorly and inferiorly by acromioclavicular ligaments (*Fig. 8.18*). Although the capsule is frequently described as weak, the acromioclavicular ligaments may provide the primary support to the joint in instances of small displacements and low loads [26,55]. In addition, the acromioclavicular ligaments appear to provide important limitations to posterior glide of the acromioclavicular joint regardless of the magnitude of displacement or load [26]. The inferior acromioclavicular ligament also may provide substantial resistance to excessive anterior displacement of the clavicle on the scapula [55]. The joint also possesses an intraarticular meniscus that is usually less than a whole disc and provides no known additional support.

The other major support to the acromioclavicular ligament is the extracapsular coracoclavicular ligament that runs from the base of the coracoid process to the inferior surface of the



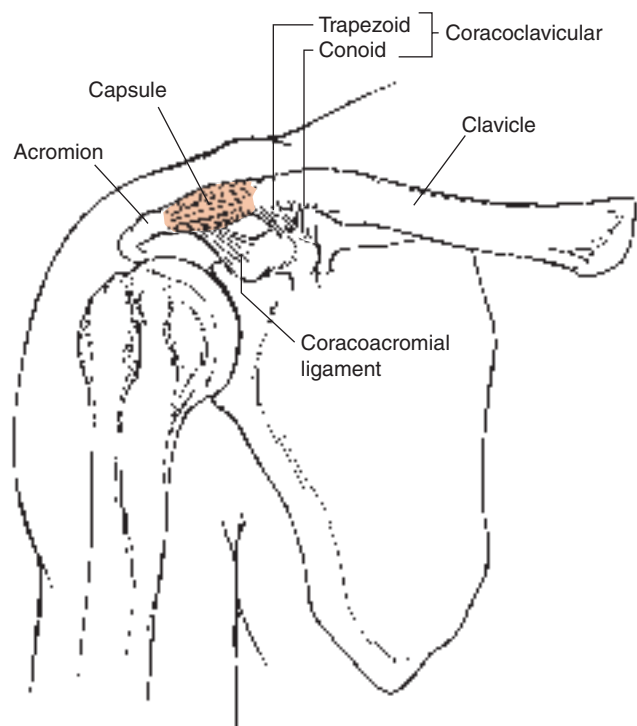
**Figure 8.17:** The articular surfaces of the acromioclavicular joint are relatively flattened and beveled with respect to one another.

clavicle. This ligament provides critical support to the acromioclavicular joint, particularly against large excursions and medial displacements [26,55]. It is regarded by many as the primary suspensory ligament of the shoulder complex. Mechanical tests reveal that it is substantially stiffer than the

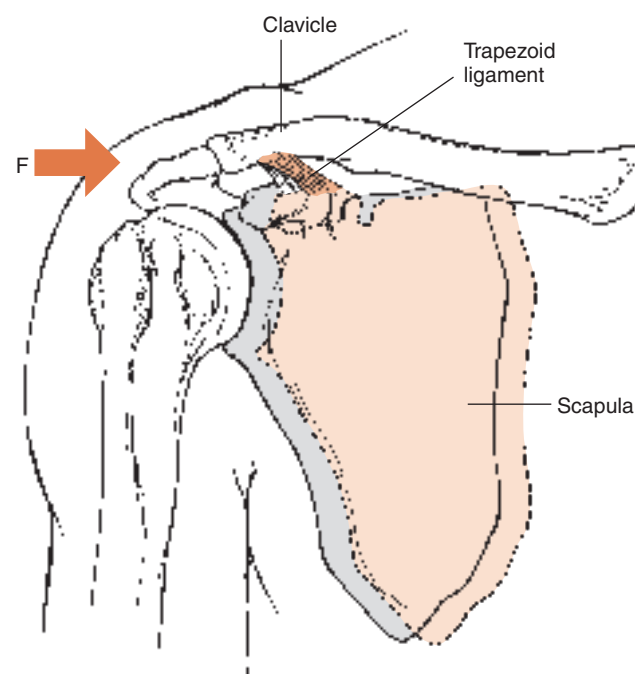
acromioclavicular, coracoacromial, and superior glenohumeral ligaments [13].

It is curious that a ligament that does not even cross the joint directly can be so important in providing stability. An understanding of the precise orientation of the ligament helps explain its role in stabilizing the joint. The ligament is composed of two parts, the conoid ligament that runs vertically from the coracoid process to the conoid tubercle on the clavicle and the trapezoid ligament that runs vertically and laterally to the trapezoid line. The vertically aligned portion, the conoid ligament, reportedly limits excessive superior glides at the acromioclavicular joint. The acromioclavicular ligaments purportedly limit smaller superior displacements [26,55].

The more obliquely aligned trapezoid ligament protects against the shearing forces that can drive the acromion inferiorly and medially under the clavicle. Such forces can arise from a fall on the shoulder or a blow to the shoulder. The shape of the articular surfaces of the acromioclavicular joint causes it to be particularly prone to such displacements. As stated earlier, the articular facet of the clavicle faces laterally and inferiorly, while that of the acromion faces medially and superiorly. These surfaces give the acromioclavicular joint a beveled appearance that allows medial displacement of the acromion underneath the clavicle. Medial displacement of the acromion results in simultaneous displacement of the coracoid process, since it is part of the same scapula. Examination of the trapezoid ligament shows that it is aligned to block the medial translation of the coracoid process, thus helping to keep the clavicle with the scapula and preventing dislocation (*Fig. 8.19*) [82]. Dislocation of the acromioclavicular



**Figure 8.18:** Acromioclavicular joint. The acromioclavicular joint is supported by the capsule, acromioclavicular ligaments, and the coracoclavicular ligament.



**Figure 8.19:** Trapezoid ligament. The trapezoid ligament helps prevent medial displacement of the acromion under the clavicle during a medial blow to the shoulder.

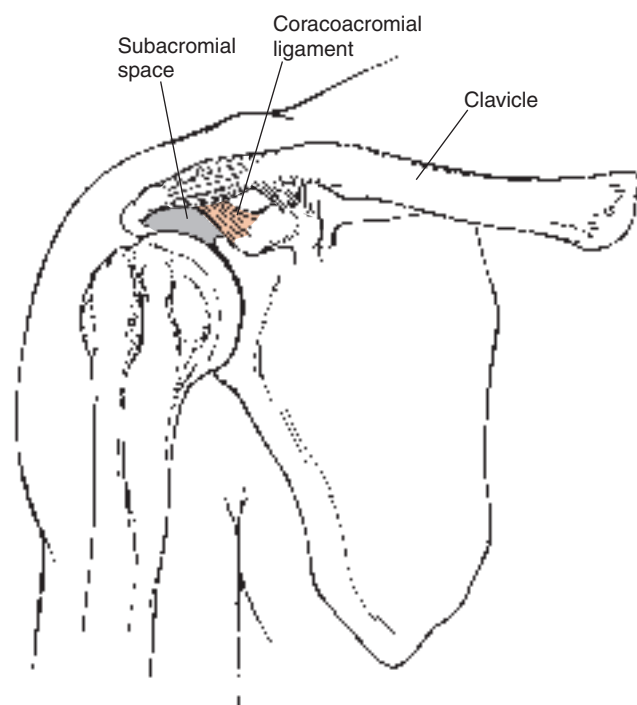
joint can be accompanied by disruption of the coracoclavicular ligament and by fractures of the coracoid process.

### Clinical Relevance

#### DISLOCATION OF THE ACROMIOCLAVICULAR JOINT:

Dislocation of the acromioclavicular (AC) joint is a common sports injury, especially in contact sports such as football and rugby. The mechanism is similar to that of clavicular fractures, a blow to or fall on the shoulder. Because of the strength of the coracoclavicular ligament, dislocation of the AC joint often occurs with a fracture of the coracoid process (Type III dislocation) instead of a disruption of the ligament itself.

The coracoacromial ligament is another unusual ligament associated with the acromioclavicular joint. It is unusual because it crosses no joint. Instead it forms a roof over the glenohumeral joint by attaching from one landmark to another landmark on the scapula (Fig. 8.20). This ligament provides protection for the underlying bursa and supraspinatus tendon. It also provides a limit to the superior gliding of the humerus in a very unstable glenohumeral joint [58]. The coracoacromial ligament also is implicated as a factor in impingement of the structures underlying it and is thicker in some shoulders with rotator cuff tears. The question remains whether the thickening is a response to contact with the

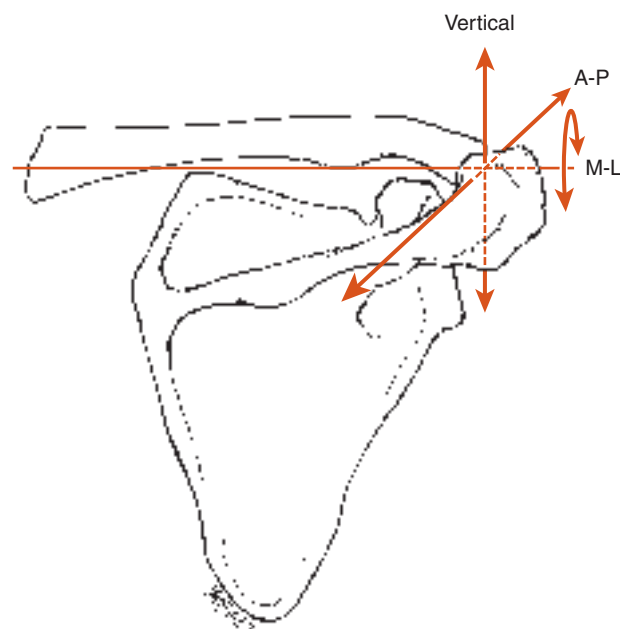


**Figure 8.20:** Coracoacromial ligament. The coracoacromial ligament forms a roof over the humeral head and helps create the subacromial space.

unstable humerus resulting from the disrupted rotator cuff or whether the thickening is itself a predisposing factor for rotator cuff tears [88]. Additional research is needed to clarify the relationship between the morphology of the coracoacromial ligament and the integrity of the rotator cuff muscles.

Few studies report objective measurements of the excursions of the acromioclavicular joint. Sahara et al. report total translations of approximately 4 mm in the anterior and posterior directions and approximately 2 mm in inferior/superior directions during shoulder movement [87].

Although gliding joints allow only translational movements, many authors describe rotational movement about specific axes of motion at the acromioclavicular joint [17,82,101]. The axes commonly described are vertical, AP, and medial/lateral (ML) (Fig. 8.21). The vertical axis allows motion of the scapula that brings the scapula closer to, or farther from, the clavicle in the transverse plane. Motion about the AP axis results in enlarging or shrinking the angle formed by the clavicle and spine of the scapula in the frontal plane. Motion about the ML axis tips the superior border of the scapula toward the clavicle or away from it. Direct measurements of angular excursions vary and range from less than 10° to 20° about individual axes [40,82]. Using a screw axis (a single axis that describes the total rotation and translation), Sahara et al. report a total of 35° of rotation with full shoulder abduction [87]. These studies suggest that the acromioclavicular joint allows significant motion between the scapula and clavicle.



**Figure 8.21:** Axes of motion of the acromioclavicular joint. Motion about a vertical axis of the acromioclavicular joint moves the scapula in the transverse plane. Motion about an anterior–posterior (AP) axis turns the glenoid fossa upward and downward. Motion about a medial–lateral (ML) axis tilts the scapula anteriorly and posteriorly.



Viewed in the context of the shoulder complex, the acromioclavicular joint is responsible for maintaining articulation of the clavicle with the scapula, even as these two bones move in separate patterns. Whether this results in systematic rotational motions or in a gliding reorientation of the bones is not critical to the clinician, since in either case the motions cannot be readily measured. What is essential is the recognition that although the clavicle and scapula move together, their contributions to whole shoulder motion require that they also move somewhat independently of one another. This independent movement requires motion at the acromioclavicular joint.

### Clinical Relevance

#### OSTEOARTHRITIS OF THE ACROMIOCLAVICULAR

**JOINT:** *The acromioclavicular joint is a common site of osteoarthritis particularly in individuals who have a history of heavy labor or athletic activities. The normal mobility of the joint helps explain why pain and lost mobility in it from arthritic changes can produce significant loss of shoulder mobility and function.*

### Scapulothoracic Joint

The scapulothoracic joint, as stated earlier, is an atypical joint that lacks all of the traditional characteristics of a joint except one, motion. The primary role of this joint is to amplify the motion of the glenohumeral joint, thus increasing the range and diversity of movements between the arm and trunk. In addition, the scapulothoracic joint with its surrounding musculature is described as an important shock absorber protecting the shoulder, particularly during falls on an outstretched arm [50].

Primary motions of the scapulothoracic joint include two translations and three rotations (Fig. 8.22). Those motions are

- Elevation and depression
- Abduction and adduction
- Downward (medial) and upward (lateral) rotations
- Internal and external rotations
- Scapular tilt

**Elevation** is defined as the movement of the entire scapula superiorly on the thorax. **Depression** is the opposite. **Abduction** is defined as the entire medial border of the scapula moving away from the vertebrae, and **adduction** as movement toward the vertebrae. Abduction and adduction of the scapulothoracic joint are occasionally referred to as protraction and retraction. However, protraction also is used by some to refer to the combination of abduction and upward rotation of the scapula. Others use the term protraction to refer to a rounded shoulder posture that may include abduction and downward rotation of the scapula. Therefore to avoid confusion, this text describes scapular movements discretely as elevation and depression, abduction and adduction, and upward and downward rotation. *Protraction* and *retraction*

refer solely to the motions of the sternoclavicular joint in the transverse plane.

**Downward (medial) rotation** of the scapula is defined as a rotation about an AP axis resulting in downward turn of the glenoid fossa as the inferior angle moves toward the vertebrae. **Upward (lateral) rotation** is the opposite. The location of the axis of downward and upward rotation is controversial but appears to be slightly inferior to the scapular spine, approximately equidistant from the vertebral and axillary borders [97]. It is likely that the exact location of the axis varies with ROM of the shoulder.

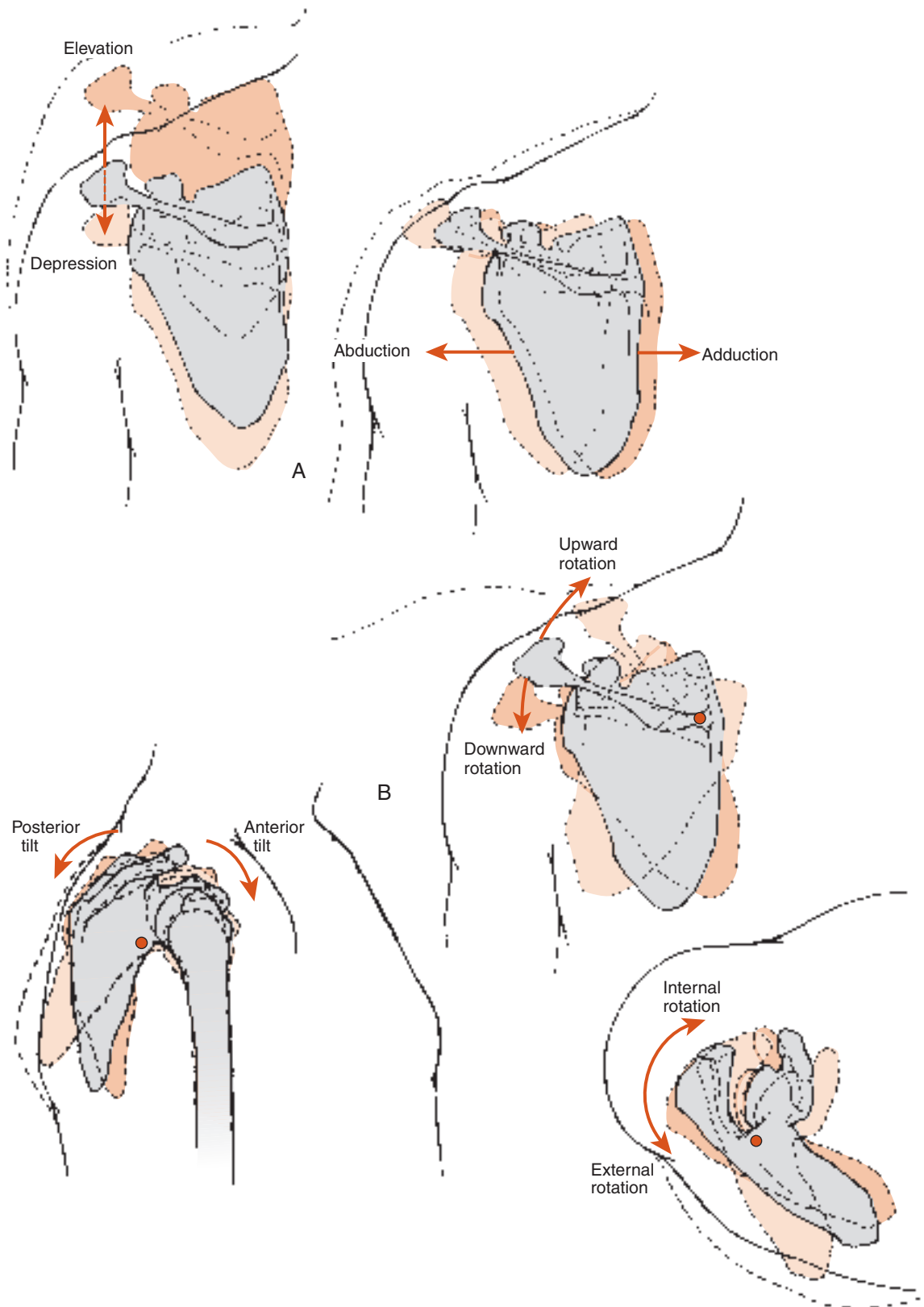
Internal and external rotations of the scapula occur about a vertical axis. Internal rotation turns the axillary border of the scapula more anteriorly, and external rotation turns the border more posteriorly. The shape of the thorax can enhance this motion. As the scapula translates laterally on the thorax in scapular abduction, the scapula rotates internally. Conversely, as the scapula adducts, it tends to rotate externally.

Anterior and posterior tilt of the scapula occur about a ML axis. Anterior tilt moves the superior portion of the scapula anteriorly while moving the inferior angle of the scapula posteriorly. Posterior tilt reverses the motion. Again, the shape of the thorax can enhance these motions. As the scapula elevates it tends to tilt anteriorly, and as it depresses it tends to tilt posteriorly (Fig. 8.23).

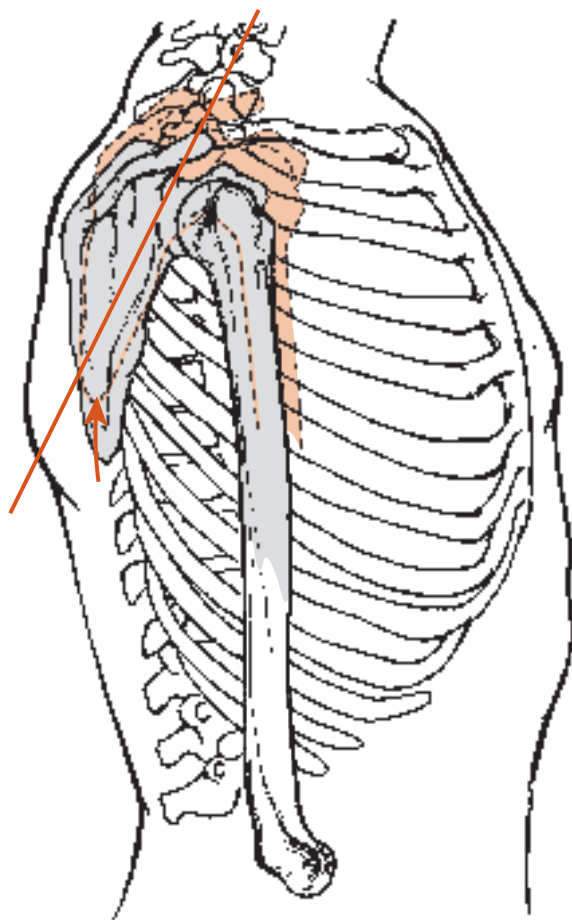
The motions of the scapulothoracic joint depend upon the motions of the sternoclavicular and acromioclavicular joints and under normal conditions occur through movements at both of these joints. For example, elevation of the scapulothoracic joint occurs with elevation of the sternoclavicular joint. Therefore, an important limiting factor for scapulothoracic elevation excursion is sternoclavicular ROM. Similarly, limits to scapulothoracic abduction and adduction as well as rotation include the available motions at the sternoclavicular and acromioclavicular joints. Tightness of the muscles of the scapulothoracic joint—particularly the trapezius, serratus anterior, and rhomboid muscles—may limit excursion of the scapula. The specific effects of individual muscle tightness are discussed in Chapter 9.

Although excursion of the scapulothoracic joint is not typically measured in the clinic and few studies exist that have investigated the normal movement available at this joint, it is useful to have an idea of the magnitude of excursion possible at the scapulothoracic joint. Excursions of 2–10 cm of scapular elevation and no more than 2 cm of depression are found in the literature [46,50]. Ranges of up to 10 cm are reported for abduction and 4–5 cm for adduction [46,50].

Upward rotation of the scapula is more thoroughly investigated than other motions of the scapulothoracic joint. The joint allows at least 60° of upward rotation of the scapula, but the full excursion depends upon the sternoclavicular joint elevation and acromioclavicular joint excursion available [40,63,80]. Tightness of the muscles that downwardly rotate the scapula may prevent or limit normal excursion of the scapula as well. Downward rotation on the scapula, on the other hand, is poorly studied. There are no known studies that



**Figure 8.22:** Primary motions of the scapulothoracic joint. A. Translations. B. Rotations.



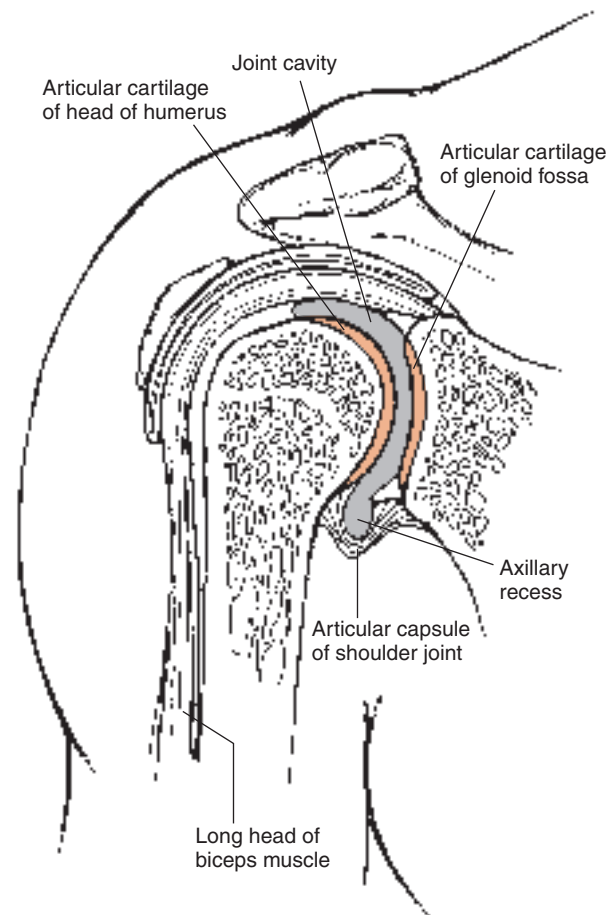
**Figure 8.23:** Scapular motion on the elliptical thorax. The shape of the thorax causes the scapula to tilt anteriorly as it elevates on the thorax.

describe its excursion. However, downward rotation is greatly reduced compared with upward rotation. Although full potential excursions are not reported, the scapula reportedly tilts posteriorly and rotates externally approximately  $30^\circ$  and  $25^\circ$ , respectively, during shoulder elevation.

### Glenohumeral Joint

Although the glenohumeral joint is frequently referred to as the *shoulder joint*, it must be emphasized that the “shoulder” is a composite of four joints, of which the glenohumeral joint is only a part, albeit a very important part. The glenohumeral joint is a classic ball-and-socket joint that is the most mobile in the human body [18]. Yet its very mobility presents serious challenges to the joint’s inherent stability. The interplay between stability and mobility of this joint is a major theme that must be kept in mind to understand the mechanics and pathomechanics of the glenohumeral joint.

The two articular surfaces, the head of the humerus and the glenoid fossa, are both spherical (*Fig. 8.24*). The curve of their surfaces is described as their **radius of curvature**. As detailed in Chapter 7, the radius of curvature quantifies the amount of curve in a surface by describing the radius of the circle from which the surface is derived. Although the bony



**Figure 8.24:** Articular surfaces of the glenohumeral joint. The humeral head and the glenoid fossa possess similar curvatures.

surfaces of the humeral head and glenoid fossa may have slightly different curvatures, their cartilaginous articular surfaces have approximately the same radius of curvature [39,89,99]. Because these surfaces have similar curvatures, they fit well together; that is, there is a high degree of congruence. Increased congruence spreads the loads applied to the joint across a larger surface area and thus reduces the stress (force/area) applied to the articular surface. However, the amount of congruence is variable, even in healthy glenohumeral joints [4]. In cadavers, decreased congruence leads to an increase in the gliding motions between the humeral head and the glenoid fossa [4,48]. Thus decreased congruence may be a contributing factor in glenohumeral joint instability.

Although the articular surfaces of the glenohumeral joint are similarly curved, the actual areas of the articular surfaces are quite different from one another. While the head of the humerus is approximately one half of a sphere, the surface area of the glenoid fossa is less than one half that of the humeral head [45,52]. This disparity in articular surface sizes has dramatic effects on both the stability and mobility of the glenohumeral joint. First, the difference in the size of the articular surfaces allows a large degree of mobility since there is no bony limitation to the excursion. The size of the articular surfaces is an important factor in making the

glenohumeral joint the most mobile in the body. However, by allowing tremendous mobility, the articular surfaces provide little or no stability for the glenohumeral joint [58]. The stability of the glenohumeral joint depends upon nonbony structures.

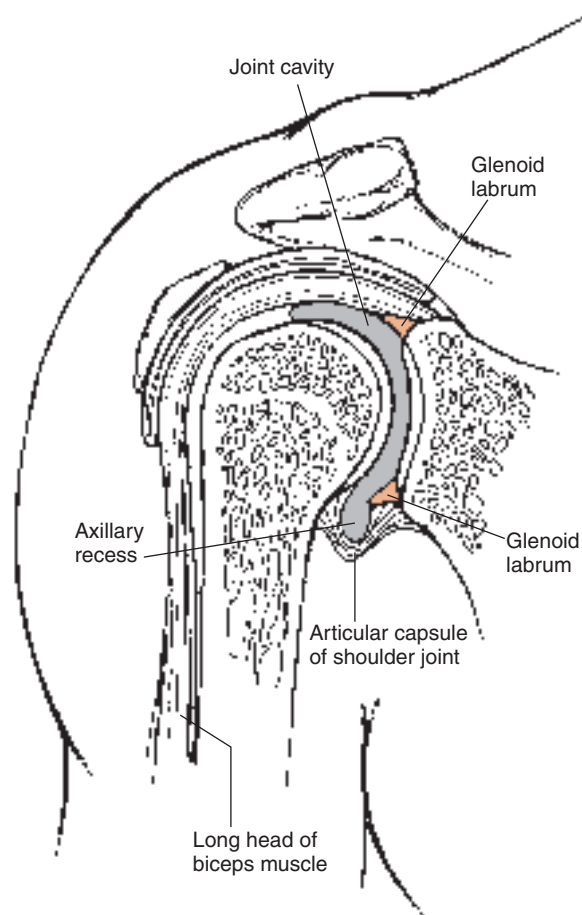
### SUPPORTING STRUCTURES OF THE GLENOHUMERAL JOINT

The supporting structures of the glenohumeral joint consist of the

- Labrum
- Capsule
- Three glenohumeral ligaments
- Coracohumeral ligament
- Surrounding musculature

The noncontractile supporting structures of the glenohumeral joint are discussed in this section. The role of muscles in supporting the joint is discussed in Chapter 9.

The shallow glenoid fossa has already been identified as a contributing factor in glenohumeral joint instability. The stability is improved by deepening the fossa with the labrum (Fig. 8.25). The labrum is a ring of fibrous tissue and fibrocartilage surrounding the periphery of the fossa, approximately doubling the depth of the articular surface of the fossa [38,70]. Besides increasing the depth of the articular surface,



**Figure 8.25:** Glenoid labrum. The glenoid labrum deepens the glenoid fossa.

the ring increases the articular contact area, which also decreases the stress (force/area) on the glenoid fossa. The labrum provides these benefits while being deformable, thereby adding little or no restriction to glenohumeral movement. Magnetic resonance imaging (MRI) shows considerable variation in the shape of the labrum in asymptomatic shoulders, including notches and separations, particularly in the anterior aspect of the ring. A small percentage of individuals lack portions of the labrum [77].

Labral tears are well described in the clinical literature [16,76]. Mechanical tests of the ring demonstrate that it is weakest anteriorly and inferiorly, which is consistent with the clinical finding that anterior tears are the most common [31]. However, the functional significance of a torn labrum in the absence of other pathology remains controversial [17,76,79]. The amount of dysfunction that results from a labral tear probably depends upon the severity of the lesion. Small tears may have little or no effect, while large tears that extend to other parts of the joint capsule produce significant instability. The normal variability of the labrum in asymptomatic shoulders lends strength to the concept that small isolated labral tears do not result in significant dysfunction. However, additional studies are needed to clarify the role of labral tears in glenohumeral dysfunction.

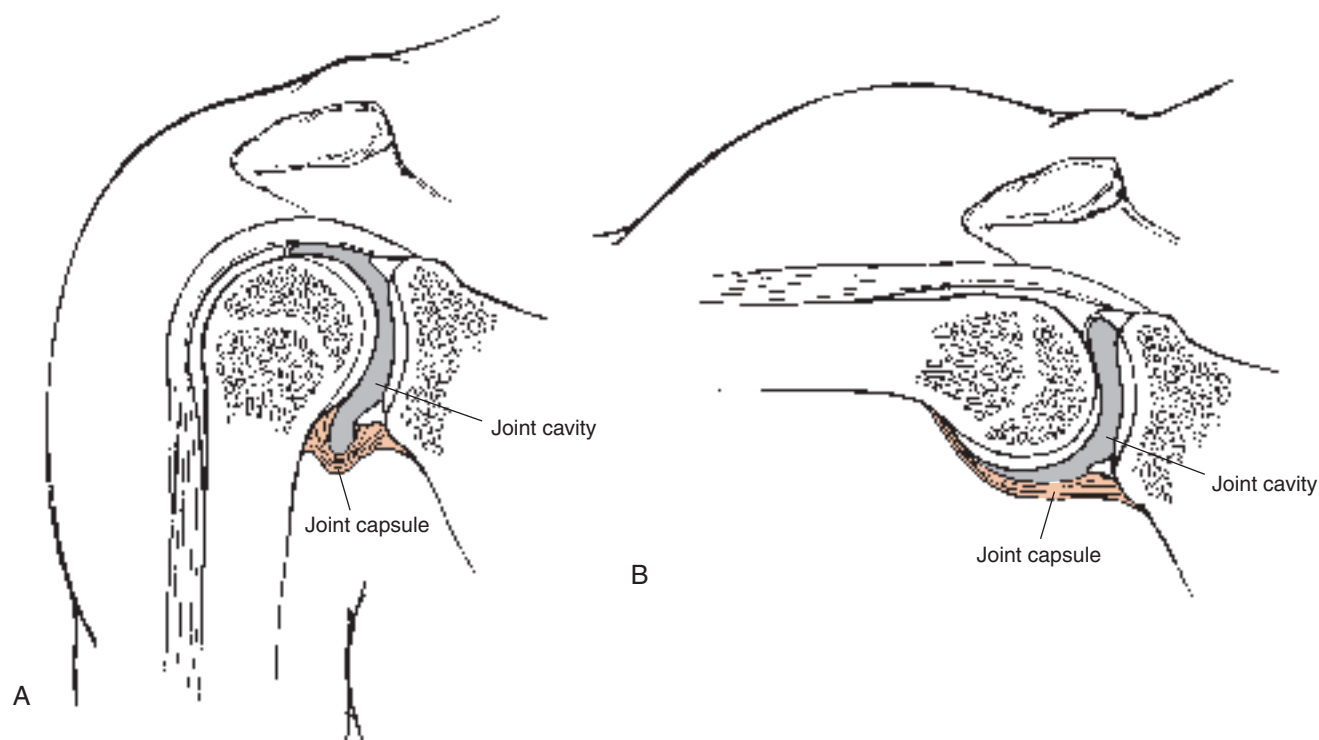
The remaining connective tissue supporting structures of the glenohumeral joint are known collectively as the **capsuloligamentous complex**. It consists of the joint capsule and reinforcing ligaments. It encircles the entire joint and provides protection against excessive rotation and translation in all directions. It is important to recognize that the integrity of the complex depends on the integrity of each of its components.

The fibrous capsule of the glenohumeral joint is intimately related to the labrum. The capsule attaches distally to the anatomical neck of the humerus and proximally to the periphery of the glenoid fossa and/or to the labrum itself. Inferiorly, it is quite loose, forming folds (Fig. 8.26). These folds must open, or unfold, as the glenohumeral joint elevates in abduction or flexion.

### Clinical Relevance

**ADHESIVE CAPSULITIS:** In adhesive capsulitis, fibrous adhesions form in the glenohumeral joint capsule. The capsule then is unable to unfold to allow full flexion or abduction, resulting in decreased joint excursion. Onset is frequently insidious, and the etiology is unknown. However, the classic physical findings are severe and painful limitations in joint ROM [30,73].

The normal capsule is quite lax and, by itself, contributes little to the stability of the glenohumeral joint. However, it is reinforced anteriorly by the three glenohumeral ligaments and superiorly by the coracohumeral ligament. It also is supported anteriorly, superiorly, and posteriorly by the rotator cuff muscles that attach to it. Only the most inferior portion of the capsule is without additional support.

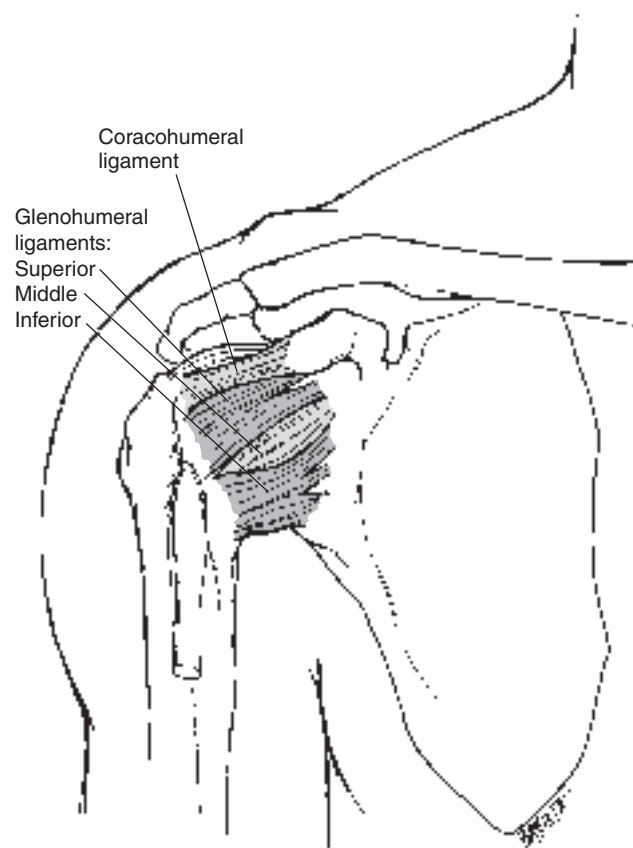


**Figure 8.26:** Glenohumeral joint capsule. **A.** When the shoulder is in neutral, the inferior portion of the capsule is lax and appears folded. **B.** In abduction the folds of the inferior capsule are unfolded, and the capsule is pulled more taut.

The three glenohumeral ligaments are thickenings of the capsule itself (*Fig. 8.27*). The superior glenohumeral ligament runs from the superior portion of the labrum and base of the coracoid process to the superior aspect of the humeral neck. The middle glenohumeral ligament has a broad attachment on the anterior aspect of the labrum inferior to the superior glenohumeral ligament and passes inferiorly and laterally, expanding as it crosses the anterior aspect of the glenohumeral joint. It attaches to the lesser tubercle deep to the tendon of the subscapularis. The superior glenohumeral ligament along with the coracohumeral ligament and the tendon of the long head of the biceps lies in the space between the tendons of the supraspinatus and subscapularis muscles. This space is known as the **rotator interval**.

The inferior glenohumeral ligament is a thick band that attaches to the anterior, posterior, and middle portions of the glenoid labrum and to the inferior and medial aspects of the neck of the humerus. The coracohumeral ligament attaches to the lateral aspect of the base of the coracoid process and to the greater tubercle of the humerus. It blends with the supraspinatus tendon and with the capsule.

These reinforcing ligaments support the glenohumeral joint by limiting excessive translation of the head of the humerus on the glenoid fossa. Tightness of these ligaments actually contributes to increased translation of the humeral head in the opposite direction [34]. The coracohumeral ligament provides protection against excessive posterior glides of the humerus on the glenoid fossa [7]. All three of the glenohumeral ligaments help to prevent anterior displacement of the humeral head on the glenoid fossa, especially when they are pulled taut by lateral



**Figure 8.27:** Glenohumeral joint. The glenohumeral joint capsule is reinforced by the superior, middle, and inferior glenohumeral ligaments. The joint is also supported by the coracohumeral ligament.

rotation of the glenohumeral joint [68]. The position of the glenohumeral joint in the frontal plane influences what parts of these ligaments are pulled taut [18]. In neutral and in moderate abduction, the superior and middle glenohumeral ligaments are pulled tight. However in more abduction, the inferior glenohumeral ligament provides most of the resistance to anterior displacement [5,37,78,81]. The three glenohumeral ligaments also limit excessive lateral rotation of the glenohumeral joint [54,75]. As with anterior displacement, increasing



abduction increases the role the inferior glenohumeral ligament plays in limiting lateral rotation [43].

Although the posterior capsule is reinforced passively only by a portion of the inferior glenohumeral ligament, it too provides resistance to excessive glide of the glenohumeral joint. The posterior capsule functions as a barrier to excessive posterior glide of the humeral head. It also limits excessive medial rotation of the joint. In certain positions of the glenohumeral joint, the anterior and posterior portions of the glenohumeral joint capsule are under tension simultaneously, demonstrating how the function of the capsule and its reinforcing ligaments is complex and interdependent [10,95].

There are opposing views regarding the support of the glenohumeral joint against inferior glide. The weight of the upper extremity in upright posture promotes inferior glide of the humeral head on the glenoid fossa. Some authors suggest that inferior glide of the humeral head is resisted by the pull of the coracohumeral ligament and to a lesser degree by the superior glenohumeral ligament, particularly when the joint is laterally rotated [18,34,42]. However, another cadaver study reports little support from the superior glenohumeral ligament against inferior subluxation [90]. This study, which suggests that the inferior glenohumeral ligament provides more support in the inferior direction, with additional support from the coracohumeral ligament, examines smaller displacements than the preceding studies. The individual contributions from these supporting structures may depend on the position of the glenohumeral joint and the magnitude of the humeral displacements. Additional research is needed to elucidate the roles the glenohumeral joint capsule and ligaments play in supporting the glenohumeral joint. Subtle changes in joint position also appear to alter the stresses applied to the capsuloligamentous complex.

## Clinical Relevance

### EXAMINING OR STRETCHING THE GLENOHUMERAL JOINT LIGAMENTS:

*Altering the position of the glenohumeral joint allows the clinician to selectively assess specific portions of the glenohumeral capsuloligamentous complex. For example, lateral rotation of the glenohumeral joint reduces the amount of anterior translation of the humeral head by several millimeters. If the clinician assesses anterior glide of the humeral head with the joint laterally rotated and does not observe a reduction in the anterior glide excursion, the clinician may suspect injury to the anterior capsuloligamentous complex.*

*Similarly, by altering the position of the glenohumeral joint, the clinician can direct treatment toward a particular portion of the complex. Anterior glide with the glenohumeral joint abducted applies a greater stretch to the inferior glenohumeral ligament than to the superior and middle glenohumeral ligaments. The clinician can also use such knowledge to reduce the loads on an injured or repaired structure.*

One of the factors coupling the support of the glenohumeral ligaments and capsule to each other is the **intraarticular pressure** that also helps to support the glenohumeral joint [41,42]. Puncturing, or **venting**, the rotator interval in cadavers results in a reduction of the inferior stability of the humeral head, even in the presence of an otherwise intact capsule [42,102]. Isolated closure of rotator interval defects appears to restore stability in young subjects who have no additional glenohumeral joint damage [23]. This supports the notion that tears in this part of the capsule can destabilize the joint not only by a structural weakening of the capsule itself but also by a disruption of the normal intraarticular pressure.

Thus the capsule with its reinforcing ligaments acts as a barrier to excessive translation of the humeral head and limits motion of the glenohumeral joint, particularly at the ends of glenohumeral ROM. It also contributes to the normal glide of the humerus on the glenoid fossa during shoulder motion. However, this complex of ligaments still is insufficient to stabilize the glenohumeral joint, particularly when external loads are applied to the upper extremity or as the shoulder moves through the middle of its full ROM. The role of the muscles in stabilization of the glenohumeral joint is discussed in Chapter 9.

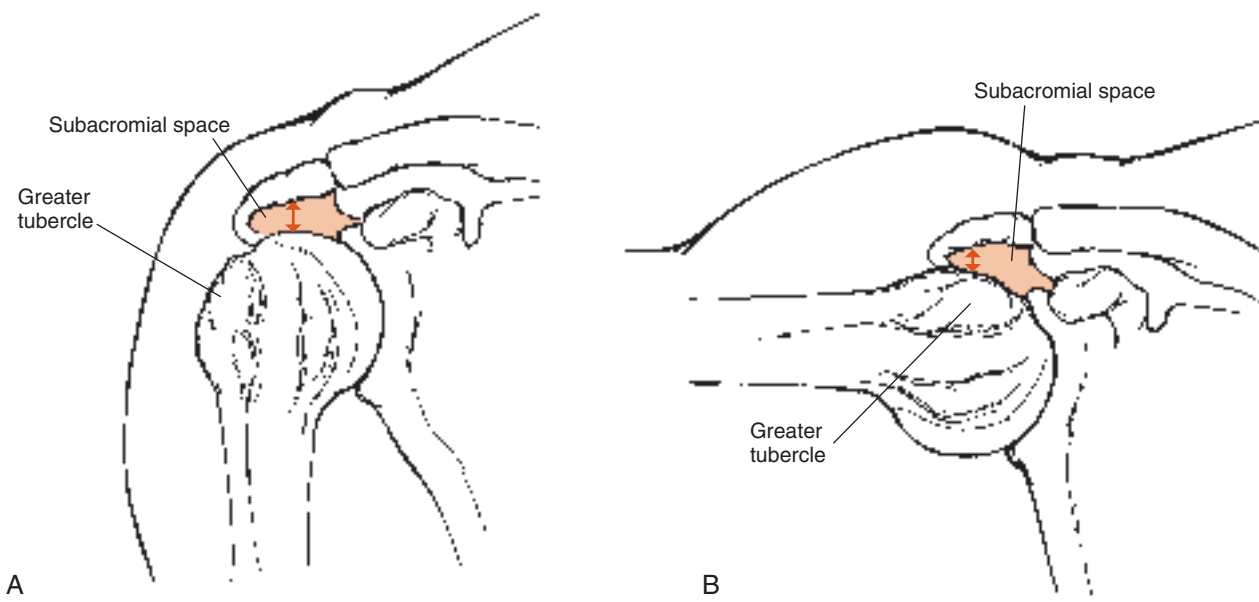
## MOTIONS OF THE GLENOHUMERAL JOINT

As a ball-and-socket joint, the glenohumeral joint has three axes of motion that lie in the cardinal planes of the body. Therefore the motions available at the glenohumeral joint are

- Flexion/extension
- Abduction/adduction
- Medial/lateral (internal/external) rotation

Abduction and flexion sometimes are each referred to as **elevation**. Authors also distinguish between elevation of the glenohumeral joint in the plane of the scapula and that in the sagittal and frontal planes.

Flexion and abduction in the sagittal and frontal planes of the body, respectively, occur with simultaneous rotation of the glenohumeral joint about its long axis. Rotation of the humerus during shoulder elevation is necessary to maximize the space between the acromion and proximal humerus. This space, known as the **subacromial space**, contains the subacromial bursa, the muscle and tendon of the supraspinatus, the superior portion of the glenohumeral joint capsule, and the intraarticular tendon of the long head of the biceps brachii



**Figure 8.28:** Subacromial space during abduction. **A.** The subacromial space is large when the shoulder is in neutral. **B.** During shoulder abduction the greater tubercle moves closer to the acromion, narrowing the subacromial space.

(Fig. 8.28). Each of these structures could sustain injury with the repeated or sustained compression that would occur without humeral rotation during shoulder elevation.

Determining the exact direction and pattern of humeral rotation during shoulder elevation has proven challenging. The traditional clinical view is that lateral rotation of the humerus accompanies shoulder abduction, and medial rotation occurs with shoulder flexion [6,86,93]. Consistent with this view is that little or no axial rotation occurs with shoulder elevation in the plane of the scapula [86]. Data to support these concepts come from cadaver and two-dimensional analysis of humeral motion in vivo.

More recently three-dimensional studies of arm-trunk motion call these data into question. Most of these reports agree that the humerus undergoes lateral rotation during shoulder abduction [63,94]. However, these studies also suggest that lateral rotation may occur in shoulder flexion as well. In order to interpret these differing views regarding axial rotation and shoulder flexion, it is essential to note that these more recent studies use three-dimensional analysis and employ euler angles to describe these motions. Euler angles are extremely sensitive to the order in which they are determined and are not comparable to two-dimensional anatomical measurements.

Despite the confusion regarding the exact anatomical rotations that occur with shoulder elevation, it remains clear that axial rotation of the humerus is an essential ingredient of shoulder elevation. Large compressive forces are reported on the coracohumeral ligament in healthy individuals who actively medially rotate the shoulder through the full ROM while maintaining 90° of shoulder abduction [103]. Such forces would also compress the contents of the subacromial space, thereby creating the potential for an impingement syndrome.

## Clinical Relevance

### SHOULDER IMPINGEMENT SYNDROME IN COMPETITIVE SWIMMERS:

*Impingement syndrome is the cluster of signs and symptoms that result from chronic irritation of any or all of the structures in the subacromial space. Such irritation can come from repeated or sustained compression resulting from an intermittent or prolonged narrowing of the subacromial space. Symptoms of impingement are common in competitive swimmers and include pain in the superior aspect of the shoulder beginning in the midranges of shoulder elevation and worsening with increasing excursion of flexion or abduction.*

*Most competitive swimming strokes require the shoulder to actively and repeatedly assume a position of shoulder abduction with medial rotation. This position narrows the subacromial space and consequently increases the risk of impingement. Some clinicians and coaches suggest that to prevent impingement, swimmers must strengthen their scapular muscles so that scapular position can enhance the subacromial space even as the humeral position tends to narrow it.*

Although flexion, abduction, and rotation of the glenohumeral joint imply pure rotational movements, the asymmetrical articular areas of the humeral head and glenoid fossa, the pull of the capsuloligamentous complex, and the forces from the surrounding muscles result in a complex combination of rotation and gliding motions at the glenohumeral joint. If the motion of the glenohumeral joint consisted entirely of pure rotation, the motion could be described as a

rotation about a fixed axis. When rotation is accompanied by gliding, the rotation can be described as occurring about a moving axis. As described in Chapter 7, the degree of mobility of the axis of rotation in the two-dimensional case is described by the **instant center of rotation (ICR)**. The ICR is the location of the axis of motion at a given joint position. The more stable the axis of motion, the more constant is the ICR. The ICR of the glenohumeral joint moves only slightly during flexion or abduction of the shoulder, indicating only minimal translation [100].

The amount of humeral head translation during shoulder motion has received considerable attention among clinicians and researchers [28,33,34,52,100]. Glenohumeral translation is less during active shoulder motions when muscle contractions help to stabilize the humeral head than during passive motions [28]. In active elevation of the glenohumeral joint in the plane of the scapula, the humeral head undergoes minimal superior glide ( $\leq 3$  mm) and then remains fixed or glides inferiorly no more than 1 mm [11,21,28,50,80,89]. Individuals with muscle fatigue or glenohumeral instability, however, consistently exhibit excessive superior glide during active shoulder elevation [10,18,21,46].


The humeral head glides posteriorly in shoulder extension and in lateral rotation; it translates anteriorly during abduction and medial rotation [28,33,68,70,75,89]. These data contradict the so-called **concave–convex rule**, which states that the convex humeral head glides on the concave glenoid fossa in directions opposite the humeral roll. For example, the concave–convex rule predicts that inferior glide of the humerus accompanies its superior roll in flexion or abduction, and lateral rotation occurs with anterior glide [86,93]. Direct measurements reveal otherwise, showing repeatedly that the concave–convex rule does *not* apply to the glenohumeral joint.

Although slight, joint glides appear to accompany glenohumeral motions. This recognition supports the standard clinical practice of restoring translational movement to restore full ROM at the glenohumeral joint. The concept of joint glide at the glenohumeral joint also forms the theoretical basis for many mobilization techniques used in the clinic. Reporting the amount of available passive humeral head glide as a percentage of the glenoid diameter in the direction of the glide, a study of anesthetized subjects without shoulder pathology reports that the humeral head can glide 17, 26, and 29% in the anterior, posterior, and inferior directions, respectively, with the glenohumeral joint in neutral [35]. Passive glides of almost 1.5 cm are reported in subjects without shoulder impairments [9,65]. Patients with anterior instabilities demonstrate significant increases in both anterior and inferior directions. Patients with multidirectional instabilities exhibit significantly increased excursions in all three directions [11,21]. It is essential for the clinician to understand that slight translation occurs in normal glenohumeral joint motion. Yet excessive translation may contribute to significant dysfunction.

Total glenohumeral joint elevation is most frequently described as a percentage of shoulder complex motion. Glenohumeral flexion and abduction are reported to be 100–120° [40,80,98]; however, shoulder rotation comes solely

from the glenohumeral joint. Although protraction of the sternoclavicular joint and abduction and internal rotation of the scapulothoracic joint cause the humerus to face medially, these are substitutions for medial rotation of the shoulder rather than contributions to true medial rotation. Similarly, retraction of the sternoclavicular joint and adduction, posterior tilting, and external rotation of the scapulothoracic joint can substitute for lateral rotation of the shoulder. True shoulder rotation ROM values range from approximately 70 to 90° for both medial and lateral rotation. There are no known studies that identify the contribution of the glenohumeral joint to shoulder extension, but the glenohumeral joint is the likely source of most extension excursion, with only a minor contribution from adduction, downward rotation and anterior tilt of the scapulothoracic joint.

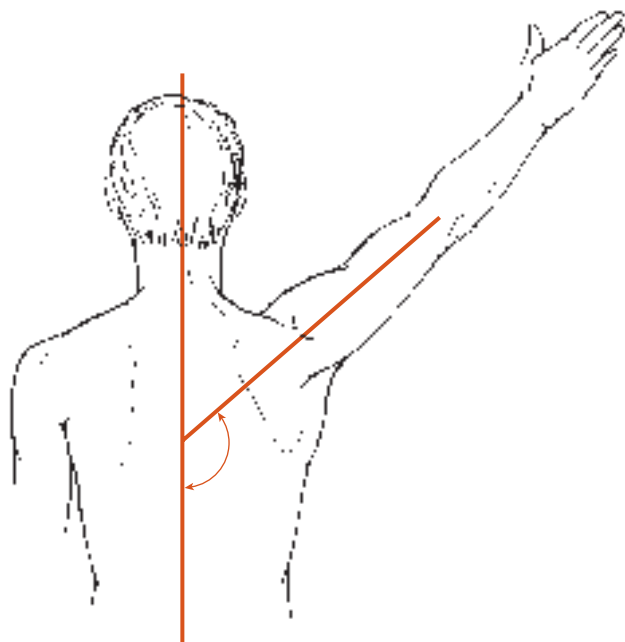
In summary, this section reviews the individual joints that constitute the shoulder complex. Each joint has a unique structure that results in a unique pattern of mobility and stability.

 The overall function of the shoulder complex depends on the individual contributions of each joint. A patient's complaints to the clinician usually are focused on the function of the shoulder as a whole, such as an inability to reach overhead or the presence of pain in throwing a ball. The clinician must then determine where the impairment is within the shoulder complex. A full understanding of the role of each joint in the overall function of the shoulder complex is essential to the successful evaluation of the shoulder complex. The following section presents the role of each joint in the production of normal motion of the shoulder complex.

## TOTAL SHOULDER MOVEMENT

The term *shoulder* means different things to different people (i.e., the shoulder complex or the glenohumeral joint). Therefore, motion in this region is perhaps more clearly presented as **arm–trunk motion**, since motion of the shoulder complex generally is described by the angle formed between the arm and the trunk (*Fig. 8.29*). However, the literature and clinical vocabulary commonly use **shoulder motion** to mean arm–trunk motion. Therefore, both terms, *arm–trunk motion* and *shoulder motion*, are used interchangeably in the rest of this chapter. For the purposes of clarity, the terms **arm–trunk elevation** and **shoulder elevation** are used to mean abduction or flexion of the shoulder complex. These can occur in the cardinal planes of the body or in the plane of the scapula. When the distinction is important, the plane of the motion is identified. It is essential to recognize the distinction between *shoulder elevation*, which involves all of the joints of the shoulder complex, and *scapular elevation*, which is motion of the scapulothoracic joint and indirectly produces elevation at the sternoclavicular joint but does not include glenohumeral joint motion. The following section describes the individual contributions of the four joints of the shoulder complex to the total arm-trunk motion. In addition, the timing of these contributions and the rhythmic interplay of the joints are discussed.



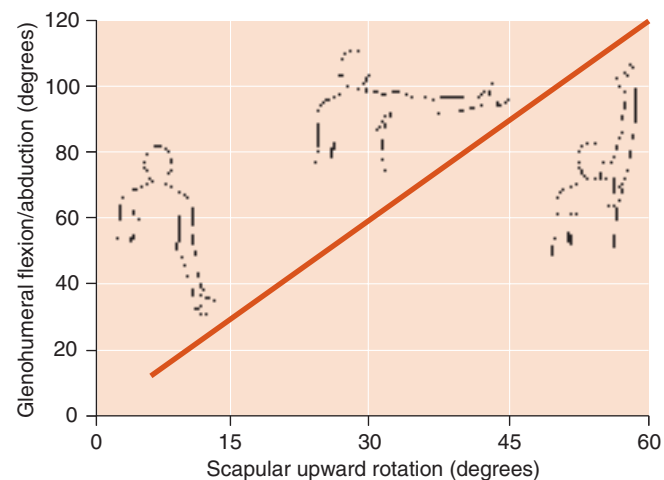


**Figure 8.29:** Arm–trunk motion. Shoulder motion is described by the orientation of the mechanical axis of the arm with respect to the trunk.

### Movement of the Scapula and Humerus during Arm–Trunk Elevation

During arm–trunk elevation the scapula rotates upward as the glenohumeral joint flexes or abducts. In addition, the scapula tilts posteriorly about a medial–lateral axis and rotates externally about a vertical axis during shoulder elevation [29,47,60,63]. Upward rotation is the largest scapulothoracic motion in shoulder elevation. It has long been recognized that the upward rotation of the scapula and the flexion or abduction of the humerus occur synchronously throughout arm–trunk elevation in healthy individuals [66]. In the last 50 years, several systematic studies have been undertaken to quantify this apparent rhythm, known as **scapulohumeral rhythm**. The vast majority of these studies have examined the relationship of movement at the joints of the shoulder complex during voluntary, active shoulder movement. In addition, some of these investigations examine arm–trunk movement in the cardinal planes of the body, while others report motions in the plane of the scapula. Some of the differences in the results of the studies discussed below may be attributable to these methodological differences.

The classic study of the motion of the shoulder is by Inman et al. in 1944 [40]. Although some of the data reported in this study have been refuted, the study continues to form the basis for understanding the contributions made by the individual joints to the total movement of the shoulder complex. These investigators report on the active, voluntary motion of the shoulder complex in the sagittal and frontal planes of the body in individuals without shoulder pathology. They state that for every 2° of glenohumeral joint abduction or flexion there is 1° of upward rotation at the scapulothoracic joint, resulting in



**Figure 8.30:** Contribution of the glenohumeral and scapulothoracic joints to arm–trunk motion. There is approximately 2° of glenohumeral motion to every 1° of scapulothoracic motion during shoulder flexion or abduction.

a 2:1 ratio of glenohumeral to scapulothoracic joint movement in both flexion and abduction (Fig. 8.30). Thus these authors suggest that the glenohumeral joint contributes approximately 120° of flexion or abduction and the scapulothoracic joint contributes approximately 60° of upward rotation of the scapula, yielding a total of about 180° of arm–trunk elevation. The authors state that the ratio of glenohumeral to scapulothoracic motion becomes apparent and remains constant after approximately 30° of abduction and approximately 60° of flexion. McClure et al. also found a 2:1 ratio for scapulohumeral rhythm during active shoulder flexion [63]. In contrast these authors and others report mostly smaller ratios for shoulder elevation in the scapular plane [1,25,29,63,80]. In other words, these authors report more scapular (or less glenohumeral) contribution to the total movement.

These results are presented in *Table 8.1*. McQuade and Smidt do not report average ratios [66]. However, in contrast to the data reported in *Table 8.1*, their data suggest even more contribution to the total movement by the glenohumeral joint than is suggested by Inman et al., with ratios varying from approximately 3:1 to 4:1 through the range. In addition, several authors report a variable ratio rather than the constant ratio reported by Inman et al. [1,29,66,80]. Although there is little agreement in the actual change in the ratios, most

**TABLE 8.1: Reported Average Ratios of Glenohumeral to Scapulothoracic Motion during Active Arm–Trunk Elevation in the Plane of the Scapula**

Authors	Ratio
Freedman and Munro [25]	1.58:1
Poppen and Walker [80]	1.25:1
Bagg and Forrest [1]	1.25:1 to 1.33:1
Graichen et al. [29]	1.5:1 to 2.4:1
McClure [63]	1.7:1

authors report a greater contribution to arm–trunk motion from the scapulothoracic joint late in the ROM rather than in the early or midrange.

Some authors have also investigated the effect of muscle activity on the scapulohumeral rhythm. Passive motion is reported to have a higher glenohumeral contribution to the movement early in the range, with a greater scapulothoracic joint contribution at the end of the motion as well as a higher overall glenohumeral contribution to the total motion [29,66]. Resistance and muscle fatigue during active movement reportedly decrease the scapulohumeral rhythm, resulting in an increased scapulothoracic contribution to the motion [64,66].

In addition to upward rotation, the scapula also exhibits slight external rotation until at least 90° of shoulder elevation [19,22,63]. The scapula also exhibits a few degrees of posterior tilt through at least the first 90° of shoulder elevation.

Despite the differences reported in the literature, some very important similarities exist. Conclusions to be drawn from these studies of healthy shoulders are

- The scapulothoracic and glenohumeral joints move simultaneously through most of the full range of shoulder elevation.
- Both the glenohumeral and scapulothoracic joints contribute significantly to the overall motion of flexion and abduction of the shoulder.
- The scapula and humerus move in a systematic and coordinated rhythm.
- The exact ratio of glenohumeral to scapulothoracic motion may vary according to the plane of motion and the location within the ROM.
- The exact ratio of glenohumeral to scapulothoracic motion during active ROM is likely to depend on muscle activity.
- There is likely to be significant variability among individuals.

The clinician can use these observations to help identify abnormal movement patterns and to help understand the mechanisms relating shoulder impairments to dysfunction.

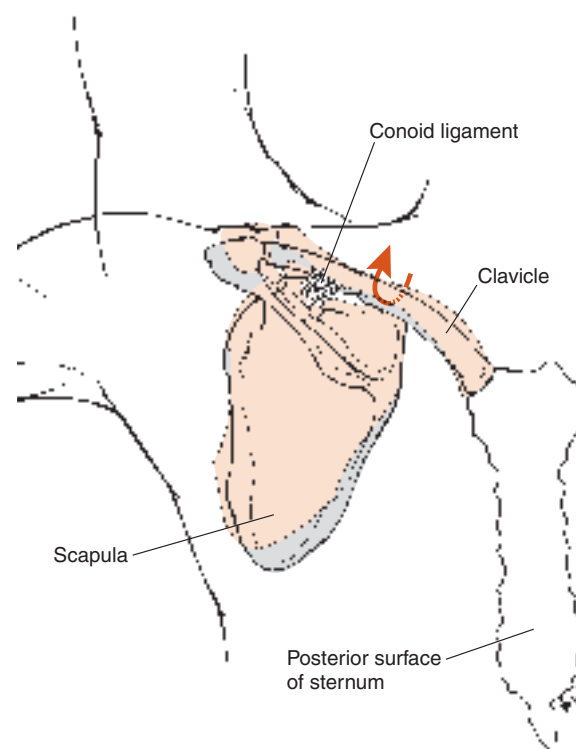
### Clinical Relevance

**ANOTHER POSSIBLE MECHANISM PRODUCING SHOULDER IMPINGEMENT SYNDROME:** *Shoulder, or subacromial, impingement syndrome results from a persistent or repeated compression of the structures within the subacromial space, the space between the acromion process and humeral head. As noted earlier in the chapter, abnormal humeral axial rotation may contribute to the compressive forces leading to impingement. Another possible source of impingement is abnormal scapulothoracic motion during shoulder elevation. Either excessive scapular internal rotation or anterior tilt could narrow the subacromial space and produce compression of the subacromial contents. Repeated or prolonged compression could cause an inflammatory response resulting in pain.*

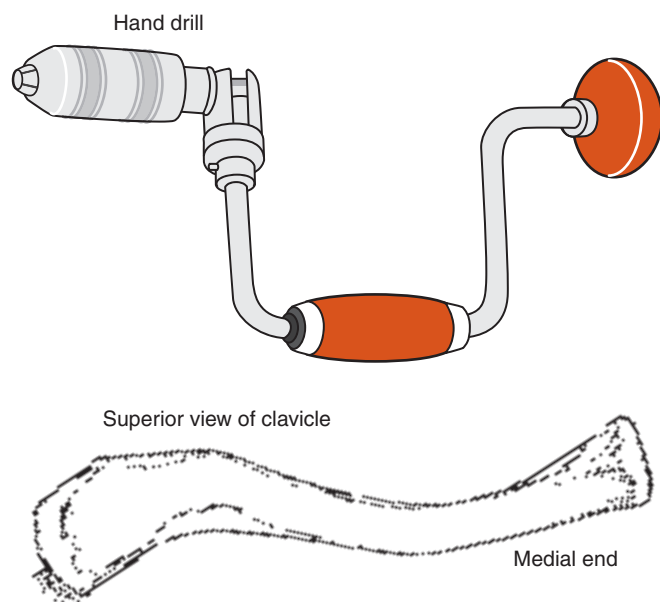
### Sternoclavicular and Acromioclavicular Motion during Arm–Trunk Elevation

With the upward rotation of the scapula during arm–trunk elevation, there must be concomitant elevation of the clavicle to which the scapula is attached. The sternoclavicular joint elevates 15–40° during arm–trunk elevation [1,40,59,98]. The joint also retracts and upwardly rotates during arm–trunk elevation [40,63,59].

Note that the total scapular upward rotation is 60° and the total clavicular elevation is approximately 40°. This disparity of motion suggests that the scapula moves away from the clavicle, causing motion at the acromioclavicular joint (Fig. 8.31). Although the motion at the acromioclavicular joint is inadequately studied, its motion during arm–trunk flexion and abduction appears undeniable [82,87,98]. A possible mechanism to control the acromioclavicular motion is proposed by Inman et al. [40]. As the scapula is pulled away from the clavicle by upward rotation, the conoid ligament (the vertical portion of the coracoclavicular ligament) is pulled tight and pulls on the conoid tubercle situated on the inferior surface of the crank-shaped clavicle. The tubercle is drawn toward the coracoid process, causing the clavicle to be pulled into upward rotation (Fig. 8.31). The crank shape of the clavicle allows the clavicle to remain close to the scapula as it completes its lateral rotation, without using additional elevation ROM at the sternoclavicular joint. The sternoclavicular joint thus elevates



**Figure 8.31:** Upward rotation of the clavicle during arm–trunk motion. As the scapula moves away from the clavicle during arm–trunk elevation, the conoid ligament is pulled taut and causes the clavicle to rotate upwardly.



**Figure 8.32:** Crank shape of clavicle. The shape of the clavicle allows the conoid tubercle to rotate toward the scapula while the medial and lateral ends of the clavicle stay relatively fixed.

less than its full available ROM, which is approximately  $60^\circ$ . Therefore, full shoulder flexion or abduction can still be augmented by additional sternoclavicular elevation in activities that require an extra-long reach, such as reaching to the very top shelf. This sequence of events demonstrates the significance of the crank shape of the clavicle and the mobility of the acromioclavicular joint to the overall motion of the shoulder complex (Fig. 8.32). The coordinated pattern of movement at the sternoclavicular and scapulothoracic joints during normal shoulder flexion and abduction also reveals the role of the conoid ligament in *producing* movement, unlike most ligaments that only limit movement.

This description of sternoclavicular and acromioclavicular motion reveals the remarkable synergy of movement among all four joints of the shoulder complex necessary to complete full arm–trunk flexion and abduction. The scapulothoracic joint must rotate upward to allow full glenohumeral flexion or abduction. The clavicle must elevate and upwardly rotate to allow scapular rotation. This extraordinary coordination occurs in activities as diverse and demanding as lifting a 20-lb child overhead and throwing a 95-mph fastball. However, the rhythm certainly is interrupted in some individuals. Any of the four joints can be impaired. The following section considers the effects of impairments of the individual joints on overall shoulder movement.

### Impairments in Individual Joints and Their Effects on Shoulder Motion

The preceding section discusses the intricately interwoven rhythms of the four joints of the shoulder complex during arm–trunk motion. This section focuses on the effects of

alterations in the mechanics of any of these joints on shoulder motion. Common pathologies involving the glenohumeral joint include capsular tears, rheumatoid arthritis, and inferior subluxations secondary to stroke. The sternoclavicular joint can be affected by rheumatoid arthritis or by ankylosing spondylitis. The acromioclavicular joint is frequently dislocated and also is susceptible to osteoarthritis. Scapulothoracic joint function can be compromised by trauma such as a gunshot wound or by scarring resulting from such injuries as burns. These are just examples to emphasize that each joint of the shoulder complex is susceptible to pathologies that impair its function. Each joint is capable of losing mobility and thus affecting the mobility of the entire shoulder complex. It is not possible to consider all conceivable pathologies and consequences. The purpose of this section is to consider the altered mechanics and potential substitutions resulting from abnormal motion at each of the joints of the shoulder complex. Such consideration illustrates a framework from which to evaluate the function of the shoulder complex and the integrity of its components.

### LOSS OF GLENOHUMERAL OR SCAPULOTHORACIC JOINT MOTION

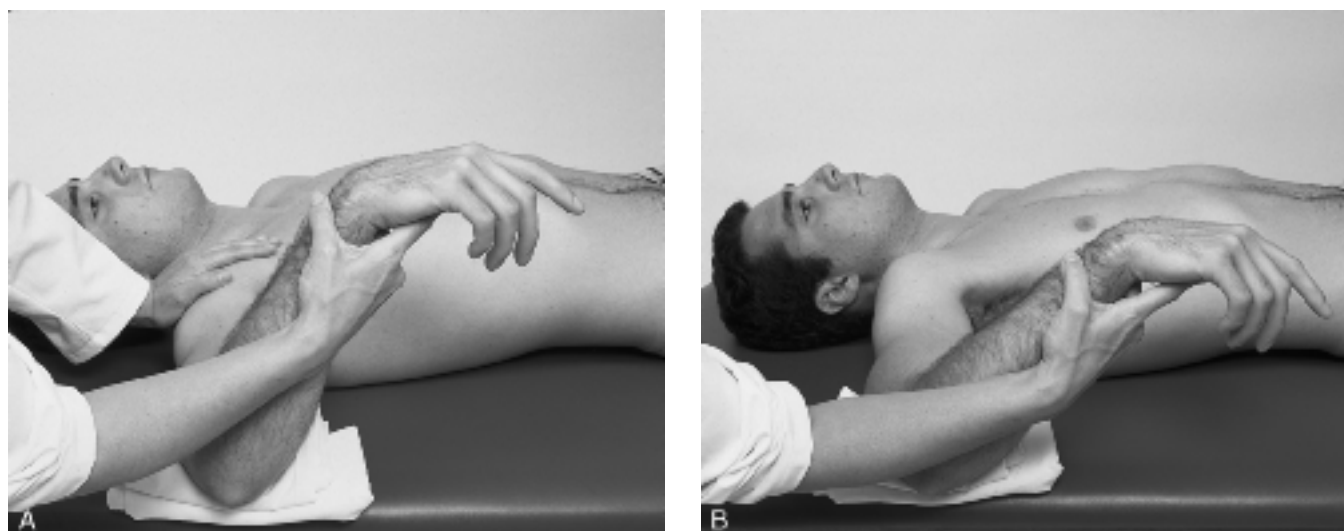
As discussed earlier in this chapter, the data from studies of scapulohumeral rhythm suggest that the glenohumeral joint provides more than 50% of the total shoulder flexion or abduction. Therefore, the loss of glenohumeral motion has a profound effect on shoulder motion. However, it must be emphasized that shoulder motion is not lost completely, even with complete glenohumeral joint immobility. The scapulothoracic and sternoclavicular joints with the acromioclavicular joint combine to provide the remaining one third or more motion. In the absence of glenohumeral movement these joints, if healthy, may become even more mobile. Thus without glenohumeral joint motion and in the presence of intact scapulothoracic, sternoclavicular, and acromioclavicular joints, an individual should still have at least one third the normal shoulder flexion or abduction ROM.

Complete loss of glenohumeral joint motion, however, results in total loss of shoulder rotation. Yet even under these conditions scapulothoracic motion can provide some substitution. Forward tipping of the scapula about a medial–lateral axis is a common substitution for decreased medial rotation of the shoulder.



### Clinical Relevance

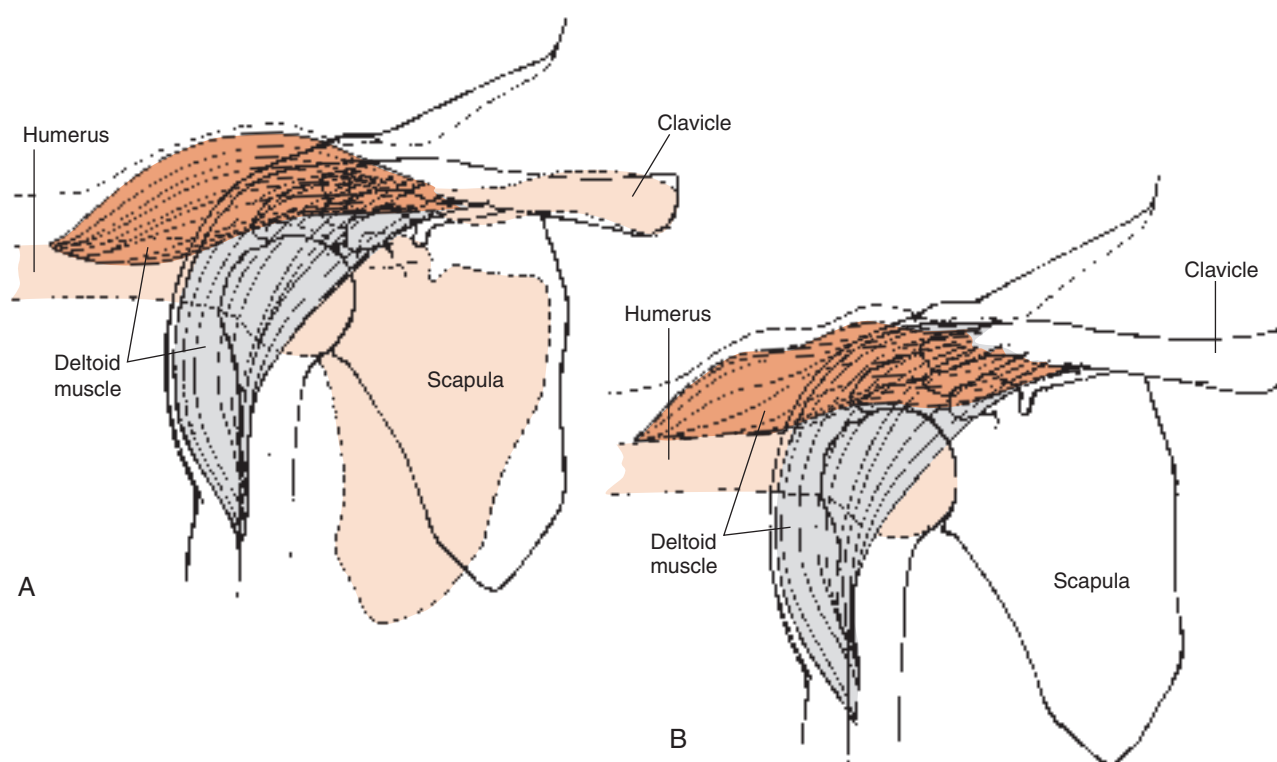
**MEASUREMENT OF MEDIAL ROTATION ROM OF THE SHOULDER:** *Goniometry manuals describe measurement of medial rotation of the shoulder with the subject lying supine and the shoulder abducted to  $90^\circ$  [74]. In this position the shoulder is palpated to identify anterior tilting of the scapula as the shoulder is medially rotated. Firm manual stabilization is usually necessary to prevent the scapula from tilting anteriorly to substitute for medial rotation (Fig. 8.33).*



**Figure 8.33:** Scapular substitutions in shoulder ROM. **A.** Standard goniometric measurement of medial rotation ROM of shoulder requires adequate stabilization of the scapula. **B.** Inadequate stabilization allows anterior tilting of the scapula with an apparent increase in medial rotation ROM of the shoulder.

Conversely, the loss of scapulothoracic motion results in a loss of at least one third of full shoulder elevation ROM. Although this appears to be roughly true in passive ROM, Inman et al. report that in the absence of scapulothoracic joint motion, active shoulder abduction is closer to 90° of abduction rather than the expected 120° [40]. These authors hypothesize that upward rotation of the scapula is essential to maintaining

an adequate contractile length of the deltoid muscle. Scapular upward rotation lengthens the deltoid even as the muscle contracts across the glenohumeral joint during abduction (*Fig. 8.34*). In the absence of upward scapular rotation, the deltoid contracts and reaches its maximal shortening, approximately 60% of its resting length, by the time the glenohumeral joint reaches about 90° of abduction. (See Chapter 4 for details



**Figure 8.34:** Scapular motion and deltoid muscle function. **A.** During normal active shoulder abduction, the upward rotation of the scapula lengthens the deltoid, maintaining an adequate contractile length. **B.** During shoulder abduction without scapular rotation, the deltoid reaches its maximal shortening and is unable to pull the glenohumeral joint through its full abduction ROM.

on muscle mechanics.) Thus without the contributions of the scapulothoracic joint motion, passive ROM of shoulder flexion and abduction are reduced by at least one third. However, active ranges in these two directions appear to be even more severely affected.

In addition to the overall loss of passive and active excursion, decreased scapulothoracic joint motion impairs the synergistic rhythm between the scapulothoracic and glenohumeral joints. This may contribute directly to abnormal glenohumeral joint motion and result in an impingement syndrome.

### Clinical Relevance

**NO WONDER SHOULDER IMPINGEMENT IS SO COMMON!** *Shoulder impingement syndrome is the most common source of shoulder complaints, and the complicated and finely coordinated mechanics of the shoulder complex help explain the frequency of complaints [67]. Earlier clinical relevance boxes demonstrate the possible contributions to impingement syndromes from dysfunction within individual components of the shoulder complex, such as abnormal axial rotation of the humerus or abnormal scapular positions [50,53,61]. Abnormal scapulothoracic rhythm during shoulder flexion or abduction is also associated with impingement syndromes, although it is unclear whether the abnormal rhythm is a cause or an effect of the impingement [12,60].*

*The multiple mechanical dysfunctions that can lead to symptoms of impingement demonstrate the importance of understanding the normal mechanical behavior of each individual component of the shoulder complex as well as the behavior of the complex as a whole. With such an understanding the clinician will be able to thoroughly and accurately evaluate the movements and alignments of the individual parts of the shoulder as well as the coordinated function of the entire complex in order to develop a sound strategy for intervention.*

### LOSS OF STERNOCLAVICULAR OR ACROMIOCLAVICULAR JOINT MOTION

For the scapulothoracic joint to rotate upwardly 60°, the sternoclavicular joint must elevate, and the acromioclavicular joint must glide or rotate slightly. If the clavicle is unable to elevate but the acromioclavicular joint can still move, the scapulothoracic joint may still be able to contribute slightly to total shoulder motion but is likely to have a significant reduction in movement. The effects of lost or diminished scapulothoracic joint motion noted in the preceding section would then follow. If acromioclavicular joint motion is lost, disruption of scapulothoracic joint motion again occurs, although perhaps to a lesser degree than with sternoclavicular joint restriction.

It is important to recognize the potential plasticity of the shoulder complex. Decreased motion at the acromioclavicular joint appears to result in increased sternoclavicular motions, and decreased motion at the sternoclavicular joint results in increased motion at the acromioclavicular joint [82].

Inman et al. report that one subject with the acromioclavicular joint pinned had only 60° of shoulder elevation remaining [40]. However, others report far less dysfunction with loss of motion at the acromioclavicular joint [51]. Perhaps the effects of the loss of acromioclavicular motion depend upon the viability of the remaining structures or the presence of pain.

Case reports suggest that total resection of the clavicle secondary to neoplastic disease and chronic infection have no negative effects on passive ROM of the shoulder [57]. However, scapulohumeral rhythms are not reported. Similarly in another study, 71% of the individuals who underwent distal resection of the clavicle to decrease acromioclavicular pain returned to recreational sports [24]. These data suggest that while there is clear interplay among the four joints of the shoulder complex, there also appears to be a remarkable capacity to compensate for losses by altering the performance of the remaining structures. However, an important consequence of such alterations may be the overuse of remaining joints or the development of hypermobility elsewhere in the system. Therefore, diagnosis of mechanical impairments of the shoulder requires careful assessment of overall shoulder function but also identification of each joint's contribution to the shoulder's total motion.

### Clinical Relevance

**IDENTIFYING LINKS BETWEEN A PATIENT'S COMPLAINTS AND ABNORMAL JOINT MOBILITY:** *A 60-year-old male patient came to physical therapy with complaints of shoulder pain. He reported a history of a severe "shoulder" fracture from a motorcycle accident 30 years earlier. He noted that he had never regained normal shoulder mobility. However, he reported that he had good functional use of his shoulder. He owned a gas station and was an auto mechanic and was able to function fully in those capacities, but he reported increasing discomfort in his shoulder during and after activity. He noted that the pain was primarily on the "top" of his shoulder.*

*Active and passive ROM were equally limited in the symptomatic shoulder: 0–80° of flexion, 0–70° of abduction, 0° medial and lateral rotation. Palpation during ROM revealed a 1:1 ratio of scapular to arm–trunk motion, revealing that all of the arm–trunk motion was coming from the scapulothoracic joint. Palpation revealed tenderness and crepitus at the acromioclavicular joint during shoulder movement.*

*These findings suggested that in the absence of glenohumeral joint motion, the sternoclavicular and acromioclavicular joints developed hypermobility as the patient maximized shoulder function, ultimately resulting in pain at the acromioclavicular joint. This impression was later corroborated by radiological findings of complete fusion of the glenohumeral joint and osteoarthritis of the acromioclavicular joint. Since there was no chance of increasing glenohumeral joint mobility, treatment was directed toward decreasing the pain at the acromioclavicular joint.*

It should be clear that because shoulder motion originates from several locations and normally occurs in a systematic and coordinated manner, evaluation of total shoulder function depends on the ability to assess the individual components and then consider their contributions to the whole. The evaluation requires consideration of the shoulder movement as a whole as well. The following section presents a review of normal arm–trunk ROM.

## SHOULDER RANGE OF MOTION

Values of “normal” ROM reported in the literature are presented in *Table 8.2*. Examination of this table reveals large differences among the published values of normal ROM, particularly in extension, abduction, and lateral rotation of the shoulder complex. Unfortunately, many authors offer no information to explain how these normal values were determined. Consequently, it is impossible to explain the disparity displayed in the literature.

All but one of the references report that lateral rotation is greater than medial rotation. The two studies that report empirical data also suggest that abduction ROM may be slightly greater than flexion ROM, although direct comparisons are not reported [8,71]. In addition, these two studies indicate that gender and age may have significant effects on these values. Thus at the present time, values of “normal” ROM must be used with caution to provide a perspective for the clinician without serving as a precise indicator of the presence or absence of pathology. The clinician must also consider the contributions to the total motion made by the individual components as well as the sequencing of those contributions.

## Clinical Relevance

### SHOULDER MOTION IN ACTIVITIES OF DAILY LIVING:

*Magermans et al. report the shoulder mobility required in diverse activities of daily living (ADL) [62]. Activities such as combing one's hair use an average of 90° of glenohumeral flexion or abduction, 70° of lateral rotation of the shoulder, and approximately 35° of concomitant scapular upward rotation. In contrast personal hygiene activities such as perineal care use glenohumeral hyperextension and essentially full medial rotation ROM. As the clinician strives to help a patient regain or maintain functional independence, the clinician must work to ensure that the mobility needed for function is available and that all four components of the shoulder complex contribute to the mobility appropriately.*

## SUMMARY

This chapter examines the bones and joints of the shoulder complex, which allow considerable mobility but possess inherent challenges to stability. The bones provide little limitation to the motion of the shoulder under normal conditions. The primary limits to normal shoulder motion are the capsuloligamentous complex and the surrounding muscles of the shoulder. The normal function of the shoulder complex depends on the integrity of four individual joint structures and their coordinated contributions to arm–trunk motion. The glenohumeral joint is the sole contributor to medial and lateral rotation of the shoulder and contributes over 50% of

**TABLE 8.2: Normal ROM Values from the Literature (in Degrees)**

	Flexion	Extension	Abduction	Medial Rotation	Lateral Rotation	Abduction in Scapular Plane
Steindler [93]	180	30–40	150			
US Army/Air Force [20]	180	60	180	70	90	
Boone and Azin [8] <sup>a</sup>	165.0 ± 5.0	57.3 ± 8.1	182.7 ± 9.0	67.1 ± 4.1	99.6 ± 7.6	
Hislop and Montgomery [36] <sup>b</sup>	180	45	180	80	60	170
Murray, et al [71]	170 ± 2 <sup>c</sup>	57 ± 3 <sup>c</sup>	178 ± 1 <sup>c</sup>	49 ± 3 <sup>c</sup>	94 ± 2 <sup>c</sup>	
	172 ± 1 <sup>d</sup>	58 ± 3 <sup>d</sup>	180 ± 1 <sup>d</sup>	53 ± 3 <sup>d</sup>	101 ± 2 <sup>d</sup>	
	165 ± 2 <sup>e</sup>	55 ± 2 <sup>e</sup>	178 ± 1 <sup>e</sup>	59 ± 2 <sup>e</sup>	82 ± 4 <sup>e</sup>	
	170 ± 1 <sup>f</sup>	61 ± 2 <sup>f</sup>	178 ± 1 <sup>f</sup>	56 ± 2 <sup>f</sup>	94 ± 2 <sup>f</sup>	
Gerhardt and Rippstein [27]	170	50	170	80	90	
Bagg and Forrest [1]						168.1
Freedman and Munro [25]						167.17 ± 7.57

<sup>a</sup>Data from 56 adult males. These values are also used as “normal” values by the American Academy of Orthopedic Surgeons.

<sup>b</sup>Reported wide ranges from the literature.

<sup>c</sup>Data from 20 young adult males.

<sup>d</sup>Data from 20 young adult females.

<sup>e</sup>Data from 20 male elders.

<sup>f</sup>Data from 20 female elders.

the motion in arm–trunk elevation. The remaining arm–trunk elevation comes from upward rotation of the scapula. The scapula also undergoes posterior tilting and lateral rotation about a vertical axis during arm–trunk elevation. In addition to glenohumeral and scapulothoracic contributions to arm–trunk elevation, the sternoclavicular and acromioclavicular joints contribute important motions to allow full, pain-free arm–trunk elevation. Impairments in the individual joints of the shoulder complex produce altered arm–trunk movement and are likely contributors to complaints of pain in the shoulder complex.

Throughout this chapter the importance of muscular support to the shoulder is emphasized. The following chapter presents the muscles of the shoulder complex and discusses their contributions to the stability and mobility of the shoulder.

## References

1. Bagg SD, Forrest WJ: A biomechanical analysis of scapular rotation during arm abduction in the scapular plane. *Am J Phys Med Rehabil* 1988; 238–245.
2. Basmajian JV, DeLuca CJ: *Muscles Alive. Their Function Revealed by Electromyography*. Baltimore: Williams & Wilkins, 1985.
3. Bearn JG: Direct observations on the function of the capsule of the sternoclavicular joint in clavicular support. *J Anat* 1967; 101: 159–170.
4. Bigliani L, Morrison DS, April EW: The morphology of the acromion and its relationship to rotator cuff tears. *Orthop Trans* 1986; 10: 228 (Abstract).
5. Bigliani LU, Kelkar R, Flatow EL, et al.: Glenohumeral stability biomechanical properties of passive and active stabilizers. *Clin Orthop* 1996; 330: 13–30.
6. Blakely RL, Palmer ML: Analysis of rotation accompanying shoulder flexion. *Phys Ther* 1984; 64: 1214–1216.
7. Blasier RB, Soslowsky LJ, Malicky DM, Palmer ML: Posterior glenohumeral subluxation: active and passive stabilization in a biomechanical model. *J Bone Joint Surg* 1997; 79A: 433–440.
8. Boone DC, Azen SP: Normal range of motion of joints in male subjects. *J Bone Joint Surg* 1979; 61-A: 756–759.
9. Borsa PA, Sauers EL, Herling DE, Manzour WF: In vivo quantification of capsular end-point in the noninjured glenohumeral joint using an instrumented measurement system. *J Orthop Sports Phys Ther* 2001; 31: 419–431.
10. Branch TP, Lawton RL, Iobst CA, Hutton WC: The role of glenohumeral capsular ligaments in internal and external rotation of the humerus. *Am J Sports Med* 1995; 23: 632–637.
11. Chen SK, Simonian PT, Wickiewicz TL, et al.: Radiographic evaluation of glenohumeral kinematics: a muscle fatigue model. *J Shoulder Elbow Surg* 1999; 8: 49–52.
12. Cohen RB, Williams GR Jr: Impingement syndrome and rotator cuff disease as repetitive motion disorders. *Clin Orthop* 1998; 95–101.
13. Costic RS, Vangura A, Fenwick JA, et al.: Viscoelastic behavior and structural properties of the coracoclavicular ligaments. *Scand J Med Sci Sports* 2003; 13: 305–310.
14. Couteau B, Mansat P, Darmana R, et al.: Morphological and mechanical analysis of the glenoid by 3D geometric reconstruction using computed tomography. *Clin Biomech* 2000; 15: S8–S12.
15. Crenshaw AH: *Campbell's Operative Orthopaedics*. Vol 2. St. Louis: Mosby Year Book, 1992.
16. Crenshaw AH: *Campbell's Operative Orthopaedics*. Vol 3. St. Louis: Mosby Year Book, 1992.
17. Culham E, Peat M: Functional anatomy of the shoulder complex. *JOSPT* 1993; 18: 342–350.
18. Curl LA, Warren RF: Glenohumeral joint stability selective cutting studies on the static capsular restraints. *Clin Orthop* 1996; 54–65.
19. Dayanidhi S, Orlin M, Kozin S, et al.: Scapular kinematics during humeral elevation in adults and children. *Clin Biomech* 2005; 20: 600–606.
20. Departments of the U.S. Army and Air Force. *US Army Goniometry Manual: Technical Manual No. 8-640*. Air Force Pamphlet No. 160-14. 1-8-1968. Washington, DC: Departments of the Army and Air Force.
21. Deutsch A, Altchek DW, Schwartz E, et al.: Radiologic measurement of superior displacement of the humeral head in the impingement syndrome. *J Shoulder Elbow Surg* 1996; 5: 186–193.
22. Ebaugh DD, McClure PW, Karduna AR: Three-dimensional scapulothoracic motion during active and passive arm elevation. *Clin Biomech* 2005; 20: 700–709.
23. Field LD, Warren RF, O'Brien SJ, et al.: Isolated closure of rotator interval for shoulder instability. *Am J Sports Med* 1995; 23: 557–563.
24. Flatow EL, Duralde XA, Nicholson GP, et al.: Arthroscopic resection of the distal clavicle with a superior approach. *J Shoulder Elbow Surg* 1995; 4: 41–50.
25. Freedman L, Munro RR: Abduction of the arm in the scapular plane: scapular and glenohumeral movements a roentgenographic study. *J Bone Joint Surg* 1966; 48A: 1503–1510.
26. Fukuda K, Craig EV, An K, et al.: Biomechanical study of the ligamentous system of the acromioclavicular joint. *J Bone Joint Surg* 1986; 68A: 434–440.
27. Gerhardt JJ, Rippstein J: *Measuring and Recording of Joint Motion Instrumentation and Techniques*. Lewiston, NJ: Hogrefe & Huber, 1990.
28. Graichen H, Stammberger T, Bonel H, et al.: Glenohumeral translation during active and passive elevation of the shoulder—a 3D open-MRI study. *J Biomech* 2000; 33: 609–613.
29. Graichen H, Stammberger T, Bonel H, et al.: Magnetic resonance based motion analysis of the shoulder during elevation. *Clin Orthop* 2000; 370: 154–163.
30. Grubbs N: Frozen shoulder syndrome: a review of literature. *JOSPT* 1993; 18: 479–487.
31. Hara H, Ito N, Iwasaki K: Strength of the glenoid labrum and adjacent shoulder capsule. *Shoulder Elbow Surg* 1996; 5: 263–268.
32. Harrington MA Jr, Keller TS, Seiler JGI, et al.: Geometric properties and the predicted mechanical behavior of adult human clavicles. *J Biomech* 1993; 26: 417–426.
33. Harryman DT II, Sidles JA, Clark JM, et al.: Translation of the humeral head on the glenoid with passive glenohumeral motion. *J Bone Joint Surg* 1990; 72-A: 1334–1343.
34. Harryman DT II, Sidles JA, Harris SL, Matsen FA III: The role of the rotator interval capsule in passive motion and stability of the shoulder. *J Bone Joint Surg [AM]* 1992; 74: 53–66.
35. Hawkins R, Schutte J, Janda D, Huckell G: Translation of the glenohumeral joint with the patient under anesthesia. *J Shoulder Elbow Surg* 1996; 5: 286–292.

36. Hislop HJ, Montgomery J: Daniel's and Worthingham's Muscle Testing: Techniques of Manual Examination. Philadelphia: WB Saunders, 1995.
37. Hjelm R, Draper C, Spencer S: Anterior-inferior capsular length insufficiency in the painful shoulder. *JOSPT* 1996; 23: 216–222.
38. Howell SM, Galinat BJ: The glenoid-labral socket. A constrained articular surface. *Clin Orthop* 1989; 243: 122–125.
39. Iannotti JP, Gabriel JP, Scheck SL, et al.: The normal glenohumeral relationships an anatomical study of one hundred and forty shoulders. *J Bone Joint Surg* 1992; 74A: 491–500.
40. Inman VT, Saunders JB, Abbott LC: Observations of the function of the shoulder joint. *J Bone Joint Surg* 1944; 42: 1–30.
41. Inokuchi W, Iken B, Ojbjerg J, Neppen O: The relation between the position of the glenohumeral joint and the intra-articular pressure: an experimental study. *J Shoulder Elbow Surg* 1997; 6: 144–149.
42. Itoi E, Berglund LJ, Grabowski JJ, et al.: Superior-inferior stability of the shoulder: role of the coracohumeral ligament and the rotator interval capsule. *Mayo Clin Proc* 1998; 73: 508–515.
43. Jansen JHW, de Gast A, Snijders CJ: Glenohumeral elevation-dependent influence of anterior glenohumeral capsular lesions on passive axial humeral rotation. *J Biomech* 2006; 39: 1702–1707.
44. Jobe CM: Superior glenoid impingement. *Orthop Clin North Am* 1997; 28: 137–143.
45. Jobe CM, Iannotti JP: Limits imposed on glenohumeral motion by joint geometry. *J Shoulder Elbow Surg* 1995; 4: 281–285.
46. Kapandji IA: *The Physiology of the Joints. Vol 1, The Upper Limb.* Edinburgh: Churchill Livingstone, 1982.
47. Karduna AR, McClure PW, Michener L: Scapular kinematics: effects of altering the Euler angle sequence of rotations. *J Biomech* 2000; 33: 1063–1068.
48. Karduna AR, Williams GR, Williams JL, Iannotti JP: Glenohumeral joint translations before and after total shoulder arthroplasty. *J Bone Joint Surg* 1997; 79-A: 1166–1174.
49. Kebaetse M, McClure P, Pratt NA: Thoracic position effect on shoulder range of motion, strength, and three-dimensional scapular kinematics. *Arch Phys Med Rehabil* 1999; 80: 945–950.
50. Kelley MJ: Biomechanics of the shoulder. In: *Orthopedic Therapy of the Shoulder.* Kelley MJ, Clark WA, eds. Philadelphia: JB Lippincott, 1995.
51. Kennedy JC, Cameron H: Complete dislocation of the acromio-clavicular joint. *J Bone Joint Surg* 1954; 36: 202–208.
52. Kent BE: Functional anatomy of the shoulder complex a review. *Phys Ther* 1971; 51: 867–888.
53. Kibler WB: The role of the scapula in athletic shoulder function. *Am J Sports Med* 1998; 26: 325–337.
54. Kuhn JE, Huston LJ, Soslowsky LJ, et al.: External rotation of the glenohumeral joint: ligament restraints and muscle effects in the neutral and abducted positions. *J Shoulder Elbow Surg* 2005; 14: 39S–48S.
55. Lee K, Debski RE, Chen C, et al.: Functional evaluation of the ligaments at the acromioclavicular joint during anteroposterior and superoinferior translation. *Am J Sports Med* 1997; 25: 858–862.
56. Levinsohn EM, Santelli ED: Bicipital groove dysplasia and medial dislocation of the biceps brachii tendon. *Skeletal Radiol* 1991; 20: 419–423.
57. Lewis MM, Ballet FL, Kroll PG, Bloom N: En bloc clavicular resection: operative procedure and postoperative testing of function case reports. *Clin Orthop* 1985; 214–220.
58. Lucas D: Biomechanics of the shoulder joint. *Arch Surg* 1973; 107: 425–432.
59. Ludewig PM, Behrens SA, Meyer SM, et al.: Three-dimensional clavicular motion during arm elevation: reliability and descriptive data. *JOSPT* 2004; 34: 140–149.
60. Ludewig PM, Cook TM: Alterations in shoulder kinematics and associated muscle activity in people with symptoms of shoulder impingement. *Phys Ther* 2000; 80: 276–291.
61. Lukasiewicz AM, McClure P, Michener L, et al.: Comparison of 3-dimensional scapular position and orientation between subjects with and without shoulder impingement. *J Orthop Sports Phys Ther* 1999; 29: 574–586.
62. Magermans DJ, Chadwick EKJ, Veeger HEJ, van der Helm FCT: Requirements for upper extremity motions during activities of daily living. *Clin Biomech* 2005; 20: 591–599.
63. McClure PW, Michener LA, Sennett BJ, Karduna AR: Direct 3-dimensional measurement of scapular kinematics during dynamic movements in vivo. *J Shoulder Elbow Surg* 2001; 10: 269–277.
64. McQuade KJ, Dawson J, Smidt GL: Scapulothoracic muscle fatigue associated with alterations in scapulohumeral rhythm kinematics during maximum resistive shoulder elevation. *JOSPT* 1998; 28: 74–80.
65. McQuade KJ, Murthi AM: Anterior glenohumeral force/translation behavior with and without rotator cuff contraction during clinical stability testing. *Clin Biomech* 2004; 19: 10–15.
66. McQuade KJ, Smidt GL: Dynamic scapulohumeral rhythm: the effects of external resistance during elevation of the arm in the scapular plane. *JOSPT* 1998; 27: 125–133.
67. Michener LA, McClure PW, Karduna AR: Anatomical and biomechanical mechanisms of subacromial impingement syndrome. *Clin Biomech* 2003; 18: 369–379.
68. Moore SM, Musahl V, McMahon PJ, Debski RE: Multidirectional kinematics of the glenohumeral joint during simulated simple translation tests: impact on clinical diagnoses. *J Orthop Res* 2004; 22: 889–894.
69. Moseley H: The clavicle: its anatomy and function. *Clin Orthop* 1968; 58: 17–27.
70. Moseley H, Övergaard B: The anterior capsular mechanism in recurrent anterior dislocation of the shoulder. *J Bone Joint Surg* 1962; 44 B: 913–927.
71. Murray MP, Gore DR, Gardner GM, Mollinger LA: Shoulder motion and muscle strength of normal men and women in two age groups. *Clin Orthop* 1985; 268–273.
72. Nettles JL, Linscheid RL: Sternoclavicular dislocations. *J Trauma* 1968; 8: 158–164.
73. Neviaser TJ: Adhesive capsulitis. *Orthop Clin North Am* 1987; 18: 439–443.
74. Norkin CC, White DJ: *Measurement of Joint Motion. A Guide to Goniometry.* Philadelphia: FA Davis, 1995.
75. Novotny JE, Beynon BD, Nichols CE: Modeling the stability of the human glenohumeral joint during external rotation. *J Biomech* 2000; 33: 345–354.
76. Novotny JE, Nichols CE, Beynon BD: Kinematics of the glenohumeral joint with Bankart lesion and repair. *J Bone Joint Surg* 1998; 16: 116–121.
77. Nuemann CH, Petersen SA, Jahnke AH: MR imaging of the labral-capsular complex: normal variations. *Am J Roentgenol* 1991; 157: 1015–1021.



78. O'Connell PW, Nuber GW, Mileski RA, Lautenschlager E: The contribution of the glenohumeral ligaments to anterior stability of the shoulder joint. *Am J Sports Med* 1990; 18: 579–584.
79. Pagnani MJ, Deng XH, Warren RF, et al.: Effect of lesions of the superior portion of the glenoid labrum on glenohumeral translation. *J Bone Joint Surg* 1995; 77A: 1003–1010.
80. Poppen NK, Walker PS: Normal and abnormal motion of the shoulder. *J Bone Joint Surg* 1976; 58A: 195–201.
81. Pratt NE: Anatomy and biomechanics of the shoulder. *J Hand Ther* 1994; 7: 65–76.
82. Pronk GM, van der Helm FCT, Rozendaal LA: Interaction between the joints in the shoulder mechanism: the function of the costoclavicular, conoid and trapezoid ligaments. *Proc Inst Mech Eng* 1993; 207: 219–229.
83. Roberts D: Structure and function of the primate scapula. In: *Primate Locomotion*. Jenkins FA Jr, ed. New York: Academic Press, 1974; 171–200.
84. Romanes GJE: *Cunningham's Textbook of Anatomy*. Oxford: Oxford University Press, 1981.
85. Saha AK: Mechanics of elevation of glenohumeral joint, its application in rehabilitation of flail shoulder in upper brachial plexus injuries and poliomyelitis and in replacement of the upper humerus by prosthesis. *Acta Orthop Scand* 1973; 44: 668–678.
86. Saha AK: The classic mechanism of shoulder movements and a plea for the recognition of “zero position” of glenohumeral joint. *Clin Orthop* 1983; 3–10.
87. Sahara W, Sugamoto K, Murai M, et al.: 3D kinematic analysis of the acromioclavicular joint during arm abduction using vertically open MRI. *J Orthop Res* 2006; 24: 1823–1831.
88. Soslowky LJ, An CH, Johnston SP, Carpenter JE: Geometric and mechanical properties of the coracoacromial ligament and their relationship to rotator cuff disease. *Clin Orthop* 1994; 10–17.
89. Soslowky LJ, Flatow EL, Bigliani L, et al.: Quantitation of in situ contact areas at the glenohumeral joint: a biomechanical study. *J Orthop Res* 1992; 10: 524–534.
90. Soslowky LJ, Malicky DM, Blasler RB: Active and passive factors in inferior glenohumeral stabilization: a biomechanical model. *J Shoulder Elbow Surg* 1997; 6: 371–379.
91. Spencer EE, Valdevit A, Kambic H, et al.: The effect of humeral component anteversion on shoulder stability with glenoid component retroversion. *J Bone Joint Surg* 2005; 87: 808–814.
92. Stanley D, Trowbridge EA, Norris SH: The mechanism of clavicular fracture: a clinical and biomechanical analysis. *J Bone Joint Surg* 1988; 70B: 461–464.
93. Steindler A: *Kinesiology of the Human Body under Normal and Pathological Conditions*. Springfield, IL: Charles C. Thomas, 1955.
94. Stokdijk M, Eilers PHC, Nagels J, Rozing PM: External rotation in the glenohumeral joint during elevation of the arm. *Clin Biomech* 2003; 18: 296–302.
95. Terry GC, Hammon D, France P, Norwood LA: The stabilizing function of passive shoulder restraints. *Am J Sports Med* 1991; 19: 26–34.
96. Thomas CB Jr, Friedman RJ: Case report ipsilateral sternoclavicular dislocation and clavicle fracture. *J Orthop Trauma* 1989; 3: 353–357.
97. van der Helm FCT: A finite element musculoskeletal model of the shoulder mechanism. *J Biomech* 1994; 27: 551–569.
98. van der Helm FCT, Pronk G: Three-dimensional recording and description of motions of the shoulder mechanism. *J Biomech Eng* 1995; 117: 27–40.
99. van der Helm FCT, Veeger HEJ, Pronk GM: Geometry parameters for musculoskeletal modelling of the shoulder mechanism. *J Biomech* 1992; 25: 129–144.
100. Veeger HEJ: The position of the rotation center of the glenohumeral joint. *J Biomech* 2000; 33: 1711–1715.
101. Williams P, Bannister L, Berry M, et al: *Gray's Anatomy, The Anatomical Basis of Medicine and Surgery*, Br. ed. London: Churchill Livingstone, 1995.
102. Wuelker N, Korell M, Thren K: Dynamic glenohumeral joint stability. *J Shoulder Elbow Surg* 1998; 7: 43–52.
103. Yanai T, Fuss FK, Fukunaga T: In vivo measurements of subacromial impingement: substantial compression develops in abduction with large internal rotation. *Clin Biomech* 2006; 21: 692–700.