



UNIT 6

Digestive System

Pathological Conditions

APPENDICITIS

- ❑ Inflammation of the appendix, which is usually acute and caused by blockage of the appendix followed by infection.
 - *Treatment for acute appendicitis is appendectomy within 48 hours of the first symptom. When left untreated, appendicitis rapidly leads to perforation and peritonitis as fecal matter is released into the peritoneal cavity.*

ASCITES

- ❑ Abnormal accumulation of serous fluid in the peritoneal cavity.
 - *Ascites may be a symptom of inflammatory disorders in the abdomen, venous hypertension caused by liver disease, or heart failure (HF).*

BORBORYGMUS

- ❑ Gurgling or rumbling sound heard over the large intestine that is caused by gas moving through the intestines.

CIRRHOSIS

- ❑ Chronic liver disease characterized by destruction of liver cells that eventually leads to ineffective liver function and jaundice.

DIVERTICULAR DISEASE

- ❑ Condition in which bulging pouches (diverticula) in the gastrointestinal (GI) tract push the mucosal lining through the surrounding muscle.
 - *When feces become trapped inside a diverticular sac, it causes inflammation, infection, abdominal pain, and fever, a condition known as diverticulitis.*

DYSENTARY

- ❑ Inflammation of the intestine, especially of the colon, which may be caused by chemical irritants, bacteria, protozoa, or parasites.
 - *Dysentary is common in underdeveloped areas of the world and in times of disaster and social disorganization when sanitary living conditions, clean food, and safe water are not available. It is characterized by diarrhea, colitis, and abdominal cramps.*

FISTULA

- ❑ Abnormal passage from one organ to another, or from a hollow organ to the surface.
 - *An anal fistula is located near the anus and may open into the rectum.*

GASTROESOPHAGEAL REFLUX DISEASE (GERD)

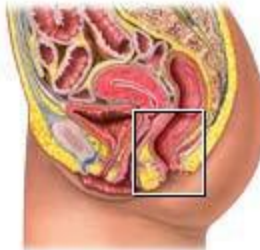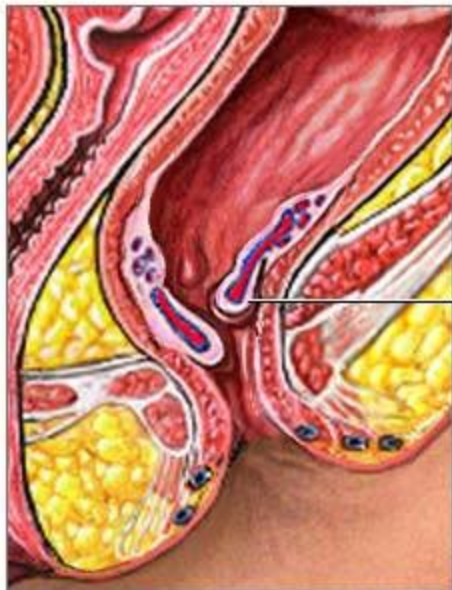
- ❑ Backflow (reflux) of gastric contents into the esophagus due to malfunction of the lower esophageal sphincter (LES).
 - *Symptoms of GERD include heartburn (burning sensation caused by regurgitation of hydrochloric acid from the stomach to the esophagus), belching, and regurgitation of food. Treatment includes elevating the head of the bed while sleeping, avoiding alcohol and foods that stimulate acid secretion, and administering drugs to decrease production of acid.*

HEMATOCHEZIA

- ❑ Passage of stools containing bright red blood.

HEMORRHOID

- ❑ Mass of enlarged, twisted varicose veins in the mucous membrane inside (internal) or just outside (external) the rectum; also known as *piles*.

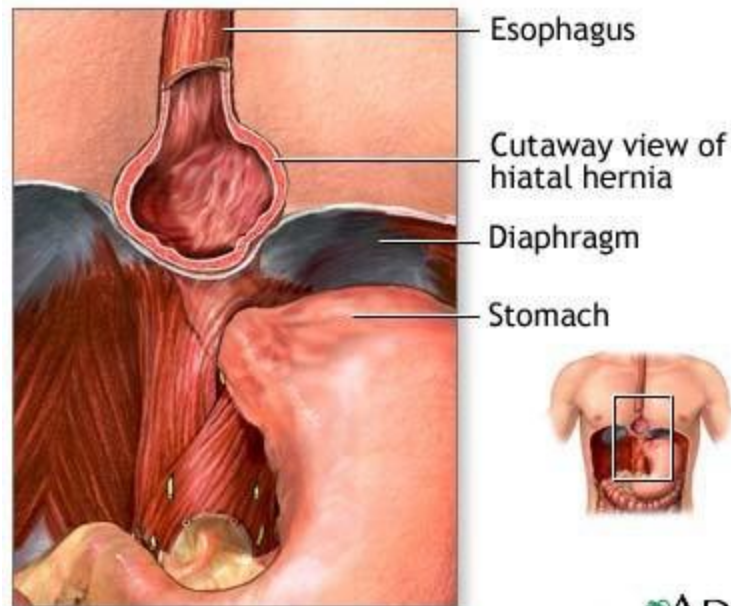


Inflamed hemorrhoids

Hemorrhoids are enlarged veins located within tissues of the lower portion of the rectum or anus

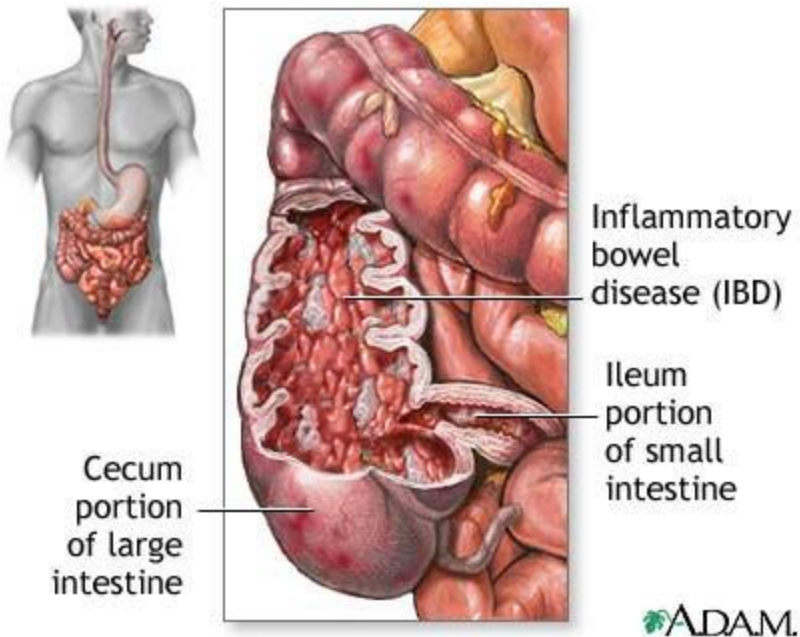
HERNIA

- ❑ Protrusion or projection of an organ or a part of an organ through the wall of the cavity that normally contains it.



INFLAMMATORY BOWEL DISEASE (IBD)

- ❑ Ulceration of the colon mucosa.
 - *Crohn disease and ulcerative colitis are forms of IBD.*

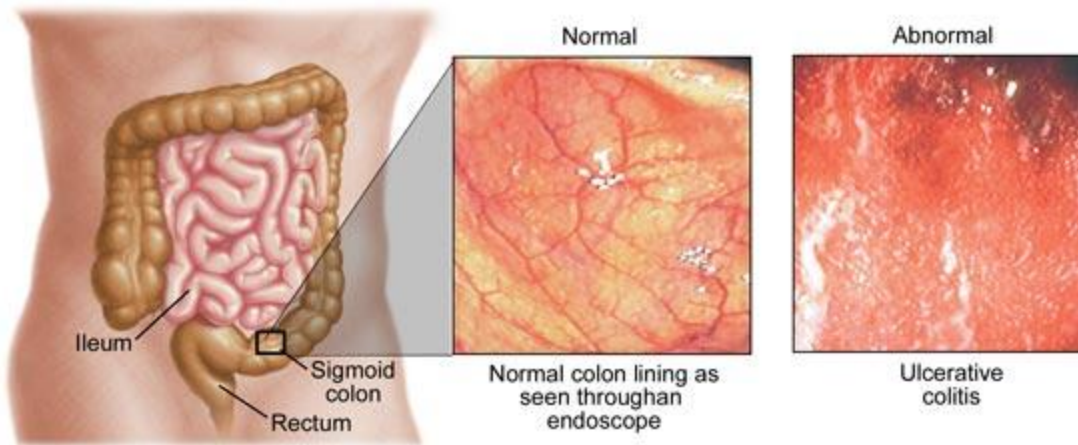


CROHN DISEASE

- ❑ Chronic IBD that usually affects the ileum but may affect any portion of the intestinal tract.
 - *Crohn disease is distinguished from closely related bowel disorders by its inflammatory pattern, which tends to be patchy or segmented; also called regional colitis.*

ULCERATIVE COLITIS

- ❑ Chronic IBD of the colon characterized by episodes of diarrhea, rectal bleeding, and pain.

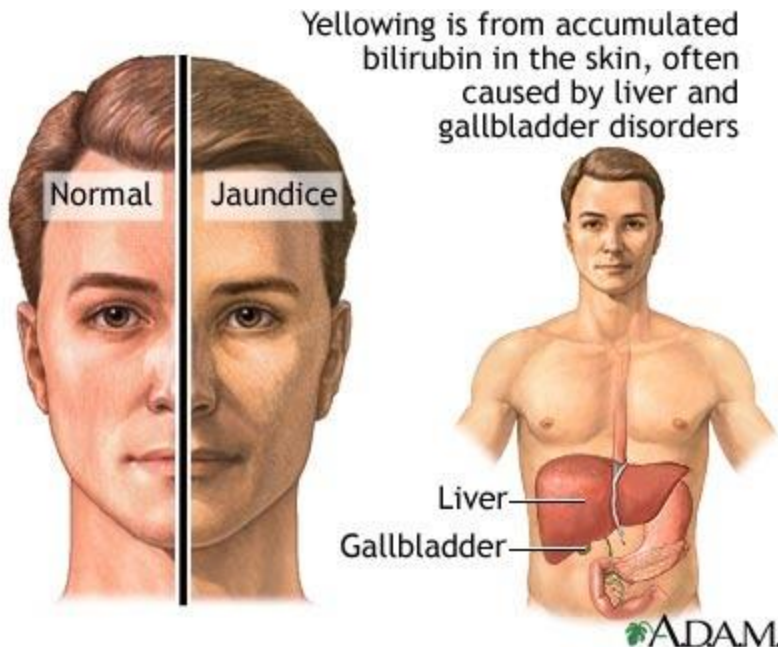


IRRITABLE BOWEL SYNDROME (IBS)

- ❑ Condition characterized by gastrointestinal signs and symptoms, including constipation, diarrhea, gas, and bloating, all in the absence of organic pathology; also called *spastic colon*.
 - *Contributing factors of IBS include stress and tension. Treatment consists of dietary modifications, such as avoiding irritating foods or adding a high-fiber diet and laxatives if constipation is a symptom. It also includes antidiarrheal and antispasmodic drugs as well as alleviating anxiety and stress.*

JAUNDICE

- ❑ Yellow discoloration of the skin, mucous membranes, and sclerae of the eyes caused by excessive levels of bilirubin in the blood (hyperbilirubinemia).



OBESITY

- ❑ Condition in which a person accumulates an amount of fat that exceeds the body's skeletal and physical standards, usually an increase of 20 percent or more above ideal body weight.

MORBID OBESITY

- More severe obesity in which a person has a body mass index (BMI) of 40 or greater, which is generally 100 or more pounds over ideal body weight.
 - *Morbid obesity is a disease with serious medical, psychological, and social ramifications.*

POLYP

- ❑ Small, tumorlike, benign growth that projects from a mucous membrane surface.
 - *Polyps have potential of becoming cancerous, so they are checked frequently or removed the detect any abnormalities at an early stage. Colonic polyps have a high likelihood of becoming colorectal cancer.*

COLONIC POLYPOSIS

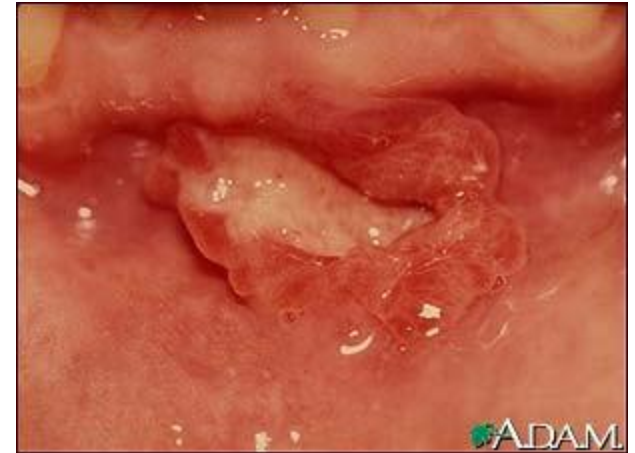- ❑ Condition in which polyps project from the mucous membrane of the colon.

POLYPOSIS

- ❑ Condition in which polyps develop in the intestinal tract.

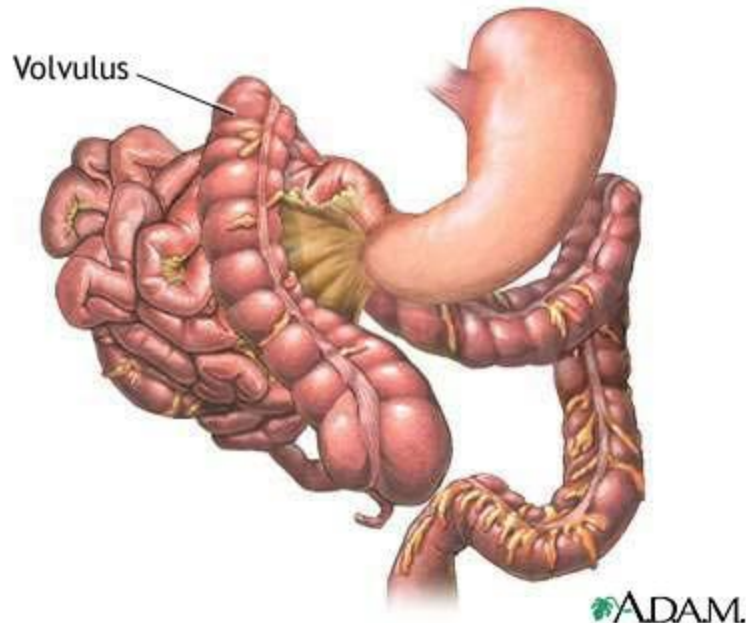
ULCER

- ❑ Open sore or lesion of the skin or mucous membrane accompanied by sloughing or inflamed necrotic tissue.
 - *An ulcer may be shallow, involving only the epidermis, or it may be deep, involving multiple layers of the skin. Examples of ulcers are peptic ulcer, duodenal ulcer, and pressure ulcer (decubitus ulcer).*



VOLVULUS

- ❑ Twisting of the bowel on itself, causing obstruction.
 - *Volvulus usually requires surgery to untwist the loop of a bowel.*



BARIUM ENEMA (BE)

- ❑ Radiographic examination of the rectum and colon after administration of barium sulfate (radiopaque contrast medium) into the rectum.
 - *BE is used for diagnosis of obstructions, tumors, or other abnormalities, such as ulcerative colitis.*

BARIUM SWALLOW

- ❑ Radiographic examination of the esophagus, stomach, and small intestine after oral administration of barium sulfate (radiopaque contrast medium); also called *upper GI series*.
 - *Structural abnormalities of the esophagus and vessels, such as esophageal varices, may be diagnosed using this technique.*

COMPUTED TOMOGRAPHY (CT)

- ❑ Radiographic technique that uses a narrow beam of x-rays that rotates in a full arc around the patient to acquire multiple views of the body that computer interprets to produce cross-sectional images of that body part.
 - *CT scans are used to view the gallbladder, liver, bile ducts, and pancreas and diagnose tumors, cysts, inflammation, abscesses, perforation, bleeding, and obstructions. A contrast material may be used to enhance the structures.*

ENDOSCOPY

- ❑ Visual examination of a cavity or canal using a specialized lighted instrument called an *endoscope*.
 - *The organ, cavity, or canal being examined dictates the name of the endoscopic procedure. A camera and video recorder are commonly used during the procedure to provide a permanent record.*

UPPER GI

- Endoscopy of the esophagus (esophagoscopy), stomach (gastroscope), and duodenum (duodenoscopy).
 - *Endoscopy of the upper GI tract is performed to identify tumors, esophagitis, gastroesophageal varices, peptic ulcers, and the source of upper GI bleeding. It is also used to confirm the presence and extent of varices in the lower esophagus and stomach in patients with liver disease.*

LOWER GI

- Endoscopy of colon (colonoscopy), sigmoid colon (sigmoidoscopy), and rectum and anal canal (proctoscopy).
 - *Endoscopy of the lower GI tract is used to identify pathological conditions in the colon. It may also be used to remove polyps. When polyps are discovered in the colon, they are removed and tested for cancer.*

MAGNETIC RESONANCE IMAGING (MRI)

- ❑ Radiographic technique that uses electromagnetic energy to produce multiplanar cross-sectional images of the body.
 - *In the digestive system, MRI is particularly useful in detecting abdominal masses and viewing images of abdominal structures.*

STOOL GUAIAIC

- ❑ Test performed on feces using the reagent gum guaiac to detect presence of blood in feces that is not apparent on visual inspection; also called *hemoccult test*.

ULTRASONOGRAPHY

- Imaging technique that uses high-frequency sound waves (ultrasound) that bounce off body tissues and are recorded to produce an image of an internal organ or tissue.
 - *Ultrasound is used to view the liver, gallbladder, bile ducts, and pancreas, among other structures. It is also used to diagnose digestive disorders, locate cysts and tumors, and guide insertion of instruments during surgical procedures.*

BARIATRIC SURGERY

- Group of procedures that treat morbid obesity.
 - *Commonly employed bariatric surgeries include vertical banded gastroplasty and Roux-en-Y gastric bypass.*

VERTICAL BANDED GASTROPLASTY

- ❑ Bariatric surgery in which the upper stomach near the esophagus is stapled vertically to reduce it to a small pouch and a band is inserted that restricts and delays food from leaving the pouch, causing a feeling of fullness.

ROUX-EN-Y GASTRIC BYPASS (RGB)

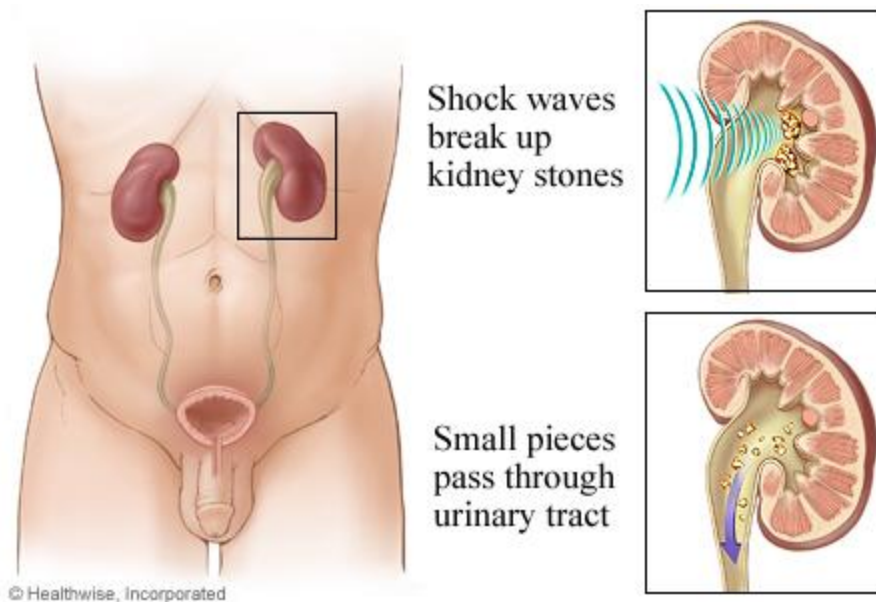
- Bariatric surgery in which the stomach is first stapled to decrease it to a small pouch and then the jejunum is shortened and connected to the small stomach pouch, causing the base of the duodenum leading from the nonfunctioning portion of the stomach to form a Y configuration, which decreases the pathway of food through the intestine, thus reducing absorption of calories and fats.
 - *RGB is performed laparoscopically using instruments inserted through small incisions in the abdomen. When laparoscopy is not possible, gastric bypass can be performed as an open procedure (laparotomy) and involves a large incision in the middle of the abdomen. RGB is the most commonly performed weight loss surgery today.*

LITHOTRIPSY

- ❑ Procedure for eliminating a stone within the gallbladder or urinary system by crushing the stone surgically or using a noninvasive method, such as ultrasonic shock waves, to shatter it.
 - *The crushed fragments may be expelled or washed out.*

EXTRACORPOREAL SHOCKWAVE LITHOTRIPSY (ESWL)

- Use of shock waves as a noninvasive method to destroy stones in the gallbladder and biliary ducts.
 - *In ESWL, ultrasound is used to locate the stone or stones and monitor their destruction. The patient usually undergoes a course of oral dissolution drugs to ensure complete removal of all stones and stone fragments.*



NASOGASTRIC INTUBATION

- ❑ Insertion of a nasogastric tube through the nose into the stomach.
 - *Nasogastric intubation is used to relieve gastric distention by removing gas, gastric secretions, or food. It is also used to instill medication, food, or fluids or obtain a specimen for laboratory analysis.*