

See discussions, stats, and author profiles for this publication at: <https://www.researchgate.net/publication/335686805>

# Biomedical Signal Processing and Analysis Techniques: Challenges and Applications

Presentation · September 2019

CITATIONS

0

READS

8,589

1 author:



Md. Kafiul Islam

Independent University, Bangladesh

114 PUBLICATIONS 1,089 CITATIONS

SEE PROFILE

Some of the authors of this publication are also working on these related projects:



Design and Development of a EOG-based System to Control Electric Wheelchair for People Suffering from Quadriplegia/Quadriplegia [View project](#)



Development of a Software GUI for Artifact Removal from Neural Signals [View project](#)



Department of  
**Electrical & Electronic Engineering**  
Independent University, Bangladesh

# Biomedical Signal Processing and Analysis Techniques: Challenges and Applications

1

Md. Kafiul Islam, PhD, SMIEEE

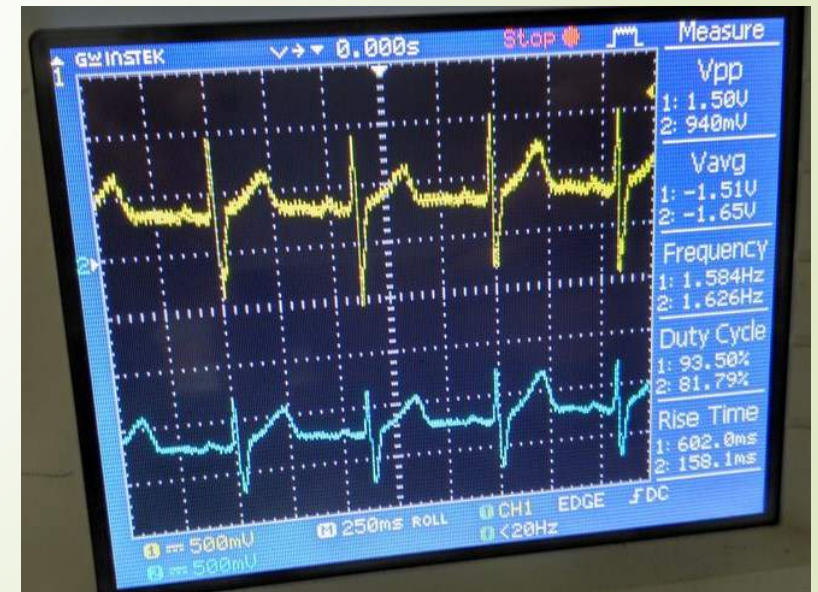Assistant Professor, Dept. of EEE, IUB

Lab Head, **Biomedical Instrumentation and Signal Processing Lab**

Web: [https://www.researchgate.net/profile/Md\\_Kafiul\\_Islam](https://www.researchgate.net/profile/Md_Kafiul_Islam)

Email: [kafiul\\_islam@iub.edu.bd](mailto:kafiul_islam@iub.edu.bd)

Dr. Md. Kafiul Islam



# About Us!

2

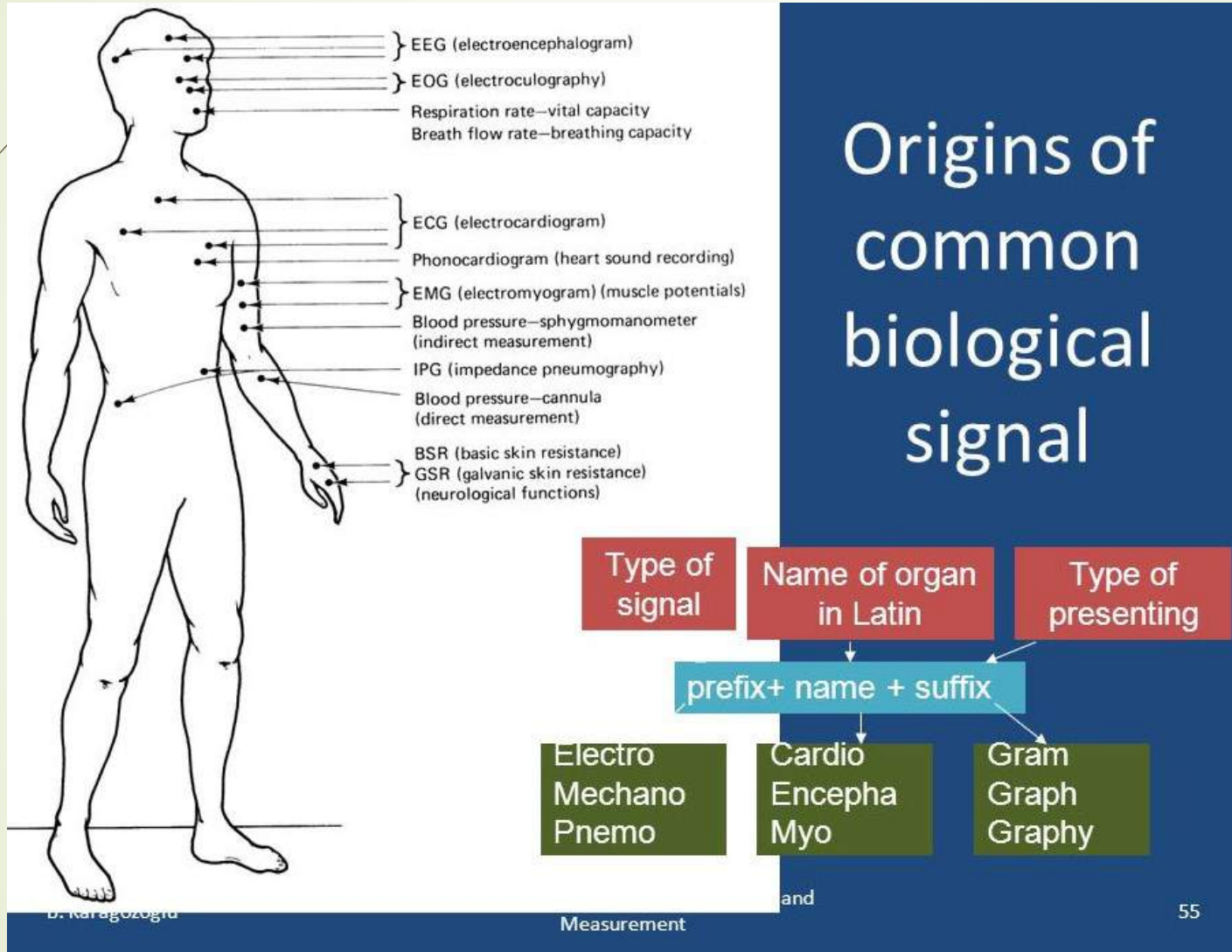
## Biomedical Instrumentation and Signal Processing Lab

### Featured Projects:

1. **EOG** based Computer **Mouse Cursor Control** for Physically Challenged People
2. Design and Development of a **EOG**-based System to **Control Electric Wheelchair** for People Suffering from Quadriplegia/Quadriparesis
3. Design and Implementation of a Low-cost **EMG** Signal Recorder for Application in **Prosthetic Arm** Control for Developing Countries.
4. Development of a Low Cost and Portable **ECG Monitoring System** for Rural/Remote Areas of Bangladesh
5. Video Category (**Emotion**) Classification using Wireless **EEG** Devices
6. Motion Artifact Removal from Ambulatory **EEG**

# Background<sup>1</sup>

3



Dr. Md. Kafiul Islam

[1] <https://slideplayer.com/slide/9446025/>

# Motivation (Application)

## Patient › Signals › Processing › Decision<sup>2</sup>

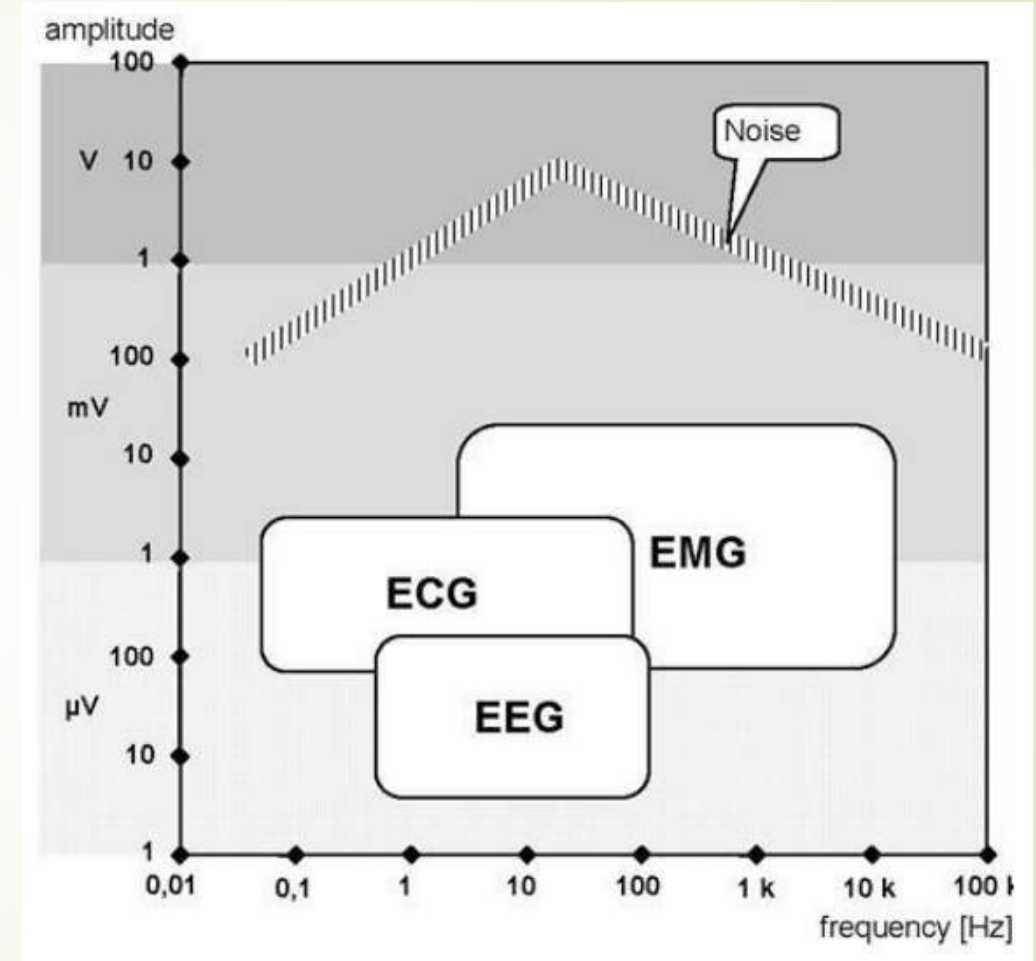
- Patient Monitoring (critical care)
  - ICU, Coma, NICU
- Disease Detection/Diagnosis
  - Heart (ECG), Brain (EEG), Muscle (EMG), etc.
- Preventive Healthcare (Prediction)
- Human-Machine Interfacing (HMI)
  - BCI, BMI, HMI, etc.
  - Controlling wheelchair, prosthetic arm
- Treatment and Rehabilitation
- Basic understanding of the organ's physiology and function

Dr. Md. Kafiul Islam

[2] <https://www.embs.org/about-biomedical-engineering/our-areas-of-research/biomedical-signal-processing/>

# Challenges with Biomedical Signals<sup>3</sup>

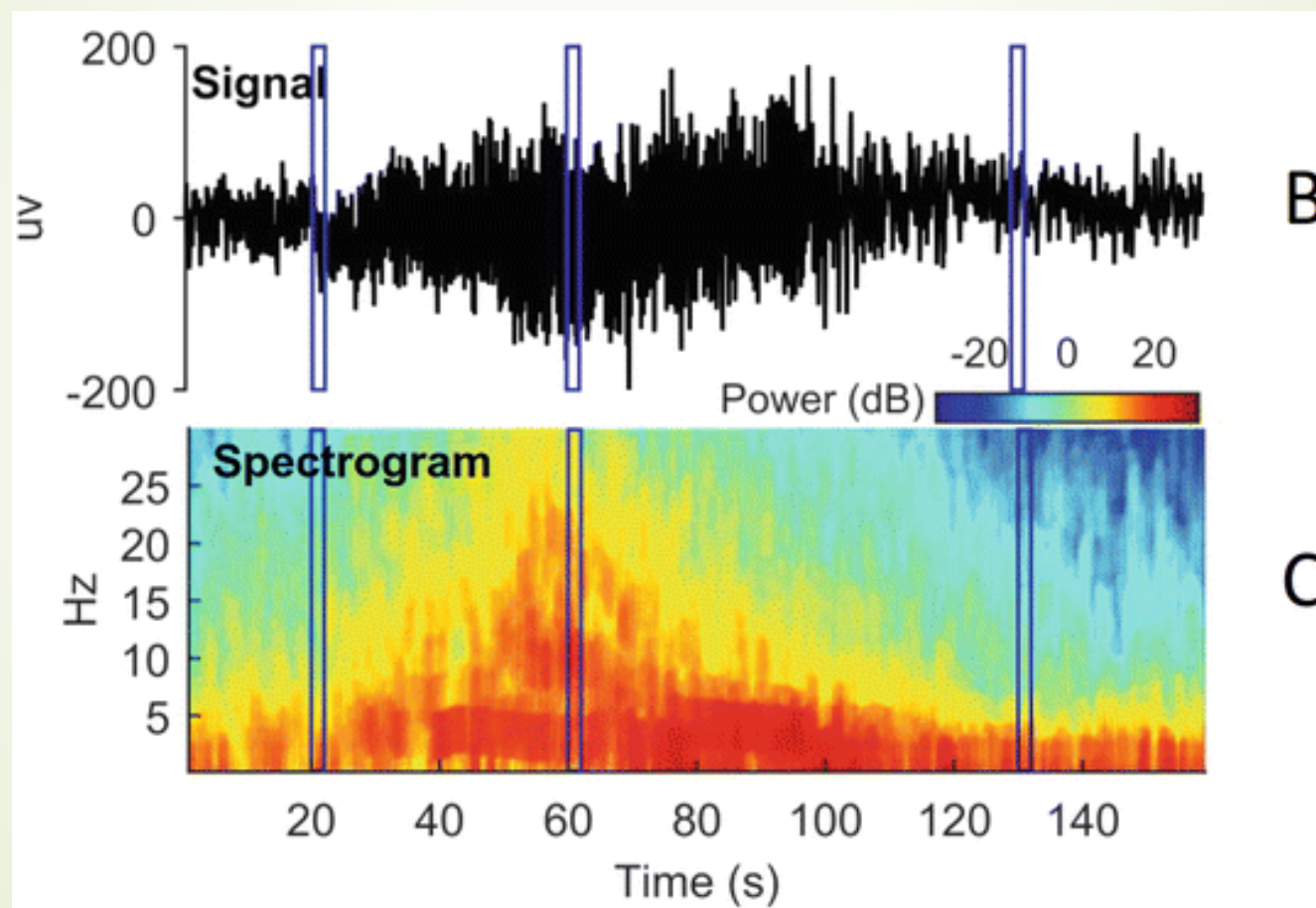
- Very **low** SNR
- **Non-stationarity** and **non-linearity** properties of biosignals
- **Diverse** types of noise
- Noise and Artifacts **overlap** both in Spectral and Temporal Domain
- False alarms and errors can **mislead** the diagnosis, treatment or control of any external devices
- **Traditional** Signal processing techniques fail



# Advanced Signal Analysis & Processing Techniques

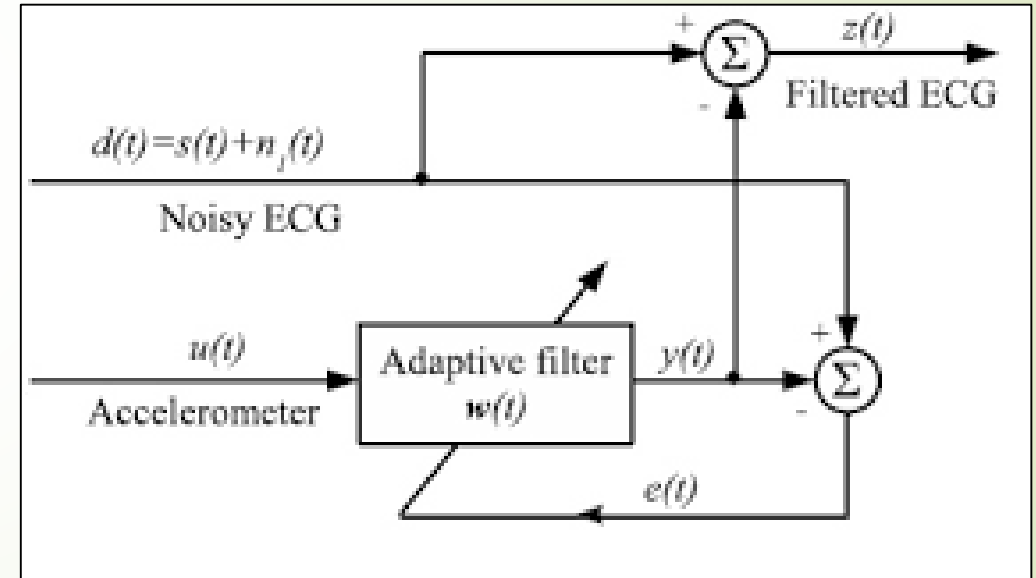
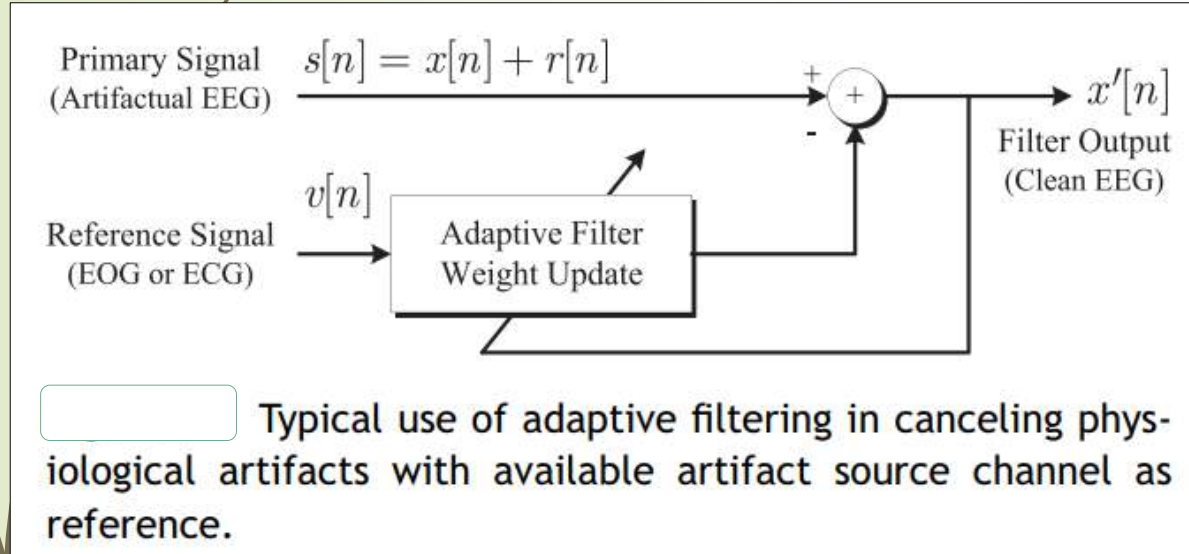
- ❑ Fourier Transform / PSD (pwelch)
- ❑ Adaptive filtering (use of **reference** channel)
- ❑ A-priori user input required
  - Wiener/Kalman/Particle Filtering
- ❑ Blind Source Separation
  - **ICA**/CCA/MCA
- ❑ Time-series Analysis
  - Wavelet transform / Spectrogram (STFT)
- ❑ Empirical Techniques
  - HHT/EMD/EEMD

# Spectrogram (using STFT)<sup>4</sup>





# Adaptive Filtering (for ECG Noise Removal<sup>5</sup> and EEG Artifact Removal<sup>6</sup>)

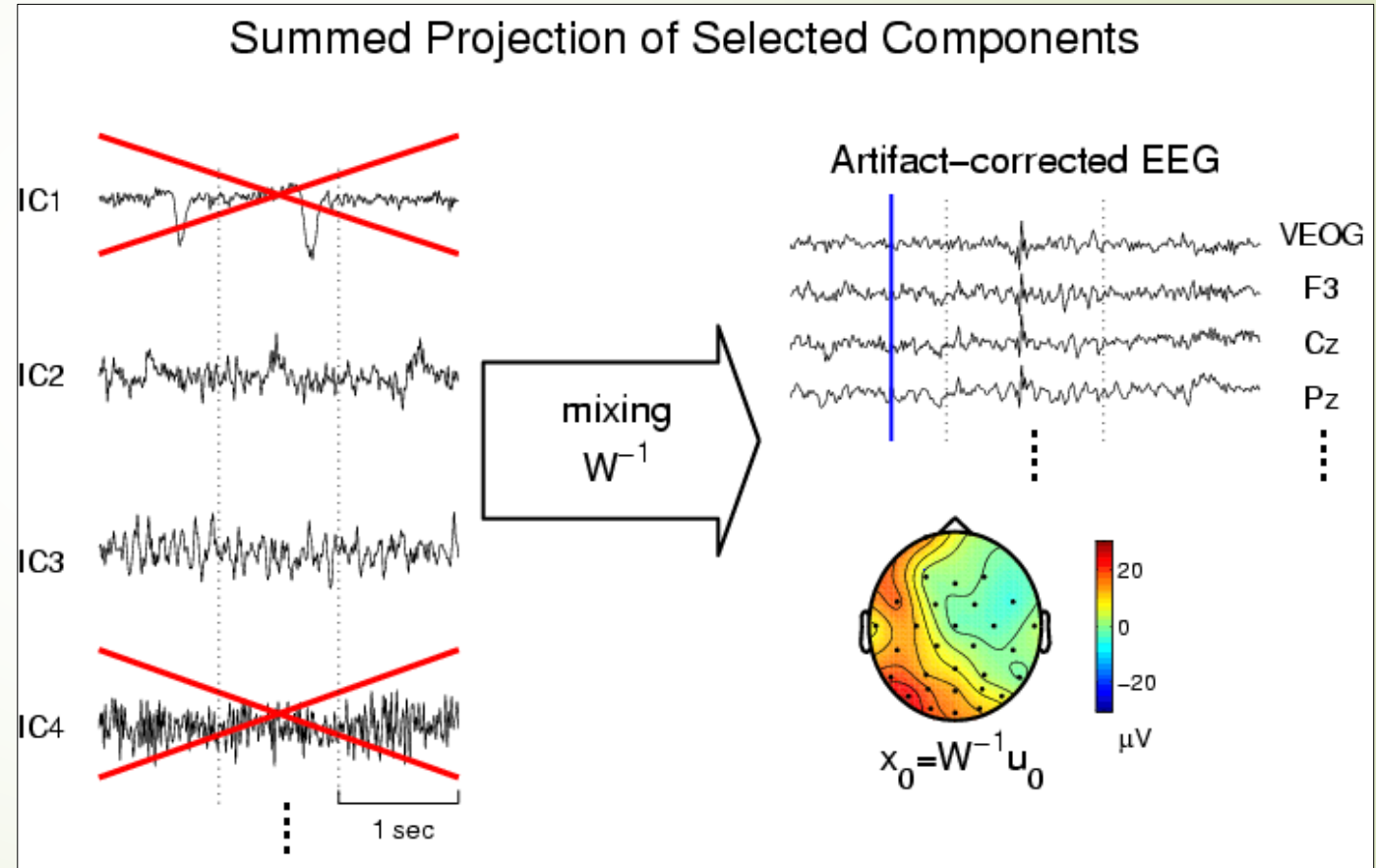
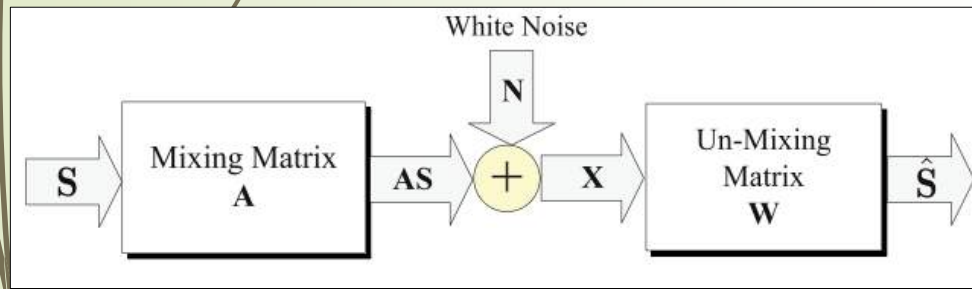


[5] <http://www.jscholaronline.org/articles/JBER/Signal-Processing.pdf>

[6] <https://www.sciencedirect.com/science/article/pii/S098770531630199X>

# Independent Component Analysis (ICA)

(for EOG and EMG artifact removal from EEG<sup>7</sup>)



# Wavelet Transform

## (A Multi-resolution Analysis)

- Split Up the Signal into a Bunch of Signals
- Representing the Same Signal, but all Corresponding to Different Frequency Bands
- Only Providing What Frequency Bands Exist at What Time Intervals

$$\text{CWT}_x^\psi(\tau, s) = \Psi_x^\psi(\tau, s) = \frac{1}{\sqrt{|s|}} \int x(t) \cdot \psi^*\left(\frac{t - \tau}{s}\right) dt$$

**Translation**  
(The location of the window)

**Scale**

**Mother Wavelet**

### Wavelet

- Small wave
- Means the window function is of finite length

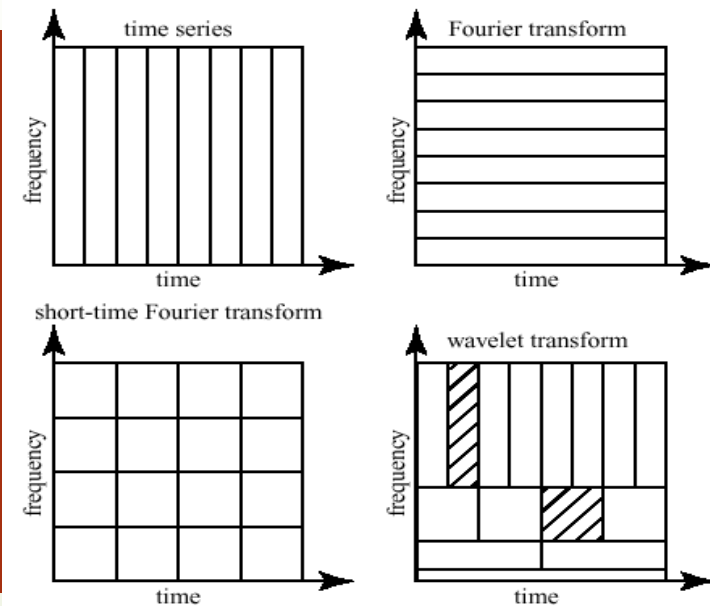
### Mother Wavelet

- A prototype for generating the other window functions
- All the used windows are its dilated or compressed

Dr. Md. Kafiul Islam

and shifted versions

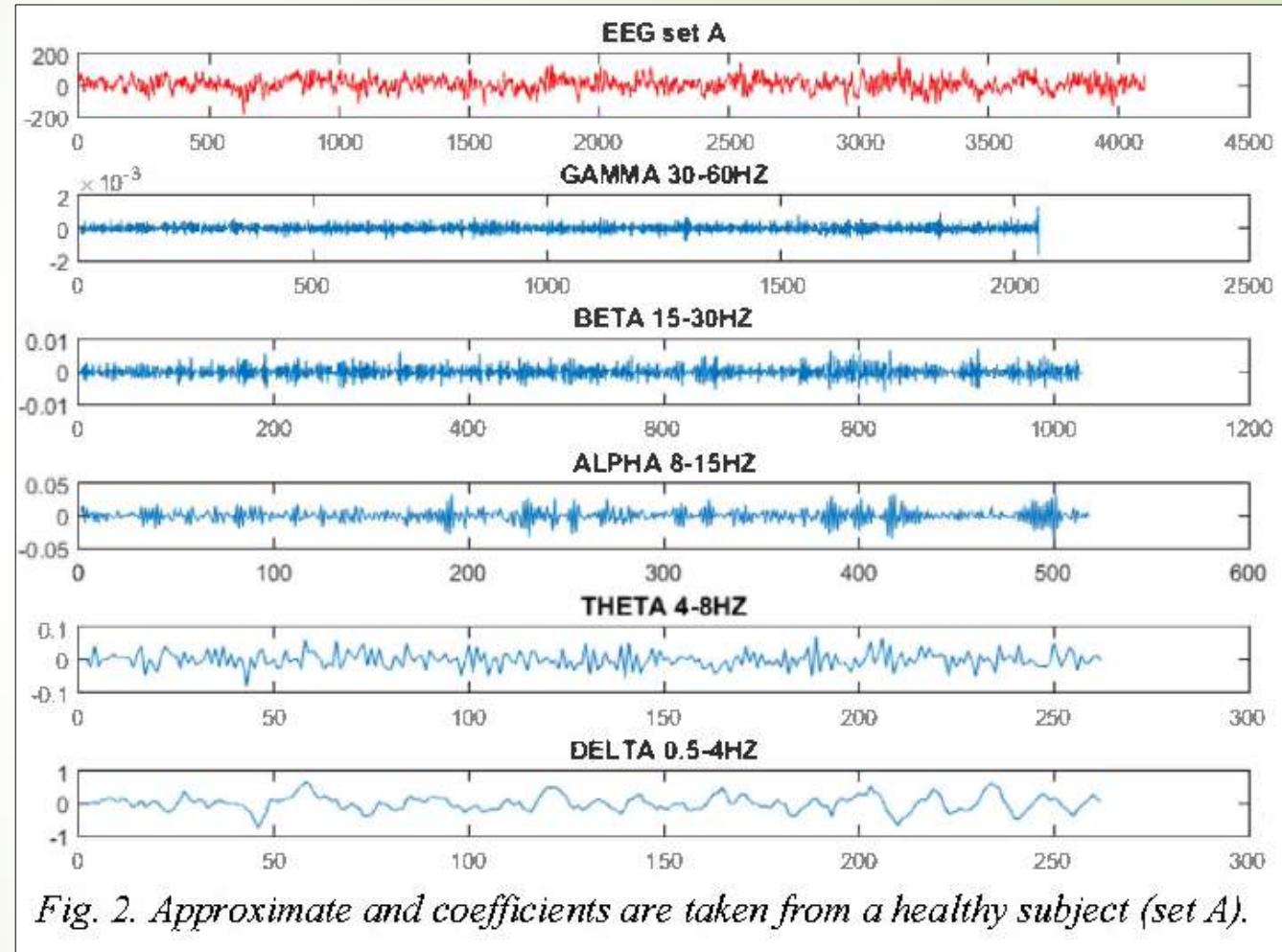
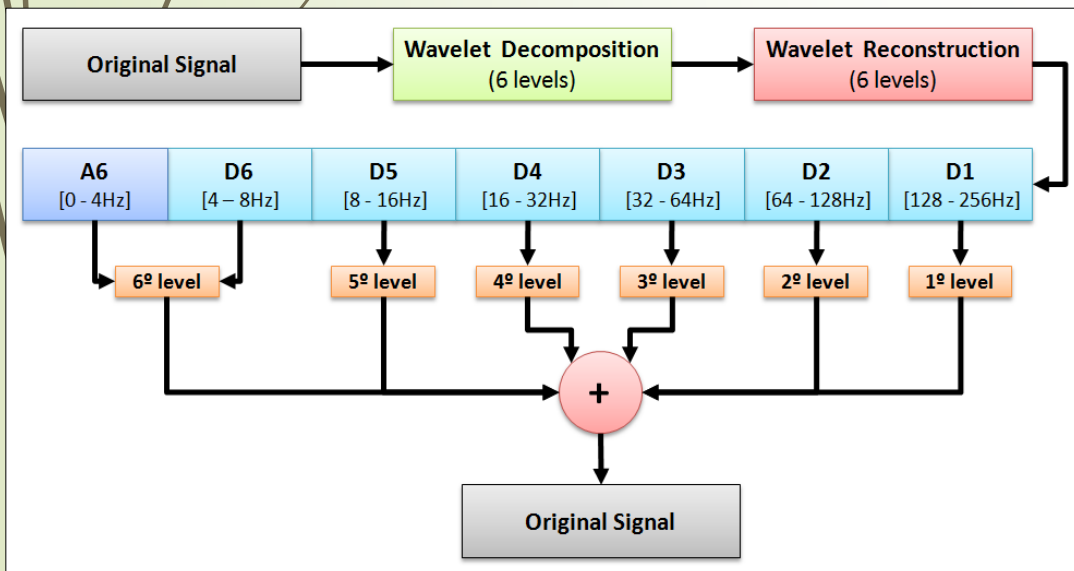
**Scale**  $S > 1$ : dilate the signal  
 $S < 1$ : compress the signal



# Wavelet Transform on EEG Signals

(for separating different EEG sub-band rhythms<sup>8</sup>)

Rhythm or Transient	EEG Signal Component	Freq. Band (Hz)
Rhythm	Delta	< 4
	Theta	4 – 8
	Alpha	8 – 13
	Beta	14 – 30
	Gamma	> 30
Transient	Seizure Activities	0.5 – 30



[8] <http://ieeexplore.ieee.org/stamp/stamp.jsp?tp=&arnumber=7856467>

# EMD on EEG Signals

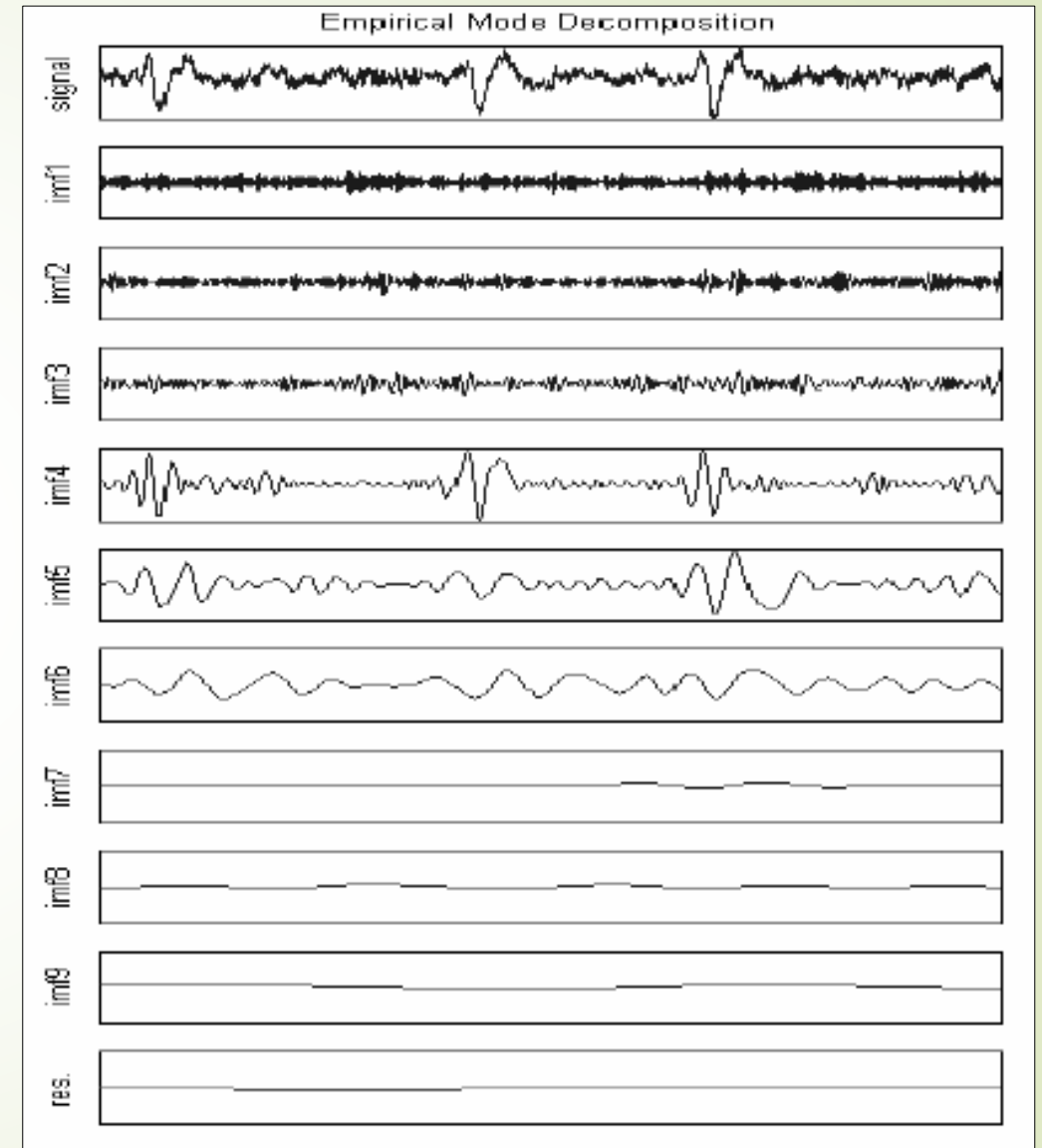
(for detecting Eye-blink artifacts<sup>9</sup>)

Process flow of EMD algorithm to generate IMFS.

Input: data sequence  $s[n]$

1. Identify all the local extrema
2. Separately connect all the maxima and minima with natural cubic spline lines to form the upper,  $u[n]$ , and lower,  $l[n]$ , envelopes
3. Find the mean of the envelopes as  $z[n] = [u[n] + l[n]]/2$
4. Take the difference between the data and the mean as the proto-IMF,  $h[n] = s[n] - z[n]$
5. Check the proto-IMF against the definition of IMF and the stoppage criterion to determine if it is an IMF
6. If the proto-IMF does not satisfy the definition, repeat step 1 to 5 on  $h[n]$  as many time as needed till it satisfies the definition
7. If the proto-IMF does satisfy the definition, assign the proto-IMF as an IMF component,  $c[n]$
8. Repeat the operation step 1 to 7 on the residue,  $q[n] = s[n] - c[n]$ , as the data
9. The operation ends when the residue contains no more than one extremum

Dr. Md. Kafiul Islam



# Brain Recordings!

13

## Non-Invasive

➤ **EEG** (electrical) and MEG (magnetic)

## ➤ Invasive

➤ Sub-scalp EEG (S-EEG)

➤ ECoG / iEEG

➤ Intracortical Implant

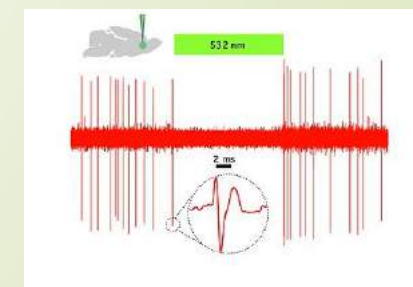

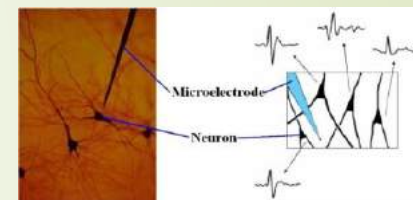
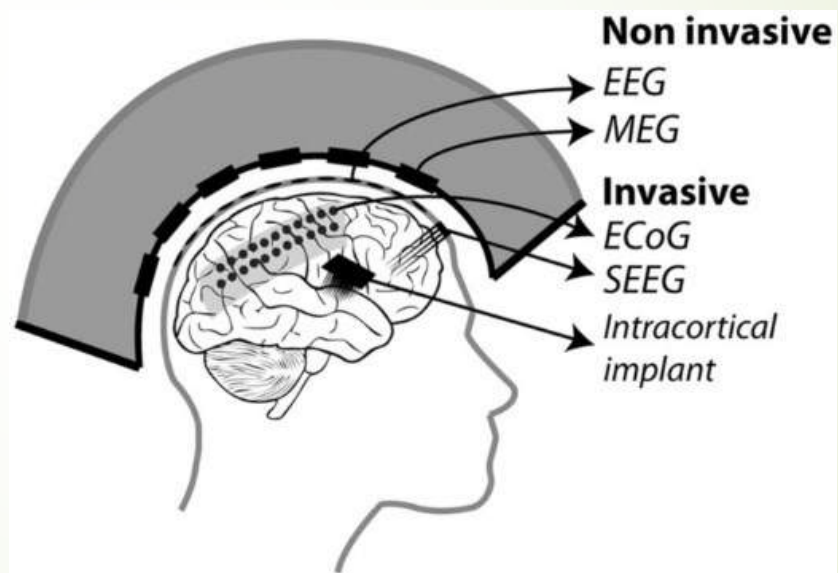
➤ Better signal quality but ...!?

Signal Type	Bandwidth (Hz)	Range (mV <sub>pp</sub> )
ECoG	0.1 ~ 64	0.02 ~ 1
EMG	1 ~ 128	0.02 ~ 1
LFPs	0.1 ~ 100	0.1 ~ 1
EAPs	100 ~ 10K	0.04 ~ 0.2
IAPs	100 ~ 10K	~ 100

Dr. Md. Kafiul Islam

## Motivation to record brain signals:


- How brain works?
  - Information processing
  - Memory formation
- Understanding neurological disorders & providing treatment



# What is EEG?

Electro-encephalo-gram = Electrical-Brain-Picture

- ▶ Recording of the brain's spontaneous electrical activity over a period of time by placing flat metal discs (electrodes) attached to the scalp.
- ▶ Measures voltage fluctuations resulting from ionic current within the neurons of the brain.
- ▶ Scalp-EEG: Most popular brain recording technique
  - ▶ Low cost
  - ▶ Non-invasive
  - ▶ Portable
  - ▶ Reasonable temporal resolution



The first human EEG recording obtained by **Hans Berger** in **1924**. The upper tracing is EEG, and the lower is a 10 Hz timing signal.

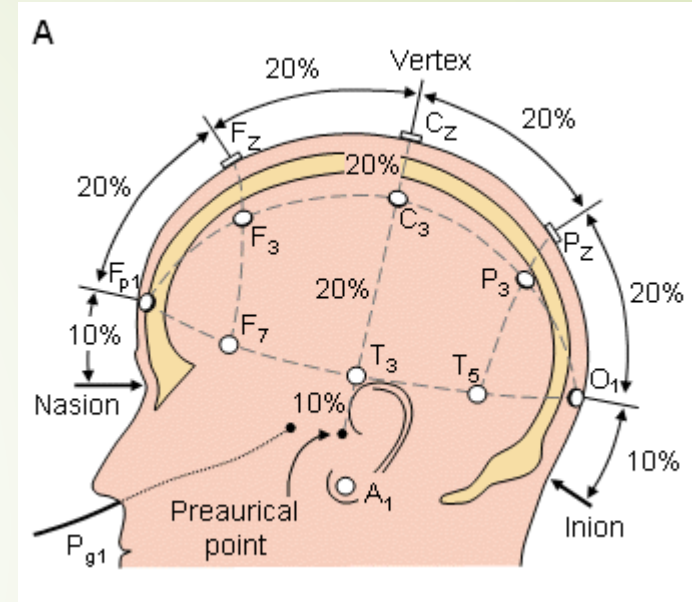
# EEG Acquisition

15

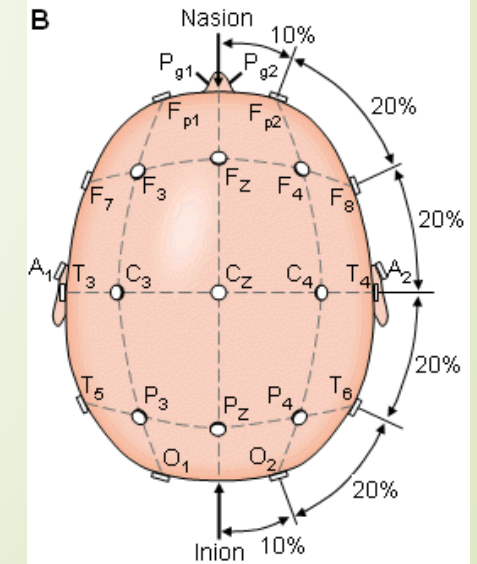
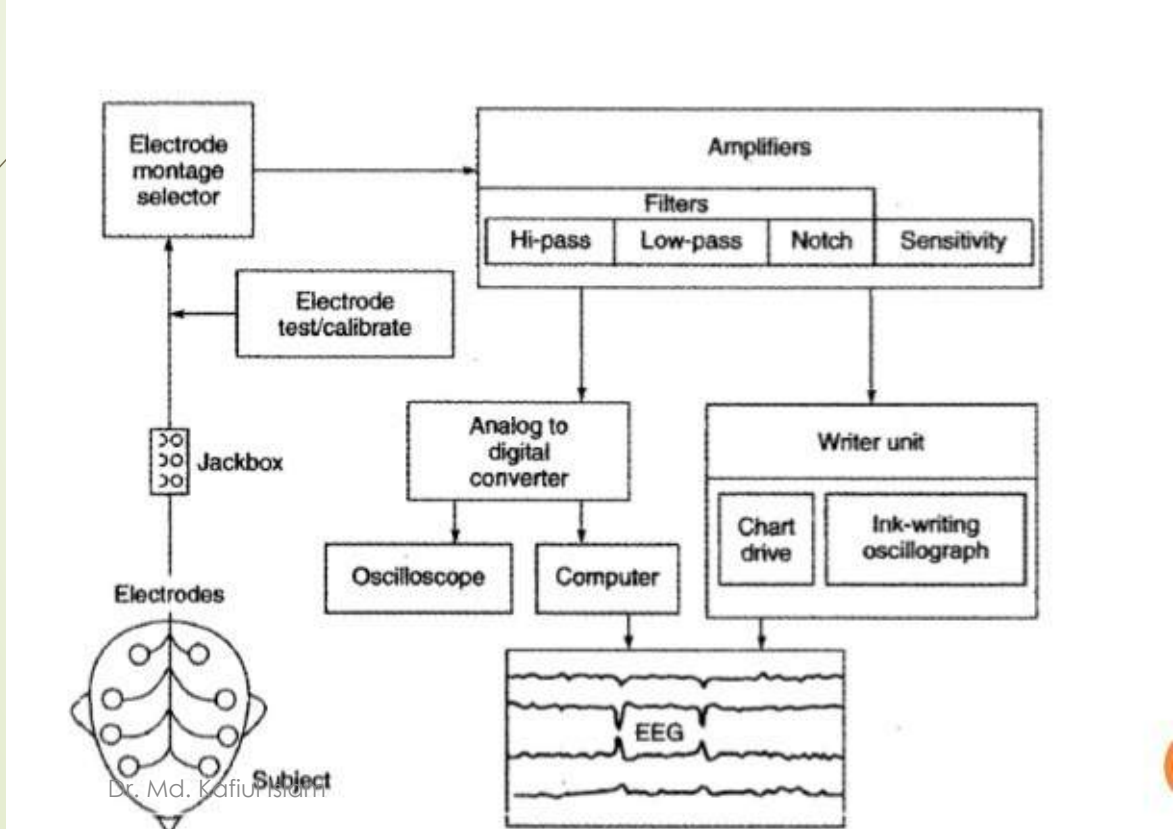
- ❑ Acquisition involves
  - ❑ Electrodes
  - ❑ Amplification (IA)
  - ❑ Filtering (Active)
  - ❑ Digitizing (ADC)
  - ❑ Storage

**Challenge:** To detect signal as low as  $10 \mu\text{V}$ !

## Standard 10-20 Electrode Montage



## SCHEMATIC DIAGRAM OF AN EEG MACHINE





# EEG Rhythms (Frequency Bands)

16

- **Rhythmic:** EEG activity consisting in waves of approximately constant frequency.
- **Arrhythmic:** EEG activity in which no stable rhythms are present.
- **Dysrhythmic:** Rhythms and/or patterns of EEG activity that characteristically appear in patient groups or rarely or seen in healthy subjects.

## ▶ **Delta: (< 4 Hz)**

- adult slow-wave sleep
- in babies
- continuous-attention tasks

## ▶ **Theta: (4 - 8 Hz)**

- higher in young children
- drowsiness in adults and teens
- idling

## ▶ **Alpha: (8 - 13 Hz)**

- relaxed/reflecting
- closing the eyes

## ▶ **Beta: (14 - 30 Hz)**

- active thinking, focus, high alert, anxious

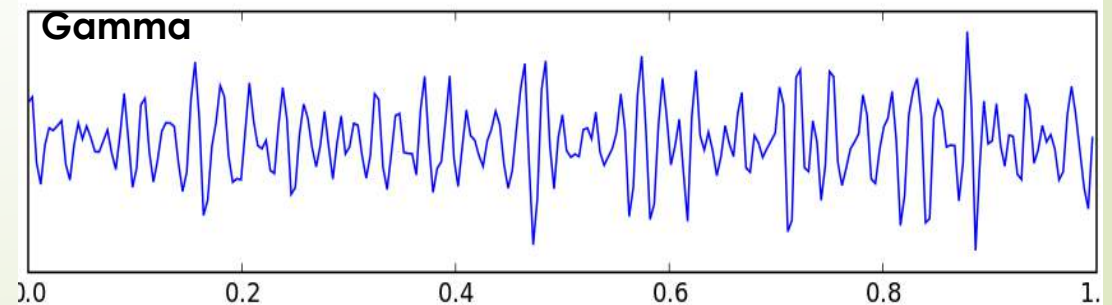
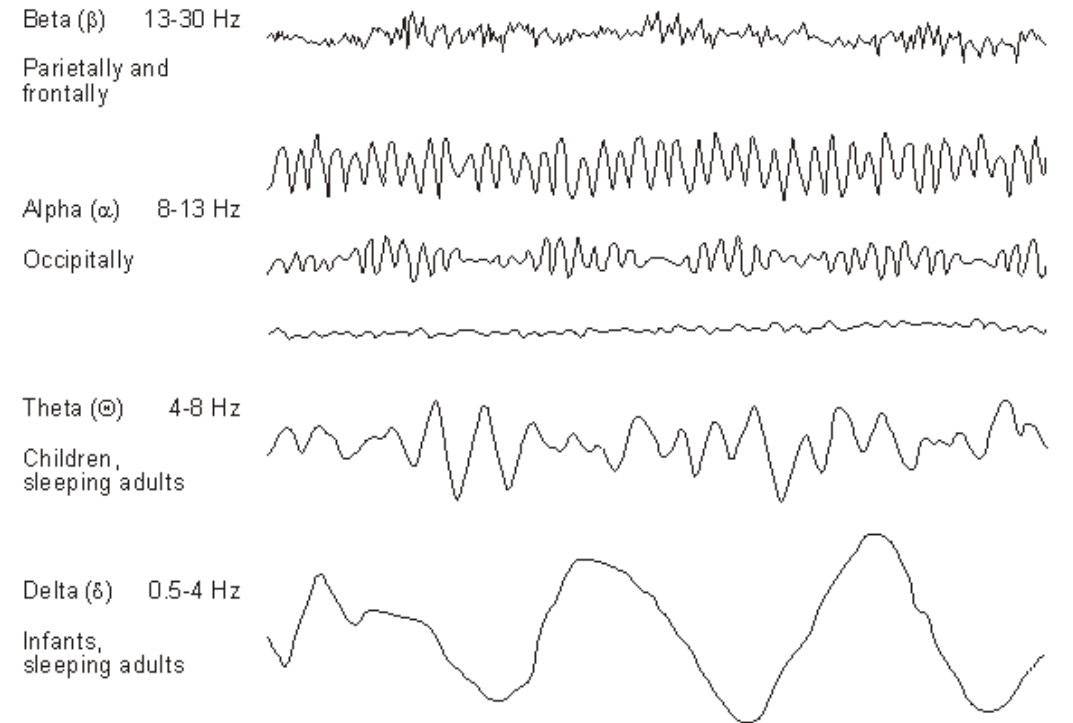
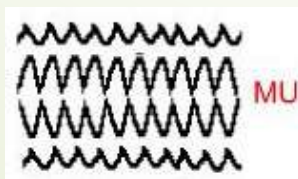
## ▶ **Gamma: (> 30 Hz)**

- Displays during cross-modal sensory processing

## ▶ **Mu: (7.5 - 12.5 Hz)**

- Shows rest-state motor neurons

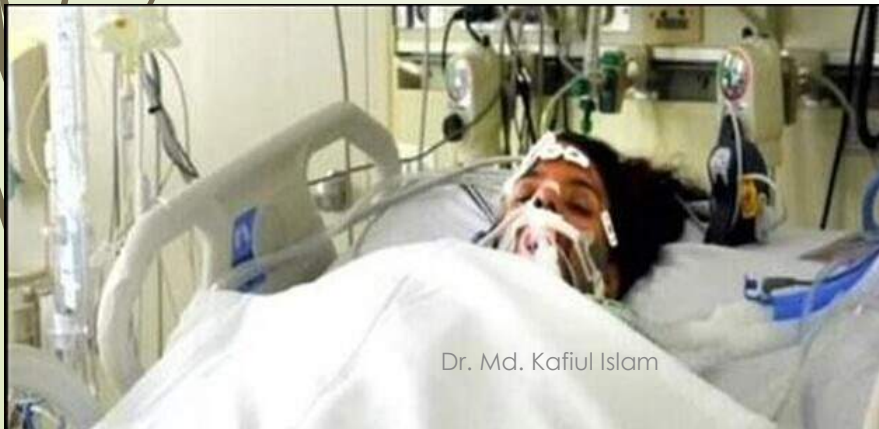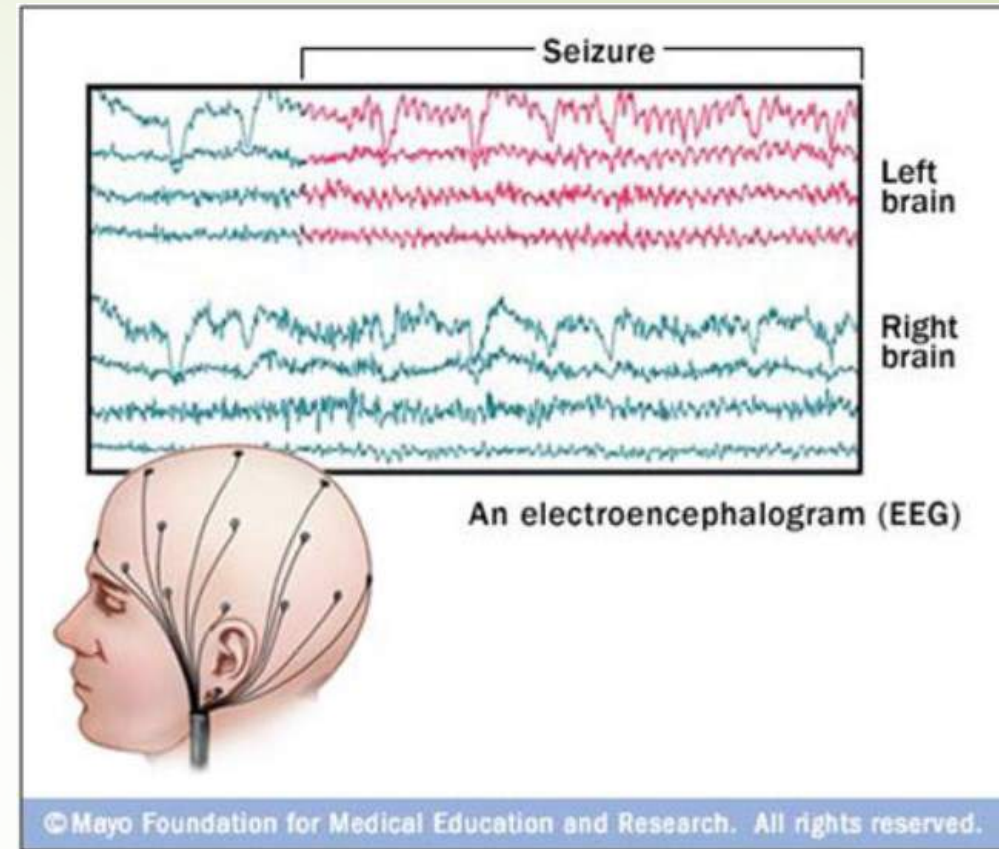
Dr. Md. Kafiul Islam



# Applications of EEG

17

- Epilepsy Diagnosis: Seizure Detection (Most Common)
- Also to diagnose sleep disorders, coma, encephalopathies, and brain death
- Brain-Computer Interface (BCI) / Neural Prosthesis
- Basic Neuroscience Research
- cognitive science, cognitive psychology, and psychophysiological research.



# Artifacts & Interferences in EEG<sup>10</sup>

18

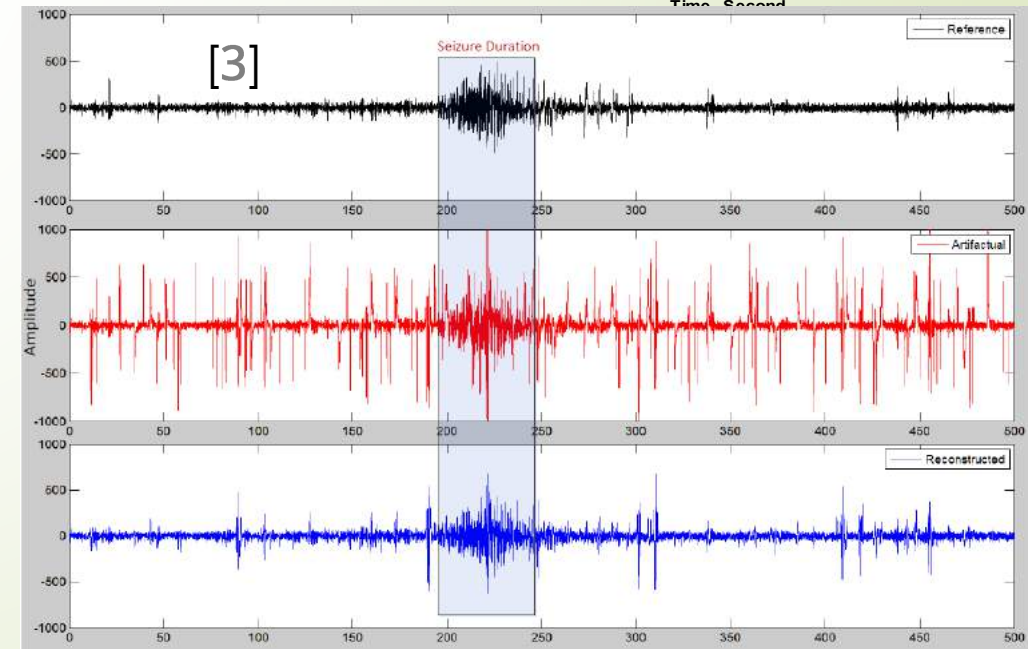
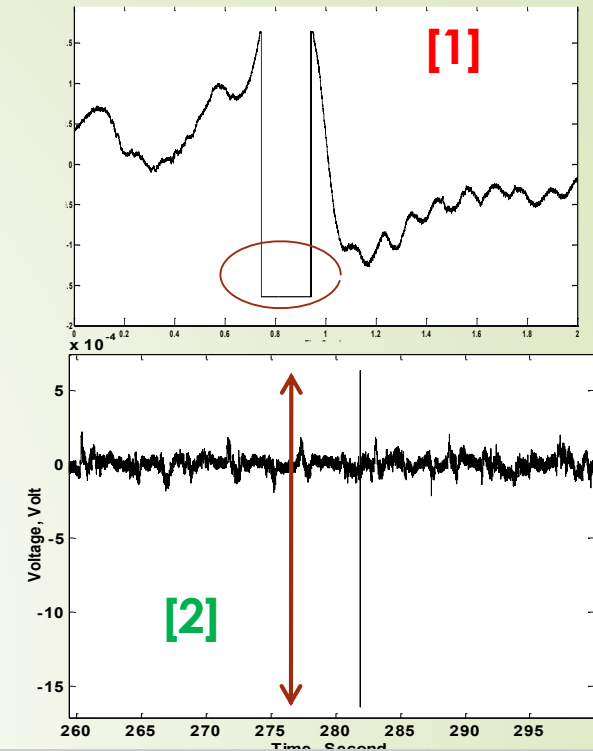
## Sources of Artifacts

- Environmental factors (e.g. power noise, sound/optical interference, EM-coupling from earth, etc.)
- Experiment factors (e.g. electrode position altering, connecting wire movement, etc. due to mainly subject motion )
- Physiological factors (e.g. EOG, ECG, EMG, etc.)

## Problems with Artifacts

- Can cause electronics saturation [1]
- High dynamic range required (Higher ENOB in ADC) [2]
- Increase false alarms in epileptic seizure detection [3]
- Mistakes in BCI classifications

[10] <https://emedicine.medscape.com/article/1140247-overview>



# Summery of Existing EEG Artifact Removal Methods

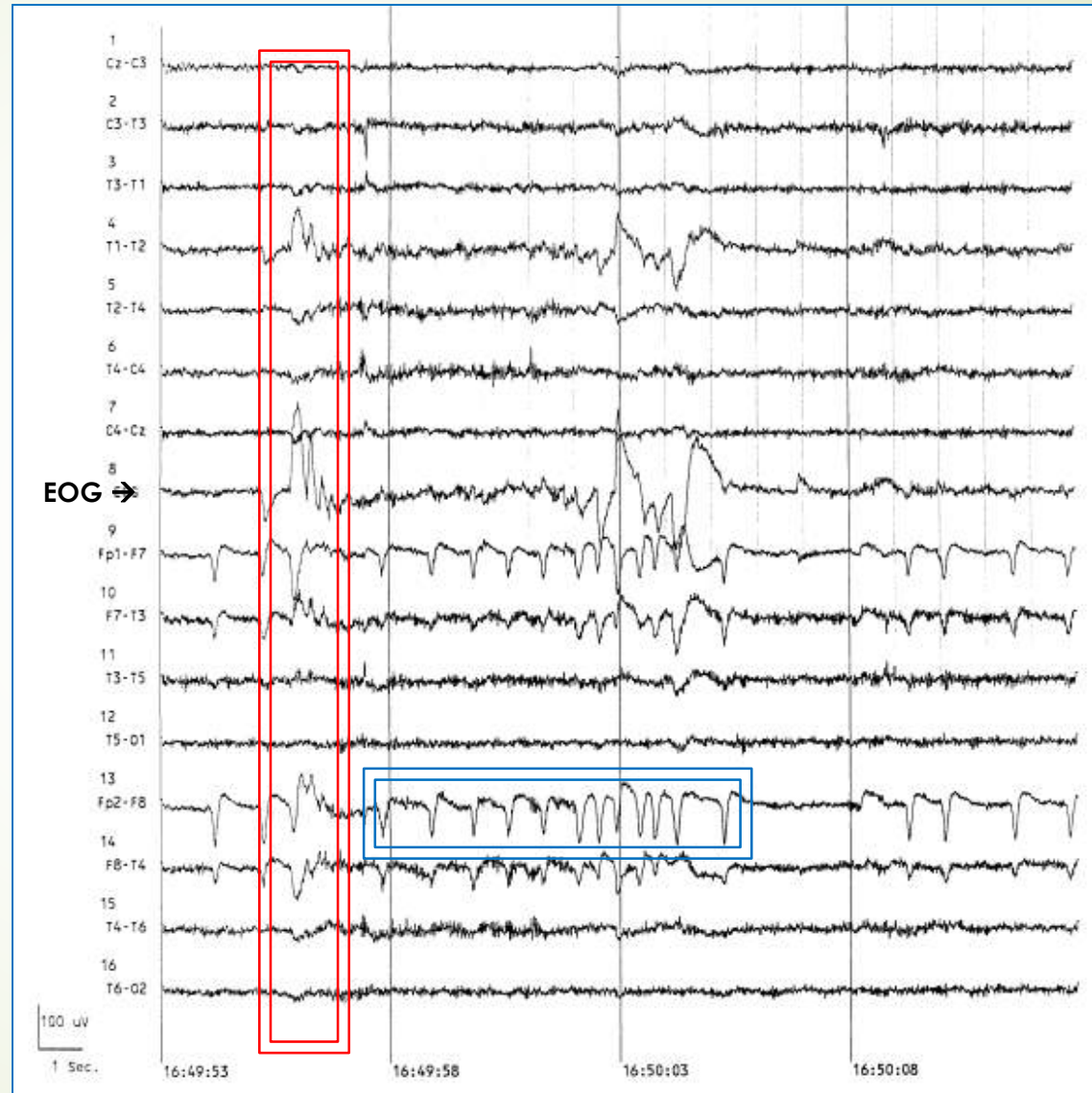
19

- Single artifact type
- Reference channel
- Mostly general purpose
- Often Manual or Semi-automatic
- Often suitable for Multi channel
- Real-time/Online processing capability
- Not enough quantitative evaluation
- Often after-effects not reported
- Lack of adequate dataset used
- Often hybrid methods (wICA, EEMD-CCA, etc.)

# Artifacts Found in EEG\* (1)

20

Horizontal Eye  
Movement (T1-T2)  
and  
Blink Artifacts  
(Frontal channels)



Dr. Md. Kafiul Islam

\*Chang, B. S., Schachter, S. C., & Schomer, D. L. (2005). *Atlas of ambulatory EEG*. Amsterdam ; London: Amsterdam ; London : Elsevier Academic Press, c2005.

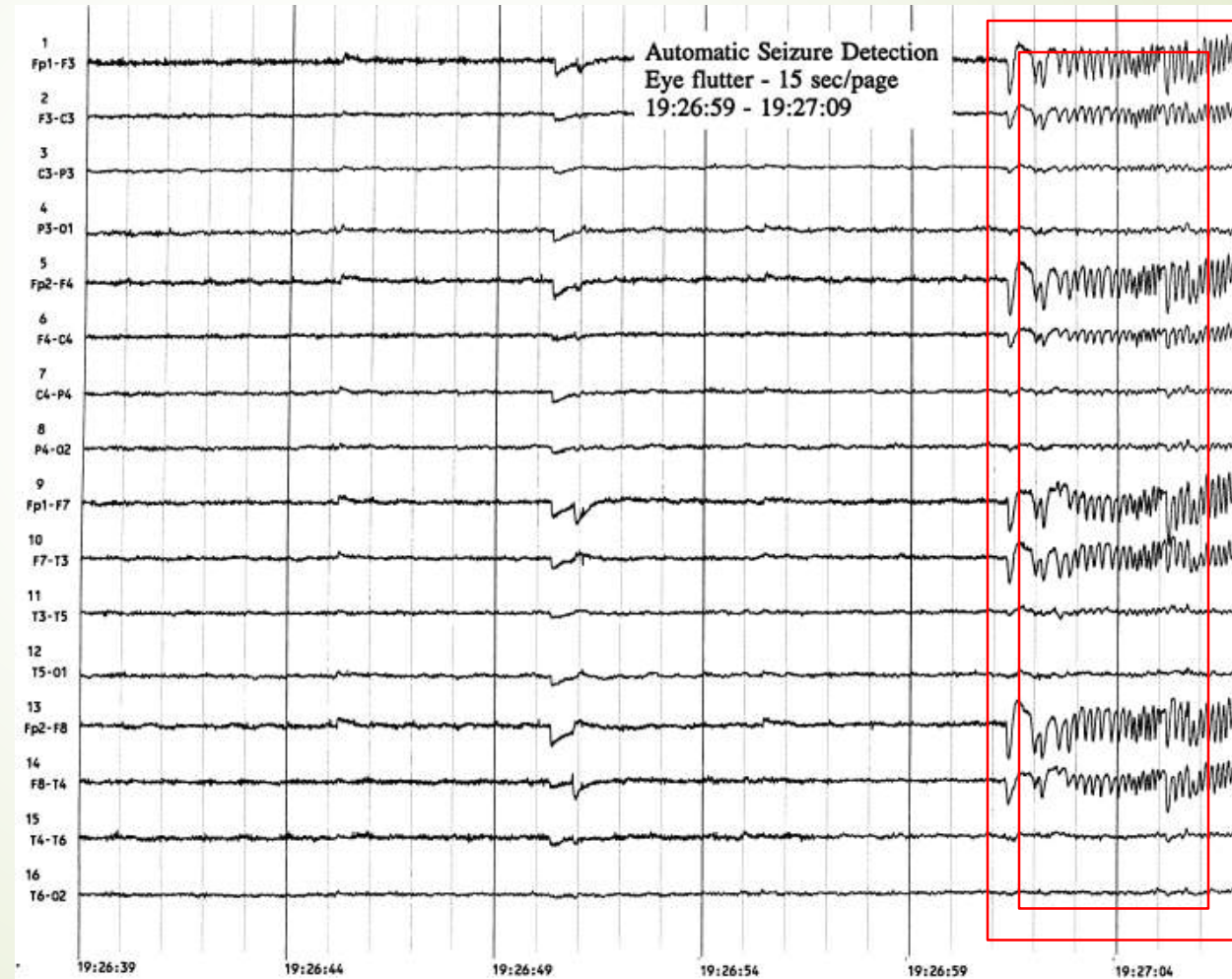
## Artifacts Found in EEG (2)

21

❑ Rhythmic eye flutter can occur at quite high frequencies, in this case 5–8 Hz, and trigger automated seizure detection algorithms.

❑ This artifact can be distinguished from ictal events in different ways, including the lack of evolution in frequency or amplitude over time.

**Eye Flutter Artifact  
recorded by Seizure  
Detection Algorithm**

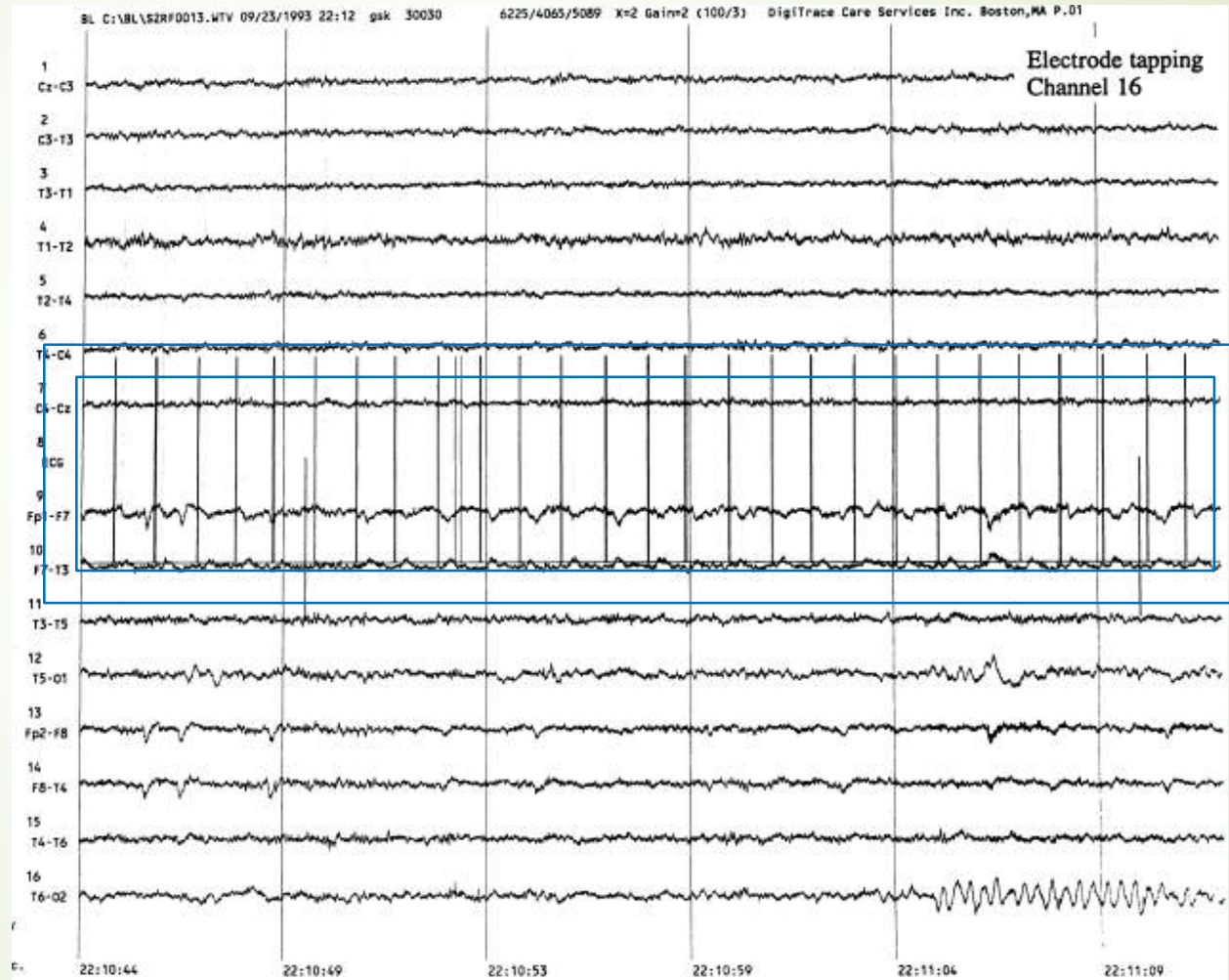


# Artifacts Found in EEG (3)

22

With ambulatory EEG recording, there may be periods in which the patient is scratching or pressing on the scalp electrodes.

## Electrode Tapping Artifact

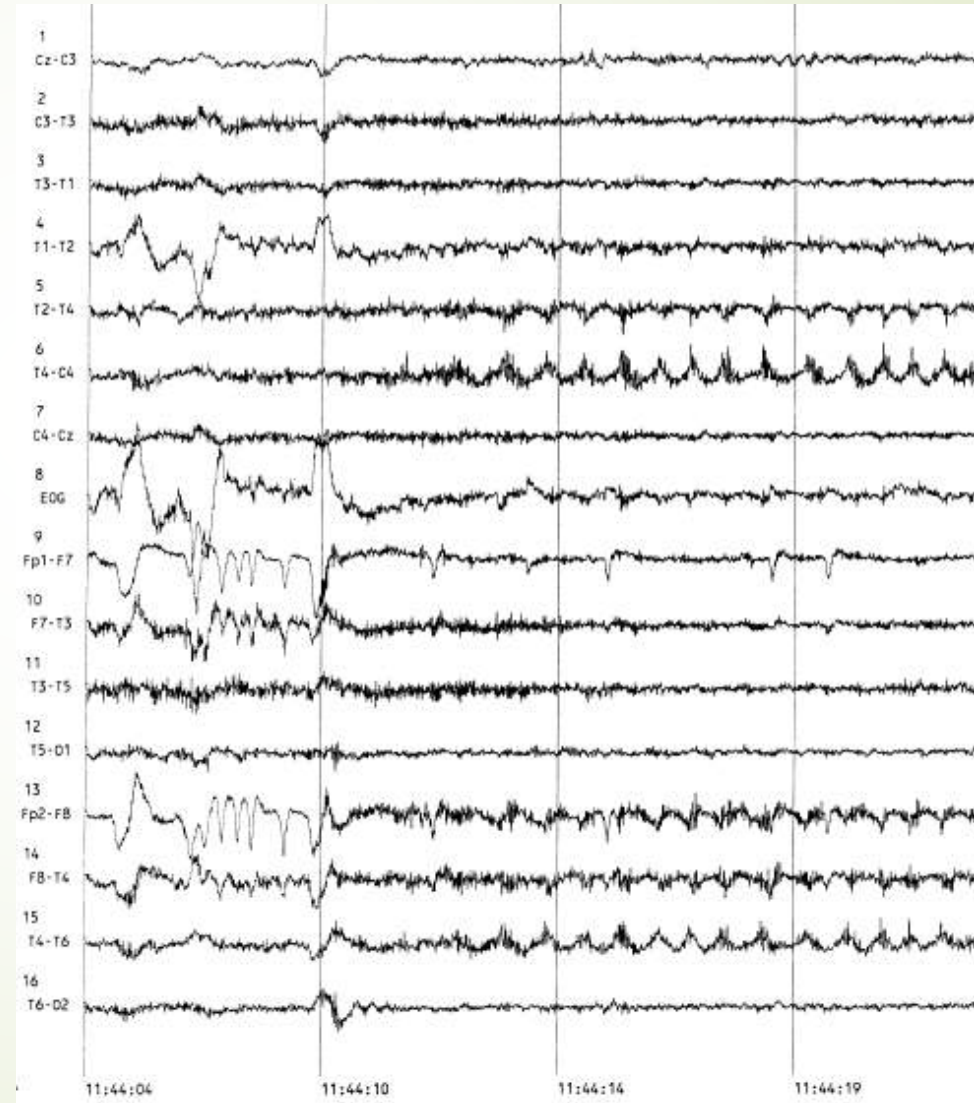


## Artifacts Found in EEG (4)

23

- ❑ Periods of jaw clenching and biting during ambulatory EEG recording can be associated with artifact.
- ❑ This activity is often most prominent over the **temporal regions**, presumably due to temporalis or masseter muscle contraction.

### Jaw-Clenching Artifact



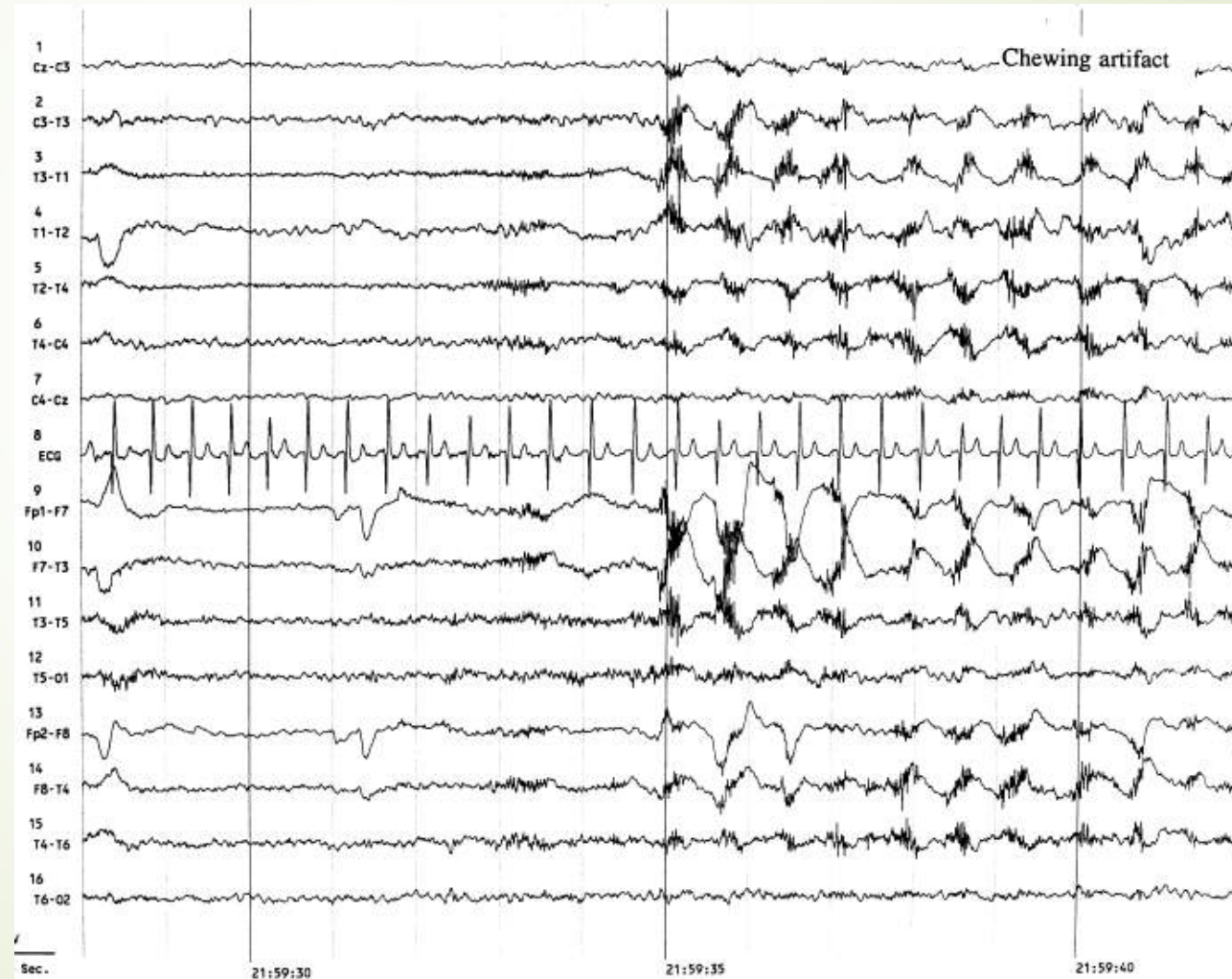


# Artifacts Found in EEG (5)

24

- ❑ Chewing artifact can often have rhythmic features and at times may resemble ictal activity.
- ❑ This artifacts are characterized by the rhythmic appearance of muscle artifact centered mostly over the **temporal** regions bilaterally.

## Chewing Artifact



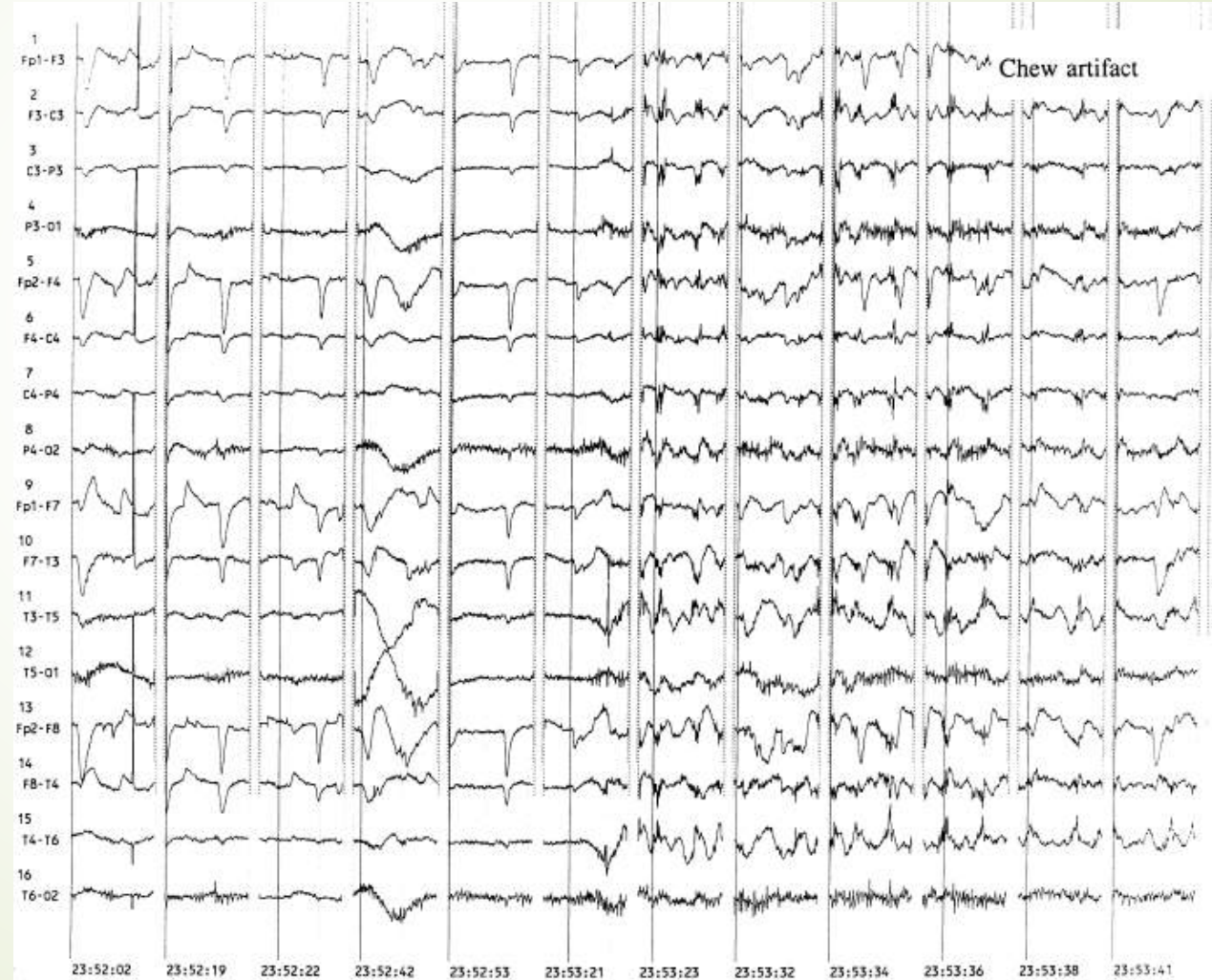# Artifacts Found in EEG (6)

25

❑ Chewing artifact can have rhythmic and sharp features, and can thus be picked up by automated detection algorithms.

❑ Here, the spike detections at 23:53:23 and at 23:53:34 capture high frequency sharp waveforms that are artifactual in nature, in association with a nighttime snack.

## Chewing Artifact Recorded by Spike Detection Algorithm

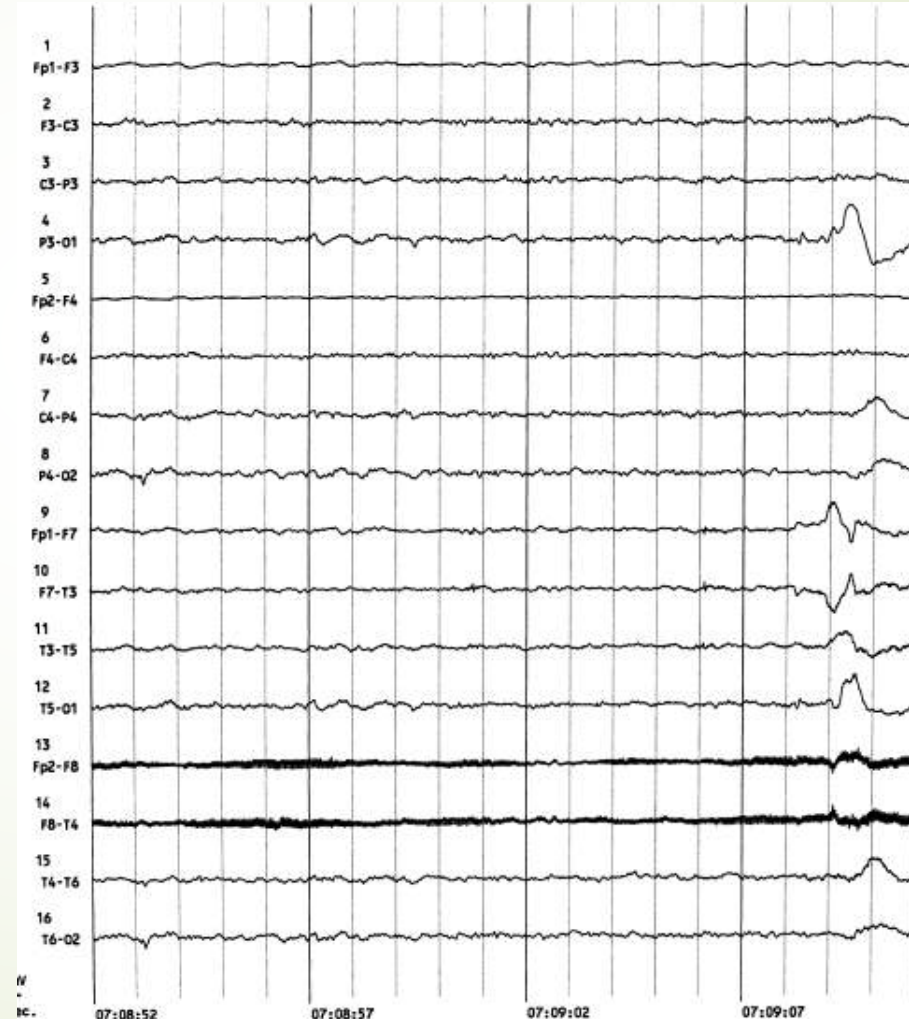


# Artifacts Found in EEG (7)

26

- ❑ One disadvantage of ambulatory EEG monitoring is the inability of technologists to check on recording quality frequently in real time and to respond with appropriate technical adjustments as needed throughout the day, as would typically occur in an inpatient monitoring unit.
- ❑ Here, a dry electrode at F8 causes an artifact seen throughout this excerpt.

## Dry Electrode Artifact

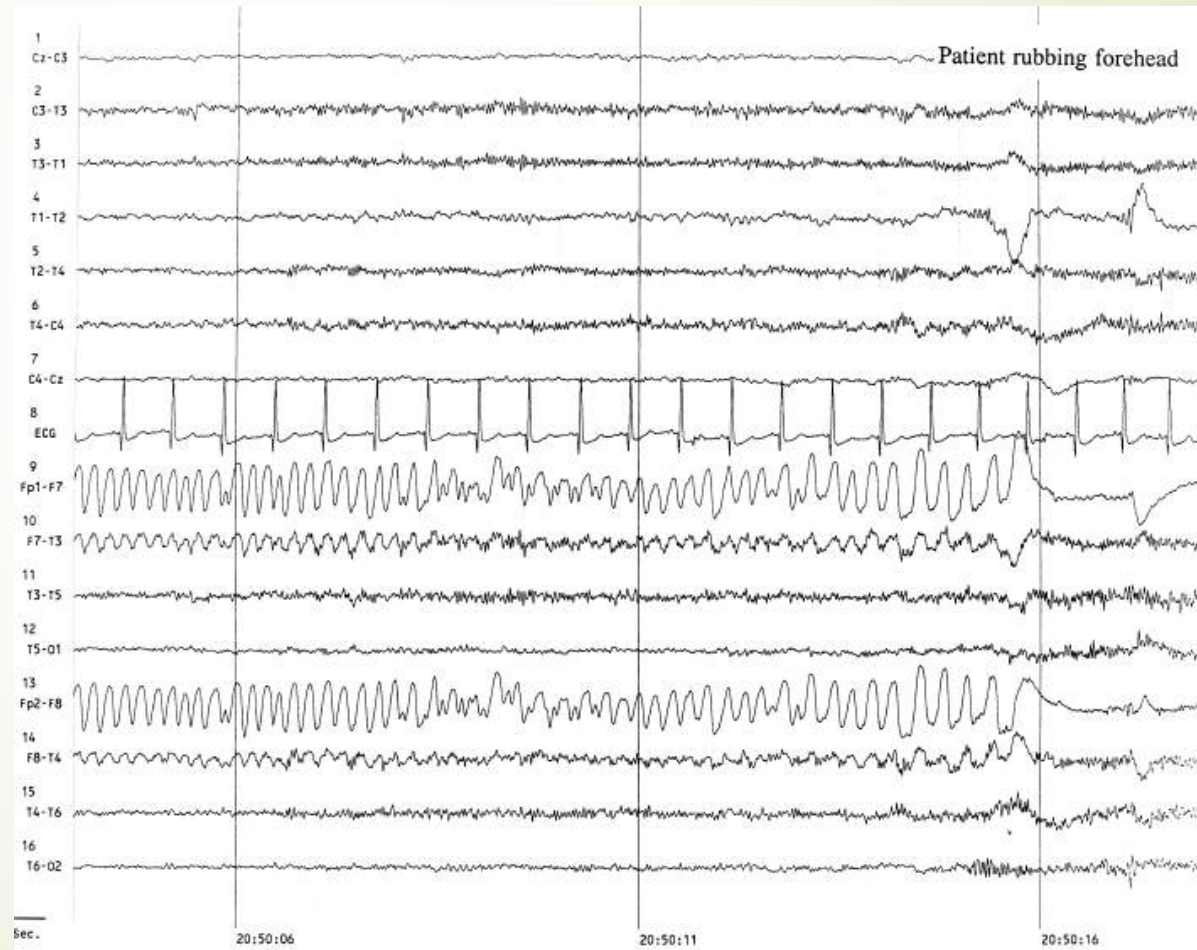


## Artifacts Found in EEG (8)

27

- ❑ As with many other patient movement artifacts, rhythmic rubbing artifact can be a potentially confusing finding on ambulatory EEG monitoring, particularly in the absence of concomitant video recording. Here, rhythmic rubbing of the forehead produces an artifact in the anterior channels, extending from the beginning of this excerpt through 20:50:16.
- ❑ Differentiation of such artifact from an ictal event, based on the lack of evolution of the artifact in frequency or amplitude, is critical.

### Forehead Rubbing Artifact

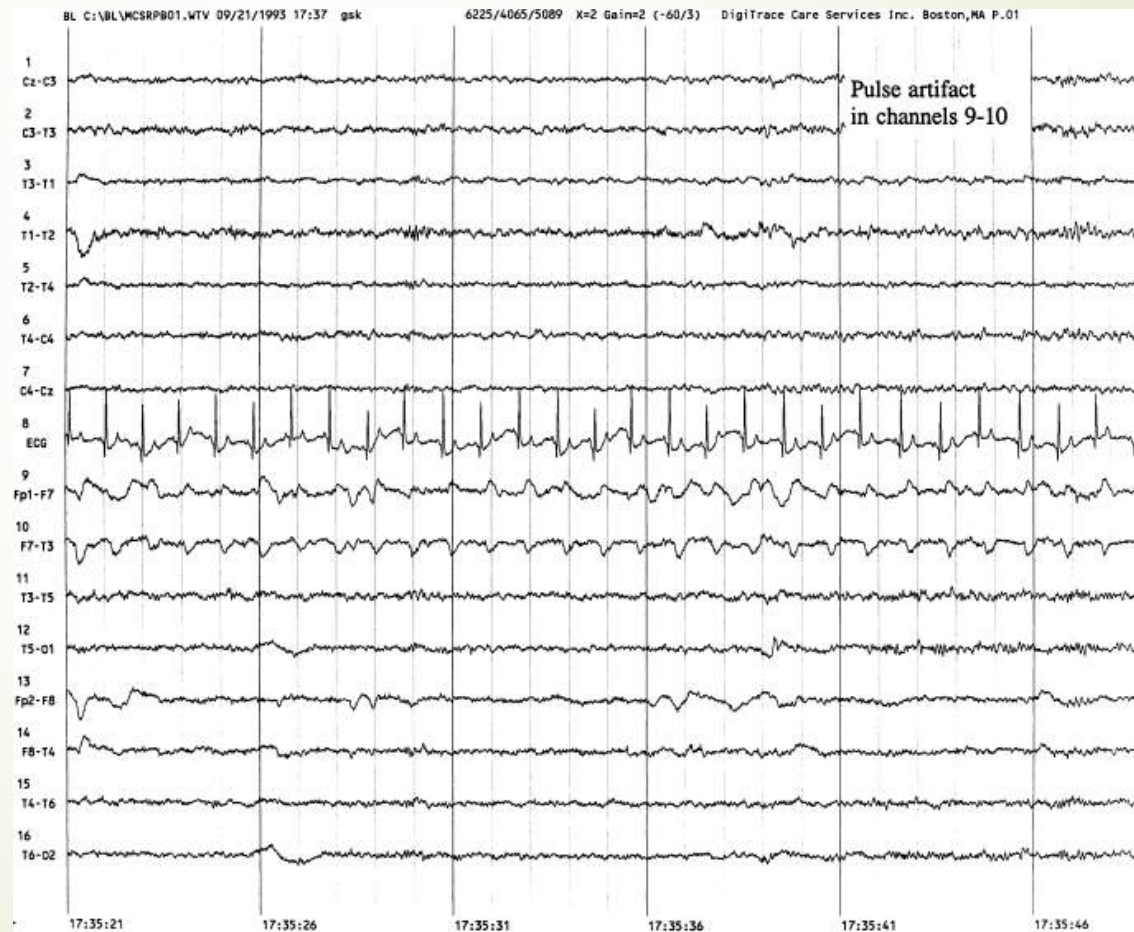


# Artifacts Found in EEG (9)

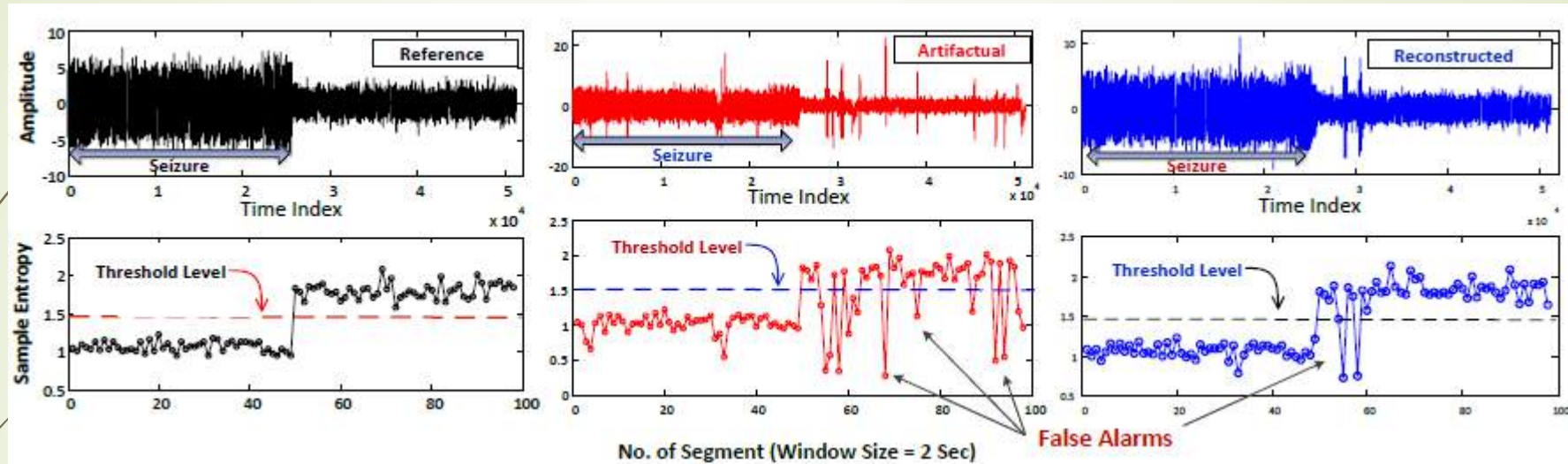
28

- ❑ Pulse artifact is caused by the rhythmic movement of scalp electrodes, usually over the temporal regions, by the pulsations of blood through vessels close to the skin, such as the superficial temporal artery.
- ❑ It is to be distinguished from the more common electrocardiographic (EKG) artifact in that pulse artifact is typically not as sharply contoured, resembles a slow wave, and follows the QRS complex rather than being simultaneous to it.
- ❑ Here, pulse artifact is seen in channels 9 and 10 over the left temporal region throughout this entire excerpt.

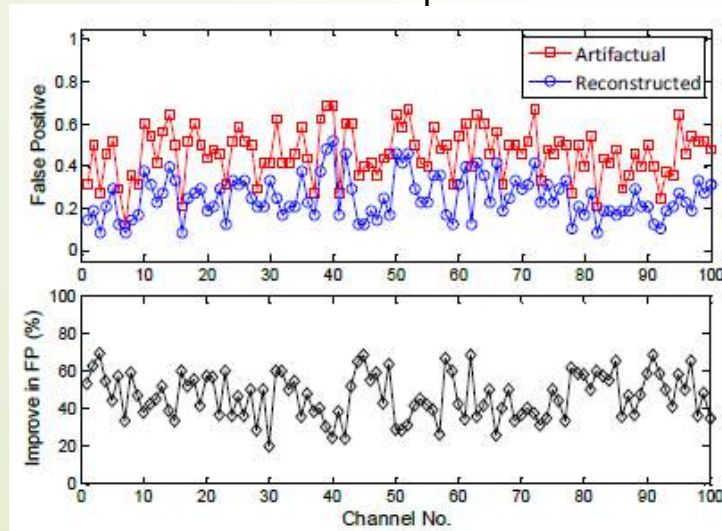
## Pulse Artifact



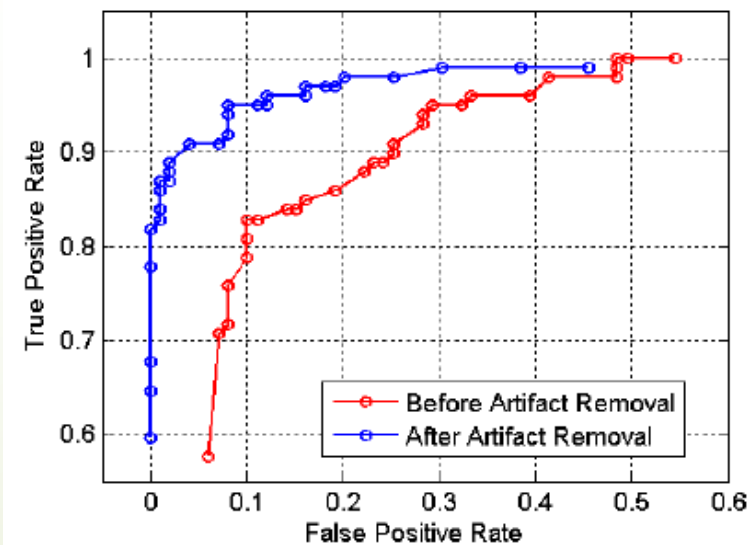
# Effect of Artifact Removal from EEG (Diagnosis)



## False alarms improvement

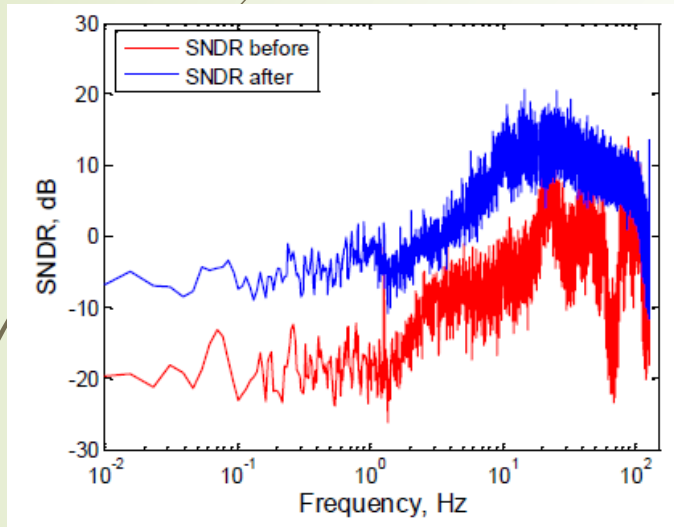


## ROC for Seizure Detection



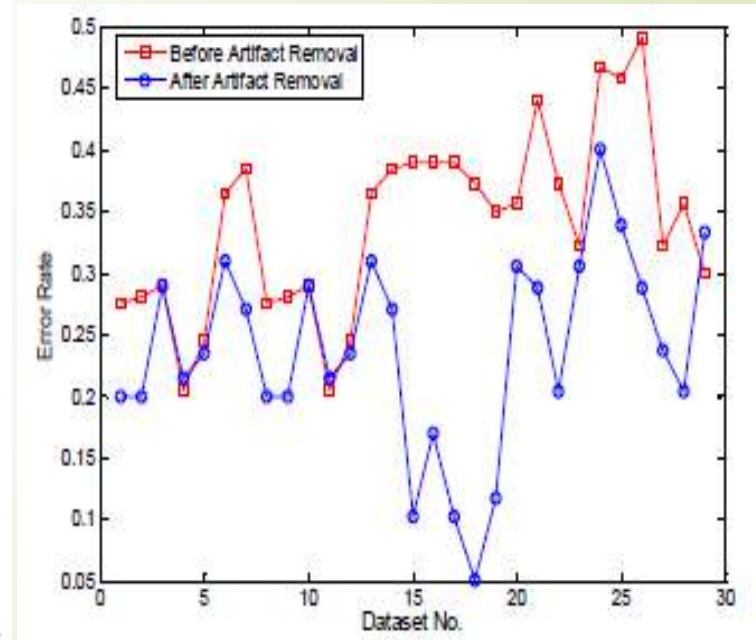
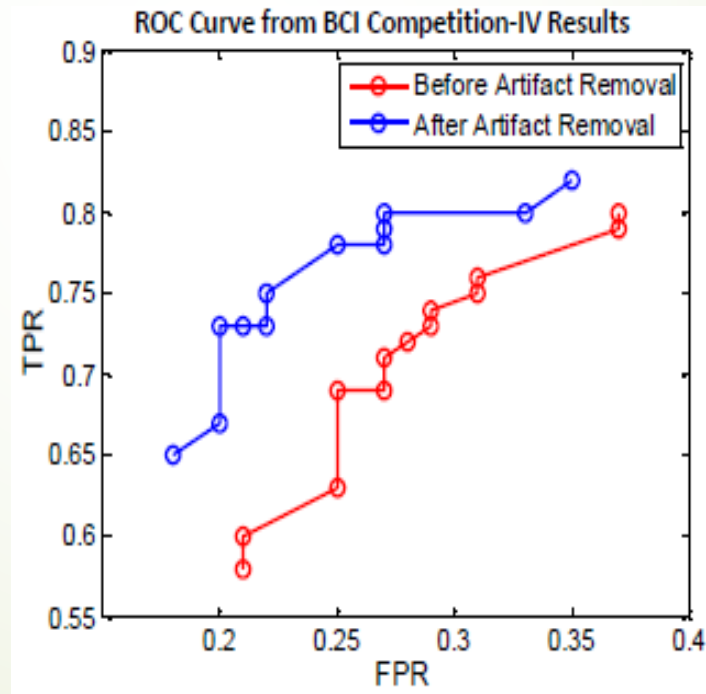
# Effect of Artifact Removal from EEG (BCI)

30



**SNDR Improvement**

## BCI Performance Improvement



# Thank You