

HISTOLOGY, CYTOLOGY AND EMBRYOLOGY (a course of lectures)

CONTENTS:

Lecture 1.	Origin and Subject Matter of Histology (V.L. Goryachkina)	2
Lecture 2.	Membranous and Nonmembranous Organelles (V.L. Goryachkina)	5
Lecture 3.	Nucleus and Cell Cycle (V.L. Goryachkina)	8
Lecture 4.	Introduction to Tissues and Tissue Development. Initial Stages of Embryonic Development (T.V. Boronikhina)	10
Lecture 5.	Epithelial Tissue (S.L. Kuznetsov)	13
Lecture 6.	Blood and Lymph (T.V. Boronikhina)	17
Lecture 7.	Connective Tissues (V.L. Goryachkina)	21
Lecture 8.	Cartilage and Bone (T.V. Boronikhina)	26
Lecture 9.	Muscle Tissues (V.L. Goryachkina)	30
Lecture 10.	Nervous Tissue – I (S.L. Kuznetsov)	33
Lecture 11.	Nervous Tissue – II (S.L. Kuznetsov)	35
Lecture 12.	Nervous System – I (S.L. Kuznetsov)	37
Lecture 13.	Nervous System – II (S.L. Kuznetsov)	39
Lecture 14.	Primary Sentient Sense Organs: The Eye and the Organ of Smell (T.V. Boronikhina)	41
Lecture 15.	Secondary Sentient Sense Organs: The Ear and the Organ of Taste (T.V. Boronikhina)	46
Lecture 16.	Cardiovascular System – I (V.L. Goryachkina)	49
Lecture 17.	Cardiovascular System – II (V.L. Goryachkina)	52
Lecture 18.	Central Organs of Hemopoiesis: Red Bone Marrow and Thymus (V.L. Goryachkina)	56
Lecture 19.	Peripheral Organs of Hemopoiesis and Immunogenesis (V.L. Goryachkina)	60
Lecture 20.	Endocrine System – I (S.L. Kuznetsov)	63
Lecture 21.	Endocrine System – II (S.L. Kuznetsov)	66
Lecture 22.	Gastrointestinal Tract – I (S.L. Kuznetsov)	69
Lecture 23.	Gastrointestinal Tract – II (S.L. Kuznetsov)	72
Lecture 24.	Gastrointestinal Tract – III (S.L. Kuznetsov)	74
Lecture 25.	Respiratory System (V.L. Goryachkina)	76
Lecture 26.	Integumentary System: Skin and Its Appendages (V.L. Goryachkina)	79
Lecture 27.	Urinary System (S.L. Kuznetsov)	83
Lecture 28.	Male Reproductive System (T.V. Boronikhina)	86
Lecture 29.	Female Reproductive System – I (T.V. Boronikhina)	90
Lecture 30.	Female Reproductive System – II (T.V. Boronikhina)	94
Lecture 31.	Human Embryology – I (T.V. Boronikhina)	98
Lecture 32.	Human Embryology – II (T.V. Boronikhina)	101

Lecture 1

The Origin and the Subject Matter of Histology (V.L. Goryachkina)

From its derivation, the word “histology” (the Greek *histos* – tissue, *logia* – study or science of) means the science of tissues. But what is a tissue? This was derived from the French *tissu*, which means a weave or texture. It was introduced in the language of biology by Bichat (1771-1802). He wrote a book on the tissues of the body, in which he named more than 20 tissues. However, he did not use the microscope to classify them. Seventeen years after Bichat’s death the term “histology” was coined by the microscopist Meier, who used microscopy for describing tissues.

It was established that there were only four basic tissues: epithelium, connective tissue, muscle tissue, and nervous tissue. In the 17th century Robert Hooke built a compound microscope. He examined a thin slice of cork and observed that it was composed of tiny empty compartments. He named the small compartments cells. Subsequently, other biologists studied plant tissue with a microscope, and it became obvious that in living plants the small compartments contained a little jelly-like body. Furthermore, as animal tissues were studied by microscopy, it became obvious that they were composed of tiny jelly-like bodies. So by 1839, the cell doctrine was postulated independently by Schleiden and Schwann. The microscope revealed the cell to have two main parts. Living cells have a more or less central part. This central part was named its nucleus (the Latin *nux* - nut), because it reminded of a nut lying in the center of its shell. For the same reason the Greek prefix “*kary*” (the Greek *karyon* - nut) may also be used in words with reference to the nucleus. For example, the dissolution of the nucleus as a cell dies is called karyolysis (the Greek *lysis* denotes dissolution). A membrane was seen to enclose the nucleus, and it was named the nuclear membrane or envelope. One or more rounded, dark-staining bodies in the interior of the nucleus were each called a *nucleolus*. Tiny granules or clumps of dark-staining material scattered about within the nucleus were called chromatin (the Greek *chrom* – color) because of their affinity for certain dyes.

The outer and generally larger part of the cell was called cytoplasm (the Greek “*kytos*” denotes something that is hollow or that covers; *plasma*, something molded). Now it is known that the cytoplasm contains organelles. These organelles lie suspended in the cytoplasmic matrix or cytosol. With the advent of electron microscopy it became possible to observe the cell membrane itself. The cell membrane received the name plasmalemma (derived from the Greek *lemma* meaning bark) for its resemblance to the bark of trees.

Cytoplasm

The cytoplasm contains organelles (they are constant structures of the cells) and inclusions (they are inconstant structures).

Organelles are described as membranous (membrane-limited) and nonmembranous.

A. The membranous organelles include:

- (1) plasma (cell) membrane;
- (2) rough-surfaced endoplasmic reticulum (rER);
- (3) smooth-surfaced endoplasmic reticulum (sER);
- (4) Golgi apparatus;
- (5) mitochondria;
- (6) lysosomes;
- (7) peroxysomes;

B. The nonmembranous organelles include:

- (1) ribosomes (both those attached to the rER membrane and those free in the cytoplasm)
- (2) centrioles (and their derivatives);
- (3) filaments (of various varieties);
- (4) microtubules. Microtubules and filaments form the cytoskeleton elements.

Cell membrane

The cell membrane is not visible under the light microscope, because the total thickness of the cell membrane is about 8 to 10 nm. With the electron microscope it appears as if it is formed of three layers: the outer dark layer, the inner dark layer, and the light layer (between the outer and the inner layers). That is why it was called the trilaminar membrane. Sometimes (with low resolution of electron microscope) we can observe only a dark line.

The cell membrane is formed of phospholipids, proteins, and carbohydrates. The phospholipid molecule is composed of two parts: hydrophobic and hydrophilic lipids. The outer dark layer and the

inner dark layer of the cell membrane are due to the presence of phospholipids. Large integral proteins are situated between phospholipids. They extend from one side of the cell membrane (the outer dark layer) to the other (the inner dark layer). Large integral proteins perform important functions in cell metabolism, regulation, and integration. They can serve as receptors of enzymes, a pump, or any combination of these functions. Peripheral proteins form a noncontinuous layer in the lipid layers (outer and inner). Cholesterol molecules are present in the cytoplasmic aspect of the cell membrane. Some carbohydrates are attached to large integral proteins and phospholipids. Carbohydrates attached to phospholipids are termed glycolipids; carbohydrates attached to proteins are termed glycoproteins. Glycolipids and glycoproteins form a cell coat or glycocalyx. This outer layer may be very thick or thin, depending on the cell function.

Functions of the glycocalyx:

1. It takes part: (a) in cell recognition; (b) in the formation of intercellular adhesion (aids in holding adjacent cells together); (c) in adsorption of molecules to the cell surface.
2. It serves as receptor sites for hormones.

Functions of the cell membrane:

- (1) Passive diffusion of small molecules. The cell membrane can allow dissolved gases, essential ions, and oxygen to pass into the cell. It also allows carbon dioxide and other metabolic wastes to leave the cell;
- (2) Active transport. In order to pass through the cell membrane, large molecules such as sugar, amino acids, and fatty acids should be combined with some catalysts. This combination requires energy. That is why this transport was termed active.
- (3) Selective transport. The presence of the receptors on the outer surface of the cell membrane allows it to select and determine which materials can enter the cell and which substances are to leave the cell;
- (4) Transport of different material by endocytosis is the process of vesicular transport when it involves substances entering the cell. Two forms of endocytosis are recognized:
 - phagocytosis (the Greek for *cell eating*). For example, the ingestion of bacteria or other cells.
 - pinocytosis (the Greek for *cell drinking*). For example, the ingestion of bulk fluid.

<p><u>Phagocytosis:</u> When a solid particle comes in contact with the cell membrane, the membrane gradually surrounds the particle from all its sides, forming a bag. This bag is pinched off from the cell membrane and moves inside the cytoplasm. It is called a phagosome.</p>	<p><u>Pinocytosis:</u> The plasma membrane invaginates to form small pits or caveolae. Gradually these pits will separate from the cell membrane. They have been referred to as pinocytosis vesicles.</p>
--	---

- (5) Vesicular transport by exocytosis.

Exocytosis is the name given to the process of vesicular transport when it involves substance leaving the cell. For example: the liver produces a very low density lipoprotein (VLDL), which is released to the blood through exocytotic vesicles. VLDL is a component of blood serum that controls the dispersal of serum lipids, a factor important in the development of atherosclerosis.

- (6) Sodium–potassium pump function.

The cell membrane is continually pumping sodium ions to the outside of the cell. As a result the concentration of sodium is higher in the tissue fluid than in the cytoplasm. The concentration of potassium ions is higher in the cytoplasm than in the tissue fluid.

The sodium–potassium pump is responsible for the cell membrane polarization. It keeps the cell membrane with a positive charge on the outside and with a negative charge on the inside.

Cell membrane modifications

The cell membrane is fluid and a dynamic system, not a static structure. It participates in the functional and metabolic activities of the cell. It forms special structures (microvilli and cilia) and junctions.

- (1) Microvilli. These microvilli are finger-like projections from the apical pole of the surface of certain cells. They increase the surface of the apical poles of cells. Microvilli are found in cells active in the transport of material, such as absorptive cells in the intestinal epithelium, or secretory cells. Microvilli have very similar sizes and shapes regardless of the cell type. Microvilli contain actin microfilaments, which are anchored to the plasma membrane at the tip and sides of the microvillus and extend to the apical pole of the cell.

(2) Cilia. They are situated on the apical pole of the epithelial cells lining the trachea and bronchi. They are special motile structures associated with the extracellular transport of material such as mucus, debris or cells. Each cilium is composed of nine double microtubules and a pair of central microtubules.

(3) Cellular junctions. There are some types of cellular junctions.

A. The tight or occluding type. This type of junction is created by localized sealing of the outer leaflets of adjacent plasma membranes. These junctions prevent the passage of water between the adjacent cells. These junctions are located between the epithelial cells.

B. Junctions of adherent type. In this type of junction there is no direct contact between the cell membrane. They are separated by a wide intercellular space (20 nm). This space is filled with adhesive material. These junctions provide lateral adhesion between epithelial cells: (a) zonula adherens, (b) macula adherens (desmosome), (c) hemidesmosomes (only on the basal part of the epithelial cells), and (d) fascia adherens (located only between the cardiac muscle cells).

C. The gap junction appears as two parallel, closely apposed plasma membranes separated by a gap of 2nm. Many special channels (or passageways) between two cells are packed at the site of the gap junction. Gap junctions allow small molecules and ions to pass directly between the cells without entering the extracellular space. These junctions are located between (a) epithelial cells, (b) smooth muscle cells, and (c) cardiac muscle cells.

Cytoskeleton

The cytoskeleton is associated with the cell membrane more than the other organelles. The cytoskeleton consists of two classes of structural elements: microtubules and filaments.

A. Microtubules. They are present in all kinds of the cells. They are cylindrical structures. They are formed of protein known as tubulin. Most of the microtubules are anchored in a region near the cell centriole, from which spindle fibers radiate. Microtubules are found in mitotic spindle fibers, centrioles, axoneme of cilia, basal bodies of cilia, elongating cell processes (such as axons), and cytoplasm, generally.

Functions of microtubules:

- (1) cell migration (elongation and movement);
- (2) intercellular transport;
- (3) movement of chromosomes during mitosis;
- (4) maintenance of cell shape;
- (5) beating of cilia and flagella.

B. Filaments. They are divided into two groups: microfilaments and intermediate filaments.

(a) *microfilaments* (actin and myosin filaments)

In muscle cells, actin and myosin microfilaments are organized into specific myofibrils. In nonmuscle cells actin may constitute up to 10% of the total protein. Actin microfilaments are often grouped as bundles close to the cell membrane. It should be noted that actin filaments are visible with EM, whereas myosin is not. Yet myosin is also present, as shown by immunocytochemistry.

Functions of microfilaments:

1. Anchorage and movement of the membrane proteins;
2. Movement of the plasmalemma (as in endocytosis and exocytosis);
3. Formation of the structural core of microvilli on absorptive cells;
4. Extension of cell processes;
5. Locomotion of cells.

(b) *intermediate filaments* perform a mechanical function, i.e., the supporting or stiffening of cells and coordinating the activity of intracellular organelles. There are five major classes of intermediate filaments. This division depends on the special protein present in the tissues.

1. Keratin filaments occur in epithelial cells as tonofilaments (bundles of tonofilaments form tonofibrils).
2. The protein vimentin forms intermediate filaments that enmesh the nucleus. They appear to control the location of the nucleus. Vimentin filaments are present in the cells of mesenchymal origin (in connective tissue cells, some smooth muscle cells, and endothelial cells).
3. Desmin filaments are particularly abundant in smooth muscle cells.
4. Neurofilaments are present in neuronal cells.
5. Glial fibrillary acidic protein forms glial filaments. These filaments are present in neuroglial cells (special supporting cells that are in intimate physical contact with neurons).

Lecture 2

Membranous and Nonmembranous Organelles (V.L. Goryachkina)

Mitochondria

The main function of mitochondria is known to provide energy for cells.

They are found in large numbers in metabolically active cells. For example, liver cells, skeletal muscle fibers and cardiac muscle cells contain approximately 2000 mitochondria, whereas inactive cells contain very few mitochondria (lymphocytes). Note, that red blood cells and terminal keratinocytes of the epidermis do not contain mitochondria.

Mitochondria can be elliptical, ovoid, spherical, discoidal, rod-shaped, etc. It is very difficult to observe them with light microscope (LM), because they measure 0.2 to 2 nm in width and 2 to 7 nm in length. It is necessary to use special staining to identify them with LM. Under the light microscope mitochondria are seen to be rods or threads, which accounted for their name (derived from the Greek *mitos* meaning "thread"). Each mitochondrion is covered with two membrane layers. The outer membrane is a unit membrane, about 5 to 7 nm thick. The outer membrane is thought to play a role in controlling the movement of substances into and out of the mitochondria and the uptake of substances and release of ATP. The inner membrane is a unit membrane too, about 5-7 nm thick. The inner membrane forms folds, which are termed cristae. Each crista projects into the inner chamber (mitochondrial matrix). Toward the matrix, the inner membrane encloses elementary particles. The enzymes for oxidative phosphorylation are located in these particles. The synthesis of ATP from ADP and phosphates takes place here. The matrix is filled with a fluid. Mitochondrial DNA and ribosomes are situated within the matrix. The enzymes for the Krebs cycle, lipid and protein synthesis, the enzymes for oxidation of fatty acids are located within the matrix too. In addition to enzymes, some granules are present in the matrix. These granules are the storage sites of Ca^{++} and Mg^{++} ions.

Functions of mitochondria.

Mitochondria are energy producers of cells. Energy is produced by the Krebs cycle and oxidative phosphorylation. Mitochondria also oxidize and synthesize fatty acids, concentrate ferritin, and accumulate cations in granules.

Rough-surfaced endoplasmic reticulum - granular reticulum (rER)

Under the electron microscope rER appears as a series of interconnected, membrane-limited flattened sacs called cisternae with ribosomes studding to the exterior surface of the membrane. Under the light microscope rER is basophilic in staining due to the presence of the ribosomes.

Some rER is present in every kind of the cell. However, the quantity of the rER cisternae depends on the cell function. It should be noted that any cell containing a well-developed rER will produce proteins for export. For example: fibroblasts of connective tissue which secrete proteins and other substances that constitute the extracellular matrix (this matrix contains many proteins: collagen, elastin, etc.), and plasma cells which make up and secrete immunoglobulins (antibodies). Pancreatic acinar cells are involved in the synthesis of proteins for export.

Functions of rER:

The rER takes part in the synthesis of

- (1) enzymes contained within the lysosomes;
- (2) integral proteins of the cell membrane;
- (3) proteins for export from the cell.

Smooth-surfaced endoplasmic reticulum (sER)

The sER consists of short anastomosing tubules that are not associated with ribosomes. The sER tubules are often continuous with rER. The amount of sER in the cells varies, depending on their type, and is prominent in only certain cell types.

Functions:

- (1) The synthesis of lipids, cholesterol, lipoproteins, and steroid hormones. For example, liver cells containing a well-developed sER are known to produce the lipoproteins found in blood.
- (2) The synthesis of glycogen. Liver cells contain large amounts of sER (enzymes for glycogen formation are associated with sER).
- (3) Since the sER takes part in cholesterol production, it is indirectly involved in membrane formation.
- (4) Drug detoxification. The liver is known to be concerned with the detoxification of certain drugs. That is why hepatocytes contain many sER tubules.
- (5) Calcium storage.
- (6) Transport of different material within the cell.

Ribosomes

They are formed in the nucleus. (1) Ribosomes consist of two subunits: (a) the small subunit contains one rRNA molecule (ribosomal RNA) and 24 different proteins; (b) the large subunit contains two molecules of rRNA and 40 proteins. (2) Messenger RNA (mRNA) passes through the cleft between subunits. Ribosomes may occur free in the cytoplasm or be attached to the membrane of endoplasmic reticulum.

I. Free ribosomes.

They are scattered freely in the cytoplasm and are responsible for its basophilia. Growing cells, cancer cells, dividing cells contain many free ribosomes. It should be noted that free ribosomes are divided into two types: monoribosomes and polyribosomes or polysomes. These polysomes were termed clusters, because they contain many ribosomes attached to mRNA. These polysomes together with mRNA form a spiral structure.

II. Attached ribosomes.

They are attached to the outer surface of the membrane of endoplasmic reticulum.

Functions:

- Free ribosomes synthesize proteins, which remain in the cell, e.g., (a) keratinocytes, (b) some precursors of erythrocytes, (c) muscle fibers contain a lot of free ribosomes. In addition, most mitochondrial enzymes are synthesized by free polysomes and transferred into that organelle.
- Attached ribosomes synthesize proteins for export.

Golgi apparatus

The Golgi complex consists of

(1) flattened sacs (sacculles),

(2) a stack of sacs consisting of two faces:

- the forming face associated with small transfer vesicles;
- the maturing face; the formation of lysosomes and glycoproteins and the accumulation of secretory granules occur here.

(3) transfer vesicles, which convey proteins to sacs (to the forming face).

Functions of the Golgi apparatus:

- formation of lysosomes
- formation of glycoproteins
- accumulation of secretory granules
- excretion of secretory granules.

Lysosomes

In 1955 Cristian de Duve was the first to postulate from the biochemical data the existence of unusual organelles containing hydrolytic enzymes. De Duve and his coworkers proposed the name lysosome (the Greek *lysis* meaning dissolution)

Lysosomes are present in almost all kinds of cells. Their number varies greatly from one cell to another, depending on its type and function. It was established that lysosomes contain nearly 100 different hydrolytic enzymes: proteases, acid phosphatase, etc.

Morphofunctionally, lysosomes can be subdivided into primary lysosomes and secondary lysosomes. The lysosomes that bud off the maturing face of a stack of Golgi apparatus are termed primary lysosomes. They contain only enzymes; they are not involved in the digestive activity. Primary lysosomes are lined by a unit membrane; they measure from 25 nm to 0.05 μm in diameter and contain a homogeneous, fine granular material. Primary lysosomes may interact with the material brought into the cell from the outside or with broken down organelles. The fusion of primary lysosomes with phagosomes results in the formation of secondary lysosomes. Thus, secondary lysosomes contain both the digestive enzymes and the material to be digested. Secondary lysosomes measure from 0.5 to 1.5 μm in diameter and are enclosed by a unit membrane.

When secondary lysosomes cannot digest the materials, they turn into debris-filled vacuoles that are called residual bodies. Residual bodies or tertiary lysosomes may remain in the cell throughout its life. For example, in nerve cells it is possible to see such bodies; in nerve cells, they have been called "the age pigment" or lipofuscin granules.

Thus, lysosomes play a significant role in breaking down different materials in the cells. The absence of certain lysosomal enzymes can lead to the pathological accumulation of undigested substrate in residual bodies, resulting in some disorders referred to as lysosomal storage diseases. More than 20 storage diseases due to the deficient activity of lysosomal enzymes have been identified. For example, the

absence of lysosomal galactosidase in nerve cells produces concentric lamellated structures in residual bodies that accumulate in the nerve cells and interfere with normal function. In glycogen-storage disease, type II α -glycosidase is absent in lysosomes. As a result, hepatocytes become enlarged by stored glycogen-filled vesicles, which cannot be metabolized.

A contrasting group of lysosomal diseases is due to the intracellular break up of lysosomes. For example, in gout or uratic arthritis, urate crystals form in the synovial cavities and other connective tissue spaces as a result of the genetically induced high level of uric acid in the body fluids. Leukocytes engulf these crystals. As they become incorporated into secondary lysosomes, these crystals disrupt the lysosomes, and as a result the latter lose the hydrolytic enzymes. The leukocytes are destroyed, and the enzymes, released into the tissue, induce inflammation characteristic of uratic arthritis.

Thus, lysosomes are involved in intracellular digestion. Lysosomes not only maintain the health of normal cells but are also of great importance in the defense of the body against certain bacterial invaders.

Peroxisomes (microbodies)

They are present in all cells. Peroxisomes are lined by a unit membrane; they measure from 0.2 to 0.8 μm in diameter. Peroxisomes contain nearly 20 enzymes: catalase, peroxidase, etc. Accounting for their name, peroxisomes generate hydrogen peroxide as an oxidation product. But hydrogen peroxide is quite toxic to cells, and peroxisomes, by their catalase content, break it down to oxygen and water.

Peroxisomes are capable of generating energy. This process takes place during the oxidation of various substrates by molecular oxygen. This energy is dissipated, generating heat.

Peroxisomes are involved in the metabolism of purine bases (parts of nucleic acids). It is noteworthy that most mammals oxidize uric acid to allantoin or allantoic acid. Their peroxisomes contain urate oxidase, organized as paracrystalline arrays of hollow tubules. But the peroxisomes of birds, monkeys, and humans lack this enzyme and metabolize purines only to uric acid, the end product of purine metabolism. High levels of uric acid cause gout, a painful disease with joint inflammation and chalky deposits, due to the disturbance of purine metabolism.

Peroxisomes possess alcohol dehydrogenase and thereby degrade alcohol, thus reducing the degree of intoxication and alcohol-induced liver and nerve damage.

Another function of peroxisomes is the conversion of noncarbohydrates (amino acids and fatty acids) to carbohydrates. This phenomenon is called gluconeogenesis.

Centrioles

These organelles are paired rod-shaped bodies. They lie close to the nucleus in the center of a cell. They were termed centrioles (derived from the Greek *kentro*, meaning “to a center” or “central location”). This part of the cell was called the cell center, centrosome or centrosphere. Each rod-shaped centriole consists of nine triplets of microtubules oriented parallel to a long axis of the organelle. The centrioles in resting cells are arranged at right angles to each other but are not connected. Centrioles are surrounded by dense material (centriolar satellites) connected with each triplet. Centrioles and centriolar satellites constitute a general microtubule-organizing center in both interphase and mitosis. The centriolar satellites appear to be the actual points of polar attachment of the microtubules of the mitotic spindle.

The functions of centrioles are as follows.

(1) They play an important role in cell division. Before division centrioles duplicate themselves. Each pair of centrioles migrates to both sides of the dividing cell. Then centrioles induce the formation of microtubules of the spindle apparatus. In addition, centrioles are responsible for their depolymerization shortening during anaphase.

(2) Ciliogenesis: centrioles migrate toward the cell surface and induce the formation of the cilia and axonemes of the spermatozoon tails.

Inclusions

The cytoplasmic inclusions are “nonliving” components of the cell.

They include glycogen, neutral fat and other lipid droplets, pigment granules, and secretory granules.

Glycogen exists as deposits in cytoplasmic matrix. Glycogen may be seen with the light microscope (LM) only after special fixation and staining procedures. Glycogen appears in electron micrographs as granules of 25 to 30 nm in diameter and clusters of such granules. The liver and striated muscle fibers contain large amounts of glycogen.

Lipid inclusions (fat droplets) are stored in adipose or fat cells. Fat sometimes accumulates in liver cells and other types of cells.

The most important pigment is hemoglobin, an iron-containing pigment in red blood cells. Melanin is usually a brown-to-black pigment found chiefly in the skin and its appendages and in the eye. It is also present in the substantia nigra.

Lecture 3

Nucleus and Cell Cycle (V.L. Goryachkina)

Nucleus and cell cycle

The nucleus is a membrane-limited compartment that contains genetic information. The nucleus of nondividing cells, also called the interphase nucleus, consists of the following components: (1) chromatin organized as euchromatin and heterochromatin, (2) the nucleolus (or nucleoli), (3) membranous nuclear envelope, (4) nuclear skeleton, and (5) nucleoplasm.

Chromatin

It stores genetic information. Chromatin is a complex of DNA and proteins. Chromatin proteins include basic proteins called histone and other nonhistone proteins. These proteins connect with the folding of DNA strands and take part in the regulation of DNA activity. Histones connect the first steps of the folding. The length of DNA strand is about two meters. But the volume of the nucleus is measured in only microns. Therefore, DNA must be packed in the nucleus. After the first folding the DNA length decreases sixfold. Nonhistones take part in the following steps of the DNA folding.

The chromatin visible with LM as dense granules or clumps is called condensed chromatin. The chromatin invisible with LM is called extended chromatin. The DNA of extended chromatin is active in providing information to direct protein synthesis. Extended chromatin is termed euchromatin (good chromatin), because it works; condensed chromatin was termed heterochromatin or other kind of chromatin (derived from the Greek *heteros* meaning "other"). Heterochromatin is disposed in three locations: (1) marginal heterochromatin is found on the periphery of the nucleus, (2) central heterochromatin is scattered as irregular clumps, and (3) perinuclear chromatin. Heterochromatin predominates in metabolically inactive cells (lymphocytes). Euchromatin predominates in active cells (nerve cells). Chromatin represents the DNA-protein complex of chromosomes, which are visible in dividing cells. Chromosomes are permanent components of the nucleus composed of chromatin fibers visible with EM.

Chromatin fibers consist of nucleosomes interconnected by internucleosomal DNA (iDNA). Nucleosomes are the smallest units of chromatin. It is composed of a central globular histone octamer around which a DNA double helix winds in two full turns. This DNA in direct contact with histones was termed nucleosomal DNA (nDNA). Eight nucleosomes form nucleomeres.

The following levels of the arrangement are chromonemata, chromatid, and chromosome. Nobody knows the arrangement of these structures.

Nucleolus

The nucleolus is a portion of chromosome. The nucleolus mainly consists of RNA and ribonucleoproteins; a small amount of DNA in the form of perinucleolar and intranucleolar chromatin; RNA polymerase and other enzymes, which are responsible for the synthesis of rRNA. Basophilia is due to the presence of RNA and DNA.

The nucleolus is formed by (1) filamentous material (pars fibrosa) and (2) granular material (pars granulosa). The pars fibrosa consists of dense filaments about 5 nm thick, predominantly situated in the interior of the nucleolus. The pars granulosa consists of small particles 10 to 15 nm in diameter. Both the pars granulosa and the pars fibrosa contain RNA. The network formed by the pars granulosa and the pars fibrosa is called nucleonemata. (3) Perinucleolar chromatin represents the patches of heterochromatin attached to the periphery of the nucleolus. (4) Intranucleolar chromatin, single or twisted DNA filaments that penetrate the pars fibrosa. (5) The nucleolus matrix contains protein.

The function of the nucleolus is to synthesize rRNA.

Nuclear envelope

Under the LM, the nuclear envelope appears as a single line. Under the EM, two membranes can be observed: outer and inner. The space between these membranes was termed the perinuclear cisternal space.

The outer membrane is often rough, because it has many ribosomes on its surface. The outer membrane is continuous with the rER membranes. The inner membrane lies adjacent to the fibrous nuclear lamina. This lamina contains special filaments and provides internal support for chromatin, chromatin-associated proteins, the inner nuclear membrane, and nuclear pores.

It should be noted that during cell division the nuclear envelope breaks into vesicles, which reconstitute the nuclear envelope at the end of the anaphase and in the telophase.

Nuclear pores

Nuclear pores are seen as round or octagonal interruptions of the nuclear envelope. Every nuclear pore contains 8 granules, which form the so-called annulus. From the pores, the filamentous material

extends into both the cytoplasm and the nucleus. The pores are closed by the diaphragm with a central granule. The pore and annulus together are called the nuclear pore complex. Nuclear pores may occupy 3 to 35% of the nuclear surface. *Functions of nuclear pores:* (1) They regulate the passage of proteins between the nucleus and cytoplasm. For example, some nuclear proteins (histones, lamines) are produced in the cytoplasm. Thus, nuclear pores serve for the passage of these substances into the nucleus. (2) They also regulate the passage of mRNA and ribosomes into and out of the nucleus.

Nuclear skeleton

The nuclear skeleton (matrix) is a sponge structural framework (consisting of proteins). It is formed by 2- to 3-nm thick microfibers associated with microfibrils 20 to 30 nm in diameter. Both fibrils are connected with the nucleolus, the inner membrane, the lamina fibrosis, and the nuclear pore. The nuclear cytoskeleton is believed to play a role in the arrangement of the chromatin of meiotic and mitotic chromosomes.

Nucleoplasm

The nucleoplasm consists of nucleoproteins and a number of enzymes, which participate in the DNA and RNA synthesis.

Functions of the nucleus:

1. Regulation of cell differentiation, maturation, and function.
2. Replication and transmission of genetic message to new cells in spite of cell divisions.
3. The synthesis of messenger, transfer, and ribosomal RNA and their transport into the cytoplasm.

The cell cycle

An essential feature of the cells is their ability to divide and reproduce. In addition, after cell death, an adult needs to be compensated for by the production of new cells. Cells reproduce due to duplication of their contents and division. The phases involved in cell replication can be regarded as a cell cycle. The cell cycle is the sum of morphological and biochemical events occurring in the life of a cell between its formation and the end of its division into two daughter cells. The cell cycle is divided into two main phases: mitosis and interphase. Interphase is divided into 3 phases. The interval after mitosis is called the first "gap" or G_1 phase. During this phase, the cell growth, protein (enzymes) and RNA synthesis, as well as the formation of receptors on the cell surface take place. During the "S" phase, DNA reduplication (DNA synthesis) and hystone synthesis occur. The interval between the S phase and mitosis is called the second "gap" or G_2 . G_2 is a short phase of preparation for mitosis. The synthesis of proteins (tubulins) for the spindle apparatus occurs during this phase.

In most tissues, the majority of the cells have to differentiate after mitosis. The beginning of differentiation is associated with the cell leaving the cycle. They are said to be in the G_0 ("outside") phase. As a rule, G_0 cells leave the cycle from the G_1 phase. Occasionally, some cells leave the cycle in the G_2 phase.

The cells of the adult body can be classified into three populations: static, stable, and renewing according to their mitotic activity.

- (1) *Static cell population* consists of cells that will not divide (nerve cells, cardiac muscle cells).
- (2) *Stable cell population* consists of cells that divide episodically when they are stimulated by injury to become more mitotically active (liver cells).
- (3) *Renewing cell population:* blood cells, epidermis, epithelial cells of the lining the alimentary canal. After division, one daughter cell will differentiate; the other will remain in G_0 phase or rest phase. The latter cell was called "stem cell" or "reserve cell". After division of a stem cell, the formation of two types of the cell occurs: a new stem cell in the G_0 phase (to maintain the stem cell population) and a daughter cell (which differentiates along one cell line).

Stem cells may be in the G_0 phase and only come to reenter the cycle if there is a demand (e.g., following cell death).

It should be noted that every cell has its own program of activity and death. Approximately 20 years ago a special gene was discovered in DNA. It was called a lethal gene or the gene of death.

When this gene begins to work, the DNA is the first to be destroyed, then the nucleus is broken into fragments. This process was called apoptosis. Apoptosis is a normal process of programmed cell death. This mechanism of death is induced in cells when they are damaged, useless to the body, or dangerous. Apoptosis is the key mechanism of the developing organism. For example, our fingers are separated, because the embryonic cells that joined them died during development by apoptosis. Apoptosis takes place not only during the embryonal development, but in adult life. For example, this process can be observed in mammary glands. During pregnancy and lactation they are large, but in the absence of sucking the secretion of milk ceases, and the mammary glands begin to regress due to apoptosis.

Lecture 4

Introduction to Tissues and Tissue Development Initial Stages of Embryonic Development (T.V. Boronikhina)

Tissues are aggregates of cells and extracellular material organized to perform distinctive functions.

There are four basic tissue groups: epithelial tissues; a group of internal medium tissues including blood, lymph, and all types of connective tissues; muscular tissues; and nervous tissue.

All cells of the mature organism and all tissue types are derived from a single cell called a zygote. Two processes occur in this development: cell proliferation (division) and cell differentiation.

Differentiation is the development of specialized cell types from stem cells, during which changes in the cell structure and biochemistry occur for the cell to perform distinctive functions.

The process of cell determination precedes cell differentiation.

Determination is the process of a cell's particular fate choice, when the cell differentiation pathway is chosen.

The differential genome activity underlies determination. Each cell contains a complete genome established in the zygote during fertilization, the DNAs of all cells are identical. As cells develop, the genetic material does not change but some genes are expressed (activated) and others repressed (inactivated). Only a small percentage of the genome is expressed in each cell, so that a portion of RNA synthesized by this cell type is specific. Because determination occurs step-wise, the cells can exist in different states of differentiation and possess different potentialities.

Potentiality is the capability of a cell for differentiation that has not yet been realized.

According to their potentialities, cells may be distributed in some populations. Stem cells are pluripotent; they usually give rise to several cell types. Their immature offspring is oligopotential; their potentialities become less. Mature cells are unipotent; they have chosen the only way of differentiation. The zygote is a totipotent cell, because it serves as the progenitor for all the kinds of body cells (single produces whole).

Embryonic development

Cell differentiation and tissue development begin in embryogenesis. The embryogenesis includes the following stages: fertilization, cleavage, gastrulation, differentiation of germ layers and formation of the axial organs, and the last period (the longest and most complex) of histogenesis and organogenesis.

Fertilization

Fertilization is the sequence of events, by which a sperm fuses with an ovum to form a unicellular organism called a zygote. The mature sperm is a microscopic, free-swimming, and actively motile cell consisting of a head and a tail or flagellum. The head, forming most of the bulk of the sperm, includes the nucleus whose chromatin is greatly condensed. The anterior two thirds of the nucleus is covered by the acrosome, a membrane-limited organelle containing the enzymes that facilitate sperm penetration of the corona radiata and zona pellucida during fertilization. The sperm tail consists of three segments: the middle piece, the principal piece, and the end piece. The junction between the head and the tail is called the neck. The tail provides the sperm motility, which assists in its transport to the site of fertilization. The middle piece of the tail contains the mitochondria generating the energy for sperm motility. With respect to the sex chromosome constitution, there are two kinds of normal sperm: $22 + X$ and $22 + Y$.

The mature ovum is the secondary oocyte arrested at the metaphase of the second meiotic division (female meiosis may be completed only after fertilization). The secondary oocyte released at ovulation is surrounded by the zona pellucida and a layer of follicular cells called the corona radiata. Compared with ordinary cells and, notably, the sperm the ovum is truly large. It has an abundance of cytoplasm containing organelles, yolk granules, RNA, morphogenetic factors, and cortical granules. The ovum nucleus is haploid ($22 + X$), euchromatic, and metabolically active. The ovum is immotile and transported down the oviduct passively by the movement of cilia.

The usual site of human fertilization is the uterine tube ampulla. The fertilization process requires from 12 to 24 hours.

Capacitation of sperms

Before a mature motile sperm can penetrate the oocyte surroundings, it must undergo capacitation. This process consists of enzymatic changes that result in the removal of a thick glycoprotein coat formed during sperm incubation in the epididymis from the plasma membrane over the acrosome. This coat is known to prevent the early acrosome reaction. No morphological changes are known to occur during the capacitation process. The capacitating ability inheres in some substances of the female genital tract secretion. It takes sperms about 7 hours to be capacitated.

Acrosome reaction

The acrosome reaction may occur after sperm capacitation. This reaction consists of structural changes. The outer membrane of the acrosome fuses at many places with the overlying cell membrane of the sperm head, and the fused membranes then rupture, producing multiple perforations through which the enzymes leave the acrosome. The enzymes released from the acrosome facilitate the passage of the sperm through the oocyte envelopes. Hyaluronidase enables the sperm to penetrate the corona radiata. Acrosin appears to cause lysis of the zona pellucida, thereby forming a pathway for the sperm.

Penetration

The sperm head is attached to the surface of the secondary oocyte. The plasma membranes of the oocyte and sperm fuse and then break down at the point of contact. The sperm nucleus and centriole enter the ovum cytoplasm, leaving the sperm's plasma membrane and its tail outside, attached to the oocyte plasma membrane, where they rapidly degenerate.

Cortical reaction or zona reaction

As soon as the first sperm passes through the zona pellucida, a zona reaction occurs. The zona reaction is produced by cortical granules containing lysosomal enzymes. After penetration, the cortical granules open and release the enzymes that modify the physicochemical characteristics of the zona pellucida, converting it to impermeable to other sperms and preventing polyspermy. Although several sperms may penetrate the zona pellucida, usually only one sperm enters the ovum and fertilizes it. There is some experimental evidence that aged oocytes do not release cortical granules. As a result, the zona reaction does not take place, and multiple penetrations of sperms occur. Polyspermy results in the development of a nonviable embryo.

Events after penetration

The secondary oocyte completes the second meiotic division, forming a mature ovum and the second polar body. The ovum nucleus is known as the female pronucleus. The sperm nucleus enlarges to form the male pronucleus. The human zygote looks like a synkaryon. Then, the male and female pronuclei approach each other in the centre of the zygote, where they come in contact and lose their nuclear membranes. The maternal and paternal chromosomes intermingle at the metaphase of the first mitotic division. Fertilization is completed.

Biological significance of fertilization

The restoration of the diploid number takes place: the fusion of two haploid germ cells produces a zygote, a diploid cell with 46 chromosomes, the usual human number.

Because half of the chromosomes come from the mother and half from the father, the zygote contains a new combination of chromosomes and genetic material that is different from those of the parents.

Moreover, the embryo sex is determined at fertilization by the kind of the sperm that fertilizes the ovum. Fertilization by an X-bearing sperm produces an XX zygote, which normally develops into a female embryo. Fertilization by a Y-bearing sperm produces an XY zygote, which normally develops into a male embryo.

Fertilization initiates a series of rapid mitotic cell divisions called the zygote cleavage. The cleavage of a secondary oocyte may occur without fertilization. This process is called parthenogenesis. There is evidence that the human oocyte may start to undergo parthenogenetic cleavage, but this does not result in organized development.

Cleavage

Cleavage is a process of successive rapid mitotic divisions without the growth of the daughter cells called blastomeres.

As G1 phase in these mitotic cycles is not present, the cell cytoplasm volume does not increase; blastomeres become progressively smaller until they acquire the size of most of the somatic body cells. Thus, the normal nucleus to the cytoplasm volume ratio is restored. That is why this stage of development is termed segmentation or cleavage, but not division.

Blastomeres do not leave the cell cycle; they never begin to differentiate. They do not use their genome; they synthesize proteins on maternal RNA. Through some first mitotic divisions, blastomeres retain the zygote property, namely, totipotentiality. Occasionally, two or more blastomeres are separated, and each develops into an embryo. Thus, identical twins appear.

Initially, the embryo is under the control of maternal informational macromolecules that have accumulated in the ovum cytoplasm during oogenesis. Later, development depends on the activation of the embryonic genome, which encodes various growth factors and other macromolecules required for normal progression to the blastocyst stage.

Human cleavage occurs in the oviduct for 3 days and then in the uterus for 3 to 4 days. Cleavage begins with the first mitotic division of the zygote, then, the morula – a solid ball of 12 to 16 blastomeres that looks like a mulberry – is formed. The morula enters the uterus as it is forming. Cleavage ends with the blastula formation. Human cleavage is holoblastic (total); it means that the entire cytoplasm is cleft. Human cleavage is unequal; it means that blastomeres are different in size, i.e., small and large cells. Human cleavage is asynchronous; it means that blastomeres divide at different time and may be even or odd in number.

Blastocyst formation

Some fluid passes into the morula forming a cavity; blastomeres are also able to produce fluid. As fluid increases, it separates the morula cells into two parts: (1) an outer cell layer called the trophoblast consisting of small light blastomeres, from which the chorion and the placenta develop; and (2) an inner cell mass called the embryoblast consisting of large dark blastomeres, from which the embryo proper and some provisional organs arise. The human blastula looks like a cyst and is called the blastocyst: the trophoblast forms its wall; the embryoblast is attached to the inner side of the trophoblast and projects into the fluid-filled blastocyst cavity. The blastocyst is still surrounded by the zona pellucida and lies free in the uterine secretion before implantation.

Gastrulation

Gastrulation is a process of highly integrated cell movements whereby the germ layers, namely, the ectoderm, endoderm, and mesoderm, are formed.

The gastrulation events are as follows: extensive cell rearrangement and segregation, mitotic cell divisions, and cell differentiation. These events result in the formation of the germ layers. In mammalian species, gastrulation is a two-stage process, and all morphological changes take place only in the embryoblast.

During the first stage of gastrulation (on the 7th day of development), the embryoblast is transformed into a bilaminar embryonic disk by the mechanism called delamination. The embryonic disk is composed of a superior layer called the epiblast consisting of high columnar cells and an inferior layer called the hypoblast consisting of cuboidal cells adjacent to the blastocyst cavity. The epiblast gives rise to all the three germ layers of the embryo (the ectoderm, mesoderm, and endoderm). The hypoblast is probably displaced to extraembryonic regions.

During the second stage of gastrulation (on the 15th day of development), morphological changes take place only in the epiblast; the hypoblast does not take part in embryo formation. The second stage of gastrulation is characterized by the formation of the primitive streak. This structure forms as follows: epiblastic cells from the cranial embryo end proliferate and migrate to the caudal embryo end along the disk margins and converge at the caudal end of the disk; these cell currents then turn toward the midline and elongate back, to the cranial end. Concurrently, a narrow primitive groove develops on the top of the primitive streak. Since the primitive streak appears, it is possible to identify the embryo's craniocaudal axis, its dorsal and ventral surfaces, and its right and left sides.

The primitive streak is the origin of the embryonic mesoderm and the embryonic endoderm. The epiblastic cells move along the primitive streak and enter the primitive groove. They lose their attachment to the rest epiblastic cells and migrate inward between the epiblast and the hypoblast. The early-migrating cells are those that replace the hypoblastic cells to become the endoderm. The later-migrating cells begin to spread laterally, ventrally, and cranially to form a layer called the mesoderm. As soon as the primitive streak gives rise to the mesoderm and the endoderm, the cells that remain in the epiblast are referred to as the embryonic ectoderm. Thus, the gastrulation is completed; as a result, the embryo looks like the trilaminar disk.

Differentiation of the germ layers and the formation of the axial organs

The complex of the axial organs includes the following structures: the notochord, the neural tube, and the mesodermal somites.

At this point, the last stage of embryogenesis begins. The interaction between the germ layers is important for initiating histogenesis and organogenesis, i.e., the creation of specific tissues and organs.

Firstly, the notochord is formed, concurrently with the second stage of gastrulation. The cranial end of the primitive streak thickens to form the primitive knot (Hensen's nodule) with a central indentation known as the primitive pit. The primitive pit then extends through the epiblast to form the notochordal canal. Cell masses surrounding the primitive knot migrate through this canal, reach the hypoblast, and turn cranially to form the cellular rod or the column-like process called the notochord. It grows between the ectoderm and endoderm, from the primitive knot toward the cranial end of the disk. The wing-like mesoderm is on each side of the notochordal process.

The functions of the notochord are as follows: (1) it forms a midline axis of the embryo; (2) it does not give rise to the skeleton (the skeleton arises from the sclerotome), but it is the structure, around which the vertebral column forms; the notochord degenerates and disappears where it is surrounded by the vertebral bodies, but persists as the nucleus pulposus of the intervertebral disks; (3) it also induces the overlying ectoderm to form the neural plate, i.e., the embryonic induction of neurulation.

Neurulation or the neural tube formation includes the formation of the neural plate, the neural groove with two folds, and the fold closure forming the neural tube. As the notochord develops, the embryonic ectoderm over it thickens to form the neuroectoderm or the neural plate. The developing notochord and the mesoderm on each side of it induces this process. On about the 18th day, the neural plate invaginates along the central axis to form the neural groove with two neural folds on each side. By the end of the third week, the neural folds begin to converge and fuse, converting the neural groove to the neural tube. The neural tube is then separated from the ectoderm that is referred to as the surface (covering) ectoderm and differentiates into the skin epidermis. The neural tube is the primordium of the central nervous system consisting of the brain and the spinal cord.

As the neural folds fuse, some ectodermal cells lying along and over each fold are not incorporated in the neural tube. They appear as a cell mass between the neural tube and the covering ectoderm, constituting the neural crest. The latter gives rise to the spinal ganglia and the ganglia of the autonomic nervous system, as well as Schwann cells, the meningeal covering of the brain and the spinal cord (the pia mater and the arachnoid), the skin pigment cells, and the adrenal gland medulla.

The mesoderm on each side of the notochord and the neural tube thickens to form the longitudinal columns of the paraxial mesoderm. Each paraxial mesoderm is continuous laterally with the intermediate mesoderm, which gradually thins laterally into the lateral mesoderm. The paraxial mesoderm begins to divide into paired cuboidal bodies called somites. This series of mesodermal tissue blocks is located on each side of the developing neural tube. Somites are then subdivided into three regions: myotome that gives rise to skeletal muscles; dermatome that develops into the skin dermis, and sclerotome, from which bone and cartilaginous tissues arise. The intermediate mesoderm (somite cords) differentiates into nephrogonadotome that develops into the kidneys and gonads. Within the lateral mesoderm the space called the coelom appears, dividing the lateral mesoderm into two layers: (1) the parietal layer, somatopleure, and (2) the visceral one, splanchnopleure. The coelom is then divided into the following body cavities: the pericardial, pleural, and peritoneal ones. The cells of the parietal and visceral layers give rise to the mesothelium lining these cavities. The splanchnopleure takes part in the development of the heart (the myocardium and the epicardium are derived from it) and the adrenal gland cortex.

Some cells from the mesoderm migrate and are disposed among the axial organs, they form a loose origin called the mesenchyme. The mesenchyme gives rise to the blood, all types of connective tissue, smooth muscle cells, blood vessels, microglial cells, and endocardium.

The embryonic endoderm develops into the epithelium of the gastrointestinal tract, the liver, the pancreas, the gallbladder, and the epithelial parts of the lungs.

Lecture 5

Epithelial Tissue (S.L. Kuznetsov)

The epithelia are a diverse group of tissues, which, with rare exceptions, cover or line all body surfaces, cavities, and tubes. Epithelia thus function as interfaces between different biological compartments. As such, epithelia mediate a wide range of activities such as selective diffusion, absorption and/or secretion, physical protection, and containment; all these major functions may be exhibited at a single epithelial surface. For example, the epithelial lining of the small intestine is primarily involved in absorption of the products of digestion, but the epithelium also protects itself from intestinal contents by the secretion of a surface coating of mucus.

All epithelia are supported by a basement membrane. Basement membranes separate epithelia from underlying supporting tissues and are never penetrated by blood vessels; epithelia are thus dependent on the diffusion of oxygen and metabolites from adjacent supporting tissues.

The classification of epithelia is based on: (1) the number of cell layers: a single layer of epithelial cells is termed simple epithelium, whereas epithelia composed of several layers are termed stratified epithelia, and (2) the shape of the component cells: this is based on the appearance in sections taken at right angles to the epithelial surface. In stratified epithelia, the shape of the outermost layer of cells determines the descriptive classification. Cellular outlines are often difficult to distinguish, but the shape of epithelial cells is usually reflected in the shape of their nuclei.

Epithelia may be derived from ectoderm, mesoderm or endoderm, although in the past it was thought that true epithelia were only of ectodermal or endodermal origin. Two types of epithelia derived from mesoderm, i.e., the lining of blood and lymphatic vessels and the linings of the serous body cavities, were not considered to be epithelia and were termed endothelium and mesothelium, respectively. By both morphological and functional criteria, such distinction is of little practical value; nevertheless, the terms endothelium and mesothelium are still used to describe these types of epithelium.

Simple epithelia

Simple squamous epithelium is composed of flattened, irregularly shaped cells forming a continuous surface. The term “squamous” derives from the comparison of the cells to the scales of a fish. Like all epithelia, this delicate lining is supported by an underlying basement membrane. The basement membrane is rarely thick enough to be seen with routine light microscopy.

Simple squamous epithelium is found to line the surfaces involved in passive transport (diffusion) of gases (as in the lungs) or fluids (as in the walls of blood capillaries). Simple squamous epithelium also forms the delicate lining of the pleural, pericardial, and peritoneal cavities where it permits the passage of tissue fluid into and out of these cavities. Reflecting the minimal metabolic activity of these cells, the nuclear chromatin is condensed and the cytoplasm contains few organelles.

Simple cuboidal epithelium represents an intermediate form between simple squamous and simple columnar epithelium. The distinction between tall cuboidal and low columnar epithelium is often very slight. In section perpendicular to the basement membrane, the epithelial cells appear square, leading to its traditional description as cuboidal epithelium; on surface view, however, the cells are actually polygonal in shape. The nucleus is usually round and located in the centre of the cell.

Simple cuboidal epithelium usually lines small ducts and tubules, which may perform excretory, secretory, or absorptive functions; examples are the small collecting ducts of the kidney, salivary glands, and the pancreas.

Simple columnar epithelium is similar to simple cuboidal epithelium, except that the cells are taller and appear columnar in sections at right angles to the basement membrane. The height of the cells may vary from low to tall columnar, depending on the degree of functional activity. The nuclei are elongated and may be located at the base, in the centre or, occasionally, in the apical part of the cytoplasm. This is known as polarity. Simple columnar epithelium is most often found on highly absorptive surfaces such as in the small intestine, although it may constitute the lining of highly secretory surfaces such as that of the stomach.

Simple columnar ciliated epithelium as a type of simple columnar epithelium is traditionally described separately because of the presence of surface specializations called cilia on the apical surface of the majority of the cells. Among the ciliated cells there are some nonciliated cells, which usually perform a secretory function.

Cilia are much larger than microvilli and are badly visible with the light microscope. Each cillum consists of a finger-like projection of the plasma membrane, its cytoplasm containing a motile specialization of the cytoskeleton. Each cell may have up to 300 cilia that, along with those of other cells, beat in a wavelike manner, generating a current, which propels fluid or minute particles over the epithelial surface. Simple columnar ciliated epithelium is not common in humans, except in the female reproductive tract.

Another variant of simple columnar epithelium is described in which the majority of the cells are also usually ciliated. The term pseudostratified is derived from the appearance of this epithelium in section, which conveys the erroneous impression that there is more than one layer of cells. In fact, this is a true simple epithelium, since all the cells rest on the basement membrane. The nuclei of these cells, however, are disposed at different levels, thus creating the illusion of cellular stratification. Not all the ciliated cells extend to the luminal surface; such cells are capable of cell division, providing replacements for lost or damaged cells.

Pseudostratified columnar ciliated epithelium may be distinguished from true stratified epithelia by two characteristics. Firstly, the individual cells of the pseudostratified epithelium exhibit polarity. Secondly, cilia are never present on stratified epithelia.

Pseudostratified epithelium lines the larger airways of the respiratory system in mammals and is therefore often referred to as respiratory epithelium.

Stratified epithelia

Stratified epithelia consist of two or more layers of cells. They mainly perform a protective function, and the degree and nature of the stratification is related to the kinds of physical stresses to which the surface is exposed. The classification of stratified epithelia is based on the shape and structure of the surface cells, since the cells of the basal layer are usually cuboidal in shape.

Stratified squamous epithelium consists of a variable number of cell layers, which exhibit transition from a cuboidal basal layer to a flattened surface layer. The basal cells divide continuously. During the process, the cells undergo first maturation, then degeneration. The surface cells show the process of degeneration; this is particularly evident in the nuclei, which become progressively condensed (pyknotic) and flattened before ultimately disintegrating.

Stratified squamous epithelium is well adapted to withstand abrasion, since the loss of surface cells does not compromise the underlying tissue. It is poorly adapted to withstand desiccation. This type of epithelium lines the oral cavity, pharynx, esophagus, anal canal, uterine cervix and vagina, i.e., the sites, which are subject to mechanical abrasion but which are kept moist by glandular secretion.

The specialized form of stratified squamous epithelium constitutes the epithelial surface of the skin (epidermis) and is adapted to withstand the constant abrasion and desiccation to which the body surface is exposed. During maturation, the epithelial cells undergo a process called keratinization, resulting in the formation of a tough, non-cellular surface layer, consisting of the protein named keratin. Keratinization may be induced in normally non-keratinizing stratified squamous epithelium such as that of the oral cavity when it is exposed to excessive abrasion or desiccation.

Transitional epithelium is a form of stratified epithelium that lines the urinary tract in mammals where it is highly specialized to accommodate a great degree of stretch and to withstand the toxicity of urine. This epithelial type is so named, because it has some features, which are intermediate (transitional) between stratified cuboidal and stratified squamous epithelia. In the contracted state, transitional epithelium appears to be about four to five cell layers thick. The basal cells are roughly cuboidal, the intermediate cells are polygonal, and the surface cells are large and rounded and may contain two nuclei. In the stretched state, transitional epithelium often appears only two or three cells thick, and the intermediate and surface layers are extremely flattened.

The intercellular, luminal, and basal surfaces of epithelial cells exhibit a variety of specializations.

Intercellular surfaces of epithelial cells are linked by several different types of membrane and cytoskeletal specializations. These cell junctions permit the epithelia to form a continuous cohesive layer, in which all of the cells “communicate” and cooperate to meet the particular functional requirements of the epithelium.

Occluding junctions, also known as tight junctions, are located immediately beneath the luminal surface of simple columnar epithelium (e.g., intestinal lining), where they seal the intercellular spaces so that the luminal contents cannot penetrate between the lining cells. Each tight junction forms a continuous circumferential band or zonule around the cell and is thus also known as a zonula occludens.

Adhering junctions tightly bind the constituent cells of the epithelium together and act as anchorage sites for the cytoskeleton of each cell so that the cytoskeletons of all cells are effectively linked into a single functional unit. Adhering junctions are of two morphological types. Deep to the tight junctions of columnar epithelial cells, an adhering junction forms a continuous band (the zonula adherens) around the cell, providing structural reinforcement to the occluding junction. Secondly, adhering junctions in the form of small circular patches or spots called desmosomes (the macula adherens) are circumferentially arranged around columnar cells deep to the continuous adhering junction. The combination of the zonula occludens, the zonula adherens, and circumferentially arranged desmosomes is known as the ajunctional complex. Desmosomes (spot adhering junctions) are also widely scattered elsewhere in epithelial intercellular interfaces, binding the whole epithelial mass into a structurally coherent whole.

Adhering junctions and communicating junctions are not exclusive to epithelia and are also present in cardiac and visceral muscle where they appear to serve similar functions.

The luminal surfaces of epithelial cells may incorporate three main types of specialization: cilia, microvilli and stereocilia. Cilia are relatively long, motile structures, which are easily resolved by light microscopy. In contrast, microvilli are short, often extremely numerous projections of the plasma membrane, which cannot be individually resolved with the light microscope. Stereocilia are merely extremely long microvilli usually found only singly or in small numbers in odd sites such as the male reproductive tract.

Basal surfaces. The interface between all epithelia and underlying supporting tissues is marked by a non-cellular structure known as the basement membrane, which provides structural support for epithelia and constitutes a selective barrier to the passage of materials between the epithelium and supporting tissue. The basal plasma membranes of some simple epithelia, which are very active in ion transport (e.g., the cells of the kidney tubules), exhibit deep basal folds. These greatly enhance surface area and provide an arrangement by which the energy-providing mitochondria can be situated in intimate association with

the plasma membrane. Hemidesmosomes, a variant of the desmosome, are present on the inner aspect of the basal plasma membrane adjacent to the basement membrane and provide a means of anchorage of the cytoskeleton to the basement membrane and underlying supporting tissue.

Glandular epithelia

The epithelium, which is primarily involved in secretion, is often arranged into structures called glands. Glands are the invaginations of epithelial surfaces, which are formed during embryonic development by proliferation of epithelium into the underlying tissue. The glands, which maintain their continuity with the epithelial surface, discharging their secretion onto the free surface via a duct, are called exocrine glands. In some cases, the glands have no ducts. The secretory products of such glands, known as endocrine glands, pass into the bloodstream. Their secretions are known as hormones. Nevertheless some endocrine glands develop by migration of epithelial cells without the formation of a duct. Exocrine glands may be broadly divided into simple and compound glands.

Simple glands are defined as those with a single, unbranched duct. The secretory portions of simple glands have two main forms, tubular or acinar (spherical), which may be coiled and/or branched. Compound glands have a branched duct system, and their secretory portions have morphological forms similar to those of simple glands.

There are three modes of discharge of secretory products from the cells. Merocrine – the secretion may occur by exocytosis from the cell apex into a lumen, so neither the cell membrane nor the cytoplasm become part of the secretion. This is the usual mode of secretion of all gland cells. Apocrine – a small portion of the apical part of cytoplasm is released along with the secretory product. This is an unusual mode of secretion and applies to lipid secretory products in the breasts and some sweat glands. Holocrine secretion involves the discharge of whole secretory cells with subsequent disintegration of the cells to release the secretory product. Holocrine secretion occurs principally in sebaceous glands. In general, all glands have a continuous basal rate of secretion, which is modulated by nervous and hormonal influences. The secretory portions of some exocrine glands are embraced by contractile cells, which lie between the secretory cells and the basement membrane. The contractile mechanism of these cells is thought to be similar to that of muscle cells. These cells are called myoepithelial cells.

The simplest exocrine glands are goblet cells. Goblet cells are modified columnar epithelial cells, which synthesize and secrete mucus. They are scattered among the cells of many simple epithelial linings (of the respiratory and gastrointestinal tracts, etc.).

The distended apical cytoplasm contains a dense aggregation of mucigen granules which, when released by exocytosis, combine with water to form the viscous secretion called mucus. Mucigen is composed of a mixture of neutral and acidic proteoglycans (mucopolysaccharides) and therefore can readily be demonstrated by the PAS method, which stains mucigen pink. The “stem” of the goblet cell is occupied by a condensed, basal nucleus and crammed with other organelles involved in mucigen synthesis.

Simple tubular glands have a single, straight tubular lumen into which the secretory products are discharged. In this example, the entire duct is lined by secretory cells; the secretory cells are goblet cells. In other sites mucus is secreted by columnar cells, which do not have the classic goblet shape but function in a similar way. Simple tubular glands may be found in the large intestine.

Sweat glands are almost the only example of simple coiled tubular glands. Each consists of a single tube, which is tightly coiled in three dimensions. Portions of the gland are thus seen in various planes of section. Sweat glands have a terminal secretory portion lined by simple cuboidal epithelium, which gives way to a nonsecretory (excretory) duct lined by stratified cuboidal epithelium.

Simple branched tubular glands are found mainly in the stomach. The mucus-secreting glands of the pyloric part of the stomach are shown in this example. Each gland consists of several tubular secretory portions, which converge into a single, unbranched duct of a wider diameter; it is also lined by mucus-secreting cells. Unlike the cells of the large intestine, these mucous cells are not goblet-shaped.

Simple acinar glands occur in the form of pockets in epithelial surfaces and are lined by secretory cells. In this example of the mucus-secreting glands of the penile urethra, the secretory cells are pale-stained compared to the non-secretory cells lining the urethra. Note that the term acinus can be used to describe any rounded exocrine secretory unit.

A simple branched acinar gland consists of several secretory acini, which empty into a single excretory duct. Sebaceous glands provide a good example of this type of the gland. Their mode of secretion is holocrine, i.e., the secretory product, sebum, accumulates within the secretory cells and is discharged by degeneration of the cells.

Brunner's glands of the duodenum are the example of compound branched tubular glands. Their duct system is branched, thus defining the glands as compound glands. The secretory portions have a tubular form, which is branched and coiled.

Compound acinar glands are those in which the secretory units are acinar in form and drain into a branched duct system. This type of glands consists of numerous acini, each of which drains into a minute duct. These minute ducts, which are just discernible in the centre of some acini, drain into a system of branched excretory ducts of increasing diameter and are lined by simple cuboidal epithelium. The pancreas is a good example of this type of glands.

Compound tubulo-acinar glands have three types of secretory units, namely, branched tubular, branched acinar, and branched tubular with acinar end-pieces called demilunes. The submandibular salivary gland is the classic example. It contains two types of secretory cells, mucus-secreting cells and serous cells; the former stain poorly, but the latter, which have a protein-rich secretion (digestive enzymes), stain strongly due to their large content of rough endoplasmic reticulum. Generally, the mucous cells form tubular components, whereas the serous cells form acinar components and demilunes.

Endocrine glands are ductless glands. The secretory products diffuse directly into the bloodstream. The secretory products are known as hormones and control the activity of cells and tissues usually far removed from the site of secretion.

Most endocrine glands consist of clumps or cords of secretory cells surrounded by a rich network of small blood vessels. Each clump of endocrine cells is surrounded by a basement membrane, reflecting its epithelial origin. Endocrine cells release hormones into the intercellular spaces from which they diffuse rapidly into surrounding blood vessels.

Lecture 6

Blood and Lymph (T.V. Boronikhina)

Blood, lymph, and all types of connective tissue constitute *the group of internal medium tissues*. The tissues of this group are characterized by the following features: they originate from mesenchyme, display a variety of cells, contain a well-developed extracellular matrix, and maintain body homeostasis.

Blood is a liquid tissue, which circulates throughout the body in the closed system of vessels. Its volume in an average adult is approximately 5 liters. The predominant function of blood is transport. Blood carries gases, nutrients, waste products, hormones, antibodies, and electrolytes throughout the body. Blood is involved in defence reactions of the body, such as phagocytosis, immunity, inflammation, and blood clotting. Blood also helps maintain homeostasis in the body, regulates the osmotic and acid–base balance as well as body temperature.

Blood is composed of formed elements suspended in the fluid intercellular material known as plasma. The relative volume of the formed elements and plasma is about 40 to 45% and 55 to 60%, respectively. This value is called a hematocrit.

Plasma is the fluid extracellular amorphous ground substance of blood. Plasma contains water (90%), organic substances: proteins, hormones, glucose, cholesterol (9%), and inorganic salts (1%). Albumins, globulins, and fibrinogen are the important blood proteins. The plasma composition is studied in the course of biochemistry.

Formed elements are the major area of interest in histology. They include erythrocytes (postcellular structures), leukocytes (true cells), and platelets (cell fragments). The number of formed elements in a certain blood volume is called the blood formula or hemogram. Each cubic millimetre of blood contains 4 to 5 million erythrocytes, 4,000 to 9,000 leukocytes, and 180,000 to 320,000 platelets. Each liter of blood contains 4 to 5×10^{12} erythrocytes, 4 to 9×10^9 leukocytes, and 180 to 320×10^9 platelets.

The morphology of the blood formed elements is studied in blood smears. The specimens are not embedded in paraffin and sectioned. A drop of blood is placed directly on a slide and spread thinly over the surface of the slide, with the edge of another slide to produce a monolayer of cells. This preparation is air-dried and stained according to Romanovsky–Giemsa method, with the use of two dyes: azure II and eosin. On the basis of their appearance after staining, white blood cells are divided into granulocytes and agranulocytes.

Blood is a readily available specimen that can be withdrawn from a patient without any complications. Blood chemistry and blood cytology reveal much about the patient's health. These examinations are not too difficult, and all patients undergo them at the beginning of treatment.

Erythrocytes

Erythrocytes are the most prevalent cells in peripheral blood: each cubic millimetre of blood contains approximately 5×10^6 red cells. Erythrocytes are produced in the red bone marrow from stem cells; their life span is approximately 120 days in the circulation. Red cell destruction occurs in the spleen, and, partially, in the liver.

Erythrocytes are biconcave discs, measure from 7 to 8 μm in diameter, and stain from light salmon to pink in the blood smear. The biconcave-disc shape of erythrocytes considerably enlarges the aggregate surface area of all red cells. The immense capacity of blood to bind and transport gases is partially due to the tremendous surface area of red cells. Erythrocytes are extremely elastic and deform readily when passing through the smallest blood vessels.

Erythrocytes are surrounded by a typical plasma membrane. On the external surface of plasmalemma, the determinants for the A, B, and O blood groups, as well as the Rh-factor, reside. The ultrastructure of erythrocytes is not rich: neither organelles nor nuclei are present in the mature erythrocyte, except for microfilaments of the proteins spectrin and actin. These proteins are associated with the internal aspect of the cell membrane and serve as cytoskeleton for erythrocytes, maintaining their morphology. Since erythrocytes do not possess mitochondria, their energy requirements are met by glycolysis. Nuclei and organelles are lost during erythropoiesis in the bone marrow to clear erythrocyte cytoplasm for hemoglobin. About one-third of the erythrocyte mass is hemoglobin (Hb), a protein composed of four globin chains and an iron-containing porphyrin called heme. When hemoglobin is not present in sufficient amount, either because the normal amount in each cell is decreased or because the amount in each cell is sufficient but the cells are reduced in number, the condition clinically shows up as anaemia.

There are several types of normal hemoglobin in humans known as A₁, A₂ (adult), and F (fetal) hemoglobin. The types of hemoglobin depend on the amino acid sequences of polypeptide chains. HbA₁ is the predominant type in adult blood. HbF is the principal form of hemoglobin in the fetus (in adult only 2%), and its persistence in a high percentage in the adult is indicative of certain forms of anaemia. Additionally, abnormal hemoglobin, such as HbS, may also be present in the human population. HbS is the result of a genetic alteration (point mutation) that causes sickling of the red blood cells. This abnormality in shape occurs in sickle cell anaemia.

Peripheral blood contains immature red cells called reticulocytes, which contain aggregated reticular clusters of ribosomes. Reticulocytes comprise about 1% of all erythrocytes in the blood. Some hemolytic diseases and bleeding cause an abundance of reticulocytes.

Erythrocytes transport oxygen from pulmonary alveoli to peripheral tissues and carbon dioxide from peripheral tissues to pulmonary alveoli. In the lungs, a region of high partial pressure of oxygen, hemoglobin preferentially picks up oxygen to form oxyhemoglobin. In the peripheral tissues, a region of high partial pressure of carbon dioxide, oxyhemoglobin releases its oxygen, exchanging it for carbon dioxide, to form carboxyhemoglobin. Carbon monoxide also binds to the hemoglobin molecule to form carboxyhemoglobin. This bond is much more tenacious than that of oxygen and may cause the death of an individual.

The erythrocyte plasma membrane also takes part in the transport of amino acids and polypeptides.

Platelets

A cubic millimetre of blood contains from 180,000 to 320,000 platelets. Platelets are not cells: they are cell fragments derived from megakaryocytes in the bone marrow. Megakaryocytes are giant polyploid cells. When platelets are formed, small bits of cytoplasm are separated from the peripheral regions of the megakaryocyte. The life span of platelets is less than 2 weeks in circulation, and they are destroyed in the spleen and in the liver.

Platelets are lenticular in shape and measure 2 to 4 μm in diameter. In blood smears, they appear as round or oval particles that may be clustered in small or large masses. Platelets are surrounded by the plasma membrane that has deep surface invaginations connected with a tubular system, which probably functions in sequestering calcium ions. Platelets have a central granulomere, which stains purple in blood smears, and a peripheral hyalomere, which stains faintly. The hyalomere is rich in microfilaments and microtubules. The small bundles of these cytoskeletal elements lie just beneath the plasmalemma and encircle the periphery of the platelet, maintaining its morphology. The granulomere is composed of α -granules, dense bodies, occasional mitochondria, a few lysosomes, and clusters of glycogen particles. The α -granules are from 300 to 500 nm in diameter, contain fibrinogen, platelet thromboplastin, and the

growth factor. The dense bodies are from 250 to 300 nm in diameter, contain pyrophosphate, ADP, ATP, serotonin, and calcium ions.

Platelets are important for blood coagulation and clot formation. When the wall of a blood vessel is cut or broken, platelets adhere to the ruptured end of the vessel. The platelets will aggregate into a platelet clot at the site of vessel injury and will release, among other substances, serotonin and thromboplastin. Serotonin, a potent vasoconstrictor, causes the vascular smooth muscle cells to contract, thereby reducing the local blood flow at the site of injury. Thromboplastin initiates the series of reactions that leads to the formation of a fibrin clot. Thromboplastin transforms prothrombin into thrombin, and the latter, in turn, transforms fibrinogen into fibrin. These reactions require the presence of calcium ions. Platelets aggregate rapidly, adhering to each other and to fibrin. Masses of aggregated platelets and fibrin are the basis for clots. After the definitive clot has been formed, platelets bring about clot retraction, probably as a function of actin filaments in the hyalomere. Finally, after the clot has served its function, platelets are presumably responsible for clot dissolution, probably by releasing lysosomal enzymes into the clot.

Thromboplastin is present in the plasma as well as in the platelets. Platelet-free blood coagulates, though much more slowly, and lymph, which has no platelets, coagulates too.

Pathologically, the platelets may agglutinate and give rise to colourless intravascular clots or thrombi. Deficiency of circulating platelets is clinically known as thrombocytopenia and characterised by slow blood coagulation.

Leukocytes or white blood cells

A cubic millimetre of blood contains from 4,000 to 9,000 leukocytes. They are true cells, containing nuclei and organelles in their cytoplasm. Leukocytes are movable, they can move like an amoeba. White blood cells must be regarded as transitional cells in the blood; they leave the blood through the walls of capillaries and venules to enter the connective tissue, where they perform their specific functions. Leukocytes participate in protective reactions of the body, such as immunity and inflammation.

Leukocytes are subdivided into two groups: granulocytes and agranulocytes depending on the presence or absence of specific granules in their cytoplasm. Granulocytes include neutrophils, eosinophils, and basophils. Agranulocytes include lymphocytes and monocytes. The percentage of various leukocytes is called the leukocytic formula: neutrophils constitute 60 to 70%; eosinophils, 2 to 5%; basophils, 0.5 to 1%; lymphocytes, 20 to 30%; and monocytes, 3 to 11%.

Neutrophils

Neutrophils are the most common leukocytes in normal human peripheral blood; they comprise about 60 to 70% of all leukocytes. Neutrophils are round cells 12 to 15 μm in diameter. The nucleus has three to five lobes connected to each other by thin threads of chromatin. The cytoplasm contains two types of membrane-bounded granules: primary (nonspecific, azurophilic) and secondary (specific) granules. The azurophilic granules, which appear early in granulopoiesis and occur in all granulocytes as well as in monocytes and lymphocytes, are lysosomes.

Primary granules comprise about 20% of the granule population, stain with azure, are visible under the light microscope, and are diagnostic for neutrophils. These granules are lysosomes, which contain various hydrolytic enzymes that function in phagocytosis. They also contain the enzyme myeloperoxidase, producing bactericidal molecular oxygen from hydrogen peroxide (H_2O_2).

Specific granules (secondary) comprise about 80% of the granule population, are small (0.1 to 0.2 μm in diameter), do not stain well, and are not visible under the light microscope. They contain bactericidal substances, namely, lysozyme, phagocytin, collagenase, and alkaline phosphatase. Specific granules also contain the protein lactoferrin, which binds ferric ions required for bacterial multiplication.

The neutrophil cytoplasm includes a few mitochondria, a small Golgi apparatus, little endoplasmic reticulum, and occasional free ribosomes. Glycogen deposits are plentiful. The life span of neutrophils is less than 1 week.

The neutrophil functions are the phagocytosis and destruction of bacteria; hence, neutrophils are microphagocytes. Neutrophils form the first line of defence during acute inflammation.

Bacteria can be phagocytosed after opsonization. During opsonization, microorganisms are coated with immunoglobulin or complement proteins. Neutrophils recognize the immunoglobulin coating on the opsonized bacterium rather than a component of the bacterial cell wall itself. Thus, opsonization facilitates the phagocytosis of bacteria by neutrophils.

Neutrophils migrate from the bloodstream between endothelial cells to enter the connective tissue. Neutrophils first adhere to bacteria and then engulf them in the membrane-bound phagosome. Phagosomes fuse with secondary granules, and bactericidal substances kill the bacteria. Then primary

granules release their hydrolytic enzymes into phagolysosome, digesting the microorganisms. Ultimately, neutrophils may kill themselves. The accumulation of dead neutrophils, macrophages, microorganisms, and tissue fluid constitutes pus.

Immature neutrophils have horseshoe-shaped nuclei and are named band neutrophils. Under normal conditions, no more than 5% of band forms are seen in smears. But if there is a great need for neutrophils in the body, e.g., in cases of infection and inflammation, band neutrophils increase in number. This increase is called a shift in the leukocytic formula to the left.

Basophils

Basophils comprise from 0.5 to 1% of all leukocytes. Often, several hundred white blood cells must be examined in the blood smear before one basophil is found.

Basophils are round cells from 8 to 10 μm in diameter. The basophil has an S-shaped nucleus that is frequently masked by numerous large specific granules. Primary (azurophilic) granules are also present. Specific granules are large (0.5 to 1.3 μm in diameter), membrane-bounded, spherical structures. They contain heparin, histamine, peroxidase, and perhaps SRS-A. These granules stain metachromatically with the mixture of dyes used to stain blood smears. Metachromasia means a change in colour. This is a property of structures to change the colours of dyes, usually basic dyes. In our case, specific basophilic granules change the blue colour of azure for cherry. This property is considered to belong to histamine.

The basophilic plasmalemma contains IgE receptors. When these receptors bind the immunoglobulin complex to specific antigens, the basophils degranulate to produce allergic reactions and, in extremely severe cases, anaphylactic shock.

Basophils regulate tissue homeostasis and contribute to inflammation by releasing histamine, heparin, SRS-A, and the eosinophil chemotactic factor.

Eosinophils

Eosinophils comprise from 2 to 4% of all leukocytes. Eosinophils are round cells, from 10 to 14 μm in diameter. The eosinophilic nucleus has two or three lobes. The cytoplasm contains relatively few organelles and many glycogen deposits. The specific granules are plentiful, and a few azurophilic granules are also present. Specific granules are large, ellipsoidal, membrane-bounded, and stain reddish orange. The electron micrographs depict an elongated crystalline core in these granules. The contents of specific granules are lysosomal enzymes, peroxidase, and the major basic protein. Primary granules are few in number. They contain acid phosphatase, arylsulfatase, and other hydrolytic enzymes.

Eosinophils inactivate histamine and the slow-reacting substance of anaphylaxis released by basophils at inflammation sites. Eosinophils are implicated in inactivating and killing parasitic agents. The major basic protein from crystalloid has a poorly understood antiparasitic function. Eosinophils are believed to phagocytose antibody-antigen complexes too. Allergic reactions and parasite invasions cause an increase in the number of eosinophils in the blood.

Lymphocytes

Lymphocytes comprise 20 to 30% of all leukocytes; they are the most common agranulocytes. They are round, small cells, from 8 to 10 μm in diameter. Lymphocytes have a round deeply staining nucleus that occupies most of the cell volume and a narrow rim of the light blue cytoplasm at the periphery.

Three groups of lymphocytes can be identified according to size: small, medium, and large. In the bloodstream most lymphocytes are small- (more than 90%) or medium-sized.

The ultrastructure of lymphocytes is not rich: small lymphocytes possess a few mitochondria, a poorly developed Golgi apparatus, and a rough endoplasmic reticulum, but contain numerous free ribosomes. A few lysosomes (azurophilic granules) are also present.

There are two types of lymphocytes: T and B lymphocytes. They are classified according to their specific surface determinants and their site of differentiation. T lymphocytes are thymus-dependent. They have membrane-bound receptors, unique cell surface proteins (not antibodies) that appear during cell maturation in the thymus. These surface molecules are required to facilitate the recognition or binding of T cells to foreign antigens. B lymphocytes are so named, because they were first recognized as a separate population in the bursa of Fabricius in birds; while human B lymphocytes develop in the red bone marrow. B lymphocytes have plentiful immunoglobulins on the external surface of the plasma membrane that function as antigen receptors.

There is a third group of lymphocytes, the so-called null cells, possessing no surface determinants. The null lymphocytes may include cells that are circulating hemopoietic stem cells or natural killer cells. These cell types are indistinguishable in blood smears or tissue sections;

immunocytochemical staining for different types of receptors on their cell surface must be used to identify them.

Lymphocytes are the key cells in the immune system. T lymphocytes are primarily responsible for cell-mediated immunity, whereas B lymphocytes provide humoral immunity. When lymphocytes first encounter a specific antigen, they are stimulated to undergo several mitotic divisions and then differentiation into effector cells, i.e., the cells with specific functions. B lymphocytes differentiate into plasma cells. Plasma cells abound in rough endoplasmic reticulum and are involved in antibody production. T lymphocytes differentiate into cytotoxic T lymphocytes (killer, helper, and suppressor). Some B and T cells do not undergo differentiation into effector cells but serve as long-lived memory cells, circulating lymphocytes that can respond more rapidly to their specific antigen.

Monocytes

Monocytes comprise from 3 to 11% of all leukocytes. Monocytes are the largest of all circulating cells (12 to 15 μm in diameter). The monocyte has an acentric, kidney-shaped nucleus. In contrast to lymphocyte chromatin, monocyte chromatin stains uniformly, revealing a delicate network. The cytoplasm of monocytes is blue with numerous azurophilic granules. They are primary lysosomes containing peroxidase, acid phosphatase, and arylsulfatase among other enzymes.

The life span of monocytes is probably less than 3 days in the bloodstream. Monocytes are direct precursors of macrophages. Monocytes migrate into connective tissue and differentiate into macrophages. In the peripheral blood, they are in transit from the bone marrow to the body tissues, where they will differentiate into the various phagocytes of the mononuclear phagocytic system, i.e., the connective tissue macrophages (histiocytes), osteoclasts, alveolar macrophages, perisinusoidal macrophages in the liver (Kupffer cells), and macrophages of the lymph nodes, spleen, and bone marrow. During inflammation, the monocyte leaves the blood vessel at the site of inflammation, transforms into a tissue macrophage, and participates in the phagocytosis of bacteria, other cells, and tissue debris. The monocyte–macrophage also plays an important role in immune responses by concentrating antigen and presenting modified antigens to lymphocytes to facilitate antibody production by immunocompetent cells. The monocyte–macrophage can secrete many substances: interferon, pyrogen, lysozyme, etc.

Lymph

Lymph, like blood, consists of fluid plasma in which various elements are suspended. Red blood cells and platelets are entirely absent, and granulocytes are few in number, the chief cellular elements are lymphocytes. The lymph plasma is similar to that of blood, but it is of less fixed constitution. It carries carbonic acid but very little oxygen.

During digestion, the lymphatics of the intestine become filled with a large amount of fat globules. The lymph assumes white colour and is known as chyle. Many of the fat globules are removed before the lymph reaches the bloodstream.

Lecture 7

Connective Tissues (V.L. Goryachkina)

Connective tissue is a tissue of mesenchymal origin. Connective tissue provides structural and metabolic support for other tissues and organs throughout the body. Connective tissue contains blood vessels and mediates the exchange of nutrients, metabolites and waste products between tissues and the circulatory system.

Classification of connective tissue

1. Embryonic: mesenchyme.
2. Adult (A,B,C).

A. Connective tissues proper:

Loose connective tissue (it is widely distributed in the body), as in dermis (papillary layer), mesentery, omentum, and the lamina propria of tubular epithelial organs.

Dense connective tissue

Irregular: as in periosteum, dermis (reticular layer), and organ capsules;

Regular: as in tendons, ligaments, and cornea.

Special connective tissue

Adipose tissue: as in hypodermis (subcutaneous layer), omentum, mesentery, around the kidneys, etc.

Reticular tissue: spleen, lymph nodes, red bone marrow.

B. Cartilage

C. Bone

Connective tissue consists of cells and extracellular matrix. The cells of connective tissues may be divided into three types according their function:

- Cells responsible for the synthesis and maintenance of the extracellular matrix, e.g., fibroblasts (connective tissue proper), chondroblasts (cartilage), and osteoblasts (bone tissue);
- Cells responsible for the storage and metabolism of fat. These cells are known as adipocytes;
- Cells with defense and immune functions (see below).

The extracellular matrix consists of the ground substance and fibers (collagen fibers, elastic fibers, and reticular fibers). The extracellular matrix is important for spatial organization and mechanical stability.

Ground substance

The ground substance is mainly composed of proteoglycans and hyaluronic acid. Proteoglycans are large molecules. They are composed of core proteins to which glycosaminoglycans (GAGs) are covalently bound. GAGs are large polysaccharides, which maintain turgor and determine the diffusion of substances through extracellular matrix. They can be divided into four groups.

1. Hyaluronic acid.

- (a) it is the main component of connective tissue;
- (b) it is widely distributed in loose connective tissue;
- (c) it has been extracted in significant amounts from cartilage, blood vessels, and skin.

2. Chondroitin sulfate.

- (1) It predominates in cartilage, bone, and blood vessels;
- (2) It has also been identified in the skin and cornea.

3. Dermatan sulfate.

It is found mostly in the skin, but it also has been demonstrated in blood vessels, heart valves, tendons, and connective tissue of the lung.

4. Keratan sulfate and heparan sulfate occur in cornea and cartilage; heparan sulfate is found in the lamina lucida of basement membrane.

GAGs have the following properties: (a) the high negative charge and (b) strongly hydrophilic behavior, with the exception of hyaluronic acid, covalently bound to proteins to form proteoglycans. Besides GAGs, the ground substance contains glycoproteins. They serve as adhesive molecules between the cells and extracellular scaffold. There are some types of glycoproteins in connective tissues.

1. Fibronectin (surface glycoprotein of fibroblasts). It has affinity to collagen.
2. Laminin is a major component of the basement membrane.
3. Entactin is also a component of the basement membrane and binds to laminin.

Fibers. Collagen fibers are composed of fibrillar protein – collagen. The collagens are a large family of proteins, which can aggregate to produce either filaments, fibers, or meshwork, which then interacts with other proteins to provide support in the extracellular matrix. There are at least 20 types of collagen polypeptids (α -chains). They form different fibers. For example, type I collagen forms large bundles of collagen fibers. Their distribution is the skin, dermis, tendons, bone, ligaments, cornea, and loose connective tissue. Type II collagen forms small bundles of collagen fibers. Their distribution: hyaline and elastic cartilage, vertebral disks, vitreous of eye. Type III collagen forms small bundles of collagen (reticular) fibers. They are situated in the blood, vessels, bone marrow, spleen, lymph nodes, lung, and fetal skin. Type IV collagen forms sheet-like layers (basement membranes, the lens capsule).

The formation of collagen fibers

The production of collagen fibers involves series of events, some of which occur inside the cell, while other events occur outside the cell. Intracellular events include the uptake of amino acids (proline, lysine, etc.) by endocytosis, resulting in the production of polypeptide chains in the rER. A number of modifications of the polypeptide chains occur within the cisternae of rER and the Golgi complex. The resultant molecules are called procollagen. Then packing of the procollagen into secretory vesicles occurs inside the cell. These secretory vesicles move to the plasma membrane and leave the cell by means of exocytosis.

Extracellular events include the formation of tropocollagen and the aggregation of tropocollagen into collagen fibers.

Collagen fibers have a 68-nm banding pattern. This banding pattern is a reflection of the arrangement of tropocollagen in forming the fibril. Tropocollagen measures about 300 nm long with a head and a tail. In forming a fibril these molecules become aligned head to tail in overlapping rows with a gap between the molecules within each row. Thus, collagen fibers consist of bundles of fine collagen fibrils.

Elastic fibers

Elastic fibers provide tissues with the ability to respond to stretch and distension. They are thinner than collagen fibers. Elastic fibers are composed of elastin and microfibrils. The protein elastin is rich in proline and glycine but is poor in hydroxyproline. Microfibrils are fibrillar glycoprotein. Elastin is synthesized by the same pathway as collagen.

Cells

Resident cells (fixed cell population).

Fibroblasts, fibrocyte, myofibroblasts

Macrophages

Adipose cells

Mast cells

Undifferentiated cells

Pericytes (in the wall of capillaries and venules)

Pigment cells

Immigrant cells (wandering population)

Lymphocytes

Plasma cells

Neutrophils

Eosinophils

Basophils

Monocytes

Fibroblasts

The fibroblast is a spindle-shaped or stellate cell. Its nucleus has a regular elliptic contour and sparse and scattered chromatin. The ultrastructural organization of the fibroblast reflects its function. The fibroblast contains well-developed rER on which the precursor polypeptides of collagen, elastin, proteoglycans, and glycoproteins are synthesized. Besides rER, it contains many free ribosomes, a well-defined Golgi apparatus, mitochondria, fat droplets, and primary and secondary lysosomes. Additionally, the bundles of actin microfilaments are prominent; they are implicated in cellular motility. The function of the fibroblasts is to produce extracellular matrix.

The fibrocyte is a more elongated cell than the fibroblast. When the fibroblasts become less active during adult life, their nuclei undergo condensation and their cytoplasm appears less basophilic, they are then referred to as fibrocytes. The fibrocyte contains decreased amounts of rER and other organelles.

Myofibroblasts. This cell looks like a fibroblast. The myofibroblast contains rER, Golgi complex, mitochondria, etc. In addition, it contains bundles of longitudinally disposed actin filaments and dense bodies similar to those observed in smooth muscle cells. The myofibroblast plays a role in the contraction of wounds and may synthesize collagen fibers.

Macrophages

Macrophages are long-lived actively phagocytic cells. They are widely distributed throughout the body. They are derived from the blood monocytes. Monocytes leave the bloodstream and migrate to the tissues to turn into macrophages, for example,

- connective tissue (histiocytes),
- liver (Kupffer cells),
- lung (alveolar macrophages),
- lymph nodes (free and fixed macrophages),
- spleen (free and fixed macrophages),
- bone marrow (macrophages),
- serous cavities (pleural and peritoneal macrophages),
- bone tissue (osteoclasts),
- the central nervous system (microglial cells).

Macrophages and their precursors are assigned to the “mononuclear phagocyte system”. The minimal criteria for inclusion in this system are: (1) the derivation from the red bone marrow; (2) characteristic cell structure; (3) high level of phagocytic activity.

It should be noted that the Russian scientist Elie Mechnikoff was the first who to describe the phagocytic cells. More than 100 years ago (1882) he found that vertebrates possessed two types of cells

able to fight invading organisms. These cells are microphages (small eaters) now known as neutrophils and macrophages (big eaters). The latter include monocytes and phagocytosing cells.

The structure of macrophages. The main features of macrophages are abundant lysosomes and phagolysosomes, and numerous folds or fingerlike processes. Moreover macrophage contains a relatively large Golgi region, mitochondria, sER, and rER, and well-developed cytoskeletal elements. Bundles of actin-rich microfilaments are involved in adhesion, endocytosis, and movement.

Note that macrophages can secrete a variety of important molecules.

Secretory products of macrophages

1. Enzymes:

- (a) lysosomal hydrolases,
- (b) neutral proteinases (these enzymes participate in tissue remodeling and damage),
- (c) lysozyme (carbohydrase that digests the cell walls of many microorganisms).

2. Coagulation factors (V, VII, IX, X).

3. Molecules that regulate cell activities and cell proliferation:

- (a) interferon, an antiviral factor,
- (b) interleukin 1 (IL1), mitogenic protein for T-cells,
- (c) the tumor necrosis factor (cachetin), a protein able to kill transformed cells,
- (d) the angiogenesis factor – increases endothelial multiplication. Secretion is increased by hypoxia.

4. Other macromolecules:

- (a) endogenous pyrogen, a fever mediator and
- (b) apolipoprotein E playing an important role in the transport of cholesterol and triglycerides to the liver.

It should be noted that macrophages take part in the immune response. The participation of macrophages in the immune response involves the processing and presentation of antigens to lymphocytes. Macrophages “present” antigens on their surface. A macrophage-bound antigen serves as a trigger in the proliferation of lymphocytes. For this reason this process was termed antigen-dependent proliferation and differentiation of lymphocytes, resulting in the appearance of effector cells: T-killers, T-helpers, T-suppressors, and plasma cells.

Plasma cells

They are antibody-producing cells derived from B-lymphocytes. A plasma cell contains a highly developed rER, a well-developed Golgi apparatus, few lysosomes and mitochondria. Light microscopy shows radially arranged clumps of dense heterochromatin adjacent to the nuclear membrane. This arrangement of chromatin gives the cartwheel appearance to the nucleus. In addition, the well-developed Golgi region gives the light macula appearance near the nucleus.

Mast cells

In 1877 Paul Erlich described these cells and named them "mast" cells (the German for “feeding”). He observed the granules within these cells and presumed that they represented stored nutrients; hence, he named them "mast". As a rule, mast cells are located around blood vessels. They are numerous in the dermis and in the connective tissue of the mucous lining of the respiratory and digestive tract, connective tissue of the lungs, and the serosal lining of the peritoneal cavity. They take part in the metabolism of heparin, histamine, and other mediators producing allergic reactions.

Mediators produced by human mast cells and basophils

Mediator	Function
Histamine	Increases vascular permeability and contracts smooth muscle cells
Heparin	Anticoagulant
Eosinophil chemotactic factors	Attract eosinophils and neutrophils
Slow-reacting substance of Anaphylaxis or leukotriene C	Contracts smooth muscle cells

Note the information about anaphylactic shock:

More than 100 years ago it was found that the second injection of an antigen had harmful effect, and indeed could be fatal. In 1893, this effect was called anaphylaxis (the Greek *ana* – again; *aphylaxis* – defenseless). Anaphylaxis is easily demonstrated in guinea pigs. If a guinea pig is injected a particular antigen and then after 10 to 14 days is injected the same antigen, it goes into what is called anaphylactic shock.

This is manifested by difficulty in breathing and a rapid pulse rate; moreover, the animal may die from an inability to breathe. The reason for respiratory failure is that the smooth muscle cells of small

bronchi become so contracted that their lumen is too narrow to permit an adequate volume of air to enter and, in particular, to leave the lung. Another effect observed in anaphylaxis is that venules and capillaries become dilated and leaky so that the plasma escapes from them. As a result, blebs of plasma may form in the loose connective tissue directly under the epithelium. This phenomenon was called urticaria. It was discovered in 1914 that histamine has a profound effect on smooth muscle cells, causing dilation of capillaries and venules. Leaking plasma can be observed by EM, after breaking the tight junction.

The allergic reaction is known to be mediated by IgE. They are produced by plasma cells in response to certain antigens called allergens. Mast cells and basophils have a high affinity for IgE. IgE attaches to mast cells, but the antigen-combining sites of antibody molecules are exposed. If the antigens reenter the body again, they react with these sites. The combination of antigen with IgE triggers the release of mediators (due to the discharge of granules), producing allergic disease.

The comparative analysis of loose and dense connective tissue

Loose connective tissue	Dense connective tissue	
1. The fibers are thin and relatively sparse.	1. Thick fibers are arranged in bundles. High proportion of collagen fibers.	
2. The ground substance is abundant and occupies more volume than the fibers.	2. There is relatively a small amount of ground substance. Fibers predominate over cells.	
3. Many kinds of cells are widely distributed. <u>Distribution:</u> (a) papillary layer; (b) around vessels and inner organs; (c) tunica mucosa, tela submucosa, and serous membrane	3. The cells population is sparse (usually represented by only one type of cells).	
	irregular	regular
	The fibers are oriented in various directions (the reticular layer of the skin).	The bundles of fibers are oriented in parallel rows to each other (tendons, ligaments).

Functions of the connective tissue proper:

1. Mechanical support (fibers).
2. Exchange of metabolites between blood and tissue (ground substance).
3. Protection against infection (wandering cells).
4. Regeneration after injury (fibroblasts).

Adipose tissue

The adipose tissue is divided into two types: white and brown. White adipose tissue is composed of large fat cells or adipocytes. Every cell contains one flattened nucleus and a large single lipid droplet. If hematoxylin and eosin are used for staining, a hole will be seen instead of a lipid droplet. If special staining (sudan) is used, the lipid droplet stains orange. The EM enables one to see some organelles near the nucleus.

It is noteworthy that fat cells are organized into groups called lobules. The lobules of fat cells are separated by partitions of loose connective tissue; they have been called septa. This connective tissue conducts blood vessels and nerves into adipose tissue.

The sites of white adipose tissue:

1. It is present in the following fatty areas: under the skin (hypodermis), especially in females.
2. It is more condensed in the mammary glands and gluteal region (females).
3. Around the kidney and blood vessels.
4. In the mesentery, omentum, and the abdominal wall.

Note that the white adipose tissue can be divided into two functional kinds:

- I. Storage adipose tissue with fat readily available for energy production (adipose tissue of the hypodermis, mesenteries, omenta, retroperitoneum).
- II. Structural adipose tissue with the role of an elastic pad, mechanical support and protection (adipose tissue in the orbits of the eye, articulations, palms, soles, cheeks, etc.). Note that this adipose tissue remains practically unchanged during fasting.

Functions:

1. Reserve of calorie-rich material (or fat storage).
2. Thermoisolation (heat insulator).
3. Binding of water.
4. Replacement of involuted organs - thymus, red bone marrow.
5. Elastic pad.
6. Mechanical support (around the kidney, vessels, etc.)
7. Unusual function – space reservation for an undeveloped organ (e.g., the mammary gland, which begins to develop only during lactation).

Brown adipose tissue

It appears brown, because it is rich in cytochrome pigments and every cell is surrounded by 3 to 5 blood capillaries. The brown adipose tissue has lobular organization.

It is formed of small polygonal cells. The main features of these cells are as follows:

- (1) they are filled with many lipid droplets and numerous mitochondria;
- (2) the cell nucleus is located in the center of this cell.

The peculiarity of the metabolism of these cells is to produce the heat energy.

Distribution of the brown adipose tissue:

In hibernating animals and laboratory rodents, the brown adipose tissue is found around the thorax, near the thyroid gland and kidney. In humans, this tissue is present in large amounts in newborns. It is located in the axillae, at the nape, in the posterior triangle of the neck, in the vicinity of the thyroid gland, carotid arteries, and renal hilus.

Functions:

1. It acts as a heat generator; it distributes the heat energy to the underlying body tissues. It is very important for hibernators, e.g., the Russian bear. During winter it sleeps in the den. It does not freeze, because its blood is warmed during hibernation.
2. The brown adipose tissue is also a calorie-rich reserve material (fat storage).

Functions of connective tissues

1. Connective tissues (especially loose connective tissue) provide the exchange of nutrients, metabolites, and waste products between tissue and circulatory system.
2. Defense (protection) against pathogens microorganisms. Some connective tissue cells take part in immune response and phagocytosis.
3. The supporting function is provided by the presence of numerous collagen and elastic fibers in the intercellular matrix, e.g., irregular dense connective in the dermis or ligaments and tendons.
4. Connective tissues take part in tissue repair. Note that the processes of tissue repair are largely a function of connective tissues.
5. Morphogenetic function. For example, dense connective tissue is involved in the formation of capsules of many organs and trabeculae inside the organs.

Lecture 8**Cartilage and Bone (T.V. Boronikhina)**

Cartilage and bone are specialized types of connective tissues with skeletogenic function.

Cartilage

There are three types of cartilage: hyaline cartilage, elastic cartilage, and fibrocartilage. Hyaline cartilage is the most common cartilage in the body. It is located in the nose, larynx, trachea, and bronchi. It forms the cartilaginous parts of the ribs. It covers the articular surfaces of bones and can be found at the epiphyseal plates in the bones of growing children. Hyaline cartilage serves as the skeleton of the fetus. The matrix of hyaline cartilage appears glassy in the living state; the name hyaline is derived from the Greek “hyalos” meaning “glassy”.

Hyaline cartilage has a unique matrix and characteristic cells. The cartilaginous matrix is firm but pliable. It is composed of amorphous ground substance, type II collagen fibrils, and elastic fibrils. Collagen fibrils are prevalent and constitute about 40% of the total matrix, but they are not discernible in histologic sections, because the fibrils are very fine and have the same refractive index as the amorphous substance. The amorphous ground substance is rich in proteoglycans, hyaluronic acid, chondroitin sulphates, and keratan sulphate. The matrix adjacent to chondrocytes (the capsular matrix) is poor in collagen, but rich in glycosaminoglycans, and stains deeply basophilic. The cartilage matrix is highly hydrated. Much of this water is tightly bound to the proteoglycan aggregates, which explains the resilience of cartilage. Some of the water is loosely bound, providing high matrix permeability.

Cartilage lacks blood vessels. Nutrients, waste materials, and hormones pass to and from the cells via diffusion, except high molecular weight proteins, e.g., immunoglobulins. Therefore, cartilage transplantation in humans is successful: the engraftment is easy and the homografts are long-lasting. Again, if the matrix composition changes, its permeability may become worse. As a result, hyaline cartilage undergoes some changes: the cells hypertrophy and die, and the matrix becomes calcified.

The perichondrium is a connective tissue envelope surrounding cartilage, except at articular surfaces. The perichondrium is composed of an outer fibrous layer and an inner cellular layer. The fibrous layer contains type I collagen and elastic fibrils, fibroblasts, and blood vessels. The cellular layer contains the chondrogenic cells and chondroblasts. The perichondrium provides cartilage with nutrients and takes part in cartilage growth.

Chondrogenic cells differentiate into chondroblasts. Chondroblasts secrete extracellular matrix and are capable of mitotic division. Chondroblasts surrounded by their secretion are called chondrocytes. Chondrocytes are mature cartilaginous cells. They are proliferous cells and retain secretory activity. Located superficially, chondrocytes are ovoid and positioned so that their longitudinal axes lie parallel to the cartilage surface. Located deeper, they are more spherical and arranged in groups of four to eight cells, the so-called isogenous groups. The isogenous group cells result from successive mitotic divisions of one chondrocyte and cannot be dispersed in the dense matrix.

Chondroblasts and chondrocytes have the fine structure typical of cells that synthesize large amounts of proteins and polysaccharides to be secreted from the cells. The electron micrographs display an abundant rough endoplasmic reticulum, an extensive Golgi apparatus, and numerous mitochondria. Chondrocytes contain many cytoplasmic vacuoles with collagen precursors and glycoproteins. Chondrocytes also have large amounts of nutrients such as lipid droplets and glycogen deposits, because they exist so far from blood vessels.

There are two mechanisms of cartilage growth, the so-called appositional and interstitial growth. The appositional growth occurs from chondrogenic cells differentiating into chondroblasts, forming a new layer of matrix around the periphery of the existing cartilage. The interstitial growth is the process that forms new cartilage within the cartilage mass by chondrocyte divisions and chondrocyte matrix secretion.

Elastic cartilage is found in the ear, the auditory tube, the epiglottis, and parts of the larynx. The matrix of elastic cartilage is identical to that of hyaline cartilage, but it contains a rich network of elastic fibers that imparts to it a yellowish colour. Under the light microscope, untreated elastic cartilage appears similar to hyaline cartilage. However, special stains reveal elastic fibers composed of elastin. Elastic cartilage possesses a perichondrium with chondroblasts, its chondrocytes form isogenous groups. It does not degenerate as readily as hyaline cartilage: the matrix of elastic cartilage never undergoes calcification.

Fibrocartilage exists in the annulus fibrosus of intervertebral disks, the pubic symphysis, in the menisci of the knee joint, and in the junctions between large tendons and the articular cartilage in large joints. It does not occur alone, it serves as a transition between hyaline cartilage and connective tissue. The fibrocartilage extracellular matrix contains fewer glycosaminoglycans and by far more collagen fibers than hyaline cartilage. Collagen fibers are arranged in parallel bundles, like a tendon. The fibrocartilage chondrocytes lie in longitudinally disposed columns between collagen bundles.

Bone

Bone as an organ includes bone tissue, periosteum, endosteum, blood vessels, articular cartilages, and bone marrow, both red and yellow.

The bone serves as a support for the body and provides for attachment of muscles. It also protects the central nervous system and vital organs and contains bone marrow, which functions in hemopoiesis. The bone is an important calcium reserve, containing about 99% of the body's calcium, an element essential for muscle contraction, enzymatic activities, transmission of nerve impulses, cell adhesion, and blood coagulation.

The bone matrix contains organic and inorganic portions. The organic portion is composed of about 95% type I collagen and amorphous ground substance. The latter contains chondroitin sulphates, keratan sulphate, and osteomuroid, e.g., protein differing from collagen. The inorganic portion represents about 50% of the dry weight of the matrix and is composed of calcium, phosphorus, bicarbonate, citrate, magnesium, potassium, and sodium. The extracellular matrix also contains hydroxyapatite crystals $[\text{Ca}_{10}(\text{PO}_4)_6(\text{OH})_2]$, which are formed of calcium and phosphorus.

Both bone matrix components work synergistically to produce the extraordinary tensile strength and flexibility of bone. If the organic matrix is removed from a bone, the remaining mineralized bone is extremely brittle. If the mineral component of the bone is removed by prolonged exposure to acid, the bone becomes rubbery.

The mineralized bone matrix prevents free diffusion; therefore, in contrast to cartilage, bone is not avascular. The blood vessels entering the periosteum and endosteum penetrate the bone matrix via Volkmann's canals, which run perpendicularly to the haversian canals that they interconnect.

The periosteum is a noncalcified connective tissue layer covering bone on its external surfaces, except articular regions. It is composed of an outer fibrous and an inner cellular layers. The outer layer consists mostly of a dense collagenous connective tissue containing blood vessels; the inner layer is more cellular and contains osteogenic cells and osteoblasts. Periosteum collagen fibers, the so-called Sharpey's fibers, penetrate the bone matrix and attach the periosteum to bone. The periosteum is a source of osteogenic cells and provides bone with blood supply.

The endosteum is a specialized connective tissue lining the marrow cavities of bone. It contains the same elements as the periosteum but is thinner. The endosteum also supplies osteogenic cells and osteoblasts for growth and repair.

Osteogenic cells are derived from embryonic mesenchyme. Osteogenic cells are spindle-shaped cells in the periosteum and endosteum that are capable of differentiating into osteoblasts. A low O₂ tension may cause these cells to be transformed into chondrogenic cells.

Osteoblasts are derived from osteogenic cells and secrete the organic portion of the bone matrix. On the bone surface, osteoblasts may resemble a cuboidal layer as they begin to secrete the organic matrix. Later, as the matrix synthesis declines, they assume a flattened morphology. Osteoblasts contain cytoplasmic processes that bring them into close contact with other osteoblasts and osteocytes. The electron micrographs reveal in their cytoplasm a well-developed rough endoplasmic reticulum, Golgi apparatus, and numerous granules containing the precursors of glycosaminoglycans. The matrix secretion entraps the osteoblast in a lacuna with its cytoplasmic processes. Ceasing its secretory function, it changes its morphology and becomes an osteocyte.

Osteocytes are derived from osteoblasts. These mature bone cells housed in their own lacunae maintain communication with each other via gap junctions between their narrow cytoplasmic processes extending through the canaliculi. The nutrients and metabolites within canaliculi nourish and maintain these cells. The electron micrographs display, in contrast to osteoblasts, increased amounts of condensed nuclear chromatin, reduced amounts of rough endoplasmic reticulum, and a small Golgi apparatus in osteocytes. Osteocytes do not manufacture the bone matrix, but they maintain bone homeostasis.

Osteoclasts are multinucleated giant cells, possessing as many as 50 nuclei. They are derived from the blood monocytes and responsible for bone resorption and remodelling. The osteoclasts are located in their own lacunae, e.g., depressions located on the bone surface. These lacunae result from the osteolytic activities of osteoclasts. The electron micrographs display a ruffled border in osteoclasts. The ruffled border is composed of plasma membrane finger-like evaginations along the lacunar surface. Active bone resorption occurs here. The function of osteoclasts is osteolysis, effected by creating an acidic environment that decalcifies the surface bone layer. Acid hydrolases, collagenases, and proteolytic enzymes then degrade decalcified material, and the cell resorbs the organic and inorganic residues of the bone matrix.

There are two types of bone tissues: coarsely bundled bone tissue (primary, immature) and lamellar bone tissue (secondary, mature).

The primary bone tissue matrix contains thick bundles of collagen fibrils, which may lie parallel to each other with osteocytes between them. This type of bone occurs mostly in embryogenesis. Later, the immature bone tissue is remodelled and replaced by secondary bone tissue, except in certain places such as the tooth sockets, the skull suture lines, and the insertion sites of tendons.

The lamellar bone tissue replaces primary bone. Its collagen is arranged in lamellae (3 to 7µm thick). The osteocytes in lacunae are located between the lamellae and occasionally within them.

The lamellar bone tissue forms two types of bone substance: spongy and compact bone substance. The spongy substance is found at the epiphyses and within the diaphyses of long bones, in flat and short bones. The lamellae of spongy substance are irregularly arranged. Spongy bone is filled with spaces that are interconnected. These spaces in long bones often contain bone marrow, which may be either red (containing hemopoietic cells) or yellow (containing primarily fat). The compact substance is found at the diaphyses of long bones, in flat and short bones. The compact bone matrix is arranged in osteons or haversian systems. The osteon is cylindrical and composed of 4 to 20 concentric lamellae, surrounding a Haversian canal that transmits blood vessels, nerves, and some loose connective tissue with osteoblasts and osteoclasts.

In the diaphyses of long bones, lamellae exhibit a special arrangement: there are outer circumferential lamellae and inner circumferential lamellae, as well as typical osteons, and interstitial

lamellae between osteons. The perforating canals (Volkmann's) are the communication channels between the haversian systems, the periosteum, and the marrow cavity.

Bone histogenesis

The bone is derived from embryonic mesenchyme and develops in one of two ways: intramembranous bone formation involves development within a layer of condensed mesenchyme; and endochondral bone formation occurs via a cartilage model that is replaced by bone. Bone remodelling continues throughout life.

Intramembranous bone formation (direct osteogenesis) is typical of flat bone development. It begins when mesenchymal cells condense to form a primary ossification centre, from which osteoblasts differentiate and begin to secrete the matrix. The osteoblasts are trapped by their own matrix and become osteocytes. The osteoblasts and bone matrix with entrapped osteocytes constitutes a bone trabecula. Bone trabeculae calcify and join together. The primary bone forms first and is later replaced by the secondary bone. Blood vessels invade the area at the time when undifferentiated mesenchymal cells give rise to the bone marrow cells.

Endochondral bone formation (indirect osteogenesis) is typical of long bone development. It begins in the hyaline cartilage model. A primary centre of ossification occurs at the midriff of the diaphysis of the cartilage model. The vascularization of the perichondrium at the midriff of the cartilage model causes the transformation of chondrogenic cells into osteogenic cells, which in turn differentiate into osteoblasts. The osteoblasts elaborate the bone matrix on the cartilage core beneath the perichondrium, now known as the periosteum. The new bone appears as the subperiosteal collar (or cuff), is named the perichondral bone, and is formed similar to intramembranous bone formation. In histologic sections, the perichondral bone matrix stains acidophilic.

The chondrocytes within the cartilage model hypertrophy and begin to degenerate, the cartilaginous matrix undergoes calcification. The periosteal bud – osteogenic cells, osteoclasts, and blood vessels from the bone collar – penetrates the cartilage model. Osteoclasts begin to resorb the mineralized cartilage matrix, and osteoblasts elaborate and calcify the bone matrix, forming a calcified cartilage–calcified bone complex, the so-called endochondral bone. In histologic sections, the calcified cartilage stains basophilic, while the calcified bone stains acidophilic.

The bone collar becomes thicker and elongates toward the epiphysis. The osteoclasts resorb the endochondral bone, establishing the primitive marrow cavity. The processes recur and spread toward the epiphysis, where the secondary centre of ossification occurs. The sequence of events is similar, but not identical, to that occurring at the primary centre. The ossification begins when osteogenic cells from the blood and adjacent periosteum invade the epiphysis and differentiate into osteoblasts that elaborate the bone matrix to replace the disintegrating cartilage.

The remaining cartilage now possesses two areas: an articular surface that will remain through life and the epiphyseal plate that will be replaced by bone when growth ceases. The epiphyseal plate continues to grow by adding new cartilage at the epiphyseal end while it is being replaced by bone at the diaphyseal end. The diaphyseal bone becomes continuous with epiphyseal bone at about 20 years of age, as the epiphyseal plate ceases to grow and is replaced. In histologic sections, the epiphyseal plate appears as a zone of cell proliferation: rapid mitotic divisions give rise to rows of isogenous cell groups. This zone is called the columnar cartilage.

Influence on bone

Nutrition greatly affects bone development. Low-protein diets result in a deficiency of amino acids essential for collagen synthesis by osteoblasts. Lack of calcium, either from a low intake or inadequate absorption by the small intestine (due to lack of vitamin D) results in poorly calcified bone, which leads to rickets in children and osteomalacia in adults.

Vitamin D is also necessary for ossification, and hypervitaminosis D causes bone resorption. Vitamin A deficiency inhibits bone formation and growth, while excessive amounts of vitamin A accelerate the ossification of the epiphyseal plates. In either case, smaller stature results. Vitamin C is necessary for collagen formation; its deficiency results in scurvy, characterized by poor bone growth and inadequate repair after fractures.

Parathyroid hormone activates osteoclasts that resorb and release calcium, thus elevating the blood calcium levels. Calcitonin inhibits matrix resorption and prevents the release of calcium, thus decreasing the blood calcium levels. The pituitary growth hormone stimulates epiphyseal cartilage growth, so that its excess produces a giant, while its lack produces a dwarf. Acromegaly, a disease characterized by very thick long bones in adults, results from an excess of the growth hormone. Sex hormones affect bone growth by influencing epiphyseal ossification. In excess, a small stature develops; in deficiency, a tall stature results.

Lecture 9

Muscle Tissues (V.L. Goryachkina)

Muscle tissues are responsible for movements of the body and for changes in the size and shape of internal organs. Muscle tissues are classified on the basis of their appearance. Two different types of muscle tissues are recognized: striated and smooth. Striated muscle tissue is subclassified on the basis of its location: skeletal muscle tissue and cardiac muscle tissue.

Skeletal muscle tissue

Skeletal muscle tissue is responsible for voluntary movement under the influence of the nervous system.

Skeletal muscle tissue is composed of parallel striated muscle fibers, surrounded and held together by loose connective tissue. Tendons or some other arrangements of collagenous fibers attach to the ends of these fibers.

Every muscle fiber is cylindrical in shape, 10 to 100 μm in diameter and several centimeters in length. Each muscle fiber is a multinucleated cell formed by fusion of individual cells (myoblasts) in the process of development. Many nuclei are situated under the plasmalemma of a muscle fiber. Each muscle fiber has hundreds of myofibrils running parallel along its length. About 80% of sarcoplasm (derived from the Greek *sarcos* meaning flesh) is occupied by myofibrils separated from each other by mitochondria and sarcoplasmic reticulum. A considerable amount of glycogen, free ribosomes, and a variable number of lipid droplets can be found in sarcoplasm.

Each myofibril has characteristic banding patterns (dark and light bands). When observed under polarized light, the dark-staining bands are birefringent (anisotropic), while the light-staining ones are isotropic. Accordingly, the dark bands are called A-bands (A stands for "anisotropic") and the light ones, I-bands (I stands for "isotropic"). Owing to these alternations of dark and light bands, transverse striations in a muscle fiber can be seen with light microscope.

In addition, fine dark lines called Z-lines can be seen bisecting the light band (I-band). The Z-lines divide each myofibril into numerous contractile units, called sarcomeres, arranged end to end. The sarcomere is the functional unit of a myofibril.

If hematoxylin and eosin, are used muscle fibers stain pink due to the presence of numerous myofibrils.

The ultrastructure of muscle fibers

Each muscle fiber is surrounded by the sarcolemma. It consists of two layers: the plasmalemma (inner layer) and the basement membrane (BM). Satellite cells are interposed between BM and plasmalemma. They are stem cells. These cells are in the G_0 phase. They can proliferate after minor injury to give rise to myoblasts. Numerous mitochondria, nuclei, and Golgi apparatus are located beneath the sarcolemma.

The ultrastructure of myofibrils

Each myofibril consists of two types of filaments: thick and thin filaments. A-bands are composed of thick filaments, I-bands are composed of thin filaments. Note that both thick and thin filaments have some overlapping only in the peripheral regions of A-bands. The region of A-band, where thick and thin filaments do not overlap, was called H-bands. It should be noted that both ends of thick filaments, however, have only one end free; the other is attached to a Z-line. Thus, the thin filaments extend from each Z-line toward the middle of the sarcomere, where they project in between the thick filaments so as to interdigitate with them. A dark line can be seen in the center of an A-band. It was called M-line. The M-line is formed of a thickened segment of myosin filaments. The special protein myomesin holds myosin filaments in the region of the M-line.

The structure of thick and thin filaments at the molecular level

Each thick filament is composed of myosin molecules. Myosin molecule consists of subunits of meromyosins: (1) light meromyosin (LMM) is straight and forms the backbone of myosin filament with adjacent LMM subunit; (2) heavy meromyosin (HMM) is composed of two parts: HMM S-2 fragment projecting outward from the backbone of myosin filament and HMM S-1 fragment forming the head or the cross bridge of a myosin molecule. HMM S-1 represents an active part of myosin molecule, since it contains ATP and sites for binding ATP and actin filaments. Note that the myosin molecule has two hinge regions (near the head and at some distance from the head). These hinges permit the heads to move during relaxation. The myosin head is believed to oscillate back and forth.

Each thin filament is composed of three proteins: actin, troponin, tropomyosin. Each thin filament is formed by the polymerization of many single molecules of globular actin. Some globular actins have special active sites of actin for the binding of myosin heads. Tropomyosin winds around an actin filament

to stabilize it and to prevent the interaction between myosin heads and actin. The troponin complex is attached to tropomyosin. The troponin complex consists of three polypeptides named troponin T, I, and C. Note that the troponin C region binds Ca^{++} ions.

In addition to myosin, actin, tropomyosin, and troponin, some accessory proteins are also present. Titin (or connectin) runs parallel to the filament array and links the ends of the thick filaments to Z-disk. Desmin filaments link adjacent myofibrils to each other and maintain their register. In addition, they link myofibrils to the cell membrane.

Myofibrils are surrounded by the sarcotubular network. It was named the sarcotubular system. It consists of two types of tubules: L-tubules and T-tubules. L-tubules are the tubules of smooth sarcoplasmic reticulum running parallel or longitudinally to myofibrils. These tubules were therefore termed L-tubules of the L-system. L-system tubules open into terminal cisternae (enlargements of sarcoplasmic reticulum). The latter are continuous and completely surround each myofibril. Two adjacent cisternae do not communicate, since between them a T-tubule is interposed to form a triad. The T-tubules are transversely oriented canalicular invaginations of the plasma membrane. These tubules penetrate to all levels of muscle fibers.

The functions of T-tubules:

1. As T-tubules are connected with the extracellular space, some nutrients pass across T-tubules from the extracellular space into the fiber. The nutrients enter the sER owing to the presence of triads.
2. They conduct waves of depolarization directly to terminal cisternae.

The functions of sER (L-system):

1. Formation of glycogen and lipids.
2. Transportation of nutrients from the triad into the fiber.
3. Ca^{++} reservoir (terminal cisternae).

Contractile mechanism: the sliding filament model

Every striated muscle fiber is innervated by the terminal branch of a motoneuron. It is located in the spinal cord. The terminal part of a nerve fiber (axon) contacts with the surface of a muscle fiber forming a myoneural junction. It was called the motor end plate. When the wave of depolarization reaches the terminal part of the axon, the vesicles that contain acetylcholine fuse with the plasmalemma and empty their contents into the cleft.

Acetylcholine reacts with receptors that are situated on the muscle fiber plasmalemma. It is noteworthy that part of acetylcholine will be destroyed by the enzyme acetylcholinesterase to prevent continued stimulation. When acetylcholine combines with receptors, the sarcolemma permeability increases and the wave of depolarization arises and moves inside the fiber, reaching the terminal cisternae, which contain a high concentration of Ca^{++} ions and have electrically sensitive Ca^{++} ion channels in their wall. Membrane excitation of the T-tubule system causes these Ca^{++} ion channels to open, thus allowing Ca^{++} ions to flood into the sarcoplasm and to reach troponin (a special site for binding Ca^{++} ions). When Ca^{++} ions come into contact with troponin, the latter begins to contract (it becomes shorter) and tropomyosin becomes shorter, too. Troponin pulls tropomyosin, thus changing its disposition, and the active sites of actin become liberated from the tropomyosin block. The heads of myosin bind with the active sites of actin to form cross-bridge complexes. The contraction of these cross-bridge complexes causes the actin filaments to slide along the length of myosin filaments. This process is repeated many times during the contraction, causing individual sarcomeres to shorten. Membrane pumps in the sarcoplasmic reticulum rapidly pump the Ca^{++} ions back into the sER, and the contraction ceases. This mechanism of contraction was termed the sliding filament mechanism of contraction.

It will be interesting for future doctors to know that in myasthenia gravis characterized by muscular weakness (the Greek *mys* meaning muscle; *asthenia*, weakness), the plasmalemma of muscle fibers has fewer receptors. As a result, the muscle can respond to the nerve stimulus by only a feeble contraction. It is known that during this disease the receptors are attacked by antibodies (this was called autoimmune reaction directed against these receptors).

The structure of skeletal muscles as an organ

Skeletal muscles consist of striated muscle fibers held together by connective tissue. Every muscle fiber is surrounded by a delicate layer of loose connective tissue (it was called endomysium). Capillaries and nerves run in parallel to muscle fibers. Each fiber is provided with several capillaries. The perimysium is a thicker connective tissue layer, it surrounds groups of fibers. Larger blood vessels and nerves travel in the perimysium. The epimysium is the sheath of dense connective tissue that surrounds the whole muscle.

Innervation of fibers and motor unit

Muscle fibers are innervated by a motor neuron (motoneuron). The single motor neuron may innervate from 1 to 2000 fibers. It was termed the motor unit, i.e., the motoneuron and the muscle fibers it innervates. It is noteworthy that the structure and biochemical and physiological features of a muscle fiber depend on innervation. So, if a large neuron innervates a fiber, this fiber will have specific features; if a small neuron innervates a fiber, this fiber will have specific features, too. Owing to these features, muscle fibers are divided into three types: red (type 1 or slow-twitch fibers), white (type 2A – fast-twitch, fatigue-resistant fibers), and white (type 2B – fast-twitch, fatigue-sensitive fibers). Note that the red fibers (type 1) show a high level of oxidative metabolism; type 2A fibers, oxidative and glycolytic metabolism; type 2B fibers, only glycolytic metabolism. Some muscles have the same proportion of type 1 and type 2 fibers. In general, muscles that maintain posture (e.g., calf muscles) have a high proportion of type 1 fibers, while muscles used for a short burst of power abound in type 2 fibers. Thus, skeletal muscles consist of a mixture of different types of fibers, and the pattern often reflects the activity of the muscle.

A muscle contains stretch receptors. Sensory fibers provide information on the tension of skeletal muscle from two sources: (a) encapsulated nerve ending responding to stretch in the tendon associated with a muscle; (b) spiral nerve endings in muscle spindles sensitive to stretch and tension.

The muscle spindle is composed of a fusiform capsule of dense connective tissue surrounding a group of 8 to 15 thin fibers. These fibers are termed intrafusal fibers. Two types of intrafusal fibers are distinguished: those with a fusiform shape and a central arrangement of nuclei (nuclear bag fibers) and those of uniform width with dispersed nuclei (nuclear chain fibers).

Specialized motor nerve fibers innervate the intrafusal fibers. The spiral nerve endings are wrapped around the intrafusal fibers and form special sensory afferent fibers running back to the spinal cord.

Cardiac muscle tissue

Cardiac muscle tissue is composed of cells (cardiomyocytes). Cardiac muscle cells are mononuclear. Their nuclei are placed centrally. Between cardiomyocytes there is a very thin layer of loose connective tissue and a rich capillary blood supply. Cardiomyocytes appear to branch and anastomose with neighboring cells. Cardiac muscle cells are linked into long functional fibers by specialized cell junctions, which anchor each cell to its neighbor. Intercellular junctions, which can be seen in light microscopic preparations as straight lines running transversely across the fibers, are termed intercalated disks. This disk contains three types of junctions: (1) desmosomes, (2) fascia adherens, i.e., adherent-type junctions anchor the actin filaments of myofibrils to the end of the cell; (3) gap junctions (nexus) facilitate the passage of membrane excitation.

Ultrastructurally, cardiac muscle cells contain myofibrils virtually identical to those in skeletal muscle fibers; mitochondria are prominent in these cells. Cardiomyocytes contain a well-developed sER (L-tubules and T-tubules).

The molecular basis of the cardiac muscle contraction is very similar to that of the skeletal muscle contraction.

There is no population of stem cells in cardiac muscle; therefore, regeneration following damage cannot occur. Note that mature cardiac muscle cells do not divide. Destroyed cardiac muscle cells are replaced by connective tissue.

Smooth muscle tissue

Smooth muscle tissue forms contractile portions of the wall of most hollow viscera (e.g., gut, urinary bladder, and uterus), as well as contractile elements in blood vessels. It is also found as organized muscle bundles in the iris and ciliary body of the eye, as a thin sheet in the skin of the scrotum (the dartos muscle) and some bundles of smooth muscle cells in association with hair follicles (arrector pili muscles).

Smooth muscle tissue is composed of smooth muscle cells. These cells are spindle-shaped and tapering. Each cell contains one rod-shaped nucleus. The nucleus is centrally located, and there are no transverse striations. Each smooth muscle cell is surrounded by the basement membrane. Owing to the presence of the basement membrane, smooth muscle cells are anchored together. Note that gap junctions (nexus) connect the adjacent cells at the defect in the basement membrane. Small groups of smooth muscle cells are organized into bundles by loose connective tissue containing blood vessels and nerves.

Ultrastructurally a smooth muscle cell contains mitochondria, the Golgi apparatus, scattered profiles of rER, and free ribosomes. These organelles are mostly confined to a conical region at each pole of the nucleus. The rest of the cytoplasm is occupied largely by thin filaments. Thin filaments are composed of actin (an isoform specific to smooth muscle) and tropomyosin. There is no troponin in smooth muscle cells in contrast to striated muscle fibers. Characteristic dense bodies are distributed throughout the cytoplasm. The thin filaments appear to be inserted into these dense bodies. Some dense

bodies are directly connected with the plasmalemma. These dense bodies contain α -actinin and are evidently comparable to Z-lines of the skeletal muscle.

The abundant intermediate filaments of smooth muscle are also inserted into the dense bodies. Thick filaments are present in the smooth muscle cells, too. These filaments are composed of myosin, but of a different type to that of skeletal muscle and will only bind to actin if its light chains are phosphorylated; this phenomenon does not occur in skeletal muscle.

Smooth muscle cells have no T-system. A large number of pinocytotic vesicles are associated with the sarcolemma and sER. The vesicles and sER sequester the calcium that is released to stimulate contraction.

The contraction mechanism of smooth muscle cells differs from that of striated muscle fibers. The contractile proteins are arranged in a criss-cross lattice inserted circumferentially into the cell membrane. Due to such an arrangement of the contractile proteins, contraction results in shortening of the cell, which assumes a globular shape in contrast to its elongated shape in the relaxed state. The next feature of the contractile mechanism is associated with the control of Ca^{++} ion movement. In a relaxed smooth muscle cell, free Ca^{++} ions are normally sequestered in the sER throughout the cell. When the membrane is excited, free Ca^{++} ions are released into the cytoplasm and bind to the protein called calmodulin (calcium-binding protein). The calcium-calmodulin complex then activates an enzyme called myosin light chain kinase. The latter phosphorylates the myosin light chains. When these are phosphorylated, the myosin heads can react with actin and permit it to bind to actin. Actin and myosin interact by filament sliding to produce contraction in a way similar to that for skeletal muscle.

Smooth muscle cells are specialized for slow, prolonged contraction without fatigue. Contraction of smooth muscle cells is under the regulatory control of the autonomic nervous system (see the lecture on *The Nervous System*). Nerve terminals are located at a considerable distance from smooth muscle cells. However, not all smooth muscle cells are exposed directly to the nerve terminal. The contraction of smooth muscle cells is propagated from cell to cell via gap junctions. Note that smooth muscle cell contraction may also be stimulated by hormones.

Secretion

Smooth muscle cells have a well-developed rER and a well-developed Golgi complex. Smooth muscle cells secrete the extracellular matrix elements. Depending on the site, smooth muscle cells produce collagen, elastin, and other components of the extracellular matrix.

Renewal and repair

Smooth muscle cells may respond to injury by undergoing mitosis. Additionally, there are regularly replicating populations of smooth muscle cells. For example, smooth muscle cells in the uterus proliferate during the menstrual cycle and pregnancy.

Lecture 10

Nervous Tissue – I (S.L. Kuznetsov)

Nervous tissue consists of two principal types of cells: nerve cells (neurons) and supporting cells (glia).

The neuron or nerve cell is a functional unit of the nervous system. Nerve cells are specialized to receive stimuli and to conduct electrical impulses to other parts of the system. They are arranged as an integrated communications network, with several neurons in a chain-like fashion typically involved in sending impulses from one part of the system to another.

The specialized contacts between neurons that provide for the information from one neuron to the next in the chain are called synapses.

Supporting cells are nonconducting cells that are in intimate physical contact with neurons. In the central nervous system, they are called neuroglia or, simply, glia.

There are many blood vessels in both the central and peripheral nervous systems. The blood vessels are separated from the nervous tissue by the interposition of basal laminae and a variable amount of connective tissue. In the central nervous system, the boundary between the blood vessels and nervous tissue is so strong that many substances that readily leave the blood vessels to enter other tissues do not normally enter the nervous tissue. This construction in the central nervous system is known as the blood-brain barrier.

The neuron (nerve cell)

It is the structural and functional unit of the nervous system. There are more than ten billion neurons in the human nervous system. Although nerve cells show the greatest variety of sizes and shapes of any group of cells in the body, they fall into three general categories:

- sensory neurons that convey impulses from receptors to the central nervous system;
- motor neurons that convey impulses from the central nervous system or from ganglia to effector cells;
- interneurons, also called central neurons, that form a communicating and integrating network between sensory and motor neurons. It is estimated that more than 99.9% of all neurons belong to this integrating network.

All neurons have a cell body and processes that are named axon and dendrites, respectively. The cell body of the neuron contains the nucleus and those organelles that maintain the nerve cell. The processes extending from the cell body constitute a structural characteristic common for all neurons. Most neurons have only one axon, usually the longest process extending from the cell. Some axons may be more than one meter long. A neuron usually has many dendrites. These processes are shorter and, usually, thicker than axons.

Neurons are classified on the basis of the number of processes extending from the cell body. Thus, multipolar neurons have one axon and two or more dendrites. Bipolar neurons have one axon and one dendrite. A special type of a bipolar neuron that is called the pseudounipolar neuron has one process that divides close to the cell body into two long processes: an axon and a dendrite. A unipolar neuron has only one process.

All motor neurons and interneurons are multipolar. In interneurons, which constitute most of the neurons in the nervous system, the physiologic direction of impulses is from dendrite to cell body and, then, to axon, or from cell body to axon.

Sensory neurons are pseudounipolar. The cell body of a sensory neuron is situated in a dorsal root ganglion close to the central nervous system. One process branch extends to periphery (it is a dendrite), and one extends to the central nervous system (it is an axon). These neurons are called pseudounipolar, because during development they exist as bipolar neurons that then become unipolar as they differentiate into their mature form.

Cell body

The cell body of a neuron has the characteristics of a protein-secreting cell. The cell body or perikaryon is part of the cell surrounding a large, euchromatic nucleus with a prominent nucleolus. Nerve cell perikarya contain inclusions named Nissl bodies. They stain intensely with basic dyes and metachromatically with thionine dyes. Nissl bodies are the rough endoplasmic reticulum. The perikaryon also contains numerous mitochondria, a large perinuclear Golgi apparatus, lysosome, microtubules, neurofilaments, vesicles, and inclusions. Nissl bodies, free ribosomes, and, occasionally, the Golgi complex extend into the dendrites but not into the axon. This helps to distinguish between axons or dendrites.

Neurons do not divide, they must last for a lifetime.

Dendrites and axons

Dendrites are neuronal processes that receive stimuli from other nerve cells or from the environment. Generally, dendrites are located near the cell body. They have a greater diameter than axons. They are unmyelinated, usually form extensive arborizations called dendritic trees. Dendritic trees significantly increase the receptor surface of neuron.

Axons are neuronal processes that transmit stimuli to other neurons or to effector cells. There is only one axon for each neuron, and it may be extremely long. Some axons may travel more than a meter to reach their effector targets. Some neurons of the central nervous system, in contrast, have a short axon. An axon may give rise to a recurrent branch near the cell body and to other collateral branches. The beginning of an axon from the cell body is known as the axon hillock.

The region of the axon between the apex of the axon hillock and the beginning of the myelin sheath is called the initial segment. The initial segment is the site at which an action potential is generated in the axon. The action potential is stimulated by impulses carried to the axon hillock in the membrane of the cell body after impulses have been received on the dendrites or the cell body itself.

Axons in the nervous system may be myelinated (with a myelin sheath) or may be unmyelinated (without this sheath).

Substances needed in the axon and dendrites are synthesized in the cell body and require transport to those sites. This process is called axonal transport.

The axonal transport is a bidirectional mechanism. The first type may be described as anterograde transport, which carries material from the perikaryon to the periphery. The second type is retrograde transport, which carries material from the axon terminal and the dendrites to the perikaryon.

Glia (supporting cells)

The supporting cells are designated glial cells. Only glial cells are seen routine histologic preparations of the nervous system. It is necessary to heavy metal staining or immunocytochemical method to demonstrate the entire glial cells.

There are two types of neuroglia: macroglia and microglia. Macroglial cells are divided into three types: oligodendrocytes, astrocytes, and ependymal cells (ependyma). Oligodendrocytes are the cells that provide protection for neuronal cell bodies and processes. Astrocytes are the cells that provide physical and metabolic support for the neurons. Ependymal cells form the epithelial lining of the brain ventricles and the spinal canal. Microglial cells are the phagocytic cells of the central nervous system.

Microglial cells

They are phagocytes and are normally present only in small numbers in the adult central nervous system. They proliferate and become actively phagocytic only in regions of injury and disease. They are considered to be part of the so-called mononuclear phagocytic system.

Oligodendrocytes (oligodendroglia)

There are two types of this kind of glia: cover the processes (axons and dendrites) (Schwann cells) and that cover the bodies of the neurons (satellite cells).

The processes of the neurons be myelinated or unmyelinated. The myelinated processes are surrounded by a lipid-rich layer called the myelin sheath. The myelin sheath is composed of multiple layers of the Schwann cell membrane wrapped concentrically around the process.

The unmyelinated processes are enveloped by Schwann cells and their basal lamina. The Schwann cells are elongated in parallel to the long axis of the processes, and the processes fit into grooves on the surface of the cell. The lips of the groove may form a mesaxon. A single process or a group of processes may be enclosed in a single invagination of the Schwann cell surface.

Satellite cells

The neuronal cell bodies of the peripheral nervous system are surrounded by a layer of small cells called satellite cells. Like Schwann cell, they help to establish and maintain a controlled microenvironment around the neuronal body in the ganglion.

Astrocytes (astroglia)

They are the largest of the neuroglial cells. There are two types of astrocytes: (1) protoplasmic astrocytes, which lie in the gray matter and (2) fibrous astrocytes, which lie more often in the white matter.

Astrocytes have processes that extend between blood vessels and neurons. The ends of the processes form end feets that may cover a large area of the outer surface of a blood vessel or the axolemma. Astrocytes are now thought to play a role in maintaining the microenvironment of the neurons and to form the blood–brain barrier.

Ependyma

Ependymal cells line the fluid-filled cavities of the central nervous system. They are cuboidal to columnar cells that have the morphologic and physiologic characteristics of fluid-transporting cells.

The modified ependymal cells and associated capillaries are called the chorioid plexus.

Lecture 11

Nervous Tissue – II (S.L. Kuznetsov)

Synapses

Neurons communicate with other neurons and with effector cells by means of synapses. Synapses are specialized junctions between neurons that facilitate transmission of impulses from one neuron to another. Synapses also occur between axons and effector cells, such as muscle and gland cells. Synapses between neurons may be classified as:

- (a) axodendritic, occurring between axons and dendrites;
- (b) axosomatic, occurring between axons and the cell body;
- (c) axoaxonic, occurring between axon and axon;
- (d) dendrodendritic, occurring between dendrite and dendrite.

Synapses may also be classified as chemical or electrical. In chemical synapses, neurons and their processes are closely apposed. Usually, only the 20- to 30-nm intercellular space separates them.

At a typical chemical synapse, there is a:

- presynaptic knob (presynaptic component), which is at the end of the neuron process from which neurotransmitter is released,
- synaptic cleft, i.e., the 20- to 30-nm space that the neurotransmitter must cross, and
- postsynaptic membrane (postsynaptic component), which has receptor sites on the plasma membrane the neurotransmitter interacts with.

Electrical synapses, which are common in lower vertebrates and invertebrates, are gap junctions that permit movement of ions between cells and, consequently, permit direct spread of current from one cell to another. Mammalian equivalents of electrical synapses include the nexus in smooth muscle and the gap junctions of cardiac muscle.

Synapses are not resolvable in routine light microscopy preparations. Silver precipitation staining method (Golgi method) not only demonstrates the overall shape of some neurons but also shows synapses as oval on the surface of the receptor neuron. Typically, an axon makes several of these button-like contacts with the receptor portion of neuron. Often, the incoming neuron travels along the surface of the neuron making several synaptic contacts called “button in passing.” The axon then continues to end finally as a terminal twig with an enlarged tip (“terminal button”) or the end bulb. The number of synapses on a neuron or its processes, which may vary from just a few to tens of thousands per neuron, appears to be directly related to the number of impulses that the neuron is receiving and processing.

Synaptic transmission

The presynaptic component or the end bulb of the axon is characterized by the presence of synaptic vesicles, membrane-limited structures that range from 30 to 100 nm in diameter and contain a neurotransmitter. There are also numerous small mitochondria and a layer of dense material, the presynaptic density, on the cytoplasmic side of the presynaptic (part of the plasma membrane) membrane.

The synaptic cleft separates the presynaptic component (the presynaptic membrane) from the postsynaptic component (postsynaptic membrane). This postsynaptic component, i.e., a portion of the plasma membrane of the second neuron, is characterized by the presence of a layer of dense material, the postsynaptic density, on the cytoplasmic side of the membrane.

The transmitter release is regulated by the calcium channels in the postsynaptic membrane. When a nerve impulse reaches the postsynaptic membrane, the voltage reversal across the membrane produced by the impulse, colloquially called depolarization, causes the voltage-gated calcium channels to open in the plasma membrane. The influx of calcium from the space causes the synaptic vesicles to migrate to, and fuse with, the presynaptic membrane, thereby releasing the transmitter into the synaptic cleft by exocytosis. The transmitter diffuses across the synaptic cleft. Receptors on postsynaptic membrane bind the neurotransmitter, causing the channels to open in that membrane, which allows ions to enter the neuron. This ion flux causes the voltage reversal (“depolarization”) in the postsynaptic membrane, thereby generating a second nerve impulse.

The neurotransmitter release by the presynaptic component can cause either excitation or inhibition at the postsynaptic membrane. In excitatory synapses, a neurotransmitter causes local reversal of the voltage of the postsynaptic membrane to a threshold level that leads to the initiation of nerve impulse. In inhibitory synapses, the neurotransmitter release hyperpolarizes the postsynaptic membrane, making the generation of the nerve impulse more difficult.

The ultimate generation of a nerve impulse in a postsynaptic neuron is dependent on the summation of excitatory and inhibitory impulses reaching that neuron. In this manner, the reaction of a postsynaptic neuron (or target organ, i.e., a muscle or a gland cell) may be very precisely regulated. The function of synapses is not simply to transmit impulses in an unchanged manner from one neuron to another. Rather, synapses allow for the processing of neural input. Typically, the impulse passing from the presynaptic to the postsynaptic neuron is modified at the synaptic station by other neurons that, although not in direct pathway, nevertheless have access to the synaptic station. These other neurons may influence the membrane of the presynaptic neuron or the postsynaptic neuron and facilitate or inhibit the transmission of impulses.

A number of molecules that serve as transmitters have been identified in various parts of the nervous system. The most common transmitters are acetylcholine (ACh) and norepinephrine (NE). ACh is a transmitter between axons and striated muscle at the neuromuscular junction. ACh and NE serve as transmitters between axons and effectors in the autonomic nervous system. Other commonly found transmitters are gamma-aminobutyric acid (GABA), dopamine, serotonin, glutamic acid, and glycine. Recently, several small peptides have also been shown to act as synaptic transmitters. Among these are substance P (it was originally found in powdered acetone extracts of the brain and intestine), hypothalamic releasing hormones, enkephalins, etc.

Special enzymes, acetylcholinesterase and catecholaminetransferase, associated with the postsynaptic membrane, rapidly degrade ACh and NE, respectively. The transmitters may also be reincorporated into vesicles in the presynaptic component by endocytosis. The degradation or recapture of neurotransmitters is necessary in order to limit the duration of stimulation or inhibition of the postsynaptic membrane.

Nerve endings

There are two types of nerve endings: efferent and afferent. The efferent nerve endings or motor endings are the contacts between the axon of a motor (efferent) neuron and target cells. There are special synapses: axomuscular, axovascular, and axoglandular synapses, in which the postsynaptic membrane is the target cell cytolemma.

Afferent (sensory) endings or receptors are specialised structures, located at the distal tips of peripheral processes of sensory neurons. Although receptors may have many different structures, they have one basic characteristic in common. They are able to initiate a nerve impulse in response to a stimulus. Numerous types of receptors may be classified as exteroceptors, enteroceptors, and proprioceptors.

Exteroceptors react to stimuli from the external environment (temperature, touch, smell, sound or vision, etc.). Enteroceptors react to stimuli from within the body (the degree of filling or stretch of the alimentary canal, bladder, and blood vessels). Proprioceptors also react to stimuli from within the body, providing sensation of the body position and muscle tone and movement.

The simplest receptor is a bare axon, called a nonencapsulated (free) ending. This ending is found in epithelia, connective tissue, and in close association with hair follicles.

But most sensory nerve endings acquire connective tissue capsules or sheaths of varying complexity. Sensory nerve endings with connective tissue sheaths are called encapsulated endings. Many of these encapsulated endings are mechanoreceptors in the skin and joint capsules (the end bulb of Crause, Ruffini's corpuscles, Meissner's corpuscles and Pacini's corpuscles). Neuromuscular spindles are encapsulated sensory endings in skeletal muscle. Functionally related to Golgi tendon organs are encapsulated tension receptors found at muscle-tendon junctions.

The origin of cells of the nervous system

All the elements of nervous tissue derive from the cells of the neural tube and the neural crest.

The central nervous system neurons derive from the cells of the neural tube. These cells are called neuroblast. After the developing nerve cells have migrated to their predestined location in the neural tube and have differentiated into mature neurons, they no longer divide. Astrocytes and oligodendrocytes also derive from the cells of the neural tube (glioblasts), but studies with tritiated thymidine indicate that these neuroglial cells may undergo a slow turnover. As noted above, microglia derive from the mononuclear cells of blood along with other macrophages of the body. There is still some question, however, as to whether they are able to derive after they have reached the CNS.

Peripheral nervous system cells derive from the neural crest. The PNS ganglion cells undergo several stages in their development. At the beginning there is a proliferation of ganglion precursor cells in the neural crest. Then the cells migrate from the neural crest to their future ganglionic site. Then a second wave of mitosis begins at the site followed by the development of processes that reach the target tissues and sensory territories.

During the second mitotic wave, more cells are produced than are needed. Those that do not make functional contact with target tissues undergo cell death.

Schwann cells also arise originally from the neural crest, but they undergo mitosis along the developing nerve. Most Schwann cells are formed by mitosis of parent Schwann cells in the peripheral nerve rather than by the migration of cells from the neural crest.

Lecture 12

Nervous System – I (S.L. Kuznetsov)

The nervous system consists of all the nervous tissue in the body. It can be divided into the central nervous system (CNS) and peripheral nervous system (PNS).

The CNS consists of the brain and the spinal cord, located in the cranial cavity and spinal canal, respectively. The PNS consists of cranial and spinal nerves (both motor and sensory), ganglia (collections of nerve cells outside the CNS), and motor nerve endings and sensory nerve endings (receptors).

The nervous system allows for rapid response external stimuli. The nervous system evolved from the simple neuroeffector system of lower animals. In primitive nervous systems, only simple receptor-

effector reflex loops exist in response to external stimuli. In higher animals, the nervous system retains capability of responding to stimuli from external environment through the action of effector cells (such as skeletal muscle), but the neuronal responses are more varied. They range from simple reflexes that require only the spinal cord to complex operations of the brain that bring to bear the memory of past experiences.

In higher animals, the nervous system also regulates the function of internal organs. This part of the nervous system is the autonomic nervous system.

Peripheral nervous system (PNS)

The nerves of the PNS are made up of many nerve fibers that carry sensory and motor (effector) information between the organs and tissues of the body and the brain and spinal cord.

The cell bodies of peripheral nerves may be located in the CNS or in peripheral or paravertebral ganglia. The ganglia contain clusters of neuronal cell bodies and nerve fibers leading to and from them.

Organization of the peripheral nerve

The bulk of a peripheral nerve consists of nerve fibers and their supporting Schwann cells. The individual nerve fibers and their associated Schwann cells are held together by the connective tissue that is organized into three distinctive components: endoneurium, perineurium, and epineurium.

The endoneurium constitutes the connective tissue associated with individual nerve fibers, forming the nerve fascicles.

The perineurium is a specialized connective tissue surrounding nerve fascicles. It serves as a semipermeable barrier. It may be one or more cell layers. The cells of this layer are squamous in shape. Each layer exhibits an external (basal) lamina on both surfaces. The cells are contractile and contain actin microfilaments, collagen fibrils are present between the cell layers, but fibroblasts are typically absent.

The epineurium consists of dense connective tissue that surrounds and binds together nerve fascicles into a common bundle. It forms the peripheral nerve capsule. Adipose tissue is often associated with the epineurium in the larger nerves.

The nerves have their blood vessels in the epineurium and the perineurium. The endoneurium depends to a large extent on diffusion from and to the blood vessels through the perineurium.

Peripheral nervous ganglia

The ganglia contain clusters of neuronal bodies and nerve fibers. The cell bodies in the ganglia may belong to sensory neurons (somatic and visceral afferents) or they may belong to postsynaptic “motor” neurons (visceral efferents) of the ANS.

The peripheral nervous ganglia are made up of the large neuronal cell bodies, numerous nerve fibers, and the connective tissue that surrounds neurons and processes, playing the role of the ganglion stroma. The satellite cells surround the neuronal cell bodies.

There are two types of nervous ganglion structure: (1) the so-called separated nervous ganglia (spinal, sensory nervous ganglia, paravertebral nervous ganglia, ganglia of the nervous plexus). They are surrounded by a dense connective tissue capsule that is comparable to and continuous with the epineurium of the nerve and (2) the so-called intramural neuronal ganglia, which are situated within the organs.

Sensory or spinal ganglia have a special structure. The neuronal cell bodies are located on the periphery of the organ, the central region contains numerous nerve fibers. These ganglia contain a unique type of neurons – pseudounipolar sensitive neurons.

The cell bodies of the main motor neurons that innervate skeletal muscles (somatic nervous system) are located in the spinal cord. The axons leave the CNS and travel in peripheral nerves to the skeletal muscles that they innervate.

Autonomic nervous system (ANS)

Functionally, the nervous system is known to be divided into two parts: the somatic nervous system and the autonomic nervous system.

The somatic nervous system innervates skeletal muscles. The neurons of the somatic reflex arc are situated in the spinal ganglion (the sensory part), in the central nervous system (including the brain cortex as the central part), and in the anterior horns of the spinal cord (the motor part).

The autonomic nervous system innervates the effectors in the internal organs and regulates their function. The ANS is classified into two divisions: sympathetic and parasympathetic division.

The sensory neurons of the autonomic reflex arc have the same arrangement as other sensory neurons (of the somatic arc), their cell bodies are in sensory (spinal) ganglia, and they possess long peripheral and central axons. The main organizational difference between the somatic reflex arc and the visceral reflex arc is that the motor neurons of the latter are situated outside the CNS in peripheral and intramural ganglia.

The central sympathetic neurons are located in the thoracic and upper lumbar portions of the spinal cord. They send axons to the paravertebral ganglia of the so-called paravertebral sympathetic chain that contains the cell bodies of the effector neurons of the sympathetic division.

The central neurons of the parasympathetic division are located in the brain stem and sacral spinal cord. They send axons to visceral ganglia. These ganglia are situated in (intramural ganglia) or near (plexus) the wall of organs and contain the cell bodies of the postsynaptic effector neurons of the parasympathetic division. The intramural ganglia are usually located in the lamina propria, muscularis mucosae, submucosa, muscularis externa, and subserosa of the alimentary canal from the esophagus to the anus.

Central nervous system **Spinal cord**

The spinal cord is a cylindrical structure that is directly continuous with the brain. It is divided into 31 segments (8 cervical, 12 thoracic, 5 lumbar, 5 sacral, and 1 coccygeal). Each segment is connected to a pair of spinal nerves. Each spinal nerve is joined to its segment of the cord by a number of roots or rootlets grouped as posterior (dorsal) or anterior (ventral) roots.

In cross section, the spinal cord exhibits a butterfly-shaped gray inner substance. This gray matter is surrounded by a white peripheral substance, the white matter. The white matter contains only myelinated and unmyelinated axons travelling to and from other parts of the spinal cord and to and from the brain. Functionally related bundles of axons in the white matter are called tracts.

The gray matter contains neuronal cell bodies and their dendrites, along with axons and neuroglia. It is divided into the anterior, intermediate, and posterior horns.

In the anterior horns, ventral motor neurons are situated, they are also called anterior horn cells. They are the motor neurons of the somatic reflex arc. Their axons leave the spinal cord through the anterior root, become a component of the spinal nerve of that segment and innervate the muscles. The axons are myelinated, and near the muscle cells they divide into numerous terminal branches that form a neuromuscular synapsis with the muscle.

In intermediate horns, the central neurons of the ANS are situated. Their axons leave the spinal cord as the components of ventral spinal roots and connect with the motor neurons in peripheral paravertebral ganglia.

The posterior horns are the place through which the axons of sensitive neurons come into the spinal cord.

Functionally related groups of nerve cell bodies in the gray matter are called nuclei. In context, the term nucleus means a cluster or group of neuronal cell bodies plus fibers and neuroglia. The nuclei of the CNS are the morphologic and functional equivalents of the ganglia of the PNS. Synapses occur only in the gray matter.

Lecture 13

Nervous System – II (S.L. Kuznetsov)

The brain

The spinal cord, as you now, has the gray matter, surrounded by the white matter. The brain (cerebrum and cerebellum) contains gray matter and white matter but in a different arrangement. In the brain, the gray matter forms an outer covering or cortex; the white matter forms an inner core or medulla.

The cortex and islands of the cerebrum and cerebellum contain nerve cell bodies, axons, dendrites, and glial cells and is the site of synapses.

The white matter contains only the axons of nerve cells plus the associated glial cells and blood vessels. These axons travel from one part of the nervous system to another. Whereas many of the axons going to or coming from a specific location are grouped into bundles called tracts.

The kinds of cell bodies found in the gray matter vary according to which part of the brain or spinal cord is being examined.

Cerebral cortex

The cerebral hemispheres consist of a convoluted cortex of gray matter overlying the central medullary mass of white matter, which conveys fibers between different parts of the cortex and to and from other parts of the CNS.

Histologically, the neurons of the cerebral cortex are divided into five different morphological types arranged in several layers.

Neuron types and layers of the cortex (neocortex)

The neurons in the neocortex are arranged into six layers, the layers differing in neuron morphology, size and population density.

There are six typical layers in the cerebral cortex. They are:

- the molecular layer. This most superficial layer mainly contains dendrites and axons of cortical neurons making synapses with one another.
- the outer granular layer. A dense population of small pyramidal cells and stellate cells make up this thin layer, which also contains various axons and dendritic connections from deeper layers.
- the pyramidal layer. Pyramidal cells of medium size lie in this broad layer.
- the inner granular layer. This layer consists mainly of densely packed stellate cells.
- the ganglionic layer. Large pyramidal cells and smaller numbers of stellate cells make up this layer, the name of the layer originating from the huge pyramidal (ganglion) Betz cells of the motor cortex.
- the multiform layer. This is so named for the wide variety of differing morphological forms found in this layer. It contains numerous small pyramidal cells, as well as stellate cells, especially superficially, and fusiform cells in the deeper part.

The synaptic interconnections within the cortex are exceedingly complex, with any one neuron synapsing with several hundred others. However, there are several basic principles of cortical organization and function:

- functional units are disposed vertically, corresponding to the general orientation of axons and major dendrites.
- afferent fibers (their cell bodies lying elsewhere in the CNS) generally synapse high in the cortex with the dendrites of efferent neurons, the cell bodies of which lie in deeper layers of the cortex.
- efferent pathways, typically the axons of pyramidal cells, tend to give off branches, which pass back into more superficial layers to communicate with their own dendrites via interneuronal connections involving other cortical cell types.

Cerebellum

The cerebellum, which coordinates muscular activity and maintains posture and equilibrium, consists of the gray matter (cortex) and the white matter containing four pairs of nuclei in the central position. Afferent and efferent fibers pass to and from the brain stem via inferior, middle and superior cerebellar peduncles.

The cerebellar cortex has **three** layers.

- The molecular layer contains relatively few neurons and large numbers of unmyelinated fibers.
- The ganglionic layer is extremely cellular. It has a single layer of huge neurons called Purkinje's cells. Purkinje's cells have very large cell bodies, a relatively fine axon extending down through the granular cell layer, and an extensively branching dendritic system, which arborizes into the outer molecular layer.
- The granular cell layer contains numerous small neurons (the so-called granular cells), the unmyelinated axons, which pass outwards to the molecular layer where they bifurcate to run parallel to the surface to synapse with the dendrites of Purkinje's cells and Golgi cells scattered in the superficial part of the granular cell layer.

Afferent fibers enter the cerebellum from the brain stem and then pass via the white matter core to make complex connections with granular cells, Purkinje's dendrites and other neurons of the cerebellar cortex; these cortical cells also make numerous interconnections with each other within the molecular layer. The only efferent fibers from the cerebellar cortex are the Purkinje cell axons, which pass down through the granular cell layer into the white matter where they synapse in the central nuclei of the cerebellum.

Connective tissue of the central nervous system

Three sequential connective tissue membranes, the meninges, cover the brain and spinal cord.

The dura mater is the outermost layer. The arachnoid layer lies beneath the dura. The pia mater is a delicate layer resting directly on the surface of the brain and spinal cord.

In the cranial cavity, the thick layer of connective tissue that forms the dura mater is continuous at its outer surface with the periosteum of the skull. Within the dura mater, there are spaces lined by endothelium (and backed by periosteum and dura mater, respectively) that serve as the principal channels for the blood returning from the brain. These venous sinuses receive blood from the principal cerebral veins and carry it to the internal jugular veins. In the spinal canal, the vertebrae have their own periosteum, and the dura mater forms a separate tube surrounding the spinal cord.

The arachnoid makes delicate trabeculae between the dura and pia mater on the surface of the brain and spinal cord. The space bridged by these trabeculae is the subarachnoid space; it contains cerebrospinal fluid.

The pia mater is also a delicate connective tissue layer. It lies directly on the surface of the brain and spinal cord and is continuous with the perivascular connective tissue sheath of the blood vessels of the brain and spinal cord.

Blood–brain barrier

The blood–brain barrier restricts the passage of substances from the circulation to the CNS parenchyma. It is formed by the astrocytes' processes, covering all blood vessels inside the brain tissue (it is the main part of the blood–brain barrier) and by the complex of tight junctions existing between the endothelial cells of the blood vessels of the brain. These junctions prevent the passage of solutes and fluid from the lumen to the extravascular space via the intercellular space of endothelium.

The perineurium forms the blood–neural barrier regulating the microenvironment within the fascicles of nerve fibers in peripheral nerves.

Some parts of the CNS, however, are not isolated from substances carried in the blood. These may be areas of the brain in which sampling of materials circulating in the blood is necessary to regulate neurosecretory control of parts of the nervous system and of the endocrine system.

The surface of the spinal cord and the brain is covered by a membrane formed by the processes of astrocytes and the basement membrane that separate them from the pia mater. It is called the external glial membrane.

Choroid plexus

The choroid plexus is a vascular structure in the four ventricles of the brain and is responsible for the production of cerebrospinal fluid. It drains from the interconnected ventricular cavities via three channels connecting the fourth ventricle with the subarachnoid space that surrounds the CNS. CSF is produced at a constant rate and is reabsorbed from the subarachnoid space into the superior sagittal venous sinus via finger-like projections called arachnoid villi.

Lecture 14

Primary Sentient Sense Organs: The Eye and the Organ of Smell (T.V. Boronikhina)

The sense organs are divided into two types: primary and secondary sentient sense organs, depending on the nature of their receptor cells. The primary sentient sense organs include the eye and the organ of smell, the olfactory epithelium; their receptor cells are neurons. The secondary sentient sense organs include the ear and the organ of taste, the taste buds; their receptors are epithelial cells called neuroepithelial cells.

The sense organ is the peripheral part of the analyzer; its functions are interaction between receptors and stimuli and generation of nervous impulses. The middle part of the analyzer is the sensory nerve that transmits these impulses to the brain to be processed. The central part of the analyzer is the area of the cerebral cortex that is responsible for association and analysis of information. Damage to any part of the analyzer may result in the loss of sense.

Eye

The eye is the visual organ located in the skull bony orbit. The eye converts light to nervous impulses and transmits these impulses to the brain for processing. The eyeball is composed of three tunics: sclera, vascular layer, and retina.

Sclera

The sclera is the outer tunic of the eye, consists of relatively avascular dense regular connective tissue. The sclera covers the posterior five-sixths of the eye, maintains the shape of the eyeball, and serves as an attachment site for extrinsic oculomotor muscles. The oculomotor muscles permit the eye to rotate freely and to change the visual fields. The anterior aspect of the sclera is transparent and is known as the cornea, whose junction with the sclera is marked by the limbus.

Cornea

The cornea is the highly modified anterior portion of the outer capsule of the eye. It is slightly thicker than the sclera and has a smaller radius of the curvature. The cornea's high refractive index and small radius of the curvature make it extremely important in image formation. The cornea is composed of five layers: epithelium, Bowman's membrane, stroma, Descemet's membrane, and endothelium.

The corneal epithelium is classified as stratified squamous nonkeratinized epithelium. It has a remarkable capacity for healing and regeneration. Minor wounds are closed by cell migration; larger wounds are healed by mitosis in the basal layers and the new cell production. The superficial layer of the corneal epithelium is bathed by tears, keeping the cornea moist and protecting it from dehydration. The tears also contain lysozyme, an antibacterial agent. The corneal epithelium is highly innervated; it contains several free nerve endings that, when stimulated, cause the blinking reflex: the eyelids close, protecting the cornea, and plentiful tears begin to flow. Bowman's membrane (the anterior border membrane) rests under the corneal epithelium. It is a homogenous noncellular layer composed of interlacing collagen fibers and extracellular substances. Bowman's membrane provides form, stability, and strength to the cornea. The corneal stroma is the thickest corneal layer, comprising about 90% of the corneal thickness. The stroma is formed by fibroblasts, many layers of collagen bundles, and an amorphous ground substance rich in chondroitin sulfates and keratan sulfate. The stroma lacks blood vessels. Descemet's membrane is an extremely thick basement lamina separating the stroma from the endothelium lining the cornea. This membrane probably is the basement membrane of, and is secreted by, the corneal endothelium. The endothelium lines the posterior aspect of the cornea and is composed of simple squamous cells exhibiting numerous pinocytotic vesicles. The endothelium continually resorbs fluid from the stroma, thus contributing the transparency of the cornea.

The cornea is avascular. The centre of the cornea receives nutrition by diffusion from the aqueous humor; the periphery receives nutrition from the blood vessels in the limbus. Corneal homografts are used with considerable success, because the cornea does not contain any blood vessels or typical lymphatics.

Corneal transparency is due to the regular arrangement of its fibrous elements, the unique composition of glycosaminoglycans, and the lack of blood vessels.

The cornea and the sclera join at the limbus. The anatomy of this region is complex, and the area is quite significant clinically. The structures regulating the outflow of aqueous humor from the eye are located here. They are the trabecular meshwork and the canal of Schlemm. These two structures drain fluid from the anterior chamber of the eye into the venous system. Obstructions that prevent drainage of aqueous humor from the eye may cause an increase in the intraocular pressure, which is a characteristic feature of a severe common disease called glaucoma.

Choroid

The vascular layer of the eye (the uvea) is the middle layer of the eye whose three parts are the choroid, the ciliary body, and the iris.

The choroid is a thin layer just beneath the sclera. It consists of loose connective tissue, contains many blood vessels and numerous melanocytes. The melanocytes absorb light and impart to the choroid black colour in histologic sections. The choroid is composed of three layers: the outer layer of arterioles and venules, the middle capillary layer, and the inner layer called Bruch's membrane. Bruch's membrane is a thin structure; it is composed of a central core of elastic fibers that are bordered on the one side by the endothelium basal lamina and on the other side by the basal lamina of the retinal pigment epithelium.

Ciliary body

The ciliary body is the region of the vascular tunic located between the visual retina and the iris. The ciliary body is wedge-shaped and completely encircles the lens. Numerous long radially arranged ciliary processes project from the thick ciliary body toward the lens. Suspensory ligaments arise from the ciliary processes and insert into the lens capsule, serving to anchor it in place. The ciliary body is composed of loose connective tissue, melanocytes, and blood vessels. The main mass of the ciliary body, except the ciliary processes, consists of muscles of accommodation called the ciliary muscles.

The inner surface of the ciliary body is lined with pigmented layer of the retina. This layer lacks photoreceptors and extends anteriorly as the ciliary epithelium. The ciliary epithelium contains two cell layers: the outer layer rich in melanin and the inner unpigmented layer. The unpigmented cells lining the ciliary processes transport the blood plasma components to the posterior chamber, forming the aqueous humor. The aqueous humor nourishes the lens and the other inner structures of the eye and then flows over the lens, through the pupil, through the trabecular meshwork into the anterior chamber, and then through the canal of Schlemm into the eye venous system.

The accommodation is the focus on a close object; it is a function of the ciliary muscles. Contraction of the ciliary muscles reduces tension on the suspensory ligaments attached to the lens, and the lens becomes more convex. This allows the lens to focus images of nearby objects on the retina. Abnormalities in contraction of ciliary muscles may cause either myopia or hypermetropia. Accommodation is gradually lost with advancing age due to the loss of the lens elasticity, which results in presbyopia.

Iris

The iris is the most anterior extension of the choroid, separating the anterior and posterior chambers one from another. The posterior surface of the iris rests on the lens forming an adjustable opening, the pupil. The main mass of the iris consists of a loose, highly pigmented connective tissue containing many blood vessels. The anterior surface of the iris is covered with a simple layer of pigment cells; its deep surface is covered with a double-layer pigment epithelium. The melanocytes in the stroma and pigment cells of the epithelium prevent light from entering the interior of the eye, except via the pupil. The iris has colour. The hue of colour depends on the amount of melanocytes and the quantity of melanin in them. If only a few melanocytes are present, the eyes are blue; increasing amounts of pigment impart darker colours to the eyes.

The pupil (the iris aperture) varies in size with the amount of light in the environment. The pupillary muscles are probably the myoepithelium; they derive from the anterior pigmented layer of the iris, lose pigment, and differentiate into contractile cells. The muscle dilating the pupil is arranged radially around the pupil; when it contracts, due to stimulation by sympathetic nerve fibers, the pupil dilates. The muscle constricting the pupil is arranged in concentric rings around the pupillary orifice, and when it contracts, due to stimulation by parasympathetic nerve fibers, the pupil constricts. Thus, the pupillary muscles regulate the amount of light entering into the eye.

Lens

The lens is a biconvex transparent flexible structure located directly behind the pupil. The lens is held in place by the suspensory ligaments that arise from the ciliary body and insert upon the lens equator. The suspensory ligaments keep tension on the lens, enabling it to focus on distant objects. A degree of the lens convexity depends on the contraction or relaxation of ciliary muscles.

The lens consists of three parts: the lens capsule, the subcapsular epithelium, and the lens fibers. The lens capsule is a basement membrane, produced by the underlying anterior epithelial cells and lens fibers. The subcapsular epithelium is located only on the anterior surface of the lens. It is composed of a single cuboidal cell layer. The lens fibers are highly modified elongated cells that differentiate from the subcapsular epithelium. The mature lens fibers lack both nuclei and organelles, but are filled with proteins called crystallins. New lens fibers are added at the equator, but this function diminishes with increasing age. Cataract is opacity of the lens. Pigments or other substances can accumulate in the lens fibers, and vision is impaired.

Vitreous body

The vitreous body is the refractile gel filling the cavity between the lens and the retina. It is composed mostly of water, collagen, and hyaluronic acid. The vitreous body also contains few hyalocytes that secrete the collagen and hyaluronic acid. The collagen fibers in the vitreous body lack the usual collagen periodicity. The remnant of the embryonic hyaloid artery forms the hyaloid canal through the middle of the vitreous body.

Retina

The retina is the innermost layer of the three tunics of the eye that is responsible for photoreception. The retina has two main components: the pigmented retina (outer layer) next to the choroid and the neural retina (inner layer) next to the vitreous body. Detachment of the retina occurs when the neural and pigmented retinae become separated from each other. Since the nervous portion of the retina depends on nutrients from the choroid diffusing through the pigmented epithelium of the retina, a detached nervous portion undergoes degenerative changes unless it is successfully restored to its normal position.

The pigmented retina or pigment epithelium consists of a layer of columnar cells firmly attached to Bruch's membrane. The junctional complexes (desmosomes, gap junctions, tight junctions) attach the lateral borders of these cells together. This tightly joined layer of cells probably is a barrier between the blood and the neural retina. The cells of the pigment epithelium exhibit basal invaginations that contain basally located mitochondria, suggesting their involvement in ion transport. The microvilli and cylindrical sheaths extend from the apices of the pigment epithelial cells and invest the tips of the rods and cones. The cells of pigment epithelium phagocytose the shed tips of the outer segment of rods and cones. The melanin granules are found both apically and in cell processes. The melanin synthesized by the pigment cells absorbs light after the rods and cones have been stimulated. The pigment epithelium functions in esterification and the transport of vitamin A, which is necessary for visual pigment formation by the rods and cones.

The neural retina consists of neurons, glial cells (Müller cells), and blood vessels. The latter enter the retina via the optic disk and supply its inner portion; the outer portion is supplied by diffusion from the choroid. The retinal neurons are at least of five types: the photoreceptor cells, bipolar cells, ganglion

cells, horizontal cells, and amacrine cells. The photoreceptors, bipolar cells, and ganglion cells synapse with each other in a strict sequence and constitute the retinal neural chain that is the initial link of the optic tract. The horizontal and amacrine cells form horizontal bonds within the retinal layers and connect neurons with each other in a lateral fashion.

The neural retina includes two types of photoreceptor neurons called rods and cones. The rods and cones have a nuclear region, dendrites from two parts – the outer and inner segments, and a short axon forming a synaptic region. Their specialized dendrites, either rod- or cone-shaped, interdigitate with the cells of the pigment epithelium. Their axons form a synaptic contact with bipolar and horizontal cells.

Their dendrite outer segments are photoreceptors. They contain multiple layers of stacked plasma membranes and are rich in the photoreceptive pigments – rhodopsin in rods and iodopsin in cones. The outer membrane structures are eventually shed and subsequently phagocytosed by the pigment epithelium. The inner segments of each rod and cone contain a concentration of mitochondria and other organelles. The inner segment is a metabolic centre of a photoreceptor cell. It produces proteins that migrate to the outer segment, where they become incorporated into the membranes. The outer and inner segments are separated by a constriction that contains an incomplete cilium (without the two central microtubules) that terminates in a basal body within the inner segment.

The number of rods is about 120 million in each human retina. The rods are long, slender cells containing hundreds of stacks of flat close membranous disks in their outer segment. The disks are not continuous with the plasma membrane of the rod cells. The rods contain rhodopsin in their disks and are the receptors sensitive to light of low intensity (twilight or night vision); they are responsible for black-white vision. Some rods may form synapses with one bipolar cell and give rise to summation.

The number of cones is about 6 million in each human retina. They are photoreceptor cells similar to rods, except for a cone-shaped outer segment. Their outer segments possess invaginations of the plasma membrane (not disks) filled with the photosensitive pigment iodopsin. Their inner segments contain a large lipid drop surrounded by numerous mitochondria known as ellipsoid. The cones are sensitive to bright light and responsible for colour vision (day vision). The cone synapses individually with the bipolar cell. Iodopsin is located in different amounts in various types of cones, making the cone most sensitive either to the red, green, or blue region of the visual spectrum, thus accounting for the three types of cones. Congenital absence of certain types of cones results in daltonism, i.e., colour blindness.

The outer segments of rods and cones face the back of the eye so that light passes through the inner layers of the retina before reaching the photosensitive region of these cells; it is the so-called inverted type of the retina.

The photosensitive pigments rhodopsin and iodopsin are composed of opsins, integral transmembrane proteins, and retinal, an aldehyde form of vitamin A. Light interacts with photopigments in the disks of the rods or invaginations of the cones, and retinal becomes dissociated from opsins, which permits the diffusion of bound calcium from the membrane into the cytoplasm of the outer segment. The excess of calcium ions acts to hyperpolarize the cell by inhibiting the entrance of sodium ions into the cell (closing sodium channels). Ionic alterations generate the electrical activity in the entire cell. Reassembly of retinal and opsins is an active process occurring in the dark. It is accompanied by the recapture of calcium ions by the membranous disks or invaginations, with subsequent reopening of sodium channels, and a reestablishment of the normal resting membrane potential.

The layers of the retina are complex and are 10 in number. They are (from outside inward):

- (1) the pigment epithelium; its basement membrane is a part of Bruch's membrane, as described above;
- (2) the layer of rods and cones consists of the outer segments of photoreceptor cells and processes of the pigment epithelial cells that invest the tips of the rods and cones;
- (3) the external limiting membrane is a region characterized by junctional specializations between Müller (glial) cells and the photoreceptors;
- (4) the outer nuclear layer where the nuclear regions of the rods and cones are located;
- (5) the outer plexiform layer where synapses occur between the axons of the photoreceptor cells and bipolar and horizontal cells; the synapses between the photoreceptor and the bipolar cells are the first synapses of the optic tract, the horizontal cells synapse with numerous rods and cones in a lateral fashion;
- (6) the inner nuclear layer contains the cell bodies of bipolar cells, horizontal cells, amacrine cells, and Müller cells;
- (7) the inner plexiform layer where synapses occur between the axons of bipolar cells and the dendrites of ganglion cells (the second synapses of the optic tract); the amacrine cell processes connect the bipolar cells with ganglion cells in a lateral fashion;
- (8) the ganglion cell layer contains the ganglion cell bodies – the final neurons in the retinal neural chain;

- (9) the optic nerve fibre layer consists of the unmyelinated axons of ganglion cells, which form the fibers of the optic nerve; at the optic disk, each fibre acquires a myelin sheath;
- (10) the inner limiting membrane represents termination of the Müller cell processes and their associated basement membranes.

The optic disk is the area of the retina where the optic nerve pierces the sclera and leaves the eye. Neither the rods nor cones are present in the region of the optic disk; therefore, this retinal area lacks visual activity. The fovea centralis is the region of the retina that is responsible for the greatest visual activity. It is a depression in the posterior wall of the retina containing only cones.

There are three functional apparatus in the eye. The refractive apparatus of the eye includes the cornea, the aqueous humor in the anterior and posterior chambers of the eye, the lens, and the vitreous body. All these structures are transparent; they pass the light through themselves and refract it. The accommodative apparatus of the eye includes the iris and the ciliary body, possessing intrinsic muscles. These muscles adjust the aperture of the iris, regulating the amount of light entering into the eye, and alter the lens convexity permitting accommodation for close vision. The receptive apparatus of the eye includes only the neural retina that contains photoreceptor neurons, namely, the rods and cones. These specialized cells encode the various patterns of the image for transmission to the brain via the optic nerve.

Embryonic development of the eye

The eye develops initially as the optic vesicle from the forebrain (prosencephalon) – the anterior part of the anterior cerebral vesicle of the embryo. The optic vesicle subsequently invaginates to form a double-layer optic cup. The outer layer of the cup develops into the pigmented layer of the retina, whereas the inner wall of the cup becomes the neural retina; the attachment stalk of the optic vesicle develops into the optic nerve. At the same time the thickened ectoderm in front of the optic cup bulges inward to form the lens vesicle. The lens vesicle is then separated from the ectoderm from which it arose. The formation of the lens provides an example of embryonic induction.

The embryonic mesenchyme surrounding the developing eye gives rise to both the external and the middle layers of the eye, exclusive of the corneal epithelium that is derived from the ectoderm. The actively growing cells of the developing eye require a special blood supply and this is provided, as the eye forms, by the hyaloid artery.

Olfactory epithelium

The olfactory epithelium is located on the roof of the nasal cavity, on either side of the nasal septum, and onto the superior nasal conchae. The olfactory mucosa has a pseudostratified ciliated columnar epithelium, which makes the mucosa quite tall. This epithelium is modified for olfaction. The olfactory epithelium contains three cell types: olfactory, supporting, and basal cells.

The olfactory cells are bipolar neurons. Their modified dendrites are characterized by a bulbous projection (olfactory knob, olfactory vesicle), from which several cilia extend. The olfactory cilia are nonmotile and very long; they contain chemoreceptors, which recognize the structural differences of odoriferous substances. Serous glands in the mucosa moisten these cilia to dissolve the chemicals of inspired air. The interaction between receptors and stimulant molecules causes depolarization of the olfactory cell membrane, with subsequent generation of an action potential. Compared to other animals, the human olfactory cells have relatively short cilia, which results in a rather poorly developed sense of smell. For example, cats, which have a keen sense of smell, have cilia that are up to 80 μm long.

Numerous unmyelinated axons of the olfactory cells form bundles called fila olfactoria, which pass through the cribriform plate of the ethmoid bone to the brain and synapse with neurons in the olfactory bulb.

The supporting cells have apical microvilli and a well-developed apical Golgi complex and look like secretory cells. Supporting cells provide mechanical and metabolic support to the olfactory cells. They function in a manner comparable with glial cells.

The basal cells rest on the basal lamina but do not extend to the surface, forming an incomplete layer. Basal cells are undifferentiated and are believed to be regenerative both for olfactory and supporting cells. Olfactory cells have a normal life span of about a month. If injured, they are quickly replaced. Olfactory cells appear to be the only neurons that are replaced during postnatal life.

The lamina propria of the olfactory mucosa contains many veins, unmyelinated nerves, and Bowman's glands. Bowman's glands produce a watery serous secretion that is released onto the olfactory epithelium surface via narrow ducts. The olfactory stimuli dissolve in this material and are carried away by the secretion to prepare the receptors for new stimuli.

Lecture 15

Secondary Sentient Sense Organs: The Ear and the Organ of Taste (T.V. Boronikhina)

Ear

The ear is the vestibulocochlear apparatus; it functions in hearing and equilibrium. The ear contains complex mechanoreceptors; the motion of these mechanoreceptors is converted to electrical impulses, which are transmitted to the brain. The brain interprets the impulses as sounds, a sense of the body's position in space, or of the head movement. The ear has three regions: the external ear, the middle ear, and the inner ear.

External ear

The external ear is composed of the auricle, the external auditory meatus, and the tympanic membrane. The auricle contains irregular plates of elastic cartilage covered with thin skin. The wall of the external auditory canal is composed of elastic cartilage in the outer third and bone in the inner two-thirds. The skin that lines the meatus is similar to the skin of the auricle, but also contains a highly modified type of apocrine sweat glands called ceruminous glands, which produce earwax (cerumen). The combined secretion of the sebaceous and the ceruminous glands may accumulate, forming ceruminous plugs and keeping out sound waves.

The tympanic membrane separates the external auditory meatus and the tympanic cavity. Its external surface is covered with a stratified squamous keratinized epithelium; its internal surface is lined with a simple cuboidal epithelium. The tympanic membrane possesses fibroelastic connective tissue interposed between these two epithelial coverings.

Middle ear

The middle ear contains the tympanic cavity, the auditory ossicles, and the auditory tube (eustachian tube). The tympanic cavity is a small irregular space lying within the temporal bone. The medial wall of the tympanic cavity possesses the oval window and the round window separating the middle ear and the inner ear from each other. The cavity is lined with a simple squamous epithelium and is air-filled, because it communicates with the nasopharynx via the auditory tube. Any infection may reach the tympanic cavity from the upper respiratory tract. Middle ear infections (tympanitis) are sometimes complications of head colds, particularly, in children.

The auditory tube is lined with a pseudostratified ciliated columnar epithelium with some goblet cells. Its lamina propria has mucous glands and, in the medial portion, may be extensively infiltrated with lymphocytes, which may form discrete nodules called the tubal tonsils.

The auditory ossicles include the malleus, incus, and stapes. The ossicles are arranged in series: the malleus attached to the tympanic membrane articulates with the incus, which, in turn, articulates with the stapes, which is attached to the oval window. The ossicles transmit movements set up in the tympanic membrane by sound waves to the oval window. The latter transmits the vibrations to the perilymph of the inner ear; thus, the amplitude of vibrations is decreased, but the force is increased, because the ossicles are arranged to exert leverage.

Internal ear

The internal (inner) ear occupies a complex cavity in the petrous portion of the temporal bone called the osseous (bony) labyrinth, which is divided into three parts: the cochlea, vestibule, and semicircular canals. The cochlea contains the organ of hearing known as the spiral organ of Corti. The vestibule and semicircular canals contain the organ for detecting motion and maintaining equilibrium.

The cochlea is a spiral-shaped cavity with an axis formed by the pillar of bone called the modiolus. The vestibule includes the saccule and utricle; the semicircular canals are three in number and are oriented perpendicular to each other. Each semicircular canal possesses a dilated region named the ampulla.

All parts of the bony labyrinth are filled with perilymph. The bony labyrinth houses the membranous labyrinth; it is contained within the bony labyrinth and is lined with a simple squamous epithelium. This closed system of membranous tubes and sacs is filled with a fluid termed endolymph, and, at appropriate sites, sensory receptors are arranged inside these membranous structures. The endolymphatic fluid and cellular debris are removed from the endolymph through the endolymphatic duct to the subdural endolymphatic sac.

Organ of hearing

The cochlea is a bony tube that spirals 2.5 times around the modiolus, an osseous spiral core. The cochlea has a broad base and tapers up like a cone. The cochlea houses the cochlear duct that contains the spiral organ of Corti, which responds to various sound frequencies.

The cochlea has three compartments: the upper passage is called the scala vestibuli; the lower passage, the scala tympani; the intermediate passage, the cochlear duct (scala media). The cochlear duct contains endolymph. The scala vestibuli and scala tympani are perilymphatic spaces. The former ends at the oval window and the latter ends at the round window. The scala vestibuli and the scala tympani communicate with each other at the helicotrema – a small opening located at the apex of the cochlea.

The cochlea is divided into three chambers by the osseous spiral lamina, the vestibular membrane, and the basilar membrane. The osseous spiral lamina is a lateral projection of the modiolus. The periosteum of the osseous spiral lamina is modified to form the spiral limbus. The vestibular membrane extends between the spiral limbus and the wall of the cochlea; it is bordered by the scala vestibuli (above) and the cochlear duct (below). The vestibular membrane is composed of two layers of flattened squamous epithelial cells separated from each other by the intervening basal lamina. One cellular layer faces and lines the scala vestibuli; the other layer faces and lines the roof of the cochlear duct.

The basilar membrane is a thick membrane that extends between the osseous spiral lamina and the spiral ligament. The latter is the thickened periosteum of the cochlea on the outer wall of the cochlear duct. The basilar membrane is bordered by the cochlear duct (above) and the scala tympani (below). The basilar membrane is a thick layer of amorphous material that contains about 20,000 keratin-like fibrils. These fibrils project away from the bony modiolus and have free ends that may vibrate. The lower surface of the basilar membrane is lined with the epithelial cells of the scala tympani. The epithelial cells of the spiral organ of Corti are located on the upper surface of the basilar membrane.

The lateral aspect of the cochlear duct, the spiral ligament, is lined with a modified epithelium called the stria vascularis. The stria vascularis consists of a pseudostratified epithelium and is vascularized by capillaries. The stria vascularis secretes endolymph and is involved in the maintenance of the unusual ionic composition of this fluid.

The epithelium of the cochlear duct extends from the stria vascularis onto the basilar membrane. The cells of Claudius and the cells of Boettcher are present in the epithelium before it reaches the organ of Corti. Numerous microvilli extending from these cells suggest that they have secretory and/or absorptive functions.

The spiral organ of Corti lies upon the basilar membrane and is composed of many different types of cells: two kinds of hair cells and six kinds of supporting cells. The hair cells are neuroepithelial and are divided into the inner and outer hair cells. The inner hair cells are bulbous in shape, their nuclei are basally located, and they contain many mitochondria concentrated around the nucleus. Their free surface displays few elongated stiff stereocilia arranged in a straight line. The inner hair cells are organized as a single cellular row along the entire length of the cochlea.

The outer hair cells are columnar in shape; their nuclei are round, basally located, and surrounded by many mitochondria. Their free surface has many (approximately 100) long stiff stereocilia that are arranged in a V-formation. The outer hair cells are organized in three or more rows along the entire length of the cochlea.

Both inner hair cells and outer hair cells are associated with phalangeal cells and form synaptic contacts with afferent and efferent nervous endings. The tips of the hair cells are embedded in the tectorial membrane, which projects away from the spiral limbus into the scala media. The tectorial membrane is a glycoprotein-rich viscous material; it is secreted by the epithelium covering the spiral limbus.

The supporting cells of the organ of Corti are tall and slender and contain conspicuous tonofibrils. Their apical surfaces contact with each other, hair cells, or both to form a continuous surface called the reticular membrane. The supporting cells include the inner and outer phalangeal cells, the inner and outer pillar cells, the border cells, and the cells of Hensen.

The inner and outer phalangeal cells are the supportive elements that are intimately associated with the inner and outer hair cells, respectively. The phalangeal cells rest on the basilar membrane. Each phalangeal cell has a cup-like indentation on its apical surface. The inferior third of a hair cell rests in this depression. The apical portion of phalangeal cells expands into umbrella-like phalangeal processes, which contact with the apical portions of the hair cells. The phalangeal cells also support the slender nerve fibers that form synapses with the hair cells.

The inner and outer pillar cells possess a wide base and have elongated processes that contain microtubules, intermediate filaments, and actin microfilaments. They both rest on the basilar membrane, their apices are intimately associated with each other. These cells enclose a space called the inner tunnel of Corti. The inner tunnel contains afferent and efferent nerve processes that pass through phalangeal cells and synapse with the hair cells.

The spiral organ of Corti contains two tunnels: the inner and outer tunnel. The inner tunnel is enclosed by the inner and outer pillar cells, as described above. The outer tunnel is located between the cells of Hensen and the outer hair cells. Both tunnels are filled with endolymph and communicate with each other via intercellular spaces.

The cells of Hensen and border cells delineate the inner and outer borders of the spiral organ of Corti. The outer border is made of the cells of Hensen; they are continuous with the cells of Claudius. The inner border of the organ of Corti is made of the border cells that continue into the region of the inner phalangeal cells.

The spiral ganglion is housed inside the spiral lamina and contains the cell bodies of afferent bipolar neurons. The dendrites of these cells innervate the hair cells of the organ of Corti; their axons make up the nerve fibers of the eighth cranial nerve and project into the central nervous system.

Hearing

The vibration of the tympanic membrane is transmitted through the auditory ossicles to the oval window and, thus, to the perilymph of the scala tympani. Vibrations in the perilymph cause vibrations in the basilar membrane and the basilar fibers. The basilar fibers near the base of the cochlea are thick and short; near the apex of the cochlea they are longer and more slender. The short fat fibers vibrate in resonance with high-frequency sounds; the long thin fibers vibrate in resonance with low-frequency sounds. Thus, the maximum amplitude of the basilar membrane displacement varies with the sound stimulus frequency.

The vibration is sensed by the hair cells as a result of their hairs, which are rigidly supported at their base by the reticular lamina, becoming displaced with respect to the tectorial membrane, in which their tips are embedded. This causes the hair cells to alter the pattern of impulse activity in the afferent nervous fibers they contact with. It is noteworthy that some large efferent nerve endings that contain synaptic vesicles are believed to transmit impulses to the hair cells. Auditory impulses from the afferent endings on hair cells are carried by fibers toward nerve cell bodies in the spiral ganglion. A single dendrite of an afferent neuron may have many branches and so receives impulses from many hair cells. The bipolar cells of the spiral ganglion send their axons (as the cochlear division of the auditory nerve) to end synaptically in the cochlear nuclei of the brain stem.

Vestibular apparatus

The vestibular apparatus includes two maculae in the saccule and utricle, and three cristae in the ampullae of the semicircular canals.

The maculae are specialized sensory regions located within the epithelium of the saccule and utricle. The saccule and utricle are endolymph-filled cavities lined with simple squamous epithelium and occupy the bony vestibule. The maculae are composed of different epithelial types: two types of neuroepithelial hair cells and supporting cells. The free surface of the macula is covered with a gelatinous material probably secreted by the supporting cells and containing small calcified particles called the otoliths. This gelatinous layer is termed the otolithic membrane.

The neuroepithelial hair cells are of two types and distinguished primarily by their type of afferent innervation, although they vary somewhat in shape too. Type I neuroepithelial hair cells are bulbar in shape. Their expanded portion contains a round nucleus, numerous mitochondria, and a well-developed Golgi apparatus. Their free surface displays 50 to 100 elongated rigid sensory microvilli (stereocilia) arranged in rows and a single cilium (kinocilium). The kinocilium has the typical microtubular arrangement of a cilium. The hairs of neuroepithelial cells do not float freely in the endolymph but are embedded in the otolithic membrane. The basal portion of type I cells is almost completely surrounded by a cup-shaped nerve ending.

Type II neuroepithelial hair cells are columnar in shape, possess basally located round nuclei, and have many mitochondria and a well-developed Golgi apparatus. Their free surface displays 50 to 100 long rigid microvilli (stereocilia) arranged in rows and a single cilium (kinocilium). The small afferent terminations make contact with the basal portion of these cells.

The supporting cells occupy the spaces between the hair cells. These cells are columnar in shape; their nuclei are round and basally located. They possess many microtubules that project from the base of the cell into an extensive terminal web.

The maculae in the utricle and saccule are sensors of gravity and linear acceleration. Hair cells in the maculae are stimulated by the otolith and the otolithic membrane movements, which, in turn, are generated by the head movements. The macula is arranged vertically in the saccule and horizontally in the utricle, so that the linear acceleration (positive or negative) of the head in these two planes is detected by the central nervous system.

The semicircular ducts are located in the semicircular canals. They are three in number and are oriented perpendicular to each other. The semicircular ducts contain endolymph that communicates with that in the utricle and the saccule. Each duct possesses a dilated region, the ampulla, which houses a crista, i.e., a sensory structure that resembles a macula. The crista is a sensory receptor site composed of two types of neuroepithelial hair cells and supporting cells. The free surfaces of these cells are covered with a thick glycoprotein layer called the cupula. The cupula has a conical shape over the receptor cells and contains no otoliths.

The semicircular canals and the crista ampullaris are regarded as sensors of the angular movements of the head and, hence, of the body as a whole. The cristae of the three semicircular ducts are positioned perpendicular to each other; therefore, the angular acceleration along any of the three axes is detected by the central nervous system. The nervous impulses that are generated by the hair cells of the maculae and cristae are transmitted to the brain via the vestibular portion of the acoustic nerve.

Organ of taste – the taste buds

The taste buds are small, intraepithelial structures containing specialized receptors, which, when stimulated by contact with food, give rise to the nerve impulses that result in sensations of taste. The taste buds are located on the lateral surfaces of the lingual papillae. The lingual papillae are little projections of the mucous membrane on the dorsal surface of the tongue. Each papilla is covered by stratified squamous modestly keratinized epithelium and has a central primary papilla of the lamina propria. In all lingual papillae, connective tissue cores form secondary papillae, which interdigitate with the overlying epithelium.

There are four types of papillae on the tongue: filiform, fungiform, foliate, and circumvallate. The fungiform, foliate, and circumvallate papillae contain taste buds in their lateral epithelium. The filiform papillae are covered by keratinized epithelium and do not contain taste buds.

Each taste bud is a group of epithelial cells arranged around a small central cavity called the taste pit, like slices in an orange. A taste pore is located on the apical surface of the taste bud and leads to the taste pit. In humans, the taste buds are composed of three different types of cells: supporting (sustentacular), neuroepithelial, and basal cells. The neuroepithelial cells are taste receptor cells; the sustentacular cells support them. The electron micrographs display long microvilli on the apical surface of both the receptor cells and the sustentacular cells, which pass through the taste pore to be bathed in saliva. These microvilli are described by light microscopists as the taste hairs. The apical microvilli of neuroepithelial cells contain chemoreceptors that function in the perception of the four taste sensations: salt, bitter, sweet, and sour. The nerve fibers from the basal surface of the buds synapse with neuroepithelial cells.

In order to be tasted, substances must exist in solution and pass through the taste pores into the taste pits. Here they stimulate the chemoreceptors to generate impulses in the afferent nerve fibers, which they synapse with.

Taste impulses from the anterior two thirds of the tongue are carried by the chorda tympani division of the facial nerve and from the posterior third by the glossopharyngeal nerve. Nonmyelinated afferent fibers of these nerves enter the proximal end of taste buds and synapse with the neuroepithelial cells, as described above.

The average life span of neuroepithelial and sustentacular cells is as short as 10 days. Both types of cells differentiate from the third kind found in a basal position in the taste bud – the basal cells. Taste receptors are as vulnerable to hazards as the epithelium, in which they are located. New receptor cells are formed continuously by differentiation of the basal cells in the taste buds.

Lecture 16

Cardiovascular System – I (V.L. Goryachkina)

The cardiovascular (or circulatory) system is a transport system. There are two main circulatory systems: the blood circulatory system and the lymphatic circulatory system.

The blood circulatory system carries oxygen, carbon dioxide, nutrients and metabolic breakdown products, cells of the immune system, hormones and many other important substances. The lymphatic system drains extracellular fluid from the tissues, returning it to the blood after having passed through the lymph nodes. This system is also involved in the absorption of nutrients from the gut.

Blood circulatory system

The blood circulatory system consists of arteries, veins, and vessels of microcirculation. The microcirculation includes arterioles, capillaries, venules, and arteriolo-venular anastomoses (shunts).

General structure of the blood vessel wall

The structure of the vessels depends on the hemodynamic conditions (the blood pressure and the speed of the blood stream).

Blood vessels are composed of three layers, which vary in prominence in different vessel types. These layers are: intima, media and adventitia.

The intima is composed of a lining layer of highly specialized multifunctional flattened cells termed endothelium. Endothelial cells rest on a basal lamina; beneath it is a very thin layer of loose connective tissue.

Endothelium is highly specialized with endocrine, exocrine, cell adhesion, clotting, and transport functions. Endothelium is a slowly renewing population of infrequently dividing cells. Endothelial cells of veins have greater mitotic potential than those of arteries. Endothelial cells produce some components of the basement membrane: proteoglycans, fibronectin, laminin, etc. Endothelium is nonthrombogenic. The endothelial surface has a negative charge. Blood platelets have a negative charge, too. Thus, they repel each other. Owing to its charge, the intact endothelium is not attractive for blood cells and is therefore nonthrombogenic. Conversely, subendothelial structures (especially collagen) are highly attractive for the blood cells; hence, they are thrombogenic.

Besides, endothelium produces some substances that modulate blood coagulation and vasodilatation. For instance, endothelial cells produce (a) prostacyclin, which inhibits platelet aggregation; (b) nitric oxide, which promotes vasodilatation and inhibits platelet adhesion and aggregation; (c) thromboplastin, which promotes blood coagulation; (d) the Willebrand factor promotes platelet adhesion and activation of blood coagulation.

Endothelial cells take part in the regulation of the vascular tone. This regulation is associated with the receptors on the endothelial surface. Endothelial cells take part in capillary permeability.

The exchange diffusion is possible due to the high permeability of endothelium. Actually, the endothelial transport appears to be a very complex process. Some molecules are delivered to the endothelial cell itself (pinocytosis), whereas others are transported across the endothelial cells to the surrounding tissues (transcytosis). Some molecules use both of these pathways.

The media is composed of smooth muscle cells, a fine network of collagen and elastic fibers, elastic membranes, and the ground substance containing proteoglycans and glycoproteins.

The adventitia is composed of loose connective tissue, but smooth muscle cells may be present, particularly in veins. Within the adventitia are small blood vessels, the vasa vasorum. The vasa vasorum send penetrating branches into the media and the intima in veins. The adventitia also carries autonomic nerves, which innervate smooth muscle cells of the media.

Arteries

Types of arteries

Muscular arteries	Elastic arteries	Mixed arteries
<u>Distributing arteries:</u> (a) <u>large arteries</u> blood vessels 2 to 10 mm in diameter, receiving blood from elastic arteries and distributing it to tissues and organs and (b) <u>small arteries</u> 0.1 to 2 mm in diameter.	<u>Conducting arteries:</u> aorta, brachiocephalic artery, common carotid artery.	<u>Conducting arteries:</u> They are a transitional segment between elastic and muscular arteries: axillary, external carotid, common iliac, and subclavian arteries.

The structure of arteries

Type of arteries	Tunica interna (intima)	Tunica media	Tunica externa (adventitia)
Muscular arteries (a) large arteries	1. Endothelium: a single continuous layer of squamous epithelial cells lying on the basal lamina. 2. Subendothelial layer consisting of loose connective tissue. 3. Prominent internal elastic (lamina) membrane, (missing in the umbilical artery).	10 to 60 layers of helicoidally arranged smooth muscle cells. Smooth muscle cells predominate. Between them runs a fine network of collagen and elastic fibers and the ground substance containing proteoglycans and glycoproteins.	(a) external elastic membrane, (b) loose connective tissue, (c) vasa vasorum, (d) lymphatic vessels, (e) nervi vasorum.
(b) small arteries	(1) Endothelium; (2) No subendothelial layer; (3) Thin internal elastic membrane.	3 to 10 layers of smooth muscle cells with a few elastic fibers, and ground substance.	(a) indistinct or absent external elastic membrane, (b) loose connective tissue, (c) vasa vasorum, (d) nervi vasorum.
Elastic arteries	(1) Endothelium; (2) The subendothelial layer consisting of loose connective tissue with longitudinally disposed bundles of smooth muscle cells; (3) There is no inner elastic membrane. There are many bundles of elastic fibers instead of it.	(a) 50 to 70 concentrically arranged fenestrated elastic membranes (lamellae) interconnected by elastic* and collagen fibers, (b) smooth muscle cells (circumferentially disposed), (c) the ground substance containing proteoglycans and glycoproteins, (d) vasa vasorum (in the outer part of the tunica media).	(a) loose connective tissue, (b) vasa vasorum, (c) lymphatic vessels, (d) nerve fibers.
Mixed arteries	(1) Endothelium; (2) Subendothelial layer consisting of loose connective tissue; (3) Inner elastic membrane.	(a) fenestrated elastic membranes, (b) smooth muscle cells, (c) the ground substance, collagen and elastic fibers.	(a) loose connective tissue, (b) vasa vasorum, (c) nerve fibers.

*It should be noted that elastic structures (fenestrated elastic membranes and elastic fibers) predominate.

Microcirculation

Microcirculation is concerned with the exchange of gases, fluid, nutrients and metabolic waste products. Most of this exchange between blood and tissues occurs in the capillaries. The blood flow within the capillaries is controlled by arterioles and muscle sphincters in the arteriolo-capillary junctions called the precapillary sphincters. Blood from the capillaries enters the system of venules.

The structure of arterioles

The arteriolar wall is composed of three layers: the intima, the media, and the adventitia. The intima of an arteriole is composed of endothelial cells lying on a basement membrane. The underlying layer is a fine internal elastic membrane (the lamina). The media is composed of one or two layers of smooth muscle cells. Note that endothelial cells have basal processes, which pierce the basement membrane and make junctional contact with the smooth muscle cells. The adventitia is a very thin layer of loose connective tissue.

Arterioles vary in diameter ranging from 30 to 400 nm (0.4 mm).

Arterioles are very responsive to vasoactive stimuli and make a major contribution to vascular resistance. I.M. Sechenov termed them the taps of the circulatory system.

Blood capillaries

Capillaries are the smallest vessels of the blood circulatory system (5 to 10 nm in diameter) and form a complex interlinking network. Their function is the site of interchange of different substances between blood and tissues. That is why their wall is very thin. It consists of three layers: (1) endothelial; (2) basal layer and (3) adventitial layer. The first layer is the endothelial layer. Endothelial cells rest on the basement membrane. Endothelial cells contain many special transfer vesicles – pinocytotic vesicles. The second layer consists of the pericyte and the basement membrane. The pericyte is enclosed by the basement membrane. The basement membrane and pericyte support endothelial cells. Moreover, the basement membrane takes part in permeability. Pericytes can produce proteoglycans, collagen, and elastic fibers. They contain actin and myosin filaments suggesting a contractile function. Pericytes can give rise to smooth muscle cells during vascular growth and after tissue injury. They can pass information from the intercellular space (interstitia) to endothelial cells due to the presence of junctions between endothelial cells and pericytes.

The third layer (the adventitial layer) consists of adventitial cells of loose connective tissue. Capillaries may be of three types: continuous, fenestrated, and sinusoidal.

Types of capillaries

Continuous	Fenestrated	Sinusoidal
<p>1. Continuous endothelial cells are held together with the zonula occludens, gap junctions, and desmosomes.</p> <p>2. Continuous basal lamina (basement membrane) is thick (20 to 50 nm). This type of capillaries is found in muscular tissues, testis, ovary, CNS, lung, and connective tissue.</p>	<p>1. Very thin endothelial cells with fenestrations are held together with the zonula occludens, gap junctions, and desmosomes. Fenestrations are formed of two cell membranes, which are situated so near each other that it is not possible to observe even a short distance between them.</p> <p>2. Continuous basement membrane. It splits the enclosed pericytes. This type of capillaries is found in the endocrine glands, kidney, and small intestine.</p>	<p>1. Endothelial cells are often with large pores. These cells are held together with a zonula occludens and gap junctions.</p> <p>2. The basement membrane is scanty, discontinuous, or absent. This type of capillaries is found in the spleen, lymphatic nodes, bone marrow, and liver.</p>

Venules

The capillaries drain into postcapillary venules (10 to 15 nm in diameter). Their wall is similar in structure to that of the capillaries, but they have more pericytes. The blood flow in this venule is sluggish, and this venule appears to be the main point at which white blood cells enter and leave the circulation.

Postcapillary venules drain into collecting venules. They are larger in diameter (20 to 50 nm). The pericytes form a continuous layer here.

Collecting venules drain into muscular venules. They contain one or two layers of smooth muscle cells and a well-developed adventitia.

Muscular venules drain into small veins.

Lecture 17

Cardiovascular System – II (V.L. Goryachkina)

Shunts (anastomoses)

The blood can be also shunted from arterioles directly to venules via anastomoses. These vessels have a thick wall with an average diameter of 12 to 15 nm, which may vary from 100 to 300 nm in length. Such shunts are frequent in the skin of the finger-tips and toes, nail beds, lips, nose, intestinal tract, thyroid, and erectile tissue. The shunts are classified into three types:

The first type. It was called simple with supplementary smooth muscle cells within the media. These cells are rather short and thick, forming a sphincter that on section resembles a stratified cuboidal epithelium. These cells have been termed epithelioid cells.

The second type. It was called the glomerular type with supplementary smooth muscle cells within the media. There are two or three branches, which have a structure similar to that of the first type. But all of these branches have common adventitia. Since on section they resemble a glomus, this type of anastomosis was termed glomerular.

The third type. The feature of this anastomosis is the presence of smooth muscle cells (longitudinal direction in arrangement) within the intima. Besides, some muscle cells occur within the media. Note that these anastomoses contain a large number of both myelinated and nonmyelinated nerve fibers.

Functions:

(1) They take part in thermoregulation; they dilate in cold weather to shunt the blood to the venules to reduce heat loss. In hot weather they constrict, allowing blood to pass through the skin capillaries, thus increasing the heat loss.

(2) They take part in the regulation of the blood flow to the organs.

Veins

From venules, the blood is collected in veins of increasing size. For this reason they are classified as small, medium, and large. In addition to this classification, there exists another subdivision: muscular and unmuscular (they are devoid of smooth muscle cells). The muscular type is subdivided into the following subtypes: with a small content of smooth muscle cells (SMC), with a medium content of SMC, and with a large content of SMC. The structure of the vein conforms to the general three-layer arrangement in the circulatory system.

Types of veins

I. Unmuscular type. The intima of these veins contains endothelium. It rests on the basement membrane. The tunica media is absent. The tunica externa consists of loose connective tissue. The veins devoid of SMC: meningeal and dural sinuses, retinal veins, bones, splenic trabeculae, maternal placenta, and the nail bed.

II. Muscular veins are subdivided into three types:

(a) with a small amount of SMC. The tunica intima consists of endothelium, which rests on the basement membrane. The tunica media contains 1 to 2 SMC layers, the ground substance, collagen, and elastic fibers. The tunica externa consists of loose connective tissue.

(b) with a medium amount of SMC. The tunica intima consists of endothelium and a thin subendothelial layer. The tunica media contains several layers of SMC arranged in a circular fashion, the ground substance, collagen, and elastin fibers. The tunica externa contains loose connective tissue and SMC in longitudinal disposition.

(c) with a large amount of SMC. The tunica intima consists of endothelium, the subendothelial layer, and SMC in longitudinal disposition. The tunica media contains several layers of SMC arranged in a circular fashion, the ground substance, collagen and elastin fibers. The tunica externa contains loose connective tissue and SMC in longitudinal disposition.

Note that the adventitia of veins is often their thickest coat. For example, the vena cava inferior contains SMC within the intima, media, and adventitia; but the adventitia is approximately five times thicker than the intima and the media together. The adventitia of this vein contains bundles of longitudinally arranged SMC, surrounded by bundles of collagen fibers. It is noteworthy that the vena cava inferior has no valves.

It should be noted that there are some differences between the arteries and veins. About 50% of veins have valves* that prevent the backflow of the blood. Veins have a very thin subendothelial layer; they have no internal and external elastic membrane (except for vena cava inferior which has the internal elastic membrane). Veins have a poorly developed framework of elastic fibers and thick adventitia. They have the vasa vasorum within the intima, the media, and the adventitia.

The lymph vascular system

The lymph vascular system drains excess fluid (lymph) from the extracellular space and returns it to the blood vascular system. Lymph is formed in the following way. Water and electrolytes pass out of capillaries into the extracellular space; some plasma proteins also leak out through the endothelial wall. The excess fluid is drained by a system of lymph capillaries. Lymph flows sluggishly from the capillary network into the larger lymphatic vessels. On the way to larger veins, the lymph passes through one or more lymph nodes. During their passage any antigen can be processed by the components of the immune system. Lymph enters the venous system by a single vessel on each side of the body, namely, the thoracic duct and the right lymphatic duct. Lymphatic vessels are found in all tissues, except the central nervous system, cartilage, bone, red bone marrow, thymus, placenta, cornea, and teeth. The structure of lymphatic vessels is similar to that of veins. But lymphatic vessels have numerous valves that prevent the backflow

of lymph. Lymphatic capillaries differ from blood capillaries in several respects. Lymphatic capillaries begin mostly as blind dilatations. The cytoplasm of endothelial cells is very thin. The endothelial cells are held together with the zonula occludens. In the lacteals (blind sac-like lymphatic capillaries) of intestinal villae, there are apertures between endothelial cells. The basement membrane is rudimentary or absent, and there are no pericytes. Note that the fine collagen filaments known as anchoring filaments link to the endothelium and to the surrounding thick collagen fibers, preventing the collapse of lymphatic vessels.

Heart

The heart is a muscle pump. The wall of the heart is composed of the endocardium, the myocardium, and the epicardium.

Endocardium

Endocardium forms a complete lining for the atria and ventricles and covers all the structures projecting into them such as valves, chordae tendineae, and papillary muscles.

Endocardium consists of **four** layers:

- (a) endothelium (rests on the basement membrane),
- (b) subendothelial layer (delicate loose connective tissue),
- (c) myoelastic layer (the thickest) consisting of dense connective tissue, smooth muscle cells, elastic and collagen fibers,
- (d) external (deepest) layer, also called the subendocardial layer. It consists of loose connective tissue. This layer contains blood vessels, and in certain sites it also contains branches of the impulse-conducting system (Purkinje's fibers).

It should be noted that there are no blood vessels within the endocardium, with the exception of the external layer. The source of the endocardium development is mesenchyme.

*Valves consist of semilunar projections of the tunica intima of the vein wall: the projections are composed of loose connective tissue lined on both sides by the endothelium.

Myocardium

Myocardium consists of striated muscle cells (cardiomyocytes). These cells are joined end-to-end by cell junctions – intercalated discs.

At the end of the 19th century the German scientist Ebner, using special staining, described some dark strips on the fibers of the myocardium. He called these strips intercalated discs. He was the first to suppose that intercalated discs are the borders between two adjacent cells and the myocardium consists of the cells. With EM, it was established that intercalated discs are the borders between two cells.

Every cardiac muscle cell is cylindrical in shape. Every cell has one to two nuclei in the central disposition. Some cells are connected by anastomoses. A thin layer of loose connective tissue with many blood capillaries surrounds every cell. It should be noted that myocardium contains numerous lymphatic vessels, and a large number of nonmyelinated parasympathetic (the vagus nerve) and sympathetic nerve fibers are present in myocardium.

Note that the amount of the myocardium and the diameter of cardiomyocytes vary according to the workload of the chamber. The left and right atria have a thin wall composed of cells of small diameter. The right ventricular myocardium is composed of cells intermediate in diameter between atrial and left ventricular muscle cells. The left ventricle has the thickest myocardium with the largest diameter of muscle cells.

Ultrastructure of cardiomyocytes

Like skeletal muscle fibers, cardiac muscle cells contain many myofibrils that have longitudinal direction in arrangement. Cardiomyocytes contain much more longitudinally arranged mitochondria than skeletal muscle fibers. This fact reflects the extreme dependence of myocardium on aerobic metabolism. The intracellular network of membranes surrounding the myofilaments known as the sER (or the L-system) is well-developed in cardiomyocytes. The T-tubular network is simpler and wider in cardiac than in skeletal muscles. As a rule, one T-tubule and one cistern of the L-system form a diad (in skeletal muscle fibers, two L-tubules and one T-tubule form a triad). The sarcoplasm of cardiac muscle cells is characterized by numerous lipid droplets and glycogen particles, reflecting nutrient reserves.

Intercalated disk

The intercalated disk is the means by which cardiomyocytes are electrically and mechanically linked. It allows cardiomyocytes to function in an integrated fashion. Within the intercalated disk are intercellular junctions, i.e., specialized membrane regions that provide electrical coupling and mechanical adhesion between adjacent cells. These junctions are as follows: (a) fascia adherens junctions, (b) gap junctions, and (c) desmosomes.

The fascia adherens junction anchors actin filaments within each cell to the plasma membrane. Each fascia adherens consists of a submembranous dense attachment plaque containing placoglobin, a network of actin filaments attached to the plasma membrane by alpha-actinin and vinculin, and a very thin space filled with adhesive glycoprotein.

The gap junction (nexus) provides a low-resistance passway across the membranes of adjoining cells. These junctions are the sites where excitation spreads from one cell to another and where small molecules and ions pass readily from one cell to another.

Desmosomes serve to anchor the plasma membranes to the intermediate cytoskeletal filaments of cardiac muscle cells.

The differences between atrial and ventricular cardiomyocytes are as follows:

- (1) Atrial myocytes are smaller in diameter (12 μm) than ventricular muscle cells (15 μm);
- (2) T-tubules are absent in atrial cells, note that a lot of micropinocytosis vesicles are located beneath the plasmalemma;
- (3) A higher number of gap junctions within the intercalated discs between atrial myocytes;
- (4) Some atrial cells have special atrial electron-dense granules. These cells with special atrial granules contain a well-developed rER and Golgi complex. These granules are the site of storage of polypeptides (hormones). This is the so-called atrial natriuretic factor (ANF). The ANF causes a fall in arterial pressure, a significant diuresis and natriuresis, inhibits the secretion of several hormones involved in the regulation of water-salt balance (aldosterone, renin, and vasopressin).

Specialized conducting system

The conducting system of the heart is composed of modified muscle cells. It is known that the heart contracts involuntarily. Atrial and ventricular contractions do not depend on nerve stimulation. They depend on the impulses generated within the heart itself. The pace of this beating action is initiated at the sinoatrial node (SA-node). The SA-node is located where the vena cava superior enters the right atrium.

This node is composed of special cells. They have unusual electrophysical characteristics, and they were called pacemaker cells. These cells are small (3 to 5 μm). They contain only few myofibrils and lack an organized striation pattern; they do not have intercalated disks. They connect with each other by desmosomes. There are many nerve endings within this node.

From the SA node the impulse passes quickly to the atrioventricular (AV) node. The AV-node is located beneath the endocardium of the medial wall of the right atrium (above the tricuspid valve ring). The AV-node is also composed of the pacemaker cells. The pacemaker cells of the SA- and AV-nodes are embedded in connective tissue with numerous blood vessels and nerve fibers. Some small cells form a distinct bundle of these cells from the anterior end of the AV-node. This conducting bundle was termed the bundle of His.

The bundle of His conducts impulses from the AV-node to Purkinje's fibers (cells). Purkinje's cells are larger than ventricular muscle cells and contain a large amount of glycogen. They have few myofibrils and lack T-tubules. Purkinje's fibers lie in clusters of up to about six cells. They conduct impulses to transitional cells, which conduct impulses to ventricular cells.

Transitional cells are smaller than Purkinje's cells. They look like cardiomyocytes, but T-tubules are absent here. That is why it is impossible to identify them with light microscopy.

Epicardium

Epicardium is a very thin layer covered with flat mesothelial cells to produce a smooth outer surface. These cells lie on a connective tissue layer. This layer contains large arteries supplying blood to the heart wall and larger venous tributaries carrying blood to the heart wall. The coronary arteries and veins are surrounded by adipose tissue, which expands the epicardium.

Central fibrous skeleton of the heart

The central fibrous skeleton of the heart anchors the heart valves (they are composed of dense connective tissue) and chambers together. This skeleton is composed of dense connective tissue. Dense connective tissue forms the fibrous ring of the aorta, the pulmonary artery, and the left and right atrioventricular rings. Besides, a downward extension of dense connective tissue of the aortic valve ring forms a fibrous septum between the right and left ventricles.

Lecture 18

Central Organs of Hemopoiesis: Red Marrow and Thymus (V.L. Goryachkina)

Hemopoiesis takes place during embryonal development and postnatal life. Prenatal hemopoiesis is subdivided into three stages (see below). Postnatal hemopoiesis occurs in the red bone marrow where erythrocytes, granulocytes, monocytes, platelets, and B-lymphocytes are formed. The development of T-lymphocytes from lymphocytes derived from bone marrow occurs in the thymus. These organs (bone marrow and thymus) are therefore called the central organs of hemopoiesis. As for T- and B-lymphocytes, contact with antigens is needed for their final differentiation (antigen-dependent proliferation and differentiation – see below), these lymphocytes have to migrate to the peripheral organs of hemopoiesis, such as the spleen, lymph nodes, tonsils and lymphatic nodules (follicles) scattered in the mucosa of the alimentary canal, the conducting portion of the respiratory system, and the urethral and urinary bladder mucosa (see in detail below).

Prenatal hemopoiesis

The site of blood cell formation changes several times during fetal development, the earliest site being the wall of the yolk sac.

I. The wall of the yolk sac. Hemopoiesis begins from the 9th day to the 9th week. The first phase of hemopoiesis occurs in the “blood islands” in the wall of the yolk sac. The “blood islands” are groups of mesenchyme cells. The peripheral cells of these islands will change shape (get flattened) and will then differentiate into endothelial cells. The central cells will become round in shape and will be the stem cells (the first generation). Stem cells turn into megaloblasts. The latter turn into megalocytes. Megalocytes are primitive erythrocytes: they are large, often have a nucleus. It should be noted that hemopoiesis takes place within the vessels; that is why it was termed intravascular hemopoiesis. The formation of primitive leukocytes (only granulocytes) takes place extravascularly.

II. The second phase or hepatic phase. The first generation of stem cells migrates to the liver. Hemopoiesis in the liver begins from the 6th week. The liver becomes the major organ of hemopoiesis. The formation of all blood cells takes place extravascularly. Erythrocytes have their usual shape, are anucleous and have specific HbF. HbF is the principal form of hemoglobin in the fetus.

III. The third phase of hemopoiesis or medullar phase. The stem cells (the second generation) migrate to the spleen, lymph nodes, and red bone marrow. Initially it is here where the formation all of the blood cells takes place. But this hemopoiesis fades gradually in the spleen and lymph nodes. It will stop during the 5th month for the spleen, and the 15th week for lymph nodes.

The red bone marrow becomes the dominant hemopoietic organ in the latter half of gestation, when hemopoiesis in the liver stops. All blood cells, except T-lymphocytes, are produced in the marrow, and hemopoiesis continues throughout postnatal life.

Pre-T-cells originate in the marrow, then migrate to the thymus, where they undergo special differentiation. From the second month of gestation, the thymus is engaged in T-cells production only.

Although the liver is inactive hemopoietically after birth, it does retain its potential for hemopoiesis. In the case of bone marrow failure, hemopoiesis may be resumed in the liver or in the spleen. This phenomenon is termed extramedullary hemopoiesis.

Postnatal hemopoiesis

At birth, almost all bones are involved in hemopoiesis. Over the next few years only the marrow of the vertebrae, ribs, skull, pelvis, and proximal femurs is hemopoietic; the rest having been replaced by adipose tissue.

Postnatal hemopoiesis can be subdivided into six classes:

The first class. This class is represented by stem cells from which all blood cells originate. Hemopoietic stem cells divide infrequently. They are held in reserve and are not even in the cell cycle, being in G₀.

- (1) These cells are capable of both sustained proliferation and differentiation into mature cells;
- (2) The stem cells are multipotential (or pluripotential) cells, meaning that they are able to differentiate into any type of blood cells;
- (3) Although there is no direct evidence of the structure of stem cells, they were supposed to look like small lymphocytes;
- (4) These cells can form differentiating colonies termed colony -forming units (CFU).

The second class. Two main types of multipotential progenitor cells derive from the stem cells:
(a) lymphoid progenitor cells, which give rise to T- and B-lymphocytes; (b)

granulocyte/erythroid/monocyte/megakaryocyte (CFU-GEMM)* progenitor cells, which give rise to the main type of blood cells. Although no direct evidence of the structure of these cells exists, indirect evidence indicates that these cells are similar to the 1st class of stem cells or look like small lymphocytes.

The third class. The types of committed (unipotent) cells derived from the multipotential CFU-GEMM cells are as follows:

- (1) erythroid (CFU-E), which gives rise only to red cells;
- (2) monocyte (CFU-M), which gives rise only to monocytes;
- (3) neutrophil (CFU-N), which gives rise only to neutrophils;
- (4) eosinophil (CFU-Eo), which gives rise only to eosinophils;
- (5) basophil (CFU-Bas), which gives rise only to basophils;
- (6) megakaryocyte (CFU-Meg), which gives rise only to platelets;
- (7) T-cell lymphocyte precursor, which gives rise only to T-lymphocytes;
- (8) B-cell lymphocyte precursor, which gives rise only to B-lymphocytes.

Note that all of these precursor cells look like small lymphocytes.

The fourth class. These precursor cells are termed blast cells. It is impossible to differentiate between them with the light microscope (LM), but they can be distinguished from the cells mentioned above. These cells are larger in diameter than small lymphocytes; their nuclei are pale, their cytoplasm is blue.

The fifth class. These precursor cells differ between each other. These cells are maturing cells. We shall study them in detail later.

The sixth class. Mature blood cells.

Erythropoiesis (beginning with the 5th class)

The first recognizable erythrocyte precursor is known as the proerythroblast, a large cell with a lot of ribosomes and no hemoglobin. The next stage (basophilic erythroblast) is characterized by numerous ribosomes and little hemoglobin. The cytoplasm of these cells stains deeply with basic dyes. The intermediate stage (polychromatophilic erythroblast) is characterized by the loss of ribosomes and the accumulation of hemoglobin. The late stage of erythroblasts (orthochromatic or acidophilic erythroblasts) is characterized by the progressive loss of ribosomes and progressive hemoglobin synthesis. Due to the presence of a lot of hemoglobin, the cytoplasm of the cells is oxyphilic (acidophilic).

With maturation (beginning with erythroblasts), the cell size decreases; the nucleus becomes smaller, markedly heterochromatic and loses the nucleoli. Then nuclear loss occurs near the orthochromatic stage.

The erythroblast pool is maintained by the proliferation of basophilic and polychromatophilic erythroblasts. Acidophilic (orthochromatic) erythroblasts are postmitotic, i.e., they do not divide.

After extrusion of the nucleus, some young erythrocytes contain a relatively small number of ribosomes. These cells were termed reticulocytes due to presence of a blue web (reticulum) within a pink erythrocyte (with special staining). Reticulocytes constitute about 2% of circulating erythrocytes in normal human blood. Reticulocyte maturation is characterized by a decrease in the cell size and the loss of mitochondria and ribosomes. In mature erythrocytes, the organelles are absent. Reticulocytes and erythrocytes belong to the 6th class.

Note that red cell production is controlled by erythropoietin produced by the kidneys. Erythropoietin stimulates the last three to five divisions in erythroid maturation.

Granulopoiesis (beginning with the 5th class)

Myeloblasts (from the fourth class) (derived from the Greek *myelos* meaning “marrow”) give rise to promyelocytes (the 5th class). These cells are characterized by the development of azurophilic granules. These granules are referred to as primary granules. The primary granules are merely large lysosomes. The next stage in differentiation is myelocyte. The myelocyte is marked by the development of specific granules (secondary).

Neutrophils have two types of granules: large primary granules and small secondary granules barely resolvable by light microscopy. Basophilic and eosinophilic (secondary) granules can usually be recognized soon after their appearance. The myelocyte shows early flattening or invagination of one face of the nucleus, from which the nucleoli have disappeared. The metamyelocytes or juvenile cells show more advanced invagination of the nucleus to a reniform shape. The immediate precursors of mature granulocytes have an irregular horseshoe or sometimes ring-shaped nucleus and are termed stab cells or band forms. These cells described above belong to the fifth class. Mature granulocytes (the sixth class)

* CFU – colony-forming unit; G – granulocyte, E – erythrocyte, M – monocyte, Meg – megakaryocyte.

contain multilobulated nuclei. Note that myeloblasts, promyelocytes, and myelocytes are mitotic forms, whereas metamyelocytes, bands, and mature granulocytes are postmitotic cells. A few metamyelocytes may normally circulate.

Some substances stimulate the formation of granulocytes*. Among them are:

- (1) the granulocyte-macrophage colony-stimulating factor GM-CSF produced by endothelium, macrophages, and T-lymphocytes;
- (2) granulocyte colony-stimulating factors produced by endothelium, macrophages, and fibroblasts; the stem cell factor produced by bone marrow stromal cells, endothelial cells, and fibroblasts;
- (3) interleukin-5 (produced by T-cells) stimulates the proliferation and activation of eosinophil and basophil precursors.

Monocyte formation

Two precursors of monocytes are recognized: monoblasts and promonocytes. Monopoiesis is characterized by reduction in the cell size and progressive indentation of the nucleus. At least three cell divisions occur before the mature monocyte stage is reached. Mature monocytes leave the red bone marrow soon after their formation and there is no reserve pool.

The formation of monocytes is controlled by the following factors:

- (a) GM-CSF,
- (b) the macrophage colony-stimulating factor M-CSF produced by endothelium, monocytes, and fibroblasts,
- (c) interleukin-2 produced by T-cells.

Platelet formation

Platelets originate as portions of the megakaryocyte cytoplasm (their diameter measures more than 50 nm). The precursors of megakaryocytes are megakaryoblasts (the fourth class). The latter undergo as many as seven reduplications of the nuclear and cytoplasmic constituents without cell division (endomitosis). The result is a large nucleus (and cytoplasm) sized in proportion to the level of polyploidy (it varies from 2n to 64n). Nuclear lobulation occurs in these cells. Cytoplasmic maturation involves the elaboration of granules, vesicles, and cytoplasmic membranes. These membranes outline platelet zones as the demarcation system of membrane. They are continuous with the plasma membrane. When platelets separate from the megakaryocyte, the demarcation membranes fuse and become the surface membrane of platelets. The megakaryocyte cytoplasm is divided into three zones: **the perinuclear zone** contains the Golgi apparatus, rER and sER granules, centrioles, and microtubules; **the intermediate zone** contains vesicles and the demarcation membrane system; **the outer marginal zone** is filled with microfilaments, granules and is traversed by membranes connecting with the demarcation membrane system.

Platelets are formed by fragmentation of the cytoplasm of megakaryocytes. Megakaryocytes lie against the outside of vascular sinuses in the bone marrow, delivering platelets directly into the vascular lumen. The humoral substance (thrombopoietin) stimulates the maturation of megakaryocytes and the rate of platelet formation.

Lymphopoiesis

The bone marrow is the site of formation of precursors of lymphocytes, which give rise to B- and T-cells at different sites. Thus, stem cells destined to become T-cells originate in the red bone marrow. Then they leave the marrow (the 2nd class) and migrate to the thymus where they undergo proliferation and differentiation to become T-lymphocytes before migration to the peripheral lymphoid organs. B-cells undergo initial maturation in the red bone marrow and then migrate to the peripheral lymphoid organs (spleen, lymph nodes, tonsils, lymphoid nodules within the digestive tract mucosa, etc.). The proliferation and differentiation of T-cells in the thymus and B-cells in the red bone marrow is termed antigen-independent. The formation of receptors to antigens and cluster designation (CD) molecules occurs during the antigen-independent proliferation and differentiation.

Structure of the red bone marrow

Bone marrow can be red because of the presence of erythrocytes and their precursors, which is indicative of active hemopoiesis; or yellow owing to fat, indicating reduced hemopoiesis.

All marrow in newborn humans is red. Fat appears in long bones from the fifth to the seventh year; and by the age of 18 years, almost all limb marrow is yellow. Hemopoietic marrow in adults is largely restricted to the skull, clavicles, vertebrae, ribs, sternum, and pelvis.

The red bone marrow is within the space of bone. It is composed of (a) stromal elements, (b) blood vessels, and (c) developing blood cells at various stages of formation and maturation.

* Many of these substances can now be synthesized and are being used in the treatment of diseases of the blood.

Bone marrow stroma

It consists of

- (1) reticular cells. These cells are branched, with a pale nucleus; they contain many rER cisternae. They form reticulum meshwork. The latter holds the developing blood cells. **Functions:** (a) formation of the ground substance and reticular fibers (collagen of the 3rd type). The ground substance contains hyaluronic acid, chondroitin sulfate, and heparan sulfate. These glycosaminoglycans may bind growth factors, which control hemopoiesis. Moreover, the ground substance contains laminin and fibronectin, which facilitate adhesion of hemopoietic cells to the marrow stroma, (b) production of special hemopoietic growth factors, (c) by accumulating lipids they may transform into adipocytes found in the bone marrow.
- (2) osteogenic cells: osteoblasts and osteoclasts; they are situated on the surface of bone trabeculae (endosteum).
- (3) macrophages. There are two types of macrophages within bone marrow. The first type is represented by fixed macrophagic cells, which remove aged and defective red cells from the circulation by phagocytosis; in addition, these macrophages are involved in the production of some growth factors and, perhaps, facilitate the delivery of reticulocytes to the circulation. The second type of macrophages are nurse cells. The latter seize iron from circulation and convey it to erythroblasts. As a rule, macrophages lie among the erythroblasts, but a macrophage often lies in the center of the erythroblastic islet. The cytoplasm of this macrophage extends out and encloses the surrounding erythroblasts.
- (4) adipose cells. These cells serve as the sites of fat storage. Moreover, adipose cells take part in the production of some growth factors. It was shown that fat cells aromatize testosterone to estrogen. In some cases, for example, during severe blood loss, these cells lose their fat, thereby decreasing the volume and providing additional space for hemopoiesis.

Blood vessels

Veins and arteries constitute the vascular compartment of the marrow. The marrow lacks lymphatic vessels. The bone marrow is supplied with medullary branches from the nutrient artery of the bone. A capillary network opens into a well-developed series of thin-walled sinusoids, which empty into a large central sinus. The blood leaves the bone in the emissary vein via the nutrient canal.

The bone marrow sinusoids are lined with flat endothelial cells. They lie on a discontinuous basement membrane. In some places the cytoplasm of endothelial cells is so thin that forms "pores" (or "apertures"). Mature blood cells adhere to this pore before being realized into the circulation. Sometimes mature blood cells squeeze through endothelial junctions. Blood cells press to the junction, and the aperture appears. Apertures normally develop only in relationship to the cell passage; they are either occupied by a cell in transit or absent.

Developing blood cells form hematopoietic compartments

Erythroblasts are produced near sinuses, forming erythroblastic islets. Megakaryocytes lie close against the adventitial surface of the sinusoids. They deliver platelets to the vascular lumen. Since megakaryocytes are large cells, they resist being swept into circulation and prevent vascular leakage. Granulocytes are produced in nests or as dispersed sheets of the cells somewhat away from the vascular sinuses. Lymphocytes (precursors) occur throughout the marrow.

Macrophages, reticular, osteogenic, adipose, and vascular cells are all necessary for the formation of the blood cells. They constitute the microenvironment for developing cells.

Thymus

The thymus is divided into lobes and lobules by connective tissue septa. They extend into the organ from the connective tissue capsule. Each lobule is divided into the peripheral zone called the cortex (it is rich in lymphocytes) and the central zone, namely, medulla (less lymphocytes).

The stroma of every thymus lobule consists of branched epithelial cells. These cells are joined together by desmosomes. These epithelial cells form a reticulum (meshwork) within the lobules. That is why they were called reticulo-epithelial cells. They serve as a framework for T-lymphocytes.

Macrophages are present within the lobules. Macrophages perform the following functions: (1) phagocytosis and (2) production of the factor stimulating one division and differentiation of T-lymphocytes. It is noteworthy that the phagocytosis of macrophages is unusual. Macrophages will phagocytose only degenerating T-lymphocytes.

Large multinucleated cells are present in the outer part of the cortex. As a rule, 20 to 100 T-lymphocytes surround one of these cells. These cells were supposed to secrete some factors for differentiation of T-lymphocytes. These cells were called nurse cells.

Some granulocytes, plasma cells, mast cells, and fat cells are present in the thymus. The central zone of every lobule is occupied by reticulo-epithelial cells and lymphocytes. The reticulo-epithelial cells of the

medulla are less fully branched. The epithelial cells of medulla form thymic corpuscles or Hassall's corpuscles. These corpuscles consist of epithelial cells tightly wound upon one another in a concentric pattern. The central cells become swollen, calcified, and necrotic. The corpuscle may become keratinized, resembling the epidermis. With age the corpuscles become larger and more prominent. The functions of thymus corpuscles are not known.

The development of T-lymphocytes within the thymus

T-lymphocyte precursors (II class) migrate to the thymus during embryonic development and some months after birth. At first, these cells appear under the capsule. Proliferation and differentiation of T-lymphocytes (class II and III) begin initially in this part of lobule. Reticulo-epithelial cells secrete thymosin and thymopoetin (specific factors for T-lymphocyte differentiation). In adults only lymphoblasts (IV class) are present under the capsule. Lymphoblasts then gradually turn into T-lymphocytes. These T-lymphocytes lie only within the cortex.

This differentiation results in the following subclasses of T-lymphocytes: T-killers, T-helpers, and T-suppressors. Each type of these lymphocytes has specific receptors.

This development of T-lymphocytes was termed antigen-independent proliferation and differentiation. T-lymphocytes of the cortex cannot contact with an antigen due to the presence of the blood-thymic barrier in the cortex. This barrier consists of endothelial cells of capillary, endothelial basement membrane, perivascular connective tissue sheath containing many macrophages and reticulo-epithelial cells, the basement membrane of reticulo-epithelial cells, and the sheath of reticulo-epithelial cells.

As T-cells mature and move deep into the cortex, more than 90 to 95% of them die. Macrophages will phagocytose only T-lymphocytes that are confused about self and nonself. If this population of T-cells remains in the thymus, it would cause an autoimmune disease. Thus, only 5 to 10% of T-lymphocytes leave the thymus. These T-cells are mature, but innocent or virginal. They migrate to the peripheral organs of the immune system (spleen, lymph nodes, appendix, etc.), where lymphocytes encounter an antigen.

After this antigen stimulation, antigen-dependent proliferation and differentiation of T-lymphocytes occur in the peripheral organs of the immune system.

The thymus reaches its greatest weight at puberty followed by its slow atrophy or age involution. It involves two distinct processes: (1) fatty infiltration and (2) T-lymphocyte decrease (the lobules atrophy, and the septae widen). Although there is considerable age involution, the thymus remains a weighty functional organ. This normal process of slow thymic involution associated with ageing should be distinguished from acute thymic involution or accidental involution. This involution may occur in response to severe disease or stress. During stress many corticosteroids appear in the bloodstream. These hormones induce the lysis of immature T-cells.

Functions of the thymus

1. Secretion of thymosin and thymopoetin. These hormones stimulate T-cell differentiation and maturation.
2. Antigen-independent proliferation and differentiation of T-lymphocytes.

Lecture 19

Peripheral Organs of Hemopoiesis and Immunogenesis (V.L. Goryachkina)

T-lymphocytes and B-lymphocytes leave the thymus and the red bone marrow and migrate to the peripheral organs of hemopoiesis and immunogenesis (lymph nodes, spleen, tonsils, appendix and other lymphatic nodules, which are located in the wall of the alimentary canal, respiratory passages, and the genitourinary tract) for final differentiation. T- and B-lymphocytes circulate through these organs so that they can come into contact with antigens.

After this encounter with the antigens, B-lymphocytes will transform into:

(1) immunoblasts. The immunoblasts proliferate and differentiate into plasma cells. These cells contain well-developed rER. Their function is to synthesize antibodies, namely, immunoglobulins (Ig). Some activated cells become dormant and remain as the so-called memory cells. (2) memory cells (they are not involved in the initial or primary response). These cells are able to respond more quickly to the next encounter with the same antigen. Thus, memory cells participate in the secondary response. This response of B-lymphocytes to the antigen was termed humoral response leading to antibody-mediated immunity.

T-lymphocytes that have been activated by the interaction with antigen transform into lymphoblasts that proliferate and differentiate to effector T-lymphocytes and memory cells. This response

of T-lymphocytes to the antigen is known as cell-mediated immune response, leading to cell-mediated immunity. It should be noted that T-lymphocytes have cell surface receptors, which recognize specific antigens. The T-cell receptors have variable regions which, like antibodies, can bind to different antigens. There are two types of resulting T-cell receptors (TCR) termed TCR-1 and TCR-2. TCR-2+cells account for about 90% of lymphocytes in the blood. TCR-2+cells can be divided (owing the presence of specific markers) into three groups: (1) helper cells or TH-cells, (2) cytotoxic (killer) or TC-cells, and (3) T-suppressor cells or TS-cells. TH-cells are responsible for the transformation of immunoblasts into plasma cells. TC-cells are able to kill target cells. TS-cells are capable of inhibiting the response to TH-cells. TCR-1+cells are abundant in mucosa-associated lymphoid tissue (MALT) and perform cytotoxic function. Activated T-cells also secrete cytokines (lymphokines), which mediate interactions between cells.

These two processes, namely, humoral response leading to antibody-mediated immunity and cell-mediated immune response leading to cell-mediated immunity that take place after an encounter of T- and B-lymphocytes with an antigen, received another name, namely, antigen-dependent proliferation and differentiation of T- and B-cells. The latter takes place only in the peripheral organs of hemopoiesis and immunogenesis.

Lymph nodes

Lymph nodes are encapsulated organs. The capsule is composed of dense connective tissue and only a few smooth muscle cells. From this capsule trabeculae extend into the substance of the node.

The lymph node stroma consists of reticular tissue. It includes reticular cells and fibers. These branched cells contain well-developed rER, so their function is to produce the ground substance and collagen (like fibroblasts). But reticular cells produce type III collagen. That is why the reticular fibers are very thin and can be seen only with special staining. Reticular tissue is the supporting tissue for lymphocytes, macrophages, and plasma cells.

It should be noted that several types of macrophages are present within lymph nodes:

(1) usual macrophages, which perform the following functions:

(a) elimination of the antigen-antibody complex and (b) secretion of lymphokines (soluble substances released by sensitized lymphocytes and macrophages);

(2) special macrophages. They were called antigen-presenting cells. There are two types of antigen-presenting cells: (a) follicular dendritic cells (FDC) whose function is to present information to B-lymphocytes and (b) interdigitating cells (IDC) that present information to T-lymphocytes, especially to T-helper cells.

A bean-shaped lymph node has a hilum into which blood vessels enter. Afferent lymphatic vessels enter the node, penetrate the capsule, and drain into subcapsular, peritrabecular, and medullary sinuses. The efferent lymphatic vessel leaves the node together with the vein. The sinuses are filled with reticular cells and macrophages. Every sinus is lined with endothelial cells.

The lymph node contains three functional compartments: a network of endothelium-lined sinuses; a network of small blood vessels where circulating lymphocytes enter the node; a parenchymal compartment, which is divided into the cortex, paracortex, and medulla.

Cortex

The most prominent structures in the cortex are the lymphoid follicles or nodules. The lymphoid nodules that consist of uniform tightly packed small lymphocytes are called primary nodules. These nodules contain mainly naive B-cells and some memory cells. Other nodules contain a central zone of larger cell lymphoblasts. These cells have a pale nucleus and cytoplasm; that is why this center has been termed the light center. This center is termed the germinal center owing to the presence of lymphoblasts that proliferate. Nodules having a germinal center are called secondary nodules. The secondary nodules contain small naive B-cells peripherally and activated B-cells and macrophages in the germinal center.

Paracortex

The next compartment of lymph nodes is termed paracortex. This zone is called the thymus-dependent zone. It is filled with (a) T-lymphocytes, (b) macrophages, and (c) interdigitating cells. Interdigitating cells present information about the antigen to T-lymphocytes. After antigen stimulation, T-cells enlarge to form lymphoblasts. The latter proliferate to produce and differentiate to activated (effector) T-cells: T-killers, T-helpers, and T-suppressor cells. Additionally, memory T-cells are formed here as well.

Medulla

The medulla contains numerous medullary cords. Medullary sinuses are located between these cords. Medullary cords are composed of reticular cells, plasma cells, and their precursors (T-helper cells). The latter are the dominant cells here.

Interestingly enough, not only lymph but also lymphocytes constantly circulate through the lymph nodes. Some lymphocytes enter the node through the afferent lymphatic vessels (as a component of lymph), but more of them enter the node through the wall of postcapillary venules (they lie deep in the cortex). These venules have unusual (high) endothelium that allows lymphocytes to pass through the wall of a vessel. T-lymphocytes remain in the thymus-dependent zone, B-lymphocytes migrate to the node cortex.

Functions of lymph nodes

(1) Lymph filtration. Lymph nodes constitute extensive filtration beds. The reticular meshwork crisscrossing the sinuses acts as a mechanical filter. The flow in the lymphatic sinuses is quite slow. Lymph readily escapes from the sinuses. Macrophages lie in the sinuses and they can rapidly increase in number and become activated. The filtration efficiency is about 99%. The efficiency of filtration makes lymph nodes vulnerable. If they fail to destroy the infectious agents or malignant cells that they concentrate, the nodes become new foci and facilitate the spread of disease throughout the body.

(2) They take part in the immune response. Lymph nodes produce antibodies and are involved in cellular immunity.

Spleen

The spleen is surrounded by a capsule covered with the mesothelium. The capsule consists of dense connective tissue and contains smooth muscle cells. From the capsule the trabeculae (they contain numerous smooth muscle cells) extend into the substance of the organ. The splenic stroma consists of reticular tissue (similar to lymph nodes).

Red and white pulp

The comparison between lymph nodes and the spleen will reveal no division into zones. Lymphatic nodules are seen within the substance of the spleen. These nodules were termed white pulp, the rest of the spleen was termed red pulp. Why? If we make a fresh section of the spleen, we can observe white spheres that contain lymphocytes, i.e., white blood cells. The rest of the spleen will have the red colour owing to the presence of red blood cells. If we use hematoxylin and eosin for staining, we can see the violet staining of nodules due to the presence of lymphocytes. The red pulp that contains venous sinuses, reticular cells, macrophages, and all blood cells will stain violet with H and E, but the colour is less intense. It should be noted that the red pulp, except for the sinuses, is termed splenic cords. Splenic cords are a reticular network or a filtration bed – part of the vascular pathway – receiving blood from the arterioles and conveying it to the venous sinuses. Platelets, erythrocytes, and granulocytes are stored there. Splenic cords are populated by numerous macrophages. Splenic cords are believed to perform the function of removing particulate matter, aged or abnormal erythrocytes, and the blood platelets. Trapped cells are removed by the macrophages of sheathed capillaries and other parenchyma macrophages.

The white pulp has two components, each consisting of lymphocytes packed tightly into the filtration bed. One, the periarterial lymphatic sheath (PALS), is a cylinder through whose central axis runs the central artery (see below). The other consists of lymphatic nodules (LN) that lie within the PALS. The PALS stroma consists of reticular tissue. The latter constitutes the filtration bed that receives lymphocytes, macrophages and interdigitating cells. T-lymphocytes and plasma cells concentrate in the PALS, while B-lymphocytes, macrophages, and dendritic cells lie in lymphatic nodules. Hence, PALS may be considered to be a thymus-dependent zone similar to the paracortex of a lymph node. Splenic lymphatic nodules may become secondary nodules by developing germinal centers. The PALS is surrounded by less densely packed lymphocytes that constitute the marginal zone. The reticular cells making up the circumferential reticulum branch into the marginal zone.

Splenic circulation

The splenic artery branches and gives rise to trabecular arteries, which leave the trabeculae and enter the red pulp (pulp arteries). The pulp arteries become surrounded by the periarterial lymphatic sheath (PALS). The vessel within PALS was called the central artery. The latter gives off branches that perforate lymphatic nodules. These vessels are also called central artery. The central artery branches into 2 to 6 arterioles (called penicillar arterioles). These arterioles, in turn, give rise to capillaries. These capillaries have special arrangements of macrophages. They are described as ellipsoid sheathed capillaries. Most of these capillaries drain into the splenic parenchyma (splenic cords). Then blood (before returning to the circulation by entering the venous sinuses) will be exposed to the macrophages. Several sinuses then join to form pulp veins that drain blood into trabecular veins. This circulation was called open circulation. A small portion of capillaries drains into the marginal sinuses. The latter drain into the venous sinuses. This type of circulation was called closed circulation. This provides a system for blood to pass rapidly through the spleen without filtration.

Functions of the spleen

1. Destruction of aged or abnormal erythrocytes and platelets.
2. Filtration of blood from particulate matter, damaged and aged cells. It is noteworthy that macrophages phagocytose damaged and old red blood cells. These cells are broken down by the lysosomes of macrophages. The hemoglobin iron is retrieved and stored as ferritin. Transferrin (it is the blood plasma protein) transfers ferritin to the red bone marrow. The nurse cells of the red bone marrow seize this ferritin.
3. Production of antibodies.
4. Removal of antigen from the blood
5. Storage of plasma cells.
6. Storage of platelets in a ready reserve
7. Reservoir of blood.

Mucosa-associated lymphoid tissue (MALT)

In addition to lymph nodes and the spleen, the body contains lymphatic nodules, which are located in the walls of the gastrointestinal, respiratory, and urogenital tracts.

This tissue is known as a mucosa-associated lymphoid tissue (MALT). MALT provides immunological protection against invasion by pathogens.

The gut-associated lymphoid tissue (GALT) includes the palatine, lingual and pharyngeal tonsils (adenoids), mucosal nodules in the esophagus, Peyer's patches in the small intestine, and lymphoid nodules in the large intestine and appendix.

The bronchus-associated lymphoid tissue (BALT) is located in the bronchial wall.

Lecture 20

Endocrine System – I (S.L. Kuznetsov)

The endocrine system is made up essentially of endocrine organs and cells that produce secretions, which are passed directly into blood. It follows that endocrine cells must lie in close apposition to blood capillaries or to sinusoids. The secretions of endocrine cells are called hormones. Hormones travel through blood to target cells whose function they may regulate. Some hormones act only on one organ or on one type of cell, while other hormones may have a wider range of effects. Along with the autonomic nervous system the endocrine organs coordinate and control the metabolic activities and the internal environment of the body.

Endocrine cells are distributed in three different ways.

Some organs are entirely endocrine in function. They are known as endocrine glands and traditionally included the hypophysis cerebri (or pituitary), the thyroid gland, the parathyroid glands, and the suprarenal (or adrenal) glands. Recent work suggests that the pineal gland should also be included in this group.

Groups of endocrine cells may be present in organs that have other functions. They include the islets of the pancreas, the interstitial cells of the testes, the follicles and corpora lutea of the ovaries. Hormones are also produced by some cells in the kidney, the thymus, and the placenta.

Isolated endocrine cells may be distributed in the epithelial lining of an organ. Such cells are seen most typically in the gut. Similar cells are also present in the epithelium of the respiratory passages. Recent studies have shown that cells in many other locations in the body produce amines that have endocrine functions.

Many of these amines also act as neurotransmitters or as neuromodulators. These widely distributed cells are grouped together as the neuroendocrine system or the APUD cell system.

Hypophysis cerebri

The hypophysis cerebri is also called the pituitary gland. It is suspended from the floor of the third ventricle (of the brain) by the so-called infundibulum and lies in a depression on the upper surface of the sphenoid bone.

The hypophysis cerebri is one of the most important and complex endocrine glands. It produces several hormones some of which profoundly influence the activities of other endocrine organs. Its own activity is influenced by the hypothalamus and by the pineal body.

The hypophysis cerebri is usually divided into an anterior part, the pars anterior; an intermediate part, the pars intermedia; and a posterior part, the pars posterior (or the pars nervosa).

The pars posterior contains numerous nerve fibers. It is directly continuous with the central core of the infundibular stalk, which is made up of nervous tissue. These two parts (pars posterior and infundibular stalk) are together known as the neurohypophysis. The area in the anterior part of the infundibulum is called the median eminence.

The pars anterior (which is also called the adenohypophysis) and the pars intermedia are both made up of cells having a direct secretory function.

Adenohypophysis (pars anterior)

It consists of cords of cells separated by fenestrated sinusoids. Several types of cells, responsible for the production of different hormones, are present.

Using routine staining procedures, the cells can be divided into chromophil cells, which have brightly staining granules in their cytoplasm; and chromophobe cells in which no granules are present. Chromophil cells are further classified as acidophil when their granules stain with acid dyes (like eosin or orange G) or basophil when the granules stain with basic dyes (like hematoxylin). Basophil granules are also PAS-positive. The acidophil cells are often called alpha cells, and the basophils are called beta cells.

Studies with the EM have shown that both acidophils and basophils can be divided into subtypes on the basis of the size and shape of the granules in them. These findings have been correlated with those obtained by immunofluorescence methods.

The following functional types of cells have been described.

Types of acidophil cells

1. Somatotrophs (somatotropes) produce the somatotrophic hormone (also called somatotropin, STH or growth hormone). This hormone controls body growth, especially before puberty.
2. Mammotrophs (or mammotropes) produce the mammotropic hormone (also called mammotropin, prolactin, lactogenic hormone, or LTH), which stimulates the growth and activity of the female mammary gland during pregnancy and lactation.

Types of basophil cells

1. Thyrotrophs (or thyrotropes) produce the thyrotrophic hormone (thyrotropin or TSH), which stimulates the activity of the thyroid gland.
2. Gonadotrophs (gonadotropes or delta basophils) produce two types of hormones, each type having a different action in the male and female:
 - (a) in the female, the first of these hormones stimulates the growth of ovarian follicles. It is, therefore, called the follicle-stimulating hormone (FSH). It also stimulates the secretion of estrogens by the ovaries. In the male, the same hormone stimulates spermatogenesis.
 - (b) in the female, the second hormone stimulates the maturation of the corpus luteum and the secretion of progesterone by it. It is called the luteinizing hormone (LH). In the male, the same hormone stimulates the production of androgens by the interstitial cells of the testes and is called the interstitial cell-stimulating hormone (ICSH).

According to some investigators, the two classes of hormones are produced by different cells, but other workers hold that the same cells can produce both hormones.

Chromophobe cells probably represent:

- (a) corticotrophs (or corticotropes), which produce the corticotrophic hormone (also called adrenocorticotropin or ACTH). This hormone stimulates the secretion of some hormones of the adrenal cortex;
- (b) stem cells, which give rise to new chromophil cells.

Pars intermedia

This part is poorly developed in the human hypophysis. In ordinary preparations the most common feature is the presence of colloid-filled vesicles. The cells of the pars intermedia produce the melanocyte-stimulating hormone (MSH), which causes increased pigmentation of the skin.

The secretion of hormones from the adenohypophysis is under control of the hypothalamus.

Neurohypophysis (pars posterior)

It consists of numerous unmyelinated nerve fibers, which are the axons of neurons located in the hypothalamus. Most of the nerve fibers arise in the supraoptic and paraventricular nuclei. Situated between these axons are supporting cells of a special type called pituicytes. These cells have long dendritic processes many of which lie parallel to the nerve fibers. The axons descending into the pars posterior from the hypothalamus end in terminals closely related to capillaries.

The pars posterior of the hypophysis is associated with the release into the blood of two hormones. One of these is vasopressin (also called the antidiuretic hormone or ADH). This hormone

controls reabsorption of water by kidney tubules. The second hormone is oxytocin. It controls the contraction of smooth muscle of the uterus and mammary glands.

It is now known that these two hormones are not produced in the hypophysis cerebri at all. They are synthesized in neurons located mainly in the supraoptic and paraventricular nuclei of the hypothalamus. Vasopressin is produced mainly in the supraoptic nucleus; oxytocin, in the paraventricular nucleus. These secretions pass down the axons of the neurons concerned through the infundibulum into the pars posterior. Here they are released into the capillaries of the region and enter the general circulation.

Blood supply of the hypophysis cerebri

The hypophysis cerebri is supplied with superior and inferior branches arising from the internal carotid arteries. Some branches also arise from the anterior and posterior cerebral arteries. The inferior hypophyseal arteries are distributed mainly to the pars posterior. Branches from the superior set of arteries supply the median eminence and infundibulum. Here they end in capillary plexuses from which portal vessels arise. These portal vessels descend through the infundibular stalk and end in the sinusoids of the pars anterior. The sinusoids are drained by veins that end in neighbouring venous sinuses.

Note that the above arrangement is unusual in that two sets of capillaries intervene between the arteries and veins. One of these is in the median eminence and the upper part of the infundibulum. The second set of capillaries is represented by the sinusoids of the pars anterior. This arrangement is referred to as the hypothalamo-hypophyseal portal system. The functional significance of this system is in control of the secretion of the adenohypophysis hormones.

The secretion of hormones by the adenohypophysis takes place under higher control of neurons in the hypothalamus that are situated near the median eminence and in the infundibular nucleus. The axons of these neurons end on the capillaries in the median eminence and in the upper part of the infundibulum. Different neurons produce special releasing factors (or releasing hormones) for each hormone of the adenohypophysis. These factors are released into the capillaries. Portal vessels arising from the capillaries carry these factors to the pars anterior of the hypophysis. Here they stimulate the release of appropriate hormones. Some factors inhibit the release of hormones. The synthesis and discharge of releasing factors by the neurons is under nervous control.

Pineal gland

The pineal gland (or pineal body) is a small piriform structure present in relation to the posterior wall of the third ventricle of the brain. It is also called the epiphysis cerebri.

The organ has a mass of cells and blood capillaries and nerve fibers. A distinctive feature of the pineal in such sections is the presence of irregular masses made up mainly of calcium salts (the so-called brain sand). The organ is covered by connective tissue (representing the pia mater) from which septa pass into its interior.

With the use of special methods (including silver impregnation, EM, histochemical techniques), the following facts are now known about the pineal gland.

1. The organ is made up mainly of cells called pinealocytes. Each cell has a polyhedral body containing a spherical oval or irregular nucleus. The cell body gives off long processes with expanded terminal buds that end on the wall of capillaries or on the ependyma of the third ventricle. The cell bodies of pinealocytes contain both granular and agranular endoplasmic reticulum, a well developed Golgi complex, and many mitochondria. The processes of pinealocytes contain numerous mitochondria. Apart from other organoids, the terminal buds contain vesicles in which there are monoamines and polypeptide hormones. The neurotransmitter gamma-aminobutyric acid (GABA) is also present.
2. The pinealocytes are separated from one another by neuroglial cells that resemble astrocytes in structure.
3. The nerve fibers present in the pineal are sympathetic (adrenergic, unmyelinated). The release of pineal secretions appears to require sympathetic stimulation.
4. The pinealocytes produce a number of hormones (indolamines or polypeptides). These hormones have an important regulating influence (chiefly inhibitory) on many other endocrine organs. The organs influenced include the adenohypophysis, the neurohypophysis, the thyroid, the parathyroids, the adrenal cortex and medulla, the gonads, and the pancreatic islets. The hormones of the pineal body reach the hypophysis both through the blood and through the CSF. Pineal hormones may also influence the adenohypophysis by inhibiting the production of releasing factors. The best known hormone of the pineal gland is the amino acid melatonin (so called because it causes changes in the skin colour in amphibians). Large concentrations of melatonin are present in the pineal gland. Considerable amounts of 5-hydroxytryptamine (serotonin), which is a precursor of melatonin, are also present. The presence of related enzymes has been demonstrated.

5. The synthesis and discharge of melatonin are remarkably influenced by exposure of animals to light, the pineal gland being most active in darkness. The neurological pathways concerned involve the hypothalamus and the sympathetic nerves. Because of this light-mediated response, the pineal gland may act as a kind of biological clock, which may produce circadian rhythms (variations following a 24-hour cycle) in various parameters.
6. It has often been stated that the pineal gland degenerates with age. The corpora arenacea were considered to be the signs of degeneration. Recent studies show that the organ does not degenerate with age. The corpora arenacea are now regarded as by-products of high secretory activity. It has been postulated that polypeptide hormones first exist in the form of complexes with a carrier protein called neuroepiphysin. When hormones are released from the complex, the carrier protein combines with calcium ions and is deposited as brain sand.

Lecture 21

Endocrine System – II (S.L. Kuznetsov)

Thyroid gland

The thyroid gland is covered by a fibrous capsule. Septa, extending into the gland from the capsule, divide it into lobules. On microscopic examination each lobule is seen as aggregation of follicles. Each follicle is lined by follicular cells that rest on a basement membrane. The follicle has a cavity with a homogeneous material called colloid (which appears pink in hematoxylin- and eosin-stained sections). The spaces between the follicles are filled by a stroma made up of delicate connective tissue in which there are numerous capillaries and lymphatic vessels. The capillaries lie in close contact with the walls of the follicles.

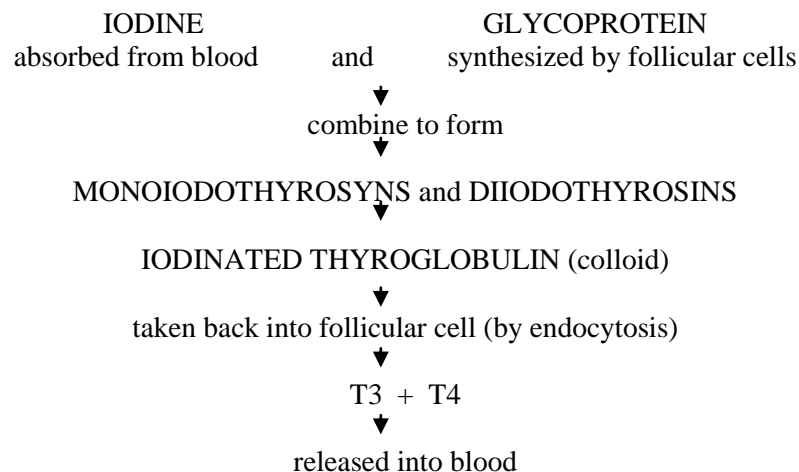
Apart from follicular cells, the thyroid gland has parafollicular cells, which are situated between the follicular cells and the basement membrane. They may also lie in the intervals between the follicles. Connective tissue stroma, surrounding the follicles, contains a dense capillary plexus, lymphatic capillaries, and sympathetic nerves.

The follicular cells vary in shape, depending on the level of their activity. Normally (at an average level of activity) the cells are cuboidal, and colloid in the follicles is moderate in amount. When the functional activity is low, the cells are flat (squamous) and the follicles are distended with abundant colloid. Lastly, when the cells are highly active, they become columnar and colloid is scanty. Different follicles may show differing levels of activity.

The follicular cells secrete two hormones that influence the rate of metabolism. Iodine is an essential constituent of these hormones. One hormone containing three atoms of iodine in each molecule is called triiodothyronine or T₃. The second hormone containing four atoms of iodine in each molecule is called tetraiodothyronine, T₄, or thyroxine.

The activity of follicular cells is influenced by the thyroid-stimulating hormone (TSH or thyrotropin) produced by the hypophysis cerebri.

The synthesis and release of the thyroid hormone take place in two phases. In the first phase, thyroglobulin is synthesized by granular endoplasmic reticulum and is packed into secretory granules in the Golgi complex. The granules travel to the luminal surface where they release thyroglobulin into the follicular cavity by exocytosis. Here the thyroglobulin combines with iodine to form colloid. Colloid is iodinated thyroglobulin.



Some steps in the formation of hormones by the thyroid gland

In the second phase, particles of colloid are taken back into the cell by endocytosis. Within the cell the iodinated thyroglobulin is acted upon by enzymes (present in lysosomes) releasing the hormones T3 and T4, which pass through the cell and are released into blood.

The parafollicular cells are also called C-cells, clear cells, or light cells. They are polyhedral, with oval eccentric nuclei. Typically, they lie between the follicular cells and their basement membrane. They may, however, lie between follicular cells, but they do not reach the lumen. In some species many parafollicular cells may lie in the connective tissue between the follicles and may be arranged in groups. With the EM, the cells show well-developed granular endoplasmic reticulum, Golgi complexes, numerous mitochondria, and membrane-bound secretory granules.

Parafollicular cells secrete the hormone thyrocalcitonin. This hormone has an action opposite to that of the parathyroid hormone on calcium metabolism. This hormone comes into play when the serum calcium level is high. It tends to lower the calcium level by suppressing the release of calcium ions from bone. This is achieved by suppressing bone resorption by osteoclasts.

Parathyroid glands

The parathyroid glands are so called, because they lie in close relationship to the thyroid gland. Normally, there are two parathyroid glands, one superior and one inferior, on either side; there being four glands in all.

Each gland has a connective tissue capsule from which some septa extend into the gland substance. Within the gland a network of reticular fibers supports the cells.

The parenchyma of the gland is made up of cells that are arranged in cords. Numerous sinusoids lie in close relationship to the cells.

The cells of the parathyroid glands are of two main types: chief cells (or principal cells) and oxyphil cells (or eosinophil cells). The chief cells are much more numerous than the oxyphil cells. With the light microscope, the chief cells are seen to be small cells with vesicular nuclei. Their cytoplasm is clear and either mildly eosinophil or basophil. In contrast, the oxyphil cells are much larger and contain granules that stain strongly with acid dyes. Their nuclei are smaller and stain more intensely than those of chief cells. Three types of chief cells (light, dark, and clear) have been described.

The chief cells produce the parathyroid hormone (or parathormone). This hormone tends to increase the level of serum calcium mainly by increasing bone resorption through the stimulation of osteoclastic activity and increasing calcium resorption from renal tubules.

With the EM, active chief cells are seen to have abundant granular endoplasmic reticulum and well-developed Golgi complexes. Small secretory granules are seen, specially in parts of the cytoplasm near the blood sinusoids. These features become much less prominent in inactive cells. Both active and inactive cells contain glycogen, which is much more abundant in the latter. In the normal parathyroid the number of inactive cells is greater than that of active cells. With the EM, it is seen that the granules of oxyphil cells are really mitochondria, large numbers of which are present in the cytoplasm. True secretory granules are not present.

The functions of oxyphil cells are unknown.

Suprarenal glands

As implied by their name, the right and left suprarenal glands lie in the abdomen, near the upper poles of the corresponding kidneys. In many animals they do not occupy a "supra" renal position, but lie near the kidneys. They are, therefore, commonly called the adrenal glands.

Each suprarenal gland is covered by a connective tissue capsule from which septa extend into the gland substance. The gland is made up of two functionally distinct parts: a superficial part called the cortex, and a deeper part called the medulla.

The volume of the cortex is about ten times that of the medulla.

The suprarenal cortex is made up of cells arranged in cords. Sinusoids lie between the cords. On the basis of the arrangement of its cells, the cortex can be divided into three layers as follows.

The outermost layer is called the zona glomerulosa. Here the cells are arranged in the form of inverted U-shaped structures. The zona glomerulosa constitutes the outer one-fifth of the cortex.

The next zone is called the zona fasciculata. Here the cells are arranged in straight columns, two cells thick. Sinusoids lie between the columns. This layer forms the middle three-fifths of the cortex.

The innermost layer of the cortex (the inner one-fifth) is called the zona reticularis. It is so called, because it is made up of cords that branch and anastomose with each other to form a kind of reticulum.

With the light microscope, the cells of the zona glomerulosa are seen to be small, polyhedral, or columnar with basophilic cytoplasm and deeply staining nuclei.

The cells of the zona fasciculata are large, polyhedral, with basophilic cytoplasm and vesicular nuclei.

The cells of the zona fasciculata are very rich in lipids, which can be demonstrated by suitable stains.

With routine methods the lipids are dissolved out during the processing of tissue, giving the cells an “empty” or vacuolated appearance. These cells also contain considerable amounts of vitamin C.

The cells of the zona reticularis are similar to those of the zona fasciculata, but the lipid content is less. Their cytoplasm is often eosinophilic.

With the EM, the cells in all layers of the cortex are characterized by the presence of agranular (or smooth) endoplasmic reticulum. The Golgi complex is best developed in the cells of the zona fasciculata. Mitochondria are unusual with tubular cisternae instead of the usual plates.

The cells of the zona glomerulosa produce the mineralocorticoid hormones (for example, aldosterone). These hormones influence the electrolyte and water balance of the body. The secretion of aldosterone is influenced by renin secreted by juxtaglomerular cells of the kidney. The secretion of hormones by the zona glomerulosa appears to be largely independent of the hypophysis cerebri.

The cells of the zona fasciculata produce the glucocorticoids (for example, cortisone and cortisol). These hormones have widespread effects, including those on carbohydrate metabolism and protein metabolism. They decrease antibody responses and have an anti-inflammatory effect.

The cells of the zona reticularis also produce some glucocorticoids (anabolic steroids). They also produce sex hormones, both estrogens and androgens.

Both functionally and embryologically the medulla of the suprarenal gland is distinct from the cortex.

Using the special chromaffin reaction, the medullar cells give a positive reaction and are called chromaffin cells. The cells of the suprarenal cortex do not give this reaction.

The medulla is made up of groups of cells. The cell groups are separated by wide sinusoids. The cells are polyhedral and have a basophilic cytoplasm. Functionally, the cells of the suprarenal medulla are considered to be modified postganglionic sympathetic neurons. Like typical postganglionic sympathetic neurons, they secrete noradrenaline (norepinephrine) and adrenaline (epinephrine) into the blood. This secretion takes place mainly at times of stress and results in widespread effects similar to those of stimulation of the sympathetic nervous system (e.g., an increase in the heart rate and blood pressure).

With the EM, the cells of the medulla are seen to contain abundant granular endoplasmic reticulum (in contrast to the agranular endoplasmic reticulum of cortical cells) and a prominent Golgi complex. The cells also contain secretory vesicles. In some cells, these vesicles are electron-dense, while in others they are not so dense. They contain noradrenaline, and the latter contain adrenaline.

The endocrine part of the pancreas

The pancreas is a gland that is partly exocrine and partly endocrine. The exocrine pancreas secretes enzymes that play a very important role in digestion.

The endocrine part of the pancreas produces two very important hormones, insulin and glucagon. These two hormones are also carried through the portal vein to the liver, where they have a profound influence on the metabolism of carbohydrates, proteins, and fats.

The endocrine part of the pancreas is in the form of numerous rounded collections of cells that are embedded within the exocrine part. These collections of cells are called the pancreatic islets, or the islets of Langerhans. The human pancreas has about one million islets. They are most numerous in the tail of the pancreas. Each islet is separated from the surrounding alveoli by a thin layer of reticular tissue. The islets are very richly supplied with blood through a dense capillary plexus. The intervals between the capillaries are occupied by cells arranged in groups or as cords. In ordinary preparations stained with hematoxylin and eosin, all the cells appear similar, but with the use of special procedures three main types of cells can be distinguished.

The alpha cells (or A-cells) secrete the hormone glucagon. They form about 20% of the islet cells.

The beta cells (or B-cells) secrete the hormone insulin. About 80% of the cells are of this type.

The delta cells (or D-cells) probably produce the hormone somatostatin.

The C-cells are the cambial part of the islets.

Apart from the four main types of cells described above, some other types are also present. These are the PP cells containing pancreatic polypeptide, and DI cells probably containing vasoactive intestinal polypeptide (or a similar amine). These cells of the pancreatic islets belong to the gastro-entero-pancreatic endocrine system. Pancreatic islets are richly innervated by autonomic nerves. Noradrenaline and acetylcholine released at nerve endings influence secretion by islet cells.

The APUD system (diffuse endocrine system)

Apart from the discrete endocrine organs, there are groups of endocrine cells located in various parts of the body. These cells have some common characteristics with each other and also with the cells of some endocrine organs. All these cells take up precursor substances from the circulation and process

them (by decarboxylation) to form amines or peptides. They are, therefore, included in what is called the amine precursor uptake and decarboxylation (APUD) cell system. These peptides or amines serve as hormones. Many of them also function as neurotransmitters. Hence, the APUD cell system is also called the diffuse endocrine system.

Some of the cells included in the APUD or diffuse endocrine systems also give a positive chromaffin reaction. They were earlier referred to as cells of the chromaffin system. However, they appear to be closely related functionally to other cells that are not chromaffin, and the tendency is to consider all these cells under the common category of diffuse neuroendocrine cells.

The diffuse endocrine system is regarded as the one representing a link between the autonomic nervous system, on the one hand, and the organs classically recognized as endocrine, on the other hand. The effects of the amines or peptides produced by the cells of the system are sometimes “local” (like those of neurotransmitters) and sometimes widespread (like those of better known hormones).

The list of cell types included in the APUD cell system, as well as of their secretions, is long.

1. The cells of the gastro-entero-pancreatic endocrine system. This system includes the cells of the pancreatic islets producing insulin, glucagon, and some other amines. It also includes endocrine cells of the epithelium of the stomach and intestines. They produce one or more of the following: 5-hydroxytryptamine, glucagon, dopamine, somatostatin, substance P, motilin, gastrin, cholecystokinin, secretin, vasoactive intestinal polypeptide (VIP), and some other peptides.
2. Glomus cells of the carotid bodies producing dopamine and noradrenaline.
3. Melanocytes of the skin produce promelanin.
4. Some cells in the pineal gland and the placenta, as well as modified myocytes of the heart, are called myoendocrine cells.

Lecture 22

Gastrointestinal Tract - I (S.L.Kuznetsov)

The gastrointestinal system is primarily involved in breaking down food for absorption into the body. This process has five main phases: ingestion, fragmentation, digestion, absorption, and elimination of waste products.

Ingestion and initial fragmentation of food occur in the oral cavity, resulting in the formation of a bolus of food, this is then conveyed to the esophagus by the action of the tongue and pharyngeal muscles during swallowing. Fragmentation and swallowing are facilitated by the secretion of saliva from three pairs of major salivary glands and numerous small accessory glands.

The esophagus conducts food from the oral cavity to the stomach where fragmentation is completed and digestion initiated. Digestion is the process by which food is enzymatically broken down into molecules, which are small enough to be absorbed into the circulation. Ingested proteins are first reduced to polypeptides. They are further degraded to small peptides and amino acids, which can then be absorbed.

In the large intestine water is absorbed from the liquid residue, which becomes progressively more solid as it passes towards the anus.

Food is passed along the gastrointestinal tract by two main mechanisms: voluntary muscular action in the oral cavity, pharynx and upper third of the esophagus and involuntary waves of smooth muscle contraction called peristalsis. Peristalsis and the secretory activity of the entire gastrointestinal system are modulated by the autonomic nervous system and a variety of hormones, some of which are secreted by the endocrine cells located within the gastrointestinal tract itself. These cells constitute a diffuse endocrine system called here the gastrointestinal endocrine system.

The wall of the oral cavity is made up partly of bone and partly of muscle and connective tissue (lips, cheeks, the soft palate, and the floor of the mouth). These structures are lined by mucous membrane. The mucous membrane is lined by stratified nonkeratinized squamous epithelium, which rests on connective tissue. Over the alveolar processes (where the mucosa forms the gums) and over the hard palate, the mucous membrane is closely adherent to the underlying periosteum. Elsewhere it is connected to the underlying structures by loose connective tissue. In the cheeks, this connective tissue contains many elastic fibers and much fat (specially in children).

Each lip has an “external” surface lined by skin and an “internal” surface lined by mucous membrane. The “external” surface of the lip is lined by true skin in which hair follicles and sebaceous glands are located. The internal substance of each lip (upper or lower) is predominantly muscular (skeletal muscle).

Tooth

A tooth consists of an “upper” part, the crown, which is seen in the mouth; and one or more roots, which are embedded in sockets in the bone (mandible or maxilla). The greater part of the tooth is formed by a bone-like material called dentin. In the region of the crown, the dentin is covered by a much harder white material called the enamel.

Over the root the dentin is covered by a thin layer of cementum. The cementum is attached to the wall of the bony socket by a layer of fibrous tissue that is called the periodontal ligament. Within the dentin there is a pulp canal (or pulp cavity), which contains a mass of cells, blood vessels, and nerves, which constitute the pulp.

The enamel is the hardest material in the body. It is made up almost entirely (96%) of inorganic salts. These salts are mainly in the form of complex crystals of hydroxyapatite (as in bone). The crystals contain calcium phosphate and calcium carbonate. The crystals of hydroxyapatite are arranged in the form of rod-shaped prisms, which run from the deep surface of the enamel (in contact with dentin) to its superficial (free) surface.

Dentin is a hard material that is made up basically of calcified ground substance in which there are numerous collagen fibers. The calcium salts are mainly in the form of hydroxyapatite. The inorganic salts account for 70% of the weight of dentin. Dentin is permeated by numerous fine canaliculi that pass radially from the pulp cavity towards the enamel (or towards cementum). These are the dentinal tubules. Each dentinal tubule contains a protoplasmic process arising from the cells called odontoblasts that line the pulp cavity.

The cementum may be regarded as a layer of true bone that covers the root of a tooth. It covers the entire dentin that is not covered by enamel. In some parts (specially towards the apex of the tooth) the cementum contains lacunae and canaliculi as in bone.

The lacunae are occupied by the cells similar to osteocytes (cementocytes).

Cementum is covered by a fibrous membrane called the periodontal ligament. The periodontal ligament fixes the tooth in its socket. It contains numerous nerve endings that provide sensory information.

The dental pulp is made up of very loose connective tissue. Delicate collagen fibers, connective tissue cells, numerous blood vessels, lymphatics and nerve fibers are present. The nerve fibers are partly sensory and partly sympathetic.

Each tooth may be regarded as a highly modified form of the stratified squamous epithelium covering the alveolar process. The thickening of epithelium grows downwards into the underlying connective tissue and enlarges to form an enamel organ. The enamel organ is invaginated (from below) by a mass of mesenchymal cells: these mesenchymal cells form the dental papilla.

As a result of this invagination the enamel organ becomes cup-shaped. The cells that line the inner wall of its cup-shaped lower end differentiate into columnar cells that are called ameloblasts. Mesodermal cells of the papilla become cuboidal and form an epithelium-like layer. The cells of this layer are odontoblasts. Odontoblasts are dentine-forming cells.

Ameloblasts are enamel-forming cells. Ameloblasts line the external aspect of the enamel and are removed by surface friction after the tooth erupts. The odontoblasts persist as a lining for the pulp cavity.

The tongue lies on the floor of the oral cavity. The substance of the tongue is made up chiefly of skeletal muscle supported by connective tissue. The muscle is arranged in bundles that run in vertical, transverse, and longitudinal directions.

The surface of the tongue is covered by the mucous membrane lined by stratified squamous epithelium. The epithelium is supported on a layer of connective tissue. The mucous membrane covering the anterior part of the dorsum of the tongue bears numerous projections or papillae. Each papilla consists of a lining of epithelium and a core of connective tissue. The epithelium over the papillae is partly keratinized.

The papillae are of various types. The most numerous papillae are small and conical in shape. They are called filiform papillae. The epithelium at the apexes of these papillae is keratinized.

At the apex of the tongue, and along its lateral margins, there are larger papillae with rounded summits and narrower bases. These are called fungiform papillae. Fungiform papillae bear taste buds. In contrast to the filiform papillae, the epithelium on fungiform papillae is (as a rule) not keratinized.

The largest papillae of the tongue are called circumvallate papillae. Taste buds are present on the walls of this papillae.

The mucous membrane of the posterior (pharyngeal) part of the dorsum of the tongue has numerous rounded elevations that are quite different from the papillae described above. These elevations

are produced by collections of lymphoid tissue. These collections of lymphoid tissue collectively form the lingual tonsil.

Numerous mucous and serous glands are present in the connective tissue of the tongue.

Salivary glands

There are the parotid, submandibular, and sublingual glands and numerous small glands in the mucous membrane of the lips (labial glands), cheeks (buccal glands), tongue (lingual glands) and palate (palatine glands). The secretions of these glands help to keep the mouth moist and provides a protective and lubricant coat of mucus. The digestive enzyme ptyalin, is also present.

Salivary glands are compound tubulo-alveolar glands. Their secretory elements (end pieces or the portio terminalis) may be rounded (acini), pear-shaped (alveoli), tubular or a mixture of these (tubuloacinar, tubuloalveolar). The secretory elements lead into a series of ducts through which their secretions are passed into the oral cavity. The secretory elements of the glands are supported by connective tissue, which divides the glands into lobules and forms capsules around them. The cells of secretory elements are usually described either as serous or mucous. In sections stained with hematoxylin and eosin, serous cells stain darkly (the colour varying from pink to dark purple). In contrast, mucous cells stain very lightly and, therefore, appear empty. The cells are in fact almost completely filled in by a mucoid material that stains very poorly.

An alveolus is typically made up entirely of serous cells or of mucous cells. However, in some cases mucous alveoli are covered (on one or more sides) by groups of serous cells that are arranged in the form of demilunes.

In the parotid gland, the alveoli are almost entirely serous. In the submandibular gland some alveoli are serous and some are mucous. The sublingual glands are made up predominantly of mucous alveoli, but a few serous demilunes may be present.

Myoepithelial cells are present in relation to the alveoli and the intercalated ducts of salivary glands. These cells lie between the epithelial cells and their basement membrane. The myoepithelial cells located on alveoli are often stellate and may form “baskets” around the alveoli. Myoepithelial cells are contractile, their contraction aiding in squeezing out secretion from alveoli.

The structure of the alimentary canal

The structure of the alimentary canal, from the esophagus up to the anal canal, shows several features that are common to all these parts. From the upper end of the esophagus up to the lower end of the anal canal the alimentary canal has the form of a fibromuscular tube. The wall of the tube is made up of four layers.

The innermost layer is the mucous membrane, which is made up of a lining epithelium; a layer of connective tissue, the lamina propria that supports the epithelium; and a thin layer of smooth muscle called the muscularis mucosae.

The mucous membrane rests on the layer of loose connective tissue called the submucosa.

Then there is a layer of muscle that surrounds the submucosa.

The serous layer or an adventitial layer covers the muscle layer.

Esophagus

The esophagus is a tube, whose wall has the usual four layers: mucous membrane, submucosa, muscle layer and adventitia. The esophagus does not have a serous covering, except over a short length near its lower end.

The mucous membrane of the esophagus shows several longitudinal folds that disappear when the tube is distended. The mucosa is lined by stratified squamous epithelium, which is normally not keratinized. At the upper and lower ends of the esophagus, some tubuloalveolar mucous glands are present in the lamina propria.

In the submucosa, the compound tubuloalveolar glands (esophageal glands proper) are located.

The muscle layer consists of the usual circular and longitudinal layers. The muscle fibers are partly striated and partly smooth. In the upper one-third of the esophagus the muscle fibers are entirely striated, while in the lower one-third all the fibers are smooth. Both types of fibers are present in the middle one third of the esophagus.

The circular muscle fibers present at the lower end of the esophagus could possibly act as a sphincter guarding the cardio-esophageal junction.

The muscle layer of the esophagus is surrounded by a layer of dense fibrous tissue that forms an adventitial coat for the esophagus. The lowest part of the esophagus is intraabdominal and covered by the peritoneum.

Lecture 23

Gastrointestinal Tract - II (S.L. Kuznetsov)

Stomach

The wall of the stomach has the four basic layers: a mucous membrane, a submucosa, a muscularis externa, and a serous layer.

The mucous membrane shows numerous folds (or rugae) that disappear when the stomach is distended.

The lining epithelium is columnar and mucus-secreting. The apical parts of the lining cells are filled with mucin. It is usually removed during tissue processing so that the cells look empty (or vacuolated). The mucus secreted by the cells of the lining epithelium protects the gastric mucosa against acid and enzymes produced by the mucosa itself. The lining epithelium dips into the lamina propria to form the depressions called gastric pits. These pits extend for a variable distance into the thickness of the mucosa. Deep to the gastric pits, the mucous membrane is packed with numerous gastric glands. These glands are of three types: the main gastric, cardiac, and pyloric glands.

The main gastric glands are present in the body of the stomach and in the fundus. The main gastric glands are simple or branched tubular glands that lie at right angles to the mucosal surface. The glands open into gastric pits, each pit receiving the openings of several glands. The gastric pits occupy the superficial one-fourth or less of the mucosa.

The most numerous cells in gastric glands are called chief cells, peptic cells, or zymogen cells. They are particularly numerous in the basal parts of the glands. The cells are cuboidal or low columnar. Their cytoplasm is basophilic. They secrete the digestive enzymes of the stomach including pepsin. With special methods the cells are seen to contain prominent secretory granules in the apical parts of their cytoplasm. The granules contain pepsinogen, which is a precursor of pepsin.

The cells (oxyntic or parietal) are large, ovoid, or polyhedral, with a large central nucleus. They are present singly among the peptic cells. They are more numerous in the upper half of the gland than in its lower half. They are called oxyntic cells, because they stain strongly with eosin. They are called parietal cells as they lie against the basement membrane. With the light microscope, they appear to be situated under buried chief cells. The EM shows, however, that each parietal cell has a narrow apical part that reaches the lumen of the gland. The cell membrane of this apical region shows several invaginations into the cytoplasm, producing intracellular canaliculi that communicate with the glandular lumen. The walls of the canaliculi have microvilli that project into the canaliculi. The cytoplasm is packed with mitochondria. Secretory granules are not present. Oxyntic cells are responsible for the secretion of hydrochloric acid. They also produce a factor, which combines with vitamin B12 (present in food) to form a complex necessary for normal formation of erythrocytes.

Near the upper end of the gland (or "neck") there are mucous-secreting cells that are called mucous neck cells. These are large cells with a clear cytoplasm. The nucleus is flattened and is pushed to the base of the cell by accumulated mucus. The chemical structure of the mucus secreted by these cells is different from that secreted by the mucous cells lining the surface of the gastric mucosa.

Near the basal parts of the gastric glands there are argentaffin cells containing granules that blacken when treated with appropriate solutions containing silver salts. They do not reach the lumen, but lie between the chief cells and the basement membrane. These cells probably secrete the hormone gastrin. Some of the cells can be shown to contain serotonin (5HT). These cells belong to the gastro-entero-pancreatic endocrine system.

The cardiac glands are situated in a small area near the opening of the esophagus. In this region, the mucosa is relatively thin. Gastric pits are shallow (as in the body of the stomach). The cardiac glands are either simple tubular or compound tubular-alveolar. They are mucus-secreting.

In the pyloric region of the stomach, the gastric pits are deep and occupy two-thirds of the depth of the mucosa. The pyloric glands, which open into these pits, are short and occupy the deeper one-third of the mucosa. They are simple or branched tubular glands. The glands are lined by mucus-secreting cells.

The mucous membrane of the stomach is packed with glands. The connective tissue of the lamina propria is, therefore, scanty. It contains the usual connective tissue cells. Occasional aggregations of lymphoid tissue are present in it.

The muscularis mucosae of the stomach is well-developed. Apart from the usual circular (inner) and longitudinal (outer) layers, an additional circular layer may be present outside the longitudinal layer.

The muscularis externa of the stomach is well-developed. Three types of layers – oblique, circular, and longitudinal (from inside out) – are usually described. The appearance of the layers in

sections is, however, highly variable, depending upon the part of the stomach sectioned. The circular fibers are greatly thickened at the pylorus where they form the pyloric sphincter. There is no corresponding thickening at the cardiac end.

Small intestine

The small intestine is a tube about five meters long. It is divided into three parts. These are (in craniocaudal sequence) the duodenum (about 25 cm long), the jejunum (about 2 m long), and the ileum (about 3 m long).

The wall of the small intestine is made up of the four layers: serous, muscular, submucous, and mucous. The serous and muscular layers correspond exactly to the description of the wall of the gastrointestinal tract. The submucosa is also typical, except in the duodenum, where it contains the glands of Brunner.

The surface area of the mucous membrane of the small intestine is extensive (to allow adequate absorption of food). This is achieved by:

- the length of the intestine,
- the presence of numerous finger-like processes or villi that project from the surface of the mucosa into the lumen,
- the presence of numerous depressions or crypts that invade the lamina propria,
- the presence of microvilli on the luminal surfaces of the cells lining the mucosa.

The villi are finger-like projections consisting of a core of connective tissue covered by a surface epithelium. The connective tissue core contains numerous blood capillaries forming a plexus. The endothelium of capillaries is fenestrated, thus allowing rapid absorption of nutrients into the blood. Each villus contains a central lymphatic vessel called a lacteal. The villi are the greatest and the most numerous in the duodenum. They progressively decrease in size and in number in proceeding caudally along the small intestine.

The crypts are tubular invaginations of the epithelium into the lamina propria. They are really simple tubular intestinal glands that are lined by the epithelium. The epithelium is supported on the outside by a basement membrane.

The epithelium, covering the villi and the areas of the mucosal surface between them, consists predominantly of columnar cells that are specialized for absorption. There are mucus-secreting goblet cells among the columnar cells. The crypts (intestinal glands) are lined mainly by undifferentiated cells that multiply to give rise to absorptive columnar cells and to goblet cells. The general characteristics of the crypts' columnar epithelium are the same as those of the columnar cells lining the mucous membrane of the small intestine.

Near the bases of the crypts there are Paneth cells that secrete enzymes and argentaffin cells.

A goblet cell looks like a drinking glass, which is broad above, and has a narrow stem attached to a base. Goblet cells are so named because of a similar shape. Each goblet cell has an expanded upper part that is distended with mucin granules. The nucleus is flattened and situated near the base of the cell. Goblet cells are mucus-secreting cells.

Undifferentiated cells are columnar cells and are present in the walls of intestinal crypts. They are similar to absorptive cells, but their microvilli are not so well-developed. The cytoplasm contains secretory granules. Undifferentiated cells proliferate actively by mitosis. The newly formed cells migrate upwards from the crypt to reach the walls of the villi. Here they differentiate either into typical absorptive cells or into goblet cells. These cells migrate towards the tips of the villi where they are shed off. In this way, the epithelial lining is being constantly replaced, each cell having a life of only a few days.

Zymogen cells (Paneth cells) are found only in the deeper parts of intestinal crypts. They contain prominent eosinophilic secretory granules. The function of zymogen cells is not well-known. They are known to produce lysozyme, which destroys bacteria. They may also produce other enzymes.

Argentaffin cells. The term argentaffin is applied to cells that have granules in their basal part of cytoplasm that blacken when treated with a silver solution. Some of them also give a positive chromaffin reaction. They are, therefore, also called enterochromaffin cells. With the introduction of immunofluorescence techniques it has been demonstrated that these cells are of various functional types and contain many amines performing the endocrine function.

Apart from the small intestine, these cells are also present in the stomach, the large intestine, the pancreas, in the ducts of the liver, and in some other glands. All these cells are now grouped together under the term gastro-entero-pancreatic endocrine system. All these are included under the term APUD (Amine Precursor Uptake and Decarboxylation) cell system.

The duodenal glands are most numerous in the proximal part of the duodenum. They are few in the distal part. The secretions of the duodenal glands contain mucus, bicarbonate ions (to neutralize gastric acid entering the duodenum), and the enzyme that activates trypsinogen produced by the pancreas.

Lecture 24

Gastrointestinal Tract - III (S.L. Kuznetsov)

Large intestine Colon

The structure of the colon conforms to the general description of the structure of the gut.

The mucous membrane of the colon shows numerous folds. There are no villi. The mucosa shows numerous closely arranged tubular glands or crypts similar to those in the small intestine. The mucosal surface and the glands are lined with a columnar epithelium cells with a striated border. Their main function is to absorb water and electrolytes from the intestinal contents. Many columnar cells secrete mucus and antibodies (IgA). The antibodies provide protection against pathogenic organisms. Numerous goblet cells are present, their number increasing caudally. The mucus secreted by them serves as a lubricant that facilitates the passage of semisolid contents through the colon. Some argentaffin cells are seen.

The submucosa often contains fat cells. The fibers of the longitudinal part of muscle layers are collected to form three thick bands, the teniae coli. A thin layer of longitudinal fibers is present in the intervals between the teniae. The teniae are shorter in length than the other layers of the colon wall. This results in the production of sacculations (also called haustrations) on the wall of the colon.

The serous layer is missing over the posterior part of the ascending and descending colon. In many situations the peritoneum forms small pouch-like processes that are filled with fat. These yellow masses are called the appendices epiploicae.

Vermiform appendix

The structure of the vermiform appendix is similar to that of the colon, but has some differences. The appendix is the narrowest part of the gut. The longitudinal muscle coat is complete and equally thick all round. The teniae coli are not present. The submucosa contains a great number of lymphoid follicles, which may form in the submucosa a structure that looks like the tonsil. The crypts are poorly formed.

Rectum and anal canal

The structure of the rectum is similar to that of the colon, but in it a continuous coat of longitudinal muscle layer is present and there are no teniae and appendices epiploicae. The anal canal is part of the rectum. The mucous membrane of the upper 15 mm of the canal is lined with columnar epithelium. The mucous membrane of this part shows six to twelve longitudinal folds that are called the anal columns. The lower ends of the anal columns are united to each other by short transverse folds called the anal valves. The mucous membrane of the next 15 mm of the rectum is lined with nonkeratinized stratified squamous epithelium. This region has no anal columns. The lowest 8 to 10 mm of the anal canal are lined with true skin in which hair follicles, sebaceous glands, and sweat glands are present. Above each anal valve there is a depression called the anal sinus. Atypical sweat glands open into each sinus. They are called the anal glands.

The anal canal is surrounded by circular and longitudinal layers of muscle continuous with those of the rectum. The circular muscle is thickened to form the internal anal sphincter. Outside the layer of smooth muscle, there is the external anal sphincter, which is made up of striated muscle.

Liver

The liver may be regarded as a modified exocrine gland that also has other functions. It is made up of liver cells or hepatocytes. Each hepatocyte is a large cell with a round nucleus. The liver substance is divisible into a large number of large lobes, each of which consists of numerous lobules. The exocrine secretion of the liver cells is called bile. Bile passes from liver cells into very delicate bile canaliculi that are present in intimate relationship to the cells. From the canaliculi bile enters into progressively larger ducts, which end in the bile duct. This duct conveys bile into the duodenum where it plays a role in the digestion of fat.

All blood draining from the stomach and intestines and containing absorbed food materials reaches the liver through the portal vein and its branches. Within the liver this blood passes through sinusoids and comes into very intimate relationship with liver cells. The liver is thus able to "screen" all substances entering the body through the gut. Some of them (e.g., amino acids) are used for the synthesis of new proteins needed by the body. Others (e.g., glucose, lipids) are stored in liver cells for subsequent

use; while harmful substances (e.g., drugs, alcohol) are detoxified. The portal vein also delivers blood from the spleen to the liver. This blood contains high concentrations of products formed by the breakdown of erythrocytes in the spleen. Some of these products (e.g., bilirubin) are used by the liver for producing bile, while some (e.g., iron) are stored for re-use in new erythrocytes.

In addition to the blood (deoxygenated) reaching the liver through the portal vein, the organ also receives oxygenated blood through the hepatic artery and its branches. The blood entering the liver from both these sources passes through the hepatic sinusoids and is collected by the different types of the hepatic veins. One such type runs through the centre of each lobule of the liver where it is called the central vein.

The central veins drain into hepatic veins, which leave the liver to end in the inferior vena cava.

The vessels in a portal triad usually give branches to parts of three lobules. The area of liver tissue (comprising parts of three hepatic lobules) supplied by one branch of the portal vein is regarded as the true functional unit of liver tissue and is referred to as a portal lobule (in distinction to the hepatic lobule described above).

The liver is covered with a connective tissue capsule (Glisson's capsule). This connective tissue extends into the liver substance through the portal canals where it surrounds the portal triads. The sinusoids are surrounded by reticular fibers. Connective tissue does not intervene between the adjoining liver cells.

Bile is secreted by the liver cells into bile canaliculi. These canaliculi have no walls of their own. They are spaces between the plasma membranes of two liver cells. The canaliculi form hexagonal networks around the liver cells. On the periphery of a lobule, the canaliculi become continuous with delicate intralobular ductules, which then become continuous with larger interlobular ductules of the portal triads. The interlobular ductules are lined with cuboidal epithelium. Some smooth muscle is present in the walls of larger ducts.

The liver performs numerous functions. The liver acts as an exocrine gland for the secretion of bile. Liver cells take up numerous substances from the blood and also pour many substances back into the blood. The liver plays a prominent role in the metabolism of carbohydrates, proteins, and fats. Metabolic functions include the synthesis of the plasma proteins fibrinogen and prothrombin and the regulation of the blood glucose and lipids. The liver acts as a store for various substances including glucose, such as glycogen, lipids, vitamins, and iron.

The liver plays a protective role by detoxifying substances, including drugs and alcohol. Removal of bile pigments from the blood and their excretion in the bile is part of this process. The macrophages (Kupffer cells) lining the sinusoids of the liver have a role similar to that of other cells of the mononuclear phagocyte system. They are of particular importance, as they are the first cells of this system that come in contact with materials absorbed through the gut. They also remove damaged erythrocytes from the blood. During fetal life the liver is the centre for hemopoiesis.

Gallbladder

The gallbladder stores and concentrates bile. This bile is discharged into the duodenum when required. The wall of the gallbladder is made up of a mucous membrane, a fibromuscular coat, and a serous layer that covers part of the organ. The mucous membrane of the gallbladder is lined with a tall columnar epithelium with a striated border. The mucosa is highly folded. The folds are called rugae. The fibromuscular coat is made up mainly of connective tissue containing the usual elements. Smooth muscle fibers are present and run in various directions. The serous layer has a lining of mesothelium resting on connective tissue. Bile is concentrated by absorption of water at the luminal surface of the cell.

Pancreas

The pancreas is a gland that is partly exocrine and partly endocrine. The exocrine pancreas secretes enzymes that play a very important role in the digestion of carbohydrates, proteins, and fats. The endocrine part of the pancreas produces two very important hormones, insulin and glucagon.

The exocrine part of the pancreas is in the form of a serous, compound tubulo-alveolar gland. Its general structure is very similar to that of the parotid gland, but the two are easily distinguished because of the presence of endocrine elements in the pancreas.

The secretory elements of the exocrine pancreas are long and tubular, but they are usually described as alveoli as they appear rounded or oval in sections. Their lumen is small. The lining cells appear triangular in section and have spherical nuclei located basally. In sections stained with hematoxylin and eosin, the cytoplasm is highly basophilic (blue) in the basal part.

With the EM, the cells lining the alveoli show features that are typical of secretory cells. Their basal cytoplasm is packed with rough endoplasmic reticulum. A well-developed Golgi complex is present in the supranuclear part of the cell. Numerous secretory granules occupy the greater part of the cytoplasm

(except the most basal part). The secretory cells produce a secretion that contains numerous enzymes, including trypsinogen, chymotrypsinogen, amylase, etc.

In addition to secretory cells, the alveoli contain centroacinar cells that are located near the centre of the acinus (or alveolus). These cells really belong to the intercalated ducts, which are invaginated into the secretory elements.

From the intercalated ducts the secretions pass into larger, interlobular ducts. They finally pass into the duodenum through the main pancreatic duct and the accessory pancreatic duct.

The pancreas is covered with connective tissue that forms a capsule for it. The septa arising from the capsule extend into the gland, dividing it into lobules.

Lecture 25

Respiratory System (V.L. Goryachkina)

The respiratory system consists of a conducting portion and a respiratory portion. The conducting portion includes: the nasal cavities, nasopharynx, larynx, trachea, and bronchi. They undergo extensive branching. The terminal parts of branching are called bronchioles. The respiratory portion includes respiratory bronchioles, alveolar ducts, alveolar sacs, and alveoli. Collectively they constitute an acinus.

The structure of the conducting portion of the respiratory tract conforms to a general plan: the respiratory tract has four distinct layers: mucosa, submucosa, cartilaginous layer, and adventitia.

Mucosa (tunica mucosa)

Mucosa consists of three layers. The first layer is a pseudostratified ciliated columnar epithelium; the second layer, containing loose connective tissue, is called the lamina propria mucosa; the third layer is the lamina muscularis mucosa. The latter consists of a circular layer of smooth muscle cells.

The ciliated columnar epithelium is composed of the following cell types:

- ciliated cells. The luminal surface of each cell bears about 200 cilia and some microvilli; the cilia beat in the direction of the larynx, moving mucus and inspired dust particles to tussigenic zones.
- goblet cells. They produce mucus.
- basal cells. They are small, rest on the basement membrane, but are not in contact with the lumen. They form a stem cell population.
- intermediate cells. After division, some of the stem cells transform into intermediate cells. The latter transform into either ciliated cells or goblet cells.
- neuroendocrine cells. They are small cells that contain secretory granules;
- brush cells. They bear short, blunt microvilli. The basal part of these cells is in synaptic contact with nerve fibers. These cells were supposed to serve as chemoreceptors.
- Langerhans cells. They are antigen-presenting cells.

The peculiarity of the lamina propria mucosa is noteworthy. There are many elastic fibers, they have a longitudinal direction. Furthermore, there are many plasma cells beneath the epithelium. The lamina muscularis mucosa consists of a circular layer of smooth muscle cells.

Submucosa (tela submucosa)

The submucosa consists of loose connective tissue. Mixed glands are present in the submucosa. There are two types of serous cells: (a) cells with basophilic granules producing amylase and (b) cells with eosinophilic granules producing lysozyme.

Cartilaginous layer

The cartilage layer consists of hyaline cartilage (except larynx; it contains hyaline and elastic cartilage). In the trachea and the main bronchi this layer has a C-shaped hyaline cartilage. Extrapulmonary bronchi and segmental bronchi have cartilage plates. Small bronchi have no cartilage at all.

Adventitia

The adventitia of trachea and extrapulmonary bronchi is composed of loose connective tissue; that of intrapulmonary bronchi, of dense irregular connective tissue.

Upper respiratory tract

The external aspect of the nostrils is covered by epidermis, which extends for a short distance. Note that the epidermis is composed of a keratinized stratified squamous epithelium. But then this epithelium becomes a nonkeratinized squamous epithelium and eventually a pseudostratified columnar epithelium.

So the nasal cavity and the paranasal sinus cavities are lined with a pseudostratified ciliated columnar epithelium. The lamina propria contains numerous glands and vessels.

Inspired air is moistened by secretion of the glands and goblet cells. The mucus picks up the dust, and dirt is moved posteriorly through the nasopharynx by the action of the cilia. The mucous will then be swallowed or expectorated.

Note that the lamina propria of the nasal cavity contains a large number of thin-walled veins. Under normal conditions these veins are collapsed. However, under certain circumstances they can become distended with blood. This increases the thickness of the nasal mucosa, which renders breathing more difficult, and is commonly encountered in “stuffed up” nose. It is very interesting to note that in certain individuals erotic stimulation was associated with stuffed up nose, or sneezing, and even nosebleeds. In medical practice it is known that many, many years ago there lived a young man who sneezed whenever he saw a pretty girl.

The main function of the nasal cavity is to filter, warm and moisten inhaled air. MALT is present in the nasopharyngeal tonsils (adenoids). The roof of the nasal cavity is the site of olfactory mucosa, which includes bipolar olfactory neurons.

Larynx

The larynx is composed of mucosa, the cartilaginous layer, and adventitia. Mucosa is lined with pseudostratified columnar epithelium, except the true vocal cords. The latter are covered with stratified squamous nonkeratinized epithelium. The lamina propria contains many mixed glands. The lamina muscularis mucosa is absent. The cartilage layer is formed by irregularly shaped plates of hyaline and elastic cartilage.

The vocal folds (true folds) contain the vocal ligament to which the skeletal muscle fibers are attached.

The functions of the larynx are as follows. It conducts air, guards against entry of anything but air, and is involved in phonation.

Trachea

The mucosa is formed by two layers: ciliated epithelium contains different types of cells. Note numerous goblet cells. This epithelium rests on distinct basement membrane. The lamina propria contains numerous elastic fibers (longitudinal direction in arrangement). The lamina muscularis is absent, but some smooth muscle cells can be found there. Lymphatic nodules, plasma cells, and lymphocytes are present in the mucosa.

The submucosa contains mixed glands.

The cartilage layer is formed by an incomplete cartilage ring. There is a gap between the ends of the cartilage ring. This gap is filled with connective tissue ligament that is rich in elastic fibers and bundles of smooth muscle cells. This ligament linking the two cartilage ends prevents dilatation.

The adventitia is composed of loose connective tissue. It binds the trachea to adjacent structures.

Bronchi

Extrapulmonary bronchi have the same structure as the trachea. Intrapulmonary bronchi differ from the extrapulmonary ones. Intrapulmonary bronchi are subdivided into large, medial, and small bronchi.

Large bronchi are lined with a ciliated epithelium. It is similar in structure to the epithelium in the other parts of the conducting airways. The lamina propria is composed of loose connective tissue with many elastic fibers. The lamina muscularis is well-developed. It consists of a circular layer of smooth muscle cells. The submucosa contains mixed glands. The cartilage layer is formed by large plates of hyaline cartilage. The adventitia is formed by dense irregular connective tissue containing bronchial arteries and veins, lymphatic vessels, and nerve fibers.

Medial bronchi are lined with the a ciliated epithelium (similar to large bronchi) but with a decreasing number of goblet cells. The submucosa contains less mixed glands. The cartilage layer consists of discontinuous cartilage plates that become reduced in size as the bronchial diameter diminishes. The adventitia consists of dense irregular connective tissue.

Small bronchi are lined with ciliated columnar epithelium. Goblet cells decrease in number and gradually disappear. The lamina muscularis is well-developed (relative to the diameter of the bronchi). The submucosa and cartilage layer are absent. The adventitia consists of dense irregular connective tissue.

Terminal bronchioles are lined with a simple ciliated cuboidal epithelium. There are no goblet cells at all. Clara cells are found among ciliated cells, brush cells, and endocrine cells. Clara cells increase in number as ciliated cells decrease along the length of the bronchiole. Clara cells have many large mitochondria, abundant sER, and some secretory granules. Clara cells perform the following functions:

detoxification and the secretory function. They produce lipoproteins, which prevent adhesion of bronchioles, especially during expiration. Moreover, Clara cells produce some special proteins that inhibit the chemotaxis of fibroblasts. In some cases, when Clara cells cannot produce these specific proteins, the fibroblasts increase in number and secrete collagen and elastin fibers, which may result in interstitial fibrosis of the lung.

The wall of terminal bronchioles contain the lamina muscularis mucosa. It is formed by discontinuous layer of smooth muscle cells. The adventitia consists of loose connective tissue containing small branches of bronchial arteries, veins, lymphatic vessels, and autonomic nerve fibers.

It should be noted that the contraction of smooth muscle cells after death provokes the formation of longitudinal mucosal folds characteristic of intrapulmonary bronchi seen in cross sections.

Respiratory portion of the respiratory system

The functional unit of the lung is the acinus. It consists of respiratory bronchioles, alveolar ducts, and alveolar sacs.

Respiratory bronchioles are lined by cuboidal epithelium (ciliated cells, Clara cells; occasional brush cells, and endocrine cells are also found). The wall of respiratory bronchioles has many openings (or apertures) that lead to the alveoli. Since gas exchange occurs in the alveoli, these bronchioles were termed respiratory bronchioles. The wall of respiratory bronchioles consists of simple cuboidal epithelium (ciliated cells, predominant Clara cells, some brush cells, and endocrine cells), loose connective tissue, and some smooth muscle cells.

Alveolar ducts are elongated airways that have almost no walls. The distance between the openings is very very short. Numerous alveoli open into an alveolar duct. Smooth muscle cells form a ring at the peripheral border of the alveoli. Owing to these smooth muscle cells, we can see some knob-like structures on sections (they look like buttons).

The alveolar sac is a cluster of alveoli at the end of an alveolar duct.

Alveoli

Alveoli are air sacs, which are the main site of gas exchange. Alveoli are connected by an apertures to alveolar ducts, alveolar sacs, or respiratory bronchioles. Most alveoli open into the alveolar sac. The alveolus is lined with type I and type II pneumocytes (alveolar cells).

Type I alveolar cells are very thin squamous cells that are joined together by tight junctions. They contain scanty mitochondria and organelles. These cells take part in the formation of the air–blood barrier. This barrier consists of the following structures: (a) type I alveolar cells, (b) the basement membrane of epithelial cells, (c) the basement membrane of capillary endothelial cells, and (d) endothelial cells.

Type II alveolar cells occupy only 5 to 10 % of the alveolar surface area. These cells are cuboidal cells with numerous mitochondria. The cytoplasm is rich in sER and rER. They contain large lamellar bodies. The latter contain phospholipids, protein, and glycosaminoglycans. The contents of lamellar bodies are released into the alveolar space by exocytosis and form a special layer known as surfactant. The surfactant covers every alveolus owing to surface tension. The surfactant prevents collapse of the alveoli. There is some water and lipids between the surfactant and pneumocytes (type I alveolocytes). This layer is termed “hypophase” or “fluid phase.” Both the surfactant and hypophase compose the alveolar–surfactant complex.

Type II alveolocytes act as stem cell precursors for type I cells. If extensive destruction of type I cells occurs, type II cells will increase in size and number and turn into type I cells.

The alveoli are surrounded and separated from one another by thin loose connective tissue (the alveolar septum) that contains numerous blood capillaries. The elastic fibers are an important component of the alveolar wall. The presence of elastic fibers allows the lung to stretch to accommodate the inhaled air, and they allow air to be expelled from the alveoli by recoiling. Other connective tissue elements are found in interalveolar septa: fibroblasts, mast cells, plasma cells, leukocytes, and macrophages (alveolar macrophages). Macrophages are an important component of the defense system of the lung.

Alveolar macrophages phagocytose inhaled bacteria and particulate matter. As a rule, alveolar macrophages lie on interalveolar septa (interstitium). They can also be observed free in the alveolar space. They phagocytose inhaled debris (dust, carbon, bacteria). They also remove superfluous surfactant and secrete lysozyme, collagenase, elastase, and acid hydrolase. After phagocytosis, macrophages may enter the lumen of the respiratory and terminal bronchioles, where they either pass into lymphatic vessels (and, hence, become transported to regional lymph nodes) or adhere to ciliated epithelium, which is the first step on the mucus cilia escalator. This escalator carries them up to the main bronchi and trachea from which they are cleared in the mucus by coughing. But they may remain in the interstitium.

Lecture 26

Integumentary System: Skin and Its Appendages (V.L. Goryachkina)

The skin consists of two main layers: epidermis and dermis. The hypodermis is under the dermis.

The epidermis – the external surface of the skin – consists of a keratinized stratified squamous epithelium. The dermis consists of two layers: (1) the papillary layer and (2) the reticular layer. The papillary layer consists of loose connective tissue. The reticular layer consists of dense irregular connective tissue. The hypodermis contains a variable amount of adipose tissue and loose connective tissue.

The skin contains the following epidermal derivatives: hairs, sweat glands, sebaceous glands, mammary glands, and nails. The skin is the largest organ of the body, constituting almost one-sixth of the total body weight. It performs the following major functions:

- Protection. The skin provides protection against (a) ultraviolet light and mechanical, chemical, and thermal damage injury and (b) desiccation.
- Sensory function. The skin contains a variety of receptors for touch, pressure, pain, and temperature perception.
- The skin plays a role in thermoregulation. This function is associated with the presence of the receptors for temperature, sweat glands and a rich vascular network. The body is insulated to prevent heat loss by the presence of hairs and subcutaneous adipose tissue.
- Metabolic function. The skin takes part in the metabolism of some hormones and vitamins. Vitamin D is formed in the epidermis.
- The skin is the site of blood storage. There are many blood vessels in the skin.
- The skin takes part in the activity of the immune system. Keratinocytes have been shown to secrete some factors that stimulate pre-T-lymphocytes to migrate from the red bone marrow to the epidermis. Moreover, the keratinocytes secrete a thymus-like factor. The latter stimulates antigen-independent proliferation and differentiation of T-lymphocytes. Thus, it may be concluded that one of the functions of the epidermis is antigen-independent proliferation and differentiation of T-lymphocytes.

Epidermis

The epidermis consists of **five** layers:

1. Stratum basale (also called germinativum).
2. Stratum spinosum (or the prickle cell layer) – spinous layer.
3. Stratum granulosum (the granular layer).
4. Stratum lucidum.
5. Stratum corneum (the cornified layer).

I. The stratum basale is a germinal layer. It consists of cuboidal cells; they rest on the basement membrane. Note the features of this layer: (1) these cells contain mitochondria, many ribosomes and filaments that are composed of keratin. The filaments are aggregated in intracellular fibrils known as tonofibrils. They are firmly attached to the basal aspect of a cell by hemidesmosomes and to the surrounding cells by desmosomes. Most keratinocyte cell divisions occur within this layer. After division, a cell may remain in the basal layer (in G₀ phase) or move outward for differentiation.

II. The stratum spinosum. Cell division is followed by differentiation. The cells become larger and polyhedral in shape. This is the first feature of this layer. This layer contains numerous desmosomes. The latter look like prickles when observed with the light microscope. That is why this layer was termed the prickle cell layer. Note an increase in tonofibrils. The bundles of tonofibrils have different directions. Many of them are associated with desmosomes. In some disease states (e.g., Hayley-Hayley disease), the associations between tonofibrils and desmosomes are disturbed. Tonofibrils form aggregate masses instead of fibrillar arrays; desmosomes break down. These disorders lead to the appearance of many blisters on the surface of the skin. Beginning with the upper spinous layer, keratinocytes accumulate specific granules. They were termed Odland bodies, lamellar granules, or keratinosomes. The latter contain glycolipids and lysosomal enzymes.

III. The stratum granulosum consists of 3 to 5 rows of cells. It differs from the previous layer.

- (1) The cells of this layer become oval in shape.
- (2) The number of keratinosomes increases. The keratinosomes are situated not only in the cytoplasm but under the cell membrane, too. The content of the keratinosomes is then secreted by exocytosis into

the intercellular spaces of the upper portion of the stratum granulosum. The glycolipid coating of the membrane, containing acylglucosylceramide, forms the water barrier of the epidermis.

- (3) The tonofibrils form parallel bundles. It should be noted that keratinocytes of the stratum granulosum produce some proteins (e.g., filaggrin). Due to filaggrin, tonofibrils are arranged in parallel bundles. Under the light microscope, granules, which were termed keratohyaline granules, can be seen. Under the EM, these granules are seen to consist of tonofibrils, filaggrin, and ribosomes.
- (4) Keratinocytes produce some specific proteins (e.g., keratolinin and loricrin). These proteins line the inner surface of the cell membrane. As a result, the envelope becomes thicker.
- (5) Within the uppermost granular layer, keratinocytes undergo a sudden and dramatic transition: the lysosomes and keratinosomes release their enzymes. These enzymes destroy the nucleus and organelles, except the tonofibrils and the cell membrane. The tonofibrils consist of keratin, that is why they do not vanish. Keratolinin and other proteins prevent the destruction of the cell membrane. Thus, after such transition, the envelope becomes thick and the cell is filled only with keratin filaments.

IV. *The stratum lucidum* consists of anucleated cells that are devoid of organelles and filled with keratin.

V. *The stratum corneum* consists of anucleated cells. These cells are unusual in shape. Each cell has the shape of a flattened tetrakaidecahedron (14-sided polygons). The stratum corneum cells are packed together in interlocking columns. They adhere to each other firmly due to the presence of lipids (ceramids) in the intercellular space. What is the origin of these lipids? Let us consider the uppermost granular layer again. Keratinosomes situated near the cell membranes release their contents into the intercellular space by exocytosis. Owing to the presence of these lipids, the stratum corneum prevents the penetration of exogenous water and microorganisms and prevents the evaporation of endogenous water.

The final step in epidermal maturation is desquamation (removal of the scales). How do the epidermal cells (corneocytes) leave the uppermost layer of the stratum corneum? It is not known today. But it was supposed that there is an alteration of the lipids deposited between the uppermost layer cells. It was shown that lipids (ceramids) turn into cholesterol only after this desquamation takes place. In medical practice it is known as ichthyosis. The skin of a patient looks like fish scales, and there is no desquamation. It is difficult to treat this disease, because these patients have no special enzyme for converting ceramids to cholesterol.

This normal process of keratinization was termed orthokeratosis. At the department of dermatology you will learn that parakeratosis is a pathological process. In this case we can observe nuclei in the stratum corneum (e.g., in psoriasis).

In addition to keratinocytes, the epidermis contains melanocytes, Langerhans cells, and Merkel cells.

Melanocytes are situated in the stratum basale. Melanocytes arise in the neural crest and migrate to the epidermis. Melanocytes have numerous dendritic processes. These cells do not have desmosomal attachment to the adjacent keratinocytes. However, melanocytes adhere to the dermis by junctions similar to the keratinocyte–dermal junction. The main function of melanocytes is to produce melanin and to distribute it to keratinocytes. It is known that melanin is the pigment that protects the skin from ultraviolet light and the ionizing effect of electromagnetic radiation. Note that the formation and deposition of melanin occur within melanosomes. The melanosomes are membrane-bounded granules that carry the enzyme tyrosinase. Only after the fusion of tyrosinase with premelanosomes (the latter have no melanin) the formation of melanin-packed melanosomes or melanin granules takes place. Melanosomes are transferred to keratinocytes by phagocytosis.

Cutaneous pigmentation is controlled by hereditary, hormonal, and environmental factors. For example, melanocyte-stimulating hormone (MSH) causes hyperpigmentation by stimulating the formation of highly dendritic melanocytes and the transfer of melanosomes to keratinocytes; in pregnancy, estrogen and progesterone stimulate increased pigmentation of facial, abdominal, and genital skin, as well the areola and nipple of the breast.

Langerhans cells are intraepidermal macrophages. They were described in 1868 by the medical student Paul Langerhans. For about 100 years the scientists supposed that these cells belonged to nervous tissue. Approximately 30 to 40 years ago, it was established that these cells are macrophages. Monocytes leave the blood stream and migrate to the tissues. One of the ways of this migration is the migration to the epidermis, where the monocytes convert to macrophages. Langerhans cells have an irregularly indented nucleus and characteristic racket-shaped granules (the Birbeck granules). These cells have no desmosomes, tonofilaments, and melanosomes. Langerhans cells carry receptors for immunoglobulin (Fc) and complement (C3). Due to the presence of Fc and C3, Langerhans cells can present antigen directly to

T-lymphocytes. But one of the main functions of these cells is to organize the epidermal proliferative unit (EPU) or epidermal pillar. One Langerhans cell is associated with 10 to 15 basal keratinocytes, 10 to 15 spinous keratinocytes, and some cells of the stratum granulosum. Langerhans cells control the proliferation and differentiation of keratinocytes due to secretion and accumulation of some special factors (e.g., one of them is epinephrine, an inhibitor of proliferation). The Langerhans cells are supposed to stimulate keratinization: they release some factors for the disruption of lysosome and keratinosome membranes. It was shown under experimental conditions that the destruction of Langerhans cells leads to parakeratosis, i.e., the appearance of nuclei in the stratum corneum.

Merkel cells are located in the stratum basale. Since these cells have intermediate (keratin) filaments in the cytoplasm, it was concluded that Merkel cells are epithelial cells. Merkel cells are bound to keratinocytes by desmosomes. The main feature of these cells is the presence of neurosecretory granules that are morphologically identical to the chromaffin granules found in the adrenal medulla. Merkel cells are associated with the terminal bulb of nonmyelinated nerve fiber. The combination of the terminal neuron and Merkel cell, called Merkel corpuscle, is a very sensitive mechanoreceptor.

Dermal–epidermal junction

The epidermis is attached to the dermis by the dermo-epidermal junction. This junction includes three components: (1) the basal cell plasma membrane with hemidesmosomes, (2) the basal lamina (or the basement membrane), which consists of the lamina lucida and the lamina densa, and (3) the connective tissue fibers below the basal lamina, which include anchoring fibrils, microfibril bundles, and collagen fibers. Note that the lamina lucida contains laminin (adhering glycoprotein), and the lamina densa is composed of collagen fibers (type IV) and heparan sulfate.

Functions of the dermo-epidermal junction:

- (1) to bind the epidermis and dermis;
- (2) to support the epidermis;
- (3) to prevent the transfer of the material and cells across the junction.

Note that in some skin diseases, when basal keratinocytes cannot produce laminin, the epidermis separates from the dermis; as a result, many blisters appear on the surface of the skin.

Dermis

The dermis consists of two layers: the papillary layer and the reticular layer.

The papillary layer consists of loose connective tissue. This layer was termed the papillary layer, because the connective tissue papillae extend up into the epidermis. Note that the papillae are complementary by what appears to be similar to epidermal protrusions called epidermal ridges or rete ridges. The epidermal ridges can be seen with the naked eye. These ridges form a distinctive pattern that is determined by hereditary factors. The papillary layer has a rich blood supply. One group of capillaries extends into the papillae; these capillaries provide nourishment for the epidermis and are also involved in heat regulation. Another group forms a flat bed below the basis of papillae.

The reticular layer consists of dense irregular connective tissue. This layer was called reticular, because bundles of collagen and elastic fibers form net-like structures. This network varies in character and thickness with a body region. The mechanical properties of this layer depend on the extensible elastic fibers interwoven in the mesh of rather rigid collagen fibers. The orientation of collagen and elastic fibers varies from area to area. The pattern of their orientation gives rise to certain lines of extensibility, namely, Langer's lines (named after the German physician who was the first to describe them). The direction of these tension lines can be demonstrated by removing a round piece of skin and observing the resultant elliptical hole. The reticular layer of the dermis contains two vascular plexuses: (1) a deep vascular plexus in the lower reticular dermis close to its border with the hypodermis and (2) a superficial vascular plexus in the upper reticular dermis close to its border with the papillary layer.

In addition to connective tissue, the reticular layer contains the epidermal appendages (hair, sweat and sebaceous glands, vessels, lymphatics, and nerves). The skin appendages are supplied with branches from vessels connecting the deep and superficial vascular plexuses. Differences between thin and thick skin

The thin skin covers all of the body, except for the palms of the hands and the soles of the feet. The surface of the thin skin, unlike that of the thick skin, is not thrown into ridges and grooves. The epidermis of the thin skin is thinner than the epidermis of the palms and feet. It has fewer layers than the thick skin. The stratum basale is similar to that of the thick skin, but the stratum spinosum is thinner. The stratum granulosum is thinner, too. The stratum lucidum is absent, and the stratum corneum is relatively thin in the thin skin. The thin skin contains sweat glands, but they are not as numerous as in the thick skin. The thin skin contains hair follicles, sebaceous glands, and smooth muscle cells (the arrector pili muscle).

Skin appendages

Skin appendages are derived from the downgrowth of the epidermal epithelium during development. They include hair follicles, sebaceous and sweat glands, and nails.

Sweat glands. There are two types of sweat glands: eccrine and apocrine glands.

Eccrine sweat glands

In humans, the major source of evaporative heat loss is through eccrine sweat glands. Sweat is a hypotonic watery solution containing various ions, particularly sodium, potassium, and chloride ions. These glands are found over the body; they are particularly numerous on the forehead, scalp, axillae, palms and soles but absent on the glans penis, clitoris, and labia minora. The eccrine gland is a tubular structure consisting of ductal and secretory segments. The secretory portion is present in the deep dermis and consists of a coil. Two distinct eccrine secretory cells are recognized: clear cells and dark cells. These cells form the inner layer of the secretory segment. The outer layer consists of myoepithelial cells (contractile cells). The duct is subdivided into dermal and epidermal portions. The dermal duct consists of two layers of dark-staining cuboidal cells. The epidermal duct becomes coiled and consists of flattened cells.

Apocrine sweat glands

These glands are located in special areas: the axillae and anogenital areas. Modified apocrine glands are found in the eyelids (Moll's gland), in the areolar skin around the nipple, and in the external auditory canal. Here they form the seruminous glands responsible for the protection of ear wax.

The apocrine gland is a tubular gland, like the eccrine gland. It consists of a secretory coil and a more or less straight duct, which opens into the pilosebaceous unit usually above the entrance of the sebaceous gland. The secretory segment is composed of (1) cuboidal single-layer epithelium and (2) myoepithelial cells. The duct consists of a double layer of cuboidal cells.

The apocrine secretion contains proteins, carbohydrates, ammonia, lipids, ferric ions, and fatty acids. The function of the apocrine glands has not been established.

Sebaceous glands

Sebaceous glands consist of lobular secretory portions and a ductal portion that empties into the upper hair follicle. The secretory portion consists of one type of cells – sebocytes. Between these sebocytes one can distinguish basal cells, secretory cells, and broken cells. Basal cells rest on the basement membrane and serve as the source of secretory cells. Secretory cells accumulate sebum vesicles until the cytoplasm is filled; at this point the cell breaks down and releases its contents into the duct (holocrine secretion). Sebum consists of glycerides and fatty acids, but wax esters and squalene are also present. Sebum is believed to be secreted continuously. The activity of sebaceous glands is controlled by androgens (is stimulated) and inhibited by estrogens.

The number, size, and activity of sebaceous glands vary from site to site within the skin. They are particularly abundant on the face, scalp, ears, nostrils, vulva, and around the anus, but are absent on the soles and palms. In certain areas of the body, these glands do not empty into hair follicles but open directly onto the epidermal surface: the labia minora, the areolar skin around the nipple, the eyelids where they are known as Meibomian glands, the lips, and buccal mucosa (Fordyce spots).

Pilosebaceous apparatus

The pilosebaceous apparatus is made up of a hair follicle, its attached smooth muscle, a sebaceous gland, and, in specific regions, an apocrine gland.

Hair follicle

The hair follicle is composed of external and internal root sheathes, a follicular bulb with the germinal matrix (it gives rise to hair), and a dermal papilla, which consists of loose connective tissue. The follicle is surrounded by a connective tissue sheath to which the arrector pili muscle is attached. The outermost part of the hair follicle or the external root sheath represents a downward continuation of the epidermis. The internal root sheath arising from the cells of the bulb lateral to those forming the hair shaft consists of three layers. The hair consists of a medulla, cortex, and cuticle.

The hair length varies from region to region, because there are differences in the growth period and the growth rate of a hair follicle. All hair growth is cyclical. Three phases of the hair growth cycle are known: anagen, the growth phase; catagen, the regressing phase; and telogen, the resting phase. In the human scalp, the anagen phase varies from 2 to 6 years; the catagen phase, from 2 to 3 weeks; the telogen phase, from 3 to 4 months. After telogen, the old hair shaft sheds, and a new hair shaft appears.

Innervation of the skin

There are two types of nerve endings in the skin: free nerve endings and encapsulated endings. The most numerous nerve endings are free nerve endings. They are located in the epidermis and the

papillary dermis. They serve as thermoreceptors and nociceptors. Basket-like arrangements of free nerve endings surround hair follicles. They serve as mechanoreceptors.

Encapsulated nerve endings include Pacinian corpuscles, Meissner's corpuscles, and Ruffini endings. Pacinian corpuscles respond to pressure and vibrations; Meissner's corpuscles are touch receptors; Ruffini endings are mechanoreceptors.

Lecture 27

Urinary System (S.L. Kuznetsov)

The urinary system consists of the right and left kidneys, ureters, the urinary bladder, and the urethra.

Kidney

Each kidney has a convex lateral margin and a concavity on the medial side, which is called the hilum. The hilum leads into a space called the renal sinus. The renal sinus is occupied by the upper expanded part of the ureter, which is called the renal pelvis. Within the renal sinus the pelvis divides into two or three parts called major calices. Each major calyx divides into a number of minor calices. The end of each minor calyx is shaped like a cup. A projection of kidney tissue, called a papilla, fits into the cup.

Kidney tissue consists of an outer part called the cortex and an inner part called the medulla.

The medulla is made up of triangular areas of renal tissue that are called renal pyramids. Each pyramid has a base directed towards the cortex; and an apex (or papilla) which is directed towards the renal pelvis and opens into a minor calyx. Pyramids show striations that pass radially towards the apex.

The renal cortex consists of two parts. The tissue lying between the bases of the pyramids and the surface of the kidney forms the cortical lobules. This part of the cortex shows light and dark striations. The light lines are extensions of the pyramids into the cortex and are called medullary rays. The tissue, lying between the pyramids, is also a part of the cortex. This part constitutes the renal columns.

From the functional point of view the kidney may be regarded as a collection of numerous tubules that are specialized for the excretion of urine. Each tubule consists of an excretory part called the nephron and of a collecting tubule. The collecting tubules, draining different nephrons, join to form larger tubules called the papillary ducts (of Bellini), each of which opens into a minor calyx at the apex of a renal papilla. Each kidney contains one to two million nephrons.

Urinary tubules are held together by connective tissue. Blood vessels, lymphatics, and nerves lie in this connective tissue.

The nephron consists of a renal corpuscle (or Malpighian corpuscle) and a long complicated renal tubule. The renal corpuscle is a rounded structure consisting of a rounded tuft of blood capillaries called the glomerulus and a cup-like two-layer covering for the glomerulus called the glomerular capsule (or Bowman's capsule).

Between the two layers of the capsule there is a urinary space, which is continuous with the lumen of the renal tubule.

The renal tubule is divisible into several parts. Starting from the glomerular capsule, there are the proximal convoluted tubule, the loop of Henle consisting of a descending limb, a loop, and an ascending limb, and the distal convoluted tubule, which ends by joining a collecting tubule.

Renal corpuscles and the greater parts of the proximal and distal convoluted tubules are located in the cortex of the kidney. The loops of Henle and the collecting ducts lie in the medullary rays and in the substance of the pyramids.

The glomerulus is a rounded tuft of anastomosing capillaries. Blood enters the tuft through an afferent arteriole and leaves it through an efferent arteriole. The afferent and efferent arterioles lie close together at a point that is called the vascular pole of the renal corpuscle.

The glomerular capsule is a two-layer cup, the two layers of which are separated by the urinary space. The outer layer is lined by squamous cells. With the light microscope, the inner wall also appears to be lined by squamous cells, but the EM shows that these cells, called podocytes, have a highly specialized structure. The urinary space becomes continuous with the lumen of the renal tubule at the urinary pole of the renal corpuscle. This pole lies diametrically opposite the vascular pole.

The renal tubule is made up of the proximal convoluted tubule, the loop of Henle, and the distal convoluted tubule. The distal convoluted tubule ends by opening into a collecting tubule.

The descending limb, the loop itself, and part of the ascending limb of the loop of Henle are narrow and thin-walled. They constitute the thin segment of the loop. The upper part of the ascending limb has a larger diameter and a thicker wall and is called the thick segment.

The distal convoluted tubule has a short straight part continuous with the ascending limb of the loop of Henle and a convoluted part lying in the cortex. At the junction between the two parts, the distal tubule lies very close to the renal corpuscle of the nephron to which it belongs.

Along its entire length, the renal tubule is lined by a single layer of epithelial cells that are supported on a basal lamina.

The proximal convoluted tubules have a relatively small lumen. They are lined by cuboidal cells having a prominent brush border. The nuclei are central and euchromatic. The cytoplasm stains pink with hematoxylin and eosin. The basal part of the cell shows a vertical striation.

The thin segment of the loop of Henle is lined by low cuboidal or squamous cells. The thick segment of the loop is lined by cuboidal cells.

The distal convoluted tubules can be distinguished from the proximal tubules as they have a much larger lumen, the cuboidal cells lining them do not have a brush border, and they stain less intensely pink with eosin.

The smallest collecting tubules are lined by a simple cuboidal or columnar epithelium. Collecting tubules can be easily distinguished from convoluted tubules. Collecting tubules have larger lumina. In transverse sections, their profiles are circular in contrast to the irregular shapes of convoluted tubules.

In the renal corpuscle, water and various small molecules pass, by filtration, from the blood of the glomerular capillaries to the urinary space of the glomerular capsule. Theoretically, the barrier across which the filtration would have to occur, is constituted by the capillary endothelium, by the cells – podocytes, forming the visceral layer of the glomerular capsule, and by the glomerular basement membrane, which intervenes between the two layers of the cells named above.

The endothelial cells show numerous fenestrae or pores that are larger than pores in many other situations. The fenestrae are not closed by membrane. As a result, filtrate passes easily through the pores, and the endothelial cells do not form an effective barrier.

The podocytes are so called, because they possess foot-like processes. Each podocyte has a few primary processes that give the cell a star-shaped appearance. Each primary process terminates in numerous pedicels or end feet, which rest on the basal lamina. The cell body of the podocyte comes in contact with the basal lamina only through the pedicels. Between the areas of attachment of individual pedicels there are gaps in which the basal lamina is not covered by podocyte cytoplasm.

Filtration takes place through the basal lamina at these gaps, which are, therefore, called filtration slits. These slits are covered by a layer of fine filaments that constitute the glomerular slit diaphragm. From what has been said above it will be clear that the filtrate does not have to pass through the podocyte cytoplasm.

The cytoplasm of podocytes contains numerous mitochondria, vesicles, and filaments. In addition to the endothelial cells and podocytes, the renal corpuscle contains mesangial cells that are present around capillaries. These cells are believed to be phagocytic.

With the EM, the lining cells of the proximal convoluted tubules show microvilli on their luminal surfaces. The striae seen with the light microscope near the base of each cell are shown by EM to be produced by infoldings of the basal plasma membrane and by numerous mitochondria that lie longitudinally in the cytoplasm intervening between the folds. The presence of microvilli and the basal infoldings greatly increases the surface area available for transport.

The loop of Henle is also called the *ansa nephroni*. With the EM, the flat cells lining the thin segment of the loop of Henle show very few organoids, indicating that the cells play only a passive role in ionic movements across them. The thick segment of the loop of Henle is lined by cuboidal cells with short microvilli, numerous mitochondria, and deep folds of the basal plasma membrane.

The cells of the distal convoluted tubules have only a few small microvilli. The basal infoldings of plasma membrane are very prominent and reach almost to the luminal surface of the cell. This feature is characteristic of cells involved in the active transport of ions.

The cells of the collecting ducts do not have microvilli, or lateral infoldings of the plasma membrane. Very few organoids are present in the cytoplasm.

Water and various other molecules pass from blood into the urinary space of the glomerular capsule by the process of filtration.

The ultimate composition of urine leaving the kidneys depends upon these three processes of filtration, reabsorption, and secretion.

Selective reabsorption takes place mainly in the proximal convoluted tubules. The substances reabsorbed include water, glucose, amino acids, proteins of small molecular size, and various ions including sodium, chloride, phosphate, bicarbonate and calcium. Reabsorption is facilitated by the

presence of microvilli and foldings of the lateral and basal plasma membranes. Energy for the process is provided by the numerous mitochondria present.

Considerable quantities of sodium and chloride are reabsorbed through the distal convoluted tubules. When first formed, the glomerular filtrate is isotonic with blood. With the selective reabsorption of ions it tends to become hypotonic so that an osmotic gradient is created, which forces water out of the tubules.

A very large proportion of water in the glomerular filtrate is reabsorbed through the loops of Henle. This is possible because of the following factors. The spaces, surrounding the descending and ascending limbs of the loops of Henle, are surrounded by a tissue fluid, which is hypertonic. The hypertonicity is achieved by the active transport of chloride and sodium ions out of the ascending limbs of the loops into the surrounding space, but the flow of water is not allowed. This is the so-called countercurrent multiplier system.

The walls of the limbs of the loops of Henle are highly permeable to water. The permeability is controlled by the hormone aldosterone produced by the adrenal cortex. Because of this permeability water passively diffuses out of the loops into the surrounding space because of the osmotic gradient.

The absorption of water from the filtrate would be expected to make the filtrate hypertonic. However, this does not happen as the absorption of water is accompanied by the selective absorption of sodium and chloride by the cells of the ascending limb of the loop of Henle and the distal convoluted tubule. As a result, the filtrate entering the collecting ducts is in fact hypotonic. As the filtrate passes through the collecting ducts, it once more enters the hypertonic environment of the medulla. This hypertonic environment, combined with the high permeability of the collecting ducts to water, renders the urine hypertonic by the time it is poured into the renal pelvis.

The proximal and distal convoluted tubules add various substances to the glomerular filtrate. These include hydrogen ions, ammonia, creatinine and paraaminohippuric acid. Various drugs or their breakdown products are also excreted in this way.

Juxtaglomerular apparatus

A part of the distal convoluted tubule lies close to the vascular pole of the renal corpuscle, between the afferent and efferent arterioles. In this region, the muscle cells in the wall of the afferent arteriole are modified. They are large and rounded and have spherical nuclei. Their cytoplasm contains granules that can be stained with special methods. These are juxtaglomerular cells. The wall of the distal convoluted tubule is also modified at the site of contact with the arteriole. They are densely packed together and are columnar. These cells form the macula densa. The cells of the macula densa lie in close contact with the juxtaglomerular cells, they together forming the juxtaglomerular apparatus or complex.

The granules of the juxtaglomerular cells contain the enzyme renin. Renin acts on angiotensin, a substance present in blood, and converts it to angiotensin I. Another enzyme converts angiotensin I to angiotensin II. Angiotensin II increases blood pressure. The juxtaglomerular apparatus is a mechanism that controls the blood pressure by release of renin.

Interstitial cells of the kidney

These cells are present in the renal medulla. They lie in the connective tissue between collecting ducts. The long axis of each cell is placed at right angles to that of the ducts, the cells forming vertical piles. These cells are important, because they produce prostaglandins.

Ureters

The wall of the ureter has **three** layers: an outer fibrous coat, a middle layer of smooth muscle, and an inner lining of the mucous membrane.

The mucous membrane has a lining of transitional epithelium. It rests on a layer of fibrous tissue containing many elastic fibers.

The muscle layer has an inner layer and an outer spiral layer of smooth muscle. The layers are not distinctly marked off from each other. Some workers have reported that the musculature of the ureter is really in the form of a meshwork formed by branching and anastomosing bundles of muscle fibers.

The outer fibrous coat consists of loose connective tissue. It contains numerous blood vessels, nerves, lymphatics, and some fat cells.

Urinary bladder

The wall of the urinary bladder consists of an outer serous layer, a thick coat of smooth muscle, and a mucous membrane.

The mucous membrane is lined by transitional epithelium. The epithelium rests on a layer of loose fibrous tissue. There is no muscularis mucosae.

The muscle layer is thick. The smooth muscle in it forms a meshwork. Internally and externally the fibers tend to be longitudinal. In between them there is a thicker layer of oblique fibers. Contraction of this muscle coat is responsible for emptying of the bladder. That is why it is called the detrusor muscle. Just above the junction of the bladder with the urethra, the circular fibers are thickened to form the sphincter vesicae.

The serous coat lines part of the bladder and has the usual structure.

Urethra

The structure of the male and female urethra is the same. The wall of the urethra is composed of the mucous, submucous and muscular layers. In males, the prostatic urethra is surrounded by prostatic tissue; and the penile urethra by erectile tissue of the corpus spongiosum.

The mucous membrane consists of a lining epithelium that rests on connective tissue.

The submucosa consists of loose connective tissue.

Lecture 28

Male Reproductive System (T.V. Boronikhina)

The male reproductive system consists of the testes, the epididymes, the genital ducts (excurrent duct system), the accessory reproductive glands, and the external genitalia. The accessory glands include the seminal vesicles, the prostate, and the bulbourethral glands.

Testis (male sex gland, male gonad)

The testis functions to produce spermatozoa and to secrete the male sex hormones androgens, mainly testosterone.

The testis is an egg-shaped organ housed inside the scrotum. A thick connective tissue capsule – the tunica albuginea – covers each testis. On the testicular posterior surface, the capsule thickens and forms the mediastinum. Blood vessels, lymphatics, and the genital ducts pass through the mediastinum as they either enter or leave the testis.

Connective tissue septa project from the capsule inward the testis and divide it into approximately 250 lobules. Each lobule contains seminiferous tubules and intertubular connective tissue (interstitial tissue). The seminiferous tubules are responsible for spermatogenesis, whereas the interstitial tissue contains steroid-secreting cells and represents the endocrine part of the male gonad. Each seminiferous tubule within the lobule forms a loop and, because of its considerable length, is highly convoluted. Two free ends of the loop open into short straight tubules (the tubuli recti), which are the origin of the genital ducts. The straight tubules continue into anastomosing channels within the mediastinum called the rete testis. Only the seminiferous tubules are the sites of sperm production, the tubuli recti and the rete testis are intratesticular genital ducts. The extratesticular excurrent duct system is composed of the ductuli efferentes (about 12 to 15) that make up the epididymal head, the ductus epididymidis that constitutes the epididymal body and tail, the ductus deferens that fuses with the seminal vesicle ductus excretorius to form the ductus ejaculatorius. The latter enters the prostate to empty into the prostatic urethra.

Spermatogenesis

The spermatogenesis is a process of the sperm development. It includes four stages or phases: the stage of proliferation, stage of growth, stage of maturation, and stage of formation.

The stage of proliferation (spermatogonial phase) is represented by population of spermatogonia that mitotically divide and undergo initial differentiation. Human spermatogonia are typical diploid cells, which are classified into three types: Type A dark (Ad) spermatogonia are thought to be the stem cells, type A pale (Ap) spermatogonia and type B spermatogonia are committed spermatogonia. The stem cell divides to give rise to two daughter cells: one remains as a stem cell (Ad), while the other (Ap) is committed to the differentiation process that produces the sperm. Type Ap spermatogonia undergo several successive mitotic divisions increasing their progeny number. An unusual feature of committed spermatogonium division is that the daughter cells remain connected by a thin cytoplasmic bridge as a result of incomplete cytokinesis. The same phenomenon is characteristic of each subsequent mitotic and meiotic division, and eventually all offspring of a stem spermatogonium becomes connected with bridges to form a syncytium. These connections remain intact up to the last stages of spermatid maturation. It is believed that the syncytium is essential for synchronous development of each clone from an original Ap cell.

The stage (phase) of growth is represented by primary spermatocytes. They enter the meiosis, replicate their DNA (4c, 2n), and pass through the prophase of the first meiotic division, complex phase with conjugation, tetrad formation, and exchange of genetic material known as crossing-over. In fact, cell growth is not pronounced.

The stage (phase) of maturation includes the meiosis: secondary spermatocytes ($n, 2c$) appear after the first division, and early spermatids (n, c) result from the second meiotic division. In our textbook, the stage of growth and the stage of maturation are united and called the spermatocyte phase.

The stage of formation (spermatid phase, spermiogenesis) is represented by spermatids that differentiate into spermatozoa. Spermatids are haploid in DNA content and in chromosome number, but morphologically they are trivial cells containing a cytoplasm with the usual set of organelles. The haploid spermatids undergo the transformation process known as spermiogenesis that produces mature spermatozoa. The spermiogenesis includes four phases: the Golgi phase, the cap phase, the acrosome phase, and the maturation phase.

In the Golgi phase, the acrosomal granule appears in the Golgi apparatus. This granule is positioned above the nucleus and determines the anterior sperm pole. The centrioles migrate in the opposite direction to determine the posterior sperm pole. The proximal centriole remains near the nucleus, forming connecting piece of the sperm, and the distal centriole initiates the assembling of microtubules that constitute the sperm axonemal complex (nine peripheral doublets and a central doublet of microtubules).

In the cap phase, the acrosomal vesicle covers the anterior half of the nucleus and becomes condensed to form an acrosomal cap or acrosome. The acrosome contains enzymes (hyaluronidase, acid phosphatase, and trypsin-like protease) necessary for the penetration of the membranes covering the egg. The nucleus also becomes more condensed.

In the acrosome phase, the nucleus becomes most condensed and elongated. The mitochondria migrate to arrange helically around the axonemal complex in the middle piece of the sperm tail. The mitochondria provide sperm movements by energy. The principal piece of the sperm tail includes the axonemal complex surrounded by the fibrous sheath; the end piece consists of microtubules only.

In the maturation phase, the spermatids lose the excess of cytoplasm (a residual cytoplasm or residual body). The residual bodies are phagocytosed by the Sertoli cells; the intercellular bridges remain with the residual cytoplasm. Spermatozoa become individual cells; they are no longer attached to one another. Individualization completes spermatogenesis.

The spermiogenesis produces a structurally unique cell. The mature human spermatozoon is about $60\ \mu\text{m}$ long. Its head includes the nucleus and the acrosomal cap surrounded with a narrow cytoplasmic rim. Its tail is subdivided into the connecting piece, the middle piece, the principal piece, and the end piece. The short connecting piece contains a centriole and the origin of the coarse fibers. The middle piece contains the mitochondria helically wrapped around the coarse fibers and the axonemal complex. The principal piece contains the fibrous sheath external to the coarse fibers and the axonemal complex. The end piece contains only the axonemal complex.

Morphologically mature testicular spermatozoa are functionally immature, because they are not motile. They acquire capacity for motion after longer incubation in the epididymal channels. Nonmotile spermatozoa are carried from the testis with the testicular fluid by contractions of the seminiferous tubules.

There are specific associations of differentiating spermatogenic cell types. These associations occur, because intercellular bridges are present between the progeny of each stem spermatogonium; they undergo synchronous mitosis, meiotic divisions and differentiation. These cell associations are known as stages of the seminiferous epithelium cycle (there are 6 stages in the human cycle). The seminiferous epithelium cycle is the stage series that appears between two same stages at any tubule site. The seminiferous epithelium wave is the stage distribution along the tubule length. There are no waves in the human seminiferous epithelium.

Certain physiological conditions are essential for normal proceeding of spermatogenesis. Testosterone is necessary as the only hormone directly regulating almost all the stages of the sperm production; the androgen-binding proteins (ABP) from the testicular fluid provide a high testosterone concentration inside the seminiferous tubules.

Spermatogenesis requires the optimal temperature. The scrotum temperature is 2 to 3°C below the body temperature; this low temperature is essential for sperm production. Shortly before birth, the testes descend from the abdominal cavity into the scrotum. If the testes fail to descend into the scrotum (cryptorchidism), spermatogenesis does not begin.

Spermatogenic cells are in need of isolation from the immunocompetent cells. Spermatogenic cells (except spermatogonia) are recognized as foreign (not self, antigenic) by the immune system. Spermatogenic cells first appear at puberty long after the individual has become immunocompetent. The blood-testis barrier plays an essential part in spermatogenic cells isolating from the immune system.

Spermatogenesis includes two unique processes: meiosis and spermiogenesis. Due to their complexity these processes may give rise to mistakes and produce abnormal cells. Meiosis results in the formation of approximately 5% of abnormal cells; spermiogenesis, in 25%. Both the male and female reproductive systems possess cell populations to eliminate these abnormal cells.

Spermatogenic cells are very sensitive to noxious agents, such as dietary deficiencies, general or local infections, elevated testicular temperature, steroid hormones, pesticides, and radiation. Proliferating cells are particularly sensitive to these agents. Stem cells, which demonstrate low mitotic activity, are much less vulnerable than actively dividing and differentiating spermatogenic cells.

Seminiferous tubules

Seminiferous tubules consist of the seminiferous epithelium surrounded by the tunica propria. The central tubular cavity (lumen) is filled with the testicular fluid. The seminiferous epithelium is a cellular complex with stratified appearance including two populations of cells: spermatogenic cells, which regularly replicate and differentiate into mature sperm, and Sertoli cells (supporting or sustentacular cells) that do not undergo proliferation. In this complex, only Sertoli cells are true epithelial components, mesodermal by nature. The spermatogenic cells arising from the extragonadal embryonic origin – primordial germ cells (gonoblasts) – are not epithelial.

Sertoli cells are tree-shaped cells, their broad basal portions (trunks) rest on the basal lamina, their multiple apical and lateral processes (branches) extend through the full thickness of the seminiferous epithelium towards the lumen. The lower processes of the adjacent cells are bound to one another by an unusual junctional complex. The latter includes tight junctions, flattened sER cisternae parallel to the plasma membrane of each cell, and hexagonally packed actin filament bundles interposed between sER cisternae and the plasma membrane. The Sertoli–Sertoli junctions give structural organization to the tubules, because they establish two compartments in the seminiferous epithelium: a basal compartment, between the junctions and the basal lamina, and a luminal compartment, above the junctions. The basal compartment is easy to reach for substances entering the tubule from blood or lymph. The tight junctions block free access to the luminal compartment, and only selective transport of Sertoli cells creates its unique chemical composition, rich in androgens, but free from cholesterol, LH, and immunoglobulins. Thus, the luminal compartment manufactures the specific microenvironment for spermatogenic cell development.

Spermatogenic elements occupy both the basal and luminal compartments. Spermatogonia and early primary spermatocytes reside in the basal compartment. More mature and antigenic spermatocytes and spermatids are housed in the luminal compartment; meiosis and spermiogenesis take place here. In development, primary spermatocytes must pass through the junctional complex to gain the luminal compartment from the basal one. This displacement occurs through the formation of a transitional compartment: a new junctional complex between Sertoli cell processes appears beneath the newly formed spermatocytes, and then the junction above them breaks down to allow spermatocytes to reach the luminal compartment. This phenomenon maintains chemical and immunological homeostasis necessary for spermatogenesis.

The Sertoli cell cytoplasm contains a well-developed sER, an extensive rER, numerous mitochondria, a well-developed Golgi complex, and varying numbers of microtubules, lysosomes, lipid droplets, vesicles, glycogen granules, and filaments. The Sertoli cell nucleus is light, euchromatic, ovoid or triangular in shape, and with deep folds of karyolemma. Its shape and location vary. The nucleolus is present and may be complex in shape.

The appearance of the Sertoli cell nucleus and the organelle richness of its cytoplasm reflect the variety of cell functions. Sertoli cells support spermatogenic cells, provide tubular compartmentalization, and exchange metabolites between the tubular lumen and the circulatory system. They phagocytose and break down the residual bodies, eliminate abnormal spermatogenic cells, secrete the tubule fluid, and produce the ABP necessary for the high testosterone concentration to be attained in the seminiferous tubules. It is believed that Sertoli cells are involved in local regulation of spermatogenesis and, notably, of spermiogenesis. In addition, they possess endocrine capacity: Sertoli cells secrete inhibin, a protein hormone involved in the feedback loop that regulates FSH production by the adenohypophysis. These cells can metabolize all the steroids reaching the seminiferous tubules to testosterone and, partially, to estrogens. Sertoli cells themselves are under hormonal control: receptors for FSH and testosterone are found on their plasma membrane. Both FSH and testosterone stimulate Sertoli cell functions, FSH is believed to be essential for their secretory activity, notably, the ABP production.

The tunica propria (lamina propria) of the seminiferous tubules is a multilayered connective tissue structure disposed externally to the Sertoli cell basal lamina and including the amorphous ground substance, fibers, and cells. The tunica propria lacks typical fibroblasts; it contains the so-called myoid

cells (peritubular contractile cells) that are true highly modified myofibroblasts. These elongated cells are concentrically arranged in three or five layers with interposed collagen fibrils. Ultrastructurally, the myoid cells demonstrate features associated with smooth muscle cells: they are surrounded by their own basal lamina, their plasma membrane is bound to numerous pinocytotic vesicles, their cytoplasm contains large numbers of actin filaments. They also exhibit a significant amount of rER, a feature indicative of their role in collagen synthesis in the absence of typical fibroblasts. Rhythmic contractions of the myoid cells create peristaltic waves that help spermatozoa and the testicular fluid to move through the seminiferous tubules towards the duct system. Due to their border position, the myoid cells are involved in the selective transport of metabolites both into and out of the seminiferous tubules, which allows the peritubular cells, as well as the whole tunica propria, to be assigned to the essential components of the blood–testis barrier.

Leydig cells

Leydig cells (glandulocytes) are endocrine testicular cells located in the intertubular connective tissue. They are large, polygonal, and acidophilic cells arising from the mesenchyme. Their ultrastructure corresponds to the morphology of other steroid-secreting cells: their cytoplasm is rich in sER, Golgi apparatus, mitochondria with tubulovesicular cristae, and lipid droplets. The lipochrome pigment is frequently seen in these cells. They typically contain the crystals of Reinke, whose function is unknown.

In embryogenesis, Leydig cells differentiate early and secrete testosterone during fetal life. Androgens take part in the normal development of a male fetus; they influence the formation of the male reproductive organs and hypothalamic sex differentiation. At puberty, Leydig cells again differentiate into androgen-secreting cells and resume hormone production. In this period, androgens are responsible for sexual maturation, the initiation of spermatogenesis, secretion of the accessory sex glands, and development of the secondary sex characteristics. In the adult, the secretion of testosterone is essential for sperm production, the functional activity of the genital ducts and the male accessory glands, and the maintenance of secondary sex characteristics.

Like typical endocrine cells, Leydig cells are in contact with capillaries, but the testicular blood capillaries are narrow and of continuous type. Testosterone is primarily released into the testicular lymph. The testicular lymphatic capillaries are extraordinary: they are sinusoidal and surround seminiferous tubules like sheaths.

Blood–testis barrier

The blood–testis barrier is a structural complex disposed on the pathway of substances between the testicular blood and spermatogenic cells. It includes the capillary wall, the interstitial connective tissue, the lymphatic sinusoid, and the tunica propria of the seminiferous tubules, Sertoli cells and the Sertoli–Sertoli junctional complex. The blood–testis barrier provides the selective transport of metabolites and creates a specific microenvironment for sperm maturation. The ionic, amino acid, carbohydrate, and protein content in the fluid of the seminiferous tubules and the excurrent ducts considerably differs from the composition of the blood plasma and testicular lymph.

The blood–testis barrier maintains the hormonal balance and homeostasis in the seminiferous tubules: it blocks the access of cholesterol and LH, but provides the free transport of androgens and FSH. The levels of exocrine secretory products of the Sertoli cells, particularly the androgen-binding proteins (ABP), are high in the lumen. As testosterone is essential for normal maturation of the developing sperm, the ABP contributes to the testosterone concentration in the seminiferous tubule lumen.

The blood–testis barrier plays an essential role in isolating the spermatogenic cells from the immune system of an adult male. Spermatogenic cells (except spermatogonia) are recognized as antigenic by the immune system. That is the reason why, on the one hand, plasma immunoglobulins are excluded from the lumen of the tubules; on the other hand, the sperm antigens are prevented from reaching the systemic circulation. The damage to the blood–testis barrier (e.g., posttraumatic alteration) increases the barrier permeability and results in the development of the autoimmune reaction, causing the destruction of spermatogenic cells.

Regulation of the testis functions

The testes are adenohipophysis-dependent glands. Two gonadotropins – FSH and LH – possess target cells in the male gonads. FSH interacts with Sertoli cells and stimulates their functions, in particular, the secretory activity and ABP production. The protein hormone inhibin secreted by Sertoli cells provides a feedback loop with the adenohipophysis and inhibits FSH release. The testicular Leydig cells possess plasma receptors to LH that stimulate androgen synthesis by these endocrinocytes. The blood testosterone level takes part in negative feedback interaction with the pituitary gland and inhibits LH production.

Testosterone is the only hormone that directly regulates spermatogenesis. The testosterone transport through the blood–testis barrier and its sufficient concentration in the tubular lumen are provided by the high ABP level in the testicular fluid.

Prostate gland

The prostate is the largest accessory sex gland. It surrounds the proximal urethra. It is enclosed with a connective tissue capsule and consists of the prostatic glands, interglandular loose connective tissue, and smooth muscle bundles disposed in the stroma. The prostate contains 30 to 50 tubuloalveolar glands that are arranged in three concentric layers around the urethra: a mucosal layer, a submucosal layer, and the most peripheral layer containing the main prostatic glands. The glands empty into the urethra at the time of ejaculation by contraction of the prostatic smooth muscle cells. The muscles also serve as an additional urethral sphincter. The prostatic juice abounds in zinc ions, acid phosphatase, fibrinolysin, citric acid, and prostaglandins. The epithelium of the prostate is dependent on testosterone for normal morphology and function. The prostatic alveoli, especially in older men, often contain prostatic concretions. They are believed to be formed by precipitation of secretory material around cell fragments. They may become partially calcified.

Nodular hyperplasia occurs in the mucosal and submucosal glands and can lead to partial or total urethra obstruction. Prostate cancer usually develops peripherally, in the main glands.

Lecture 29

Female Reproductive System – I (T.V. Boronikhina)

The female reproductive system consists of the internal organs: the ovaries, the oviducts, the uterus, the vagina, and the external genitalia. The mammary glands are also included in this system, because their development and functional state are directly related to the hormonal activity of the female reproductive organs. The organs of this system perform numerous important functions: they produce the ova, secrete female sex hormones, provide a suitable environment for the early stages of embryogenesis, provide implantation and development of the fetus during pregnancy, participate in parturition, and provide nutrition of the newborn.

Ovogenesis

Ovogenesis is a process of the ovum maturation, the entire sequence of events, by which oogonia are transformed into ova. Ovogenesis possesses some peculiarities in comparison with spermatogenesis.

The phase of reproduction begins in early fetal life, when the oogonia proliferate by mitotic division and are converted to the primary oocytes before birth, that is why the ovaries of a newborn female infant lack the oogonia and possess only the primary oocytes.

The phase of growth is pronounced and subdivided into two steps: the small growth and the large growth. The small growth begins in the embryogenesis, since the oogonia have been transformed into the primary oocytes. The primary oocytes enter the prophase of the first meiotic division, but the completion of the prophase does not occur until puberty. The primary oocytes remain in suspended prophase called the dictyotene for several years, until sexual maturity is reached and the reproductive cycles begin at puberty.

The large growth begins at puberty. Monthly several primary oocytes enter the large growth and considerably enlarge in size, because they accumulate organelles, synthesize yolk granules, and manufacture specialized secretory vesicles known as the cortical granules. The yolk granules provide embryo nutrition during the first days of development. The cortical granules are located just beneath the oocyte plasma membrane and contain proteases that are released by exocytosis during fertilization to form the fertilization envelope preventing polyspermy. The large growth lasts for about two weeks until just before ovulation. This time the completion of the first meiotic prophase occurs. Thus, primary oocytes remain arrested in the dictyotene stage of the first meiotic division for 12 to 50 years. This long period of meiotic arrest makes the primary oocytes more sensitive to environmental influences and probably contributes to errors such as nondisjunction of chromosomes. This results in chromosomal anomalies such as trisomy of chromosome 21 – Down's syndrome.

The phase of maturation includes two meiotic divisions. Shortly before ovulation the primary oocyte completes the first meiotic division; however, the division of cytoplasm is unequal. The secondary oocyte receives almost all the cytoplasm, and the first polar body receives a minimal amount of the cytoplasm. The polar body is a small nonfunctional cell that does not divide (in humans) and soon degenerates. At ovulation the nucleus of the secondary oocyte begins the second meiotic division, but progresses only to metaphase, when division is arrested. If fertilization occurs, the second meiotic

division is completed (if the secondary oocyte is penetrated by a spermatozoon) and most cytoplasm is again retained by one cell, the mature ootid. The other cell – the second polar body – is small and soon degenerates. As soon as the second polar body is extruded, maturation of the ovum is complete.

The phase of formation is absent. In contrast to spermatogenesis, female gametogenesis proceeds in three phases, and the ootid is a mature ovum. After ovulation, the secondary oocyte remains viable for a period of approximately 24 hours. If fertilization does not occur during this period, the secondary oocyte degenerates as it passes through the oviduct.

Ovary (female sex gland, female gonad)

The ovary is a small, almond-shaped body. It has the dense connective tissue capsule (the tunica albuginea) that is invested by the germinal epithelium (a simple squamous or cuboidal epithelium). The term germinal epithelium is a carryover from earlier days when it was incorrectly thought to be the site of germ cell formation in development. It is now known that the primordial germ cells (of both the male and female) are of extragonadal origin and they migrate from the embryonic yolk sac to the cortex of the embryonic gonad where they differentiate and induce differentiation of the ovary. The ovary is subdivided into the cortex and the medulla, the central portion of the ovary. The boundary between the medulla and cortex is indistinct. The cortex contains ovarian follicles at various stages of development, atretic follicles and atretic bodies, and the corpus luteum at various stages of development up to the corpus albicans. The medulla contains loose connective tissue rich in blood vessels that provide blood supply to the cortex, lymphatic vessels, and nerves.

The ovaries have two interrelated functions: production of female gametes (oogenesis) and secretion of female sex hormones – estrogens and progesterone.

Ovarian follicles

The ovarian follicle is the oocyte surrounded by envelopes. The ovarian follicles provide the microenvironment for developing oocytes, their sizes and structure correlating with the developmental state of the oocyte. The stages of the ovarian folliculogenesis are as follows: primordial follicles, primary follicles, secondary (growing) follicles, and mature follicles (Graafian vesicles).

The primordial follicle is the earliest stage of the follicular development. The primordial follicles predominate in the ovary; they are located in the periphery of the cortex, just beneath the tunica albuginea. These follicles are the smallest and the simplest in structure. They are composed of a primary oocyte arrested in the meiotic dictyotene and a single layer of squamous follicular cells. The follicular cells are separated by a basal lamina from the surrounding stroma and are attached to each other by desmosomes. The oocyte measures about 30 μm in diameter and has an acentric nucleus with a single nucleolus.

The primary follicle is the first stage of follicle growth. The primary oocyte enters the large growth and considerably enlarges in size: its diameter becomes about 50 to 80 μm . As the oocyte grows, a homogeneous acidophilic layer called the zona pellucida appears around the oocyte, between it and the adjacent follicular cells. The growing oocyte and follicular cells secrete this gel-like layer that is rich in glycosaminoglycans and glycoproteins. The follicular cells proliferate and become cuboidal in shape; they are arranged in one or two layers round the oocyte. The follicular cells are separated from the stroma by their own basal membrane.

The secondary (growing) follicle is larger than the primary follicle. Secondary follicles contain a primary oocyte surrounded by the zona pellucida. The oocyte has reached its final size – about 125 to 150 μm in diameter. Through rapid mitotic proliferation, the single layer of follicular cells gives rise to a stratified epithelium now named the membrana granulosa or stratum granulosum; the follicular cells are identified as the granulosa cells. The basal lamina retains its position. The follicular cells of the outermost layer become columnar, the rest of them have narrow processes and communicate with each other via gap junctions. The narrow processes of the granulosa cells and the oocyte microvilli extend into and contact each other within the substance of the zona pellucida. When the stratum granulosum reaches a thickness of 6- to 12-cell layers, fluid-filled cavities appear among the granulosa cells. This fluid is called the liquor folliculi; it continues to accumulate among the granulosa cells; the cavities begin to coalesce, eventually forming a single cavity called the antrum. The follicle is now identified as a secondary antral follicle. The liquor folliculi is secreted by the granulosa cells.

The granulosa cells possess a number of follicle-stimulating hormone (FSH) receptors. FSH stimulates the follicular growth and secretion of the liquor folliculi. In response to FSH stimulation, the granulosa cells convert androgens to estrogens and release them. Estrogens stimulate, in turn, proliferation of the granulosa cells.

As the granulosa cells proliferate, the stroma immediately surrounding the follicle forms a sheath of connective tissue, known as the theca folliculi, just external to the basal lamina. The theca folliculi further differentiates into two layers: the theca interna and the theca externa.

The theca interna is the inner layer. It contains loose connective tissue, a rich network of small vessels, and secretory cells called the theca cells. These are cuboidal cells possessing ultrastructural features characteristic of steroid-producing cells: they are rich in sER profiles, Golgi apparatus, vesicular mitochondria, and lipid droplets. They synthesize and secrete the androgens that are the precursors of estrogens. These cells possess a large number of luteinizing hormone (LH) receptors; in response to LH stimulation, the theca cells produce their secretion.

The theca externa is the outer layer of connective tissue; it mainly contains bundles of collagen fibers and smooth muscle cells. The boundaries between the thecal layers and between the theca externa and the surrounding stroma are not distinct.

The growing follicles are hormone-producing structures of the ovary, they produce estrogens. As the follicles grow, the estrogen blood level increases and attains the maximal size by approximately the 14th day of the menstrual cycle, just before ovulation.

Histophysiology of the follicle growth

Gonadotropin-releasing hormone (GnRH) from the hypothalamus causes the release of FSH and LH by the pars anterior of the pituitary gland. LH stimulates the theca cells to produce androgens. FSH stimulates the granulosa cells to convert androgens to estrogens and release them into the liquor folliculi and then into the blood. Estrogens inhibit FSH release (by suppressing the release of GnRH), but stimulate LH release and facilitate an increase in the LH blood content by the time of ovulation called the peak (surge) of LH.

The mature follicle or Graafian vesicle represents the final stage of the follicular development, just prior to ovulation. It measures 10 mm and more in diameter. Because of its very large size, it extends through the full thickness of the cortex as a bulge on the ovarian surface. The oocyte is acentrically positioned, and its final size is about 150 μm in diameter. Before ovulation, the first meiotic division of the primary oocyte resumes forming the secondary oocyte and the first polar body. The oocyte is surrounded by the zona pellucida and the corona radiata, i.e., the granulosa cells located immediately around the zona pellucida. The microvilli of the oocyte and processes of the corona radiata cells contact with each other via gap junctions. The antrum increases in size and is surrounded by several layers of follicular cells. The stratum granulosum has relatively uniform thickness except for the region associated with the oocyte. Here, the granulosa cells form a thickened mound – the cumulus oophorum – that projects into the antrum. The cumulus oophorum cells that immediately surround the oocyte and remain with it at ovulation make up the corona radiata of the ovum. The thecal layers become more prominent.

Ovulation

The ovulation is a hormone-mediated process resulting in the release of the secondary oocyte with the zona pellucida and the corona radiata from the Graafian follicle. The primary oocyte completes its first meiotic division just prior to ovulation. The secondary oocyte begins the second meiotic division, but progresses only to the metaphase, when division is arrested. Thus, metaphase II secondary oocyte leaves the ovary in ovulation.

Just before ovulation, the blood flow stops in a small area of the ovarian surface overlying the bulging follicle called the stigma. The stigma ruptures, forming a small gap in the capsule, germinal epithelium, and the wall of the Graafian follicle. Via this gap, the secondary oocyte with its surroundings leaves the ovary. Combinations of hormonal changes and enzymatic effects are responsible for this rupture and exit of the oocyte. They are as follows: increase in volume and pressure of the follicular fluid, enzymatic proteolysis of the follicular wall, enzymatic separation of the oocyte-cumulus complex from the stratum granulosum, and contractions of the smooth muscle cells in the theca externa. The hormonal control of ovulation is primarily realized by LH, whose blood level reaches the maximum at ovulation. This maximum is called the surge or peak of LH. The lack of the LH surge in women results in the lack of ovulation (anovulation) and the impossibility of pregnancy. The block of the LH surge and, as a result, the inhibition of ovulation is the basis of female hormonal contraception. FSH also reaches high concentrations by the time of ovulation, forming the FSH peak.

The oocyte is then transported into the oviduct infundibulum. At the time of ovulation, the fimbriae of the oviduct envelop the ovary, normally directing the oocyte into the oviduct and not allowing it to pass into the peritoneal cavity. The ova that fail to enter the oviduct usually degenerate in the peritoneal cavity. Occasionally, however, one of these may become fertilized and implanted on the surface of the ovary, the intestine, or inside the rectouterine (Douglas) pouch. Such ectopic implantation

usually does not develop beyond early fetal stages but may have to be removed surgically for the health of the mother.

Normally, only one follicle completes maturation in each cycle and ruptures to release its secondary oocyte. Rarely, oocytes are released from other follicles that have reached full maturity during the same cycle, leading to the possibility of multiple zygotes and fetuses.

Corpus luteum

After ovulation, the collapsed follicle undergoes reorganization into the corpus luteum or yellow body. At first, bleeding from the capillaries in the theca interna into the follicular lumen leads to the formation of the corpus hemorrhagicum with a central clot. The stromal connective tissue invades the former follicular cavity. The cells of the granulosa and the theca interna proliferate, the blood and lymphatic vessels from the theca interna rapidly grow into the granulosa layer, and a rich vascular network is established. The cells of the granulosa and the theca interna layers then undergo morphological changes: they increase in size, become filled with lipid droplets, accumulate sER and mitochondria with tubulovesicular cristae. At the ultrastructural level, the cells demonstrate features associated with steroid-secreting cells. The lipid-soluble pigment lipochrome in the cell cytoplasm imparts to them a yellow appearance in fresh preparations. Two types of luteal cells are identified: granulosa lutein cells, large (about 30 μm in diameter), pale, centrally located cells derived from the granulosa cells; and theca lutein cells, smaller (about 15 μm), more deeply staining, peripherally located cells derived from the theca interna cells. The formation of the corpus luteum is controlled by LH, a pituitary gland hormone.

The mature corpus luteum then begins to secrete progesterone that stimulates the growth and secretory activity of the endometrium to prepare it for the implantation of the developing zygote, but blocks the cyclic development of the ovarian follicles. If fertilization and implantation occur, the corpus luteum increases in size to form the corpus luteum of pregnancy. In early pregnancy, the corpus luteum attains a size of 2 to 3 cm, thereby filling most of the ovary. The corpus luteum retains its full functional capacity about half a year, and then its activity decreases. If fertilization and implantation do not occur, the corpus luteum remains active only for 14 days; in this case, it is called the corpus luteum of menstruation. The active secretion of the corpus luteum is controlled by prolactin (LTH) from the pituitary gland.

The corpus luteum degenerates and undergoes slow involution after pregnancy or menstruation. The cells decrease in size, undergo autolysis, and their remnants are phagocytosed by macrophages. A white scar – the corpus albicans – is formed in place of the former corpus luteum. The corpus albicans sinks deeper into the ovarian cortex as it slowly disappears over a period of several months.

Atresia

A few of the ovarian follicles that begin their differentiation in the embryonic ovary reach maturation and ovulate. Most of the follicles degenerate and disappear through the process called follicular atresia. A large number of follicles undergo atresia during fetal development, early postnatal life, and puberty. About 2 million primary oocytes are usually present in the ovaries of the newborn female infant, but many regress during childhood so that by puberty only 30 to 40 thousand remain. Only about 400 become secondary oocytes and are expelled at ovulation during the reproductive period.

A follicle may undergo atresia at any stage of its maturation. In atresia of primordial and primary follicles, the oocyte becomes smaller and degenerates; similar changes occur in the follicular cells. As the cells disappear, the surrounding stromal cells migrate into the space previously occupied by the follicle, leaving no trace of its existence.

In atresia of large growing follicles, the oocyte degeneration appears to occur secondarily to degenerative changes in the follicular wall. The following events take place: invasion of the granulosa layer by neutrophils, macrophages, and vascularized connective tissue; sloughing of the granulosa cells into the antrum of the follicle; invasion of connective tissue into the cavity of the follicle; hypertrophy of the theca interna cells; collapse of the follicle.

The oocyte undergoes typical changes associated with degeneration and autolysis; its remnants are phagocytosed by invading macrophages. The zona pellucida becomes folded and collapses as it is slowly broken down within the cavity of the follicle. Macrophages are involved in the phagocytosis of the zona pellucida. The basement membrane between the follicular cells and the theca interna may separate from follicular cells and increase in thickness, forming a hyaline layer called the glassy membrane. This structure is characteristic of follicles in late stages of atresia.

The enlargement of the theca interna cells occurs in the atretic follicles, and a rich capillary network develops among them. These cells produce steroid hormones, mainly estrogens. These cells are an important source of the estrogens that influence the growth and development of the secondary sex

organs. In the climacteric period, the process of atresia becomes more active, resulting in serum estrogen elevations, and this, in turn, may cause malignant growth in females.

Lecture 30

Female Reproductive System – II (T.V. Boronikhina)

The female reproductive system functions cyclically. The ovaries, the oviducts, the uterus, the vagina, and the mammary glands are involved in this cycle. The female or menstrual cycle averages about 28 to 30 days. The initiation of the female cycle, referred to as the menarche, occurs in females between the ages of 9 and 14 years and marks the end of puberty and the beginning of the reproductive life span. Between the ages of 45 and 55 years, the menstrual cycles become infrequent and then cease. This change in reproductive function is referred to as the menopause or climacterium. The cause of the female reproductive cyclic function is the cyclical secretion of the female pituitary gland that takes place only in women and develops in early embryogenesis.

Ovarian cycle

During each menstrual cycle, the ovary undergoes cyclic changes constituting the ovarian cycle. It involves two phases: the follicular phase and the luteal phase, ovulation occurs between the two phases on the 14th day of a 28-day cycle.

The follicular phase lasts from the 1st to 14th day. It begins with the development of a small number of primary follicles. During this phase follicles grow and develop, most of them undergo atresia and only one of them reaches the ovulation. Both growing follicles and atretic follicles produce steroid hormones, principally estrogens; therefore, the follicular phase is named the estrogen phase. The circulating level of estrogens rises during the follicular phase and reaches its peak by the ovulation.

The luteal phase begins immediately after ovulation and lasts up to the 28th day of cycle. During the first 2 or 3 days of this phase, the granulosa and thecal cells of the ruptured follicle undergo rapid morphologic transformation to form the corpus luteum. Late in the phase, the corpus luteum actively secretes and produces a large amount of progesterone; therefore, this phase is named the progesterone phase. Progesterone stimulates the development of the uterus and mammary glands for possible pregnancy and blocks the growth and development of the ovarian follicles. If the ovulated oocyte is not fertilized, the corpus luteum regresses into a nonfunctional corpus albicans by the 14th day after ovulation, and the progesterone level declines. This action initiates a new ovarian cycle and follicular development.

The ovarian cycle is controlled by the adenohipophysial hormones: follicle-stimulating hormone (FSH) and luteinizing hormone (LH). During the follicular phase, FSH is the principal circulating gonadotropic hormone. It influences the growth and maturation of ovarian follicles and stimulates them to produce estrogens. Estrogens, in turn, produce an inhibitory effect on FSH release. The circulating FSH level rises during the follicular phase twice, forming two peaks of FSH: on the 7th day and shortly before ovulation; the level then decreases and remains low up to the end of the cycle.

The circulating LH level is very low during the follicular phase up to the 12th day and then sharply increases by the 14th day (a brief surge of LH release). This increased level of LH induces the ovulation and formation of the corpus luteum. The LH level then declines by the 16th day and remains low up to the end of the cycle. Estrogen stimulates LH production by the adenohipophysis. At midcycle estrogen secretion reaches a peak that causes a brief surge of LH release and ovulation. In cases of anovulatory cycle, estrogens are administered to stimulate ovulation.

During the luteal phase corpus luteum dominates in the ovary and secretes progesterone. The functional activity of the corpus luteum is controlled by prolactin. The increasing progesterone level has an inhibitory effect on further release of LH by the adenohipophysis. Progesterone administration at midcycle may block the LH surge and inhibit ovulation, which is used for the female hormonal contraception. For this purpose they may also employ a mixture of estrogens and progesterone; this mixture inhibits the release of FSH and LH, hence, ovarian folliculogenesis.

Uterus

The human uterus is a pear-shaped organ located in the pelvis between the bladder and rectum. Anatomically, the uterus is subdivided into the fundus, the corpus, and the cervix. The uterine functions are multiple: it houses the developing embryo and fetus during pregnancy; its endometrium participates in the formation of the placenta; as the fetus enlarges, the uterus increases in size, forming its thick muscular coat; its myometrium contracts at parturition, aiding in the fetus and placenta expulsion.

The uterine wall is composed of three tunics. From the lumen outward they are the endometrium, myometrium, and perimetrium. The endometrium is the uterine mucosa. The myometrium is a thick

muscular layer. It is composed of three layers of smooth muscle: the inner layer, stratum submucosum, the middle layer, stratum vasculosum containing numerous blood vessels and lymphatics; and the outer layer, stratum supravasculosum. During pregnancy, the myometrium thickens due to the hypertrophy of existing smooth muscle cells and the development of new cells through the muscle cells division and differentiation of undifferentiated cells. There is also an increase in the amount of connective tissue. At parturition the hormone oxytocin released by the neurohypophysis stimulates powerful contractions of the myometrium. After parturition, the uterus becomes smaller: some muscle cells degenerate, but most return to their original size; the collagen is enzymatically degraded.

The perimetrium is the external serous layer and consists of the mesothelium and a thin layer of loose connective tissue. The serosa covers the entire posterior surface of the uterus but only a part of the anterior surface; the remaining part has only connective tissue or adventitia.

The endometrium undergoes the most marked cyclic changes each month to prepare the uterus for implantation. These changes constitute the uterine cycle named the menstrual cycle, because it is accompanied by uterine discharge called the menstruation or menses. If an embryo implants, the cycle stops.

The endometrium is subdivided into the superficial functional layer and the deeper basal layer. The functional layer is the thick part of the endometrium that degenerates, is sloughed, and is then reestablished during the menstrual cycle. The basal layer is the thin deeper endometrial layer that is retained during the cycle and serves for regeneration of the functional layer. The boundary between the two layers is indistinct.

The endometrial epithelium is simple columnar, consisting of two cell types: secretory and ciliated cells. The underlying lamina propria – the endometrial stroma – consists of loose connective tissue. The stroma has uterine glands; they are simple tubular nonbranched and produce a mucous secretion. Their basal portions (glandular bottoms) extend into the basal layer and contain stem cells for reepithelialization of the endometrium and for reestablishment of the uterine glands after menstruation.

The endometrium contains a unique system of blood vessels. It receives arteries from the myometrium: some branches called the straight arteries enter the basal layer and supply it; the main branches called the spiral (helical) arteries extend into the functional layer and supply it. The spiral arteries give rise to highly coiled spiral arterioles; the latter, in turn, give rise to a rich capillary bed. The straight arteries and the proximal part of the spiral arteries do not change during the cycle. The distal portion of the spiral arteries and spiral arterioles undergo degeneration and regeneration with each menstrual cycle.

Menstrual cycle

The menstrual cycle is a sequence of morphological and functional changes of the endometrium, primarily of its functional layer. The cycle normally repeats every 28 days and is controlled by the ovarian hormones: estrogens and progesterone. The menstrual cycle has three phases: the proliferative phase, the secretory phase, and the menstrual phase.

The proliferative phase occurs concurrently with follicular maturation and is influenced by estrogens. The proliferative phase starts at the end of the menstrual phase, after regular menstruation. At this time, the endometrium consists of the basal layer only: a thin band of connective tissue, about 1mm thick, containing the basal portions of the uterine glands and the lower portions of the spiral arteries; the functional layer having been sloughed off in the menstrual discharge. Under the influence of estrogens, stromal, endothelial, and epithelial cells proliferate rapidly. Epithelial cells of the glandular bottoms migrate to cover the denuded endometrial surface and reconstitute the glands. Stromal cells proliferate and secrete collagen and the ground substance; thus, the endometrium thickens (at the end of this phase it has reached a thickness of about 3 mm). The uterine glands are straight and narrow, because they lack secretory activity. By the end of the proliferative phase, the glands acquire a slightly wavy appearance and their cells begin to store glycogen. Spiral arteries and arterioles are reestablished; they are only slightly coiled and do not extend into the upper third of the endometrium. Stromal cells undergo the decidual reaction: they store glycogen, enlarge, and become pale-staining decidual cells. Thus, the functional layer of the endometrium is renewed. The proliferative phase continues for 1 to 2 days after ovulation.

The secretory phase of the menstrual cycle occurs concurrently with the corpus luteum functional activity and is influenced by progesterone. The secretory phase starts a day or two after ovulation. This phase is characterized by the endometrial edema and the secretion of uterine glands. The endometrium becomes edematous and may reach a thickness of 5 to 6 mm. The glands enlarge and acquire a corkscrew appearance; they become wide and full of secretory products. Their mucoid fluid is rich in nutrients, particularly glycogen, required to support development, if implantation occurs, and immunoglobulins to

provide endometrial sterility. The spiral arteries become longer and more coiled, so that they reach the superficial aspect of the functional layer.

The menstrual phase starts approximately two weeks after ovulation if fertilization does not occur, when the corpus luteum begins to regress and the circulating level of progesterone rapidly declines. Initially, the absence of progesterone causes contractions of the spiral arterioles, lasting for several hours, which results in ischemia and subsequent necrosis of the functional layer. After the extended period of vascular constriction, the spiral arterioles dilate, and their walls rupture, leading to hemorrhage into the stroma. The necrotic functional layer is then shed in the menstrual flow. Blood, uterine fluid, stromal cells, and epithelial cells mix to form the vaginal discharge. The desquamation continues until only the basal layer remains. The basal layer is not sloughed and does not become necrotic, since it is supplied by short straight vessels that do not undergo vasoconstriction. The menstrual flow normally lasts about 5 days. Blood clotting is inhibited during this period. Increased estrogen level stimulates the rapid cell proliferation in the basal layer and stops menstrual discharge; the proliferative phase of the next cycle begins.

In cases of anovulation, the corpus luteum does not develop. In the absence of progesterone, the endometrium does not enter the secretory phase and remains in the proliferative phase until menstruation. Prolonged proliferation of the endometrium under the influence of estrogens may result in cancerous diseases.

Uterine cervix

The cervix is a region of the uterus that projects into the vagina. The cervical canal has a constricted opening or os at each end. The internal os communicates with the uterine cavity, the external os communicates with the vagina.

Compared with the uterine body, the cervical myometrium has more connective tissue with numerous elastic fibers and less smooth muscle cells. It is very important for the possibility of parturition: prior to parturition the cervix becomes dilated and softens due to the lysis of collagen in response to the hormone relaxin. The softening of the cervix allows the cervical canal to be dilated and facilitates the passage of a fetus during parturition.

The cervical mucosa is lined with a simple columnar epithelium, except a portion projecting into the vagina that is covered with a stratified squamous nonkeratinized epithelium. There is an abrupt transition just outside the external os between this squamous epithelium and simple columnar epithelium of the cervical canal. Metaplastic changes in this transition zone constitute precancerous lesions of the cervix.

The cervical mucosa, which is about 2 to 3 mm thick, differs from the rest of the uterine endometrium. It lacks the spiral arteries, that is why it is not sloughed in the menstruation. The cervical glands are branched and produce their secretion during the whole cycle. During each menstrual cycle, however, the cervical glands undergo important functional changes that are related to the transport of spermatozoa in the cervical canal. The amount and properties of the glandular mucus vary under the influence of the ovarian hormones. During the proliferative phase, the secretion of the cervical glands is thin and watery. This type of secretion allows an easier passage of sperm into the uterus. At midcycle, near the ovulation, under the influence of the maximal estrogen level, there is a 10-fold increase in the amount of mucus, which provides more favourable environment for sperm migration. During the luteal phase, the cervical secretion becomes highly viscous and hinders the passage of sperm or microorganisms into the uterus. In pregnancy, the character of the cervical secretion is similar to that in the luteal phase of the menstrual cycle.

Oviduct (fallopian tube)

The oviducts are paired tubes, about 10 to 12 cm long that extend bilaterally from the uterus toward the ovaries. They transmit the ova from the ovary to the uterus, provide the necessary environment for fertilization and for the initial development of an embryo up to the morula stage.

Anatomically, the tube can be divided into four segments: the infundibulum with the fimbriae, the ampulla, the isthmus, and the intramural part.

The wall of the oviduct is composed of three tunics: the serosa, the muscularis, and the mucosa. The serosa consists of mesothelium and a thin layer of connective tissue. The muscularis is organized into an inner circular layer and an outer longitudinal layer. The mucosa lacks glands and exhibits thin longitudinal folds that project into the lumen of the oviduct throughout its length. The mucosal simple columnar epithelium is composed of ciliated and nonciliated secretory cells producing the oviduct fluid. The wave of the cilia is directed toward the uterus that may facilitate the transport of an embryo to the uterus, but muscular contractions are equally important. The epithelial cells undergo cyclic hypertrophy during the follicular phase and atrophy during the luteal phase in response to changes in hormonal levels,

particularly estrogens. The ciliated to nonciliated cell ratio also changes during the hormonal cycle: estrogens stimulate ciliogenesis, while progesterone increases the number of secretory cells.

Vagina

The vagina is a fibromuscular tube whose wall is composed of three tunics: the mucosa, the muscularis, and the adventitia. The mucosa is lined with stratified squamous nonkeratinized epithelium including superficial, intermediate, parabasal, and basal cells. Epithelial cells synthesize and accumulate glycogen; they are continuously desquamated into the vaginal lumen where the vaginal bacterial flora metabolizes glycogen into lactic acid, which lowers the pH of the vaginal fluid. The acid pH of the vagina limits the growth of pathogenic organisms. The vaginal epithelium exhibits cyclic changes in the menstrual cycle. During the follicular phase and estrogenic stimulation, the vaginal epithelium thickens. The epithelial cells synthesize and accumulate increased amounts of glycogen, especially by the moment of ovulation. Thus, the pH of the vaginal fluid, which is normally low (pH \approx 4) becomes more acid near the midcycle. Later in the cycle, as estrogen levels decline, glycogen is less abundant and the vaginal pH increases. Epithelial cells are continuously desquamated, but during the proliferative phase, superficial cells are desquamated, while during progesterone stimulation, epithelial cells from deeper layers undergo desquamation.

Stained preparations of the vaginal epithelial cells (vaginal smears) are a routine clinical method. Vaginal cytology closely correlates with the ovarian cycle. Characteristic features of vaginal smears permit to assess the follicular activity during normal menstrual cycle or after estrogenic and other therapy. Vaginal smears also provide important information for detecting pathologic or malignant conditions.

The lamina propria is composed of loose connective tissue. Neutrophils and lymphocytes are found in the lamina propria. Many of them migrate into the epithelium. The number of lymphocytes and neutrophils in the mucosa and vaginal lumen increases around the time of menstrual flow.

The muscularis is composed of a thin inner circular and a thicker outer longitudinal layer of smooth muscle. The external orifice is circumscribed by skeletal muscle fibers. The adventitia consists of connective tissue that fixes the vagina to the surrounding structures.

Mammary glands

The mammary glands are characteristic of only mammals. Phylogenetically, they are modified apocrine sweat glands and belong to the integumentary system, but their development and functional state are directly related to the hormonal activity of the female reproductive system. The mammary glands produce milk that nourishes the newborn and provides an immunological defence for the neonate.

The mammary glands are compound alveolar glands: approximately 20 glands empty at the apex of each nipple. The mammary gland has 15 to 20 lobes separated by connective tissue and subdivided into numerous lobules. Numerous adipose cells are present in the connective tissue.

In embryogenesis, the mammary glands arise from the epidermal thickenings called the milk lines, in both sexes. During embryogenesis the nipple, areola, and the rudimentary duct system develop. The duct system consists of the lactiferous ducts that open onto the nipple and the lactiferous sinuses, i.e., dilated portions of each duct. The male and female mammary glands are identical until puberty. Then, in the male, the glands remain rudimentary; in the female, the mammary glands undergo further development under hormonal influence.

At puberty, influenced by estrogens, the female mammary glands enlarge due to further formation of the duct system, mainly the terminal ductules, and the development of connective and adipose tissues in their stroma. But the secretory portions do not develop, and prepuberal mammary glands lack alveoli that appear only during pregnancy. That is why, the size of the prepuberal and nonlactating mammary glands cannot be evidence of their future secretory capacity.

During pregnancy, the mammary glands undergo dramatic proliferation and development under the hormonal influence of the corpus luteum and the placenta. The mammary glands exhibit a number of changes in preparation for lactation: the ducts branch, and alveoli develop due to cell proliferation in the terminal ductules. In the later stages of pregnancy, alveolar development becomes more prominent; the secretory cells enlarge and accumulate the secretory product. The changes in the glandular tissue are accompanied by decreases in the amount of connective and adipose tissues. The corpus luteum and placenta continuously produce estrogens and progesterone. Estrogens stimulate the proliferation of the lactiferous duct component, and progesterone stimulates the growth of alveoli.

The alveoli are composed of secretory alveolar cells and myoepithelial cells. The alveolar cells become columnar, they have numerous apical microvilli, abundant sER and rER, a well-developed Golgi apparatus, numerous mitochondria, lysosomes, and many vesicles. These cells possess abundant lipid and milk protein (casein) droplets. The protein component of the milk is released from the cell by the merocrine mode of secretion. The lipid component of the milk forms large droplets that pass to the apical

cellular region, are invested with envelope of the plasma membrane and a thin layer of cytoplasm, and are then released from the cell by the apocrine mode of secretion.

The myoepithelial cells lie between the secretory cells and their basal lamina. These cells, arranged in a basket-like network, are present in the secretory portions of the gland but are more apparent in the larger ducts. They contain numerous contractile microfilaments that help to eject milk from acini and ducts.

Human milk contains proteins (casein), lipids, lactose, electrolytes, vitamins, and water; it also contains nonspecific antibacterial substances such as lactoperoxidase and lysozyme. The milk is rich in immunoglobulins that protect the infant from the enteric infections that can cause diarrhea and dehydration. Immunoglobulins are produced by the plasma cells infiltrating the stroma of the mammary glands and are secreted across the glandular cells into the acinar lumen.

Lactation is under the neurohormonal control of the adenohypophysis and hypothalamus. The secretory activity of the alveolar cells is regulated by the hormone prolactin. The act of suckling initiates sensory impulses from the nipple to the hypothalamus. The impulses inhibit the release of prolactin-inhibiting factor, and prolactin is then released from the adenohypophysis. The sensory impulses also cause the release of oxytocin in the neurohypophysis. The oxytocin stimulates the myoepithelial cells, causing them to contract and eject the milk from the alveoli and the ducts. In the absence of suckling, secretion of milk ceases, and the mammary glands begin to regress.

Nursing women exhibit lactational amenorrhea (lack of menstruation during lactation) and infertility. This is due to the high level of serum prolactin, which suppresses the LH and FSH secretion.

The mammary glands undergo involution after menopause. In the absence of ovarian hormone stimulation, the secretory cells degenerate and are replaced by adipose and connective tissues.

Lecture 31

Human Embryology – I (T.V. Boronikhina)

Ontogenesis, the process of individual development, includes the prenatal (until birth) and the postnatal (after birth) periods. Progenesis, the process of gamete formation, precedes ontogenesis. The prenatal period or embryogenesis begins when an ovum is fertilized by a sperm forming a zygote and lasts 280 days (40 weeks or 10 lunar months). Embryogenesis is divided into three periods: the initial period (the first week of development), the embryonic period (from the 2nd week until the 8 to 9th weeks), and the fetal period (from the 8 to 9th weeks up to birth). During the first two months the developing individual is called an embryo. From the third month until birth it is called a fetus.

The embryonic development includes the following stages: fertilization and zygote formation, cleavage and blastocyst formation, gastrulation and trilaminar embryo formation, differentiation of germ layers and axial organ formation, and the last period (the longest and most complex) of histogenesis and organogenesis. These processes are accompanied by the development of the provisory organs and by the establishment of close relations between the developing individual and the maternal organism, namely, implantation and placentation.

The initial period: the first week of development

Fertilization

Fertilization is the sequence of events, by which a sperm fuses with an ovum, forming a unicellular organism called a zygote. The biological significance of fertilization consists in the restoration of the diploid number: the fusion of two haploid germ cells produces a diploid cell with 46 chromosomes. Because half of the chromosomes come from the mother and half from the father, the zygote contains a new combination of chromosomes and genetic material that is different from those of the parents. Moreover, the embryo sex is determined at fertilization by the kind of sperm that fertilizes the ovum. Fertilization by an X-bearing sperm produces an XX zygote, which normally develops into a female. Fertilization by a Y-bearing sperm produces an XY zygote, which normally develops into a male.

The usual site of fertilization is the uterine tube ampulla, the longest and the widest portion of the oviduct. The fertilization process requires about 24 h.

At ovulation, the secondary oocyte enters the infundibulum of the oviduct and then passes into the tubular ampulla largely as a result of the beating action of cilia on some tubal epithelial cells, and by muscular contractions of the tubal wall. It takes the oocyte about 25 minutes to reach the site of fertilization. Studies indicate that the ovum is viable during 24 hours after ovulation and is usually fertilized within 12 hours after expulsion.

The sperms pass by movements of their tails through the cervical canal, but sperm passage through the uterus and uterine tubes is assisted by muscular contractions of the organs. The prostaglandins present in the seminal plasma stimulate uterine motility. It is not known how long it takes sperms to reach the fertilization site, but the time of transport is probably short. Only 300 to 500 sperms from 200 to 500 million sperms deposited in the vagina and cervix reach the fertilization site. The reduction of sperms in number during the passage through the female reproductive tract is mainly the result of filtering abnormal and poorly motile sperms by the cervical mucus. The ovum produces chemical substances that attract the sperms; the sperm movement is directed by chemotaxis.

Before a mature motile sperm can penetrate the oocyte surroundings, it must undergo capacitation. This process consists of enzymatic changes that result in the removal of the thick glycoprotein coat from the plasma membrane over the acrosome. No morphological changes are known to occur during the capacitation. Sperms are capacitated by substances in secretions of the female genital tract. It takes about 7 hours to capacitate.

The acrosome reaction may occur after sperm capacitation. This reaction consists of structural changes. The outer membrane of the acrosome fuses at many places with the overlying sperm head membrane; the fused membranes then rupture, producing multiple perforations, through which the enzymes leave the acrosome. Progesterone seems to stimulate the acrosome reaction. The enzymes released from the acrosome facilitate the sperm passage through the oocyte envelopes. Hyaluronidase enables the sperm to penetrate the corona radiata. Acrosin appears to cause lysis of the zona pellucida, forming a pathway for sperm.

The sperm head attaches itself to the surface of the secondary oocyte. The plasma membranes of the oocyte and the sperm fuse and then break down at the point of contact. The sperm nucleus and the sperm centriole enter the oocyte cytoplasm, leaving the sperm plasma membrane and the sperm tail attached to the oocyte plasma membrane when they rapidly degenerate.

Once the first sperm passes through the zona pellucida, the zona (cortical) reaction occurs. It is produced by cortical granules containing lysosomal enzymes. After penetration, the cortical granules open and release the enzymes that modify the zona pellucida, converting it to impermeable to other sperms and preventing polyspermy. Alterations in the physicochemical characteristics of the zona pellucida are associated with the zona reaction, but no morphological changes are visible. There is some experimental evidence that aged oocytes do not release cortical granules. As a result, the zona reaction does not take place, and multiple penetrations of sperms occur. Polyspermy is unlikely to produce a viable embryo.

After penetration, the secondary oocyte completes the second meiotic division, forming a mature ovum and the second polar body. The ovum nucleus is known as the female pronucleus. The sperm head enlarges to form the male pronucleus. The male and female pronuclei approach each other, come in contact, and lose their nuclear membranes. Then the maternal and paternal chromosomes intermingle at the metaphase of the first mitotic division of the zygote. Fertilization is completed.

Fertilization initiates a series of rapid mitotic cell divisions called the zygote cleavage. Cleavage of the secondary oocyte may occur without fertilization. This process is called parthenogenesis. There is evidence that the human oocyte may start to undergo parthenogenetic cleavage, but this does not result in organized development.

Cleavage

Cleavage is a process of successive rapid mitotic divisions without growth of the daughter cells called blastomeres. As G1 phase is not present in these mitotic cycles, the volume of cell cytoplasm does not increase; the blastomeres become progressively smaller until they acquire the size of most of the somatic body cells. The normal nucleus to cytoplasm volume ratio is restored.

Cleavage begins with the first mitotic division of the zygote and ends with the blastocyst formation. It proceeds in the oviduct during the first three days when the morula is formed. The morula enters the uterus as it is forming. The process then continues in the uterus for 3 to 4 days when the blastula forms. Human cleavage is holoblastic (total); it means that all the zygote cytoplasm is cleft. Human cleavage is unequal; it means that blastomeres are different in size: there are small and large blastomeres. Human cleavage is asynchronous; it means that blastomeres divide at different time; blastomeres may be either even or odd in number.

Blastomeres do not leave the cell cycle; they never begin to differentiate. Through the first mitotic divisions blastomeres retain totipotentiality. Occasionally, two or more blastomeres separate, and each develops into an embryo. Thus, identical twins appear.

Initially, the embryo is under the control of maternal informational macromolecules that have accumulated in the ovum cytoplasm during oogenesis. Later, development depends on the activation of

the embryonic genome, which encodes various growth factors and other macromolecules required for normal progression to the blastocyst stage.

Blastocyst formation

The uterine fluid passes in the morula, forming a cavity. As fluid increases, the cavity separates blastomeres into two parts: an outer cell layer – the trophoblast, from which the chorion and a part of the placenta develop, and an inner cell mass – the embryoblast, from which the embryo proper arises. The blastula looks like a cyst and is called the blastocyst: the trophoblast forms its wall, the embryoblast is attached to the inner side of the trophoblast and projects into the cavity. The blastocyst surrounded by the zona pellucida lies free in the uterine secretions. The zona pellucida then degenerates and disappears, which allows the attachment of the blastocyst to the endometrium at the beginning of implantation. The zona pellucida prevents the blastocyst implantation at an abnormal site.

Implantation

It is a process of the blastocyst invasion into the endometrium. It begins on the 5th or 6th day after fertilization. Invasion proper lasts about 40 hours; implantation completely ends during the second week of development.

Once the zona pellucida disappears, the trophoblast attaches itself to the uterine epithelium. The trophoblast starts to proliferate and differentiate, forming two layers: an inner layer – the cytotrophoblast, which maintains the cellular structure, and an outer layer – the syncytiotrophoblast, consisting of a multinucleated cytoplasm mass without cell boundaries. The cytotrophoblast is mitotically active and forms new cells that migrate to the syncytiotrophoblast where they fuse and lose their membranes to form a syncytium.

The syncytiotrophoblast never demonstrates mitoses, but displays high metabolic activity: it produces and releases enzymes facilitating the blastocyst invasion. The finger-like processes of syncytiotrophoblast grow into the endometrium and invade the uterine mucosa: its epithelium, stroma, capillaries, and glands. The blastocyst goes deeper and deeper in the mucosa until the whole of it has buried itself within the thickness of the endometrium. It is called the interstitial type of implantation.

The blastocyst invasion stimulates the decidual reaction of the uterine mucosa: the endometrial stromal cells undergo transformation into large pale cells rich in glycogen, the so-called decidual cells. They form the cellular layer restricting the blastocyst invasion.

By the end of the first week, the blastocyst is superficially implanted in the compact layer of the endometrium; by the 10th day, the embryo is completely embedded in the endometrium. For about two days, the defect in the surface epithelium is closed by a closing plug consisting of a blood clot and cellular debris. By the 12th day, regenerated uterine epithelium covers the blastocyst, completing implantation.

Implantation window is the period when the uterus is receptive for the blastocyst invasion. The human implantation window begins on the 6th day and is completed by the 10th day after ovulation.

Implantation site is an endometrial region where the blastocyst invasion occurs. The blastocyst usually implants in the midportion of the uterine body, more frequently on the posterior than on the anterior wall. Implantation in the lower uterine segment near the internal os of the cervical canal may cause the placenta previa and severe bleeding. Implantation outside the uterine cavity is called ectopic and includes tubular, cervical, and interstitial types. The decidual reaction never develops in the uterine cervix or in the oviduct; the blastocyst invasion in these organs results in severe bleeding and is dangerous for the woman's life.

The embryonic period: the second week of development

Gastrulation

The first stage of gastrulation occurs on the 7th day of development. Only the inner cell mass of the blastocyst, namely the embryoblast, participates in gastrulation; the trophoblast does not take part in this process. The embryoblast is transformed into a bilaminar embryonic disk by the mechanism called delamination. The upper layer of the embryonic disk called the epiblast consists of high columnar cells; the lower layer called the hypoblast consists of cuboidal cells. The epiblast subsequently gives rise to all three germ layers of the embryo (ectoderm, mesoderm, and endoderm). The hypoblast does not take part in the formation of the embryo body proper and is later displaced to extraembryonic regions.

Formation of the provisory organs

Concurrently, two small vesicles, two provisory organs appear. These are the amniotic vesicle and the yolk sac. The two vesicles are associated with the embryonic disk: the epiblast forms the floor of the amniotic cavity, whereas the hypoblast represents the roof of the yolk sac. The cells forming the amniotic wall are called the amnioblasts or amniotic epithelium. The wall of the yolk sac is called the yolk extraembryonic endoderm. It arises from the hypoblastic cells that grow out from the embryonic

disc. The loosely arranged cells called the extraembryonic mesoderm differentiate and surround the amnion and the yolk sac stabilizing their walls. The derivation of both the amnioblasts and extraembryonic mesoderm is not clear. It is supposed that these cells may arise from the cytotrophoblast; the other point of view refers their origination to the embryonic disk cells.

The trophoblast grows, forming processes called the primary chorionic villi that extend toward the endometrium penetrating it. Only the trophoblast makes up the primary villi: the syncytiotrophoblast lies superficially, and the cytotrophoblastic cells underlie it. When the extraembryonic mesoderm grows into the primary villi, they become the secondary chorionic villi. Each secondary villus acquires a mesodermal core enclosed by the cytotrophoblast and the syncytiotrophoblast along the surface. The latter produces the enzymes that lyse and erode the endometrium, forming the cavities called the lacunae. Owing to the high enzymatic activity of the syncytiotrophoblast, the trophoblastic lacunar network is established. The lacunae are filled with maternal blood from ruptured endometrial capillaries. The chorionic villi contact with maternal blood, providing the mother–embryo exchange.

The chorion forms the chorionic sac with the chorionic cavity within it. The embryo, its amnion, and the yolk sac are suspended in this cavity by the connecting stalk from the extraembryonic mesoderm. The connecting stalk attaches the complex of the embryonic disk with its vesicles to the inner surface of the chorionic sac.

The second week of the embryogenesis is often called as “the period of twos”, because two embryonic layers – the epiblast and hypoblast – make up the embryonic disk; two vesicles – the amnion and yolk sac – develop; and two layers of the trophoblast – the cytotrophoblast and syncytiotrophoblast – differentiate.

The distinctive feature of the human embryogenesis is the early development of the provisory organs: the chorion, the amnion, and the yolk sac. The chorion provides exchange between the embryo and the maternal organism, secretes enzymes to erode the endometrium, provides defence of the embryo, especially immune defence, and produces hormones. Human chorionic gonadotropin (hCG) is secreted by the syncytiotrophoblast in maternal blood and is then excreted with maternal urine. This hormone maintains the corpus luteum and stimulates it to continue progesterone production. The detection of hCG in the woman’s urine is a simple, rapid, and an early test to detect pregnancy. Further, the chorion will take part in the placenta formation.

The amnion grows with the embryo and fetus development. It is filled with the amniotic fluid that creates watery environment for the fetus and provides its mechanical defence. It exists and functions up to birth as part of the fetal bladder or the amniochorionic membranes. At the beginning of the parturition, the membranes rupture, and the amniotic fluid flows out into the vagina.

The yolk sac exists only for two months and then undergoes regression; its remnant will be part of the umbilical cord. The yolk sac lacks yolk and does not take part in the embryo nourishment. In its endoderm, primary hemopoiesis and angiogenesis occur. Moreover, from the end of the first week to the beginning of the third week, the primary germ cells, known as gonoblasts, are located in the yolk sac endoderm before they begin their return into the embryo body.

Lecture 32

Human Embryology – II (T.V. Boronikhina)

The embryonic period: the third week of development

Gastrulation

Gastrulation is a process of the germ layer formation. It proceeds in two stages: during the first stage two germ layers – the epiblast and hypoblast – are formed; during the second stage three germ layers – the ectoderm, endoderm, and mesoderm – develop. The first stage of gastrulation occurs on the 7th day, the second stage occurs at the 14th or 15th day of embryogenesis.

In mammalian species, the morphological changes of the second stage of gastrulation take place only in the epiblast. The hypoblast does not take part in the embryo formation; it only gives rise to the yolk sac. The primitive streak, the key structure of the gastrulation second stage, appears in the epiblast. Epiblastic cells from the cranial end of the embryonic disk proliferate and migrate along the disk margins to its caudal end. Cellular currents converge at the disk caudal end, then turn towards the midline, and elongate back to the disk cranial end. The anterior portion of the primitive streak thickens to form the primitive knot or Hensen’s nodule. Concurrently, a narrow primitive groove develops in the primitive streak, which is continuous with a depression in the primitive knot known as the primitive pit.

Since the primitive streak appears, it becomes possible to identify the craniocaudal axis of the embryo, its cranial and caudal ends, and its right and left sides.

The primitive streak is a source of the embryonic mesoderm and embryonic endoderm: epiblastic cells move medially towards the primitive streak and enter the primitive groove. They lose their attachment to the rest of the epiblastic cells and migrate inwardly between the epiblast and hypoblast. The early-migrating cells are those that replace hypoblastic cells to become the endoderm. The later-migrating cells begin to spread laterally, ventrally, and cranially to form the mesoderm. As soon as the primitive streak gives rise to the mesoderm and endoderm, the cells that remain in the epiblast are referred to as the embryonic ectoderm. Thus, the gastrulation is completed: the trilaminar embryo is formed.

Formation of the axial organs

The complex of axial organs includes the following structures: the notochord, the neural tube, and the mesodermal somites.

The notochord is the first to appear. The primitive pit extends into the primitive knot to form the notochordal canal. The cells migrating through this canal give rise to the notochord. The notochordal process looks like a cellular rod extending cranially from the primitive knot between the ectoderm and endoderm. The wing-like mesoderm is on each side of the notochordal process.

The notochord forms a midline axis of the embryo. It is not the embryonic origin of the skeleton (the skeleton arises from the sclerotome); it is the structure, around which the vertebral column forms. The notochord degenerates and disappears where it becomes surrounded by the vertebral bodies, but persists as the nucleus pulposus of the intervertebral disks. The notochord also induces the overlying ectoderm to form the neural plate, i.e., the embryonic induction of neurulation.

Neurulation is a process of the neural tube formation. It includes a sequence of events, by which the neural plate, the neural groove with neural folds, and the neural tube successively develop. As the notochord develops, the embryonic ectoderm over it, the so-called neuroectoderm, thickens to form the neural plate. The developing notochord with the adjacent mesoderm induces this process. On about the 18th day, the neural plate invaginates along the central axis to form the neural groove with neural folds on each side of it. By the end of the third week, the neural folds begin to move and close up, converting the neural plate to the neural tube. The neural tube is then separated from the surface ectoderm that differentiates into the skin epidermis. The neural tube is the primordium of the central nervous system consisting of the brain and the spinal cord.

As the neural folds close, some ectodermal cells lying along and over each fold are not incorporated in the neural tube. They look like a cell mass between the neural tube and the covering ectoderm constituting the neural crest. The latter gives rise to the spinal ganglia and the ganglia of the autonomic nervous system, as well as Schwann cells, the meningeal covering of the brain and the spinal cord (the pia mater and the arachnoid), the skin pigment cells, and the adrenal gland medulla.

The mesoderm on each side of the appeared notochord and neural tube thickens to form the longitudinal columns of the paraxial mesoderm. Each paraxial mesoderm is continuous laterally with the intermediate mesoderm, which gradually thins laterally to form the lateral mesoderm. The paraxial mesoderm begins to divide into paired cuboidal bodies called somites. This series of mesodermal tissue blocks is located on each side of the developing neural tube. Somites are subdivided into three regions: the myotome that gives rise to skeletal muscles; the dermatome that gives rise to the skin dermis; and the sclerotome, from which bone and cartilaginous tissues arise. The intermediate mesoderm, the so-called somite cord, differentiates into nephrogonadotome that gives rise to the kidney and gonads.

Within the lateral mesoderm the space called the coelom appears dividing the lateral mesoderm into two layers: the parietal layer, the somatopleure, and the visceral one, the splanchnopleure. The coelom is then divided into the following body cavities: the pericardial, pleural, and peritoneal ones. The cells of the parietal and visceral layers give rise to the mesothelium lining these cavities. The splanchnopleure takes part in the development of the myocardium, epicardium, and the adrenal gland cortex.

Some mesodermal cells migrate and are disposed among the axial organs; they form a loose origin called the mesenchyme. The mesenchyme gives rise to the blood, all types of connective tissue, smooth muscle cells, blood vessels, microglial cells, and endocardium.

The embryonic endoderm develops into the epithelium of the gastrointestinal tract, the liver, the pancreas, the gallbladder, and the epithelial parts of the lung.

Formation of the primitive cardiovascular system

Blood vessel development, i.e. angiogenesis, begins in the extraembryonic mesoderm of the yolk sac, the connecting stalk, and the chorion; the embryonic vessels begin to develop from mesenchyme about two days later. The primitive heart also arises from mesenchymal cells. It appears as paired

endothelial channels called the endocardial heart tubes. The cardiovascular system is the first system to attain a functional state.

The mesenchymal cells inside the chorionic villi differentiate into blood vessels. These vessels then become connected with the embryonic vessels via the vessels differentiating in the connecting stalk. Angiogenesis and hemopoiesis occur concurrently: the primitive blood cells differentiate from mesenchyme inside embryonic vessels (the so-called intravascular hemopoiesis). By the end of the third week, the embryonic blood begins to circulate through the capillaries of the chorionic villi. The villi containing the blood vessels are called the tertiary villi. Some villi are attached to the maternal tissue and are called the stem or anchoring villi. The villi growing from the stem villi are called the branch villi. The villi absorb nutrients from the maternal blood in the intervillous spaces and excrete wastes from the embryo into them.

The embryonic period: from the fourth to the eighth weeks of development

Early in this period, two longitudinal folds – the cranial and caudal folds – and two transverse folds appear. They convert the flat trilaminar embryonic disk into a C-shaped cylindrical embryo, and the body shape is thus established. During folding, the embryo body is separated from the yolk sac, and the primitive gut is formed.

The three germ layers differentiate into various tissues and organs, so that by the end of the embryonic period all the main organ systems begin to develop, but the function of most organs is minimal. That is why the period from the 4th to the 8th weeks is the most critical period of the embryonic development. Developmental disturbances during this period may give rise to major congenital malformations.

Placentation

During pregnancy, the endometrium is called the decidua graviditas, because it will be shed with the placenta at parturition. Three different regions of the decidua are identified by their relationship to the site of implantation:

- (1) the decidua basalis is the portion of the endometrium that underlies the implantation site;
- (2) the decidua capsularis is a thin portion of the endometrium that lies between the implantation site and the uterine lumen;
- (3) the decidua parietalis includes the remaining endometrium.

As the fetus grows to the point, at which the overlying decidua capsularis fuses with the decidua parietalis of the opposite wall, the uterine cavity obliterates. Concurrently with the fetus development, the amnion enlarges so that the amniotic wall becomes fused with the chorionic wall and underlies it. The developing fetus is disposed inside the amnion. The amniotic fluid surrounds and bathes the fetus body. The fetus and its amnion completely fill the chorionic cavity.

Up to about the 8th week, the chorionic villi cover the entire surface of the chorionic sac. As the sac grows, the villi associated with the decidua capsularis become compressed, their blood supply reduced; subsequently, these villi begin to degenerate, producing a relatively avascular area known as the smooth chorion or the chorion laeve. The villi associated with the decidua basalis rapidly increase in number, branch, and enlarge. This portion of the chorionic sac is known as the villous chorion or the chorion frondosum. Thus, the chorion is divided into two parts: the villous chorion that faces the decidua basalis and takes part in placenta formation and the smooth chorion that faces the decidua capsularis and represents one of the membranes enveloping the fetus. The fetal membranes make up the fetal bladder and are as follows from inside outwards: the amniotic wall, the smooth chorion, and the thinnest layer of the decidua capsularis.

The placenta is a combined organ: both the fetus and the maternal body take part in its formation. The fetal portion of the placenta is formed by the villous chorion; the maternal portion is represented by the decidua basalis. These two parts are involved in the physiological exchange of substances between the maternal and fetal circulation. The shape of the placenta is determined by the form of the villous chorion: the latter is circular, imparting to the placenta a discoid shape.

The fetal part of the placenta includes the chorionic plate, a layer of extraembryonic connective tissue containing large blood vessels coming from the fetus body through the umbilical cord. The tertiary villi arise from the chorionic plate and project into the intervillous spaces or lacunae containing the maternal blood. The tertiary villi are formed by the end of the third week, when the blood vessels have been developed in the cores of the secondary villi. Some villi are attached to the maternal tissues and called the stem or anchoring villi. At the sites of attachment, the cytotrophoblastic cells penetrate the syncytiotrophoblastic layer to form the cytotrophoblastic shell, by which the villi are attached to the endometrium. The villi that grow from the stem villi are called the branch or the floating villi; they float in the lacunae and are bathed by the maternal blood. The main fetoplacental exchange occurs here,

through the branch villi. The syncytiotrophoblast is highly invasive; as a result, there is considerable necrosis of the decidua basalis and deposition of the fibrinoid material. A more or less continuous layer of the fibrinoid material separates the fetal and maternal parts of the placenta. The amnion underlies the chorionic plate and continues as a covering of the umbilical cord that is attached to the fetal surface. The umbilical cord vessels are subdivided on the fetal surface to form the chorionic vessels, which supply the villi.

The maternal part of the placenta is represented by the decidua basalis. This comprises all the endometrium beneath the fetal component of the placenta, except the deepest part called the decidual plate. This layer remains after parturition and is involved in the subsequent regeneration of the endometrium. A characteristic feature of the decidua is the decidual cells. They are large, pale, and rich in glycogen and lipids. They begin to appear just after implantation, which initiates the decidual reaction of the endometrium, when stromal cells undergo transformation into decidual cells. The full significance of the decidual reaction is not understood at present. It is suggested that the decidual cells may provide some nourishment for the embryo, protect the maternal tissues against uncontrolled invasion by the trophoblast, and create a specialized layer facilitating the placenta separation from the uterine wall at the termination of pregnancy. They secrete the peptide hormone relaxin involved in the softening of the cervix and the pelvic ligaments in preparation for parturition.

As the villi invade the decidua basalis, they leave several wedge-like areas of the endometrium called the placental septa. They arise from the decidua basalis and divide the placenta into 15 to 25 irregular lobules called the cotyledons. Each cotyledon consists of two or more main stem villi and their many branches.

Placentation results in the establishment of the uteroplacental circulatory system. Fetal blood enters the placenta through paired umbilical arteries. As the arteries pass into the placenta, they branch into several vessels in the chorionic plate and then in the villi, forming an extensive capillary network in close association with maternal blood-filled lacunae. Fetal blood returns through a system of veins that converge on a single umbilical vein.

The maternal blood reaches the placenta through the spiral endometrial arteries penetrating the basal plate and flows into the base of the intervillous spaces. The lacunae are divided into compartments by the placental septa, but because the septa do not reach the chorionic plate, there is a communication between the compartments. The differential pressure between the arterial and venous vessels that communicate with the lacunae establishes directional flow from the maternal arteries into the maternal veins, thereby establishing a primitive uteroplacental circulation. Maternal blood circulates through the intervillous spaces, delivering nutritive and other substances necessary for embryonic and fetal development, and carries away the waste products of fetal metabolism.

Fetal blood never mixes with maternal blood. This separation of the fetal and maternal blood, referred to as the placental barrier, is maintained primarily by the layers of the fetal tissues. The placental barrier consists of the syncytiotrophoblast, cytotrophoblast, the trophoblastic basal lamina, villous connective tissue, the endothelial basal lamina, and the endothelium of the fetal capillaries in the tertiary villi. By the last trimester of pregnancy the barrier becomes very thin: the inner cytotrophoblastic layer degenerates, connective tissue disappears, and fetal capillaries become disposed just below the syncytiotrophoblast. This thinning serves to facilitate the exchange of products through the placental barrier.

The selective exchange between fetal and maternal blood is the main placental function. Oxygen and carbon dioxide pass through the placental barrier by simple diffusion. Fetal hypoxia primarily results from the factors that diminish either the uterine blood flow or the fetal blood flow. Nutrients, water, free fatty acids, vitamins, and glucose are transported through the barrier. There is little or no transfer of maternal cholesterol, triglycerides, and phospholipids. Electrolytes are freely exchanged across the placenta. When a mother receives intravenous fluid, they also pass to the fetus and affect its water and electrolyte status. Urea and uric acid pass through the placental barrier by simple diffusion.

Hormones of protein nature do not reach the fetus in significant amounts, except thyroxine and triiodothyronine. Steroid hormones cross the placental barrier freely. Testosterone passes through the placenta and may cause masculinization of the female fetus.

Antibodies can pass through the barrier and enter the fetal circulation to provide passive immunity against such diseases as diphtheria, smallpox, and measles, but no immunity is acquired to pertussis (whooping cough) and chickenpox.

Red blood cells may pass in either direction through breaks in the placental barrier. If the fetus is Rh-positive and the mother Rh-negative, the fetal cells may stimulate the formation of anti-Rh antibodies

by the mother. These pass into the fetal bloodstream and cause hemolysis of the fetal Rh-positive blood cells and anaemia in the fetus.

Most drugs freely cross the placenta by simple diffusion; many of them cause congenital malformations. Fetal drug addiction may occur after maternal use of drugs such as heroin.

Infectious agents, such as viruses of measles and poliomyelitis, may pass through the barrier and cause fetal infection. In some cases (rubella virus), congenital malformations may be produced. The etiological agent of syphilis may cross the placenta, causing congenital syphilis of the fetus.

The placental barrier does not exclude many potentially dangerous agents (alcohol, nicotine, and heavy metals). Therefore, during pregnancy there is need to avoid the use of these agents to reduce the risk of damage to the embryo or fetus.

The placenta, particularly during early pregnancy, synthesizes glycogen, cholesterol, and fatty acids, serving as a source of nutrients and energy for the embryo. Placental syncytiotrophoblast releases the enzymes to erode the maternal endometrium.

The placenta is a major endocrine gland producing steroid and protein hormones: progesterone, estrogens, human chorionic gonadotropin (hCG), human placental lactogen (hPL) or human chorionic somatomammotropin (hCS), and several growth factors. Immunocytochemical studies show the syncytiotrophoblast to be the site of hormone synthesis.

The umbilical cord

As the amniotic sac enlarges, the amnion sheathes the umbilical cord, forming its covering. The umbilical cord usually contains two arteries and one vein surrounded by mucoid connective tissue arising from the extraembryonic mesoderm of the connecting stalk. Because the umbilical vessels are longer than the cord, the vessels frequently form loops. The umbilical cord also includes the remnants of the yolk sac and allantois.

The allantois

The allantois appears on about the 16th day as a relatively thin finger-like projection from the embryo into the connecting stalk. It remains very small in the human embryo. During the second month, the extraembryonic portion of the allantois degenerates, but its remnant may be seen in the umbilical cord. It is involved in blood formation and angiogenesis. Its intraembryonic portion is associated with the development of the urinary bladder.

The yolk sac

By the 9th week, the yolk sac shrinks, forming a small pear-shaped remnant that exists as part of the umbilical cord. The yolk sac functions to produce the first blood cells and blood vessels. In addition, the primordial germ cells appear in its wall in the third week and subsequently migrate to the developing gonads, where they become either spermatogonia or oogonia.

The amnion

The amnion is a sac surrounding the embryo. As the amnion enlarges, it gradually obliterates the chorionic cavity and sheathes the umbilical cord, forming its epithelial covering. Its junction with the embryo is located on the ventral surface of the body. The amniotic fluid is derived from the maternal blood by transport across the amnion; the amniotic cells also take part in the fluid production. Fetal swallowing of amniotic fluid is a normal occurrence. Most of the fluid passes into the gastrointestinal tract, but some of it passes into the lungs. In either case, the fluid is absorbed into the fetal circulation and then passes into the maternal circulation via the placental barrier. The amniotic fluid contains water, approximately equal portions of organic and inorganic salts, and desquamated fetal epithelial cells. Because fetal urine is added to the amniotic fluid, studies of the fetal enzyme system, amino acids, hormones, and other substances can be conducted using the fluid removed by amniocentesis. Studies of cells in the amniotic fluid allow the fetal sex and chromosomal abnormalities to be determined. The amnion creates a protective buffer for the embryo like a water cushion, helps to control the embryo body temperature, and enables the fetus to move freely, thus aiding in musculo-skeletal development.

