

## How to read x-rays?

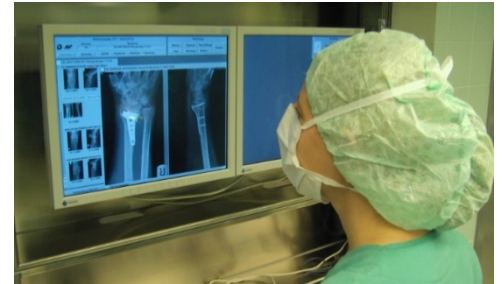### Disclaimer

All contents of this study guide are owned by AO Foundation/AO Trauma and cannot be used for any other than private purposes. This work may only be used for your private education.

### How to use this handout?

The left column is the information as given during the lecture. The column at the right gives you space to make personal notes.

Knowledge on the characteristics of x-rays is required.



## Learning outcomes

At the end of this lecture you will be able to:

- Read x-rays systematically
- Describe fracture patterns
- Interpret healing of fractures

## Physical facts of x-rays

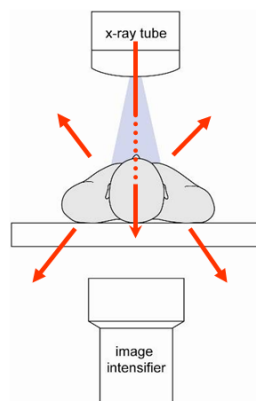
### Scattered radiation

Radiation not absorbed by the patient is scattered. This scattered radiation can affect the team and surgeon.

In this example, the x-ray tube is emitting photons, which are either reflected or absorbed by the patient.

Just a fraction of the x-rays, 800 photons, pass through the patient to the image intensifier.

For every thousand photons reaching the patient, 100–200 photons are scattered. Just 20 reach the image detector. The rest are absorbed by the patient. This is the radiation dose.



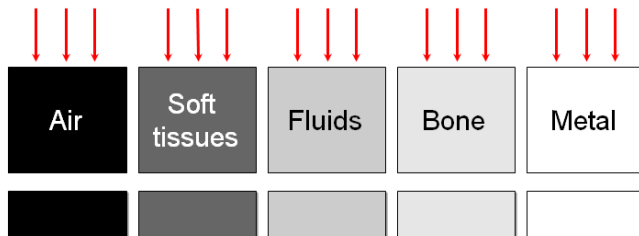
### X-ray projection

X-ray projection depends on the thickness of the tissue that is to be penetrated.

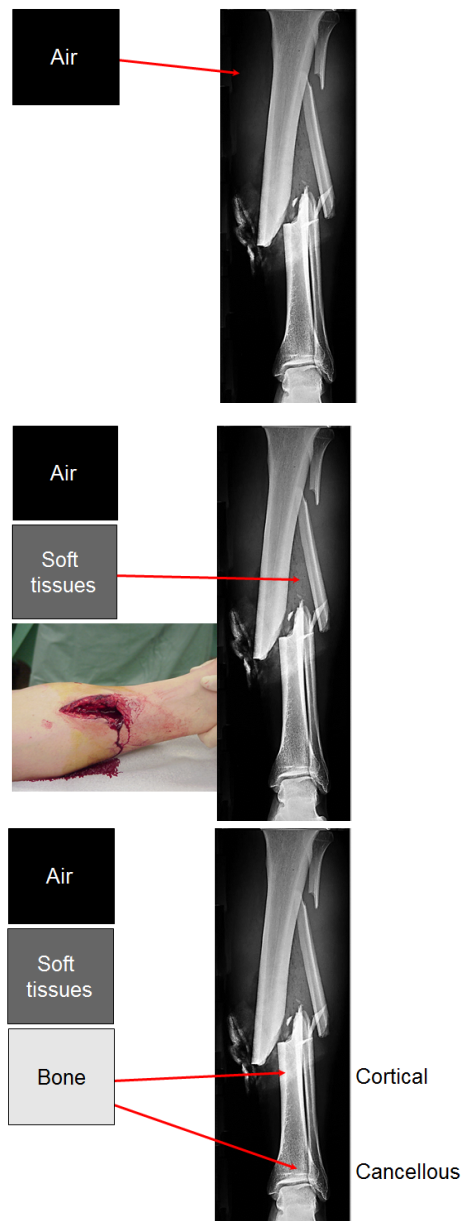
When there is no tissue to penetrate, the color of the picture will be black.

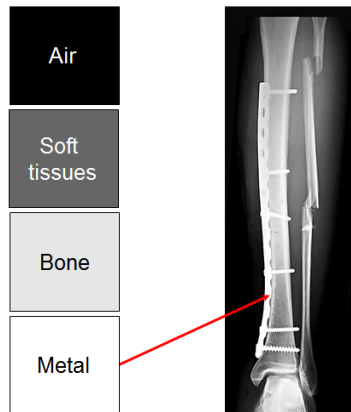
The greater the depth, the lighter the grey.

- Air is projected as black
- Soft tissues are grey
- Fluids are a lighter grey
- Bone is an even lighter grey
- Metal is projected as white



**Example**



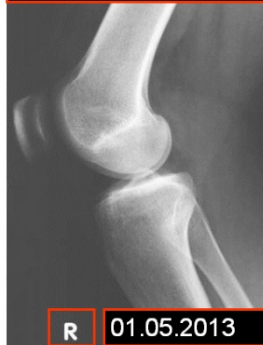

## Systematic reading of x-rays

Information found on the x-ray are:

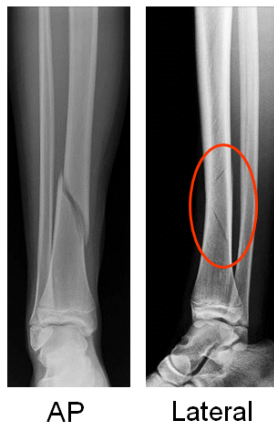- Name and date of birth of the patient
- Side of extremity/body
- Date of x-ray

John Doe, 20.05.1970



Two views help to fully describe the fracture in both planes.

It is easy to miss a fracture with only one view (see red circle).

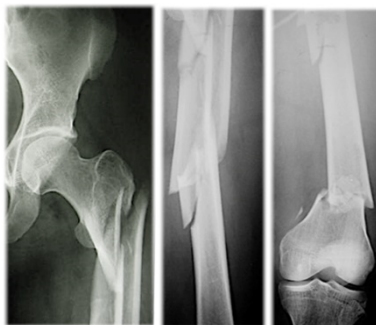


AP

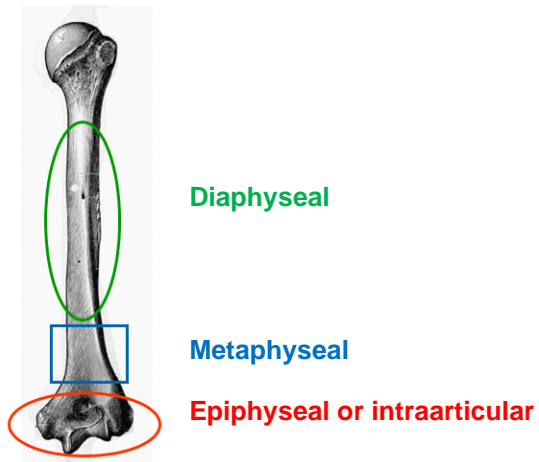
Lateral

X-rays of the two adjacent joints must be taken. Just a shaft view is not enough.

- One of the two fractures could be missed in an x-ray not showing the entire bone.
- Or, a joint injury could be missed with just one x-ray.
- Both adjacent joints need to be seen.

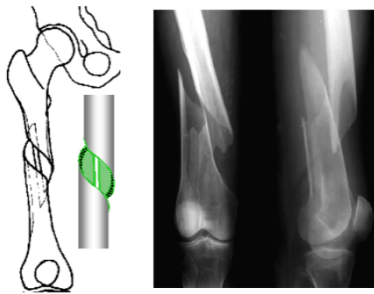


In a next step the bone and the fractured part of the bone are identified.

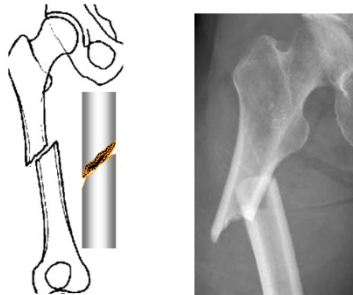


The type of fracture is identified:

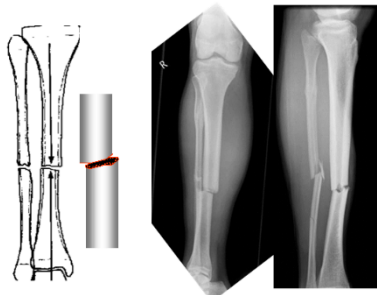
1. Simple spiral fracture



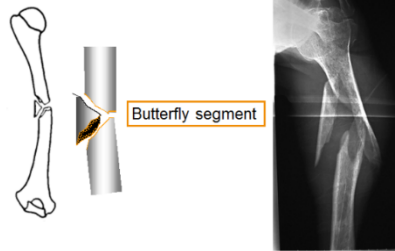
2. Simple oblique fracture



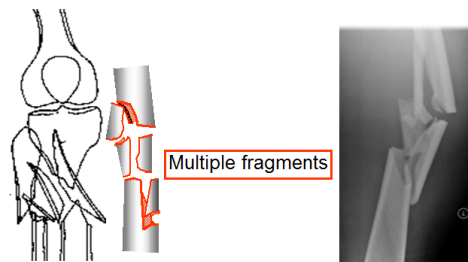
3. Simple transverse fracture



4. Wedge fracture



5. Multifragmentary (comminuted) fracture

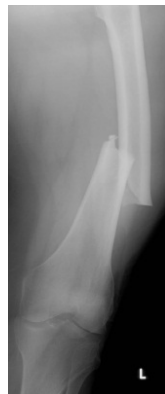

Also the fracture displacement is described.

- Shortening
- Angulation
- Rotation

This x-ray shows a short oblique fracture of the left femur with:

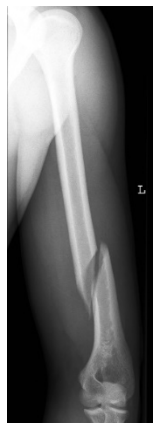- Medial dislocation
- Shortening of at least 3 cm
- Varus displacement



**Question 1**

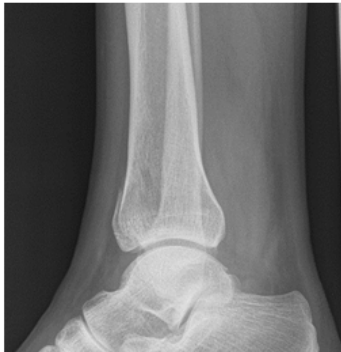Identify the fracture

1. Which bone?
2. Which part of the bone?
3. Which type of fracture?

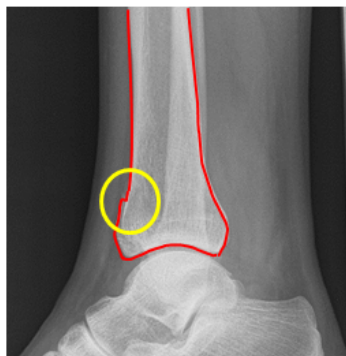


## More about x-rays

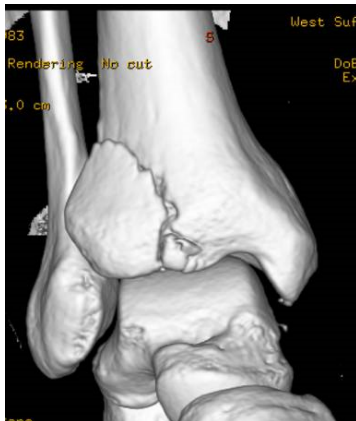How to spot a difficult fracture?



Follow the cortex of the bone and look for any defects.

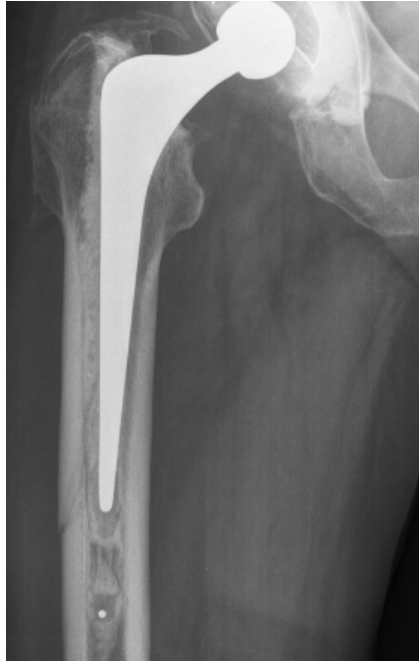

Get more information with a scan.



Question 2

Locate the fracture?

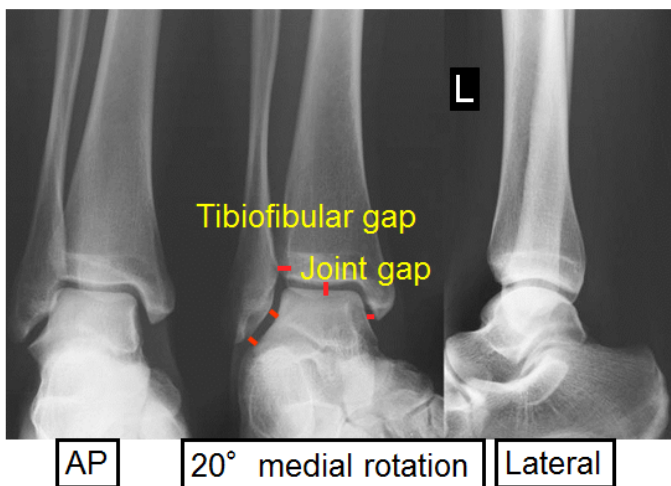


Articular fractures

Malleoli

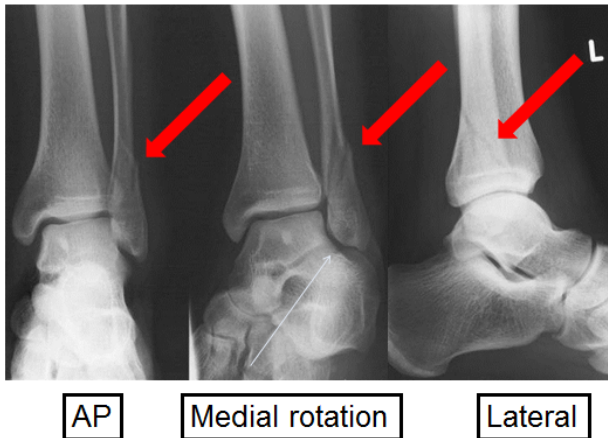
Normal aspect of malleoli:

- Tibiofibular gap is less than 6 mm.
- Joint gap is of equal width.
- Joint surfaces are parallel to each other.
- Talus is in correct position.



Fractured malleoli

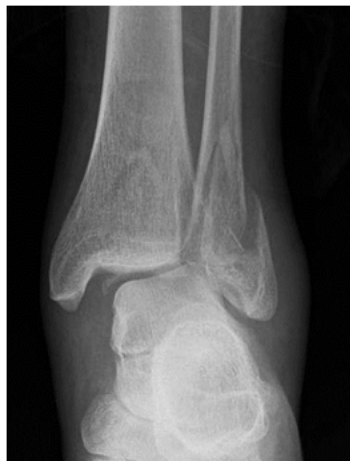- The following x-ray shows a shortened fibula.
- The joint gap between the lateral ankle and talus is no longer parallel.
- The fibula is rotated and fractured.



**Question 3**

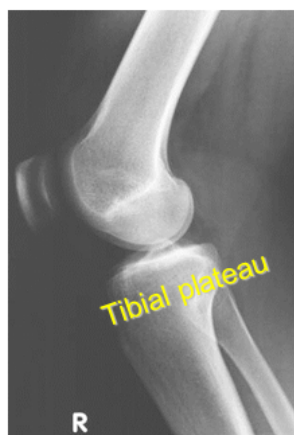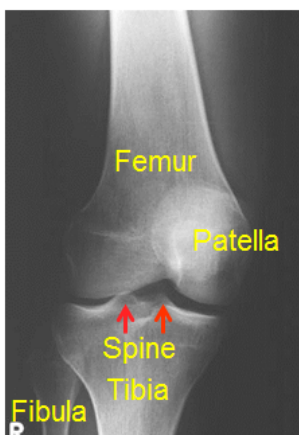
Describe this fracture.

1. What about the joint gap?
2. What about the fibula?



**Knee**

Normal aspect of the knee:

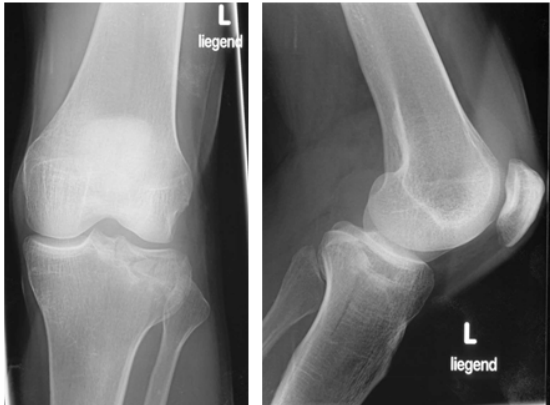

- There is no fracture or arthrosis.
- The position of the tibia toward the femur is correct.
- The position of the patella is correct (not too high, not too low).
- The articular surface of the tibial plateau is intact and at the same level on both sides.



**Question 4**

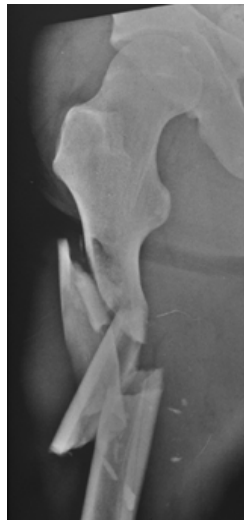Describe this fracture.



**Question 5**

Describe the fracture.

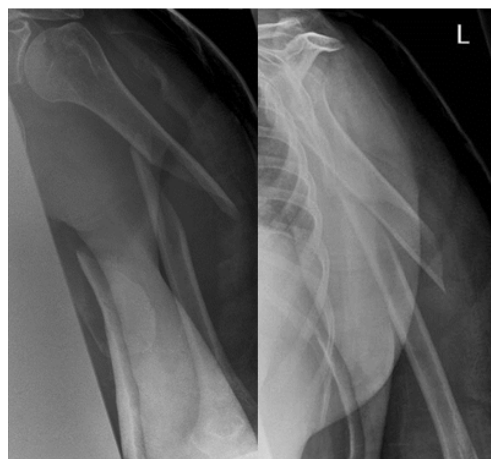1. Which bone?
2. Which part of the bone?
3. Which type of fracture?



**Question 6**

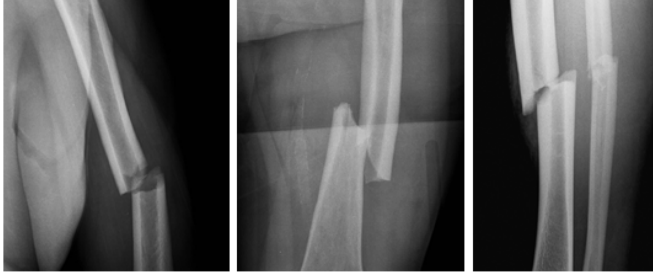Describe the fracture.

1. Which bone?
2. Which part of the bone?
3. Which type of fracture?



**Question 7**

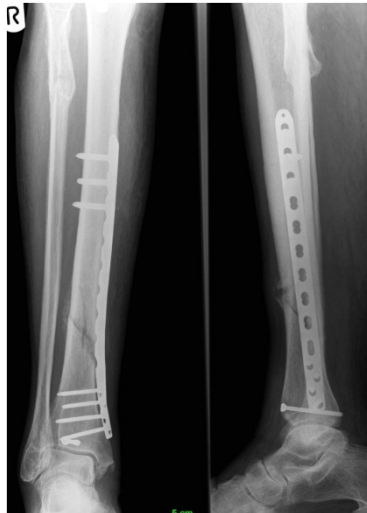Which bone?



**Question 8**

x-ray 8 weeks post-op

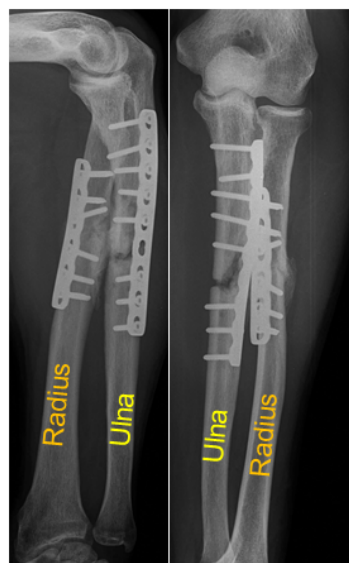
What do you see here?  
What would you tell the patient?



**Question 9**

8 months post-op

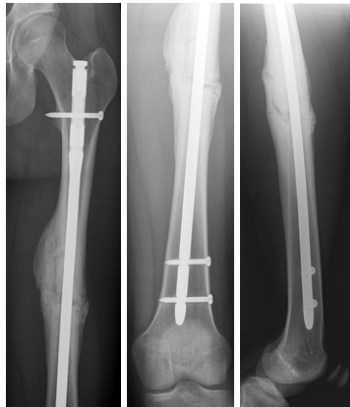What do you see here?  
What would you tell the patient?



**Question 10**

3 months post-op

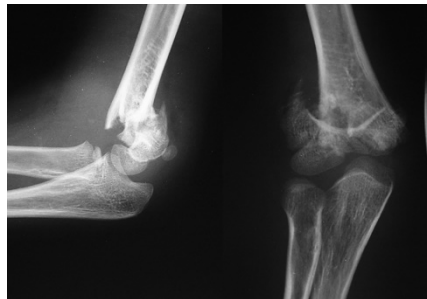
What do you see here?  
What would you tell the patient?



**Question 11**

How old is the patient?

What is your diagnosis?



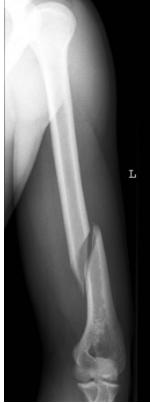**Summary**

You should now be able to:

- Read x-rays systematically
- Describe fracture patterns
- Interpret healing of fractures

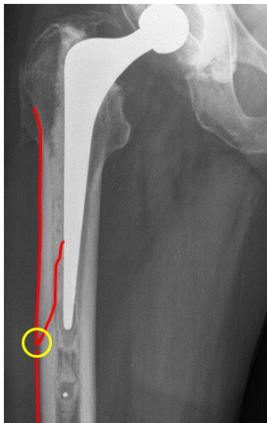## Answers on in-course questions

### Question 1

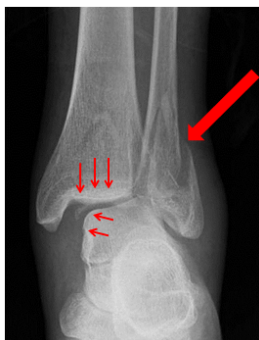

1. Humerus
2. Diaphyseal
3. Spiral

### Question 2

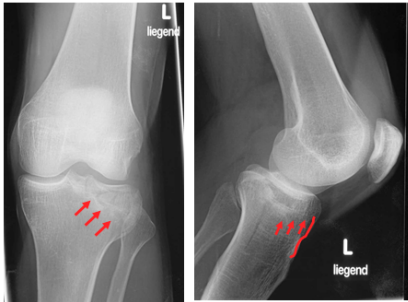


### Question 3



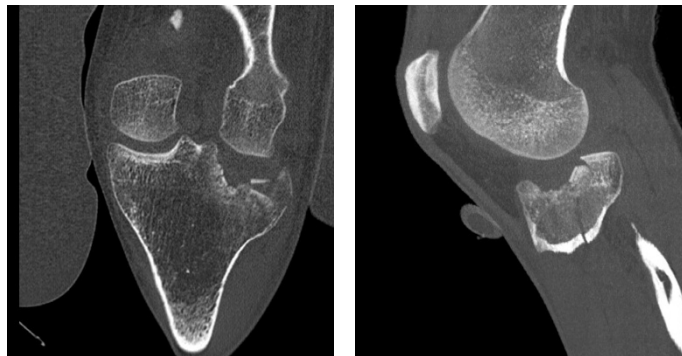
- The fibula is shortened and rotated due to a dislocated fracture.
- The talus is subluxated laterally.
- The joint gap is no longer parallel and not of equal width.

Question 4



If we compare the medial and the lateral tibial head, we see that:

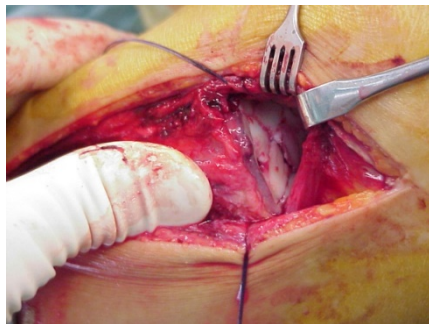
- There is an intact plateau medially.
- There are fracture lines and hyperdense zones laterally (ie, compression fractures of cancellous bone).
- This is an indication for a CT scan to clearly visualize the whole fracture.



More information is needed. A CT-scan is made.

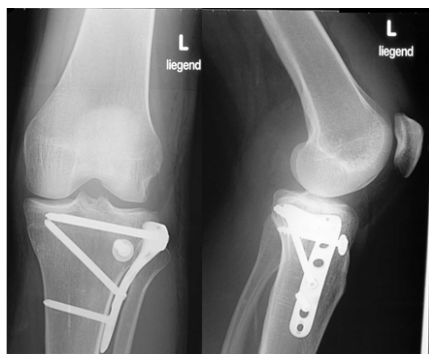
Treatment of this fracture includes

1. Intraoperative reduction of tibia plateau

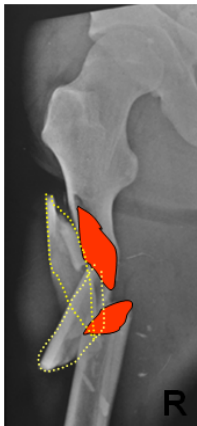


2. Surgical treatment:

- L-plate 4.5 mm
- Cancellous bone screw 6.5 mm (lag screw) and washer

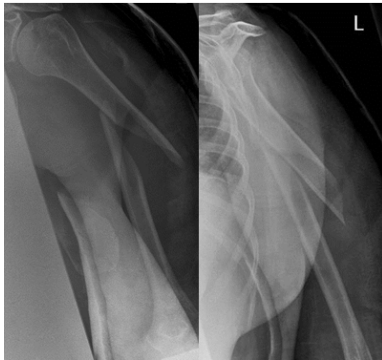

**Question 5**



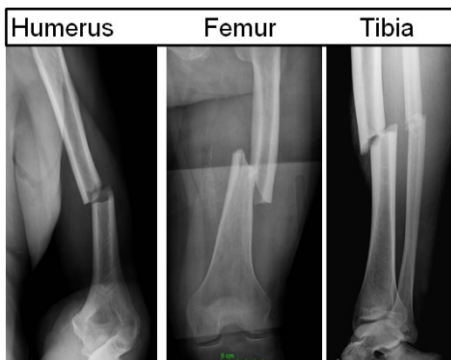
- Right femoral fracture
- Subtrochanteric fracture
- Multifragmentary

**Question 6**

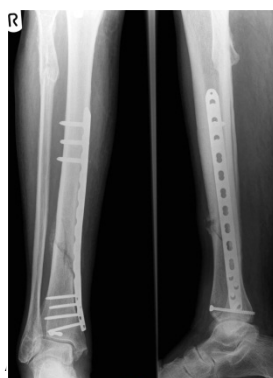

- Humeral
- Diaphyseal
- Spiral

**Question 7**



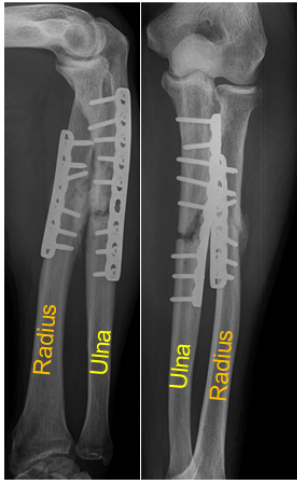
**Question 8**



This x-ray shows an osteosynthesis with plate and screws in a tibial fracture after 8 weeks.

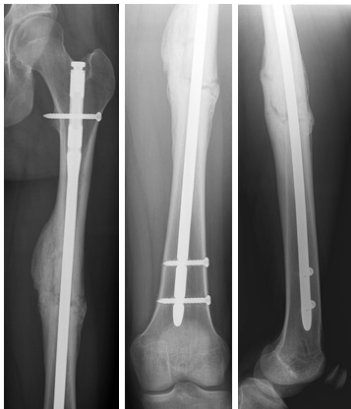- The fracture is still visible, which is normal after only 8 weeks, without axial malalignment.
- There is minimal callus formation on the lateral side.
- There is no screw loosening. The osteosynthesis is stable.
- Fracture healing is underway.

**Question 9**



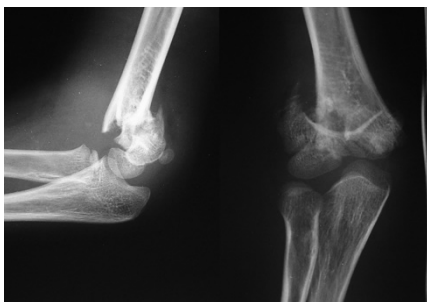
- The radial fracture is healing.
  - There is little callus on the radius.
- The ulnar fracture is still open.
  - There is a large gap in the ulna without any visible callus formation yet. This is called atrophic pseudarthrosis.
- There is no screw loosening. The plates are (still) stable.
- After 8 months no further healing can be expected.
- Reoperation of the ulna is indicated.

**Question 10**



- This fracture is stable. There is healing with callus formation.
- Recommend doing a follow-up plus x-ray in 1 year.

**Question 11**



- This is the x-ray of a child of 8 years of age with open epiphyseal lines.
- The patient has a dislocated supracondylar fracture of the humerus.