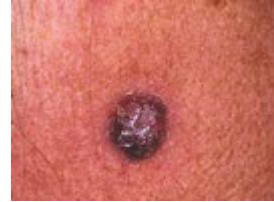

Terminology in dermatology

Lesion

A lesion is any single area of altered skin. It may be solitary or multiple.



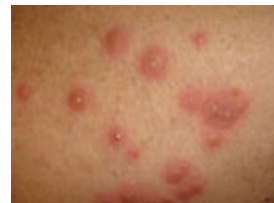Rash

A rash is a widespread eruption of lesions.



Dermatosis

Dermatosis is another name for skin disease.



When examining the skin, a dermatologist assesses distribution, morphology and arrangement of skin lesions, i.e. their number, size and colour, which sites are involved, their symmetry, shape and arrangement.

The dermatologist will carefully feel individual lesions, noting surface and deep characteristics.

Which layer(s) of the skin are involved? If scaly, does the surface flake off easily? If crusted, what is underneath?

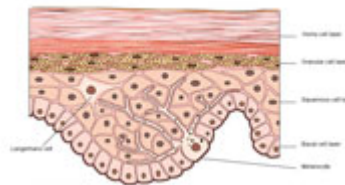
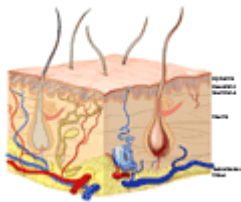
Specialised techniques include:

- Wood's light (long wave UVA) examination for pigmentary changes and fluorescent infections
- [Dermoscopy](#) for pigmented lesions to diagnose melanoma

Structure of the skin

The skin is considered to have three parts: the outer epidermis, middle dermis and deep subcutaneous tissue. There is a basement membrane that separates the epidermis from the dermis and acts as a communication channel between the two layers.

Structure of the skin



Images provided by University of Auckland

Epidermis

The epidermis is a complex 'brick wall' made of cells called **keratinocytes**, which produce a protein called **keratin**. The epidermis also contains pigment cells called **melanocytes**, which produce **melanin**, **Langerhans cells**, which present antigens to the immune system, and **Merkel cells**, which have a sensory function.

- **Basal layer:** the columnar or rectangular cells at the bottom of the epidermis from which new cells are continuously produced. Scattered melanocytes are normally found in this layer.
- **Squamous cells:** as the keratinocytes mature and move upwards towards the skin surface, they become flat in shape, or squamous (also called spinous or prickle cells). Langerhans cells are found in this layer.
- **Granular layer:** flattened cells filled with dark granules containing **keratohyaline** protein.
- **Horny layer:** stacks of dead cells without nuclei make up the dry or keratinised stratum corneum. The top layer of cells loosens and falls off.

- **Desmosomes:** the structures that stick adjacent keratinocytes tightly together, rather like cement between bricks.

Epidermal appendages include:

- **Eccrine glands**, which produce sweat
- **Apocrine glands**, scent glands found in armpits and groins
- **Pilosebaceous structures** containing hair and sebaceous glands (oil glands)
- **Nails**

Dermis

The dermis is made up of connective tissue that supports the epidermis, providing nutrients and protecting it. The papillary dermis is the upper portion beneath the epidermis and the lower portion is the reticular dermis.

- **Collagen:** protein fibres arranged in bundles providing strength to the skin.
- **Elastin:** protein making up fibres that allow the skin to stretch
- **Ground substance:** gel containing hyaluronic acid and other polysaccharides.
- **Fibroblasts:** cells that produce collagen, elastin and ground substance.
- **Nerves:** sensory and autonomic fibres with distinct nerve endings for touch, heat, cold, pressure and pain.
- **Blood vessels:** arteries, arterioles, capillaries, venules and veins carrying blood to and from the skin.
- **Lymphatics:** extensive network of thin-walled vessels nourishing and draining the skin.
- **Arector pili muscles:** attached to hair follicles. Contraction results in goose bumps.
- **Cellular infiltrations:** immune cells around blood vessels, and recruited in great numbers to heal wounds and fight infection. Many skin diseases are characterised by specific patterns of these cells.

Subcutaneous tissue

The subcutaneous tissue, also called subcutis, is made up of **adipose cells** or **lipocytes** (fat cells). These are surrounded by connective tissue, blood vessels and nerves.

Distribution

Distribution refers to how the skin lesions are scattered or spread out. Skin lesions may be isolated (solitary or single) or multiple. The localisation of multiple lesions in certain regions helps diagnosis, as skin diseases tend to have characteristic distributions. What is the extent of the eruption and its pattern?

Acral

Affects distal portions of limbs (hand, foot) and head (ears, nose).

Blaschko's lines

Following a roughly linear, segmental pattern described by Blaschko and thought to be indicative of somatic mosaicism.

Dermatomal

Corresponding with nerve root distribution.

Extensor

Involving extensor surfaces of limbs. Contrast with **flexor** surfaces.

Flexural

Involving skin flexures (body folds); also known as **intertriginous**.

Follicular

Individual lesions arise from hair follicles. These may be grouped into confluent plaques.

Generalised

Universal distribution: may be mild or severe, **scattered** or **diffuse**

Herpetiform

Grouped umbilicated vesicles, as arise in *Herpes simplex* and *Herpes zoster* infections.

Koebnerised

Arising in a wound or scar. The Koebner phenomenon refers to the tendency of several skin conditions to affect areas subjected to injury.

Photosensitive

Favouring sun exposed areas. Does not affect skin that is always covered by clothing.

- Head & neck: spares eyelids, depth of wrinkles & furrows, areas shadowed by hair, nose & chin. Typically involves V of neck.
- Backs of hands: spares finger webs. More severe on proximal than distal phalanges.
- Forearms: extensor rather than flexor.
- Feet: dorsal surface, sparing areas covered by footwear.
- Lower legs: may affect extensor and/or flexor surfaces
- Trunk: rarely affected

Pressure areas

Affecting areas regularly prone to injury from pressure at rest.

- Tops of the ears when sleeping
- Buttocks when sitting
- Heels when lying

Seborrhoeic

The areas generally affected by seborrhoeic dermatitis, with a tendency to oily skin (seborrhoea). Scalp, behind ears, eyebrows, nasolabial folds, sternum and interscapular.

Symmetrical

In the same regions, the left side is affected in a similar way to the right side.

Truncal

Favours trunk and rarely affects limbs.

Unilateral

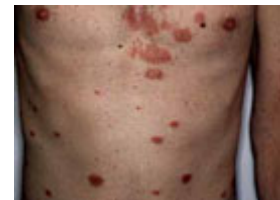Wholly or predominantly on one side of the affected region.

Configuration of Lesions

Configuration refers to the shape or outline of the skin lesions. Skin lesions are often grouped together. The pattern or shape may help in diagnosis as many skin conditions have characteristic configuration.

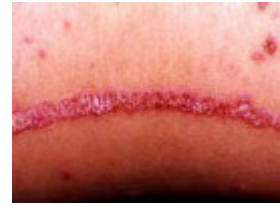Nummular lesion

Round (coin-shaped) lesions. Also known as **discoid**.



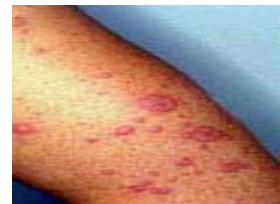Linear lesion

A linear shape to a lesion often occurs for some external reason such as scratching.
Also **striate**.



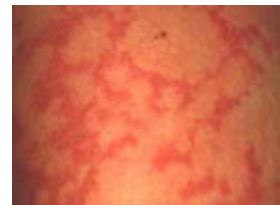Target lesion

Concentric rings like a dartboard. Also known as **iris lesion**.



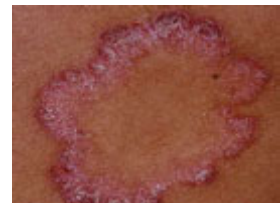Gyrate rash

A rash that appears to be whirling in a circle.



Annular

Lesions grouped in a circle.



Colour

Descriptive terms used to describe skin colour include:

Carotenaemia

Excessive circulating beta-carotene (vitamin a precursor derived from yellow/orange coloured vegetables and fruit) results in yellow/orange skin colouration. Tends to be pronounced on palms and soles. Does not affect cornea.

Hyperpigmentation

Hypermelanosis or haemosiderin deposits result in skin colour that is darker than normal.

Hypopigmentation

Loss of melanin results in skin colour that is paler than normal but not completely white.

Leukoderma

White skin. Also known as **achromia**.

Infarcts

Infarcts are black areas of necrotic tissue due to interrupted blood supply.

Jaundice

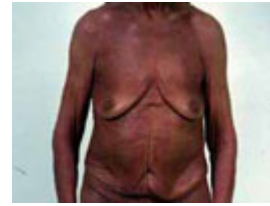Excessive circulating bilirubin results in yellow/green skin colour, prominent in cornea.

Erythema

Red skin due to increased blood supply and blanch with pressure (diascopy).

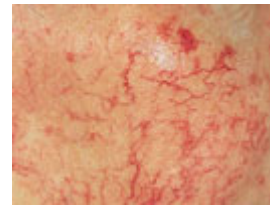
Erythroderma

The skin condition affects the whole body or nearly the whole body, which is red all over.



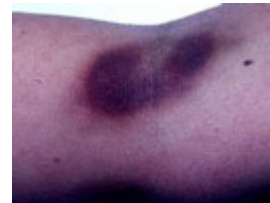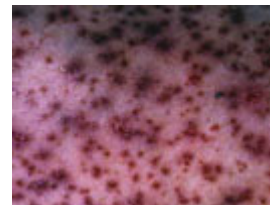
Telangiectasia

Telangiectasia is the name given to prominent cutaneous blood vessels.



Purpura

[Purpura](#) is bleeding into the skin. This may be as **petechiae** (small red, purple or brown spots) or **ecchymoses** (bruises). Purpura does not blanch with pressure (diascopy).



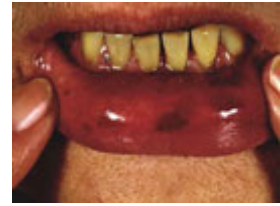Morphology

Morphology is the form or structure of an individual skin lesion.

- Skin lesions may be **flat**, **elevated** above the plane of the skin or **depressed** below the plane of the skin.
- They may be **skin coloured** or **red, pink, violaceous, brown, black, grey, blue, orange, yellow**.
- Consistency may be **soft, firm, hard, fluctuant** or **sclerosed** (scarred or board-like).
- The lesions may be **hotter** or **cooler** than surrounding skin.
- They may be **mobile** or **immobile**.

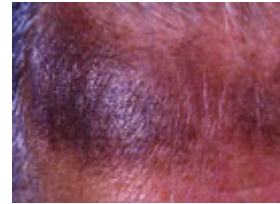Macule

A macule is an area of colour change less than 1.5 cm diameter.
The surface is **smooth**.




Patch

A patch refers to a large area of colour change, with smooth surface.



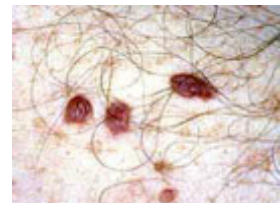Papule

Papules are small palpable lesions. The usual definition is that they are less than 0.5 cm diameter, although some authors allow up to 1.5 cm. They are raised above the skin surface, and may be **solitary** or **multiple**.



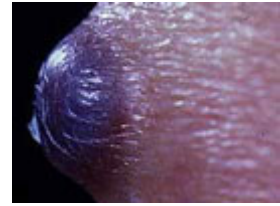
Papules may be:

- **Acuminate** (pointed)
- **Dome-shaped** (rounded)
- **Filiform** (thread-like)
- **Flat-topped**
- **Oval or round**
- **Pedunculated** (with a stalk)
- **Sessile** (without a stalk)
- **Umbilicated** (with a central depression)
- **Verrucous** (warty)



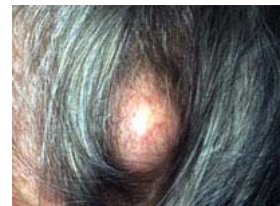Nodule

A nodule is an enlargement of a papule in three dimensions (height, width, length). It is a solid lesion.



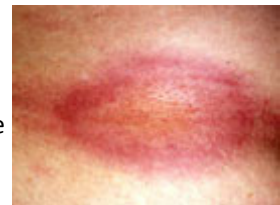Cyst

A cyst is a papule or nodule that contains fluid so is fluctuant.



Plaque

A plaque is a palpable flat lesion greater than 0.5 cm diameter. Most plaques are elevated, but a plaque can also be a thickened area without being visibly raised above the skin surface. They may have well-defined or ill-defined borders.

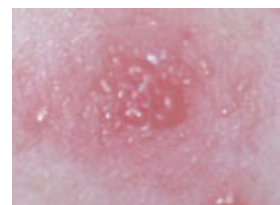

Plaques may be:

- **Annular** (ring shaped)
- **Arcuate** (half-moon)
- **Polygonal** (varied non-geometric shape)
- **Polymorphic** (varied shape)
- **Serpiginous** (in the shape of a snake)
- **Poikilodermatous** (variegated appearance, usually mixed pallor, telangiectasia & pigmentation)

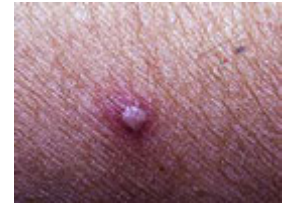Vesicle

Vesicles are small fluid-filled blisters less than 0.5cm diameter. They may be single or multiple.



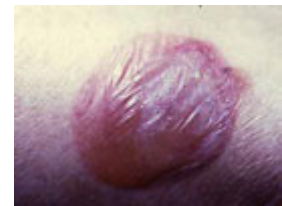Pustule

A pustule is a purulent vesicle. It is filled with neutrophils, and may be white, or yellow. Not all pustules are infected.



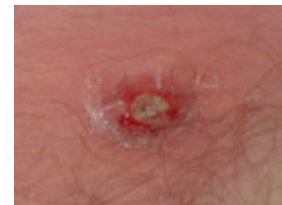Bulla

A bulla is a large fluid-filled blister. It may be a single compartment or multiloculated.



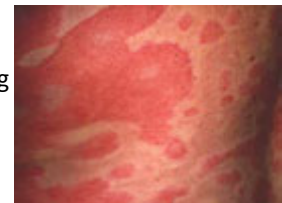Abscess

An abscess is a localised collection of pus.



Weal

A wheal is an oedematous papule or plaque caused by swelling in the dermis. Wealing often indicates urticaria.



Skin surface

The skin surface of a skin lesion may be normal or smooth because the pathological process is below the surface, either dermal or subcutaneous. Surface changes indicate epidermal changes are present.

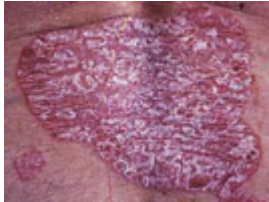
Scaling

Scaling or **hyperkeratosis** is an increase in the dead cells on the surface of the skin (stratum corneum).

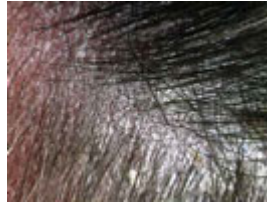Descriptive terms for scale include:

- **Desquamation** (skin coming off in scales)
- **Psoriasiform** (large white or silver flakes)
- **Pityriasiform** (branny powdery scale)
- **Lichenoid** (apparent scale is tightly adherent to skin surface)
- **Keratotic** (horny scale)
- **Exfoliation** (peeling skin)

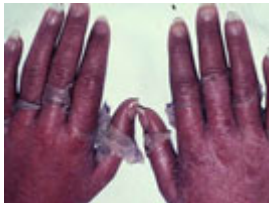- **Maceration** (moist peeling skin)
- **Verrucous** (warty)



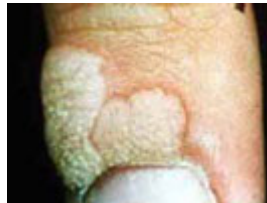Psoriasiform scale



Pityriasiform scale



Exfoliation

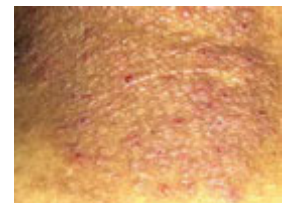

Verrucous scale

Secondary changes

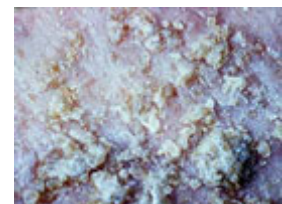
Lichenification

Lichenification is caused by chronic rubbing, which results in palpably thickened skin with increased skin markings and lichenoid scale. It occurs in chronic atopic eczema and lichen simplex.



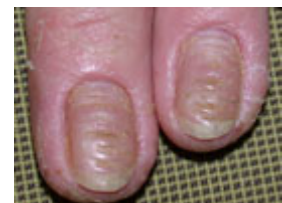Crusting

Crust occurs when plasma exudes through an eroded epidermis. It is rough on the surface and is yellow or brown in colour. Bloody crust appears red, purple or black.



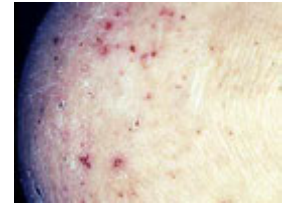Dystrophy

Dystrophy refers to degeneration or abnormal formation of the skin. It is often used to refer to nail diseases.



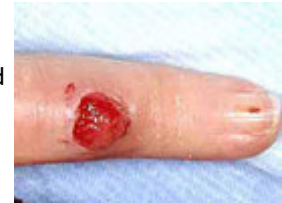Excoriation

An excoriation is a scratch mark. It may be linear or a picked scratch (**prurigo**). Excoriations may occur in the absence of a primary dermatosis.



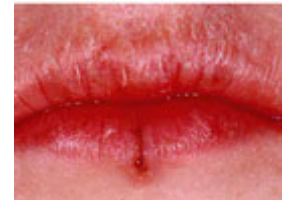Erosion

Erosion is caused by loss of the surface of a skin lesion; it is a shallow moist or crusted lesion.



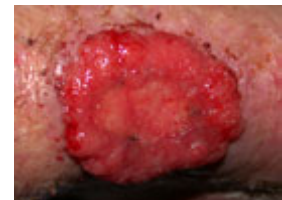Fissure

A fissure is a thin crack within epidermis or epithelium, and is due to excessive dryness.



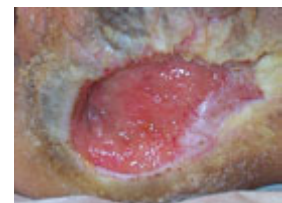Fungating

Refers to a large malignant tumour that is erupting like a mushroom or fungus.



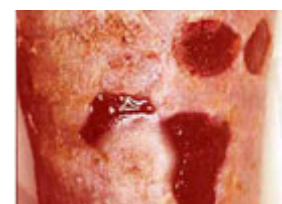Granulation tissue

Granulation tissue is made of a mass of new capillaries and fibrous tissue in a healing wound.



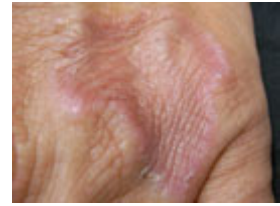Ulcer

An ulcer is full thickness loss of epidermis or epithelium. It may be covered with a dark-coloured crust called an **eschar**.



Granuloma

A granuloma is a histological (pathological) term referring to chronic inflammation in which there are several types of inflammatory cells including giant cells. Granulomas form in response to foreign bodies, certain infections (tuberculosis, leprosy) and inflammatory skin diseases (granuloma annulare, granuloma faciale, sarcoidosis).



Hypertrophy

Some component of the skin such as a scar is enlarged or has grown excessively. The opposite is **atrophy** or thinned skin.

