

# ***FORENSIC SEROLOGY***

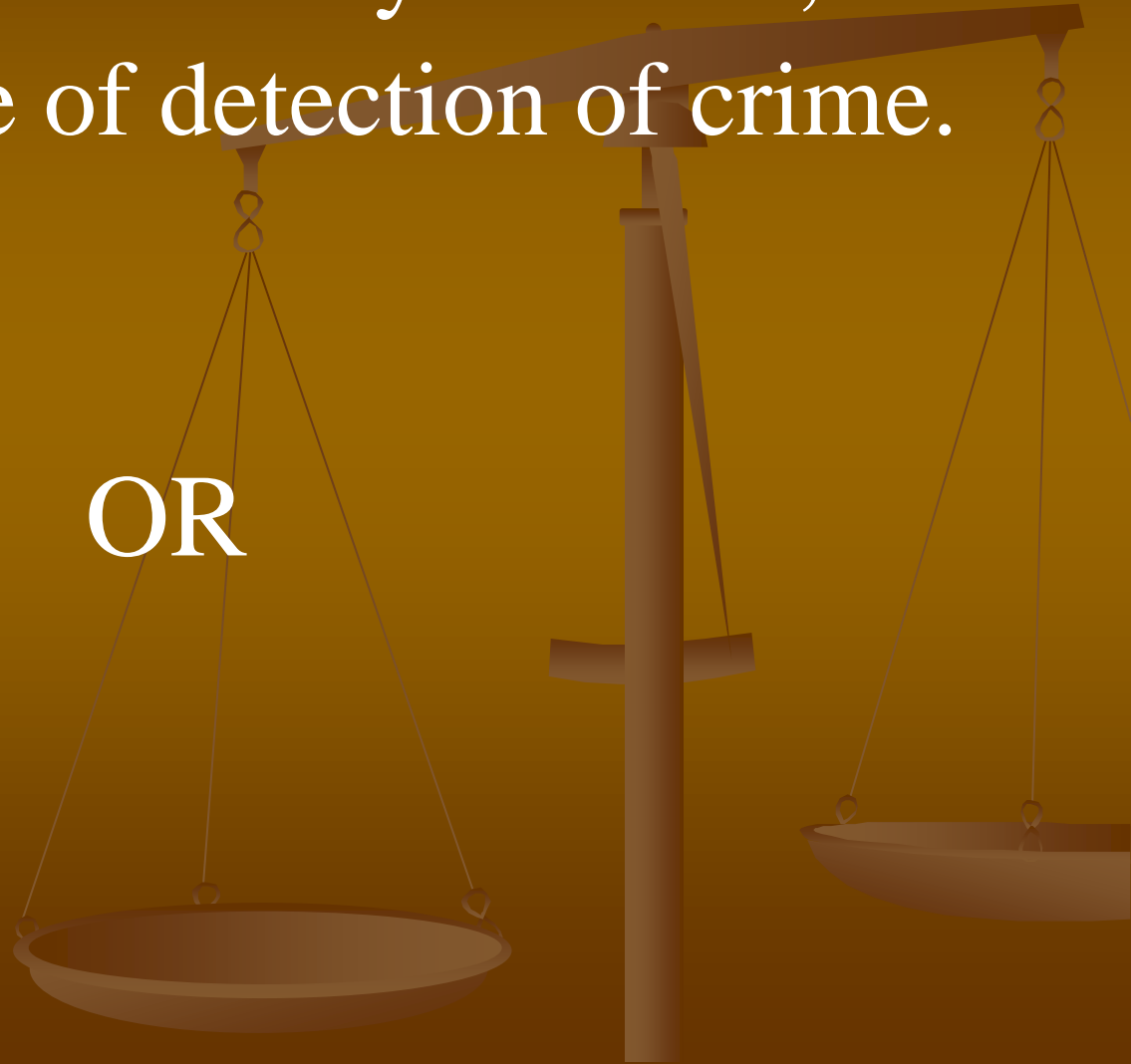## ***LECTURE BY***



**CAPT FARHAT H . MIRZA**  
**DOW UNIVERSITY OF HEALTH**  
**SCIENCES, KARACHI.**

Study of antigen- antibody reaction, used  
for the purpose of detection of crime.

OR

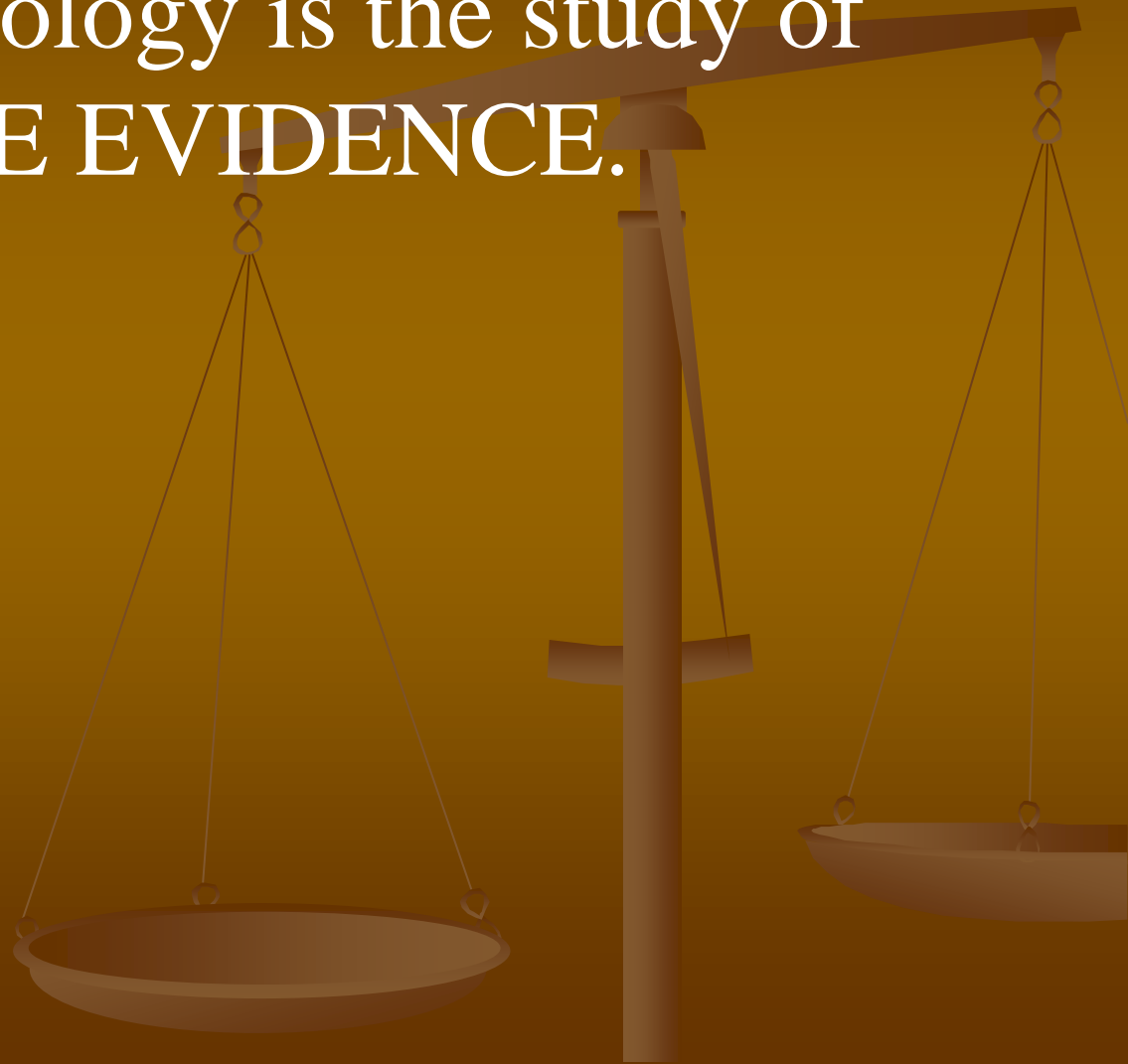


Study of body fluids or parts e.g. blood, semen, saliva, milk, urine, faecal matter, hair etc, used for the purpose of detection of crime.

OR



Forensic Serology is the study of  
**TRACE EVIDENCE.**



## **TRACE EVIDENCE:**

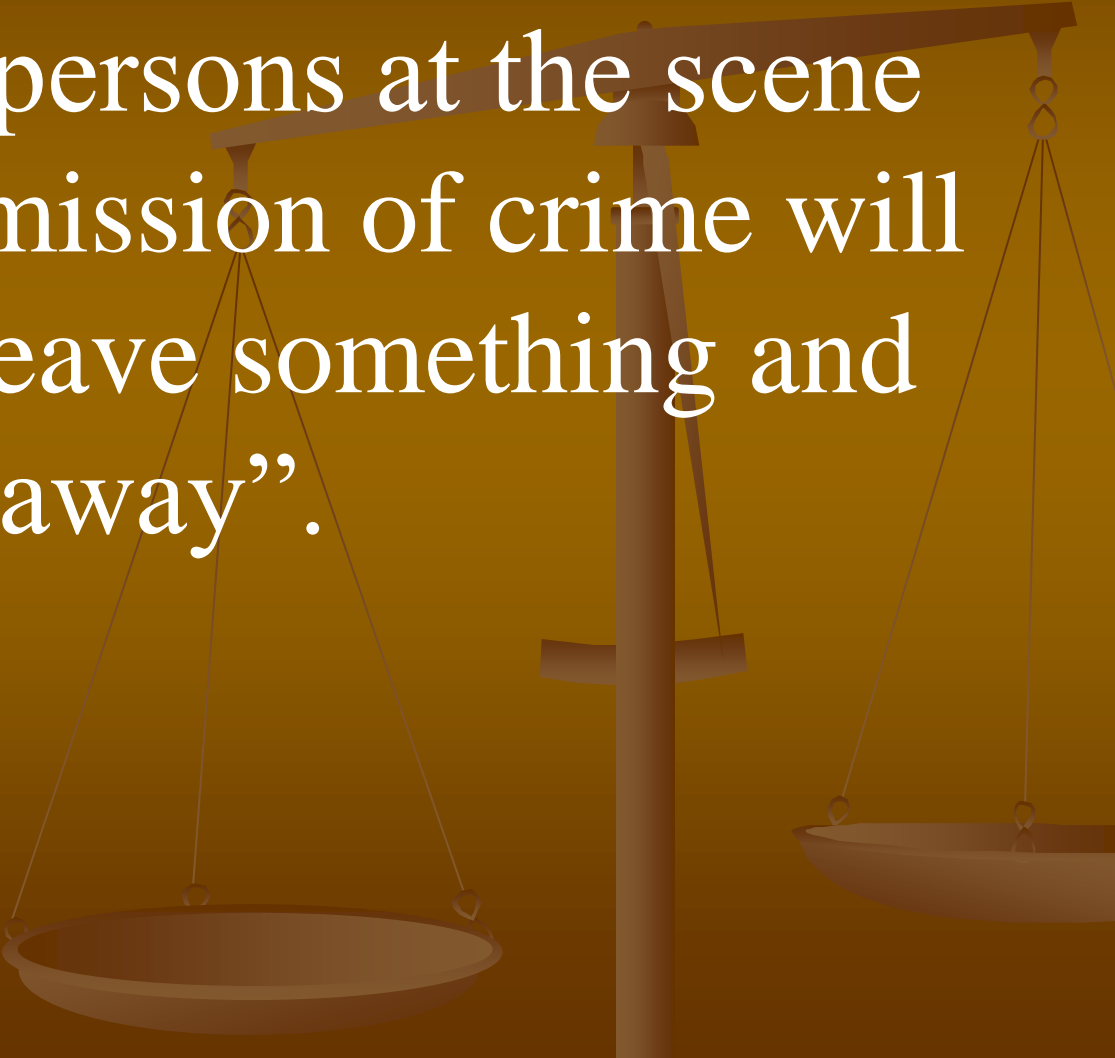
Edmond Locard, Head of Institute of Criminalistics in university of Lyon in France, put far ward his THEORY OF INTERCHANGE.

Also known as, LOCARD'S PRINCIPLE OF EXCHANGE.

“Whenever two objects come in contact with each other, always there is some exchange of material from one to the other, which may and may not be visible to the naked eye”.

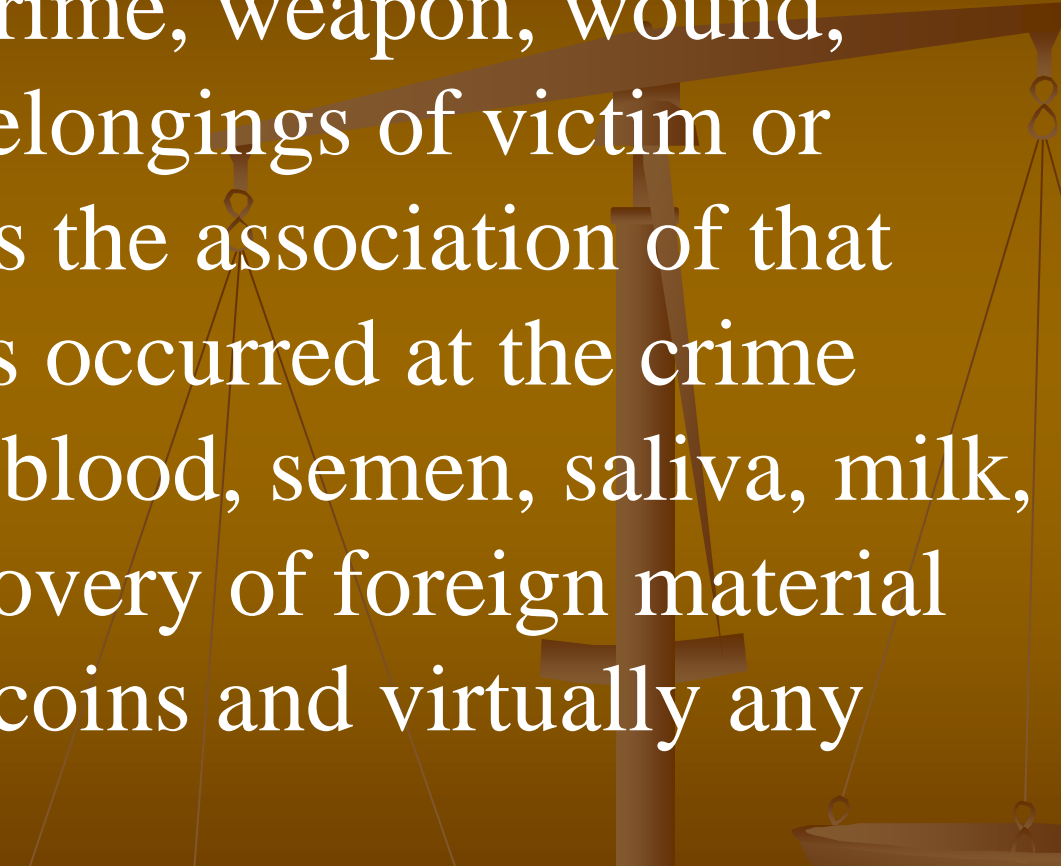
## *TRACE EVIDENCE:*

Edmond Locard also proposed that “The person or persons at the scene during the commission of crime will almost always leave something and take something away”.




## **TRACE EVIDENCE:**

Definition: It's the material evidence collected from the scene of crime, weapon, wound, body, clothing or belongings of victim or assailant and proves the association of that person to the events occurred at the crime scene e.g. stains of blood, semen, saliva, milk, urine, faeces or recovery of foreign material like hairs, buttons, coins and virtually any thing.





# FINGERPRINT PATTERNS AND CLASSIFICATIONS




## PLAIN ARCHES

In plain arches the ridges enter on one side of the impression and flow or tend to flow out the other side with a rise or wave in the center.




## TENTED ARCHES

Tented arches are similar to plain arches with the exception that the ridges in the center form a definite angle; or one or more ridges at the center form an upthrust; or they approach the loop type, possessing two of the basic characteristics of the loop but lacking in the third.





## ULNAR LOOPS

Ulnar loops are those types of patterns in which the loops flow in the direction of the little fingers.




## RADIAL LOOPS

Radial loops are those types of patterns in which the loops flow toward the thumbs.




## DOUBLE LOOP

The double loop consists of two separate loop formations, with two separate and distinct sets of shoulders and two deltas.




## PLAIN WHORL

A plain whorl has two deltas and at least one ridge making a complete circuit, which may be spiral, oval, or any variant of the circle. An imaginary line drawn between the two deltas must touch or cross at least one of the recurring ridges within the pattern area.



## CENTRAL POCKET WHORL

The central pocket whorl consists of one or more recurring ridges, or an obstruction at right angles to the inner line of flow, with two deltas between which an imaginary line would cut or touch no recurring ridge within the pattern area. The inner line of flow of a central pocket loop is determined by drawing an imaginary line between the inner delta and the center of the innermost recurve or looping ridge.



## ACCIDENTAL WHORL

The accidental whorl is a pattern with two or more deltas, and a combination of two or more different types of patterns exclusive of the plain arch. This classification also includes those exceedingly unusual patterns which may not be placed by definition into any other classes.





<b>Evidence</b>	<b>Likely Location of DNA on the Evidence</b>	<b>Source of DNA</b>
Baseball bat or similar weapon	Handle, end	Sweat, skin, blood, tissue
Hat, bandanna, or mask	Inside	Sweat, hair, dandruff
Eyeglasses	Nose or ear piece, lens	Sweat, skin
Facial tissue, cotton swab	Surface area	Mucus, blood, sweat, semen, ear wax
Dirty laundry	Surface area	Blood, sweat, semen
Toothpick	Tip	Saliva
Used cigarette	Cigarette butt	Saliva
Stamp or envelope	Licked area	Saliva
Tape or ligature	Inside/outside surface	Saliva, skin
Bottle, can, or glass	Side, mouthpiece	Saliva, sweat
Used condom	Inside/outside surface	Semen, vaginal or rectal cells
Blanket, pillow, sheet	Surface area	Sweat, hair, semen, urine, saliva
"Through and through" bullet	Outside surface	Blood, tissue
Bite mark	Person's skin or clothing	Saliva
Fingernail, partial fingernail	Scrapings	Blood, sweat, tissue

# ***BLOOD AS TRACE EVIDENCE:***

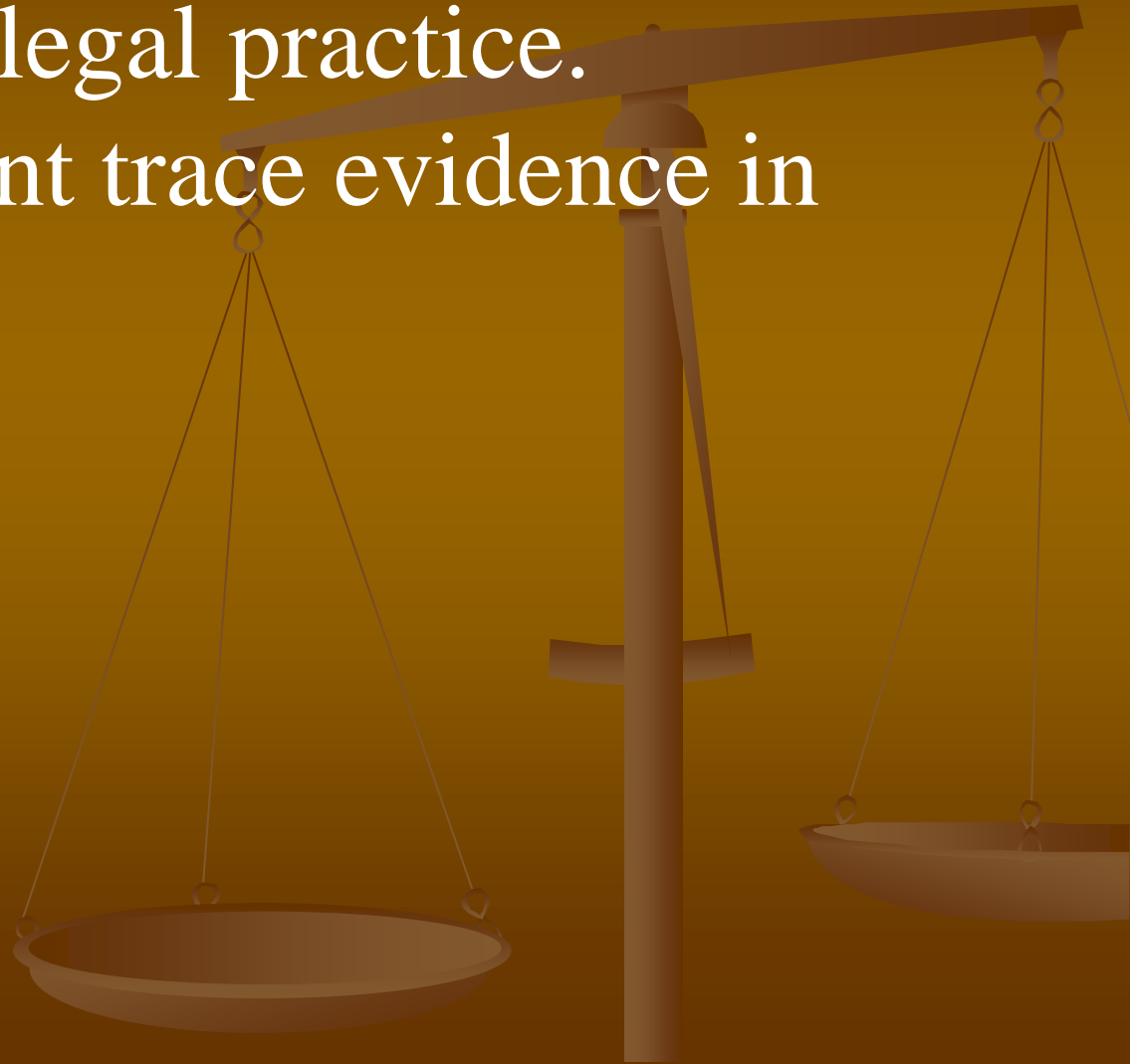
Blood itself is an extremely important entity in medico-legal practice.

It can be important trace evidence in cases of :

Injuries

Murders

Sexual Offenses.



# *EXAMINATION OF BLOOD STAIN:*

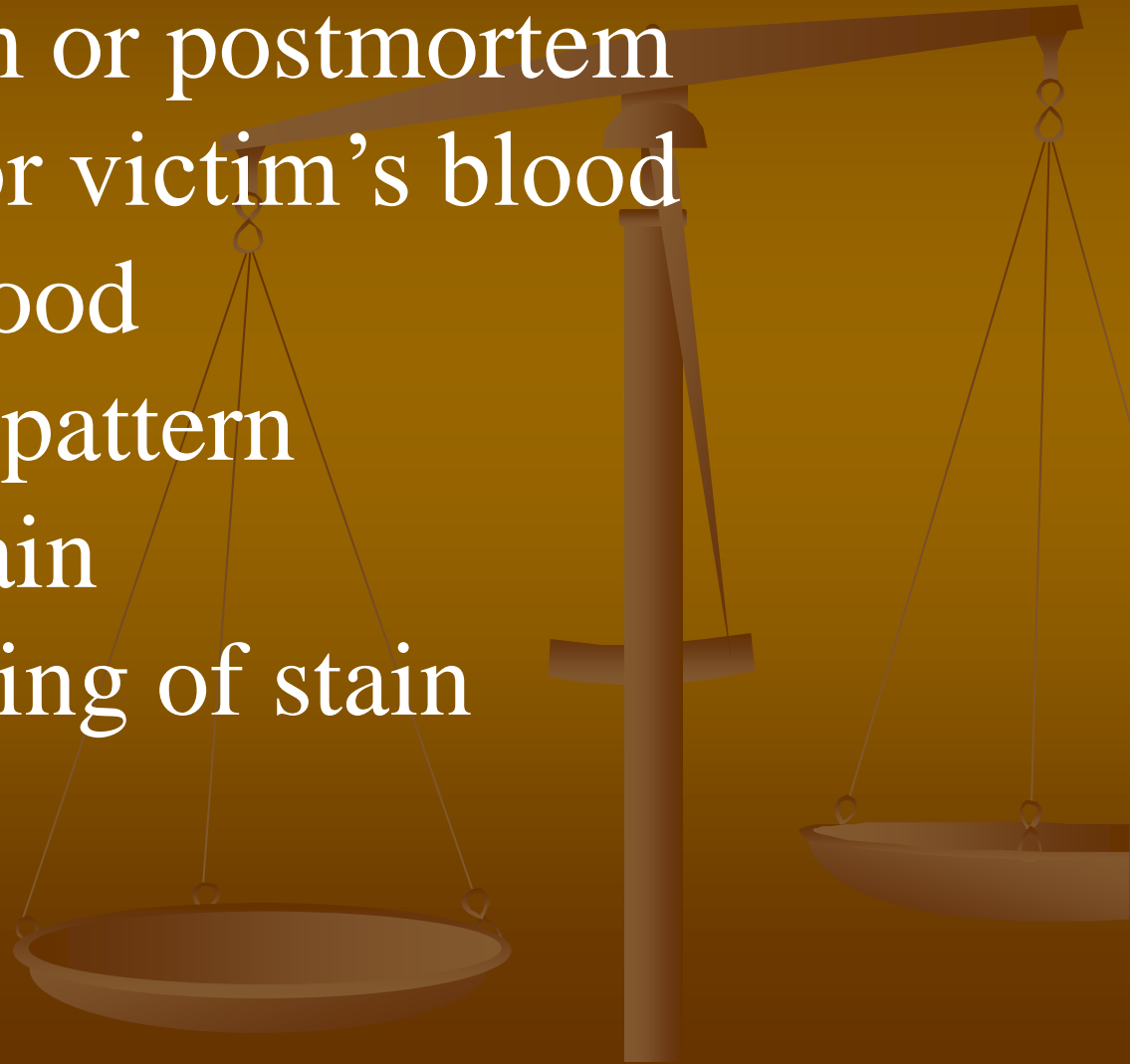
With the help of Physical, Chemical, Microscopic, Spectroscopic, Biological and Enzymological examination we have to satisfy the following questions.

Whether, the stain is blood or some other material.

If blood, whether human or of animal origin.

If human then one should try to find out

- Age of stain
- Arterial or venous blood
- Ante mortem or postmortem
- Assailant's or victim's blood
- Source of blood
- Distribution pattern
- Sexing of stain
- Blood grouping of stain



# WHETHER, THE STAIN IS BLOOD OR SOME OTHER MATERIAL:

Some substances produce stains which simulate the blood stains e.g. fruit juices, paan, henna, paints, dyes, rust etc.

## PRELIMINARY TESTS:

Benzidine Test.

Blue color change

Positive

Phenolphthalein Test

Pink color change

Positive

( Kastle Mayer's Test)

Principle: Hb detection tests.

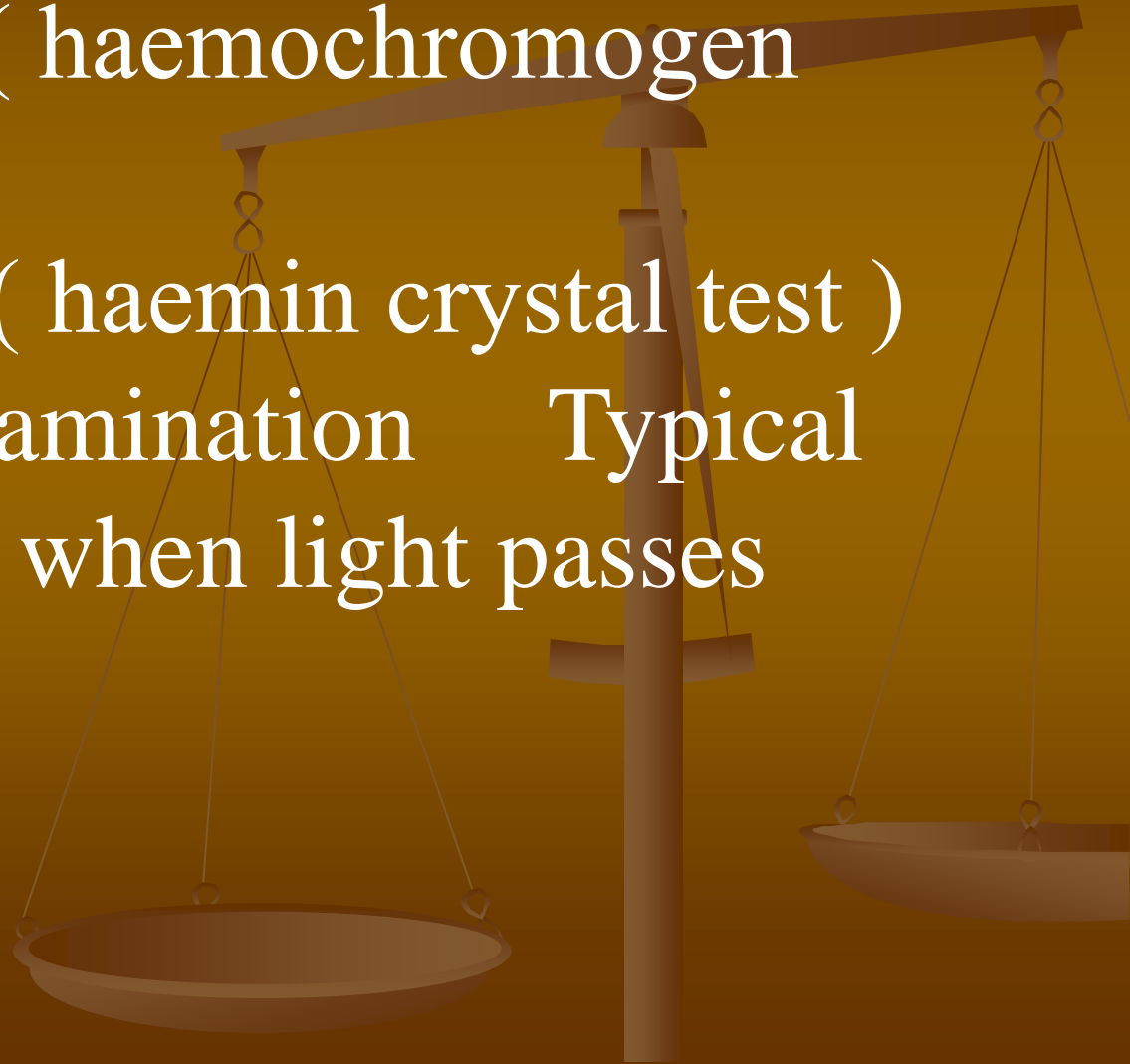
# *CONFIRMATORY TESTS:*

Microscopic examination.

Takayama's test ( haemochromogen  
crystal test )

Teichman's test ( haemin crystal test )

Spectroscopic examination      Typical  
absorption bands when light passes  
through liquid



**IF BLOOD, WHETHER HUMAN OR  
OF ANIMAL ORIGIN:**

Precipitin Test

Haemagglutination inhibition Test

Latex Test

**ENZYMOLOGICAL TESTS:**

Lactate Dehydrogenase ( LDH )

Peroxidase ( Px )

# *PRECIPITIN TEST:*

Human blood contains antigens

When it's injected in animal over a longer period, the antibodies are produced in animal

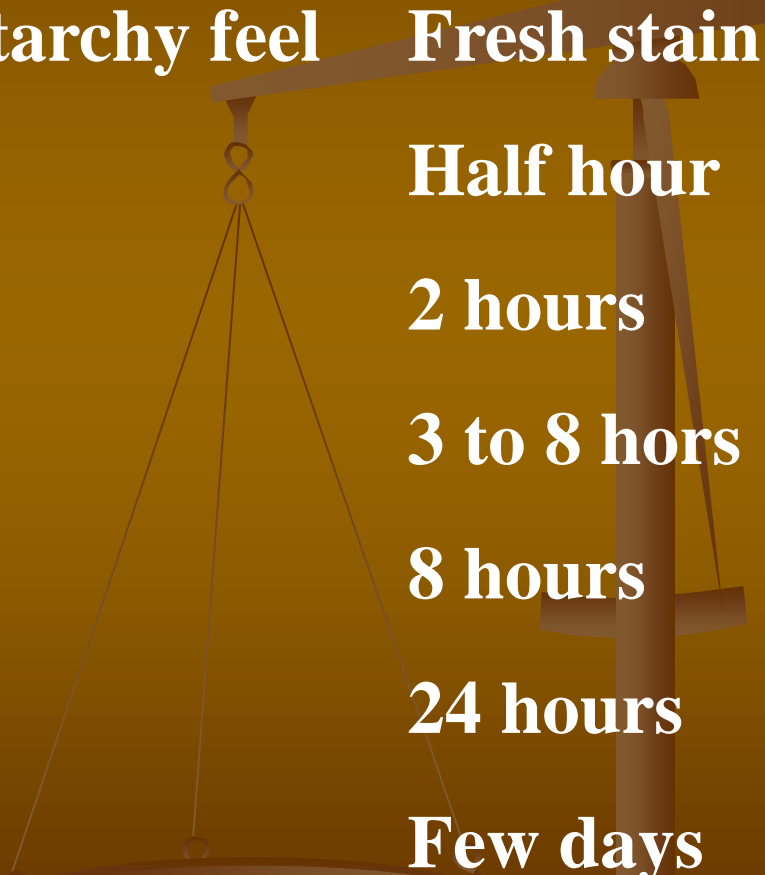
When serum of that animal is mixed with human blood sample it causes agglutination

Human serum is injected in rabbit for longer time in smaller quantities. Later on the serum of rabbit is persevered and used for this testing.



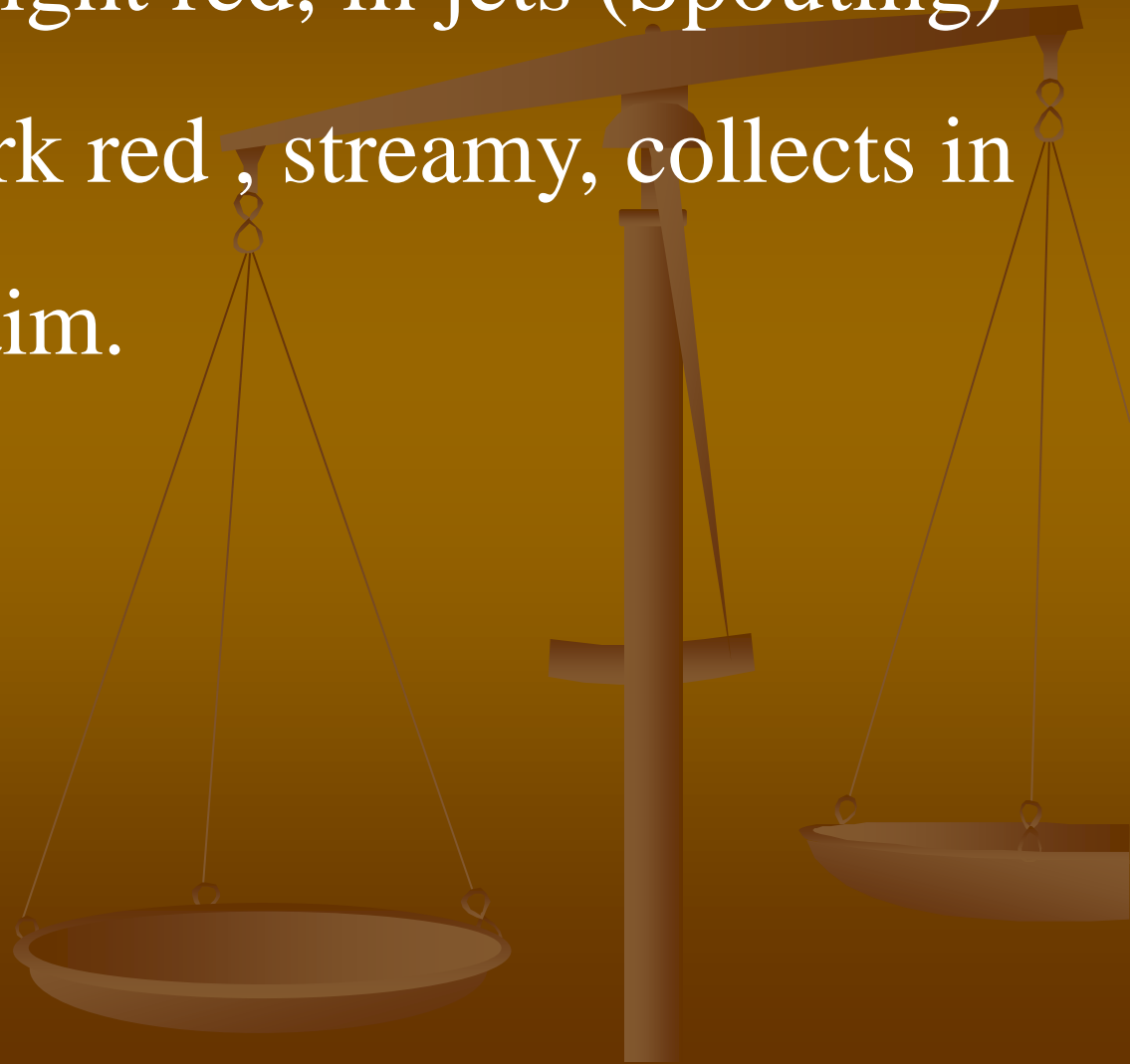
# **AGE OF STAIN:**

**On touching the stain, the following findings are noted:**

- **Wet bright red, starchy feel**      **Fresh stain**
  - **Red liquid blood**      **Half hour**
  - **Sticky feel**      **2 hours**
  - **Yellow liquid**      **3 to 8 hours**
  - **Hard set**      **8 hours**
  - **Reddish brown**      **24 hours**
  - **Black**      **Few days**
- 

# *ARTERIAL OR VENOUS BLOOD:*

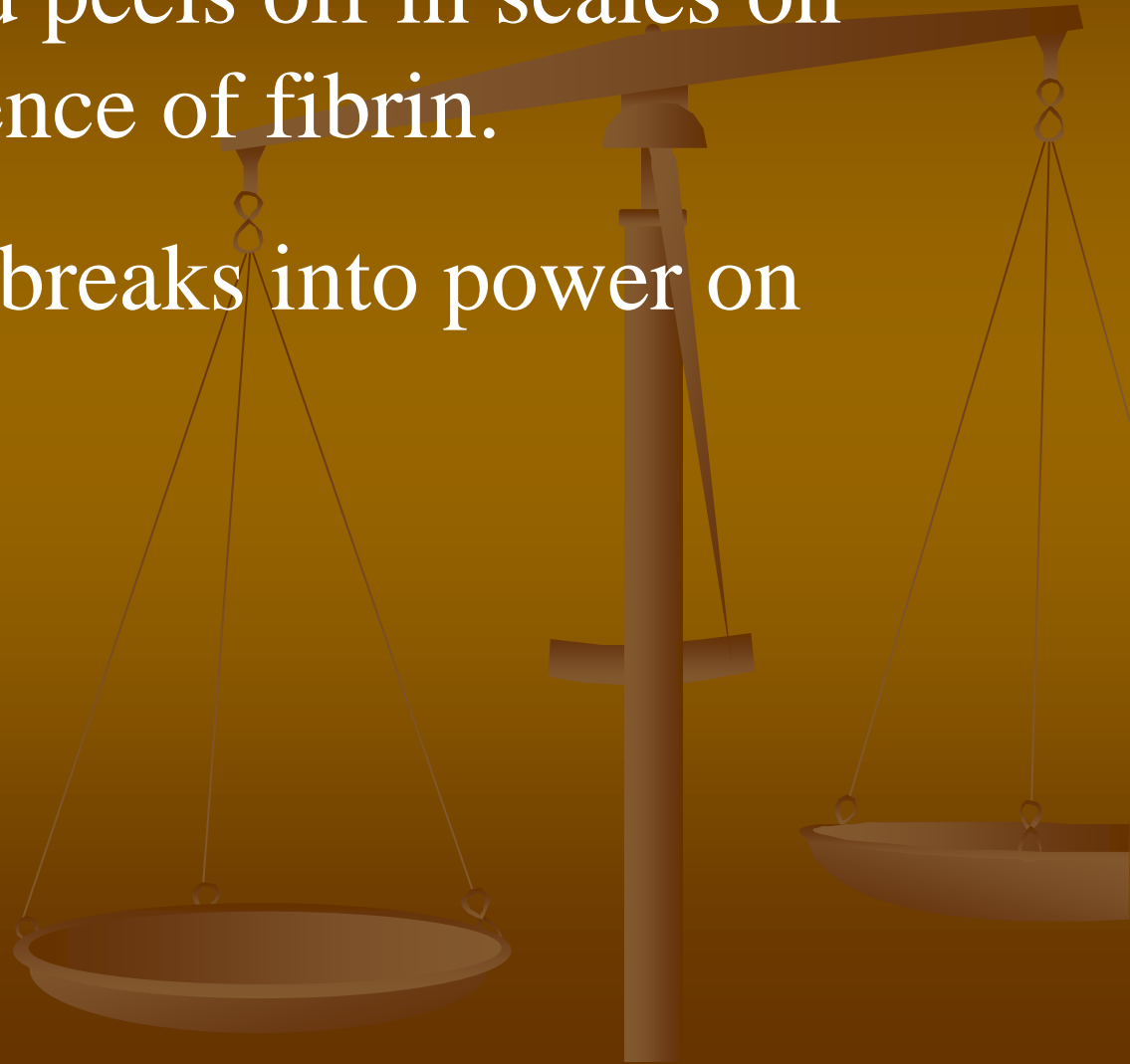
Arterial blood is bright red, in jets (Spouting)  
venous blood is dark red, streamy, collects in  
a pool near the victim.



# *ANTE MORTEM OR POSTMORTEM :*

Ante mortem blood peels off in scales on drying due to presence of fibrin.

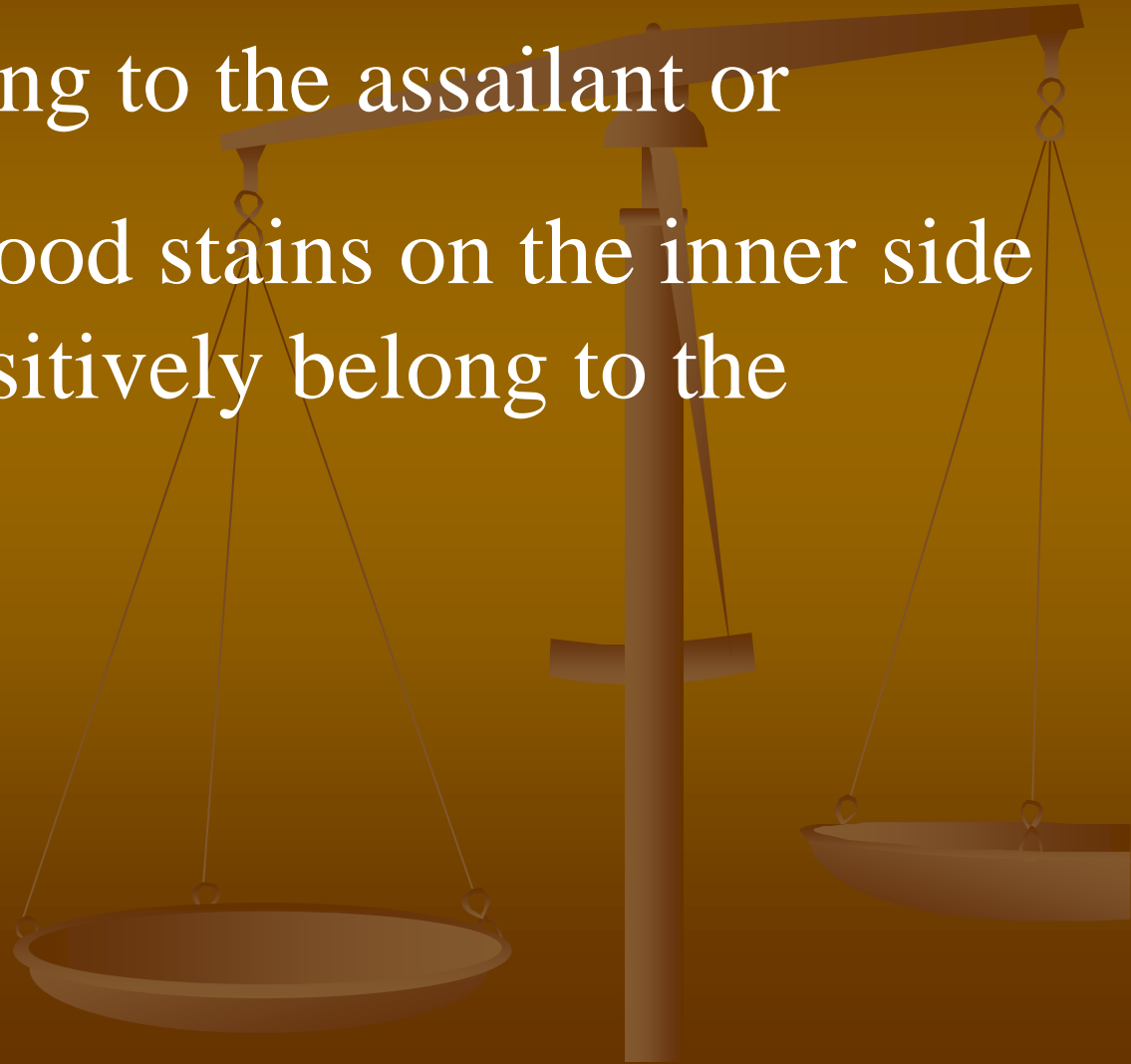
Postmortem blood breaks into powder on drying.



# *ASSAILANT'S OR VICTIM'S BLOOD:*

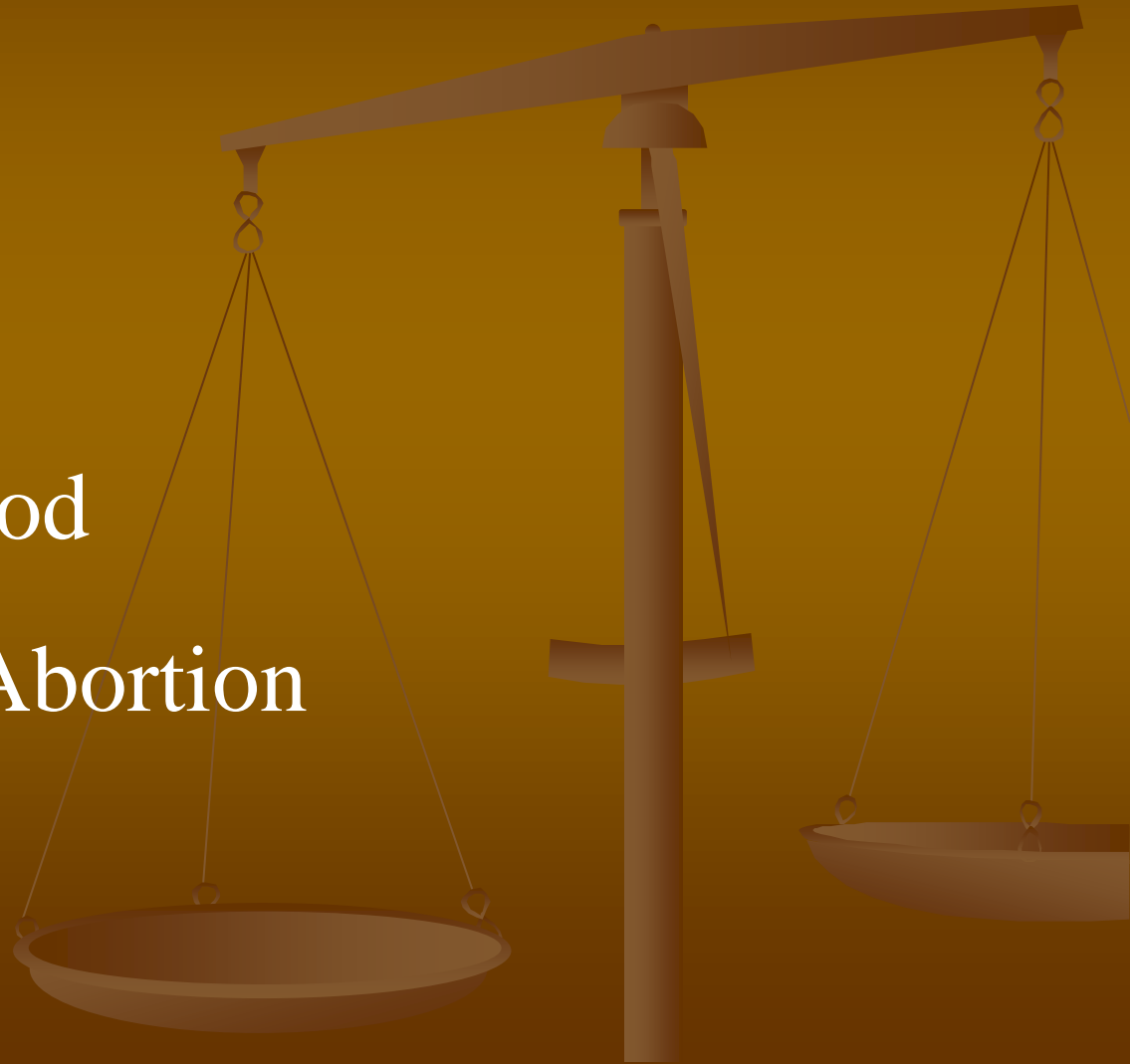**Assailant's blood** on the outer side of the garments may belong to the assailant or

**Victim's blood:** blood stains on the inner side of the garments positively belong to the victim.



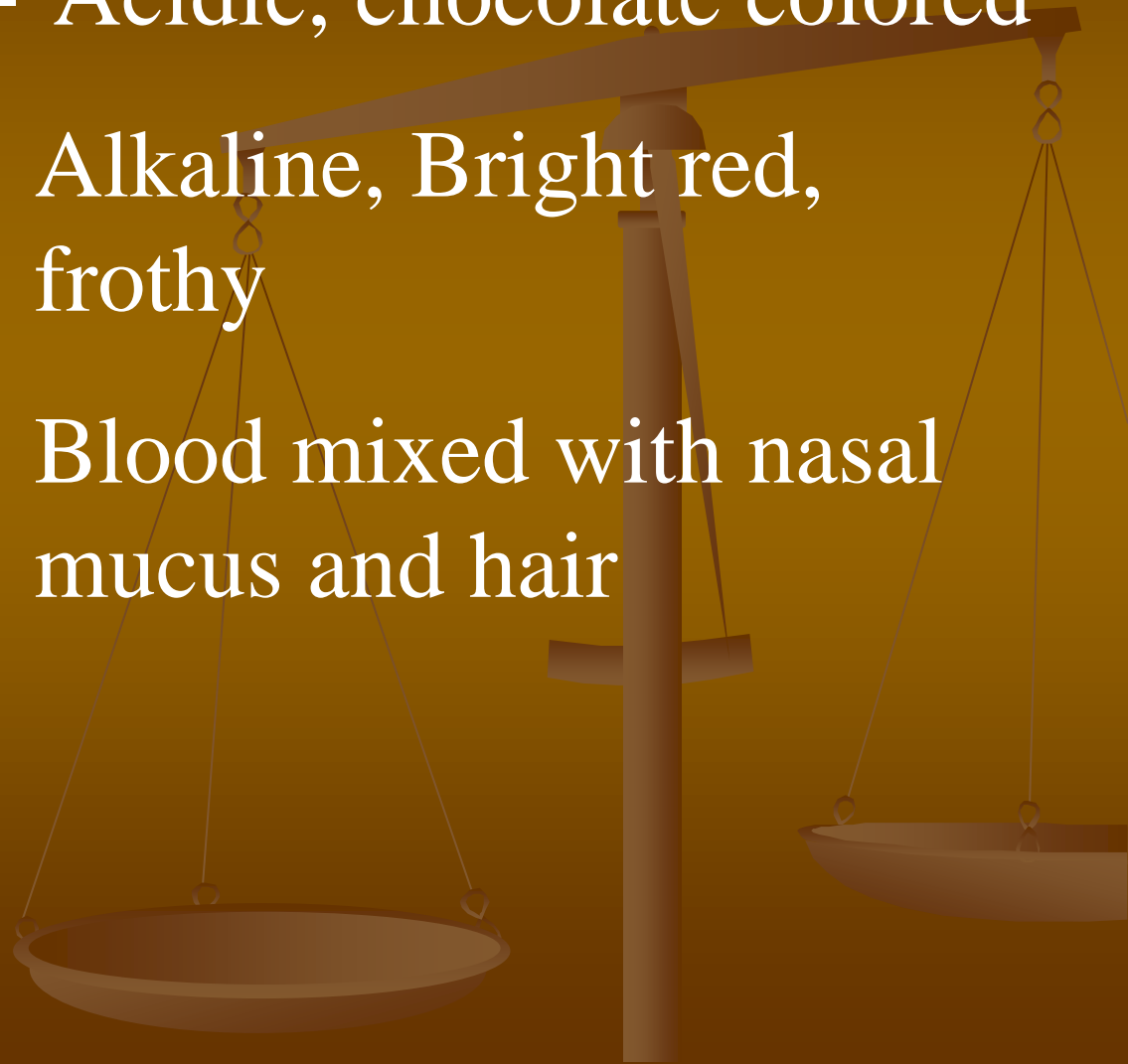
# *SOURCE OF BLOOD:*

- Hemetmesis
- Hemoptysis
- Epistaxis
- Menstrual blood
- Parturition / Abortion

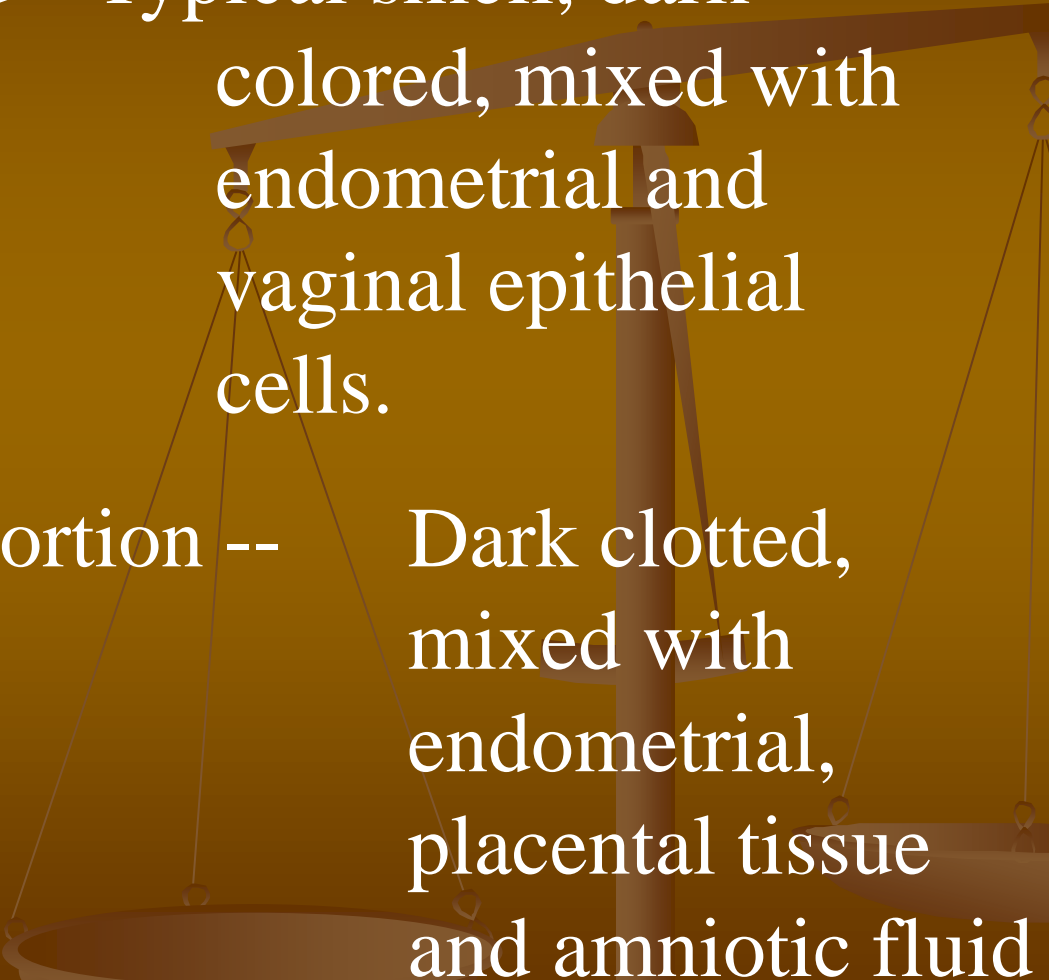


# *SOURCE OF BLOOD:*

- Hemetmesis -- Acidic, chocolate colored
- Hemoptysis -- Alkaline, Bright red, frothy
- Epistaxis -- Blood mixed with nasal mucus and hair



# *SOURCE OF BLOOD:*

- Menstrual blood – Typical smell, dark colored, mixed with endometrial and vaginal epithelial cells.
  - Parturition / Abortion -- Dark clotted, mixed with endometrial, placental tissue and amniotic fluid
- 
- A faint, stylized illustration of a balance scale is visible in the background. The scale is positioned vertically, with a horizontal beam at the top. Two pans are suspended from the beam by thin lines. The scale is rendered in a dark brown color, matching the overall theme of the slide.

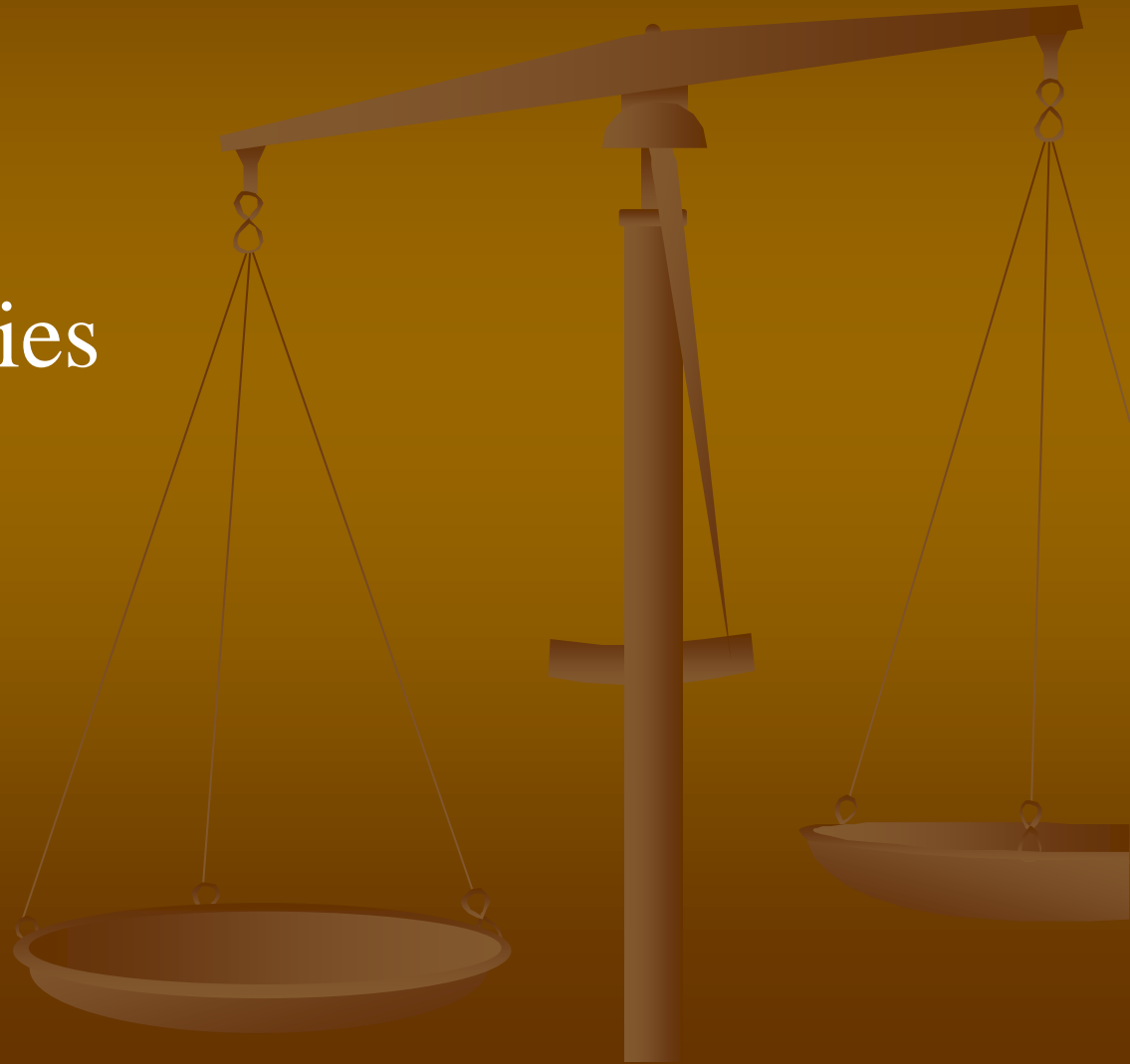# *SEXING OF STAIN:*

## **Females:**

- Bar bodies
- Davidson bodies

## **Males:**

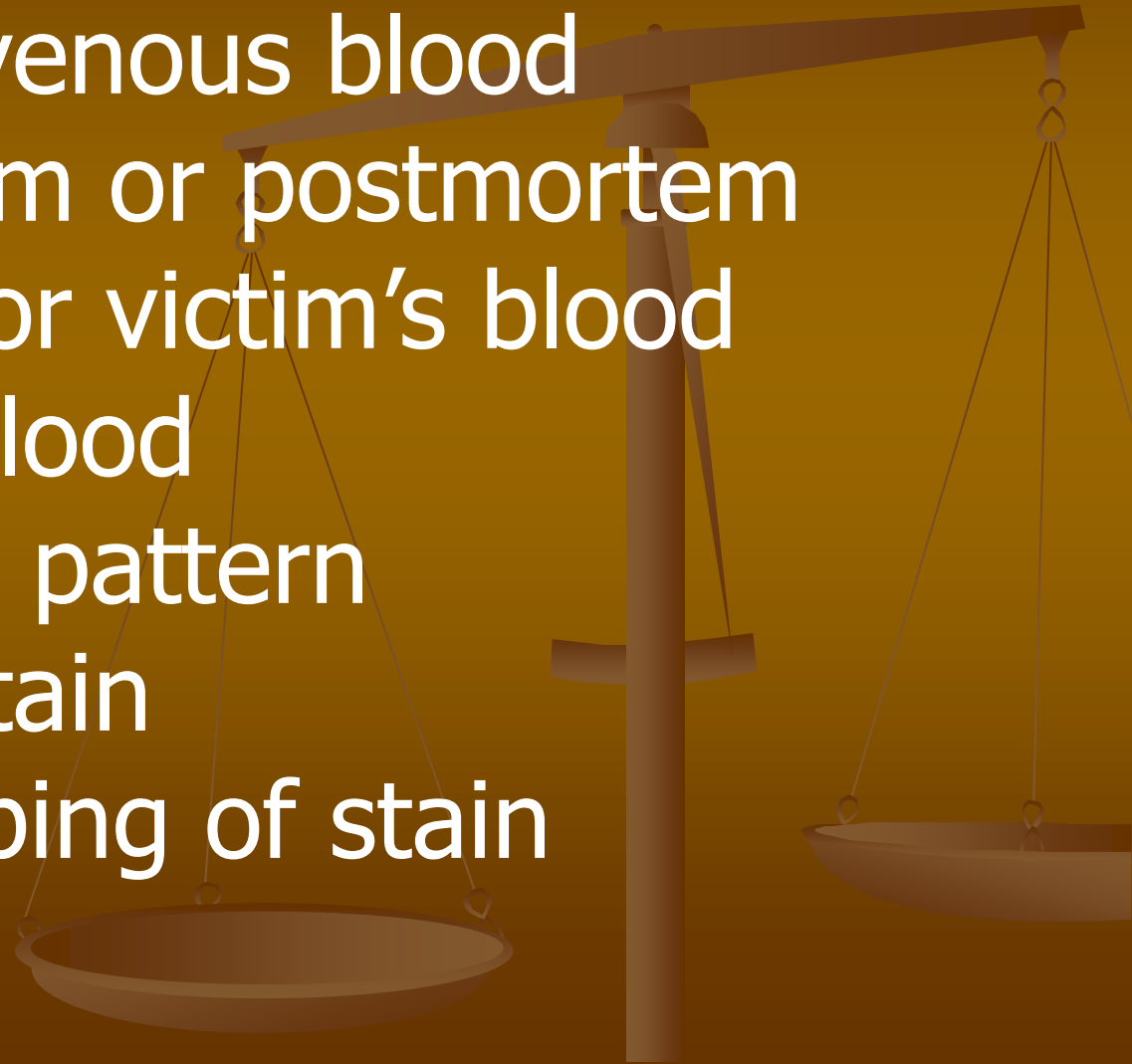
- Y bodies





# *GROUPING OF STAIN:*

- Age of stain
- Arterial or venous blood
- Ante mortem or postmortem
- Assailant's or victim's blood
- Source of blood
- Distribution pattern
- Sexing of stain
- Blood grouping of stain



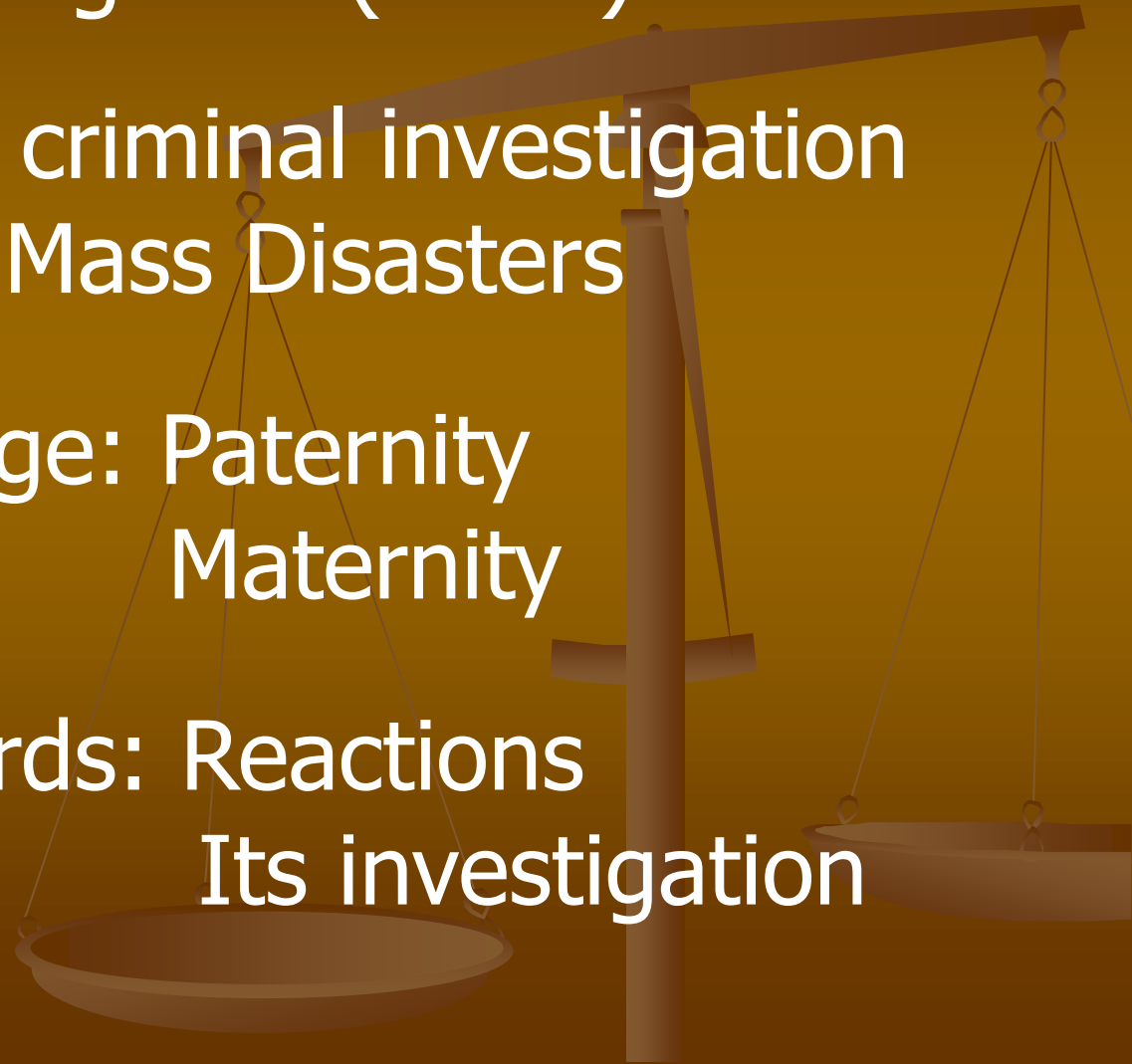# **BLOOD GROUPING OF STAIN:**

Why blood grouping? ( MLI )

Identification : in criminal investigation  
in Mass Disasters

Disputed Parentage: Paternity  
Maternity

Transfusion Hazards: Reactions  
Its investigation



# **MASS DISASTER:**

According to WHO, its an occurrence that causes damage, ecological disruption, loss of human life to such an extent that warrant an extraordinary response from outside the affected community or area. Or the number of casualties is more than 12 in a single Mishap.

Can be Natural or Man made.

# **DISPUTED PARENTAGE:**

## **Paternity Disputes:**

Alleged adultery and nullity of marriage suits. When wife seeks divorce on the ground that her husband is father of some child out of wedlock.

Blackmailing.

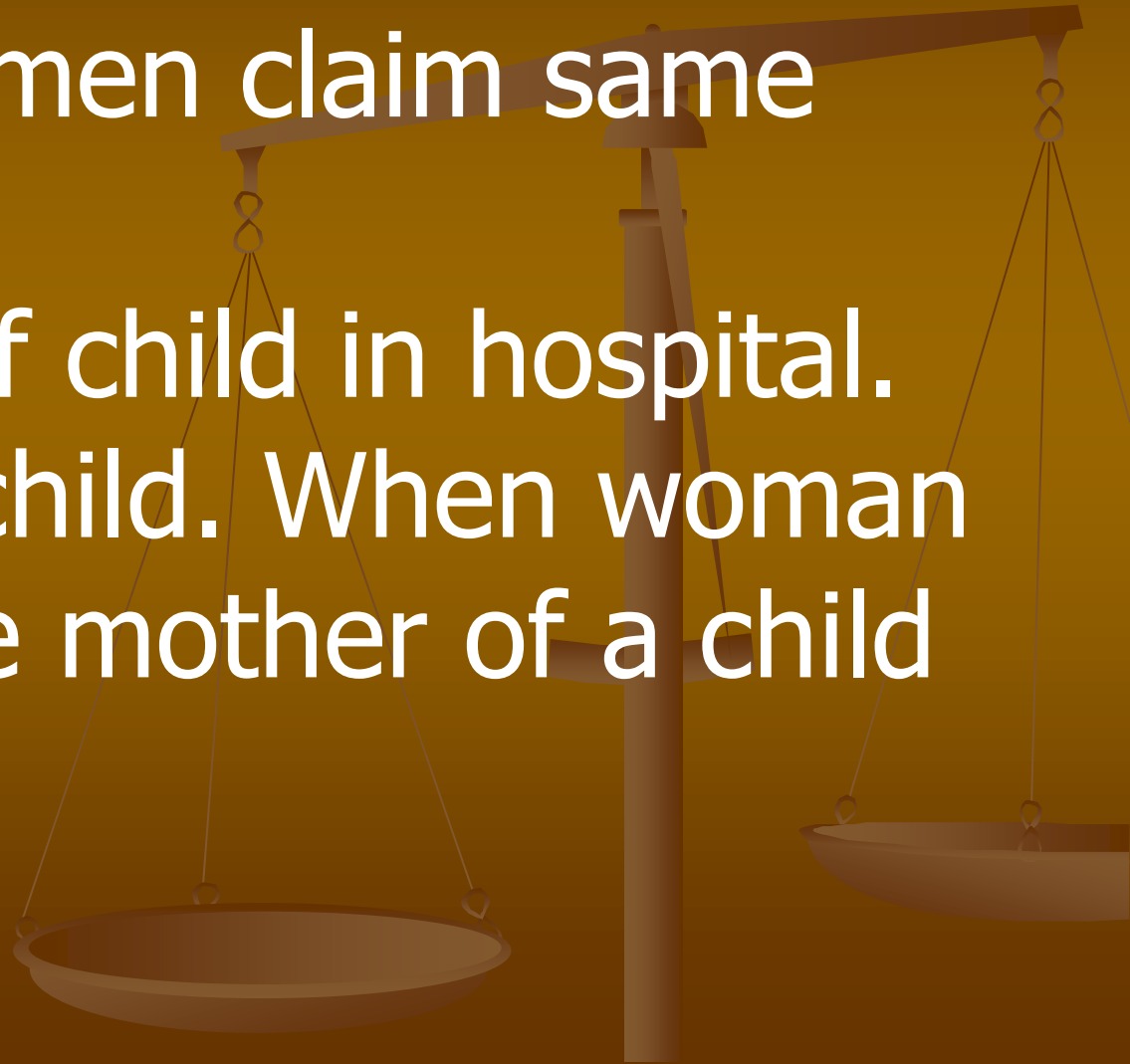
Property and insurance claims

# **MATERNITY DISPUTES:**

When two women claim same child.

Interchange of child in hospital.

Suppositious child. When woman pretends to be mother of a child



# **TRANSFUSION HAZARDS:**

In cases of Transfusion Reactions Labs, Doctors and Paramedics may be charged with allegations of negligence.

Its investigations include verification of cross match, proper handling, proper delivery and transfusion.

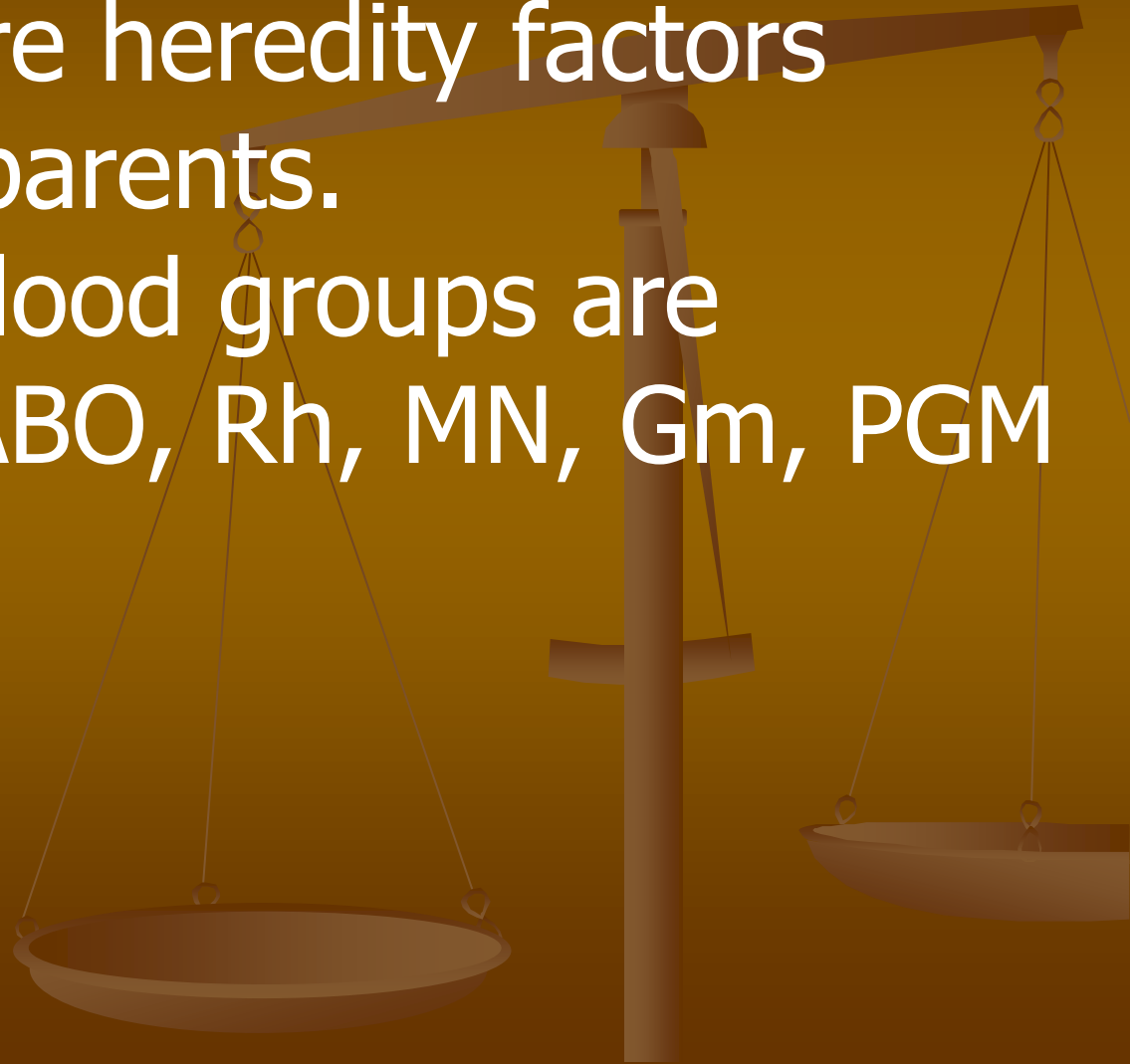
Empty bottle syndrome.

Autopsy in fatal reactions.

# **BLOOD GROUPS:**

Blood groups are heredity factors inherited from parents.

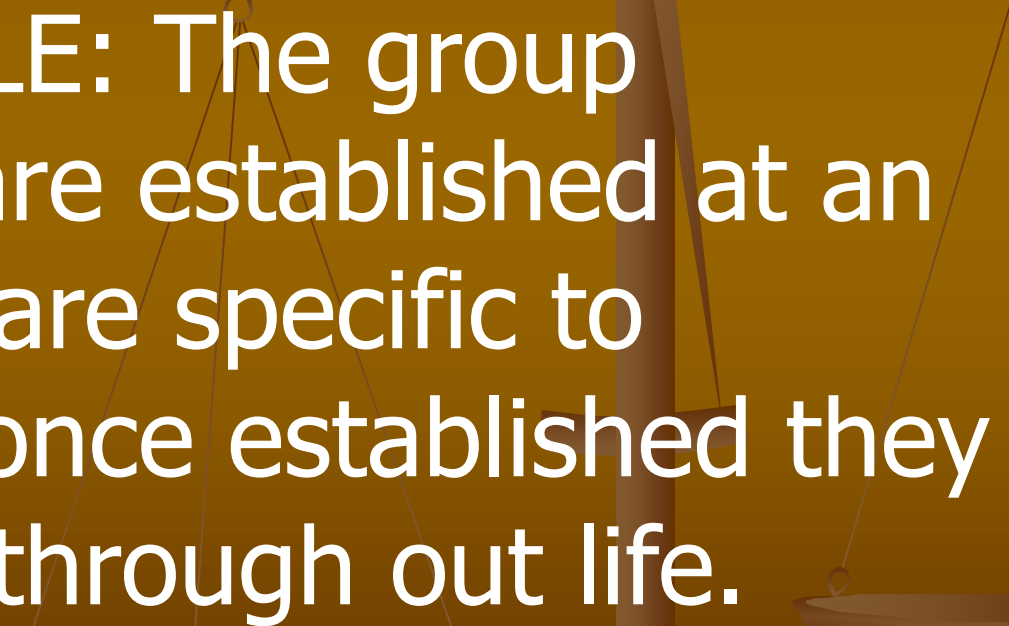
More than 30 blood groups are identified e.g. ABO, Rh, MN, Gm, PGM etc.



# **INHERITANCE OF BLOOD GROUPS:**

These are inherited according to the Mendel's Law of Inheritance.

**FIRST PRINCIPLE:** The group characteristics are established at an early age, they are specific to individual, and once established they are unchanged through out life.





## **SECOND PRINCIPLE:**

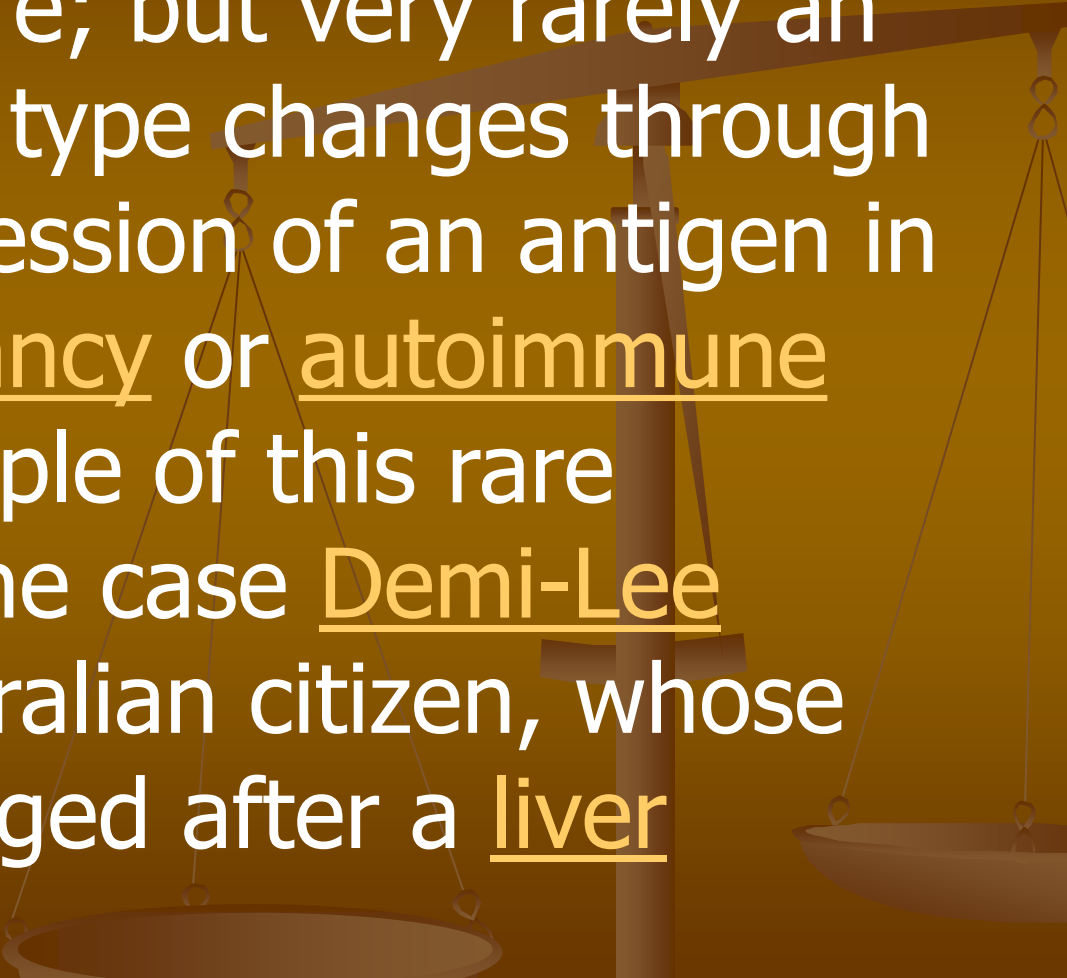
The individual can not possess any antigen which both of his parents' lack.

## **THIRD PRINCIPLE:**

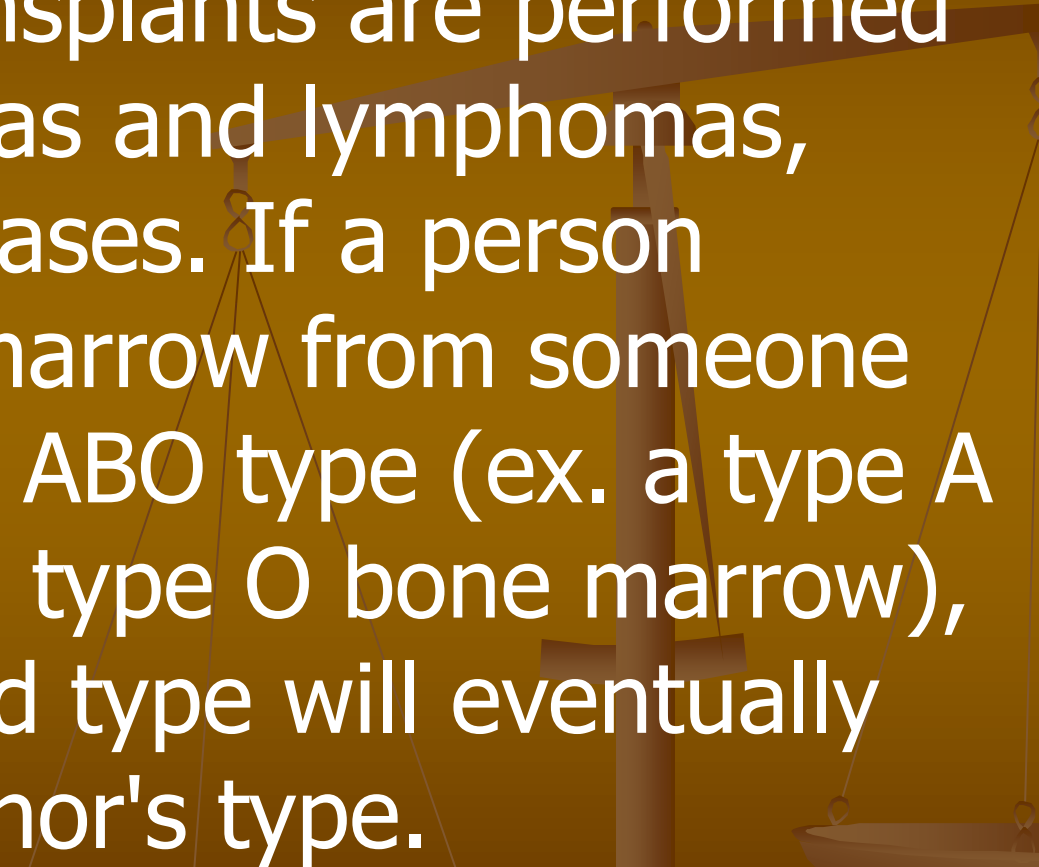
If one the parent is homozygous for a particular blood group antigen, that antigen must appear in child's blood.

# **CAN BLOOD GROUP BE CHANGED?**

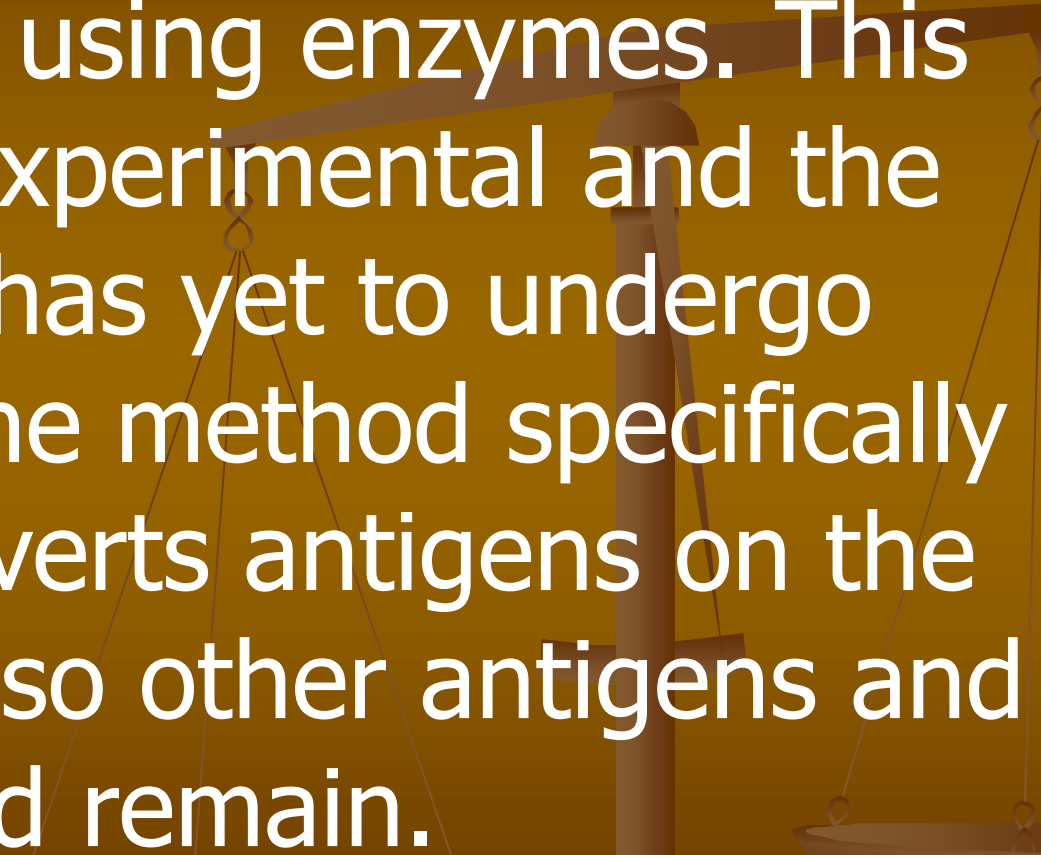
Almost always, an individual has the same blood group for life; but very rarely an individual's blood type changes through addition or suppression of an antigen in infection, malignancy or autoimmune disease. An example of this rare phenomenon is the case Demi-Lee Brennan, an Australian citizen, whose blood group changed after a liver transplant.

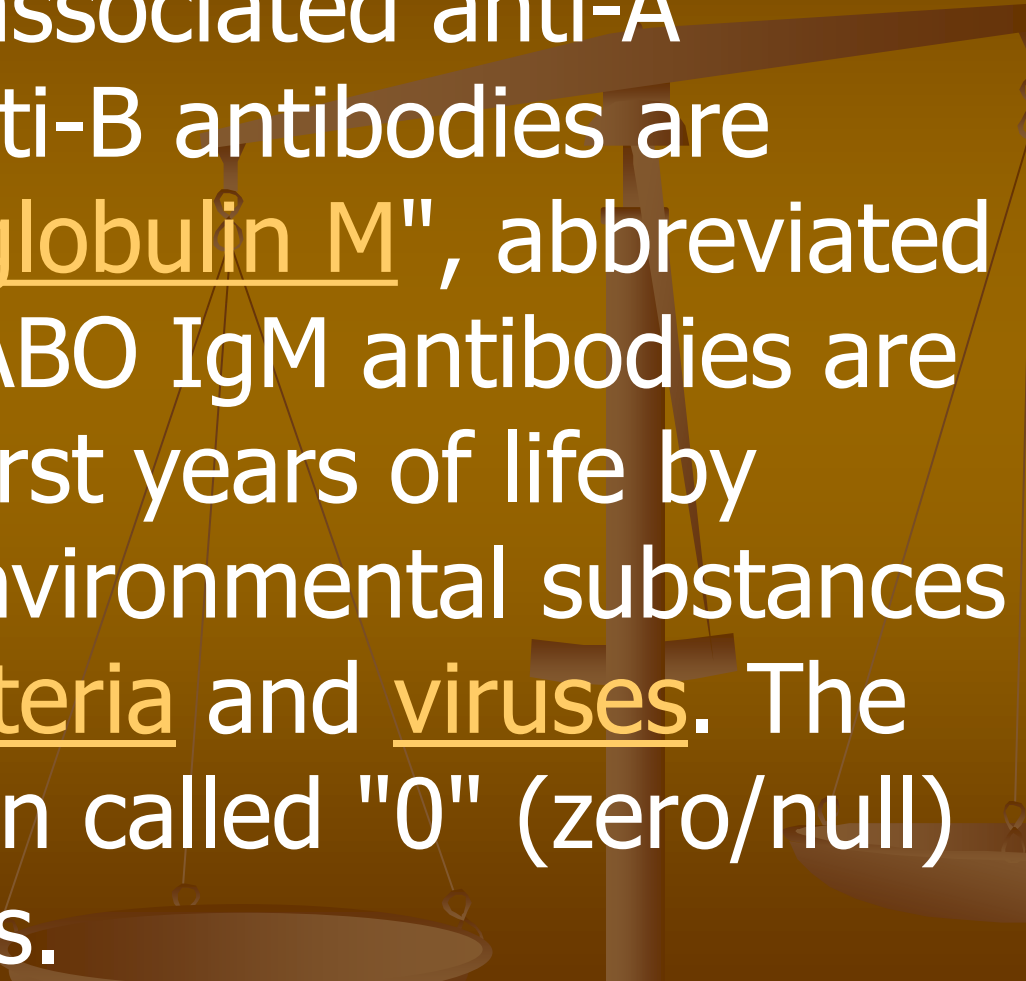


Another more common cause in blood type change is a bone marrow transplant. Bone marrow transplants are performed for many leukemias and lymphomas, among other diseases. If a person receives a bone marrow from someone who is a different ABO type (ex. a type A patient receives a type O bone marrow), the patient's blood type will eventually convert to the donor's type.

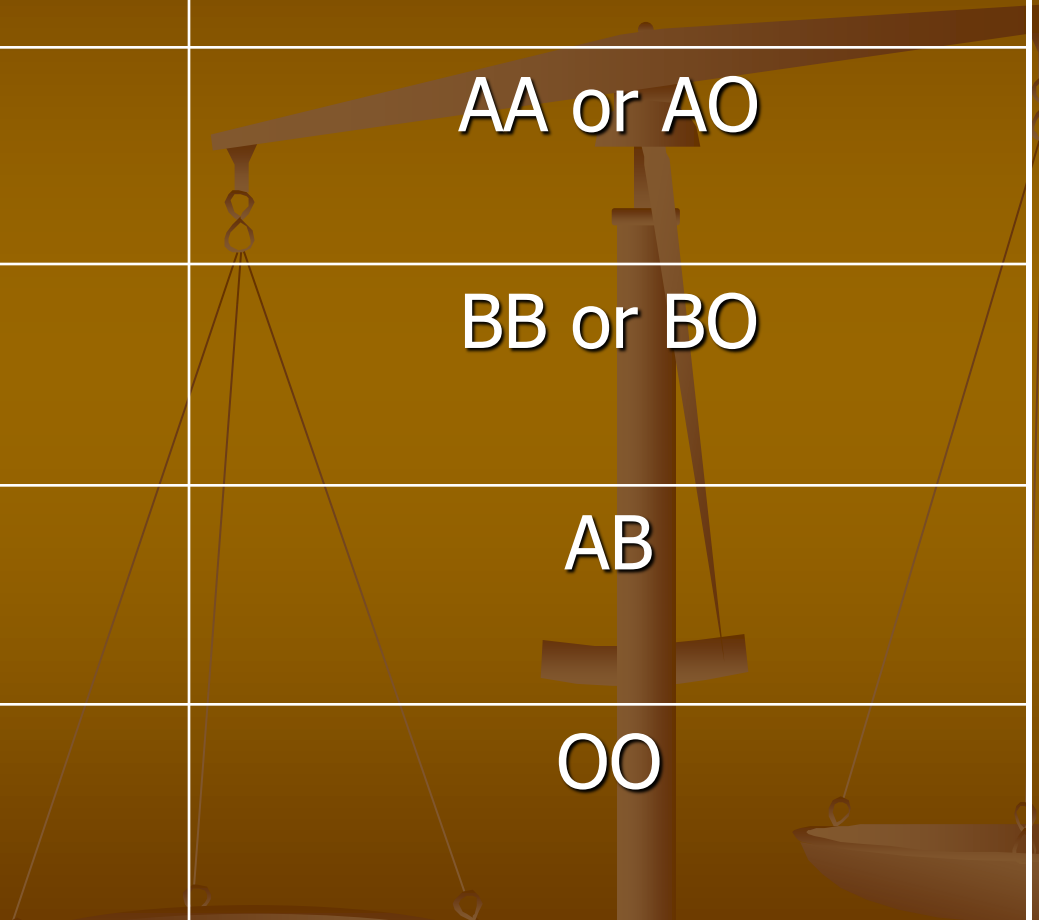


In April 2007 a method was discovered to convert blood types A, B, and AB to O, using enzymes. This method is still experimental and the resulting blood has yet to undergo human trials. The method specifically removes or converts antigens on the red blood cells, so other antigens and antibodies would remain.

A faint, stylized illustration of a balance scale is visible in the background. The scale is positioned on the right side of the frame, with its vertical post and horizontal beam extending across the middle. Two pans are suspended from the beam by thin lines. The scale is rendered in a dark brown color, matching the background's gradient.



The ABO system is the most important blood group system in human blood transfusion. The associated anti-A antibodies and anti-B antibodies are usually "Immunoglobulin M", abbreviated IgM, antibodies. ABO IgM antibodies are produced in the first years of life by sensitization to environmental substances such as food, bacteria and viruses. The "O" in ABO is often called "0" (zero/null) in other languages.

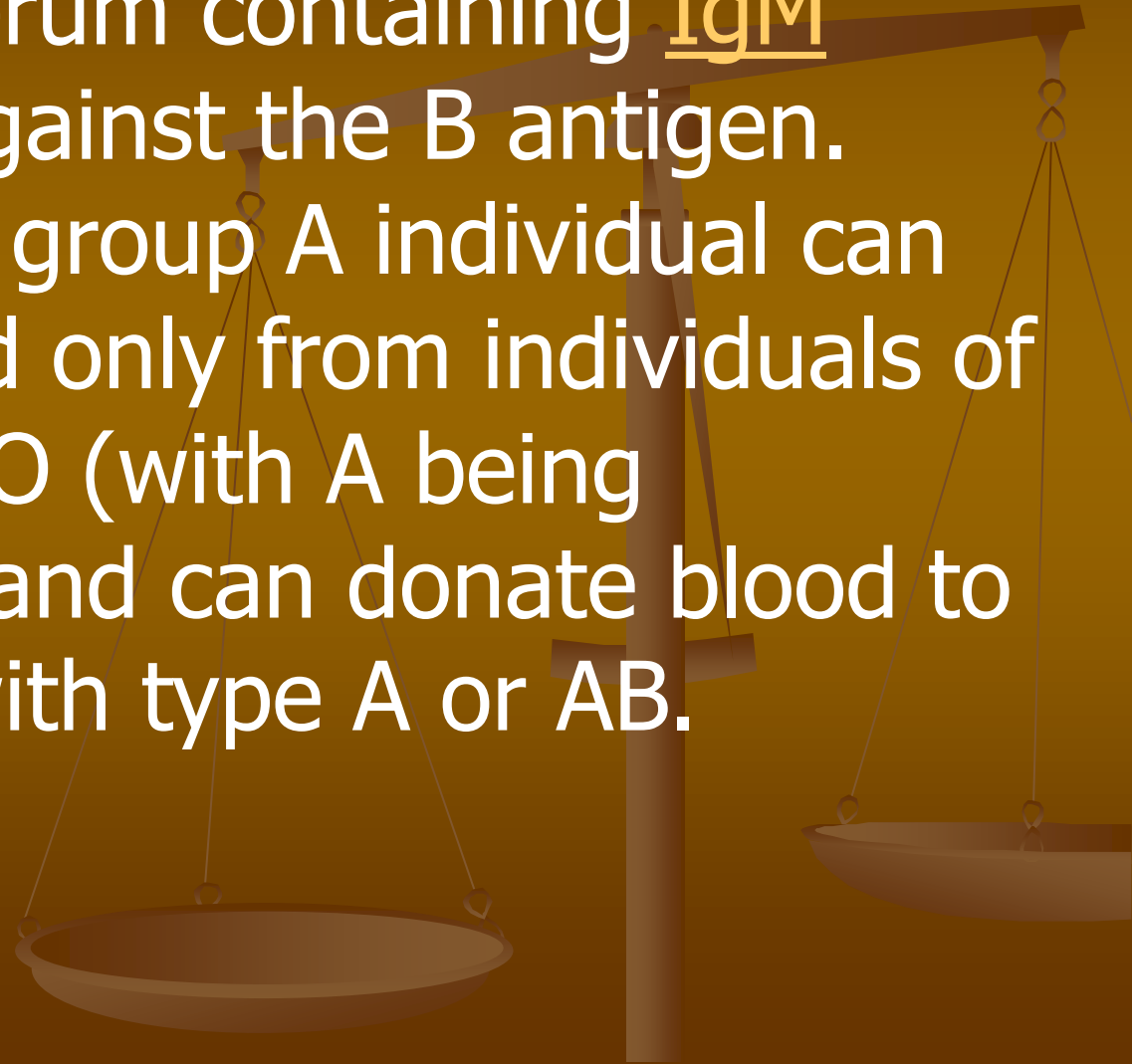


<u>Phenotype</u>	<u>Genotype</u>
A	AA or AO
B	BB or BO
AB	AB
O	OO

## **RED BLOOD CELL COMPATIBILITY:**

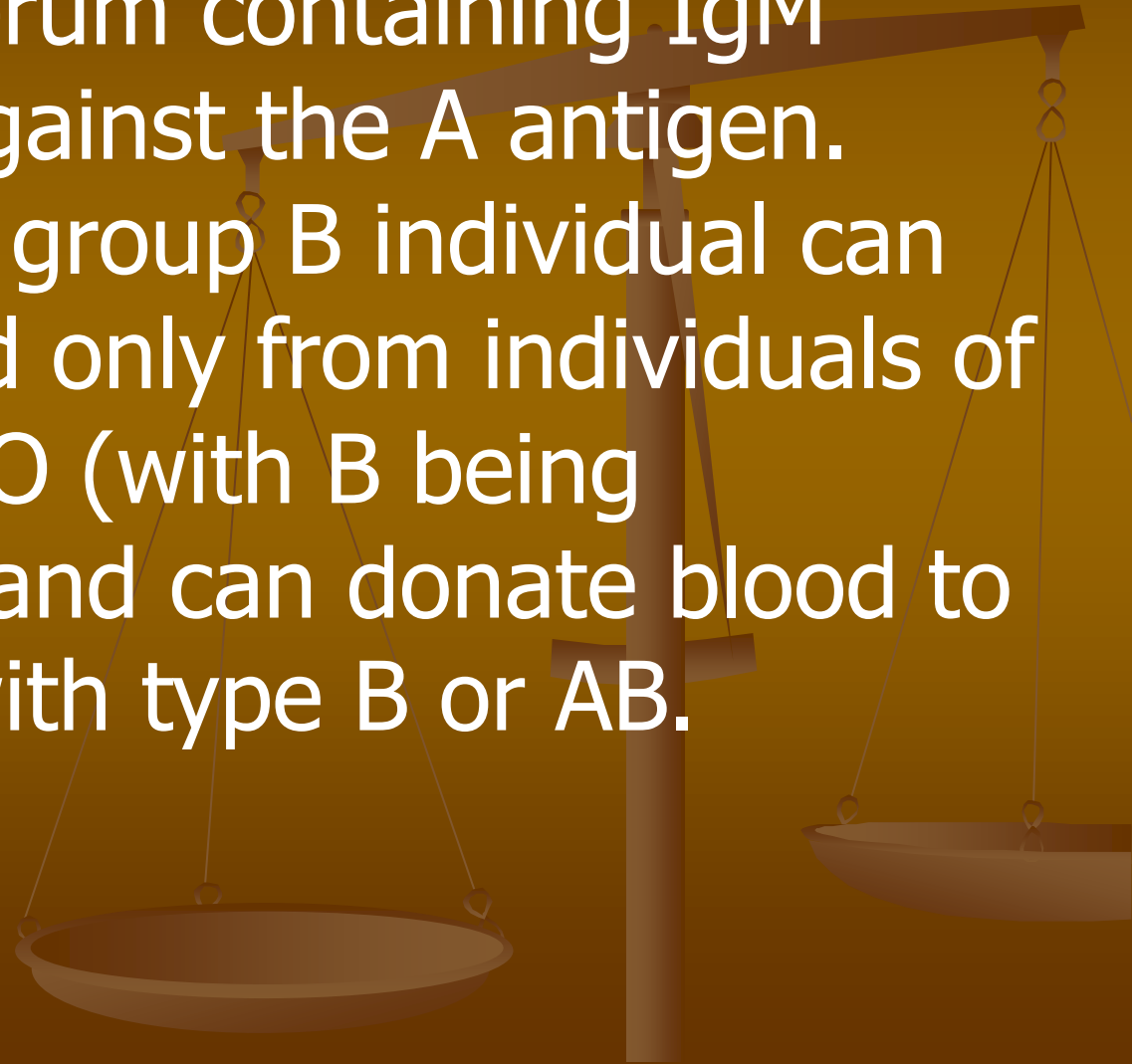
- Blood group AB individuals have both A and B antigens on the surface of their RBCs, and their blood serum does not contain any antibodies against either A or B antigen. Therefore, an individual with type AB blood can receive blood from any group (with AB being preferable), but can donate blood only to another group AB individual.

- Blood group A individuals have the A antigen on the surface of their RBCs, and blood serum containing IgM antibodies against the B antigen. Therefore, a group A individual can receive blood only from individuals of groups A or O (with A being preferable), and can donate blood to individuals with type A or AB.





- Blood group B individuals have the B antigen on the surface of their RBCs, and blood serum containing IgM antibodies against the A antigen. Therefore, a group B individual can receive blood only from individuals of groups B or O (with B being preferable), and can donate blood to individuals with type B or AB.

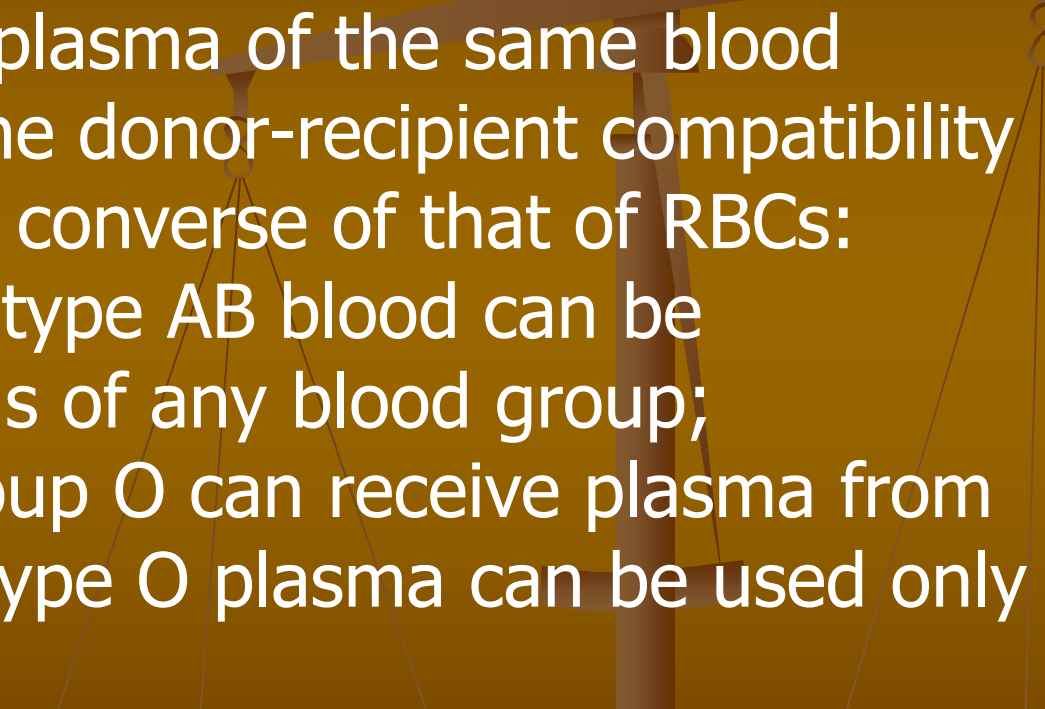


- Blood group O (or blood group zero in some countries) individuals do not have either A or B antigens on the surface of their RBCs, but their blood serum contains IgM anti-A antibodies and anti-B antibodies against the A and B blood group antigens. Therefore, a group O individual can receive blood only from a group O individual, but can donate blood to individuals of any ABO blood group (ie A, B, O or AB). If anyone needs a blood transfusion in a dire emergency, and if the time taken to process the recipient's blood would cause a detrimental delay, O Negative blood can be issued.

# **PLASMA COMPATIBILITY :**

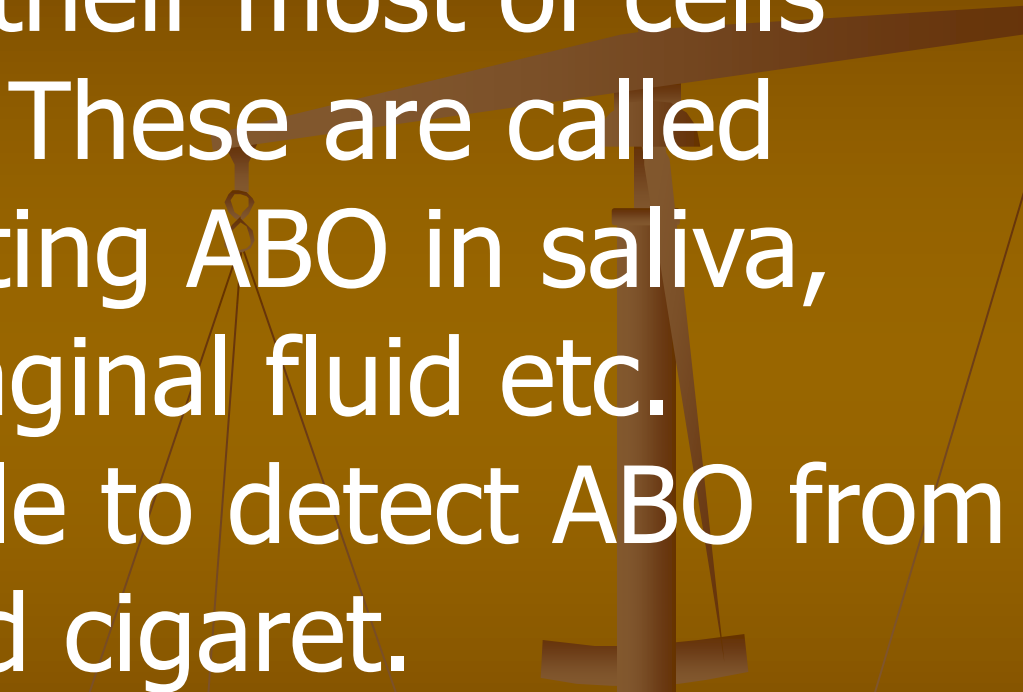
In addition to donating to the same blood group; plasma from type AB can be given to A, B and O; plasma from types A and B can be given to O.

Recipients can receive plasma of the same blood group, but otherwise the donor-recipient compatibility for blood plasma is the converse of that of RBCs: plasma extracted from type AB blood can be transfused to individuals of any blood group; individuals of blood group O can receive plasma from any blood group; and type O plasma can be used only by type O recipients.



## **SECRETOR – NON SECRETOR:**

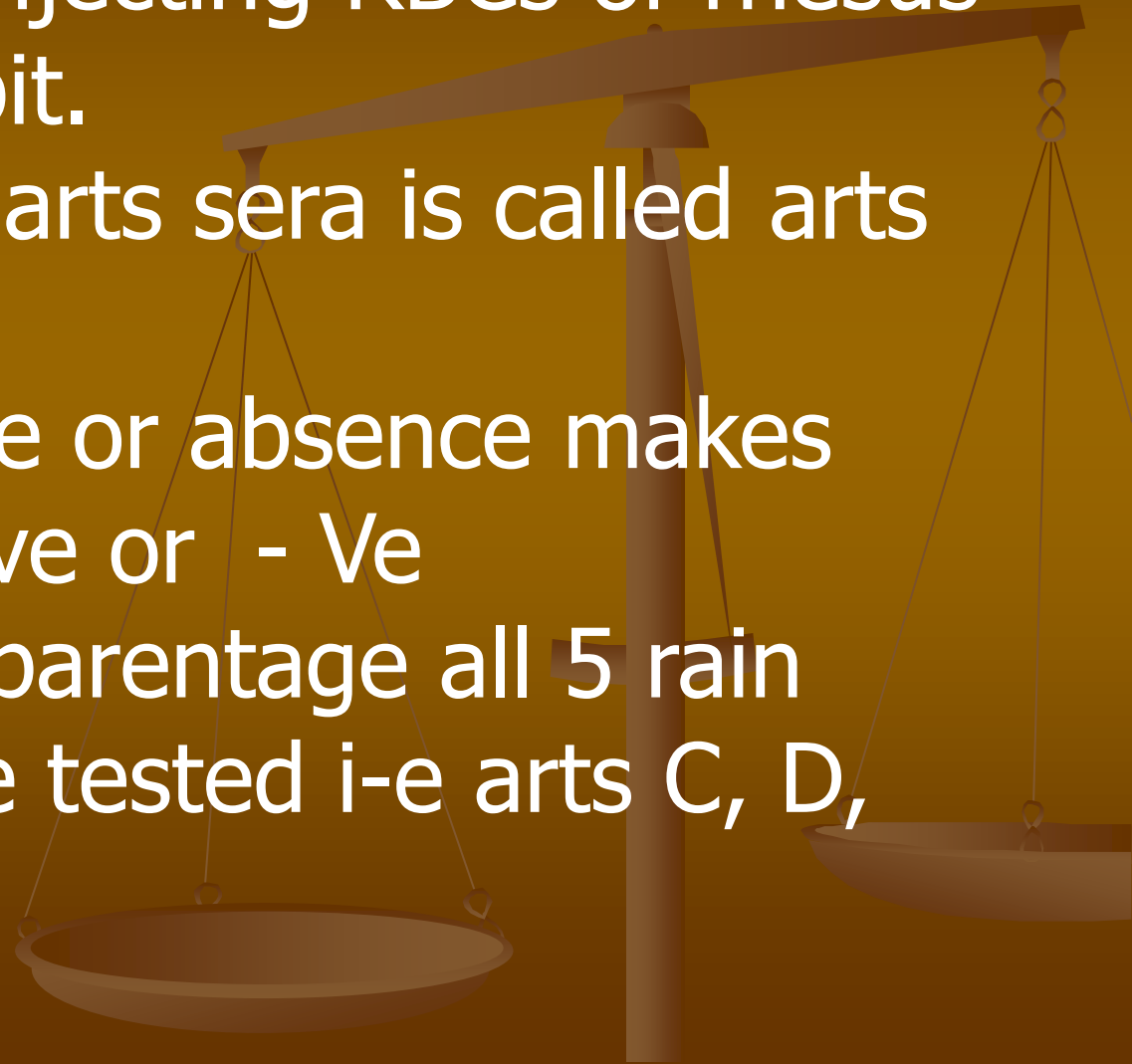
About 80% of population secret ABO blood groups in their most of cells and body fluids. These are called Secretors, secreting ABO in saliva, semen, urine, vaginal fluid etc. Hence its possible to detect ABO from saliva on smoked cigaret.



# **Rh BLOOD GROUP SYSTEM:**

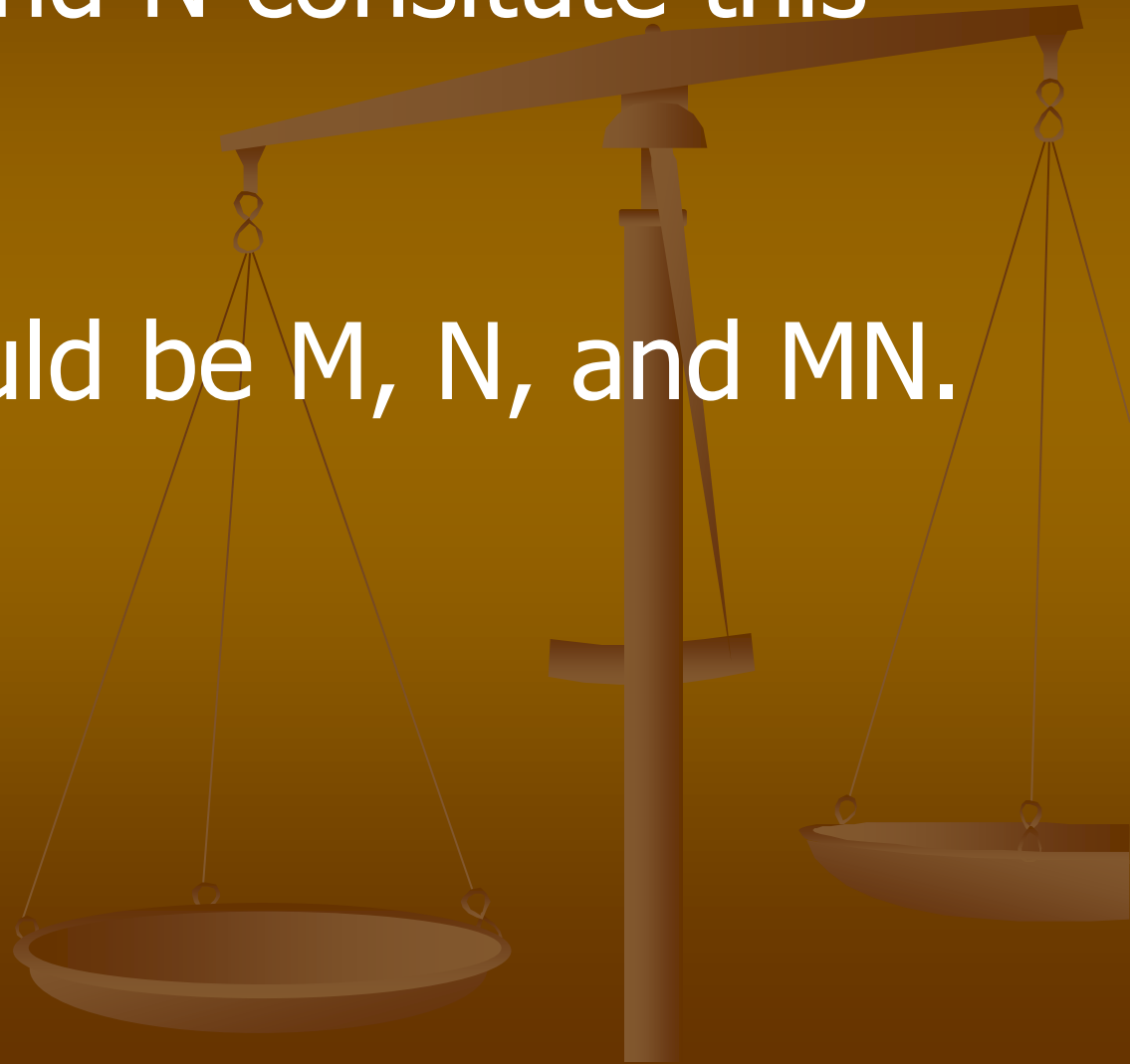
Called rhesus group because its antiserum was obtained by injecting RBCs of rhesus monkey in to rebbit.

- This group is arts sera is called arts D.
- Its preseence or absence makes the person +ve or - Ve
- For disputed parentage all 5 rain ties should be tested i-e arts C, D, E, C, E,



# ***MN GROUP:***

- Antigen M and N constitute this group.
- Varieties could be M, N, and MN.



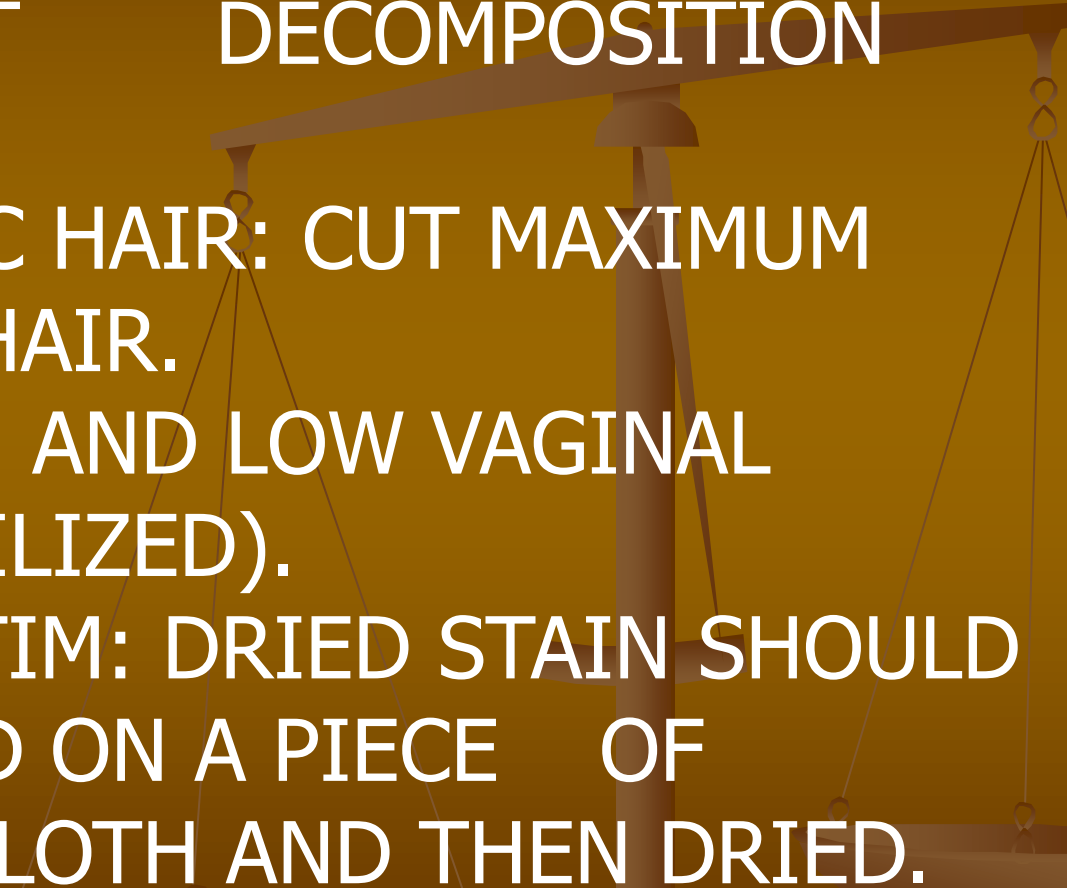
<u>Blood Group</u>		<u>Blood Group of Children</u>	
Parent 1	Parent 2	Possible	Not Possible
O	O	O	A, B, AB
O	A	O, A	B, AB
A	A	O, A	B, AB
O	B	O, B	A, AB
B	B	O, B	A, AB
A	B	O, A, B, AB	None
O	AB	A, B	O, AB
A	AB	A, B, AB	O
B	AB	A, B, AB	O
AB	AB	A, B, AB	O

# *Examination of Seminal Stain:*

- Seminal stains are next in importance to blood stains.
- this examination is required in cases of sexual offenses e.g.
  - Rape
  - sodomy
  - bestiality
  - attempted sexual murder / lust murder.

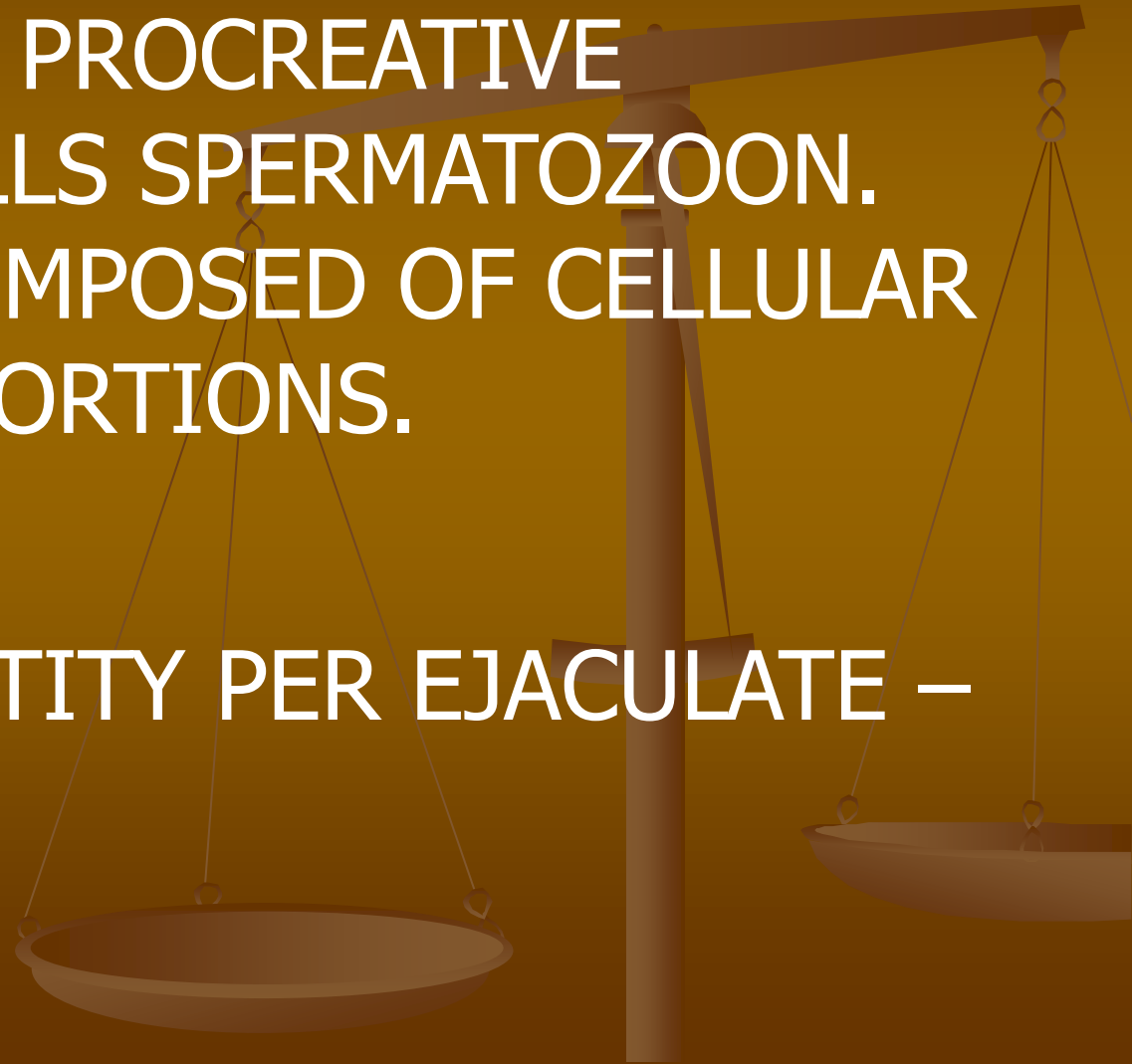


# **HOW TO COLLECT SAMPLE?**

1. CLOTH: CLOTH IS CUT AROUND STAIN, DRIED TO PREVENT DECOMPOSITION AND PACKED.
  2. MATTED PUBIC HAIR: CUT MAXIMUM PORTION OF HAIR.
  3. VAGINA: HIGH AND LOW VAGINAL SWABS (STERILIZED).
  4. BODY OF VICTIM: DRIED STAIN SHOULD BE COLLECTED ON A PIECE OF MOISTENED CLOTH AND THEN DRIED.
- 

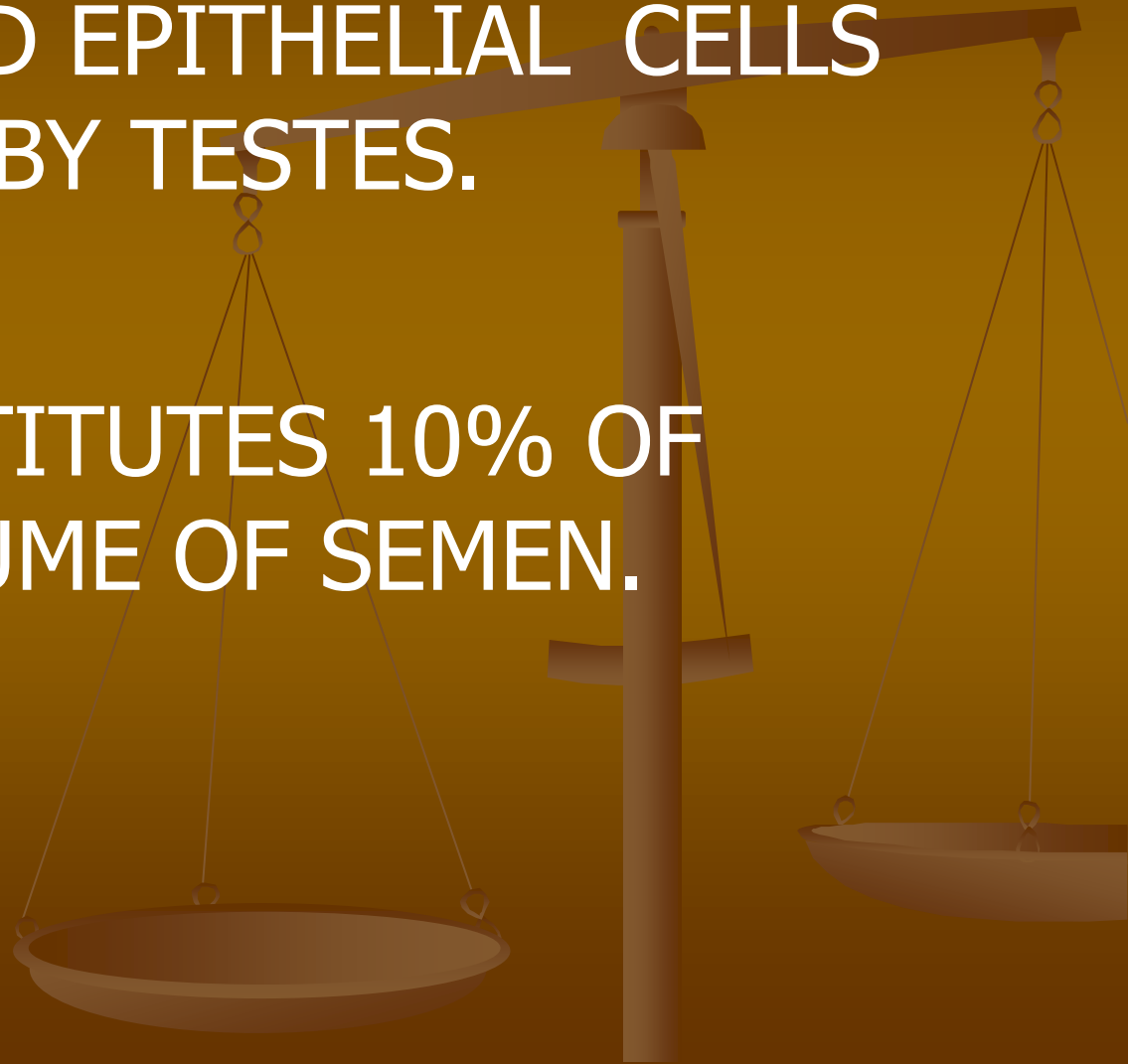
# **SEMEN:**

- SEMEN IS MALE'S BODY FLUID CONTAINING PROCREATIVE HAPLOID CELLS SPERMATOZOOM.
- SEMEN IS COMPOSED OF CELLULAR AND FLUID PORTIONS.
- TOTAL QUANTITY PER EJACULATE – 2-5 ML



## **CELLULAR PORTION:**

- THIS PORTION CONSISTS OF SPERMS AND EPITHELIAL CELLS PRODUCED BY TESTES.
- THIS CONSTITUTES 10% OF TOTAL VOLUME OF SEMEN.



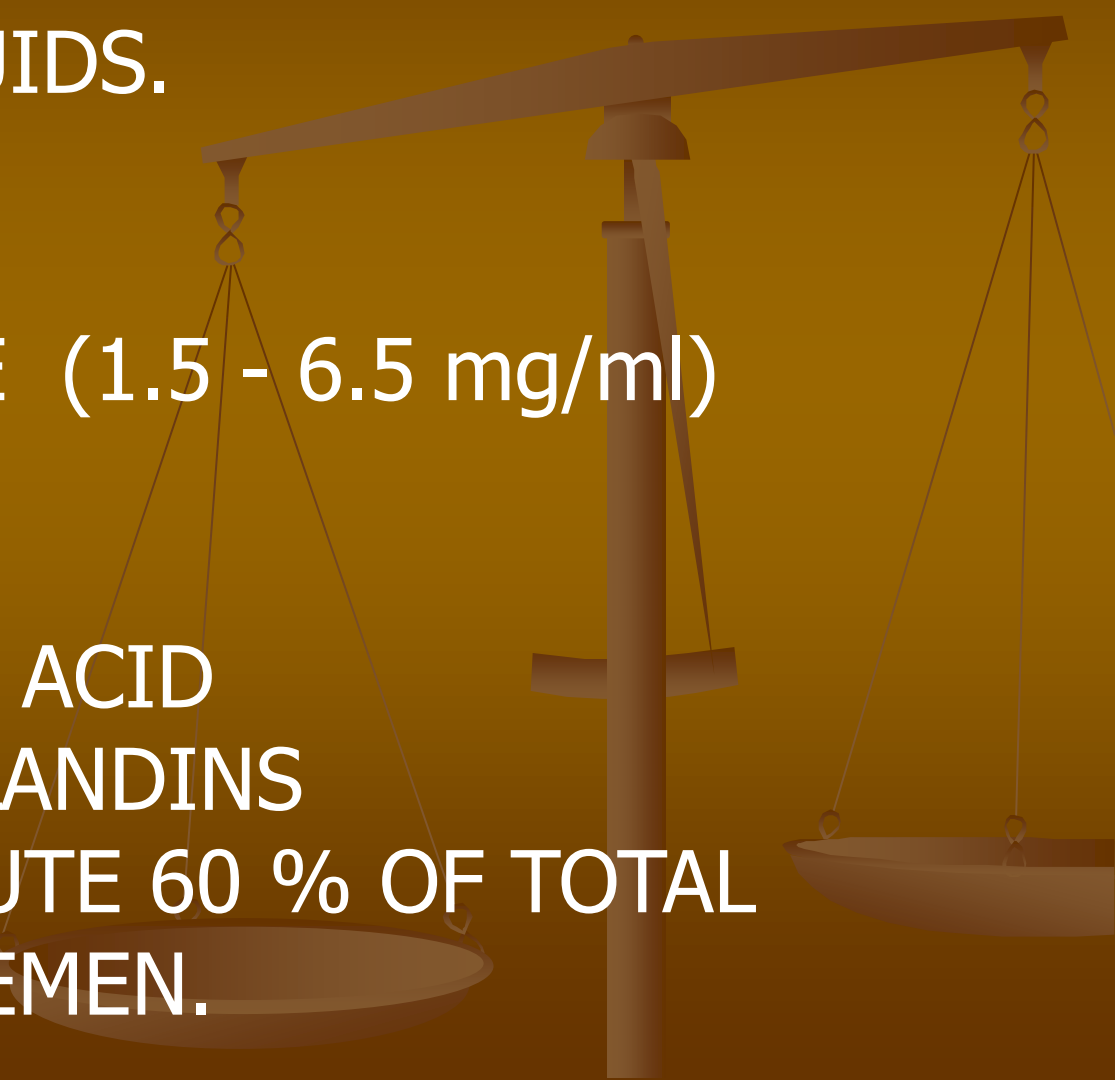
# **FLUID PORTION:**

- THIS CONSISTS OF SEMINAL AND PROSTATIC FLUIDS.

## **SEMINAL FLUID:**

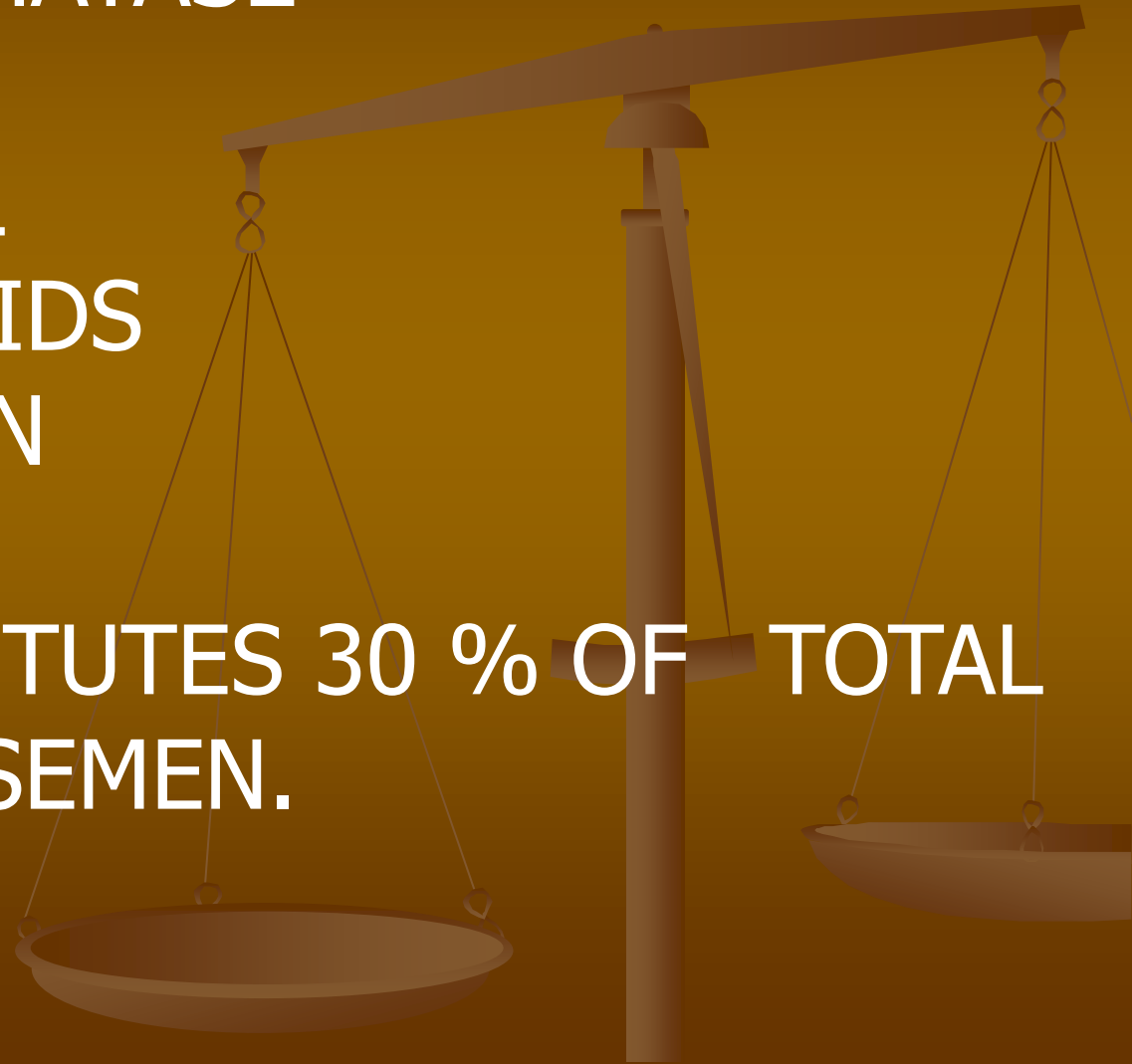CONTAINS

- FRUCTOSE (1.5 - 6.5 mg/ml)
- CHOLINE
- LECITHIN
- ASCORBIC ACID
- PROSTAGLANDINS
- THIS CONSTITUTE 60 % OF TOTAL VOLUME OF SEMEN.

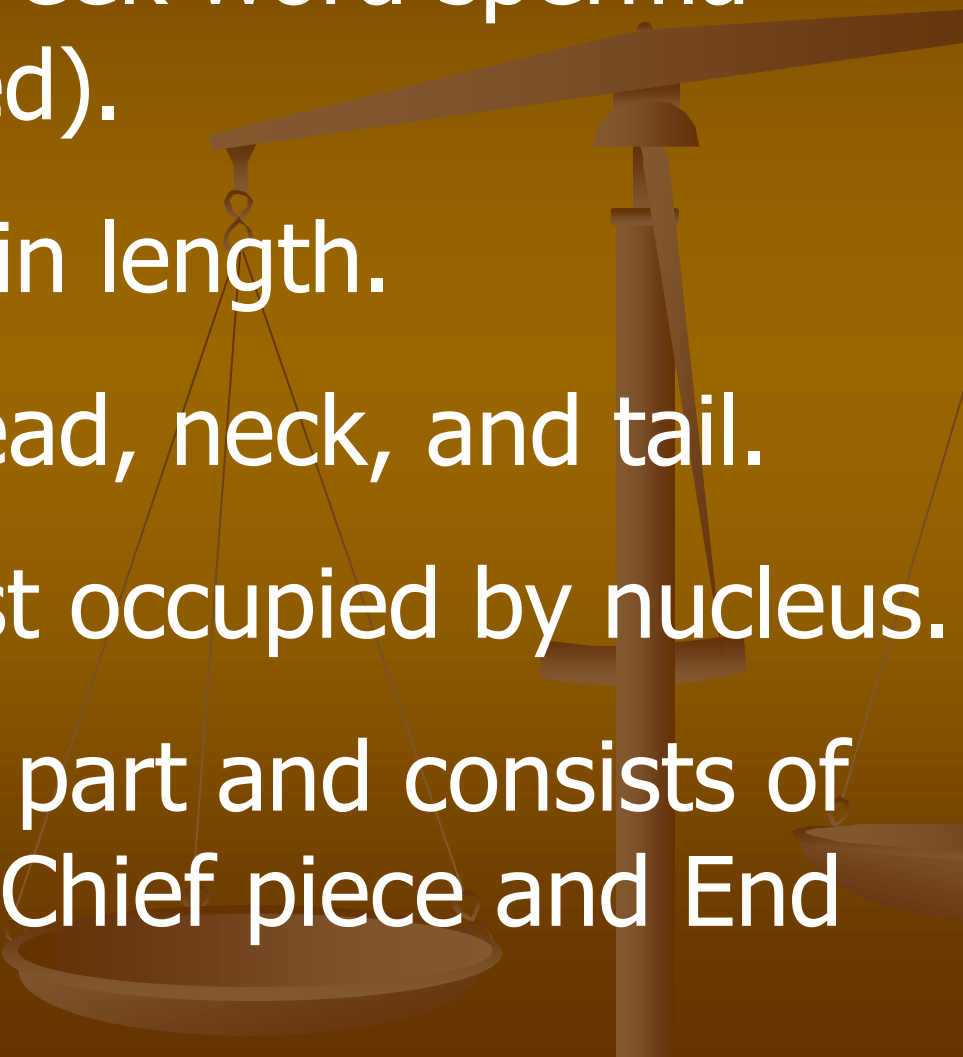


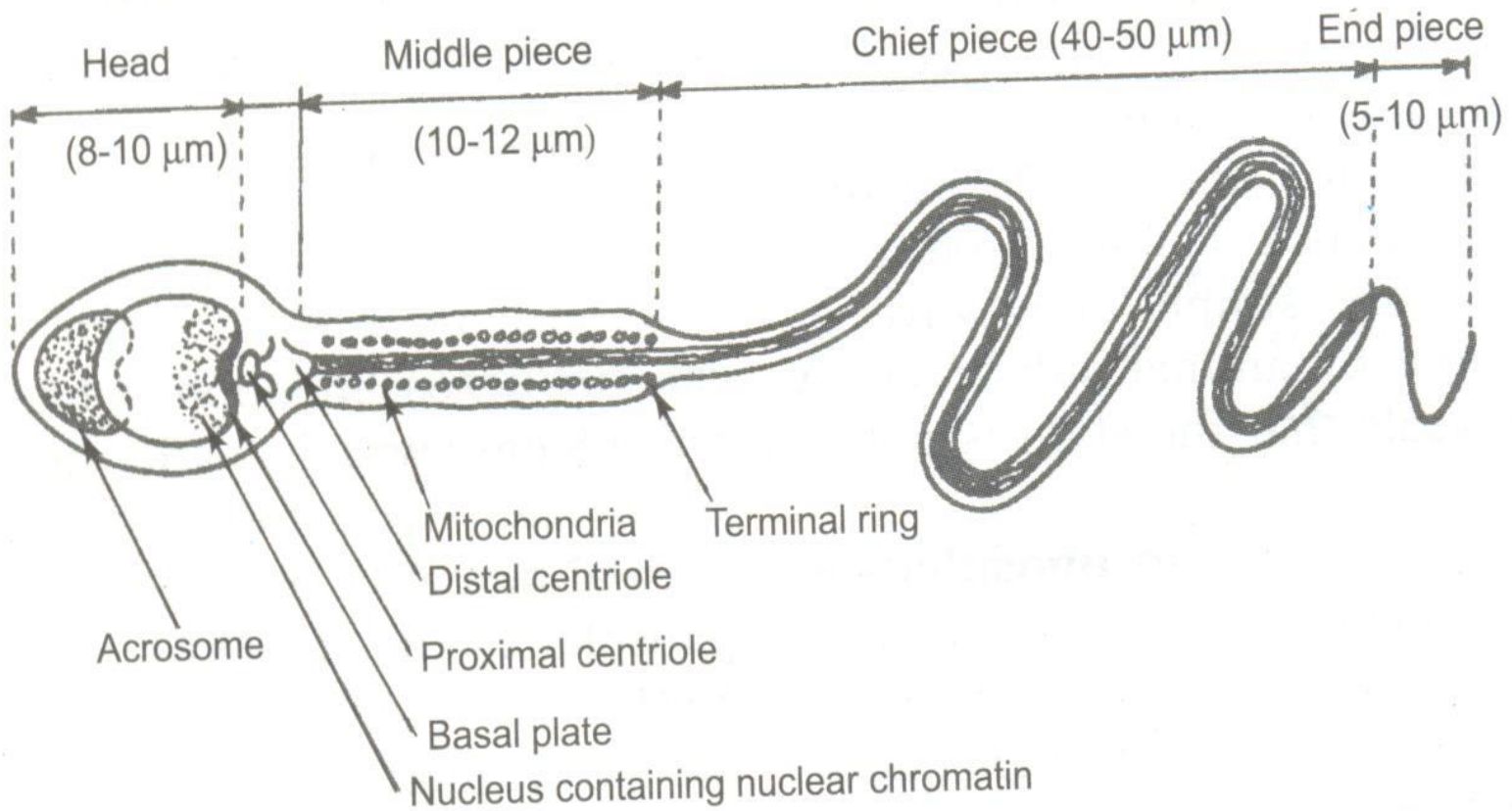
# ***PROSTATIC FLUID***

- ACID PHOSPHATASE
- SPERMINE
- CHOLESTROL
- PHOSPHOLIPIDS
- FIBRINOLYSIN
- ZINC
- THIS CONSTITUTES 30 % OF TOTAL VOLUME OF SEMEN.



# **SPERM:**

- Taken from Greek word sperma (means = seed).
  - About 60  $\mu\text{m}$  in length.
  - Consists of head, neck, and tail.
  - Head is almost occupied by nucleus.
  - Tail is longest part and consists of Middle piece, Chief piece and End piece.
- 



**Fig. 22.6.** Ultramicroscopic structure of human sperm.

# *Normal physiology of sperm:*

- COUNT - 40 – 20 Millions / ml

( <40 = OLIGOSPERMIA )

- MOTILITY - > 80% SPERMS ARE MOTILE

- SPEED 1-4 mm / Minute

- <80% ASTHENOSPERMIA )

- MORPHOLOGY - 80 % NORMAL.

## **HARD PARAMETERS TO OVER COME**

- ADVERSE ACIDIC pH OF VAGINA

- IRREGULAR, UPWARD, UNEVEN PATHWAY.



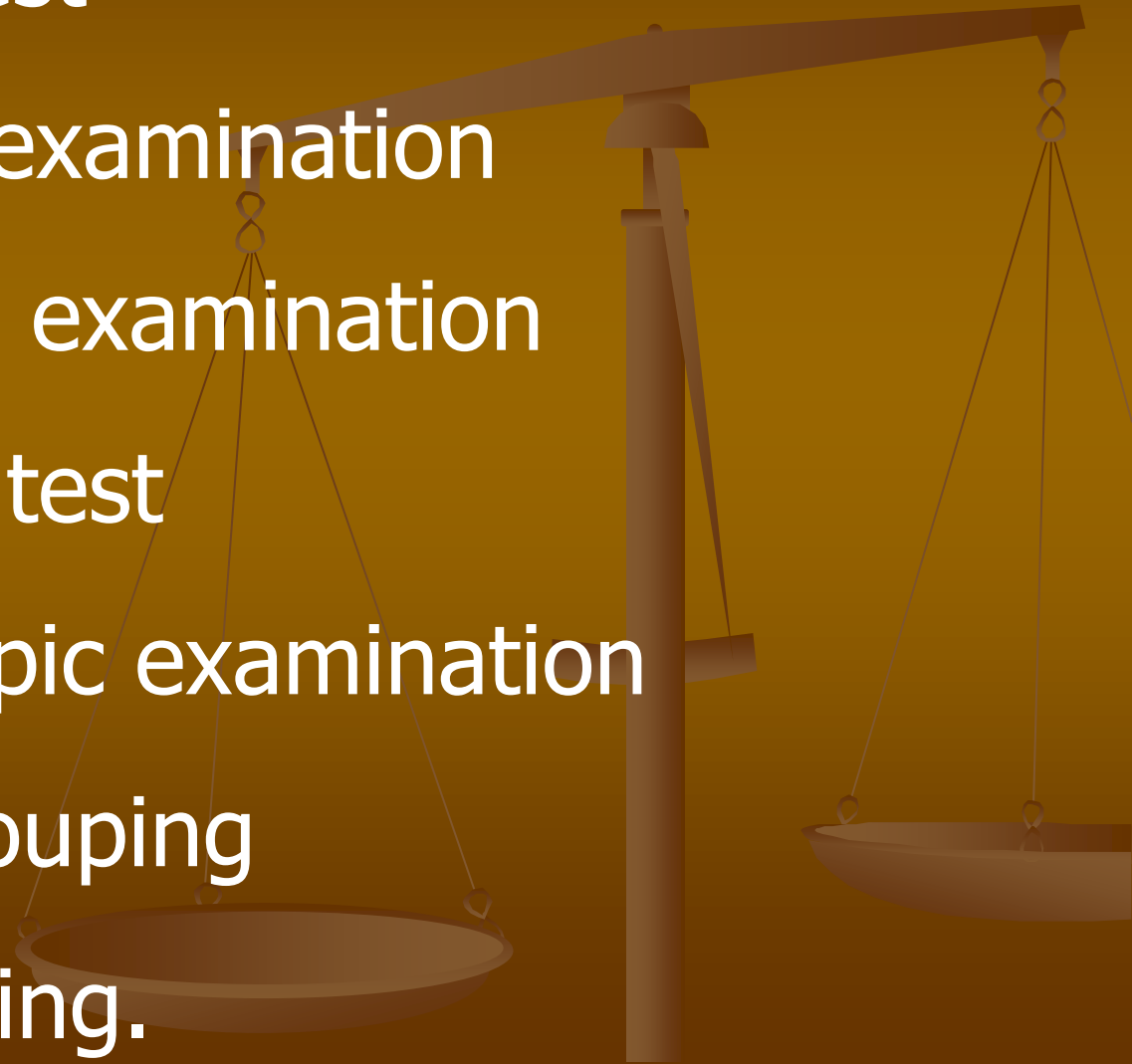
# *Step of Examination of Seminal stain:*

## 1. Preliminary test

- Physical examination
- Chemical examination

## 2. Confirmatory test

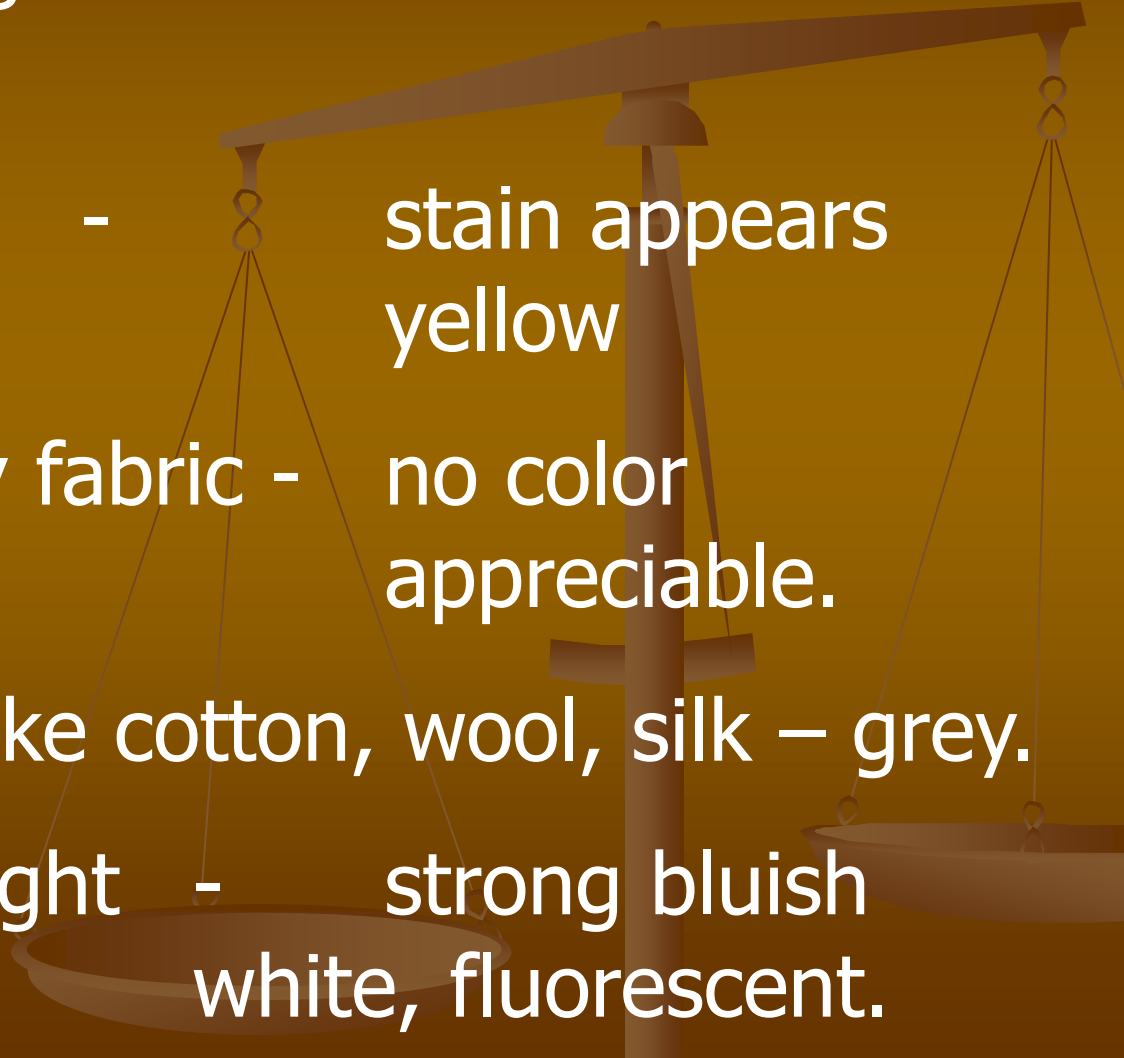- Microscopic examination
- blood grouping
- DNA testing.



# **PHYSICAL EXAMINATION OF STAIN:**

Depends upon background on which stain is located.

- Fabric (white) - stain appears yellow
- Colored or dirty fabric - no color appreciable.
- On absorbent like cotton, wool, silk – grey.
- On ultraviolet light - strong bluish white, fluorescent.



# **CHEMICAL EXAMINATION:**

- Florence test.

for detection of choline (seminal origin)

- Barberio's test

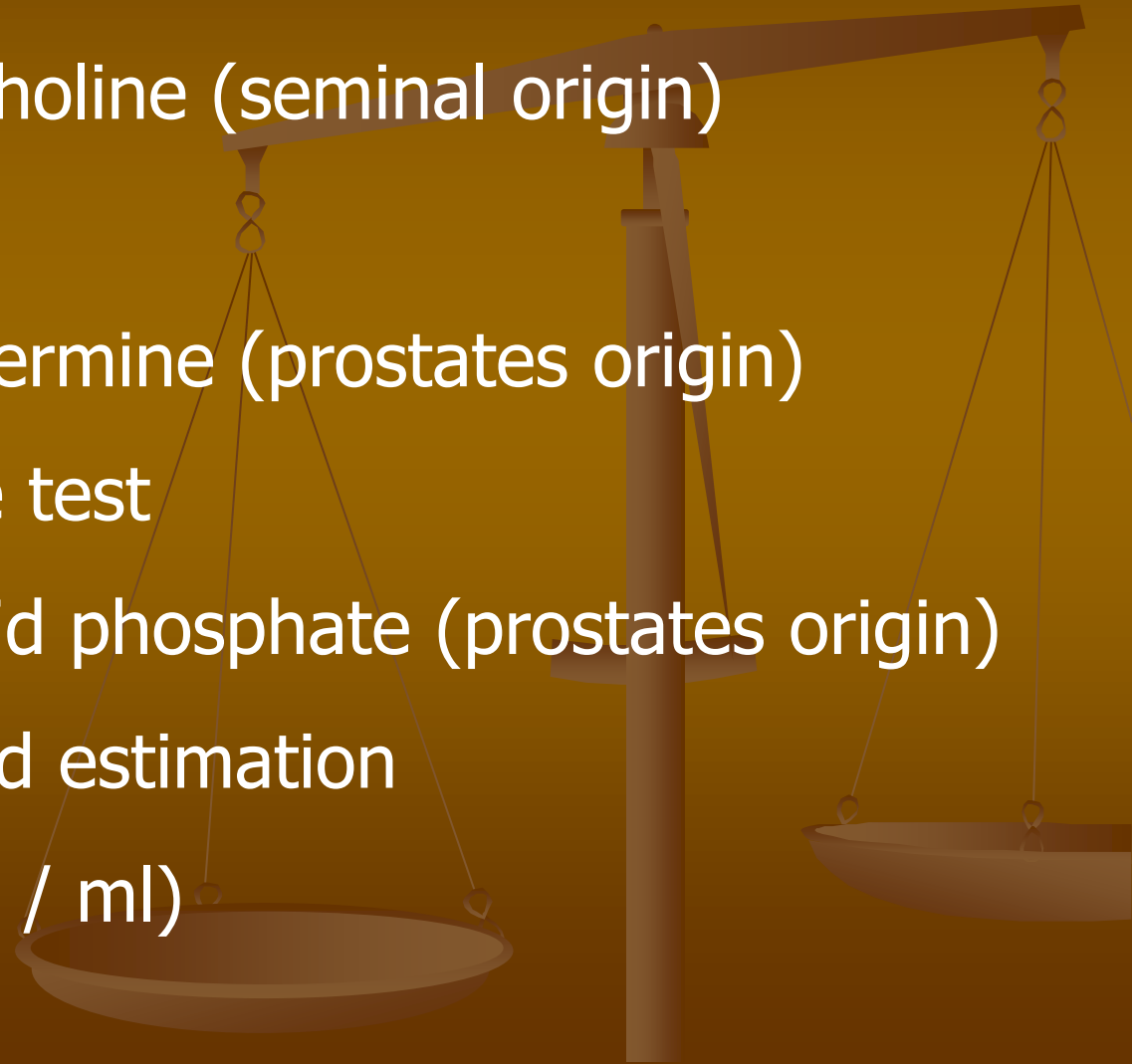
for detection of spermine (prostates origin)

- Acid phosphatase test

for detection of acid phosphate (prostates origin)

- Zinc detection and estimation

(normal – 140 ug / ml)

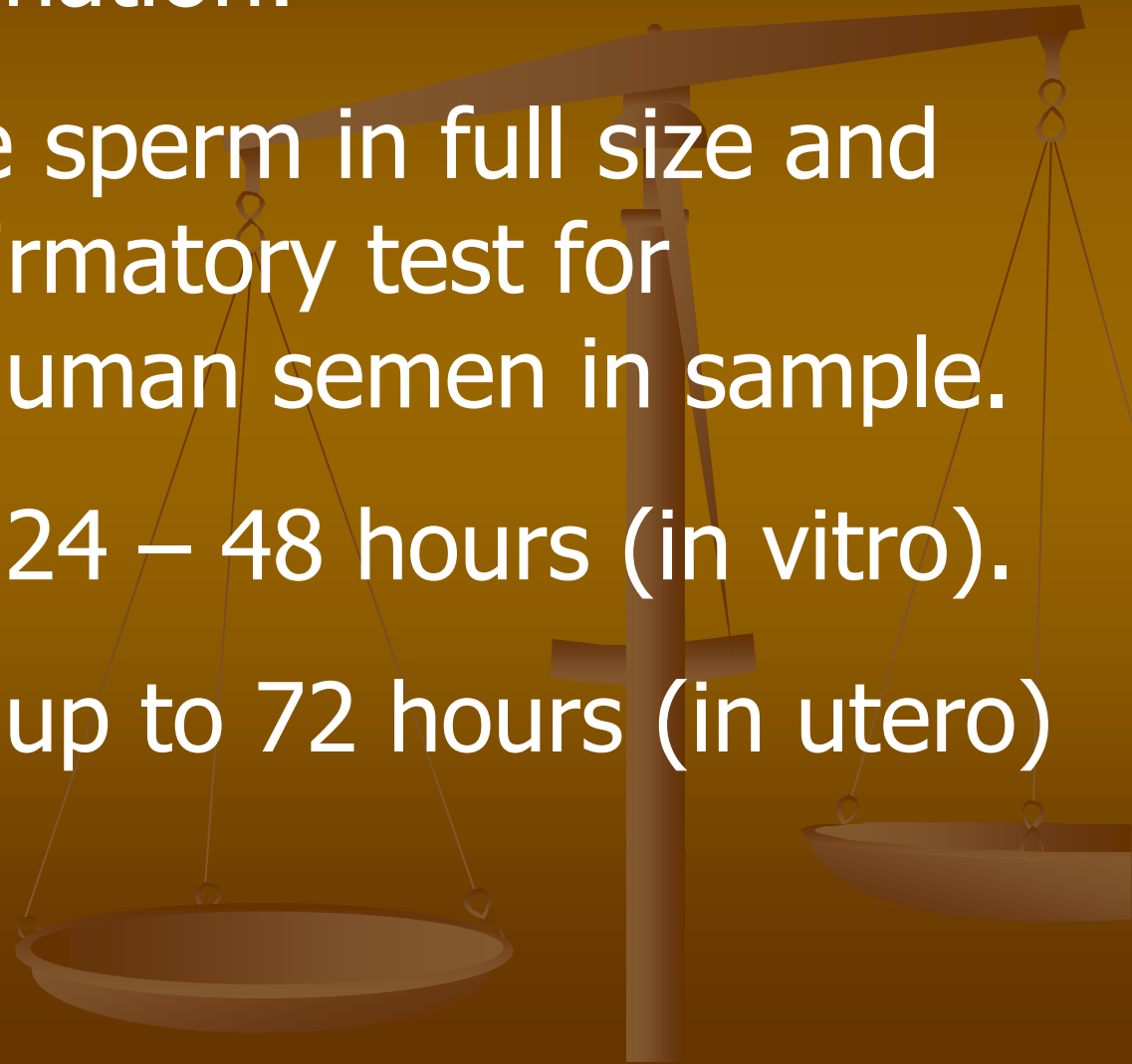


# *Confirmatory tests:*

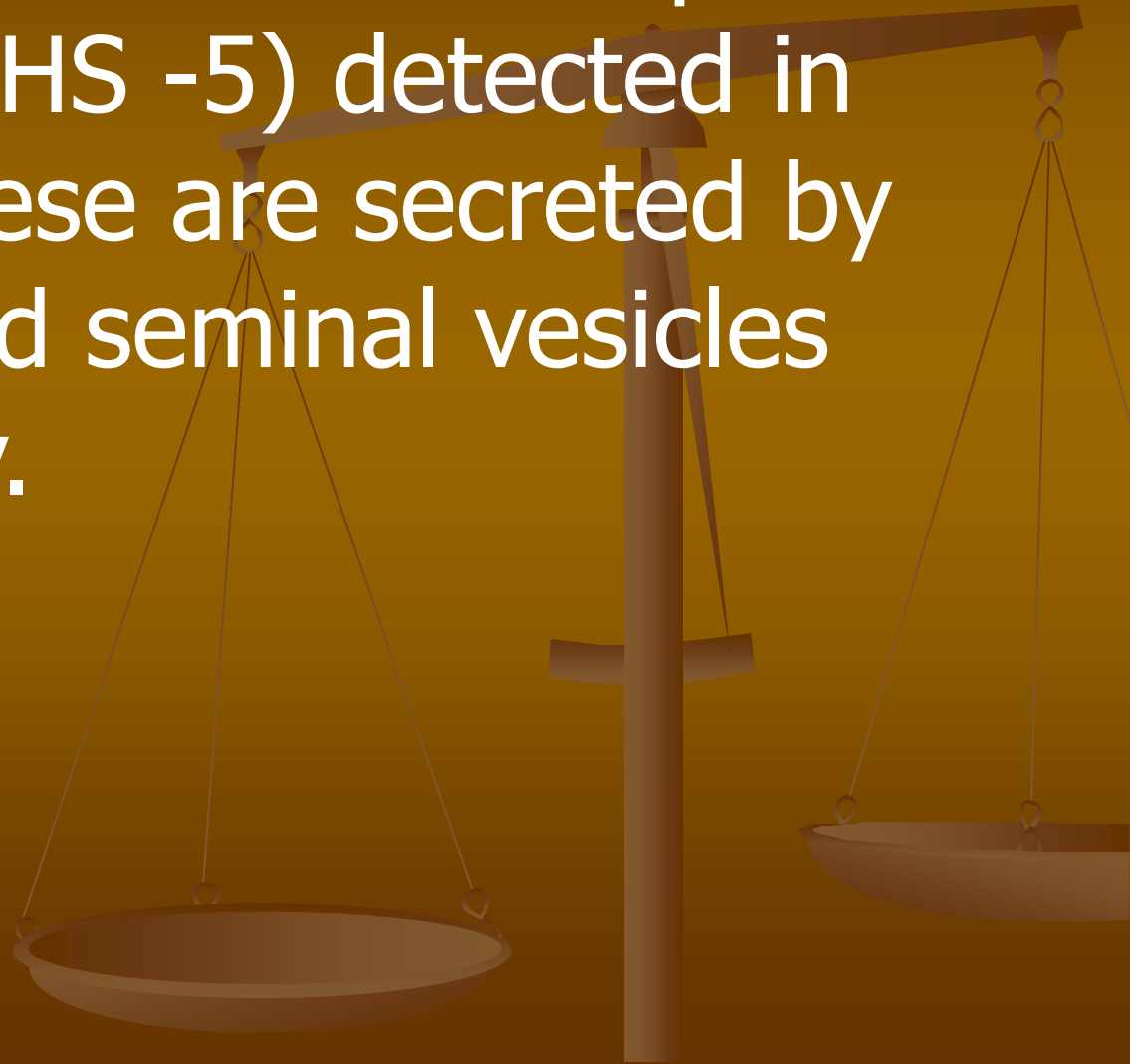Microscopic examination:

- Demonstrable sperm in full size and shape is confirmatory test for presence of human semen in sample.

Age of sperm.      24 – 48 hours (in vitro).  
up to 72 hours (in utero)



- PSA prostates specific antigen (P-30), and seminal vesicle specific antigen ( MHS -5) detected in sample. These are secreted by prostate and seminal vesicles respectively.

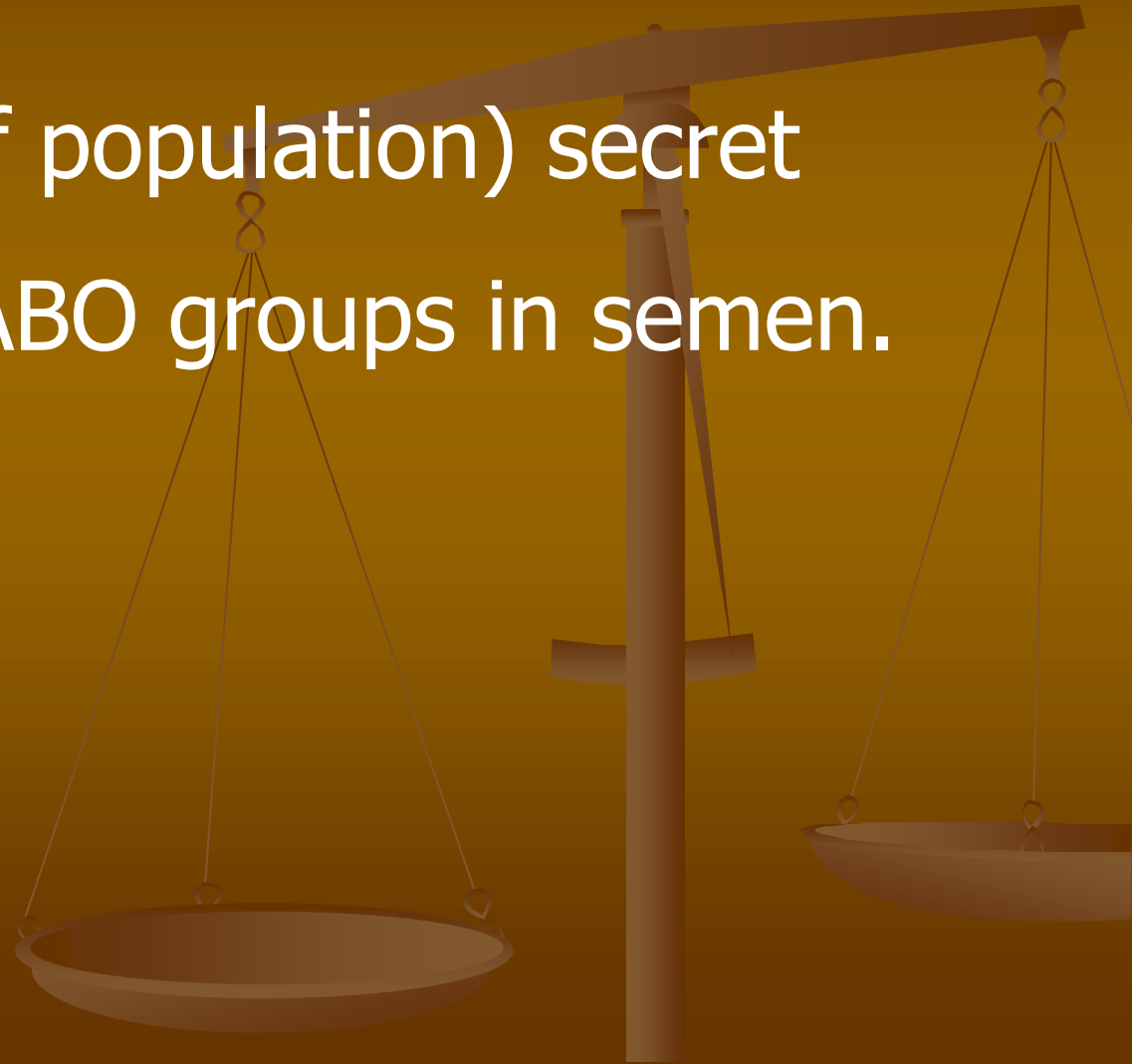

## **Blood groups:**

Secretors (80% of population) secrete

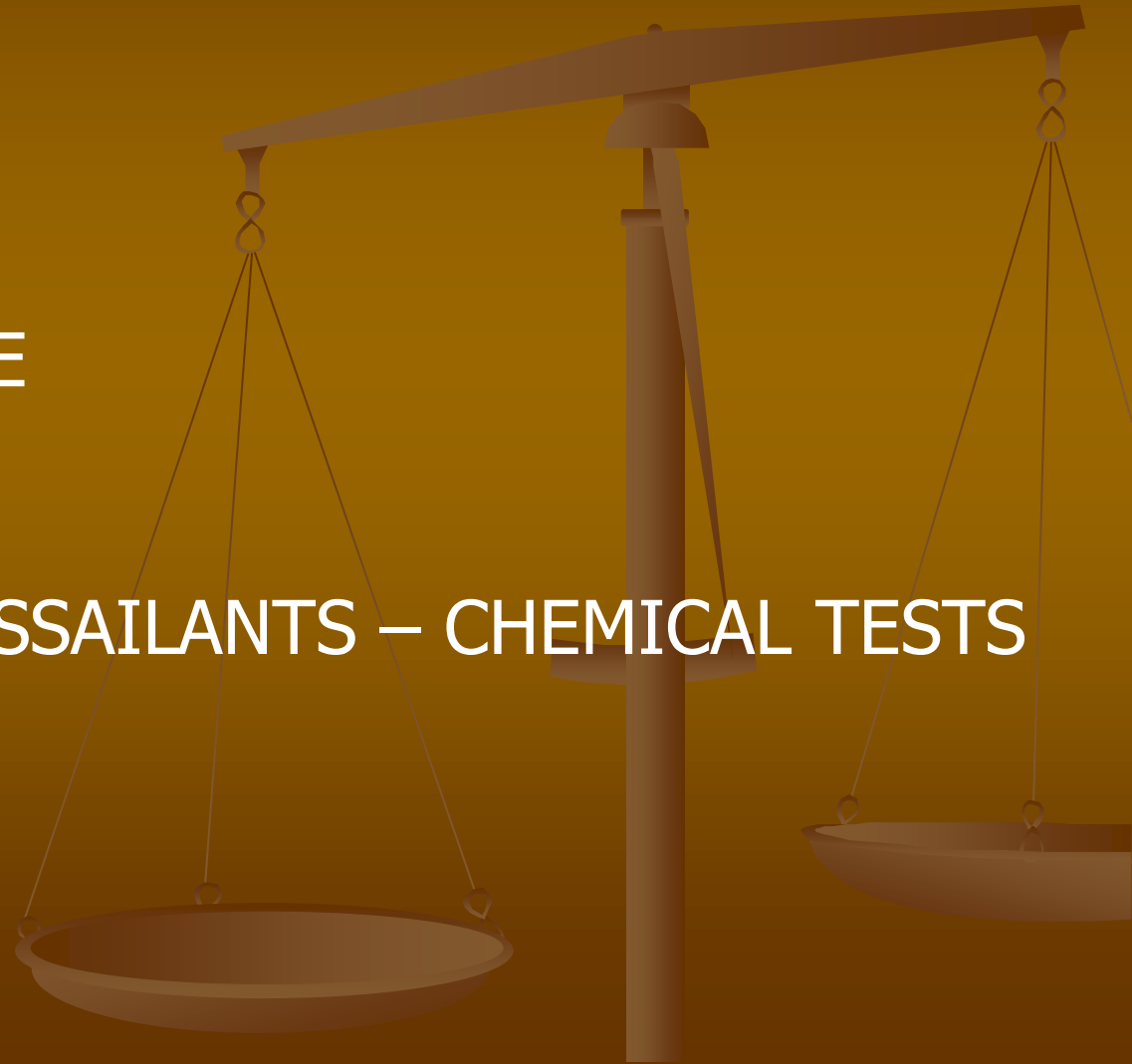
ABO groups in semen.

**DNA Testing.**



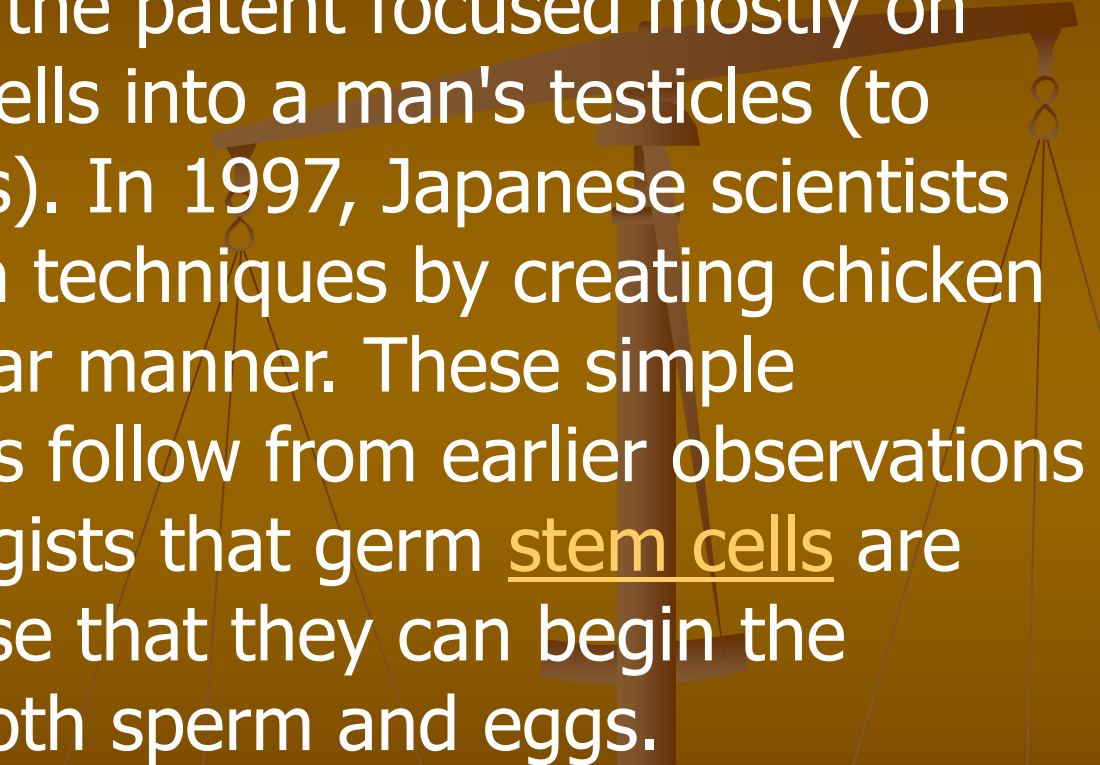
# MLI

- RAPE
- SODOMY
- BESTIALITY
- ATTEMPTED RAPE
- LUST MURDERS
- AZOOSPERMIC ASSAILANTS – CHEMICAL TESTS
- FEMALE SPERM ?
- MALE EGGS ?



# **FEMALE SPERM:**

Creating female sperm was first raised as a possibility in a patent filed in 1991 by injecting a woman's cells into a man's testicles, though the patent focused mostly on injecting altered male cells into a man's testicles (to correct genetic diseases). In 1997, Japanese scientists partially confirmed such techniques by creating chicken female sperm in a similar manner. These simple transplantation methods follow from earlier observations by developmental biologists that germ stem cells are autonomous in the sense that they can begin the processes to become both sperm and eggs.

A faint, semi-transparent illustration of a balance scale is visible in the background of the slide. The scale is positioned vertically, with its central pillar and horizontal beam extending across the right side of the frame. Two pans are suspended from the beam by thin wires. The entire background has a dark, textured brown color.

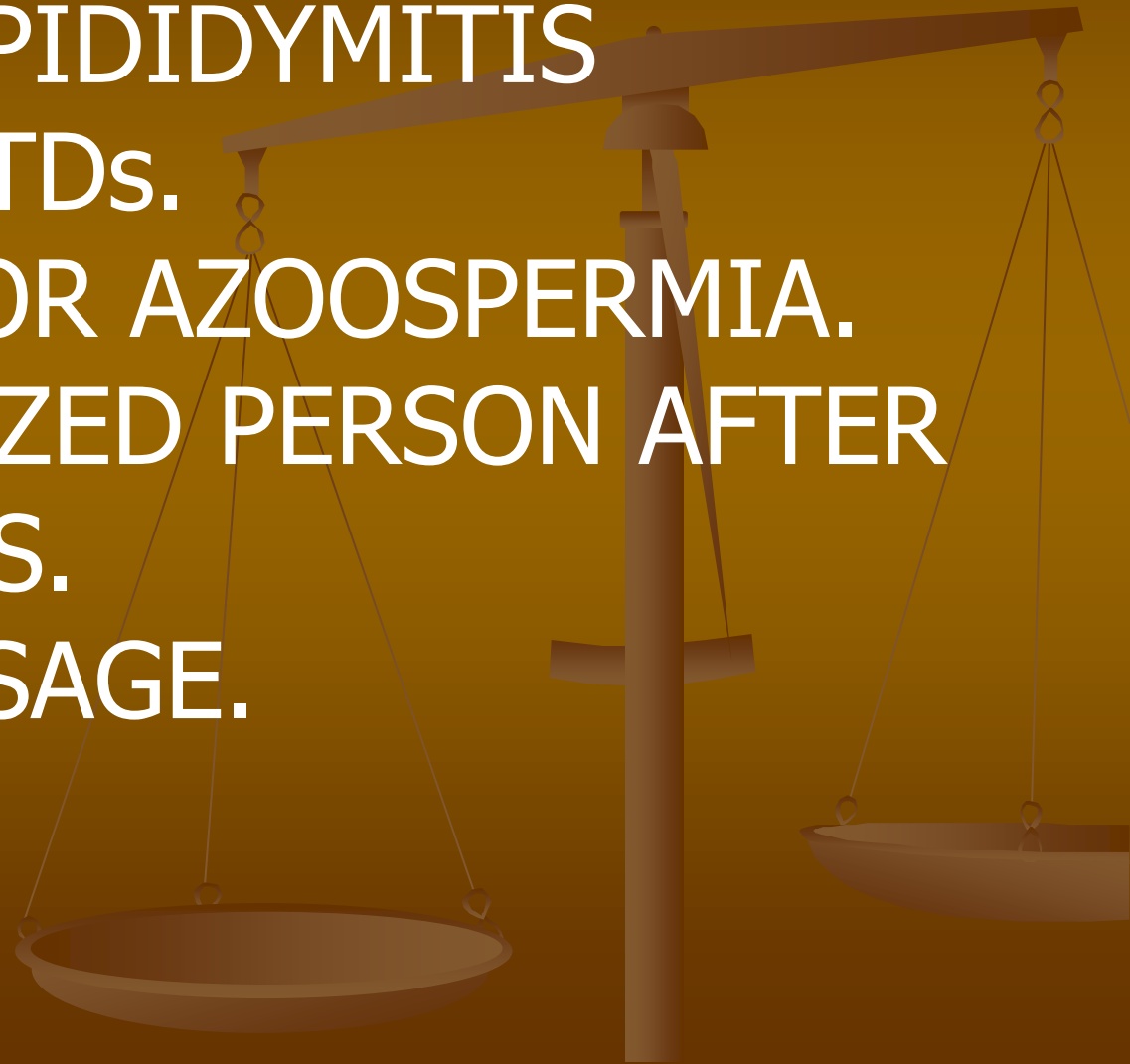


# **MALE EGGS:**

Male eggs are the currently theoretical result of a process in which the eggs of a female would be emptied of their genetic contents (a technique used in the cloning process), and those contents would be replaced with male DNA. Such eggs could then be fertilized by sperm. The procedure was conceived by Dr. Calum MacKellar, a Scottish bioethicist. With this technique, two males could be the biological parents of a child. However, such a procedure would additionally require an artificial womb or a female gestational carrier.

# **FAILURE TO FIND SPERMS IN STAIN**

- CHRONIC EPIDIDYMITIS
- CHRONIC STDs.
- ASPERMIA OR AZOOSPERMIA.
- VASECTOMIZED PERSON AFTER SIX MONTHS.
- CONDOM USAGE.



# *HAIR*



CONSISTS OF

ROOT

SHAFT

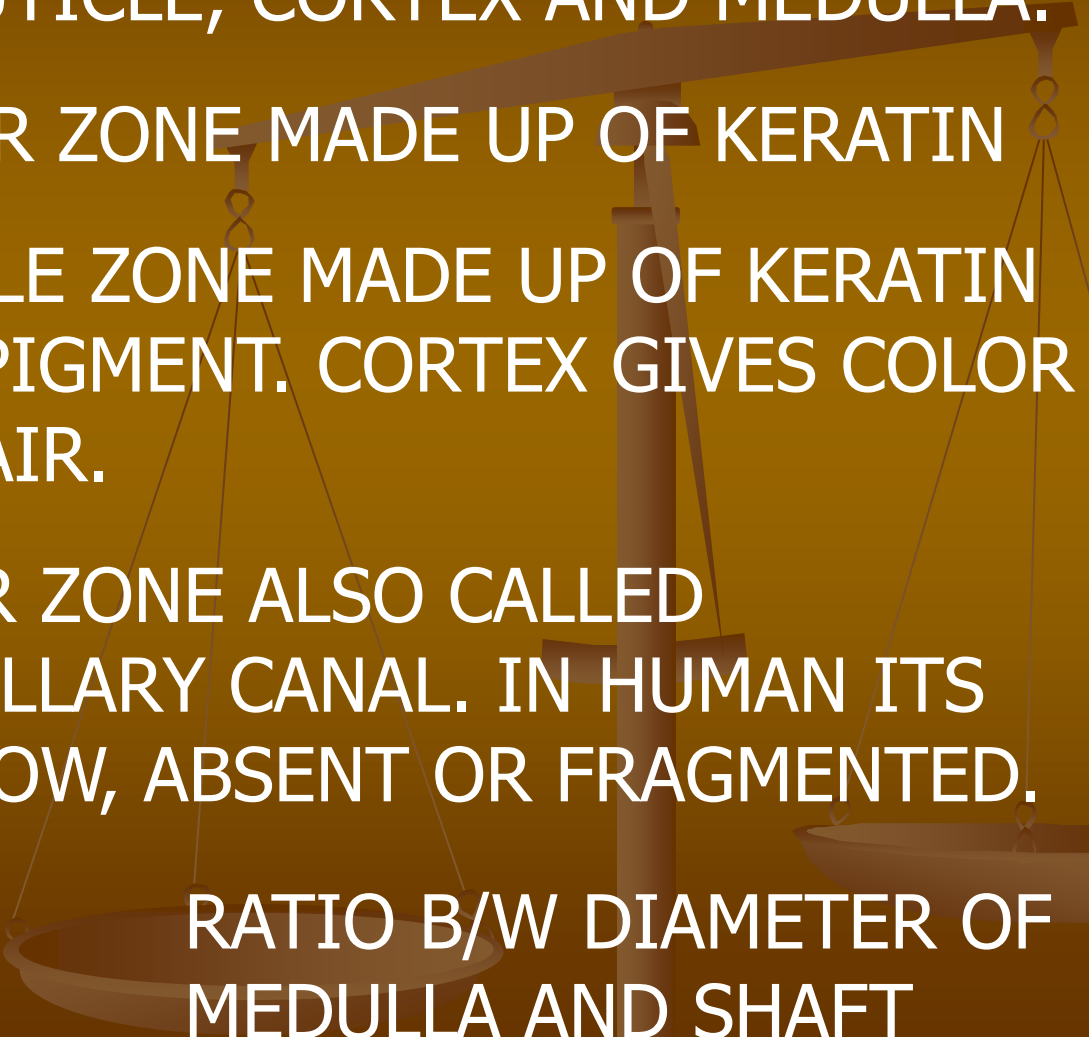
TIP

LIES IN DERMIS

PROTRUDED PART  
OF HAIR

DISTAL END OF  
SHAFT

# ***STRUCTURE OF HAIR***

- CONSISTS** OF CUTICLE, CORTEX AND MEDULLA.
- CUTICLE:** OUTER ZONE MADE UP OF KERATIN
- CORTEX:** MIDDLE ZONE MADE UP OF KERATIN AND PIGMENT. CORTEX GIVES COLOR TO HAIR.
- MEDULLA:** INNER ZONE ALSO CALLED MEDULLARY CANAL. IN HUMAN ITS NARROW, ABSENT OR FRAGMENTED.
- MEDULLARY INDEX:** RATIO B/W DIAMETER OF MEDULLA AND SHAFT
- 

# **MEDICO LEGAL IMPORTANCE OF HAIR**

**SPECIES.** MEDUL/INDEX 0.3 IN  
HUMAN MORE THAN 0.5 IN  
ANIMALS

**RACE.** PAKISTANI. BLACK, LONG FINE.  
CHINESE. BLACK, LONG THICK.  
NEGROS . WOOLY, SHORT  
CURLY.  
EUROPEAN. FAIR, BROWNISH/  
REDISH AND SHORT.

# AGE

**NEW BORN.**

LANUGO. FINE, SOFT, NON PIGMENTED, NON MEDULLATED.

**NEXT HAIR.**

LESS FINE, PIGMENTED AND MEDULLATED.

**13/14 YEARS.**

PUBIC HAIR APPEAR.

**14/15 YEARS.**

AXILLARY HAIR APPEAR.

**16/18 YEARS.**

BEARD AND MOUSTACHES.

**40 YEARS.**

HAIR APPEAR IN AUDITORY MEATUS. GREYING STARTS.

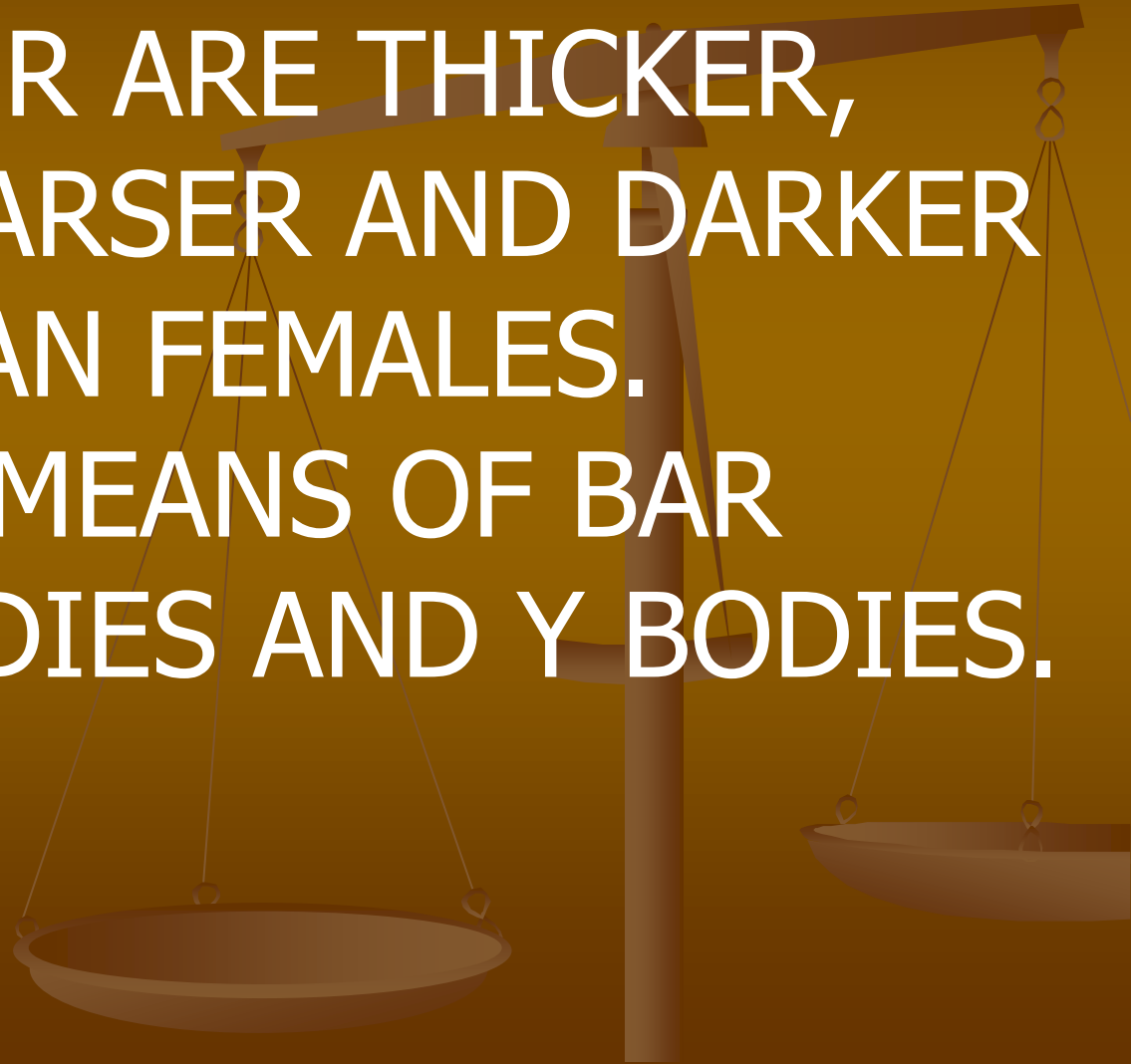
**50/60 YEARS.**

LOSS OF AXILLARY HAIR IN FEMALES.

# *SEX*

**MALES.** HAIR ARE THICKER,  
COARSER AND DARKER  
THAN FEMALES.

**SEXING.** BY MEANS OF BAR  
BODIES AND Y BODIES.



# ***INJURED HAIR***

**RUPTURED CORTEX:**

BLUNT INJURY.

**IRREGULAR HAIR BULB:**

FORCIBLE  
EXTRACTION.

**CLEAR CUT:**

SHARP INJURY.

**SWOLLEN, TWISTED, FOUL SMELL:**

BURNS/  
SINGEING.



# ***HAIR/ HAIRS AS FOREIGN BODY***

**\* RECALL LOCARD'S PRINCIPLE \***

**HUMAN HAIR ON ANIMAL:**

**BESTIALITY.**

**PUBIC HAIR ON OTHER'S BODY:**

**SEXUAL ACT.**

**MUD ON HAIR:**

**STRUGGLE.**

**SEMEN ON HAIR:**

**SEXUAL ACT.**

**BLOOD ON HAIR:**

**INJURY.**

**SALIVA ON HAIR:**

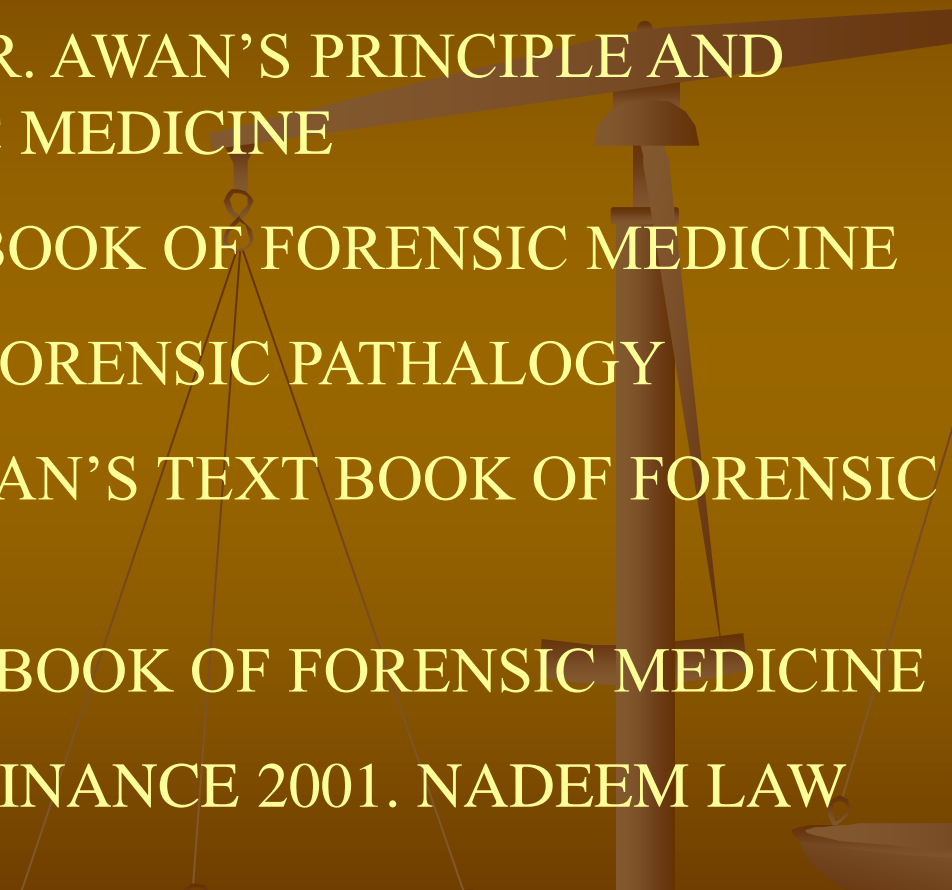
**ASPHYXIA.**

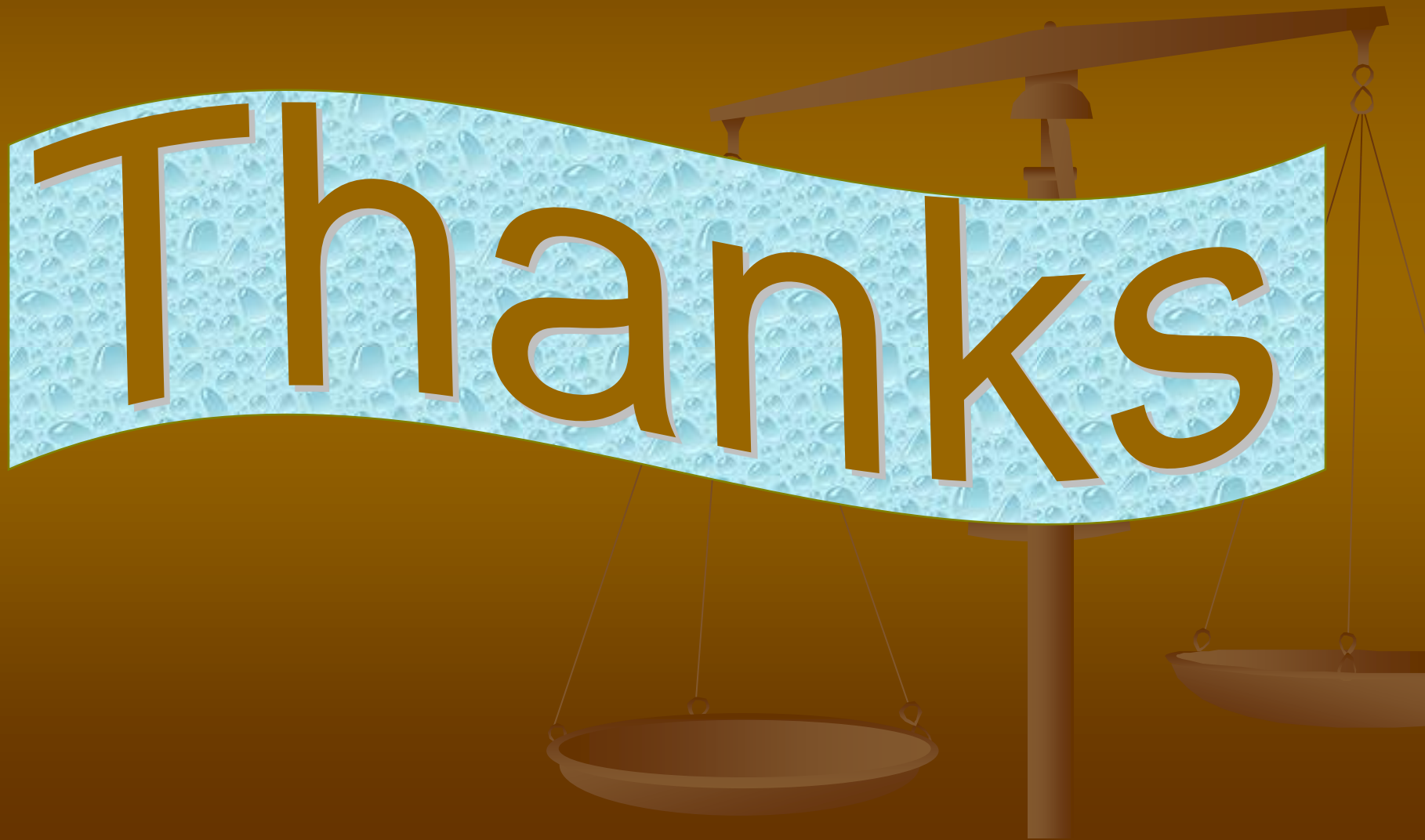**POISON IN HAIR:**

**METALLIC**

**POISONING**

# References

- C.K. PARIKH'S TEXT BOOK OF FORENSIC MEDICINE
  - PROFESSOR NASEEB. R. AWAN'S PRINCIPLE AND PRACTICE OF FORENSIC MEDICINE
  - KRISHAN VIJ'S TEXT BOOK OF FORENSIC MEDICINE
  - BERNARD KNIGHT'S FORENSIC PATHALOGY
  - PROFESSOR UMER KHAN'S TEXT BOOK OF FORENSIC MEDICINE
  - R. K. SHARMA'S TEXT BOOK OF FORENSIC MEDICINE
  - MENTAL HEALTH ORDINANCE 2001. NADEEM LAW BOOK HOUSE, LAHORE.
- 



Thanks