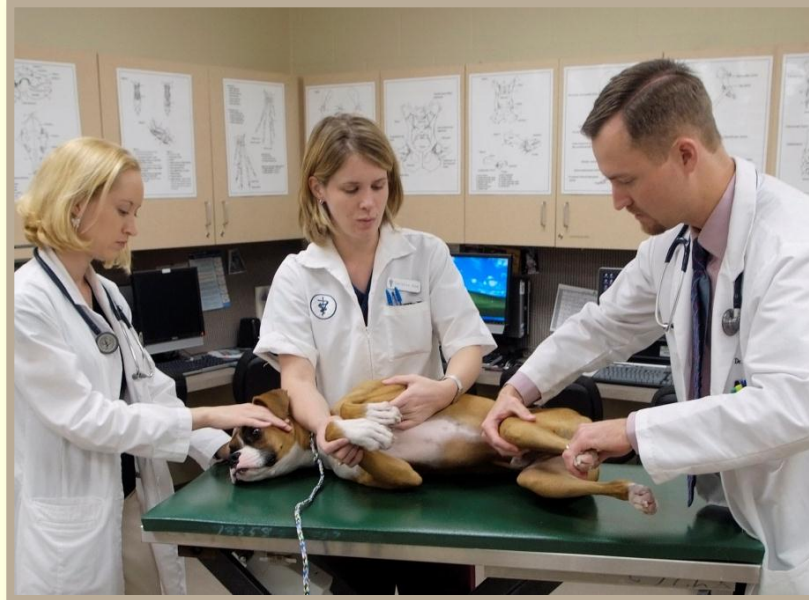

# Veterinary Science

Preparatory Training for the Veterinary Assistant

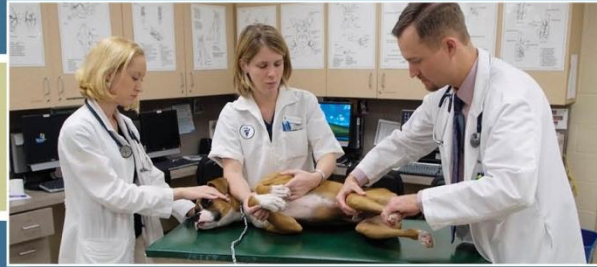Floron C. Faries, Jr., DVM, MS



**FAZD CENTER**

NATIONAL CENTER FOR FOREIGN ANIMAL  
AND ZOONOTIC DISEASE DEFENSE

fazd.tamu.edu



# Anatomy & Physiology of Animals

Floron C. Faries, Jr., DVM, MS

**FAZD CENTER**

NATIONAL CENTER FOR FOREIGN ANIMAL  
AND ZOONOTIC DISEASE DEFENSE

[fazd.tamu.edu](http://fazd.tamu.edu)

# Objectives

---

- Define anatomy
- Discuss the different fields of anatomy
- Identify and describe the integumentary system
- Identify and describe the musculoskeletal system
- Identify and describe the cardiovascular system
- Identify and describe the lymphatic system
- Identify and describe the digestive system
- Identify and describe the respiratory system
- Identify and describe the endocrine system
- Identify and describe the urinary system
- Identify and describe the reproductive system
- Identify and describe the nervous system and special senses

# Definitions

---

- Anatomy
  - The study of the structures of living things
- Physiology
  - The study of the functions of living things
    - Mechanical, physical, or biochemical

# Latin – Anatomy

---


- “ana” “tome”
  - “ana” – again or go back
  - “tome” – to cut
- “cut again” or “go back and cut”
- The study of the structure of the animal body and the relationships of its many parts

# Fields of Anatomy

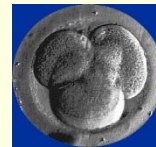---

- Gross anatomy

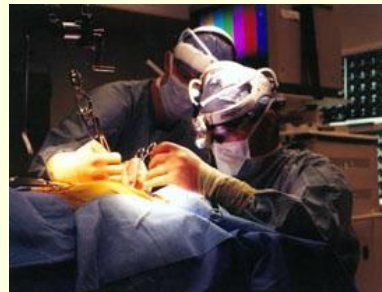
- Microscopic anatomy



- Developmental anatomy



- Applied anatomy



# Study of gross anatomy



- Systemically
- Regionally

## Macroscopic Anatomy (gross anatomy)

Seen with the naked eye by dissection.

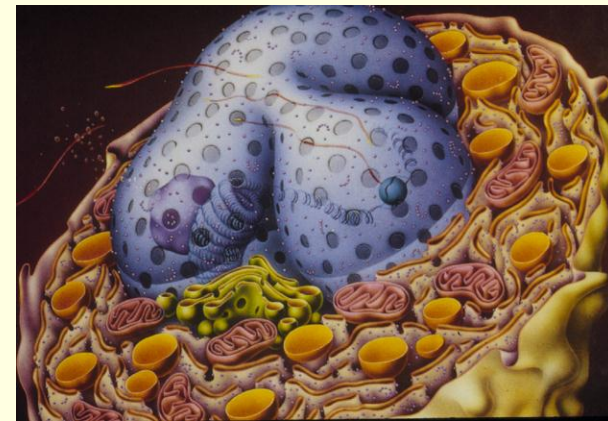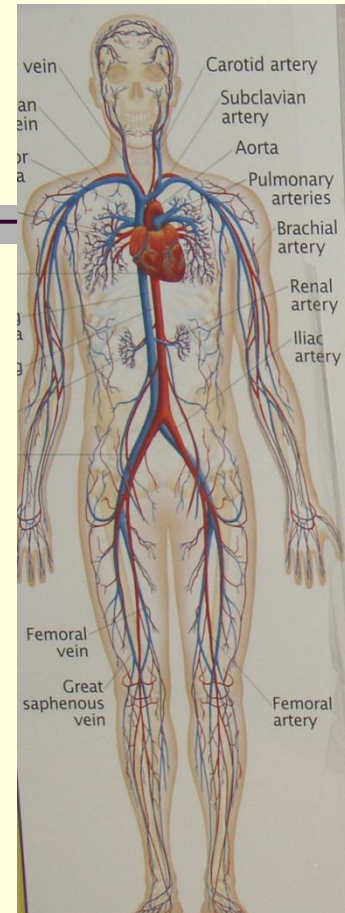
Organs and organ systems

## Microscopic Anatomy

Viewed with a microscope.

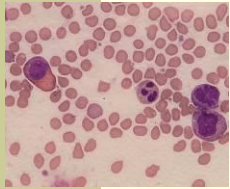
**Cytology**: the study of cells

**Histology**: the study of the *four basic types of tissues*



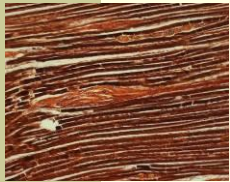


**CELL** – Smallest unit of protoplasm



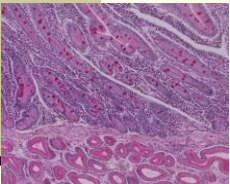
**CELL**

**TISSUE** – Groups of cells with same general function  
e.g., muscle, nerve



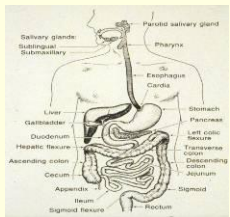
**TISSUE**

**ORGAN** – Two or more types of tissues  
e.g., skin, kidney, intestine, blood vessels



**ORGAN**

**ORGAN SYSTEM** – Several organs  
e.g., respiratory, digestive, reproductive systems

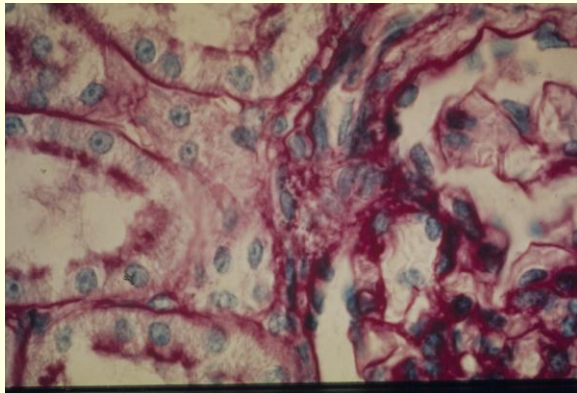


**SYSTEM**

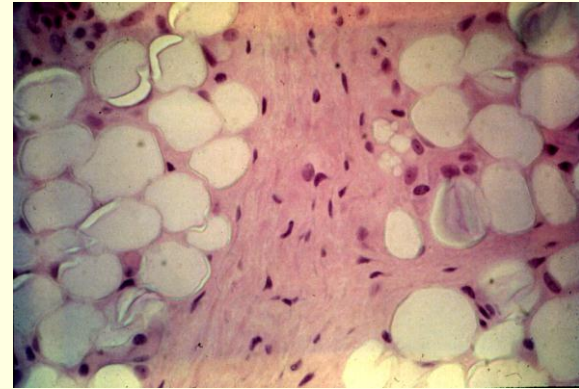
# Four Basic Types of Tissue

---

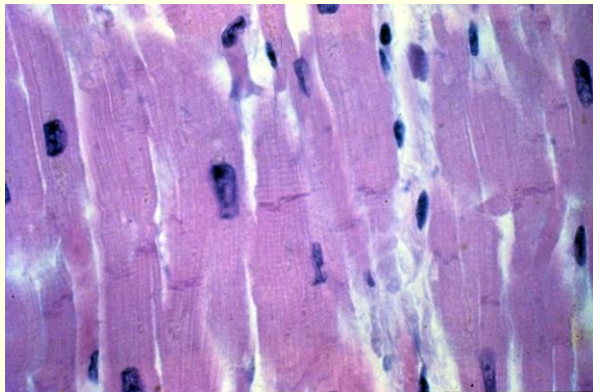
## EPITHELIUM TISSUE



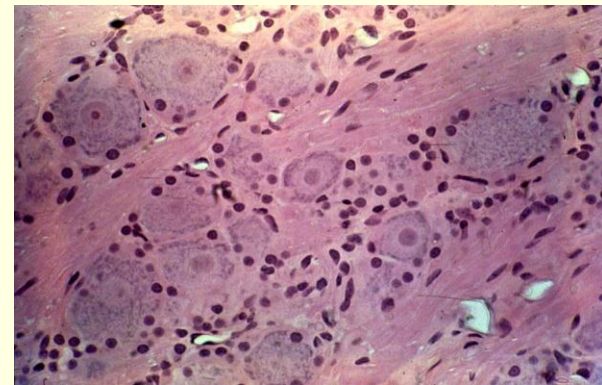
## CONNECTIVE TISSUE



## MUSCULAR TISSUE



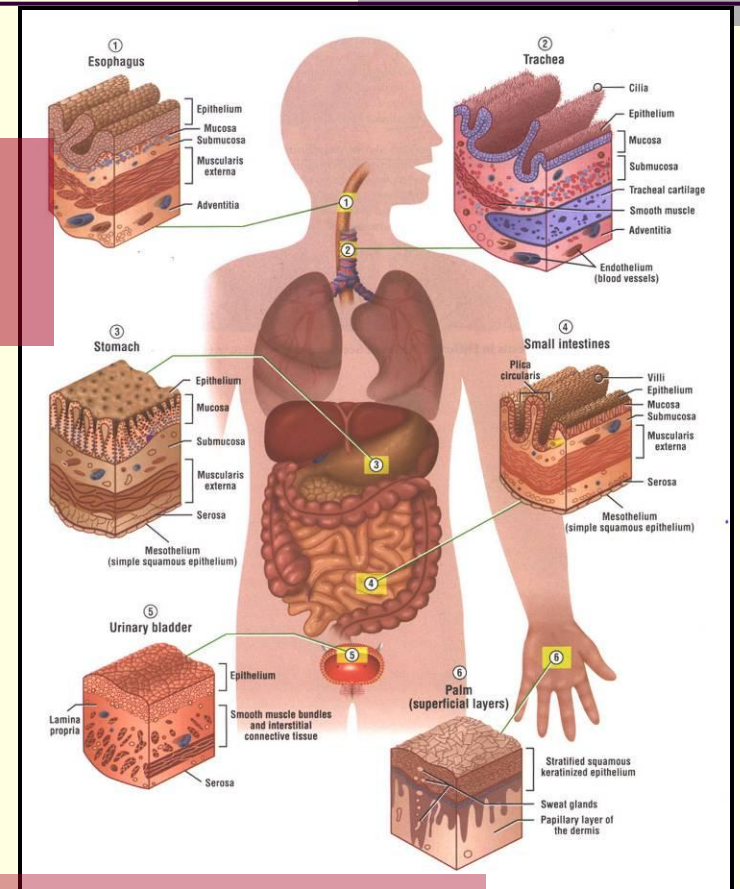
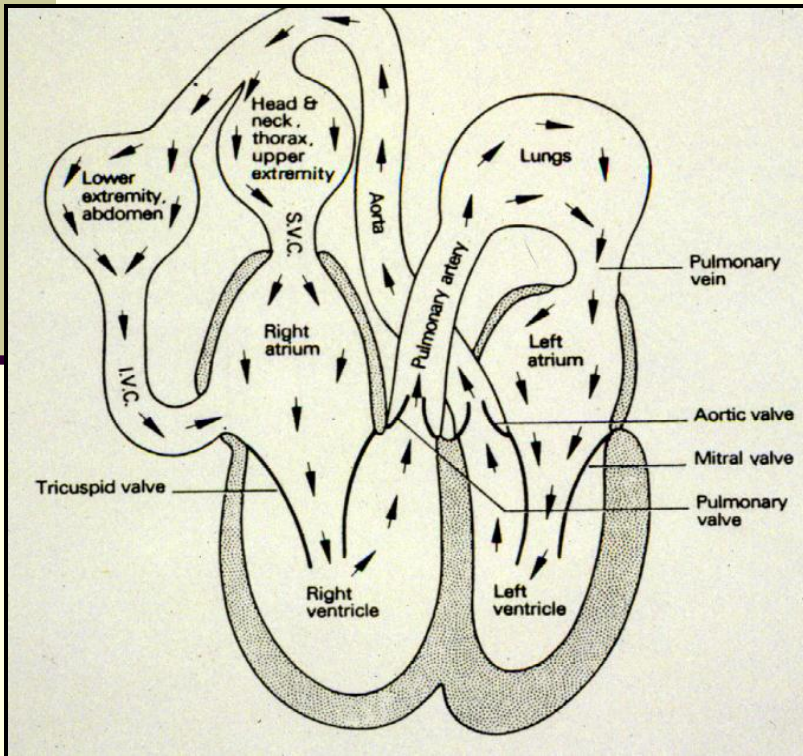
## NERVOUS TISSUE



# Functions of Epithelium

Covers organs

Lines viscera and blood vessels



Secretory cells of glands

# Functions of Connective Tissue

---

- Provides mechanical support.
- Provides place for metabolite exchange.
- Provides place for energy storage.
- Provides place for inflammation.
- Provides place for fibrosis – healing.

# Connective Tissue and Blood Cells

## Red Cells

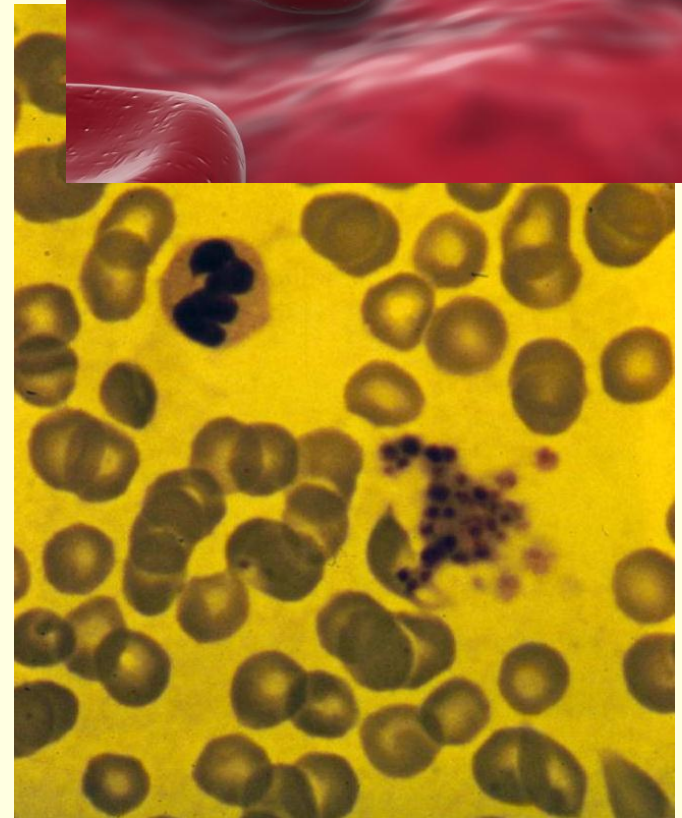
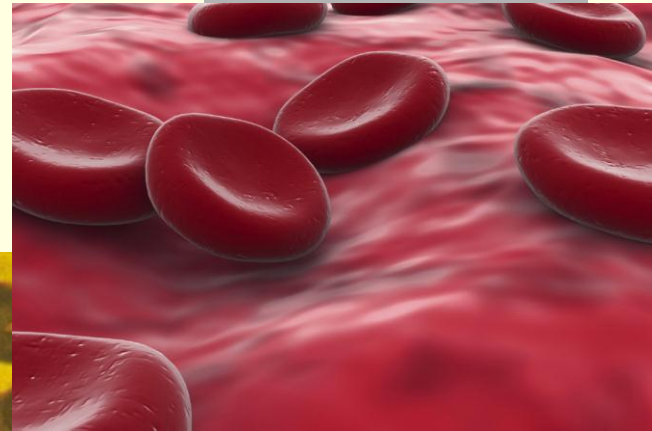
Carry oxygen to and carbon dioxide from the body's tissues.

## White Cells

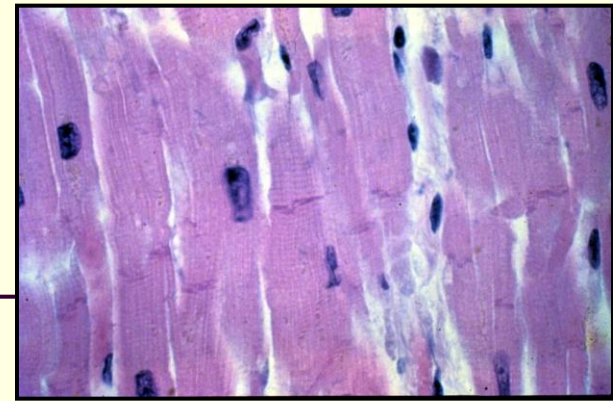
Manufactured in bone marrow.  
Pass through the blood to connective tissue for defense.

## Platelets

Act in blood clotting.



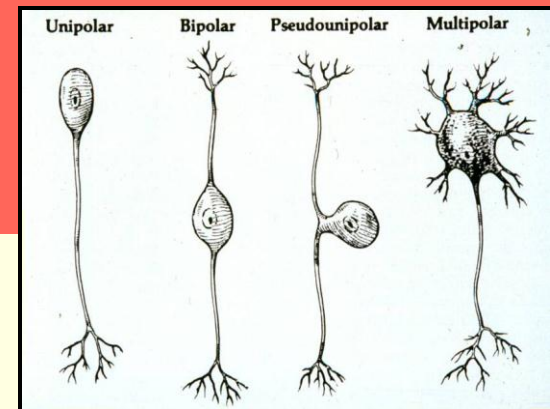
# Muscular Tissue



## Function

Generates contractile force.

# Nervous Tissue



## Function

Provides transmission, reception, and integration of electrical impulses.

# Organs

---

Definition: a distinct collection of two or more tissues that performs a specific function or functions

Examples:

- bones
- brain
- liver
- kidney
- heart



# Organ Systems

---

Definition: a group of interconnected organs that work together with a common purpose or purposes





# Organ Systems

---

- Digestive
- Respiratory
- Urinary
- Reproductive
- Musculoskeletal
- Endocrine
- Nervous
- Integumentary
- Cardiovascular (circulatory)
- Lymphatic (immune)

# Integumentary System

- **Epidermis**

Outermost layer of skin

- **Dermis**

Beneath the epidermis

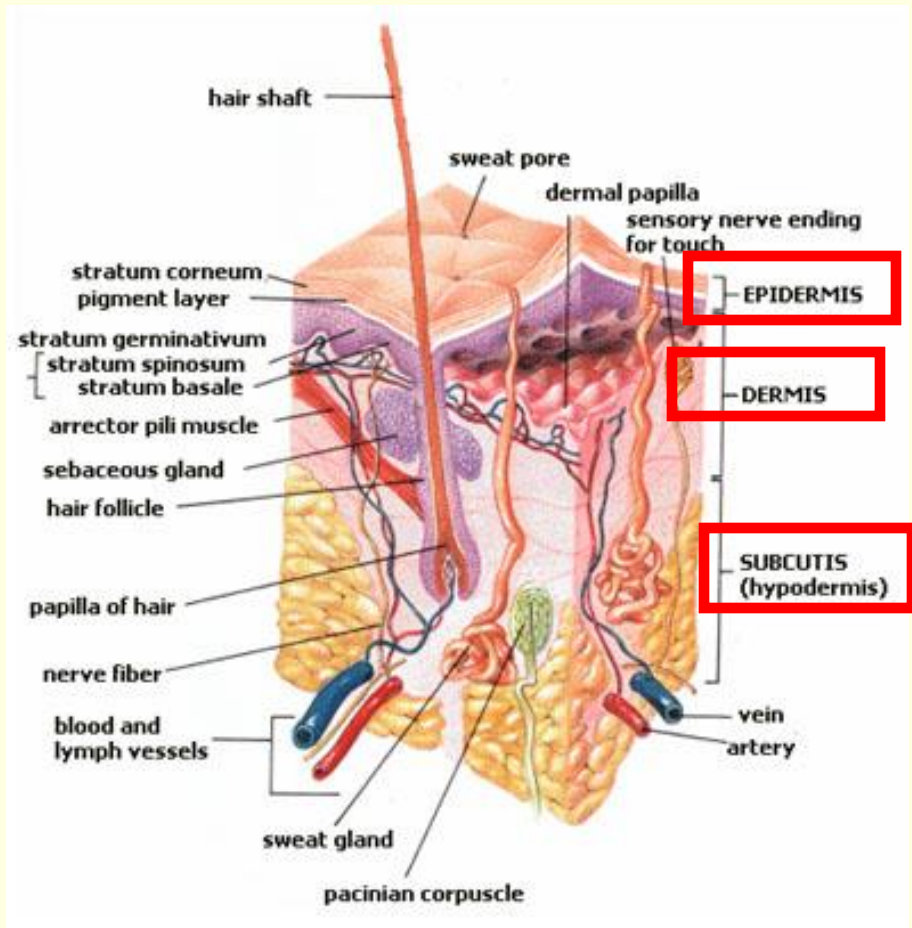
Consists of connective tissue

- **Hypodermis**

Subcutis

Lowest layer of skin

Mainly houses fat



# Functions of Skin

---

- Protects against injury and desiccation.
- Maintains water balance.
- Excretes various substances.
- Provides thermoregulation.
- Receives stimuli.
  - Temperature
  - Pain
  - Pressure
- Provides basis of recognition of well-being.
- Provides place for fat metabolism in the hypodermis.



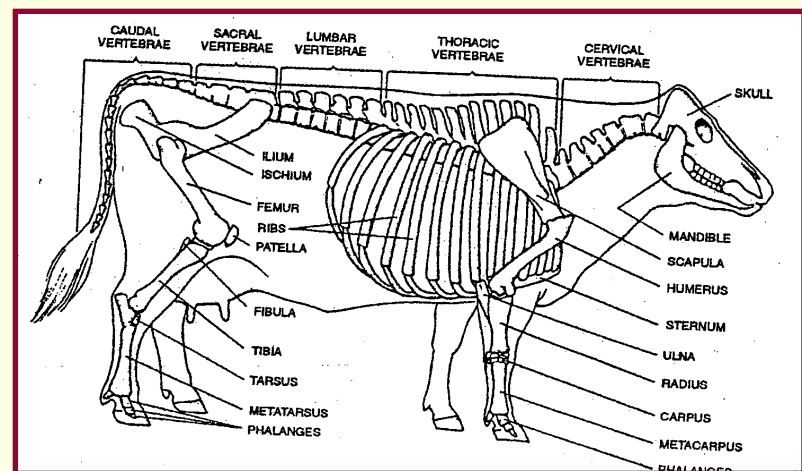
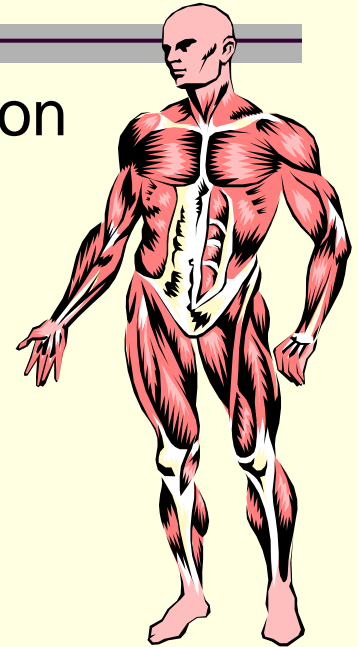
# Parts and Functions of the Musculoskeletal System

**Muscles:** system of levers that aid muscle action

- Smooth Muscle
- Skeletal Muscle
- Cardiac Muscle

**Bones:** provide support and protection

- Long bones
- Short bones
- Flat bones
- Irregular bones



# Parts and Functions of the Musculoskeletal System

- **Joints**

Form the junction between two or more bones.

- **Cartilage**

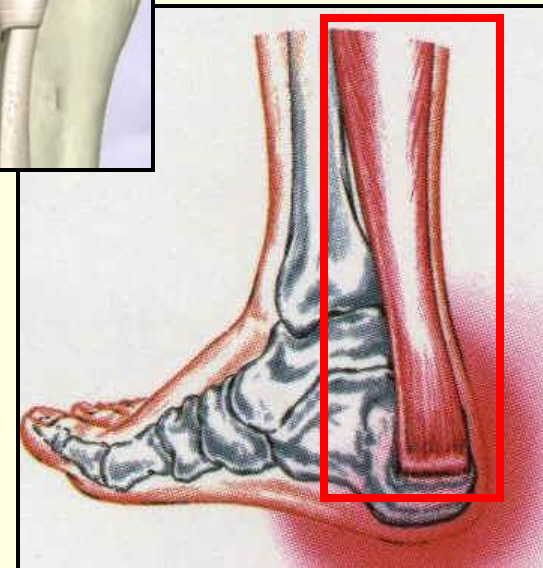
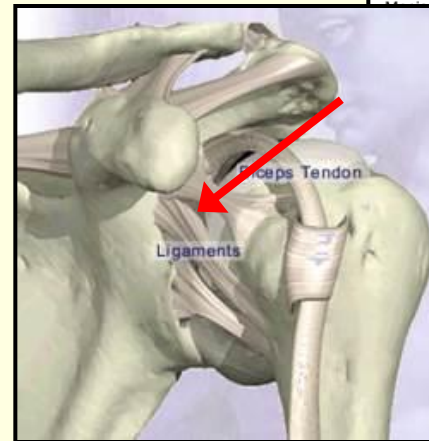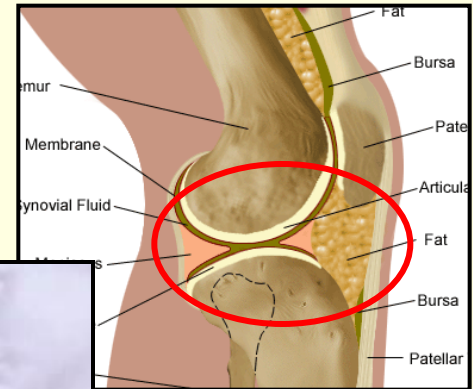
Forms cushion.

- **Ligaments**

Connect bone to bone.

- **Tendons**

Attach muscles to bone.



# Functions of Muscle

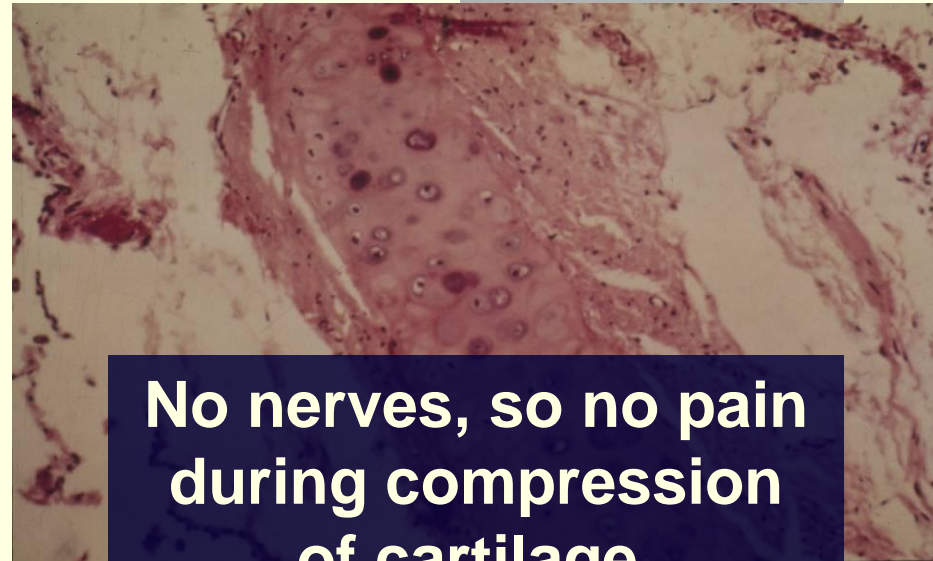
---

- Produces contractibility (movement).
  - Running, walking, jumping
- Produces posture.
- Stabilizes joints.
- Produces heat.

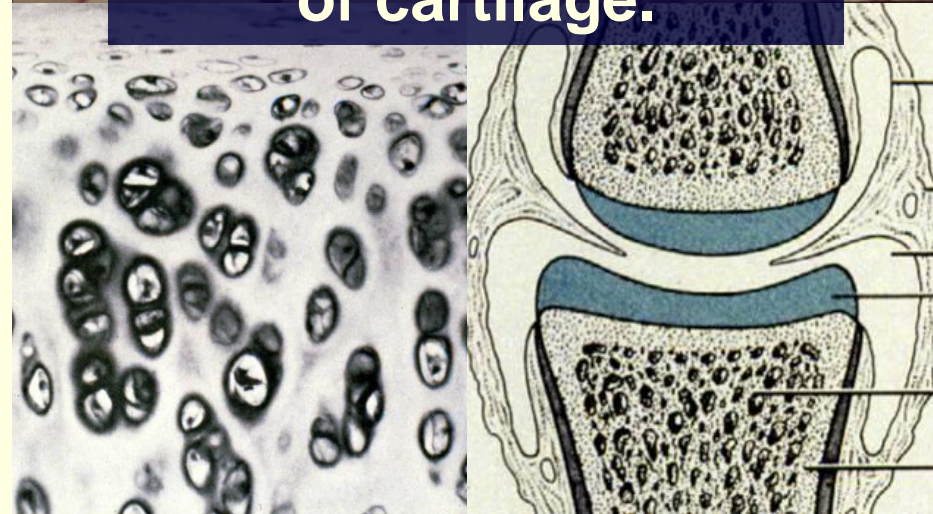


# Functions of Cartilage

- Provides flexible support.  
(ears, nose, and respiratory)
- Slides across each other.  
(joints)
- Provides a cushion.  
(joints)

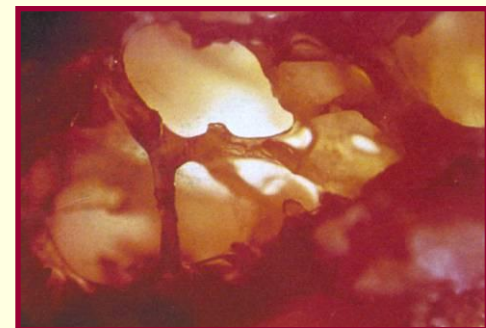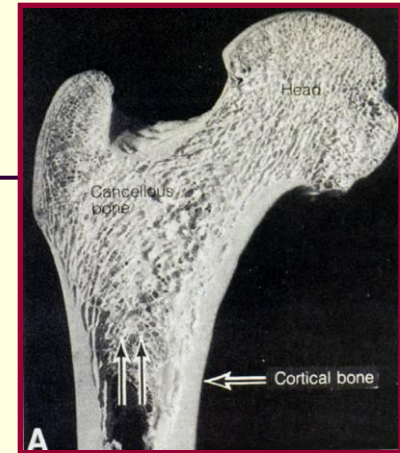


**No nerves, so no pain  
during compression  
of cartilage.**

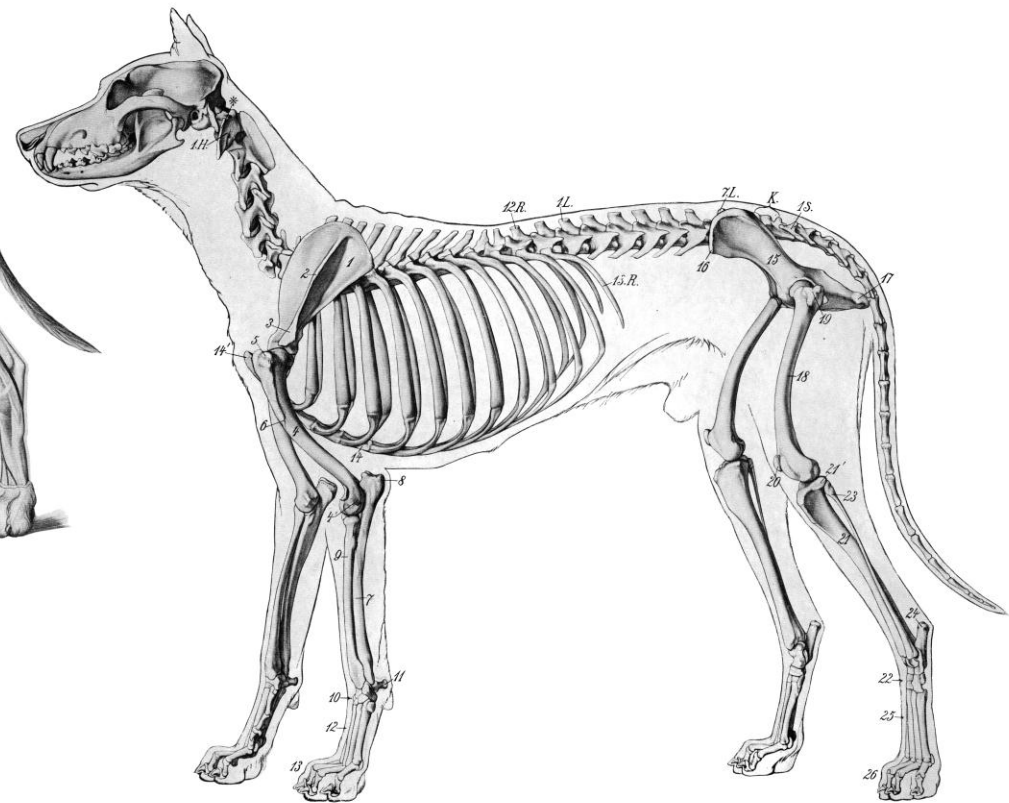
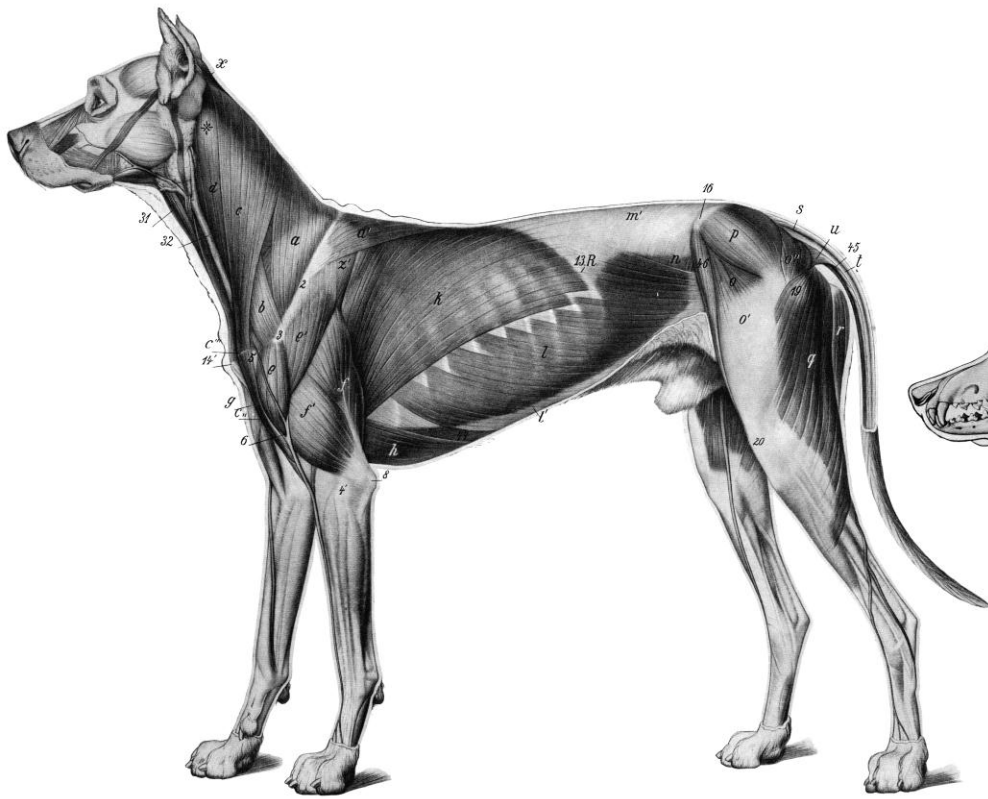


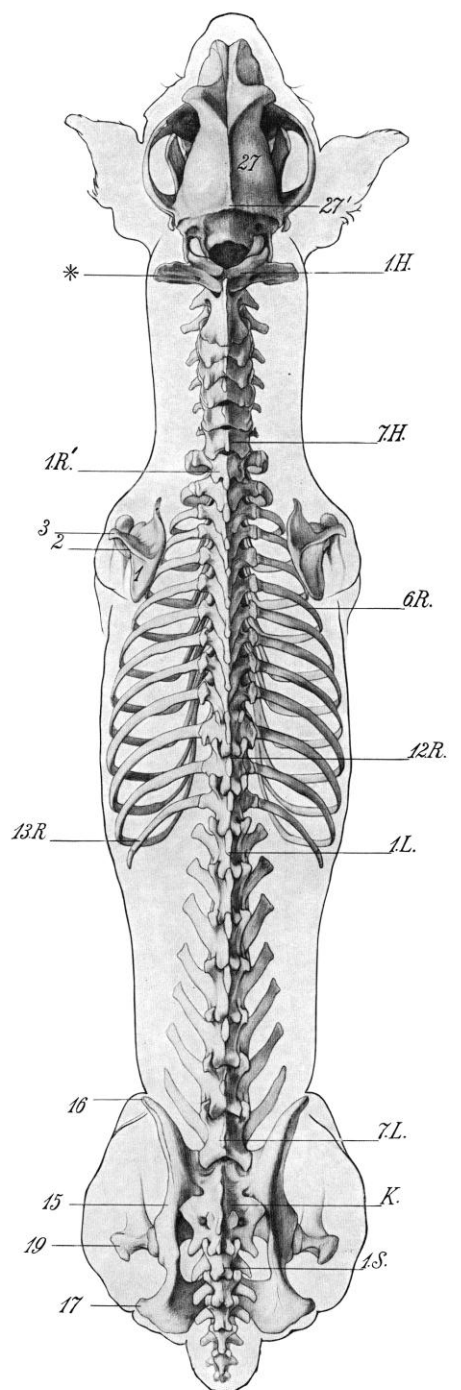
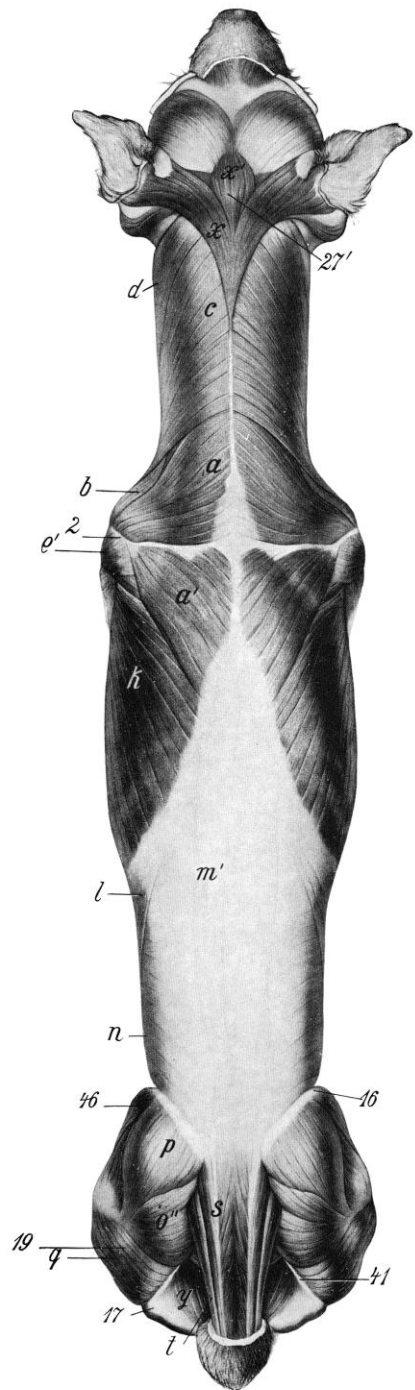
# Functions of Bone

- Provides skeletal support.
- Provides protective enclosure.
  - Skull to protect brain.
  - Long bone to protect blood producing cells.
- Regulates calcium.
- Provides place for hemopoiesis.
  - Blood cell formation in the body









# Skeleton of the “hand”

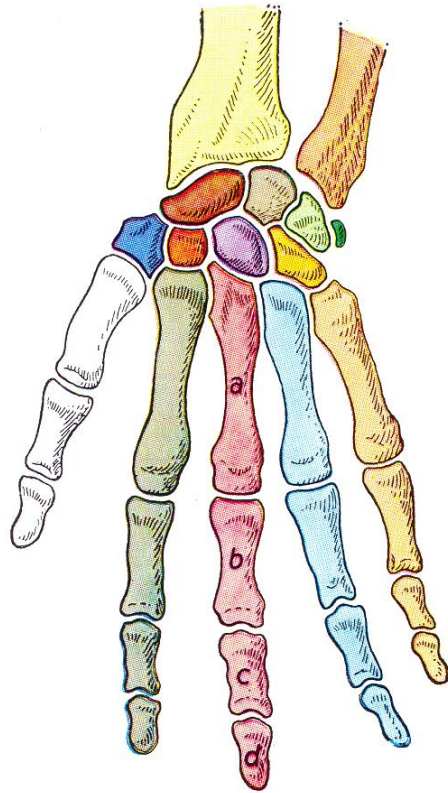


Fig. 116 (man)

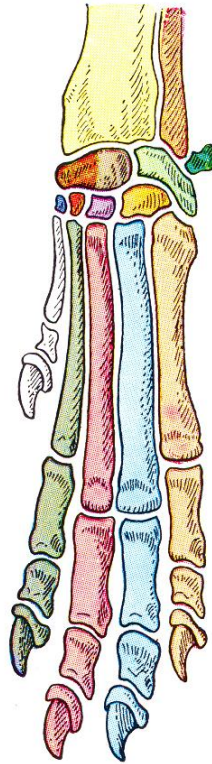


Fig. 117 (dog)

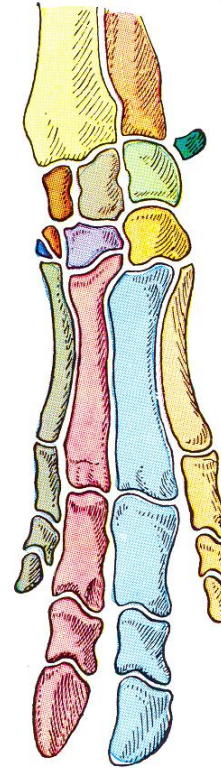


Fig. 118 (pig)

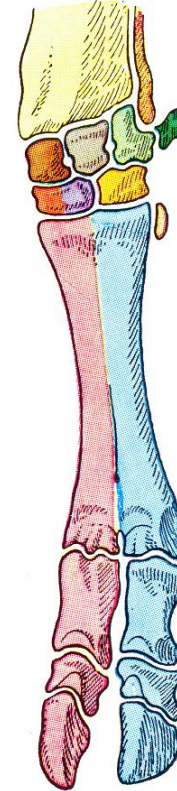


Fig. 119 (ox)

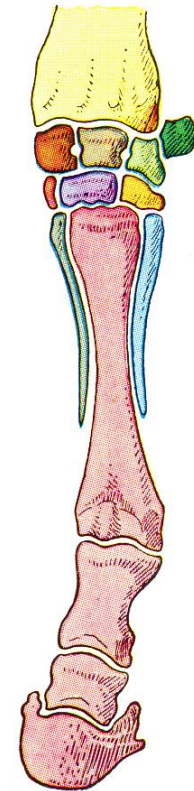
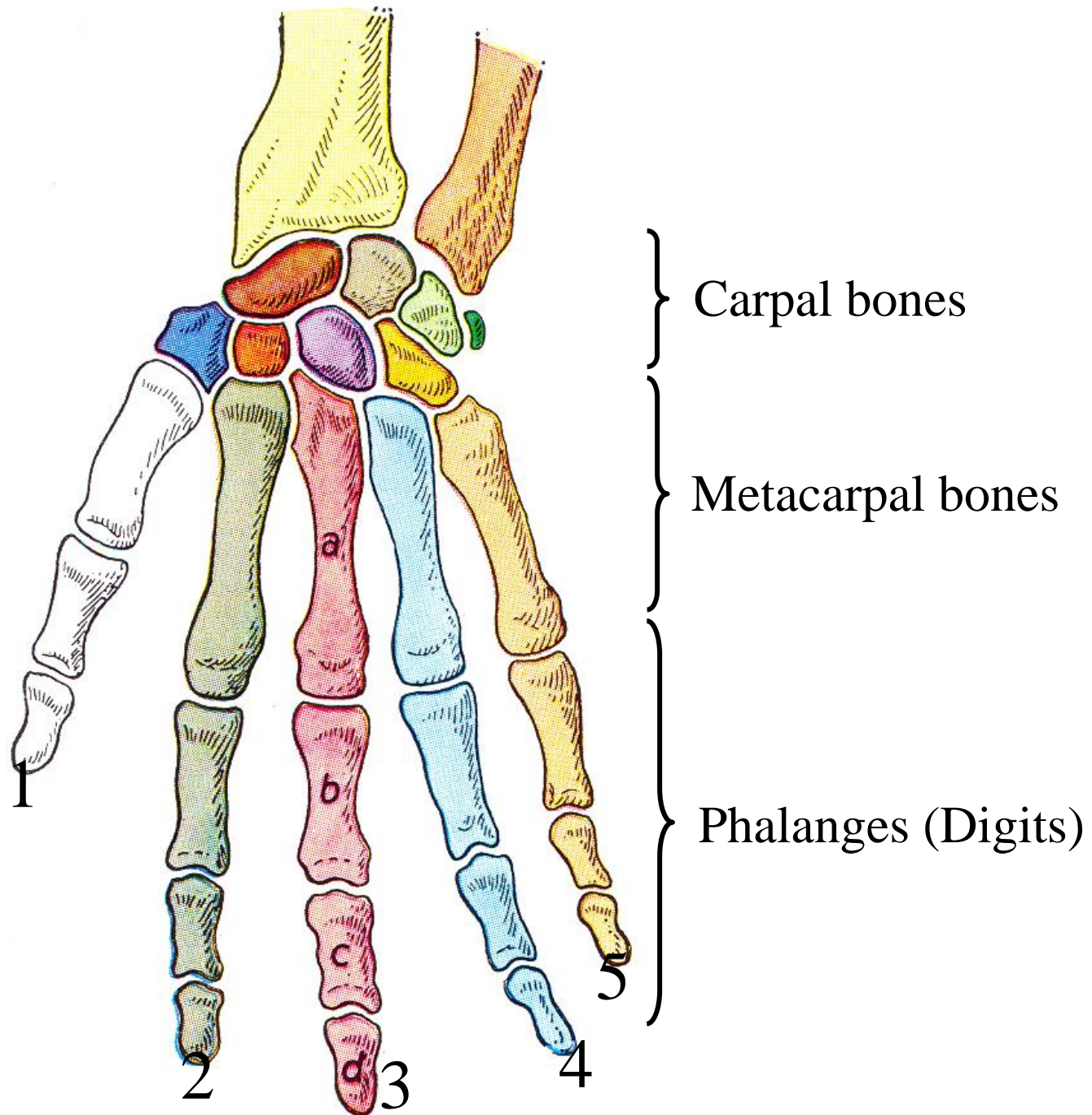


Fig. 120 (horse)



Carpal bones

Metacarpal bones

Phalanges (Digits)

1

2

3

4

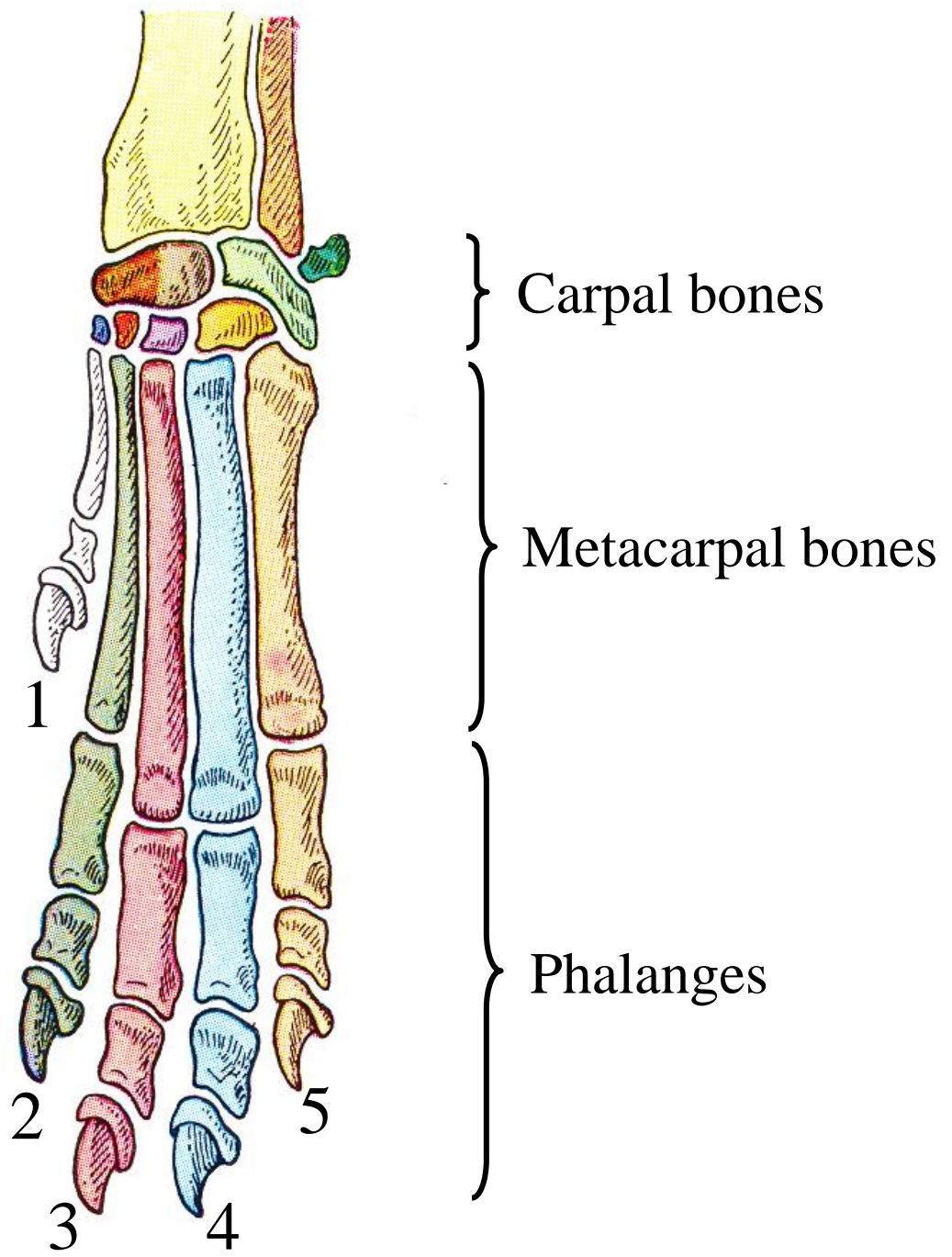
5

a

b

c

d



Carpal bones

Metacarpal bones

Phalanges

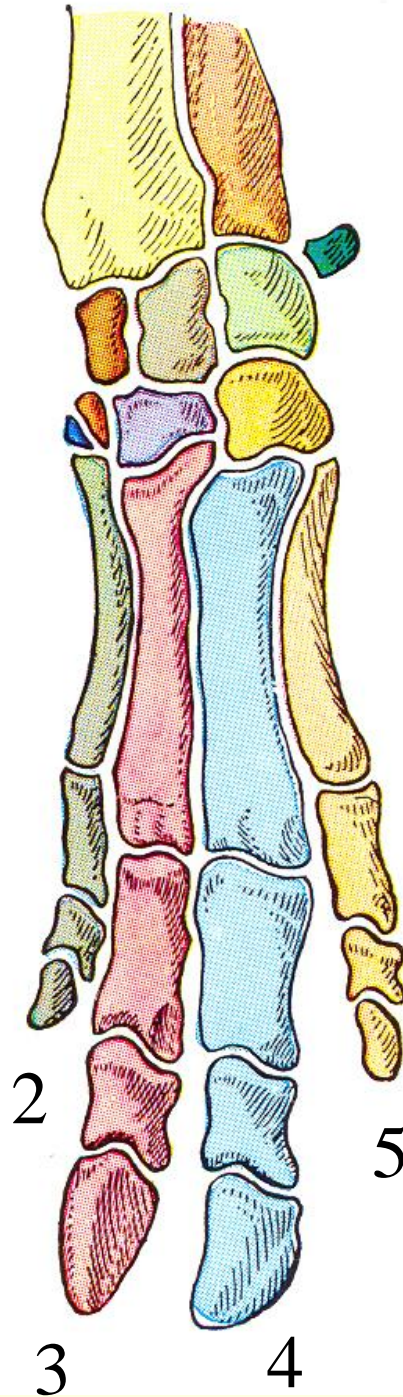
1

2

3

4

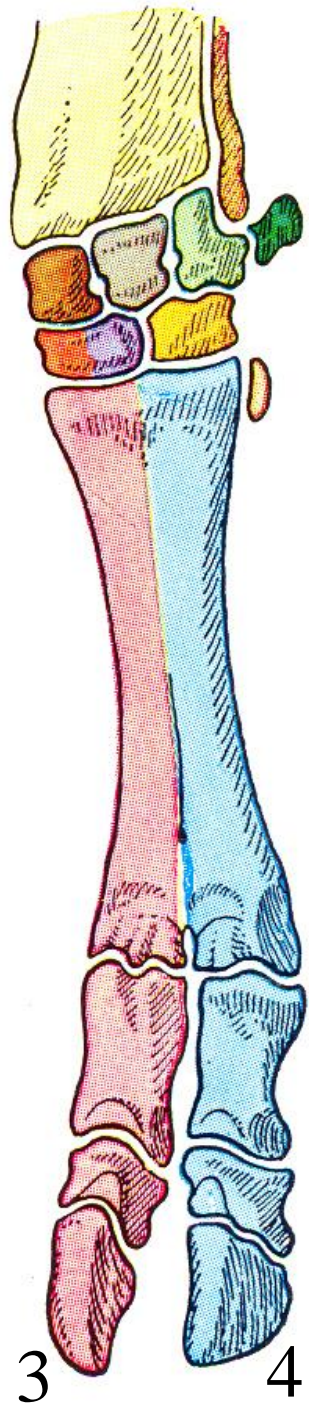
5



} Carpal bones

} Metacarpal bones

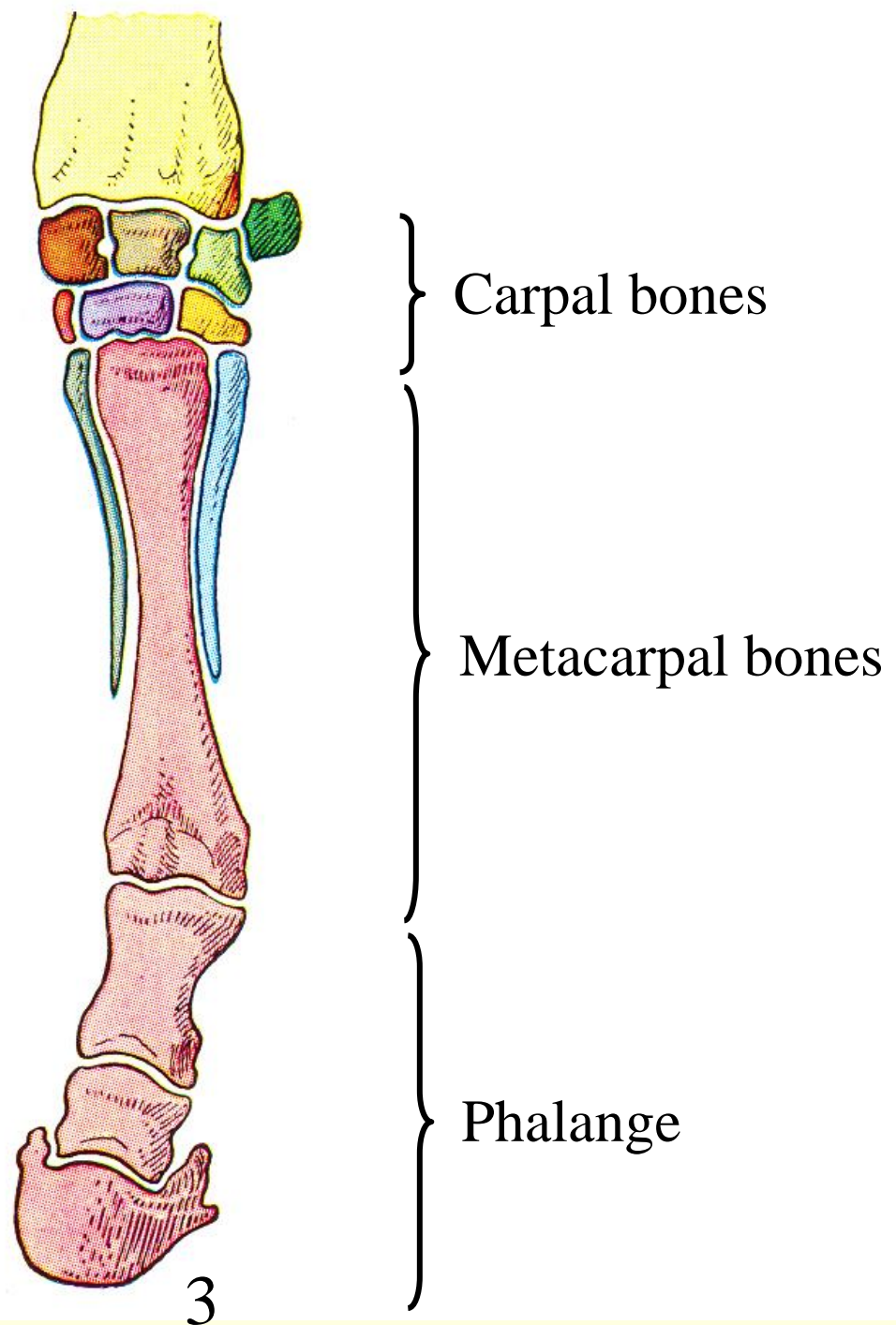
} Phalanges



} Carpal bones

} Metacarpal bones

} Phalanges

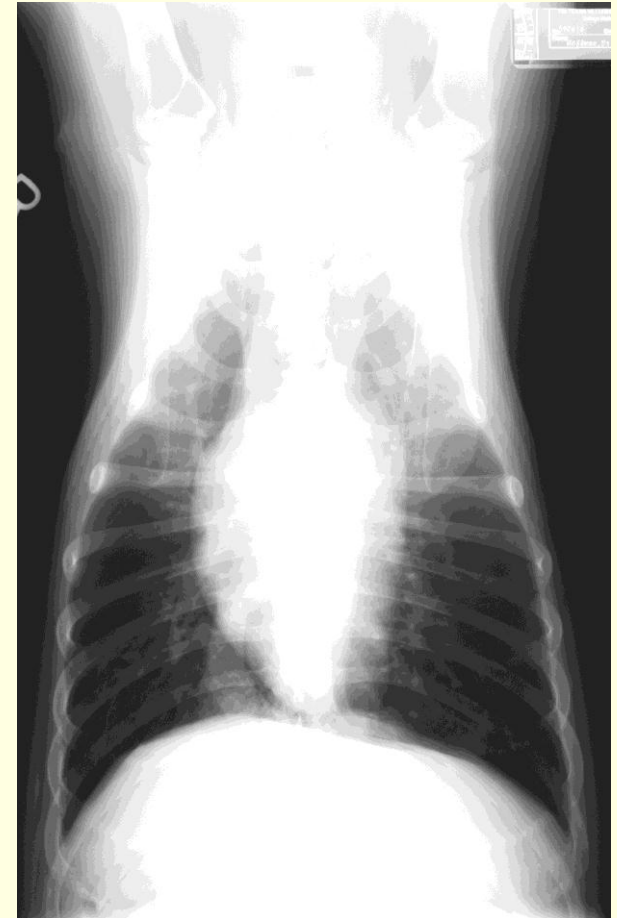
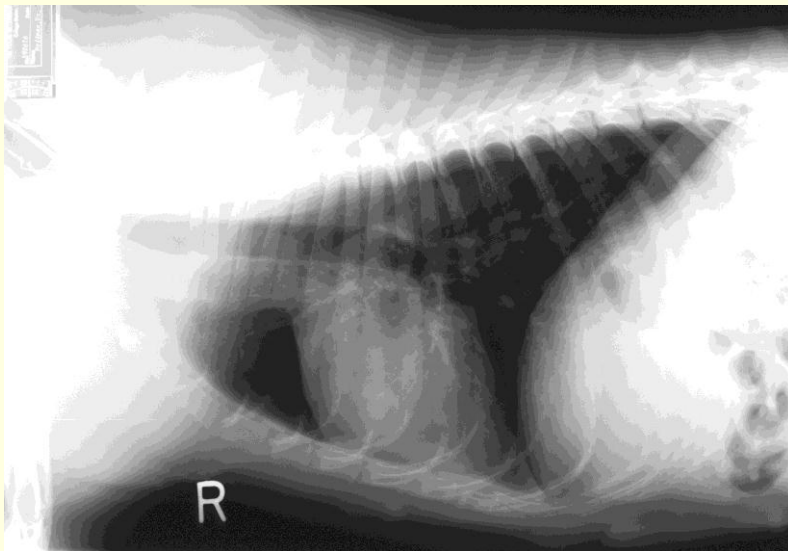




# Cardiovascular System

---

- Heart
- Arteries
- Veins
- Capillaries



# Parts and Functions of the Cardiovascular System

---

## **Heart**

Produces blood pressure during systole.

## **Elastic arteries**

Conduct blood and maintain pressure during diastole.

## **Muscular arteries**

Distribute blood and maintain pressure.

## **Arterioles**

Provide peripheral resistance.  
Distribute blood.

## **Capillaries**

Exchange nutrients and waste.

## **Venules**

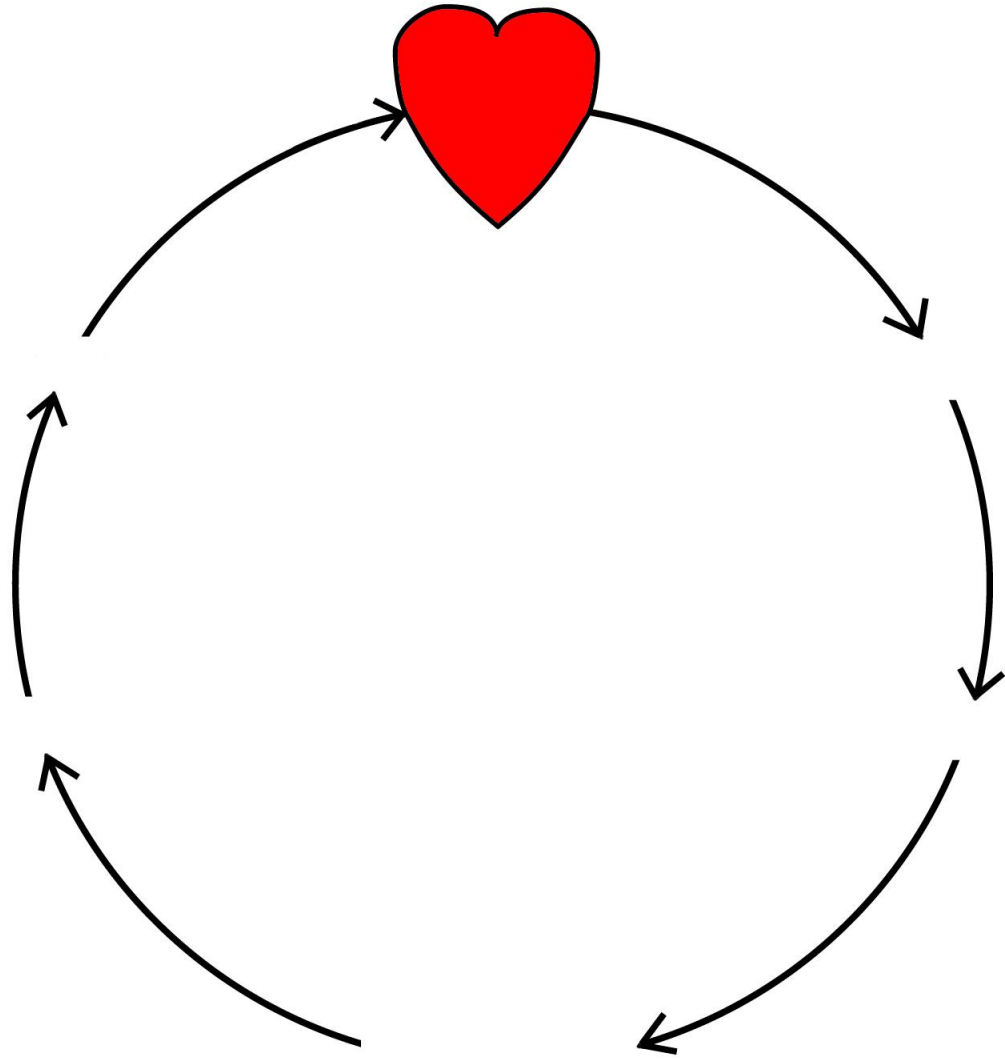
Collect blood and edema from capillaries.

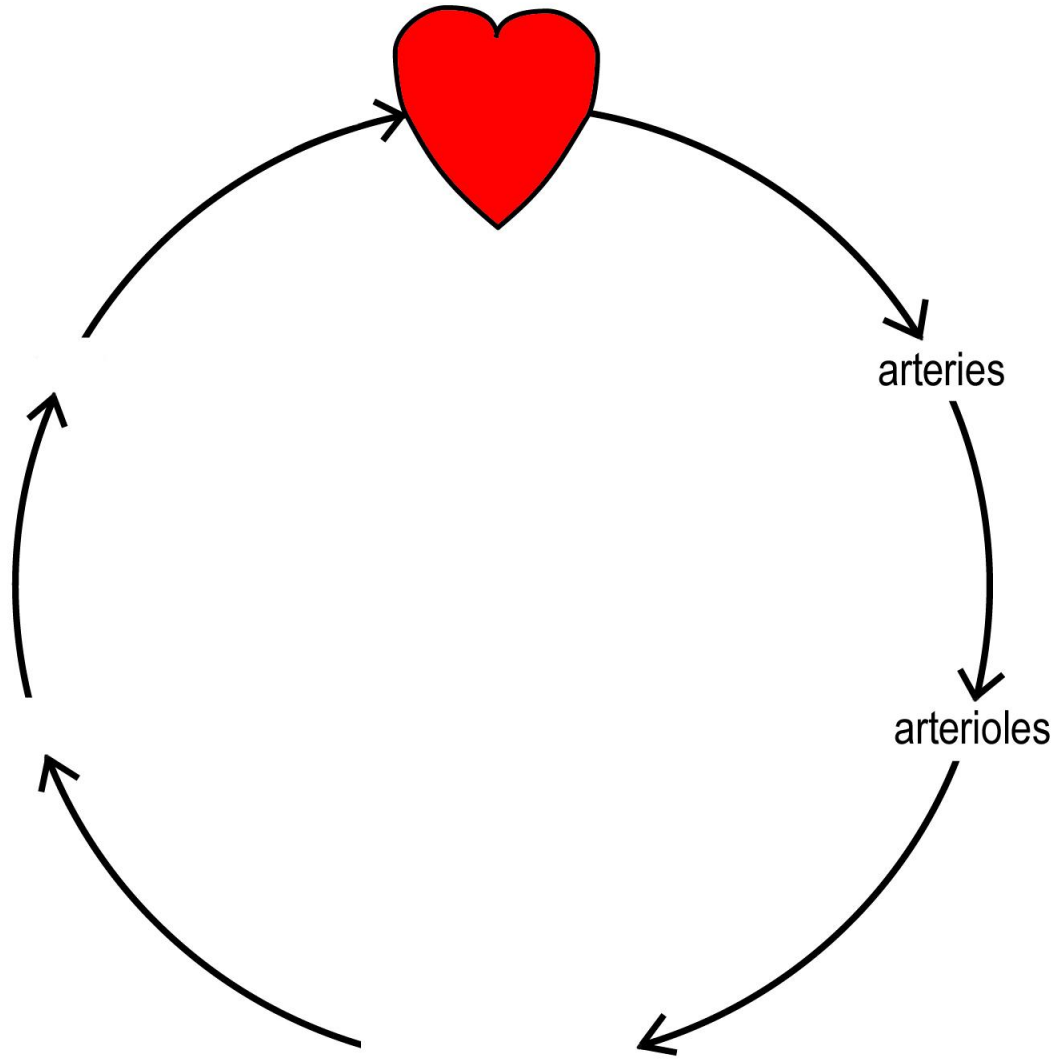
## **Veins**

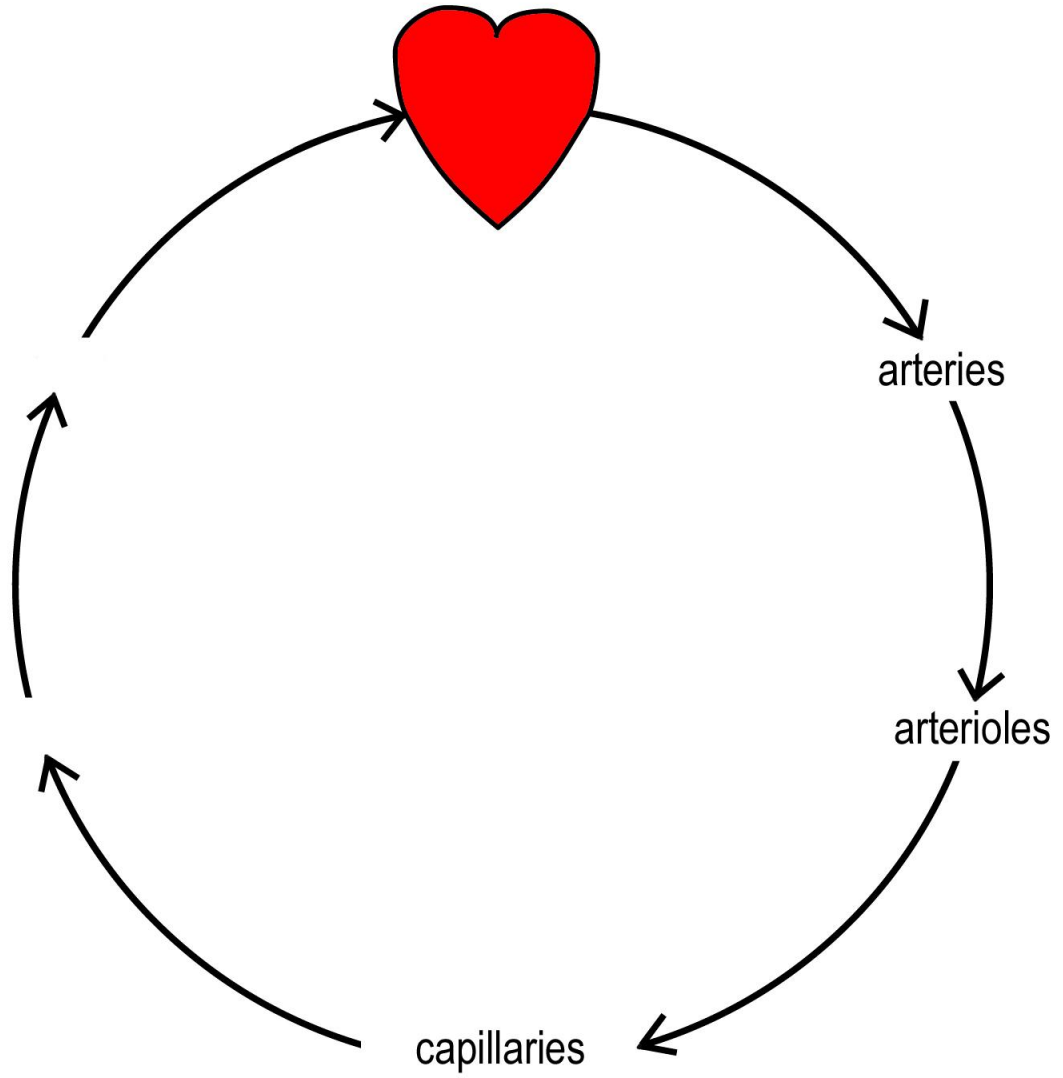
Transmit blood to large veins. (reservoir)

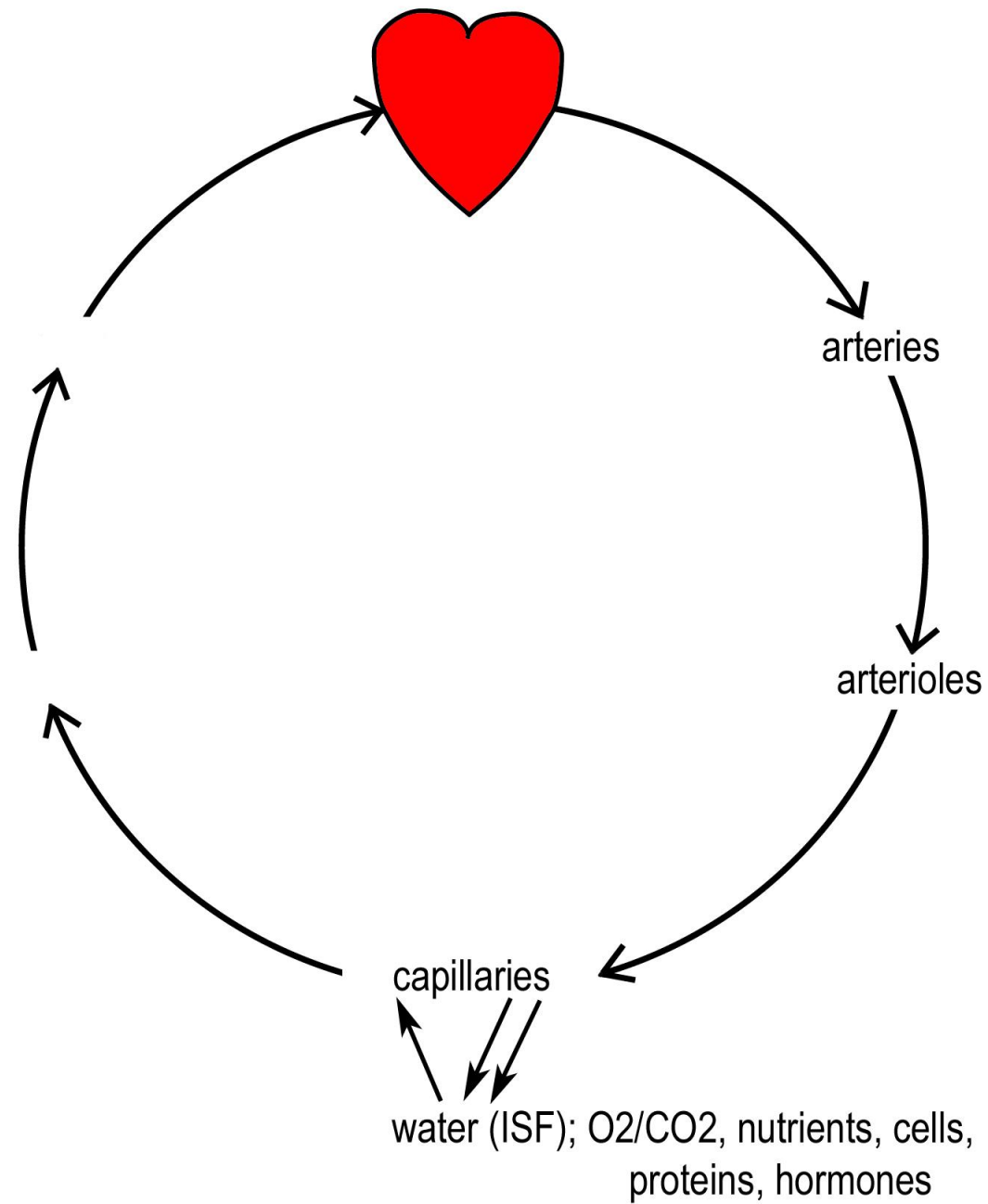
## **Large veins**

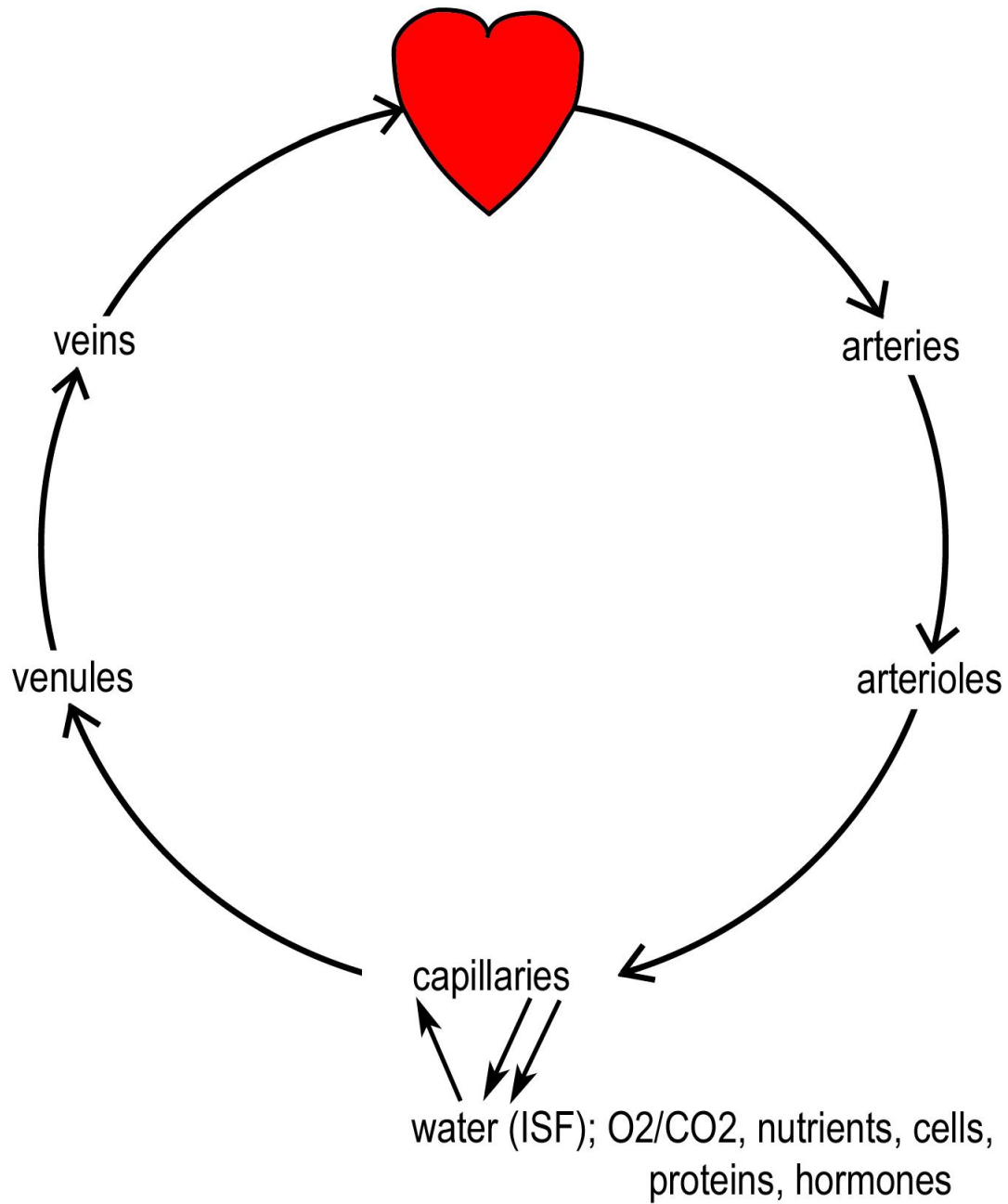
Receive lymph and return blood to heart. (reservoir)







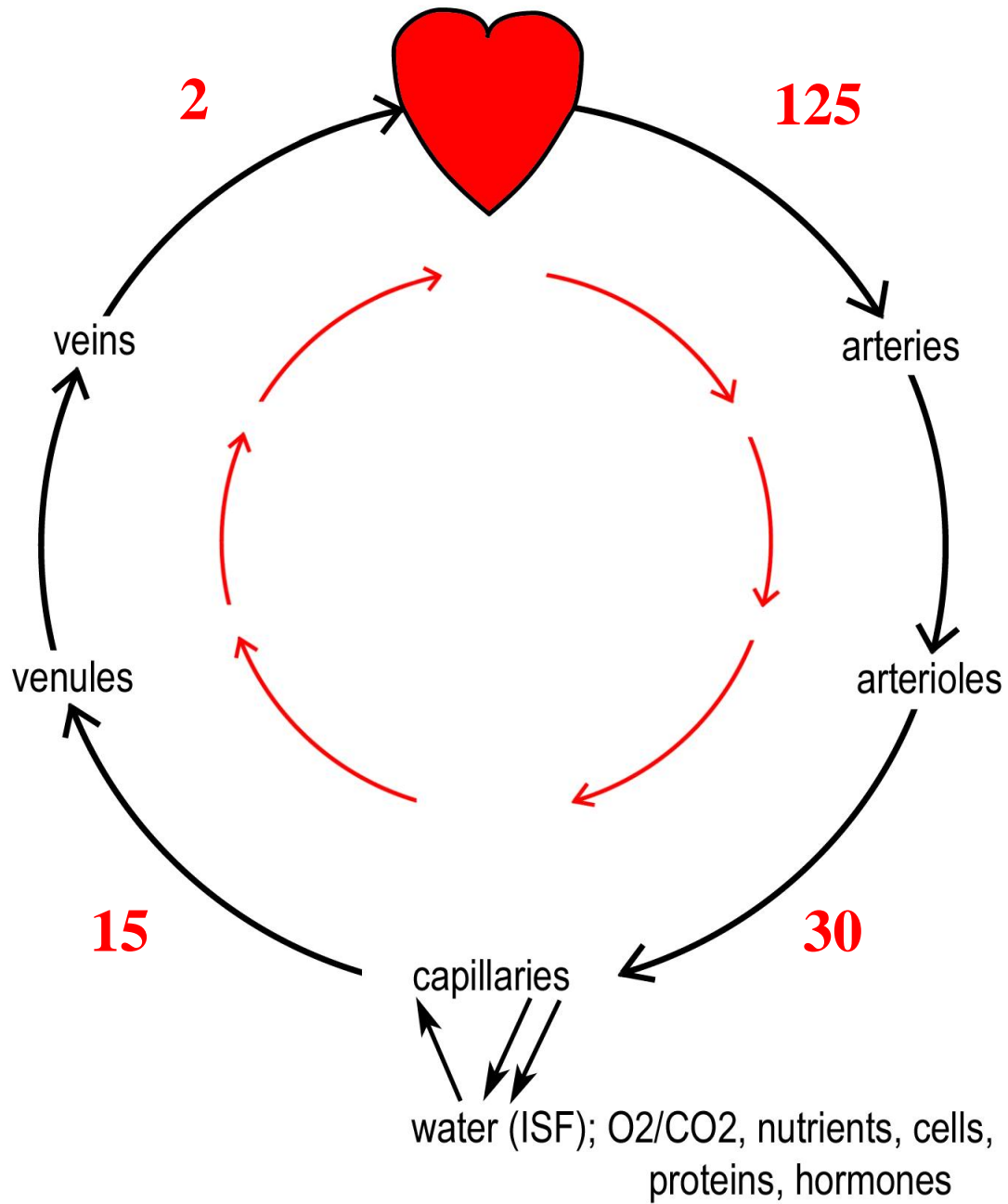


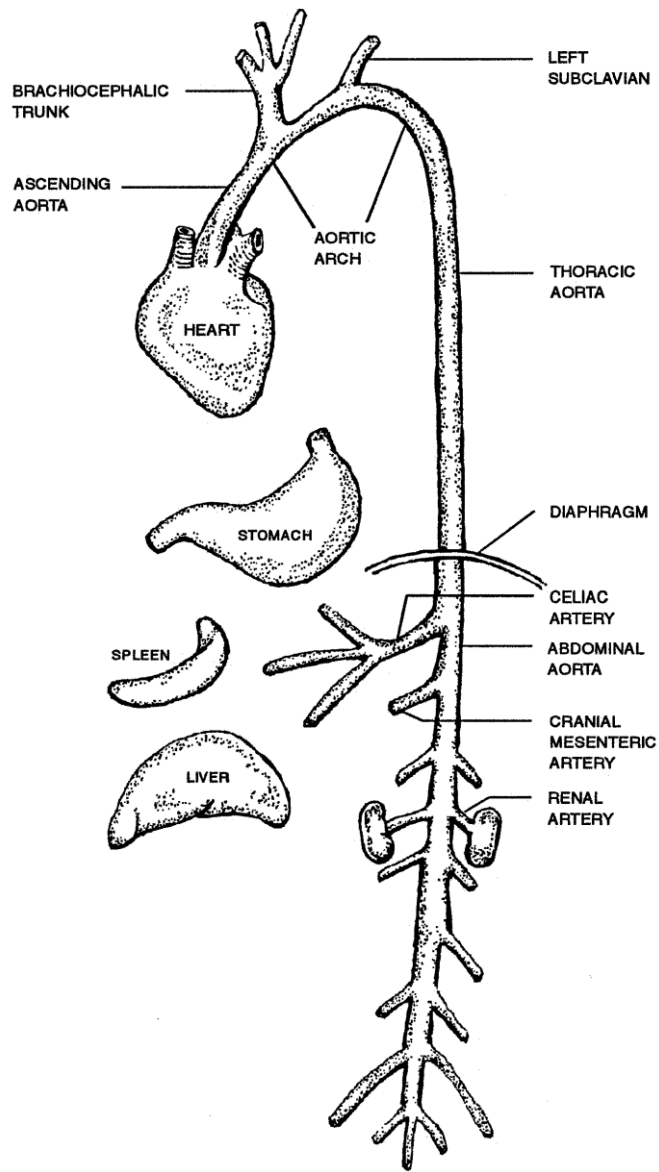




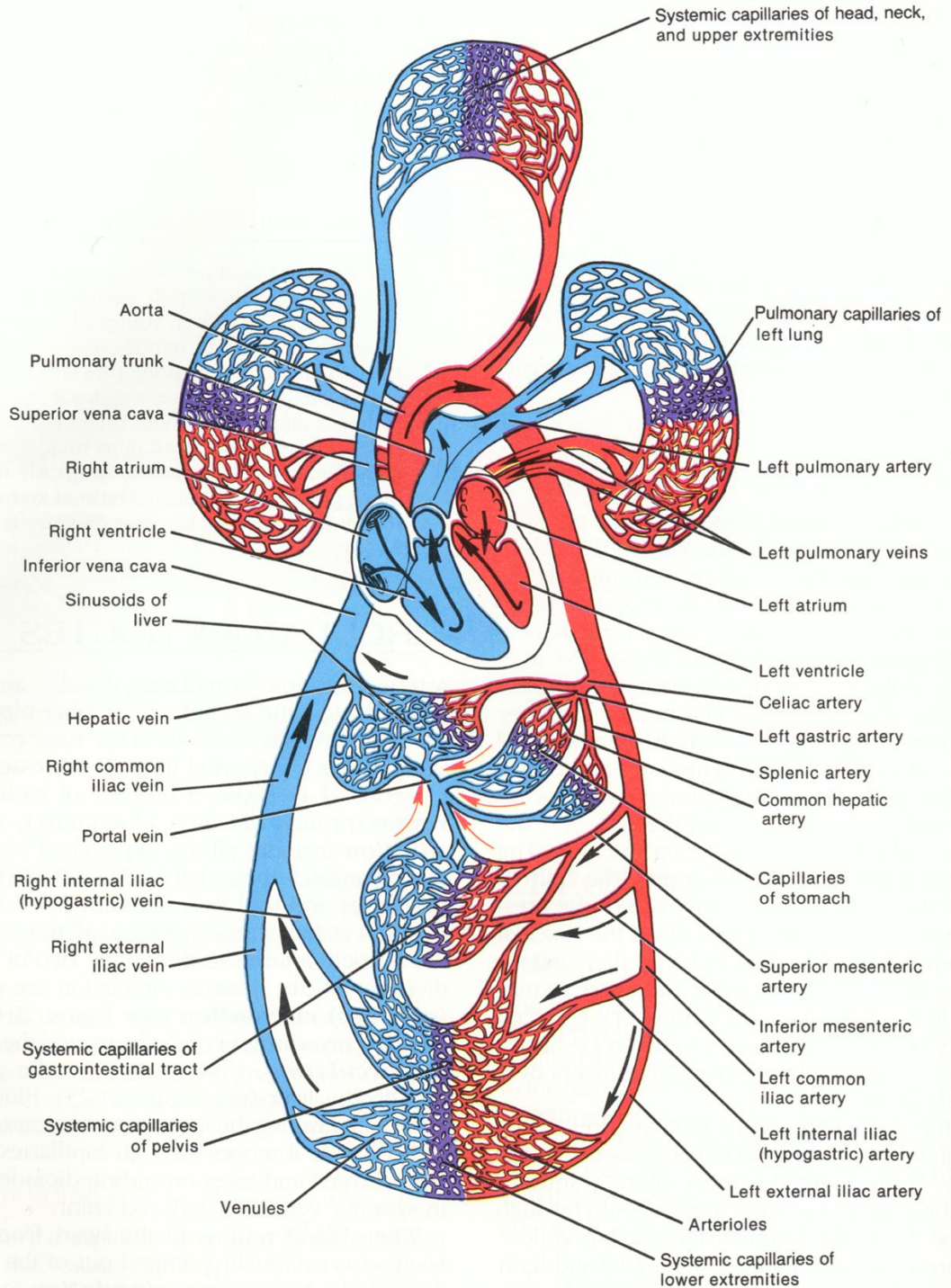
# Closed Loop with Pressure Drop



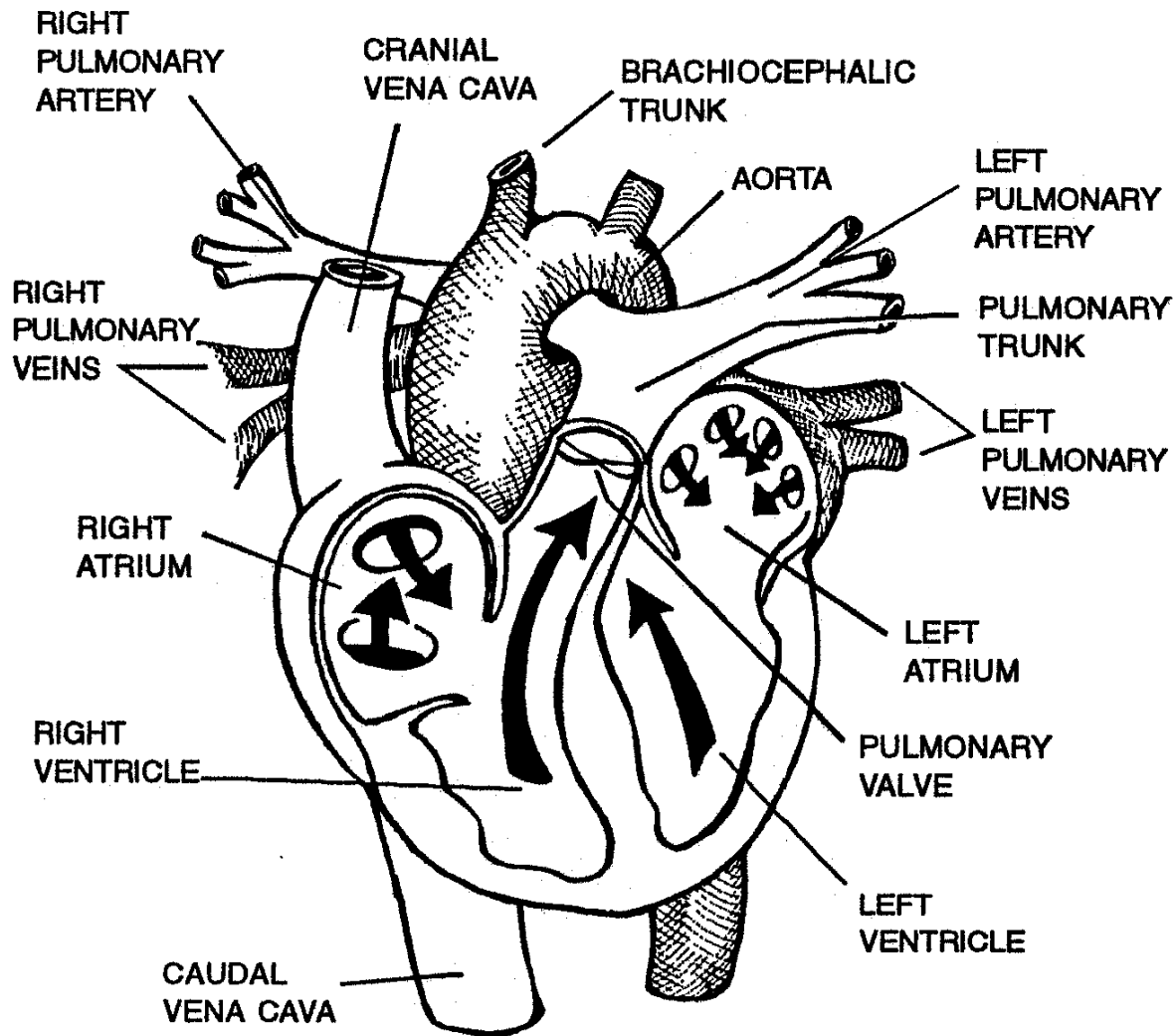




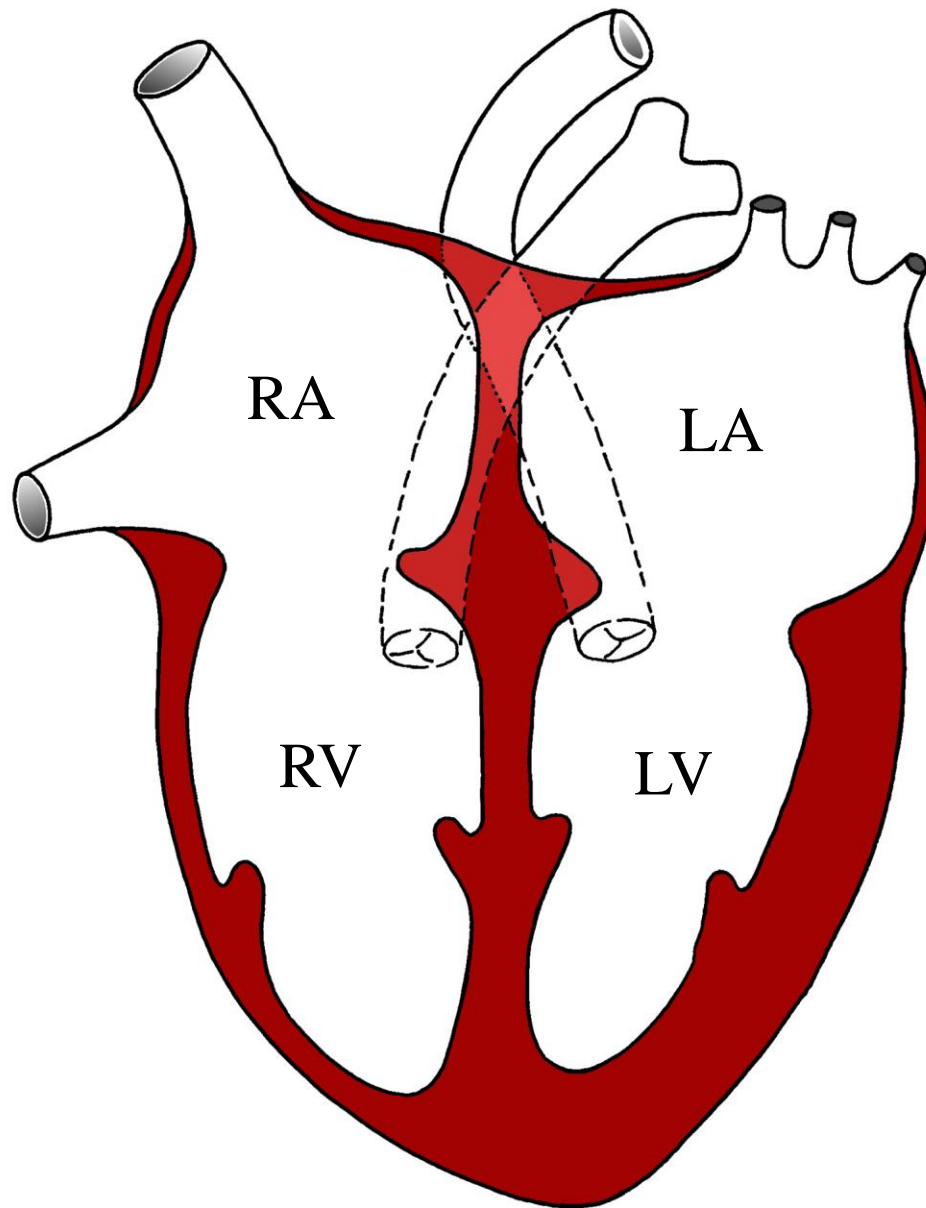
Major Branches of the Aorta



# Heart



base



RA

LA

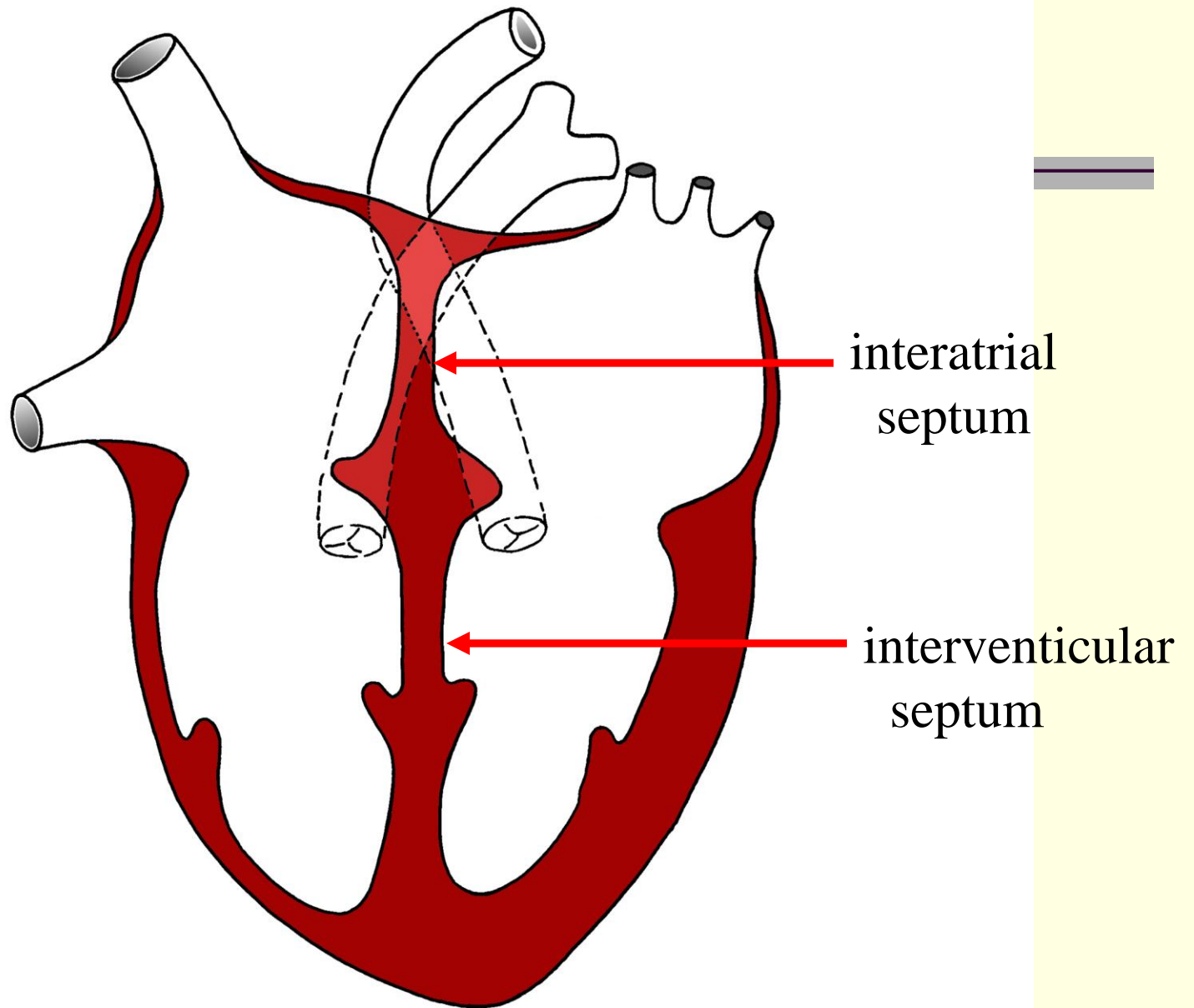
atria

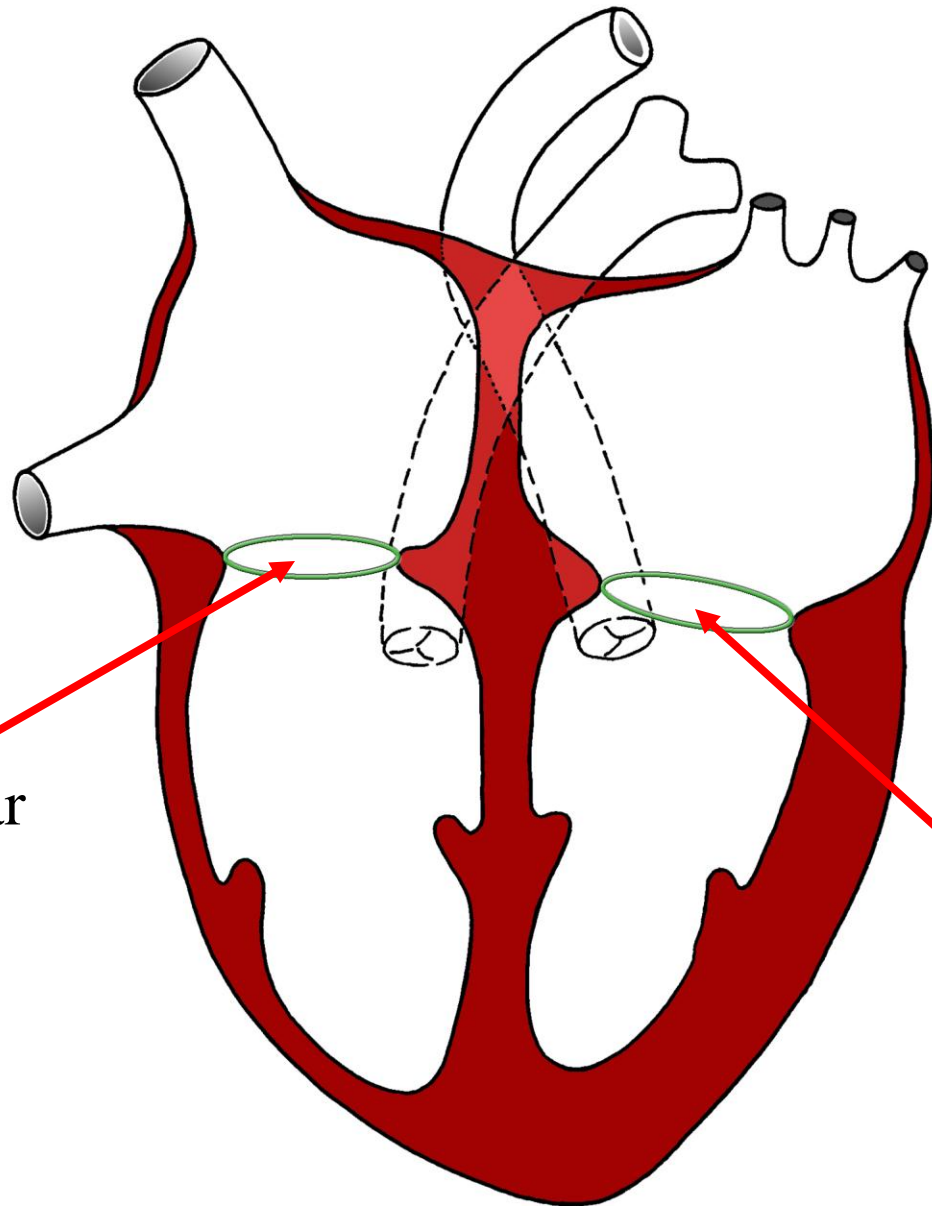
RV

LV

ventricles

apex

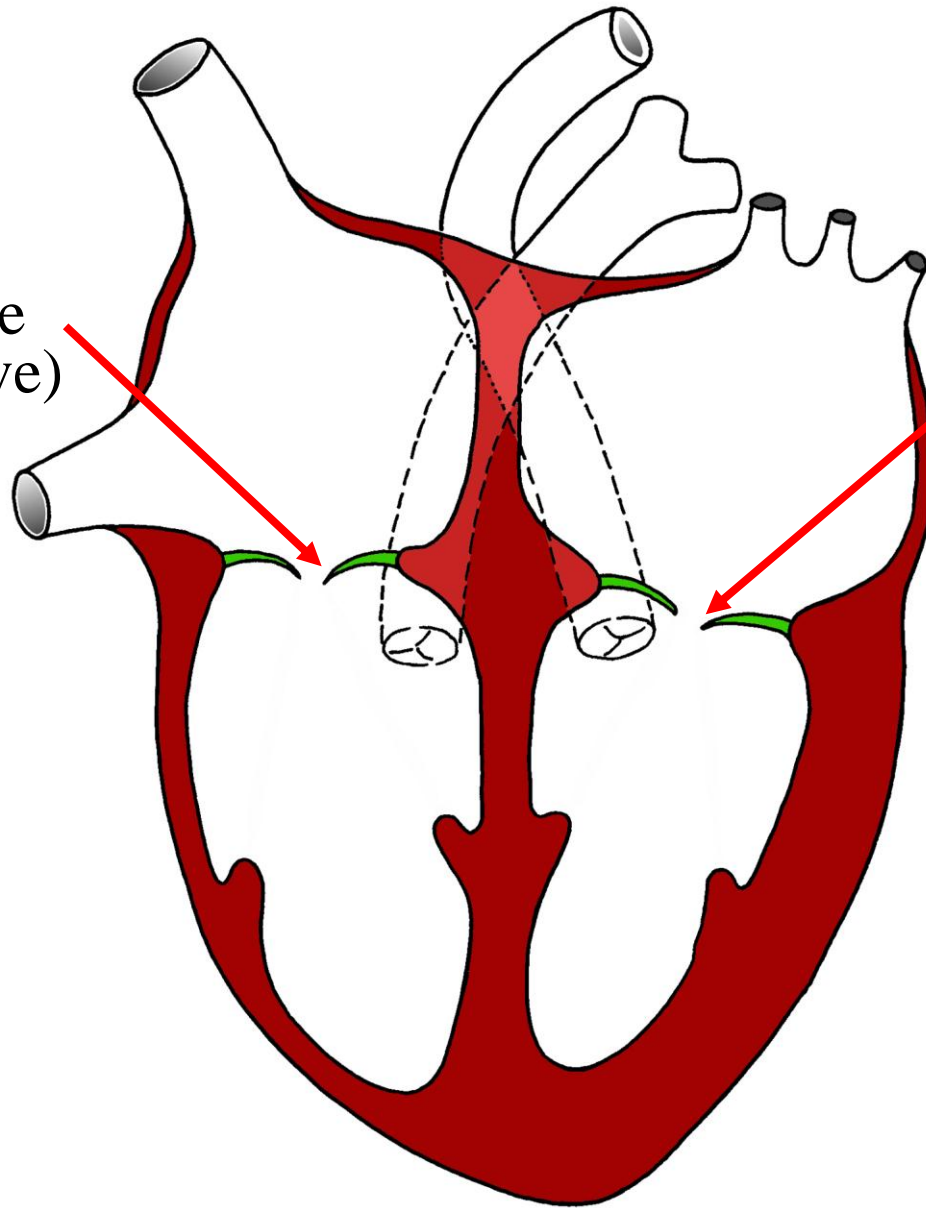




R. atrioventricular  
orifice

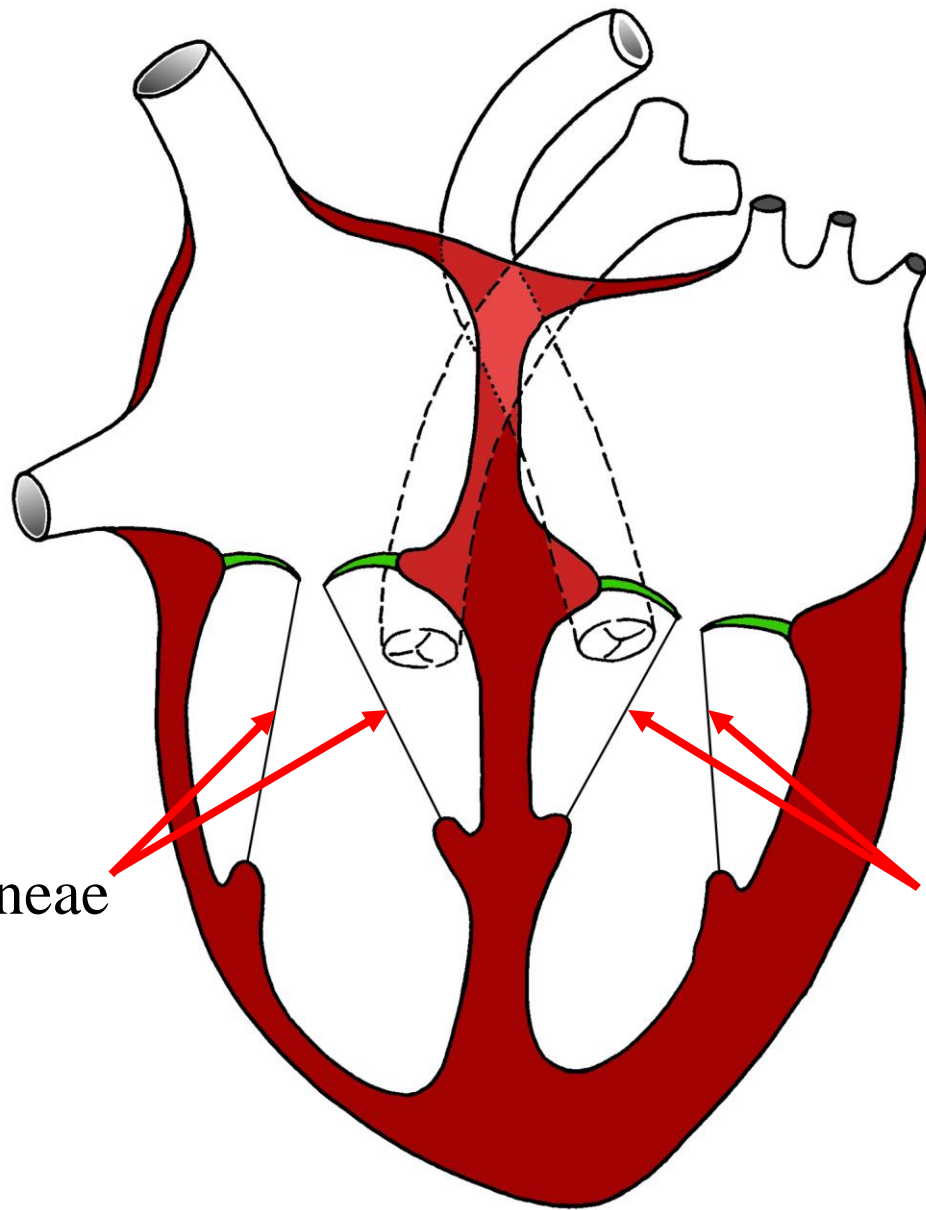
L. atrioventricular  
orifice

R. AV valve  
(tricuspid valve)



L. AV valve  
(mitral valve)



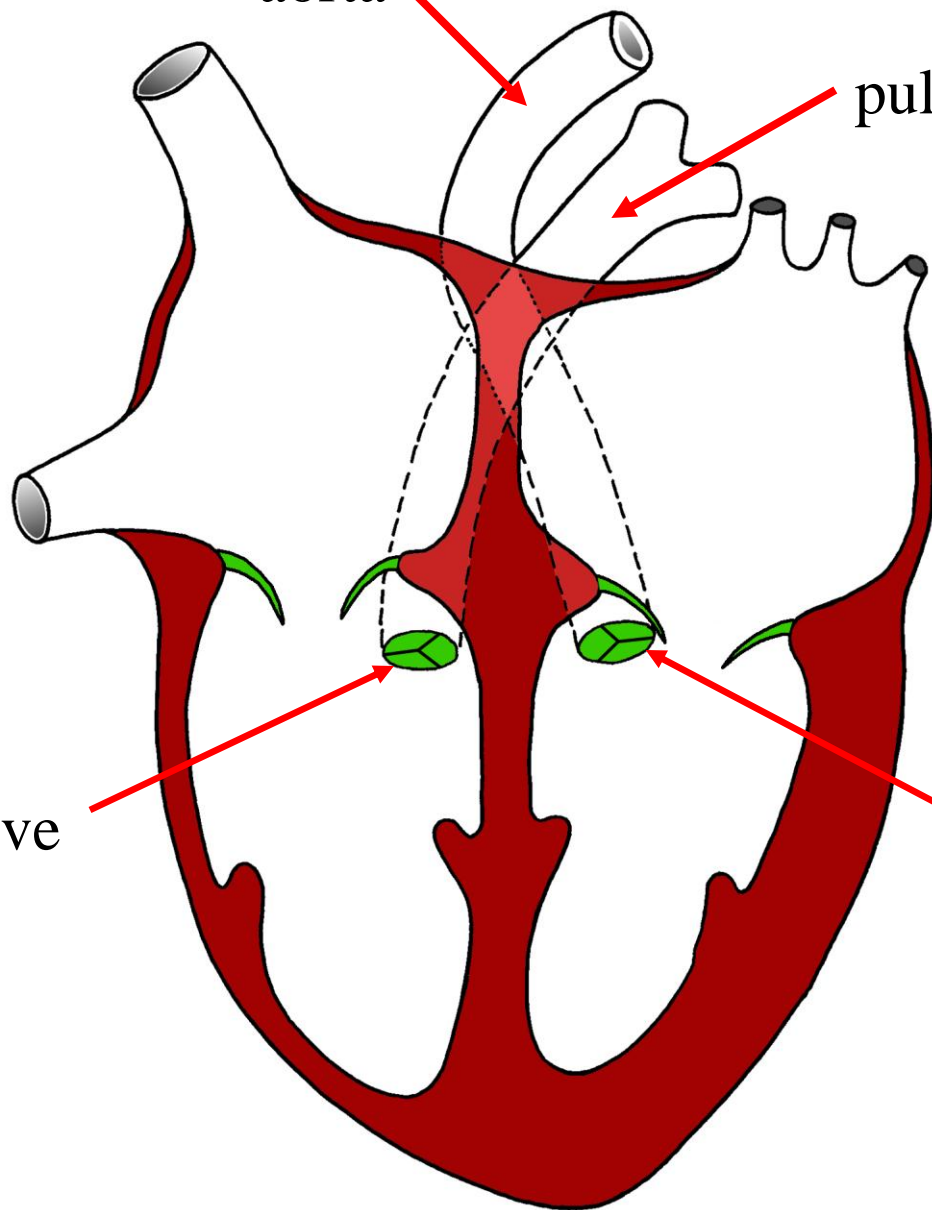


chordae tendineae

chordae tendineae

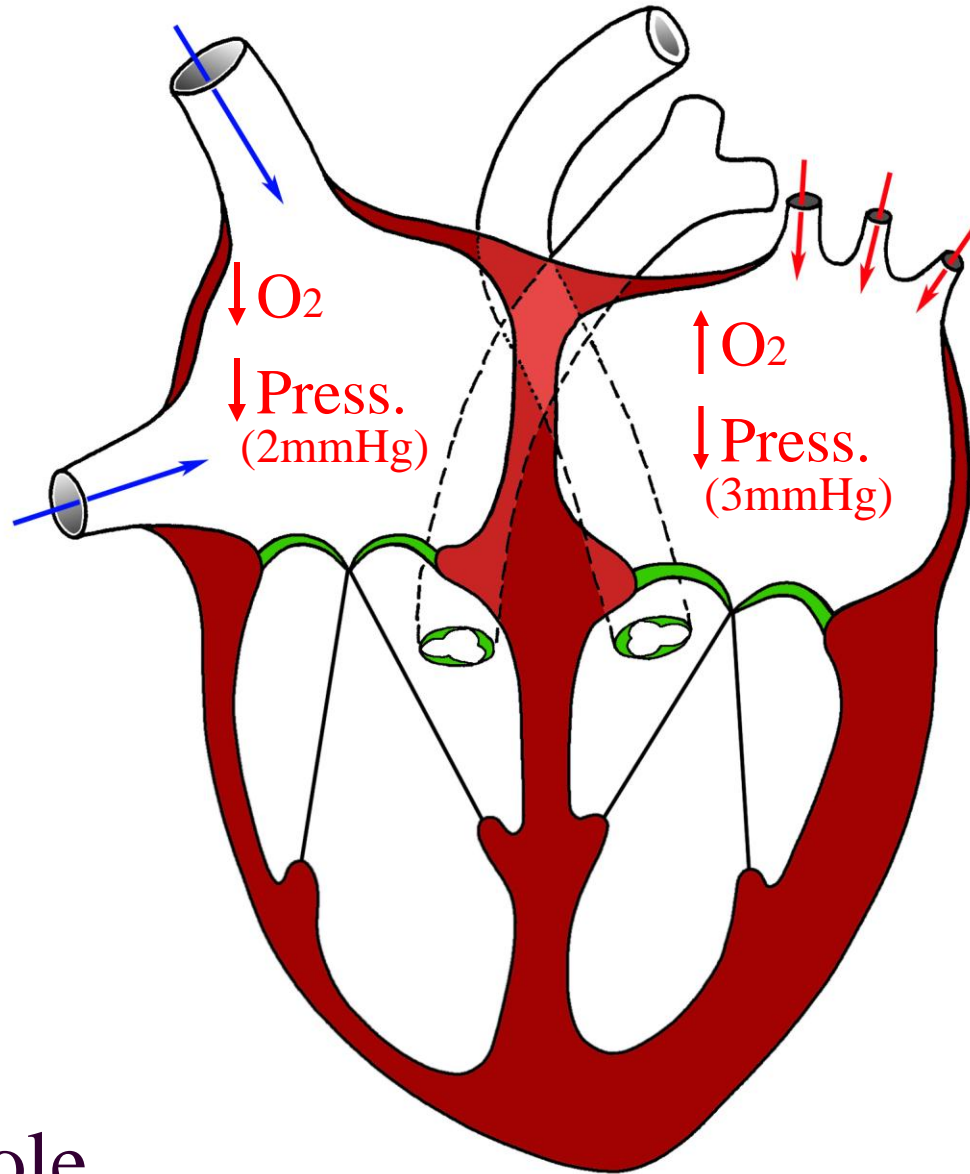
aorta

pulmonary trunk

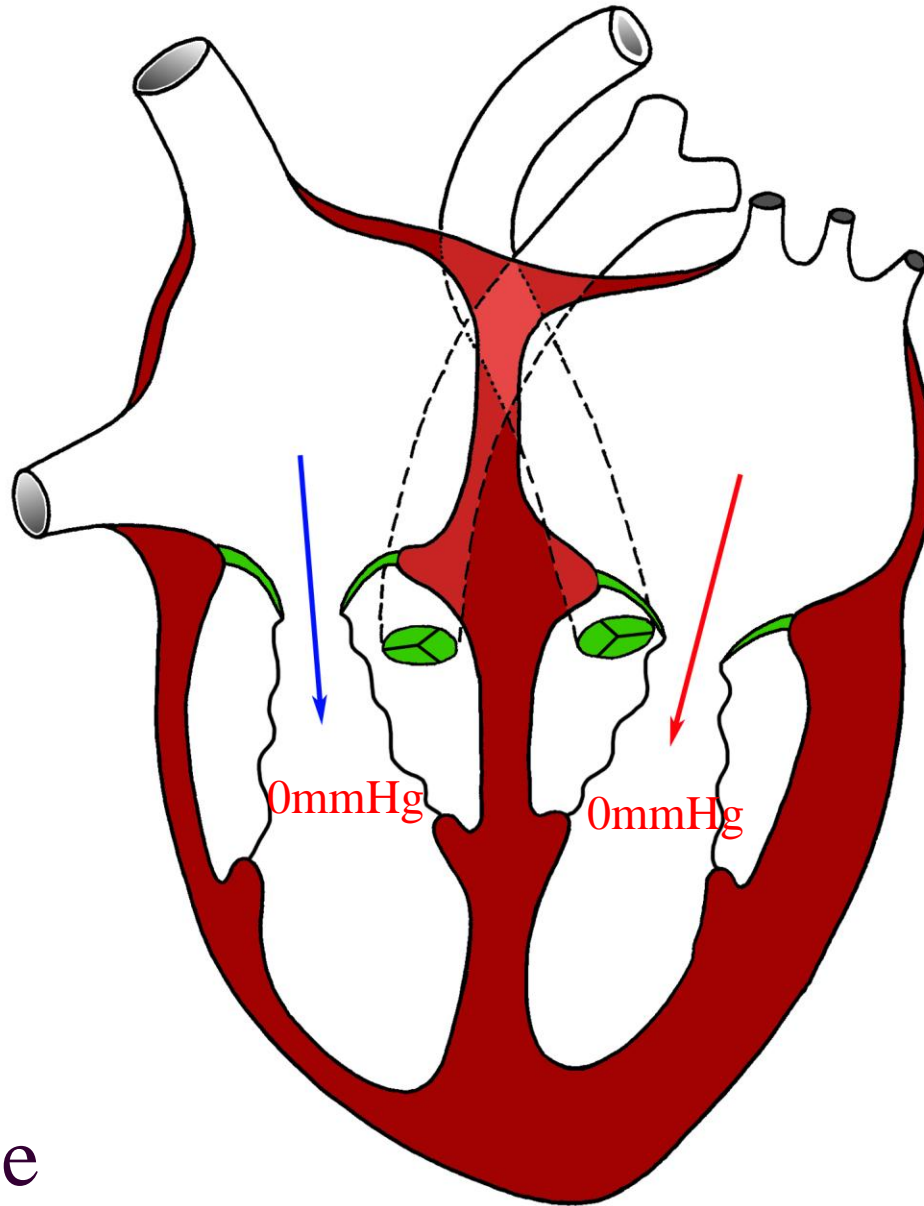


pulmonary valve

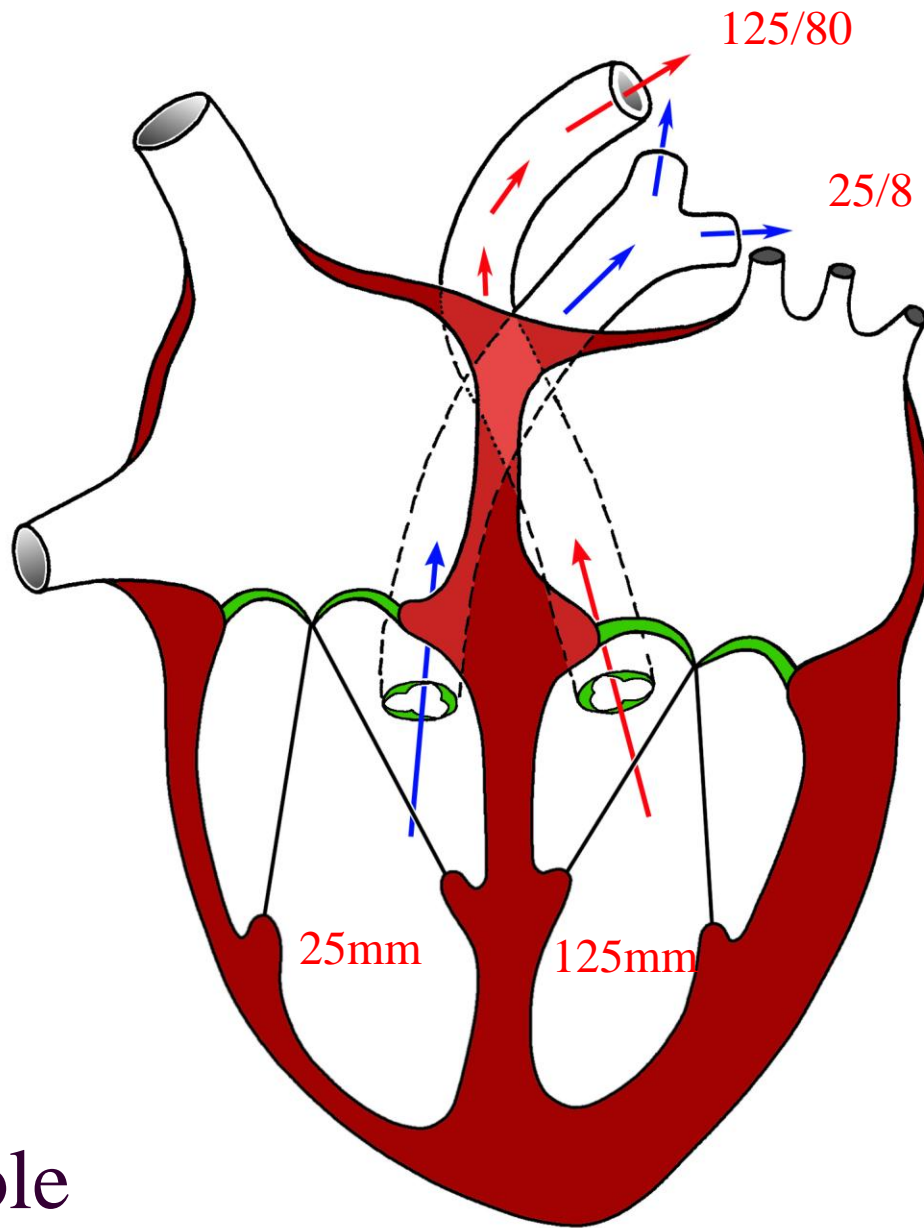
aortic valve



Systole



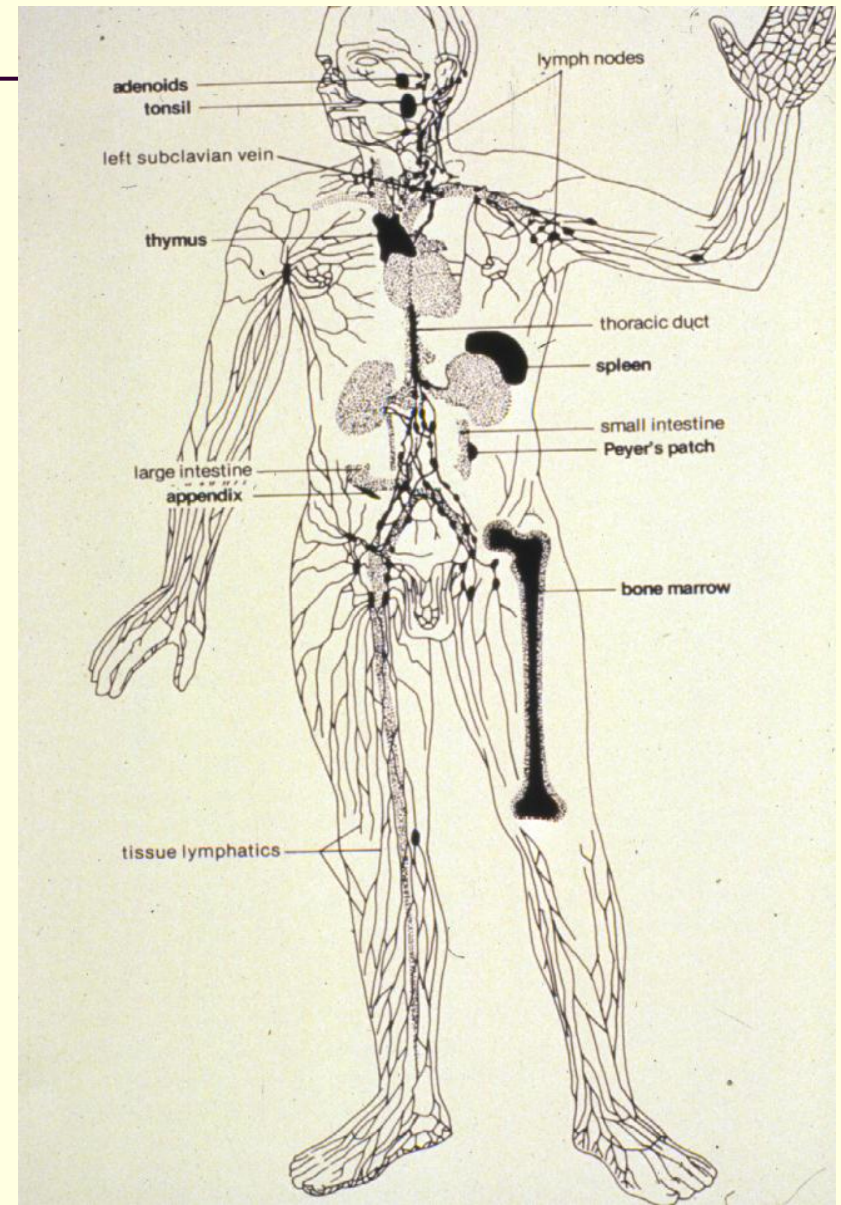
Diastole



Systole

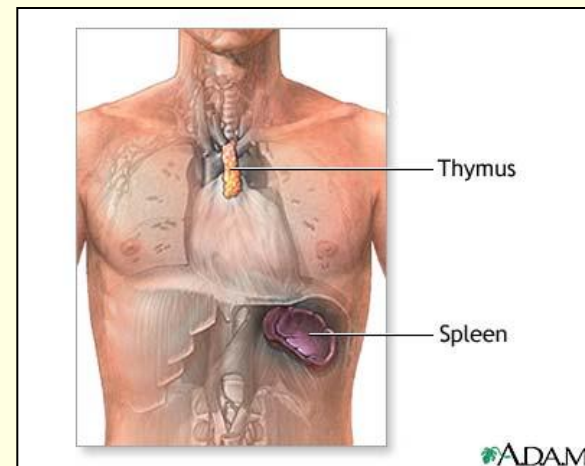
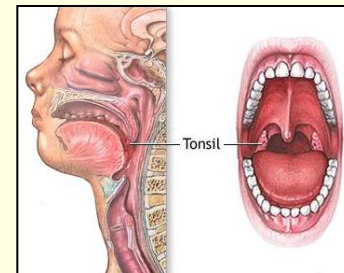
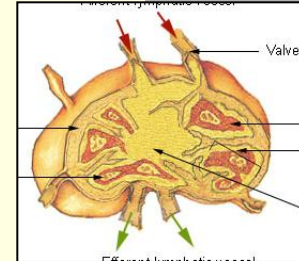
# Lymphatic System

- Returns fluid from the tissues to the circulatory system.
- Consists of:
  - Lymph
  - Lymphatic vessels
  - Lymphatic structures



# Parts and Functions of the Lymphatic System

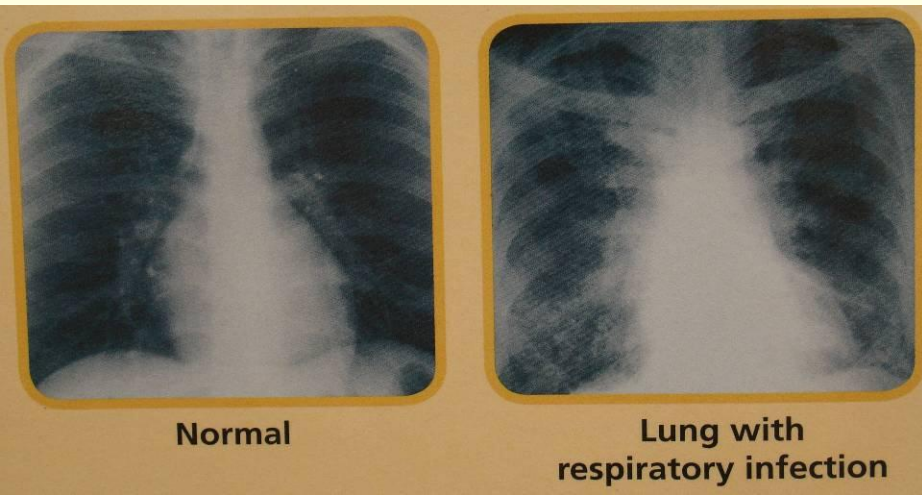
- Lymph nodes
  - Filters and traps foreign particles.
  - Contain white blood cells.
- Tonsils
  - Protects against bacteria.
- Thymus
  - Helps with immunologic cells.
- Spleen
  - Clears out old red blood cells.



# Functions of the Lymphatic System

---

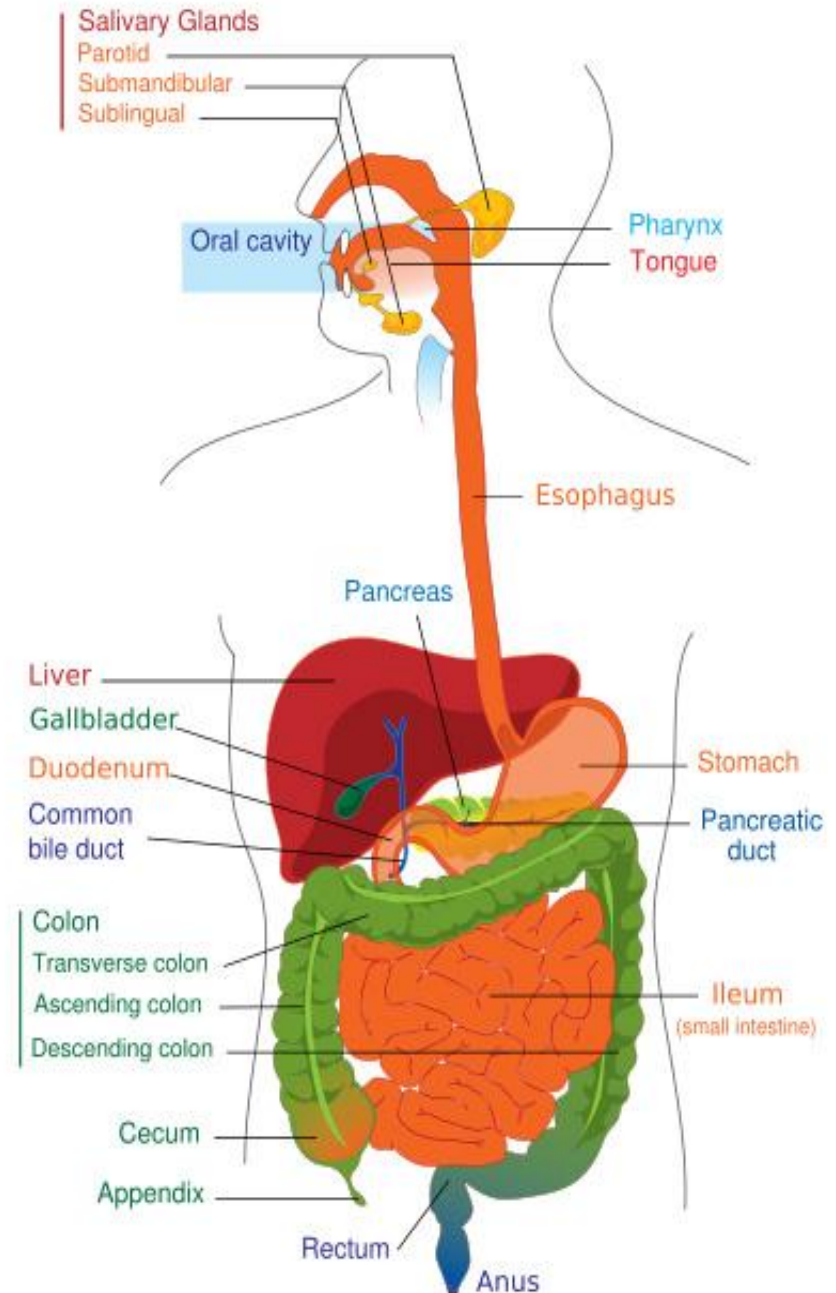
- Removes excess fluids from body tissues.
- Absorbs fatty acids.
- Transports fat.
- Produces immune cells (lymphocytes).
- Helps combat infections.





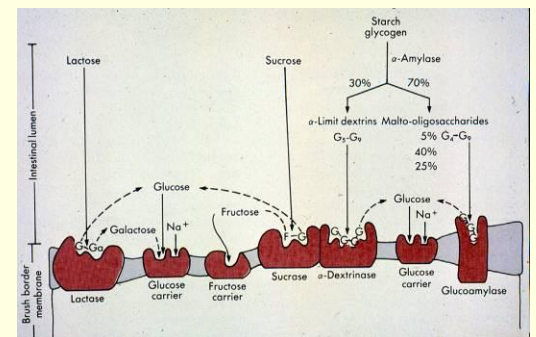
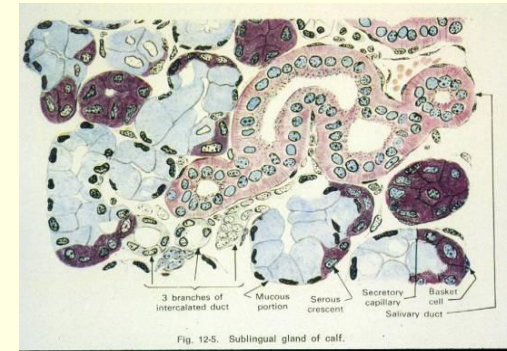
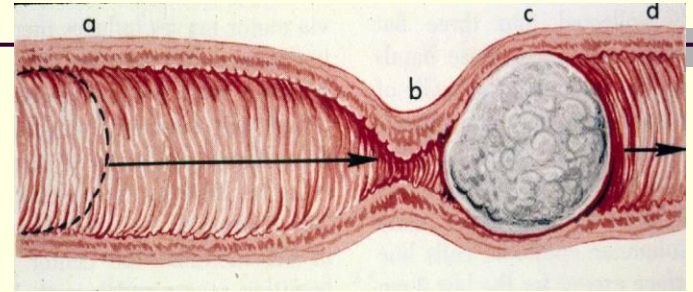
# Digestive System

- Involves
  - Prehension
  - Digestion
  - Absorption of food
  - Elimination of solid waste material
  
- Parts
  - Oral cavity
  - Esophagus
  - Stomach (gastro)
  - Small intestines
  - Large intestines



# Functions of the Gastro-Intestinal Tract (G-I Tract)

- Moves food.
- Secretes of digestive juices.
- Absorbs digested foods, water, and electrolytes.

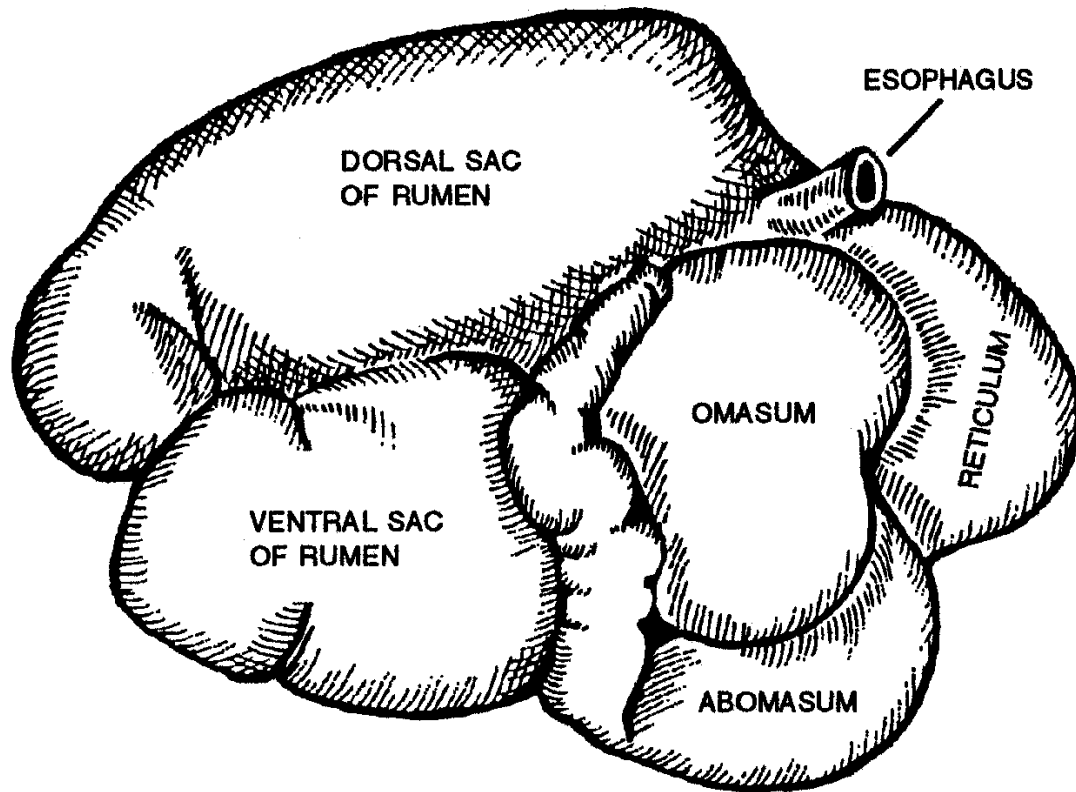


## Stomach of Ruminants

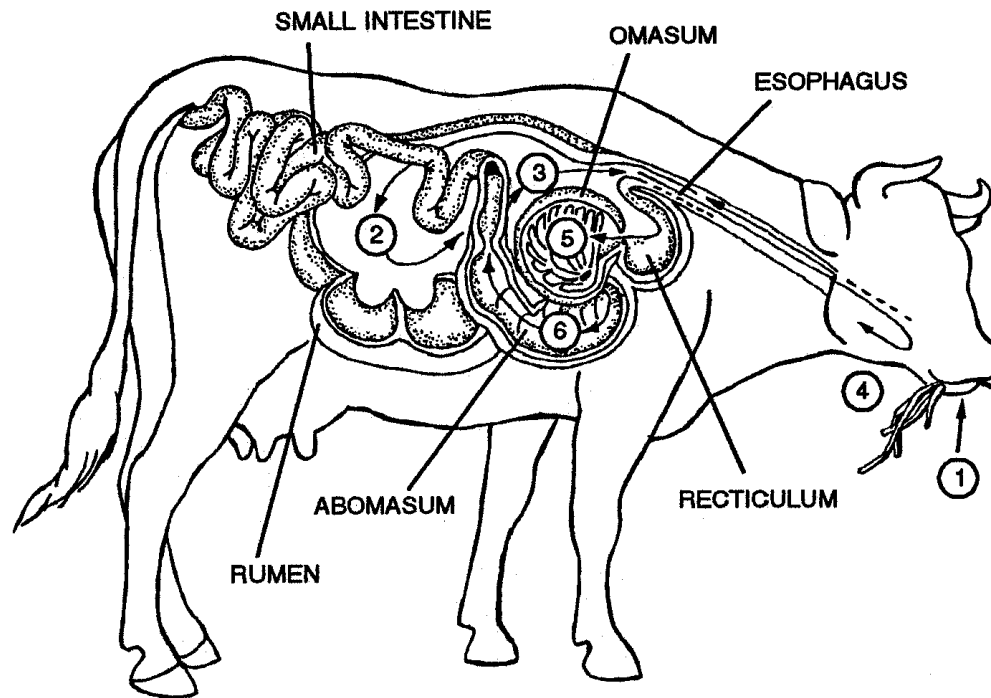
- Four chambers
  - Rumen
  - Reticulum
  - Omasum
  - Abomasum

## Stomach of Monogastrics

- Single stomach



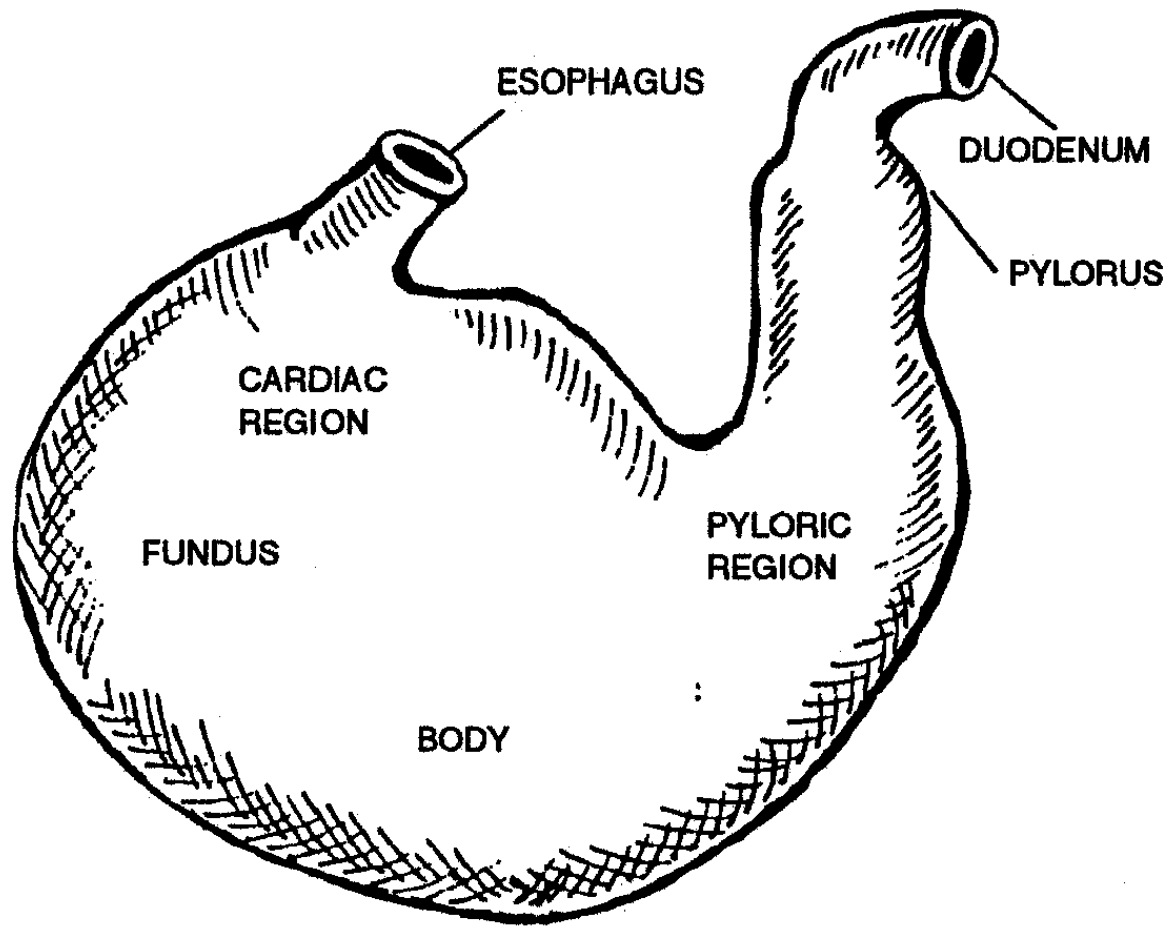
**RUMINANT STOMACH**



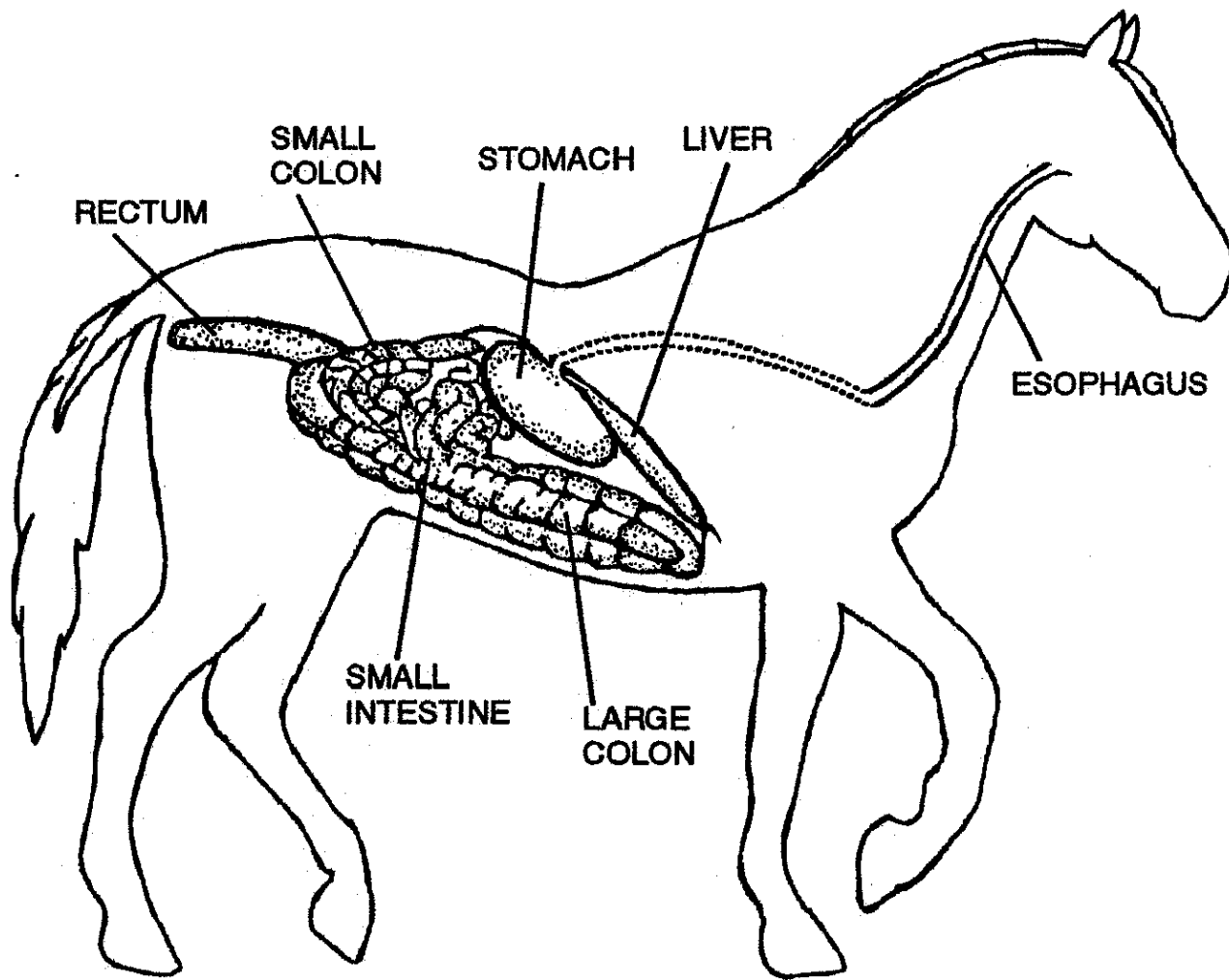
## RUMINANT DIGESTIVE SYSTEM

1. Ingestion
2. & 3. Rumen and reticulum work together with symbiotic bacteria to help break down feed. The reticulum sorts the feed and sends it back to be chewed further.
4. The cow regurgitates and rechews the cud to break down the fibers further.
5. The omasum removes water from the feed.
6. Abomasum, where digestion continues.

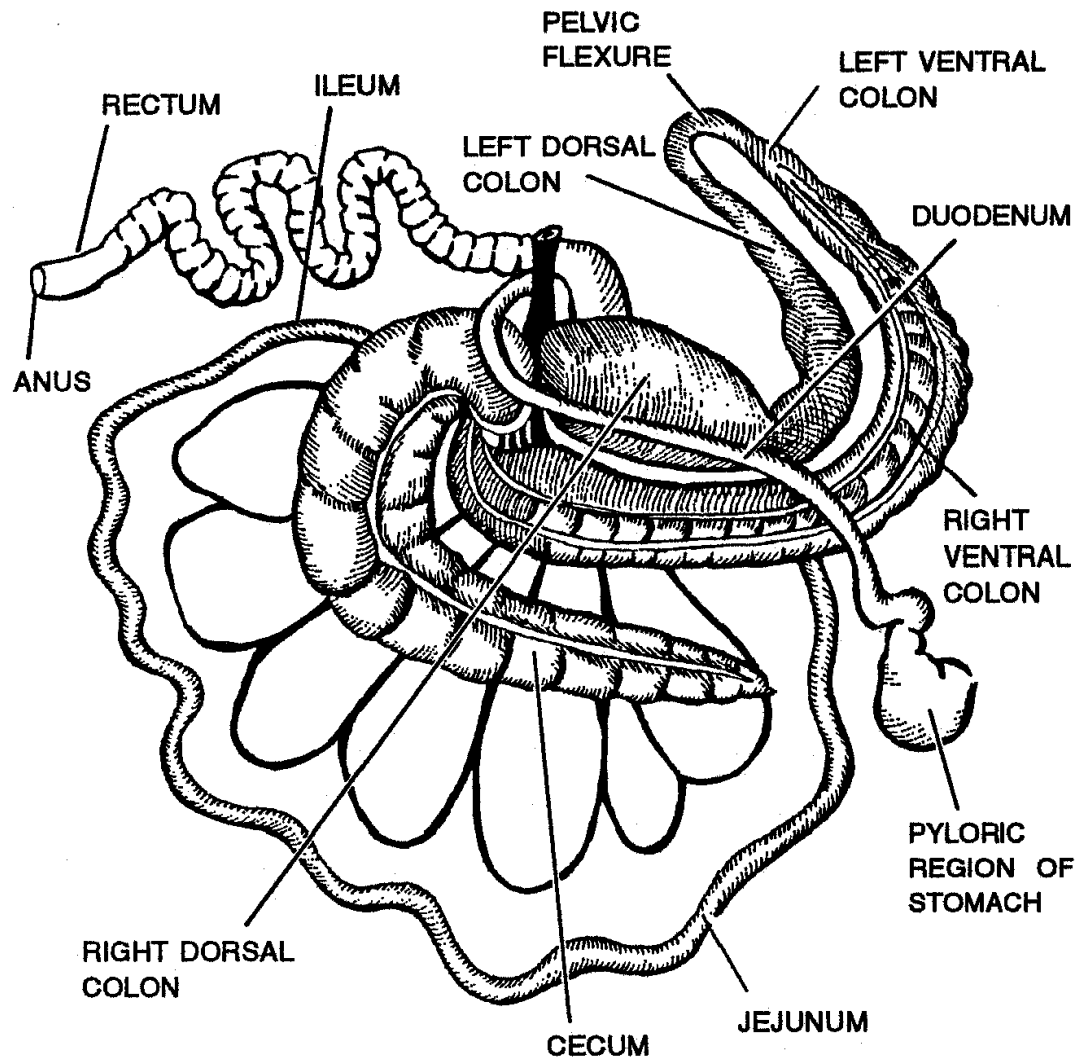
**Note:** Many of the nutrients a cow receives comes from the by-products of the bacteria that help the cow digest the hay and grass it eats.



**MONOGASTRIC STOMACH**



**Digestive System of the Horse**



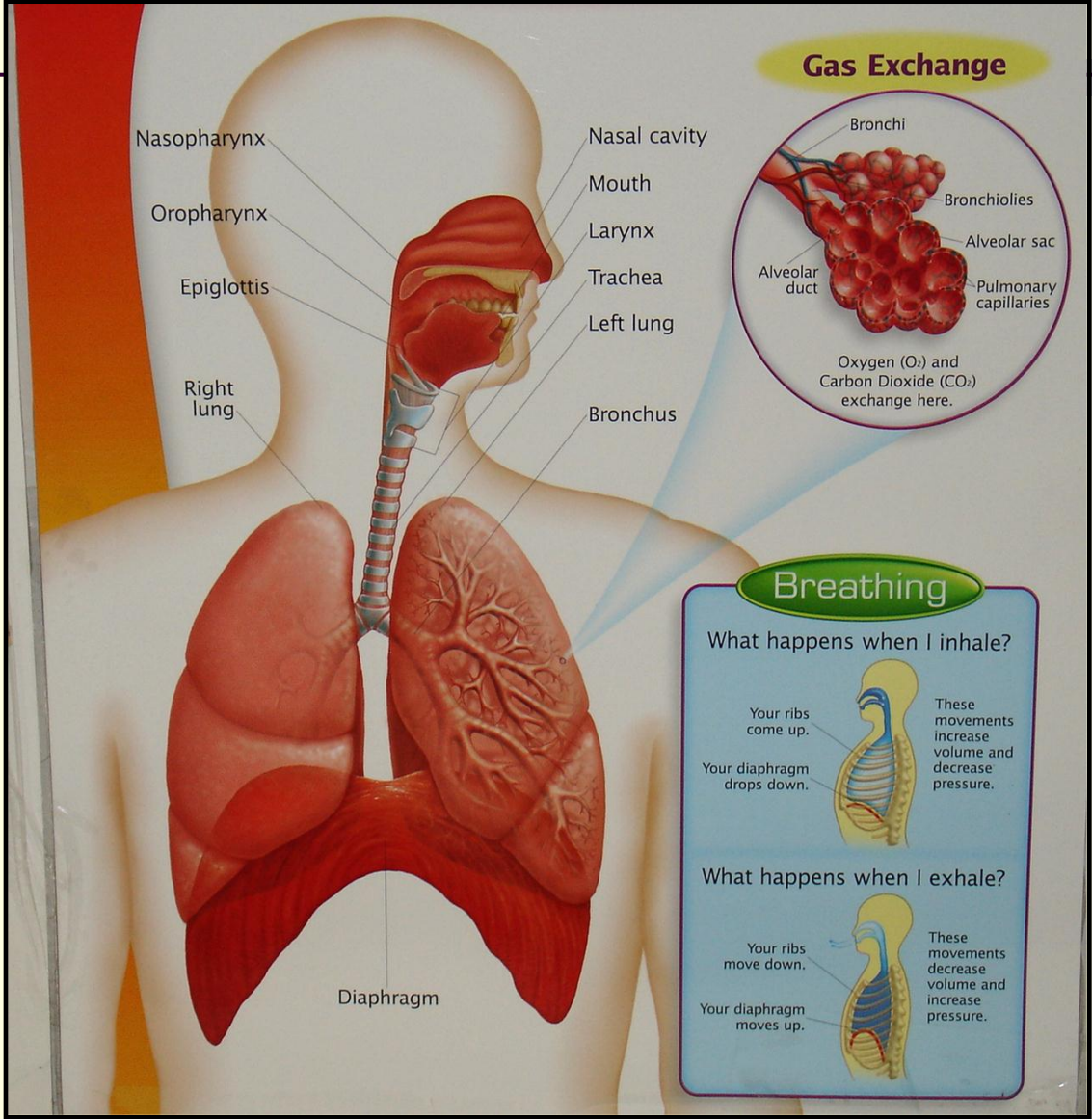
**Intestinal Tract of the Horse**



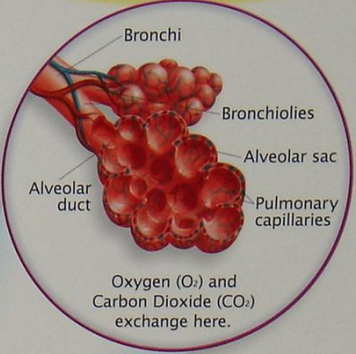
# Parts of the Respiratory System

---

- For conducting air:
  - Nasal cavity
  - Nasopharynx
  - Larynx
  - Trachea
  - Bronchi
  - Bronchioles
- For exchanging gas:
  - Alveoli



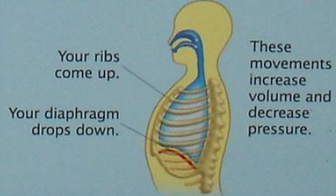
### Gas Exchange



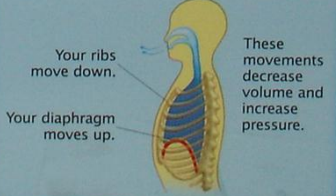Oxygen (O<sub>2</sub>) and Carbon Dioxide (CO<sub>2</sub>) exchange here.

### Breathing

What happens when I inhale?



What happens when I exhale?

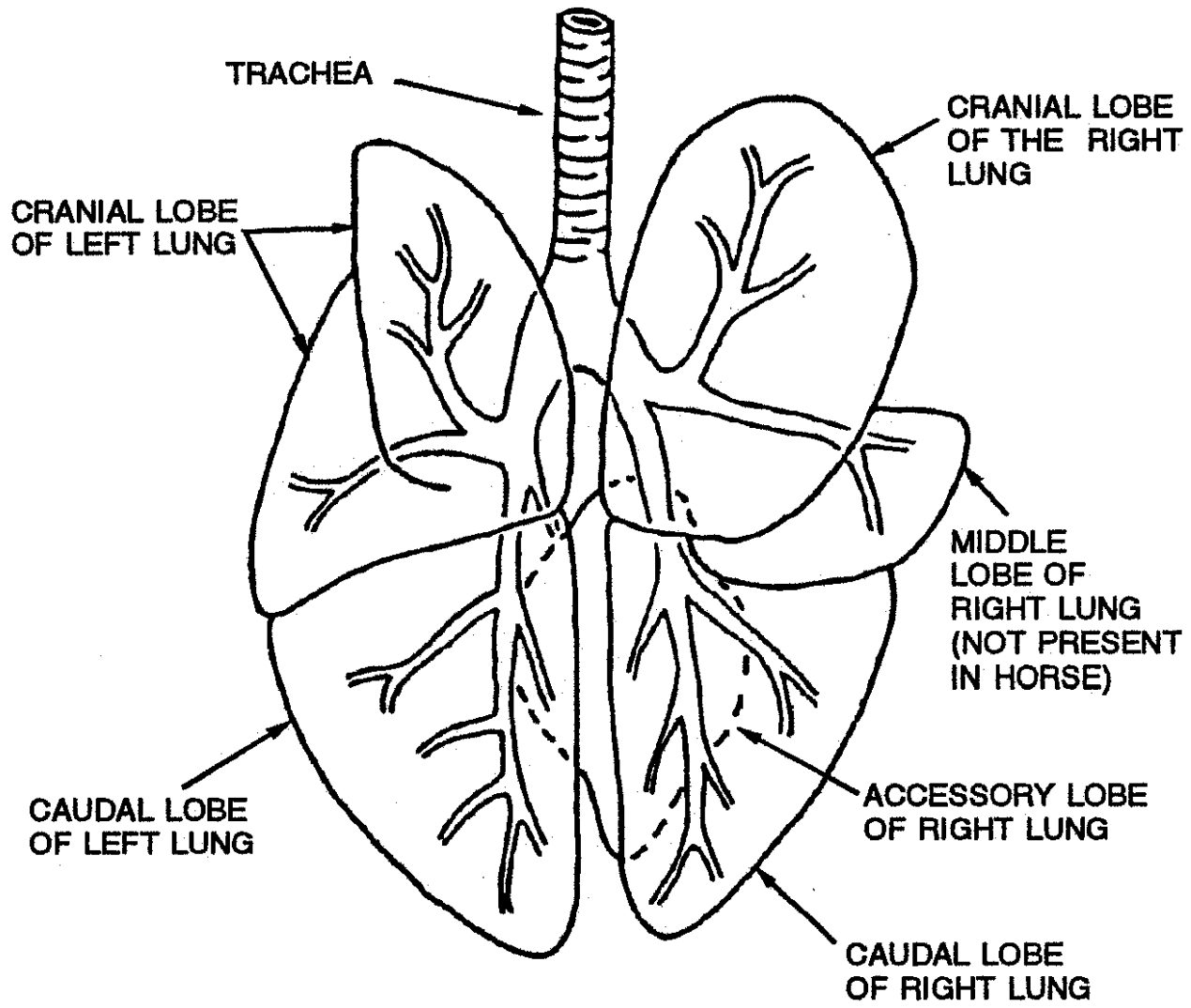


# Functions of the Respiratory System

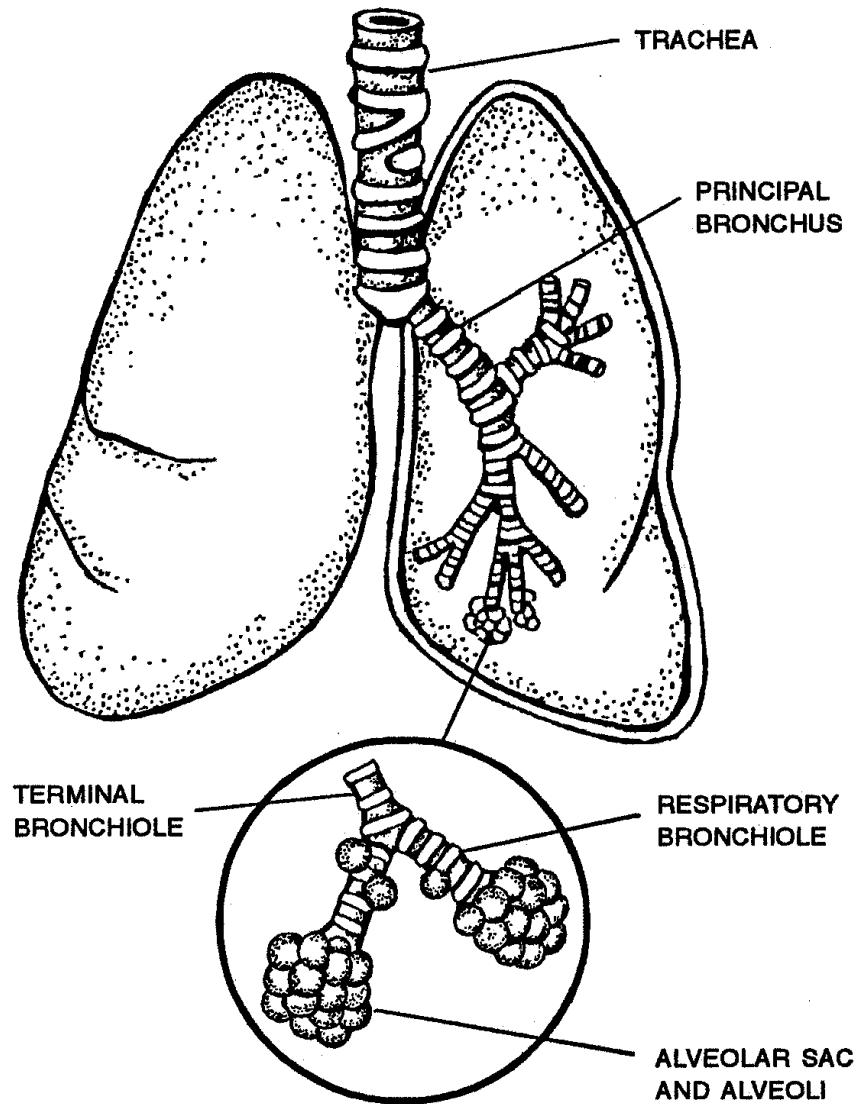
---

- Includes inspiration and expiration.
- Provides an exchange of respiratory gases.  
(oxygen and carbon dioxide)
- Warms, cleans, and humidifies air.
- Aids olfaction and phonation.





**DOG**

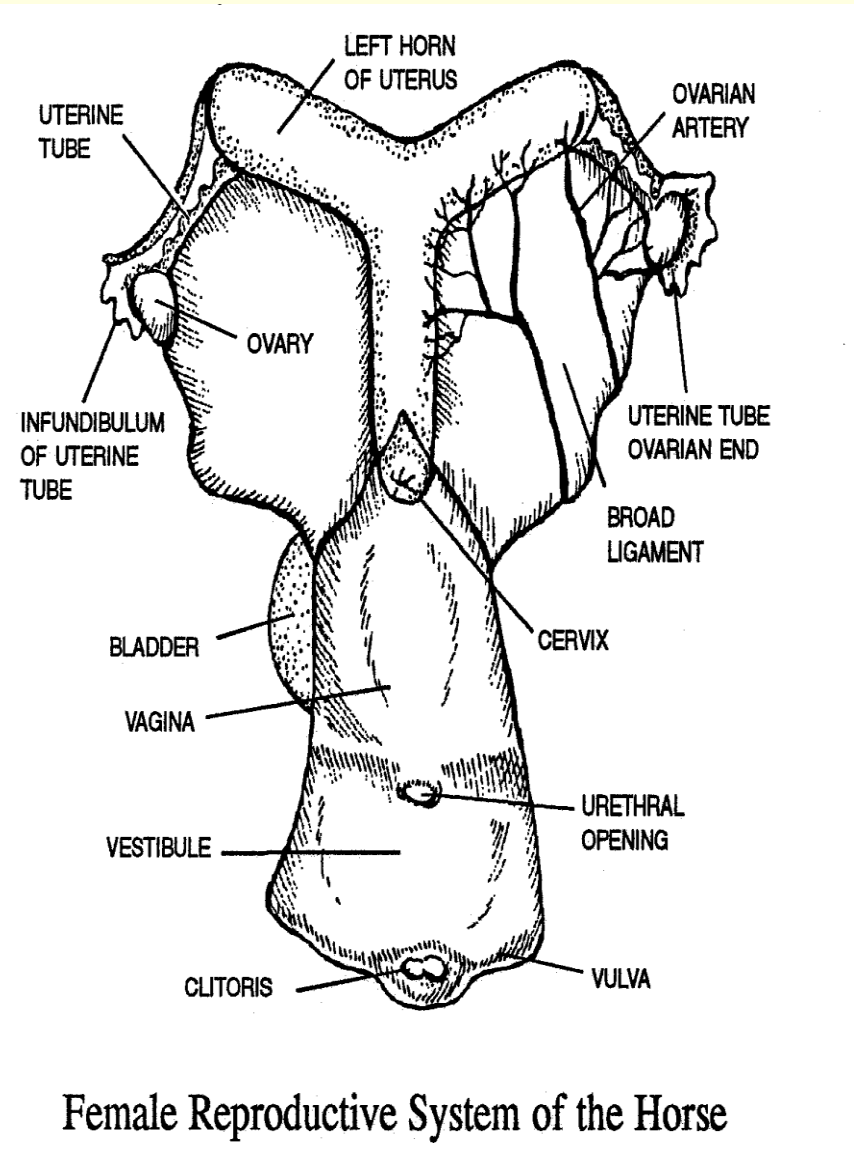
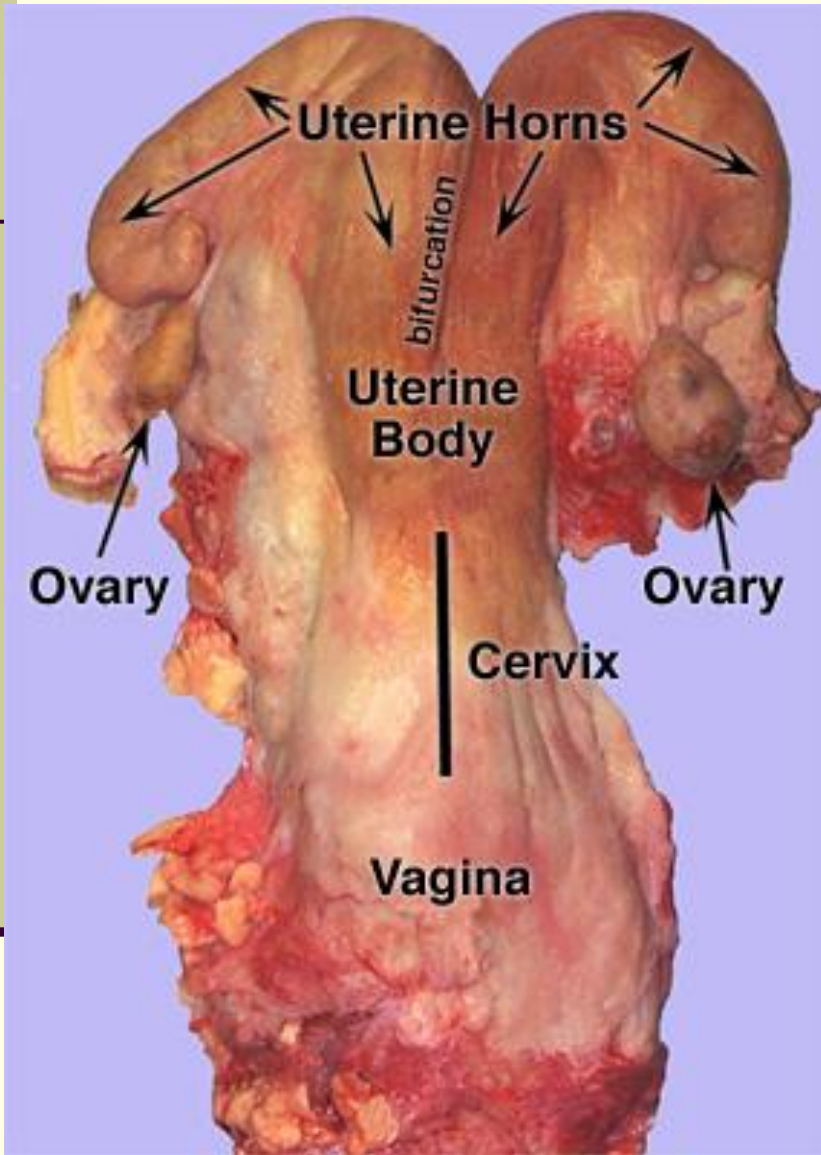


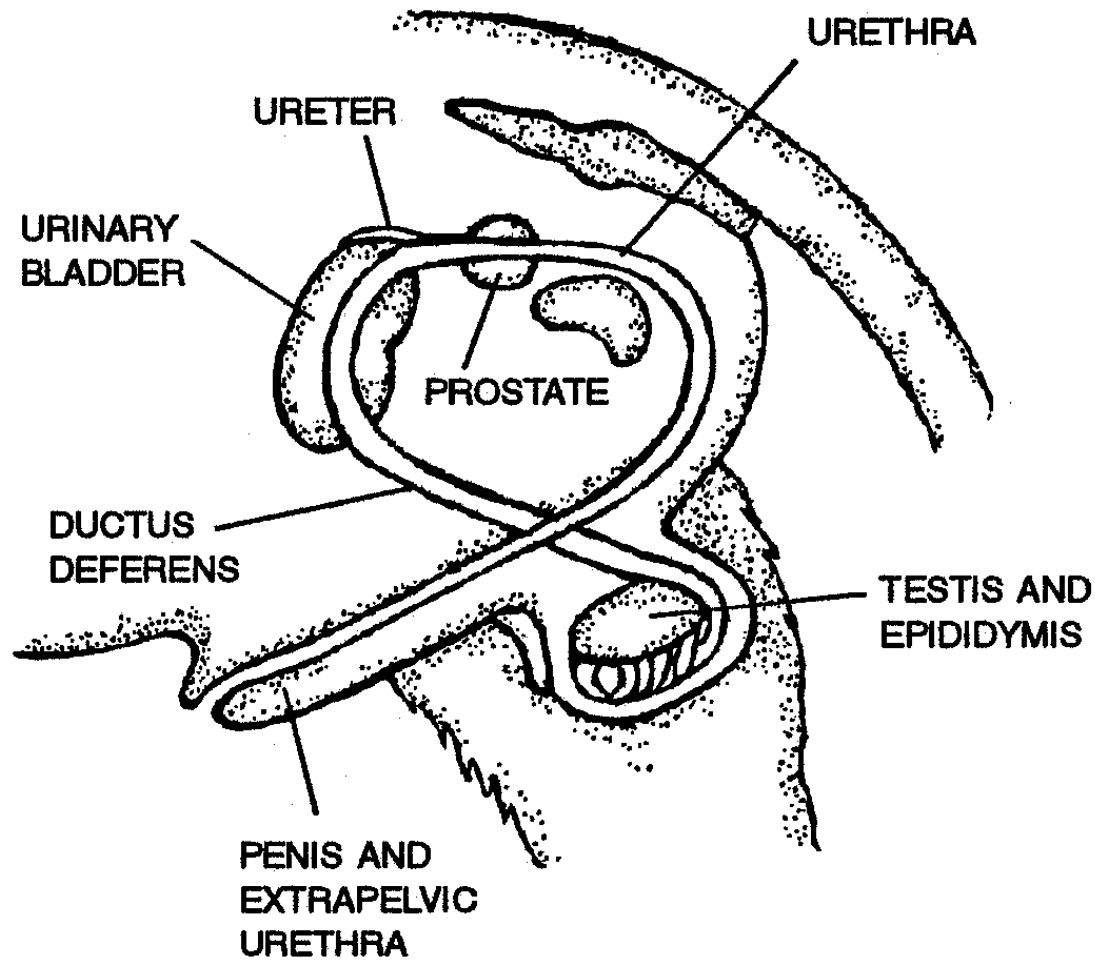
Internal Anatomy of the Lungs

# Reproductive System

---

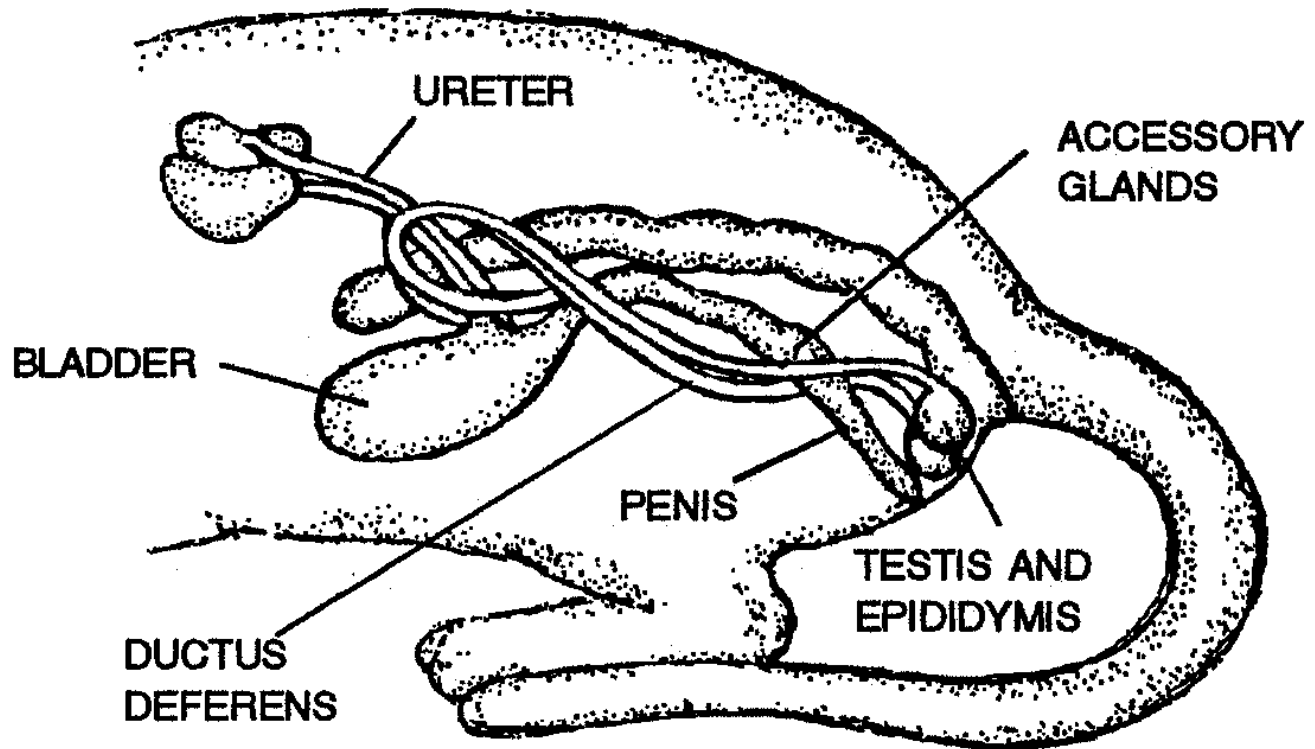
- Functions of the reproductive system
  - Provides process for reproduction.
    - Production of offspring
- Parts of the reproductive system
  - Female animals
  - Male animals



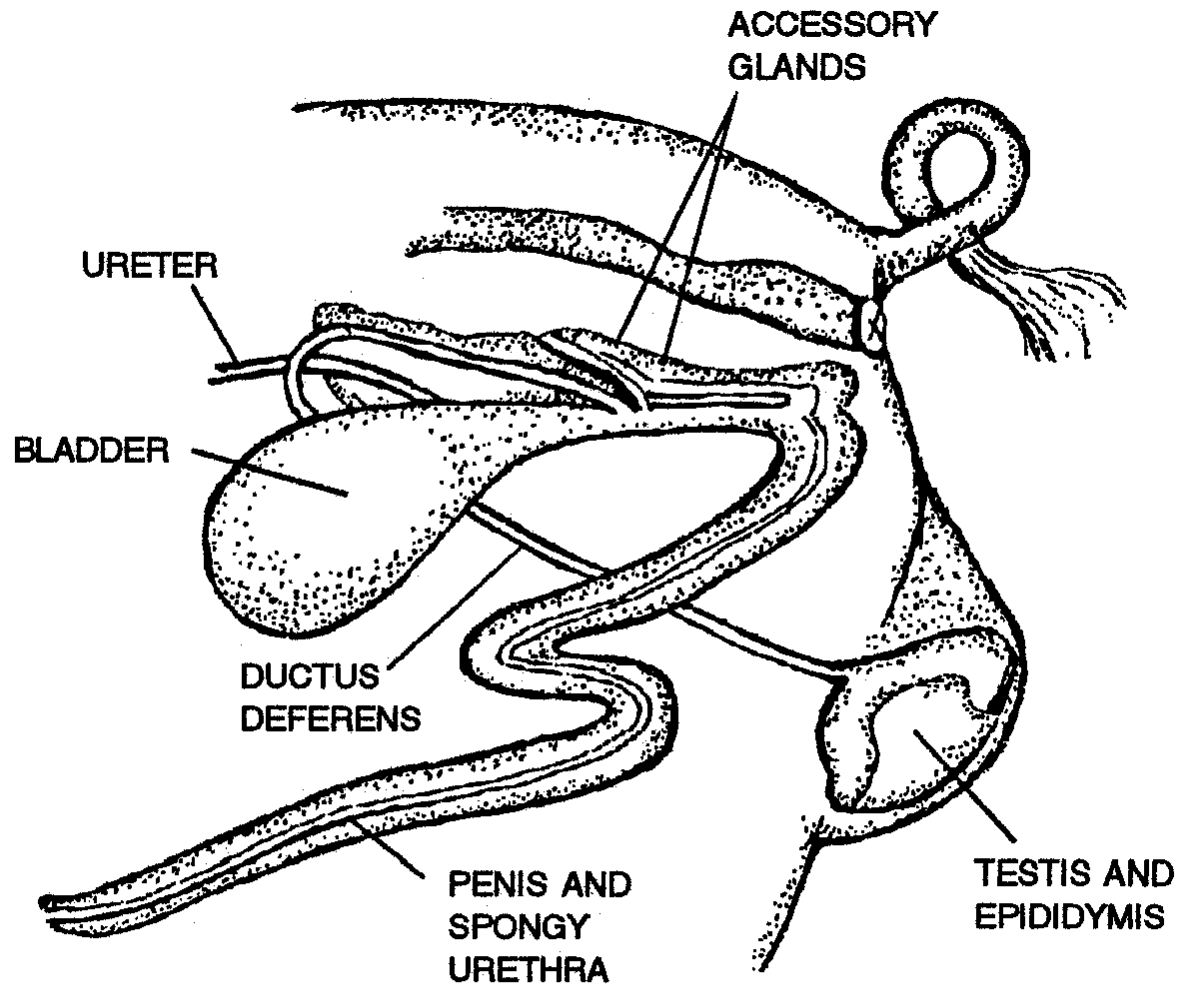


**DOG**

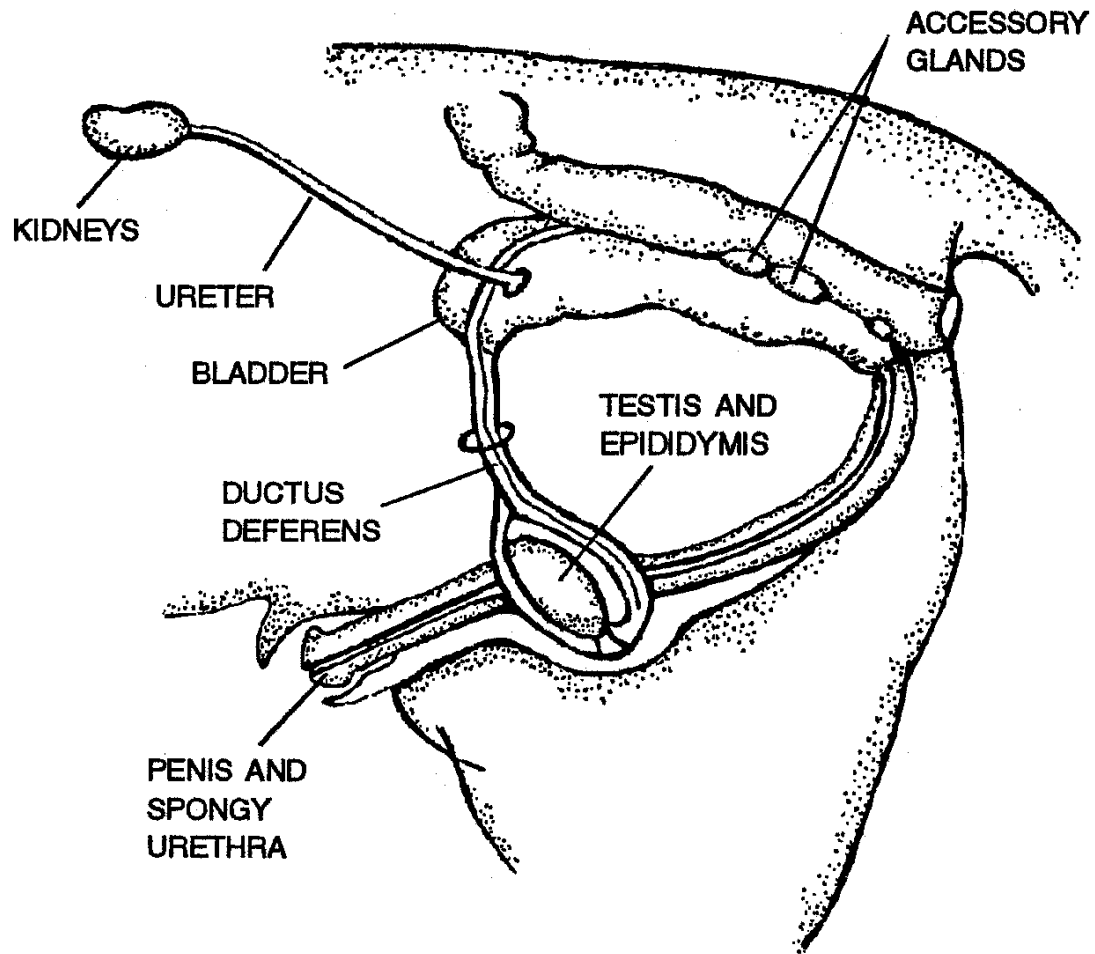




**CAT**



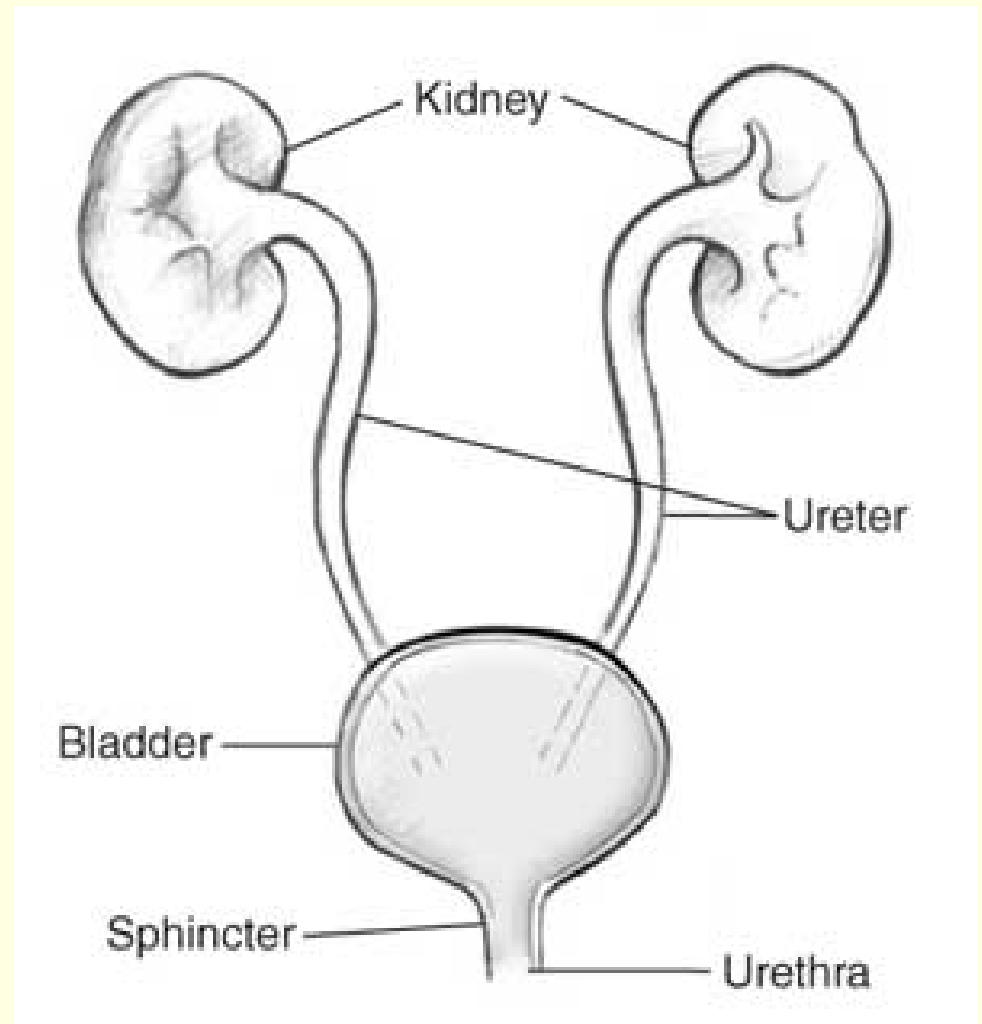
FIG



**HORSE**

# Parts of the Urinary System

- Kidneys
- Urinary bladder
- Ureters
- Urethra



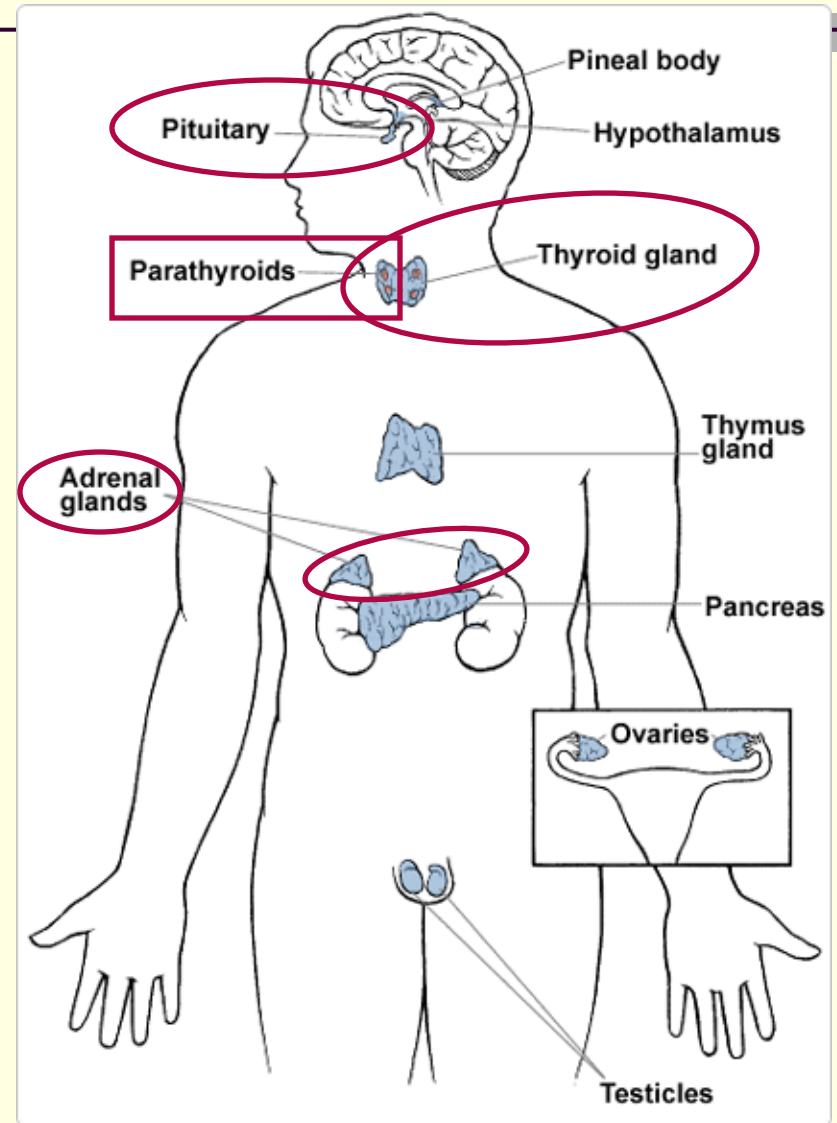
# Functions of the Urinary System

---

- Absorbs metabolites.
- Stores urine temporarily.
- Eliminates urine.
  - Excretes waste products.

# Parts of the Endocrine System

- Pituitary gland
- Thyroid gland
- Parathyroid glands
- Adrenal glands
- Related parts:
  - Pancreas
  - Gonads
  - Placenta
  - G-I tract



# Functions of the Endocrine System

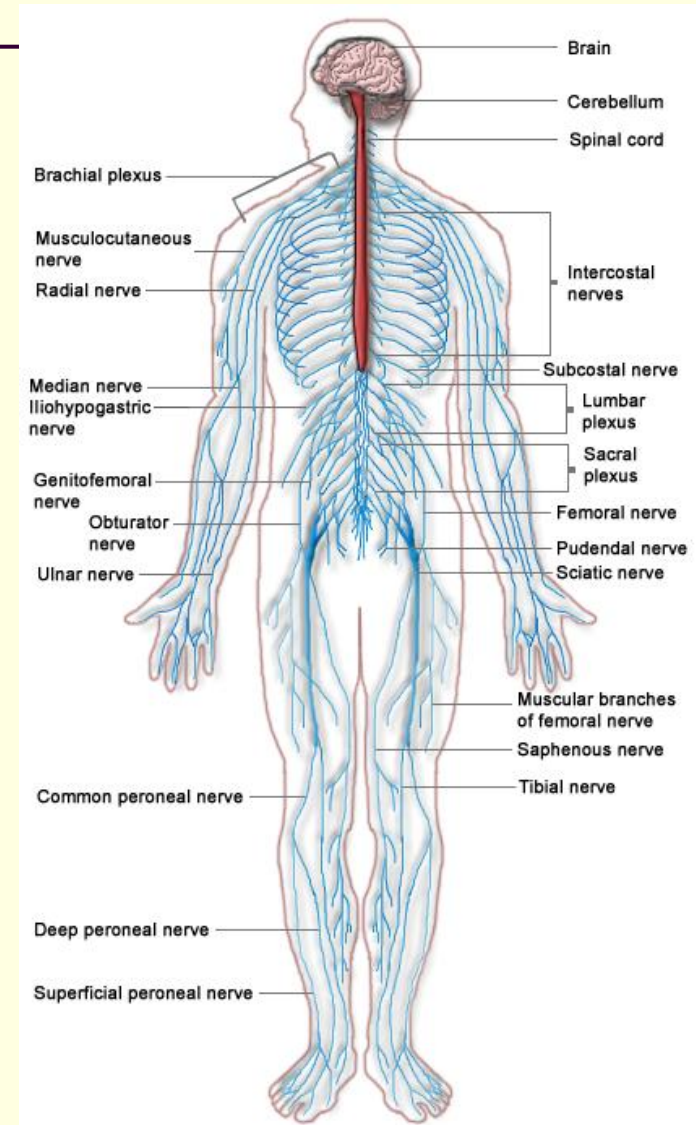
- Releases hormones.
- Regulates metabolism.
- Regulates growth/development.
- Regulates tissue function.
- Regulates mood.



A custom-tailored suit, fitted by a normal-size tailor, was a necessity for the 8-foot-5-inch (2.5-meter) giant Robert Wadlow.

# Parts of the Nervous System

- Central nervous system
  - Brain
  - Spinal cord
- Peripheral nervous system
  - Somatic nerves
  - Automatic nerves





# Functions of the Nervous System

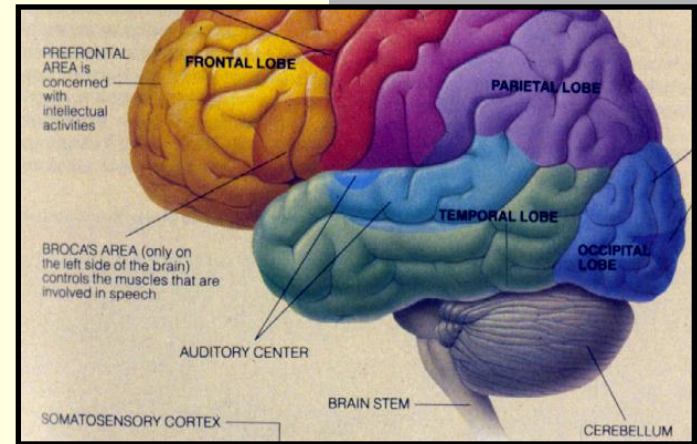
---

- Controls functions and movement of:
  - Organs
  - Muscles
  - Sensory organs
- Neurons relay and receive information.
- Neurons conduct electrochemical signals.

# The Central Nervous System (CNS)

## The Brain

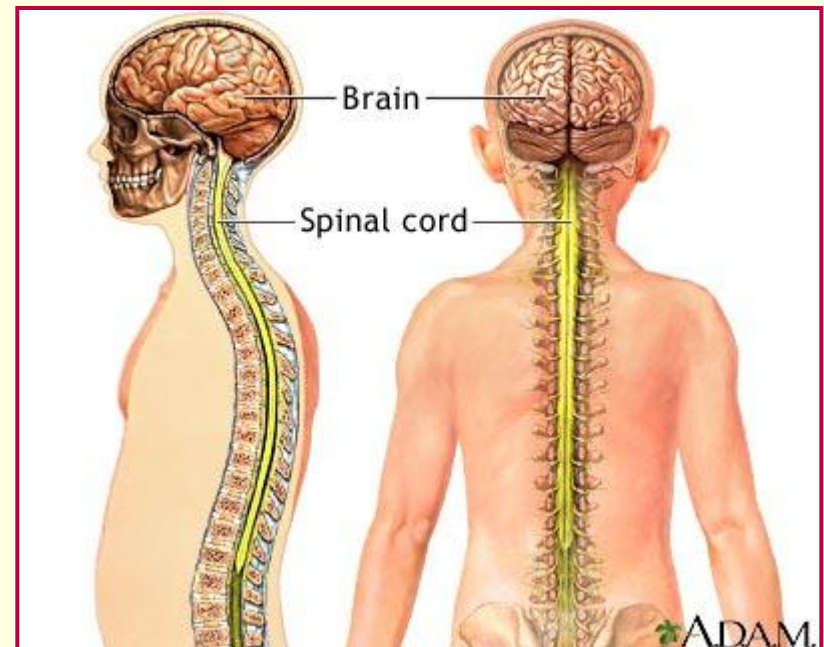
The central information processing organ of the body



## The Spinal Cord

Long, thin tubular bundle of nerves

Connected to the brain



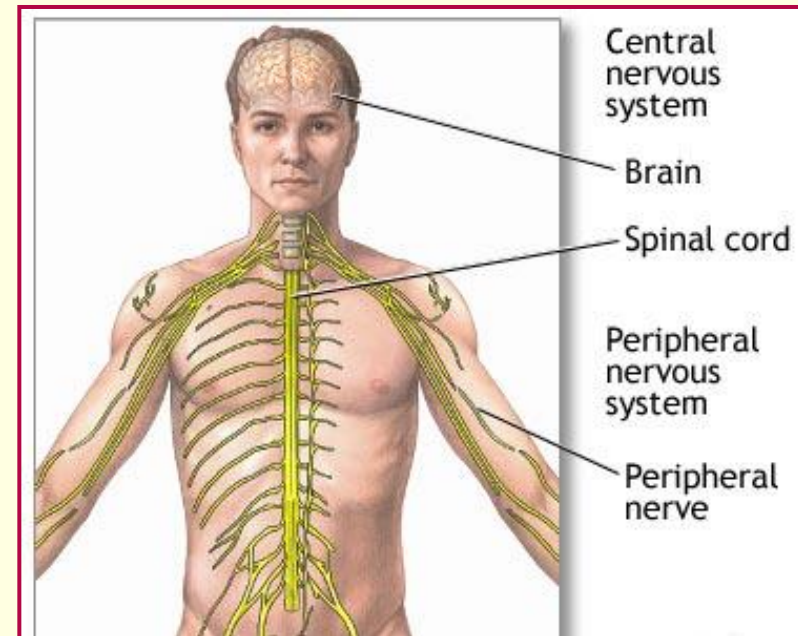
# The Peripheral Nervous System

## Somatic Nerves

Control voluntary muscles that provide movement.

## Autonomic Nerves

Control involuntary responses.  
(smooth muscle, cardiac muscle, glands, and organs)



# Special Systems

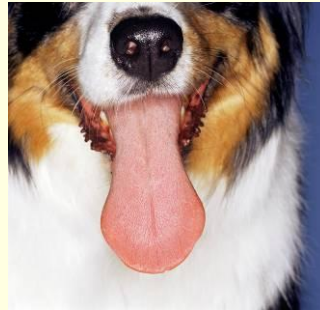The Eye (sight)



The Ear (hearing and balance)



The Tongue (taste)



The Nasal Cavity (smell)

