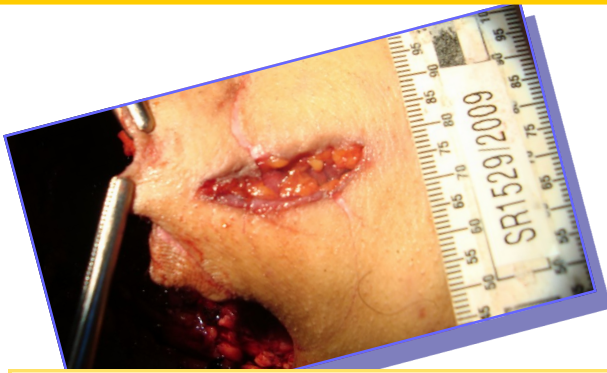
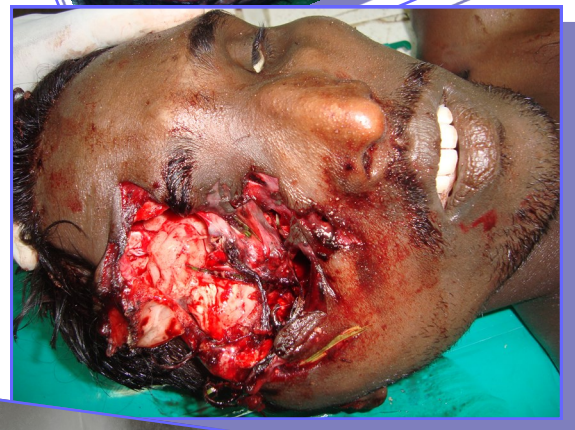
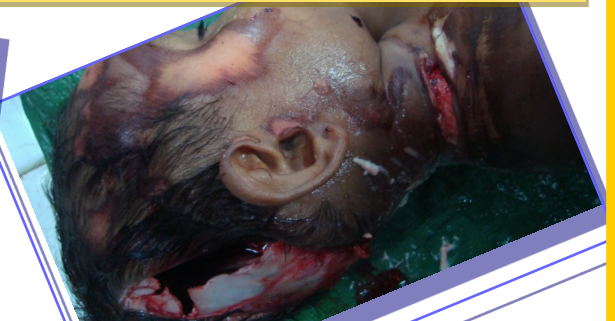GUIDELINES ON AUTOPSY PRACTICE

CRIMINALLY SUSPICIOUS CASES AND HOMICIDES



DEPARTMENT OF FORENSIC MEDICINE

Dr. I.G.D. Kitulwatte & Prof. P.A.S. Edirisinghe

GUIDELINES ON AUTOPSY PRACTICE

CRIMINALLY SUSPICIOUS CASES AND HOMICIDES

DEPARTMENT OF FORENSIC MEDICINE

Dr. I.G.D. Kitulwatte

Prof. P.A.S. Edirisinghe

I. INTRODUCTION

These guidelines were developed to improve the standards of the autopsies conducted in the Department of Forensic Medicine of the Faculty of Medicine, University of Kelaniya. The guidelines are intended to assist specially the trainees in deciding how to perform certain postmortem examinations, and to steer clear of pitfalls.

The guidelines include:

- Guidelines for autopsies performed on;
 - Homicidal or criminal suspicious deaths
 - Deaths associated with sexual violence
 - Deaths during restraint
 - Deaths following blunt force trauma to head
 - Deaths following penetrating or perforating trauma
 - Criminally suspicious deaths of children
 - Deaths associated with traumatic subarachnoid haemorrhage
- Sections on
 - formation of the opinion
 - peer review
 - communication with various stakeholders

These guidelines are recommended best practices and the applicability it in a specific case is balanced by the state of the body, information known at the time of the postmortem examination, and professional judgment.

This document will be revised in the future as forensic pathology evolves and new facilities are available.

II. GENERAL OBJECTIVES

The aim of these guidelines are

- To provide assistance and support to the trainees
 - To decide on the best practices applicable to a particular case
 - To minimize non-reviewable errors at autopsy.
 - To help ensure that autopsy findings, are documented adequately using uniform procedures
- To ensure appropriate samples are collected at autopsy.
- To ensure appropriate ancillary testing is performed after autopsy

III. ACKNOWLEDGEMENT

These guidelines were developed based on the “Guidelines on autopsy practice for forensic pathologists; Criminally suspicious cases and homicides” prepared and used by the Ontario Forensic Pathology Service, Toronto, Canada under the guidance of Prof. Michael Pollanen.

IV. THE CONTENT

1. Role of the forensic pathologist at an autopsy
2. The opinion of the expert in forensic medicine
3. Communication with the police and inquirer(ISC/Magistrate) coroner and the relatives
4. Autopsy guidelines for common forensic cases with criminal suspicion
5. Undifferentiated criminally suspicious death including cases of suspected mechanical asphyxia
6. Rape-homicide or death associated with sexual violence
7. Death during restraint
8. Blunt trauma of head or body
9. Penetrating or perforating trauma from projectiles or sharp instrument(s)
10. Homicidal or criminally suspicious death in infancy or childhood
11. Traumatic subarachnoid hemorrhage

1. ROLE OF THE FORENSIC PATHOLOGIST AT AN AUTOPSY

1. To conduct medico-legal post-mortem examinations and provide opinions to the cause and the mechanism of death and any other relevant issues within the expertise of forensic pathology based on scientific reasoning.
2. To prepare a post-mortem report with expert opinion addressing the important medico-legal issues
3. To take part as a team member in the death investigation
4. Provide expertise in forensic pathology to the criminal justice system
5. A specialist in forensic medicine must remain professionally independent of the magistrate, Inquirer into sudden death, police and legal representatives of both state and defence.
6. A specialist in forensic medicine is responsible for performing the post-mortem examination. Autopsy technicians will provide assistance at the postmortem examination under the direct supervision of the specialist in forensic medicine.
7. The autopsy must include
 - opening all four-body cavities (cranial, thoracic, abdominal, and pelvic cavities)
 - appropriate dissection of the tissues/organs.
 - The neck viscera with tongue must be excised and examined in all cases.However, the precise method used to perform the autopsy is left to the discretion of the specialist in forensic medicine.
8. It is the responsibility of the specialist in forensic medicine to:
 - Ensure chain of custody of the samples collected at autopsy prior to release of samples to the police or other investigative agency.
 - Ensure the collection of physical evidence to minimize the chances of contamination.
 - Personally perform critical forensic dissections such as neck dissection, pelvic dissection and musculo-skeletal dissection etc.

Scope of application

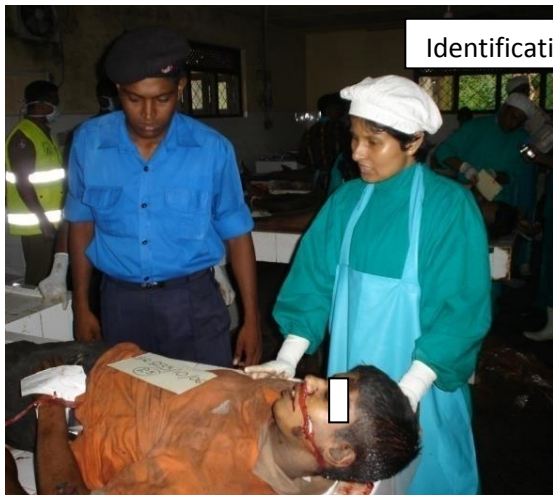1. The categories of cases addressed in this document are not exhaustive.
2. Depending on the case, you need to apply various aspects of the guidelines.
3. There may be limitations in application of guidelines in some situations such as decomposition, hospitalization, partial remains etc.
4. The guidelines are designed to assist the trainees and the specialists in forensic medicine to improve the quality of work and not to replace professional judgement.

Attendance at the autopsy

1. Attendance at the autopsy is limited to support staff (e.g., autopsy assistants), medical professionals, appropriate trainees (both undergraduate and postgraduate), Magistrates, inquirers into sudden death, and people from relevant investigative agencies including the police, fire investigators, and traffic investigators.

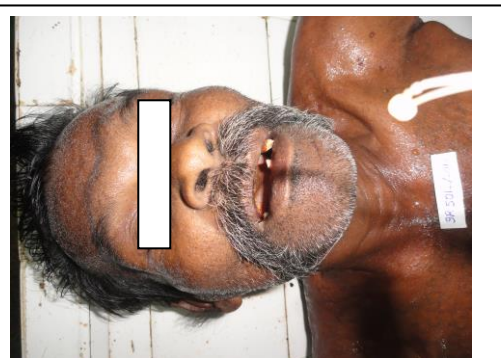Identification of the body

1. The identification of the body is not the responsibility of the pathologist but a responsibility of the police and the inquirer.
2. However you should make sure the body is correctly identified before starting the autopsy
3. You may assist in the identification process by facilitating fingerprinting, dental/radiographic identification, anthropological examination, or DNA analysis as well as in the final reconciliation.

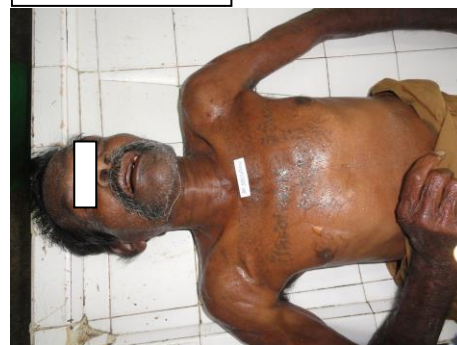

Identification of a deceased in front of the Forensic pathologist

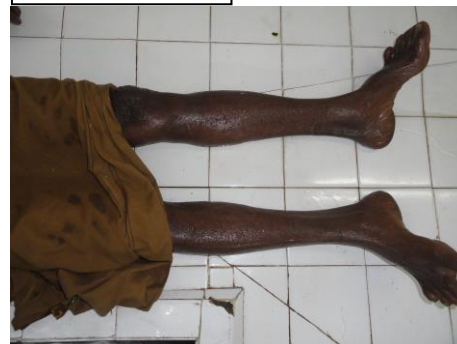Photograph 1:



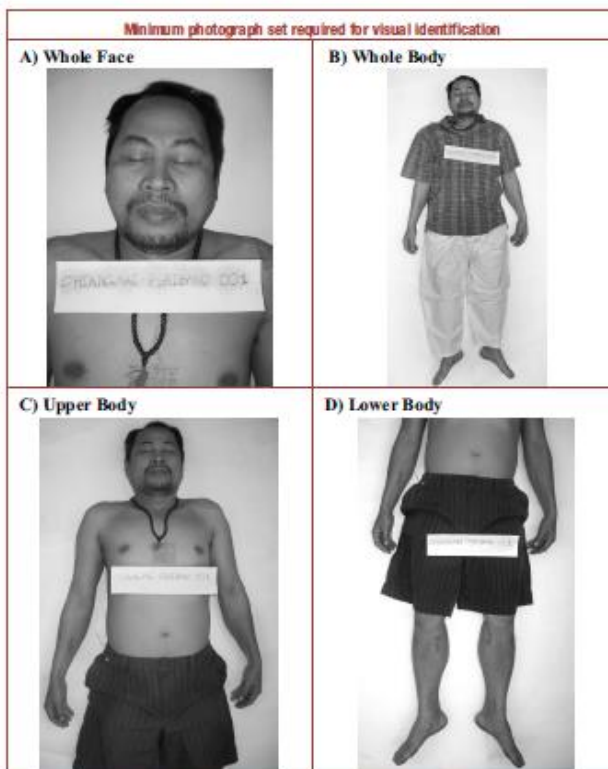Whole face



Upper body



Lower body



Photographs 2: Recommended photographs for identification (Courtesy of Management of dead bodies after disaster (Field Manual 2009))

Photograph 3A,3B,3C (a deceased)

Reviewability

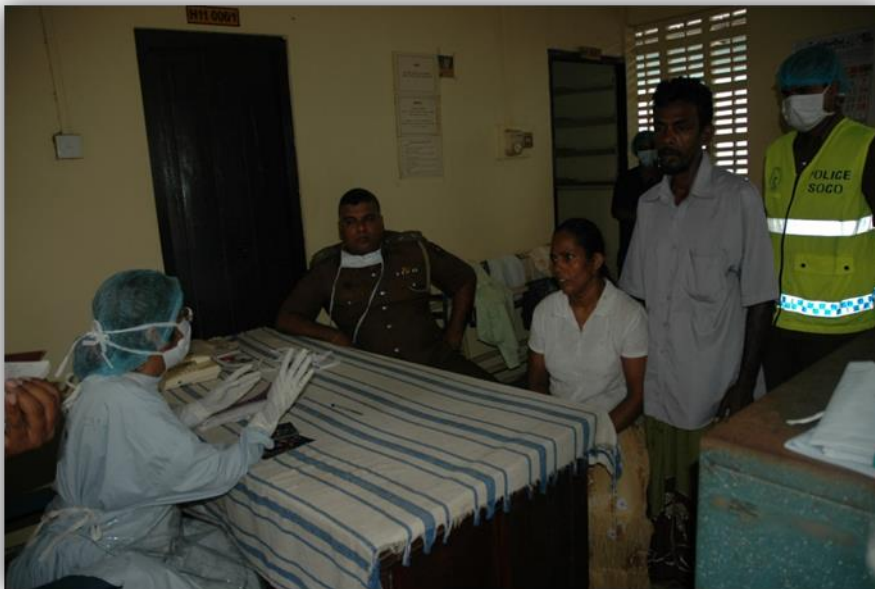1. You must recognize the importance of providing reviewable documentation of the autopsy to ensure adequate disclosure to relevant parties in a death investigation, or court proceeding.
2. Ensure all samples collected from the body are disclosed in the autopsy report, including:
 1. All tissues retained and fixed in formalin.
 2. Whole organs or *en bloc* specimens.
 3. All trace evidence, or other physical exhibits collected from the body.
 4. All swabs and smears.
 5. All samples of tissues or body fluids for toxicological, biochemical, or microbiologic studies.
 6. Post-mortem radiographs.
 7. Digital images taken by the practitioners in forensic medicine or designate that are not represented in the images obtained by police SOCO units.
 8. All tissue samples referred to consultants.
 9. The practitioners in forensic medicine must ensure that all the results of the investigations are stated in the autopsy report.

2. THE OPINION OF THE EXPERT IN FORENSIC MEDICINE

1. If the investigation results are awaiting, the cause of death should not be concluded and preliminary report may be issued where the cause of death is stated as pending or under investigation.
2. At the end of the autopsy, the expert is responsible for determining the cause of death, and giving other medico-legally relevant opinions based on the autopsy findings, results of ancillary testing and circumstantial information relating to the death.
3. The opinions and the reasoning that forms the opinion should be explained in writing in the autopsy report. Therefore, the autopsy report should not be just a documentation of observations or only a recording of findings.
4. At the same time, ensure that all autopsy findings that form the basis of the opinions are documented in a form that can be reviewed by peers (e.g., macroscopic photography, histology).
5. The expert opinions should, whenever possible, be evidence-based and not only informed by anecdotal experience.
6. Do not base any expert opinion on unproven evidence such as reported confessions, or assumptions that cannot be independently validated or corroborated by other evidence.
7. The cause of death must not be approximate. In the cause of death statement, avoid terms such as: *asphyxia*, *consistent with asphyxia*, and *cardio-respiratory arrest*.
8. If the cause of death cannot be objectively determined by combining information from the history, autopsy, and ancillary testing, then the cause of death should be listed as *unascertained* or *undetermined*.
9. You should be ready to modify an originally held opinion based on new facts which emerge during the death investigation, sometimes even in the course of a trial.
10. Give any new facts due consideration and ensure that that the opinion remains objective and unbiased. If previously held conclusions can no longer be substantiated, an amended opinion must be promptly and clearly stated. An amended report or supplementary letter to the coroner or magistrate should be made in these circumstances.
11. Keep in mind that your duty is to be an independent expert witness to the court. This duty does not include purposely advancing opinions that are specifically beneficial to the state or defence.

3. COMMUNICATION WITH THE POLICE, INQUIRER (ISD/MAGISTRATE) AND THE RELATIVES

1. Ensure clear communication of your opinion to the ISD/magistrate, police and relatives and ensure that the opinions are understood.
2. Expressing the opinion in native language (Sinhala/Tamil) is highly recommended. You may organize a case conference with relevant parties to ensure a frank and open discussion.
3. At the conclusion of the gross examination, if the cause of death is apparent, then the practitioner in forensic medicine should report the cause of death to the police and ISD/magistrate.
4. The cause of death provided to the police and ISD/magistrate must be recorded in written form at the conclusion of the gross examination preferably also in Sinhala or Tamil.
5. At the conclusion of the gross examination, if the cause of death is not readily apparent, then the pathologist should give the cause of death as *pending, under investigation*, or other similar language.
6. A preliminary opinion on the cause of death or other critical issues must not be given to the police if ancillary testing have any reasonable chance of significantly altering the preliminary opinion.
7. However, depending on the case, reveal the facts to the investigative authorities. (Eg: presence of a definite natural fatal condition in an alleged criminally suspicious death where investigations are pending only to determine underlying natural aetiology)



Photograph 4: Communication with police, relatives and SOCO officers

4. AUTOPSY GUIDELINES FOR COMMON FORENSIC CASES WITH CRIMINAL SUSPICION

Indications

1. Criteria for application of specific guidelines will be dependent on the case and judgment of the expert in forensic medicine.
2. Attendance to the death scene is desirable, whenever possible, attend the death scene after discussion with the police investigators and/or coroner.
3. Sometimes review of digital photographs or a videographic recording of the scene may be a useful alternative to visiting the scene.
4. The guidelines in this section are the core or basic procedures related to external examination, photography, sample collection, internal examination, and ancillary testing that are applicable to most cases.



Photograph 5:

Digital photographs of the scene visit provided by the Police officers are examined prior to the autopsy

External examination

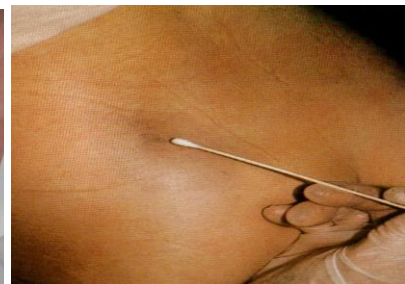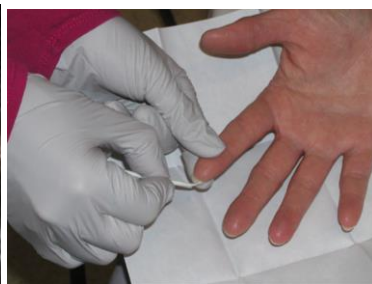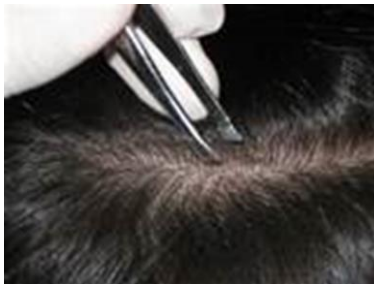A minimum set of photographs should be obtained in all cases. The absence of injuries may be as relevant to the case as the presence of injuries.

1. Face.
2. Conjunctivae.
3. Labial mucosa (inner surface of lips).
4. Neck.
5. Anterior surface of entire body.
6. Posterior surface of entire body.
7. Dorsum of hands.
8. Palms of the hands.
9. Wrists.
10. All external evidence of injury, scars and lesions should be photographed with scale.

Collection of external samples

In many cases, the following external samples are to be obtained: however collection of other samples is at the discretion of the practitioner in forensic medicine.

1. Any trace evidence, including loose hairs and fibres.
2. Pulled hair sample for comparison.
3. Fingernail clippings/scrapings.
4. Fingernail clippings must be obtained with a disposable, brand new nail clipper/ surgical blade and using a new clipper/ surgical blade for each hand. The nail clippings and nail clippers should be submitted to the laboratory together.
5. Any visible stains on the body, especially on the genitalia, thighs, face, or perineum.
6. Any visible clumped pubic hair.
7. Consider obtaining swabs and smears from the mouth, vagina and anus.
8. All samples (e.g., trace evidence and swabs) collected at autopsy should be clearly labelled, sealed and transferred into the custody of the police/keep under safe custody until dispatched to the relevant laboratory. Chain of custody should be clearly maintained.
9. Tissues organs, or bones for further pathologic or histologic examination or documentary storage should be kept under the custody of the expert who did the autopsy.



Photograph 6: Pulled hair sample Photograph 7: finger nail scrapings Photograph 8: swabbing of the stains
(photographs curtsy of Google images)

Internal examination

1. An internal examination of the head, neck, chest, abdomen, and pelvis is performed.
2. Special dissections can be performed as indicated in the relevant guideline and at the discretion of the pathologist and documented with representative photographs.

Retention of tissues and histology

1. Retention of tissues and organs is listed in the relevant guideline.
2. Retention of whole organs and specialty consultation is at the discretion of the forensic pathologist, and inform the relevant ISD/magistrate.
3. If injuries are found after examination of a formalin-fixed specimen (e.g., brain), then the images has to be taken to ensure complete photographic record.
4. Routine histologic sections should be obtained from heart, lung, liver and kidney. Additional histology is discussed in the relevant guideline. Furthermore, other sections are taken at the discretion of the practitioner in forensic medicine.

5. Consider histology of injuries (e.g., footwear marks and bite wounds) to determine timing with evidence of healing.

Ancillary testing

1. In all applicable cases relevant toxicologic testing will be performed by the Department of Government Analyst/ any other accredited toxicology lab Collection of the following samples, if present, is required:
 - a. Blood from the heart.
 - b. Blood from femoral blood vessels.
 - c. Stomach contents.
 - d. Urine.
 - e. Sample of liver.
 - f. In cases with hospitalization, blood drawn at admission (and prior to transfusion) may be the best sample for toxicologic testing.
2. Vitreous fluid should be obtained and can be used for biochemical studies.

5. UNDIFFERENTIATED CRIMINALLY SUSPICIOUS DEATH INCLUDING CASES OF SUSPECTED MECHANICAL ASPHYXIA

Points to remember

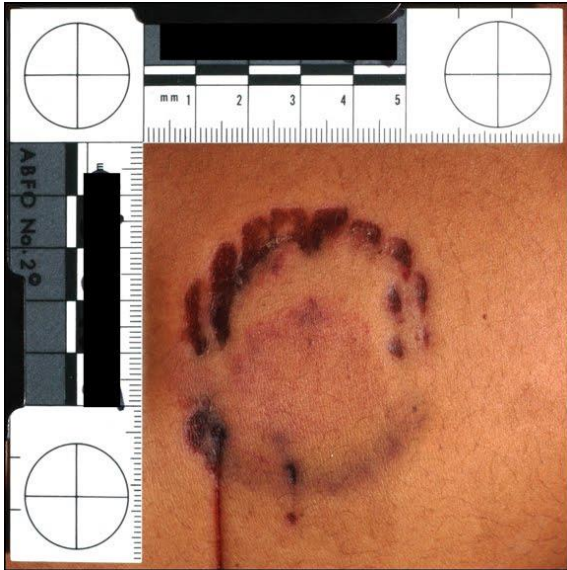- Keep an open mind to the possibilities of a concealed violent death.
- Ensure necessary special dissections
- Ensure collecting trace evidence and biological samples.
- Personally perform the special dissection of the anterior neck.
- Ensure that histology and toxicology are performed

Indications

1. This section describes the guidelines for the autopsy of an individual who dies in violent or criminally suspicious circumstances.
 - No readily apparent cause of death, indicating the possibility of mechanical asphyxiation (e.g. strangulation).
 - The body is in a concealed location, including apparently 'dumped' bodies.
 - The body is in an uncontrolled environment (e.g., found in public places, out of doors environments, naturally occurring bodies of water, unlocked premises).
 - Any other
2. At the end, most of the cases that are initially thought to be criminally suspicious will revealed to be sudden natural deaths, or deaths related to drug/alcohol intoxication.
3. However, it is important to keep an open mind to the possibilities of a concealed violent death.

External examination, photography and sample collection

1. Perform meticulous external examination.
2. Routine basic photographs should be obtained. All external evidence of injury should be photographed with scale. Photographic services may be provided by the SOCO units.
3. A special examination for bite marks should be made. If a suspected bite mark is found, appropriate biological swabs should be obtained. Consultation with a forensic odontologist is required prior to manipulation of the bite mark, or dissection of the body, since special photography is usually required.
4. In all cases, the following external samples are to be obtained:
5. Any trace evidence, including loose hairs and fibres.
6. Pulled scalp and pubic hair.
7. Fingernail clippings.
8. Swabs and smears from the mouth.
9. Swabs and smears from the vagina.
10. Swabs and smears from the surface of the penis.
11. Swabs and smears from the distal rectum.
12. Any visible stains on the body, particularly on the genitalia, thighs, face, or perineum.
13. Any visible clumped pubic hair.



Photograph 9: Bite mark photographed with a scale
(Photograph: <http://willsavive.blogspot.com/2012/05/using-impression-evidence-to-get.html>)

Internal examination

1. Perform internal examination of the head, chest, abdomen, and pelvis.
2. In all cases, perform a forensic dissection of the anterior neck.
3. Special dissection of the posterior neck and torso and other special dissections are performed at the discretion of the expert depending on the case.

Histology and ancillary testing

1. Routine histology should be performed.
2. Toxicology should be performed where applicable.

6. RAPE-HOMICIDE OR DEATH ASSOCIATED WITH SEXUAL VIOLENCE

Points to remember

- Ensure necessary special dissections and collecting trace evidence and biological samples
- Collect all postmortem samples that could be reasonably expected to provide a DNA profile of a alleged assailant.
- Personally perform the special dissection of the anterior neck.
- Remove the pelvic organs *en bloc* and retain the specimen in formalin.
- All injuries must be photographed and confirmed histologically.

Indications

1. This section describes the guidelines for the autopsy of an individual who dies during sexual assault, or when there are suspicions that death might have occurred under these circumstances.
2. Inclusion criteria for application of these guidelines include:
 - a. suspicion of sexual assault at the scene of body recovery.
 - b. The lower body garments including underwear are disturbed, torn, or cut.
 - c. Death of a female or child that may be due to manual or ligature strangulation.
 - d. Most cases with human bite marks.
 - e. Most cases of nude bodies in uncontrolled environments.
3. Rape-homicides are rare, but must be recognized since such cases may not be identified until an autopsy is performed.
4. It is very important to ensure performance of necessary special dissections and collecting biological samples.

External examination

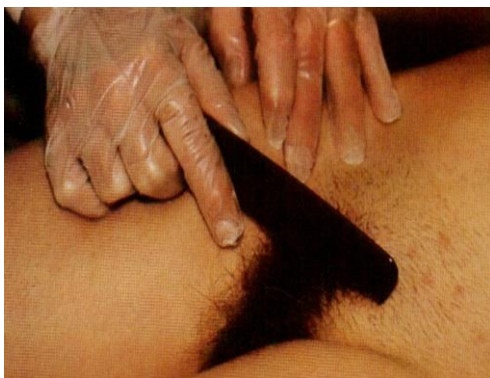1. The body must be examined thoroughly. Any relevant samples or stains must be collected and submitted.
2. Relevant photographs should be obtained. All external evidence of injury should be photographed with scale.
3. A special survey for bite marks should be made. If a suspected bite mark is found, appropriate biological swabs should be obtained.
4. Consultation with a forensic odontologist is required prior to manipulation of the bite mark, or dissection of the body, since special photography is usually required.

Collection of external samples

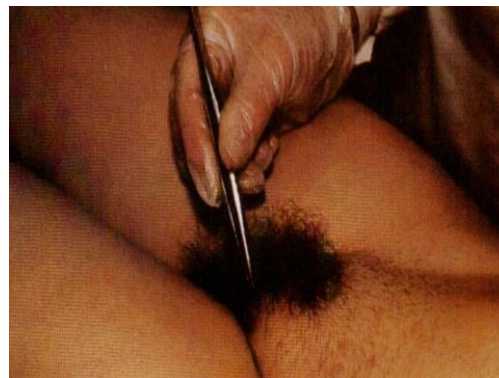In all cases, the following external samples are to be obtained:

1. Any trace evidence, including loose hairs and fibres.
2. Any physical evidence or samples of stains.

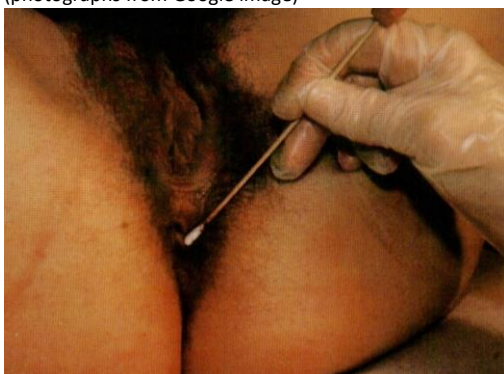3. Pubic hair combings.
4. Pulled scalp and pubic hair.
5. Fingernails clippings.
6. Swabs and smears from the mouth.
7. Swabs and smears from the vagina.
8. Swabs from the external genitalia
9. Swabs and smears from the surface of the penis.
10. Swabs and smears from the distal rectum.
11. Any visible stains on the body, particularly on the genitalia, thighs, face, or perineum (dry and wet).
12. Any visible clumped pubic hair.
13. Any ligature marks should be sampled using the taping method.
14. Any bite marks should be swabbed.



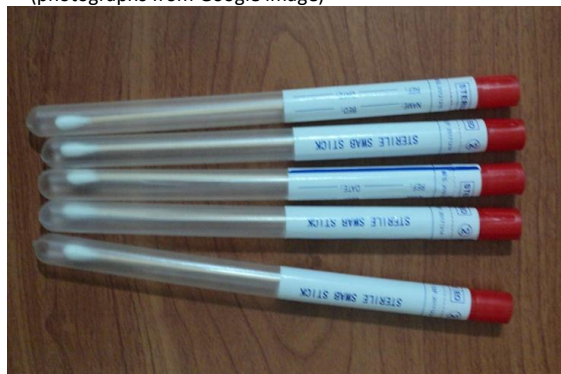Photograph 10: Pubic hair combings
(photographs from Google image)



Photograph 11: Pulled pubic hair
(photographs from Google image)



Photograph 12: External genital swabbing
(photographs from Google image)



Photograph 13: Vaginal swabs

Internal examination

1. An internal examination should include:
 1. Special dissection of the anterior neck and face.
 2. Special dissection of the posterior neck and posterior torso.
 3. Special dissection of the pelvic organs with *en bloc* excision of the external genitalia (female only), perineum (male and female), and anus (male and female) must be performed, if injuries are found or suspected to be present. The specimen can be

provisionally dissected at autopsy, and then immersion fixed in formalin for definitive dissection after fixation.

4. Removal of the testes with dissection of the tunica vaginalis and testicular parenchyma.
 5. Consider dissection of the extremities (e.g., wrist and ankle ligature marks).
2. A minimum set of internal photographs should be obtained in all cases, document significant negatives and all positives.
 1. Layers of the anterior neck.
 2. Layers of the posterior neck.
 3. Layers of the posterior torso.
 4. Vaginal canal and cervix.
 5. Rectum.
 6. Testes and tunica vaginalis.
 7. All internal injuries.
 3. If key injuries are found after examination of the formalin-fixed genital pelvic specimen, then the investigative police should be informed. Ensure that the photographic record is complete on fixed specimens.

Retention of tissues, histology, and toxicology

1. The hyoid bone and larynx should be retained in formalin. If the hyoid larynx complex is fractured, then radiographs should be obtained.
2. Routine histologic sections of major organs and tissues should be prepared. Additional considerations include:
 1. Skin, subcutaneous fat, and skeletal muscle: Documentation of injuries as considered appropriate.
 2. Pelvic organs: If injuries are present, the injuries should be studied using representative sections.
 3. Anus: If anorectal injuries are present, then the anorectal junction should be submitted *en toto* as a 'cone biopsy', as is performed for the cervix in surgical pathology. It is essential that histologic sampling be used to confirm the presence of grossly apparent anogenital injuries. All histologic sections should be 'trimmed in' after formalin-fixation of the pelvic specimen to avoid microscopic artefacts.
 4. Any additional microscopic sections considered appropriate depending on the case.
 5. In all cases, vitreous fluid should be obtained and routine toxicology should be performed.

7. DEATH DURING RESTRAINT

Points to remember

- Carefully examining the body collect trace evidence.
- Perform special dissections of the anterior neck/face, posterior neck, torso (anterior and posterior), testes, and the extremities.
- Personally perform the special dissection of the anterior neck.
- Retain and radiograph the hyoid bone, even if not apparently fractured.
- Ensure the entire gastrointestinal tract has been opened.
- Ensure that histology, toxicology, and relevant ancillary testing are performed.

Indications

1. The section describes the guidelines for the autopsy of an individual who dies suddenly during restrain or physical struggle with law enforcement officers or medical or psychiatric therapy. Such individuals may appear to be agitated, aggressive, or have features indicative of excited delirium.
2. Inclusion criteria for application of these guidelines includes cases where death follows the use of:
 - Pepper spray.
 - A taser.
 - Hand-or ankle cuffing.
 - Hogtying.
 - Neck holds (e.g., carotid sleeper hold).
 - Prone-positioning.

External examination

1. The body is examined thoroughly, prior to autopsy. Any relevant items of physical exhibits, or stains must be collected.
2. Routine photographs should be obtained
3. Lesions that may be related to taser use (electrothermal lesions, or penetrating injuries from electrode deployment) should be photographed, described, measured (including the clearance between the lesions), and studied histologically.
4. If patterned injuries are present (e.g., tram-line contusions), appropriate photographs using a scale are essential.

Collection of external samples

1. In all cases, the following external samples are to be obtained:
 - a. Any trace evidence.
 - b. Pulled scalp hair.
 - c. Fingernail clippings.

- d. If there is reason to believe that pepper spray was used, swabs of periorbital skin should be collected.

Internal examination

1. An internal examination of the head, neck, chest, abdomen, and pelvis is performed and following special dissections should also be performed:
 1. Special dissection of the anterior neck and face.
 2. Special dissection of the anterior torso.
 3. Special dissection of the posterior neck and posterior torso.
 4. Removal of the testes with dissection of the tunica vaginalis and testicular parenchyma.
 5. Dissection of the extremities as at the discretion of the practitioner in forensic medicine.

2. A minimum set of photographs should be obtained in all cases, since the absence of injuries may be as relevant to the case as the presence in injuries.
 1. Layers of the anterior neck.
 2. Layers of the posterior neck.
 3. Layers of the anterior torso.
 4. Layers of the posterior torso.
 5. Testes and tunica vaginalis.
 6. All internal injuries.
 7. The entire gastrointestinal tract must be opened to determine if foreign objects are present.

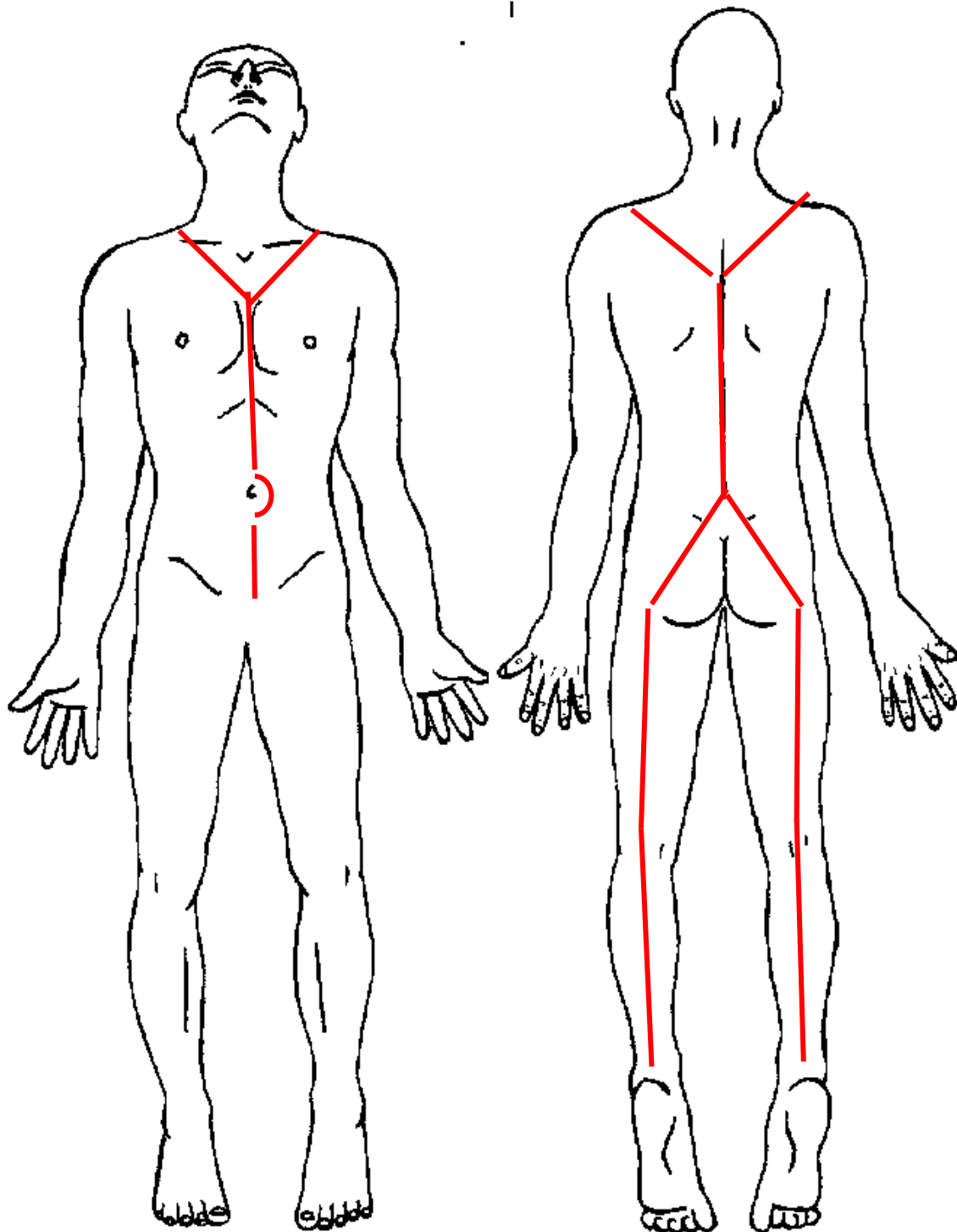
Retention of tissues and histology

1. The hyoid bone and larynx must be retained in formalin. The hyoid larynx complex should be radiographed, even if no visible fractures.
2. Routine histologic sections should be obtained and additional sections should be submitted as follows:
 - Skin and subcutaneous fat: Documentation of injuries as deemed appropriate
 - If significant fractures or injury to subcutaneous fat is found at autopsy, consider histologic studies for fat embolism.
 - Any additional histologic sections deemed appropriate

Ancillary testing

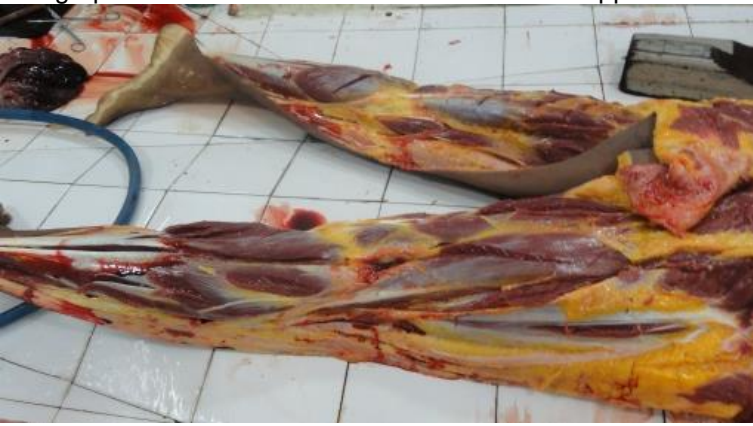1. In all appropriate cases, a post-mortem blood samples should be collected and submitted for hemoglobin electrophoresis.
2. Vitreous fluid should be obtained and can be submitted for biochemical analysis.
3. Comprehensive toxicologic testing should be performed in all cases.

Diagram 1: Muscular –skeletal dissection





Photograph 14 A: Muscular skeletal dissection the appearance of the back



Photograph 14 B: Muscular skeletal dissection legs



Photograph 14 C & D Muscular skeletal dissection back & legs with muscle cuts

8. BLUNT TRAUMA OF HEAD OR BODY

Points to remember

- Ensure patterned injuries, and other injuries are appropriately documented.
- Consider appropriate additional dissections to define internal blunt injuries, if appropriate.

Indications

1. This section describes the guidelines for the autopsy of an individual who dies under criminally suspicious or homicidal circumstances with initial evidence of blunt impact of the head, or body.
2. Inclusion criteria for application of the guidelines includes (but is it not limited to) the following types of cases:
 1. Blunt impact head trauma.
 2. Homicidal beating, including punching, kicking and stomping.
 3. Bodies with unexplained widespread acute bruising.
 4. Custodial death with injuries that might relate to baton impacts.
 5. Selected cases of vehicular impact, or an alleged fatal descent from height.
3. Many cases of criminally suspicious or homicidal death in this category will overlap with other categories in this document.

External examination and collection of samples

1. Through external examination and collection of samples.
2. Routine photographs should be obtained. All external evidence of injury should be photographed with scale.
3. If patterned injuries are present (e.g., tram-line contusion, footwear impressions) appropriate photographs using a scale are essential.
4. If 'bumper fractures' are present, then the precise measurements should be obtained from the level of the heel.

Internal examination

1. An internal examination of the head, neck, chest, abdomen, and pelvis is performed. In cases where the blunt injuries are widespread (i.e., not concentrated on the head), the forensic pathologist performs the following special dissections:
 - Special dissection of the anterior neck and face.
 - Special dissection of the anterior torso. (i.e., such as in stomping and kicking injuries).
 - Special dissection of the posterior neck and torso.

2. Dissection of the extremities and testes may provide additional evidence of injury (or exclude injury). Dissection of the legs to reveal bumper fractures, if vehicular collision is suspected.
3. In the case of blunt impact head trauma with injuries that could have been caused by the application of a specific instrument(s), then the following should be considered:
 - a. Additional scale photographs of the scalp injuries.
 - b. Removal of the pericranial membrane to allow precise photography of the fracture pattern (e.g., pond fractures, and intersecting fracture lines).
 - c. Depressed fractures should be carefully photographed and measured, particularly if the pattern is characteristically geometric in appearance. Consider *en bloc* excision of depressed fractures or moulding-casting of the depressed fractures.
 - d. Reconstruct extensively fragmented skulls. This may facilitate determining the number of individual impact sites, if there are overlapping injuries, and a detailed assessment of basal skull fracture patterns
4. May retain the brain for examination after fixation.

Retention of tissues and histology

1. Representative samples of major organs and tissues should be collected and retained in formalin.
2. May retain the hyoid bone and larynx in formalin. The hyoid-larynx complex should be radiographed, if fractured.
3. Routine histologic sections should be obtained. Other sections can be obtained as follows:
 - Brain (in head injury): Representative sections of the brain and its covering and focal injuries.
 - Skin, subcutaneous fat, and skeletal muscle: Documentation of injuries as deemed appropriate
 - If significant fractures or injury to subcutaneous fat is found at autopsy, then consider histologic studies for fat embolism.

Ancillary testing

1. In all cases of apparently fatal soft tissue injury and the appropriate circumstances, the pathologist should consider collecting and submitting post-mortem blood for hemoglobin electrophoresis.
2. Routine toxicologic testing in all cases. Blood from sequestered hematomas should also be collected (e.g., subdural hematoma,).

9. PENETRATING OR PERFORATING TRAUMA FROM PROJECTILES OR SHARP INSTRUMENT(S)

Points to remember

- Ensure radiographic examination of the body for projectiles or tips of sharp instruments.
- Accurately determine the nature of all individual penetrating and perforating wounds.
- Collect all projectiles or other foreign bodies that may have evidentiary value

Indications

1. This section describes the guidelines for the autopsy of an individual who dies after inflicted penetrating or perforating injury from a projectile (firearm) or a sharp instrument.
 - Firearm injuries
 - Penetrative/perforating injuries from shrapnel
 - Stab wounds, cutting wounds, or stab/incised wounds.

External examination and photography

1. Ideally the body should be radiographed prior to autopsy.
2. The clothing should be examined for defects and bloodstains that correlate with the injuries.
3. Careful external examination prior to autopsy. Any relevant samples or stains must be collected.
4. All external evidence of injury should be photographed with scale. It is particularly important to photograph the external wounds of all penetrating and perforating injuries using both regional photographs to demonstrate the anatomical location of the wounds, and with close-up photography to show the wound features. Photographs can be taken with and without a scale.
5. The corners of some stab wounds are often shown best after approximating the edges
6. Describe all penetrating and perforating wounds, or if impractical due to the multiplicity of wounds, specified groups of wounds. These procedures apply to gunshot wounds, shotgun wounds, and stab wounds:
 - Record the anatomical location of the wound using layman's terms (e.g., forehead), or relative to key landmarks (i.e., tip of the nose, nipple).
 - Measure the location of the wound using co-ordinates in a plane with reference points like the top of the head and midline plane. (horizontal and vertical)
 - Measure the size of the wound on the skin.

- For gunshot wounds, determine if the wound is an entrance or exit wound and whether there is evidence of contact or close-range firing, or stippling (measure diameter of stippled area, if present). Note intermediate target effects.
- For shotgun wounds, determine if the wound is an entrance or exit wound and whether there is scalloping of the margin, or other indicators of increasing range of discharge. Note if a wadding injury is present.
- Measure the diameter of distant shotgun wounds of entrance, and specify the number of individual perforations if the ammunition is buckshot.
- For stab wounds, determine the nature of the corners (sharp or blunt) and edges (smooth or with tags) of the wounds and if hilt marks are present.
- Document the size and the direction of the abrasion collar

Collection of external samples

1. Gunshot residue sampling can be performed from the hands, if applicable. The police will perform the sampling.
2. Consider sampling bloodstains on the surface of the body, particularly in cases of sharp force injury.

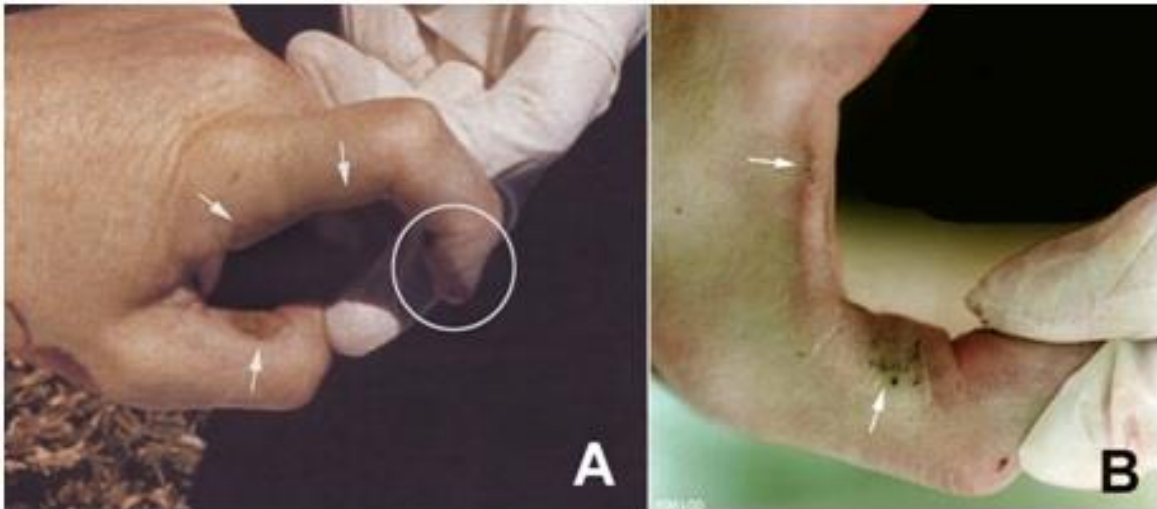
Internal examination

An internal examination of the head, neck, chest, abdomen, and pelvis is performed. Dissection and examination of the internal wound paths should include:

1. Assessment of the direction of the wound path in three dimensions (e.g., front to back, right to left, and upward).
2. Internal injuries are documented and volumes of blood in body cavities are measured.
3. All projectiles should be recovered if they are relatively intact. In the case of birdshot, a representative sample is obtained. If a bullet has fragmented then the lead core, main fragment, and/or a portion of a jacket can be sampled.
4. In the case of shotgun wounds all wadding should be recovered.
5. Beveling and 'keyholes' should be recorded on the wounds of the skull or flat bones.
6. In the case of stab wounds, the depth should be measured, if possible. The depth should not be estimated since the estimate may be inaccurate.
7. In the case of stab wounds, the tip of the sharp instrument may be found embedded in bone. Such tips should be collected and retained.

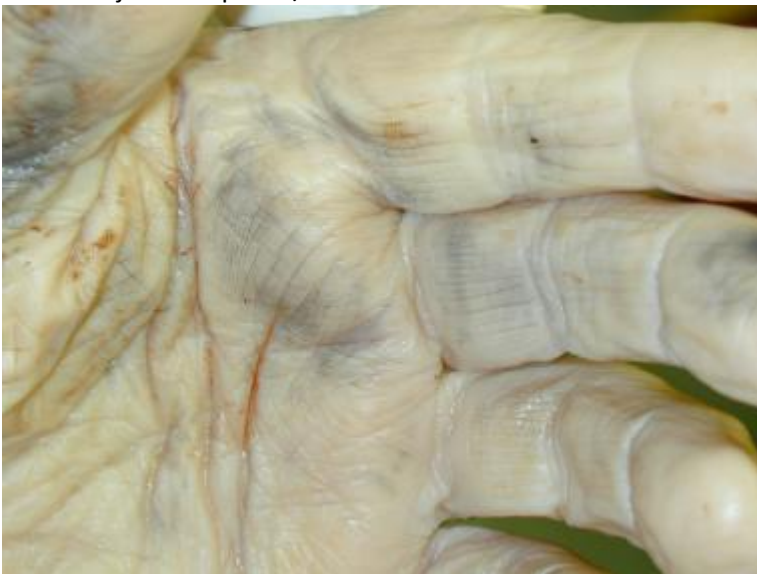Retention of tissues, histology, and ancillary testing

1. Representative samples of major organs and tissues should be collected and retained in formalin. Routine histology and toxicology should be performed.
2. If organs were removed during emergent surgery it may be of help to examine the organs if available.

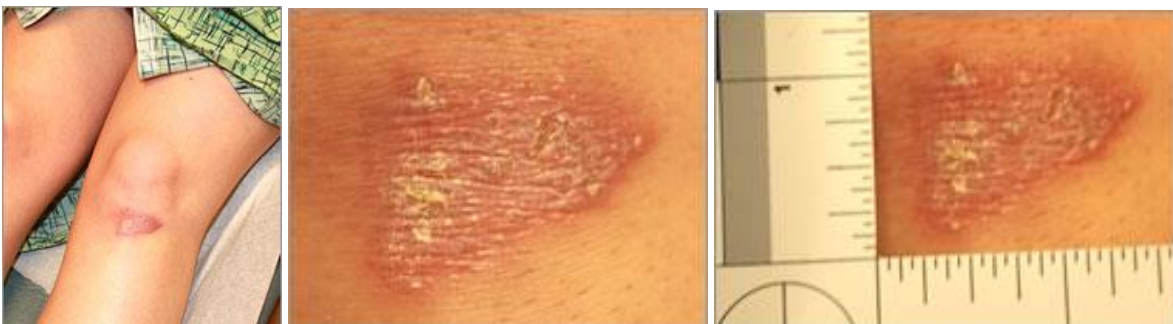

Photograph 15 : Gunshot residues in the finger

Photograph: <http://www.veteranstoday.com/2011/12/11/marine%E2%80%99s-murder-ignored-by-scientific-journals-part-ii/>



Photograph 16: Soot on palmer surface of the hand (curtsy of Google image)



Photograph 17A,B,C : Recommended shots in photographing an injury, A: identify the anatomical site, B: Close up of the injury, C: close up with a ruler (Photographs curtsy of Google image)

10. HOMICIDAL OR CRIMINALLY SUSPICIOUS DEATH IN INFANCY OR CHILDHOOD

Points to remember

- Keep an open mind to death by child abuse and diseases or conditions that may mimic child abuse.
- Collect all relevant post-mortem samples including retention of tissues and whole organs for examination after fixation (e.g., brain, spinal cord and eyes).
- Ensure that post-mortem radiographs, histology, toxicology and other relevant tests are performed.
- Emphasize balanced, reasonable and evidence-based expert opinions balancing the role of the physician involving in child welfare promotion and considering our special duty to provide unbiased evidence to the criminal justice system as expert witnesses.

Indications

1. This document describes the guidelines for the autopsy of an infant or young child that dies under criminally suspicious circumstances, or by apparent homicidal means.
2. Inclusion criteria for application of these guidelines include:
 - Known history of child abuse.
 - Unusual/suspicious appearance of the death scene.
 - History of an unusual fall or 'accident'.
 - Poor hygiene, lice infestations, or other evidence of neglect.
 - Cachexia or dehydration of unclear nature.
 - Bruising or other injuries of unclear nature.
 - Thermal burns or scalds of unclear nature.
 - Prior sudden and unexplained sudden infant death in a sibling.
 - History of recurrent life-threatening episodes (ALTE').
3. In general, must keep an open mind to the possibilities of occult violent death, child abuse, sexual assault, maltreatment and neglect. Therefore, ensure necessary special dissections and collection of biological samples.
4. Consider the special challenges of pediatric forensic pathology some of which include:
 - The pathology of the different forms of acute and chronic physical child abuse.
 - The pathology of neglect and starvation.
 - The evolving nature of forensic pathology of infantile head injury including the so-called 'shaken baby syndrome'.
 - The pitfalls of the autopsy diagnosis of mechanical asphyxia in infants and small children (i.e., the problems with under- and over-diagnosis).
 - Issues related to the medico-legal interpretation of multiple fractures.
 - Post-mortem and autopsy artefacts that can be over-interpreted as injuries (e.g., post-mortem anal dilation).

- The place and limitations of histology for dating injuries.
- Diseases and conditions that can mimic child abuse.
- Carefully balance the role of the physician as patient or child welfare *promoter* while considering our special duty to provide unbiased evidence to the criminal justice system as *expert witnesses*.

External examination

1. A standardized radiographic skeletal survey should be performed prior to autopsy. When practical, the skeletal survey should be assessed by a radiologist and reported to the pathologist before dissection commences and, in all cases, whenever practical, the. Bones showing radiological abnormalities should be excised for specimen radiography and histologic analysis after de-calcification.
2. An external examination is performed according to the standard practice of forensic pathology and samples are obtained. Appropriate body measurements should be obtained.
3. Relevant photographs should be obtained. May elect to obtained additional photographs not obtained by the police, but the existence of these photographs should be disclosed in the autopsy report. The minimum set of photographs should include:
 - Overview – anterior and posterior surfaces of entire body;
 - Face – overview of anterior, right and left sides; close-up views of ears; nose and philtrum; ocular conjunctivae; lips; and inner labial mucosa / frenula.
 - Neck – anterior, posterior, and sides.
 - Hands – dorsal and palmar aspects.
 - Wrists – ventral, dorsal, and lateral aspects. Feet.
 - External genitalia / perineum – including anus; buttocks; and medial thighs.
 - All external evidence of injury including patterned injuries should be photographed with an appropriately positioned scale.
 - A special survey for bite marks should be made. If a suspected bite mark is found, appropriate biological swabs should be obtained including a control swab. Consultation with a forensic odontologist prior to manipulation of the bite mark, or dissection of the body is required.

Collection of external samples

The following external samples are to be obtained as indicated:

1. Any trace evidence, including loose hairs and fibres.
2. Swabs of any stains/secretions particularly about the genitalia, thighs, face, or perineum as noted by the naked eye examination.
3. Pulled scalp hair.
4. Cutting or scrapings of the fingernails.
5. Swabs and smears from the mouth.
6. Swabs and smears from the vagina or surface of the penis.
7. Swabs and smears from the anus.

Internal examination

1. An internal examination of the head, neck, chest, abdomen, and pelvis is performed. In many cases, the following special dissections are indicated:
2. Layered dissection of the anterior torso.
3. Forensic dissection of the anterior neck and face.
4. Forensic dissection of the posterior neck.
5. Forensic dissection of the posterior torso.
6. Forensic dissection of the extremities.
7. If sexual assault is suspected, then special dissection of the pelvic organs with *en bloc* excision of the external genitalia (female only), perineum (male and female), and anus (male and female). The specimen can be provisionally dissected at autopsy, and then immersion fixed in formalin for definitive dissection after fixation.
8. A minimum set of photographs should be obtained to document the presence or absence of injuries:
 - a. Layers of the anterior torso.
 - b. Layers of the anterior neck.
 - c. Layers of the posterior neck.
 - d. Layers of the posterior torso.
 - e. Viscera and brain *in situ*.
 - f. All internal injuries, including *ex situ* prosections.
9. Other special dissections may be performed depending on the case and at the discretion of the expert. These may include:
 - a. *En bloc* excision and fixation of a liver-pancreas-duodenal specimen to examine the juxta-hepatic venous system, hepatic portion of the inferior vena cava, or a duodenal-pancreatic laceration.
 - b. Fractured ribs are excised along with adjacent and/or contralateral non-fractured ribs are excised for specimen radiography and histological examination. Sometime larger sampling may be appropriate including retention of the entire ribcage.
 - c. *En bloc* excision of epiphyses-metaphyses in cases with radiological evidence of a metaphyseal lesion. Contra-lateral long bone segments are also to be excised for comparison purposes.
 - d. The brain and spinal cord should be retained for examination after fixation. The brain can be removed with the upper cervical spinal cord in continuity using the posterior approach.
 - e. If there is evidence of head injury (or at the discretion of the expert), the eyes with retro-bulbar optic nerves and extra-ocular muscles and fat removed and retained for examination after fixation.

Retention of tissues and histology

1. The brain and spinal cord (+ eyes) are retained for examination after formalin fixation.
2. The hyoid bone and larynx are retained in formalin in those cases where there is suspected neck compression.

3. Retention of any other organs and / or specialty consultations is at the discretion of the expert after informing the coroner or magistrate.
4. Histological sections should be submitted as follows:
 - a. Heart: at least 5 sections.
 - b. Lung: at least one section from each lobe.
 - c. At least one each of liver, kidney, spleen, adrenal gland, thyroid gland, pituitary gland, gastrointestinal tract, stomach, pancreas, lymph nodes.
 - d. Brain: to include at least sections of cerebral cortex; basal ganglia; hippocampus; midbrain/pons; cerebellum; deep cerebral white matter; and spinal cord.
 - e. Pelvic organs: If injuries are present, the injuries should be studied using representative sections.
 - f. Anus: If ano-rectal injuries are present, then the ano-rectal junction should be submitted *en toto* as a 'cone biopsy', as is performed for the cervix in surgical pathology.
 - g. Eyes and optic nerves (if retained).
 - h. Bone and bone marrow, including any fractures, recent or old.
 - i. Skin, subcutaneous fat, and skeletal muscle: Documentation of injuries as deemed appropriate.
 - j. Any other histological sections as deemed appropriate.
5. If significant fractures or injury to subcutaneous fat is found at autopsy, the pathologist should consider histologic studies for fat embolism.

Ancillary testing

1. Comprehensive post-mortem toxicological testing will be performed.
2. Bacteriological cultures of blood and tissue can be performed at the discretion of the pathologist.
3. The need for biochemical analysis (electrolytes, urea, creatinine, ketones, and glucose) of the vitreous fluid must be weighed against the value of retention and fixation of the eyes.
4. Consider obtaining blood for genetic studies

11. TRAUMATIC SUBARACHNOID HEMORRHAGE

Points to remember

- Ensure that the intracranial and extra cranial vertebral arteries and samples of systemic arteries are removed for histologic examination in all cases of traumatic subarachnoid hemorrhage.
- Retain and fix the brain and spinal cord for post-fixation examination.

Indications

1. This section describes the guidelines for the autopsy of an individual who dies suddenly with traumatic or unexplained (but likely traumatic) subarachnoid hemorrhage.
2. Additional inclusion criteria, or situations that are applicable to these guidelines include cases of subarachnoid hemorrhage or brainstem/cerebellar infarction, with:
 1. History of head/neck trauma, including assault.
 2. History of spinal manipulative therapy.
 3. Use of stimulant drugs or compounds.
 4. Suspected or known connective tissue disorders or arteriopathy.
3. Rarely, sudden death occurs after a single impact to the face, head, or neck and no grossly apparent lethal lesion is found at routine autopsy. In these cases, should implement the guidelines in this section, even if acute subarachnoid hemorrhage is not found at autopsy.
4. In cases of subarachnoid hemorrhage or brainstem/cerebellar infarction after assault, the procedures found in the 'blunt trauma to head or body' section are applicable, in addition to those specified in this section.

Internal examination

1. Special dissection of the posterior neck is performed.
2. Removal of the vertebral arteries is performed.

The two most common methods

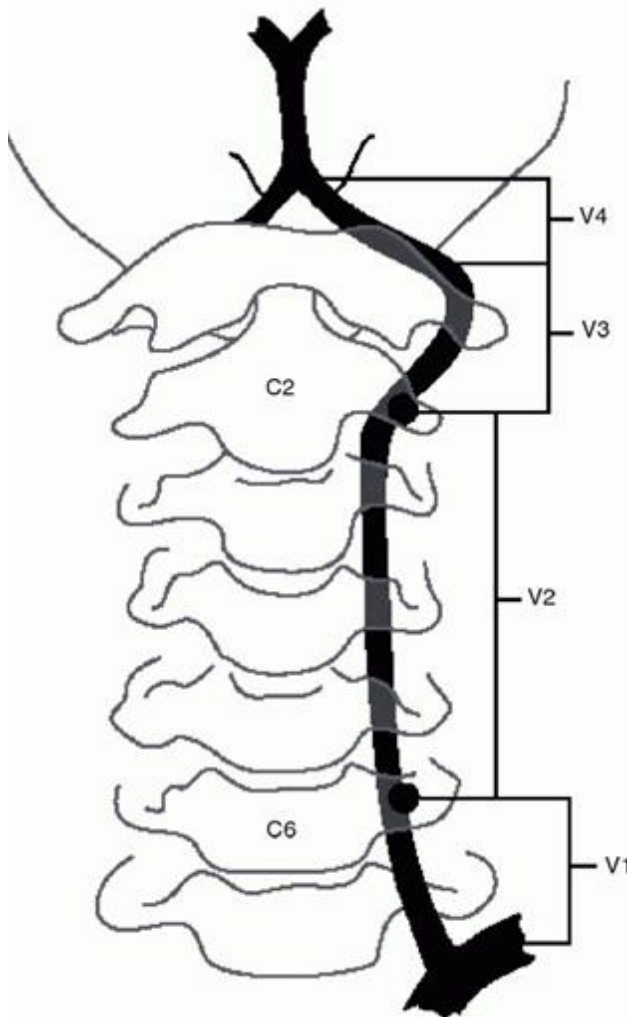
- a. En bloc excision of the base of skull and cervical spine
- b. Segmental excision of the vertebral arteries.

(However, it is recommended that the vertebral arteries be removed segmentally ('piecemeal'), rather than excising the entire cervical spine and base of the skull en bloc for decalcification)

The segments to be excised include:

1. Distal intracranial (present at the base of the brain, after brain removal);
2. Proximal intracranial (need to be excised from the foramen magnum once brain is removed); V4.

3. Transitional or distal extracranial segment after the artery emerges from the cervical spine (the roof of the transverse foramen of the atlas should be excised with the Stryker saw to remove this segment); V3
4. The intraosseous extracranial segment (the roof of the transverse foramen of the C2-C5/6 should be excised with the Stryker saw to remove this segment); V2
5. The point of origin of the extracranial segment at the subclavian arteries. V1



3. Consider removal of the spinal cord using the posterior approach.
4. A minimum set of photographs should be obtained in all cases, since the absence of injuries maybe as relevant to the case as the presence in injuries.
 1. Layers of the posterior neck.
 2. Layers of the posterior torso.
 3. Brain (vertex and base).
 4. All internal injuries.
 5. Other special dissections at the discretion of the forensic pathologist.

6. If the subarachnoid hemorrhage is not concentrated in the posterior fossa, removal of the cavernous and clinoidal segment of the internal carotid arteries is recommended (i.e., a lesion may be found in these locations).

Retention of tissues and histology

1. Representative samples of major organs and tissues should be collected and retained in formalin.
2. The whole brain and spinal cord should be retained and fixed in formalin for post-fixation examination.
3. Routine histologic sections should be obtained and include the following:
 - Brain: Representative sampling; May submit additional sections from the brain, especially the brainstem.
 - Skin, subcutaneous fat, and skeletal muscle: Documentation of injuries as deemed appropriate.
 - Arteries: Appropriate sections of multiple arteries (e.g., extra and intracranial vertebrals; carotids; superior mesenteric; renal; common iliac; aorta; and other arteries as deemed necessary).

Ancillary testing

1. A sterile skin biopsy can be obtained for fibroblast culture, if appropriate or practical. The sample should be collected from the primary incision.
2. The fibroblast culture will allow for analysis of collagen type III (i.e. Ehlers-Danlos type IV), and other assays (e.g., Marfan's syndrome).
3. Routine toxicology is performed.