

See discussions, stats, and author profiles for this publication at: <https://www.researchgate.net/publication/280829776>

Methodology of Iris Image Analysis for Clinical Diagnosis

Conference Paper · November 2014

DOI: 10.1109/MedCom.2014.7006010

CITATIONS

9

READS

4,202

2 authors:



Sandeep Panwar Jogi

JSS Academy of Technical Education

2 PUBLICATIONS 9 CITATIONS

SEE PROFILE



Bharat Bhushan Sharma

JSS Academy of Technical Education

52 PUBLICATIONS 181 CITATIONS

SEE PROFILE

Some of the authors of this publication are also working on these related projects:



Industrial Applications [View project](#)



Acoustics [View project](#)

Methodology of Iris Image Analysis for Clinical Diagnosis

Sandeep Panwar Jogi
 Deptt. of Instrumentation & Control Engg.
 JSSATE, Noida
 Uttar Pradesh, India
 nathsandeep1983@gmail.com

Bharat Bhushan Sharma
 Deptt. of Electrical Engg.
 Jamia Millia Islamia
 New Delhi, India
 mbbs.research@gmail.com

Abstract – Healthcare has been a matter of concern for centuries as far as diagnostic techniques for human development are concern. These techniques have been evolving through the ages and human beings have become selective towards cheaper and convenient ones (convenient according to that period of scientific development). But in this selection process we suppress the rare scientific techniques which are no more popular but still exist in our society. This paper is an attempt to collaborate our ancestral knowledge with modern science to make diagnostic techniques more efficient, rapid and user friendly. The main idea is to combine IRIDOLOGY and Image processing with its scientific reasons to open up a new research field and healthcare diagnostic technique. Implementing this method practically requires special image processing where iris feature extraction plays a crucial role. In this paper we study Iridology, a branch of medical science and develop a methodology to implement synergy on image processing with it. This paper will explain the work of image processing of the iris image, the effects of various parameters of algorithm, different image acquisition system specifications, various environments and different sizes of images.

Keywords: *Iridology, Iris, Integro-differential operator, nerves, optical nerve, neuro-transmitter, ANW, Scaling, Slit lamp, Retinal camera*

1. INTRODUCTION

Iridology is the branch of medical science to study the iris of eyes and associate clinical features with it. The iris of an eye is connected to an immense number of minute nerve filaments which through optic nerves, optic thalami and spinal cord receive impressions from every nerve in the body. The nerve filaments, muscle fibers and minute blood vessels in different areas of the iris reproduce changing conditions in the corresponding organs. Here, we extract the clinical information by means of various marks, signs, abnormal colors or discolorations in the iris. These signs, marks and discolorations make known acute and chronic inflammatory or catarrhal conditions, local lesions, destruction of tissues, various drug poisons and changes in structures and tissues caused by accidental injury or by surgical mutilations. Our approach is to analyze the clinical features in the iris image and extract useful information with the help of iridology and iridology chart. For these analyses, the image of an eye is first captured and the iris is extracted or there is localization of iris. Then, the iris is unwrapped and an

attempt is made to interpret it with different organs of the human body. Later, the changes in different image parameters are analyzed to define clinical information. Correct diagnosis is the first essential to rational treatment. Men of high standing in the medical diagnostic profession have many a time admitted to the uncertainty of medical diagnosis. In a study by Dr. Cabot of Harvard University, he had conducted postmortem examinations of one thousand cases he found that the ante-mortem diagnosis was correct only in fifty-three percent of the cases. Correct prescription, according to allopathic standards, can be based only on correct diagnosis. Since prominent members of the medical profession admit the utter inadequacy of allopathic methods of diagnosis and prognosis. It is required to increase the horizon of diagnostic techniques with scientific means to adopt ancestral or suppressed techniques.

Need For Diagnosis Technique:

- Accuracy
- Rapid diagnostic tool
- Early detection
- Cost effectiveness
- Non-invasive
- System requires less maintenance
- System should be easy to handle
- System should be easy to use

1.1 Feasibility Of Idea

Our approach is to extract the clinical information from iris as Iridologist did once upon a time but with certain changes and use of advent tools. By merging this approach with new techniques of image processing human errors will be suppressed and the requirement for an expert person for diagnosis will no longer be needed. Working on it and conducting a survey of literature available, we found that a handful of doctors are looking forward to this approach as a step ahead in medical diagnosis. It has been seen that there is a correlation between the disease and the change in the iris.

1.2 The Bowels In The Iris

The bowel signs are centered in the first major zone. Look for bowel pockets, defects, radii soleris, prolapse,

and changes of the basic colour and shape of the bowel area. The relationship of the bowel shape to the ANW (Autonomic Nerve Wreath) is very close, as the nervous and digestive systems work intricately together [1]. The bowel is either the key to a healthy body and a clean blood stream, or to toxicity and disease. Cleansing and regeneration of the bowel is an essential requirement for healing. If it is not functioning properly as an eliminative channel, it will be a major contribution to any disease pattern.

1.3 The lymph system in the iris

The lymph system is seen clearly in the lymphatic zone of the iris next to the skin zone in the ciliary edge. This zone shows imbalances in a variety of ways: as a lymphatic rosary, as individual lymphatic topi in organs or other areas and as grey, yellow, orange, brown or black abnormal colors indicating the level of encumbrance and malfunction. Nerve rings which run through the lymph zone indicate that muscular tension is inhibiting the flow of the lymph. The sodium, calcium or hyper-cholesterol ring can cover over the lymph zone with transparent to opaque white coloration. Also, whenever catarrh and mucus collect in the circulatory zone next to the ANW this is an indication of impaired lymphatic function. Check the iris areas for groin, underarm (axilla), neck, breast, adenoids in the nose, tonsils in the neck, appendix in the caecum area, and peyr's patches in the small intestines. The area for the thymus is found in both eyes near the sternum. These are all important parts of the lymphatic system and should be assessed if immunity is weak or the person is suffering from lymphatic disorders. Note the colours of the lymphatic markings, remembering that white indicates an active exudative state, grey means underactive, yellow definitely sluggish, and brownish markings a clearly toxic condition of chronic malfunction.

1.4 Kidneys In The Iris

Kidney iris areas very often show large lesions called medussas and radials. They also appear as white inflammatory, or sub-acute with grey shading. Inherent weakness or kidney lesions need to be carefully assessed and constitutional weaknesses evaluated. Look for lymphatic topi in the kidney area [2]. Congestion of lymph or insufficient blood circulation to the kidneys will cause problems. Also evaluate the condition of both left and right kidneys. Often one is compensating for another, thus overworking while the weak kidney is hypoactive. See whether nerve rings point to the kidneys and note also where they start. Psora spots on the kidneys will indicate diminished function and radii soleris or bowel pockets in the kidney zone will reveal toxic accumulation and negativity. Observe whether the radial in the brain's inherent mental or anxiety zone is also showing a marking. Radials, lacunae, bowel pockets and radii

soleris, which weaken the kidney, may also affect the adrenal glands. If so, treat the adrenal glands as well.

1.5 Lung Signs In The Iris

A variety of iris markings reveal information about the condition of the lungs. Inherent weakness shows up as open or closed lesions combined with colours from white to black. Observe whether a bowel pocket or radii soleris magnifies the condition by sending toxins to the area. Reflexive fibers (whether swollen or pink) reveal increased levels of irritation. Observe the condition of the absorption ring, the shape of the ANW, the lymphatic rosary. Are there nerve rings, psora or dark spots? How wide is the scurf rim in the lung areas? Medulla markings must always be considered because of its function as the respiratory brain. Observe the differences between the left and the right iris. Often the iris bulges out at 3 o'clock on the left iris, 9 o'clock in the right iris, extending a thin grey shadow over the sclera. Dorothy Hall seems confident that this is related to vitamin B3 insufficiency. The decrease of the shadow has been observed during eliminative and systemic purification and regeneration. Over the years lung cancer patients have either displayed black spots in the lung area or no visible sign. It is clear that observation of many cases would be needed to draw general conclusions. Each case should be considered individually.

1.6 The Skin In The Iris

The skin zone is on the ciliary edge of the iris. When it is sluggish, inactive or has collected toxins it shows up in varying shades of grey, brown and black. The darker and thicker the zone is, the more toxic and inactive the skin. When this zone manifests small dark spots, the condition is even more serious. Scurf rims in infants register the degree of inherited toxins. During life they deepen as a result of incorrect dietary and living habits. Childhood diseases are the body's attempt to throw off inherited toxins, and often the scurf rim is left after the illness. Change of climate can make considerable differences to scurf rims.

1.7 The Blood Supply of the Iris

The long and short ciliary blood vessels form a complete ring around the peripheral border of the iris. From this major circle branches are given off which converge toward the pupil shown in Fig.1. At a short distance from the outer border of the sphincter muscle they divide and anastomose to form a second ring. From this minor circle branches continue their course to the pupillary border.

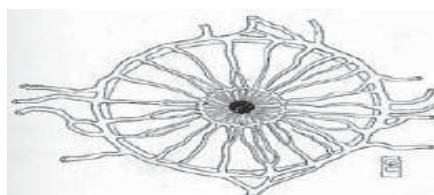


Fig. 1. Blood Supply to Iris.

1.8 The Nerve Supply of the Iris

The nerve supply of the iris deserves special attention shown in Fig.2. The circular muscle fibres are supplied by the short ciliary nerve branch of the motor oculi, or third cranial nerve, coming directly from the brain. The other structures are supplied by the long ciliary nerve, which is in direct communication with the cervical ganglia of the sympathetic nervous system. These nerves travel forward to the iris through the choroid coat of the eyeball. Along the attached margin of the iris they form a plexus from which nerve filaments are given off to the muscle fibres and other structures of the iris. Some of these nerve filaments also go to form a complete network on the surface of the iris immediately underneath the surface endothelium.

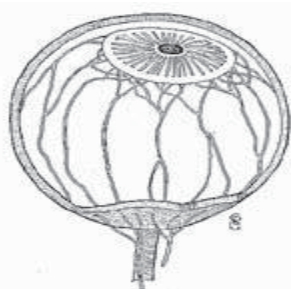


Fig. 2. Eyeball with nerve supply

These are arranged in triangles, the bases of which rest on the outer rim of the iris, and whose apices point toward the pupil. (Fig.3) The sides of these triangles coincide with the blood vessels, these with the sympathetic nerve supply, and these in turn with the borders of the organ areas.




Fig. 3. Triangles Formed by Nerves.

The direct connection of the nerve filaments in the surface layers of the iris with the cervical ganglia of the sympathetic nervous system explains how impressions (vasomotor changes) from all over the body may be conveyed to the iris.

Iridology is as yet a new science, and much remains to be discovered and to be better explained. Many times we do not find a sign in the iris for the lesion or diseased condition which we know to exist in the body. At other times the records in the eyes indicate more serious conditions than can be ascertained by other methods. As regards this point, however, it is well to remember that old school physicians, notwithstanding their up-to-date

scientific equipment, only too often see their diagnosis discredited by the postmortem findings.

Those who confine their examinations to the eye or the spine fall as far short of making a reliable diagnosis or prognosis as the old school country doctor with his limited equipment. In our work we do not confine ourselves to Iridiagnosis, but combine with it the diagnostic methods (physical diagnosis) of the allopathic school of medicine, spinal analysis, basic diagnosis, as well as laboratory tests and microscopic examinations.

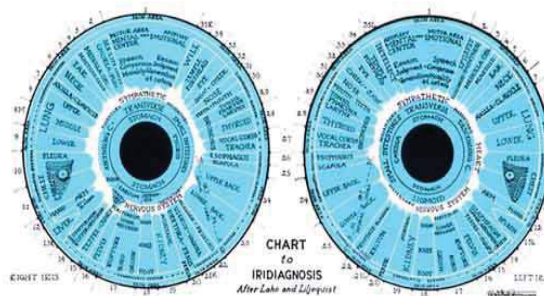


Fig. 4. Iridology Chart

The purpose of interpretation is to select the outstanding, significant markings. The next step is to determine the relationship and the effect that the significant markings have on each other, and at this stage it is important to understand the interaction of physiological processes. Thus each body system is seen in relation to every other system, affecting and being affected by every other system. The living ecological processes of the interior world are in constant movement, change and interaction. If one system is hyperactive it may drain resources from other systems. If it is under active another system may have to work harder to compensate. The permutations are infinite. Every case of TB, or any other disease, is different. This is why treatment based on individual iridology analysis is so successful.

Here, we have attempted to analyze the image of the iris for clinical features using MATLAB for its ease in image manipulation and Integrodifferential operator application. The first step is to acquire an image and then use it for localization by sizing to analyze the effect of sizing. Then we normalize the localized iris and at the same time normalize the iris chart (Fig.4) image for comparison of different parts of the iris.

2. IMPLEMENTATION

2.1 Image Acquisition

To acquire the image, we can use different optical devices such as lens, slit lamp and retinal camera with high speed CCD camera. We set a high resolution of gray and color image, in JPEG and PNG format. Furthermore, we can take the eye pictures using a suitable image acquisition device, maintaining appropriate setting of light and distance to camera. Near infra-red light source is used for minimizing the reflection, as near infra-red

spectrum absorbs by organic compound [11]. In addition, the resolution of the image should be very high (1280 x 1024), because for further processing and feature detection regarding disease marks, it is needed.

2.2 Image Manipulation

In the preprocessing stage, we transformed the images from RGB to gray level and from eight-bit to double precision thus facilitating the manipulation of the images in subsequent steps. At some level, we carry out equalization of the image to enhance the contrast of image. Both color and gray level processing is required for further study and to analyze iris images for clinical diagnosis. Reflection should be restricted to the pupil area to avoid loss in information. In addition, the image enhancement techniques are also used as image equalization, contrasting and threshold for ease in further processing.

2.3 Iris localization

First Wildes [6] et al approach was used to set the threshold and to find the approximate centre of the iris as (x_0, y_0) . Then it was decided to apply the John Daugman approach of integro-differential operator to find the center of the iris (x, y) at the neighbor of the approximate center (x_0, y_0) . Daugman had used an integro-differential operator for locating the circular iris and pupil regions, and also the arcs of the upper and lower eyelids. The integro-differential operator is defined as

$$\max_{(r, x_0, y_0)} \left| G_{\sigma}(r) * \frac{\partial}{\partial r} \int_{r_0}^r \frac{I(x, y)}{2\pi r} ds \right| \quad (1)$$

Where $I(x, y)$ is the eye image, r is the radius to search for, $G_{\sigma}(r)$ is a Gaussian smoothing function, and s is the contour of the circle given by r, x_0, y_0 . The operator searches for the circular path where there is maximum change in pixel values, by varying the radius and centre x and y position of the circular contour [8]. The operator is applied iteratively with the amount of smoothing progressively reduced in order to attain precise localization. Eyelids are localized in a similar manner, with the path of contour integration changed from circular to an arc. Fig. 5 shows the localized iris image.



Fig. 5: Localization of Acquired image

We also carry out the resizing of the image to reduce its size by some factor 'x'(for example) and then attempt to find the center of the iris and the pupil, and then increase the size of the image and the center by resizing it by factor '1/x'. We found less the size of image, more speed

of localization, which enhanced the speed of diagnosis within a fraction of seconds. But as we reduce the speed accuracy of localization is also reduce. So to reduce the size we can go for limited range of reducing, to get the optimize result of localization. In the same way, our attempt is localization of iris from the iridology charts. For comparison and defining the area of different organs in the iris, it is required to normalize both images by the same parameters. This process of algorithm is called as iris normalization technique.

2.4 Iris Normalization

Once the iris region is segmented successfully from an eye image, the next stage is to transform the iris region so that it has fixed dimensions which allow comparisons. The dimensional inconsistencies between eye images are mainly due to the stretching of the iris caused by pupil dilation from varying levels of illumination. Other sources of inconsistency include varying imaging distance, rotation of the camera, head tilt, and rotation of the eye within the eye socket. The normalization process will produce iris regions, which have the same constant dimensions; hence, two photographs of the same iris under different conditions will have characteristic features at the same spatial location.

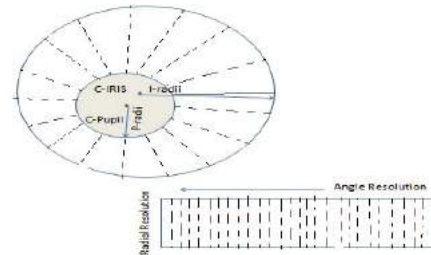


Fig. 6: Iris Normalization

Another point to be noted is that the pupil region is not always concentric within the iris region, and is usually slightly nasal [4]. This must be taken into account if we are trying to normalize the 'doughnut' shaped iris region to have a constant radius. For normalization of iris regions a technique based on Daugman's rubber sheet model was employed [5]. The centre of the pupil was considered as the reference point and radial vectors pass through the iris region, as illustrate in fig.6.

Using equation below, and give the increment to 'r' by radial resolution up to radius of iris, and give increment to 'θ' by $\frac{2\pi}{\text{angular division}}$. It stored the value of each pixel to normalize the iris image.

Where r = Radius of pupil
 θ = Angle

$$X_{pi} = \text{round} (x_{\text{pupil}} + r * \cos(\theta)); \quad (2)$$

$$Y_{pi} = \text{round} (y_{\text{pupil}} - r * \sin(\theta)); \quad (3)$$

For image registration interpolation, technique was applied on each stored column of the normalized iris

image. In the same manner, normalization of the localized iris chart was processed. Normalization of both iris and iris chart is required because the pupil is not concentric with the iris, and so localized iris cannot be directly compared with the localized iris chart.

2.5 Image Registration

The iris clinical diagnosis, image registration is the process for defining the different human organs on the normalized iris according to the iris chart. Both normalized images are superimposed and the area defined by iridology is worked on as reference on the normalized iris image.

3. RESULT AND PERFORMANCE

3.1 Localization

Localization of the iris from the eye image is a most important part of the iris diagnosis system. It takes maximum time among all steps of iris algorithms like localization, normalization and image registration. The time elapsed in localization depends upon the image quality and size. Different databases have different quality of images and different size of images, therefore localization of the iris takes different amount of time. Table 1 shows variation in localization time as size and quality of images change as database changes within in a same database.



Fig. 7: Right eye Iris localized image

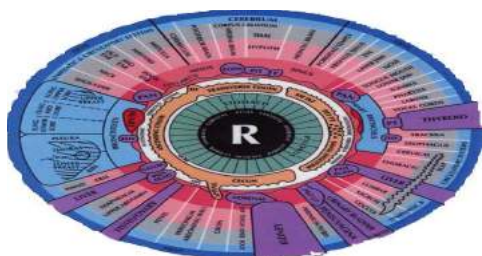


Fig. 8: Right eye Iris chart localized image

In this, the localized image in the above figure (Fig.7 & Fig.8) can be compared to find out the region of human organs in the iris but the problem is that pupil is not concentric as shown in the Iris chart and the second difficulty faced by iridologists is that size of the pupil varies with Image acquisition flash light. The pupil contracts when high intensity of light falls on it to control the incoming light and same way it dilates with low intensity of light to allow incoming light rays up to an appropriate threshold. This mechanism to control incoming light intensity on the optical nerve, varies the

quantity of light. To avoid this varying size, process of normalization has been used.

Table 1
Iris Localization elapsed time of different database and size of image

Name of Database	Scaling of Image	Total elapsed time (in second)	Localization elapsed time (in Second)	Quality of localization
UPOL	1	228 - 168	228 - 167	Very high
	0.25	5.9 - 8.4	4.3 - 5.4	High
	0.1	5.2 - 7.4	3.9 - 6.1	Low
CASIA 320x280	1	7.6 - 9.8	6.3 - 8.2	Very High
	0.2	.9 - 1.5	.8 - 1.1	High
UBIRIS 200x150	1	2-13	1.7-12	Very High
	0.75	1.9 - 5.4	1.4 - 4	High
	0.5	1.2 - 2.6	0.8 - 1.9	Low
Image taken by us 1280 x1024	1	10.7 - 3.3	9.7 - 1.9	Very High
	0.1	2.1 - 3.2	1.4 - 1.6	High

The result of localization of eye images also shown pupil of eye is not concentric with the iris of the eye. Distance between the centre of iris and pupil of each database shown in table 2. It is needed to localize the iris with high accuracy, otherwise it will lose information of periphery.

Table 2
Distance between center of iris and pupil for different database

Name of database	Distance of center of iris and pupil (in pixels)
UPOL	4-80
CASIA	5-26
UBIRIS	1 - 7
Image taken by us	140-170

3.2 Normalization

Normalization of iris image is an important part of the iris disease diagnosis system. For the iris diagnosis system, normalization is a important step for image registration and comparison with iridology chart. Table 3 shows the time elapsed in normalization of iris image.



Fig. 9: Right eye Iris normalized image

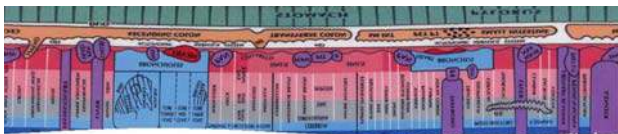


Fig. 10: Right eye Iris chart normalized image

Table 3
Time elapsed in normalization process

Name of Database	Time Elapsed in Normalization (in seconds)
UPOL 576x768	0.10 – 0.14
CASIA 320x280	0.10 - 0.13
UBIRIS 200x150	0.10 - 0.12
Image take by us 1280 x1024	0.12 - 0.17

Fig. 9 is overlapped with Fig.10 for defining the different areas. The size of a normalized image is also an important feature. Therefore, it has been decided to create different sizes of normalized images. For iris recognition system 200x20, 200x40, 240x20, 240x40 pixels size is taken. It is assumed that further, a large normalized image may be required in future to detect minute features.

3.3 Image Registration

After overlapping the normalized iris chart on a normalized iris image, the chart defines the different areas registered for different organs on the iris.

4. CONCLUSION

Iris diagnosis system may not replace convenient diagnosis system, but it can be use as a screening level diagnosis and further help medicos in managing time and resources. Performance of iris diagnosis system depends upon image acquisition system as well as the quality of image, resolution, light, duration required to capture the image, etc. Localization of image is a important step of iris diagnosis system and its accuracy and speed depending upon acquisition system and environment. The time taken by the localization process is more than in other processes. Localization time can be controlled by resizing the image to reduce size in pay of accuracy of localization. Our attempt is to scale this empirical science towards a scientific method which is widely acceptable. It gives iridology a new dimension to grow and flourish.

REFERENCES

[1] Dr. Farida Sharan, School Of Natural Medicine, "Iridology" internet excerpt at www.purehealth.com

[2] Harri Wolf, Simon A, Worthen DM, Mitas JA, "Detecting Kidney Disease - JAMA and Rebuttal," Source JAMA, Vol. 242, No.13, pp.1385-9, 1979.

[3] Knipschild P, "Looking for gall bladder disease in the patient's iris," Source BMJ, Vol. 297, pp.1578-81, 1988.

[4] Daugman G. , " How Iris Recognition Works" IEEE Transaction on Circuits and System for Video Technology , Vol . 14, No. I, pp . 21-30, 2004.

[5] S. Sanderson, J. Erbetta, "Authentication for secure environments based on iris scanning technology," IEE Colloquium on Visual Biometrics, 2000.

[6] R. Wildes, "Iris recognition: an emerging biometric technology," Proceedings of the IEEE, Vol. 85, No. 9, 1997.

[7] D. Field, "Relations between the statistics of natural images and the response properties of cortical cells," Journal of the Optical Society of America, 1987.

[8] Libor Masek, "Recognition of Human Iris Patterns for Biometric Identification," The University of Western Australia, 2003.

[9] <http://www.macula.org/anatomy/>

[10] Chinese academy of Sciences, I.O.A, "CASIA iris Image Database," Available at: <http://www.sinobiometrics.com/resources.htm>.

[11] Zhi Yuan Wang, "Near-infrared absorbing organic materials," Pure Appl. Chem., Vol. 76, Nos. 7{8, pp.1435{1443, 2004.

[12] A. Oppenheim, J. L., "The Importance of phase in signals," proceedings of the IEEE, pp. 529-541, 1981.

[13] Dobes, M. and Machala, L., "UPOL Iris Image Database". 2004. Available at: <http://www.phoenix.inf.upol.cz/iris/>

[14] Ubiris Iris Image Database at: <http://www.iris.di.ubi.pt>