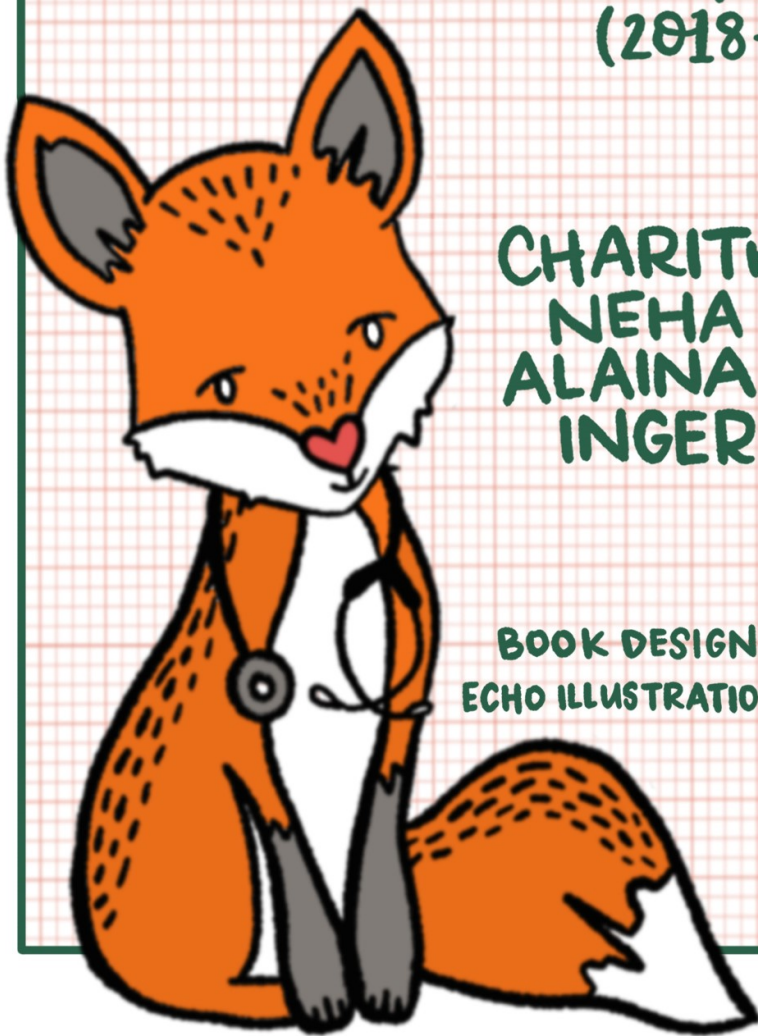


PEDIATRIC
acute care
CARDIOLOGY
handbook
EDITION 2
(2018-2019)



CHARITHA REDDY,
NEHA PURKEY,
ALAINA KIPPS, and
INGER OLSON

BOOK DESIGN *by* TARA THOMAS
ECHO ILLUSTRATIONS *by* MARIELLE EVANS

Pediatric Cardiac Acute Care Handbook

Edition 2 (2018-2019)

Compiled by:

Alaina K. Kipps, MD, MS; Inger Olson, MD; Neha Purkey, MD; Charitha Reddy, MD

I. General Principles of Cardiology

a. Cardiac Anatomy.....	1
b. History and Physical.....	6
c. Cardiac Catheterization.....	10
d. Echocardiography.....	14

II. Common Complaints in Cardiology

a. Murmurs.....	25
b. Chest Pain.....	28
c. Syncope.....	30
d. Preventative Cardiology.....	32

III. EKG Interpretation and Common Arrhythmias

a. EKG Reading.....	34
b. Arrhythmia Algorithm.....	42
c. Common Arrhythmias.....	45

IV. Congenital Heart Disease

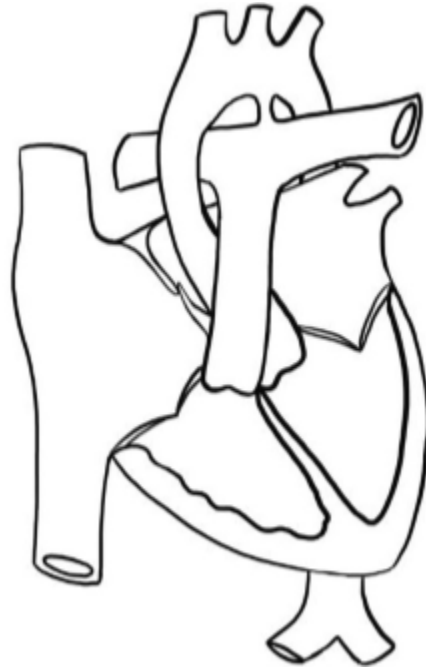
a. Neonatal Presentation of CHD.....	64
--------------------------------------	----

V. Acyanotic Lesions

a. ASD.....	68
b. VSD.....	71
c. AVSD.....	74
d. PDA.....	77
e. Ebstein Anomaly.....	81
f. Bicuspid Aortic Valve.....	84
g. Aortic Stenosis.....	86
h. Pulmonary Stenosis.....	89
i. Coarctation.....	92
j. Interrupted Aortic Arch.....	95

VI. Cyanotic Lesions	
a. DTGA.....	97
b. TOF.....	100
c. TOF/PA/MAPCAs.....	103
d. Truncus.....	107
e. DORV.....	109
f. HLHS.....	112
g. PA/IVS.....	117
h. Tricuspid Atresia.....	119
i. TAPVC.....	122
VII. Surgical Repairs.....	126
VIII. Cardiomyopathies.....	136
IX. Congestive Heart Failure	141
X. Pulmonary Hypertension.....	143
XI. Acquired Heart Disease	148
XII. Common Associations	
a. Genetic Syndromes.....	161
XIII. Appendix.....	173

Cardiac Anatomy: Learning the Language

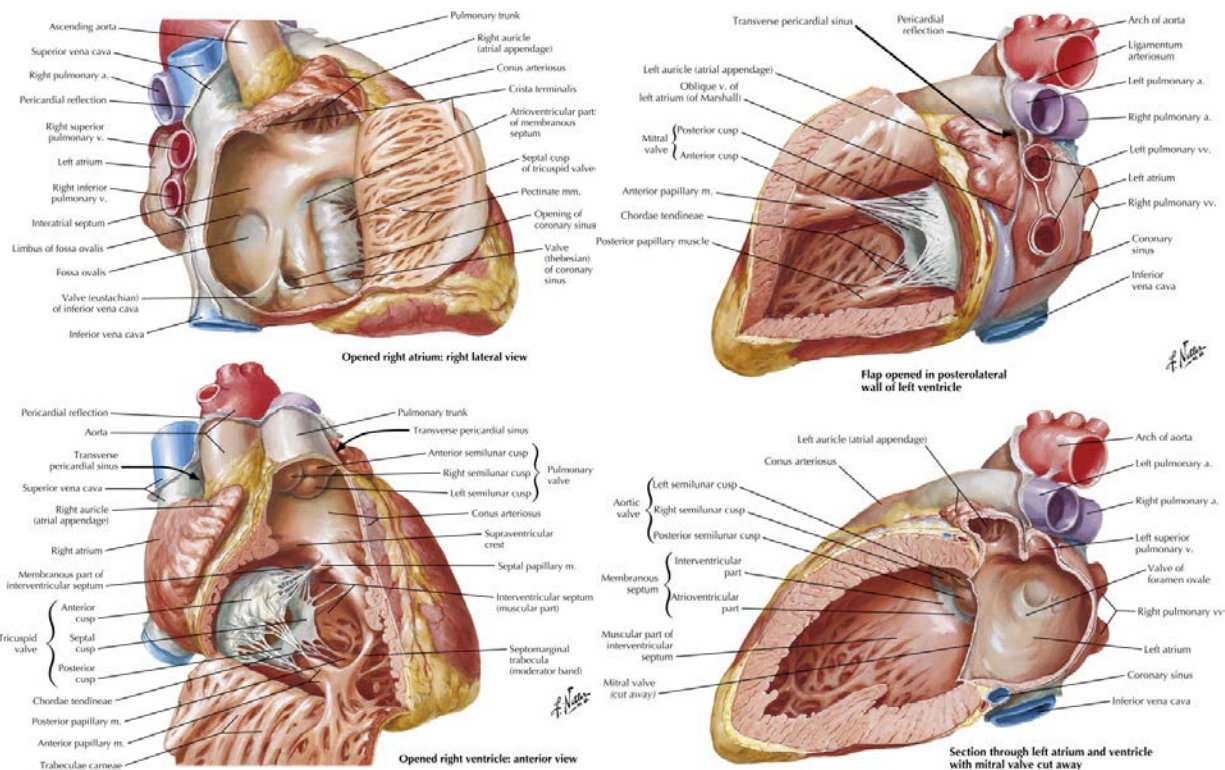


- In congenital heart disease, the heart can be located anywhere in the chest, and the components of the heart can be arranged in a number of different ways.
- “Right” and “left” do not refer to the side of the body, but to specific anatomic criteria that identify different components of the heart.

Cardiac Position

- Levocardia: heart is in the left chest, apex points leftward (normal position)
- Mesocardia: heart in the midline, apex points inferiorly
- Dextro**cardia**: heart in the right chest, apex points rightward
- Dextro**position**: heart in the right chest, with apex pointing leftward
- Dextro**rotation**: heart in the left chest, apex rotated rightward
- Ectopia cordis: heart partially or completely outside of the chest/sternum

The Main Chambers of the Heart



Netter's Correlative Imaging: Cardiothoracic Anatomy

Right Atrium: receives the SVC, IVC and coronary sinus, limbus of fossa ovalis present

- Broad-based, triangular appendage with pectinate muscles that extend into the right atrial body
- Crista terminalis present

Left Atrium: receives the pulmonary veins (but this is not a defining feature)

- Narrow-based, thin, finger-like appendage with pectinate muscles that are confined to the appendage
- Visible attachments of septum primum to septum secundum

Right Ventricle:

- Coarse trabeculae with a prominent septal band, parietal band and moderator band
- **Septophilic** attachments of the tricuspid valve (attaches to the septum and free wall)
- Well-developed infundibulum (or conus) – the muscle underneath the semilunar valve, which results in lack of fibrous continuity between the tricuspid and semilunar valves
- The tricuspid valve always belongs to the right ventricle

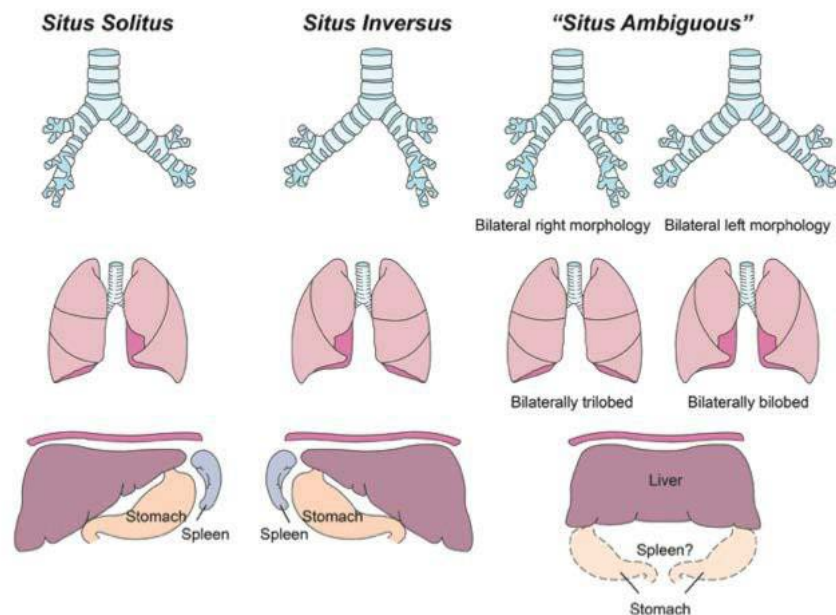
Left Ventricle:

- Smooth septal surface with fine trabeculae
- **Septophobic** attachments of the mitral valve (attaches only to the free wall)
- No infundibulum under the semilunar valve, so there is fibrous continuity between the mitral and semilunar valves

Segmental or “Van Praaghian” Approach to Cardiac Anatomy { __, __, __ }

1st letter { __, X,X } = Visceral and atrial situs

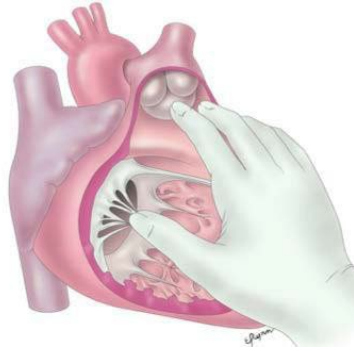
- Position of the abdominal organs (liver, spleen and stomach) and atria
- **Solitus (S)**: normal anatomy with liver on right, spleen and stomach on left, right atrium on right, left atrium on left
- **Inversus (I)**: mirror image of normal: liver on left, spleen and stomach on right, right atrium on left, left atrium on right
- **Ambiguous (A)**: indeterminate situs: midline liver, cannot differentiate between right and left atria, usually associated with heterotaxy or “atrial isomerism”



www.pedscards.com

2nd letter, { X, __, X } : Ventricular Looping

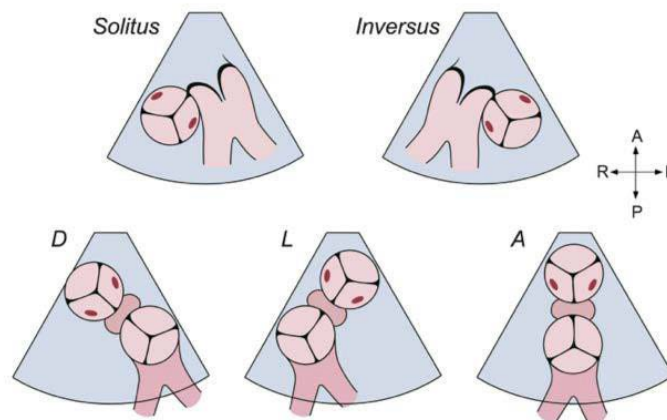
- **D-loop (D)**: normal anatomy with right ventricle to the right of the left ventricle
- **L-loop (L)**: left ventricle to the right of the right ventricle
- The “hand rule” demonstrates the chirality of the ventricles. A D-looped right ventricle is a “right handed” ventricle because only the right hand will fit inside the ventricle so the thumb is in the inflow, fingers are in the outflow, and the palm faces the septum. An L-looped right ventricle is “left handed” because the left hand will fit in the right ventricle.



Right hand fits in the right ventricle = D-loop
www.pedscards.com

3rd letter, {X,X,___}: Great Arteries = the relative position of the semilunar valves to each other

- **Solitus (S):** normal anatomy with aortic valve posterior and to the right of the pulmonary valve
- **Inversus (I):** mirror image with aortic valve posterior and to the left of the pulmonary valve
- **D-malposition (D):** aortic valve is anterior and to the right of the pulmonary valve
- **L-malposition (L):** aortic valve is anterior and to the left of the pulmonary valve
- **Anterior (A):** aortic valve is directly anterior to the pulmonary valve
- **Posterior (P):** aortic valve is directly posterior to the pulmonary valve



www.pedscards.com

If the anatomy of a segment cannot be determined, then an “X” is used for that segment. The connecting segments and ventriculo-arterial connections are described separately.

The Andersonian Approach to Cardiac Anatomy

A different approach to describing cardiac anatomy was championed by Dr. Bob Anderson. If the right atrium connects to the right ventricle, and the left atrium connects to the left ventricle, this is described as **atrioventricular concordance**. If the pulmonary artery arises from the right ventricle and the aorta arises from the left ventricle, this is described as **ventriculoarterial concordance**. If the right atrium

connects to the left ventricle, this is termed **atrioventricular discordance**. If the pulmonary artery arises from the left ventricle, this is termed **ventriculoarterial discordance**.

Questions

- What are the anatomic features of the tricuspid and mitral valves?
- What are the anatomic features of the semilunar valves?
- What is the anatomic relationship of the systemic arteries?
- Describe normal branching of the aortic arch.

Resources

Anderson RH, Becker AE, Freedom RM, et al. Sequential segmental analysis of congenital heart disease. *Pediatric Cardiology* 1984; 5(4): 281-287.

Edwards WD, Maleszewski JJ. Cardiac Anatomy and Examination of Cardiac Specimens. In: Allen HD, Driscoll DJ, Shaddy RE, Feltes TF, 8th, editors. *Moss and Adams' Heart Disease in Infants, Children, and Adolescents: Including the Fetus and Young Adult*. Philadelphia: Lippincott Williams & Wilkins; 2013. p.1-31.

Van Praagh R. Terminology of congenital heart disease: Glossary and commentary. *Circulation* 1977; 56:139-143.

The Cardiac History & Physical Exam

Questions to Ask

- How is the child growing?
- How much activity can the child tolerate? Can they keep up with peers?
- How was the mother's pregnancy? Did the mother have diabetes or other medical problems? Did she take any drugs or prescription medications during the pregnancy?
- Is there a family history of congenital heart disease, sudden death or early cardiac death?
- Does the child have a syndrome that is associated with cardiac disease?
- Does the child have any symptoms: poor growth, poor feeding, developmental delay, diaphoresis, poor exercise tolerance, cyanosis, syncope, palpitations, or edema?

Vitals Signs Are Vital!

- Tachycardia is a clue that the child requires increased cardiac output
- Tachypnea can be a consequence of increased pulmonary blood flow or congestion.
 - Quiet/comfortable or with respiratory distress.
- Pulse oximetry will identify if an infant is cyanotic

Inspection

- Look for a precordial bulge or hyperdynamic precordium
- Look for extracardiac signs: dysmorphic facial features, clubbing of the digits, edema, respiratory distress (grunting, retractions)

Palpation

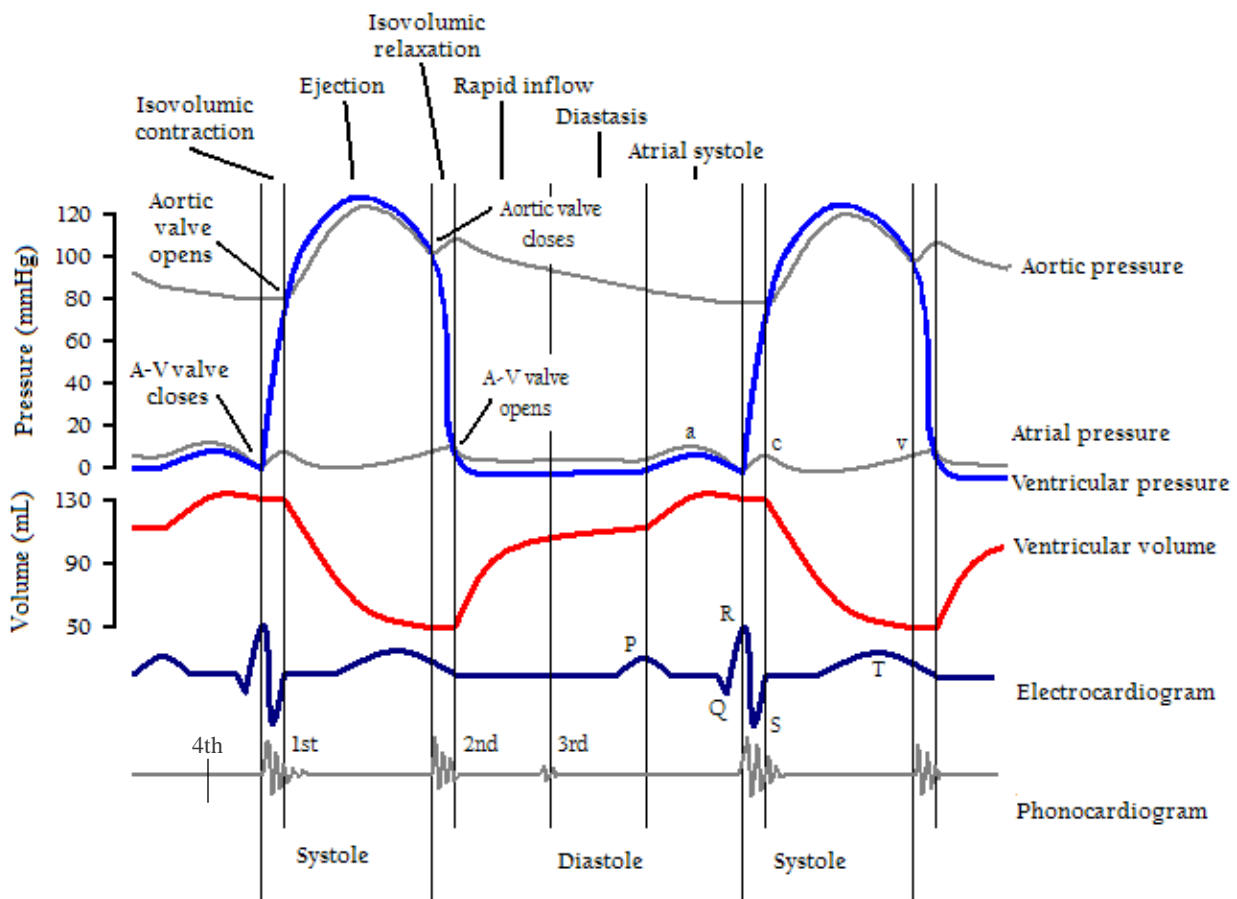
- Arterial exam:
 - Pulses: rate, rhythm, volume, character. Assess for brachial-femoral delay.
 - **Femoral pulses should be part of every exam, particularly in neonates**
 - Assess distal perfusion by the warmth of the digits and capillary refill time.
- Venous exam:
 - Assess position, size, consistency of the liver
 - Assess for jugular venous distention in an older child
- Precordial exam:
 - Entire palm and hand should be placed on chest to assess for thrills or heaves
 - Assess the position and character of the apical impulse

Auscultation

- **S1: the first heart sound**
 - From closure of the mitral and tricuspid valves, can occasionally be audible as a split S1
 - Best heard with the diaphragm of the stethoscope
- **S2: the second heart sound**
 - From closure of the semilunar valves
 - Usually consists of a louder, earlier sound from aortic valve closure (A2) followed by a quieter sound from pulmonary valve closure (P2).
 - Splitting of S2 during inspiration or "physiologic splitting" is a normal finding related to increased right heart filling and decreased left heart filling during inspiration, causing

the right ventricle to take longer to empty, and the pulmonary valve to take longer to close. To say the “S2 is normal” is to say you heard this variable splitting!!

- A loud S2 is likely from early closure of the pulmonary valve and may suggest pulmonary artery hypertension.
- **S3 gallop: “Kentucky”**
 - Heard early in diastole during rapid filling
 - May be normal in older children and competitive athletes
- **S4 gallop: “Tennessee”**
 - Heard when the myocardium is poorly compliant, from rapid filling of the ventricle during atrial contraction (late in diastole)
 - Always pathologic in children, usually associated with CHF
- **Ejection Clicks:** early systolic, high-frequency sound associated with abnormal semilunar valves
- **Midsystolic click:** midsystolic, high-frequency sound associated with mitral valve prolapse



Adapted from: https://upload.wikimedia.org/wikipedia/commons/9/9a/Wiggers_Diagram.png

- **Murmurs:** caused by turbulent blood flow creating audible sound waves in the range of 20Hz to 2000Hz
 - **Described by:**
 - **Timing:**
 - When in the cardiac cycle does the murmur occur?
 - What is the murmur's relationship to S1 and S2?
 - **Intensity or loudness:**
 - Depends on the size of the orifice or vessel through which blood flows, the pressure difference or gradient across the site, and the blood flow or volume across the site
 - **For systolic murmurs:**
 - **Grade 1:** heard only with intense concentration
 - **Grade 2:** faint, but heard immediately
 - **Grade 3:** easily heard, of intermediate intensity
 - **Grade 4:** easily heard, associated with a thrill (a palpable vibration on the chest wall)
 - **Grade 5:** very loud with a thrill, audible with only the edge of the stethoscope on the chest wall
 - **Grade 6:** audible with the stethoscope off the chest wall
 - Duration of the murmur
 - Configuration: the dynamic shape of the murmur
 - Pitch: the frequency range of the murmur
 - Quality: the presence of harmonics or overtones
 - Location on the chest wall:
 - Point of maximal intensity: Where is the sound loudest?
 - Extent of radiation: Over what area is the sound audible?
 - **Systolic Murmurs occur between S1 and S2**
 - **Holosystolic murmurs:** obscure S1 and terminate at S2
 - **Ejection murmurs:** crescendo-decrescendo or diamond-shaped
 - **Early systolic murmurs:** start abruptly at S1, but taper and disappear before S2 – associated exclusively with small muscular VSDs
 - **Mid- to late systolic murmurs:** begin midway through systole, often heard with midsystolic clicks and the mitral regurgitation heard with mitral valve prolapse
 - **Diastolic Murmurs occur between S2 and S1**
 - **Early diastolic murmurs:** decrescendo murmurs, arise from aortic or pulmonary valve regurgitation
 - **Mid-diastolic murmurs:** diamond shaped murmurs, associated with increased flow across a normal mitral or tricuspid valve, or normal flow across a stenotic mitral or tricuspid valve
 - **Late diastolic murmurs:** crescendo murmurs, created by stenotic or narrowed mitral or tricuspid valves, the noise is associated with atrial contraction
 - **ALWAYS pathologic!**
 - **Continuous Murmurs occur throughout the cardiac cycle**
 - Flow through vessels beyond the semilunar valves is not confined to systole or diastole
 - Murmur is heard from S1 and extends beyond S2 into diastole
 - These can be innocent (e.g. venous hum).

References and Advanced Reading

Pelech A. Evaluation of the Pediatric Patient with a Cardiac Murmur. *Pediatr Clin North Am* 1999; 46(2):167-88.

Pelech A. Physiology of Cardiac Auscultation. *Pediatr Clin North Am* 2004; 51(6):1515-35, vii-viii.

Gersh BJ. "Auscultation of heart sounds." *UpToDateonline.com*

Further Questions:

- Name common causes of holosystolic murmurs? Systolic ejection murmurs? Diastolic murmurs?
- What is pulsus paradoxus? How do you measure it? What is the differential diagnosis?
- What is a widened pulse pressure? What is the differential diagnosis?
- How do you distinguish between central cyanosis and acrocyanosis?
- Name common causes of widely split or fixed splitting of S2.

Introduction to Cardiac Cath

What information can be obtained in the cath lab?

- Measure pressures in the cardiac chambers
- Sample blood to measure oxygen saturations in each chamber
- Examine anatomy by injecting contrast
- Use the numbers obtained to calculate cardiac output, shunts and vascular resistance

Indications for Cath

- Confirm or complete the anatomic diagnosis
- Obtain hemodynamic information
- Clinical signs and symptoms do not fit with a patient's diagnosis
- Clinical course is not progressing as expected
- Specific interventions

CALCULATIONS:

Oxygen Capacity: maximal amount of oxygen that can be taken up by hemoglobin in the blood

$$O_2 \text{ capacity (mL/L)} = 1.36 \times \text{Hgb (gm/dL)} \times 10$$

Oxygen Content: Amount of oxygen present in a blood sample (includes amount bound to hemoglobin and amount dissolved in plasma). At normal body temperature (37°C):

$$O_2 \text{ content (mL/L)} = O_2 \text{ bound to hemoglobin} + O_2 \text{ dissolved in plasma} \\ = (O_2 \text{ capacity} \times O_2 \text{ saturation}/100) + (0.03 \times PO_2)$$

In room air, amount of dissolved O₂ in the sample is ignored as it represents ~1.5% of total body oxygen, so we simplify to:

$$O_2 \text{ content (mL/L)} = (1.36 \times \text{Hgb} \times 10) \times O_2 \text{ saturation}/100$$

Fick Equation: uses the speed of oxygen usage to estimate blood flow

Uptake of a substance = Flow x [concentration of substance in – concentration of substance out]

Q_p = pulmonary blood flow

Q_s = systemic blood flow = Cardiac Index

$$Q_p \text{ (L/min)} = \frac{\text{Oxygen consumption (mL/min)}}{\text{Pulmonary venous } O_2 \text{ content} - \text{Pulmonary arterial } O_2 \text{ content}}$$

$$Q_s \text{ (L/min)} = \frac{\text{Oxygen consumption (mL/min)}}{\text{Systemic arterial } O_2 \text{ content} - \text{Mixed venous } O_2 \text{ content}}$$

$$Q_p:Q_s^* = \frac{\text{Systemic arterial } O_2 \text{ saturation} - \text{Mixed venous } O_2 \text{ saturation}}{\text{Pulmonary venous } O_2 \text{ saturation} - \text{Pulmonary arterial } O_2 \text{ saturation}}$$

**assuming samples were obtained in room air*

Oxygen consumption is an estimated value based on the patient's age, gender and heart rate

Ohm's Law:

R_p = pulmonary vascular resistance R_s = systemic vascular resistance

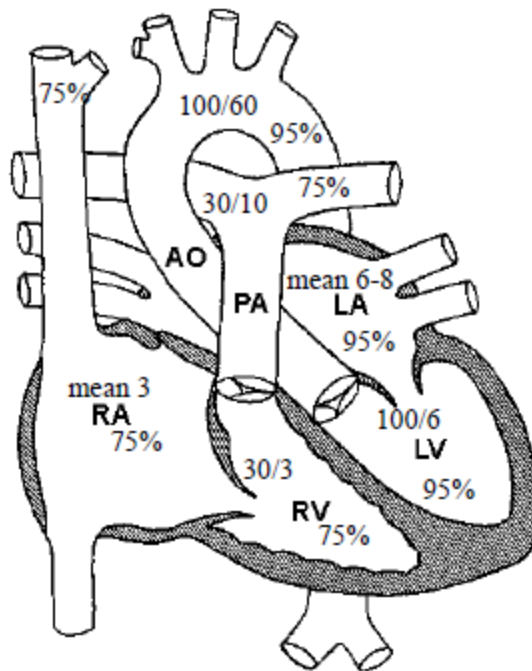
$$\text{Resistance} = \frac{\text{Change in Pressure}}{\text{Flow}}$$

$$R_p = \frac{\text{Pressure in Pulmonary Artery} - \text{Pressure in Left Atrium}}{Q_p}$$

$$R_s = \frac{\text{Pressure in Aorta} - \text{Pressure in Right Atrium}}{Q_s}$$

Mean pressures are used for all calculations

Site	Pressures (mmHg)	Oxygen Saturation
SVC		70-75%
IVC		~3-5% > SVC sat
RA	Mean 3-6	70-75%
RV	20-30/0-3	70-75%
PA	20-30/8-12 (mean 10-15)	70-75%
LA = PCW	Mean 5-10	95-100%
LV	70-120/5-10	95-100%
Ao	70-120/50-80	95-100%



NORMAL VALUES: Cardiac Index 3-5, PVR < 2

Common Post-Cath Complications

- <1% risk of major complications (death, myocardial infarction, stroke)
- Inducible arrhythmias: atrial tachyarrhythmias, ventricular tachycardia, ventricular fibrillation, bradycardia, AV conduction abnormalities
- Perforation of the heart or great vessels
- Allergic reaction to local anesthetic or iodinated contrast
- Valvar damage, particularly during endomyocardial biopsies
- Radiation exposure
- Infection
- **Local vascular complications (most common):** acute thrombosis, dissection, hemorrhage, hematoma, arteriovenous fistula, pseudoaneurysm

Questions:

- What information is obtained during a pre-Glenn cath?
- What information is obtained during a cath in a patient with Tetralogy of Fallot, Pulmonary Atresia and MAPCAs?

Case A: 3 month old patient, intubated in 21% FiO₂. Patient’s hemoglobin in 14.7g/dL. Assume the oxygen consumption is 150mL/min and pulmonary venous saturations are 100%. Calculate the Q_p.

- Calculate Q_s.
- What is the PVR?
- What is the likely lesion and why?

Site	Pressures (mm Hg)	Oxygen Saturation
SVC		60%
RA	mean 4	62%
RV	80/3	63%
PA	20/8, mean 12	63%
PV	mean 5	96%
LV	80/5	75%
Ao	82/45	75%

Case B: 1 day old patient, intubated in 50% FiO₂. O₂ capacity is 200mL. Assume the oxygen consumption is 120mL/min/m² and pulmonary venous saturations are 100%.

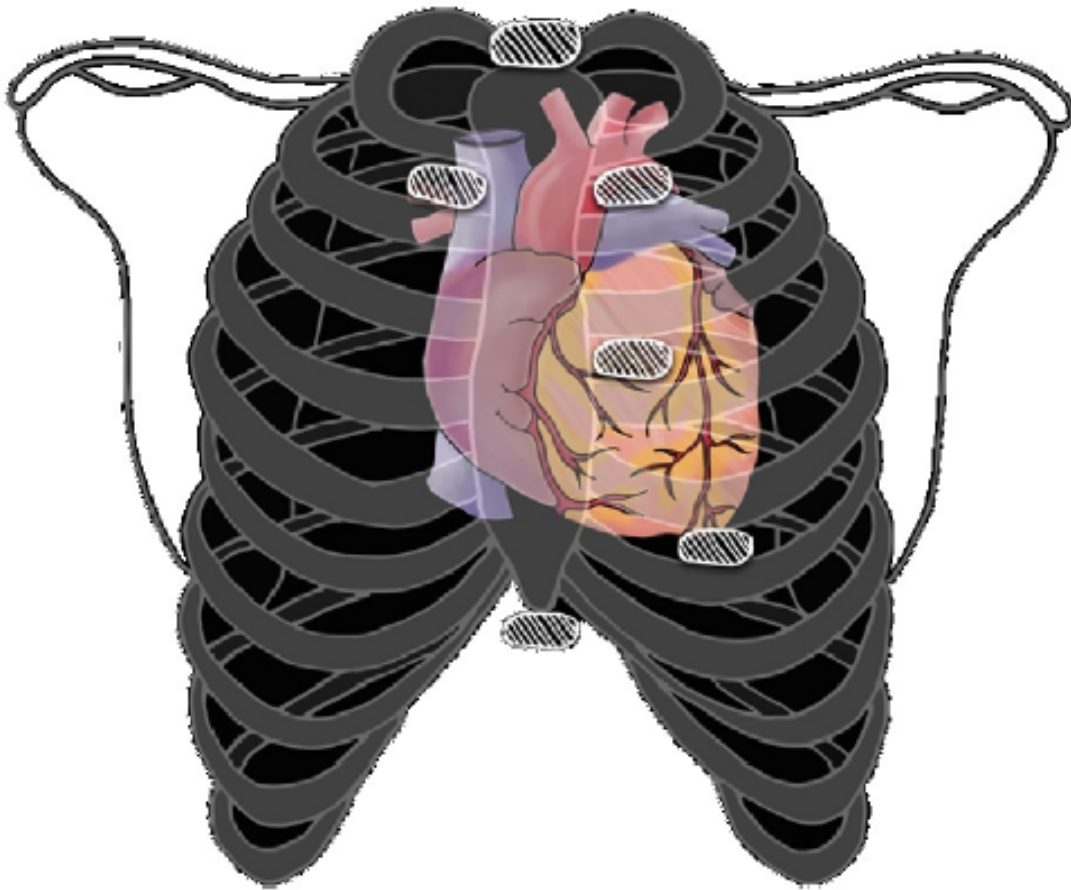
- Calculate the Q_p.
- Calculate Q_s.
- What is the Q_p:Q_s?
- What is the likely lesion and why?

Site	Pressures (mm Hg)	Oxygen Saturation	Oxygen Content (mL/L)
SVC		40%	80
RA	mean 6	62%	124
RV	75/5	65%	130
PA	60/40, mean 46	92%	184
PV	mean 5	100%	200
LV	60/6	96%	192
Ao	75/55, mean 62	65%	130

References

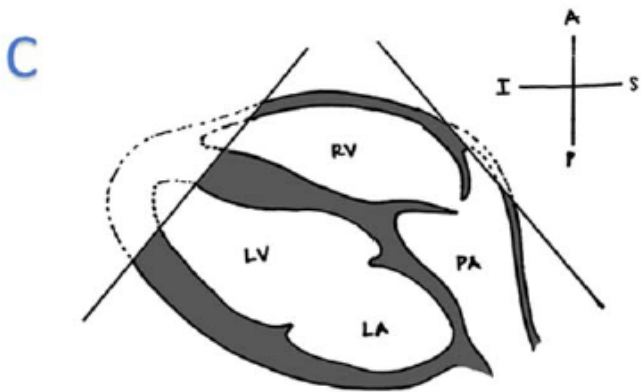
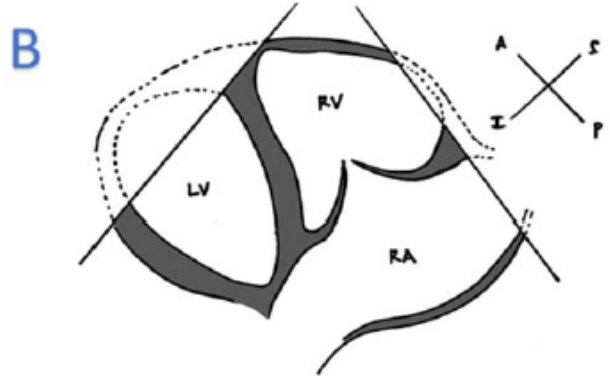
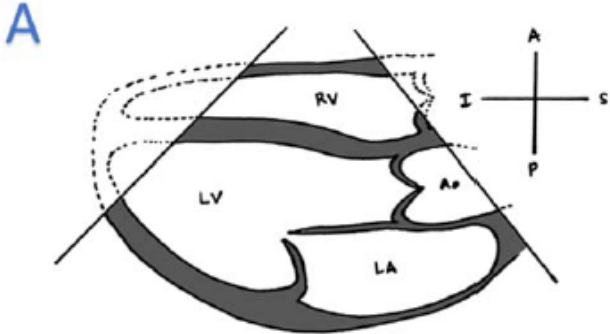
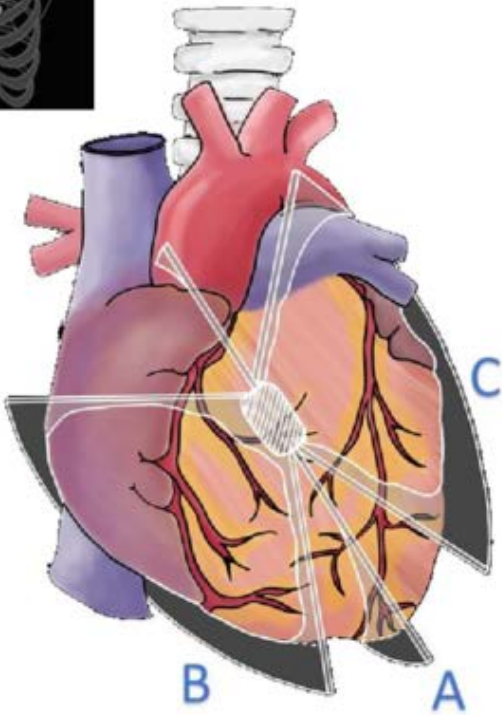
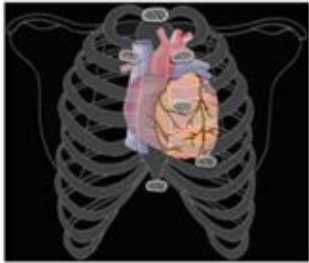Taggart NW, Cabalka AK. Cardiac Catheterization and Angiography. In: Allen HD, Driscoll DJ, Shaddy RE, Feltes TF, 8th, editors. Moss and Adams’ Heart Disease in Infants, Children, and Adolescents: Including the Fetus and Young Adult. Philadelphia: Lippincott Williams & Wilkins; 2013. p.258-287.
 Carrozza JP. Complications of diagnostic cardiac catheterization. *Uptodate.com*

Echocardiogram Cards



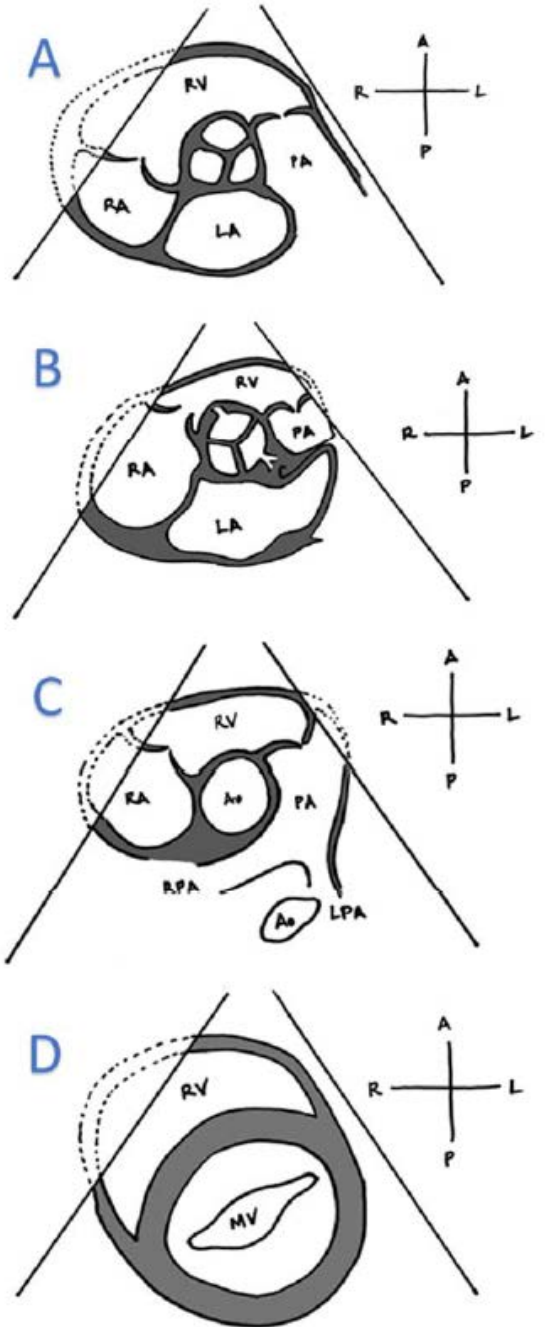
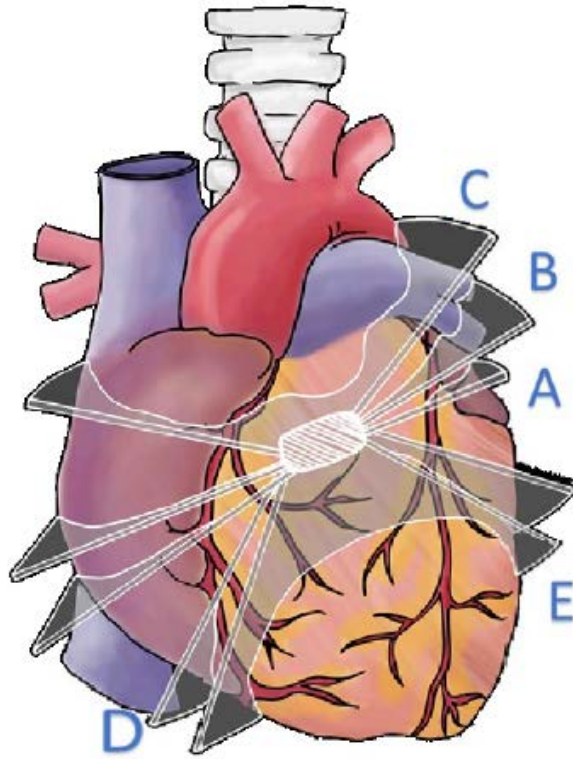
Compiled by Alaina Kipps, MD with
illustrations by Marielle Evans

Parasternal Long Axis



- A: Standard/Starting Plane
- B: RV Inflow Plane
- C: RV Outflow Plane

Parasternal Short Axis



A: Standard/Starting plane at base of heart

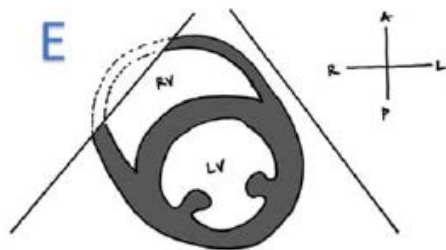
B: Level of Coronary Arteries

C: Branch Pas

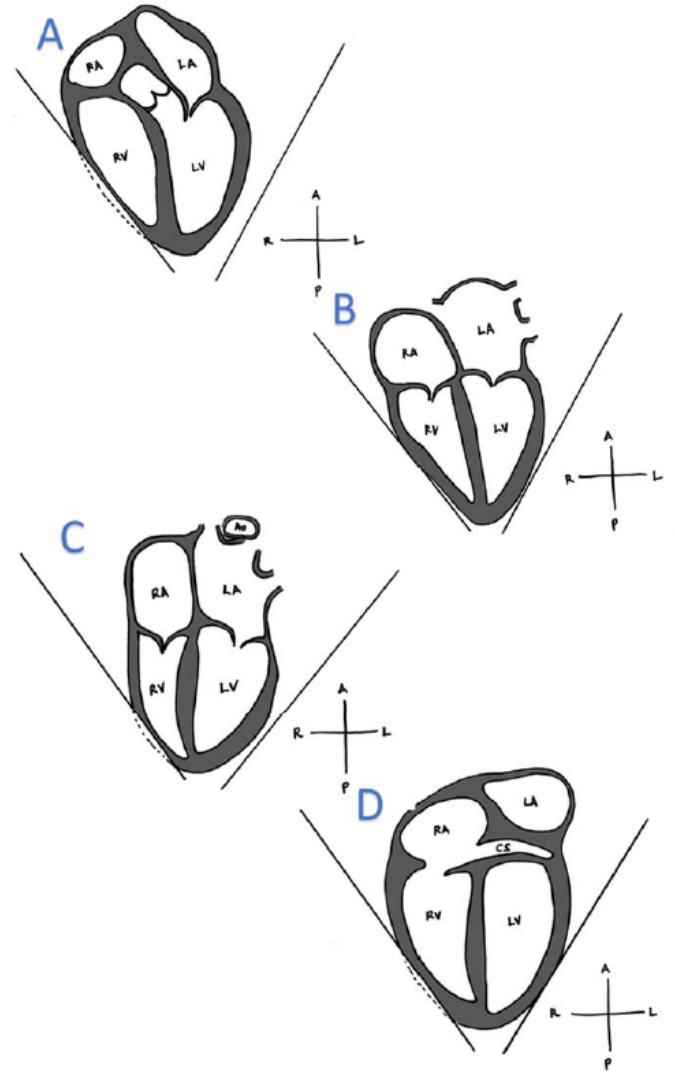
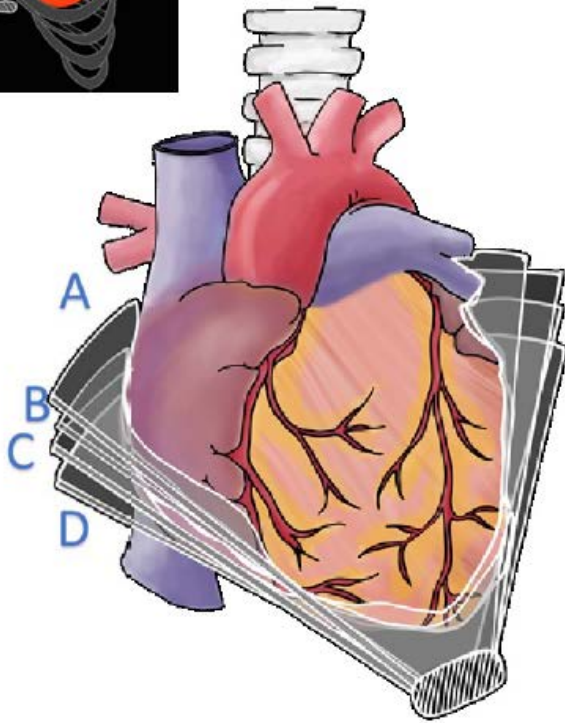
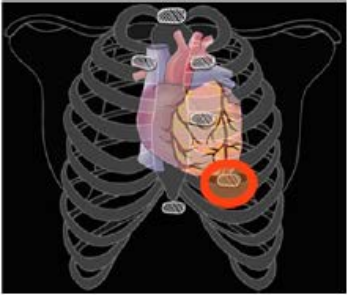
D: Mitral Valve

E: LV Papillary

Muscles



Apical 4-Chamber



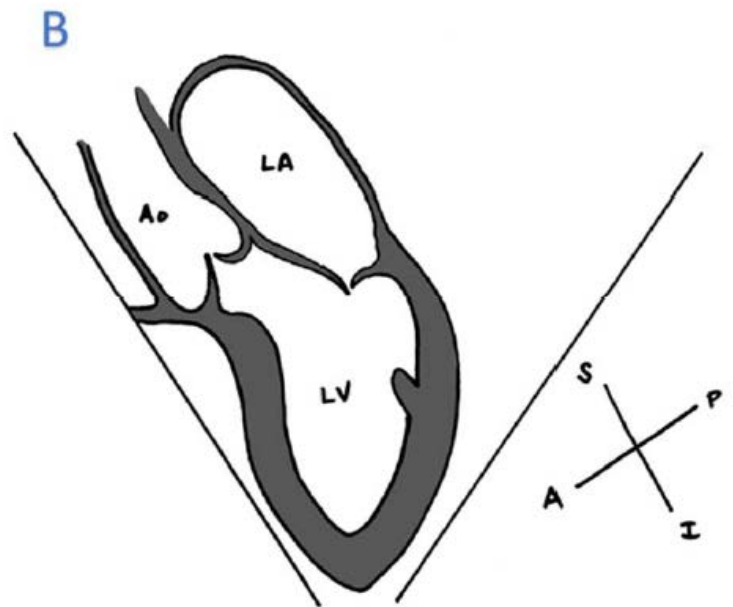
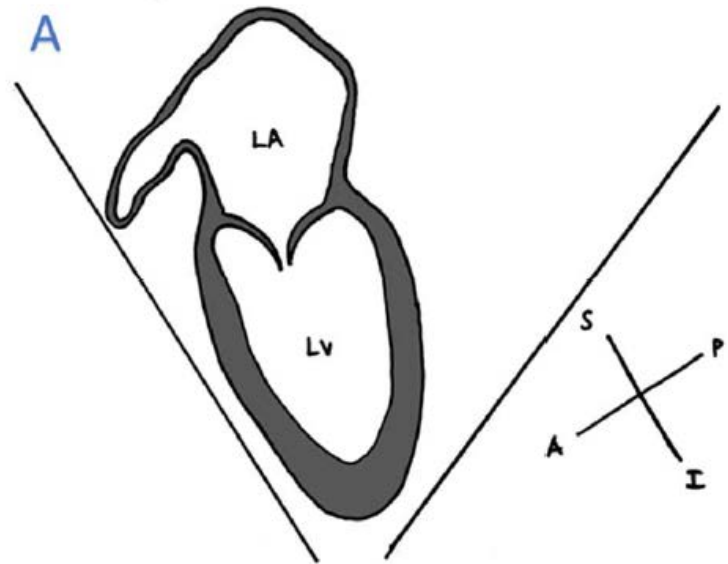
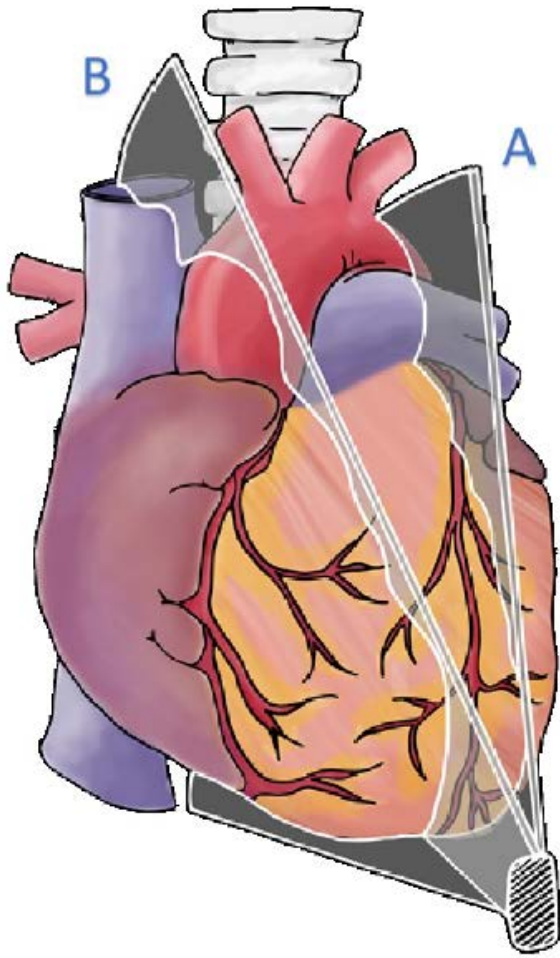
A: LVOT

B: 4-Chambers

C: 4-Chamber + descending aorta

D: Coronary Sinus / Posterior Heart

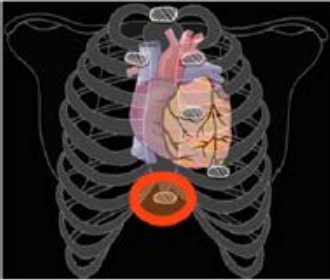Apical 2-Chamber



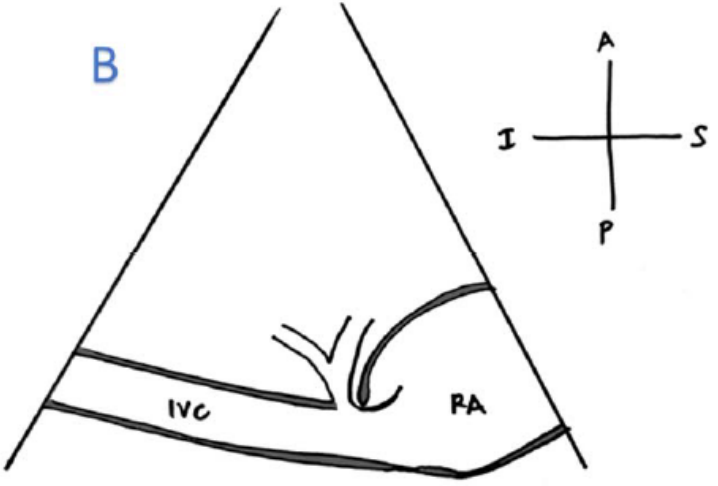
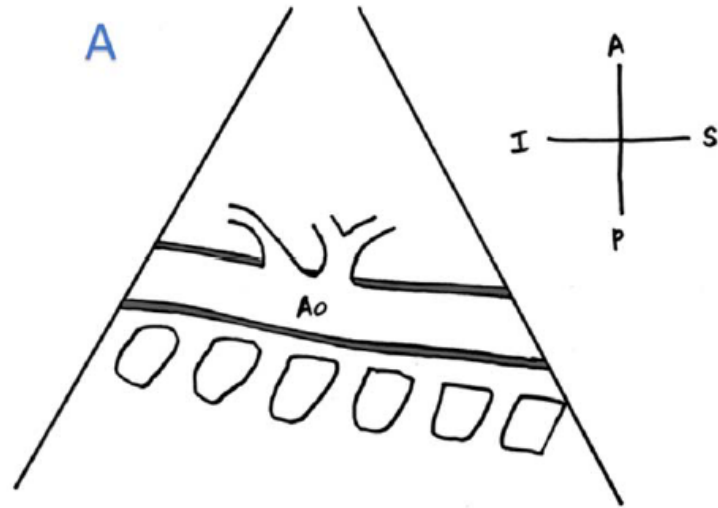
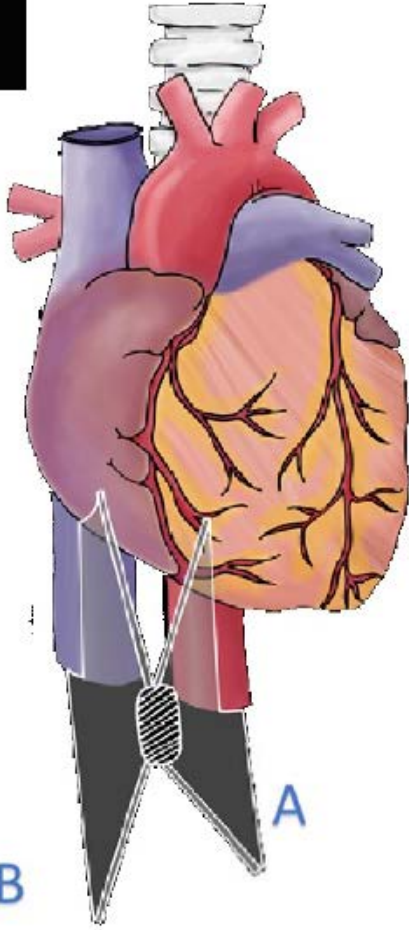
A: For use in Simpson Biplane EF calculation + LA Appendage

B: LVOT View

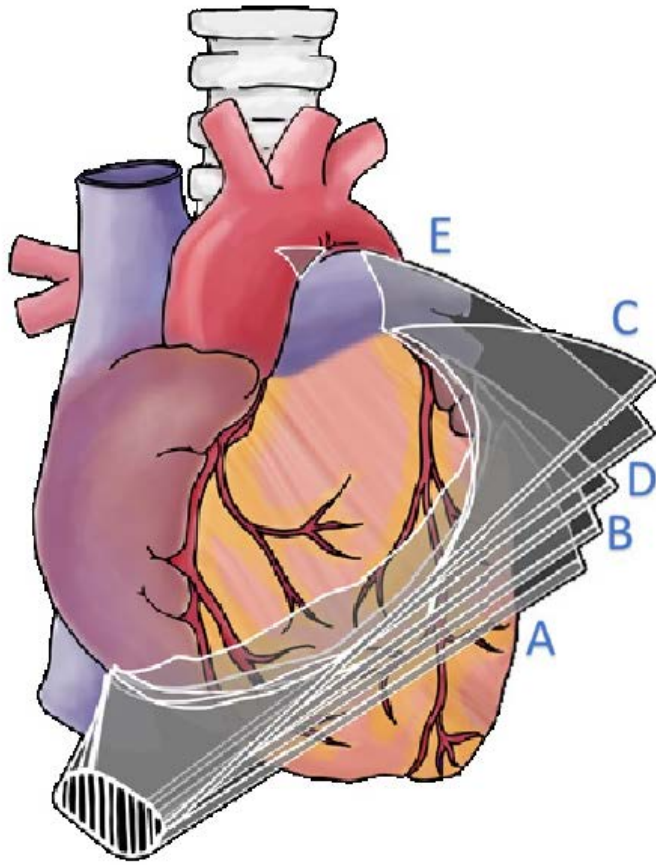
Subcostal IVC and Aorta



A: Aorta
 B: IVC into RA



Subcostal Long-Axis



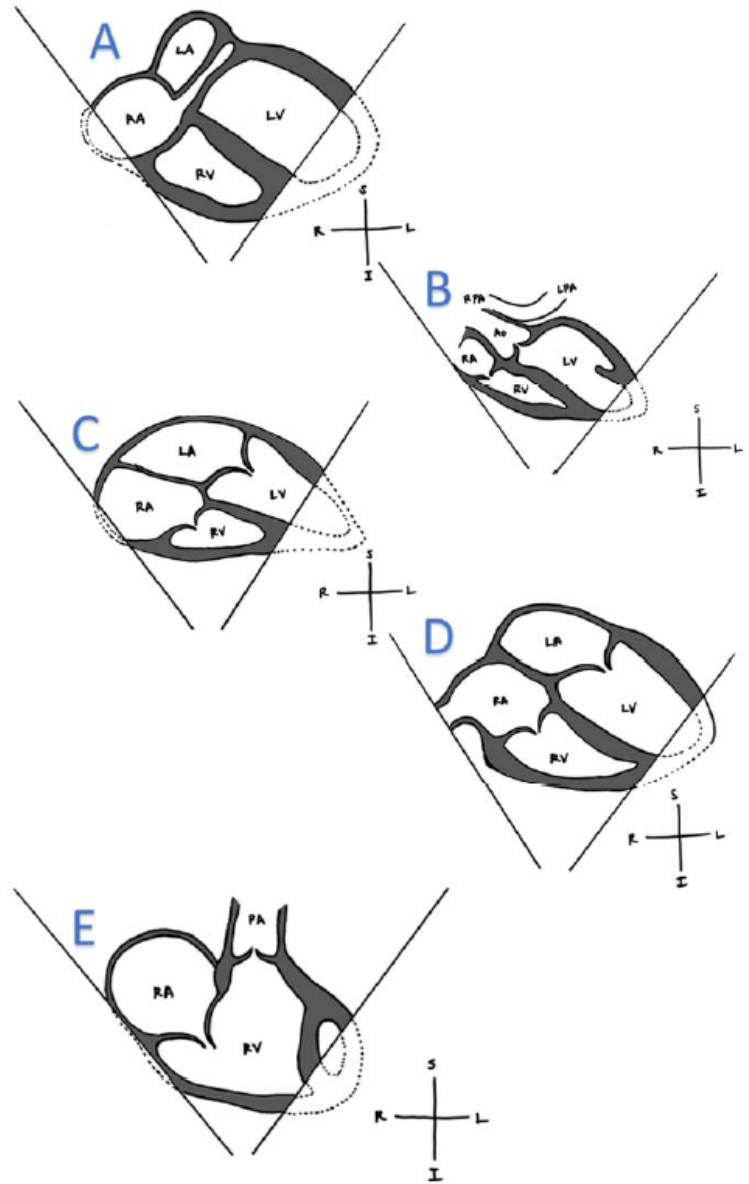
A: Level of Coronary Sinus

B: Level of Inlets to both ventricles

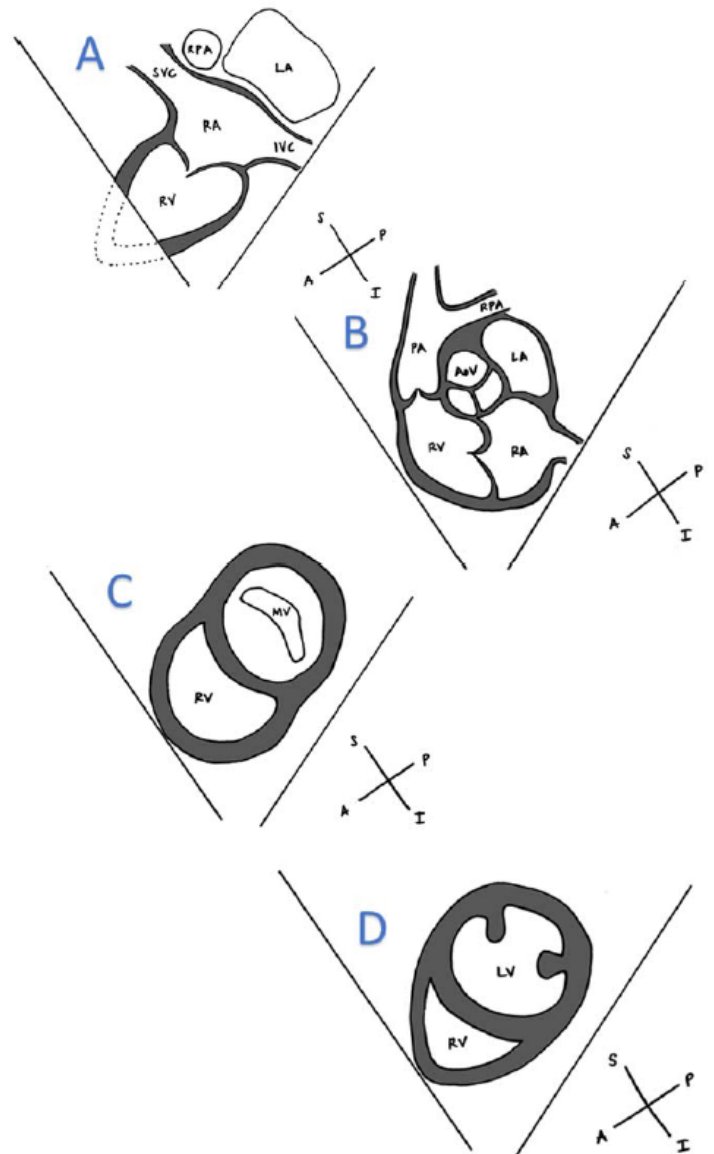
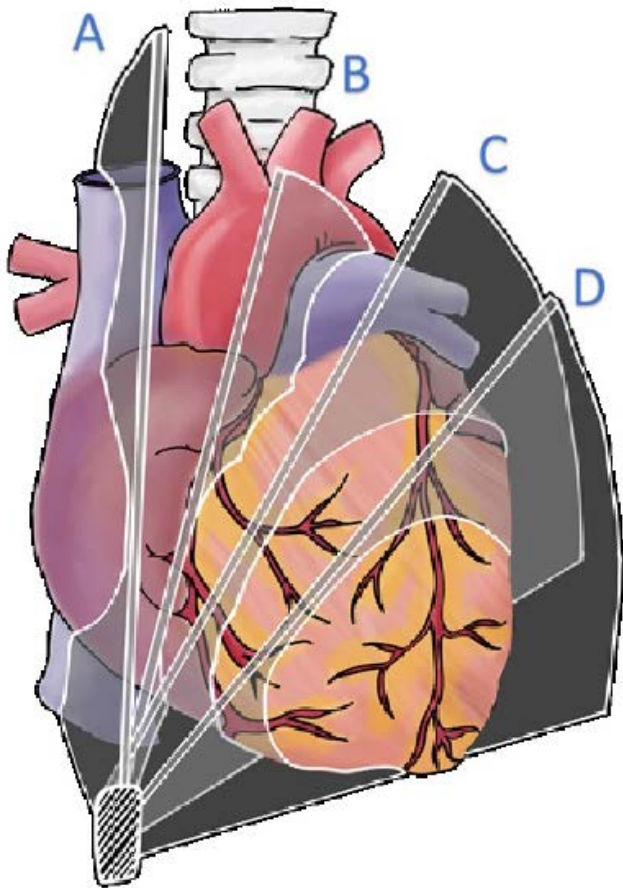
C: Level of the Atrial Septum

D: Level of LVOT

E: Level of RVOT



Subcostal Short-axis



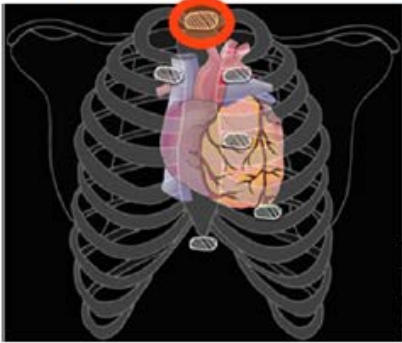
A: Bicaval View

B: RV Inflow and Outflow

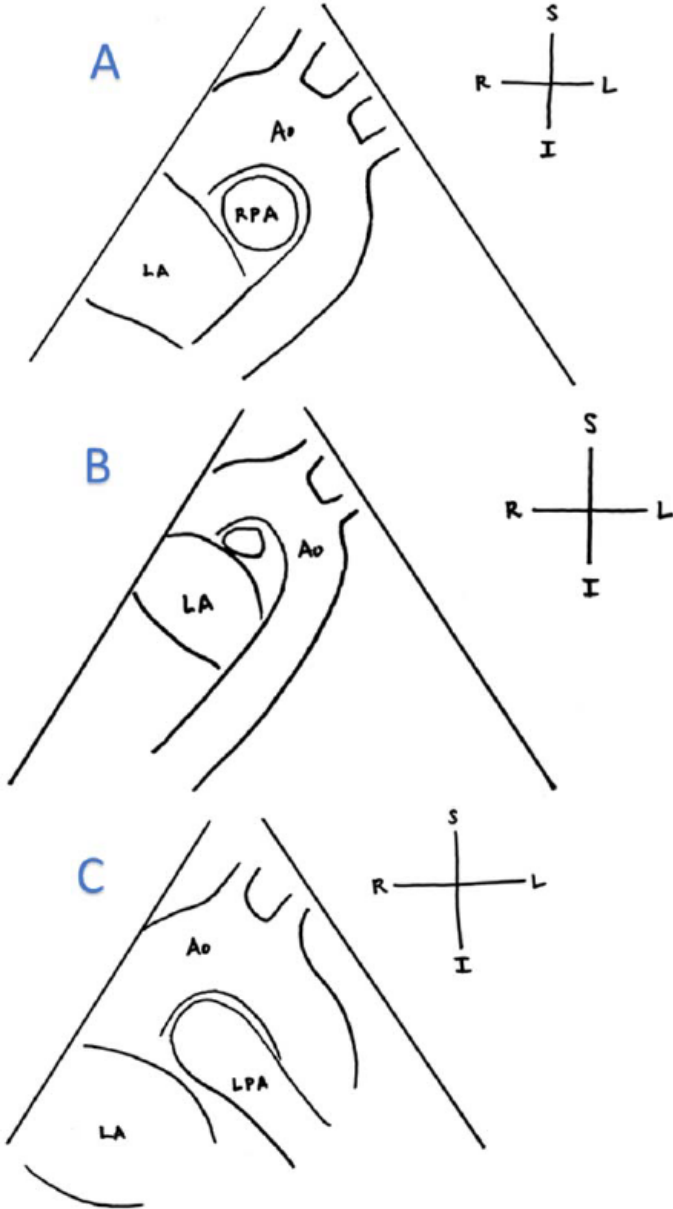
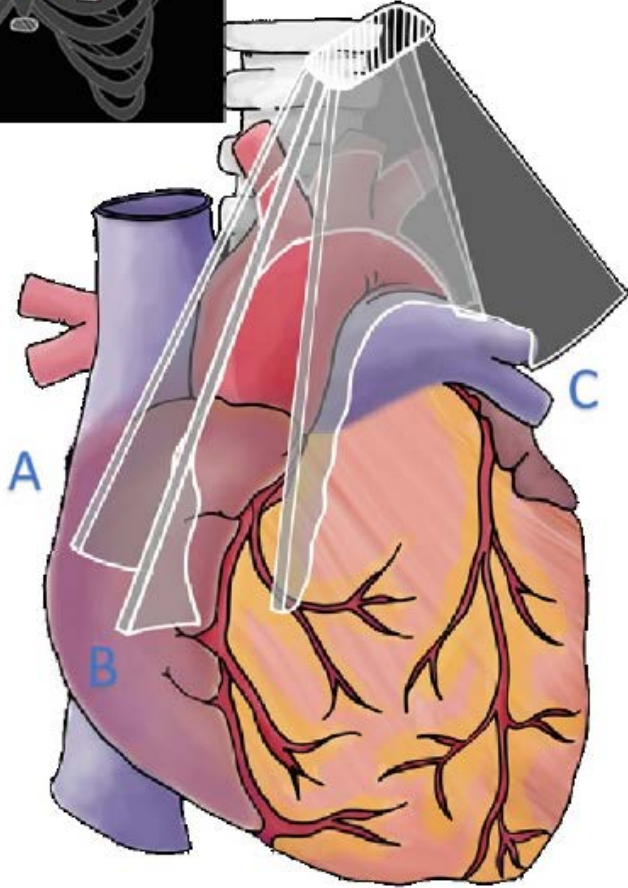
C: Level of the Mitral Valve

D: Level of the LV Papillary Muscles

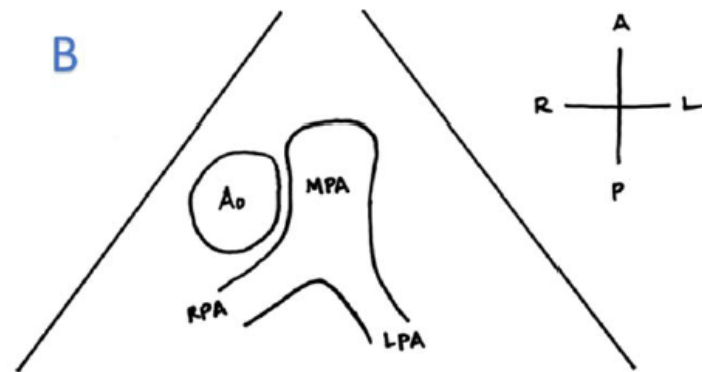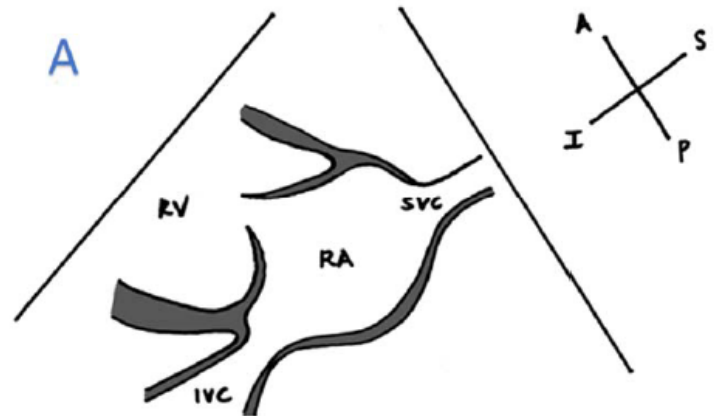
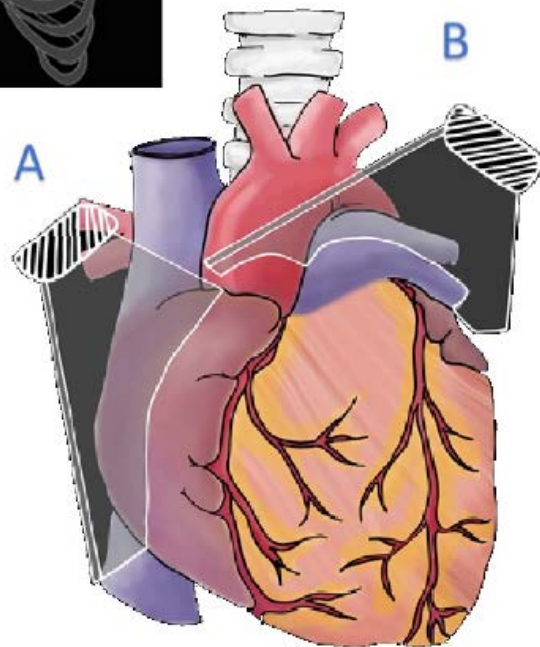
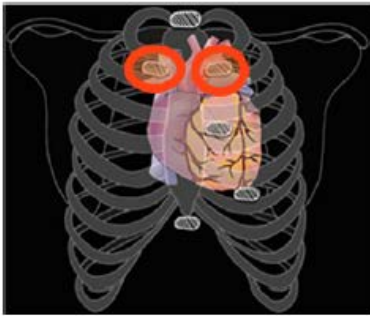Suprasternal Long-axis



- A: Aorta "candy cane" +RPA
- B: Similar
- C: LPA Elongated



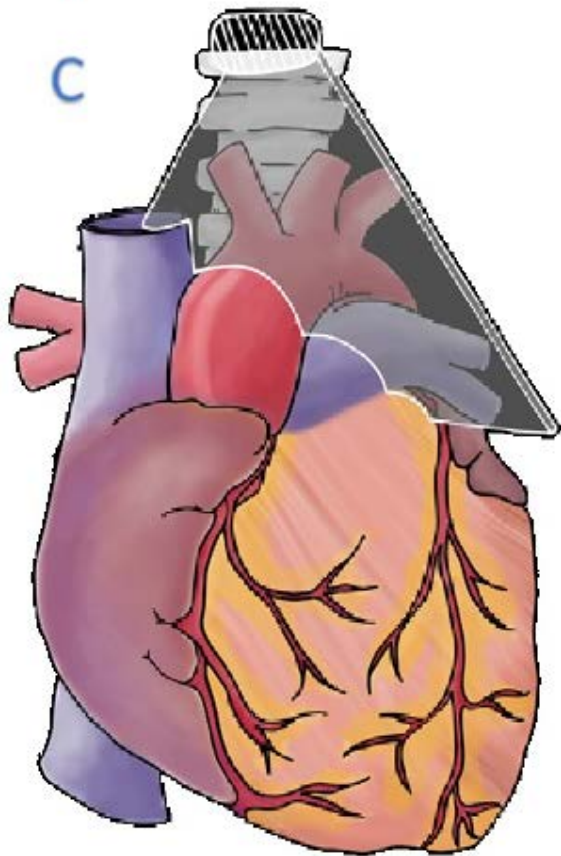
Subclavicular Views



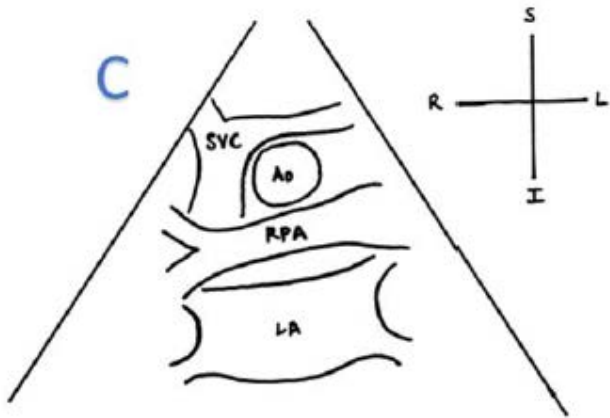
A: Bicaval View

B: Branch Pas "pants" view

Suprasternal Short-axis



C: SVC/Aorta/
RPA and Left
Atrium "crab"
view

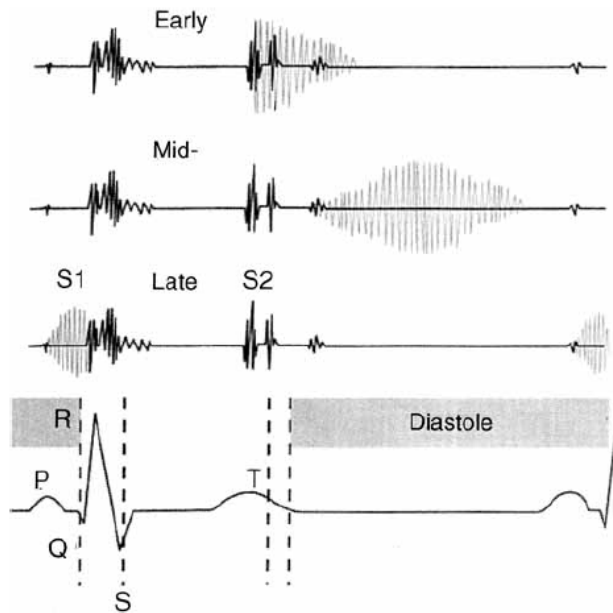
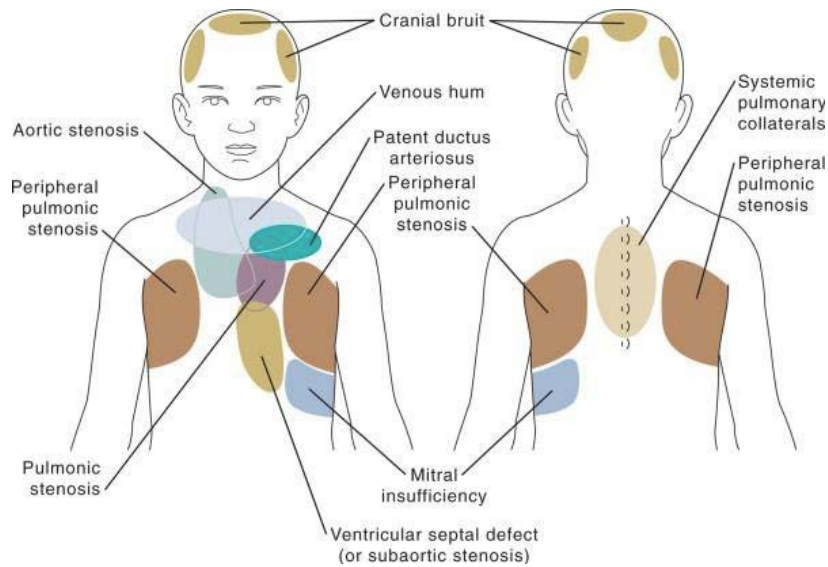


Murmurs

See *Cardiac History & Physical Exam* for introductory discussion of murmurs.

Innocent Murmurs of Childhood

	<i>Age</i>	<i>Timing & Configuration</i>	<i>Intensity</i>	<i>Pitch</i>	<i>Quality</i>	<i>Location</i>	<i>Etiology</i>
Still's	2-6 years, may be audible from infancy to adulthood	Early systole	Grade 1-3	Low to medium	Vibratory "twang" or "musical" ↑ when supine	L LSB, extends to apex	Ventricular false tendons
Pulmonary flow murmur	All ages	Early- to mid-systolic, Crescendo-decrescendo	Grade 2-3		Rough, dissonant ↑ when supine	2 nd and 3 rd intercostal spaces	Audible flow across pulmonary outflow tract
Peripheral pulmonic stenosis	0-6 months	Ejection murmur beginning in mid-systole	Grade 1-2	Low to medium		L USB, radiates to bilateral axillae and back	Acute take off of the branch PAs in neonates ↑ with respiratory infections
Venous Hum	~3-8 years	Continuous murmur, ↑ in diastole	Grade 1-3		Whining, roaring or whirring ↑ when supine ↑ with head turned away from examiner ↓ with compression of jugular vein	Low anterior neck, extends to infraclavicular area, R>L	Turbulence at confluence of jugular and subclavian veins as they enter SVC, or angulation of IJV as it courses over transverse process of atlas
Supraclavicular or brachiocephalic systolic murmur	Children and teenagers	Brief, crescendo-decrescendo	Grade 1-3	Low to medium	Disappears with hyperextension of shoulders	Above clavicles, radiates to neck	Major brachiocephalic vessels arising from aorta
Aortic systolic murmur	Older children and adults	Ejection	Grade 1-3	Low to medium		R USB	↑ with anxiety, anemia, hyperthyroidism or fear
Mammary Artery Soufflé	Teenagers and pregnant women	Systolic murmur, extends into diastole	Grade 1-3	High	Varies from day to day	Anterior chest wall over breast	Blood flow in arteries and veins leading to and from breasts



Evaluation of a Murmur

- Take a good history, including symptoms with exercise and family history

“The Seven S’s” of Innocent Murmurs

- Sensitive – varying intensity with changes in posture and respiration, loudest when supine
- Short duration – not holosystolic
- Single – no associated clicks or gallops
- Small – limited to a small area, non-radiating
- Soft – low amplitude
- Sweet – not harsh
- Systolic – occurs only during in systole

Red Flags

- History suggestive of cardiac disease
- Presence of a holosystolic or diastolic murmur
- Grade 3 or higher murmur
- Abnormal S2 or audible click
- Systolic murmur that intensifies with standing
- Neonates and very young infants (murmurs are more likely to represent congenital heart disease, though young infants can have innocent murmurs too!)

Questions

- When should you refer to a patient with a murmur to Cardiology?
- How can you distinguish a pulmonary flow murmur from the murmur caused by an ASD?
Or from the murmur caused by pulmonary valve stenosis?

References:

- Cassidy SC, Allen HD, Phillips JR. History and Physical Examination. In: Allen HD, Driscoll DJ, Shaddy RE, Feltes TF, 8th, editors. *Moss and Adams' Heart Disease in Infants, Children, and Adolescents: Including the Fetus and Young Adult*. Philadelphia: Lippincott Williams & Wilkins; 2013. p.91-92.
- Frank JE, Jacobe KM. Evaluation and management of heart murmurs in children. *Am Fam Physician* 2011; 84(7):793-800.
- Pelech A. Evaluation of the Pediatric Patient with a Cardiac Murmur. *Pediatr Clin North Am* 1999; 46(2):167-88.

Chest Pain

Chest pain is generally a benign condition in pediatrics (94-99% of the time!)

It is a common chief complaint and there is a large differential diagnosis (see flow chart). Idiopathic and chest wall pain are the most common etiologies, followed by GI pain (e.g. GERD) and asthma.

Cardiac Causes: usually from compromised coronary supply and/or a mismatch of oxygen supply and demand to cardiac tissue

- Left ventricular outflow tract obstruction
 - Hypertrophic cardiomyopathy
 - Aortic stenosis
 - Coarctation of the aorta
- Coronary artery abnormalities
 - Abnormal coronary origins
 - Sequelae of Kawasaki Disease
 - Slit-like coronary orifice or acute angle of take-off of the coronary artery
 - Myocardial bridge (muscle covering part of coronary vessel)
- Classic angina in patients with severe hyperlipidemia or a history of Kawasaki Disease
- Variant angina (coronary vasospasm) after recreational drug use (cocaine, amphetamines, bath salts, marijuana, synthetic cannabinoids)
- Pericarditis
- Myocarditis
- Dilated cardiomyopathy
- Tachyarrhythmias
- Aortic root dissection
- Ruptured sinus of Valsalva aneurysm
- Pulmonary Hypertension

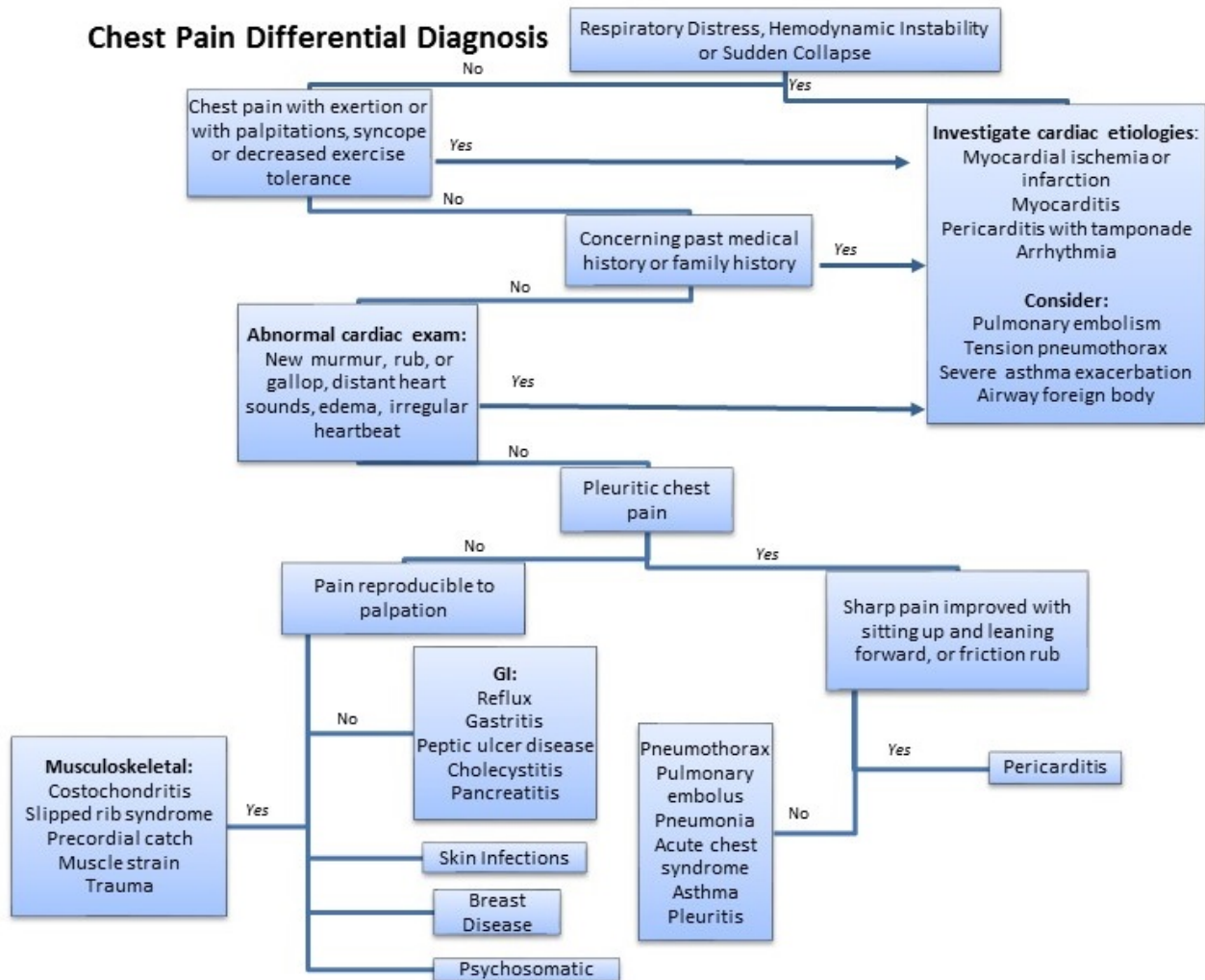
Cardiac Chest Pain Red Flags

- Patient describes chest pain that is “deep,” “crushing,” or “substernal” with radiation to the neck, shoulder or arm.
- Chest pain associated with vomiting, diaphoresis, change in mental status, dizziness, dyspnea
- Chest pain with exertion
- Decreased exercise tolerance
- Exertional syncope or dizziness
- Palpitations
- Heart failure symptoms
- History of congenital heart disease, heart transplant, Kawasaki disease, substance abuse
- Family history of cardiomyopathy, cardiac arrhythmia, sudden death in parents or siblings before the age of 50, connective tissue disorders, or hypercoagulable states

Diagnostic Work-up

- History, history, history (and family history!)
- Vital signs
- EKG
- Consider a chest X-ray
- Consider a trial of NSAIDs if musculoskeletal cause is suspected
- Cardiology consultation for echo or exercise stress testing

Chest Pain Differential Diagnosis



Questions

- When should a patient be referred to Cardiology clinic? To the ED?
- When should a patient be restricted from exercise?
- For each of the cardiac causes listed above, make a list of other signs or symptoms suggestive of the diagnosis.

References

- Johnson JN, Driscoll DJ. Chest Pain in Children and Adolescents. In: Allen HD, Driscoll DJ, Shaddy RE, Feltes TF, 8th, editors. *Moss and Adams' Heart Disease in Infants, Children, and Adolescents: Including the Fetus and Young Adult*. Philadelphia: Lippincott Williams & Wilkins; 2013. p.1509-1513.
- Geggel RL, Endom EE. Causes of nontraumatic chest pain in children and adolescents. *Uptodateonline.com*
- Geggel RL, Endom EE. Nontraumatic chest pain in children and adolescents: Approach and initial management. *Uptodateonline.com*
- Kocis KC. Chest Pain in Pediatrics. *Pediatric Clinics of North America*. 1999; 46(2): 189-203.

Syncope

>95% of all syncopal episodes in otherwise healthy adolescents are of benign etiology

Non-Cardiac Causes

- Neurocardiogenic syncope
- Breath holding spells
- POTS
- Seizures
- Psychogenic

Cardiac Causes

- Arrhythmia
 - Long QT Syndrome
 - Heart block
 - SVT
 - VT
- Structural cardiac disease (left ventricular outflow tract obstruction)
- Vascular disease

Red Flags for Cardiac Disease

- No prodrome (dizziness, nausea, pallor) prior to loss of consciousness
- Syncope in response to loud noise, surprise or extreme emotional stress
- Syncope during exercise
- Syncope while supine
- Family history of sudden death in a close family member before age 30
- LVH on the EKG

Evaluation

- History, history, history!
- Vitals, including testing orthostatics
- EKG
- Consider a cardiac event monitor
- Consider a neurologic work-up with an EEG

A Word on Postural Orthostatic Tachycardia Syndrome (POTS)

- Increase in heart rate by more than 30bpm within 10 minutes, or overall heart rate increase to above 120bpm in adults
 - Children may have hypotension, but adults typically do not
 - Exercise intolerance
 - Lightheadedness
 - Palpitations
- Typically seen in patients aged 15-50 years of age, 75-80% are female
- Etiology
 - Possibly related to central hypovolemia with excessively decreased venous return to the heart while upright, an abnormal inflammatory response or autonomic system dysfunction
 - Often symptoms begin after a viral illness, pregnancy, major surgery or trauma

- Association between POTS and joint hypermobility (such as Ehlers-Danlos Syndrome)
- Treatment
 - Increase water intake to 8-10 16oz glasses of water per day
 - Increase sodium intake to 200mEq per day
 - Cross the legs and fold the arms, especially while standing, to maintain blood pressure
 - Increase aerobic exercise and resistance training
 - Consider drug therapy: fludrocortisone, alpha agonists, beta blockers, SSRIs

Questions

- What questions should you ask when evaluating a patient with syncope?
- When would you refer a patient with syncope to the ED?
- How would you test for orthostasis in the clinic or ED?
- How would you follow a patient with syncope as an outpatient? When would you refer to Cardiology?

References

- Ackerman MJ. Cardiac Channelopathies, Syncope and Sudden Death. In: Allen HD, Driscoll DJ, Shaddy RE, Feltes TF, 8th, editors. *Moss and Adams' Heart Disease in Infants, Children, and Adolescents: Including the Fetus and Young Adult*. Philadelphia: Lippincott Williams & Wilkins; 2013. p.397-398.
- Lewis DA, Dhala A. Syncope in the pediatric patient. *Pediatric Clinics North America* 1999; 46(2):205-219.
- McLeod KA. Syncope in Childhood. *Arch Dis Child* 2003; 88:350-353.
- Medow MS, Stewart J. The Postural Tachycardia Syndrome. *Cardiology in Review* 2007; 15(2):67-75.

Preventive Cardiology

Risk factors associated with atherosclerotic changes & coronary artery disease:

- Overweight (BMI > 85th percentile for age and gender) or obese (BMI > 95th percentile)
- **Hypertension:** BP consistently \geq 95th percentile for age, height and gender
- **Dyslipidemia:** higher levels of total serum and LDL, lower levels of HDL, higher levels of triglycerides
 - Look for xanthomas (firm, fatty deposits) under the skin
 - Consider inherited disorders of LDL metabolism (Familial Hypercholesterolemia, Familial Combined Hyperlipidemia, Hyperapobetalipoproteinemia, Polygenic Hypercholesterolemia, Small Dense LDL)
- Cigarette smoke exposure, including second-hand smoke
- Physical inactivity
- Obstructive Sleep Apnea
- Positive family history
 - Heart attack, treated angina, interventions for coronary artery disease, stroke, or sudden cardiac disease in a male parent or sibling before age 55, or a female parent or sibling before age 65

High risk conditions associated with coronary artery disease before age 30:

- Diabetes (type 1 or 2)
- Chronic kidney disease
- Heart transplant recipients
- Kawasaki disease with persistent coronary aneurysms

Moderate risk conditions associated with evidence of accelerated atherosclerosis before age 30:

- Kawasaki disease with regressed coronary aneurysms
- Chronic inflammatory disease
- HIV infection
- Nephrotic syndrome
- Major depressive disorder and bipolar disorder

Routine screening recommended at health supervision visits by the AAP, the AHA and the NHLBI:

- Obtain history of diet, physical activity and possible smoke exposure
- Review the family history for premature coronary artery disease
- Identify conditions associated with higher risk of early atherosclerosis
- Measure blood pressure for every well-child visit over 3 years of age
 - Use tables for age, height and gender to establish patient's percentile
 - Confirm appropriate size blood pressure cuff
 - Normal: < 90th percentile
 - Prehypertension: \geq 90th percentile or 120/80 AND \leq 95th percentile
 - Stage 1 Hypertension: \geq 95th percentile to \leq 99th percentile + 5mm Hg
 - Stage 2 Hypertension: \geq 99th percentile + 5mm Hg
- Measure height and weight and calculate BMI

- Perform lipid screening at ages 9-11 AND ages 17-21 or every 3 years in children with a family history of early cardiovascular disease or a parent with high cholesterol
- Obtain a fasting blood sugar every 2 years in patients age 10 or older with a BMI above the 85th percentile and 2 additional risk factors for diabetes (family history of type 2 diabetes, ethnicity with a high risk for diabetes, signs of insulin resistance, or conditions with a high risk for diabetes such as Polycystic Ovary Syndrome)

Questions

- Define the categories of hypertension and review proper technique for diagnosing hypertension
- What other studies or physical exam maneuvers should the pediatrician do to evaluate for secondary hypertension?
- When should you refer to cardiology?

References

- De Ferranti SD, Newburger JW. "Risk factors and development of atherosclerosis in childhood." *UptoDateOnline.com*
- De Ferranti SD, Newburger JW. "Pediatric prevention of adult cardiovascular disease: promoting a healthy lifestyle and identifying at-risk children." *UptoDateOnline.com*
- De Ferranti SD, Newburger JW. "Overview of the management of the child at risk for atherosclerosis." *UptoDateOnline.com*
- "Defining Childhood Obesity." CDC Division of Nutrition, Physical Activity and Obesity. <http://www.cdc.gov/obesity/childhood/defining.html>. 2015.
- Expert Panel on Integrated Guidelines for Cardiovascular Health and Risk Reduction in Children and Adolescents, National Heart, Lung, and Blood Institute. Expert panel on integrated guidelines for cardiovascular health and risk reduction in children and adolescents: summary report. *Pediatrics* 2011; 128 Suppl 5:S213.
- National Cholesterol Education Program (NCEP): highlights of the report of the Expert Panel on Blood Cholesterol Levels in Children and Adolescents. *Pediatrics* 1992 Mar; 89(3): 495-501.

Definition of lipid levels in children from the 2011 Expert Panel Integrated Guidelines for Cardiovascular Health and Risk reduction in Children and Adolescents*

Category	Acceptable mg/dL (mmol/L)	Borderline mg/dL (mmol/L)	High ^Δ
TC	<170 (4.4)	170 to 199 (4.4 to 5.2)	≥200 (5.2)
LDL-C	<110 (2.8)	110 to 129 (2.8 to 3.3)	≥130 (3.4)
Non-HDL-C	<120 (3.1)	120 to 144 (3.1 to 3.7)	≥145 (3.8)
ApoB	<90 (2.3)	90 to 109 (2.3 to 2.8)	≥110 (2.8)
TG			
• 0 to 9 years	<75 (0.8)	75 to 99 (0.8 to 1.1)	≥100 (1.1)
• 10 to 19 years	<90 (1 mmol/L)	90 to 129 (1 to 1.5)	≥130 (1.5)
Category	Acceptable	Borderline	Low ^Δ
HDL-C	>45 (1.2)	40 to 45 (1 to 1.2)	<40 (1)
ApoA-1	>120 (3.1)	115 to 120 (3 to 3.1)	<115 (3)

TC: total cholesterol; LDL-C: low-density lipoprotein cholesterol; HDL-C: high-density lipoprotein; ApoB: apolipoprotein B; ApoA-1: apolipoprotein A-1; TG: triglycerides.

* Values for plasma lipid and lipoprotein levels are from the National Cholesterol Education Program (NCEP) Expert Panel on Cholesterol Levels in Children. Non-HDL-C values from the Bogalusa Heart Study are equivalent to the NCEP Pediatric Panel cut points for LDL-C. Values for plasma apoB and apoA-1 are from the National Health and Nutrition Examination Survey III (NHANES III).

Δ The threshold points for high and borderline-high values represent approximately the 95th and 75th percentiles, respectively. Low threshold points for HDL-C and apoA-1 represent approximately the 10th percentile.

Reproduced from: Daniels SR, Benuck I, Christakis DA, et al. Expert panel on integrated guidelines for cardiovascular health and risk reduction in children and adolescents: Full report, 2011. National Heart Lung and Blood Institute. Available at: http://www.nhlbi.nih.gov/guidelines/cvd_ped/peds_guidelines_full.pdf.

Causes of secondary dyslipidemia in children

Exogenous
Alcohol
Drug therapy
<ul style="list-style-type: none"> Corticosteroids Isotretinoin Beta-blockers Some oral contraceptives Select chemotherapeutic agents Select antiretroviral agents
Endocrine/Metabolic
<ul style="list-style-type: none"> Hypothyroidism/hypopituitarism Diabetes mellitus types 1 and 2 Pregnancy Polycystic ovary syndrome Lipodystrophy Acute intermittent porphyria
Renal
<ul style="list-style-type: none"> Chronic renal disease Hemolytic uremic syndrome Nephrotic syndrome
Infectious
<ul style="list-style-type: none"> Acute viral/bacterial infection* Human immunodeficiency virus (HIV) infection Hepatitis
Hepatic
<ul style="list-style-type: none"> Obstructive liver disease/cholestatic conditions Biliary cirrhosis Alagille syndrome
Inflammatory disease
<ul style="list-style-type: none"> Systemic lupus erythematosus Juvenile rheumatoid arthritis
Storage disease
<ul style="list-style-type: none"> Glycogen storage disease Gaucher's disease Cystine storage disease Juvenile Tay-Sachs disease Niemann-Pick disease
Other
<ul style="list-style-type: none"> Kawasaki disease Anorexia nervosa Solid organ transplantation Childhood cancer survivor Progeria Idiopathic hypercalcemia Klinefelter syndrome Werner's syndrome

* Delay measurement until ≥ 3 weeks postinfection.

Reproduced from: Daniels SR, Benuck I, Christakis DA, et al. Expert panel on integrated guidelines for cardiovascular health and risk reduction in children and adolescents: Full report, 2011. National Heart Lung and Blood Institute. Available at: http://www.nhlbi.nih.gov/guidelines/cvd_ped/peds_guidelines_full.pdf.

UpToDate®

Causes of secondary hypertension in children and adolescents

Renal disease	Psychologic causes
Pyelonephritis	Mental stress
Renal parenchymal disease	Anxiety
Congenital anomalies	Pharmacologic causes
Reflux nephropathy	Sympathomimetics
Acute glomerulonephritis	Corticosteroids
Henoch-Schönlein purpura	Stimulants
Renal trauma	Oral contraceptives
Hydronephrosis	Anabolic steroids
Hemolytic uremic syndrome	Cocaine
Renal stones	Phencyclidine (PCP)
Nephrotic syndrome	Licorice
Wilm's tumor	Nicotine
Hypoplastic kidney	Caffeine
Polycystic kidney disease	Vascular disease
Endocrine disease	Renal artery abnormalities
Hyperthyroidism	Renal vein thrombosis
Congenital adrenal hyperplasia	Coarctation of the aorta
Cushing syndrome	Patent ductus arteriosus
Primary aldosteronism	Arteriovenous fistula
Primary hyperparathyroidism	Other causes
Diabetes mellitus	Neuroblastoma
Hypercalcemia	Heavy metal poisoning
Pheochromocytoma	Acute pain
Neurologic causes	Collagen vascular diseases
Increased intracranial pressure	Neurofibromatosis
Guillain-Barré syndrome	Tuberous sclerosis

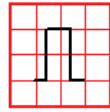
Data from:

1. Tunnessen WW, Roberts KB. Hypertension. In: *Signs and Symptoms in Pediatrics, 3rd ed*, Lippincott, Williams & Wilkins, Philadelphia 1999. p.413.
2. Pappadis SL, Somers MJ. Hypertension in adolescents: a review of diagnosis and management. *Curr Opin Pediatr* 2003; 15:370.

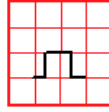
UpToDate®

Steps to Interpreting the Pediatric ECG

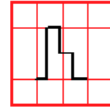
Is the ECG full standard? Full standard: ECG amplitudes were not reduced in size to fit on the paper. Half standard: amplitudes are displayed at half the size; must multiply by 2 to normalize them. Full/Half: limb leads (I, II, III, aVR, aVL, aVF) are full standard, while chest leads (V1 – V6) are half standard.



Full



Half



Full/Half

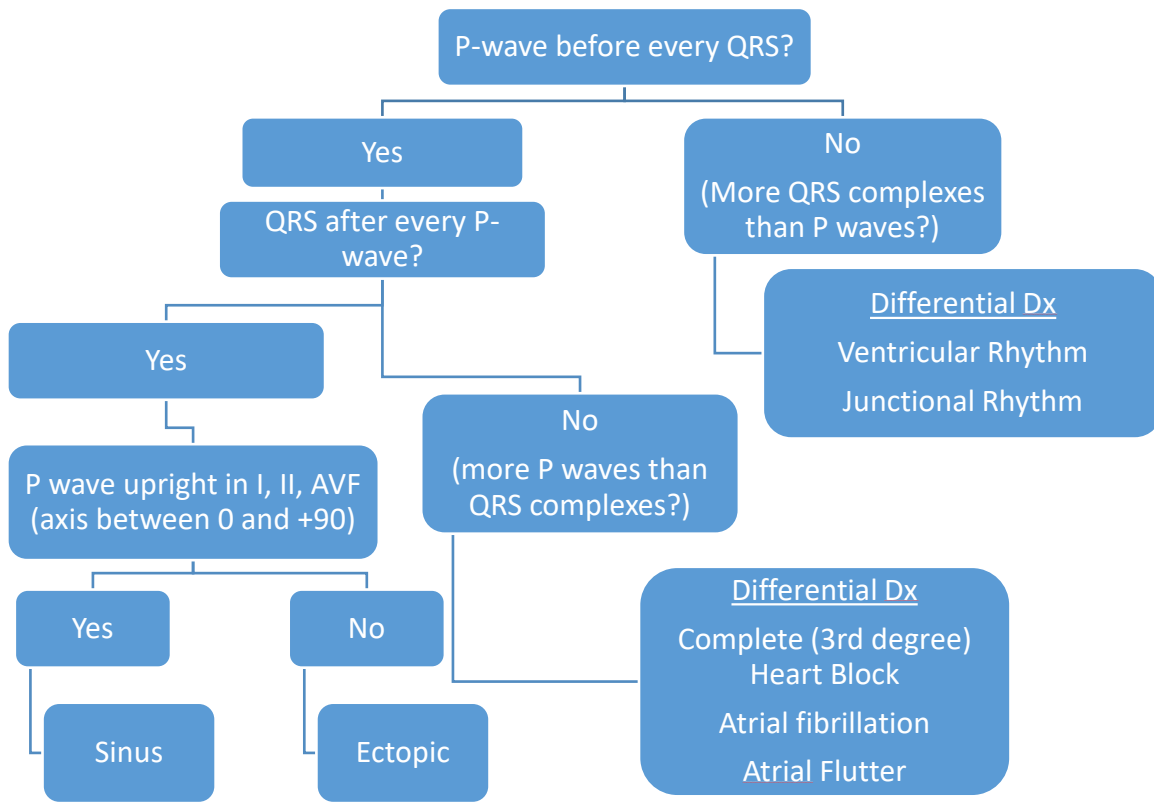
Heart rate

- $HR = 300 / (\# \text{ of big boxes between one R-R interval})$
- **Quick rule - If RR interval:** 1 big box ~ 300 bpm, 2 big boxes ~ 150 bpm, 3 big boxes ~ 100 bpm, 4 big boxes ~ 75 bpm, 5 big boxes ~ 60 bpm
- Tachycardia/Bradycardia/Normal based on age

Is the ECG standard speed (25 mm/sec)? If yes:

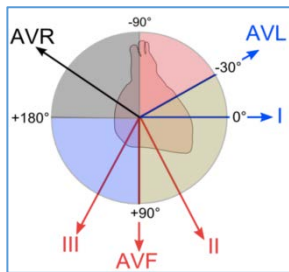
- Little box (1mm) = 0.04 seconds
- Big box (5 mm) = 0.2 seconds

Rhythm

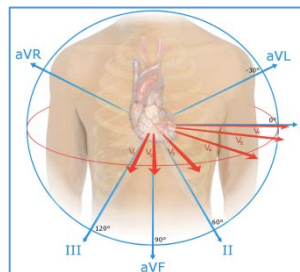


Axis

- Normal P wave axis: 0 to +90
- Normal QRS axis: -15 to +180
 - Determine what quadrant the QRS axis is in by using leads I and AVF (i.e. positive in I and AVF = right lower quadrant, 0 to +90)
 - Determine isoelectric lead. QRS axis is perpendicular to the isoelectric lead, and should fall within the quadrant determined in Step 1. (e.g. if isoelectric lead is AVL, QRS axis will be +60)
 - I negative, avF negative = Northwest axis (AV Canal Defect, Tricuspid Atresia, lead transposition, occasionally WPW)



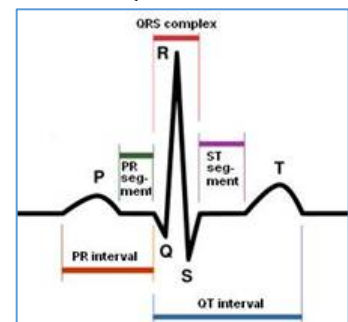
www.rebelem.com/ecg-basics/



By Nicholas Patchett [CC BY-SA 4.0
(<http://creativecommons.org/licenses/by-sa/4.0/>)]

Intervals (See table below)

- PR interval (~120 ms)
 - Prolonged (>200ms) – 1st degree AV block
 - Short (< 80ms) – possible WPW (if delta wave present and no q waves)
- QRS complex (Normal dependent on age, <80msec kids, 80-120msec adults)
- QT interval (~340 ms to 420 ms)
 - QTc (dependent on HR, Males < 450 ms, Females < 460 ms)
 - Bazett's Formula: $QTc = \frac{QT}{\sqrt{R-R}}$, where R-R interval is the one that precedes the measured QT.
 - Short (<350ms): associated with channelopathy
 - Use JTc* if QRS is wide at baseline



Morphology

P waves

- Right atrial enlargement (RAE): peaked P waves >2.5 mV
- Left atrial enlargement (LAE): Biphasic P-wave in V1 or > 0.10 s duration of the P-wave in the limb leads

QRS Complex

Right ventricular hypertrophy (RVH)

- Right axis deviation for age (see table below)
- Voltages: Tall R wave in V1 or V2 >25 mV -AND- Deep S wave in V5 or V6 >25 mV
- rSR' in V1
- Positive T-wave in V1 or right lateral leads (V3R, V4R) in kids 7d-7yo*
- Pure QR wave in V1 or right lateral leads*
- Pure R wave in right lateral leads (>10 mm in newborns)*

*Absolute criteria for diagnosis of RVH

QRS Complex

Left ventricular hypertrophy (LVH)

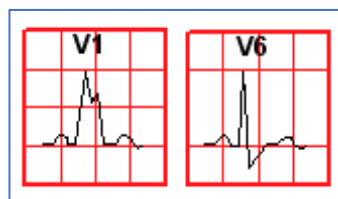
- Left axis deviation
- Voltages: Deep S wave in V1 or V2 >25 mV -AND- Tall R wave in V5 or V6 >25 mV
- LVH with "strain" pattern (T wave inversion or J-point depression in lead I, V5-V6)
- Q waves in inferior leads (II, III, AVF) and V5-V6

QRS Complex

○ Right Bundle Branch Block (RBBB):

- Broad, POSITIVE R-wave in V1, NEGATIVE S-wave in I and V5-6
- rsR' in R precordial leads (V1, V2)
- QRS interval must be prolonged

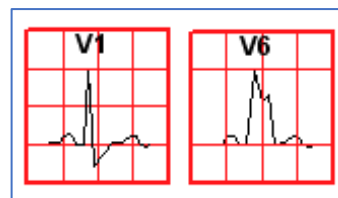
RBBB



○ Left Bundle Branch Block (LBBB)

- Broad, NEGATIVE Q-wave in V1, POSITIVE R-wave in V5-6
- In lead V1, predominantly negative deflection
- QRS interval must be prolonged

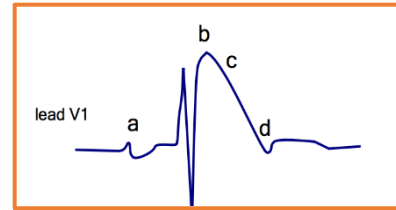
LBBB



QRS Complex

Brugada

- Incomplete RBBB + ST-segment elevation V1-V3 + T wave inversion. Can cause cardiac arrest.
 - a) Broad P wave with PQ prolongation
 - b) J point elevation
 - c) Coved ST segment elevation
 - d) Inverted T wave



T waves

- 0-7days: T waves upright in V1-V6
- 7days-7yo: T wave inversion in V1-V3 (if TW upright, suspect RVH)
- Teens: T waves in V1-V3 may become upright or stay inverted ("Persistent juvenile T wave inversion," benign)
- After 20 years of age: T waves upright in V1-V3 (if T waves inverted, suspect ischemia)
- **T-waves are ALWAYS upright in inferior (II, III, and AVF) and lateral leads (I, V4-V6) at any age (inversion concerning for LVH with strain)**
- **TWI in inferior limb leads (II, III, AVF) are pathological (suspect ischemia)**

Q waves

- Represent septal depolarization
- Pathologic Q waves are >1 small box wide and 5 small boxes deep in two contiguous leads = concern for ischemia.
 - Pathologic Q waves in II, III, AVF = concern for inferior MI
 - Pathologic Q waves in I and AVL, and V4-V6 = concern for ALCAPA

ST Segments

- ST segment elevation (>1mm) is supportive of ischemia
- T wave inversion and ST Depressions (≥ 1 mm in ≥ 2 associated leads)
- Evolution of EKG changes in ST-elevation myocardial infarctions
 - Earliest: ST elevation and hyperacute (very tall or deeply negative) T-waves
 - Hours-days: T wave inversion
 - Days-weeks: Possible resolution of QRS and T-wave changes. Persistent ST segment elevation are not only seen with full-thickness scars but also with areas of persistent dyskinesis.

Pediatric ECG: normal values by age								
Age	HR (bpm)	QRS axis (degrees)	PR interval (sec)	QRS interval (sec)	R in V1 (mm)	S in V1 (mm)	R in V6 (mm)	S in V6 (mm)
1st wk	90–160	60–180	0.08–0.15	0.03–0.08	5–26	0–23	0–12	0–10
1–3 wk	100–180	45–160	0.08–0.15	0.03–0.08	3–21	0–16	2–16	0–10
1–2 mo	120–180	30–135	0.08–0.15	0.03–0.08	3–18	0–15	5–21	0–10
3–5 mo	105–185	0–135	0.08–0.15	0.03–0.08	3–20	0–15	6–22	0–10
6–11 mo	110–170	0–135	0.07–0.16	0.03–0.08	2–20	0.5–20	6–23	0–7
1–2 yr	90–165	0–110	0.08–0.16	0.03–0.08	2–18	0.5–21	6–23	0–7
3–4 yr	70–140	0–110	0.09–0.17	0.04–0.08	1–18	0.5–21	4–24	0–5
5–7 yr	65–140	0–110	0.09–0.17	0.04–0.08	0.5–14	0.5–24	4–26	0–4
8–11 yr	60–130	–15–110	0.09–0.17	0.04–0.09	0–14	0.5–25	4–25	0–4
12–15 yr	65–130	–15–110	0.09–0.18	0.04–0.09	0–14	0.5–21	4–25	0–4
>16 yr	50–120	–15–110	0.12–0.20	0.05–0.10	0–14	0.5–23	4–21	0–4

Courtesy of Ra'id Abdullah, MD, University of Chicago, Illinois.

TABLE I Age and Rate-Related Normal Pediatric JT Intervals

	Months				Years					All
	<1	1–3	4–6	7–12	1–3	4–6	7–10	11–15	15–18	
Number of patients	100	120	120	100	120	110	110	120	100	1,000
Intervals (s)										
JT	0.21	0.21	0.21	0.22	0.23	0.24	0.27	0.28	0.26	0.23 ± 0.04
JTc	0.32	0.32	0.32	0.32	0.32	0.32	0.32	0.32	0.31	0.32 ± 0.02
RR	0.41	0.41	0.45	0.48	0.52	0.60	0.72	0.76	0.70	0.60 ± 0.17

s = second.

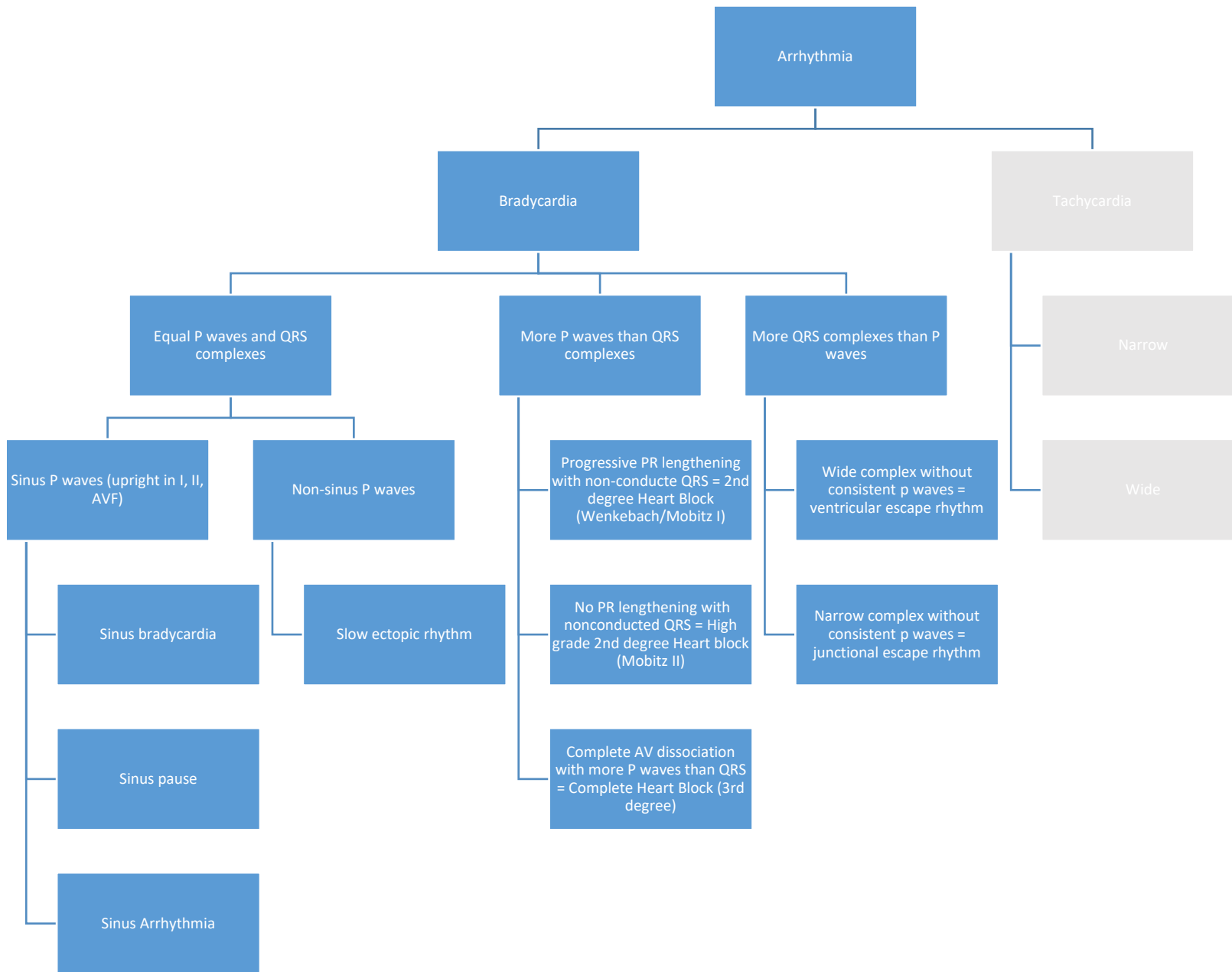
* **JTc**: For patients with long QRS duration (e.g. RBBB), best to calculate the "JTc." Measure the J-point (when the QRS first comes back to baseline) to the end of the T-wave. Then calculate JT/VRR. (Berul et al. Amer Journal of Cardiology. 74: 1254-57)

References:

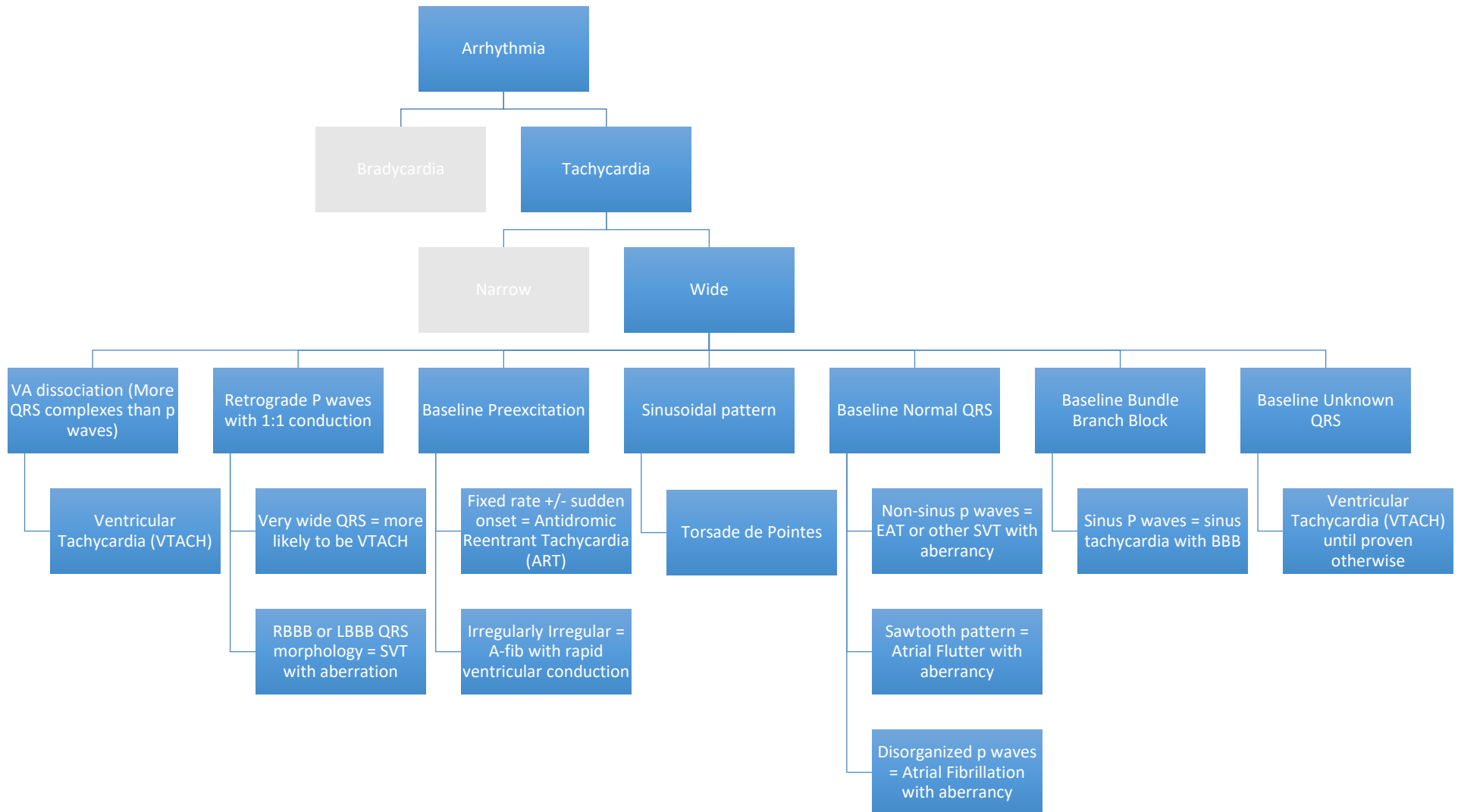
Park, Myung K., and Warren G. Guntheroth. *How to Read Pediatric ECGs*. 4th ed. Philadelphia: Mosby/Elsevier, 2006.

Robinson, Bradley, Paul Anisman, and Eshagh Eshaghpour. "A Primer on Pediatric ECGs." [In English]. *Contemporary Pediatrics* 11 (1994): 69-96.

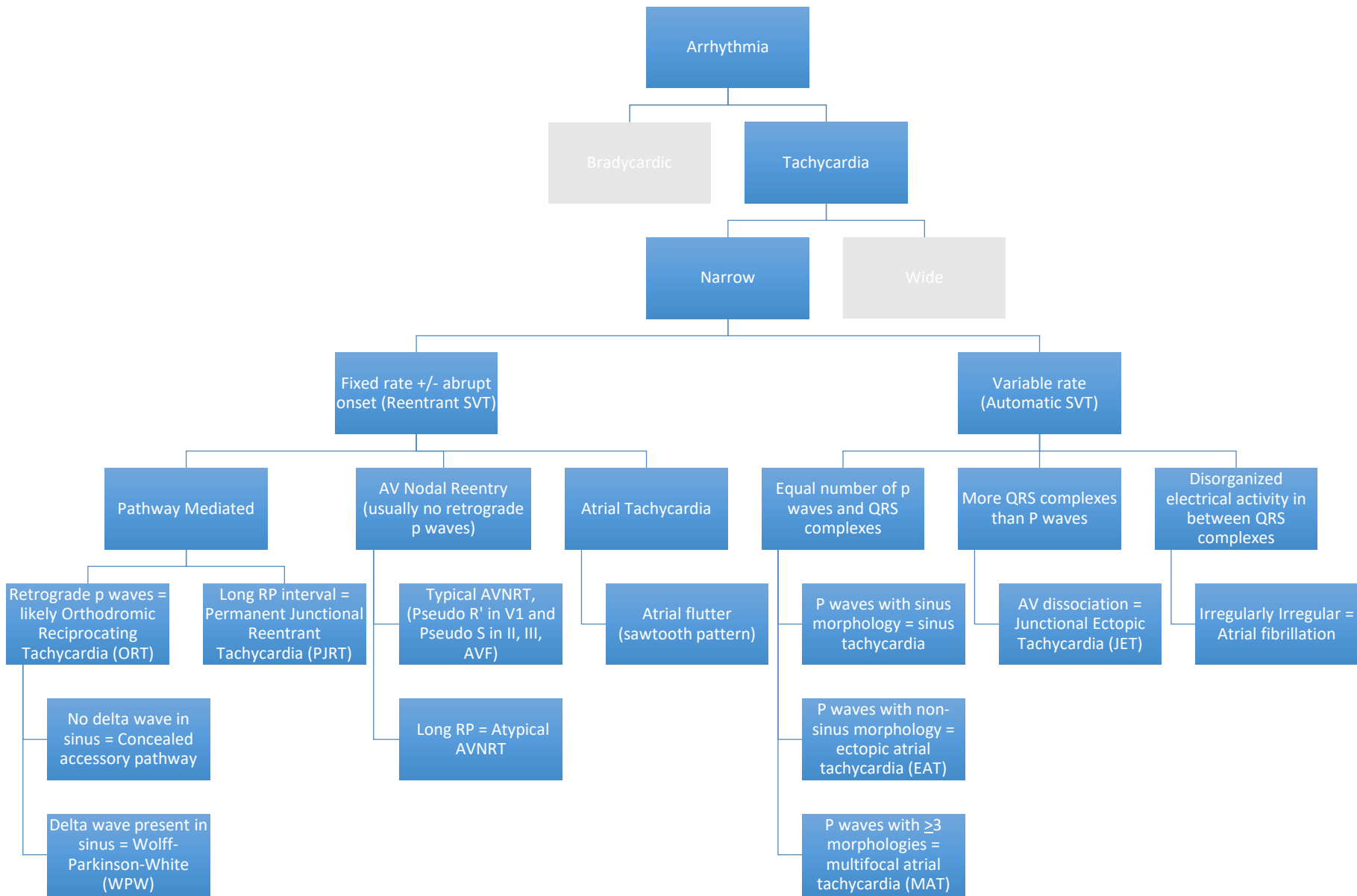
Bradycardia Algorithm



Wide Complex Tachycardia Algorithm

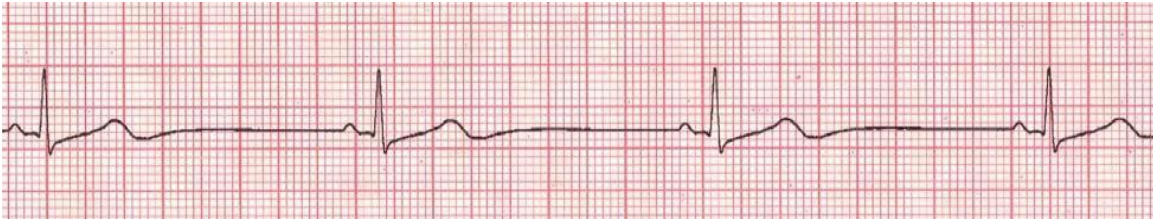


Narrow Complex Tachycardia Algorithm



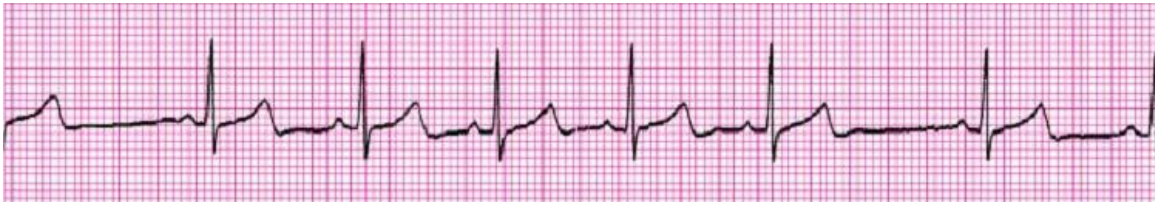Sinus Node Arrhythmias

Sinus Bradycardia



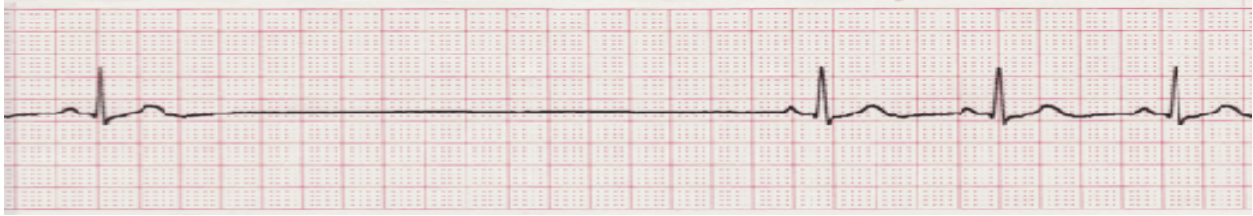Features	Causes	Management
<ul style="list-style-type: none"> • P wave before every QRS • Normal P wave axis • Rate is slower than expected for age range 	<ul style="list-style-type: none"> • Generally benign, especially in athletes or overnight • Sinus node dysfunction, Anorexia, medication-related (beta blockers, Lithium, Digitalis), hypothyroidism, Cushing triad, hyperkalemia, hypothermia, myocarditis 	<ul style="list-style-type: none"> • If no underlying cause, unlikely to need treatment • Should evaluate rate response to activity to assess sinus node function

Sinus Arrhythmia



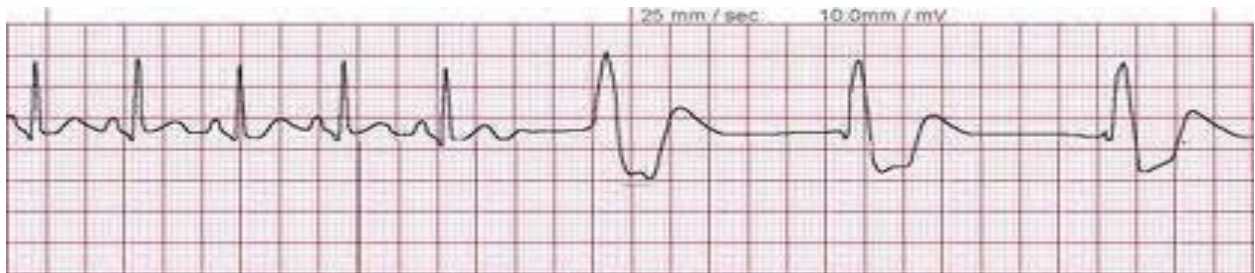Features	Causes	Management
<ul style="list-style-type: none"> • P wave before every QRS • Normal P wave axis • Rate varies with inspiration and expiration 	<ul style="list-style-type: none"> • Benign, related to inspiration and expiration 	<ul style="list-style-type: none"> • No intervention necessary • If more than 100% variation in rate (60 to 120bpm), consider other etiologies

Sinus Pauses



Features	Causes	Management
<ul style="list-style-type: none"> • P wave before every QRS • Normal P wave axis • Abrupt pause with no P wave 	<ul style="list-style-type: none"> • Breath-holding spells • Increased vasovagal/autonomic tone (intubated state, newborn, etc) 	<ul style="list-style-type: none"> • Resolution of underlying cause of increased vagal tone • Unlikely to need intervention unless frequent syncope

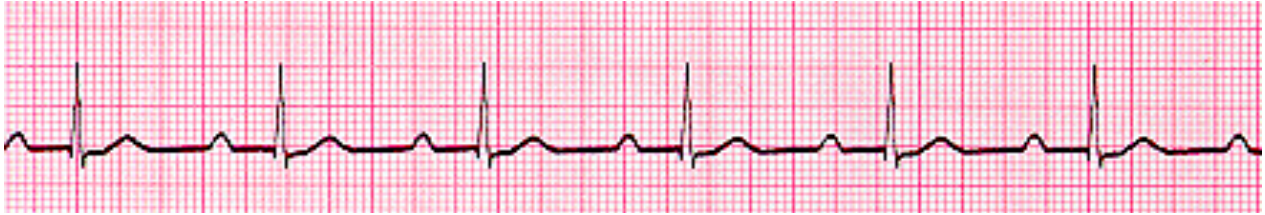Ventricular escape rhythm



Features	Causes	Management
<ul style="list-style-type: none"> • Slow, wide-complex rhythm • AV Dissociation • Few P waves or sinus pauses with regular rate of ventricular rhythm 	<ul style="list-style-type: none"> • Always pathologic • Myocarditis, sick sinus syndrome, accelerated ventricular rhythm 	<ul style="list-style-type: none"> • If no reversible cause, would recommend permanent pacemaker, especially if function affected

AV Node Dysfunction

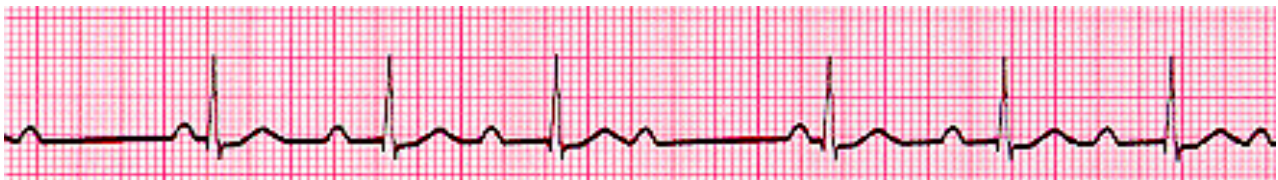1st degree heart block



Features	Causes	Management
<ul style="list-style-type: none">• Prolonged PR interval (based on age)	<ul style="list-style-type: none">• Can be normal• Increased vagal tone• Rheumatic fever, Ebstein's, AVSDs, medications, abnormal electrolytes	<ul style="list-style-type: none">• Usually no clinical significance

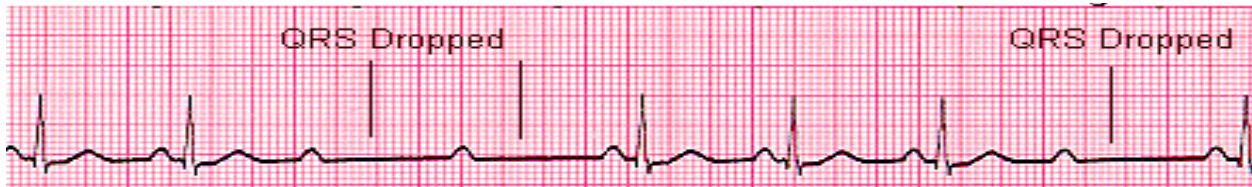2nd degree Heart block

Mobitz Type I (Wenckebach)



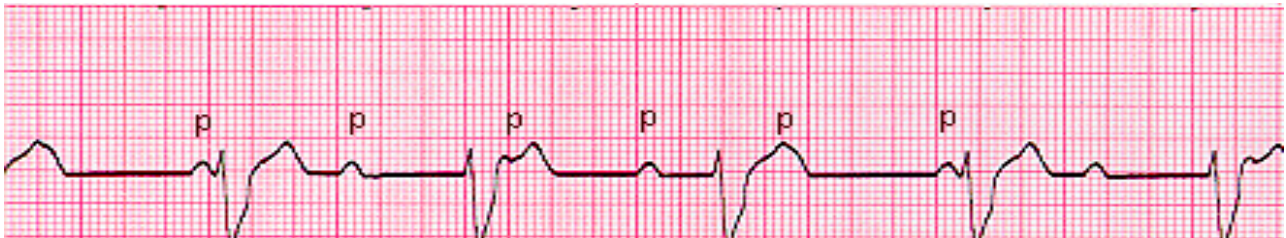Features	Causes	Management
<ul style="list-style-type: none">• Progressive prolongation of PR intervals• Progressive shortening of RR interval• Eventual dropped QRS after P wave	<ul style="list-style-type: none">• Can be normal• Increased vagal tone or during sleep• May be due to delayed conduction in AV node, or within or below His bundle	<ul style="list-style-type: none">• If physiologic, no intervention• If happens during exercise, considered pathologic

Mobitz Type II



Features	Causes	Management
<ul style="list-style-type: none"> Constant P-P interval without prolongation of PR interval and sudden non-conducted P wave 	<ul style="list-style-type: none"> Always pathologic; conduction defect below bundle of His Most common: myocarditis, post-surgical, rejection 	<ul style="list-style-type: none"> If no reversible cause, would recommend permanent pacemaker Acute: if hypotensive, consider isuprel or atropine Chronic: Consider pacemaker

3rd Degree Heart block (Complete AV block)



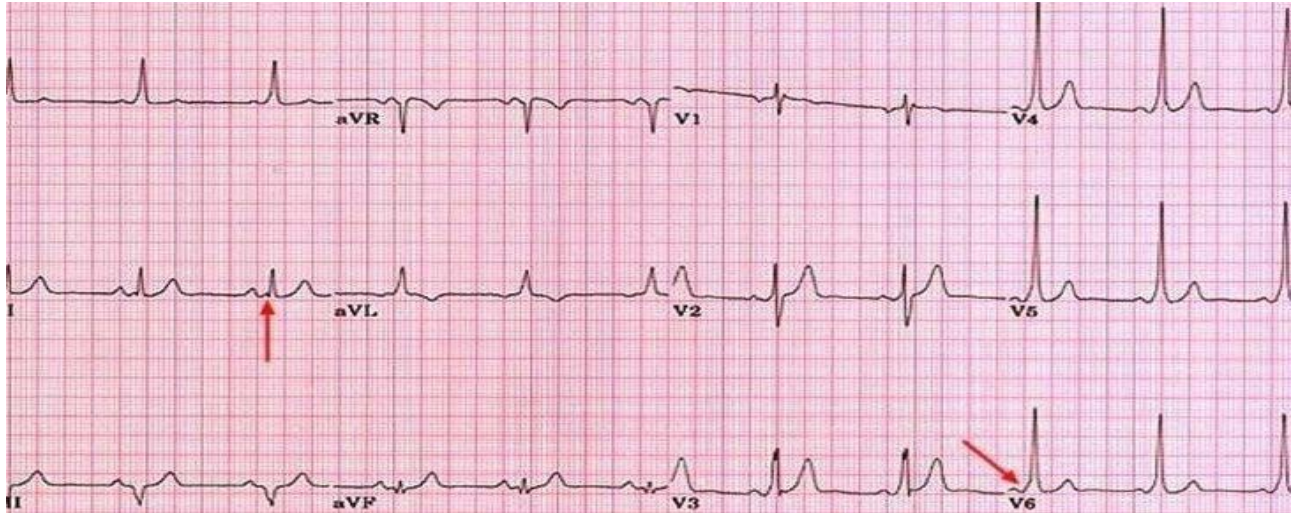
Features	Causes	Management
<ul style="list-style-type: none"> Complete AV dissociation More P waves than QRS complexes 	<ul style="list-style-type: none"> Structural cardiac disease, maternal autoimmune connective tissue disorders causing congenital heart block, post-surgical, infections, myopathies, genetic disorders 	<ul style="list-style-type: none"> Newborn with HR <55 and structurally normal heart will get pacemaker. With CHD, if <70, will also get pacemaker. If asymptomatic in older children, Holter for eval of sinus pauses, exercise test to eval for Vtach, echo for chamber dilation In post-surgical patients, will require temporary pacing for 7-14 days to evaluate for resolution prior to pacemaker placement

Narrow Complex Arrhythmias (Supraventricular Tachycardia)

These are the most common symptomatic arrhythmias in children. There is usually a bimodal distribution, with peaks in the <1 year period, and again during adolescence. 40-60% of SVT diagnosed as an infant will resolve by 1 year of life.

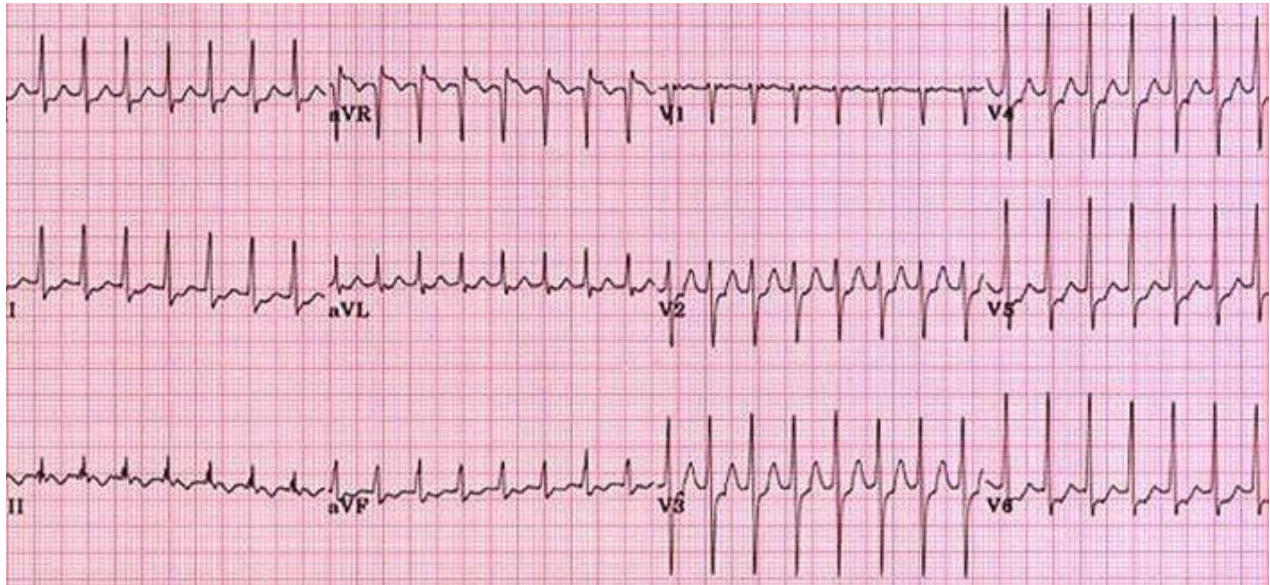
Orthodromic Reentrant Tachycardia

Wolff-Parkinson-White



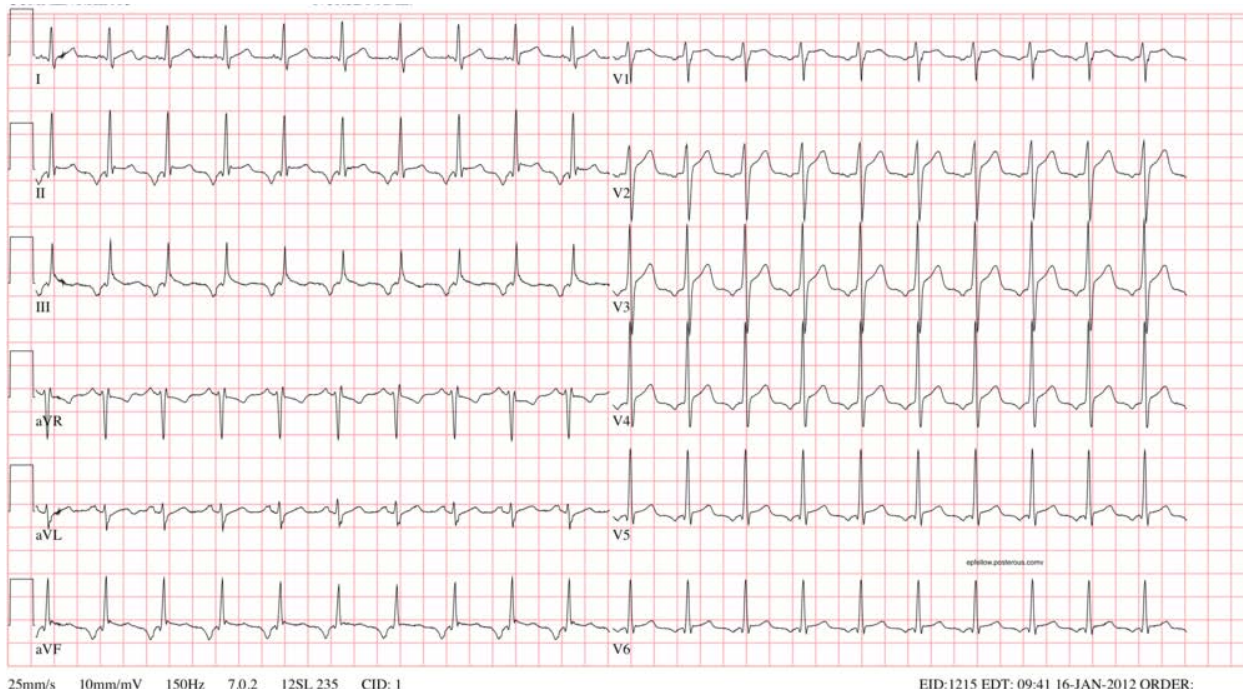
Features	Causes	Management
<p>In sinus rhythm:</p> <ul style="list-style-type: none"> • Short PR interval • Delta wave • Longer QRS than normal for age <p>In Tachycardia:</p> <ul style="list-style-type: none"> • May have retrograde p waves between QRS and T-waves • Abrupt onset and resolution 	<ul style="list-style-type: none"> • Conduction is antegrade through AV node and retrograde through accessory pathway in a cycle • Pathway can conduct antegrade and retrograde <p>Associations:</p> <ul style="list-style-type: none"> • Ebstein's Anomaly • L-TGA • HCM • Tuberous sclerosis • Glycogen storage disease 	<ul style="list-style-type: none"> • If asymptomatic – plan for risk stratification with exercise test. If loss of delta wave, considered low risk. • Acute: Vagal maneuvers, Adenosine, Procainamide gtt • Hemodynamically Unstable: Direct synchronized cardioversion at 0.5 – 1 J/Kg. • Chronic: If symptomatic, can treat with beta blockers and eventual ablation if still frequent or high risk. • At risk of sudden death if A-fib can conduct through pathway to cause V-fib (not possible in all patients with WPW) – Cardioversion in these situations. • Avoid digoxin

Concealed Accessory Pathway



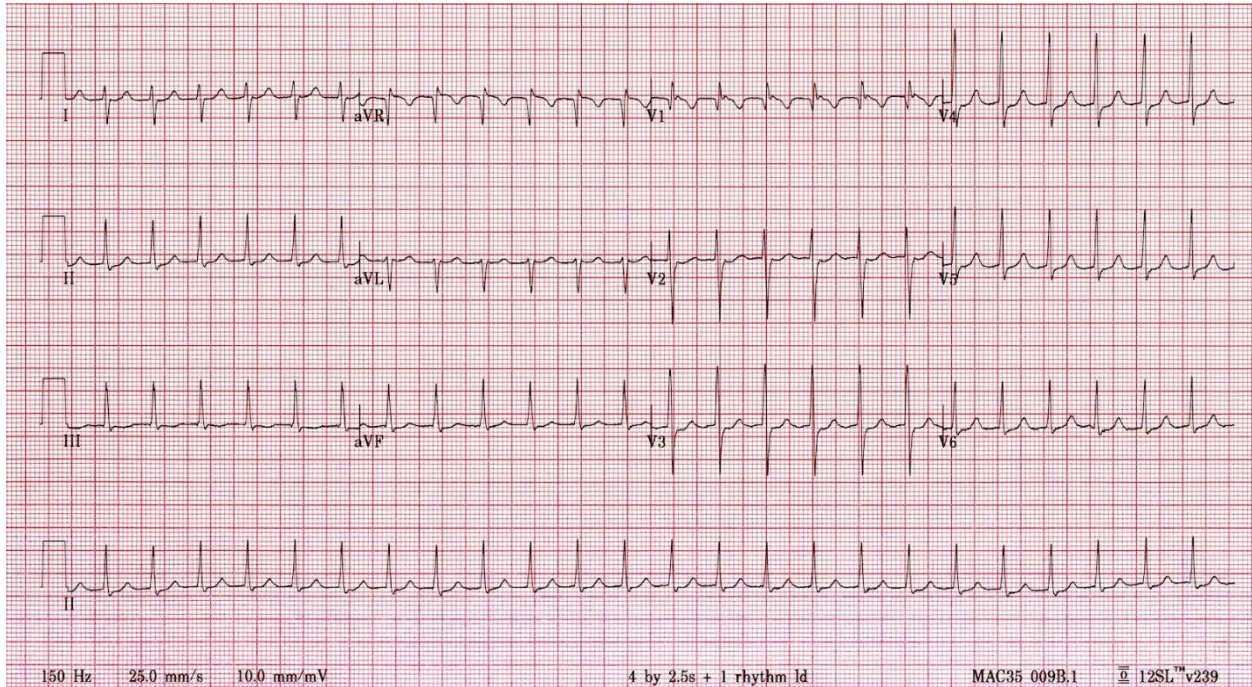
Features	Causes	Management
<p>In sinus rhythm:</p> <ul style="list-style-type: none"> • Normal EKG <p>In Tachycardia:</p> <ul style="list-style-type: none"> • May have retrograde p waves between QRS and T-waves • Abrupt onset and resolution 	<ul style="list-style-type: none"> • Conduction is antegrade through AV node and retrograde through accessory pathway in a cycle • Pathway only conducts retrograde 	<ul style="list-style-type: none"> • Low risk of sudden death since pathway does not conduct antegrade • Acute: Vagal maneuvers, Adenosine, Procainamide gtt • Chronic: If symptomatic, can treat with beta blockers and future ablation

Permanent Junctional Reciprocating Tachycardia (PJRT)



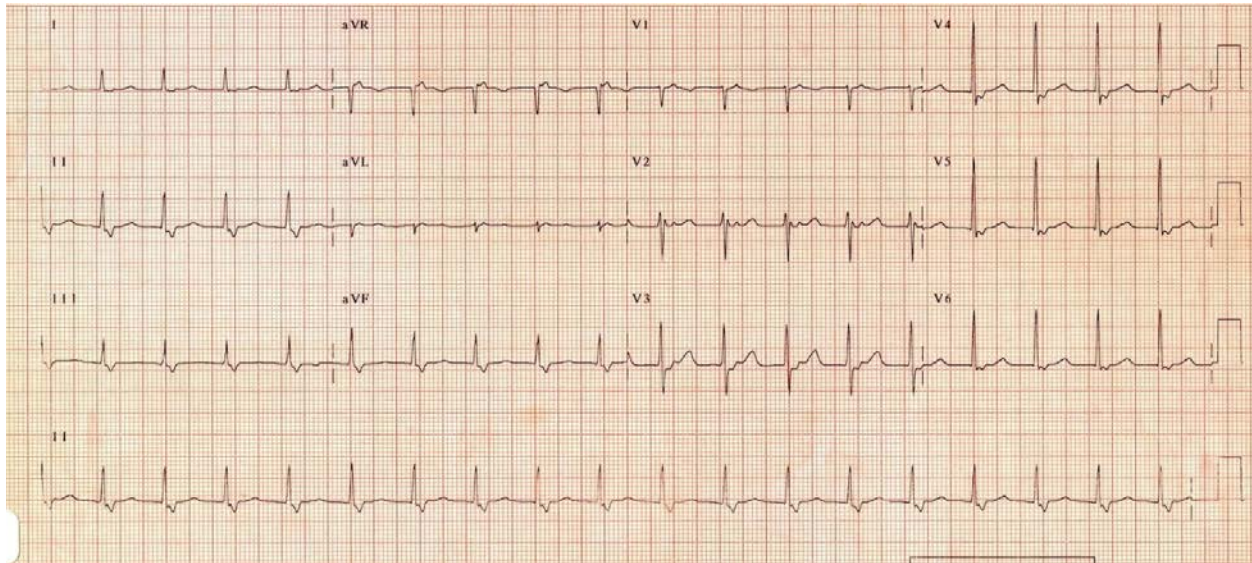
Features	Causes	Management
<p>In sinus rhythm:</p> <ul style="list-style-type: none"> • Normal EKG <p>In Tachycardia:</p> <ul style="list-style-type: none"> • “Long RP tachycardia,” where p wave is visible past the halfway point of the RR interval • P waves are deeply negative in II, III, and aVF • Relatively “slow” tachycardia • Abrupt onset and resolution 	<ul style="list-style-type: none"> • Conduction is antegrade through AV node and retrograde through a <u>slowly</u> conducting accessory pathway in a cycle • Pathway only conducts retrograde 	<ul style="list-style-type: none"> • No risk of sudden death since pathway does not conduct antegrade • Can be incessant and lead to tachycardia-induced cardiomyopathy • Acute: Vagal maneuvers, Adenosine • Chronic: If symptomatic, can treat with beta blockers and future ablation

AV Nodal Reentrant Tachycardia (AVNRT)



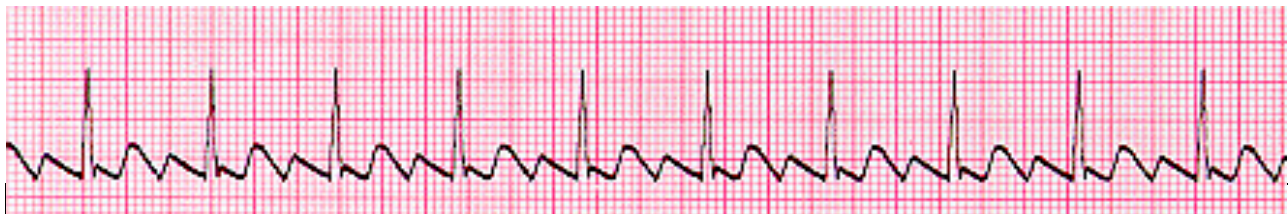Features	Causes	Management
<p>In sinus rhythm:</p> <ul style="list-style-type: none"> • Normal EKG <p>In Tachycardia:</p> <ul style="list-style-type: none"> • P waves likely buried in T wave • If visible, may be as "pseudo R prime" wave in lead V1 or a "pseudo S" wave in the inferior leads. • Abrupt onset and resolution 	<ul style="list-style-type: none"> • Conduction is antegrade through slow pathway of AV node and retrograde through fast pathway creating cycle within AV node 	<ul style="list-style-type: none"> • Acute: Vagal maneuvers, Adenosine • Chronic: If symptomatic, can treat with beta blockers and future ablation

Atypical AVNRT



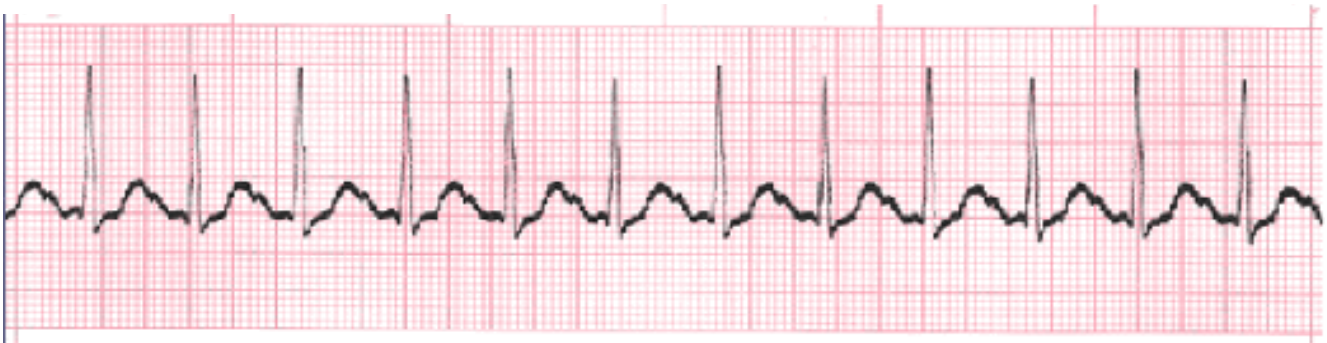Features	Causes	Management
<p>In sinus rhythm:</p> <ul style="list-style-type: none"> • Normal EKG <p>In Tachycardia:</p> <ul style="list-style-type: none"> • "Long RP tachycardia," where p wave is visible past the halfway point of the RR interval • Abrupt onset and resolution 	<ul style="list-style-type: none"> • Conduction is antegrade through fast pathway of AV node and retrograde through slow pathway in a cycle 	<ul style="list-style-type: none"> • Acute: Vagal maneuvers, Adenosine, Procainamide gtt • Chronic: If symptomatic, can treat with beta blockers and future ablation

Atrial Flutter



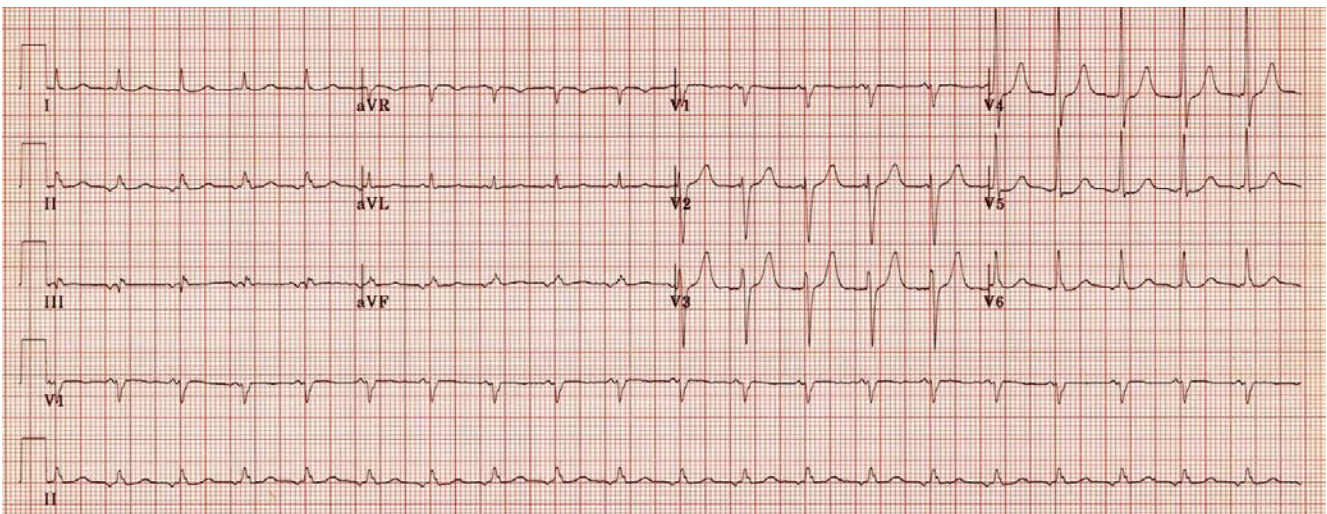
<ul style="list-style-type: none"> • "Sawtooth pattern," seen predominantly in II, III, AVF, V1 • Ventricular rate can be variable, 1:1, 2:1, etc. • Abrupt onset • Can have a wide complex presentation as well 	<ul style="list-style-type: none"> • Rapid atrial depolarization • Post-surgical • Patients with atrial dilation 	<ul style="list-style-type: none"> • Initial: Adenosine can be given to reveal flutter waves and confirm diagnosis • Acute: To treat, synchronized cardioversion at 0.5 to 1 J/kg. • Chronic: rare to have chronic a-flutter
--	---	---

Sinus Tachycardia



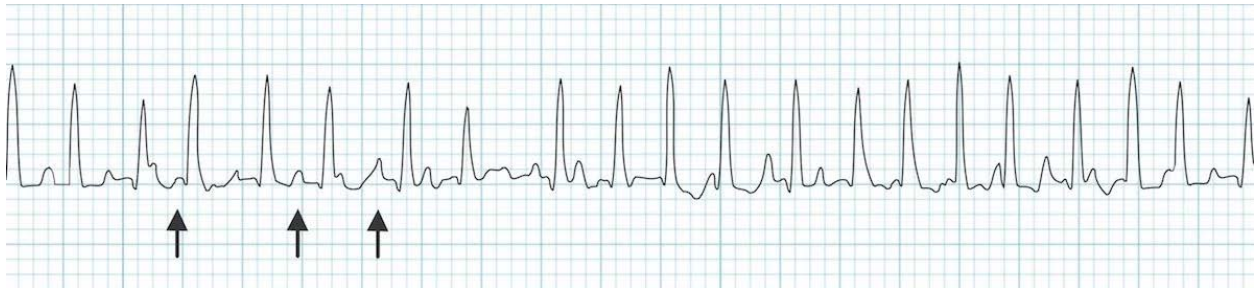
Features	Causes	Management
<ul style="list-style-type: none"> • P wave before every QRS • P wave has normal axis • P wave may be partially slurred with T wave • Gradual warm-up and cool-down phase 	<ul style="list-style-type: none"> • Fever, infection/sepsis, agitation, pain, dehydration, anemia, etc. 	<ul style="list-style-type: none"> • Evaluation for various underlying causes and treatment of those

Ectopic Atrial Tachycardia (EAT)



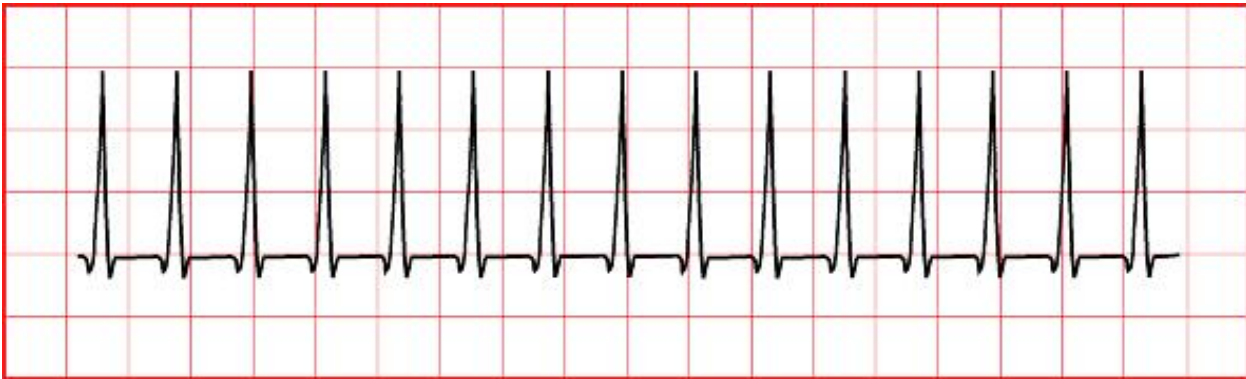
Features	Causes	Management
<ul style="list-style-type: none"> • “Long RP tachycardia,” where P wave is after the halfway point between the RR interval. • P waves precede every QRS • Abnormal axis, often different morphology than sinus • Gradual warm-up and cool-down phase 	<ul style="list-style-type: none"> • Abnormal focus in atria that allows atria to depolarize before sinus node • Post-surgical, inflammatory state, fevers, increase in catecholamines 	<ul style="list-style-type: none"> • Can be incessant and lead to tachycardia-induced cardiomyopathy • Diagnosis: Adenosine usually will not stop arrhythmia. • If post surgical: can rapid atrially pace or cardiovert. • Chronic: can try beta-blockade, eventual ablation if persists

Multifocal Atrial Tachycardia (MAT)



Features	Causes	Management
<ul style="list-style-type: none"> • Three or more p wave morphologies • Rapid and chaotic tachycardia; can look similar to atrial fibrillation 	<ul style="list-style-type: none"> • Multiple foci of atrial signals • Seen often in structurally normal hearts, as well as acute bronchiolitis or advanced pulmonary disease 	<ul style="list-style-type: none"> • Can be difficult to treat with pacing, cardioversion, or adenosine. Also not amenable to ablation often. • Chronic: Rate control or Potassium channel blockers

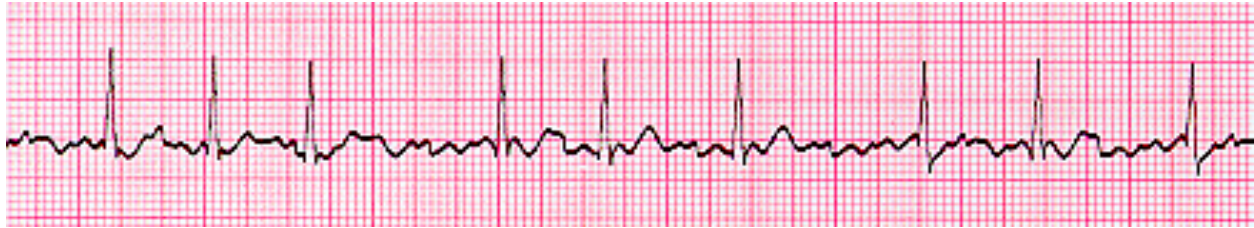Junctional Ectopic Tachycardia (JET)



<http://www.pedcard.rush.edu/mp/ECG/regular-fastlrate-normalQRS-nop.htm>

Features	Causes	Management
<ul style="list-style-type: none"> • QRS is identical to sinus rhythm • AV Dissociation • May see retrograde p waves 	<ul style="list-style-type: none"> • Post-surgical, especially in those with VSD patches • Familial/Congenital JET (very rare) 	<ul style="list-style-type: none"> • Can be incessant and lead to tachycardia-induced cardiomyopathy • Post-surgical: Cooling, weaning pressors, increasing sedation, temporary pacing above JET rate

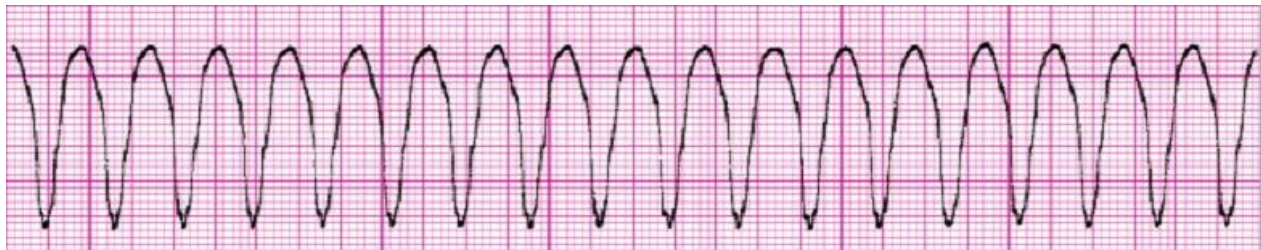Atrial Fibrillation



Features	Causes	Management
<ul style="list-style-type: none"> Irregularly Irregular rhythm QRS complex is similar to that of sinus rhythm Very disorganized P waves with variable conduction Can have a wide complex presentation as well 	<ul style="list-style-type: none"> Multiple foci firing at once within atria. Can happen in WPW, post Glenn, post Mustard or Senning Hyperthyroidism, myocarditis, digoxin toxicity 	<ul style="list-style-type: none"> If there is a pathway and conducts to V-fib, can result in sudden death. Acute: Direct cardioversion (if <48 hours) If >48 hours, initiate anticoagulation first Refractory: Can consider AV node ablation and pacemaker placement (rare)

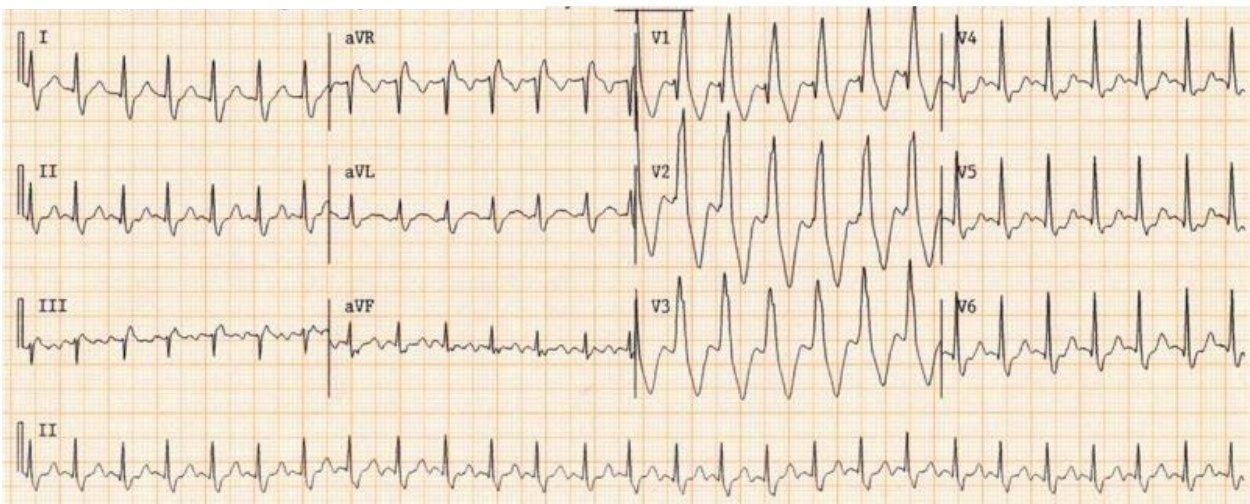
Wide Complex Tachycardias

Ventricular Tachycardia



Features	Causes	Management
<ul style="list-style-type: none"> More than 3 PVCs in a row at a rate faster than 120 bpm (if slower, can be considered an accelerated ventricular rhythm) AV Dissociation with more QRS complexes than P waves Wide QRS, usually monomorphic, but can be polymorphic Usually abrupt onset 	<ul style="list-style-type: none"> Cardiomyopathies, RVOT VT (benign variant), Idiopathic Left VT (benign variant), myocarditis, prolonged QT syndrome, Catecholamine sensitive polymorphic VT (CPVT), medication toxicity, Arrhythmogenic ventricular cardiomyopathy (ARVC), coronary artery abnormalities, post-surgical 	<ul style="list-style-type: none"> Depends on underlying cause Primary prevention in patients with channelopathies or cardiomyopathies Asymptomatic: beta blockers Decreased function: Can consider ablation Sustained or hemodynamically unstable: ICD placement

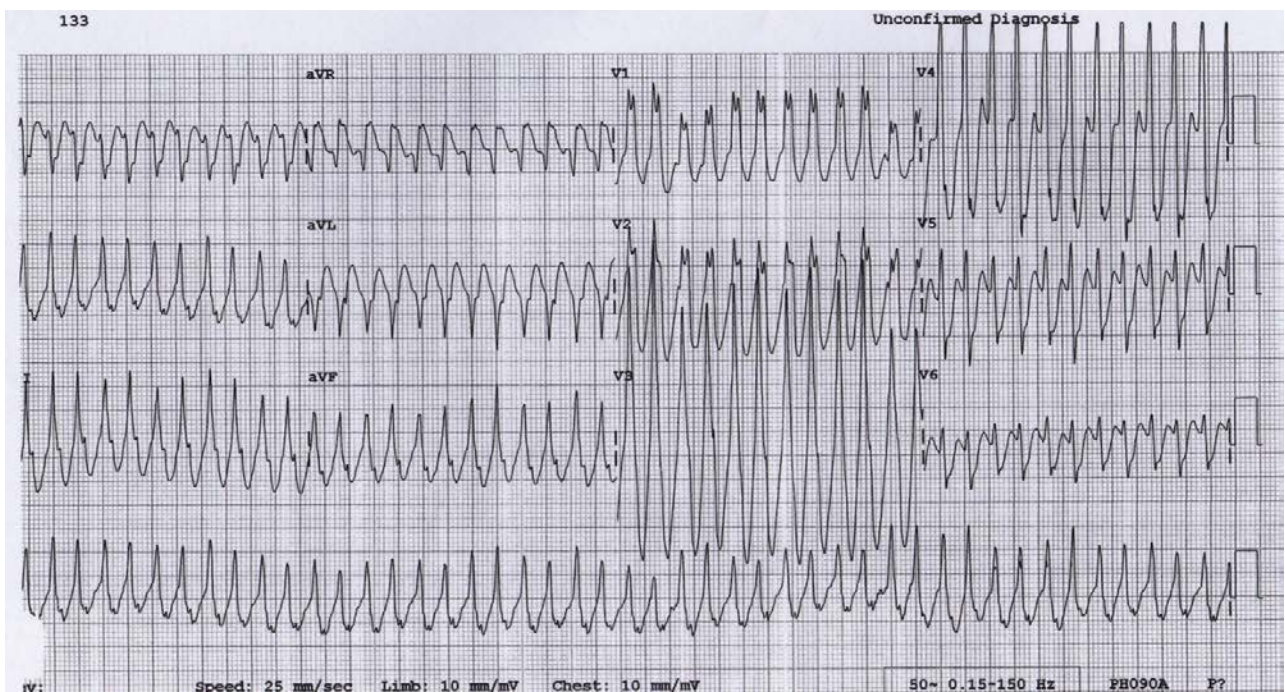
SVT with aberration or baseline BBB



http://www.wikidoc.org/index.php/Wide_complex_tachycardia_electrocardiogram

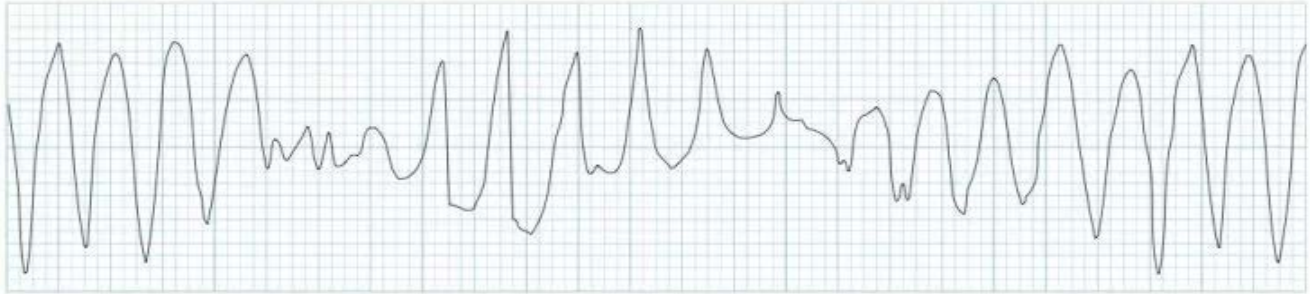
Features	Causes	Management
<ul style="list-style-type: none"> Depends on type of SVT <p>Wide complex appearance due to:</p> <ul style="list-style-type: none"> Baseline BBB that continues in tachycardia Reaching effective refractory period of right or left bundle when tachycardia begins. 	<ul style="list-style-type: none"> Depends on type of SVT 	<ul style="list-style-type: none"> Depends on type of SVT

Antidromic Reentrant tachycardia



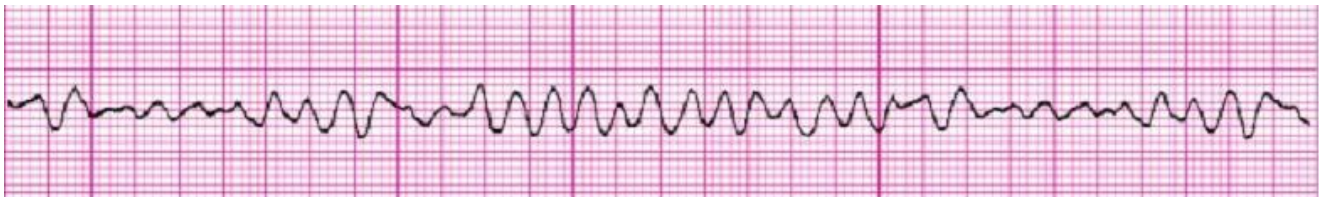Features	Causes	Management
In sinus rhythm: <ul style="list-style-type: none"> • See WPW* In Tachycardia: <ul style="list-style-type: none"> • Wide complex QRS complexes 	<ul style="list-style-type: none"> • Conduction is antegrade through accessory pathway, and retrograde through AV node in a cycle 	<ul style="list-style-type: none"> • At risk of sudden death since pathway conducts antegrade • Acute: vagal maneuvers, adenosine, procainamide gtt, cardioversion if unstable • Chronic: Recommend beta blockers and ablation

Torsade



Features	Causes	Management
<ul style="list-style-type: none"> • Polymorphic VT with "twisting" of QRS complex around baseline in a sinusoidal appearance 	<ul style="list-style-type: none"> • Hypokalemia, hypomagnesemia • Channelopathies: Brugada, Long QT (congenital or drug induced) • Endocrine disorders (hypothyroidism, hyperparathyroidism, pheochromocytoma) • Myocarditis 	<ul style="list-style-type: none"> • Can progress to V-Fib and sudden death • May respond to Isuprel or magnesium

Ventricular Fib

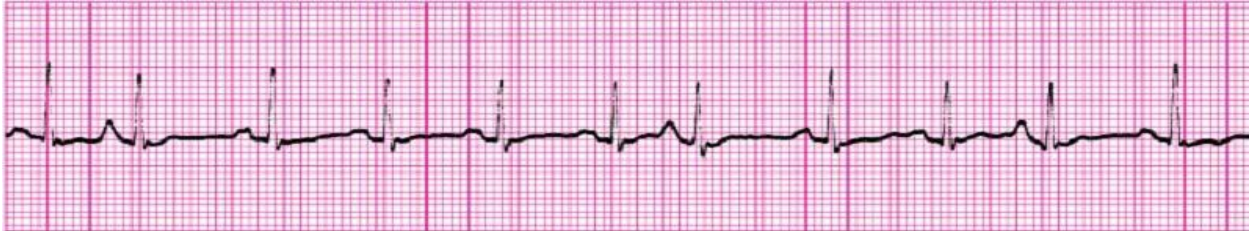

Features	Causes	Management
<ul style="list-style-type: none"> • Disorganized and chaotic rhythm • Very fast rates • Complete AV dissociation (more QRS), p waves may not even be visible 	<ul style="list-style-type: none"> • Multiple foci from the ventricle causing depolarization • Myocarditis, electrolyte abnormalities, cardiogenic shock, long QT, Brugada 	<ul style="list-style-type: none"> • Risk of sudden cardiac death • ICD recommend for aborted sudden cardiac death

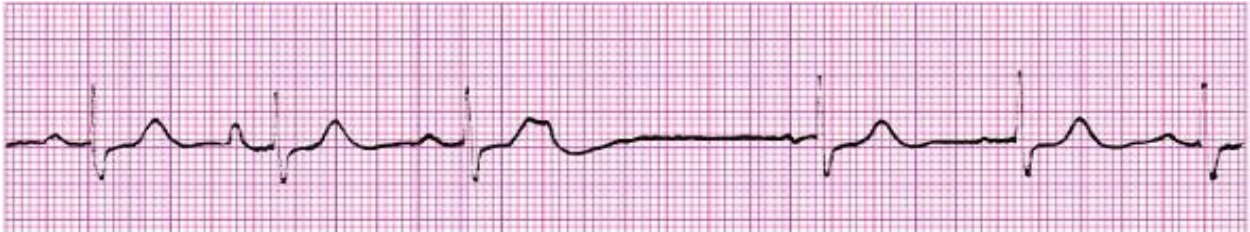Common Miscellaneous Arrhythmia Complaints

Premature Atrial Complexes (PACs)

Conducted PAC

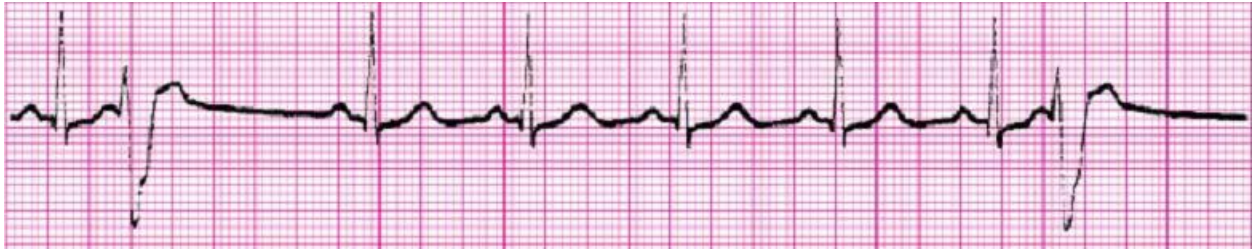

Blocked PAC



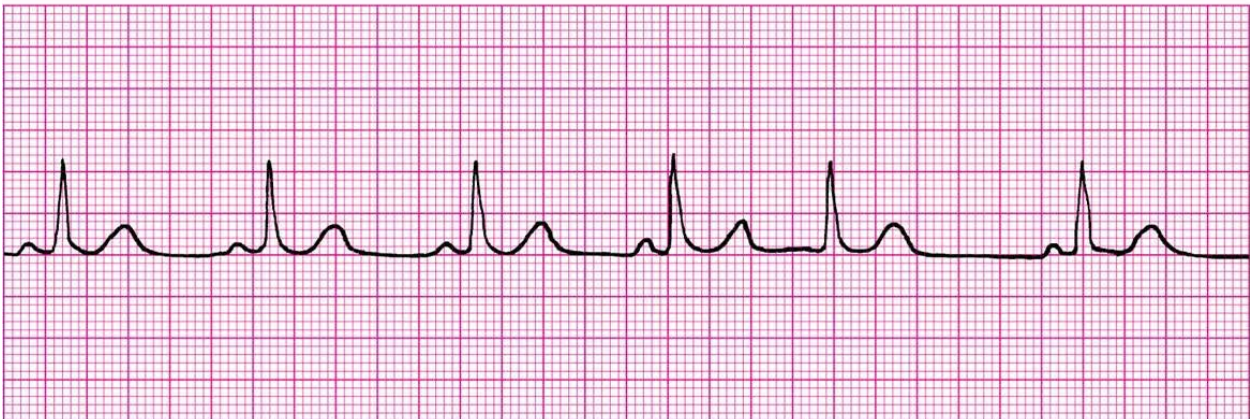
Features	Causes	Management
<ul style="list-style-type: none">• Must be premature (shorter PP interval than other beats)• Usually, p wave has different morphology and axis than sinus• Conducted PAC: p wave visible followed by normal QRS• Blocked PAC: p wave visible but no QRS	<ul style="list-style-type: none">• Depolarization of atrial tissue, separate from sinus node• Can be normal• Increased incidence in electrolyte abnormalities, central lines in right atrium, post-surgical, etc	<ul style="list-style-type: none">• Usually benign and do not require intervention• If very frequent, should have Holter to evaluate for SVT

Premature Ventricular Complexes (PVCs)



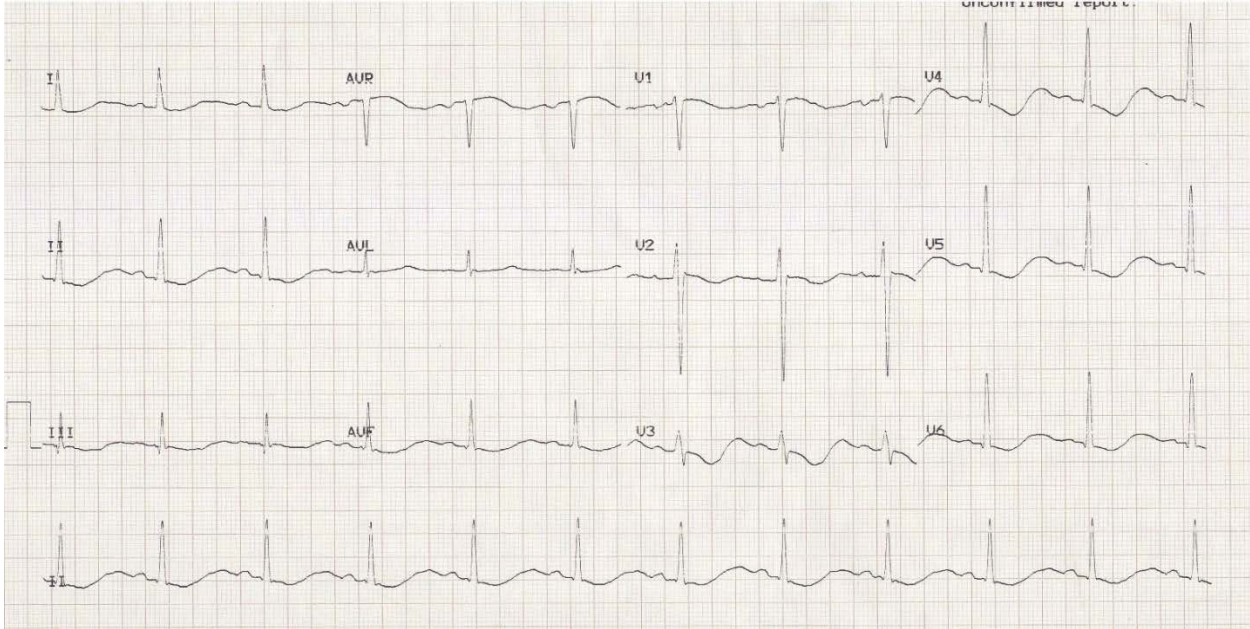
Features	Causes	Management
<ul style="list-style-type: none"> • Must be premature (QRS is earlier than expected RR interval) • Morphology is wider and usually different than normal QRS • Couplet is two PVCs in a row, bigeminy is every other beat is a PVC, trigeminy is every third beat is a PVC 	<ul style="list-style-type: none"> • Depolarization of ventricular tissue due to a random foci within the ventricle • Can be normal • Increased incidence in electrolyte abnormalities, HCM, Long QT, intraop, post-surgical, etc 	<ul style="list-style-type: none"> • Usually benign and no intervention necessary • If burden of PVCs is high, evaluate with Holter. If >15%, require closer evaluation for PVC induced cardiomyopathy

Premature Junctional Complexes



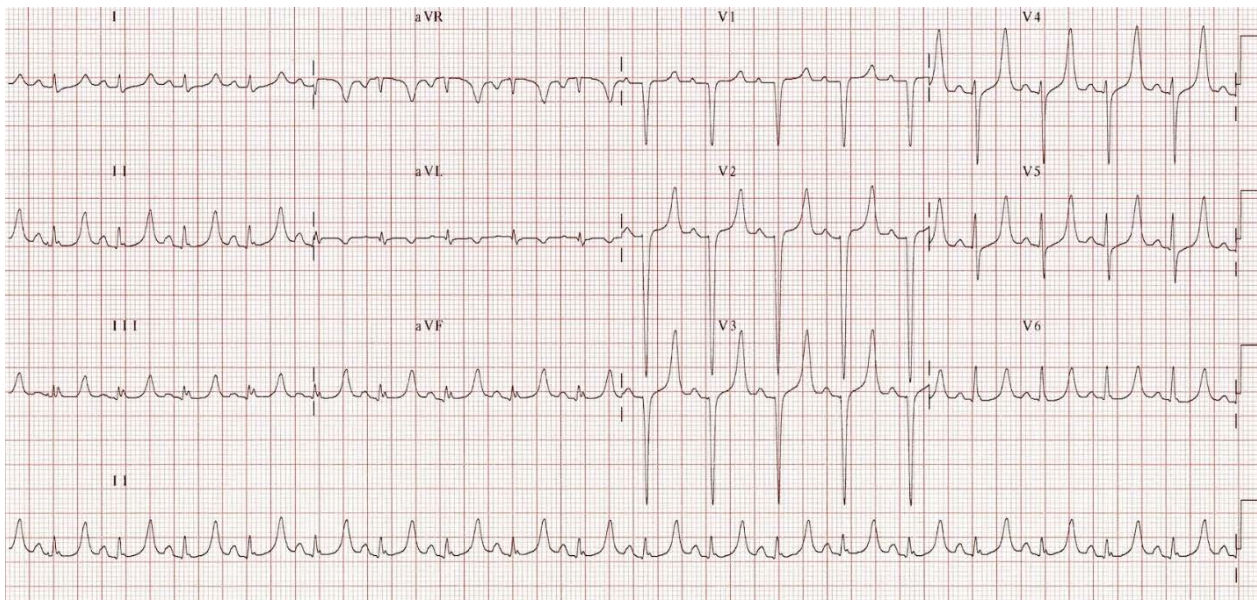
Features	Causes	Management
<ul style="list-style-type: none"> • Must be premature (QRS is earlier than expected RR interval) • QRS morphology is same as sinus • P wave usually not visible 	<ul style="list-style-type: none"> • Depolarization of ventricular tissue due to focus that originated in the AV junction • Increased incidence in electrolyte abnormalities, intraop, post-surgical, etc 	<ul style="list-style-type: none"> • Usually benign and does not require intervention

Hypokalemia



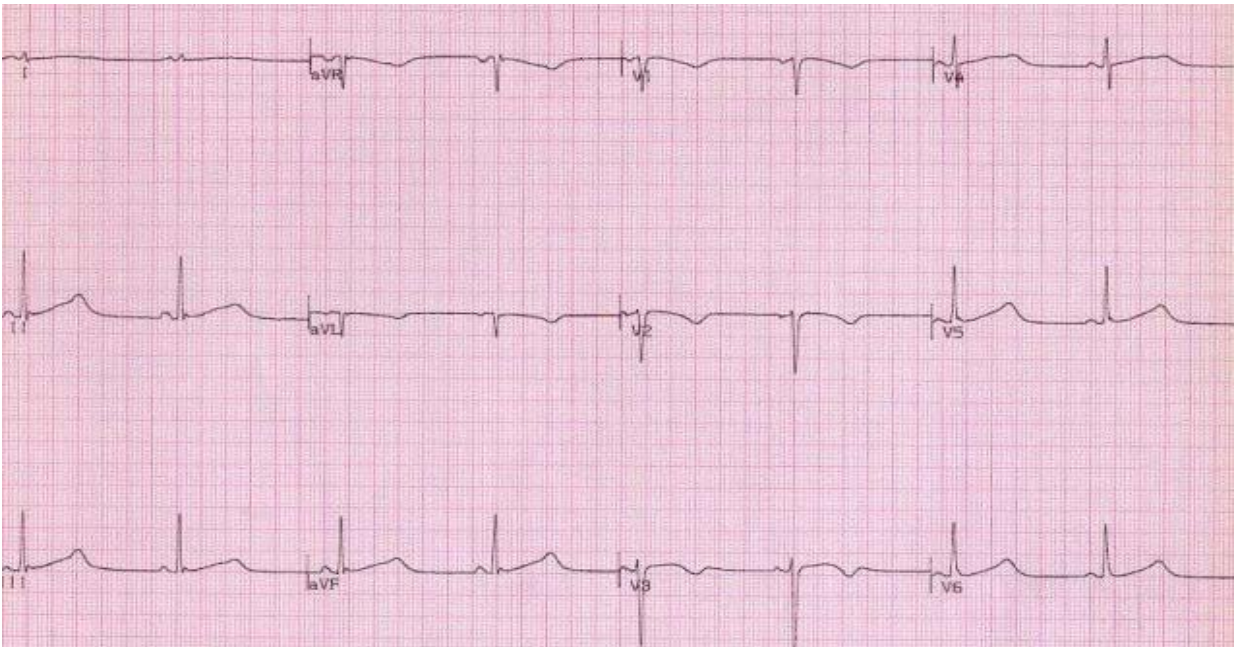
Features	Causes	Management
<ul style="list-style-type: none"> • T wave inversion and prominent U waves • Increasing PACs or PVCs 	<ul style="list-style-type: none"> • Low K⁺ • Can be associated with hypomagnesemia 	<ul style="list-style-type: none"> • Can degenerate into Torsade de Pointes and eventually V-fib and sudden cardiac death • Correct hypokalemia

Hyperkalemia



Features	Causes	Management
<ul style="list-style-type: none"> • Peaked T waves (early) • Widened p wave, PR segment lengthening (mid) • Prolonged QRS, high grade AV block (late) 	<ul style="list-style-type: none"> • Elevated K+ 	<ul style="list-style-type: none"> • Can progress to asystole, V-fib, or PEA with wide complex rhythm <p>Correct hyperkalemia:</p> <ul style="list-style-type: none"> • Calcium Gluconate to stabilize cardiac membrane • IV Sodium Bicarbonate • Kayexelate • Albuterol • Insulin and Glucose

Long QT Syndrome



Features	Causes	Management
<ul style="list-style-type: none"> • Prolonged QT interval • QTc >450ms considered abnormal in males, >460ms in females 	<ul style="list-style-type: none"> • Congenital/Familial due to channelopathies • Acquired due to medications, electrolyte abnormalities 	<ul style="list-style-type: none"> • Congenital/Familial: Beta blockade, if history of syncope or arrest, may require ICD • Acquired: removal of medications or resolution of electrolyte abnormalities

References

Cannon BC, Snyder CS. Disorders of Cardiac Rhythm and Conduction. In: Allen HD, Shaddy RE, Penny DJ, Feltes TF, Cetta F, 9th, editors. Moss and Adams' Heart Disease in Infants, Children, and Adolescents: Including the Fetus and Young Adult. Philadelphia: Lippincott Williams & Wilkins; 2016. p.624-654.

Images from:

Allen HD, Shaddy RE, Penny DJ, Feltes TF, Cetta F, 9th, editors. Moss and Adams' Heart Disease in Infants, Children, and Adolescents: Including the Fetus and Young Adult.

Lifeinthefastlane.com

Neonatal Presentations of Congenital Heart Disease or Scary Newborn Stuff

“Central” Cyanosis: arterial oxygen desaturation

- Bluish discoloration of the mucous membranes and skin
- Occurs when >5g/dL of deoxyhemoglobin is present – seen with *inadequate pulmonary blood flow* OR *transposition physiology*

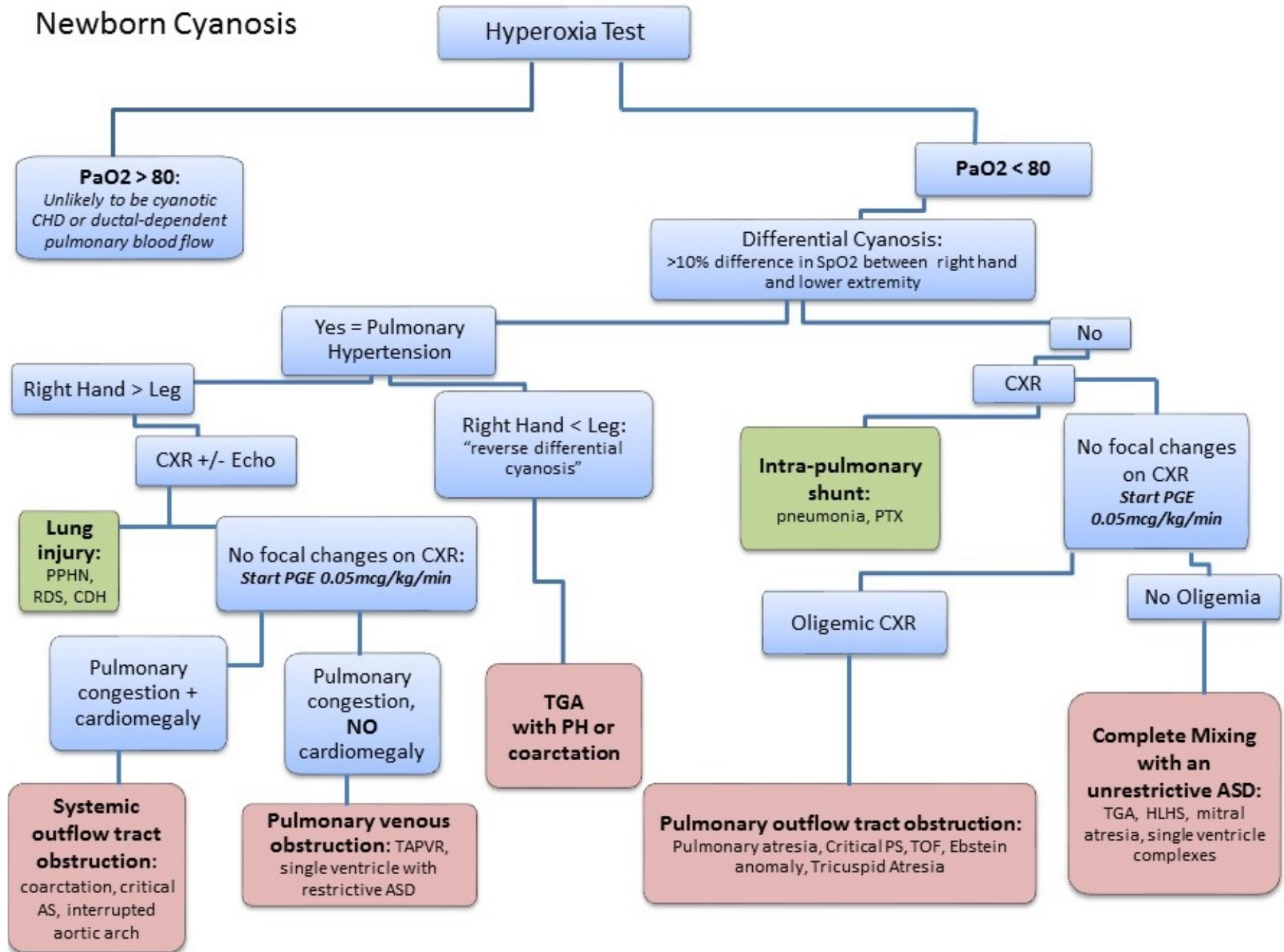
“Peripheral” Cyanosis: normal arterial oxygen saturation

- Due to sluggish peripheral circulation
- Normal in acrocyanosis, abnormal in shock

Assessment

1. History, including family history, prenatal care, fetal imaging
2. Exam
 - Presence or absence of a murmur
 - Upper and lower extremity blood pressures
 - Femoral pulses
 - Pre- and post-ductal saturations
 - **Assess for cyanosis**
 - Hypoventilation (neurologic disease): shallow respirations, low tone
 - Pulmonary disease: tachypnea, crackles, retractions, grunting
 - *Cardiac disease: comfortable or “happy” tachypnea*
3. Ancillary tests
 - Chest X-ray
 - ECG
 - Hyperoxia test
4. Call Pediatric Cardiology!
5. Escalate care fast!
 - Plan for emergent transfer to a cardiac center.
 - Give oxygen to cyanotic babies. Consider intubation.
 - Get prostaglandin and dopamine ready.
 - Place umbilical lines or secure stable access.

Newborn Cyanosis



Initial Therapy for Symptomatic Heart Disease

	Therapy	Rationale
Cyanosis: 1. Decreased PBF <i>Tricuspid atresia</i> <i>Ebstein anomaly</i> <i>Tetralogy of Fallot</i> <i>PA/IVS</i> <i>Critical PS</i> 2. Circulations in parallel <i>Transposition</i> <i>+/- VSD or ASD</i> <i>DORV</i>	PGE1 Atrial septostomy	Increases pulmonary blood flow Decompresses elevated left atrial pressure, allows for mixing in transposition physiology
Respiratory Distress 1. Pure left to right shunt, Qp > Qs <i>ASD</i> <i>AVSD</i> <i>VSD</i> <i>AP window</i> <i>PDA</i> <i>AVM</i> <i>PAPVR</i> 2. Complete mixing lesion, Qp > Qs <i>ASD with common atrium</i> <i>AVSD</i> <i>VSD with single ventricle</i> <i>Truncus arteriosus</i> <i>Unobstructed TAPVR</i>	+/- Oxygen Diuretics Mechanical Ventilation Indomethacin	May increase pulmonary venous saturations, but may increase pulmonary blood flow in a child who is already overcirculated Decreases pulmonary edema, may improve work of breathing Decreases respiratory work, LV afterload, and possibly alveolar edema Closes the PDA – only use if there is no concern for LV outflow tract obstruction
Hypoperfusion 1. Left-sided obstruction <i>Obstructed TAPVR</i> <i>Supramitral ring</i> <i>Mitral stenosis</i> <i>HLHS</i> <i>Aortic stenosis</i> <i>Arch interruption</i> <i>Coarctation</i> 2. Cardiomyopathy <i>Primary</i> <i>Infectious</i> <i>Immunologic</i> <i>Hematologic</i> <i>Metabolic</i> <i>Ischemic</i> <i>Arrhythmic</i> <i>Infiltrative</i>	PGE1 Inotropes Oxygen Atrial septostomy	Allows RV to supply systemic circulation Improves ventricular contractility Increases pulmonary venous saturations if there is alveolar edema, but may increase pulmonary blood flow in a child who is already overcirculated Minimizes atrial pressure differences, maximizes systemic flow

Continued

General	Correct electrolyte derangements	Maintain metabolic balance and normal pH
	PRBC transfusion	Maximize oxygen delivery with normal viscosity
	Thermoregulation	Minimize oxygen consumption
	Pharmacologic paralysis	Minimize oxygen consumption
	Calories	Maximize substrate delivery

Questions

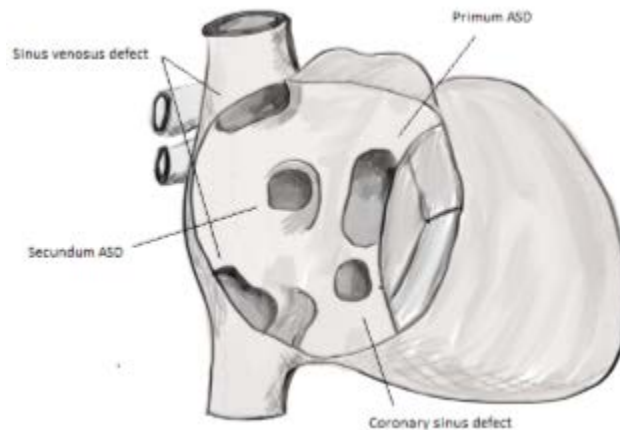
- How do you accurately check pre- and post-ductal saturations?
- Describe how children with hypoperfusion will appear on physical exam. What history might you get from the family or NICU?
- You discover a heart murmur in a term, 3.1kg male infant immediately after birth. The infant is cyanotic with an O₂ saturation of 65%. His breathing is unlabored, there is no hepatomegaly or splenomegaly, and the distal pulses are excellent. A chest X-ray demonstrates clear lung fields and a normal cardiac silhouette, but a narrowed mediastinal shadow. What is the most likely diagnosis?
- You note severe cyanosis and an oxygen saturation of 73% in a 3 hour old infant in the nursery. Echo reveals severe pulmonary stenosis. The child is hemodynamically stable. What are your next steps of management?
- A 4 week old, ex-term infant ate well and gained weight for the first 3 weeks of life. His mother reports that for the last week, he appears hungry, but fatigues with feeds and he now takes twice as long to complete a feeding as he did 1 week ago. He also breathes fast during his feedings and has to stop frequently to “catch his breath.” What is the most likely explanation for his symptoms?
- A 3 day old, ex-29 week infant was born weighing 1200g. He has respiratory distress syndrome and is receiving assisted ventilation. This morning, you note a grade III/VI holosystolic murmur, hyperdynamic precordium and widened pulse pressures. What is the most likely cause of the murmur? What are your next steps of management?

References

Artman M, Mahony L, Teitel DF. Neonatal Cardiology. 2nd ed. New York: The McGraw-Hill Companies, Inc; c2011. Chapter 5: Initial Evaluation of the Newborn with Suspected Cardiovascular Disease; p.75-88.

Atrial Septal Defects

13% of congenital heart disease, affects 0.2% of the population



Anatomic Variations

- Patent foramen ovale (PFO)
 - In fetal life, most blood returning to the heart crosses the PFO to the left atrium and enters the systemic circulation. This allows for the most oxygenated blood to reach the brain.
 - Once pulmonary blood flow increases after birth, pulmonary venous return fills the left atrium, left atrial pressure rises and the PFO flap usually closes.
 - 30% of normal, healthy adults still have a PFO
- Primum ASD (15-20%), an endocardial cushion defect
- Secundum ASD (70%), a defect in the septum primum
- Sinus venosus defect (5-10%) – most are associated with partial anomalous pulmonary venous return
- Coronary Sinus defect (<1%)
 - Almost always associated with a persistent left SVC
 - Rarely there is no coronary sinus at all
- An ASD is required for survival in many cyanotic heart lesions to ensure adequate mixing of systemic and pulmonary venous return

Clinical Presentation

- Often asymptomatic until later in life
 - Older patients may present with exercise intolerance, dyspnea, and fatigue
- Physical Exam
 - Wide, fixed splitting of S2 due to RV volume overload delaying closure of pulmonary valve.
 - Systolic ejection murmur at the left upper sternal border due to a relative increase in flow across the pulmonary valve.
 - A loud P2 will reflect pulmonary hypertension

- Over time, the patient may show clinical evidence of right heart failure
- Genetic Syndromes associated with secundum type ASDs
 - Holt-Oram syndrome (*TBX5* gene): secundum ASD + upper limb abnormalities
 - Familial forms also associated with *GATA4*, *MYH6*, *NKX2-5* or chromosome 5p mutations or Noonan, Treacher Collins or TAR syndromes.

Natural History

- As the PVR drops, left atrial to right atrial shunting will increase.
- Eventually, shunting across the ASD will result in right ventricular (RV) volume overload and RV dilation.
- Atrial stretch may manifest as atrial arrhythmias
- In 5-10% of patients, flow-related pulmonary arterial hypertension and pulmonary vascular obstructive disease (PVOD) develop, leading to Eisenmenger syndrome (right to left shunting causing cyanosis)
- Spontaneous closure of secundum defects can occur in younger patients (up to 8 years of age)
 - Other types of ASDs do not close
 - Most secundum ASDs less than 5mm will close, greater than 8 -10mm unlikely

Diagnostic Work-Up

- ECG
 - Small lesions will have a normal EKG
 - For larger shunts: rSR' in V1 due to RV volume overload, tall p waves reflect right atrial volume load.
 - Late in life, may be associated with atrial fibrillation or atrial flutter
- Echo confirms the diagnosis

Treatment

- **Secundum ASDs**
 - Treatment is indicated in patients older than 2 years of age with a Qp:Qs \geq 1.5 or if there is echo evidence of RV volume overload
 - **Percutaneous device-based closure in the cath lab**
 - Hemodynamic cath evaluates degree of shunting
 - Device closure can be attempted for lesions meeting specific criteria
- **Surgical closure** via suture closure or patch closure for other types of ASDs and secundum defects not amenable to device closure

Post-Op complications

- 25% develop post-pericardiotomy syndrome (fever >72 h postoperatively, irritability, pleuritic chest pain, or pericardial friction rub + pericardial effusion).

Long term outcomes

- If repaired in childhood – excellent outcome
- If repaired in adulthood – may have progressive PVOD and difficult to control atrial arrhythmias

Questions

- What are the expected saturations for a patient with an ASD?
- What factors affect shunting at the atrial level?
- What congenital heart disease lesions have an obligate right to left shunt?
- What is a bubble study and what is it used to evaluate?
- What are the expected cath numbers for a patient with an ASD?

References

Moss and Adam's Heart Disease in Infants, Children, and Adolescents: Including the Fetus and Young Adult, 8th Ed. Chapter 28, Atrial Septal Defects.

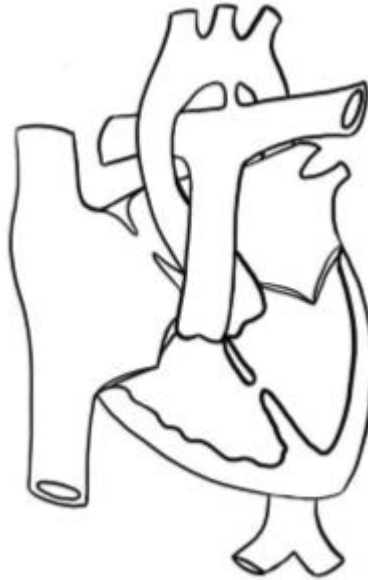Vick GW III, Bezold LI. Classification of atrial septal defects (ASDs), and clinical features and diagnosis of isolated ASDs in children. *Uptodateonline.com*

Vick FW III, Bezold LI. Management and outcome of isolated atrial septal defects in children. *Uptodateonline.com*

Ventricular Septal Defects

Incidence of 5-50/1000 live births

2nd most common congenital heart lesion, after bicuspid aortic valve



Anatomy

Types:

Multiple classification systems exist. The terms below reflect the Andersonian school of thought.

Inlet VSD (also known as AV canal type VSD):

5-8% of VSDs

- Located beneath the septal leaflet of the tricuspid valve
- True AV canal type defects involve abnormalities of the tricuspid or mitral valves and displacement of the conduction system below the defect
- Almost always large defects

Muscular VSDs

5-20% of all VSDs

- Can be multiple defects anywhere in the muscular septum

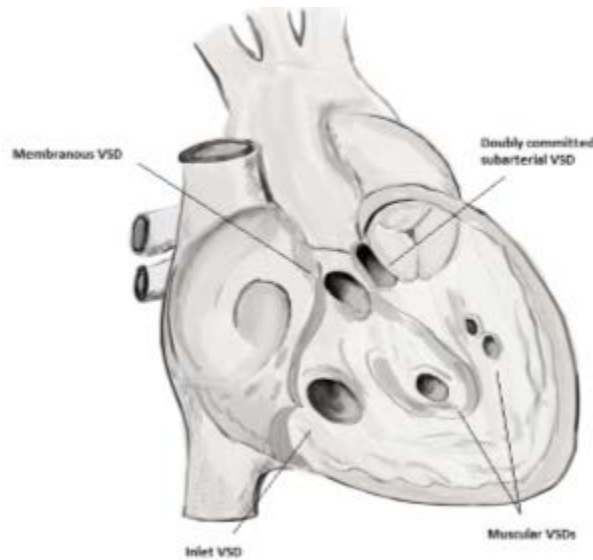
Outlet VSDs

- **Membranous or perimembranous VSDs (or infracristal or subaortic VSD)**

70% of all VSDs

- Membranous septum is a small area beneath the aortic valve. Perimembranous VSD refers to a defect involving the membranous septum and adjacent muscular tissue.
- From the LV side: visible in the outflow tract under the aortic valve
- From the RV side: lie beneath the crista supraventricularis and posterior to the papillary muscle of the conus
- May extend into the inlet, outlet, or muscular septum
- Flow through the defect may damage the septal leaflet of the tricuspid valve
- The aortic valve may prolapse through the defect causing aortic insufficiency
- **Aneurysm of the ventricular septum:** tricuspid valve septal leaflet tissue partially obstructs the defect, can lead to spontaneous closure of the VSD

- May be associated with malalignment of the ventricular septum
- **Doubly committed subarterial VSD (or supracristal or infundibular VSDs)**
5-7% of all VSDs in the Western world, 30% of all VSDs in Far Eastern countries
 - Part of the rim of the defect is formed by the pulmonary and aortic valve annuli
 - Associated with aortic valve insufficiency due to prolapse of an aortic valve cusp (usually the right coronary cusp) into the defect



Clinical Presentation

- Depends on the size of the defect and the downstream resistance to flow. Resistance can be at the valvar level (as in pulmonary stenosis) or reflect the balance of PVR and SVR
- Small defects present with a holosystolic murmur, but minimal physiologic consequences
- Large defects cause pulmonary overcirculation and symptoms of heart failure in the absence of pulmonary hypertension

Natural History

- Small defects are asymptomatic and usually do not require intervention unless there is concern for aortic valve prolapse
- Unrepaired large VSDs expose the pulmonary vascular bed to systemic level pressures and lead to the development of pulmonary vascular disease and Eisenmenger physiology

Diagnostic Work-Up

- EKG, Chest X-ray may provide supplemental information
- Echo makes the diagnosis
- Cardiac cath can be used to determine the true Qp:Qs or the PVR in older, unrepaired children

Treatment

- Medical management of heart failure (diuretics, afterload reduction)
- Transcatheter VSD occluder devices are used in adult patients, but not widely used in pediatric patients yet
- Indications for surgery:
 - Infants: large shunts should be closed before 1 year of age (usually by 6 months or earlier if patient is failing to thrive)
 - Children/Adults: Qp:Qs >2 with normal or reactive PVR, progressive aortic valve insufficiency, bacterial endocarditis
 - Surgery is contraindicated in patients with PVR/SVR ratio >0.5 and those with Eisenmenger physiology
- Surgical techniques
 - 1960s-1970s: infants were palliated with a PA band* and returned for a second surgery for VSD closure when they were older
 - Now: pericardial patch closure via a transatrial or pulmonary arterial approach

Post-op Complications

- AV block
- Right bundle branch block, especially if a right ventriculotomy is required
- Residual defects (usually do not require further intervention) occur in < 5%

Long-term Complications

- 25 year survival ~87% using older data
- Low risk of serious arrhythmia or sinus node dysfunction late after repair

Questions

- What determines the intensity of a VSD murmur?
- What are the expected saturations?
- Which chambers enlarge with a hemodynamically significant VSD?
- What will the EKG look like in a patient with an inlet VSD?
- What other lesions are commonly associated with VSDs?
- What genetic syndromes can be associated with VSDs?
- What are the expected cath numbers in an infant with an unrepaired large VSD?

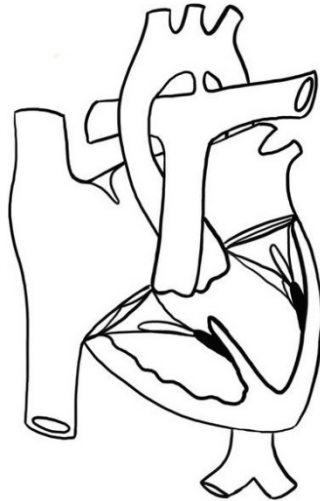References

- Rubio AE, Lewin MB. Ventricular Septal Defects. In: Allen HD, Driscoll DJ, Shaddy RE, Feltes TF, 8th, editors. Moss and Adams' Heart Disease in Infants, Children, and Adolescents: Including the Fetus and Young Adult. Philadelphia: Lippincott Williams & Wilkins; 2013. p.713-721.
- Park MK. Park's Pediatric Cardiology for Practitioners. 6th ed. Philadelphia: Elsevier Saunders; c2014. Chapter 12: Left-to-Right Shunts; p.160-168.

Atrioventricular Septal Defect/AV canal defect/Endocardial cushion defects

4-5% of CHD, affects 0.19 in 1000 live births

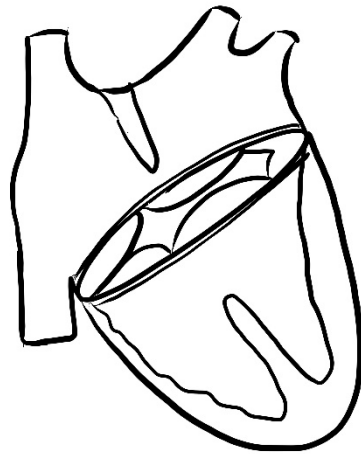
40-50% of infants with Trisomy 21 have CHD. 45% of those with heart disease have an AVSD.



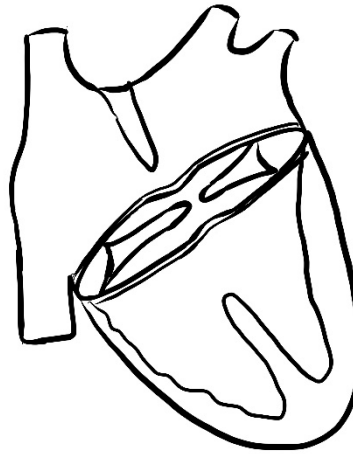
50% of infants with AVSD have Trisomy 21.

Anatomic variations

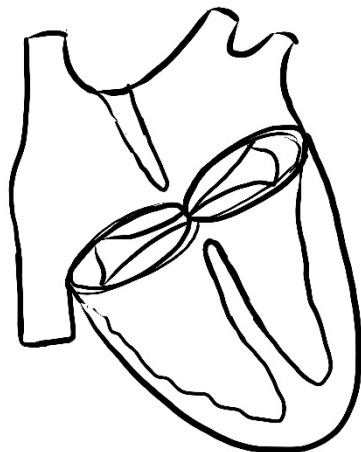
- All types have the following: atrioventricular (AV) valve leaflets insert at the same level at the cardiac crux, anterior displacement of aortic valve with an elongated LVOT, cleft left AV valve
- Because the AV valves are abnormal, they are referred to as “left” and “right” instead of mitral and tricuspid
- **Complete AVSD:** large septal defect with interatrial and interventricular components and a common AV valve with one orifice that spans the entire defect
 - Rastelli Type A (most common): Anterior bridging leaflet is divided and attached to crest of ventricular septum, multiple chordae.
 - Rastelli Type B (least common): Anterior bridging leaflet is partly divided and not attached to the crest of the septum, it predominantly inserts onto papillary muscles in the right ventricle
 - Rastelli Type C: Anterior bridging leaflet is not divided and not attached to the crest of the septum, “free floating”
 - **Intermediate AVSD:** complete AVSD with separate right and left AV valve orifices, large primum ASD, and a large inlet VSD
 - **Large Inlet VSD without a primum ASD:** also a form of complete AVSD
- **Partial AVSD:** primum ASD (usually large) with 2 distinct right and left AV valve orifices, no VSD, cleft left AV valve
 - **Transitional AVSD:** partial AVSD with a small, restrictive inlet VSD



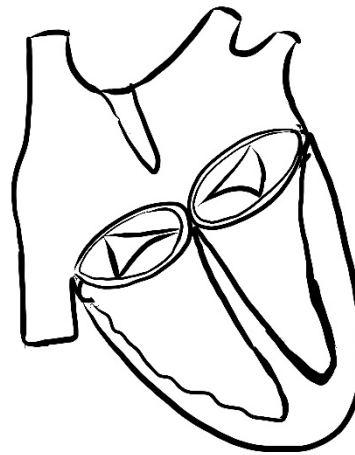
Complete AVSD



Intermediate AVSD



Transitional AVSD



Partial AVSD

- **Unbalanced AVSD** (10% of all AVSDs) occurs when more than half the AV junction is committed to one ventricle leaving the other ventricle hypoplastic
- Associated anomalies: secundum ASD, PDA, persistent L-SVC to coronary sinus, Tetralogy of Fallot, double outlet right ventricle, pulmonary valve atresia, coarctation

Clinical presentation

- Associated with Trisomy 21, heterotaxy, and Ellis-van Creveld syndromes
- Tachypnea and poor weight gain from excess pulmonary blood flow and left AV valve regurgitation
- Possible II/VI systolic ejection murmur due to increased pulmonary blood flow
- Possible holosystolic murmur best heard at the apex due to left AV valve regurgitation
- There may not be a murmur if there is pulmonary hypertension!
- **Partial AVSD:** may not have symptoms until adulthood – similar exam to a secundum ASD
- **Complete AVSD:** similar exam to an uncomplicated large VSD

Natural History

- Without repair, patients present with symptoms of excess pulmonary blood flow

Diagnostic Work-up

- **EKG:** conduction system's path is altered by the defect resulting in extreme left axis deviation (a superior axis) and PR prolongation
- **Echo** confirms the diagnosis

Treatment

- Surgical repair within 6 months of age for complete AVSD to avoid pulmonary vascular disease
 - Requires closure of the interventricular and interatrial defects and construction of 2 separate and competent AV valves
 - **Two patch technique:** separate atrial and ventricular patches*
 - **One patch technique:** one large patch to close both the VSD and ASD
 - **"Australian" technique:** patch ASD closure, suture closure of the VSD
- Unbalanced AVSD may require single ventricle palliation

Post-op complications

- Left AV valve regurgitation or stenosis
- Right AV valve regurgitation
- Left ventricular outflow tract obstruction
- Residual defects

Long-term complications

- Same as immediate post-op period – 15-20% may require reoperation over time

Questions

- What are the expected saturations for each variant of this lesion?
- What are the expected cath numbers for each variant of this lesion?
- What factors may affect shunting through the lesions?
- Why is LVOT obstruction a long-term consequence of an AVSD?

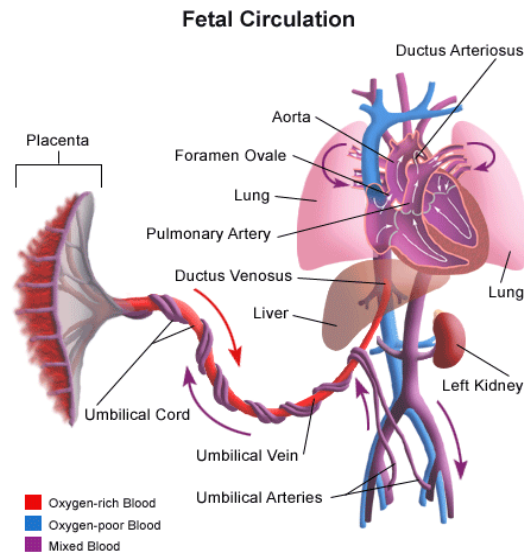
Resources

Cetta F, Truong D, Minich LL, et al. Atrioventricular Septal Defects. In: Allen HD, Shaddy RE, Penny DJ, Feltes TF, Cetta F, 9th, editors. Moss and Adams' Heart Disease in Infants, Children, and Adolescents: Including the Fetus and Young Adult. Philadelphia: Lippincott Williams & Wilkins; 2016. p.757-782.

Patent Ductus Arteriosus

5-10% of all congenital heart disease, excluding premature babies.

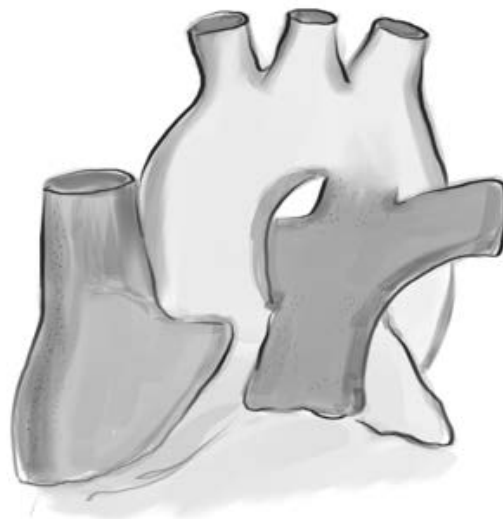
- Isolated PDA among term infants ranges from 3 to 8 per 10,000 live births
 - In premature infants: 45% of infants with a birth weight <1750g, 80% of infants with a birth weight <1200g
- Female predominance for PDA with a 2:1 female to male ratio



www.stanfordchildrens.org

The ductus arteriosus is a normal and important structure in fetal life and connects the aorta to the left pulmonary artery distal to the origin of the left subclavian artery (in a left-sided ductus)

- In utero, it allows for blood to bypass the lungs and perfuse the lower half of the body.
- Immediately after birth, the drop in PVR and increase in SVR change the direction of ductal flow. The increased oxygen content of blood flowing through the ductus promotes vasoconstriction of the smooth muscle and closure of the ductus.
- Persistent patency of this fetal structure in an otherwise normal heart causes a left to right shunt after birth



Clinical Presentation

- A small PDA usually causes no symptoms. It can be picked up incidentally on echo or due to a murmur on exam.
- Moderate to large PDAs
 - Increased risk of lower respiratory tract infections
 - Congestive heart failure symptoms
 - Exertional dyspnea
 - Exam:
 - Widened pulse pressure with bounding pulses
 - Hyperactive precordium
 - Grade 1-4/6 continuous, “machinery-like” murmur heard at the left infraclavicular or upper left sternal border, may be heard on back
 - Differential cyanosis (cyanosis in only the lower half of the body) can be seen if pulmonary hypertension develops with a right to left shunt across the PDA.
- Premature infants are at risk of systemic hypoperfusion from a significant left to right shunt
 - Risk of intracranial hemorrhage, renal injury, myocardial ischemia and necrotizing enterocolitis
 - Present with widened pulse pressure and excess Qp causing pulmonary edema
 - Machinery-like murmur uncommon

Natural History

- Spontaneous closure is rare in full-term infants (after first few weeks) and older children
- If a large PDA is left untreated, pulmonary vascular obstructive disease and pulmonary hypertension may develop
- Any size PDA has a 1% per year lifetime risk of bacterial endarteritis
- Ductus arteriosus aneurysm carries a risk of thrombus formation or dissection

Diagnostic Work-Up

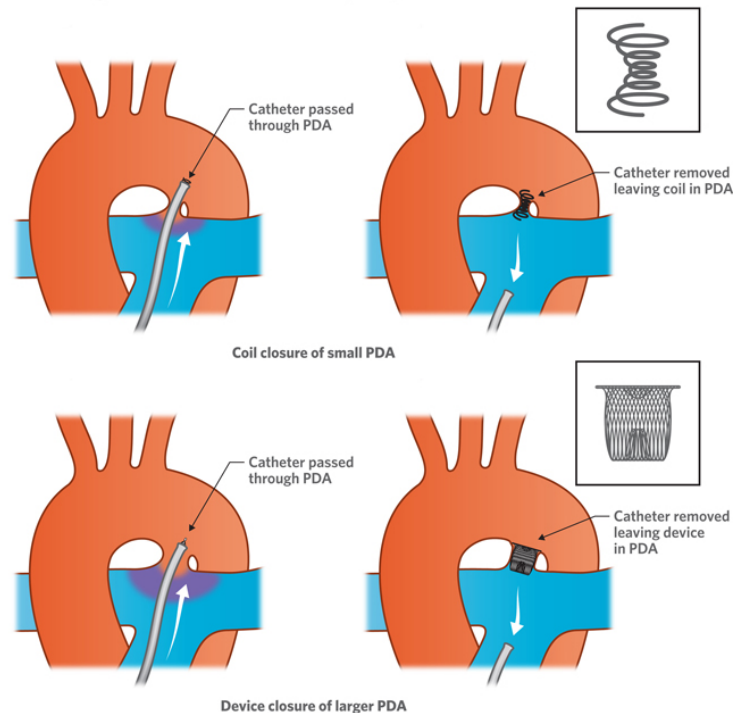
- Chest X-ray: pulmonary edema, left atrial enlargement, left ventricular enlargement
- Echo confirms the diagnosis

Treatment

- Hemodynamically important PDAs in preterm infants:
 - Fluid restriction to 120mL/kg/day + diuretic
 - Indomethacin or ibuprofen
 - Contraindicated in infants with renal dysfunction, thrombocytopenia, bleeding diathesis, known intracranial hemorrhage, necrotizing enterocolitis and hyperbilirubinemia
 - If medical management fails, the PDA is surgically ligated via a thoracotomy
 - New evidence suggests no PDAs should be closed – stay tuned!
- Indications for treatment in full-term infants and children
 - Small PDAs

- If audible, recommend elective closure by cath procedure when >15kg due to a small risk of infective endocarditis.
 - Closing a “silent” tiny PDA (a PDA found on echo, but not heard on exam) is not recommended.
 - Large PDAs are closed to treat congestive heart failure and prevent the development of pulmonary vascular obstructive disease
 - Refer for closure when patient develops left heart enlargement or signs of heart failure
- **Device closure** in the cath lab is standard of care in term infants and children.
 - Rule out pulmonary hypertension prior to closure of the shunt
 - **Complications**
 - Damage to blood vessels, particularly the femoral artery in smaller infants
 - Device embolization
 - Obstruction of blood vessels by the device

Closure of patent ductus arteriosus (PDA)



© The Royal Children's Hospital, Melbourne, Australia

- **Surgical closure** involves ligation and division via a left posterolateral thoracotomy without cardiopulmonary bypass
 - **Complications**
 - Unilateral vocal cord paralysis (injury to recurrent laryngeal nerve)
 - Chylothorax (injury to thoracic duct)
 - Diaphragm paresis (injury to phrenic nerve)
 - Pneumothorax
 - Late scoliosis > 10 degrees related to thoracotomy (~20%).

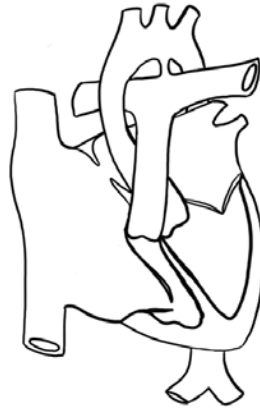Questions

- How does gestational age at birth and postnatal age affect the presentation of a PDA?
- Which chambers enlarge with a PDA in an otherwise normal heart?
- What determines the direction of the shunt?
- When might a PDA be beneficial?
- What are the expected saturations in the hands and the feet?
- What are the expected cath numbers in an older child with a PDA?

References

- Taggart NW, Qureshi MY. Patent Ductus Arteriosus and Aortopulmonary Window. In: Allen HD, Shaddy RE, Penny DJ, Feltes TF, Cetta F, 9th, editors. Moss and Adams' Heart Disease in Infants, Children, and Adolescents: Including the Fetus and Young Adult. Philadelphia: Lippincott Williams & Wilkins; 2016. p.803-819.
- Park MK. Park's Pediatric Cardiology for Practitioners. 6th ed. Philadelphia: Elsevier Saunders; c2014. Chapter 12: Left-to-Right Shunts; p.168-174.

Ebstein Anomaly



Prevalence ~ 2.4/10,000 live births with no preference for either sex.

Anatomic Variations

Ebstein anomaly develops from the failure of the septal and inferior leaflets of the tricuspid valve to fully delaminate, leading the attachments of the leaflets to be downward (apically) displaced from the annulus, and the leaflets to be abnormal. This leads to a spectrum of tricuspid valve regurgitation and a dysfunctional, "atrialized" right ventricle.

Anatomic Variations

- Ebstein with LV non-compaction
- Ebstein with mitral valve abnormalities (40%)
- Ebstein with pulmonary atresia
- Associated anomalies: WPW, RVOT obstruction at multiple levels

Clinical Presentation

- Presentation depends largely on amount of displacement of tricuspid valve leaflets, amount of functional right ventricle, degree of TV regurgitation and RVOT obstruction.
- Mild Ebstein anomaly
 - May be asymptomatic until adulthood
 - May have murmur, exertional dyspnea and occasionally cyanosis (with a PFO), and palpitations in adulthood
- Severe Ebstein anomaly
 - Can present in utero with fetal hydrops from poor tolerance of elevated RA pressure from TR
 - Neonates with severe displacement of the tricuspid valve leaflets will present with cyanosis due to right to left shunting at the atrial level
 - Cyanosis and respiratory failure can be exacerbated by pulmonary hypoplasia due to severe cardiomegaly
 - May have functional or anatomic pulmonary stenosis or atresia, making them ductal dependent for adequate pulmonary blood flow
- Physical Exam

- Variable, depending on severity of disease
- “Multiplicity of sounds” or clicking due to sail-like anterior leaflet
- Severe TR has a holosystolic murmur at the left sternal border.
- RVOT obstruction murmur may also be heard.
- Apical impulse may be displaced rightward.
- Cyanosis may or may not be present

Natural History

- Severe Ebstein’s is fatal if left untreated due to the severity of RV dysfunction and cyanosis.
- Mild forms of Ebstein’s may remain undiagnosed until adolescence or adulthood with the first sign being arrhythmia or progressive exercise intolerance.
- All patients have some degree of RV dysfunction.

Diagnostic Work-Up

- ~60% are diagnosed before 1 year of age, with many diagnosed prenatally
- ~10% may remain undiagnosed until adulthood
- CXR:
 - In mild Ebstein’s, may appear normal
 - In severe Ebstein’s, the RA is markedly enlarged, causing severe cardiomegaly and a pathognomonic “wall-to-wall” heart appearance
- Echo confirms the diagnosis
- EKG is almost always abnormal; look a delta wave as WPW is common.

Treatment

- In mild Ebstein’s, children are likely to be asymptomatic and need infrequent outpatient cardiology visits.
- In moderate Ebstein’s, infants may need supplemental O2 until PVR drops and TR improves
- In severe Ebstein’s, management strategies are aimed at augmenting pulmonary blood flow and sustaining cardiac output.
 - PGE may be needed to keep the PDA open and provide PBF as the dysfunctional and small RV may not be able to generate any antegrade pressure and flow across pulmonary valve. However, in keeping the PDA open, the MPA pressure and thus RV remains at systemic pressure causing severe TR to remain.
 - In patients with pulmonary regurgitation, a “circular shunt” can develop, in which: Blood in the MPA regurgitates into RV → volume load increases TR → forces more blood from RA to LA → blood from LA goes out to aorta and through PDA → into MPA. Since this blood is never oxygenated, leads to worsening cyanosis and decreased cardiac output.
- Surgery in neonates
 - RV Exclusion approach (Starnes’ Procedure) – used in patients with pulmonary atresia who will require single ventricle pathway
 - Tricuspid valve oversewn with fenestration
 - ASD enlargement
 - RA reduction
 - Systemic-to-pulmonary artery shunt

- Biventricular Repair – used if tricuspid valve is reparable and muscular RV and pulmonary valve are adequate
 - Tricuspid valve repair
 - Partial or complete atrial septal closure
 - RA reduction
- Surgery in Children and Adults
 - Indication is decreased exercise tolerance, cyanosis, progressive RV dilation, and frequency of arrhythmias
 - Should have electrophysiologic study prior to surgery
 - Primary strategy is tricuspid valve repair to obtain a competent valve, minimizing right to left shunting at the atrial septum, preserving RV function, and preventing arrhythmias
 - Multiple options for tricuspid valve repair with “Cone reconstruction,” Carpentier Repair, “monocusp” Repair
 - In patients with significant RV dysfunction, Glenn may be performed to help offload some of the volume to the RV
 - Maze procedure and RA plication are often done to diminish arrhythmogenic area

Post-Op complications

- In severe Ebstein anomaly, cyanosis and single ventricle physiology management remain challenging, especially if LV is affected
- Early mortality is associated with severe tethering of all leaflets, LV dysfunction, and pulmonary atresia

Long Term complications

- Atrial tachyarrhythmias
- Progressive tricuspid valve regurgitation or stenosis after repair (decreasing incidence with improving techniques)
- Continued cyanosis (especially with exertion) if atrial septum not closed completely

Questions

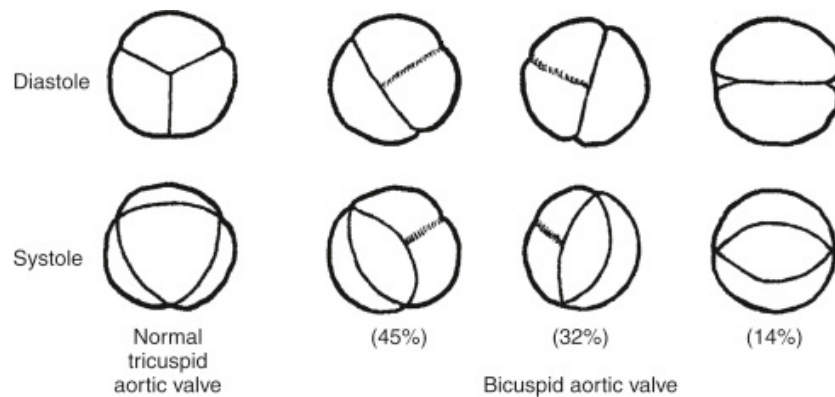
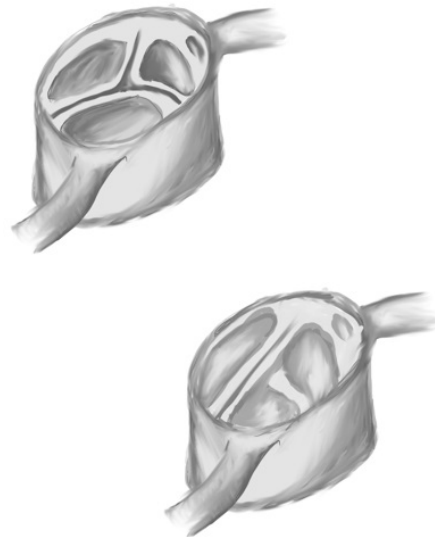
- What are common EKG findings in Ebstein anomaly?
- What are expected saturations and pressures at birth in a neonate with severe Ebstein anomaly? With mild Ebstein anomaly?
- Explain the physiology behind a circular shunt.

References

Cetta F, Dearani JA, O’Leary PW, Driscoll DJ. Tricuspid Valve Disorders: Atresia, Dysplasia and Ebstein Anomaly. In: Allen HD, Shaddy RE, Penny DJ, Feltes TF, Cetta F, 9th, editors. Moss and Adams’ Heart Disease in Infants, Children, and Adolescents: Including the Fetus and Young Adult. Philadelphia: Lippincott Williams & Wilkins; 2016. p.959-978.

Bicuspid Aortic Valve

1% of general population, most common congenital heart defect



Park's Pediatric Cardiology

Clinical Presentation

- 70-85% of bicuspid valves are fused between the right- and left-coronary cusps
 - This type has higher incidence of coarctation.
- Next most common is fusion of right and noncoronary cusp
 - This type has higher incidence of aortic valvar stenosis and/or regurgitation.
- 20-85% of patients with isolated coarctation of the aorta also have bicuspid aortic valve
- Bicuspid aortic valve and other left-sided obstructive lesions (including HLHS) cluster in families, suggesting a genetic etiology.
 - Heritability of bicuspid aortic valve has been estimated as 89%

- Exam: May hear murmurs of AS or AI, often hear a midsystolic ejection click

Natural History

Valvar stenosis increases over time and will likely require intervention in adulthood

- Valve calcifies earlier than a trileaflet valve (starting around 30 years of age)
- Sclerosis of the valve may begin as early as the teenage years
- Risk of aortic insufficiency over time as the valve degenerates
- Associated with dilatation and dissection of the aortic root

Diagnostic Work-up

- Echo confirms the diagnosis
- The valve diameter, sinus, and ascending aortic size are followed over time by echo

Treatment

- Aggressive control of hypertension to avoid exacerbating risk of aortic dissection
 - Some evidence that angiotensin receptor blockers may inhibit aortic root dilation
- Further intervention depends on the degree of aortic stenosis and regurgitation and the size of the aortic root

Questions

- What are the expected saturations in the hands and feet?
- What other lesions are associated with bicuspid aortic valve?
- Who should be screened for bicuspid aortic valve? If a mother has a bicuspid aortic valve, is a fetal echo indicated during pregnancy?
- What genetic syndromes are associated with a bicuspid aortic valve?
- What are the expected cath numbers in a patient with a bicuspid aortic valve?

References

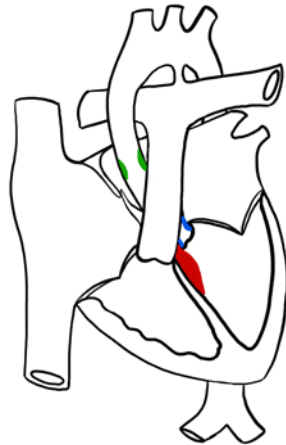
- Friedland-Little JM, Zampi JD, Gajarski RJ. Aortic Stenosis. In: Allen HD, Shaddy RE, Penny DJ, Feltes TF, Cetta F, 9th, editors. Moss and Adams' Heart Disease in Infants, Children, and Adolescents: Including the Fetus and Young Adult. Philadelphia: Lippincott Williams & Wilkins; 2016. p.1085-1105.
- Park MK. Park's Pediatric Cardiology for Practitioners. 6th ed. Philadelphia: Elsevier Saunders; c2014. Chapter 13: Obstructive Lesions; p.184-205.

Aortic Stenosis

Up to 10% of all congenital heart disease. More common in males.

Anatomic variations

- Stenosis can occur at, above, or below the level of the aortic valve



Valvar AS (80-85%)
Supravalvar AS (0.005%)
Subvalvar AS (15%)

- **Valvar AS:** bicuspid or unicuspid valve, or stenosis of a trileaflet valve
 - Stenosis usually progresses in adulthood as the valve calcifies
- **Subvalvar stenosis:** can be a discrete membrane, a fibromuscular ridge or tunnel-like stenosis
 - Discrete membrane stenoses often acquired over time, associated with perimembranous VSD
 - Tunnel-like stenosis usually develops after prior cardiac surgery
 - Also associated with other left-sided cardiac lesions
- **Supravalvar stenosis:** constriction at or above the level of the sinus of Valsalva
 - Caused by an arteriopathy related to elastin; common lesion in Williams syndrome
 - 40-80% of patients also have RVOT obstruction (peripheral branch PA stenosis)
 - Associated with coronary ostial stenosis

Clinical Presentation

- **Critical AS:** primitive small valve, often monocusp, usually with a hypoplastic ascending aorta.
 - Implies ductal dependence for systemic output. As the duct closes, the infant will present in cardiogenic shock.
 - LV outflow obstruction at any level is poorly tolerated by neonates and causes LV dysfunction
 - Associated lesions include other small left-sided structures (mitral valve, left ventricle, aortic arch, coarctation)
- Severe LVOT obstruction in older children can cause angina, exertional dyspnea, fatigue or syncope

Natural History of Valvar AS

- Progressive stenosis increases the afterload on the left ventricle, leading to LV hypertrophy and ultimately LV failure if untreated
- Earlier presentation denotes a poorer prognosis
- All forms of aortic stenosis can lead to aortic valve insufficiency

Diagnostic Work-Up

- EKG: normal in mild cases, LVH with strain seen in severe cases
- Echo: Doppler estimates a gradient, but often overestimates the gradient found at cath.
 - If there is poor cardiac output due to LV dysfunction, the gradient will underestimate the degree of anatomic stenosis.
- Cath: Gold standard to identify peak-to-peak gradient across the area of narrowing
- **Mild AS:**
 - peak velocity 2.0-2.9m/s (mean pressure gradient \leq 20mm Hg)
 - peak-to-peak gradient in cath lab $<$ 30mm Hg
- **Moderate AS:**
 - peak velocity 3.0-3.9m/s (mean pressure gradient 20-39mm Hg)
 - peak-to-peak gradient in cath lab 30-50mm Hg
- **Severe AS:**
 - peak velocity \geq 4m/s (mean pressure gradient \geq 40mm Hg)
 - peak-to-peak gradient in cath lab $>$ 50mm Hg

Treatment

- **Balloon valvuloplasty for valvar AS**
 - Newborns with isolated critical valvar AS
 - Children with isolated valvar AS and LV dysfunction
 - Children with isolated valvar AS with a peak-to-peak gradient $>$ 50 mmHg by cath
 - Children with isolated valvar AS with resting peak systolic gradient $>$ 40 mm Hg or symptoms or signs of ischemia on ECG
 - Complications: hemorrhage, femoral arterial thrombus, damage to the aortic or mitral valves or left ventricle
- **Surgical intervention**
 - **Critical AS:** Approach depends on the size of other left-sided structures for biventricular vs. single ventricle palliation
 - **Valvar AS:** if balloon valvuloplasty fails or causes severe aortic insufficiency
 - Aortic valve commissurotomy, valve replacement, or Ross procedure*
 - **Subaortic membrane:** for peak gradient $>$ 35mm Hg and mild AI or worse
 - 25-30% risk of recurrence after repair
 - **Tunnel-like subaortic stenosis:** for gradient $>$ 50mm Hg. Konno procedure
 - **Supravalvular AS:** for gradient $>$ 50-60mm Hg, severe LVH, new AI, or if coronary ostial involvement

Long-Term Complications

- **Balloon valvuloplasty:** Residual stenosis, re-stenosis over time, aortic regurgitation
 - Most patients who undergo balloon valvuloplasty will require aortic valve replacement at some point in the future
- **Surgical valve replacement:**
 - Mechanical valves last longer, but require anticoagulation
 - Bioprosthetic valves are less likely to develop clot, but degenerate quicker
 - Will require repeated replacements over time as the child grows, and then several times in adulthood due to degeneration of the artificial valve over time

Questions

- Define critical aortic stenosis. How do these children present? What are the expected saturations in critical aortic stenosis?
- What is Shone complex?
- What are the expected exam findings with aortic stenosis?
- Which genetic syndromes are associated with aortic stenosis?
- What is the Ross procedure?

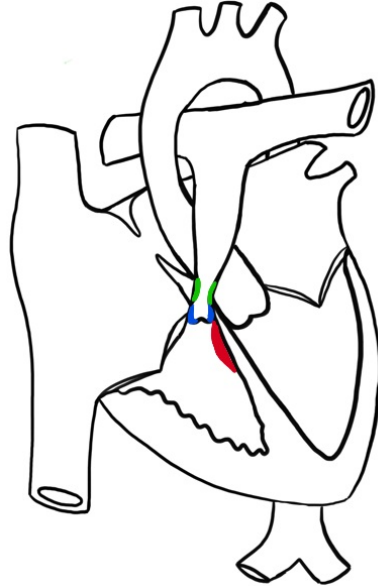
Resources

Friedland-Little JM, Zampi JD, Gajarski RJ. Aortic Stenosis. In: Allen HD, Shaddy RE, Penny DJ, Feltes TF, Cetta F, 9th, editors. *Moss and Adams' Heart Disease in Infants, Children, and Adolescents: Including the Fetus and Young Adult*. Philadelphia: Lippincott Williams & Wilkins; 2016. p.1085-1105.

Park MK. *Park's Pediatric Cardiology for Practitioners*. 6th ed. Philadelphia: Elsevier Saunders; c2014. Chapter 13: Obstructive Lesions; p.184-205.

Pulmonary Stenosis with Intact Ventricular Septum

- Obstruction can occur **below the valve**, **at the level of the valve** (80-90%), **above the valve** and in the branch pulmonary arteries
- PS occurs in 25-30% of all congenital heart disease, often associated with other lesions



Clinical presentation

- Spectrum of disease from critical PS to mild PS that requires no intervention
 - Critical PS refers to ductal dependence for pulmonary blood flow after birth
- Valve may be conical or dome shaped without clear valve leaflets, or may have a varying number of diffusely thickened leaflets. Valve annulus may be hypoplastic.
 - **Mild PS:**
 - Gradient < 30-35mm Hg across the valve
 - RV pressure < ½ systemic pressure
 - **Moderate PS:**
 - Gradient 40-60mm Hg across the valve
 - RV pressure > ½ and < ¾ systemic pressure
 - **Severe PS:**
 - Gradient >60-70mm Hg
 - RV pressure ≥ ¾ systemic
- Associated with Noonan Syndrome, LEOPARD syndrome, neurofibromatosis

Natural History

- Prognosis related to the degree of stenosis
 - Mild PS usually does not progress or require intervention and may improve over time
 - Moderate PS may progress over time
 - Symptoms usually do not develop until adulthood
- Valvar PS leads to right ventricular hypertrophy, right atrial dilation and post-stenotic dilatation of the main pulmonary artery

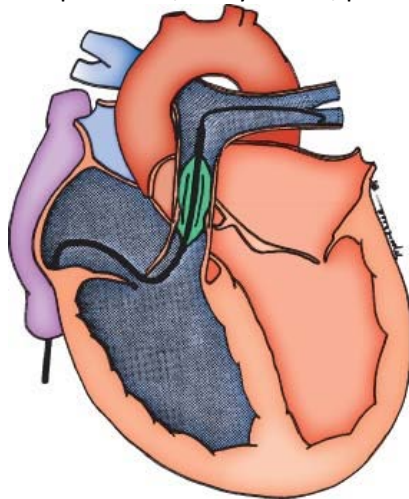
- Moderate to severe stenosis may cause exertional dyspnea and fatigue, possibly cyanosis if there is an ASD or PFO, and over time, ischemia and ventricular arrhythmias may occur as right heart failure develops
- Infundibular hypertrophy can occur as a consequence of valvar obstruction. If the narrowing is severe, relief of the valvar stenosis can cause a “suicide RV” with acute RV failure. In less significant infundibular stenosis, RV remodeling will occur over weeks to months after repair.

Diagnostic Work-Up

- ECG: right axis deviation, RVH and strain
 - Neonates with severe stenosis may have a hypoplastic RV, leading to left axis deviation and LVH on ECG
- CXR: prominent RV border, dilated MPA segment, dark lung fields
- Echo confirms diagnosis

Treatment

- **Balloon pulmonary valvuloplasty in the cath lab**
 - First line treatment at any age for valvar PS
 - Neonates may still require a BT or central shunt or a ductal stent for pulmonary blood flow while RV compliance improves
 - Complications: damage to cardiac structures including perforation, cath-related complications, arrhythmias, pulmonary regurgitation



Moss and Adams

- Surgical valvotomy, may require a transannular patch* if the pulmonary valve annulus is too small
 - Complications: pulmonary regurgitation

Long-term complications

- Most patients have good long-term results without need for re-intervention
- Pulmonary insufficiency can be caused by either valvuloplasty or valvotomy and may require pulmonary valve replacement later in life due to:
 - RV volume overload and RV failure

- Decreased exercise tolerance
- Atrial and ventricular ectopy

Questions

- What are the expected saturations in critical PS?
- What are the expected exam findings in critical PS?
- What are the expected cath numbers in a neonate with critical PS?
- What is the initial treatment of critical PS?
- What are the expected exam findings in valvar PS in a 4 year old child?

Resources

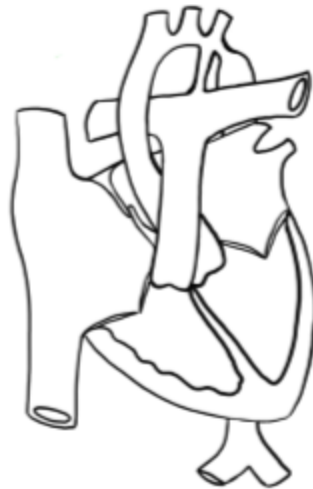Prieto LR, Latson LA. Pulmonary Stenosis. In: Allen HD, Shaddy RE, Penny DJ, Feltes TF, Cetta F, 9th, editors. *Moss and Adams' Heart Disease in Infants, Children, and Adolescents: Including the Fetus and Young Adult*. Philadelphia: Lippincott Williams & Wilkins; 2016. p.983-995.

Coarctation of the Aorta

4-6% of all congenital heart disease; prevalence of 4 per 10,000 live births.

1.5x more common in males than females.

5-15% of girls with coarctation have Turner syndrome, ~30% of patients with Turner syndrome have coarctation.



Narrowing of the descending aorta, typically located at the insertion of the ductus arteriosus just distal to the left subclavian artery

Clinical Presentation

- Bimodal distribution with severe disease presenting in infancy and asymptomatic patients presenting later in life with hypertension
- Can occur in isolation or with more complex congenital heart disease (TGA, HLHS, etc)
 - Both forms of presentation associated with bicuspid aortic valve and VSD
- Can be discrete or long-segment stenosis
- 10% of patients also have intracerebral aneurysms (compared to 2-3% general population)
- **Symptomatic Infants (20-30%):** associated with aortic hypoplasia and other small left-sided structures
 - Ductal dependent for distal flow, “critical coarctation”
 - Present in shock and/or heart failure within the first 6 weeks of life as the LV cannot withstand the increased afterload.
- **Asymptomatic Infants:** normal arch size apart from discrete coarctation, collateral flow begins to develop in fetal life and continues as the child ages
 - Collateral arteries to bypass the narrowed region can arise from the internal mammary, intercostal and anterior spinal arteries
 - Patients may complain of lower extremity weakness or pain after exercise
 - Exam may show absent or delayed lower extremity pulses, right arm hypertension

Natural History

- Critical coarctation progresses to left heart failure and renal failure and is fatal without intervention
- Asymptomatic children are at future risk:
 - Left ventricular failure
 - Aortic rupture
 - Intracranial hemorrhage
 - Hypertensive encephalopathy
 - Hypertensive cardiovascular disease
 - Endarteritis

Diagnostic Work-Up

- **Critical coarctation:**
 - ECG: normal, or right axis with RVH (also normal for age)
 - CXR: cardiomegaly, pulmonary edema
- **Asymptomatic children:**
 - ECG: normal or may show LVH with left atrial enlargement
 - CXR: “3 sign” showing an indentation in the aorta, rib notching from collaterals
 - MRI: can also confirm diagnosis, identifies collateral supply
- Echo confirms diagnosis, identifies associated anomalies

Management

- **Critical Coarctation:** prostaglandin, medical therapy for heart failure, inotropic support
 - Surgical repair has a lower risk of recoarctation than balloon angioplasty in small infants
 - Options include an extended resection with end-to-end or end-to-side anastomosis, a patch aortoplasty or a subclavian flap
- **Asymptomatic Children:** surgical repair or balloon angioplasty +/- stent
 - Surgical repair at 6 months to 2 years of age to balance risk of recoarctation (when corrected too early) with risk of persistent hypertension (when corrected too late)*

Post-op Complications

- Surgical risk
 - Spinal cord ischemia and resulting paralysis (older children and adults)
 - Injury to adjacent structures: recurrent laryngeal nerve, thoracic duct
 - Rebound hypertension (“post-coarctectomy syndrome”) can cause mesenteric arteritis and bowel ischemia
- Balloon angioplasty +/- stent
 - Femoral artery injury or thrombosis
 - Aortic aneurysm

Long-term Complications

- Persistent hypertension
- Recoarctation, can be addressed with balloon angioplasty +/- stent
- Subaortic stenosis, can develop even years after surgery
- Aneurysm formation at repair site
- Rupture of cerebral aneurysms, especially if hypertension is not managed
- Endarteritis

Questions

- What are the expected saturations in an infant with coarctation of the aorta (hands and feet)?
- What is the most common site of coarctation? Why?
- What genetic syndromes are associated with coarctation?
- What other cardiac lesions are associated with coarctation?
- Describe the physical exam findings in an asymptomatic child with coarctation.
- What are the expected cath numbers in an infant with critical coarctation?

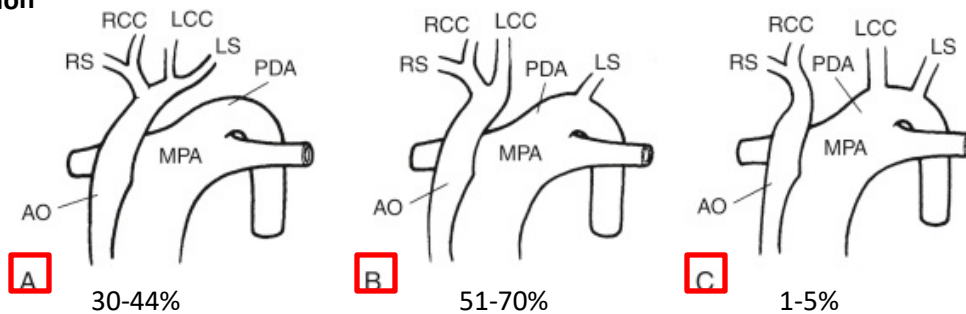
References

- Beekman RH III. Coarctation of the Aorta. In: Allen HD, Shaddy RE, Penny DJ, Feltes TF, Cetta F, 9th, editors. *Moss and Adams' Heart Disease in Infants, Children, and Adolescents: Including the Fetus and Young Adult*. Philadelphia: Lippincott Williams & Wilkins; 2016. p.1107-1123.
- Park MK. *Park's Pediatric Cardiology for Practitioners*. 6th ed. Philadelphia: Elsevier Saunders; 2014. Chapter 13: Obstructive Lesions; p.184-205.

Interrupted Aortic Arch

0.7-1.4% of all congenital heart disease

Classification



Adapted from: Park's Pediatric Cardiology for Practitioners

- Associated with VSD (often a posterior malaligned VSD and associated LVOT obstruction), bicuspid aortic valve, anomalous origin of the subclavian artery, and complex cardiac lesions
- Type B is commonly associated with DiGeorge Syndrome

Clinical Presentation

- Often associated with posteriorly malaligned ventricular septum, subaortic stenosis, VSD.
- Neonates present with signs of shock or cardiac failure after ductal closure
 - Differential cyanosis may not be seen because of mixing across the large VSD

Natural History

- Without surgical intervention, interrupted aortic arch is almost always fatal once the PDA closes

Diagnostic Work-Up

- Echo confirms the diagnosis
- CT and MRI can be used to clarify anatomy if needed

Management

- Prostaglandin for stabilization until surgical repair
- Primary complete repair of the interrupted arch and VSD is typical, but depends on the complexity of the cardiac anatomy
- Associated LVOT obstruction may require single ventricle palliation, a Ross-Konno or a Yasui procedure

Long-term Complications

- Depends on associated lesions and type of repair
- Recurrent LVOT obstruction is a common concern
- Patients are often asymptomatic, but do not perform normally on exercise tests

Questions

- What are the expected saturations in each limb in each form of interrupted aortic arch?
- What genetic syndromes are associated with interrupted aortic arch?
- What other cardiac lesions are associated with interrupted aortic arch?
- What are the expected cath numbers in a neonate with unrepaired interrupted aortic arch?

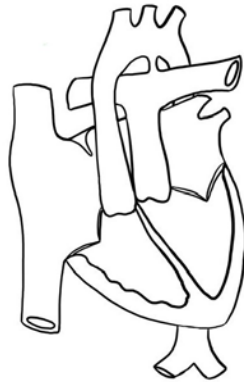References

- Ezon DS, Penny DJ. Aortic Arch and Vascular Anomalies. In: Allen HD, Shaddy RE, Penny DJ, Feltes TF, Cetta F, 9th, editors. Moss and Adams' Heart Disease in Infants, Children, and Adolescents: Including the Fetus and Young Adult. Philadelphia: Lippincott Williams & Wilkins; 2016.p.858-860.
- Park MK. Park's Pediatric Cardiology for Practitioners. 6th ed. Philadelphia: Elsevier Saunders;c2014. Chapter 13: Obstructive Lesions; p.184-205.

D-Transposition of the Great Arteries

Incidence is 2-3/10,000 live births. ~3% of all CHD, 20% of all cyanotic CHD.

- Male predominance



Concordant atrioventricular connections, and (normal) D-looped ventricles, but with discordance of the ventriculoarterial connections: the right ventricle is connected to the aorta, while the left ventricle gives rise to the pulmonary artery, causing the 2 circulations to be in parallel instead of in series.

Anatomic Variations

- TGA with intact ventricular septum (~50%)
- TGA with VSD
- TGA with LV outflow tract obstruction (LVOTO) and consequently limited pulmonary blood flow, with or without a VSD
- Associated anomalies: VSDs of all different types, LVOT obstruction at all levels, coarctation or interrupted aortic arch, coronary abnormalities

Clinical Presentation

- Associated with chromosomal syndromes, dextrocardia and heterotaxy, maternal pre-gestational diabetes and maternal vitamin A excess
- Presentation depends on anatomic associations, like intact ventricular septum vs. VSD and presence or absence of left ventricular outflow tract obstruction.
- **ALL will present with cyanosis at birth**
- If there is difficulty with mixing of oxygenated and deoxygenated circulations, hypotension and poor systemic perfusion will develop
 - A PDA or VSD can aid mixing, but often these are unreliable on their own
 - An unrestrictive ASD is necessary for adequate mixing!
- Exam:
 - Single S2
 - Typically no murmur, but if there is left ventricular outflow tract obstruction, a harsh systolic ejection murmur can be heard

Natural History

- Transposition is fatal if untreated, usually within the first week of life.
- Late presentation is possible (usually in developing countries) in children with a large ASD and VSD. There is a high risk of developing pulmonary hypertension unless there is enough LV outflow tract obstruction to limit pulmonary blood flow.
- ~20% are diagnosed prenatally, but D-TGA can be missed on the routine 20 week ultrasound

Diagnostic Work-up

- **CXR:**
 - Because the aorta and pulmonary artery have a closer anterior-posterior relationship, the mediastinal shadow is narrow, giving the “egg on a string” appearance
 - If there is a large VSD and overcirculation, cardiomegaly and increased pulmonary vascular markings are present
- Echo confirms the diagnosis

Treatment

- In the newborn period, adequate mixing is of paramount importance.
 - PGE is administered to keep the PDA open and promote the flow of deoxygenated blood from the aorta to the pulmonary arteries and increase pulmonary venous return to the left atrium so more oxygenated blood can cross to the right atrium to RV and out the aorta. The PDA itself is NOT AN IMPORTANT location for mixing.
 - Catheter based balloon atrial septostomy (BAS) is performed to increase mixing at the atrial level if there is severe cyanosis due to inadequate mixing
- Arterial Switch Operation (ASO)*
 - Standard of care for TGA with intact ventricular septum or TGA/VSD without LVOTO
 - Involves transecting both great arteries above the valves and reimplanting the coronary arteries. The pulmonary valve now acts as the aortic valve and is called the “neo-aortic valve.”
 - Usually performed in the early neonatal period, otherwise as the PVR falls, the LV can decondition as it is only pumping blood to the lungs (low pressures system). After repair, the LV will pump to the aorta and need to be able to pump at systemic blood pressures.
 - Developed in 1975, so relatively new.
- Rastelli Procedure*
 - Procedure for TGA with VSD and LVOTO
 - Involves closure of the VSD to baffle LV flow to the aorta and placement of an RV-PA conduit
 - May be delayed for months as the LVOTO may be somewhat protective against pulmonary overcirculation and the risk of pulmonary hypertension
 - May require a shunt to avoid cyanosis if pulmonary blood flow is significantly decreased.
- Current adults may have undergone Mustard/Senning procedure* – or an “atrial” switch operation, allowing deoxygenated blood to go to the LV and then to the lungs, and oxygenated blood goes to the RV and to the aorta.

Post-op Complications

- After Arterial Switch Operation
 - Branch PA stenosis is common due to the LeCompte maneuver of draping PAs anterior to aorta, may require ballooning or stenting.
 - Coronary compression with resulting ischemia is possible after reimplantation
- After Rastelli Procedure
 - LVOTO (blood must pass from LV through the former VSD and out the aorta that is still anterior and rightward of normal position)
 - Heart block
 - VSD patch leaks
- After Mustard/Senning operation
 - Baffle leaks in the atria
 - Rhythm issues due to all the sutures in the atria

Long-Term Complications

- Neurodevelopmental issues
- After Arterial Switch Operation:
 - Supravalvar pulmonary stenosis, branch pulmonary artery stenosis, semilunar valve dysfunction, neo-aortic arch dilation
 - Coronary abnormalities
- After Rastelli Procedure
 - Right or left ventricular outflow tract obstruction
 - Need for RV-PA conduit revisions as child grows + conduit calcifies/narrows
- After Mustard/Senning
 - Baffle leaks
 - Baffle obstruction leading to pulmonary hypertension
 - Systemic AV valve (tricuspid valve) regurgitation
 - Systemic right ventricular failure
 - Atrial and ventricular arrhythmias, sinus node dysfunction

Questions

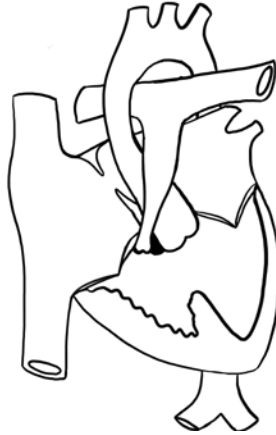- What is the definition of transposition of the great arteries?
- What are the expected saturations at birth?
- How can one differentiate at the bedside between a respiratory cause for cyanosis and a congenital heart lesion?
- Why might a newborn have “reverse” differential cyanosis?
- What are the expected cath numbers in a neonate with unrepaired D-TGA?

Resources

Qureshi AM, Justino H, Heinle JS. Transposition of the Great Arteries. In: Allen HD, Shaddy RE, Penny DJ, Feltes TF, Cetta F, 9th, editors. Moss and Adams' Heart Disease in Infants, Children, and Adolescents: Including the Fetus and Young Adult. Philadelphia: Lippincott Williams & Wilkins; 2016. p.1163-1185.

Tetralogy of Fallot:

TOF accounts for ~10% of cases of congenital heart disease (CHD), occurs in 3 infants for every 10,000 births, and is the most common cause of cyanotic CHD. There is no known gender preference.



4 components: pulmonary stenosis, (usually unrestrictive) VSD, right ventricular hypertrophy, and aortic override. Now considered to be a “monology,” as all components are sequelae of the anterior deviation of the outlet septum and related to underdevelopment of the pulmonary infundibulum.

Anatomic variations and clinical presentation

- Clinical symptoms depend on degree of right ventricular outflow tract obstruction.
 - If there is severe obstruction, neonates may shunt right to left across the VSD and present with cyanosis within days of life due to reduced pulmonary blood flow – “blue tet”
 - If there is minimal obstruction, neonates may have normal saturations – “pink tet.” May present at 4-6 weeks of life due to heart failure symptoms from the large VSD as PVR drops.
 - Hypercyanotic episodes “tet spells” happen when there is an abrupt worsening in cyanosis and breathlessness provoked by crying, causing right to left shunting across VSD, severe reduction of pulmonary blood flow, with risk of ischemia from cyanosis.
 - Management (in order of severity progression):
 - Comfort and remove stressors
 - Flex knees or place in squatting position
 - Give fluid bolus
 - Morphine
 - IV propranolol
 - Phenylephrine to drive up SVR and promote pulmonary flow
 - Anesthesia with intubation.
 - Once a patient has had a TOF spell, surgery should occur within days.
- Variants: Tetralogy of Fallot/pulmonary atresia, Tetralogy of Fallot/pulmonary atresia/multiple aortopulmonary collateral arteries, Tetralogy of Fallot with absent pulmonary valve.

Associations

- Commonly associated with a dysplastic and bicuspid pulmonary valve
- Approximately 5-7% of patients have coronary abnormalities: e.g. LCA arising from the right cusp or a single coronary artery.
- In 20-25% of patients, there is a right sided aortic arch.
- Significant association with 22q11.2 deletion, Holt-Oram, Alagille syndrome, Trisomies 21, 18 and 13.

Natural History

If unrepaired, progressive infundibular stenosis and RVH reduces pulmonary blood flow, causing worsening right to left shunting and cyanosis.

Diagnostic Work-up

- Physical Exam: Normal first heart sound, +/- single second heart sound, and a loud SEM heard best at LUSB that radiates to back. The murmur is from right ventricular outflow tract obstruction (RVOTO), not the VSD. If very severe RVOTO, may have very soft murmur due to minimal antegrade flow (e.g. during TOF spell).
- Many patients are now diagnosed prenatally with fetal echocardiogram
- Echo confirms the diagnosis

Treatment

- **Surgical Repair:** Patch closure of VSD (usually via right atriotomy), PFO/ASD closure and relief of RVOT obstruction via a combination of the following:
 - Infundibular muscle bundle resection
 - Transannular patch* (requires a tiny ventriculotomy and destroys the integrity of the pulmonary valve causing free pulmonary insufficiency)
 - Pulmonary valve-sparing valvuloplasty*
 - Main pulmonary artery plasty and/or infundibular patch
 - May require RV to PA conduit* if there is coronary involvement or if pulmonary atresia
- **Timing**
 - Blue Tet: likely will require neonatal repair; some centers will palliate with BT shunt with full repair ~6 months later
 - Pink Tet: Elective repair at 3-6 months of age.

Post-op complications

- Residual VSD
- Residual RVOTO
- Arrhythmia (JET, complete heart block)
- Pulmonary insufficiency, residual RVOTO, residual VSDs, tricuspid regurgitation, and RVOT aneurysms

Long-term complications

- Pulmonary insufficiency contributes most to post-op pathophysiology: leads to chronic RV overloading that can be tolerated for a time, but may become irreversible, leading to ventricular arrhythmias, overt RV failure, and risk of sudden death
 - Often need pulmonary valve replacement (surgical or catheter intervention) once pulmonary insufficiency develops
- Rhythm abnormalities (major issue, may eventually need an AICD) – right bundle branch block is a common finding from damage to the right bundle branch during VSD closure

Questions

- What determines the expected saturations in a patient with unrepaired Tetralogy of Fallot?
- What are the typical ECG findings?
- What are 3 other common problems in patients with DiGeorge syndrome?
- What are the expected cath numbers in an infant with unrepaired TOF?

Resources

Gaca AM, Jagers JJ, Dudley T, Bisset GS. Repair of Congenital Heart Disease: A Primer – Part 2. Radiology 2008; 248 (1): 54.

Roche L, Greenway S, Redington A. Tetralogy of Fallot with Pulmonary Stenosis and Tetralogy of Fallot with Absent Pulmonary Valve. Moss and Adams 8th edition.

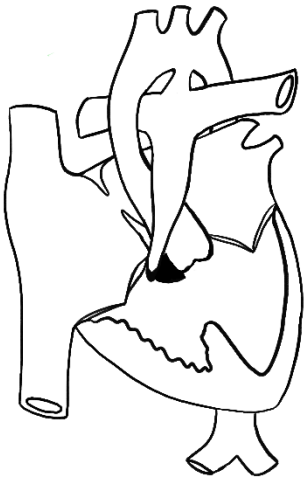Tetralogy of Fallot with Pulmonary Atresia or Pulmonary Atresia with VSD

2% of congenital heart disease. ~20% of all forms of Tetralogy of Fallot.

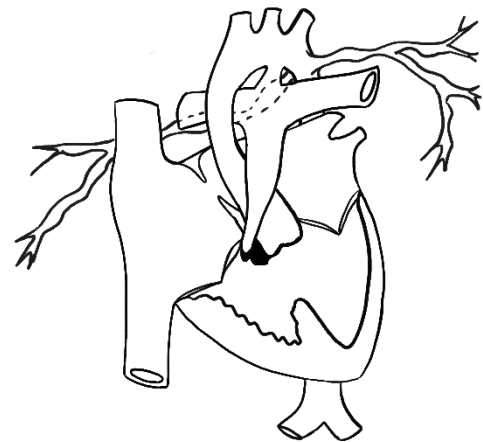
10% of patients with 22q11 deletion have TOF/PA.

All forms have an atretic pulmonary valve with an anteriorly malaligned VSD and RVH **Spectrum of Disease depending on the source of pulmonary blood flow**

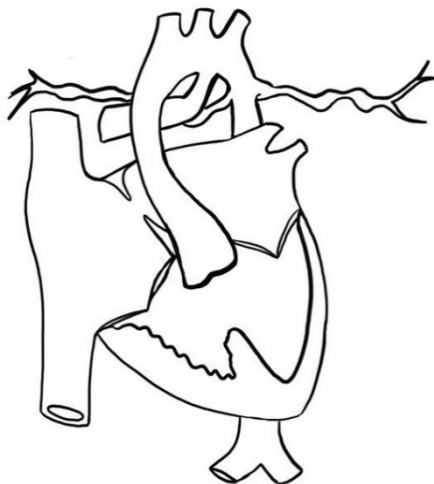- Confluent, well-developed PAs supplied by large PDA
- Hypoplastic confluent branch PAs with a few MAPCAs (Major Aortopulmonary Collateral Arteries)
- Discontinuous branch PAs and variable supply



TOF/PA with a duct to the central PAs

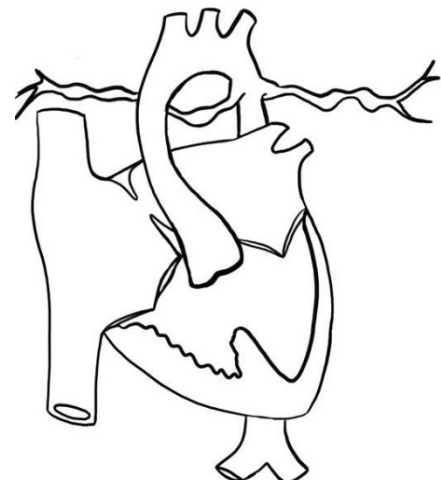

TOF/PA with a duct to central PAs plus MAPCAs



TOF/PA with a duct supplying 1 PA, flow to the other lung via

TOF/PA/MAPCAs with absent PAs



Clinical Presentation

Presentation depends on pulmonary blood supply

- Majority are cyanotic at birth, worsens as duct closes.
- If MAPCAs are well-developed, may not show cyanosis until later.
- In rare cases, if MAPCAs are large, there is overcirculation and evidence of heart failure.
- Associations
 - Right sided aortic arch
 - ASD/PFO

Natural History

- Ductal dependent PAs: the neonate will become critically hypoxic if the duct closes
- Small MAPCAs can become stenotic over time and cause progressive hypoxia
- Large MAPCAs can cause excessive pulmonary blood flow leading to heart failure

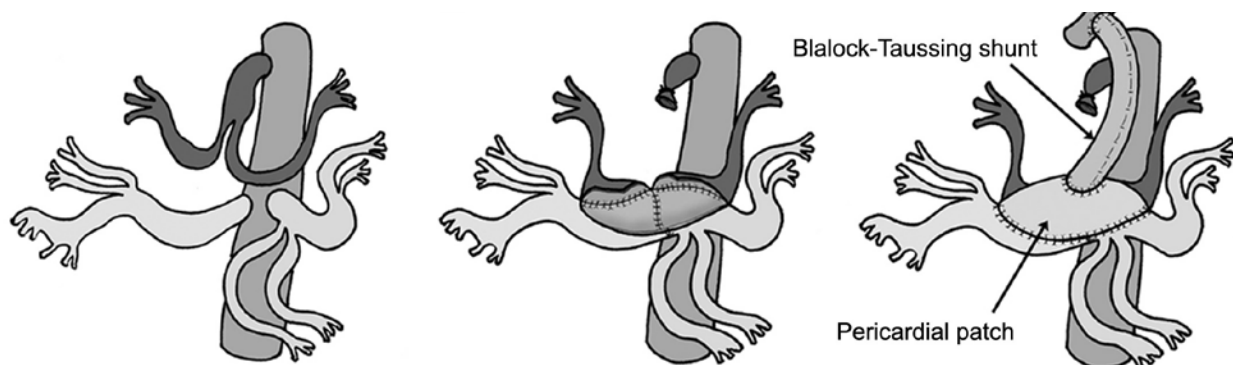
Diagnosis/Workup

- Most patients are now diagnosed prenatally
- Echo confirms the diagnosis
- If there are small central PAs, or multiple MAPCAs, CT or Cath is recommended to delineate the pattern of blood flow

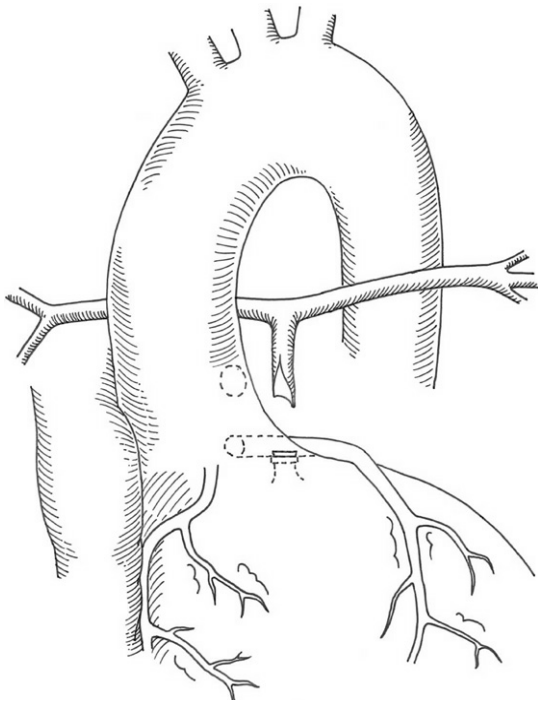
Surgical Repair

- Depends heavily on the degree of communication between the central PAs and the MAPCAs and the degree of pulmonary blood flow
 - If there is limited pulmonary blood flow and no central PAs: augment pulmonary blood flow with a central shunt and unifocalization of the MAPCAs. Can eventually close the VSD once the central PAs have grown and connect the RV to the PAs with a conduit, “complete intracardiac repair.”
 - If there are hypoplastic central PAs that supply all regions of the lungs (all “dual supply”): augment pulmonary blood flow with an AP window and ligate the MAPCAs. Can eventually close the VSD and connect the RV to the PAs with a conduit.
 - If there are single supply MAPCAs and PAs, a combination of methods may be used.

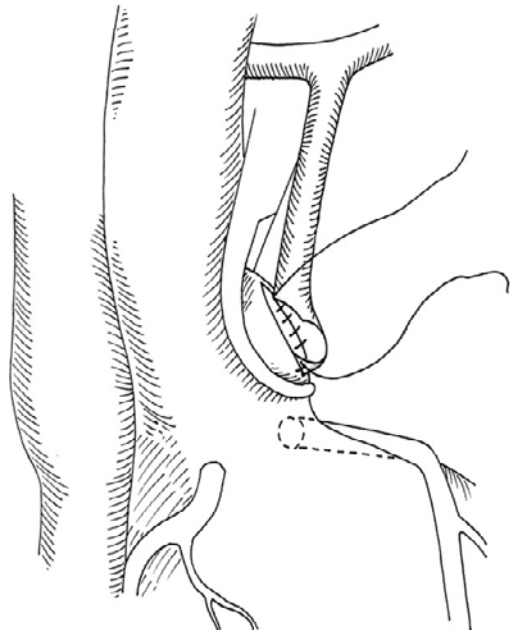
Unifocalization



AP Window

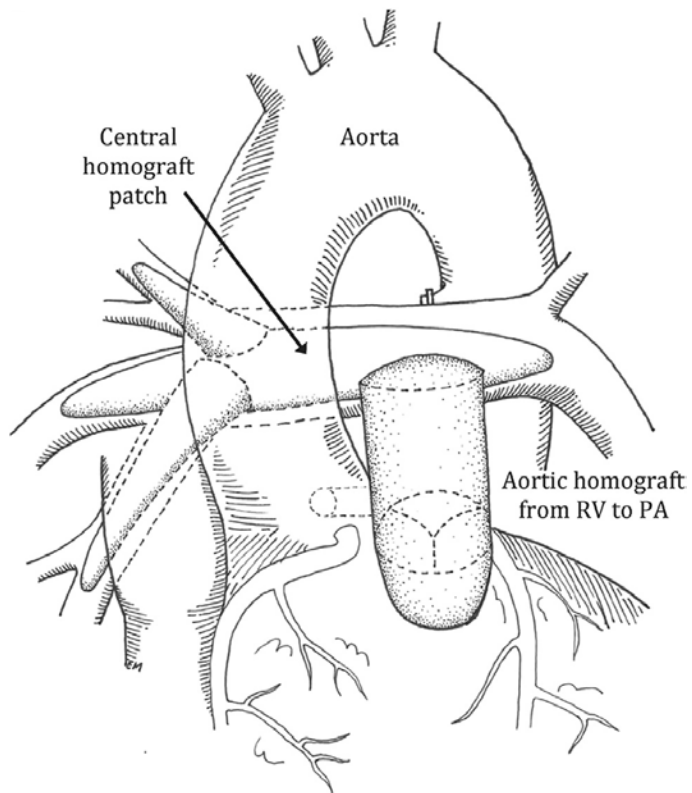


Watanabe, et al.



Complete Repair

Watanabe, et al.



Long-term complications

- Conduit will require upsizing over time as the child grows.
- Restenosis of MAPCAs can cause increased RV pressure and hypoxemia.
- Abnormal pulmonary architecture predisposes patients to pulmonary hypertension.
- Pulmonary insufficiency requiring conduit revisions.
 - Chronic right ventricular overloading may become irreversible over time, leading to ventricular arrhythmias, overt RV failure, and sudden cardiac death.
- Rhythm abnormalities.
- Some patients never become candidates for VSD closure and remain hypoxic for life.

Questions

- What determines the child's saturation?
- What murmur would you expect to hear?
- What are some genetic syndromes associated with TOF/PA/MAPCAs?

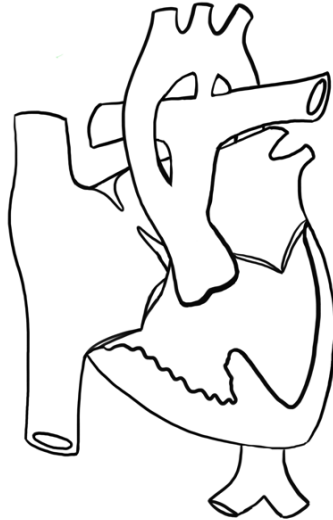References

- O'Leary PW, Edwards WD, Julsrud PR, Burkhart HM. Pulmonary Atresia and Ventricular Septal Defect. In Allen HD, Driscoll DJ, Shaddy RE, Feltes TF, 8th, editors. *Moss and Adams' Heart Disease in Infants, Children, and Adolescents: Including the Fetus and Young Adult*. Philadelphia: Lippincott Williams & Wilkins; 2013, p.959-968.
- Shinkawa T, Yamagishi M, Shuntoh K, Yaku H. One-stage unifocalization followed by staged Fontan operation. *Interact CardioVasc Thorac Surg* 2007; 6(3):416-47.
- Watanabe N, Mainwaring RD, Reddy VM, Palmon MP, Hanley FL. Early complete repair of pulmonary atresia with ventricular septal defect and major aortopulmonary collaterals. *Ann Thorac Surg* 2014; 97: 909-915.

Truncus arteriosus

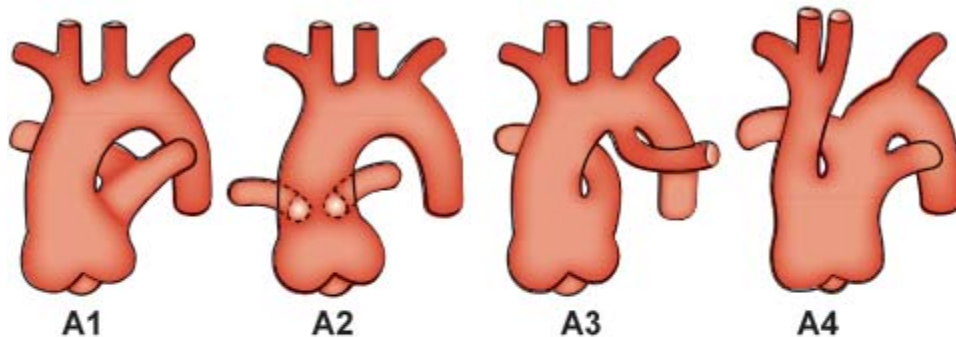
Uncommon malformation, no gender preference.

Usually occurs in isolation, but can be associated with 22q11 deletion or maternal diabetes.



Failure of septation of the arterial trunk into 2 great arteries. By definition the systemic, pulmonary, and coronary circulations arise from one ascending artery.

Van Praagh Classification



50-70%

Short pulmonary trunk originates from the aorta and gives off both PAs

No pulmonary trunk, both PAs arise directly from the ascending aorta

RPA arises directly from the aorta, LPA arises from the ductus arteriosus

Underdeveloped arch, may have complete arch interruption where 1 PA arises from the disconnected descending aorta

Adapted from *Moss and Adams*

- All have a VSD
- Truncal valve can be tricuspid (~70%), quadricuspid (~20%), bicuspid (9%), pentacuspid, or unicuspid. Usually truncus arises from both ventricles equally (above the VSD), but in ~10-20% it arises from the RV, and in 5% it arises from the LV.

- Associations: Right aortic arch, coronary origin abnormalities, coronary ostial abnormalities, interrupted aortic arch, absent ductus, stenotic and/or incompetent truncal valve.

Clinical Presentation

- Neonates rarely present with cyanosis. Most have tachypnea, tachycardia, diaphoresis, and poor feeding as severe pulmonary overcirculation develops.
- If there is severe truncal insufficiency, heart failure symptoms will present even earlier.
- Physical exam: Usually loud single S2, often opening clicks, loud pansystolic murmur heard at LLSB. If truncal insufficiency is present, can have a diastolic murmur.

Natural History

- Rarely survival to adulthood if unrepaired; mean age of death is ~5 weeks.
- Cause of death is heart failure
- Hypertrophied ventricle is exposed to ischemia due to runoff from the aorta to the PAs and diminished perfusion (especially if there is truncal valve insufficiency with a low diastolic BP).
- Most will develop severe hypertensive pulmonary vascular disease due to constant exposure of the pulmonary bed to systemic blood pressures and extra pulmonary blood flow.
- Infective endocarditis is also common

Diagnosis/Workup

- CXR may show cardiomegaly and increased pulmonary markings
- ECHO confirms the diagnosis

Types of Repair

- Complete repair in neonatal period is preferred
- Use the truncus as the aorta, place an RV to PA conduit to branch PAs, and close the VSD*
- If there is truncal valve regurgitation or stenosis, attempt primary repair.

Long-term Complications

- Determined by degree of truncal valve regurgitation/stenosis - may require neo-aortic valve replacement in the future
- Infective endocarditis
- Development of branch PA stenosis due to the LeCompte maneuver (see appendix)
- All children will need RV to pulmonary artery conduit replacements as they grow.

Questions

- What are the expected saturations at birth? After 5 days?
- What are some reasons that truncal insufficiency may lead to poor prognosis for patients?
- How is truncus arteriosus different from TOF/PA/MAPCAs?

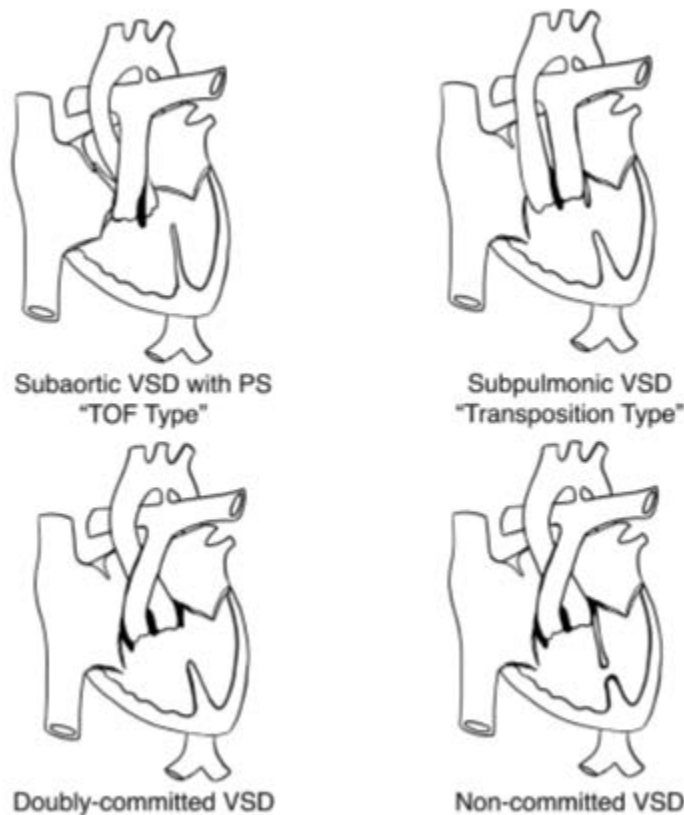
References

Cabalka AK, Edwards WD, Dearani JA. Truncus Arteriosus. In: Allen HD, Shaddy RE, Penny DJ, Feltes TF, Cetta F, 9th, editors. Moss and Adams' Heart Disease in Infants, Children, and Adolescents: Including the Fetus and Young Adult. Philadelphia: Lippincott Williams & Wilkins; 2016. p.1053-1063.

Double Outlet Right Ventricle (DORV)

- 0.006% of all live births, occurs in fewer than 1% of all congenital heart defects
- No race or gender preference

DORV is a conotruncal defect, and the heterogeneity in this diagnosis is dependent on the amount of conus (tube of muscle) under the aortic and pulmonary valves, directing their locations. It can be found in univentricular and atrioventricular discordant hearts as well. Some use the “>50% rule” to define DORV: Fifty percent or more of both great arteries arise from the right ventricle in the presence of a ventricular septal defect. Others label DORV when there is fibrous discontinuity (presence of conal muscle) separating the mitral valve and semilunar valve.



Anatomic Variants

- The most common variant is DORV with subaortic VSD and PS, also known as a “TOF-Type” DORV. In this lesion, the majority of conus is underneath the pulmonary valve, pushing it anteriorly and superiorly, and the minimal conus below the aortic valve pushes the aortic valve slightly to override the ventricular septum, similar to TOF. There may be less than 50% of Aorta over the RV, but there will be fibrous discontinuity between mitral and aortic valves.

- The second most common variant is DORV with subpulmonic VSD, also known as “Transposition-Type” DORV or a “Taussig-Bing” anomaly. In this, the majority of the conus sits below the aortic valve, pushing it anteriorly and superiorly, and the small amount of conus below the pulmonary valve causes it to slightly override the ventricular septum. The physiology is similar to that of TGA.
- The third most common variant is DORV with subaortic VSD and no PS, also known as the “VSD-type” of DORV. In this lesion, there is more conus tissue underneath the pulmonary valve, but still enough under the aortic valve to push it rightward, though not anterior. The physiology of this type is similar to a large VSD which will not close on its own and require surgery, which is true of all conotruncal VSDs.
- Many other variants of DORV exist with varying levels of conus under each valve, including DORV with non-committed VSD, and DORV with doubly-committed VSD.

Clinical Presentation

- Depends on morphology of the conus and relative location of VSD to great arteries. *Always specify the great artery relationship in a patient with DORV.*
- DORV with subaortic VSD and PS (“TOF-Type”):
 - Degree of cyanosis depends on degree of pulmonary stenosis
 - Can have hypercyanotic episodes, like TOF
 - Harsh systolic ejection murmur, loudest at LUSB
- DORV with subpulmonic VSD (“Transposition-Type”):
 - Cyanotic neonate due to transposition physiology
 - Can be associated with subaortic narrowing, leading to arch hypoplasia or interruption. Should always use PGE until full arch imaging complete.
- DORV with subaortic VSD without PS (“VSD-Type”)
 - Significant left to right shunting as pulmonary vascular resistance falls in first few weeks of life.
 - Pulmonary overcirculation leads to congestive heart failure symptoms (See VSD.)
 - Failure to thrive, tachypnea, etc.

Natural History

- History depends on morphology and follows the physiology that they closely approximate.

Diagnostic Work-Up

- DORV with subaortic VSD and PS (“Tet-Type”):
 - CXR: diminished pulmonary markings, oligemic pulmonary circulation
 - EKG: Right axis deviation, RVH
 - ECHO confirms the diagnosis
- DORV with subpulmonic VSD (“Transposition-Type”):
 - CXR: increased pulmonary markings, edema
 - ECHO confirms the diagnosis
- DORV with subaortic VSD without PS (“VSD-Type”):

- CXR: increased pulmonary markings, edema
- ECHO confirms the diagnosis

Treatment

- Depending on morphology, medical management can be a temporizing measure, but surgical intervention is required in ALL forms. Conoventricular VSDs do not close on their own, so even in simple DORV without PS, VSD closure in infancy indicated.
- Type of surgery depends on anatomic factors: size and position of VSD, distance between tricuspid valve and pulmonary valve, relationship and sizes of the great arteries, presence of RVOTO or LVOTO, coronary abnormalities, etc.
- May involve palliation with shunting or pulmonary arterial banding to augment or limit pulmonary blood flow depending on Qp/Qs.
- With malposed great arteries, surgery will be Rastelli or arterial switch, depending on position and size of the VSD and ability to create a connection between the left ventricle and the aorta. Potential for single ventricle pathway if above options are not possible.

Long-term Complications

- Depending on the surgery, patients may have reoperation due to:
 - LVOT or RVOT obstruction
 - RV to PA conduit replacements (if Rastelli performed).
 - RV failure
- Like all complex CHD, risk of arrhythmias in the future
- Overall survival is high

Questions

What are the expected saturations for a “Tet-type” DORV? “Transposition-Type”? “VSD-Type?”

What are the expected cath numbers for each?

What type of arrhythmias might you expect to see in the future?

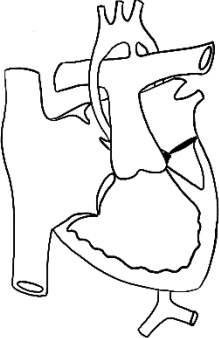
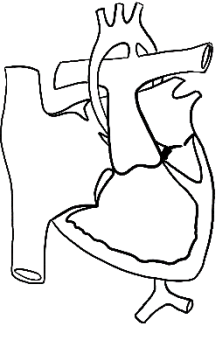

References

Wright GE, Maeda K, Silverman NH, et al. Double-Outlet Right Ventricle. In: Allen HD, Shaddy RE, Penny DJ, Feltes TF, Cetta F, 9th, editors. Moss and Adams’ Heart Disease in Infants, Children, and Adolescents: Including the Fetus and Young Adult. Philadelphia: Lippincott Williams & Wilkins; 2016.p.1201-1216.

Hypoplastic Left Heart Syndrome

- 0.02% of all live births, 1.4-3.8% of all congenital heart disease
- Most common form of functional single ventricle heart disease and a significant portion of congenital cardiac-related neonatal mortality.
- Male to female ratio approximately 1.5:1.

Hypoplasia of all left sided structures with an intact ventricular septum. Requires ductus arteriosus for systemic blood flow and is fatal without prostaglandin therapy and subsequent surgical palliation.

 <p>HLHS (MA/AA)</p> <p>36-46% Most extreme form with a string-like arch</p>	 <p>HLHS (MS/AA)</p> <p>20-29% Inflow into LV without avenue for decompression causes a hypertrophied LV with endocardial fibroelastosis, risk for coronary-cameral fistulae, and abnormal RV-LV interactions</p>	 <p>HLHS (MS/AS)</p> <p>23-26% Arch hypoplasia less significant, on the spectrum of critical AS</p>
--	---	---

Higher Risk Subgroups:

- Heterotaxy
- Pulmonary vein abnormalities (5%)
- Restrictive atrial septum (1%)
- Tricuspid valve abnormalities or acquired tricuspid valve regurgitation

Clinical presentation:

- Infants who do **not** have a restrictive ASD usually have a "honeymoon" period right after birth because of adequate systemic perfusion through a PDA and initially relatively high PVR
 - In some cases, a dusky appearance due to cyanosis is noted in the newborn nursery, but other patients may appear normal and be discharged home. **Key population for universal oximetry in WBN to detect these babies!**
 - As the PDA begins to close and PVR falls, infants become symptomatic with a decrease in systemic perfusion → diminished peripheral pulses and increasing pulmonary blood flow → hypotension, acidosis, and respiratory distress → heart failure and cardiogenic shock
- Infants with a restrictive or no ASD at birth present with *severe* cyanosis and respiratory distress **immediately** because of inadequate mixing of oxygenated and deoxygenated blood and increasing pulmonary venous congestion.
 - Requires urgent creation of an adequate interatrial communication (via atrial septostomy) or cardiogenic shock and death ensue
- Exam: cyanosis, respiratory distress, cool extremities, typically NO murmur, decreased peripheral pulses.
- 2-4% risk of left-sided heart disease in first degree relatives of infants with this disease
- Associations:
 - Turner syndrome
 - Jacobsen's syndrome
 - Trisomies 13, 18 and 21
 - Noonan syndrome
 - Kabuki syndrome
 - Smith-Lemli-Opitz syndrome
 - Holt-Oram
 - Ellis-van Creveld
 - CHARGE syndrome.
- 15-30% have extracardiac anomalies, of these 29% have a brain anomaly (agenesis of the corpus callosum, holoprosencephaly)

Natural History

- With medical and surgical interventions, the five-year survival rate is ~65 to 70 percent
- If left untreated, 95 percent of neonates with HLHS die within the first few weeks of life

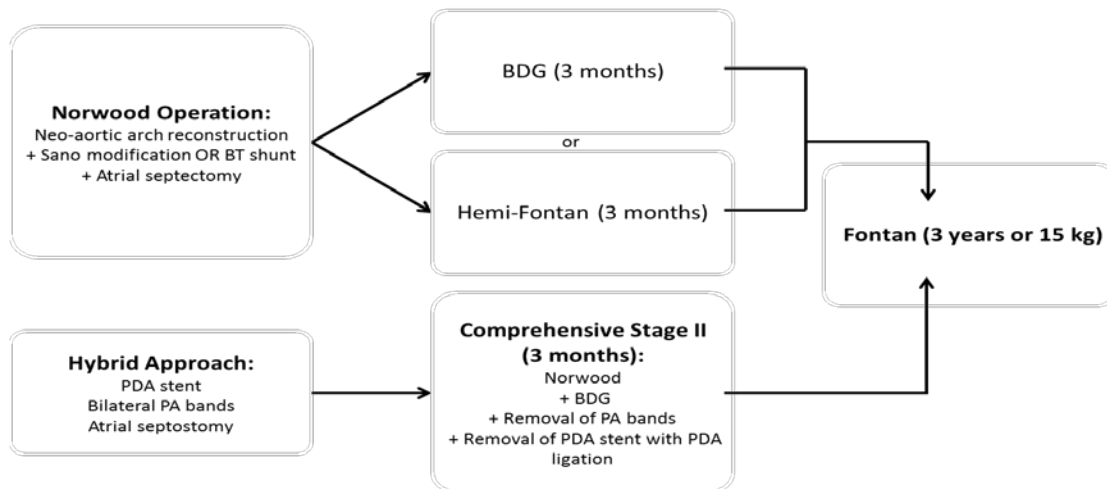
Diagnostic Work-up

- Echo confirms the diagnosis
- Cath is recommended in some cases to outline other anomalies and/or evaluate coronary flow in patients with MS/AA type anatomy

Types of Repairs

(1) Single Ventricle Pathway: staged palliation to separate circulations with goal of passive blood flow to the lungs and use of the right ventricle as the systemic pumping chamber

- **Stage 1** goal is to provide unobstructed blood flow from the RV to the systemic circulation, place a controlled source of pulmonary blood flow (BT shunt or RV-PA Sano shunt or PDA stent), and ensure an unobstructed pathway between the pulmonary venous return and the systemic RV
 - **Norwood operation*:** DKS and creation of neo-aorta, source of pulmonary blood flow, and atrial septectomy
 - **Hybrid operation*:** avoids cardiopulmonary bypass in the neonatal period, but commits the infant to a much more involved stage 2 procedure
- **Stage 2: Bidirectional Glenn or Superior Cavopulmonary Connection*** (connection of SVC to PAs)
- **Stage 3: Fontan*** (connection of IVC to PAs, via a Lateral Tunnel Fontan or Extracardiac Conduit)
 - May be fenestrated for a “pop off” if PVR rises – preference here is for no fenestrations to be placed except for very high risk Fontan candidates
 - The fenestration usually spontaneously closes, or it can be closed in the cath lab at a later date



(2) Cardiac transplantation: still done as primary surgery at a few institutions

- Overall mortality rate while awaiting transplant still 21-37%

Post-op Complications

- **After Stage 1 (Norwood)**
 - Unbalanced Qp/Qs
 - Arrhythmias: junctional ectopic tachycardia, SVT, VT, complete heart block
 - RV failure
 - Re-coarctation

Adapted from: Park's Pediatric Cardiology

- Shunt thrombosis (either RV-PA conduit or modified BT shunt)
- High mortality rates in the “interstage” period (between Stage 1 and Stage 2 palliations)
 - Improved with careful home monitoring of weight and saturation and close communication with the patient’s medical team
 - Higher risk of interstage mortality associated with initial anatomy of aortic atresia or restrictive atrial septum and with post-op development of recurrent arch obstruction, obstruction to pulmonary blood flow, distortion of pulmonary arteries, tricuspid valve regurgitation and arrhythmias
- **After Stage 2 (Bidirectional Glenn or Hemi-Fontan)**
 - SVC Syndrome
 - Pleural effusions including chylothorax
 - Venovenous collaterals
 - Pulmonary arteriovenous malformations
 - Re-coarctation
 - RV failure
 - Arrhythmias
- **After Stage 3 (Fontan)**
 - Pleural effusions, including chylothorax
 - RV failure or diastolic dysfunction
 - Elevated CVP leading to decreased cardiac output
 - Fontan thrombosis
 - Arrhythmias

Long-term Complications of Fontan Physiology (Lateral Tunnel or Extracardiac Conduit)

- Venovenous collaterals causing cyanosis
- Sinus node dysfunction
- Atrial arrhythmias
- Protein losing enteropathy: intestinal protein loss leading to hypoalbuminemia
 - Unclear etiology, may be due to elevated systemic venous pressures, diastolic dysfunction or inflammation of the bowel wall
 - Most commonly begins 2-3 years after Fontan, 46% 5 year survival after diagnosis
- Hepatic dysfunction
- Plastic bronchitis
- Thromboembolic complications, including stroke and pulmonary embolus
- RV dysfunction (systolic and diastolic)
 - Symptoms include exercise intolerance, fatigue, dyspnea or syncope
- Developmental delays
- **At this point, most and perhaps all patients with HLHS will ultimately require cardiac transplantation**

Questions

- What are the expected saturations in the neonatal period, after stage 1, after stage 2, and after Fontan?
- What are signs and physical exam findings of pulmonary overcirculation?
- In the absence of prenatal diagnosis, how will infants present?
- Describe the physiology of an infant with HLHS maintained on prostaglandin therapy.
- What are the side effects of prostaglandin therapy?
- Describe the blood flow in a patient with HLHS and an intact atrial septum.
- Which patients are higher risk candidates for the Norwood? Glenn? Fontan?
- What cath numbers make a patient a “good” candidate for the Glenn and Fontan? What other information is assessed during the pre-surgical cath for each stage?

References

Feinstein JA, Benson DW, Dubin AM, et al. Hypoplastic Left Heart Syndrome. *JACC* 2012; 59(1):S1-S42.

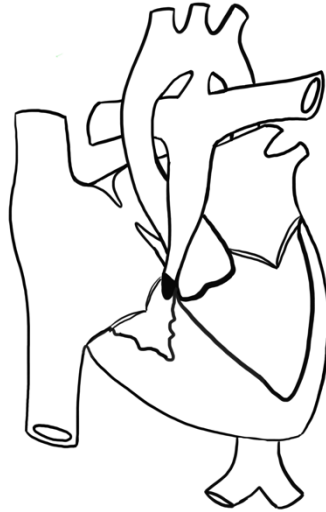Park MK. Park's Pediatric Cardiology for Practitioners. 6th ed. Philadelphia: ElsevierSaunders;c2014.

Chapter 14: Cyanotic Congenital Heart Defects; p.206-289.

Tweddell JS, Hoffman GM, Ghanayem NS, et al. Hypoplastic Left Heart Syndrome. In: Allen HD, Shaddy RE, Penny DJ, Feltes TF, Cetta F, 9th, editors. Moss and Adams' Heart Disease in Infants, Children, and Adolescents: Including the Fetus and Young Adult. Philadelphia: Lippincott Williams &Wilkins; 2016.p.1125-1161.

Pulmonary Atresia with Intact Ventricular Septum (PA/IVS)

4-8 per 100,000 live births, 1-3% of patients with congenital heart disease.



Anatomic variations and clinical presentation

Spectrum of lesions involving pulmonary atresia with variable degrees of hypoplasia of the right ventricle and anomalies of the coronary arteries.

- Spectrum of disease: From atresia of the entire RVOT with tiny RV to nearly-normal sized right ventricle, tricuspid valve, and main pulmonary artery with plate-type atresia.
- Prognosis depends on:
 - Type of pulmonary valve atresia: 2 main forms
 - 80% have membranous atresia at the level of the valve (with a well-formed infundibulum and trileaflet pulmonary valve with fused cusps)
 - 20% long segment muscular atresia of the right ventricular outflow tract, associated with severe right ventricular hypoplasia, increased risk and severity of coronary artery abnormalities, and poor outcome.
 - Presence (25%) or absence (75%) of a right ventricular-dependent coronary circulation (RVDCC)
 - RV-coronary sinusoids often present in small, hypertrophied RVs
 - Stenoses can form in these sinusoidal connections, making flow to cardiac muscle distal to the stenosis dependent on the high pressure RV
 - RVDCC defined as coronary blood flow that is at least partially dependent upon retrograde blood flow from the RV.
 - Decompression of an RV with RVDCC by opening up the pulmonary valve can result in decreased flow to these coronaries, myocardial ischemia and death
 - Degree of tricuspid regurgitation and size of the tricuspid valve
 - Size of the right ventricle
 - RV myocardium can show evidence of ischemia, fibrosis and endocardial fibroelastosis with poor RV compliance

- Neonates present with cyanosis and a murmur consistent with tricuspid regurgitation
- No known genetic etiology or gender association.

Natural History

Without medical/surgical intervention, 80% die by 6 months of age or whenever the ductus closes

Diagnostic Work-up

- Physical exam: Single second heart sound due to a single semilunar valve (the aortic valve); Systolic murmur due to tricuspid regurgitation
- Chest X-ray: cardiomegaly from right atrial enlargement, dark lung fields due to low pulmonary blood flow
- EKG: LVH (always abnormal in neonates!), right atrial enlargement
- Echo confirms the diagnosis, defines membranous vs. muscular type atresia
- Cardiac cath: assess for a right ventricular-dependent coronary circulation, consider intervention to open pulmonary valve

Treatment

- Prostaglandin to keep PDA open.
- Non-RV-dependent coronary circulation
 - Perforation of pulmonary valve in cath lab or surgical opening of the pulmonary valve
 - +/- central shunt* or PDA stent* to supply additional pulmonary blood flow in setting of small restrictive RV.
 - Monitor for RV growth over time – some patients will achieve a 2 ventricle repair
- RV-dependent coronary circulation
 - Central shunt or PDA stent for pulmonary blood flow
 - Proceed down single ventricle pathway*; never decompress the RV.
 - Some institutions refer for transplant

Long-term complications

Depends on palliative strategy

- RV myocardium is abnormal, leads to restrictive physiology even in 2 ventricle repairs
- Patients with a biventricular repair may require pulmonary or tricuspid valve replacements
- Atrial and ventricular arrhythmias
- Risk of sudden death

Questions

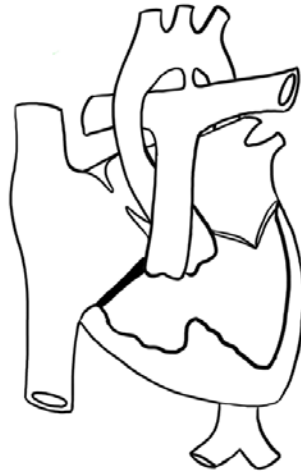- Describe blood flow in the neonate with PA/IVS.
- What are the expected saturations?
- What is the purpose of a “1 ½ ventricle” repair?
- What are the expected cath numbers in an infant with unrepaired PA/IVS?

Resources

Nykanen DG. Pulmonary Atresia and Intact Ventricular Septum. In: Allen HD, Shaddy RE, Penny DJ, Feltes TF, Cetta F, 9th, editors. Moss and Adams' Heart Disease in Infants, Children, and Adolescents: Including the Fetus and Young Adult. Philadelphia: Lippincott Williams & Wilkins; 2016. p.1009-1026. Park MK. Park's Pediatric Cardiology for Practitioners. 6th ed. Philadelphia: Elsevier Saunders; c2014.

Tricuspid Atresia

2.7% of all congenital heart disease.



Inlet portion of the right ventricle is absent and often there is a dimple in the floor of the right atrium where the valve would have been.

Type I (70-80%): Normally related great arteries → 3 main varieties:

- No VSD and pulmonary atresia
- Small VSD and pulmonary stenosis
- Large VSD without pulmonary stenosis.

Type II (10-25%): Transposed great arteries → 3 main varieties:

- VSD and pulmonary atresia
- VSD and pulmonary stenosis
- VSD without pulmonary stenosis

Type III (<10%): Congenitally corrected transposition of the great arteries

Clinical Presentation

- Presentation depends on type
 - No subpulmonary (at VSD) or pulmonary stenosis = increased pulmonary blood flow, relatively high saturations, and signs of overcirculation including tachypnea and poor weight gain
 - Pulmonary/subpulmonary (at VSD) stenosis or pulmonary atresia = marked cyanosis, may be dependent on PDA for pulmonary blood flow
 - Most patients with normally related great arteries will have progressive pulmonary or subpulmonary (at VSD) stenosis, while those with transposed great arteries usually have unobstructed pulmonary blood flow
- The VSD in tricuspid atresia has a muscular circumference and tends to become smaller over time. If there are normally related great arteries, this causes pulmonary obstruction and increasing hypoxemia. If there are transposed great arteries, this leads to subaortic obstruction.

- Physical exam: RV impulse may be diminished, first heart sound is single. If great arteries are transposed, may have single or louder second heart sound. If VSD present, may have holosystolic murmur.
- Associations
 - 22q11 deletion
 - Trisomies 13, 18 and 21
 - Mutations on chromosomes 3, 4, and 8.

Natural History

- Neonates with pulmonary atresia or critical pulmonary stenosis will die without prostaglandin and eventual surgical intervention.
- Cyanosis is variable in patients with less pulmonary stenosis, but this will increase over time as the VSD closes; 1 year mortality is 90% in unoperated patients.
- In patients with unobstructed pulmonary blood flow, congestive heart failure and pulmonary vascular obstructive disease develops over time.
- Bacterial endocarditis and brain abscesses are common complications

Diagnosis/Work-up

- History and Physical Exam. Many are now diagnosed prenatally.
- CXR is usually normal. May show prominent right heart border secondary to enlarged right atrium. If patients have pulmonary atresia, may show diminished lung markings, or if unobstructed, may have pulmonary edema.
- EKG will have a left or northwest axis
- ECHO is important to delineate the orientation of the great arteries, outflow obstruction, and VSD size. Will show an obligatory right to left shunt across the atrial septum.

Management/Types of Repair

- Cyanotic patients: Initiate PGE to maintain shunt, eventual need for surgical shunt in neonates and Glenn
- Unrestricted pulmonary blood flow patients: medically manage with diuretics, surgically place pulmonary artery band*
- Subaortic obstruction: consider VSD enlargement or DKS* and systemic-to-pulmonary shunt
- Eventual palliation to Glenn* and then Fontan*

Post-Op Complications

- Shunt thrombosis
- Residual subaortic obstruction
- Arrhythmias

Long-Term Complications

- Long-term Fontan complications

Questions

- What is the classic EKG finding in tricuspid atresia?
- What are the expected pressures and saturations?
- What are some of the late complications after Fontan palliation?

References

Cetta F, Dearani JA, O'Leary PW, Driscoll DJ. Tricuspid Valve Disorders: Atresia, Dysplasia and Ebstein Anomaly. In: Allen HD, Shaddy RE, Penny DJ, Feltes TF, Cetta F, 9th, editors. Moss and Adams' Heart Disease in Infants, Children, and Adolescents: Including the Fetus and Young Adult. Philadelphia: Lippincott Williams & Wilkins; 2016. p.949-959.

Total Anomalous Pulmonary Venous Connection (TAPVC)

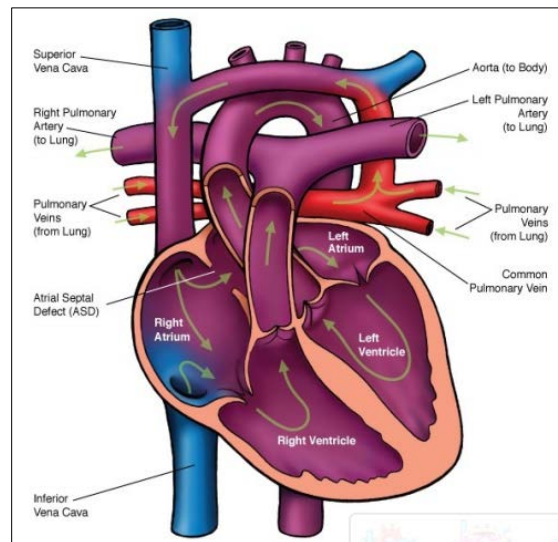
~ 0.4% and 2% of infants with congenital cardiac disease. There is a higher prevalence of TAPVC to the portal vein in males, though the rest of the connections have no gender preference.

The pulmonary veins in TAPVC have no connection with the left atrium, either draining into one of the systemic veins or into the right atrium.

Four types: supracardiac type, cardiac type, infracardiac type, and mixed type.

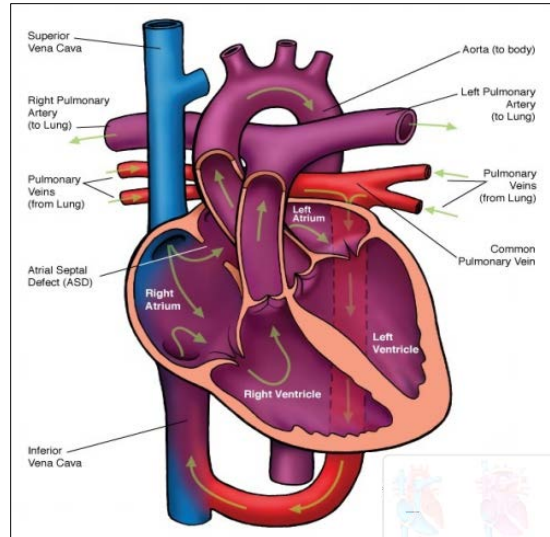
Anatomy

- All cases of TAPVC are associated with RA, RV, and PA dilation due to the left-to-right shunt. LA size is smaller than normal though LV size usually measures normally.
- Other anatomic features depend on type of connection:
 - **Supracardiac type**
 - Connection to the left innominate vein (most common): pulmonary veins create a confluence behind LA and a vertical vein originates from the left side, ascending to join the left innominate vein and then drain via the right SVC to the right atrium. Less commonly, the vertical vein connects to the posterior aspect of right SVC or azygos vein.
 - 50% of supracardiac type will develop venous obstruction, especially if the vertical vein courses between the left main bronchus and left pulmonary artery creating a vise.



www.childrensheartclinic.org

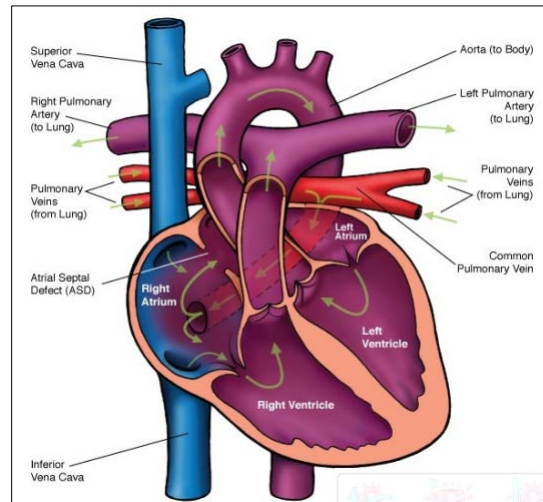
- **Cardiac Type**
 - Connection to the Coronary Sinus: pulmonary veins come together to create a common vein that connects to the CS.
 - Total anomalous venous drainage (TAPVD): all veins drain directly into RA
 - All veins may attach normally to the left atrium, but the atrial septum can be malpositioned way leftward so that pulmonary venous blood returns to the RA
 - Rarely have venous obstruction



www.childrensheartclinic.org

○ **Infracardiac Type**

- Connection to below the diaphragm: pulmonary veins create a confluence behind the LA and a vertical vein descends through the diaphragm and joins the portal vein (most common), ductus venosus, hepatic veins, or IVC.
- Usually have venous obstruction



www.childrensheartclinic.org

○ **Mixed type**

- Pulmonary veins drain into two or more of the aforementioned sites

○ **Associations**

- TGA, TOF, single ventricle, Truncus, Tricuspid Atresia, HLHS, PA/IVS, etc.
- TAVPD occurs in patients with visceral heterotaxy and polysplenia, and occasionally in heterotaxy patients with asplenia

Clinical Presentation

Symptoms depend on the amount of restriction at the level of the connection between the left and right sides of the heart, whether at the atrial septal communication or the vertical veins. There is obligate right to left flow at the atrial septum in order to allow for any blood to enter the left ventricle and provide cardiac output. **This is a complete mixing lesion.**

- **TAPVC without pulmonary venous obstruction:**
 - Initially, PVR and SVR are equal, so infants can be well balanced with saturations in mid-80% range. Over time, PVR drops, and saturations increase with pulmonary overcirculation. This leads to tachypnea, failure to thrive, and congestive heart failure.
 - Physical exam
 - Prominent RV heave
 - Loud S1, widely split S2 with no respirophasic variability
 - Third heart sound always heard at the apex
- **TAPVC with pulmonary venous obstruction:**
 - The obstruction can be at the level of the atrial septum or at the vertical vein.
 - Patients present with severe respiratory distress, cyanosis, acidosis, and shock.
 - Physical exam
 - Split second heart sound with loud P2
 - Rales at lung bases
 - Hepatomegaly and peripheral edema usually present

Natural History

- TAPVC without obstruction will progress to cardiac failure by 6 months of age due to the significant pulmonary overcirculation. Rarely, patients develop pulmonary hypertension and make it to childhood.
- TAPVC with obstruction will progress to death rapidly if not managed (**surgical emergency!**)

Diagnostic Work-up

- **EKG**
 - In TAPVC without obstruction: tall p waves due to RAE, right axis deviation and RVH
 - In TAPVC with obstruction: RVH and right axis deviation, less likely to have RAE
- **CXR**
 - TAPVC without obstruction may show a “snowman” appearance if the vertical vein connects to the innominate vein.
 - TAPVC with obstruction will show a “whiteout” of the lung fields – often hard to differentiate from RDS or meconium aspiration.
- **ECHO** confirms the diagnosis.

Treatment

- Surgical intervention should be performed as soon as possible, especially if obstructed.
- Supracardiac or infradiaphragmatic TAPVC*:
 - A large end-to-side anastomosis is created between LA and pulmonary venous confluence, the ASD is closed, and vertical vein is ligated.

- TAPVC to CS:
 - Common wall of CS and LA is removed to create a connection, and CS orifice is closed.

Post-op Complications

- Pulmonary hypertension leading to failure of repair (obstructed TAPVR especially at risk)
- Residual stenosis (e.g. anastomosis not big enough and causes obstruction to pulmonary venous drainage)
- Residual shunts

Long-term Complications

- Late pulmonary venous obstruction requiring reoperation
- SVC obstruction (if TAPVC to SVC)
- Late arrhythmias (usually atrial)

Questions

- What strategies might you use to support a patient with obstructed total anomalous venous return?
- What is a sutureless repair?
- What are the cath saturations and pressures in a neonate with TAPVC?

References

Brown DW, Geva T. Anomalies of the pulmonary veins In: Allen HD, Shaddy RE, Penny DJ, Feltes TF, Cetta F, 9th, editors. Moss and Adams' Heart Disease in Infants, Children, and Adolescents: Including the Fetus and Young Adult. Philadelphia: Lippincott Williams & Wilkins; 2016. p.881-910.

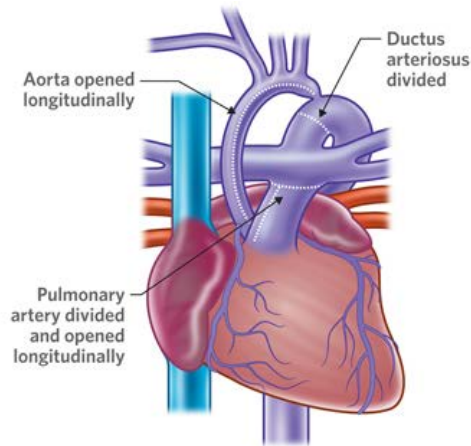
Surgical Appendix

Except where noted, images courtesy of The Royal Children's Hospital, Melbourne, Australia (www.rch.org.au)

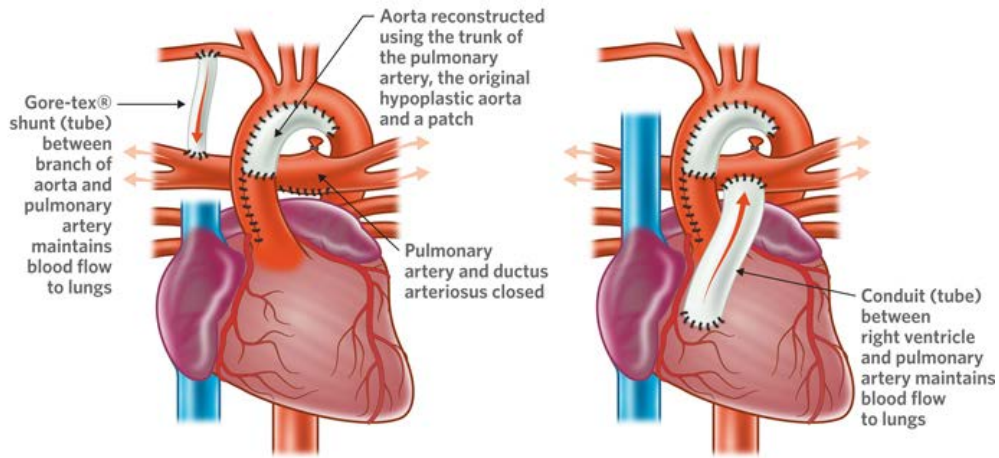
Single Ventricle Palliation

Stage 1: Norwood operation, 1981

Goals: establish unobstructed outflow from single ventricle to the body (Damus-Kaye-Stansel + arch reconstruction), remove any restriction to atrial mixing of venous blood (atrial septectomy), and re-establish pulmonary blood flow (BT shunt or Sano conduit).



Pre-operative anatomy



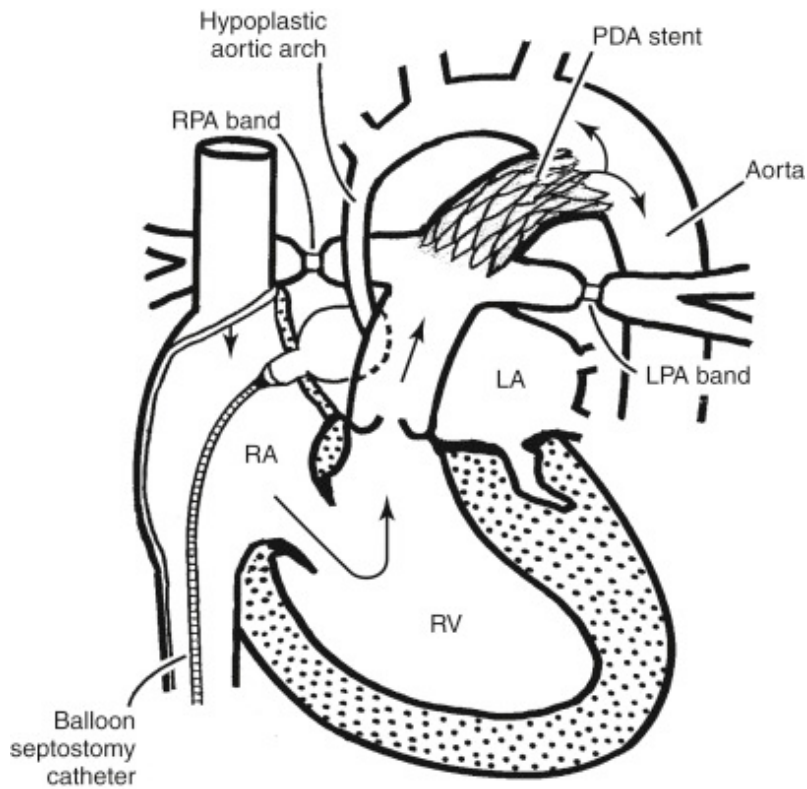
Norwood operation

Norwood operation (Sano)

© The Royal Children's Hospital, Melbourne, Australia

Stage 1: Hybrid procedure, 1993

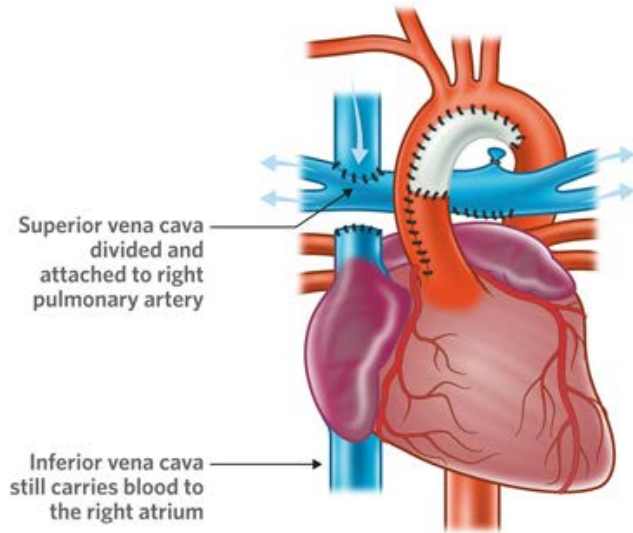
Alternative to the Norwood: establishes unobstructed outflow from single ventricle to the body (PDA stent to maintain ductal patency), remove any restriction to atrial mixing of venous blood (balloon atrial septostomy), and minimize pulmonary overcirculation (bilateral PA bands)



Park's Pediatric Cardiology

Stage 2: Bidirectional Glenn, 1958

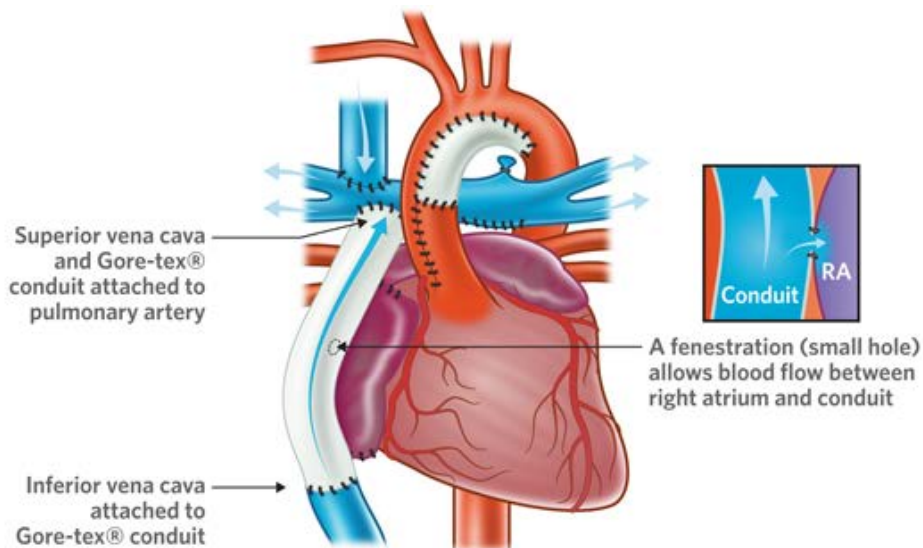
Anastomosis of SVC to the pulmonary arteries and removal of the BTS or Sano conduit



© The Royal Children's Hospital, Melbourne, Australia

Stage 3: Fontan, 1971

Connection of the IVC to the pulmonary arteries so that all systemic venous blood flows passively to the pulmonary circulation (apart from coronary sinus that continues to drain to the common atrium).



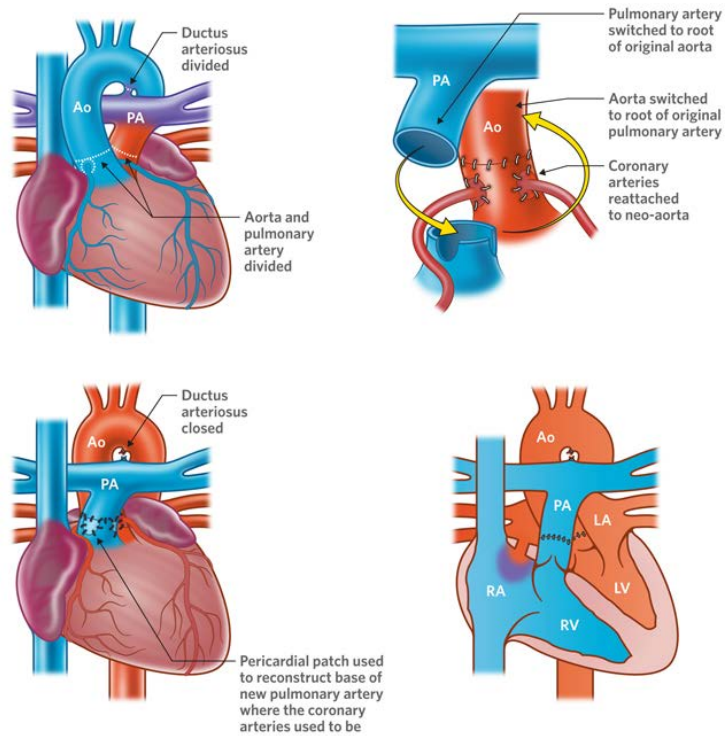
Fontan operation with extracardiac conduit

© The Royal Children's Hospital, Melbourne, Australia

Other Surgical Procedures

Arterial Switch Operation (ASO or Jatene procedure), 1976

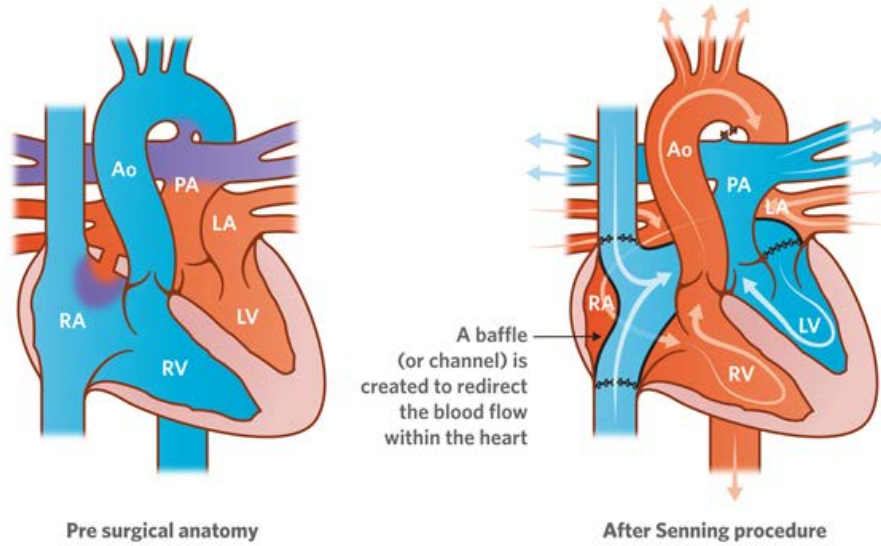
For transposed great arteries



© The Royal Children's Hospital, Melbourne, Australia

Atrial switch operation (Senning, 1959 or Mustard, 1964)

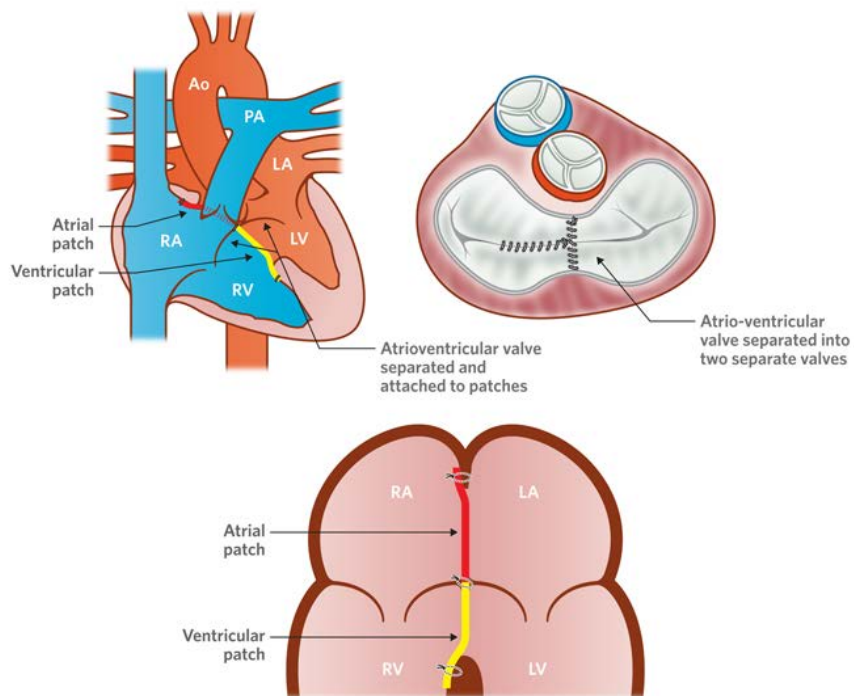
For transposed great arteries



© The Royal Children's Hospital, Melbourne, Australia

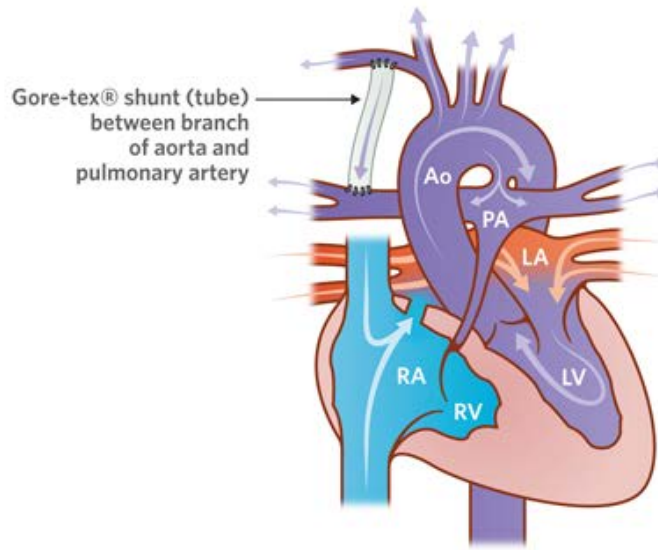
Atrioventricular Septal Defect Repair (2 patch technique), 1975

Separation of the single AV valve into a left (mitral) and right (tricuspid) valve and patch closure of the atrial level and ventricular level septal defects



© The Royal Children's Hospital, Melbourne, Australia

Blalock-Thomas-Taussig (BT) Shunt, 1945

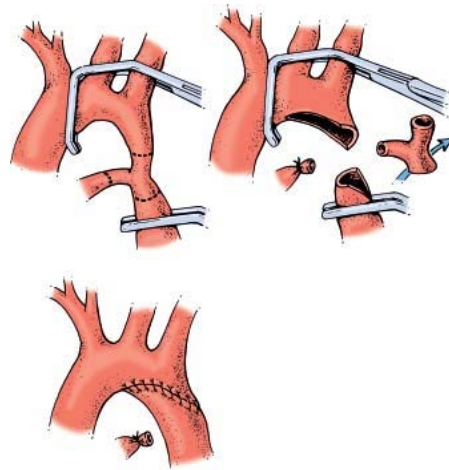


Gore-tex® shunt (tube)
between branch
of aorta and
pulmonary artery

Shunt operation

© The Royal Children's Hospital, Melbourne, Australia

Coarctation repair with extended end-to-end anastomosis, 1985

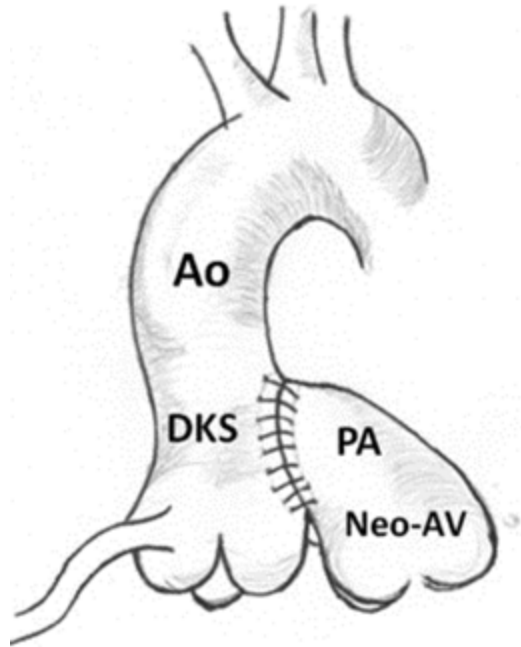


Adams

Moss and

Damus-Kaye Stansel Procedure (DKS), 1975

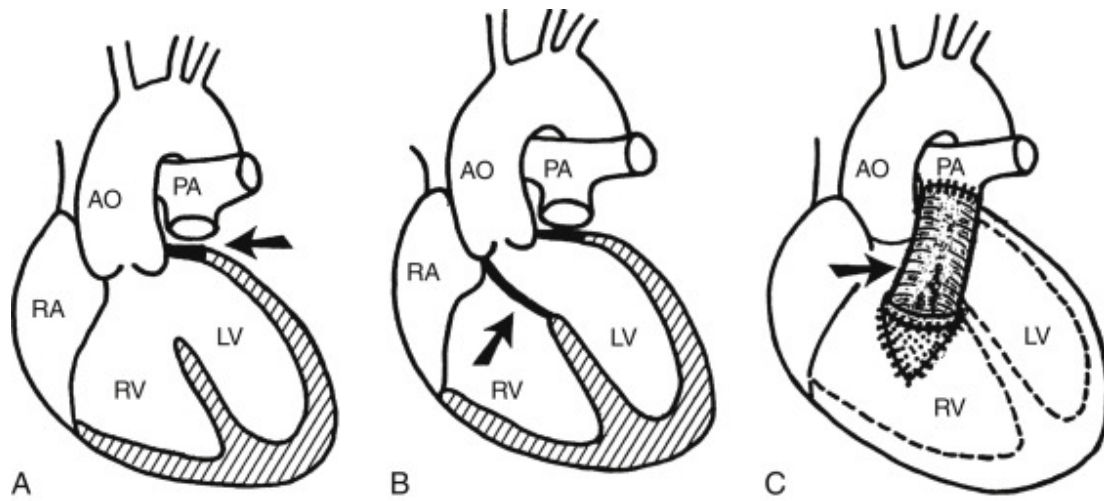
Anastomosis of ascending aorta and main pulmonary artery and placement of RV-PA conduit.



Bobylev D, Breymann T, Boethig D, et al. Semilunar valve Replacement with Decellularized Homograft after Damus-Kaye-Stansel Anastomosis and Fontan Procedure. Ann Thorac Surg 2014; 97(5): 1792-5.

Rastelli operation, 1969

Originally used for transposition of the great arteries, now used for numerous complex repairs, including truncus arteriosus. The VSD patch is angled to divert LV outflow across the aorta and an RV-PA conduit is placed.

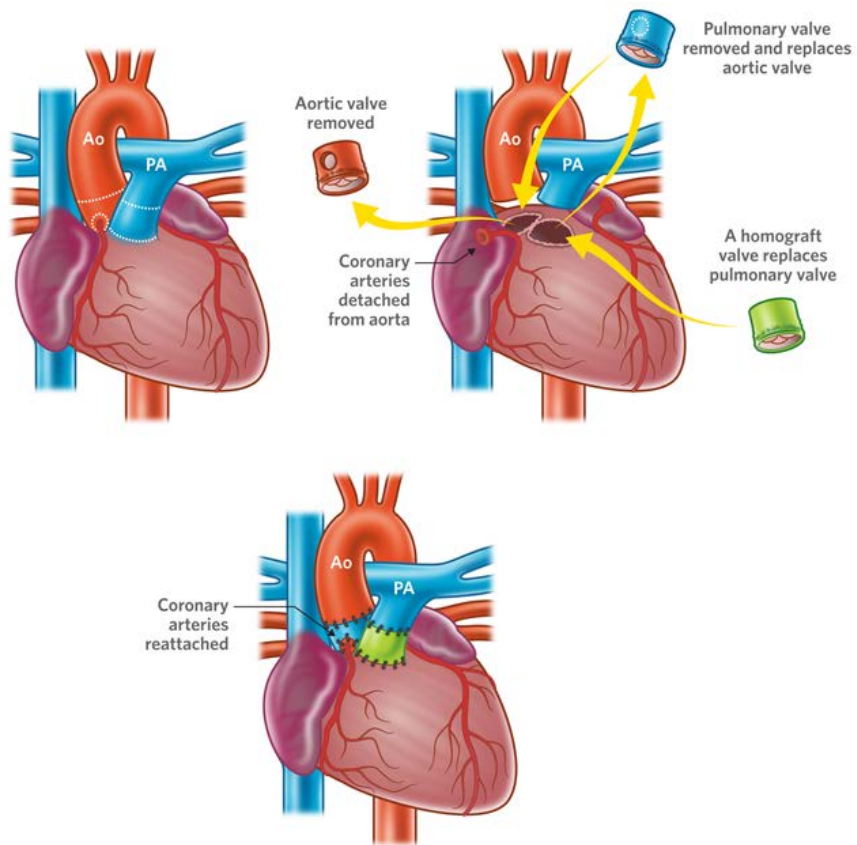


Park's Pediatric

Cardiology

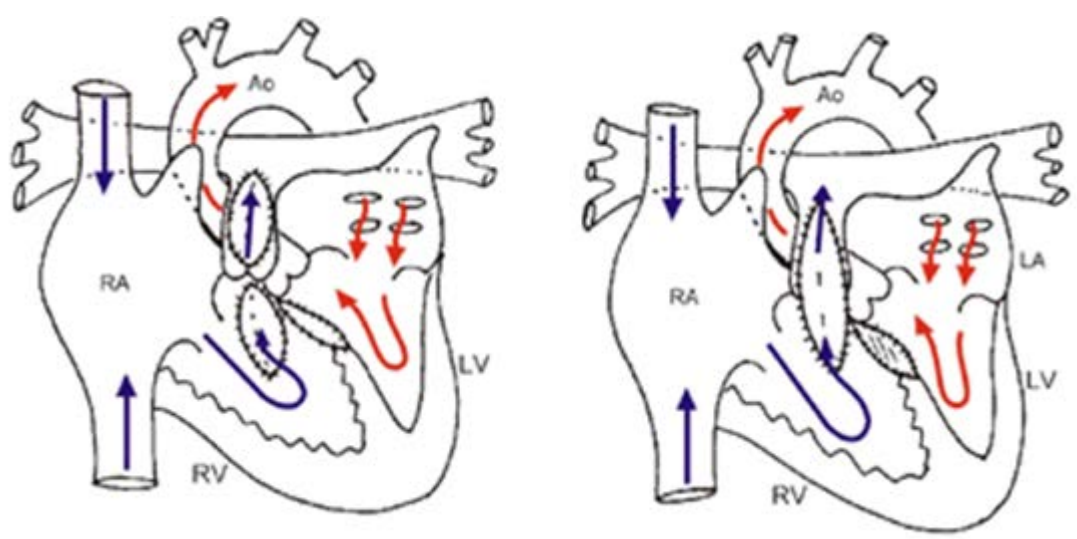
Ross operation for aortic stenosis, 1962

Transplantation of the pulmonary valve into the aortic position and placement of a prosthetic pulmonary valve



© The Royal Children's Hospital, Melbourne, Australia

Tetralogy of Fallot Repair

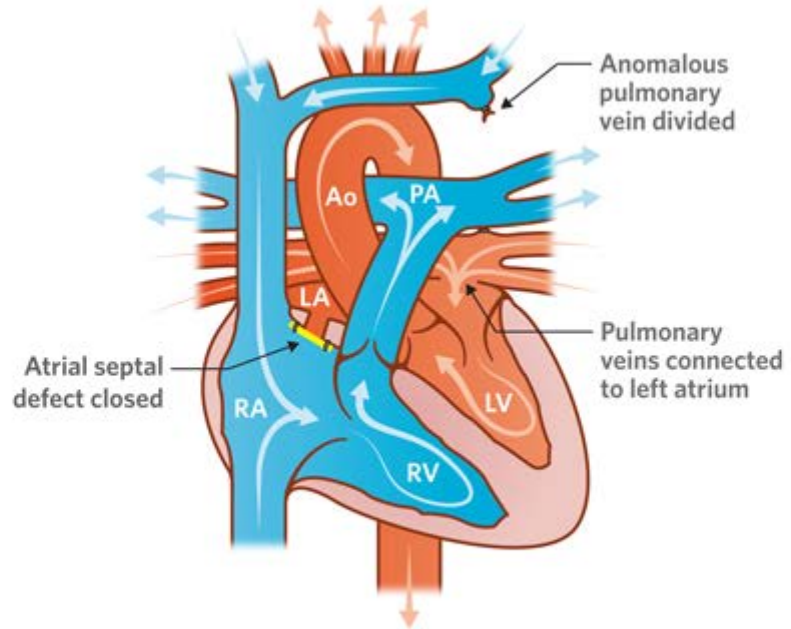


Valve-sparing repair, 1990s

Transannular patch, 1959

www.chw.org

Total Anomalous Pulmonary Venous Connection Repair, 1956



© The Royal Children's Hospital, Melbourne, Australia

Cardiomyopathies

Cardiomyopathies are defined as a “heterogenous group of diseases of the myocardium associated with mechanical and/or electrical dysfunction that usually (but not invariably) exhibit inappropriate ventricular hypertrophy or dilatation” and can have a genetic cause. Additionally, they can be an isolated condition, or part of a systemic disease.

- Etiologies
 - Primary Cardiomyopathies (primarily involving the heart)
 - Genetic
 - Hypertrophic Cardiomyopathy
 - Arrhythmogenic Right Ventricular Cardiomyopathy
 - Left Ventricular Non-Compaction Cardiomyopathy
 - Glycogen Storage (Danon, PRKAG2)
 - Conduction Defects
 - Mitochondrial Myopathies
 - Ion Channel Disorders (LQTS, Brugada, SQTS, CPVT, etc.)
 - Restrictive Cardiomyopathy
 - Mixed
 - Dilated Cardiomyopathy
 - Acquired
 - Inflammatory (Myocarditis)
 - Stress-Provoked (Tako-Tsubo)
 - Peripartum
 - Tachycardia-induced
 - Infants of Diabetic Mothers
 - Secondary Cardiomyopathies (systemic disease involving the heart)
 - See Table 1.

The two most common cardiomyopathies in pediatric patients are Hypertrophic Cardiomyopathy and Dilated cardiomyopathy, so those are discussed here. For further information on other types of cardiomyopathies, see the References section.

Hypertrophic Cardiomyopathy

Most frequently occurring cardiomyopathy (1:500 of general population) and has an autosomal dominant pattern of inheritance. Most common cause of sudden cardiac death in young people and competitive athletes.

Clinical Presentation

- Hypertrophied but non-dilated LV with no other structural cause of hypertrophy (e.g. not reactive to aortic stenosis or coarctation or systemic hypertension).
- LVH is generally asymmetric, with parts of the LV free wall being thicker than others, but occasionally there may be concentric thickening.
- Exam: Can have a systolic ejection murmur – depending on degree of LV outflow tract gradient, rapidly rising arterial pulses, active precordium. Murmur will likely get louder when standing. Often there is nothing abnormal about the exam.
- Symptoms: Exertional dyspnea, chest pain, syncope, near-syncope, sudden death

Natural History

- LVH is usually not present at birth and early childhood, but begins to develop and shows a rapid increase in thickness, especially during adolescence.
- Mitral valve systolic anterior motion (SAM) usually develops by teen years as well, and contributes to left ventricular outflow obstruction, also known as hypertrophic obstructive cardiomyopathy (HOCM). Patients can have structural abnormalities of the mitral valve.
- Myocardial ischemia and diastolic dysfunction develop over time. Subtle diastolic changes can be appreciated before objective hypertrophy with careful echocardiography.
- While heart failure may be secondary to progressive LVOT obstruction, sudden death is less associated with LVOT obstruction. Ventricular tachycardia and fibrillation can occur in patients without significant obstruction and cause sudden death.
- Significant heterogeneity in presentation makes it a very unpredictable disease.

Diagnostic Evaluation

- EKG: LVH may be first sign (again, many patients will have normal EKG, making it difficult to diagnose)
- ECHO: LVH, systolic anterior motion (SAM) of mitral valve, LV outflow tract obstruction
- Cardiomyopathy panel (screens for 91 gene mutations including DMD, BMD, Noonan, Alstrom, etc.)
- Family and genetic screening (especially if positive cardiomyopathy panel)

Treatment

- Heart failure symptoms:
 - Consider beta blockers for HR slowing and improved ventricular filling as well as decreased metabolic demand
 - Depends on systolic vs. diastolic heart failure
- Prevention of Sudden Death
 - ICD placement is only proven method of improving lifespan in patients with HCM
 - Primary prevention: Family history of sudden death, unexplained syncope, LVH wall thickness ≥ 3 cm
 - Secondary prevention: after an aborted sudden cardiac death event
- Surgical myomectomy: resection of muscle tissue to relieve LVOT obstruction

Dilated Cardiomyopathy

Most common cardiomyopathy in children, with 0.57/100,000 cases.

Clinical Presentation

- Dilated cardiomyopathy (DCM) is defined by left ventricular systolic dysfunction and dilation, leading to diminished cardiac output.
- Multiple etiologies lead to DCM, including other types of cardiomyopathies (e.g. Friedreich's ataxia related hypertrophic cardiomyopathy typically becomes dilated prior to death due to heart failure), myocarditis, storage diseases, muscular dystrophies, channelopathies, arrhythmia-induced, etc.
- If symptomatic, may present with symptoms of acute or chronic congestive heart failure (See Congestive Heart Failure.)
- Exam: depends on if in compensated vs. decompensated heart failure:
 - Chronic:
 - Gallop rhythm
 - Tachypnea, rales
 - Baseline tachycardia
 - Peripheral edema, hepatomegaly
 - Acute:
 - Poor perfusion, cool extremities
 - Hypotension
 - Arrhythmias (ventricular tachycardia, atrial arrhythmias)

Natural History

- Initially patients may be asymptomatic, but as function worsens, patients begin to develop signs of congestive heart failure.
- They often have signs of chronic heart failure, ranging from respiratory symptoms from pulmonary edema, abdominal symptoms of nausea, vomiting and feeding intolerance, chest pain, and exertional dyspnea.
- Depending on the etiology, they may present in acute heart failure (poor perfusion and hypotension), or progress to acute heart failure after being in compensated chronic heart failure.
- Long term outcomes depend on etiology as well, but overall morbidity and mortality is high. Transplant-free survival at 5 years is only 50%.

Diagnostic Evaluation and Work-up

- CXR: pulmonary edema, cardiomegaly
- EKG: LVH, ST segment abnormalities
- ECHO: confirms diagnosis, evaluates function, mitral regurgitation, right ventricular function, and diastolic function
- MRI can be helpful, especially in myocarditis (looking for delayed enhancement)
- Labs: B-type natriuretic peptide (BNP), and N-terminal pro-BNP, Chem 10, lactate, end-organ function labs (e.g. LFTs.)
- Cardiac catheterization to evaluate hemodynamics and diastolic dysfunction; consider endomyocardial biopsy
- Holter or Zio-patch to assess for arrhythmias
- Family screening

Treatment

- Chronic
 - ACE inhibition is very important – both for down-regulation of renin-angiotensin-aldosterone system, and improvement in LV geometry and EF.
 - Fluid and salt restriction
 - Beta blockers
 - Spironolactone for remodeling
 - Diuretics for improvement in congestion
 - ICD placement to resynchronize ventricular action and improve cardiac output
- Acute
 - Milrinone for afterload reduction and inotropy
 - Dopamine for blood pressure and cardiac output augmentation
 - Continuous diuretic infusions
- If unable to improve acute exacerbation, consider ventricular assist device (VAD) placement as a bridge to transplant, bridge to recovery, or as an endpoint (destination).
- Heart transplantation

Secondary Cardiomyopathies	
Infiltrative	Amyloidosis, Gaucher, Hurler's, Hunter's
Storage	Hemochromatosis, Fabry's disease, Glycogen Storage (Type II, Pompe), Niemann-Pick
Toxicity	Drugs, heavy metals, chemical agents
Endomyocardial	Endomyocardial fibrosis, Hypereosinophilic (Loeffler's)
Inflammatory	Sarcoidosis
Endocrine	Diabetes, Hyper/hypothyroidism, Hyperparathyroidism, Pheochromocytoma, Acromegaly
Cardiofacial	Noonan syndrome
Neuromuscular	Friederich's Ataxia, Duchenne, Becker, Emery-Dreyfuss, Myotonic, NF, Tuberous Sclerosis
Nutritional Deficiencies	Beriberi (thiamine), pellagra, scurvy (Vit C), selenium, carnitine, kwashiorkor
Autoimmune	SLE, Dermatomyositis, RA, scleroderma, PAN
Electrolyte Imbalance	
Cancer Therapy	Anthracyclines, cyclophosphamide, Radiation

Adapted from AHA Scientific Statement on "Contemporary definitions and classification of the cardiomyopathies"

References

- Maron BJ, Towbin JA, Thiene G, et al. Contemporary definitions and classification of the cardiomyopathies: an American Heart Association Scientific Statement from the Council on Clinical Cardiology, Heart Failure and Transplantation Committee; Quality of Care and Outcomes Research and Functional Genomics and Translational Biology Interdisciplinary Working Groups; and Council on Epidemiology and Prevention. *Circulation*. 2006;113:1807–1816.
- Maron BJ. Hypertrophic Cardiomyopathy. In: Allen HD, Driscoll DJ, Shaddy RE, Feltes TF, 9th, editors. Moss and Adams' Heart Disease in Infants, Children, and Adolescents: Including the Fetus and Young Adult. Philadelphia: Lippincott Williams & Wilkins; 2016. p.1263-1281.
- Lin KY, Rossano JW. Dilated Cardiomyopathy. In: Allen HD, Driscoll DJ, Shaddy RE, Feltes TF, 9th, editors. Moss and Adams' Heart Disease in Infants, Children, and Adolescents: Including the Fetus and Young Adult. Philadelphia: Lippincott Williams & Wilkins; 2016. p.1283-1295.
- McMahon CJ, Pignatelli RH. Left Ventricular Noncompaction Cardiomyopathy. In: Allen HD, Driscoll DJ, Shaddy RE, Feltes TF, 9th, editors. Moss and Adams' Heart Disease in Infants, Children, and Adolescents: Including the Fetus and Young Adult. Philadelphia: Lippincott Williams & Wilkins; 2016. p.1297-1311.
- Thrush PT, Mendell JR, Flanigan KM, Hoffman TM, Allen HD. The Heart in Muscular Dystrophies. In: Allen HD, Driscoll DJ, Shaddy RE, Feltes TF, 9th, editors. Moss and Adams' Heart Disease in Infants, Children, and Adolescents: Including the Fetus and Young Adult. Philadelphia: Lippincott Williams & Wilkins; 2016. p.1343-1353.
- Maron BJ, Udelson JE, Bonow RO, et al. Eligibility and disqualification recommendations for competitive athletes with cardiovascular abnormalities: Task Force 3: hypertrophic cardiomyopathy, arrhythmogenic right ventricular cardiomyopathy and other cardiomyopathies, and myocarditis. *J Am Coll Cardiol*, 66 (2015), pp. 2362–2371

Questions

- What are the exercise recommendations for a patient with HCM? DCM? Myocarditis?
- What causes a gallop rhythm?

Congestive Heart Failure

Cardiac output cannot keep up with metabolic demand → activation of sympathetic nervous system and renin angiotensin systems.

Etiologies

- Ventricular Pump Dysfunction (failure under even normal demands)
 - Chronic arrhythmias
 - Primary cardiomyopathies (dilated, hypertrophic or restrictive)
 - Myocarditis
 - Myocardial ischemia (ALCAPA, coronary events)
 - Non-cardiac causes: toxins (anthracyclines, radiation), muscular dystrophy, metabolic disease, renal failure, sepsis, severe anemia (sickle cell disease)
- Volume Overload Lesions (failure due to increased demands)
 - Congenital heart disease with significant left to right shunts: VSD, PDA, AP window, atrioventricular septal defect, single ventricle with unobstructed pulmonary blood flow
 - Valvular regurgitation causing a volume load on the heart: aortic insufficiency, mitral regurgitation, pulmonary insufficiency, tricuspid valve regurgitation
 - Non-cardiac causes: arteriovenous malformations, renal failure
- Pressure Overload Lesions
 - Primary or secondary pulmonary hypertension
 - Unrepaired left or right-sided obstructive lesions

Diagnostic Evaluation

- Chest X-ray: look for signs of pulmonary congestion, a sign of left heart failure
- EKG: look for atrial enlargement, ventricular hypertrophy, signs of ischemic changes, etc
- Vital signs including four extremity blood pressures and pre- and post-ductal sats
- Labs:
 - CBC, CMP
 - Troponin and CK: markers of myocardial injury in ischemia or myocarditis
 - Inflammatory markers may suggest myocarditis
 - NT-proBNP
 - released in response to increased wall stress or impaired ventricular function
 - increases with diastolic dysfunction, heart failure exacerbations, high-output states (sepsis, cirrhosis, hyperthyroidism), pulmonary disease
 - Levels vary with age, peak in neonates at 1-2 days of life

Initial Management

- Cardiology consult for echocardiogram and further imaging (cardiac cath, CTA, MRI)
- Neonates: prostaglandin for unexplained shock!
- **Acute Heart Failure**
 - Emergent stabilization including obtaining vascular access, administering oxygen, etc.
 - Diuretics
 - Inotropes: catecholaminergic agents, milrinone

- Consider positive pressure ventilation
- Consider mechanical support (ECMO)
- Surgical or catheter-based interventions
- AVOID a fluid bolus in the setting of pulmonary edema or hepatomegaly – it will make things worse!
- **Chronic Heart Failure**
 - Correct non-cardiac causes of cardiac dysfunction (acidosis, sepsis, anemia, hypertension)
 - Surgical or catheter-based interventions to correct anatomic defects
 - Pharmacologic therapy for symptomatic relief and ventricular remodeling: diuretics, angiotensin-converting enzyme inhibitors or angiotensin receptor blockers, beta blockers, aldosterone antagonists, digoxin, pulmonary vasodilators (see Purple Team Logistics Guidebook for mechanism of action and typical dosages).
 - Optimize nutrition and physical rehabilitation
 - Restrict sodium, total fluids and free water
 - Anticoagulation to minimize risk of intracardiac thrombi
 - Cardiac resynchronization therapy
 - Implantable cardioverter defibrillators in patients with risk of malignant ventricular arrhythmias
 - Consider mechanical support, ECMO or ventricular assist devices

Questions

- Define cardiogenic shock.
- Describe the history and physical exam findings of infants with heart failure.
- Describe the history and physical exam findings of children and adolescents with heart failure.
- Suggest some congenital heart diseases that can present with CHF in the neonate.
- How do ACE inhibitors treat heart failure?
- Why are beta blockers used in heart failure?
- Why are aldosterone antagonists used in heart failure?
- How does digoxin work?

References

- Shaddy RE, Tani LY. Chronic Heart Failure in Children. In: Allen HD, Driscoll DJ, Shaddy RE, Feltes TF, 8th, editors. *Moss and Adams' Heart Disease in Infants, Children, and Adolescents: Including the Fetus and Young Adult*. Philadelphia: Lippincott Williams & Wilkins; 2013. p.1565-1578.
- Rosenthal D, Chrisant MRK, Edens E, et al. International Society for heart and Lung Transplantation: Practice Guidelines for Management of heart Failure in Children. *J Heart Lung Transplant* 2004; 23(12):1313-1333.
- Singh RK, Singh TP. "Etiology and diagnosis of heart failure in infants and children." *Uptodate.com*
- Singh RK, Singh TP. "Management of heart failure in infants and children." *Uptodate.com*

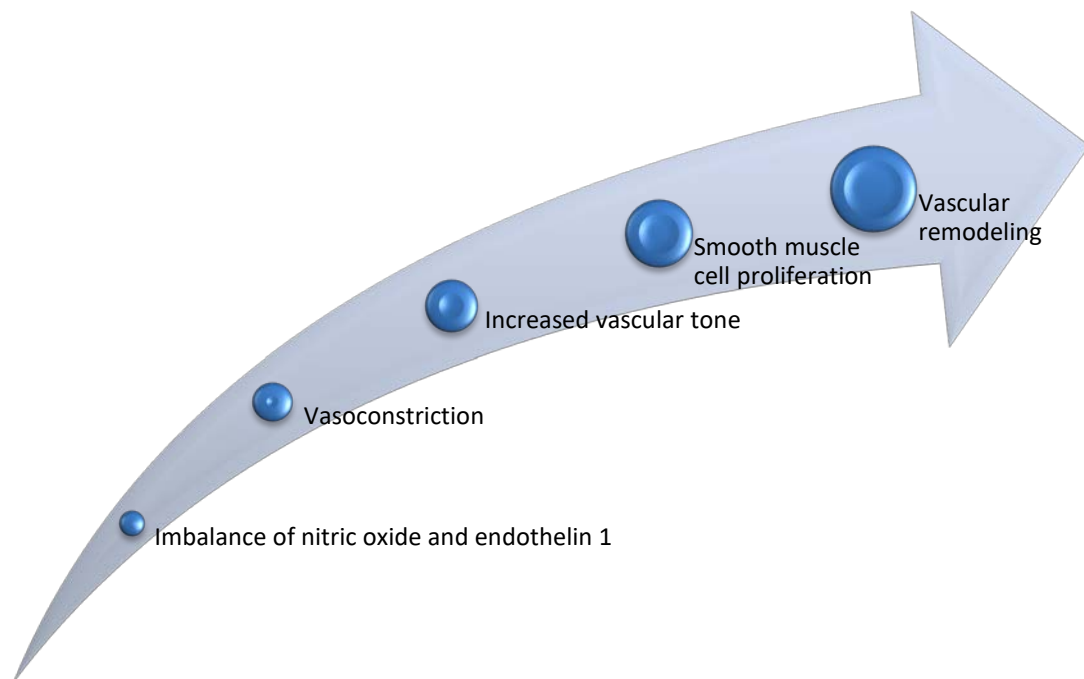
Pulmonary Hypertension

Definition

- **Pulmonary Hypertension (PH):** mean pulmonary artery (PA) pressure ≥ 25 mm Hg at rest, ≥ 30 mm Hg with exercise
- **Pulmonary Vascular Disease:** abnormal vascular changes with elevated pulmonary vascular resistance (PVR)
- **Pulmonary Arterial Hypertension:** related to pre-capillary disease, mean PA pressure > 25 mm Hg with a normal left atrial pressure of < 15 mm Hg
- Affects 30% unoperated CHD patients, 15% repaired CHD patients
 - “Dynamic” PH is related to shunt flow and reverses after closing the shunt
 - Some defects require maintenance of a low PVR (single ventricle patients)
 - Immediate postoperative or “reactive” pulmonary arterial hypertension
 - Late, postoperative pulmonary arterial hypertension can develop after palliation
 - Eisenmenger’s physiology can develop with longstanding pulmonary vascular disease and implies reversal of shunt flow (to right to left)

Pathophysiology

- A stimulus (decreased blood flow, hypoxia, or shear stress) induces increased production of endothelin 1 and decreased production of nitric oxide



Clinical Presentation

- Depends on pulmonary arterial pressure and right ventricular function
- Dyspnea on exertion
- Hemoptysis
- Chest pain
- Dizziness
- Syncope
- Atrial arrhythmias
- In patients with Eisenmenger's: clubbing, cyanosis
- Symptoms of right heart failure: edema, ascites, hepatosplenomegaly
- Infants: poor appetite, failure to thrive, lethargy, diaphoresis, tachycardia, tachypnea, irritability
- Cardiac exam findings
 - RV lift from elevated RV pressures
 - Loud S2
 - High pitched diastolic murmur consistent with pulmonary insufficiency
 - Holosystolic murmur of tricuspid regurgitation
 - Possible gallop rhythm

Clinical Classification of PH (WHO World Symposium 2013, Nice):

1. Pulmonary arterial hypertension (PAH)

- 1.1 Idiopathic PAH
- 1.2 Heritable
 - 1.2.1 BMPR2
 - 1.2.2 ALK1, endoglin, SMAD9, CAV1, KCNK3
 - 1.2.3 Unknown
- 1.3 Drug and toxin induced
- 1.4 Associated with
 - 1.4.1 Connective tissue diseases
 - 1.4.2 HIV infection
 - 1.4.3 Portal hypertension
 - 1.4.4 Congenital heart disease
 - 1.4.5 Schistosomiasis

1'. Pulmonary veno-occlusive disease (PVOD) and/or pulmonary capillary hemangiomatosis (PCH)

1". Persistent pulmonary hypertension of the newborn (PPHN)

2. PH due to left heart disease

- 2.1 Left ventricular systolic dysfunction
- 2.2 Left ventricular diastolic dysfunction
- 2.3 Valvular disease
- 2.4 Congenital/acquired left heart inflow/outflow tract obstruction and congenital cardiomyopathies

3. PH due to lung diseases and/or hypoxia

- 3.1 COPD
- 3.2 Interstitial lung disease
- 3.3 Other pulmonary diseases with mixed restrictive and obstructive pattern
- 3.4 Sleep-disordered breathing
- 3.5 Alveolar hypoventilation disorders
- 3.6 Chronic exposure to high altitude
- 3.7 Developmental abnormalities

4. Chronic thromboembolic PH (CTEPH)

5. PH with unclear or multifactorial mechanisms

- 5.1 Hematologic disorders: chronic hemolytic anemia, myeloproliferative disorders, splenectomy
- 5.2 Systemic disorders: sarcoidosis, pulmonary Langerhans cell histiocytosis, lymphangioleiomyomatosis, neurofibromatosis, vasculitis
- 5.3 Metabolic disorders: glycogen storage disease, Gaucher disease, thyroid disorders
- 5.4 Others: tumoral obstruction, fibrosing mediastinitis, chronic renal failure, segmental PH

Natural History: Predictors of mortality (in patients with idiopathic disease):

- NYHA functional class III or IV
- Low 6-minute walk distances
- Elevated right atrial (RA) pressures
- Higher PA pressures
- Decreased cardiac output
- Lack of response to pulmonary vasodilator testing

Diagnostic Work-up

- ECG: RA enlargement and RVH
- Chest X-ray: RA and RV enlargement, dilated PAs, lung fields
- Lab tests to rule out secondary causes of PH: clotting abnormalities, LFTs, rheumatologic studies, immunologic studies, TFTs
- PFTs: assess reactivity to bronchodilators and diffusion capacity
- V/Q scan: rule out thromboembolic disease
- MRI or CTA: assess lung parenchyma and vasculature
- Consider lung biopsy
- Echocardiogram
- Exercise testing
- Right heart cath with vasodilator testing (gold standard)

Therapeutic Options

- Calcium channel blockers
 - Indicated only for patients who show “reactivity” in the cath lab (decreased PVR with pulmonary vasodilators like oxygen and iNO)
 - Contraindicated in patients who are unreactive or who have right heart failure due to a risk of negative inotropic effects
- Endothelin receptor antagonists (ambrisentan, bosentan)
 - Progressive decline in benefit after 1 year of therapy
 - Side effects: elevated transaminases, severe headaches, near-syncope
- Phosphodiesterase type 5 inhibitors (sildenafil, tadalafil)
 - Side effects: URIs, fevers, vomiting, priapism, headaches, visual changes, concern for increased mortality with high doses
- Prostacyclin analogues (iloprost, treprostinil, epoprostenol)
 - IV therapy side effects: nausea, diarrhea, jaw pain, bone pain, headaches, catheter-related side effects
 - SQ therapy side effects: discomfort at infusion site
- Adjunctive agents: diuretics, oxygen, anticoagulation, digoxin
- Consider atrial septostomy, Potts shunt, or evaluation for lung or heart/lung transplantation

Prognosis

- Survival has improved with advent of PH therapies:
- REVEAL registry reports 96 ±4% survival at 1 year, 84 ±5% at 3 years, 74 ±6% at 5 years with no difference between idiopathic PAH and congenital heart disease leading to PAH

Outpatient Care

- Synagis if eligible
- Influenza and pneumococcal vaccines
- Close monitoring of growth
- Early recognition and treatment of infectious respiratory illnesses
- SBE prophylaxis in patients with cyanosis or with indwelling central lines
- Exercise testing prior to participation in any athletic activities

- Patients with severe PH or a recent history of syncope should not participate in competitive sports
- During exercise, PH patients should engage in light to moderate aerobic activity, avoid strenuous and isometric exercises, remain well hydrated and be allowed to self-limit their activity
- Pregnancy is not well tolerated in women with significant PH

Questions

- How do you distinguish between PPHN from meconium aspiration and cyanotic congenital heart disease in a neonate? Think about exam findings and saturations.
- What conditions are associated with cor pulmonale and PH?
- When should an atrial septectomy be considered in a patient with PH? How might it help?
- Name several complications associated with Eisenmenger syndrome.
- What are the expected cath numbers in a patient with a structurally normal heart and pulmonary vascular disease?

References

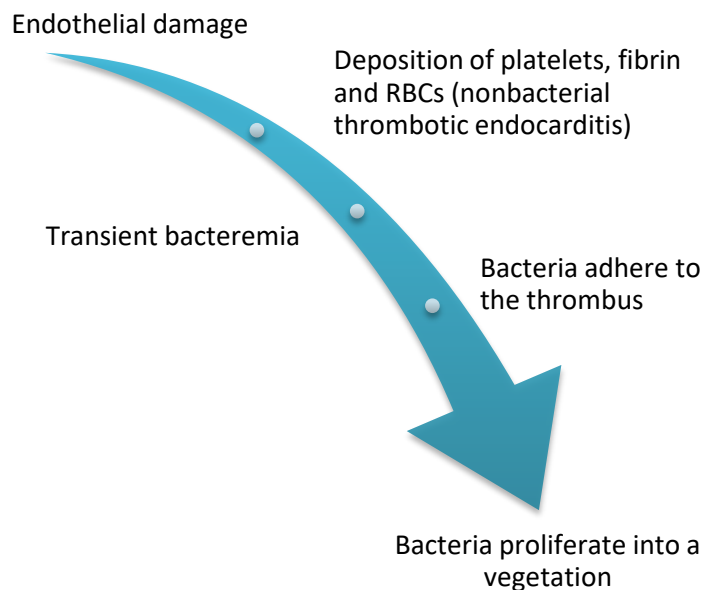
- Feinstein JA. Evaluation, Risk Stratification and Management of Pulmonary Hypertension in Patients with Congenital Heart Disease. *Semin Thorac Cardiovasc Surg Pediatr Card Surg Ann* 2009; 12:106-111.
- Hopper RK, Abman SH, Ivy DD. Persistent Challenges in Pediatric Pulmonary Hypertension. *Chest* 2016; 150(1):226-236.
- Ivy DD. Clinical Management of Pediatric Pulmonary Arterial Hypertension. In: Allen HD, Driscoll DJ, Shaddy RE, Feltes TF, 8th, editors. *Moss and Adams' Heart Disease in Infants, Children, and Adolescents: Including the Fetus and Young Adult*. Philadelphia: Lippincott Williams & Wilkins; 2013. p.1433-1462.
- Rosenzweig EB, Feinstein JA, Humpl T, Ivy DD. Pulmonary arterial hypertension in children: diagnostic work-up and challenges. *Prog Pediatr Cardiol* 2009; 27(1):4-11.

Infective Endocarditis

Far more common in children with congenital heart disease, especially those who have undergone surgical palliation. Most frequently associated with VSDs, TOF and aortic stenosis.

Endocarditis: infection of the endocardial surface of the heart, including native or prosthetic heart valves, septal defects, the mural endocardium, foreign devices or patches, surgical shunts and indwelling central venous catheters.

Endarteritis: similar illness involving arteries, including a PDA, great vessels, aneurysms or arteriovenous shunts



COMMON PATHOGENS	
Most Common	α -hemolytic (Viridans group) Streptococci
2nd Most Common	<i>Staphylococcus aureus</i>
Uncommon	β -hemolytic Streptococci, Coagulase negative Staphylococci Candida Other Strep species
Rare	Enterococci Pneumococci Gram-negative enteric bacteria <i>Pseudomonas</i> species <i>Neisseria</i> species HACEK organisms: <i>Haemophilus</i> , <i>Actinobacillus</i> , <i>Cardiobacterium</i> , <i>Eikenella</i> , <i>Kingella</i> Other fungi

Relative Risk of Endocarditis for Various Cardiovascular & Underlying Conditions	
High Risk Prosthetic valves Previous episode of endocarditis Complex cyanotic congenital heart disease Surgically constructed shunts Injection drug use Indwelling central venous catheters	Moderate Risk Uncorrected PDA Uncorrected VSD Uncorrected ASD (other than secundum) Bicuspid aortic valve Mitral valve prolapse with regurgitation Rheumatic mitral or aortic valve disease Other acquired valvar diseases Hypertrophic cardiomyopathy

Moss and Adams

MODIFIED DUKE CRITERIA FOR DIAGNOSIS OF INFECTIVE ENDOCARDITIS
MAJOR CRITERIA
Positive blood cultures: Typical microorganisms consistent with IE from 2 separate blood cultures <i>Staphylococcus aureus</i> Viridans streptococci <i>Streptococcus gallolyticus</i> (formerly <i>Streptococcus bovis</i>), including nutritional variant strains (<i>Granulicatella</i> species and <i>Abiotrophia defectiva</i>) HACEK organisms Community-acquired enterococci without a primary focus OR Persistently positive blood culture For typical causes of IE: at least 2 positive blood cultures from samples drawn >12 hours apart For organisms that are more commonly skin contaminants: 3 or a majority of ≥ 4 separate blood cultures (1 st and last drawn at least 1 hour apart) OR Single positive blood culture for <i>Coxiella burnetii</i> or phase I IgG antibody titer > 1:800
Evidence of endocardial involvement: Positive echo Vegetation (oscillating intracardiac mass on a valve or on supporting structures, in the path of regurgitant jets, or on implanted material, in the absence of an alternative explanation) OR Abscess OR New partial dehiscence of a prosthetic valve New valvular regurgitation on echo Increase in or change in preexisting murmur is NOT sufficient
MINOR CRITERIA
Predisposing factor: IV drug use, presence of a predisposing cardiac condition (prosthetic valve or a valve lesion associated with significant regurgitation or turbulent flow)

(Continued)

Fever $\geq 38.0^{\circ}\text{C}$
 Vascular phenomena: major arterial embolic, septic pulmonary emboli, mycotic aneurysm, intracranial hemorrhage, conjunctival hemorrhages, Janeway lesions
 Immunologic phenomena: glomerulonephritis, Osler nodes, Roth spots, positive Rheumatoid factor
 Microbiologic evidence: positive blood cultures that do not meet major criteria
OR
 Active infection with an organism consistent with infective endocarditis

www.uptodateonline.com

MODIFIED DUKE CRITERIA FOR DIAGNOSIS OF INFECTIVE ENDOCARDITIS

DEFINITE

Pathologic Criteria

Pathologic Lesions: vegetation or intracardiac abscess demonstrating active endocarditis on histology

OR

Microorganism on culture or histology of a vegetation or intracardiac abscess

Clinical Criteria

2 major clinical criteria

OR

1 major and 3 minor clinical criteria

OR

5 minor clinical criteria

POSSIBLE

Presence of 1 major and 1 minor clinical criteria

OR

Presence of 3 minor clinical criteria

REJECTED

A firm alternate diagnosis is made

OR

Resolution of clinical manifestations occurs after ≤ 4 days of antibiotic therapy

OR

No pathologic evidence of infective endocarditis found at surgery or autopsy after ≤ 4 days of antibiotic therapy

OR

Clinical criteria for possible or definite infective endocarditis not met

www.uptodateonline.com

Of note, neonates may present atypically. They often do not have fever and may present with only generalized sepsis or focal neurologic findings from emboli to the brain.

Diagnostic Evaluation

- Send multiple blood cultures!
- Echo has a sensitivity of $>80\%$ in patients with suspected infectious endocarditis, **but cannot rule out the diagnosis**. Positive findings can include:
 - Vegetation

- Valve dysfunction (perforation, rupture, regurgitation)
- New heart block!

Treatment

Prolonged course of IV therapy with a bactericidal antibiotic – specifics depend on the site and organism involved.

Recommendations for Prophylaxis were updated by the AHA in 2007

- For dental procedures and perforation of the oral mucosa
- NO LONGER recommended for patients undergoing GI or GU procedures
- In general only recommends prophylaxis for HIGH risk group (not MODERATE risk)

Prosthetic Cardiac Valve or prosthetic material used for repair of a valve

Previous Infective Endocarditis

Congenital Heart Disease

- Unrepaired cyanotic CHD, including palliative shunts and conduits
- Completely repaired CHD with prosthetic material or device (placed surgically or by cath) for the first 6 months after the procedure.
- Repaired CHD with residual defects at the site or adjacent to the site of a prosthetic patch or prosthetic device (that could inhibit endothelialization)

Cardiac transplant recipients with cardiac valvulopathy

Questions

- Describe Osler nodes, Janeway lesions and Roth spots.
- What is appropriate antibiotic prophylaxis for a 3 month old with an unrepaired PDA undergoing a circumcision?
- What is appropriate antibiotic prophylaxis for a 2 year old undergoing a dental procedure 2 months after PDA closure in the cath lab?
- What is appropriate antibiotic prophylaxis for a penicillin-allergic 4 year old undergoing a dental procedure 3 months after ASD closure?

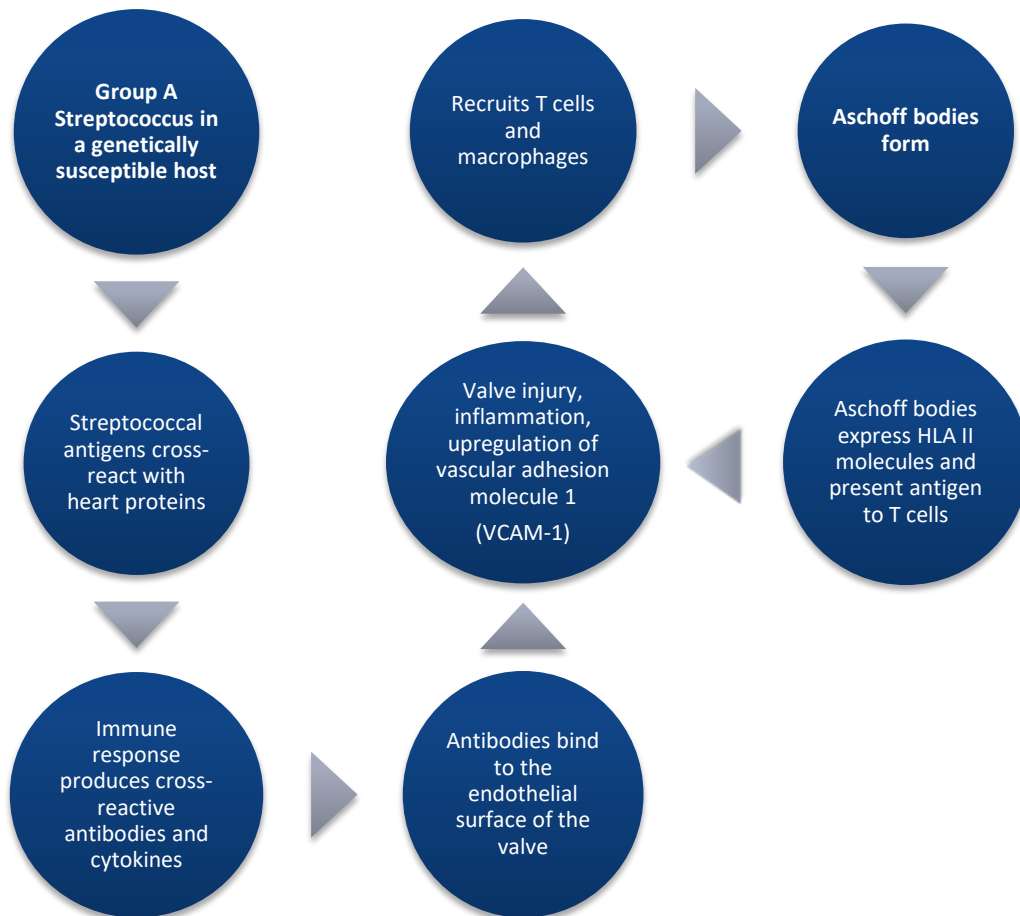
References

- Gewitz M, Taubert KA. Infective Endocarditis and Prevention. In: Allen HD, Shaddy RE, Penny DJ, Feltes TF, Cetta F, 9th, editors. *Moss and Adams' Heart Disease in Infants, Children, and Adolescents: Including the Fetus and Young Adult*. Philadelphia: Lippincott Williams & Wilkins; 2016. p.1441-1453.
- Sexton DJ, Fowler Jr. VG. Clinical manifestations and evaluation of adults with suspected native valve endocarditis. *Uptodateonline.com*
- Wilson W, Taubert KA, Gewitz M, et al. Prevention of Infective Endocarditis: Guidelines from the American Heart Association. *Circulation* 2007; 116:1736-1754.

Acute Rheumatic Fever

Incidence 200-300/100,000 in developing countries (and is the leading cause of cardiovascular death during the first five decades of life in many of these countries, above congenital heart problems), only 0.5-3/100,000 in developed countries


- An interaction between the Group A Streptococcus organism, the environment and the individual host leads to the development of acute rheumatic fever in some patients
- Most commonly occurs at 5-15 years, almost never occurs before age 2 or after age 35
 - Recurrences occur most frequently in the teenage years
- Typically 10 days to 5 weeks between Group A Strep infection and most symptoms of ARF



Diagnosis of Acute Rheumatic Fever:

2 major or 1 major + 2 minor Jones criteria + evidence of preceding Strep infection

If the diagnosis is suspected, EKG & echocardiogram should be ordered

<p>J</p>  <p>N</p> <p>E</p> <p>S</p>	<p>Joint manifestations: usually migratory large joint polyarthritis</p> <ul style="list-style-type: none"> • Rapidly responsive to NSAIDs or steroid therapy • More common and more severe in teenagers than in young children • Resolves without long-term sequelae in 4 weeks <p>Carditis: 30-70% of all ARF, 15-50% of these patients develop heart failure</p> <ul style="list-style-type: none"> • Presents within 3 weeks of Strep infection • Classically described as “pancarditis” • Valvulitis: 1-2mm verrucous vegetations form on the valve. <ul style="list-style-type: none"> ○ Over time, fibrotic changes of the valve and subvalvar apparatus lead to thickening of valve leaflets and fusion of chordae ○ Mitral regurgitation occurs in 95% with acute rheumatic carditis ○ Aortic regurgitation occurs in 20-25% with acute rheumatic carditis <ul style="list-style-type: none"> ▪ Usually in combination with MR, only 5% occur in isolation • Pericarditis almost always occurs with significant valvular disease • Myocarditis, usually without a troponin leak • Vasculitis of the coronaries and aorta • Aschoff nodule: pathognomonic for rheumatic heart disease <ul style="list-style-type: none"> ○ Central clearing of collagen with multinucleated “owl eye” cells <p>Nodules: 0.5-2.0cm round, firm, painless subcutaneous nodules on extensor surfaces of the joints or bony prominences – usually occur with carditis</p> <p>Erythema marginatum – usually occurs with carditis</p> <ul style="list-style-type: none"> • Transient, pink, nonpruritic rash, typically spares the face • May have central clearing • Sometimes elicited by a hot bath <p>Sydenham chorea due to inflammation in the basal ganglia, cerebral cortex, and cerebellum, typically starts 1-6 months after GAS infection</p> <ul style="list-style-type: none"> • Involuntary movements • Emotional lability and irritability • Obsessive compulsive symptoms
<p>Minor Criteria</p>	<p>Fever Arthralgia Elevated ESR or CRP Prolonged PR interval on EKG – can also have 2nd or 3rd degree heart block</p>
<p>Preceding Strep Infection</p>	<p>Positive throat culture or rapid Streptococcal test Elevated or rising Streptococcal antibody titer</p>

Treatment

- Treatment of Group A Streptococcus (typically oral penicillin for 10 days)
- Anti-inflammatory treatment with aspirin or NSAIDs
 - There is some evidence for the use of steroids in severe heart failure from ARF
- Heart failure treatment for severe symptoms
- Surgical intervention may be required if there is severe regurgitation due to valve leaflet or chordae tendineae rupture

Chronic Rheumatic Heart Disease

Prevalence <0.5/1000 in developed countries, 15% of all heart failure in developing countries, accounts for 275,000 annual deaths worldwide.

Natural History of Cardiac Involvement

- Spectrum from complete resolution to heart failure from severe valvular disease
- Depends on the severity of the initial cardiac involvement and number of ARF recurrences
- Predictors of chronic cardiac disease:
 - Severe carditis with first episode of ARF
 - Recurrent episodes of ARF
 - Aortic regurgitation
 - Female gender
 - Age younger than 5 years at presentation
- **Prevalence of RHD-related valvar disease follows this pattern: Mitral Valve > Aortic Valve > Tricuspid Valve > Pulmonary Valve. Valvar regurgitation precedes stenosis.**
- Chronic mitral regurgitation
 - Moderate/severe mitral regurgitation will ultimately lead to left atrial and left ventricular enlargement, left ventricular failure, left atrial hypertension, and pulmonary hypertension
- Chronic rheumatic aortic regurgitation will also ultimately lead to left ventricular dysfunction
- Mitral stenosis usually occurs 15-40 years after the onset of acute rheumatic fever
 - More common in women
 - Usually occurs with mitral regurgitation, but may occur in isolation
 - Risk of co-morbidities including atrial fibrillation, thromboembolic events
- Aortic stenosis occurs 20-40 years after the onset of acute rheumatic fever

Treatment

- Medical management of heart failure
- Surgical intervention is recommended once a patient becomes symptomatic from valvar disease or if left ventricular dysfunction develops
- Consideration of balloon mitral valvotomy in young adults with mitral stenosis
- “Secondary prophylaxis” with daily penicillin after the acute illness to prevent ARF recurrences

- RF with carditis and residual heart disease: 10 years after last attack or until age 40 (or lifelong if needed valvular surgery)
- RF with carditis, but no residual heart disease: 10 years or until age 21
- RF without carditis: 5 years or until age 21

Questions

- How will a patient with acute mitral regurgitation from acute carditis present?
- How will a patient with chronic mitral regurgitation present?
- Describe some of the differences between post-Streptococcal reactive arthritis and Acute Rheumatic Fever.

References

- Gewitz MH, Baltimore RS, Tani LY, et al. Revision of the Jones Criteria for the diagnosis of acute rheumatic fever in the era of Doppler echocardiography: a scientific statement from the American Heart Association. *Circulation* 2015 May; 131(20): 1806-18.
- Mayosi B. Natural history, screening, and management of rheumatic heart disease. *Uptodateonline.com*.
- Steer A, Gibofsky A. Acute rheumatic fever: Clinical manifestations and diagnosis. *Uptodateonline.com*.
- Tani LY. Rheumatic Fever and Rheumatic Heart Disease. In: Allen HD, Shaddy RE, Penny DJ, Feltes TF, Cetta F, 9th, editors. *Moss and Adams' Heart Disease in Infants, Children, and Adolescents: Including the Fetus and Young Adult*. Philadelphia: Lippincott Williams & Wilkins; 2016. p.1373-1404.

Myocarditis

It is difficult to estimate the incidence of pediatric myocarditis because there is no sensitive and specific diagnostic test for myocarditis. Likely ~1 case annually/100,000 children.

- Bimodal distribution with peaks in infancy and adolescence
- More common in young adult males

ETIOLOGIES OF MYOCARDITIS	
Viral (most common)	
Enteroviruses (Coxsackieviruses A and B)	CMV
Adenovirus	EBV
HHV6	Hepatitis C
Parvovirus B19	HIV
Influenza A and B	RSV
Bacterial	
<i>Mycoplasma pneumonia</i>	<i>Streptococcus</i>
<i>Chlamydia pneumonia</i>	Lyme disease (<i>Borrelia burgdorferi</i>)
<i>Listeria monocytogenes</i>	TB
<i>Staphylococcus</i>	<i>Corynebacterium diphtheria</i>
Fungal	
Eosinophilic myocarditis	
Toxins	Kawasaki Disease
Hypersensitivity reactions	Parasites: Chagas disease (<i>Trypanosoma cruzi</i>)
Autoimmune disease (SLE, IBD, sarcoid, etc)	
Giant cell myocarditis	

Clinical Findings

- **Spectrum of disease**
 - Dilated cardiomyopathy with LV dysfunction
 - Dilation may not be seen in cases of acute myocarditis
 - Fulminant myocarditis with sudden presentation of heart failure with severe ventricular dysfunction, shock, and arrhythmias – often progresses rapidly, requiring resuscitation, mechanical ventilation, and even ECMO
 - Acute coronary syndrome is sometimes seen in young adult males
 - Sudden death

Diagnosis

- Lab Tests
 - Inflammatory markers may be elevated
 - Elevated troponin T and I are often seen, but not required for the diagnosis
 - Serum, respiratory or stool testing for an infectious agent
- ECG: sinus tachycardia, tachyarrhythmias, low voltages, ST- and T-wave changes, conduction delays or AV block (1st to 3rd degree)
- CXR (abnormal in about 50% of cases): cardiomegaly, pulmonary edema, pleural effusions
- Echo: assess LV function and dilation, assess for other diagnoses
- Cardiac MRI: delayed enhancement of contrast is evidence of myocardial injury and fibrosis
- **Endomyocardial biopsy** (gold standard): inflammatory cell infiltrate, cardiac myocyte injury
 - Can also test for an infectious agent

- Suboptimal sensitivity since only patches of the myocardium may be affected (myocarditis is confirmed by biopsy in less than 20 to 50 % of pediatric patients with clinically suspected disease).
- Risk of cardiac perforation.

Treatment

- 2g/kg IVIG associated with improved survival
- Steroids and immunosuppressants are used for giant cell and eosinophilic myocarditis
- Exercise restriction for at least 6 months after diagnosis
- Supportive care for heart failure symptoms including arrhythmias
- Mechanical cardiac support (ECMO or VAD) if needed
- Many children will have normalization of function over time (53% at 3 years), but a proportion of patients go on to require chronic heart failure management or heart transplantation (4-18%)

Questions

- How might cardiologists distinguish between acute viral myocarditis and primary dilated cardiomyopathy exacerbated by a viral illness?
- What is in the differential diagnosis for a baby with myocarditis?
- How would a baby with fulminant myocarditis present?

References

Allan CK, Fulton DR. Treatment and prognosis of myocarditis in children. *Uptodateonline.com*
Simpson KE, Anwar S, Canter CE. Myocarditis. In: Allen HD, Shaddy RE, Penny DJ, Feltes TF, Cetta F, 9th, editors. *Moss and Adams' Heart Disease in Infants, Children, and Adolescents: Including the Fetus and Young Adult*. Philadelphia: Lippincott Williams & Wilkins; 2016. p.1313-1330.

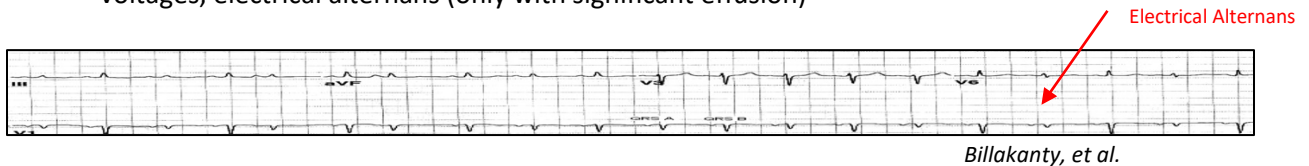
Pericarditis

Clinical findings

- **Positional** precordial or substernal chest pain (patient prefers to sit upright and lean forward)
 - May be pleuritic or worsened by movement or coughing
- **Friction rub**, a “scratchy” or “sandpaper” sound on cardiac exam in the context of chest pain is pathognomonic for pericarditis
- Heart sounds may be muffled in the presence of a large effusion
- May be associated with fever or abdominal pain from hepatic distention

Diagnosis

- CXR: cardiomegaly if a pericardial effusion is present, chronic pericarditis may cause calcifications in the pericardium
- Echo: diagnoses a pericardial effusion
- EKG: diffuse ST segment elevation, PR depression in limb leads, T wave inversions, diffusely low voltages, electrical alternans (only with significant effusion)



CARDIAC TAMPONADE: compression of the heart by fluid in the pericardial sac

- Ventricular filling is limited, causing decreased cardiac output
- **Beck’s Triad:** distant heart sounds, hypotension, jugular venous distention
- Tachycardia, tachypnea, narrow pulse pressure with pulsus paradoxus
- **Clues** to tamponade on echo: RA and RV free wall collapse in diastole, IVC dilation, exaggerated respiratory variation of flow across the mitral, tricuspid, and aortic valves
- **Treatment:** IV fluids, avoid vasodilators and diuretics, urgent pericardiocentesis

THIS IS A CLINICAL DIAGNOSIS. Tamponade is not diagnosed by echo.

Normal **Cardiac Tamponade**

A) Measuring Pulsus Paradoxus

B) Ventricular Interdependence

Roy, et al.

ETIOLOGIES OF PERICARDITIS	Treatment
Viral (most common) Enteroviruses (Coxsackie B) CMV Adenovirus EBV Influenza A and B HSV Rubella HIV Mumps RSV Measles Hepatitis B	Supportive care NSAIDs Colchicine Steroids
Bacterial (via hematogenous spread) <i>Staphylococcus aureus</i> (most common) <i>Haemophilus influenzae</i> <i>Pseudomonas aeruginosa</i> <i>Streptococcus pneumoniae</i> <i>Mycoplasma species</i> Other <i>Streptococci</i> <i>Legionella</i> <i>Neisseria species</i> <i>Chlamydia psittaci</i> TB	IV antibiotics for 3-4 weeks Drainage of the pericardial fluid via pericardiocentesis or surgical pericardial window
Fungal Parasitic Protozoal Rickettsial Spirochetal	
Oncologic Processes Primary tumors Metastatic Disease Complication of chemotherapy Complication of mediastinal irradiation	
Renal Failure Kawasaki Disease Drug-Induced Hypothyroidism Trauma Autoimmune and connective tissue diseases	

Postpericardiotomy Syndrome

- Occurs in up to 30% of patients after cardiac surgery
 - Due to pericardial and pleural inflammation
 - Most frequent after repair of ASD, VSD, TOF or after heart transplant
- Can be a single event, or can have a relapsing course for years
- Benign and self-limited, usually treated with NSAIDs and diuretics
- Like all forms of pericarditis, can lead to tamponade.

Questions

- What is pulsus paradoxus? How do you test for it?
- How will an infant with tamponade present?
- How do you decide if a patient requires a pericardiocentesis?

References

- Billakanty S, Bashir R. Echocardiographic demonstration of electrical alternans. *Circulation* 2006; 113:e866-e868.
- Johnson JN, Cetta F. Pericardial diseases. In: Allen HD, Shaddy RE, Penny DJ, Feltes TF, Cetta F, 9th, editors. *Moss and Adams' Heart Disease in Infants, Children, and Adolescents: Including the Fetus and Young Adult*. Philadelphia: Lippincott Williams & Wilkins; 2016. p.1427-1440.
- Roy CL, Minor MA, Brookhart MA, Choudhry NK. Does this patient with a pericardial effusion have cardiac tamponade? *JAMA* 2007; 297(16): 1810-1818.

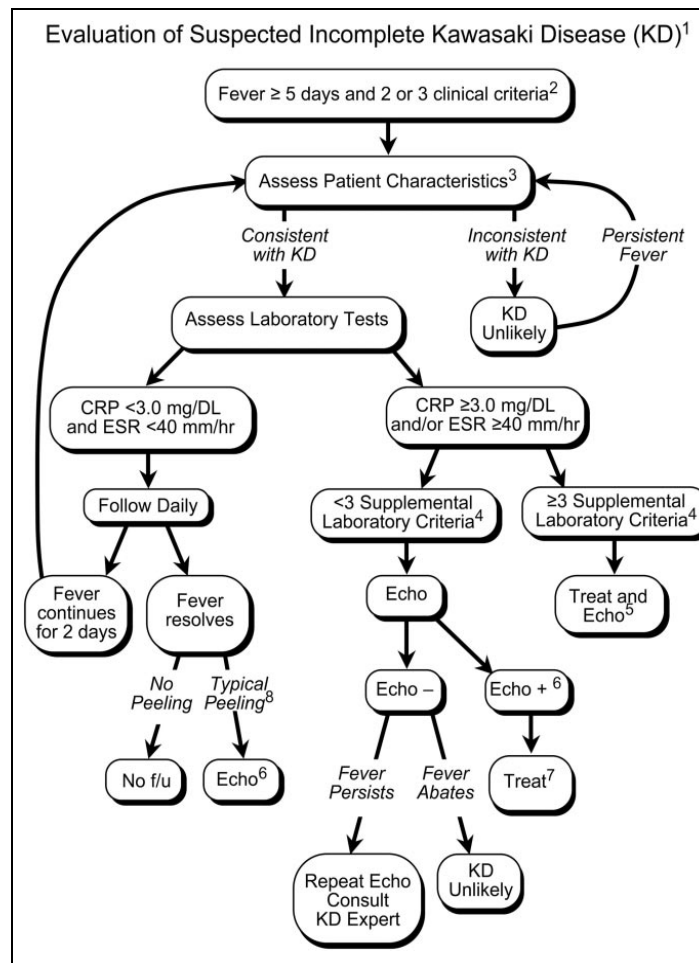
Kawasaki Disease or Mucocutaneous Lymph Node Syndrome

Suspected to be an immune response to an environmental trigger in a susceptible host.

- Incidence 20/100,000 children in the US
- Affects males more than females
- Typically affects children less than 5 years of age
- Higher incidence in Asians and Pacific Islanders

“Complete” Kawasaki Disease:

- **Fever for ≥ 5 days**
- **At least 4 of the following features:**
 - Extremity changes: erythema +/- edema, or later in the illness membranous desquamation starting in the subungual regions
 - Polymorphous rash (no bullae or vesicles)
 - Bilateral non-exudative conjunctival injection, often limbic-sparing
 - Mucositis: changes to lips and oral cavity, “strawberry tongue”
 - Cervical lymphadenopathy, usually large and unilateral
 - Exclusion of other possible diagnoses



- Infants ≤ 6 months with ≥ 7 days of fever and no other explanation should have inflammatory labs sent and, if positive, an echo even in the absence of other clinical criteria for KD
- **Supplemental Lab Criteria**
 - Albumin ≤ 3.0 g/dL
 - Anemia for age
 - Elevated ALT
 - Platelets ≥ 450,000 after 7 days
 - WBC ≥ 15,000
 - Urine ≥ 10 WBC per high-powered field
- It is ok to treat before obtaining an echo
- If the echo is positive, give IVIG if:
 - ≤ 10 days of fever, or
 - ≥ 10 days of fever and evidence of continued inflammation (elevated ESR or CRP)

Differential Diagnosis of Kawasaki Disease: Diseases and Disorders With Similar Clinical Findings

- Viral infections
(eg, measles, adenovirus, enterovirus, EBV)
- Scarlet fever
Staphylococcal scalded skin syndrome
Toxic shock syndrome
Bacterial cervical lymphadenitis
Drug hypersensitivity reactions
Stevens-Johnson syndrome
Juvenile rheumatoid arthritis
Rocky Mountain Spotted Fever
Leptospirosis
Mercury hypersensitivity reaction (acrodynia)

Newburger, et al. 2004

Cardiac Sequelae

- Coronary aneurysms
 - Higher risk of coronary aneurysms in infants or children over age 8
 - Risk of sudden death from acute thrombosis or rupture of a coronary aneurysm (highest risk at 15-45 days after onset of KD)
 - After resolution of the illness, there is risk of scarring, stenosis and calcification of the coronary arteries as they recanalize (after 40 days)
- Cardiac involvement may also include pericarditis, valvulitis, conduction system disease or fulminant myocarditis with risk of heart failure

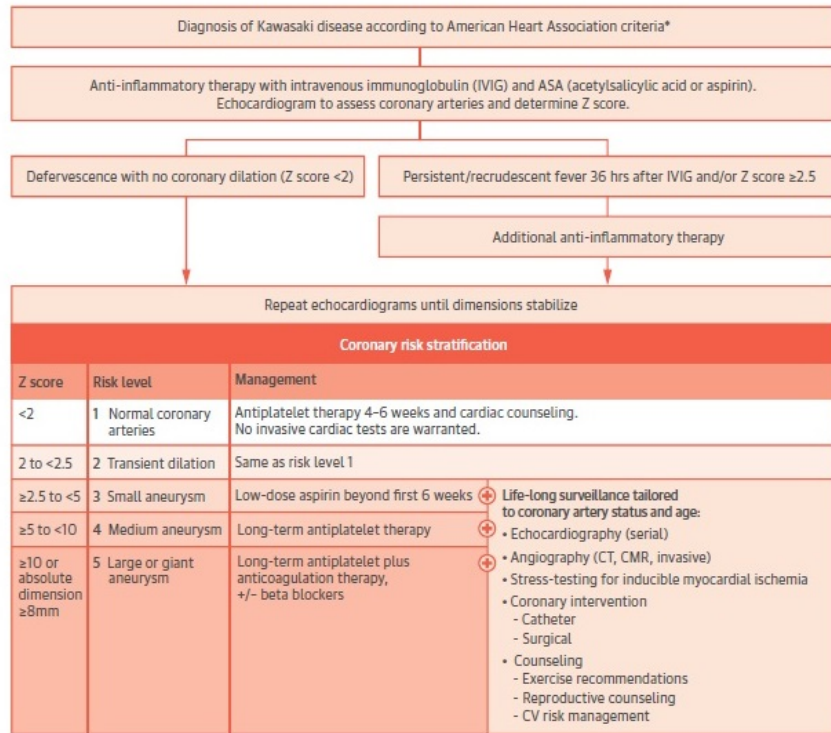
Diagnosis of Cardiac Disease

- EKG: sinus tachycardia, PR and QTc prolongation, decreased voltages, T-wave flattening
- Echo can be used to confirm the diagnosis and assess for coronary aneurysms or ectasia
 - Echo at diagnosis, at ~2 weeks and at ~6 weeks to assess for dilation and aneurysms.
 - If any ectasia or dilation of the coronaries is noted, then more frequent echocardiograms are warranted.
- Stress testing, cardiac catheterization, MRI and CT can be used for prognosis and follow-up in children with documented coronary aneurysms by echo

Treatment

- **Standard of care: 2g/kg IVIG + aspirin**
 - IVIG reduces the risk of coronary aneurysms from 25% to < 5% if given within 7-10 days of onset of the illness
 - Give IVIG after 10 days of illness if there is persistent fever, coronary changes or continued evidence of inflammation by lab data
 - High dose aspirin (80-100mg/kg/day divided q6 hours) until patient has defervesced for 48 hours, then continued 3-5mg/kg aspirin daily for ~6 weeks if no coronary involvement, or indefinitely if the coronaries are involved
- 10-20% have recrudescence of fever, and need a second course of IVIG with consideration given to treatment with steroids, infliximab, abciximab, methotrexate, cyclosporine, cyclophosphamide or anakinra

CENTRAL ILLUSTRATION Management of Kawasaki Disease



Newburger, J.W. et al. J Am Coll Cardiol. 2016;67(14):1738–49.

Newburger, et al. 2016

Risk Stratification

Risk Level	Antiplatelet Therapy	Exercise Restriction	Follow-up	Invasive Testing	Prognosis
I: (no coronary changes)	None after 1 st 6-8 weeks	No restrictions beyond 1 st 6-8 weeks	Cardiovascular risk assessment, counseling every 5 years	None	Same as general population
II (transient coronary artery ectasia, disappears within 1 st 6-8 weeks)	None after 1 st 6-8 weeks	No restrictions beyond 1 st 6-8 weeks	Cardiovascular risk assessment, counseling every 3-5 years	None	½ of aneurysms regress to normal in 1-2 years, but coronaries remain abnormal
III (1 small-medium coronary artery aneurysm)	Low-dose aspirin until aneurysm regression documented	<11 yo: no restrictions beyond 1 st 6-8 weeks 11-20 yo: guided by biennial stress test/myocardial perfusion scan Avoid contact sports while taking anti-platelet agents	Annual cardiology follow-up with echo and EKG + cardiovascular risk assessment, counseling Biennial stress test or myocardial perfusion scan	Angiography if noninvasive testing suggests ischemia	½ of aneurysms regress to normal in 1-2 years, but coronaries remain abnormal
IV (≥ 1 large or giant coronary aneurysm or multiple or)	Moderate/large aneurysms: low-	Avoid contact sports due to bleeding risk, other	Biannual follow-up with echo and EKG	1 st angiography (or CTA) at 6-12	Less likely to regress, risk for ischemic heart

(Continued)

complex aneurysms in same coronary artery, without obstruction)	dose aspirin + clopidogrel Giant aneurysms: warfarin or Lovenox + low-dose aspirin	recommendations guided by stress test/myocardial perfusion scan	Annual stress test/myocardial perfusion scan	months or sooner if clinically indicated Repeat angiography if other evidence of ischemia	disease via acute thrombosis or remote infarcts as arteries stenosis
V (coronary artery obstruction)	Cath or tissue plasminogen activator to restore perfusion Warfarin or Lovenox + low-dose aspirin +/- clopidogrel Consider beta-blockers, statins	Avoid contact sports due to bleeding risk, other recommendations guided by stress test/myocardial perfusion scan	Biannual follow-up with echo and EKG Annual stress test/myocardial perfusion scan	Angiography for therapeutic options, some suggest CTA for diagnostic purposes	Risk for ischemic heart disease via acute thrombosis or remote infarcts as arteries stenosis

Adapted from Newburger, et al. 2004

Questions

- Describe the time course of the illness. Which symptoms present earlier and later in the disease course?
- How do you distinguish Kawasaki Disease from other diagnoses?
- How would you counsel the parents of a child with a new diagnosis of Kawasaki Disease? How would you address concerns for risk of Reye syndrome with aspirin use?
- A 5 year old child has been diagnosed with Kawasaki Disease, but has no coronary aneurysms. How long will this child need follow-up with a cardiologist? What are the next steps for treatment and management?

References

- De Ferranti SD, Burns JC, Newburger JW. Kawasaki Disease (Mucocutaneous Lymph Node Syndrome). In: Allen HD, Shaddy RE, Penny DJ, Feltes TF, Cetta F, 9th, editors. *Moss and Adams' Heart Disease in Infants, Children, and Adolescents: Including the Fetus and Young Adult*. Philadelphia: Lippincott Williams & Wilkins; 2016. p.1355-1371.
- Newburger JW, Takahashi M, Burns JC. Kawasaki Disease. *JACC* 2016; 67(21):1738-1749.
- Newburger JW, Takahashi M, Gerber MA, et al. Diagnosis, Treatment and Long-Term Management of Kawasaki Disease: A statement for health professional from the committee on rheumatic fever, endocarditis and Kawasaki disease, Council on Cardiovascular Disease in the Young, American Heart Association. *Circulation* 2004; 110:2747-2771.

Superior Vena Cava Syndrome

Caused by obstruction of venous return to the heart by invasion or external compression of the SVC

- External compression
 - Infection causing mediastinal fibrosis
 - Malignancy: mediastinal tumors, lung cancer
 - Thrombosis from central venous catheters and transvenous pacemaker wires
- Cardiac causes
 - Post-surgical: Glenn procedure, intra-atrial baffle repair (Mustard/Senning), Fontan, post-transplant
 - Intracardiac thrombus at the SVC-RA junction
 - Right coronary artery aneurysms
 - Right coronary artery –right atrium fistula
 - TAPVR to the SVC

Clinical Presentation

- Edema in the head and neck
- Cyanosis
- Functional impairment: dysphagia, cough, impaired head and eyelid movements, visual changes, stridor due to laryngeal edema
- Signs of cerebral edema: headache, dizziness, syncope, confusion, or coma

Diagnosis

- Decreased cardiac output, hemodynamic compromise, death
- Chest X-ray will identify most external sources of compression
- Echo with Doppler can assess flow through the SVC

Treatment

- Ultrasound can be helpful, but CT is usually the most useful to define the extent of disease
- Treat the cause of obstruction:
 - OR for cardiac causes
 - Stent placement in the cath lab
 - Surgical venous bypass
 - Emergent radiation therapy or chemotherapy if malignancy is the main cause
- Raise the head of the bed
- Consider anticoagulation, steroids for specific tumors, and diuretics to lower the central venous pressure

Questions

- A 5 month old develops SVC syndrome after the Glenn operation. When and how would you expect this patient to present?
- A 3 year old develops SVC syndrome after the Fontan operation. When and how would you expect this patient to present?
- Why will a right coronary artery to right atrial aneurysm cause SVC syndrome?

References

Drews RE, Rabkin DJ. Malignancy-related superior vena cava syndrome. *Uptodateonline.com*
Rein AJT, Yatsiv I, Simcha A. Intracardiac causes of superior vena cava obstruction. *Eur J Pediatr* 1988;
148: 98-100.

Genetic Syndromes and Associations with Congenital Heart Disease

These tables can be used as an answer key for a Symptom/Association/Diagnosis matching game on the following pages!

Set A (game on pages 208- 209)

Chromosomal Anomalies	Genetic Abnormality	Associated Anomalies	Cardiac Associations
Turner Syndrome	45, X0	Horseshoe kidney Webbed neck Shield-like chest Lymphedema Cystic hygroma Infertility Short stature Typical facies Hypothyroidism	Left Heart Anomalies: -Bicuspid aortic valve -Aortic stenosis -Coarctation -Mitral valve anomalies -Mitral valve prolapse -HLHS Aortic dilation Hypertension Prolonged QTc
Trisomy 21	3 copies ch 21	Global developmental delays Duodenal atresia Hypothyroidism Clinodactyly of 5 th finger Leukemoid reactions Microbrachycephaly Hypotonia Epicanthal folds Transverse palmar crease	All forms AVSD VSD Secundum ASD PDA TOF
Trisomy 13	3 copies ch 13	Polydactyly Cleft lip and palate Holoprosencephaly Renal abnormalities Scalp cutis aplasia Microphthalmia	TOF DORV VSD ASD PDA AVSD Polyvalvar dysplasia
Trisomy 18	3 copies ch 18	Overlapping digits Posterior fossa anomalies Small facial features Rocker bottom feet Renal abnormalities	Polyvalvar dysplasia VSD TOF DORV AVSD

Williams Syndrome	7p11 deletion (<i>ELN1</i> gene)	Hypercalcemia Intellectual disability "Cocktail party" personality Elfin facies	Supravalvar AS Supravalvar PS Coarctation Coronary artery stenosis Pulmonary artery stenosis
Wolf-Hirschhorn Syndrome	4p16 deletion (<i>WHSC1</i> or <i>WHSC2</i> genes)	Immunodeficiency Microcephaly "Greek warrior helmet" facies Growth restriction Hearing loss Cleft lip/palate GU anomalies Seizures	Secundum ASD Valvar PS VSD
Cri du chat	5p15 deletion	Cat-like cry Cleft lip/palate Typical facies Microcephaly Developmental delay	VSD PDA TOF
Cat-Eye Syndrome	Tetrasomy 22p	Rectoanal & GU anomalies Coloboma Mild intellectual disability Micrognathia	TAPVR PAPVR Assorted CHDs

Set B (game on pages 210-211)

Chromosomal Anomalies	Genetic Abnormality	Associated Anomalies	Cardiac Associations
Tuberous Sclerosis	<i>TSC1</i> <i>TSC2</i>	Hamartomas of skin, brain, eyes, kidneys Infantile spasms Intellectual disability Ash leaf spots Shagreen patches Adenoma sebaceum Renal angiomyolipomas	Cardiac rhabdomyomas

Alagille Syndrome	<i>JAG1</i> <i>NOTCH2</i>	Paucity of bile ducts Chronic cholestasis Butterfly vertebrae Posterior embryotoxin Typical facies	Peripheral pulmonic stenosis Valvar PS TOF +/- PA ASD VSD Coarctation
DiGeorge or Velocardiofacial Syndrome	22q11.2 deletion (<i>TBX1</i> , <i>CRKL</i> , or <i>ERK2</i> genes)	Cleft palate Hypocalcemia T-cell dysfunction Feeding and speech issues Psychiatric disorders Mild intellectual disability Typical facies	Conotruncal defects: -IAA type B -Truncus arteriosus -TOF VSD Right aortic arch
Noonan Syndrome	<i>PTPN11</i> Also: <i>KRAS</i> , <i>SOS1</i> , <i>RAF1</i> , <i>NRAS</i> , <i>BRAF</i> , <i>SHOC2</i> , <i>RIT1</i> , <i>CBL</i> , <i>KAT68</i>	Short, webbed neck Pectus excavatum Bleeding diathesis Lymphatic anomalies Variable intellectual disability Typical facies	ASD HCM
Holt-Oram Syndrome	<i>TBX5</i>	Upper limb anomalies	ASD VSD Conduction defects
Kabuki Syndrome	<i>MLL2</i> <i>KDM6A</i>	Long palpebral fissures Cleft lip/palate Skeletal abnormalities Intellectual disability	ASD VSD Left heart anomalies: -Bicuspid aortic valve -Coarctation -HLHS
Neurofibromatosis	<i>NF1</i>	Café au lait spots Lisch nodules Neurofibromas Optic glioma, astrocytomas Scoliosis Seizures Cerebral vasculature anomalies Learning differences	Valvar PS Valvar AS Coarctation HCM

Smith-Lemli-Opitz Syndrome	<i>DHCR7</i>	2-3 toe syndactyly Cleft palate Lung anomalies Genetic anomalies	Secundum ASD VSD Complete AVSD TAPVR
CHARGE Syndrome	Ch 8q12.1 (<i>CHD7</i> gene mutation)	Coloboma Choanal atresia Genital anomalies Ear anomalies Facial asymmetry Cleft lip/palate Deafness Growth delay	Conotruncal defects: -TOF -DORV +/- AVSD Aortic arch anomalies

Unknown Syndromes

Chromosomal Anomalies	Genetic Abnormality	Associated Anomalies	Cardiac Associations
Systemic Lupus Erythematosus	Unknown	Malar butterfly rash Fever Myositis or myalgias Photosensitivity Oral and nasopharyngeal ulcers Arthralgias Seizures Neuropsychiatric changes Renal disease Hemolytic anemia Pancreatitis Hepatitis	Pericarditis Endocarditis Myocarditis
VACTERL	Heterogenous mutations	Vertebral anomalies Anorectal anomalies TE Fistula Renal anomalies Radial abnormalities	Assorted CHDs Single umbilical artery

References

- Goldmuntz E, Crenshaw ML. Genetic Aspects of Congenital Heart Defects. In: Allen HD, Shaddy RE, Penny DJ, Feltes TF, Cetta F, 9th, editors. Moss and Adams' Heart Disease in Infants, Children, and Adolescents: Including the Fetus and Young Adult. Philadelphia: Lippincott Williams & Wilkins; 2016. p.87-115.
- Marcdante KJ, Kliegman RM. Chromosomal disorders. In: Marcdante KJ, Kliegman RM, 7th, editors. Nelson Essentials of Pediatrics. Philadelphia: Elsevier Saunders; 2015. p.156-160.
- Marcdante KJ, Kliegman RM. Neurocutaneous disorders. In: Marcdante KJ, Kliegman RM, 7th, editors. Nelson Essentials of Pediatrics. Philadelphia: Elsevier Saunders; 2015. p.645-647.
- Marcdante KJ, Kliegman RM. Systemic lupus erythematosus. In: Marcdante KJ, Kliegman RM, 7th, editors. Nelson Essentials of Pediatrics. Philadelphia: Elsevier Saunders; 2015. p.309-311.

Match one from each column! (see pages 212-214 for answers)

Chromosomal Anomalies	Genetic Abnormality	Associated Anomalies	Cardiac Associations
Turner syndrome	5p15 deletion	<ul style="list-style-type: none"> Immunodeficiency Microcephaly "Greek warrior helmet" facies Growth restriction Hearing loss Cleft lip/palate GU anomalies Seizures 	<ul style="list-style-type: none"> Rectoanal & GU anomalies Coloboma Mild intellectual disability Micrognathia
Trisomy 21	45 X,O	<ul style="list-style-type: none"> Global developmental delays Duodenal atresia Hypothyroidism Clinodactyly of 5th finger Leukemoid reactions Microbrachycephaly Hypotonia Epicanthal folds Transverse palmar crease 	<ul style="list-style-type: none"> Polydactyly Cleft lip and palate Holoprosencephaly Renal abnormalities Scalp cutis aplasia Microphthalmia
Wolf-Hirschhorn Syndrome	7p11 deletion (ELN1 gene)	<ul style="list-style-type: none"> Horseshoe kidney Webbed neck Shield-like chest Lymphedema Cystic hygroma Infertility Short stature Typical facies Hypothyroidism 	<ul style="list-style-type: none"> Supravalvar AS Supravalvar PS Coarctation Coronary artery stenosis
Trisomy 13	4p16 deletion (WHSC1 or WHSC2 genes)	<ul style="list-style-type: none"> Cat-like cry Cleft lip/palate Typical facies Microcephaly Developmental delay 	<ul style="list-style-type: none"> VSD PDA TOF
Cri du chat	3 copies ch 18	<ul style="list-style-type: none"> Overlapping digits Posterior fossa anomalies Small facial features Rocker bottom feet Renal abnormalities 	<ul style="list-style-type: none"> TAPVR PAPVR Assorted CHDs
Trisomy 18	3 copies ch 13	<ul style="list-style-type: none"> Hypercalcemia Intellectual disability "Cocktail party" personality Elfin facies 	<ul style="list-style-type: none"> Polyvalvar dysplasia VSD TOF DORV AVSD
Williams Syndrome	Tetrasomy 22p		<ul style="list-style-type: none"> All forms AVSD VSD Secundum ASD PDA TOF
Cat-Eye Syndrome	3 copies ch 21		<ul style="list-style-type: none"> LVOTO: Bicuspid aortic valve Aortic stenosis Coarctation Mitral valve anomalies Mitral valve prolapse HLHS Aortic dilation Hypertension Prolonged QTc

Match one from each column! (see pages 212-214 for answers)

Chromosomal Anomalies	Genetic Abnormality	Associated Anomalies	Cardiac Associations
Kabuki Syndrome	Heterogeneous mutations	Cleft palate Hypocalcemia T-cell dysfunction Feeding and speech issues Psychiatric disorders Mild intellectual disability Typical facies	Pericarditis Endocarditis Myocarditis
Tuberous Sclerosis	TBX5	Malar butterfly rash Fever Myositis Myalgias Photosensitivity Oral and nasal ulcers Arthralgias Seizures Neuropsychiatric changes Renal disease Hemolytic anemia Pancreatitis Hepatitis	Valvar PS ASD HCM
Smith-Lemli-Opitz Syndrome	NF1	Café au lait spots Lisch nodules Neurofibromas Optic glioma, astrocytomas Scoliosis Seizures Cerebral vasculature anomalies Learning differences	Valvar AS Valvar PS Coarctation HCM
Alagille Syndrome	PTPN11	Upper limb anomalies	ASD VSD Conduction defects
VACTERL	Ch 8q12.1 CHD7 gene	Paucity of bile ducts Chronic cholestasis Butterfly vertebrae Posterior embryotoxin Typical facies	Conotruncal defects: TOF DORV +/- AVSD Aortic arch anomalies
DiGeorge or Velocardiofacial Syndrome	Unknown	Long palpebral fissures Cleft lip/palate Skeletal abnormalities Intellectual disability	Peripheral PS Valvar PS TOF +/- PA ASD VSD Coarctation
CHARGE Syndrome	TSC1 TSC2	2-3 toe syndactyly Cleft palate Lung anomalies	Cardiac rhabdomyomas
Noonan Syndrome	JAG1 NOTCH2	Hamartomas of skin, brain, eyes and kidney Infantile spasms Intellectual disability Ash leaf spots Shagreen patches Adenoma sebaceum Renal angiomyolipomas	Conotruncal defects: IAA type B, TOF, Truncus arteriosus VSD Right aortic arch
Holt-Oram Syndrome	DHCR7		Secundum ASD VSD Complete AVSD TAPVR
Neurofibromatosis	MLL2 KDM6A		Assorted CHDs Single umbilical artery
Systemic Lupus Erythematosus	Ch 22q11 deletion TBX1, CRKL, ERK2 genes		ASD VSD LVOTO: Bicuspid aortic valve Coarctation HLHS

Appendix 1: Acronyms

AI	Aortic Insufficiency (also called aortic regurgitation)
AICD	Automatic implantable cardioverter-defibrillator
ALCAPA	Anomalous left coronary artery from the pulmonary artery
Ao	Aorta
AP Window	Aortopulmonary window
ARF	Acute rheumatic fever
AS	Aortic stenosis
ASD	Atrial septal defect
ASO	Arterial switch operation
AVM	Arteriovenous malformation
AVSD	Atrioventricular septal defect
BTS	Blalock-Taussig shunt (also called the Blalock-Thomas-Taussig shunt)
CHD	Congenital heart disease
CI	Cardiac index (cardiac output indexed to body surface area)
CO	Cardiac output
CS	Coronary sinus
DCM	Dilated cardiomyopathy
DKS	Damus-Kaye-Stansel procedure
DORV	Double outlet right ventricle
D-TGA	D-transposition of the great arteries
ECMO	Extracorporeal membrane oxygenation
HCM	Hypertrophic cardiomyopathy
HLHS	Hypoplastic left heart syndrome
IE	Infective endocarditis
IVC	Inferior vena cava
JET	Junctional ectopic tachycardia
KD	Kawasaki Disease
LA	Left atrium
LBBB	Left bundle branch block
LPA	Left branch pulmonary artery
L-SVC	Left-sided superior vena cava
L-TGA	L-transposition of the great arteries
LV	Left ventricle
LVH	Left ventricular hypertrophy
LVNC	Left ventricular non-compaction
LVOT	Left ventricular outflow tract
LVOTO	Left ventricular outflow tract obstruction
MAPCAs	Major aortopulmonary collaterals
MPA	Main pulmonary artery
MR	Mitral regurgitation
MS	Mitral stenosis

NSVT	Non-sustained ventricular tachycardia
PA	Pulmonary artery OR pulmonary atresia
PA/IVS	Pulmonary atresia with intact ventricular septum
PAH	Pulmonary arterial hypertension
PAPVR	Partial anomalous pulmonary venous return
PBF	Pulmonary blood flow
PDA	Patent ductus arteriosus
PFO	Patent foramen ovale
PGE	Prostaglandin E1
PH	Pulmonary hypertension
PI	Pulmonary insufficiency (also called pulmonary regurgitation)
POTS	Postural orthostatic tachycardia syndrome
PS	Pulmonary stenosis
PVOD	Pulmonary veno-occlusive disease
PVR	Pulmonary vascular resistance
Qp	Pulmonary blood flow
Qs	Systemic blood flow
RA	Right atrium
RAS	Restrictive atrial septum
RBBB	Right bundle branch block
Rp	Pulmonary vascular resistance
RPA	Right branch pulmonary artery
Rs	Systemic vascular resistance
RV	Right ventricle
RVDCC	Right ventricular dependent coronary circulation
RVH	Right ventricular hypertrophy
RVOT	Right ventricular outflow tract
RVOTO	Right ventricular outflow tract obstruction
RV-PA conduit	Right ventricle to pulmonary artery conduit
SBE	Subacute bacterial endocarditis
SVC	Superior vena cava
SVR	Systemic vascular resistance
SVT	Supraventricular tachycardia
TAPVC	Total anomalous pulmonary venous connection
TAPVR	Total anomalous pulmonary venous return
TOF	Tetralogy of Fallot
TR	Tricuspid regurgitation
TS	Tricuspid stenosis
VAD	Ventricular assist device
VO ₂	Oxygen consumption
VSD	Ventricular septal defect
VT	Ventricular tachycardia
WPW	Wolff-Parkinson-White Syndrome