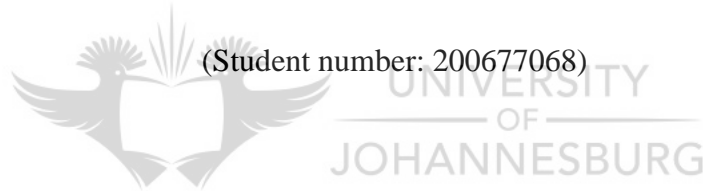

**The reliability of iridology in the diagnosis of previous acute
appendicitis, as evidenced by appendectomy**

A dissertation submitted to the Faculty of Health Sciences, University of
Johannesburg, as partial fulfilment of the requirement for the Degree: Master of
Technology: Homoeopathy by

Lora Frank



Supervisor:

Dr. J. Pellow

(M.Tech Hom (TWR))

Co-Supervisor:

Prof. J. T. Ferreira

(Ph.D, PHED.B Optom (RAU), CAS (NEWENCO))

Johannesburg, 2012



AFFIDAVIT: MASTER'S AND DOCTORAL STUDENTS TO WHOM IT MAY CONCERN

This serves to confirm that I _____
(Full Name(s) and Surname)

ID
Number _____

Student number _____ enrolled
for the

Qualification _____

Faculty _____

Herewith declare that my academic work is in line with the Plagiarism Policy of the University of Johannesburg which I am familiar with.

I further declare that the work presented in the _____
(minor dissertation/dissertation/thesis) is authentic and original unless clearly indicated otherwise and in such instances full reference to the source is acknowledged and I do not pretend to receive any credit for such acknowledged quotations, and that there is no copyright infringement in my work. I declare that no unethical research practices were used or material gained through dishonesty. I understand that plagiarism is a serious offence and that should I contravene the Plagiarism Policy notwithstanding signing this affidavit, I may be found guilty of a serious criminal offence (perjury) that would amongst other consequences compel the UJ to inform all other tertiary institutions of the offence and to issue a corresponding certificate of reprehensible academic conduct to whomever request such a certificate from the institution.

Signed at _____ on this _____ day of _____ 20__.

Signature _____ Print name _____

STAMP COMMISSIONER OF OATHS

Affidavit certified by a Commissioner of Oaths

This affidavit conforms with the requirements of the JUSTICES OF THE PEACE AND COMMISSIONERS OF OATHS ACT 16 OF 1963 and the applicable Regulations published in the GG GNR 1258 of 21 July 1972; GN 903 of 10 July 1998; GN 109 of 2 February 2001 as amended.

“The light of the body is the eye; if then your eye is true,
all your body will be full of light.” Matthew 6:22



ACKNOWLEDGEMENTS

I wish to thank the following:

My parents, Theo and Rita, for their unwavering support

My fiancée, Llewellyn, for the food and flowers

My supervisor Dr Janice Pellow for her guidance and infinite patience

My co-supervisor Professor Jannie Ferreira for his constructive criticism

The exceedingly kind and helpful staff at Rita Frank Optometrists

The individuals who participated in the study, without you this dissertation would not have been possible

The iridologists who agreed to participate in this study.



ABSTRACT

Iridology is defined as a science that identifies pathological and functional changes within organs via assessing the iris for aberrant lines, spots, and discolourations (Medow, 2000). According to iridology, the iris does not reflect changes during anaesthesia, due to its inhibitory effect on nerves impulses, and in cases of organ removal, it reflects the pre-surgical condition (Jensen, 1986).

The Homoeopathic profession is frequently associated with iridology and in a recent survey by Rostovsky *et al.* (2009) investigating the perceptions of Masters of Technology graduates in Homoeopathy on the existing programme offered by the University of Johannesburg, iridology was highly regarded as a potential additional skill requirement for assessing the health status of the patient.

This was a randomized and controlled quantitative study. The study aimed to assess the reliability of iridology in the diagnosis of previous acute appendicitis, as evidenced by appendectomy.

A total of 60 participants took part in the study. Of the 60 participants, 30 had had an appendectomy due to acute appendicitis, and 30 with their appendix intact with no prior history of appendicitis. All participants were recruited on the premises of Rita Frank Optometrists. Each participant signed a Participant Information and Consent Form (Appendix E) and a Consent Form to Photograph the iris (Appendix F). Thereafter the researcher obtained the information required in a private setting (Appendix G). Afterwards each participant's right iris was documented by photograph with the use of a specialist non-mydriatic retinal camera (Canon EOS-20D), reset for the iris, by the researcher. The photographs were then randomized by an external person and no identifying data made available to the three raters. The raters included the researcher and two practising iridologists. Data was obtained from the analyses of the photographs wherein the presence or absence of lesions (implying acute appendicitis) was indicated by the raters. All the data was captured into an Excel spreadsheet (Appendix H) and sent for statistical analysis.

None of the three raters showed a significant success rate in determining correctly who had had acute appendicitis and resultant appendectomies and who had not. The outcome of this study indicated an outcome that was subject to chance.

The null hypothesis that states that appendectomy due to acute appendicitis does not manifest in a corresponding lesion in the typical organ area of the eye, is supported. It is in the opinion of the researcher that the association of iridology with homoeopathic practice may harm the credibility of the profession and that further research on iridology is needed to disprove this conviction.

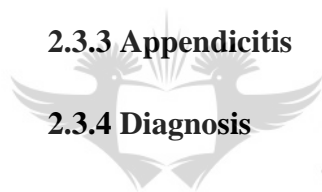


TABLE OF CONTENTS

	PAGE
AFFIDAVIT	ii
DEDICATION	iii
ACKNOWLEDGEMENTS	iv
ABSTRACT	v
APPENDICES	xii
LIST OF FIGURES	xiii
LIST OF DIAGRAMS	xiv
CHAPTER 1 – INTRODUCTION	
1.1 Problem Statement	1
1.2 Objectives	2
1.3 Hypothesis	2
1.4 Null Hypothesis	2
CHAPTER 2 – LITERATURE REVIEW	
2.1 Iridology	
2.1.1 Definitions	3
2.1.2 Brief History	3
2.1.3 Benefits and Costs of Iridology	3

2.1.4 South African Perspective	4
2.1.5 Introduction to Theory	
2.1.5.1 The Five Central Principles	5
2.1.5.2 Iris Geography	6
2.1.5.3 Textures and Lesions	7
2.1.6 Surgery	10
2.1.7 Related Research	
2.1.7.1 Negative Studies	10
2.1.7.2 Positive Studies	12
2.2 The Iris	
2.2.1 Basic Anatomy	12
2.2.2 Structure	
2.2.2.1 Introduction	13
2.2.2.2 The Anterior Border Layer	14
2.2.2.3 The Iris Stroma	15
2.2.2.4 The Pupillary Muscular Layer	16
2.2.2.5 The Posterior Epithelium	17
2.2.3 Embryology of the Iris	
2.2.3.1 Development	17
2.2.4 Congenital Defects and Anomalies	19
2.2.4.1 Defects	19
2.2.4.2 Anomalies	22

2.2.5 Colour and Individuality	23
2.2.6 Pathologies Affecting the Appearance of the Iris	23
2.2.6.1 Pathologies Predominantly Affecting Structure	24
2.2.6.2 Pathologies Predominantly Affecting Colour	27
2.3 The Appendix	
2.3.1 Anatomy and Function	29
2.3.2 Embryological Development	29
2.3.3 Appendicitis	30
2.3.4 Diagnosis	31
2.3.5 Treatment	31
2.3.6 The Appendix and Iridology	32



UNIVERSITY
OF
JOHANNESBURG

CHAPTER 3 – MATERIALS AND METHODS

3.1 Research Sample	33
3.1.1 Inclusion Criteria	33
3.1.2 Exclusion Criteria	33
3.2 Study Design	34
3.3 Study Procedure	
3.3.1 Consultation	34

3.3.2 Photography	35
3.4 Data collection	35
3.5 Validity and Reliability Measure	36
3.6 Ethics	37
3.7 Statistical Analysis	37

CHAPTER 4 – RESULTS

4.1 Introduction to Results	38
4.2 Descriptive Statistics	39
4.2.1 Group	39
4.2.2 Age	40
4.2.3 Gender	40
4.2.4 Eye Colour	41
4.2.5 Number of Years Ago of Appendectomy	42
4.2.6 Iride signs	43
4.3 Distribution of Raters' Responses	44
4.4 Contingency Analyses	45
4.5 Rater Agreement	48
4.6 Logistic Regression	48



CHAPTER 5 – DISCUSSION

5.1 Interpretation of Results

5.1.1 Distribution of Age and Gender	52
5.1.2 Distribution of Rater's Responses	53
5.1.3 Contingency Analyses	54
5.1.4 Agreement of Rater's Responses	54
5.1.5 Logistic Regression	55
5.1.6 Further Discourse on the Results	57
5.1.7 Repercussions for the Homoeopathic Profession	58

5.2 Considerations 59

CHAPTER 6 – CONCLUSION

6.1 Conclusions	61
-----------------	----

6.2 Recommendations	61
---------------------	----

GLOSSARY	63
-----------------	----

REFERENCES	71
-------------------	----

APPENDICES

APPENDIX A: Off-site Permission	77
APPENDIX B: Permission obtained from Rita Frank Optometrists	78
APPENDIX C: Operating procedure for taking anterior segment photography with the Canon EOS-20D digital camera	79
APPENDIX D: An iris chart showing the topographical relationship of the iris to organs of the body according to Bernard Jensen	80
APPENDIX E: Participant Information and Consent Form	81
APPENDIX F: Patient Consent to Clinical Photography	84
APPENDIX G: Participant Record	85
APPENDIX H: Spreadsheet	86
APPENDIX I: Distributions	87
APPENDIX J: Agreement Statistics	89
APPENDIX K: Chi-Square: Fit Y by X Group	90
APPENDIX L: Distributions	93
APPENDIX M: Logistic Rater 1	94
APPENDIX N: Logistic Rater 2	95
APPENDIX O: Logistic Rater 3	96



UNIVERSITY
OF
JOHANNESBURG

LIST OF FIGURES

FIGURE

2.1. The Zones of the Iris	6
2.2. Radial Division of the Iris	7
2.3. Textures and Lesions	8
2.4. Cross Section of Degrees of Degeneration	9
2.5. Healing Signs	9
2.6. Major Structures and Regions of the Eye	13
2.7. The Iris in Cross Section	13
2.8. The Anterior Border Layer of the Iris	14
2.9. Iris Vessels and the Minor Arterial Circle	16
2.10. Orientation of Sphincter and Dilator Muscles	17
2.11. Successive Developmental Stages of the Lens, Retina, Iris and Cornea. A, 5 weeks. B, 6 weeks. C, 20 weeks. D, newborn.	18
2.12. Anomalies of the Iris and Pupil	21
2.13. Successive Stages in the Development of the Caecum and Appendix. A, 6 weeks. B, 8 weeks. C, 12 weeks. D, at birth.	30
2.14. Lesion in the Appendix Area of the Right Iris	32

LIST OF DIAGRAMS

DIAGRAM

4.1. Distribution of Participants With and Without Appendectomies	39
4.2. Distribution of Age of Participants	40
4.3. Distribution of Gender between Participants	40
4.4. Distribution of Gender between Groups	41
4.5. Proportion of Eye Colours of Participants	41
4.6. Distribution of Eye Colour within Groups	42
4.7. Distribution of Appendectomies of Participants in Years	42
4.8. Distribution of Responses by Rater 1	43
4.9. Distribution of Responses by Rater 3	44
4.10. Distribution of Rater 1's Responses	44
4.11. Distribution of Rater 2's Responses	45
4.12. Distribution of Rater 3's Responses	45
4.13. Contingency Analysis by Group by Iride Sign (Rater 1)	46
4.14. Contingency Analysis by Group by Iride Sign (Rater 2)	47
4.15. Contingency Analysis by Group by Iride Sign (Rater 3)	47
4.16. Logistic Rater 1	49
4.17. Logistic Rater 2	50
4.18. Logistic Rater 3	51



CHAPTER 1

INTRODUCTION

1.1 Problem Statement

Iridology, also known as iris diagnosis or iridiagnosis, is defined as a science that identifies pathological and functional changes within organs via assessing the iris for aberrant lines, spots and discolourations (Medow, 2000). Iridology is a worldwide phenomenon and is frequently incorporated as an adjunct to existing diagnostic techniques by a wide range of complementary therapists. According to Ernst (2000) it is punted as the most invaluable naturopathic tool in the United States of America, and in Germany, 80% of the alternative health practitioners or Heilpraktiker use it (which includes homoeopaths). The Homoeopathic profession is frequently associated with iridology and in a recent survey by Rostovsky *et al.* (2009) to investigate perceptions of Masters of Technology graduates in Homoeopathy on the existing programme offered by the University of Johannesburg, iridology was highly regarded as a potential additional skill requirement for assessing the health status of the patient. There have been several studies on iridology which have proven it ineffective in the diagnosis of certain diseases, specifically cancer, gallbladder disease, kidney disease, ulcerative colitis, asthma, coronary heart disease and psoriasis (NCCAM, 2008; Buchanan *et al.*, 1996). Other studies have found it useful in the diagnosis of hypertension and hearing loss (NCCAM, 2008; Stearn & Swanepoel, 2006). This study aimed to establish the usefulness of iridology in determining a previous acute appendicitis as evidenced by appendectomy. This is based on the precept that exists in iridology that the iris does not reflect changes during anaesthesia, due to its inhibitory effect on nerve impulses, and in cases of organ removal, it reflects the pre-surgical condition (Jensen, 1986).

1.2 Objectives

This study aimed to assess the reliability of iridology in the diagnosis of previous acute appendicitis, as evidenced by appendectomy.

1.3 Hypothesis

It is hypothesized that an appendectomy due to a previous acute appendicitis will be represented by the typical lesion in the iris. If these typical iride signs are seen by the respective parties in the correct photographs, the hypothesis would be accepted.

1.4 Null Hypothesis

The null hypothesis is that appendectomy due to acute appendicitis does not produce any lesion in the typical location in the iris. If no such signs or correlations can be made between irises and appendectomies, the null hypothesis would be accepted.

CHAPTER 2

LITERATURE REVIEW

2.1 Iridology

2.1.1 Definitions

Iridology, also known as iris diagnosis or iridiagnosis, is defined as a science that identifies pathological and functional changes within organs via assessing the iris for aberrant lines, spots, and discolourations (Medow, 2000). Another definition of iridology, by Jensen (1989), is that it is the science of establishing acute, sub-acute, chronic and destructive levels in the afflicted organs of the body through their matching areas in the iris.

2.1.2 Brief History

The inspection of the iris as a health indicator has existed since antiquity, but the foundation for iridology was first established in 1670 by Phillipi Meyers, and extrapolated upon by Ignaz Péczely in 1881 and Nils Liljequist (a Swedish homoeopath) in 1890 (Norn, 2003). An American chiropractor, Bernard Jensen (1908-2002), later diagrammatically illustrated the position of specific organs, body parts and functions as manifested in the iris (NCCAM, 2008). His published works is considered the standard in English literature (Medow, 2000).

2.1.3 Benefits and Costs of Iridology


According to the Iridology Institute of Southern Africa, iridology offers several advantages to health professionals:

1. It is non-invasive and safe
2. It is cost effective

3. Iris signs manifest before gross pathology does, thus iridology may provide information on vital processes before symptoms manifest - therefore it is particularly useful in preventative care
4. It provides a valuable framework for assessing future limitations and potentials of a patient's health (IISA, 2011).

O'Mathuna (2003), however, is of the opinion that whilst iridology is harmless in terms of examination or photography of the eye, considerable damage can be done if iridology is used with the exclusion of other reliable diagnostic tools. He bases his conclusion on the following:

1. False negatives may cause patients to delay seeking treatment for serious conditions
2. False positives may provoke considerable anxiety and encourage unnecessary interventions
3. Patients may waste valuable resources and risk side-effects from the herbal remedies and dietary supplements prescribed by the iridologist



2.1.4 South African Perspective

A number of courses offering iridology training exist in South Africa. The training varies from correspondence courses to workshops to part-time study, as do the contact hours and methods of assessment at the end of the course. Institutions offering these courses include the Iridology Institute of Southern Africa (IISA), the South African Iridology Institute (SAII), the Institute of Natural Health (INH), the College of Iridology and Natural Health and Healing Hands International.

The course fees vary widely, from R22 000 to R4000, from most to least expensive. Each organization has its own method of assessing the appropriate outcomes of learning, be it with written exams, case studies or practical assessments. After completing the course and complying with the set criteria, the student receives a certificate or diploma from the specific institution. At present

there is no single regulatory body that governs the standard of training and persons practising iridology are not required to register under the Allied Health Professions Council, as it is considered a diagnostic tool, not a profession.

Courses are open to all individuals with an interest in iridology, although some courses may require a basic background in anatomy and physiology. According to Dr Florrie Kerschbaumer, the founder of the IISA and registered homoeopath and naturopath, a wide variety of healthcare practitioners enrol for their course, specifically medical doctors, homoeopaths, naturopaths, chiropractors and optometrists (Kerschbaumer, 2010). Indeed, the homoeopathic profession is frequently associated with iridology and in a recent survey by Rostovsky *et al.* (2009) investigating the perceptions of Masters of Technology graduates in Homoeopathy on the existing programme offered by the University of Johannesburg, iridology was highly regarded as a potential additional skill requirement for assessing the health status of the patient.

2.1.5 Introduction to Theory



Iridology is much likened to a kind of reflexology of the eye (Bodeen & Jensen, 1992). According to theory, the iris is connected to all organs through the brain and nervous system, forming a kind of iris homunculus – thus changes or derangements are relayed by a reflex physiology by nerve fibers to its corresponding segment on the iris (Jensen, 1986).

2.1.5.1 The Five Central Principles

The five central principles of iridology according to Snyman (2002) are:

1. Abnormalities in tissues are indicated by changes in the iris's pigmentation and structure.
2. Every organ, gland and tissue is reflexively represented in an exact locus in the left or right iris, or both.

3. Organs and tissues on the left side of the body are expressed in the left iris while those on the right side are expressed in the right iris. Organs and tissues in the centre of the body, as well as bilateral organs, appear in both irises.
4. The physiological change in the iris mirrors the specific pathological changes in the corresponding organ or tissue.
5. Inherent weaknesses (crypts and separations in trabeculae), inherent strengths (dense trabeculae), and the degree of nervous system sensitivity (concentric cramp rings) are shown in the iris.

2.1.5.2 Iris Geography

The iris is divided into seven equal concentric zones, from the pupil outward, as can be seen in Figure 2.1 (Bamer, 1996).




Figure 2.1: The Zones of the Iris (Bamer, 1996)

Areas falling in the zones are:

1. Gastric mucosa
2. Complete intestinal tract (small and large)
3. Heart, pancreas, pituitary gland, adrenals, aorta, gall bladder, solar plexis, parathyroid, uterus, prostate, pineal gland

4. Bronchial tubes
5. Brain and reproductive organs
6. Spleen, thyroid, liver, kidneys and spine
7. Superior (sweat glands and skin), inferior (lymphatics, circulatory, motor and sensory nerves) (Bamer, 1996).

The iris is also divided into 2 more divisions: radial – into minutes, hours or degrees, as on the face of a clock (Figure 2.2); and sectoral – from quadrants to eighths to sixteenths (Kriege & Priest, 1977). These divisions help to pinpoint exact organ locations.

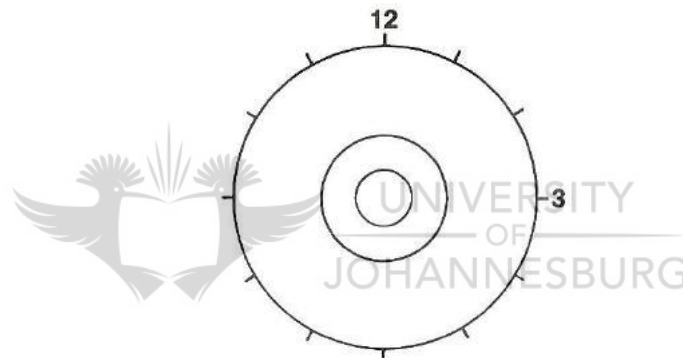


Figure 2.2: Radial Division of the Iris (Jenks, 1981)

2.1.5.3 Textures and Lesions

There are several textures and lesions that can occur in the iris, as can be seen in Figure 2.3 and which is expanded upon below:

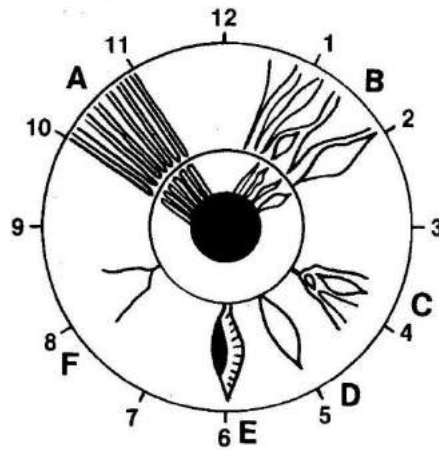


Figure 2.3: Textures and Lesions (Jenks, 1981)

- A. Tightly-knit trabeculae indicating strong recuperative ability
- B. Loose trabeculae indicative of poor recuperative ability
- C. Lesions within an open lesion
- D. Closed lesion, with white outline (blue or brown inside indicates an inherited weakness)
- E. Closed lesion, with white outline and sunken (indicates an inherently weak area, and now degenerated (black), because of continuing abuse)
- F. Open lesion (Jenks, 1981)

Figure 2.4 illustrates a cross-section of the effect of progressive degeneration on the iris. Acute (white) indicates over-activity, acute inflammation or mucous. A degenerative (black) lesion indicates major toxic build-up and degeneration, and the other two lesions, sub-acute (light-grey) and chronic (dark-grey), fall between these other two (Bamer, 1996).

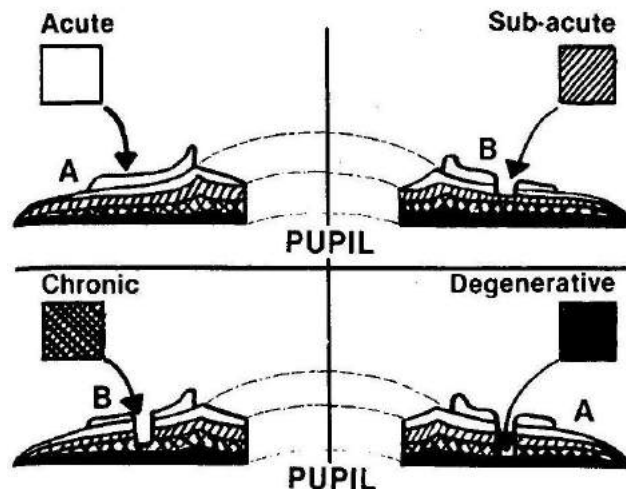


Figure 2.4: Cross Section of Degrees of Degeneration (Jenks, 1981)

Healing signs are basically the opposite of degeneration. For example, in Figure 2.5 below, healing progresses through from A to D:

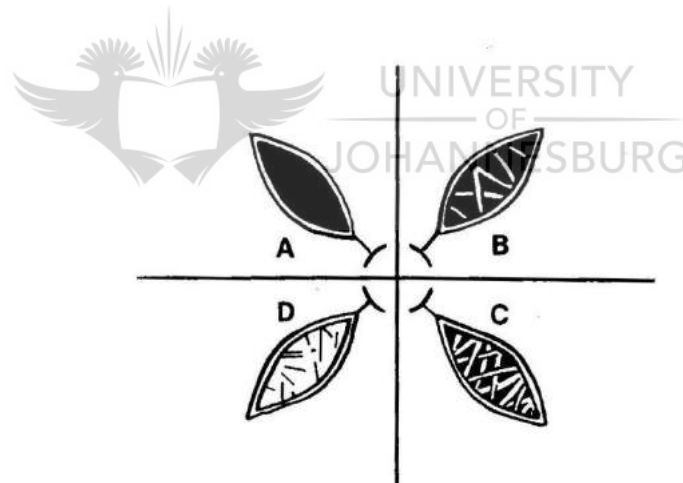


Figure 2.5: Healing Signs (Jenks, 1981)

- A. Black, sunken lesion (degenerative)
- B. Healing white lines
- C. Increase in healing signs
- D. All white acute (over-activity)

In the final step the area returns to its former colour.


2.1.6 Surgery

Past surgeries on organs are not forever imprinted in the iris, mainly because the organ heals and the iris then exhibits the typical healing signs as mentioned above. But in the case of complete surgical removal of an organ, the iris manifests the condition prior to anaesthetic administration. The anaesthetic inhibits nervous relay to the iris while the nerves are severed during resection - this essentially freezes the pre-surgical state in time – as a lesion that is permanently imprinted in the specific organ area of the iris (Jensen, 1986).

2.1.7 Related research

2.1.7.1 Negative Studies

In an article by the National Center for Complementary and Alternative Medicine (NCCAM, 2008), a scientific review was made of the evidence for iridology in terms of:

- 
- Disease diagnosis (no evidence nor scientific basis)
 - Hypertension diagnosis (preliminary research suggests that a correlation may exist)
 - Cancer diagnosis (no diagnostic accuracy)
 - Gallbladder disease (lack of evidence)
 - Kidney disease (also lack of evidence)

The researchers concluded that iridology is not an effective method to diagnose or treat disease and whilst not harmful to otherwise healthy individuals, may lead to their inappropriate treatment.

Another article published in Australian Doctor (2003), cites studies from peer-reviewed journals e. g.

- In a study done in 1981 at the University of Melbourne, researchers compared iridology evaluations (with the help of iridologists) with known

medical histories of patients who had developed acute disease (before and after). They found that no detectable typical iris changes had occurred.

- In a study done in 1979 at the University of California by Simon *et al.*, 3 iridologists (one of whom was Bernard Jensen) and 3 ophthalmologists were asked to compare photographs of 143 patients (of whom 48 had renal disease) with creatinine levels for kidney dysfunction. The statistical significance was no more reliable than chance.

O'Mathuna (2003), in his review cites a controlled blinded study where slides were taken of 39 patients scheduled to have their gallbladders removed (disease and stones confirmed in surgery) and 39 patients with no history of gallbladder disease or stones (confirmed by ultrasound). The photographs were randomly coded and evaluated by five Dutch iridologists, the results of which was that the statistical significance was also no better than chance.

In much referenced research done by Buchanan *et al.* (1996), as an investigation of the relationship between anatomical features in the iris and systemic disease, (with reference to iridology), photographic transparencies of the irises of patients suffering from either ulcerative colitis, asthma, coronary heart disease or psoriasis were evaluated by computer image analysis and a single blind manual analysis. The irides were matched with controls of similar age and sex. The results found that disease diagnosis cannot be aided by iridology.

Another recent study found iridology of no value in the diagnosis of various common cancers, with a sensitivity of 0.04 (3/68 cases). One hundred-and-ten patients participated in the study, of which 68 had histologically proven cancers of the breast, ovary, uterus, prostate or colorectum. There were 42 control subjects. All participants were evaluated by an iridologist, who was blinded to medical history and gender. He was allowed 5 potential diagnoses (Münstedt *et al.*, 2005).

2.1.7.2 Positive Studies

In contrast, in a Romanian study on the correlation between iridology and general pathology, a high connection was found. Photographs of 57 hospitalized patients were taken, in combination with their medical records, and submitted for computerized processing. The researchers concluded that iridology can be extremely useful in the diagnosis of specific general pathology (Demea, 2002).

In another recent study by Stearn & Swanepoel (2006) by the University of Pretoria, iridology was deemed effective at diagnosing moderate to profound sensorineural hearing loss in adolescents. The controlled trial included 50 hearing impaired and 50 normal patients. The photographs were randomized and then given to an iridologist (which was blinded) for evaluation. A 70% correct identification rate was obtained, indicating a statistically significant relationship.

Finally, a systematic literature review on publications and opinions on iridology for the period from 1970 to 2005, was conducted by the University of São Paulo. Twenty-five articles were found – 1 literature review, 12 research studies and 12 updates, historical reviews or editorials. Fifteen articles were in favour of the iridological method and ten against it (Salles *et al.*, 2008).

2.2 The Iris

2.2.1 Basic Anatomy

The Oxford Medical Dictionary defines the iris as the part of the eye that forms the coloured muscular diaphragm across the front of the lens which regulates the amount of light that enters through the pupil (Martin, 2007). Anatomically, the iris, together with the ciliary body and the choroid, is found in the intermediate layer of the eye wall (as can be seen in Figure 2.6 below), which is called the vascular tunic or uvea. The uvea is sandwiched between the outer fibrous tunic and the inner neural tunic or retina (Martini, 2006).

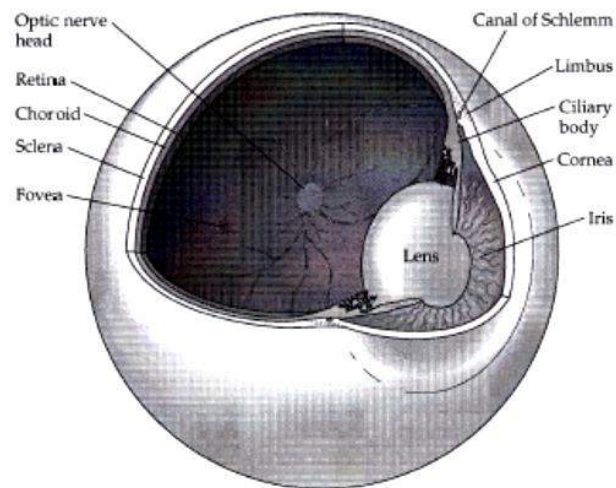


Figure 2.6: Major Structures and Regions of the Eye (Oyster, 1999)

2.2.2 Structure

2.2.2.1 Introduction

Structurally the iris is usually described as being composed of five layers of tissue, although two are not well demarcated. From anterior to posterior, the layers are: the anterior border layer, the iris stroma, the dual pupillary muscle layer (combining both the sphincter and dilator muscles) and the posterior epithelium, in that order (Oyster, 1999).

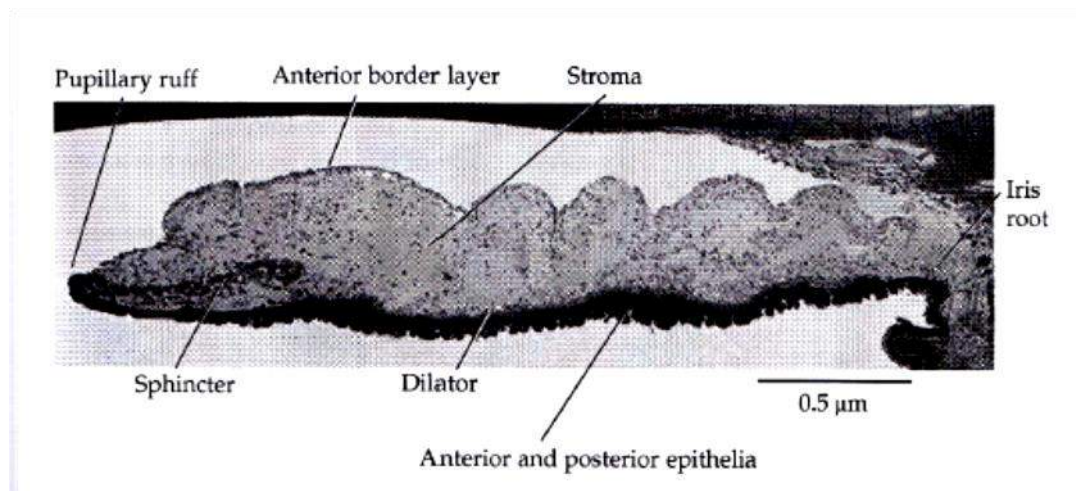


Figure 2.7: The Iris in Cross Section (Oyster, 1999)

The iris is a sheet of tissue of varying thickness as can be seen in Figure 2.7. The iris root is the junction of the iris and the ciliary body, and is the thinnest part. It is here where damage to the iris occurs most commonly during trauma, severing its attachment. The thickest part is two-thirds from iris root to pupil margin and is called the collarette, which is also the site of the minor arterial circle. It divides the iris into pupillary and ciliary regions, containing the sphincter and dilator muscles, respectively (Oyster, 1999).

2.2.2.2 The Anterior Border Layer

The first layer of the iris is the anterior border layer which is of variable texture and consistency due to its irregular arrangement of cells, predominantly melanocytes and fibroblasts, with some fine collagen fibers (Figure 2.8). The fibroblasts tend to congregate on the surface, forming a subdivision between them and the melanocytes below. This meshwork generally weaves itself in a radial fashion away from the pupil (Oyster, 1999).




Figure 2.8: The Anterior Border Layer of the Iris (Oyster, 1999)

The irregular construction of this layer is interrupted by large gaps and holes of various sizes, called the crypts of Fuchs. They are remarkable in that they vary between irises and that aqueous can flow freely from the anterior chamber to the inner stroma through them (Oyster, 1999).

Other observable features include a pupillary ruff and contraction folds. The pupillary ruff or frill is the ring of dark pigment surrounding the margin of the pupil. It is formed by the posterior epithelial layer as it folds around the inside edge of the pupil. Contraction folds are prominent circular lines that appear on the surface of the iris when the pupil is dilated (Oyster, 1999).

Iris processes are extensions of the anterior border layer that run from it to the trabecular meshwork, and are made up of cells from both layers (Oyster, 1999).

2.2.2.3 The Iris Stroma

The next layer is the body or stroma, which makes up the majority of the iris. A significant portion is basically open space filled with aqueous in vivo, while the rest consists of a loose arrangement of the same components of the previous layer (fibroblasts, melanocytes and collagen fibers). The only other important additions to this layer are blood vessels and fine nerve fibers (Oyster, 1999).

The minor arterial circle, as can be seen in Figure 2.9, is formed by small blood vessels running radially through the stroma, which branch and anastomose extensively at the collarette, and supplies the iris muscles. The arteries arise from major and intramuscular arterial circles in the ciliary body, and the veins drain through ciliary processes into the vortex veins. The arteries and veins run parallel to each other (Oyster, 1999).

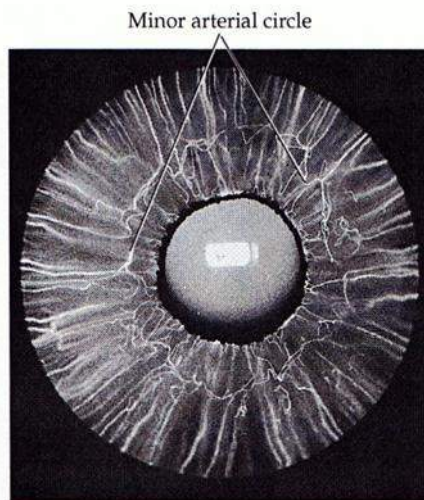


Figure 2.9: Iris Vessels and the Minor Arterial Circle (Oyster, 1999)

2.2.2.4 The Pupillary Muscular Layer

The sphincter and dilator muscles are considered together to be the pupillary muscular layer and determines the size of the pupil on contraction. The sphincter group is organized as a series of concentric rings around the pupil and innervated by the parasympathetic branch of the autonomic nervous system. The dilator group extends radially away from the edge of the pupil and is innervated by the sympathetic branch (Martini, 2006). This is clearly illustrated in Figure 2.10 below. The sphincter is substantially thicker than the dilator and the muscles are not connected, except for a few muscle fiber strands (Oyster, 1999).

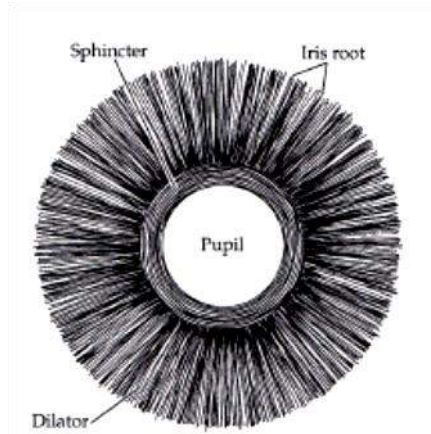


Figure 2.10: Orientation of Sphincter and Dilator Muscles (Oyster, 1999)

2.2.2.5 The Posterior Epithelium

Finally, the posterior surface of the iris is lined with two layers of epithelial cells, the anterior and posterior iris epithelia. Although both epithelial layers are pigmented, the anterior epithelium has less pigment and is myoepithelium from which the dilator muscle arises. The posterior epithelium is the major light-absorbing layer in the iris (Oyster, 1999).

2.2.3 Embryology of the Iris

2.2.3.1 Development

The eye is derived from four sources (Moore & Persaud, 2003):

1. Neuroectoderm of the brain (from which develops the retina, posterior epithelium of the iris and optic nerve)
2. Surface ectoderm of the head (lens, corneal epithelium)
3. Mesoderm between the above two layers (fibrous and vascular coats of eye)
4. Neural crest cells (choroid, sclera and corneal epithelium)

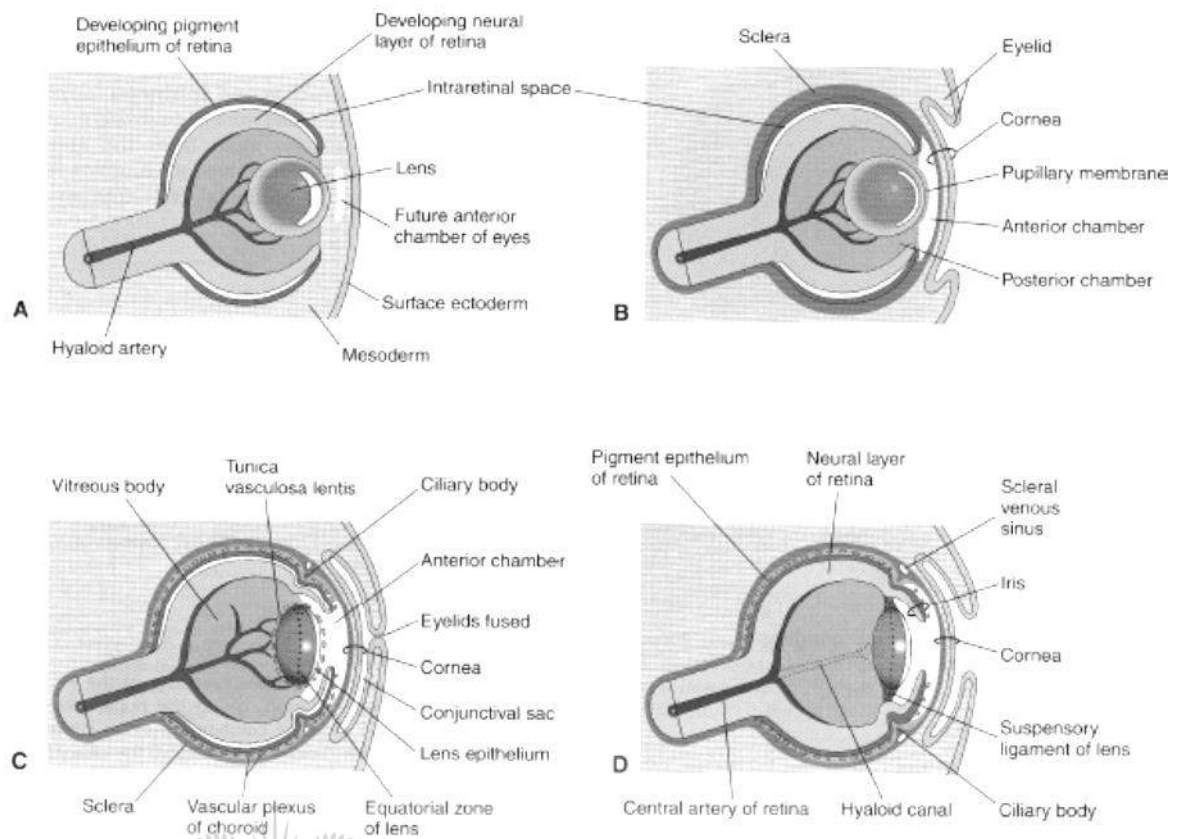


Figure 2.11: Successive Developmental Stages of the Lens, Retina, Iris and Cornea. A, 5 weeks. B, 6 weeks. C, 20 weeks. D, Newborn (Moore & Persaud, 2003).

Figure 2.11 illustrates the successive developmental stages of the eye as it develops in the embryo:

From 6 weeks the rim of the optic cup evolves inwards and incompletely covers the lens – forming the rudimental iris. Then the iris epithelium is derived from both layers of the optic cup, being a prolongation of the ciliary body’s double epithelium and the retinal pigment epithelium and neural retina. Migrated neural crest cells eventually form the connective tissue framework. The dilator and sphincter pupillae muscles are finally derived from the neuroectoderm of the optic cup appearing to stem from the anterior epithelial cells, which consequently differentiate into smooth muscle cells (Moore & Persaud, 2003).

2.2.4 Congenital Defects and Anomalies

The next section provides a brief overview of congenital defects associated specifically with the iris, and the section thereafter summarizes three anomalies frequently encountered in medical texts. For simplicity's sake a glossary of syndromes and diseases has been included on page 63 for quick reference.

Congenital disorders of the iris and cornea (iridocorneal dysgenesis) are multiple and tend to overlap significantly. Glaucoma is often but not always associated (Kanski, 1994).

2.2.4.1 Defects

Congenital and developmental defects of the iris include:

- Aniridia
- Persistent pupillary membrane (PPM)
- Coloboma
- Hypoplasia
- Subsidiary and ectopic pupils
- Heterochromia iridis and iridium
- Ectropion Uveae
- Cysts (Oyster, 1999; Yanoff & Sassani, 2009)

Congenital *aniridia* is the absence of the iris, varying from almost total to mild (Martin, 2007). It is ascribed to failure of the rim of the optic cup to proliferate (Moore & Persaud, 2007). This rare bilateral anomaly can be divided into the following four phenotypes, according to Kanski (1994):

1. With normal vision (autosomal dominant)
2. With poor vision (the result of foveal hypoplasia, also autosomal dominant)

3. With Wilms' tumour of the kidney (sporadic or deletion of part of chromosome 11)
4. With mental handicap (autosomal recessive) e.g. Crouzon's syndrome (Gold & Weingeist, 2001)

PPM is one of the most common developmental irregularities of the iris e.g. in congenital rubella (with iris hypoplasia) (Gold & Weingeist, 2001). It is the outcome of either incomplete tissue atrophy or exuberant hyperplasia. The appearance of the pupil is either distorted by strands of the post-natal remnant tissues or almost completely occluded (Yanoff & Sassani, 2009).

A **coloboma** is an otherwise normal iris with abnormal sectors or holes, giving it a key-hole appearance (Moore & Persaud, 2007), and is illustrated in Figure 2.12. It is due to unsynchronized or failed growth of the optic cup rim. It may be confined to the iris or project into the ciliary body and retina (Oyster, 1999).

A typical or simple coloboma is situated in the inferior sector of the iris (Figure 2.12a). It is commonly hereditary with autosomal dominant transmission (Moore & Persaud, 2007). Atypical colobomas occur in other sectors of the iris (Figure 2.12b) (Oyster, 1999). Syndromes associated with colobomas include: Treacher-Collins (with pupil ectopia), Hallerman-Streiff (with iris atrophy and PPM), Apert's and Carpenter's, and oculoauriculovertebral dysplasia (Gold & Weingeist, 2001).

Iris hypoplasia can be seen in Figure 2.12c. Defects may appear as an area of sparse, inadequately formed stroma and not as a total want of tissue (Oyster, 1999).

Complete or full-thickness holes extending through the iris is another developmental anomaly and is called pseudopolyopia (Kanski, 1994). It may appear as a small subsidiary pupil (Figure 2.12d) or as a break at the iris root (Figure 2.12e) (Oyster, 1999).

An *ectopic pupil* (Figure 2.12f) or corectopia is an erroneously positioned pupil in an otherwise normal iris. It is generally symmetrical and bilateral, albeit the decentralisation and direction may be markedly different between both eyes. Ectopia lentis, or the abnormal placement of the lens, is commonly associated. Any deviations from the normal iris with a central circular pupil are optically insubordinate (Oyster, 1999). Alagille’s and Treacher-Collins syndromes are commonly associated (Gold & Weingeist, 2001).

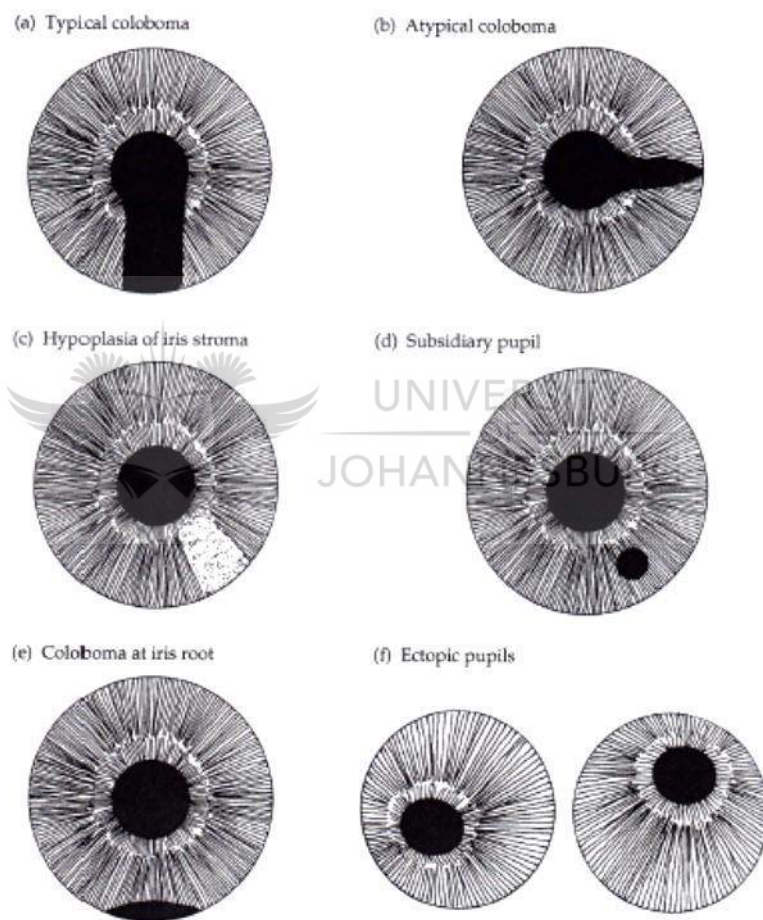


Figure 2.12: Anomalies of the Iris and Pupil (Oyster, 1999).

Heterochromia iridum is a difference in colour between two irises of the same individual. *Heterochromia iridis* is a sectoral difference in colour in the same iris (Yanoff & Sassani, 2009). Both heterochromia iridum, iridis and

hypopigmentation is encountered in Waardenburg's syndrome, for example (Gold & Weingeist, 2001).

Congenital ectropion uveae is hyperplasia of the iris pigment border (Yanoff & Sassani, 2009). This rare anomaly shows pigment on the anterior surface of the iris, with round and reactive pupils. It may be associated with neurofibromatosis type 1 (Kanski, 1994).

Congenital iris cysts or pars plicata, start as tiny out-pouchings from the epithelial layers as the iris develops (Oyster, 1999). Cysts of the iris pigment epithelium are globular, dark-brown structures which trans-illuminate (Kanski, 1994). The clinical course is usually benign and the cysts may either remain tiny or grow aberrantly for years (Yanoff & Sassani, 2009).

2.2.4.2 Anomalies

The three important anomalies according to Kanski (1994) are:

1. Axenfield's anomaly: it basically refers to the presence of a persistent pupillary membrane.
2. Reiger's anomaly: autosomal dominant, may not be symmetrical but usually affects both eyes. The signs also include PPM, with other iris (hypoplasia, pseudopolycoria) and pupil (corectopia, ectropion uvae) anomalies.
3. Peter's anomaly: autosomal dominant and also mostly bilateral. Corneal opacity is a definite characteristic, with one other feature of the following – either posterior stromal deficits, synechiae, keratolenticular adhesions, or keratolenticular strands with or without iris adhesions. Corectopia and iris hypoplasia may also be present.

In foetal alcohol syndrome (FAS) for example, anterior segment abnormalities include both Reiger's and Peter's syndrome (Gold & Weingeist, 2001).

2.2.5 Colour and Individuality

During the first 6 – 10 months of life newborn infants' irises acquire their definitive colour due to the pigmentation that occurs during this period. Most infants typically have light blue or grey irises prior. The distribution of melanin pigment determines the colour that is refracted from the iris. Pigment that is restricted to the posterior epithelium appears blue, whilst pigment that is also scattered through the stroma produces a brown effect (Moore & Persaud, 2003).

The adult eye colour spectrum ranges from pale blue through shades of grey and green to dark brown. The colour is usually the same in both eyes although small differences or different spots of colour (naevi or freckles) between irises commonly occur. Iris naevi are commonly occurring benign tumours that present as pigmented, flat or slightly elevated lesions on the outer iris. Neurofibromatosis type 1 patients are known to have an increased incidence of naevi, which are called Lisch nodules. Iris freckles are thin flat melanocytic agglomerations and smaller than naevi (Kanski, 1994). Brushfield spots (greyish-brown freckles in the iris (Martin, 2007), are found in Down's and Turner's syndromes (Gold & Weingeist, 2001).

It is speculated that the colour differences between individuals are attributed to the density and distribution of chromatophores (pigment-containing cells) as determined by their genes. Indeed, the structure and colour pattern of each individual's irises are extraordinarily unique, not unlike fingerprints (Oyster, 1999). In fact, the iris is increasingly becoming recognized as a tissue that can act as a reliable biometric for purposes of identification, due to its stability over time (Rankin *et al.*, 2010).

2.2.6 Pathologies Affecting the Appearance of the Iris

A huge number of pathologies affect the appearance of the anterior chamber and thus the iris. The following section has been subdivided into pathologies affecting structure and pathologies affecting colour. There exists considerable overlap

between these subdivisions, thus the pathologies in each group either has the main feature of structural damage or changes in pigmentation.

The list of diseases discussed below is extensive but far from complete; further elaboration is outside the scope of this study. Refer to the glossary (pp 63-70) for definitions of diseases if not provided.

2.2.6.1 Pathologies Predominantly Affecting Structure

The following section is a summary of inflammations and injuries, vascular disorders and tumours that may affect the iris, and a brief expansion on other syndromes.

Inflammations and Injuries

Iritis is inflammation of the iris. Anterior uveitis or iridocyclitis is inflammation that extends to the iris and ciliary body (both are normally involved). Uveitis is inflammation of the entire anterior compartment of the eye (Martin, 2007). The signs of acute, subacute and chronic iridocyclitis may include keratic precipitates, Koeppe and Busacca iris nodules (Koeppe – at the pupillary margin; Busacca – large nodule in mid periphery of iris), iris atrophy, anterior segment haemorrhage and ischaemia and synechiae (Boruchoff, 2001). Synechiae are adhesions or disruptions of the iris and can be posterior (iris to capsule of lens), anterior (iris to cornea) and gonio (iris to trabecular meshwork) (Boruchoff, 2001).

There are four main types of uveitis:

1. Associated with systemic disease (e.g. ankylosing spondylitis, Reiter's syndrome, psoriatic arthritis, juvenile chronic arthritis, cystinosis, sarcoidosis, Behçet's disease, Vogt-Koyonagi-Harada syndrome, AIDS, leprosy (iris pearls), syphilis).

2. Infections with bacteria (e.g. tuberculosis), fungi (e.g. candidiasis), viruses (e.g. herpes zoster), protozoans (e.g. toxoplasmosis) or roundworms (e.g. toxocariasis).
3. Idiopathic specific uveitis entities (e.g Fuch's heterochromic iridocyclitis, intermediate uveitis, juvenile chronic iridocyclitis, acute anterior uveitis in young adults, sympathetic uveitis).
4. Idiopathic non-specific entities (Kanski, 1994).

A multitude of injuries can distort the iris, including trauma to the eye (blunt or penetrative), foreign bodies and surgery. Sequelae may include iridodialysis (separation of the base of the iris), iris prolapse, iris bombe, implantation cysts, hypopyon (pus), and synechiae (Boruchoff, 2001).

Vascular disorders

Rubeosis iridis is the neovascularization of the iris vessels due to ischaemia (Martin, 2007). It is seen as abnormal engorged tortuous vessels throughout the iris, but especially at the pupillary margin (Boruchoff, 2001).

For example, arteriosclerosis of the anterior segment leads to ocular ischaemic syndrome (secondary to atherosclerotic carotid occlusive disease), which is manifested by rubeosis iridis, aqueous flare, posterior and anterior synechiae, corneal oedema and cataract (Gold & Weingeist, 2001).

Other anterior segment neovascularization vascular diseases that cause iris ischaemia due to retinal vein occlusion include diabetes mellitus, Wegener's granulomatosis and sickle-cell disease. Sequelae are atrophy, synechiae, rubeosis and glaucoma (Gold & Weingeist, 2001).

On the other side of the spectrum, disseminated intravascular coagulation (DIC) can cause haemorrhage into the iris, as can other bleeding disorders (Gold & Weingeist, 2001).

Tumours

Tumours can be epithelial, muscular, vascular, osseous, melanomatous, leukemic and lymphomatous, neural (neurofibroma, neurilemma) or secondary, either by direct extension or metastatic (Yannoff & Sassani, 2009).

Leiomyomas are very rare tumours that stem from the smooth muscle of the iris. An iris melanoma is a solitary pigmented or non-pigmented nodule with a good prognosis and comprises of 5 – 10% of uveal melanomas (Kanski, 1994).

In leukemia, the infiltration may cause observable heterochromia, with or without pseudohypopyon, and in lymphoma diffuse or localized lymphoid infiltrates may be seen with accompanying anterior segment inflammation (Kanski, 1994).

In metastatic malignant tumours, which is exceedingly rare, iris metastasis presents as a pink-yellow friable lesion that may distribute throughout the anterior chamber and mimics uveitis or endophthalmitis (Gold & Weingeist, 2001)

Other Syndromes



Other syndromes affecting the structure of the iris include: Sturge-Weber Syndrome, Marfan's syndrome, Stickler's syndrome and iridoschisis (Gold & Weingeist, 2001).

Sturge-Weber syndrome is a neuro-oculocutaneous syndrome characterized by a port-wine naevus, ipsilateral leptomeningeal angiomas and vascular malformations of the conjunctiva, episclera, choroid and retina. Iris manifestations include heterochromia iridis, melanocytic hamartomas and prominent iris processes adherent to the trabecular meshwork (Gold & Weingeist, 2001).

Marfan's syndrome also has prominent iris processes, with incomplete development of the angle structures and ciliary body, and iridodonesis (tremulousness of iris due to absence of support from the lens) (Gold & Weingeist, 2001).

Stickler's syndrome is distinguished by abnormal anterior chamber vessels, fine membranes over the trabecular meshwork and atrophic patches of the iris root either with absent iris processes, or with long thick processes (Gold & Weingeist, 2001).

Iridoschisis is a rare bilateral senile splitting of atrophic iris stroma into fibres containing blood vessels (Kanski, 1994).

2.2.6.2 Pathologies Predominantly Affecting Colour

Pigmentary Iris Degeneration

Pigmentary iris degeneration refers to acquired heterochromia of the iris. Examples of a hypochromic iris, where the involved eye becomes lighter, are: chronic Horner's syndrome, chronic iritis, Fuch's heterochromic iridocyclitis, juvenile xanthogranuloma (yellow-gray iris lesions associated with raised orange lesions, which regresses spontaneously) and metastatic cancer (Boruchoff, 2001).

Examples of a hyperchromic iris, where the involved eye becomes darker, occurs in: a diffuse naevus or melanoma, iridocorneal endothelial syndrome, iris neovascularization and siderosis (Boruchoff, 2001).

Iridocorneal Epithelial Syndromes

The iridocorneal epithelial syndromes (ICE) are made up of:

1. Essential iris atrophy (EIA)
2. Chandler's syndrome
3. Iris naevus (Cogan-Reese) syndrome (Kanski, 1994).

Their common thread is the existence of an abnormal corneal-endothelial cell layer, which has the ability to travel from the anterior chamber to the surface of the iris. Their general presentation is the development of a distorted or second pupil in a previously normal eye.

In EIA, the main feature is the development of pseudopolycoria amongst ectropion uvae, stromal atrophy and posterior synechiae formation. What distinguishes it is that the stroma of the iris between atrophies appears completely normal (Kanski, 1994).

Iris naevus syndrome is very similar to EIA, apart from the fact that a diffuse naevus spreads over the anterior of the iris. There may be iris nodules present and the normal pattern of the iris surface appears distorted (Kanski, 1994).

Chandler's syndrome falls between the other two syndromes.

Other Syndromes

Other syndromes include pigment dispersion syndrome, albinism, Chediak-Higashi syndrome, oculodermal melanocytosis and vitiligo (Gold & Weingeist, 2001).

Pigment dispersion syndrome of the iris occurs in young adult men. There is bilateral depigmentation of the iris epithelium. It is called pigment glaucoma if accompanied with glaucoma (Boruchoff, 2001).

In albinism the iris has a pale colour and transilluminates. Chediak-Higashi syndrome is a syndrome of partial oculocutaneous albinism, where the irises also transilluminate, albeit to a varying degree. In oculodermal melanocytosis, a naevus (of Ota) spreads over the iris (Gold & Weingeist, 2001).

Vitiligo also affects the uveal tract, with discrete areas of depigmentation, uveitis and atrophy of the iris pigment epithelium. (Gold & Weingeist, 2001).

2.3 The Appendix

2.3.1. Anatomy and Function

The appendix, or vermiform (worm-shaped) appendix is a blind intestinal diverticulum (6-10cm in length) that originates near the junction between the small and large intestines (Martini, 2006). More specifically, it arises from the posteromedial aspect of the caecum inferior to the ileocaecal junction. The mesoappendix is a short triangular mesentery which derives from the mesentery of the terminal ileum and attaches to the caecum and proximal part of the appendix.

The position of the appendix determines the symptoms and site of muscular spasm and tenderness when the appendix is inflamed. The position of the appendix is variable, but is usually retrocaecal – extending superiorly toward the right colic flexure - and is usually free or unattached. It occasionally lies beneath the retroperitoneal covering of the caecum, where it is often fused to the caecum or retroperitoneal wall. It may also project inferiorly toward or across the pelvic brim. The base lies deep to a point that is one-third of the way along an oblique line joining the right anterior superior iliac spine to the umbilicus (McBurney's point on the spinoumbilical line) (Moore *et al.*, 2006).

The appendix forms part of the lymphatic system of the gastro-intestinal tract (MALT – mucosa-associated lymphoid tissue) and contains a dense mass of fused lymphoid nodules (Martini, 2006).

2.3.2 Embryological Development

As can be seen in Figure 2.13, the appendix is initially a small diverticulum of the caecum, and first begins to appear in the sixth week of development. It increases rapidly in length and at birth is a relatively long tube arising from the distal end of the caecum. After birth the wall of the caecum develops disproportionately, resulting in the appendix normally twisting to the medial side, but also contributing to its considerable variation in position. As the ascending colon

elongates, the appendix may pass posterior to the caecum (retrocaecal) or colon (retrocolic). It may also descend over the brim of the pelvis (pelvic). In about 64% of people, the appendix is located retrocaecally (Moore & Persaud, 2003).

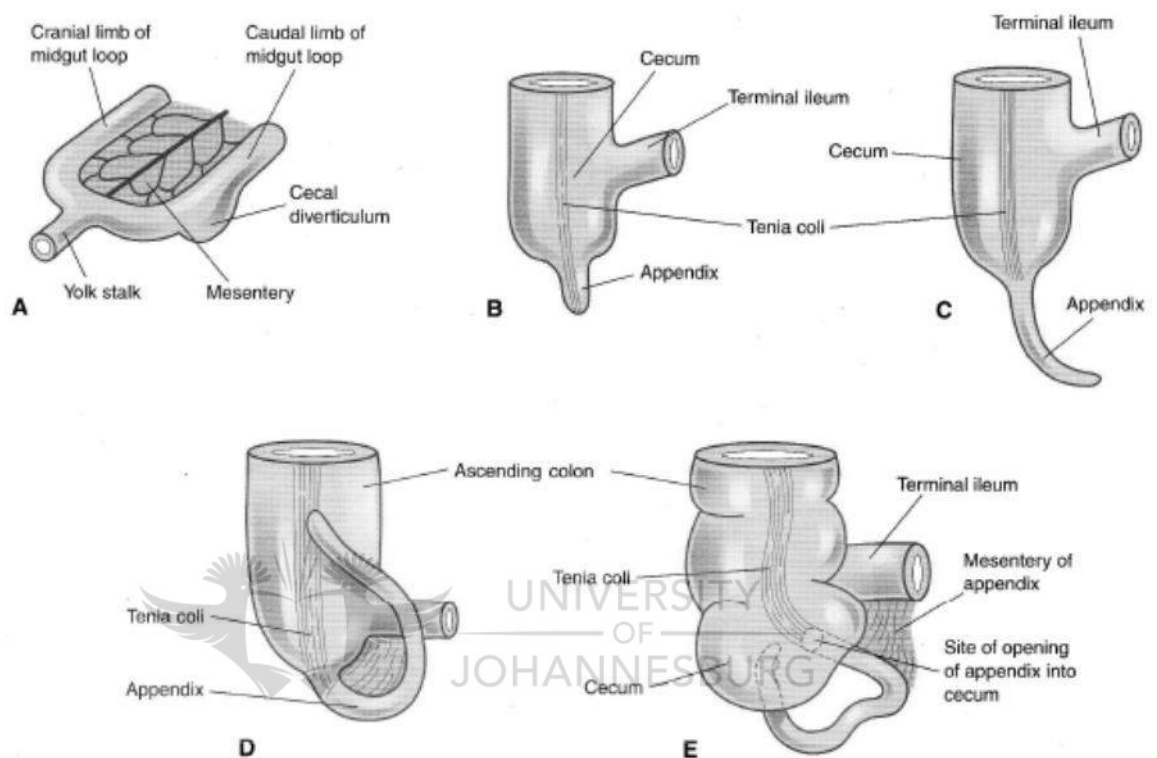


Figure 2.13: Successive Stages in the Development of the Caecum and Appendix. A, 6 weeks. B, 8 weeks. C, 12 weeks. D, At birth (Moore & Persaud, 2003).

2.3.3 Appendicitis

Appendicitis is, according to Blackbourne (2009), the inflammation of the appendix caused by obstruction of the appendiceal lumen, producing a closed loop with resultant inflammation that can lead to necrosis and perforation. The causes include lymphoid hyperplasia, faecaliths and other rare causes (for example parasites, foreign bodies or tumours). In the United States, the lifetime incidence of an acute appendicitis is approximately 7% and it is the most common cause of

emergency abdominal surgery. It can occur at any age but is most common in the teens and twenties (Beers *et al.*, 2006).

2.3.4 Diagnosis

Acute appendicitis usually presents in the following classic chronological sequence: first the patient experiences intermittent and crampy periumbilical pain (which is usually severe); second they feel nauseous and may vomit; third is anorexia; and lastly the pain moves to the right lower quadrant and becomes constant and intense within 24 hours (Blackbourne, 2009).

Classic signs are:

1. Right lower quadrant direct and rebound tenderness at McBurney's point (junction of middle and outer thirds of the line joining the umbilicus to the anterior superior iliac spine)
2. Rovsing's sign (pain on right quadrant with palpation of left lower quadrant)
3. Psoas sign (pain on extension of the right hip stretching the iliopsoas muscle)
4. Obturator sign (pain caused by passive internal rotation of the flexed thigh) (Beers *et al.*, 2006).

Unfortunately, the classic signs and symptoms of appendectomy are only present in only about 50% of patients. Low-grade fever is common and laboratory studies usually show an elevated white blood cell (WBC) count, although a normal WBC count does not exclude appendicitis. Diagnosis is clinically made and often supplemented by computerized tomography scan or ultrasound (Beers *et al.*, 2006).

2.3.5 Treatment

The treatment of acute appendicitis is with appendectomy. With early surgery, the mortality rate is less than 1%, with rapid and complete recovery. Because a delay in treatment increases the likelihood of complications (rupture, abscess or peritonitis), a negative appendectomy rate of 10% is viewed as permissible (Beers *et al.*, 2006). Surgical removal of the appendix is usually performed through a transverse or gridiron (muscle-splitting) incision centered at the McBurney point in the right lower quadrant (Moore & Dalley, 2006).

2.3.6. The Appendix and Iridology

The appendix can be found in Jensen's right iris chart (Appendix G) between 6 and 7 o'clock. As a unilateral organ, it is only found in the corresponding iris on the same side i.e. the right eye. Close inspection of the caecum and appendix areas are necessary to distinguish the origin of inflammation – in the case of appendicitis, the inflammation may extend into the abdominal wall area (Jensen, 1989). Appendicitis can manifest from the range of white (acute inflammation) to black (tissue death or necrotic) lesions in the appropriate segment. Figure 2.14 below illustrates what a potential lesion in the appendix area of the right iris may look like. Resection severs nervous relay to the iris (Jensen, 1986).

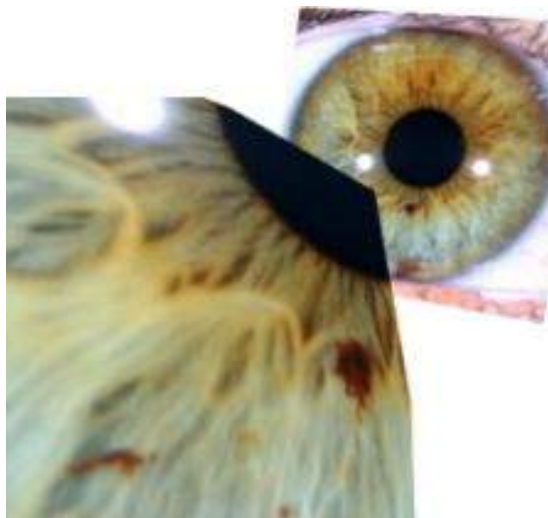

Figure 2.14: Lesion in the Appendix Area of the Right Iris (IISA, 2011).

CHAPTER 3

MATERIALS AND METHODS

3.1 Research Sample

A total of 60 participants took part in the study. Of the 60 participants, 30 were enlisted who had had an appendectomy due to acute appendicitis, and 30 with their appendix intact, with no prior history of appendicitis. All participants were recruited on the premises of Rita Frank Optometrists. Off-site permission was obtained from the University of Johannesburg (Appendix A), as well as permission from the optometric practice to use the premises, camera and to recruit from the existing extensive patient-base (Appendix B).

3.1.1 Inclusion Criteria

1. Participants were either male or female, between the ages of 18 – 65 years

The study required 30 participants who had had an appendectomy due to acute appendicitis and 30 participants with intact healthy appendices, serving as the control group.

3.1.2 Exclusion Criteria

1. Individuals who suffered from any disease that affected the appearance of the iris e.g. connective tissue disease, neurofibromatosis, benign or malignant tumours of the iris
2. Individuals who were on medication for glaucoma

3. Individuals who have had surgery on their iris
4. Individuals who suffered from bowel disorders e.g. inflammatory bowel disease (Crohn's disease, ulcerative colitis)
5. Of those who had had appendectomies, participants were excluded whom had not had the procedure done as the result of an acute appendicitis
6. Of those who had not had appendectomies, participants were excluded if they had a history of appendicitis.



3.2 Study Design

This study was a randomized and controlled quantitative study, evaluated by comparative analysis. The study aimed to establish the reliability of iridology in the diagnosis of previous acute appendicitis, as evidenced by appendectomy.

3.3 Study Procedure

3.3.1 Consultation

Each individual who met the criteria were requested to sign a Participant Information and Consent Form (Appendix E) and a Consent Form for Permission to Photograph the iris (Appendix F). Thereafter the researcher obtained the information required in a private setting at the optometrist's office (Appendix G). The photographs were then taken by the researcher.

3.3.2 Photography

Each participant's right iris was documented by photograph with the use of a specialist non-mydriatic retinal camera (Canon EOS-20D), reset for the iris, by the researcher. The digital camera is used predominantly by optometrists and ophthalmologists for retinal and anterior segment imaging. It has a 8.2 megapixel CMOS processor which allows for extremely detailed image resolution as well as image enlargement within the software parameters (Hugo, 2011). The detailed procedure is outlined in Appendix C. At least 2 photographs of each participant's right iris were taken, of which the best photograph was used for the subsequent evaluations.

Due to the nature of the camera and the quality of the photographs the iris can be minutely and thoroughly inspected for the purposes intended for by this study. The photographs were meticulously inspected by the researcher for any of the typical iride signs indicative of acute appendicitis with the aid of specialized iridology software, documenting the presence or absence thereof. The software superimposes Jensen's diagram (Appendix D) over the digital photograph, which facilitates the identification of the organ area, amongst other tools. The photographs were also given to 2 practising iridologists to evaluate.

The photographs were randomized by an external person and no identifying information was made available to the raters. All data was recorded using an Excel spreadsheet (Appendix H) and submitted for analysis.

3.4 Data Collection

Data was obtained from the analyses of the photographs wherein the absence or presence of lesions (implying acute appendicitis) was indicated by the 3 raters i.e. the researcher and 2 practising iridologists. Iridologists were remunerated for their time.

Rater 1 (the researcher) analysed the photographs with Iridology Station 5.1, which is iridology analysis and reporting software. It allows the user to manage

iridology images, overlay iridology charts and scan the iris for colour differences (Kennedy, 2007). The researcher also attended a week-long part-time basic course on iridology presented by Healing Hands International.

Rater 2 is a registered homoeopath. He completed an iridology course at the Institute of Natural Health in 2002 and has 9 years of experience. He also makes use of the Iridology Station software when analysing the iris.

Rater 3 is currently the lecturer in iridology at Healing Hands International. He completed his studies in iridology at the College of Iridology and Natural Health Sciences and has been using iridology as diagnostic tool in his naturopathic practice since 2000.

All the data captured was entered into an Excel spreadsheet (Appendix H) and sent for statistical analysis.

3.5 Validity and Reliability Measures

All the photographs were taken with the stationary, specialized camera at the optometrist's office in a reproducible and controlled environment. At least 2 photographs of each participant's right iris were taken, of which the best photograph was used for the subsequent evaluations.

The photographs were randomized by an external person. Random numbers from 1 - 60 were generated using a function in Excel and assigned to each of the 60 participants. The raters were then asked to evaluate the randomized photographs in their new numerical order (Appendix H). The raters did not know any identifying information or who had had appendectomy and thus were effectively blinded. The inclusion of a control group took into consideration the normal variations of the iris.

3.6 Ethics

This study was approved by the Higher Degrees Committee (HDC) and the Academic Ethics Committee (AEC) on the March 2011. The HDC reference number is HDC10/02-2011 and the AEC reference number is AEC13/02-2011.

Participation in the study was voluntary and by means of informed consent. All procedures were explained in detail, in the information sheet, and participants were informed of their rights. There were no risks involved in the study. The participants were told that they may ask questions at any time which was answered to the best of the researcher's ability, and that they may withdraw from the study at any time. They were ensured of the utmost privacy, and all the consultations took place in a private consultation room. Confidentiality was maintained and protected both during and after the research study by replacing names with case numbers and all case files were locked away in a secure filing cabinet. Participants had the right to anonymity and this was upheld by the researcher at all times. No identifying data was used in the research results. The results of this study were made available to all participants on request.

3.7 Statistical Analysis

The spreadsheet (Appendix H) encompassing all the data gathered was statistically analysed by Statistical Consulting Services (Gerber, 2011). The statistical tests carried out include:

- Descriptive statistics: frequency distributions of variables
- Contingency analysis (Chi-Square tests): tests for association between the rater's assessment and the outcome
- Rater agreement: measures to what extent the raters were in agreement
- Logistic regression

CHAPTER 4

RESULTS

4.1 Introduction to results

This chapter summarizes the results of this quantitative comparative study.

First is the descriptive statistics section which encompasses the frequency distributions of age, gender and eye colour of the participants; the spread of participants with and without appendectomies, and of those with appendectomies the number of years ago that the surgery was performed; as well as the spread of responses given by the researcher and both experts (the raters).

The second section shows the distribution of correct and incorrect responses given by the raters. Thereafter contingency analyses were done, with the resultant odd ratios and p-values.

The fourth section deals with the agreement statistics between the raters. Finally, logistic regression was done with the independent variables or predictors being eye colour and time lapse since appendectomy, to determine if any relationship exists with responses (correct and incorrect).

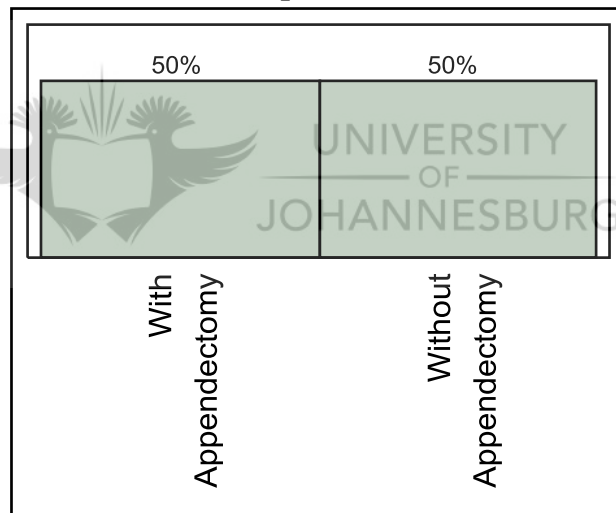
For the exact data refer to Appendices I - O attached.

4.2 Descriptive statistics

A total of 64 participants were recruited over a three week period. The majority were pre-booked patients visiting Rita Frank Optometrists for routine eye checks. The rest were either family members of patients or recruited by word of mouth (and subsequently telephonically contacted by the researcher). Of the 64, four were excluded because of the following reasons: one suffered from connective tissue disease with concomitant chronic use of corticosteroids, one had had surgery on the iris, one had had an appendectomy during a hysterectomy, and one was outside the age limit of the study.

4.2.1 Group

Diagram 4.1: Distribution of Participants With and Without Appendectomies



Participants with and without appendectomies (control group) were equally distributed, (30/30) as can be seen in the above diagram.

4.2.2 Age

Diagram 4.2: Distribution of Age of Participants

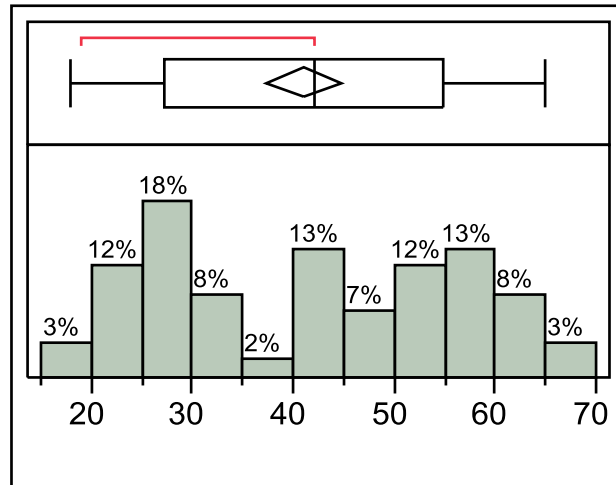
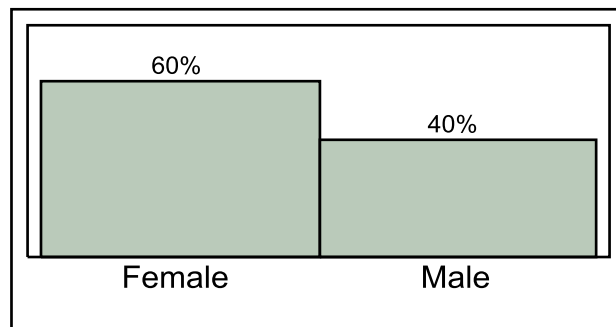


Diagram 4.2 illustrates the distribution of the age of participants. The mean age of all the participants was 40.95 years ($sd = 14.52$). The biggest percentage of participants (18%) fell in the 25 – 30 year age group.

The mean age of participants without appendectomy was 37.3 years ($sd = 13.51$) and of participants with appendectomy was 44.6 years ($sd = 14.79$).

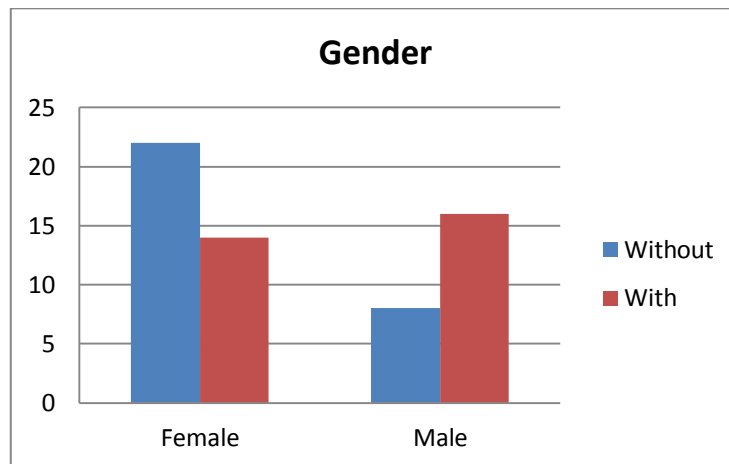
4.2.3 Gender

Diagram 4.3: Distribution of Gender between Participants



Of the participants, females constituted 60% of participants, whilst men constituted the remaining 40%, as can be seen in Diagram 4.3.

Diagram 4.4: Distribution of Gender between Groups



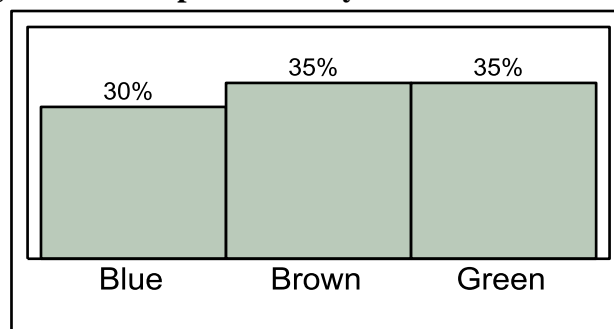
As pictured in Diagram 4.4, of the participants without appendectomy, 22 (73%) were female and 8 (27%) were male. Of the participants with appendectomy, 14 (46%) were female and 16 (52%) were male.



UNIVERSITY
OF
JOHANNESBURG

4.2.4 Eye Colour

Diagram 4.5: Proportion of Eye Colours of Participants



As can be seen in Diagram 4.5, green and brown eyes both constituted an equal proportion of participant's eye colours (35%), whilst those with blue constituted 30%, making the 3 eye colours relatively equally spread.

Diagram 4.6: Distribution of Eye Colour within Groups

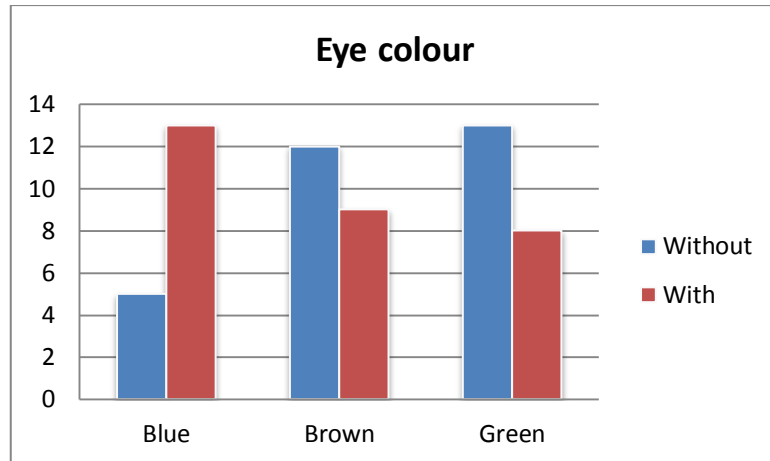
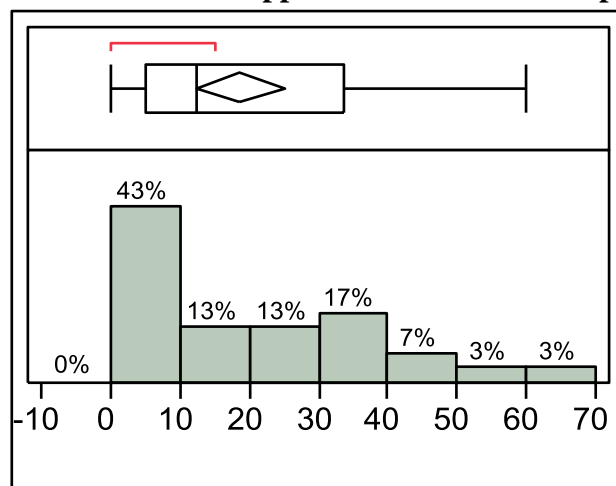


Diagram 4.6 depicts the distribution of eye colour between the two groups. Of those without appendectomy, 5 participants (17%) had blue eyes, while 12 (40%) had brown eyes and 13 (43%) had green eyes. Of those with appendectomy, 13 participants (43%) had blue eyes, 9 (30%) had brown eyes and 8 (27%) had green eyes.



4.2.5 Number of Years Ago of Appendectomy

Diagram 4.7: Distribution of Appendectomies of Participants in Years



As is seen Diagram 4.7, almost 13/30 appendectomies of participants occurred within the last 10 years (43%). The 11 – 29 years ago group constituted 26% or eight participants, and the 30+ years ago group accounted for 30% or nine


participants. The average number of years lapsed was 18.73 years since appendectomy ($sd = 17.24$ years).

4.2.6 Iride Signs

The raters were asked to evaluate randomized photographs for iride signs depicting appendectomy, noting if signs were present or absent. They did not know any identifying information or who had had appendectomy and were thus effectively blinded. They did know, however, that half of the participants were included as controls.

Rater 1 and 2

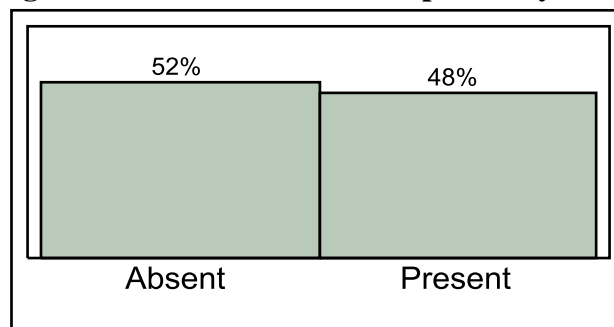
Diagram 4.8: Distribution of Responses by Rater 1



The distribution of responses by the researcher was exactly equal (Diagram 4.6), as was expected. Rater 2's distribution was identical to Rater 1's.

Rater 3

Diagram 4.9: Distribution of Responses by Rater 3

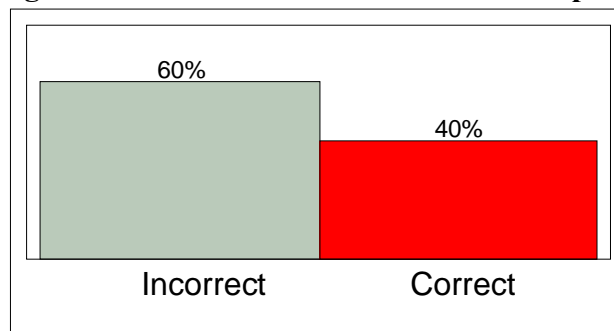


As can be seen in Diagram 4.9, the distribution of responses by Rater 3 was not equally distributed, responding as 52 % (31/60) absent iride signs and 48 % (29/60) present iride signs.

4.3 Distribution of Raters' Responses

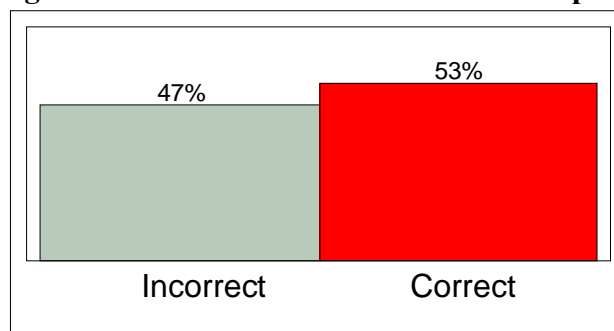
After rating, the photographs were unblinded.

Diagram 4.10: Distribution of Rater 1's Responses



The researcher i.e. Rater 1 had attended a week-long part-time basic iridology course and evaluated the photographs with assistance of iridology software (Iridology Station 5.1). Rater 1 chose 36/60 (60%) incorrect and 24/60 (40%) correct as illustrated by Diagram 4.10.

Diagram 4.11: Distribution of Rater 2's Responses



Rater 2 also evaluated the photographs with the use of the same iridology software and had 9 years of experience of using iridology in practice. He chose 28/60 (47%) incorrectly and 32/60 (53%) correctly (Diagram 4.11).

Diagram 4.12: Distribution of Rater 3's Responses

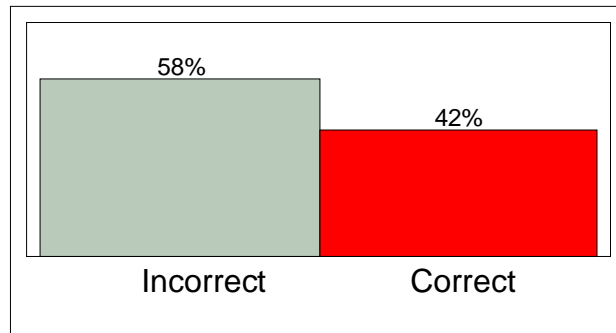


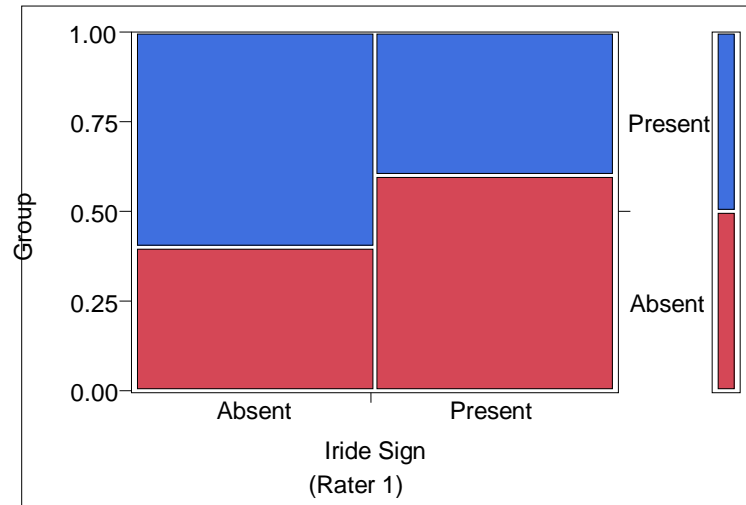
Diagram 4.12 shows that Rater 3 identified 35/60 (58%) incorrectly and 25 (42%) correctly. Rater 3 has 11 years of experience of iridology in practice and analysed the photographs without the use of software.

4.4 Contingency Analyses

To test for the association between the rater's assessment and the outcome, a Chi-Square test was used.

The Chi-Square test is used to test for association between two variables (nominal). The test only tells us whether two variables are dependent (or related), it does not say anything about the magnitude of the dependency. Statistical significance is indicated by the probability value (p-value) produced by the test (the Prob>ChiSq value in the data gives the resultant p-value). If the p-value is smaller than 0.05, then significant association exists between the variables at a 95% level of confidence (Gerber, 2011).

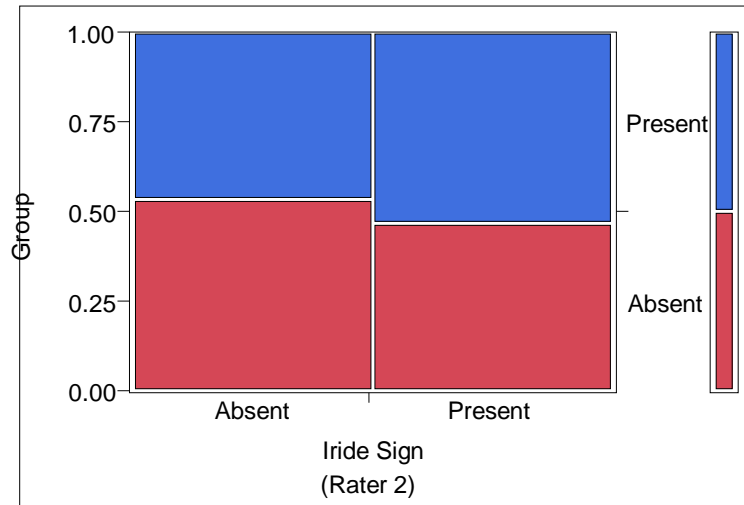
Diagram 4.13: Contingency Analysis of Groups by Iride Sign (Rater 1)



A mosaic plot is a graphical display that allows you to examine the relationship among two or more categorical variables. As is illustrated in Diagram 4.13, the probability of Rater 1 rating true (absent=absent) was 12/30 (40%). The probability for rating false (absent=present) was 18/30 or (60%). The odds ratio for being correct was 0.44, which indicates a poor probability of rating correctly.

The Chi-Square test shows if there is a significant difference between these proportions (present or absent). The values for the contingency analysis for Rater 1 was: $X^2(1, n = 60) = 2.416, p = 0.1202$; indicating that no significant association exists between Rater 1's choice and the outcome, at a 95% level of confidence.

Diagram 4.14: Contingency Analysis of Group By Iride Sign (Rater 2)



The probability of Rater 2 rating correctly was 16/30 (53%). The probability of him rating incorrectly was 14/30 (47%) (Diagram 4.14). The odds ratio was 1.3, which indicates a moderate probability of rating correct. The values generated by the contingency analysis for Rater 2 was: $X^2(1, n = 60) = 0.267, p = 0.6054$; also indicating that no significant association exists between Rater 2's choice and outcome at a 95% level of confidence.

Diagram 4.15: Contingency Analysis of Group By Iride Sign (Rater 3)

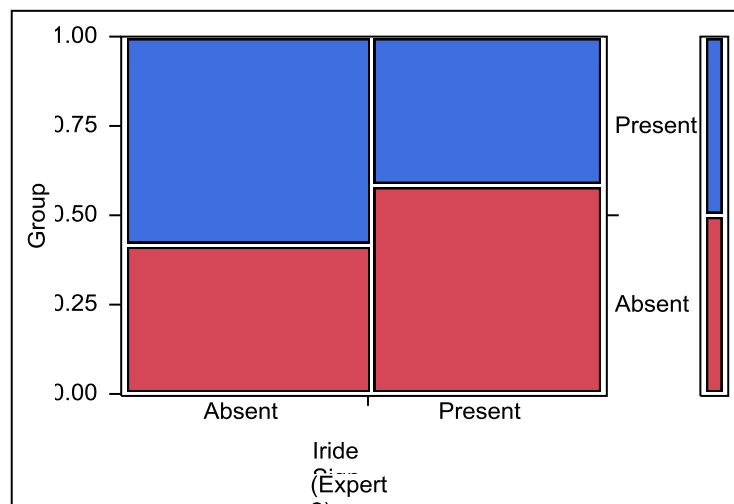


Diagram 4.15 above shows that the probability of Rater 3 rating correctly was 12.5/30 (42%). The probability of him rating incorrectly was 17.5/30 (58%). The odds ratio was 0.5, which indicates a poor probability of being correct. The values

for the contingency analysis for Rater 3 was: $X^2(1, n = 60) = 1.676, p = 0.1954$; indicating no statistical significance between Rater 3's choice and outcome at a 95% level of confidence.

4.5 Rater Agreement

Statistics were also done on the degree of agreement between raters. The p-value for the agreement between Rater 1 and Rater 2 was 0.1306, for Rater 1 and Rater 3 was 0.8527, and between Rater 2 and Rater 3 was 0.1779. All p-values were greater than 0.05, thus no agreement existed between raters.

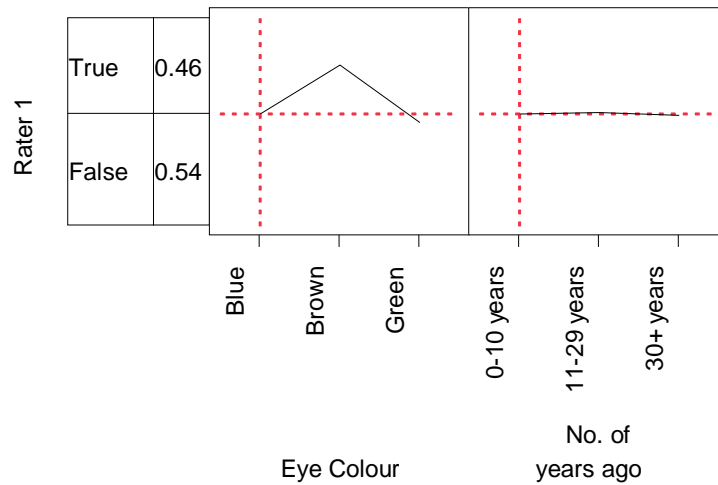
4.6 Logistic Regression

To account for other variables such as eye colour and time lapse after appendectomy, logistic regressions were done. Regression analysis is a collective name for the techniques for the modelling and analysis of numerical data consisting of values of a dependant variable (also called response variable or measurement) and of one or more independent variables (also known as explanatory variables or predictors) (Gerber, 2011).

Prediction Profiler for Eye Colour and Time Lapse

In this case the dependant variable was the correct (true) or incorrect (false) identification of iride signs with the independent variables being eye colour and time lapse after appendectomy. Thus it was determined if either eye colour or time lapse after appendectomy, or both, would have a significant impact on the outcome.

Diagram 4.16: Logistic Rater 1

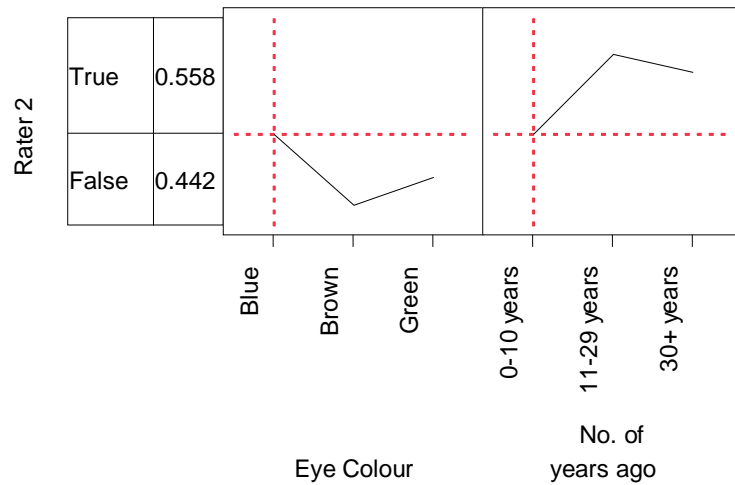


The overall values generated by the model for Rater 1 was: $X^2 (4, n = 60) = 1.8135, p = 0.77$; which indicates that the model is statistically insignificant at a 95% level of confidence. The values as shown on the left of the diagram are the probabilities of scoring true or false, respectively. The probability changes with every variable added. The time lapse in years ago was divided into 3 groups: 0 – 10 years ago, 11 - 29 years ago and 30+ years.

As can be seen in Diagram 4.16 above, Rater 1 had a better probability of scoring ‘true’ if the eye colour was brown and borderline probabilities for scoring true or false for blue and green eyes. Analysis showed that $X^2 (2, n = 60) = 1.7064, p = 0.4260$; which indicates that there was no statistical significance ($p > 0.05$) between eye colour and outcome.

The time lapse is graphically illustrated as a straight line, which indicates that no preference for any age group existed. Indeed, $X^2 (2, n = 60) = 0.0027, p = 0.9986$; indicating statistical insignificance ($p > 0.05$).

Diagram 4.17: Logistic Rater 2



Rater 2 presents us with an entirely different-looking diagram. The model had $X^2(4, n = 60) = 8.662, p = 0.0701$, which indicates a statistically insignificant relationship, although much closer to 0.05 than the previous model for Rater 1.

Rater 2 tended to score blue eyes the most correct, with the highest probability of scoring brown eyes incorrect and green eyes second. No statistical significance existed ($X^2(2, n = 60) = 3.2946, p = 0.1926$) between scoring correct and eye colour ($p > 0.05$). Interestingly, Rater 2 scored the most recent time lapse of 0 - 10 years ago the least correct, whilst scoring the 11 - 29 years ago group most correct, with a slow decline in the 30+ years ago group. The p-value for the time lapse was also statistically insignificant ($X^2(2, n = 60) = 3.375, p = 0.1850$), at a 95% level of confidence.

Diagram 4.18: Logistic Rater 3

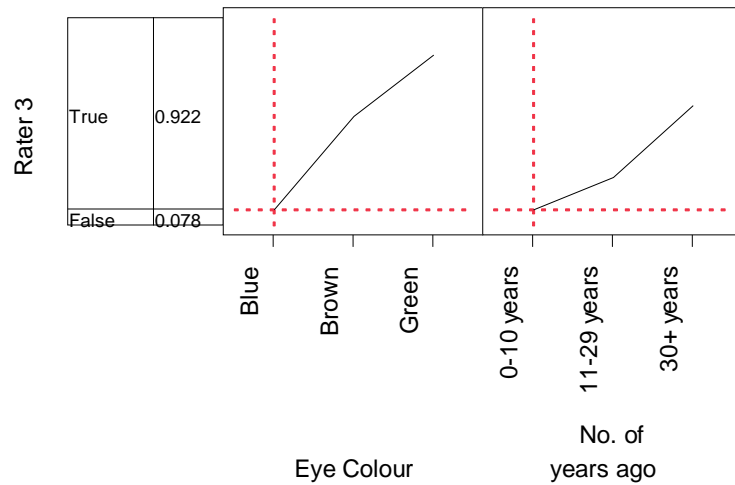


Diagram 4.18 shows the analysis for Rater 3's model was: $X^2 (4, n = 60) = 10.0194, p = 0.0401$; indicating statistical significance of the model at a confidence level of 95%. Rater 3 had the highest probability of scoring green eyes correct, followed by brown eyes and then blue eyes. Indeed, $X^2 (2, n = 60) = 9.6258, p = 0.0081$; which is statistically significant ($p < 0.05$) for scoring correct if analysing green eyes.

Under time lapse we see that the most recent group (0 -10 years ago) was least correct, following a steady incline to the 11 – 29 years ago, with a sharp incline in the 30+ years ago group. Analysis showed that $X^2 (2, n = 60) = 4.4475, p = 0.1082$; which is insignificant ($p > 0.05$).

CHAPTER 5

DISCUSSION

This study was a comparative quantitative study. The study aimed to establish the reliability of iridology in the diagnosis of previous acute appendicitis, as evidenced by appendectomy. A total of 64 participants were recruited, of which 60 took part in the study. All participants were recruited on the premises of Rita Frank Optometrists. Participants were male or female, between the ages of 18 – 65 years. Of the 64, four were excluded because of the following reasons: one suffered from connective tissue disease with concomitant chronic use of corticosteroids, one had had surgery on the iris, one had had an appendectomy during a hysterectomy, and one was outside the age limit of the study. Of the 60 remaining participants, 30 were enlisted who had had an appendectomy due to acute appendicitis, and 30 with their appendix intact with no prior history of appendicitis or any other inflammatory bowel disease. Photographs of each participant's right iris were taken by the researcher. The photographs were consequently randomized by an independent person and analysed by 3 raters who were effectively blinded.

5.1 Interpretation of Results

5.1.1 Distribution of Age and Gender

The average age of all the participants was 40.95 years ($sd = 14.52$) (Diagram 4.2). The average age of participants without appendectomy was 37.3 years ($sd = 13.51$) and of participants with appendectomy was 44.6 ($sd = 14.79$). Thus the control and experimental group were well matched for age and relatively equally spread.

Overall, females constituted 60% of the participants and men the remaining 40% (Diagram 4.3). The majority of participants without appendectomy were female,

whilst in the group with appendectomy, genders were relatively equally spread (Diagram 4.4).

From the above it is clear that there were only minor differences in the experimental and control groups in terms of age and gender, and that these differences would be unlikely to have had an effect on the results.

5.1.2 Distribution of Raters' Responses

As can be seen in section 4.3 illustrating the distribution of raters' responses, no rater had significant skill in ascertaining correctly whether or not an acute appendicitis and thus appendectomy was likely in the participant's history.

Both Rater 1 and Rater 2 made use of the same iridology software to help guide their responses, whilst Rater 3 relied solely on his experience in the field. Both Rater 2 and 3 had been practising iridology as a diagnostic tool in their practices for 9 and 11 years, respectively, whilst Rater 1 was new to the iridological method, having completed a week-long part-time basic course.

Rater 2 was the most successful scoring 53% correctly, followed by Rater 3 who scored 42% correctly and Rater 1 who only scored 40% correctly. Thus the raters overall performed poorly, with only Rater 2 scoring more than half correctly – a result more congruent with luck than certainty.

The differences in the success rates between raters were 11% between Rater 2 and Rater 3, and 13% between Rater 2 and Rater 1, respectively. One can argue that the difference between Rater 2 and 3 may be ascribed to Rater 2's use of software to assist in analysis, and that the difference between Rater 1 and 2 may be ascribed to Rater 2's experience in the field. However, both arguments are refuted when it is considered that Rater 2's relative success was still poor; after-all, Rater 3 had the most experience and performed only marginally better than the novice Rater 1, and both Rater 1 and 2 used exactly the same software.

5.1.3 Contingency analyses

Next, a more complicated model, in the form of contingency analyses (using Chi-Square tests), was done to determine the true association between rater's assessment and outcome (section 4.4).

Importantly, probabilities of being correct could be established from these models. As expected, Rater 2 had the highest probability of the raters of being correct, with an odds ratio of 1.3. This means that he was 1.3 times more likely to score correctly, or 0.7 times more likely to score incorrectly. Thus he had a moderate probability of scoring correctly.

Rater 1 had the worst probability of scoring correctly at 0.44, while Rater 3 fell between the other two at 0.5. Both these odds ratios indicate a poor probability as was expected.

Looking at the above information it would seem that Rater 2 outperformed Rater 1 and 3 significantly. Yet, looking at the p-values for raters as established by the models, another picture emerges. The p-value indicates statistical significance - in this case, between rater's choice and outcome – if it is less than 0.05. The p-value for Rater 1 was 0.1201, for Rater 2 was 0.6056 and for Rater 3 was 0.1965. Thus no statistically significant association existed for any of the raters.

This result is not surprising, given that, as stated earlier, scoring in the 50% range does not indicate a good prospect of being correct, rather an outcome subject to chance.

5.1.4 Agreement of Rater's Responses

To determine the degree of agreement between raters, or in other words, to determine the extent to which raters overlapped when scoring irises, agreement statistics were done (section 4.5).

The p-value for the agreement between Rater 1 and 2 was 0.1306, for Rater 1 and 3 was 0.8527, and between Rater 2 and 3 was 0.1779. Therefore none of the raters

scored similarly to each other and no statistically significant relationship existed at a 95% level of confidence.

What is apparent from this lack of accord is the highly individualistic approach that is employed by each rater; and that this heterogeneity is impossible to predict – an undesirable attribute for a diagnostic tool.

5.1.5 Logistic Regression

Finally, to account for other factors which may have exerted an influence on the raters' response, logistic regressions were done. Factors that were speculated could influence the way in which raters scored and therefore their outcome were eye colour and the time lapse after appendectomy.

Eye Colour

According to iridology, only two basic iris colours exist – blue and brown (Jenks, 1981). Also it is stated that it is not uncommon for eyes to change colour as treatment progresses to optimal health, for example from hazel to blue (Bamer, 1996). This is not supported by medical literature, with changes in eye colour being mainly attributed to pathology (section 2.2.6) in adulthood. Bodeen & Jensen (1992) state that blue irides are easier to analyse than brown because the iris fibers are more distinct.

Therefore it was conjectured that eye colour might influence the ease of identification of iride signs, with light eyes such as blue being the easiest to identify correctly, and brown being the most difficult. As can be seen in Diagram 4.5, the proportions of the eye colours of participants were relatively equal, with 30% blue, 35% green and 35% brown eyes. Of the participants without appendectomy, the majority had green eyes (43%), followed by brown eyes (40%) and blue eyes (17%). Of the participants with appendectomy, the majority had

blue eyes (43%), followed by brown eyes (30%) and then green eyes (27%) (Diagram 4.6).

Thus, when scoring absent for appendectomy, green eyes had a marginal advantage while blue eyes had a relative disadvantage, and when scoring present for appendectomy, blue eyes had the advantage, with other colours being relatively equal.

In the model for Rater 1 the opposite to our conjecture occurred. Rater 1 had a better probability for scoring correct if the participant's iris was brown, with poorer probabilities for scoring true outcomes with blue or green eyes. The p-value correlating eye colour and outcome was 0.4260, suggesting that no statistical association existed.

Rater 2, on the other hand, scored blue eyes more correctly, with green second and brown last. This was consistent with the proposed theory, although the p-value of 0.1926 suggested no such relationship existed.

Rater 3 tended to score green eyes the most correct, followed by brown and lastly blue eyes. The p-value generated was, in this case, statistically significant at a 95% level of confidence, at 0.0081. It seems that, at least for Rater 3, the eye colour of the participant had a significant effect on the outcome, but also not in the way that was theorized.

Time Lapse After Appendectomy

Another factor which was thought could influence the accuracy of responses was the extent of the time lapse that occurred after the appendectomy was performed. Here it was postulated that the more recent surgeries would be indicated as more obvious lesions in the iris. This was based on the notion that healing (section 2.1.5.3; Figure 2.5) may still have occurred in the iris, even though nervous relay was severed during surgery (section 2.1.6).

Forty-three percent of the appendectomies of participants occurred within the last 10 years. The 11 – 29 years ago group constituted 26%, and the 30+ years ago group accounted for 30% (Diagram 4.7). From this it can be supposed that because the more recent group constituted the majority, it was more likely to have an influence on outcome.

No raters had p-values indicating significant association between time lapse and outcome. The p-values were, for Raters 1, 2 and 3, 0.9986, 0.1850 and 0.1082, respectively. Rater 1 showed no preference for any specific group, Rater 2 scored the intermediate group more correct, whilst Rater 3 progressively scored more correct from the most recent to the largest time lapse. This was exactly the opposite of what was expected.

5.1.6 Further Discourse on the Results

The results found in this study is in accordance with other studies conducted on iridology wherein the statistical significance was also no better than chance. These included the diagnoses of gallbladder disease (O'Mathuna, 2003) and kidney disease (Simon *et al.*, 1979).

Studies conducted where no diagnostic accuracy was found included research done by Buchanan *et al.* (1996), on iridology and systemic disease, specifically ulcerative colitis, asthma, coronary heart disease and psoriasis; and a study conducted by Münstedt *et al.* (2005) on cancer diagnosis.

In all the above-mentioned studies, all the patients included in the experimental groups currently had the manifest pathology which was queried by iridological analysis. No other study, to the knowledge of the researcher, has attempted to test the theory that surgery severs the nervous feedback of the organ to the iris (Jensen, 1986).

The purpose of diagnostic testing as specified by Beers *et al.* (2006) is to help the clinician to make choices by: reducing ambiguity, making diagnoses or identifying patients who are at risk of developing occult disease. As is clear from

this study and literature, iridology as a diagnostic tool does not meet these requirements - increasing uncertainty and poorly discriminating between patients with and without disease.

The agreement of rater's responses in this study was also not statistically significant - this leads to the deduction that iridology is a maverick practice, with no accord amongst iridologists themselves.

Neither of the other two theories tested – that eye colour and time lapse may have had an effect on outcome – had the result that was expected from theory, causing the researcher to question iridological ideas.

5.1.7 Repercussions for the Homoeopathic Profession

O'Mathuna (2003) is of the opinion that iridology is ultimately harmful to the patient because of its poor efficacy. Section 2.1.3 expands on this viewpoint. As was established by the results of this study, the likelihood of generating false positives and false negatives was considerable. Although the study attempted to determine a past surgery, the correct/incorrect diagnosis of which would not significantly impact the patient, a false negative in the diagnosis of an acute appendicitis would be detrimental to the patient. Jensen and Bodeen (1992) in their book on iridology, state that inflammation of the appendix rarely necessitates its removal and can be effectively managed through timeous conservative management. This is in direct contradiction with conventional medical practice, since as was discussed in section 2.3.5 delay in treatment significantly increases the probability of complications occurring and mortality.

A false positive may prompt unwarranted stress and behaviour of the patient, not to mention the wastage of the patient's resources and unnecessary prescriptions. The treatment course of the patient may take an entirely different route that may not be in the best interest of the patient.

It is the opinion of the researcher that the association of iridology with homoeopathic practice may harm the credibility of the profession. Further

research providing concrete evidence on iridology is needed to shift it from the realm of pseudoscience to reality.

5.2 Considerations

There are several considerations to be made regarding this study. First and foremost, the study attempted to establish the reliability of iridology in the diagnosis of previous acute appendicitis, as evidenced by appendectomy – this only tests one theory that exists in iridology, namely that the surgery severs the feedback to the iris and that the lesion is effectively frozen in time (Jensen, 1986). Iridologists are in disagreement amongst themselves with this precept and there also exists a multitude of other theories pertaining to iridology that have yet to be proven or disproven.

A problem confronted with when recruiting iridologists was the lack of standardisation of training between iridologists. As was elaborated upon in section 2.1.4, training in South Africa is hugely variable and it is problematic to establish what constitutes a competent iridologist, since the training is not clearly specified or accredited.

Another issue encountered was the fact that the researcher recruited and interviewed the participants, and took and analysed the photographs. Although considerable time passed between the taking of photographs and the consequent analysis, and although the photographs were assigned new random numbers and interpreted in their new sequence without any other original identifying information, the researcher's outcome could still have been influenced, even though the researcher scored the worst among raters.

Another concern with the study was the fact that the raters knew that half of the participants were included as controls. This might have led to different scoring behaviour that might have otherwise been the case.

Lastly, consideration must always be given to the size of the study. The greater the number of participants, the greater the distribution approximates the actual population.



CHAPTER 6

CONCLUSIONS AND RECOMMENDATIONS

6.1 Conclusions

This study was designed to assess the reliability of iridology in the diagnosis of previous acute appendicitis, as evidenced by appendectomy. It was hypothesized that an appendectomy due to previous acute appendicitis would be represented by the typical lesion in the iris.

None of the 3 raters showed a significant success rate in determining correctly who had had previous acute appendicitis or who had not. These outcomes indicated an outcome that was subject to chance. The fact that there was noticeable variability in each rater's response compounded the supposition that choices were random.

These results suggest that the null hypothesis that states that appendectomy due to acute appendicitis does not manifest in a corresponding lesion in the typical organ area of the eye, is supported. It is the opinion of the researcher that the association of iridology with homoeopathic practice may harm the credibility of the profession and that further research on iridology is needed to disprove this conviction.

6.2 Recommendations

Recommendations for future studies of this nature include:

- Testing the reliability of iridology in the diagnosis of acute appendicitis, prior to surgery
- Testing the reliability of iridology in cases of surgery of other organs
- Limiting the study to one eye colour e.g. green

- Withholding the proportions of control and experimental groups from evaluators
- Appointing different persons to take photographs and analyse photographs
- Increasing the sample size



GLOSSARY

DEFINITIONS OF DISEASES

(all definitions are according to the Oxford Concise Colour Medical Dictionary (Martin, 2007), reproduced with permission from the Oxford University Press, unless stated otherwise)

AIDS (Acquired immune deficiency syndrome): a syndrome caused by infection with the Human Immuno-deficiency Virus (HIV), which is sexually transmitted. HIV attacks and destroys CD4 lymphocytes, weakening the immune system.

Alagille syndrome (arteriohepatic dysplasia): an autosomal dominant hepatic disease in which the bile ducts become progressively smaller, causing prolonged neonatal jaundice. It is associated with abnormalities of other organs, such as the heart, kidneys, eyes and spine.

Albinism: the inherited absence of pigmentation in the skin, hair, and eyes, resulting in white hair and pink skin and eyes. The pink colour is produced by blood in underlying blood vessels. Ocular signs are reduced visual acuity, sensitivity to light and nystagmus.

Ankylosing spondylitis: a sero-negative arthritis predominantly affecting young adult Caucasian males. The inflammation affects the joint capsules and their attached ligaments and tendons, principally the intervertebral joints and sacroiliac joints. The disorder may lead to severe deformities of the spine and hip joint.

Apert's syndrome (acrocephalosyndactyly): a hereditary disorder characterized by craniosynostosis, underdevelopment of the midfacial tissues resulting in a sunken facial appearance, and syndactyly (fusion) of 2-5 digits (mitten glove). Variable mental retardation and cleft palate commonly result. The condition may be associated with Crouzon's syndrome, in which case the fusion of the digits is less marked.

Arteriosclerosis: an imprecise term used for any of the several conditions affecting the arteries.

Behçet's disease: a recurrent multisystem disease characterized by aphthous ulcers in the mouth, genital ulcers, severe inflammation of the iris and other parts of the uveal tract of the eye, and retrobulbar neuritis. It may also involve the joints and cause inflammation of the veins; skin lesions occur in the majority of patients. The condition, the cause of which is unknown, occurs more often in men than in women.

Candidiasis: a common yeast infection of the moist areas of the body, usually caused by *Candida albicans*. It may develop in those receiving broad spectrum antibiotics as well as in those who are immune-compromised.

Carpenter's syndrome: premature closure of sutures leading to cranial, orbital, and skeletal deformities with occasional coloboma of the iris and choroid.

Chediak-Higashi syndrome: a genetic disorder inherited as an autosomal recessive and characterized by partial albinism, abnormal granules in the white blood cells, and marked susceptibility to bacterial infections (Medlineplus, 2011).

Crouzon syndrome (craniofacial dysostosis): a genetic disorder characterized by premature fusion of the skull sutures, leading to a distortion in the shape of the head. It is a generalized form of craniosynostosis, with a wide skull, high forehead, widely spaced eyes (ocular hypertelorism) and exophthalmos. *See also Apert syndrome.*

Cystinosis: an inborn defect in the metabolism of amino acids, leading to abnormal accumulation of the amino acid cysteine in the blood, kidneys and lymphatic system.

Diabetes mellitus: a disorder of carbohydrate metabolism in which sugars in the body are not oxidized to produce energy due to a lack of the pancreatic hormone insulin.

DIC (disseminated intravascular coagulation): a condition resulting from overstimulation of the blood-clotting mechanisms in response to disease or injury, such as severe infection, malignancy, acute leukemia, burns, severe trauma, or severe haemorrhage during childbirth. The overstimulation results in generalized blood coagulation and excessive consumption of coagulation factors. The resulting deficiency of these may lead to spontaneous bleeding.

Down's syndrome: a condition resulting from a chromosomal abnormality most commonly due to the presence of three copies of chromosome 21, which is most likely to occur with advanced maternal age. Affected individuals share certain clinical features, including a characteristic flat facial appearance with slanting eyes, broad hands with short fingers and a single crease along the palm, malformed ears, eyes with speckled iris, short stature and hypotonia. Many individuals also have a degree of mental retardation, although the range of ability is wide and some individuals are of normal intelligence. The incidence of congenital heart defects is 40-50%, and other structural malformations and associated abnormalities (e.g. deafness, squints, obesity, type 2 diabetes) may also be present.

Foetal alcohol syndrome (FAS): a condition of newborn babies that results from the toxic effects on the foetus of maternal alcohol abuse. Babies have a low birth weight and growth is retarded: there may be head and facial abnormalities and possibly mental retardation. The greater the alcohol abuse, the more severe the manifestations.

Fuch's heterochromic iridocyclitis: a condition characterized by chronic low-grade inflammation of the ciliary body and iris (anterior uveitis) affecting one eye and depigmentation of the affected iris. Glaucoma and cataract can develop in the affected eye.

Glaucoma: a condition in which loss of vision occurs because of an abnormally high pressure in the eye. In most cases there is no other ocular disease.

Hallerman-Streiff syndrome (oculomandibulodyscephaly): a congenital disorder that affects growth, cranial development, hair growth and dental development (Quercia, 2002).

Herpes zoster (shingles): is caused by the varicella-zoster virus which also causes chickenpox. Following an attack of chickenpox, the virus lies dormant in the dorsal root ganglia of the spinal cord. Later, under one of a number of influences, the virus migrates down the sensory nerve to affect one or more dermatomes on the skin in a band, causing the characteristic shingles blistering rash. One side of the face or an eye (ophthalmic zoster) may be involved. Shingles may be chronically painful (post-herpetic neuralgia), especially in the elderly.

Horner's syndrome: a syndrome consisting of a constricted pupil, drooping of the upper eyelid (ptosis) and an absence of sweating over the affected side of the face. The symptoms are due to a disorder of the sympathetic nerves in the brainstem or cervical region.

Juvenile chronic arthritis (JCA, Still's disease): any one of a group of conditions characterized by inflammation of the joints lasting longer than 6 weeks and occurring before the age of 16. The causes are unknown but immunological and infective mechanisms are suspected.

Juvenile xanthogranuloma: a form of histiocytosis, classified as non-Langerhans cell histiocytosis. Non-X histiocytoses are a clinically well-defined group of cutaneous syndromes characterized by infiltrates of monocytes/macrophages, as opposed to X-type histiocytoses in which the infiltrates contain Langerhans cells (Medical Dictionary Online, 2011).

Leprosy (Hansen's disease): a chronic disease, caused by the bacterium *Mycobacterium leprae*, that affects the skin, mucous membranes and nerves. It is confined mainly to the tropics and transmitted by direct contact. After an incubation period of 1-30 years, symptoms develop gradually and mainly involve the skin and nerves. Lepromatous leprosy is a contagious steadily progressive form of the disease characterized by the development of widely distributed lumps on the skin, thickening of skin and nerves, and in severe cases by severe

numbness of the skin, muscle weakness and paralysis, which leads to disfigurement and deformity.

Leukemia: any one of a group of malignant diseases in which the bone marrow and other blood-forming organs produce increased numbers of certain types of white blood cells (leukocytes). Overproduction of these white blood cells, which are immature or abnormal forms, suppresses the production of normal white cells, red cells, and platelets. This leads to increased susceptibility to infection (due to neutropenia), anaemia, and bleeding (due to thrombocytopenia). Other symptoms include enlargement of the spleen, liver and lymph nodes.

Marfan's syndrome: an inherited disorder of the connective tissue characterized by excessive tallness, abnormally long and slender fingers and toes, heart defects and partial dislocation of the lenses of the eye.

Neurofibromatosis: either of two hereditary conditions inherited as autosomal dominant traits and characterized by benign tumours growing from the fibrous coverings of the eyes.

Oculoauriculovertebral (OAV) dysplasia (Goldenhar syndrome): Congenital malformation of the jaw, cheek and ear associated with vertebral defects. There is deformity of the external ear and abnormal smallness of that half of the face. Coloboma (cleft) of the upper eyelid is frequent. These features represent problems that occurred in the development of structures known as the first and second branchial archs during embryonic life. Most of the children with the disorder are of normal intelligence (MedicineNet, 2011).

Oculodermal melanocytosis (Nevus of Ota): A macular lesion on the side of the face, involving the conjunctiva and lids, as well as the adjacent facial skin, sclera, ocular muscles, and periosteum. Histological features vary from those of a mongolian spot to those of a blue nevus (Medical Dictionary Online, 2011).

Psoriatic arthritis: arthritis associated with psoriasis. It occurs in only a small minority of patients with psoriasis but may be painful and disabling. It often

affects the small joints, such as the terminal joints of the fingers and toes, or the spine and sacroiliac joints.

Reiter's syndrome: a condition characterized by inflammation of the urethra, conjunctivitis and polyarthritis, usually affecting young men. Horny areas develop on the skin. No causative agent has been positively identified, although a virus may be implicated.

Rubella (German measles): a mild highly contagious virus infection, mainly of childhood, causing enlargement of lymph nodes in the neck and widespread pink rash.

Sarcoidosis (Boeck's disease): a chronic disorder of unknown cause in which the lymph nodes in many parts of the body are enlarged and small fleshy nodules develop in the lungs, liver and spleen. The skin, nervous system, eyes, and salivary glands are also commonly affected, and the condition has features similar to tuberculosis. Recovery is complete with minimal after-effects in two-thirds of all cases.

Sickle-cell disease (drepanocytosis): a recessive hereditary blood disease that mainly affects people of African ancestry. It is characterized by the production of an abnormal type of haemoglobin which precipitates in the red cells when the blood is deprived of oxygen, forming crystals that distort the cells into the characteristic sickle shape: this process is known as sickling. Sickle-cells are rapidly removed from the circulation, leading to jaundice and anaemia.

Siderosis: the deposition of iron oxide dust in the lungs, occurring in iron finishers, arc welders, and haematite miners. Iron oxide itself is inert, but pulmonary fibrosis may develop if fibrogenic dusts such as silica are also inhaled.

Stickler syndrome: a variable disorder of connective tissue involving the skeleton, face, and eyes that is characterized by myopia, retinal detachment, cleft palate, micrognathia, flat facies, premature arthritis, hip deformity, and hyperextensibility of the large joints and that is inherited as an autosomal dominant trait (Medlineplus, 2011).

Syphilis: a sexually transmitted disease caused by the bacterium *Treponema pallidum*, resulting in the formation of lesions throughout the body. The primary symptom – a hard painless ulcer (chancre) at the site of infection – forms 2-4 weeks after exposure. Neighbouring lymph nodes enlarge about 2 weeks later. Secondary stage symptoms appear about two months after infection and include fever, malaise, general enlargement of lymph nodes and a faint red rash on the chest that persists for 1-2 weeks. After months, or years, the disease enters its tertiary stage with widespread formation of tumour-like masses (gummas). Tertiary syphilis may cause serious damage to the heart and blood vessels or the brain and spinal cord, resulting in tabes dorsalis, blindness and general paralysis of the insane.

Toxocariasis (visceral larva migrans): an infestation with the larvae of the dog and cat roundworms, *Toxocara canis* and *T.cati*. humans, who are not normal hosts, become infected on swallowing eggs of *Toxocara* present on hands or in food and drink contaminated with the faeces of infected domestic pets. The larvae, which migrate around the body, cause destruction in various tissues; the liver becomes enlarged and lungs inflamed. Symptoms may include fever, joint and muscle pains, vomiting, an irritating rash and convulsions. Larvae can also lodge in the retina of the eye where they cause inflammation and granuloma. The disease primarily affects children.

Toxoplasmosis: the disease of mammals and birds caused by the protozoan *Toxoplasma gondii*, which is transmitted to humans through ingesting undercooked meat or cat faeces. Generally symptoms are mild (swollen lymph nodes and an influenza-like illness), but can be serious in immunocompromised patients.

Treacher Collins syndrome (mandibulofacial dysostosis): a hereditary disorder of facial development. It is characterized by underdevelopment of the jaw and zygomatic bones and the precursors of the ear fail to develop, which results in a variety of ear and facial malformations.

Tuberculosis: an infectious disease caused by the bacillus *Mycobacterium tuberculosis* and characterized by the formation of nodular lesions (tubercles) in the tissues.

Turner's syndrome (gonadal dysgenesis): a genetic defect in women in which there is only one X chromosome instead of the usual two. Affected women are infertile: they have female external genitalia but their ovaries fail to develop normally, resulting in the absence of menstrual periods. Characteristically they are short and have variable developmental defects, which may include webbing of the neck.

Vitiligo: a common disorder in which symmetrical white or pale macules appear on the skin. It affects all races, but is more conspicuous in dark-skinned races. It is an autoimmune disease and may occur with other diseases (e.g. thyroid disease or alopecia areata). It is usually progressive, although spontaneous repigmentation may occur.

Vogt-Koyanagi-Harada (VKH) syndrome (uveodermatologic syndrome): is a condition involving various melanocyte-containing organs, characterized by uveitis (inflammation of the inside of the eye), poliosis (whitening of hair), vitiligo (loss of pigment in the skin), and meningitis.

Waardenburg's syndrome: autosomal dominant form of deafness accompanied by a characteristic white forelock of hair and multiple colours within the iris of the eyes.

Wegener's granulomatosis: an autoimmune disease predominantly affecting the nasal passages, lungs and kidneys, characterized by granuloma formation in addition to arteritis.

Wilms' tumour (Aniridia syndrome, nephroblastoma): a malignant tumour arising from the embryonic kidney and occurring in young children. In some children it is associated with an abnormality of chromosome 13; in these cases other features, such as aniridia and hemihypertrophy, are present.

REFERENCES

Australian Doctor (2003). *Skeptics*. Academic OneFile. Available from: <http://www.gale.cengage.com/PeriodicalSolutions/academicOnefile.htm> (Accessed 11 September 2010).

Bamer, D., R. (1996). *Practical Iridology and Sclerology*. Utah: Woodland Publishing, pp33, 54-66.

Beers, M. H., Porter, R. S., Jones, T. V., Kaplan, J. L., Berkwits, M. (Editors). (2006). *The Merck Manual of Diagnosis and Therapy*, USA: Merck Research Laboratories, pp101-102.



Bodeen D. V., Jensen, B. (1992). *Visions of Health: Understanding Iridology*. USA: Avery, pp56-58.

Boruchoff, S. A. (2001). *Anterior Segment Disease: A Diagnostic Color Atlas*. United States of America: Butterworth-Heinemann, pp12-33.

Blackbourne, L. H. (2009). *Surgical Recall*. 5th Edition. United States of America: Lippincott Williams & Wilkins, pp88-89.


Buchanan, T. J., Sutherland, C. J., Strettle, R. J., Terrell, T. J., Pewsey, A. (1996). An Investigation of the relationship between anatomical features in the iris and

systemic disease, with reference to iridology. *Complementary Therapies in Medicine*, 4(2): 98-102.

Demea, S. (2002). Correlation between iridology and general pathology. *Oftalmologia*, 55(4): 64-69.

Ernst, E. (2000). Iridology: not useful and potentially harmful. *Archives of Ophthalmology*, 118(1): 120-121.

Gerber, H. (2011). Statistical Consulting Services. Personal Discussion, 1 September. (+27 83 229 9993), (email: hjgerber@statisticalservices.co.za) Available at: <http://www.statisticalservices.co.za>.



Gold, D. H., Weingeist, T. A. (2001). Eds. *Color Atlas of the Eye in Systemic Disease*. Philadelphia: Lippincott Williams & Wilkins, pp63, 168, 277, 292, 415, 498, 544, 582, 594, 623.

Hugo, S. (2011). Personal communication via email. Johannesburg: Genop Holdings (Pty) Ltd. (email: stephenh@genop.co.za).

IISA. (2011). Iridology Institute of Southern Africa. Available from: <http://www.iridology.co.za> (Accessed 1 October 2011).

Jenks, J. D. (1981). *The Eyes Have It: An Introduction To Iridology*. USA: J. D. Jenks, pp5 - 14.

Jensen. D. C. (1982). *Iridology: Science and Practice in the Healing Arts*. Volume 2. California: Bernard Jensen Enterprises, p21, 37-39.

Jensen. D. C. (1986). *The Science and Practice of Iridology*. 16th Edition. California: Bernard Jensen Enterprises, p135, 352.

Kanski, J. J. (1994). *Clinical Ophthalmology: A Systematic Approach*. 3rd Ed. Oxford: Butterworth-Heinemann, pp151-200, 207-210 226-272.

Kennedy, S. R. (2007). *Iridology Station 5.1: Iridology Studio and Browser*. Australia: Iris Supplies. Available from: <http://iris-supplies.com.au> (23 August 2011).

Kerschbaumer, F. (2010). Iridology Institute of Southern Africa. Personal communication via telephone, November 2010. (+27 82 552 9066), (email: info@iridology.co.za).

Kriege, T., Priest, A. W. (1977). *Fundamental Basis of Irisdiagnosis*. Great Britain: Camelot Press Limited, pp14-19.

Martin, E. A. (Editor) (2007). *Oxford Concise Colour Medical Dictionary*. 4th Ed. Oxford: Oxford University Press.

Martini, F. H. (2006). *Fundamentals of Anatomy & Physiology*. 7th Ed. San Francisco: Pearson Education, pp554 -562, 770, 897.

Medical Dictionary Online (2011). Available from: <http://www.online-medical-dictionary.org/> (Accessed 27 October 2011).

MedicineNet (2011). Available from: <http://www.medicinenet.com> (Accessed 27 October 2011).

Medlineplus (2011). *Medical Dictionary*. Available from: <http://www.nlm.nih.gov/medlineplus/mplusdictionary.html> (Accessed 27 October 2011).

Medow, N.B. (2000). Iridology uses marks on iris as windows to diagnosis. *Ophthalmology Times*, 25(8): 22-24.

Moore, K. L., Dalley, A. F. (2006). *Clinically Oriented Anatomy*. 5th Ed. USA: Lippincott Williams & Wilkins, pp271-277, 964-968.

Moore, K. L., Persaud, T. V. N. (2003). *The Developing Human: Clinically Oriented Embryology*. 7th Ed. China: Saunders Elsevier, pp268-273, 466, 471-472.

Münstedt, K., El-Safadi, S., Brück, F., Zygmunt, M., Hackethal, A., Tinneberg, H. (2005). Can Iridology Detect Susceptibility to Cancer? A Prospective Case-Controlled Study. *The Journal of Alternative and Complementary Medicine*. 11(3): 515-519.

Naidoo, S. (2010). *Patient Consent to Clinical Photography and Video Recordings*. Department of Community Health, UWC.

NCCAM (2008). Iridology. *National Center for Complementary or Alternative Medicine*. Available from:
<http://www.gale.cengage.com/PeriodicalSolutions/academicOnefile.htm>
(Accessed 11 September 2010).

Norn, M. (2003). Analysis of the iris: history and future. (Abstract). *Dansk Medicinhistorisk Arbog*, pp103-117.

O'Mathuna, D. P. (2003). Iridology as a Diagnostic Tool. *Alternative Medicine Alert*. Available from
<http://www.gale.cengage.com/PeriodicalSolutions/academicOnefile.htm>
(Accessed 11 September 2010).

Oyster, C. W. (1999). *The Human Eye: Structure and Function*. USA: Sinauer Associates, Inc, pp411-446.

Quercia, N. (2002). Gale Encyclopedia of Genetic Disorders, Part 1. Available from: <http://www.healthline.com> (Accessed 27 October 2011).

Rankin, D. M., Scotney, B. W, Morrow, P., McDowell, D. R., Pierscionek, B, K. (2010). Dynamic Iris Biometry: a technique for enhanced identification. *BMC Research Notes*, 3:182.

Rostovsky, J. D., Saunders, B., Gower, N. (2009). *A Survey to Investigate the Current Perceptions of Graduates of the University of Johannesburg M. Tech: Homoeopathy Programme and a Training Needs Analysis for Continued Professional Development*. Unpublished dissertation. Johannesburg: University of Johannesburg.

Salles L. F., Silva, M. J. (2008). Iridology: a systematic review. *Revista Da Escola De Enfermagem Da USP*, 42(3): 596-600. Simon, A., Worthen, D. M., Mitas, J. A. (1979). An evaluation of iridology. *JAMA: The Journal of The American Medical Association*. Vol. 242 (13), pp1385-9.

Simon, A., Worthen, D. M., Mitas, J. A. (1979). An evaluation of iridology. *JAMA: The Journal of The American Medical Association*. Vol. 242 (13), pp1385-9.



Snyman, T. (2002). Class notes. *Institute of Natural Health Academy*.

Stearn, N., Swanepoel, D. W. (2006). Identifying hearing loss by means of iridology. *African Journal of Traditional, Complementary, and Alternative Medicines*, 4(2): 205-210.

Yannoff, M., Sassani, J. W. (2009). *Ocular Pathology*. 6th Ed. China: Mosby Elsevier, pp333-359.

APPENDIX A

Off-site Permission

From: Snyman, Ria

Sent: 13 June 2011 11:02 AM

To: Ferreira, Jannie; Cc: Razlog, Radmila

Subject: L FRANK; Importance: High

Dear Prof Ferreira,

This is to inform you that the student's request to conduct research outside UJ, has been approved at the meeting held on Thursday, 26 May 2011.



Regards

Ria Snyman

University of Johannesburg

Faculty of Health Sciences

Research Office

APPENDIX B

Permission obtained from Rita Frank Optometrists

RITA FRANK OOGKUNDIGES

Tel (061) 222656, Fax (061) 223575, P.O.Box 21019 Windhoek

Bismarckstreet 47, E-Mail: frankr@ritafrank.com.na

27 – 03 – 2011

To the Dean of the Faculty of Health Sciences at the University of Johannesburg.

Dear Professor

I, Rita Frank, sole proprietor of Rita Frank Optometrist (practice no. 0700007009437), hereby give Lora Frank (student no. 200677068) permission to advertise for the study that she will be conducting on the reliability of iridology in the diagnosis of previous acute appendicitis, as evidenced by appendectomy, at my practice.

I also grant full access to the premises and to the Canon EOS-20D for the photographic purposes as required by the aforementioned study.

This practice has been in existence for 27 years and currently employs, apart from myself, 3 more South African qualified optometrists. As a result the practice has a large and varied patient base which will facilitate the kind of research envisaged by the student.

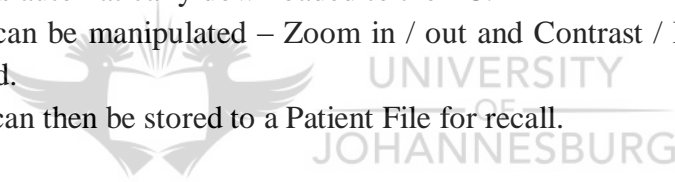
Kind Regards

Rita Frank

APPENDIX C

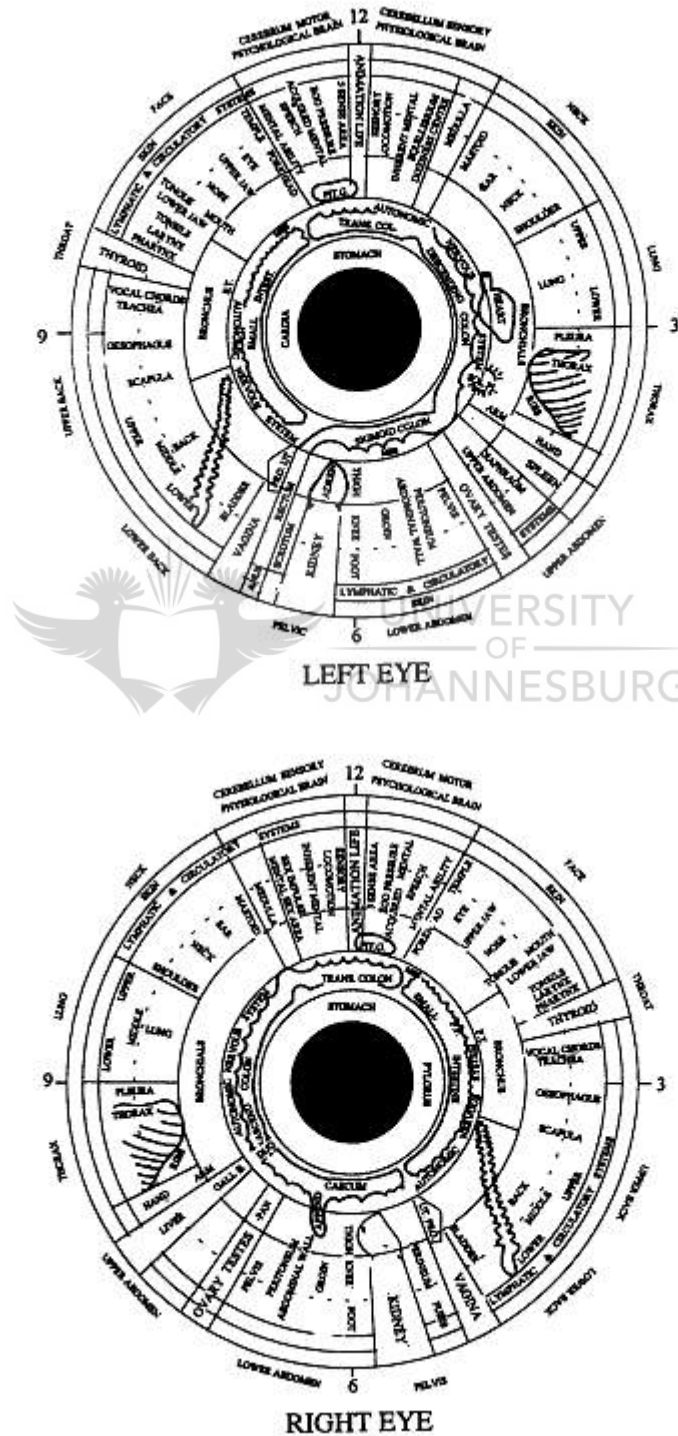
Operating procedure for taking anterior segment photography with the Canon EOS-20D digital camera (Hugo, 2011)

1. Place patient comfortably behind chinrest on Canon Non-mydratic Retinal camera.
2. Align patient's eyes with Canthus marker to ensure easy minimal adjustment with Retinal Camera Joystick.
3. Ensure patient's forehead is 2cm away from Forehead Rest.
4. Ask patient to fixate on the Fixation lamp within Retinal camera.
5. Ensure that the Computer is running and the Retinal Imaging software programme is running.
6. Introduce the Plus Accessory Lens.
7. Introduce the Alignment Lens
8. Focus the Iris Image to be taken on the TV monitor by moving the joystick Left / Right and up / down.
9. Once Image is in optimum Focus, Press the Trigger Button.
10. Image is automatically downloaded to the PC.
11. Image can be manipulated – Zoom in / out and Contrast / Brightness can be adjusted.
12. Image can then be stored to a Patient File for recall.



APPENDIX D

An iris chart showing the topographical relationship of the iris to organs of the body according to Bernard Jensen (Buchanan *et al.*, 1996).



APPENDIX E

Participant Information and Consent Form

Dear Prospective Participant

My name is Lora Frank and I am a Master's student of Homoeopathy at the University of Johannesburg. As part of my qualification it is required to undertake research on a subject of interest, and I intend to determine the efficacy of Iridology as a diagnostic tool.

Iridology is the diagnosis of disease by inspection of the iris. The main idea behind iridology is that all the organs of the body are represented by specific areas in the iris – when there is an imbalance or disease, certain signs show up in the iris by a kind of reflex physiology. When an organ is removed the iris records the pre-surgical condition of the organ, as if frozen in time. I thus intend to determine if individuals who have had an appendectomy due to an acute appendicitis have the typical lesion in the appendix area of the right eye.

If you fit into the following categories (*inclusion criteria*) you are invited to participate:

- Participants may be male or female, between the ages of 18 - 65 years
- I require 30 participants who have had an appendectomy due to acute appendicitis and 30 with their appendices intact, serving as the control group.

Unfortunately you will not be suitable for this study if any of the following applies to you (*exclusion criteria*):

- Individuals who suffer from any disease that affects the appearance of the iris eg. connective tissue disease, neurofibromatosis, benign or malignant tumours of the iris.
- Individuals who are on medication for glaucoma
- Individuals who have had surgery on their iris
- Individuals who suffer from bowel disorders eg inflammatory bowel disease (Crohn's disease, ulcerative colitis), irritable bowel disease

Once you have signed this consent form and have agreed to participate in this research study, I will conduct a brief interview to note age, gender and eye colour, and to determine if, of those who have had appendectomies, it was due to an acute appendicitis, and when the procedure was done. I will also note chronic disease and medication. Then once-off photographs will be taken in the optometrist's office of the eye.

Your participation in the study is voluntary, and you are free to withdraw from it at any time. All information submitted by you will be confidential. Measures in place to ensure this include keeping your file in a secure cabinet and replacing your name with case numbers. Contact details of the researcher and supervisor involved in the study will be made available to you. There are no risks associated with this study. A signed copy of this form will be given to you. The results of this study will be made available to you on request.

Thank you for considering this study



UNIVERSITY
OF
JOHANNESBURG

Lora Frank

I, the participant, have been fully informed of the procedure of this research study. If at any time I have more questions about the study I understand that they will be answered. In signing this consent form, I agree to participate and understand that I am free to withdraw consent at any time.

Date: _____ Signature: _____

I, the researcher, have fully explained the procedure and purpose of the study. I have also asked whether the participant has any further questions regarding the procedures and have answered these questions to the best of my ability

Date: _____ Signature: _____

CONTACT DETAILS:

Researcher: Lora Frank

Cell no: 071 880 3865

Work: 061 2226565

Home: 061 222770

Email: lorafrank@gmail.com

Supervisor: Dr Janice Pellow

Office no: 011 559 6828

Email: jpellow@uj.ac.za

APPENDIX F

Patient consent to clinical photography (adapted from Naidoo, 2010)

UNIVERSITY OF JOHANNESBURG
FACULTY OF HEALTH SCIENCES
DEPARTMENT OF HOMOEOPATHY



PATIENT CONSENT TO CLINICAL PHOTOGRAPHY

Surname:	Date of Birth:
Name:	Gender:

I, _____ hereby consent to photographs being taken of me/my child as requested, I understand that these photographs will be stored appropriately, treated with utmost confidentiality and be part of my participant record. I hereby give consent for the images to be used for **approved research purposes and publication** – this may involve the photographic images being used for example in the researcher’s dissertation, medical-publications, journals, e-publications and on the Internet. Images may be seen by health professionals and researchers who use the publications in their professional education. The images may be seen by the general public. Images will not be used with identifying information such as a name, however, full confidentiality is not guaranteed.

Participant Signature: _____ Date: _____

Signature: _____ Date: _____

Witness Name & Signature: _____ Date: _____

APPENDIX G
Participant Record

No.

Age:

Sex:

Eye colour:

- I've had an appendectomy due to acute appendicitis

(Symptoms of acute appendicitis include:

1. severe abdominal pain, umbilical or right lower quadrant
2. nausea and vomiting)

Date of surgery:



UNIVERSITY
OF
JOHANNESBURG

- My appendix is intact

Do you suffer from any chronic disease? If so, what?

Chronic medication:

I would like to receive an email regarding the results of the study

yes

no

Email:

APPENDIX H

Spreadsheet

No.	Date of Birth	Random no	Age	Gender	Eye Colour	Group	No. of years ago	Iride Sign (Lora Frank)	Iride Sign (Expert 1)	Iride Sign (Expert 2)
1	10181		15	30	Female	Brown	With Appendectomy	10	Present	Absent
2	11081		29	29	Female	Green	Without Appendectomy		Absent	Present
3	30181		23	30	Male	Green	With Appendectomy	15	Present	Present
4	31265		24	45	Male	Brown	Without Appendectomy		Present	Absent
5	41071		48	40	Male	Green	Without Appendectomy		Absent	Present
6	50448		41	63	Male	Blue	With Appendectomy	22	Present	Present
7	50751		5	60	Male	Green	With Appendectomy	3	Absent	Present
8	60446		11	65	Female	Blue	With Appendectomy	60	Absent	Present
9	61168		56	42	Female	Green	Without Appendectomy		Present	Present
10	61260		26	50	Female	Green	Without Appendectomy		Present	Absent
11	80560		6	50	Female	Blue	With Appendectomy	33	Present	Absent
12	80571		9	40	Female	Green	Without Appendectomy		Present	Absent
13	91248		54	63	Male	Brown	Without Appendectomy		Absent	Present
14	101090		27	20	Male	Green	Without Appendectomy		Absent	Present
15	110767		7	44	Male	Blue	With Appendectomy	20	Present	Absent
16	111072		3	49	Female	Brown	With Appendectomy	1	Absent	Present
17	120456		46	55	Female	Blue	With Appendectomy	40	Present	Absent
18	120669		14	42	Female	Green	Without Appendectomy		Present	Present
19	131088		44	22	Female	Blue	Without Appendectomy		Absent	Present
20	141182		39	28	Female	Brown	Without Appendectomy		Absent	Absent
21	141274		12	35	Male	Brown	Without Appendectomy		Absent	Absent
22	150654		22	57	Female	Green	With Appendectomy	23	Absent	Present
23	160383		53	28	Female	Blue	Without Appendectomy		Present	Present
24	170581		25	30	Male	Brown	With Appendectomy	1	Absent	Present
25	170886		37	24	Female	Green	Without Appendectomy		Absent	Present
26	180850		34	60	Female	Brown	Without Appendectomy		Present	Present
27	181167		40	47	Female	Brown	Without Appendectomy		Present	Absent
28	190292		10	19	Female	Green	Without Appendectomy		Present	Absent
29	210852		35	59	Male	Blue	With Appendectomy	54	Absent	Absent
30	230282		20	29	Female	Brown	Without Appendectomy		Absent	Absent
31	230490		49	21	Female	Blue	With Appendectomy	10	Absent	Absent
32	240185		16	26	Male	Brown	Without Appendectomy		Present	Absent
33	240354		30	57	Male	Green	With Appendectomy	5	Absent	Present
34	241155		31	58	Male	Green	With Appendectomy	5	Absent	Absent
35	250457		58	54	Female	Brown	Without Appendectomy		Absent	Absent
36	251185		32	25	Male	Brown	Without Appendectomy		Absent	Present
37	251268		4	42	Female	Green	Without Appendectomy		Present	Present
38	260158		59	52	Male	Blue	With Appendectomy	0	Present	Present
39	260485		33	26	Female	Green	Without Appendectomy		Present	Present
40	260786		42	24	Female	Green	Without Appendectomy		Present	Present
41	261282		19	28	Female	Brown	Without Appendectomy		Present	Absent
42	280250		36	61	Female	Blue	Without Appendectomy		Present	Absent
43	280287		2	24	Male	Blue	With Appendectomy	8	Absent	Present
44	290588		57	22	Female	Brown	With Appendectomy	5	Absent	Present
45	290654		21	57	Female	Blue	Without Appendectomy		Present	Present
46	300359		60	52	Female	Blue	With Appendectomy	36	Absent	Present
47	300683		43	27	Female	Green	Without Appendectomy		Absent	Present
48	300860		17	51	Male	Green	With Appendectomy	45	Present	Present
49	301283		45	27	Male	Blue	With Appendectomy	9	Present	Absent
50	7021984		13	27	Female	Green	With Appendectomy	6	Present	Present
51	9061956		51	55	Male	Blue	Without Appendectomy		Present	Absent
52	12081958		47	53	Male	Blue	With Appendectomy	39	Present	Present
53	17061966		38	44	Female	Blue	With Appendectomy	30	Absent	Absent
54	17101946		55	65	Male	Brown	With Appendectomy	15	Absent	Absent
55	20011980		1	34	Female	Brown	Without Appendectomy		Present	Absent
56	23011981		28	30	Male	Brown	With Appendectomy	21	Absent	Absent
57	24021993		50	18	Female	Brown	With Appendectomy	0	Absent	Present
58	25011953		52	58	Female	Brown	With Appendectomy	37	Absent	Present
59	29061970		8	41	Female	Green	With Appendectomy	8	Present	Absent
60	31101974		18	46	Male	Brown	With Appendectomy	1	Present	Absent

APPENDIX I

DISTRIBUTIONS

Age

Quantiles

100.0%	maximum	65
99.5%		65
97.5%		65
90.0%		60
75.0%	quartile	54.75
50.0%	median	42
25.0%	quartile	27.25
10.0%		22.2
2.5%		18.525
0.5%		18
0.0%	minimum	18

Moments


Mean	40.95
Std Dev	14.518749
Std Err Mean	1.8743624
Upper 95% Mean	44.700591
Lower 95% Mean	37.199409
N	60

Gender

Frequencies

Level	Count	Prob
Female	36	0.60000
Male	24	0.40000
Total	60	1.00000

N Missing
0
2 Levels



Eye Colour

Frequencies

Level	Count	Prob
Blue	18	0.30000
Brown	21	0.35000
Green	21	0.35000
Total	60	1.00000

N Missing
0
3 Levels

Group

Frequencies

Level	Count	Prob
With Appendectomy	30	0.50000
Without Appendectomy	30	0.50000
Total	60	1.00000

N Missing
0
2 Levels

No. of years ago

Quantiles

100.0%	maximum	60
99.5%		60
97.5%		60
90.0%		44.5
75.0%	quartile	33.75
50.0%	median	12.5
25.0%	quartile	5
10.0%		1
2.5%		0
0.5%		0
0.0%	minimum	0

Moments

Mean	18.733333
Std Dev	17.244556
Std Err Mean	3.1484108
Upper 95% Mean	25.172556
Lower 95% Mean	12.29411
N	30

Iride Sign (Rater 1)

Frequencies

Level	Count	Prob
Absent	30	0.50000
Present	30	0.50000
Total	60	1.00000

N Missing
0
2 Levels
UNIVERSITY OF JOHANNESBURG

Iride Sign (Rater 2)

Frequencies

Level	Count	Prob
Absent	30	0.50000
Present	30	0.50000
Total	60	1.00000

N Missing
0
2 Levels

Iride Sign (Rater 3)

Frequencies

Level	Count	Prob
Absent	31	0.51667
Present	29	0.48333
Total	60	1.00000

N Missing
0
2 Levels

APPENDIX J

Agreement Statistics

Rater

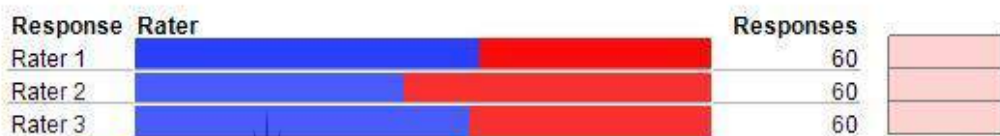
Frequency



Response	False	Correct	Responses
Rater 1	36	24	60
Rater 2	28	32	60
Rater 3	35	25	60

Share of Responses

Response	False	Correct	Responses
Rater 1	0.6000	0.4000	60
Rater 2	0.4667	0.5333	60
Rater 3	0.5833	0.4167	60

Share Chart



False 
Correct 

Agreement Statistics

Degree of Agreement

Response1	Response2	Kappa	Std Err	Bowker Symmetry	Bowker PValue
Rater 1	Rater 2	0.078947	0.123913	2.285714	0.1306
Rater 1	Rater 3	0	0.129023	0.034483	0.8527
Rater 2	Rater 3	0.10989	0.124583	1.814815	0.1779

For 2-by-2 tables, Bowker's Test is equivalent to McNemar's Test.

Details

Rater Row	Rater Col	Level	False	Correct
Rater 2	Rater 1	False	18	10
Rater 2	Rater 1	Correct	18	14
Rater 3	Rater 1	False	21	14
Rater 3	Rater 1	Correct	15	10
Rater 3	Rater 2	False	18	17
Rater 3	Rater 2	Correct	10	15

APPENDIX K

CHI-SQUARE: Fit Y by X Group

Contingency Analysis of Group By Iride Sign (Rater 1)

Contingency Table

Iride Sign (Rater 1) By Group

Count	Absent	Present	
Total %			
Col %			
Row %			
Absent	12 20.00 40.00 40.00	18 30.00 60.00 60.00	30 50.00
Present	18 30.00 60.00 60.00	12 20.00 40.00 40.00	30 50.00
	30 50.00	30 50.00	60

Tests

N	DF	-LogLike	RSquare (U)
60	1	1.2081308	0.0290

Test	ChiSquare	Prob>ChiSq
Likelihood Ratio	2.416	0.1201
Pearson	2.400	0.1213

Fisher's Exact Prob Alternative Hypothesis

Test

Left	0.0982 Prob(Group=Present) is greater for Iride Sign (Lora Frank)=Absent than Present
Right	0.9651 Prob(Group=Present) is greater for Iride Sign (Lora Frank)=Present than Absent
2-Tail	0.1964 Prob(Group=Present) is different across Iride Sign (Lora Frank)

Odds Ratio

Odds Ratio	Lower 95%	Upper 95%
0.444444	0.158196	1.248648

Contingency Analysis of Group By Iride Sign (Rater 2)

Contingency Table

Iride Sign (Rater 2) By Group

Count	Absent	Present	
Total %			
Col %			
Row %			
Absent	16 26.67 53.33 53.33	14 23.33 46.67 46.67	30 50.00
Present	14 23.33 46.67 46.67	16 26.67 53.33 53.33	30 50.00
	30 50.00	30 50.00	60

Tests

N 60 DF 1 -LogLike 0.13343227 RSquare (U) 0.0032

Test	ChiSquare	Prob>ChiSq
Likelihood Ratio	0.267	0.6054
Pearson	0.267	0.6056

Fisher's Exact Prob Alternative Hypothesis

Test

Left 0.7805 Prob(Group=Present) is greater for Iride Sign (Expert 1)=Absent than Present
 Right 0.3983 Prob(Group=Present) is greater for Iride Sign (Expert 1)=Present than Absent
 2-Tail 0.7965 Prob(Group=Present) is different across Iride Sign (Expert 1)

Odds Ratio

Odds Ratio	Lower 95%	Upper 95%
1.306122	0.473637	3.601824

Contingency Analysis of Group By Iride Sign (Rater 3)

Contingency Table

Iride Sign (Expert 2) By Group

Count	Absent	Present	
Total %			
Col %			
Row %			
Absent	13 21.67 43.33 41.94	18 30.00 60.00 58.06	31 51.67
Present	17 28.33 56.67 58.62	12 20.00 40.00 41.38	29 48.33
	30 50.00	30 50.00	60

Tests

N	DF	-LogLike	RSquare (U)
60	1	0.83818836	0.0202

Test

Test	ChiSquare	Prob>ChiSq
Likelihood Ratio	1.676	0.1954
Pearson	1.669	0.1965

Fisher's Exact

Prob Alternative Hypothesis

Test

Left	0.1507 Prob(Group=Present) is greater for Iride Sign (Expert 2)=Absent than Present
Right	0.9398 Prob(Group=Present) is greater for Iride Sign (Expert 2)=Present than Absent
2-Tail	0.3015 Prob(Group=Present) is different across Iride Sign (Expert 2)

Odds Ratio

Odds Ratio	Lower 95%	Upper 95%
0.509804	0.182526	1.423905

APPENDIX L

DISTRIBUTIONS

Rater 1

Frequencies

Level	Count	Prob	N Missing
False	36	0.60000	0
Correct	24	0.40000	2 Levels
Total	60	1.00000	

Rater 2

Frequencies

Level	Count	Prob	N Missing
False	28	0.46667	0
Correct	32	0.53333	2 Levels
Total	60	1.00000	

Rater 3

Frequencies

Level	Count	Prob	N Missing
False	35	0.58333	0
Correct	25	0.41667	2 Levels
Total	60	1.00000	

APPENDIX M

LOGISTIC RATER 1

Ordinal Logistic Fit for Rater 1

Whole Model Test

Model	-LogLikelihood	DF	ChiSquare	Prob>ChiSq
Difference	0.906779	4	1.813557	0.7700
Full	19.283571			
Reduced	20.190350			

RSquare (U)	0.0449
AICc	51.0671
BIC	55.5731
Observations (or Sum Wgts)	30

Measure	Training	Definition
Entropy RSquare	0.0449	$1 - \text{Loglike}(\text{model}) / \text{Loglike}(0)$
Generalized R-Square	0.0793	$(1 - (L(0)/L(\text{model}))^{2/n}) / (1 - L(0)^{2/n})$
Mean -Log p	0.6428	$\sum -\text{Log}(p_{ij})/n$
RMSE	0.4755	$\sqrt{\sum (y_{ij} - p_{ij})^2/n}$
Mean Abs Dev	0.4523	$\sum y_{ij} - p_{ij} /n$
Misclassification Rate	0.4000	$\sum (p_{ij} \neq p_{\text{Max}})/n$
N	30	n

Lack Of Fit

Source	DF	-LogLikelihood	ChiSquare
Lack Of Fit	4	1.521222	3.042444
Saturated	8	17.762349	Prob>ChiSq
Fitted	4	19.283571	0.5507

Parameter Estimates

Term	Estimate	Std Error	ChiSquare
Intercept[False]	0.46825718	0.5982428	0.6
Eye Colour[Blue]	-0.3060352	0.5813167	0.2
Eye Colour[Brown]	0.77805827	0.6275372	1.5
No. of years ago 3[11-29 years- 0-10 years]	0.02868587	0.9713187	0.0
No. of years ago 3[30+ years- 11-29 years]	-0.0559306	1.0687984	0.0

Effect Likelihood Ratio Tests

Source	Nparm	DF	L-R ChiSquare	Prob>ChiSq
Eye Colour	2	2	1.70641715	0.4260
No. of years ago 3	2	2	0.00275151	0.9986

APPENDIX N

LOGISTIC RATER 2

Ordinal Logistic Fit for Rater 2

Whole Model Test

Model	-LogLikelihood	DF	ChiSquare	Prob>ChiSq
Difference	4.331219	4	8.662437	0.0701
Full	16.396481			
Reduced	20.727699			

RSquare (U)	0.2090
AICc	45.293
BIC	49.7989
Observations (or Sum Wgts)	30

Measure	Training	Definition
Entropy RSquare	0.2090	$1 - \text{Loglike}(\text{model}) / \text{Loglike}(0)$
Generalized R-Square	0.3349	$(1 - (L(0)/L(\text{model}))^{2/n}) / (1 - L(0)^{2/n})$
Mean -Log p	0.5465	$\sum -\text{Log}(p_{ij})/n$
RMSE	0.4306	$\sqrt{\sum (y_{ij} - p_{ij})^2/n}$
Mean Abs Dev	0.3684	$\sum y_{ij} - p_{ij} /n$
Misclassification Rate	0.3000	$\sum (p_{ij} \neq p_{\text{Max}})/n$
N	30	n

Lack Of Fit

Source	DF	-LogLikelihood	ChiSquare
Lack Of Fit	4	3.045686	6.091373
Saturated	8	13.350794	Prob>ChiSq
Fitted	4	16.396481	0.1924

Parameter Estimates

Term	Estimate	Std Error	ChiSquare
Intercept[False]	-1.2035244	0.7041451	2.9
Eye Colour[Blue]	0.97130662	0.6285874	2.3
Eye Colour[Brown]	-0.9917799	0.6913867	2.0
No. of years ago 3[11-29 years- 0-10 years]	1.80699888	1.0787138	2.8
No. of years ago 3[30+ years- 11-29 years]	-0.5228696	1.1859454	0.1

Effect Likelihood Ratio Tests

Source	Nparm	DF	L-R ChiSquare	Prob>ChiSq
Eye Colour	2	2	3.29461299	0.1926
No. of years ago 3	2	2	3.37504785	0.1850

APPENDIX O

LOGISTIC RATER 3

Ordinal Logistic Fit for Rater 3

Whole Model Test

Model	-LogLikelihood	DF	ChiSquare	Prob>ChiSq
Difference	5.009710	4	10.01942	0.0401*
Full	15.180640			
Reduced	20.190350			

RSquare (U)	0.2481
AICc	42.8613
BIC	47.3673
Observations (or Sum Wgts)	30

Measure	Training	Definition
Entropy RSquare	0.2481	$1 - \text{Loglike}(\text{model}) / \text{Loglike}(0)$
Generalized R-Square	0.3838	$(1 - (L(0)/L(\text{model}))^{2/n}) / (1 - L(0)^{2/n})$
Mean -Log p	0.5060	$\sum -\text{Log}(p_{ij})/n$
RMSE	0.4033	$\sqrt{\sum (y_{ij} - p_{ij})^2/n}$
Mean Abs Dev	0.3316	$\sum y_{ij} - p_{ij} /n$
Misclassification Rate	0.2667	$\sum (p_{ij} \neq p_{\text{Max}})/n$
N	30	n

Lack Of Fit

Source	DF	-LogLikelihood	ChiSquare
Lack Of Fit	4	3.739388	7.478777
Saturated	8	11.441252	Prob>ChiSq
Fitted	4	15.180640	0.1126

Parameter Estimates

Term	Estimate	Std Error	ChiSquare
Intercept[False]	-0.2700817	0.7538451	0.1
Eye Colour[Blue]	-2.2034308	0.9404308	5.4
Eye Colour[Brown]	0.3848585	0.7217224	0.2
No. of years ago 3[11-29 years- 0-10 years]	1.28863321	1.2899162	1.0
No. of years ago 3[30+ years- 11-29 years]	1.51015357	1.3795027	1.2

Effect Likelihood Ratio Tests

Source	Nparm	DF	L-R ChiSquare	Prob>ChiSq
Eye Colour	2	2	9.62581377	0.0081*
No. of years ago 3	2	2	4.44753646	0.1082



UNIVERSITY
OF
JOHANNESBURG