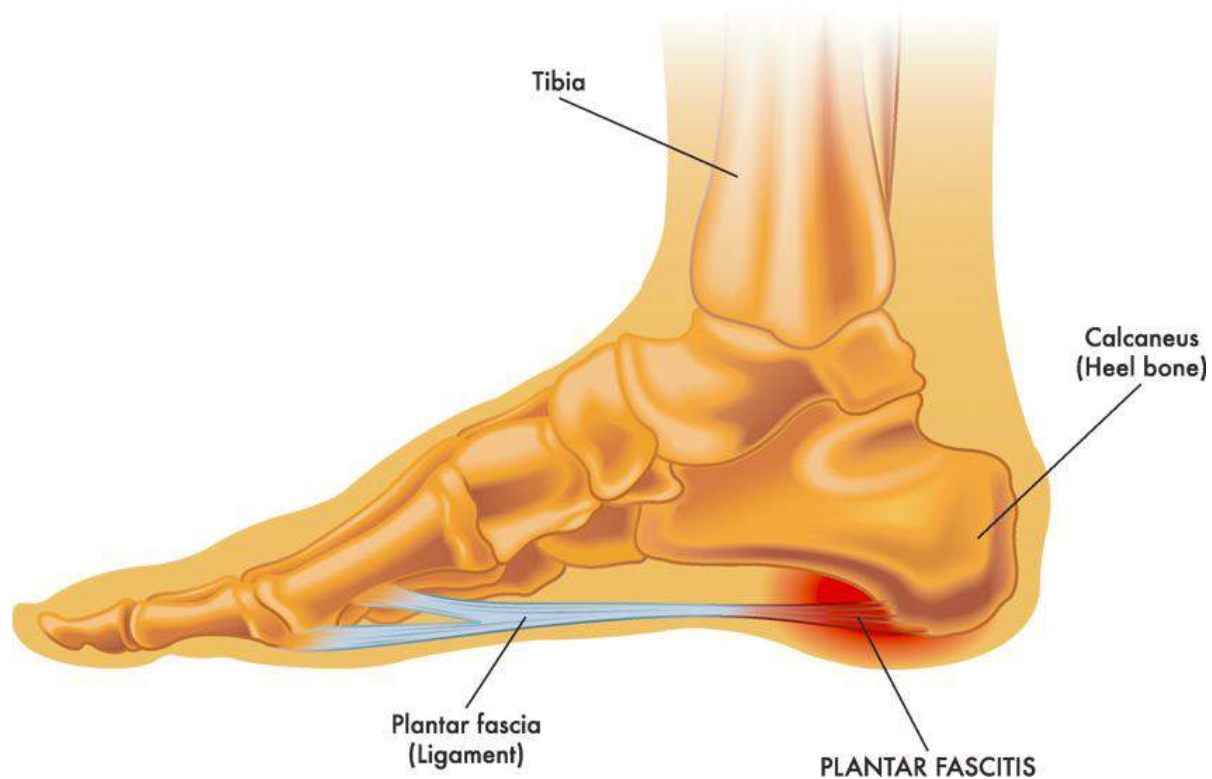


Acupuncture Plantar Fasciitis Relief Confirmed

Published by [HealthCMi](#) on November 2017



Acupuncture combined with herbal medicine foot baths is a proven and effective therapeutic method for the elimination of plantar fasciitis. Guangxi People's Hospital researchers compared using only Traditional Chinese Medicine (TCM) foot baths as a standalone therapy with a combination of TCM foot baths and acupuncture. Compared with Chinese herbal medicine foot bath monotherapy, adding acupuncture treatments to the regimen of care significantly decreases pain and swelling while simultaneously reducing relapse rates.

Plantar fasciitis involves pain and inflammation of the band of tissue running across the sole of the foot, the plantar fascia. A major cause of heel pain, many people with plantar fasciitis experience severe pain with the first few steps in the morning after getting out of bed. Plantar fasciitis pain is also exacerbated when walking after sitting for an extended period of time. Essentially, the pain becomes intense when

placing weight onto the foot. Pain on the posterior aspect of the heel often indicates achilles tendinitis and pain on the underside of the heel is an indicator of plantar fasciitis.

The acupuncture plus herbal foot bath protocol achieved a total treatment effective rate of 91.8%. Using only TCM foot baths, the total treatment effective rate was 69.8%. Adding acupuncture to foot bath therapy increases the total effective rate by 22%. Relapse rates (determined at three months after completion of all therapies) plunged when acupuncture was combined with TCM foot baths. Using only foot baths, the relapse rate was 66.67%. The combination of acupuncture plus herbal foot baths yielded a 27.78% relapse rate, a significant improvement.

A total of 74 plantar fasciitis patients from Guangxi People's Hospital were treated and evaluated. They were randomly divided into two groups of 37, the integrated treatment group and the foot bath only control group. Both groups were given identical TCM foot baths. All patients fulfilled the following inclusion criteria:

- *Heel pain or discomfort for ≥ 2 months*
- *≥ 5 VAS score for foot pain and pain points*
- *No severe internal diseases*
- *No foot surgery history*
- *No skin conditions on the feet*
- *Not suffering from other conditions that may cause heel pain*

The demographics of both groups were equivalent ($P > 0.05$) at the beginning of the study prior to treatment. For the control group, there were 10 males, 27 females, the mean age was 50.51 ± 7.29 years, the BMI was 21.82 ± 4.02 kg/m², the mean illness duration was 2 – 28 months. For the treatment group, there were 14 males, 23 females, the mean age was 52.28 ± 10.52 years, the BMI was 23.72 ± 5.93 kg/m², and the mean illness duration was 2 – 20 months. The following primary acupoints were selected for the treatment group:

- Taixi (KD3)
- Rangu (KD2)
- Kunlun (BL60)
- Qiuxu (GB40)
- Ashi

A 0.30 mm x 0.50 mm needle was inserted into each acupoint until deqi was elicited. The insertion angle was either perpendicular or at 45°. All needles were manipulated with the mild reinforcement and attenuation (Ping Bu Ping Xie) technique. The skin surrounding the acupoints were then covered with gauze or tissue to prevent falling moxa ashes from irritating the skin. An approximately 2 cm moxa roll was attached to the end of each needle and ignited. Needles were retained until the moxa rolls self-extinguished and the needles cooled. Pressure was applied after removing the needles to prevent bleeding. One acupuncture session was conducted daily for a total of 10 days. The prescription for the TCM foot bath was comprised of the following herbs in equal quantities:

- Du Zhong
- Niu Xi
- Chuan Duan
- Hong Hua
- Tao Ren
- Mu Gua
- Qin Jiu
- Wei Ling Xian
- Hai Feng Teng
- Shen Jin Cao
- Luo Shi Teng

The herbs were decocted in a stainless steel pot. After adding 2,500 ml of water, herbs were left to soak for 30 minutes. Next, the water was brought to a boil with high heat and was subsequently simmered for 20 – 25 minutes at low heat. After simmering, 1,500 – 2,000 ml of the water was removed and kept (1st brew). This process was repeated for the remaining liquid in the pot (2nd brew). The 1st brew and 2nd brew were combined with a small amount of vinegar. This final mixture was used as the foot bath, keeping it at between 40 – 50°C throughout the bath soaking time. One 30 minute bath was applied daily for a total of 10 days.

The results indicate that TCM foot baths are effective for the alleviation plantar fasciitis. The addition of acupuncture significantly increases the positive patient outcome rates. Based on the data, the researchers find acupuncture plus TCM foot baths effective for the treatment of plantar fasciitis.

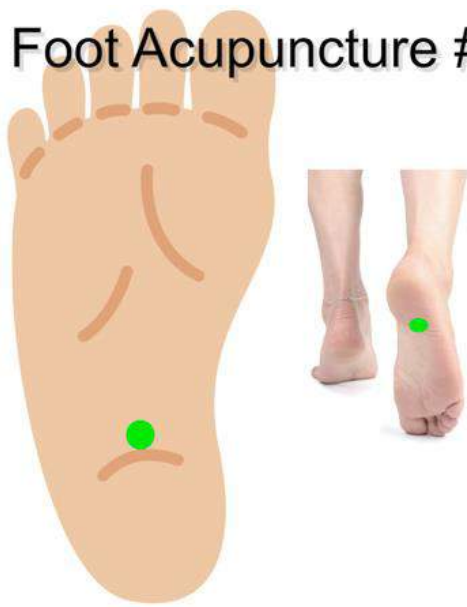The Healthcare Medicine Institute offers an online plantar fasciitis acupuncture continuing education course for CEU and PDA credit. To learn more about the course, view a sample of the course material:

The following is a basic overview of common acupuncture points used for the treatment of plantar fasciitis. In TCM, local Ahshi points are indicated for the treatment of plantar fasciitis. Common primary channel and extra acupoints used for the treatment of plantar fasciitis include KD1 (Yongquan), KD2 (Rangu), N-LE-48 (Chuxixue), KD3 (Taixi), KD6 (Zhaohai), BL57 (Chengshan), BL60 (Kunlun), BL61 (Pucan), BL62 (Shenmai), BL63 (Jinmen), SP4 (Gongsun), LV3 (Taichong), GB40 (Qixu), and foot acupuncture point #1. The following highlights a few of the aforementioned acupoints:

Foot Acupuncture Point #1

This acupuncture point is located on the sole of the foot at the midpoint between the medial and lateral malleoli. Foot acupuncture point #1 is indicated for the treatment of neurasthenia, hysteria, insomnia, and low blood pressure. Its sedative effects are often remarkably effective. Its location makes this acupoint suitable for the treatment of plantar fasciitis.

Foot Acupuncture #1



KD2 (Rangu)

This acupuncture point is located on the medial aspect of the foot, distal and inferior to the medial malleolus in the depression that is distal and inferior to the navicular tuberosity. Rangu, translated as blazing fire, is a ying-spring and fire point of the kidney channel. This acupoint clears deficiency heat, benefits the kidneys, and regulates the lower jiao (burner). KD2 benefits patients with plantar fasciitis and

is used for the treatment of painful throat obstruction, pain at the medial aspect of the foot, and xerostomia.

N-LE-48 Chuqixue (Vent Gas Orifice)

This point is located 0.5 cun posterior to KD2 (Rangu). A slanted needle insertion of 0.5–1 cun is often used. Chuqixue may be used for the treatment of plantar fasciitis or dissension along the gastrointestinal tract with gas in the later stage of cancer of the esophagus.

AhShi Points

Often there is discomfort in the depressions located approximately 1 cun inferior to BL62 (Shenmai) and KD6 (Zhaohai). These acupoints are suitable for the treatment of plantar fasciitis.

The aforementioned research is not an isolated finding. Guangzhou Dongsheng Hospital and Guangzhou Social Welfare House researchers (Tang et al.) performed a meta-analysis of 19 independent plantar fasciitis clinical trials. A total of 16 of the 19 studies made extensive use of Ahshi acupuncture points. Based on the data, the researchers determined that acupuncture is effective for the treatment of plantar fasciitis. The following are some of the studies included in the meta-analysis.

Xu Xuemeng et al. randomly divided 66 plantar fasciitis patients into an acupuncture group and a conventional therapy control group. The acupuncture group received standard acupuncture and the control group received triamcinolone acetonide acetate injections and local blocking therapy. The results were assessed 6 months after the completion of all treatments. The acupuncture group achieved a total effective rate of 97% and the drug therapy group had a 76% effective rate.

He Yucai et al. performed a clinical trial involving 75 patients with plantar fasciitis. Acupoints Yongquan (KI1), Rangu (KI2), Taixi (KI3), Sanyinjiao (SP6), Chengshan (BL57), and Ashi acupoints on the affected side were administered. Needles were rapidly inserted perpendicularly using the lifting and thrusting method and mild reinforcing and reducing manipulation methods. Needles were immediately withdrawn after a deqi sensation was achieved.

Next, moxibustion was applied to Ashi points on the heel for 10 minutes. Acupuncture and moxibustion were administered once per day for a period of 6 days, comprising one course of therapy. The second course of care started two days after the completion of the first. After two courses of acupuncture and moxibustion therapy, the acupuncture group significantly outperformed a control group that received

ibuprofen sustained release capsules and the herbal formula Zhuanggu Guanjie Wan (Strengthening Bone and Joint Pills).

Acupuncture has a proven and lengthy track record for producing significant positive patient outcome rates for patients with plantar fasciitis. The data indicates that access to acupuncture, moxibustion, and TCM herbal foot baths is an adequate solution for the vast majority of patients.

References:

Liu DJ, Xia H. Shockwave therapy with foot massage in treating plantar fasciitis 100 cases [J]. *China TCM Orthopedics Journal*, 2013, 21(7): 56.

Ly XY, Ding XH, Liu Y Et al. Semiconductor laser with ultrashort wave therapy in treating plantar fasciitis [J]. *Laser Journal*, 2011, 32(1): 66.

Zhang LN, Ding P. Plantar fasciitis fundamentals and clinical research advancements [J]. *Hainan Medicine Institute Newsletter*, 2013, 19(3): 429-431.

Wang ZY. *Foot and ankle surgery* [M]. Beijing: People's Health Publishing House, 2006: 7.

Wei GK. *TCM Ligament Injury* [M]. Shanghai: Shanghai Scientific Technology Publishing House, 1997: 137.

Digiovanni BF, Nawoczenski DA, Malay DP. Plantar fascia-specific stretching exercise improves outcomes in patients with chronic plantar fasciitis. A prospective clinical trial with two-year follow-up [J]. *Bone Joint Surg Am*, 2006, 88(8): 1775-1781.

Drake M, Bittenbender C, Boyles RE. The short-term effects of treating plantar fasciitis with a temporary custom foot orthosis and stretching [J]. *Orthop Sports Phys Ther*, 2011, 41(4): 221-231.

Cozzarelli J, Sollitto RJ, Thapar J Et al. A 12-year long-term retrospective analysis of the use of radiofrequency nerve ablation for the treatment of neurogenic heel pain [J]. *Foot Ankle Spec*, 2010, 3: 338-346.

Gao F, Zhao B, Fan XH. Thrust acupuncture and injection therapy in treating plantar fasciitis 150 cases [J]. *Yunnan TCM Herbs Journal*, 2015, 36(6): 80-81.

Liang YH. Plantar fasciitis internal and external treatment 80 cases [J]. *Shanxi TCM Institute Newsletter*, 2006, 7(1): 41.

Tang, Cuanqi, et al. "Progress of Clinical Research on Acupuncture and Moxibustion for Heel Pain." *World Chinese Medicine* 9.1 (2014): 120-123.