

## **LECTURE NOTES**

For Nursing Students

# *Human Anatomy and Physiology*



**Ethiopia Public Health  
Training Initiative**

Nega Assefa  
Alemaya University  
Yosief Tsige  
Jimma University

In collaboration with the Ethiopia Public Health Training Initiative, The Carter Center,  
the Ethiopia Ministry of Health, and the Ethiopia Ministry of Education

2003



Funded under USAID Cooperative Agreement No. 663-A-00-00-0358-00.

Produced in collaboration with the Ethiopia Public Health Training Initiative, The Carter Center, the Ethiopia Ministry of Health, and the Ethiopia Ministry of Education.

### **Important Guidelines for Printing and Photocopying**

Limited permission is granted free of charge to print or photocopy all pages of this publication for educational, not-for-profit use by health care workers, students or faculty. All copies must retain all author credits and copyright notices included in the original document. Under no circumstances is it permissible to sell or distribute on a commercial basis, or to claim authorship of, copies of material reproduced from this publication.

©2003 by **Nega Assefa and Yosief Tsige**

All rights reserved. Except as expressly provided above, no part of this publication may be reproduced or transmitted in any form or by any means, electronic or mechanical, including photocopying, recording, or by any information storage and retrieval system, without written permission of the author or authors.

*This material is intended for educational use only by practicing health care workers or students and faculty in a health care field.*

## Preface

There is a shortage in Ethiopia of teaching / learning material in the area of anatomy and physiology for nurses. The Carter Center EPHTI appreciating the problem and promoted the development of this lecture note that could help both the teachers and students.

Human anatomy and physiology is more than just interesting, it is fascinating. To help get the students and instructions involved in the study of this subject, a number of special features are incorporated throughout the lecture note.

The lecture note provides a thorough review of human anatomy and physiology applicable to the nurses. It covers all body parts using a systemic approach. Each chapter is designed to aid effective student learning.

Each chapter contains:

- The Learning objectives: what the students are expected to accomplish upon completion of a particular chapter.
- Key concepts: summary of selected key terms included in the chapter.
- Illustrations: there will aid the students to achieve a better understanding of the subject matter.

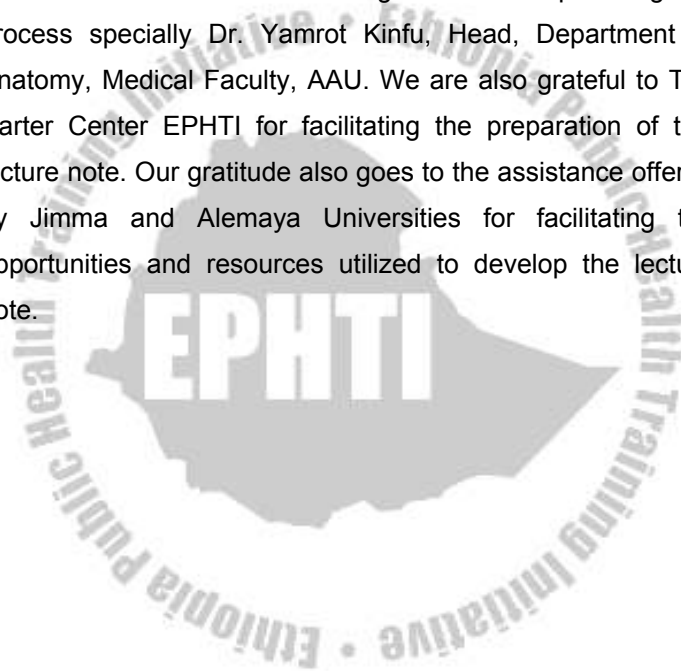
- Review questions: a cross check to know if the students have come to grasp concepts stated in the chapter.

We hope that you enjoy the lecture note of Human Anatomy and Physiology for nurses. Please let us know if you have any comments regarding this lecture note.



## Acknowledgments

We are highly indebted to acknowledge the authors of the reference books we used in preparing this lecture note. We would like to extend our appreciation to the different professionals involved in reviewing this manuscript through its process specially Dr. Yamrot Kinfu, Head, Department of Anatomy, Medical Faculty, AAU. We are also grateful to The Carter Center EPHTI for facilitating the preparation of this lecture note. Our gratitude also goes to the assistance offered by Jimma and Alemaya Universities for facilitating the opportunities and resources utilized to develop the lecture note.



## Table of Contents

Preface

Acknowledgement

Table of contents

List of tables

Abbreviations

Introduction

**CHAPTER ONE – INTRODUCTION TO HUMAN ANATOMY AND PHYSIOLOGY**

**CHAPTER TWO – CELL**

**CHAPTER THREE – TISSUES AND MEMBRANE**

**CHAPTER FOUR – THE INTEGUMENTARY SYSTEM**

**CHAPTER FIVE – THE SKELETAL SYSTEM**

**CHAPTER SIX – THE MUSCULAR SYSTEM**

**CHAPTER SEVEN – THE NERVOUS SYSTEM**

**CHAPTER EIGHT – THE ENDOCRINE SYSTEM**

**CHAPTER NINE – CARDIOVASCULAR SYSTEM**

**CHAPTER TEN – RESPIRATORY SYSTEM**

**CHAPTER ELEVEN – DIGESTIVE SYSTEM**

**CHAPTER TWELVE – THE URINARY SYSTEM**

**CHAPTER THIRTEEN – FLUID AND ELECTROLYTE BALANCE**

**CHAPTER FOURTEEN – THE REPRODUCTIVE SYSTEM**

Glossary

Answers to the study questions

References

## List of Tables

Table 1.1 Directional terms

Table 5. 1 Comparison between bone and cartilage

Table 5.2 Divisions of the adult skeleton (206 bones)

Table 5.3 Descriptions and functions of Cranial Bones

Table 5.4 Descriptions and Functions of Facial bones

Table 5.5 Bones of the vertebral column (26 bones)

Table 5.6 Upper extremity bones and their function

Table 5.7 Bones of the lower extremity and their function

Table 5.8 Classifications of joints

Table 5.9 Various types of movements by synovial joint

Table 6-1 Summary of events in the contraction of a muscle fiber

Table 6-2 Head and neck muscles

Table 6-3 Trunk muscles

Table 6-4 Upper limb muscles

Table 6-5 Lower limb muscles

Table 7-1 Functions of Major Divisions of the Brain

Table 7-2 Effects of the sympathetic and Parasympathetic Systems on Selected Organs

Table 7-3 Special Sense Organs

Table 9-1 The ABO Blood Group System

Table 10-1 Breathing Volumes

Table 11-1 Chemical Digestion

Table 12.1 The main structural components of a nephron and their function.

Table 14.1 The Menstrual Cycle

Table 14.2 Summary of major reproduction hormones

## Abbreviations

Ach:	Acetylcholine
ACTH:	Adreno Cortico Tropic Hormone
ADH:	Anti di Uretic Hormone
ADP:	Adenosine Di Phosphate
ANS:	Autonomic Nervous System
ATP:	Adenosine Tri Phosphate
C:	Cervical, cervical vertebrae, (C4 cervical vertebrae 4)
cm:	Centi meter
CNS:	Central Nervous System
CRH:	Corticotropin Releasing Hormone
CSF:	Cerebro Spinal Fluid
DIT:	Di Iodo Tyrosine
DNA:	Deoxyribo Nucleic Acid
/d:	Per day
ECF:	Extra Cellular Fluid
ER:	Endoplasmic Reticulum
FSH:	Follicular stimulating hormone
g:	Gram
GHIH:	Growth Hormone Inhibiting Hormone
GHRH:	Growth Hormone Releasing Hormone
GI:	Gastro Intestinal
GnRH:	Gonadotrophin Releasing Hormone
HCG:	Human Chorionic Gonadotrophin hormone
Hcl:	Hydrochloric acid



hGH: Human Growth Hormone  
ICSH: Interstitial Cell Stimulating Hormone  
IGF: Insulin like Growth Factors  
IUD: Intra Uterine Device  
L: Lumbar, lumbar vertebrae, (L3, lumbar vertebrae 3)  
l: liter  
LES: Lower esophageal sphincter  
LH: Leutinizing Hormone  
LPH: Lito tropin Hormone  
m: Meter  
MIT: Mono Iodo Tyrosine  
ml.: Mili liter  
mm: Milli meter  
P: Phosphate  
PBI: Protein Bound Iodine  
P<sup>H</sup>: Power of Hydrogen  
PIH: Prolactin Inhibiting Hormone  
PNS: Peripheral Servous System  
POMC: Pro-Opio Melano Cortin  
PRH: Prolactin Releasing Hormone  
PTH: Para Thyroid Hormone  
RNA: Ribo Neuclic Acid  
rRNA: Ribosomal Ribo Neuclic Acid  
T: Thoracic, thoracic vertebrae, (T1 thoracic vertebrae 1)  
T<sub>3</sub>: Tri iodo tyronin  
T<sub>4</sub>: Thyroxin

TGB: Tyro globulin

TRH: Tyro tropin Releasing Hormone

TSH: Thyroid Stimulating Hormone

UV: Ultra Violet



## Introduction

The course human anatomy and physiology for nurses is designed to help student nurses learn and understand how the human body is organized and function. Equipping the student nurse with the knowledge of anatomy and physiology will further assist the student in understanding what happens and what to do when the body is injured, diseased or placed under stress. This teaching and learning material (lecture note) for nursing students at a diploma level is prepared in line with this concept.

Therefore, the students are expected to achieve the following general educational objectives after completion of the course:

- Understand and use anatomical terms.
- Understand the function of the various organs and their relations with one another.
- Know the location of each organ and the important anatomical land marks.
- Know the normal structure of the human body in general.
- Use the knowledge of anatomy and physiology in nursing practice.

# CHAPTER ONE

## INTRODUCTION TO HUMAN ANATOMY AND PHYSIOLOGY

### Learning Objective

At the end of this chapter, the students should be able to:

- Define Anatomy and Physiology
- Explain Homeostasis
- Describe levels of structural organization of the human body
- Discuss directional terms, anatomical position, planes and sections used in Anatomy.
- Differentiate body cavities

### Selected Key terms

The following terms are defined in the glossary:

Anatomical position	Body regions
Anatomy	Directional terms
Appendicular skeleton	Homeostasis
Axial skeleton	Physiology
Body cavities	Quadrants
Body plane	

## 1.1 What are Anatomy and Physiology?

**Anatomy:** the word anatomy is derived from a Greek word “*Anatome*” meaning to cut up. It is the study of structures that make up the body and how those structures relate with each other.

The study of anatomy includes many sub specialties. These are Gross anatomy, Microscopic anatomy, Developmental anatomy and Embryology.

**Gross anatomy** studies body structure with out microscope. *Systemic anatomy* studies functional relationships of organs within a system whereas *Regional anatomy* studies body part regionally. Both systemic and regional approaches may be used to study gross anatomy

**Microscopic anatomy (Histology)** requires the use of microscope to study tissues that form the various organs of the body.

**Physiology:** the word physiology derived from a Greek word for study of nature. It is the study of how the body and its part work or function.

Hence, Anatomy and physiology are studied together to give students a full appreciation and understanding of human body.

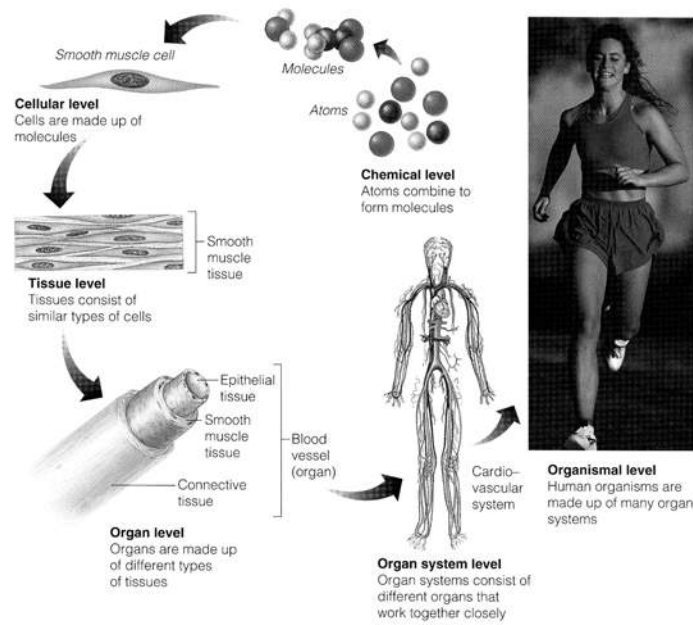
### **Homeostasis**

When structure and function are coordinated the body achieves a relative stability of its internal environment called *homeostasis* / staying the same. Although the external environmental changes constantly, the internal environment of a healthy body remains the same within normal limits.

Under normal conditions, homeostasis is maintained by adaptive mechanisms ranging from control center in the brain to chemical substances called hormones that are secreted by various organs directly into the blood streams. Some of the functions controlled by homeostasis mechanisms are blood pressure, body temperature, breathing and heart rate.

## **1.2 Level of structural organization of the body**

The human body has different structural levels of organization, starting with atoms molecules and compounds and increasing in size and complexity to cells, tissues, organs and the systems that make up the complete organism.



**Figure: 1.1 Levels of structural organization of the body** (source: Elaine n. MARIEB, (2000), Essentials of human anatomy and physiology, Addison welsey longman inc., San Francisco, 6<sup>th</sup> ed)

**Atoms molecules and compounds:** - At its simplest level, the body is composed of atoms. The most common elements in living organism are carbon, hydrogen, oxygen, nitrogen phosphorus and sulfur.

Atoms → Molecule → Compounds.

**Cell:** The smallest independent units of life. All life depends on the many chemical activities of cells. Some of the basic functions of cell are: growth, metabolism, irritability and reproduction.

**Tissue:** tissue is made up of many similar cells that perform a specific function. The various tissues of the body are divided in to four groups. These are epithelial, connective, nervous and muscle tissue.

*Epithelial tissue:* - Found in the outer layer of skin, lining of organs, blood and lymph vessels and body cavities.

*Connective tissue:* - Connects and supports most part of the body. They constitute most part of skin, bone and tendons.

*Muscle tissue:* - Produces movement through its ability to contract. This constitutes skeletal, smooth and cardiac muscles.

*Nerve tissue:* - Found in the brain, spinal cord and nerves. It responds to various types of stimuli and transmits nerve impulses.

**Organ:** - Is an integrated collection of two or more kinds of tissue that works together to perform specific function. For example: Stomach is made of all type of tissues



**System:** Is a group of organs that work together to perform major function.

For example: Respiratory system contains several organs.

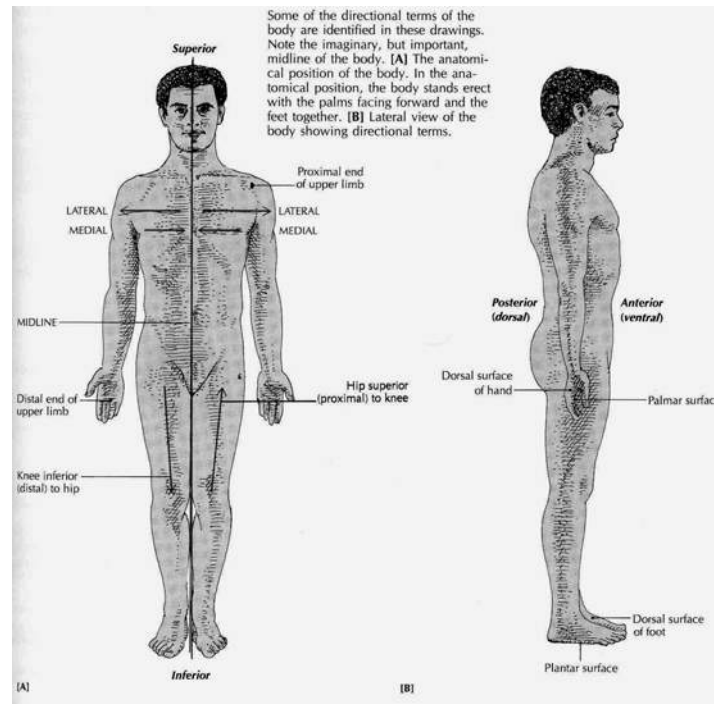
**Organism level:** - The various organs of the body form the entire organism.

### 1.3 Anatomical Terminologies

The language of anatomy will probably be unfamiliar to you at first. But once you have understood the basic word roots, combining word forms, prefixes and suffix you will find that anatomical terminologies are not as difficult as you first imagined.

#### 1.3.1. Anatomical Position.

Anatomical positions are universally accepted as the starting points for positional references to the body. In anatomical position the subject is standing erect and facing the observer, the feet are together, and the arms are hanging at the sides with the palms facing forward.



**Figure 1.2 Relative directional terms of the body.** (Source: Carola, R., Harley, J.P., Noback R.C., (1992), Human anatomy and physiology, Mc Graw hill inc, New York, 2<sup>nd</sup> ed, pp 15)

### 1.3.2 Relative Directional terms

Standardized terms of reference are used when anatomists describe the location of the body part. Relative means the location of one part of the body is always described in relation to another part of the body.

**Table: 1.1 Directional terms** (source: Carola, R., Harley, J.P., Noback R.C., (1992), Human anatomy and physiology, Mc Graw hill inc, New York, 2<sup>nd</sup> ed, pp 15)

Term	Definition and example
Superior (cranial)	Toward the head. The leg is superior to the foot.
Inferior (caudal)	Toward the feet. The foot is inferior to the leg.
Anterior (ventral)	Toward the front part of the body. The nose is anterior to the ears.
Posterior (dorsal)	Towards the back of the body. The ears are posterior to the nose.
Medial	Towards the midline of the body. The nose is medial to the eyes.
Lateral	Away from the midline of the body. The eyes are lateral to the nose.
Proximal	Toward (nearer) the trunk of the body or the attached end of a limb. The shoulder is proximal to the wrist.
Distal	Away (farther) from the trunk of the body or the attached end of a limb. The wrist is distal to the forearm.
Superficial	Nearer the surface of the body. The ribs are superficial to the heart.
Deep	Farther from the surface of the body. The heart is deeper to the ribs.
Peripheral	Away from the central axis of the body. Peripheral nerves radiate away from the brain and spinal cord.

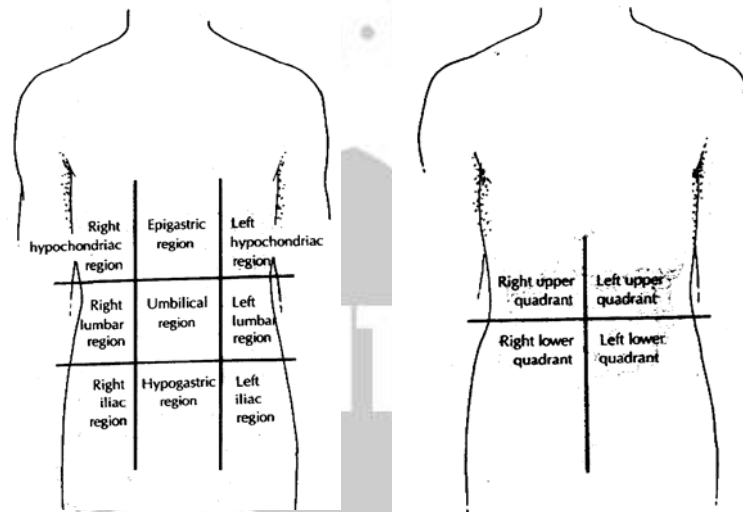
### 1.3.3. Body parts Regions

The body can generally be described to have areas of:

**Axial body part:** - It is the part of the body near the axis of the body. This includes head, neck, thorax (chest), abdomen, and pelvis.

**Appendicular body part:** - It is the part of the body out of the axis line. This includes the upper and lower extremities.

It is customary to subdivide the abdominal area into nine regions or more easily in to four quadrants.



**Figure 1.3 Abdominal sub divisions** (Source: Carola, R., Harley,J.P., Noback R.C., (1992), Human anatomy and physiology, Mc Graw hill inc, New York, 2<sup>nd</sup> ed, pp 17)

## 1.4 Body planes and sections

Body planes are imaginary surfaces or planes lines that divide the body in to sections. This helps for further identification of specific areas.

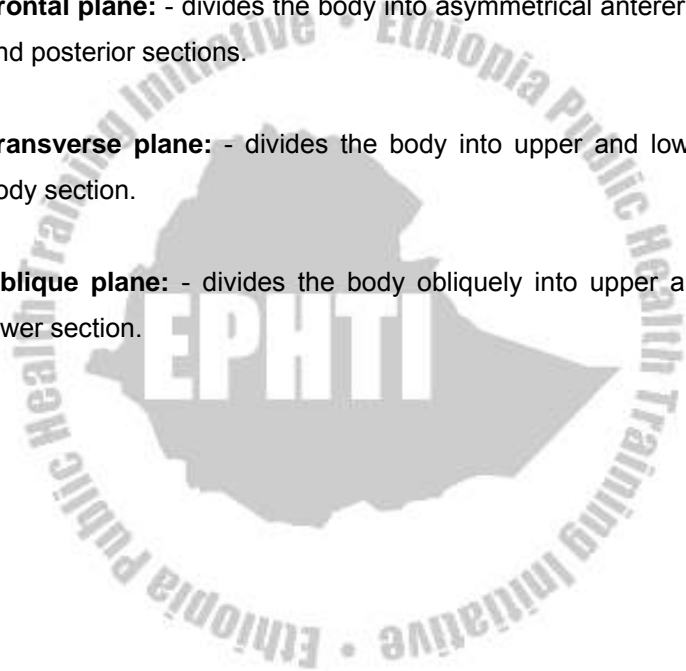
**Sagittal plane:**

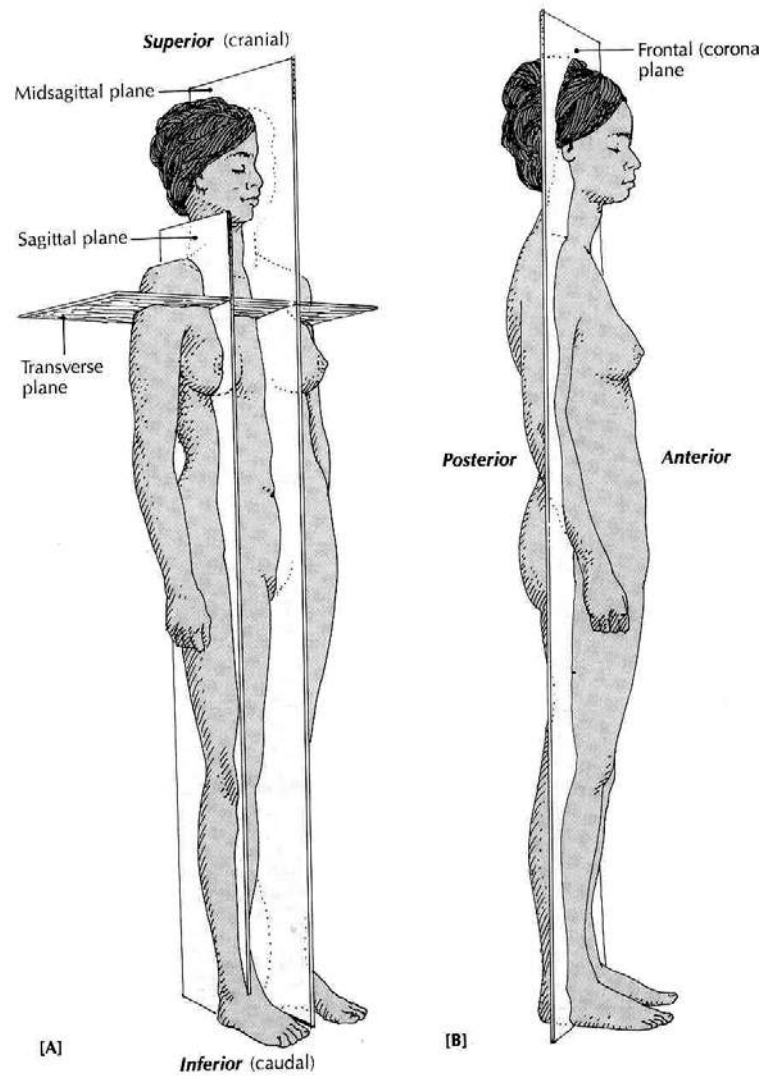
- divides the body into right and left half.
- Mid sagittal plane: - divides body into equal left and right halves.
- Para sagittal plane: - divides body into unequal left and right

**Frontal plane:** - divides the body into asymmetrical anterior and posterior sections.

**Transverse plane:** - divides the body into upper and lower body section.

**Oblique plane:** - divides the body obliquely into upper and lower section.





**Figure 1.4 Body planes** (Source: Carola, R., Harley, J.P., Noback R.C., (1992), Human anatomy and physiology, Mc Graw hill inc, New York, 2<sup>nd</sup> ed, pp18)

## 1.5 Body Cavities

The cavities of the body house the internal organs, which commonly referred to as the viscera. The two main body cavities are the larger ventral (anterior) and the smaller, dorsal (posterior) body cavity.

**The ventral body cavity** constitutes the thoracic cavity and the abdomino-pelvic body cavity.

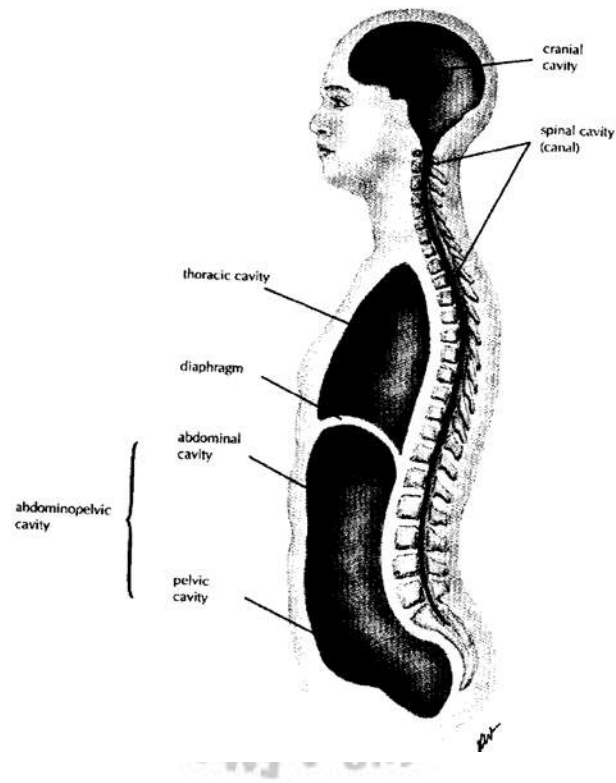
*The Thoracic cavity* houses lung and heart. It is protected by the rib cage & associated musculature and the sternum anteriorly. It consists of the right and left pleural cavities and mediastinum (the portion of tissues and organs that separates the left and right lung).

*Abdomino-pelvic Cavity* extends from the diaphragm inferior to the floor of the pelvis. It is divided into superior abdominal and inferior pelvic cavity by imaginary line passing at upper pelvis.

*Abdominal cavity* contains the stomach, intestine, liver, spleen and gallbladder.

*The pelvic cavity* contains urinary bladder, rectum, and portions of the reproductive organs.

**The dorsal body cavity:** it constitutes the cephalic cavity containing brain and the vertebral canal containing the spinal cord.



**Figure: 1.5 Body cavities** (Source: Memmler, Ruth Lundeen, Barbara Jansen Cohen and Dena Lin Wood (1996), *The Human Body in Health and Disease*, 8<sup>th</sup> Ed, pp 9).



## Review Questions

1. The anatomical term opposite to lateral is: -
  - a) Proximal
  - b) Distal
  - c) Medial
  - d) Superficial
  - e) Caudal.
2. When structure and function coordinated the body gets a relative stability. This phenomenon is called:
  - a) Anatomical integrity
  - b) Physiological stability
  - c) Homeostasis
  - d) Hemostasis
  - e) Body stasis
3. Which of the following is not the correct description of anatomical position?
  - a) Body facing forward
  - b) Head turned to side
  - c) Palms facing forward
  - d) Body standing
  - e) Feet together.
4. A plane that divided the body into anterior and posterior parts is: -
  - a) Medial plane
  - b) Coronal or frontal plane
  - c) Sagittal plane
  - d) Transverse plane
  - e) Oblique plane
5. The abdominal cavity contains the
  - a) Heart and lung
  - b) Reproductive organs and urinary bladder
  - c) Liver, spleen and stomach
  - d) Urinary bladder and lungs
  - e) Testes and ovaries

# CHAPTER TWO

## CELL

### Learning objective

At the end of this chapter, the students should be able to:

- Explain structure and characteristics of human cell
- Describe movements of particles across cell membrane
- Discuss organelles of human cell & their function
- Explain abnormal cellular function (cancer)

### Selected Key terms:

The following terms are defined in the glossary

Active movement

Cancer

Cell

Cell inclusion

Cytoplasm

Diffusion

Organelle

Osmosis

Passive movement

Plasma membrane

## 2.1 Cell

Cell is the basic living structural and functional unit of the body.

Cytology: - It is a branch of science concerned with a study of cells

Cell Theory explains about

- a) All living organisms are composed of cell and cell products.
- b) Cell is the basic unit of structure & function of all living organisms.
- c) All cells come from the division of pre existing cell.
- d) An organism as a whole can be understood through the collective activities & interactions of its cells.

To know more about cell, we can divide the cell in to four principal parts: -

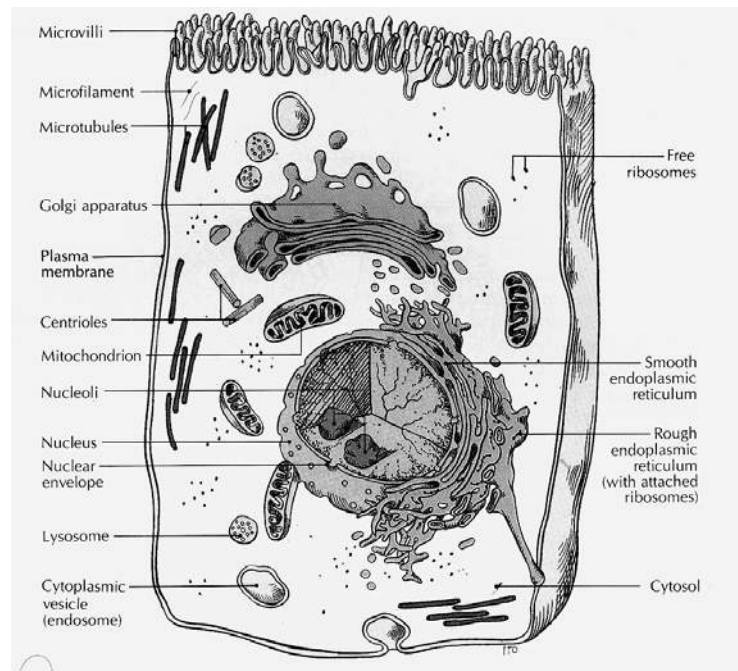
*Plasma (cell) membrane:* it is the outer lining, limiting membrane separating the cell internal parts from extra cellular materials & external environment.

*Cytoplasm:* cytoplasm is the substance that surrounds organelles and is located between the nucleus and plasma membrane

*Organelles*: these are permanent structures with characteristic morphology that are highly specialized in specific cellular activity.

*Inclusions*: they are the secretions and storage products of cells.

Extra cellular materials are also referred to as the matrix, which are substances external to the cell surface.



**Figure: 2.1 structure of a cell** (Source: Carola, R., Harley, J.P., Noback R.C., (1992), Human anatomy and physiology, Mc Graw hill inc, New York, 2<sup>nd</sup> Ed, pp 57)

### 2.1.1 Plasma Membrane

Plasma membrane is a thin outer membrane, which maintains the integrity of the cell. It keeps the cell and its contents separate and distinct from the surrounding. It is a double layered measuring about 4.5 nm and made of phospholipids, cholesterol, glyco-lipid, & carbohydrate (oligosaccharides). The bi-layer is self-sealing. If a needle is injected and pulled out, it automatically seals.

Functions: -

1. Separate the cytoplasm inside a cell from extra cellular fluid.
2. Separate cell from one another
3. Provide an abundant surface on which chemical reaction can occur.
4. Regulate the passage of materials in to and out of cells. It also let some things in and keeps others out. The quality selective permeability

#### **Movement across-cell membrane**

Movements a cross membrane takes place in two ways. These are passive and active movements. Passive movement uses energy whereas active movement consumes energy in the form of ATP.

**Passive movement:** includes

- a. *Simple diffusion*, the random movements of molecules from area of high concentration to the area of low concentration. Example air in alveoli of lung
- b. *Facilitated diffusion*, larger molecules, which are not soluble in lipid need protein channel to pass through the plasma membrane. No direct energy needed. Example: - Amino acid passes through the cell membrane.
- c. *Osmosis*, a special type of diffusion referring to the passage of water through a selectively permeable membrane from an area of high water concentration to lower water concentration.
- d. *Filtration*, small molecules pass through selectively permeable membrane in response to force of pressure. Example: - filtration in the kidney in the process of urine formation.

**Active movements across membranes**

Substances move through a selectively permeable membrane from areas of low concentration on side of a membrane to an area of higher concentration on the other side. This is against concentration gradient. Therefore, it requires energy.

- a) *Active Transport*: till equilibrium substances could move by passive movement. But if equilibrium reached and still more molecules are needed, they must be pumped

through the membrane against concentration gradient. This process requires the use of ATP. One example of such processes is Sodium – potassium pump and calcium pump. In this process all follows similar process. These are molecules bind to carrier protein, molecule- carrier complex pass through the membrane, assisted by an enzyme & ATP and carrier protein returns to its original shape & repeat the process.

- b) *Endocytosis*, pocketing in by plasma membrane. It includes:
- Pinocytosis – cell drinking
  - Receptor – mediated Endocytosis- Endocytosis with the help of receptor.
  - Phagocytosis- cell eating.
- c) *Exocytosis*, opposite to Endocytosis, to remove out undigested particles.

### **2.1.2 Cytoplasm**

Cytoplasm is a matrix or ground substance in which various cellular components are found. It is thick semi transparent, elastic fluid containing suspended particles and a series of minute tubules and filaments that form cytoskeleton. Water constitutes 75-90% of the cytoplasm. It also contains solid components, proteins, carbohydrates, lipids and inorganic substances. The inorganic components exist as solutions

because they are soluble in water. The majority of organic substances however are found as colloids. Colloids are particles that remain suspended in the surrounding medium.

### 2.1.3 Organelles

Organelles are specialized portion of the cell with a characteristic shape that assume specific role in growth, maintenance, repair and control.

- a) *Nucleus*, Oval in shape and is the largest structure in the cell. Contain the hereditary factor in the cell. Hence it controls cell activity & structure. Most cell contain single nucleus but some like matured Red Blood cell do not contain. However Muscle cell contain several nucleuses. The nucleus separated from other cell structure by double membrane called *nuclear membrane*. Pores over the nuclear membrane allow the nucleus to communicate with the cytoplasm. In the nucleus a jelly like fluid that fill the nucleus is *karylymph (neucleoplasm)*, which contain the genetic material called *chromosome*. Nucleus also contain dark, somewhat spherical, non-membrane bound mass called *nucleolus*. It contains DNA, RNA and protein, which assist in the construction of ribosome.
- b) *Ribosome*, tiny granules, composed of Ribosomal RNA (rRNA). They are site of protein synthesis



- c) *Endoplasmic reticulum* is a double membrane channel. It is continuous with the nuclear membrane. It involved in intracellular exchange of material with the cytoplasm. Various products are transported from one portion of the cell to another via the endoplasmic reticulum. So it is considered as intracellular transportation. It is also storage for synthesized molecules. Together with the Golgi complex it serves as synthesis & packaging center.

Endoplasmic reticulum (ER) is divided in to two. These are, granular E.R. Containing granule and involving in synthesis of protein and agranular E.R. that synthesize lipid & involves in detoxification.

- d) *Golgi Complex*, near to the nucleus. It consist 4-8 membranous sacs. It process, sort, pack & deliver protein to various parts of the cell.
- e) *Mitochondria*, a small, spherical, rod shaped or filamentous structure. It generates energy. Each mitochondria posses two membrane, one is smooth (upper) membrane and the other is arranged with series of folds called cristae. The central cavity of a mitochondrion enclosed by the inner membrane is the matrix.
- f) *Lysosomes* appear as membrane enclosed spheres. They are formed from Golgi complexes & have single membrane. They contain powerful digestive (hydrolytic

enzyme capable of breaking down many kinds of molecules. The lysosomal enzyme believed to be synthesized in the granular endoplasmic reticulum and Golgi complex.


- g) *The cyto-skeleton*, the cytoplasm has a complex internal structure consisting of a series of exceedingly small microfilaments, microtubule & intermediate filaments together referred to as the cyto-skeleton.
- h) *Centrosme*, a dense area of cytoplasm generally spherical and located near the nucleus it contain centrioles. It also contains DNA that controls their replication. Centrosmes are made of microtubules, which seam drinking straws. They are Involved in the movement of chromosome during cell division.
- i) *Cilia/flagella*, thread like appendages, which are made of microtubules. When they are beating forms rhythmic movement. They are found in female reproductive organ and upper respiratory tube.

#### **2.1.4 Cell inclusion**

Large and diverse group of chemicals, which are produced by cells, are cell inclusions. It is mainly organic and includes melanin, glycogen & Lipids.

## 2.2 Cells out of control/cancer

Normal human body cells usually divide at a controlled rate required to replace the dying ones and for growth. Cancer cells are different. They lack the controlling mechanism. Cancer occurs when cells grows and divide at abnormal rate & then spread beyond the original site. Some of the risk factors for cancer occurrence are radiation, chemicals, extreme pressure and hormonal therapy.



## Review Questions

- 1) The random movement of molecules from an area of high concentration to an area of lower concentration is called: -
  - a. Diffusion
  - b. Exocytosis
  - c. Facilitated diffusion
  - d. Active transport
  - e. Endocytosis
- 2) The most important structural elements of the cytoskeleton are: -
  - a. Microfilaments
  - b. Vacuoles
  - c. Ribosome
  - d. Asters
  - e. Microtubules
- 3) Mitochondria functions in the synthesis of
  - a. DNA
  - b. mRNA
  - c. ATP
  - d. rRNA
  - e. tRNA
- 4) The nucleolus
  - a. Is the site of ribosomal RNA synthesis
  - b. Has a surrounding structure
  - c. Contains ATP used in chromosome replication
  - d. It is smaller in secretory cell than in non-secretory.
  - e. Specifies the chemical structure of enzymes.
- 5) The Centrosome contains
  - a. Endoplasmic reticulum
  - b. Cilia
  - c. Centrioles
  - d. Flagella
  - e. Vacuoles

# CHAPTER THREE

## TISSUES & MEMBRANES

### Learning Objective

At the end of this chapter, the students should be able to:

- Describe types of tissues
  - a) Epithelial tissue
  - b) Connective tissue
  - c) Nerve tissue
  - d) Muscle tissue
- Explain location and function of tissues in the body
- Discuss membranes of the body

### Selected Key terms:

The following terms are defined in the glossary

Cartilage	Nervous tissue
Connective tissue	Osseous tissue
Epithelial tissue	Serous membrane
Glandular tissue	Synovial membrane
Mucus membrane	Tissue
Muscle tissue	Vascular tissue

### 3.1 TISSUE

Cells are highly organized units. But in multicellular organisms, they do not function in isolation. They work together in-group of similar cells called *tissue*. Tissue is a group of similar cell and their intercellular substance that have a similar embryological origin and function together to perform a specialized activity. A science that deals with the study of a tissue is Histology.

The various tissues of the body are classified in to four principal parts according to their function & structure. These are epithelial, connective, muscular, and Nervous tissue.

#### 3.1.1 Epithelial tissue

Epithelial tissues covers body surface, lines body cavity & ducts and form glands. They are subdivided in to:

- Covering & lining epithelium
- Glandular epithelium

**Covering and lining epithelium:** it forms the outer covering of external body surface and outer covering of some internal organs. It lines body cavity, interior of respiratory & gastro intestinal tracts, blood vessels & ducts and make up along with the nervous tissue (the parts of sense organs for smell,

hearing, vision and touch). It is a tissue from which gametes (egg & sperm) develops.

Covering and lining epithelium are classified based on the arrangement of layers and cell shape.

According to the arrangement of layers covering and lining epithelium is grouped in to:

- a) *Simple epithelium*: it is specialized for absorption, and filtration with minimal wear & tear. It is a single layered
- b) *Stratified epithelium*, it is many layered and found in an area with high degree of wear & tear.
- c) *Pseudo-stratified*, is a single layered but seam to have many layer.

Based on the cell shape covering and lining epithelium is grouped in to:

- a) *Squamous*: - flattened & scale like
- b) *Cuboidal*: - cube shaped
- c) *Columnar*: - tall & cylindrical
- d) *Transitional*: - combination of cell shape found where there is a great degree of distention or expansion, these may be cuboidal to columnar, cuboidal to polyhydral and cuboidal to Squamous

Therefore considering the number of layers and cell shape we can classify covering and lining epithelium in to the following groups:

### **Simple epithelium**

- a) Simple – Squamous epithelium, contain single layer of flat, scale like resemble tiled floor. It is highly adapted to diffusion, osmosis & filtration. Thus, it lines the air sacs of lung, in kidneys, blood vessels and lymph vessels.
- b) Simple – cuboidal epithelium, Flat polygon that covers the surface of ovary, lines the anterior surface of lens of the eye, retina & tubules of kidney
- c) Simple – columnar epithelium, Similar to simple cuboidal. It is modified in several ways depending on location & function. It lines the gastro-intestinal tract gall bladder, excretory ducts of many glands. It functions in secretions, absorption, protection & lubrication.

### **Stratified epithelium**

It is more durable, protects underlying tissues form external environment and from wear & tear.

- a) Stratified Squamous epithelium: In this type of epithelium, the outer cells are flat. Stratified squamous epithelium is subdivided in to two based on presence of keratin. These are Non-Keratnized and Keratinized stratified squamous



epithelium. Non-Keratinized stratified squamous epithelium is found in wet surface that are subjected to considerable wear and tear. Example: - Mouth, tongue and vagina. In Keratinized, stratified squamous epithelium the surface cell of this type forms a tough layer of material containing keratin. Example: skin. *Keratin*, is a waterproof protein, resists friction and bacterial invasion.

b) Stratified cuboidal epithelium, rare type of epithelium. It is found in sweat glands duct, conjunctiva of eye, and cavernous urethra of the male urogenital system, pharynx & epiglottis. Its main function is secretion.

c) Stratified columnar epithelium, uncommon to the body. Stratified columnar epithelium is found in milk duct of mammary gland & anus layers. It functions in protection and secretion.

#### **Transitional epithelium**

The distinction is that cells of the outer layer in transitional epithelium tend to be large and rounded rather than flat. The feature allows the tissue to be stretched without breakage. It is found in Urinary bladder, part of Ureters & urethra.

### **Pseudo stratified epithelium**

Lines the larger excretory ducts of many glands, epididymis, parts of male urethra and auditory tubes. Its main function is protection & secretion

### **3.1.2 Glandular Epithelium**

Their main function is secretion. A gland may consist of one cell or a group of highly specialized epithelial cell. Glands can be classified into exocrine and endocrine according to where they release their secretion.

*Exocrine:* Those glands that empties their secretion in to ducts/tubes that empty at the surface of covering. Their main products are mucous, oil, wax, perspiration and digestive enzyme. Sweat & salivary glands are exocrine glands.

*Endocrine:* They ultimately secrete their products into the blood system. The secretions of endocrine glands are always hormones. Hormones are chemicals that regulate various physiological activities. Pituitary, thyroid & adrenal glands are endocrine.

#### **Classification of exocrine glands**

They are classified by their structure and shape of the secretary portion. According to structural classification they are grouped into:

a) *Unicellular gland*: Single celled. The best examples are goblet cell in Respiratory, Gastrointestinal & Genitourinary system.

b) *Multicultural gland*: Found in several different forms

By looking in to the secretory portion exocrine glands are grouped into

a) *Tubular gland*: If the secretory portion of a gland is tubular.

b) *Acinar gland*: If the secretory portion is flask like.

c) *Tubulo-acinar*: if it contains both tubular & flask shaped secretory portion.

Further more if the duct does not branch it is referred as a simple gland and if it branch's it is compound gland. By combining the shape of the secretory portion with the degree of branching of the duct of exocrine glands are classified in to

- Unicellular
- Multi-cellular
  - Simple tubular
  - Branched tubular
  - Coiled tubular
  - Acinar
  - Branched Acinar

- Compound
  - Tubular
  - Acinar
  - Tubulo-acinar

### **3.1.2 Connective tissue**

Connective tissues of the body are classified into *embryonic connective tissue* and *adult connective tissue*.

#### **Embryonic connective tissue**

Embryonic connective tissue contains mesenchyme & mucous connective tissue. Mesenchyme is the tissue from which all other connective tissue eventually arises. It is located beneath the skin and along the developing bone of the embryo. Mucous (Wharton's Jelly) connective tissue is found primarily in the fetus and located in the umbilical cord of the fetus where it supports the cord.

#### **Adult connective tissue**

It is differentiated from mesenchyme and does not change after birth. Adult connective tissue composes connective tissue proper, cartilage, osseous (bone) & vascular (blood) tissue

a) *Connective tissue proper*, connective tissue proper has a more or less fluid intercellular matrix and fibroblasts. The various forms of connective tissue proper are:

- Loose (areolar) connective tissue, which are widely distributed and consists collagenic, elastic & reticular fibers and several cells embedded in semi fluid intercellular substances. It supports organs, blood vessels & nerves. It also forms subcutaneous layer/superficial fascia/hypodermis.
- Adipose tissue: It is the subcutaneous layer below the skin, specialized for fat storage. Found where there is loose connective tissue. It is common around the kidney, at the base and on the surface of the heart, in the marrow of long bone, as a padding around joints and behind the eye ball. It is poor conductor of heat, so it decrease heat loss from the body
- Dense (Collagenous) connective tissue: Fibers are closely packed than in loose connective tissue. Exists in areas where tensions are exerted in various directions. In areas where fibers are interwoven with out regular orientation the forces exerted are in many directions. This occurs in most fascia like deeper region of dermis, periosteum of bone and membrane capsules. In other areas dense connective tissue adapted tension in one direction and fibers have parallel arrangement. Examples are tendons

and ligaments. Dense connective tissues provide support & protection and connect muscle to bone.

- Elastic connective tissue: Posses freely branching elastic fibers. They stretch and snap back in to original shape. They are components of wall of arteries, trachea, bronchial tubes & lungs. It also forms vocal cord. Elastic connective tissue allows stretching, and provides support & suspension.
- Reticular connective tissue: Lattice of fine, interwoven threads that branch freely, forming connecting and supporting framework. It helps to form a delicate supporting stroma for many organs including liver, spleen and lymph nodes. It also helps to bind together the fibers (cells) of smooth muscle tissue.

#### **b) Cartilage**

Unlike other connective tissue, cartilages have no blood vessels and nerves. It consists of a dense network of collagenous fibers and elastic fibers firmly embedded in chondriotin sulfate. The strength is because of collagenous fibers. The cells of a matured cartilage are called *chondrocyte*. The surface of a cartilage is surrounded by irregularly arranged dense connective tissue called *perichondrium*. Cartilages are classified in to hyaline, fibro & elastic cartilage.

*Hyaline cartilage* is called gristle, most abundant, blue white in color & able to bear weight. Found at joints over long bones as articular cartilage and forms costal cartilage (at ventral end of ribs). It also forms nose, larynx, trachea, bronchi and bronchial tubes. It forms embryonic skeleton, reinforces respiration, aids in free movement of joints and assists rib cage to move during breathing.

*Fibro cartilage*: they are found at the symphysis pubis, in the inter-vertebral discs and knee. It provides support and protection.

*Elastic cartilage*: in elastic cartilage the chondrocyte are located in thread like network of elastic fibers. Elastic cartilage provides strength and elasticity and maintains the shape of certain organs like epiglottis, larynx, external part of the ear and Eustachian tube.

### **c) Osseous tissue (Bone)**

The matured bone cell osteocytes, embedded in the intercellular substance consisting mineral salts (calcium phosphate and calcium carbonate) with collagenous fibers. The osseous tissue together with cartilage and joints it comprises the skeletal system.

**d) Vascular tissue (Blood tissue)**

It is a liquid connective tissue. It contains intercellular substance plasma. Plasma is a straw colored liquid, consists water and dissolved material. The formed elements of the blood are erythrocytes, leukocytes and thrombocytes. The fibrous characteristics of a blood revealed when clotted.

**3.1.3 Muscle tissue**

Muscle tissue consists of highly specialized cells, which provides motion, maintenance of posture and heat production. Classification of muscles is made by structure and function. Muscle tissues are grouped in to skeletal, cardiac and smooth muscle tissue.

- Skeletal muscle tissue are attached to bones, it is voluntary, cylindrical, multinucleated & striated
- Cardiac muscle tissue: It forms the wall of the heart; it is involuntary, uni-nucleated and striated.
- Smooth muscle tissue: located in the wall of hollow internal structure like Blood vessels, stomach, intestine, and urinary bladder. It is involuntary and non-striated.



### 3.1.4 Nervous tissue

Nervous tissue contains two principal cell types. These are the neurons and the neuroglia. Neurons are nerve cells, sensitive to various stimuli. It converts stimuli to nerve impulse. Neurons are the structural and functional unit of the nervous system. It contains 3 basic portions. These are cell body, axons and dendrites. Neuroglia are cells that protect, nourish and support neurons. Clinically they are important because they are potential to replicate and produce cancerous growths.

### 3.2 Membranes

Membranes are thin pliable layers of epithelial and/or connective tissue. They line body cavities, cover surfaces, connect, or separate regions, structures and organs of the body. The three kinds of membranes are mucous, serous and synovial.

- Mucous membranes (mucosa) lines body cavity that opens directly to the exterior. It is an epithelial layer. Mucous membranes line the entire gastro intestine, respiratory excretory and reproductive tracts and constitute a lining layer of epithelium. The connective tissue layer of mucous membrane is lamina propria. To

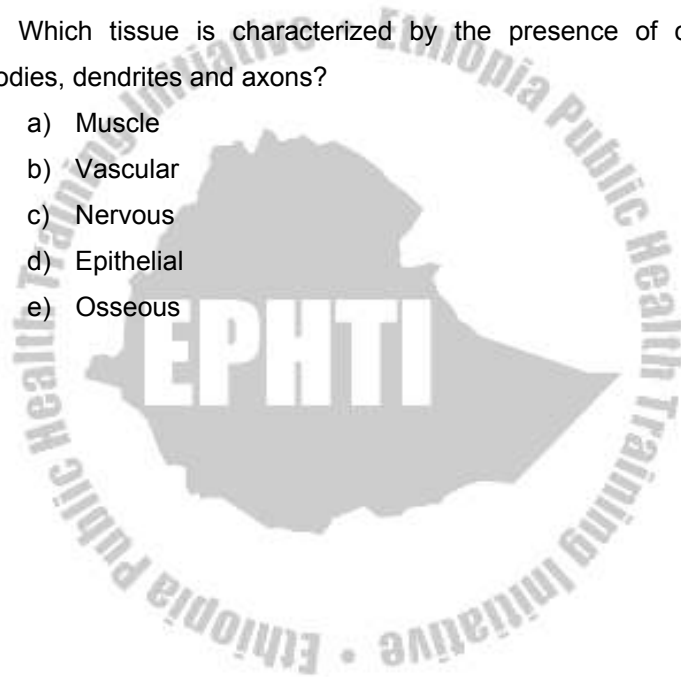
prevent dry out and to trap particles mucous membranes  
secrete mucous.

- Serous membrane / serosa: contains loose connective tissue covered by a layer of mesothelium. It lines body cavity that does not open directly to the exterior. Covers the organs that lie within the cavity. Serosa is composed of parietal layer (pertaining to be outer) and visceral layer (pertaining to be near to the organ). Pleura and pericardium are serous membranes that line thoracic and heart cavity respectively. The epithelial layer of a serous membrane secretes a lubricating fluid called serous fluid. The fluid allows organs to glide one another easily.
- Synovial membrane: Unlike other membranes this membrane does not contain epithelium. Therefore, it is not an epithelial membrane. It lines the cavities of the freely movable joints. Like serous membrane it lines structures that do not open to the exterior. Synovial membranes secrete synovial fluid that lubricates articular cartilage at the ends of bones as they move at joints.

## Review Questions

1. Unicellular glands composed of columnar cells that secrete mucous are known as:-
  - a) Cilia
  - b) Microvilli
  - c) Goblet cell
  - d) Endocrine glands
  - e) Basal cell
2. A group of similar cell that has a similar embryological origin and operates together to perform a specialized activity is called:-
  - a) Organ
  - b) Tissue
  - c) System
  - d) Organ system
  - e) Organism
3. Mucous membranes
  - a) Lines cavities of the body that are not open to the outside
  - b) Secrete thin watery serous fluid
  - c) Cover the outside of such organs as the kidney and stomach
  - d) Are found lining the respiratory & urinary passages
  - e) Are described by none of the above.

4. Which of the following is involuntary and striated?
- a) Skeletal muscle tissue
  - b) Cardiac muscle tissue
  - c) Smooth muscle tissue
  - d) Visceral muscle tissue
  - e) Neural tissue
5. Which tissue is characterized by the presence of cell bodies, dendrites and axons?
- a) Muscle
  - b) Vascular
  - c) Nervous
  - d) Epithelial
  - e) Osseous



# CHAPTER FOUR

## THE INTEGUMENTARY SYSTEM

### Chapter objectives:

At the end of this chapter, the students should be able to

- Describe skin of the human body
- Discuss glands of the skin
- Explain the structure and function of hair
- Discuss about nails

### Selected Key terms:

The following terms are defined in the glossary:

Dermis  
Epidermis  
Eponychium  
Hypodermis  
Hyponychium  
Lunula  
Sebaceous glands  
Sudoriferous glands

The Integumentary system consist the skin and its derivatives. These include hair, nails, and several types of glands.

The system functions in protection, in the regulation of body temperature, in the excretion of waste materials, in the synthesis of vitamin D<sub>3</sub> with the help of sunrays, and in the reception of various stimuli perceived as pain, pressure and temperature.

#### **4.1 Skin**

Skin is the largest organ in the body occupying almost 2m<sup>2</sup> of surface area thickens of 2mm. Skin has 3 main parts. These are the epidermis, dermis and hypodermis.

**Epidermis** is the outer layer of the skin that is made of stratified squamous epithelium. It has no blood supply. Epidermis contains 4-5 strata. These are stratum corneum, lucidium, granulosum, spinosum and basale, Stratum corneum is the outer, dead, flat, Keratinized and thicker layer.

Stratum lucidium is next to stratum corneum. It consists of flat, translucent layers of cells. This stratum found in thick skin only.

Stratum granulosum lies just below stratum lucidium. The cells in this layer are in the process of keratinization.

Stratum spinosum: next down to stratum granulosum. The cells in this stratum have a poly-hydral shape and they are in the process of protein synthesis.

Stratum basale rests on the basement membrane, and it is the last layer of epidermis next to stratum spinosum. Stratum basale together with stratum spinosum constitute stratum germinativum.

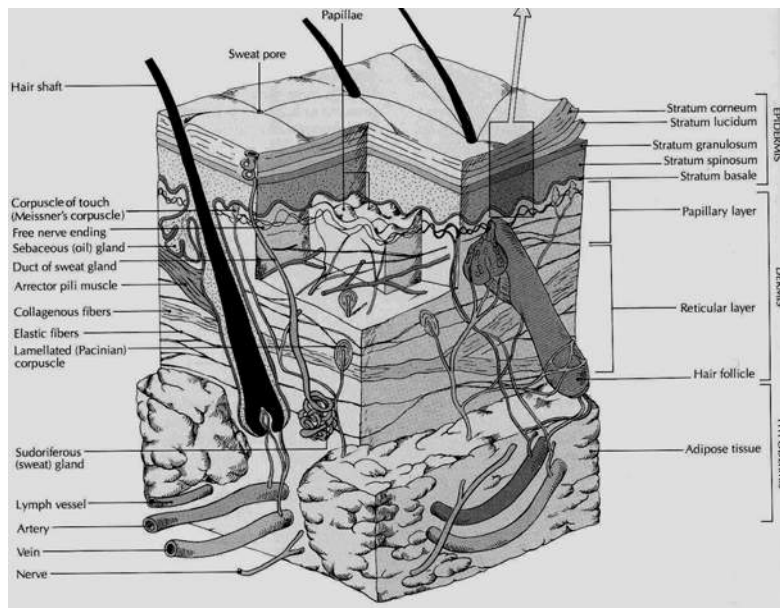
**Dermis / true skin/** a strong, flexible, connective tissue mesh work of collagen, reticular and elastic fibers. Most part of the skin is composed of dermis.

Dermis contains papillary and reticular layers. *Papillary layer* is next to stratum basale of the epidermis. It contains loose connective tissue with in the bundles of collagenous fibers. It also contains loose capillaries that nourish the epidermis. In some areas papillary layer have special nerve endings that serve as touch receptors (meissner's corpuscles). Indentations of papillary layer in the palms and soles reflected over the epidermis to create *ridges*.

*Reticular layer:* next to papillary layer. It is made of dense connective tissue with course of collagenous fiber bundles that crisscross to form a stroma of elastic network. In the reticular layer many blood and lymphatic vessels, nerves, fat cell, sebaceous (oil) glands and hair roots are embedded.

Receptors of deep pressure (pacinian corpuscles) are distributed through out the dermis.

**Hypoderms:** it is found beneath the dermis. It is a subcutaneous layer (under the skin). Hypodermis is composed of loose, fibrous connective tissue, which is richly supplied with lymphatic and blood vessels and nerves. Hypodermis is much thicker than dermis. With in it coils of ducts of sudoriferous (sweat) glands, and the base of hair follicles.



**Figure: 4.1 The skin** (source: Carola, R., Harley,J.P., Noback R.C., (1992), Human anatomy and physiology, Mc Graw hill inc, New York, 2<sup>nd</sup> ed, pp 124)



### 4.1.1 Functions of Skin

1. *Protection:* against harmful microorganisms, foreign material and it prevents excessive loss of body fluid.
2. *Temperature regulation:* with the sweat, heat leaves the body
3. *Excretion:* Small amount of waste products from the body such as urea
4. *Synthesis:* By the action of UV. Vitamin D is synthesized in the skin. Vitamin D is necessary for absorption calcium from intestine.
5. *Sensory reception:* it contains sensory receptors of heat, cold, touch, pressure, and pain.

### 4.1.2 Color of the skin

Skin's color is determined by 3 factors

1. The presence of *melanin* a dark pigment produced by specialized cell called melanocyte
  2. The accumulation of yellow pigment *carotene*.
  3. The *color of blood* reflected through the epidermis
- \* The main function of melanin is to screen out excessive ultraviolet rays.
  - \* All races have some melanin in their skins although the darker races have slightly more melanocyte. The person

who is genetically unable to produce any melanin is an *albino*.

## 4.2 Glands of the Skin

Glands of the skin are the *sudoriferous* and *sebaceous* glands.

### 4.2.1. Sudoriferous /sweat/ glands

Types: Eccrine and Apocrine glands

*Eccrine glands* are small, simple coiled tubular glands distributed over nearly the entire body, and they are absent over nail beds, margins of lips of vulva, tips of penis. Eccrine glands are numerous over the palms and soles. Their secretory portion is embedded in the hypodermis. The sweat they secrete is colorless, aqueous fluid containing neutral fats, albumin, urea, lactic acid and sodium chloride. Its excretion helps body temperature to be regulated.

*Apocrine glands* are odiferous, found at the armpits, in the dark region around nipples, the outer lips of the vulva, and the anal and genital regions. They are larger and deeply situated than eccrine sweat glands. An apocrine sweat gland becomes active at puberty. They respond to stress including sexual activity. The female breasts are apocrine glands that have

become adapted to secrete and release milk instead of sweat. The ceruminous glands in the outer ear canal are also apocrine skin glands.

#### **4.2.2 Sebaceous (Oil) glands**

Sebaceous glands are simple branched alveolar glands found in the dermis. Their main functions are lubrication and protection. They are connected to hair follicles and secrete oily secretion called *sebum*. It is a semi fluid substance composed of entirely lipids. It functions as a permeability barrier, an emollient (skin softening) and a protective agent against bacteria and fungi. This type of gland is found all over the body except in the palms and soles. Acne vulgaris is a condition when there is over secretion of sebum, which may enlarge the gland and plug the pore.

#### **4.3 Hair**

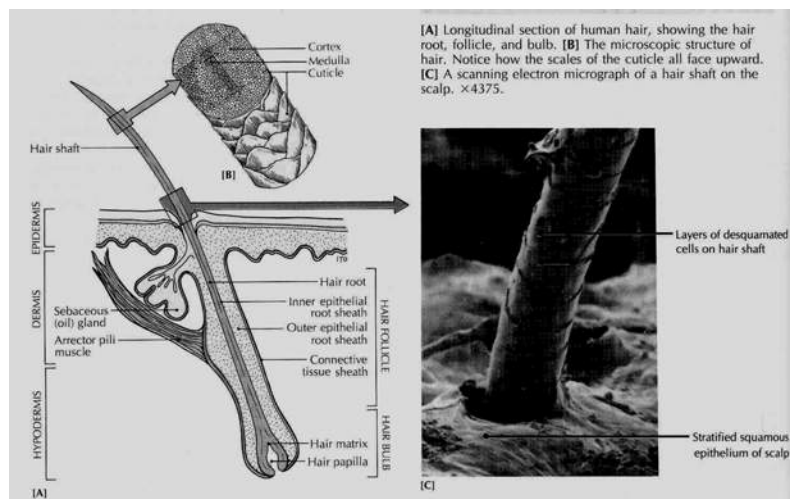
Hair is composed of keratinized threads of cells, which develop from the epidermis. Because it arises from the skin, it is considered an appendage of the skin. It covers the entire body except the palms, soles, lips, tip of penis, inner lips of vulva and nipples.

### 4.3.1 Function

- *Insulation* against cold in scalp
- *Against glare* in eye brows
- *Screen* against foreign particles (eye lashes)
- In the nostrils *trap* dust particles in the inhaled air
- *Protect* openings from foreign particles.

### 4.3.2 Structure of Hair

Hair has two parts, *the shaft* the part above skin and *the root* embedded in the skin. Hair consist epithelial cell arranged in



**Figure: 4.2 Structure the Hair** (source: Carola, R., Harley,J.P., Noback R.C., (1992), Human anatomy and physiology, Mc Graw hill inc, New York, 2<sup>nd</sup> ed, pp132)

y

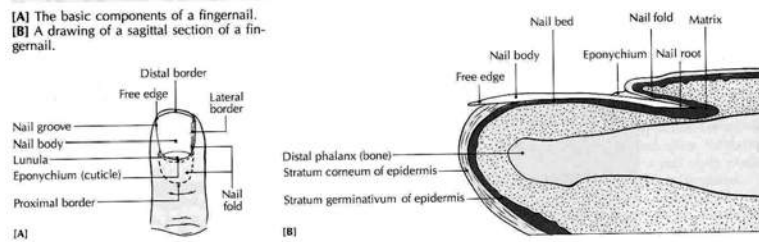


The lower portion of the root, located in the hypodermis enlarges to form *the bulbs*. The bulb is composed of the matrix of epithelial cells. The bulb pushes in ward along its bottom to form a papilla of blood rich connective tissue. Part of the hair follicle is attached with the bundle of smooth muscle about halfway down the follicle. These are *arrector pili muscles*. When it contracts in pulls the follicles and its hair to an erect position producing goose bump. Hair grows and when it finishes its growth sheds. The growth rate of hair depends on its position. The fastest growth rate occurs over

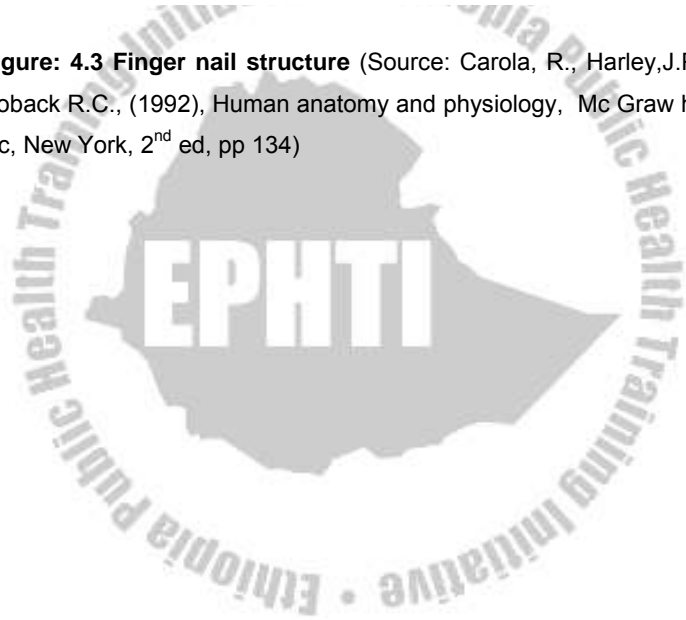
the scalp of women aged 16 to 24 years. Scalp hair grows 0.4 m.m per day (an average scalp contain 125.000 hairs). Hair sheds when it growth is complete. Just before a hair is to be shed, the matrix cell gradually become inactive and eventually dies.

#### 4.4 Nail

Nails, like hair are modifications of the epidermis. They are made of hard keratin. Nails are composed of flat, cornified plates on the dorsal surface of the distal segment of the fingers and toe. The proximal part of nail is *lunula*, which is white in its color because of the capillaries underneath are covered by thick epithelium. Nail has *body* and *root*. The body is the exposed part and the root is hidden under the skin. The nail ends with a free edge that overhangs the tip of the fingers. Epithelial layer covering underneath of the fore-hang nail is *hyponychyem*. The nail rests on an epithelial layer of skin called nail bed. The thicker layer of skin beneath the nail root is the *matrix*, where new cells are generated. Nail grows 0.5 m.m a week. Thin layers of epidermis called *eponychium* originally cover the growing nail. Our nail protects our fingers and toes. It also allows picking up and grasping objects as well we use them to scratch.



**Figure: 4.3 Finger nail structure** (Source: Carola, R., Harley, J.P., Noback R.C., (1992), Human anatomy and physiology, Mc Graw hill inc, New York, 2<sup>nd</sup> ed, pp 134)

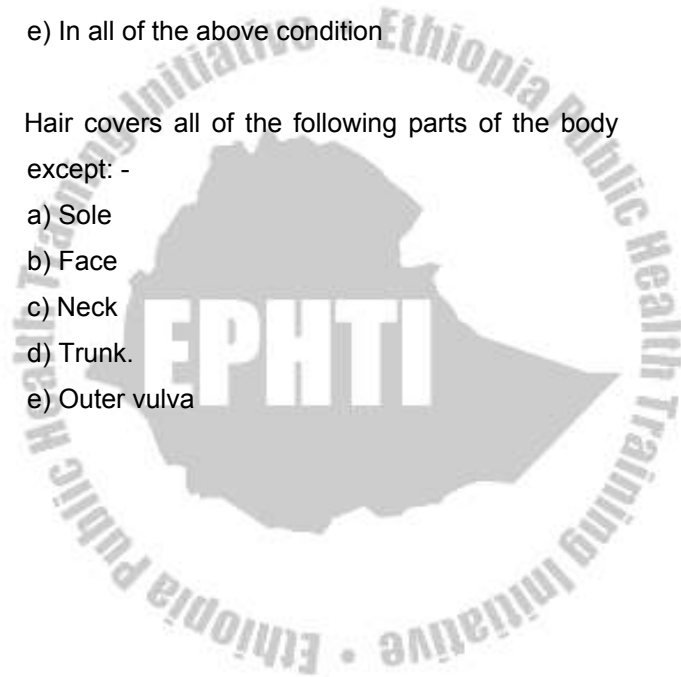


## Review Questions

1. Which of the following skin layers undergoes cellular regeneration?
  - a) Stratum basale
  - b) Stratum spinosum
  - c) Stratum granulosum
  - d) a and b only
  - e) a, b and c
  
2. Which of the following is /are found in the reticular layer of the skin?
  - a) Blood and lymph vessels
  - b) Nerves
  - c) Sensory nerve endings
  - d) Sebaceous glands
  - e) All of the above
  
3. Skin gets its color from
  - a) Carotene
  - b) Underlying blood vessels
  - c) Melanin
  - d) a and b only
  - e) a, b and c



4. Sudoriferous glands secrete their secretion in response to:
- a) Physiological process
  - b) Heat
  - c) Stress
  - d) Sexual experience
  - e) In all of the above conditions
5. Hair covers all of the following parts of the body except: -
- a) Sole
  - b) Face
  - c) Neck
  - d) Trunk
  - e) Outer vulva



# CHAPTER FIVE

## THE SKELETAL SYSTEM

### Learning Objective

At the end of this chapter, the students should be able to:

- Discuss bone tissue.
- Explain the general feature and surface markings of bones.
- Discuss skeleton and its function:
  - Axial skeleton
  - Appendicular skeleton.
- Explain joints, types of joints and their movements

### Selected Key terms

The following terms are defined in the glossary:

Appendicular skeleton	Myeloid tissue
Articulation	Orbits
Axial skeleton	Ossicles
Bone cell	Ossification
Cranium	Perichondrium

Diaphysis	Periosteum
Endosteum	Skull
Epiphyseal plate	Surface marking
Epiphysis	Sutures
Fontanel	Tendons
Intervertebral disc	Thorax
Metaphysis	Vertebrae

The word skeleton comes from the Greek word *skeleton* meaning “dried up”. It is strong yet light adapted for its function of body protection and motion. The skeletal system includes bones, joints, cartilages and ligaments. The joint give the body flexibility and allow movements to occur. But from structural point of view, the human skeletal system consists of two main types of supportive connective tissue, *bone and cartilage*.

**Functions of the skeletal system:**

1. **Support:** it forms the internal framework that supports and anchors all soft organs.
2. **Protection:** bones protect soft body organs.
3. **Movement:** skeletal muscles attached to the skeletal system use the bone to levers to move the body and its part.

4. **Storage:** fat is stored in the internal cavities of bones. Bone itself serves as a storehouse of minerals. The most important being calcium and phosphorus.
5. **Blood cell formation:** it occurs within the marrow cavities of certain bones.

## 5.1 Bone

Bone (osseous) is specialized connective tissue that has the strength of cast iron and lightness of pinewood. Living bone is not dry, brittle or dead. It is a moist changing, productive tissue that is continually resorbed, reformed and remodeled.

### 5.1.1 Types of bone

*Long bone*, are called long as its length is greater than its width. The most obvious long bones are in the arm and leg. They act as levers that pulled by contraction of muscles.

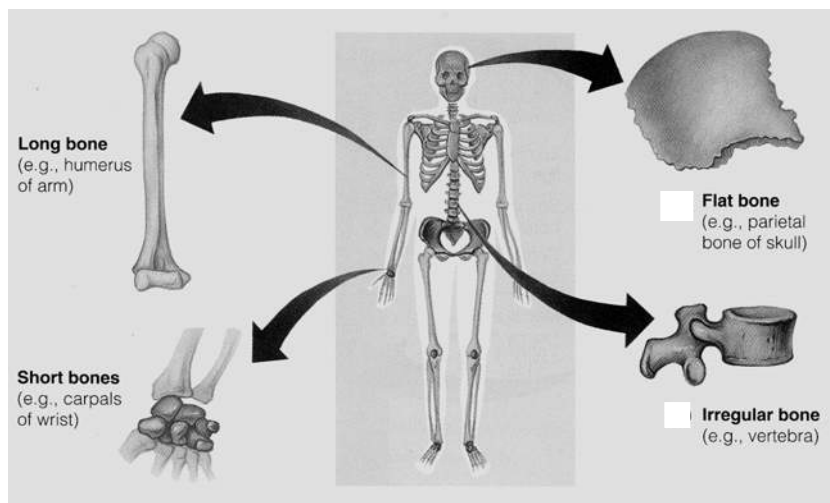
*Short bones* are about equal in length, width and thickness, which are shaped with regular orientation. They occur in the wrist and ankle.

*Flat bones* are thin or curved more often they are flat. This includes ribs, scapulae, sternum and bone of cranium.

*Irregular bones*, they do not fit neatly into any other category. Examples are the vertebral, facial, and hipbone.

*Sesamoid bones* are small bones embedded with in certain tendons, the fibrous cord that connects muscle to bones. Typical sesamoid bones are patella and pisiform carpal bone, which are in the tendon of quadriceps femoris and flexor carp ulnaris muscle respectively.

*Accessory bones* are most commonly found in the feet. They usually occur in the developing bone and do not fuse completely. They look like extra bones or broken on X-ray. *Sutural (wormian)* bones are examples of accessory bones.



**Figure: 5.1 Types of bones** (Source: Elaine n. MARIEB, (2000), Essentials of human anatomy and physiology, Addison welsey longman inc., San Francisco, 6<sup>th</sup> Ed)

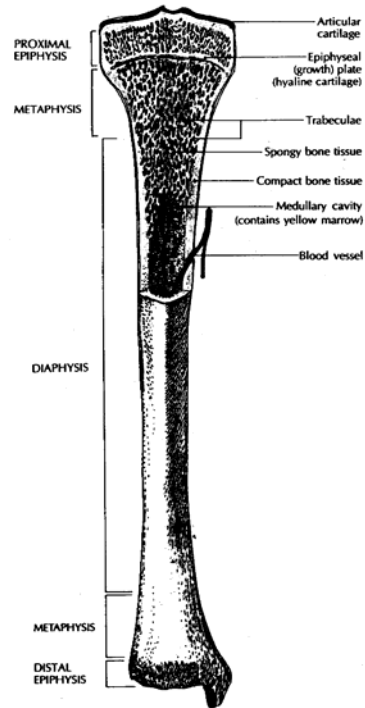
### 5.1.2. Gross anatomy of a typical long bone

You can take **Tibia** (in the leg) one of the longest bones in the body.

In adults it have:  
*Diaphis*, the tubular shaft, hallow cylindrical with walls of compact bone tissue. The center of the cylinder is the medullary cavity, which is filled with marrow.

*Epiphysis* is roughly spherical end of the bone. It is wider than the shaft. Flat and irregular bones of the trunk and limbs have many epiphysis and the long bones of the finger and toe have only one epiphysis.

*Metaphysis* is the part separating diaphysis from epiphysis. It is made up of epiphyseal plate and adjacent bony trabeculae of cancellous bone tissue.



**Figure: 5.2 Typical long bone**  
(Source: Carola, R., Harley, J.P., Noback R.C., (1992), Human anatomy and physiology, Mc Graw hill inc, New York, 2<sup>nd</sup> ed, pp 145)

*Epiphyseal plate* is a thick plate of hyaline cartilage, which provides the framework of synthesis of the cancellous bone tissue within metaphysis.

- The medullary cavity running through the length of the diaphysis contains *Yellow marrow*.
- The porous latticework of the spongy epiphyses is filled with *red bone marrow*. The red marrow also known as *myeloid tissue*

*Endosteum* is the lining the medullary cavity of compact bone tissue and covering the trabeculae of spongy bone tissue.

*Periosteum*: it is covering the outer surface of the bone. It is absent at joints and replaced by articular cartilage.

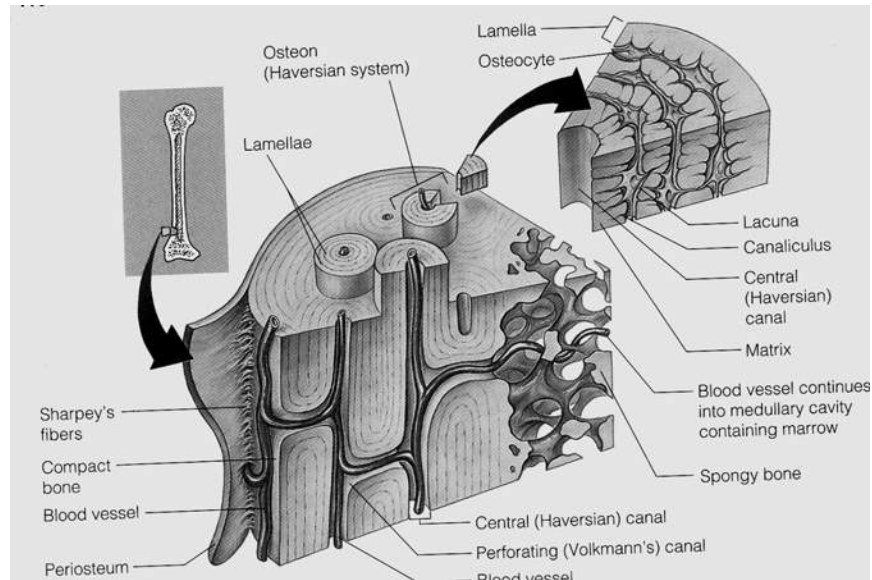
### **5.1.3 Bone (Osseous) Tissue**

Bone tissue is composed of cells embedded in a matrix of ground substances and fibers. It is more rigid than other tissues because it contains inorganic salts mainly calcium phosphate & calcium carbonate. A network of collagenous fibers in the matrix gives bone tissue its strength and flexibility. Most bones have an outer sheet of compact bone tissue enclosing an interior spongy bone tissue.

*Compact bone tissue* forms the outer sheet of a bone. It is very hard and dense. It appears to naked eye to be solid but not. Compact bone tissue contains cylinders of calcified bone known as *osteons (Haversian system)*. Osteons are made up of concentric layers called *lamellae*, which are arranged seemingly in wider and wider drinking straws. In the center of the osteons are *central canals (haversian canal)*, which are longitudinal canals that contains blood vessels, nerves and lymphatic vessels. Central canals, usually have branches called *perforating canals /volkmann's canal* that run at right angle to central canal extending the system of nerves and vessels out ward to periosteum and to endosteum. *Lacunae* (Little spaces) that houses osteocytes (bone cells) are contained in lamella. Radiating from each lacuna are tiny canaliculi containing the slender extensions of the osteocytes where nutrients and wastes can pass to and from central canal.

*Spongy (cancellous) Bone tissue* is in the form of an open interlaced pattern that withstands maximum stress and supports in shifting stress. *Trabeculae* are tiny spikes of bone tissue surrounded by bone matrix that has calcified.





**Figure: 5.3 Compact bone tissues** (Source: Elaine n. MARIEB, (2000), Essentials of human anatomy and physiology, Addison welsey longman inc., San Francisco, 6<sup>th</sup> Ed)

### Bone Cells

Bone contain five types of cells

- a) *Osteogenic (osteoprogenitor) cells*: these are small spindle shaped cell. They found mostly in the deepest layer of periosteum and endosteum. They have high mitotic potential and can be transformed into bone forming cells (osteoblasts).
- b) *Osteoblasts* are found in the growing portion of bone including periosteum. They are able to synthesize and

secrete un-mineralized ground substance, act as pump cell to move calcium and phosphate in and out of bone tissue.

- c) *Osteocytes* are the main cell of fully developed bones. They have a cell body that occupies a lacuna. Osteocytes are derived from osteoblasts. They together with osteoclasts play an important role of homeostasis by helping to release calcium.
- d) *Osteoclasts* are multinuclear giant cell, which are found where bone is resorbed during its normal growth. Osteoclasts are derived from white blood cells called monocytes.
- e) *Bone - lining cells* are found on the surface of most bones in the adult skeleton. They are believed to be derived from osteoblast that ceases their physiological activity.

### **5.1.5 Developmental Anatomy and Growth of Bones**

Bones develop through a process known as *Ossification*. Bone in embryo develops in two ways: *Intra-membranous ossification*, If bone develops directly from mesenchymal tissue. Examples are vault of the skull, flat bones and part of the clavicle. In this type of ossification development continues rapidly from the center. *Endochondrial Ossification*, When bone tissue develops by replacing hyaline cartilage. The

cartilage it self do not converted into bone but the cartilage is replaced by bone through the process. Endochondrial ossification produces long bones and all other bones not formed by intra-membranous ossification.

**Function of bone**

- Supportive and protection of internal organs.
- The store house and main supply of reserve calcium and phosphate.
- The manufacture of red and white blood cell.

**Table 5.1 Comparison between bone and cartilage**

(Source: Carola, R., Harley,J.P., Noback R.C., (1992), Human anatomy and physiology, Mc Graw hill inc, New York, 2nd ed, pp 153)

Feature	Bone	Cartilage
Components	Bone cells substances component	Ground mineral Cartilage cell chondrocyte Collagenous fiber Ground substances
Locations of cell	In lacunae	In lacunae
Outer covering	Periosteum	Perichondrium
Derivation	Mesenchyme	Mesenchyme
Blood vessels	Contain B/V	Has no B/v
Strength	Stronger than cartilage	Not strong as bone
Nutrients	By capillaries to cell by diffusion Through canaliculi	From tissue fluid by diffusion

## 5.2 The Skeleton

### General features and surface markings

Looking to the bone reveals the surface is not smooth but scarred with bumps, holes and ridges. These are surface markings where muscles, tendons and ligaments attached, blood & lymph vessels and nerves pass.

### Depression and openings

*Fissure* narrow, cleft like opening between adjacent parts of bone. Example: Supra of orbital fissure.

*Foramen*, a bigger, round opening. Example: Foramen magnum.

*Meatus*: a relatively narrow tubular canal. Example: External auditory meatus

*Groves and sulcus*: are deep furrow on the surface of a bone or other structure.

Example: Inter-vertebral and radial groves of humers.

*Fossa*: shallow depressed area. Example: Mandibular fossa.

### Processes that form joints

*Condyle* / knuckle like process/ concave or convex. Example Medial condyle of femur *Head, expanded*, rounded surface at proximal end of a bone often joined to shaft by a narrowed neck. Example: Head of femur

*Facet*: small, flat surface. Example: Articular facet of ribs.

**Process to which tendons, ligaments and other  
Connective tissue attach**

*Tubercle*: it is a knob like process. Example: Greater tubercle of humerus.

*Tuberosity*: it is large, round roughened process. Example: ischeal tuberosity.

*Trochanter*: it is a large, blunt projection found only on femur

*Crest* is a prominent ridge. Example: Iliac crest.

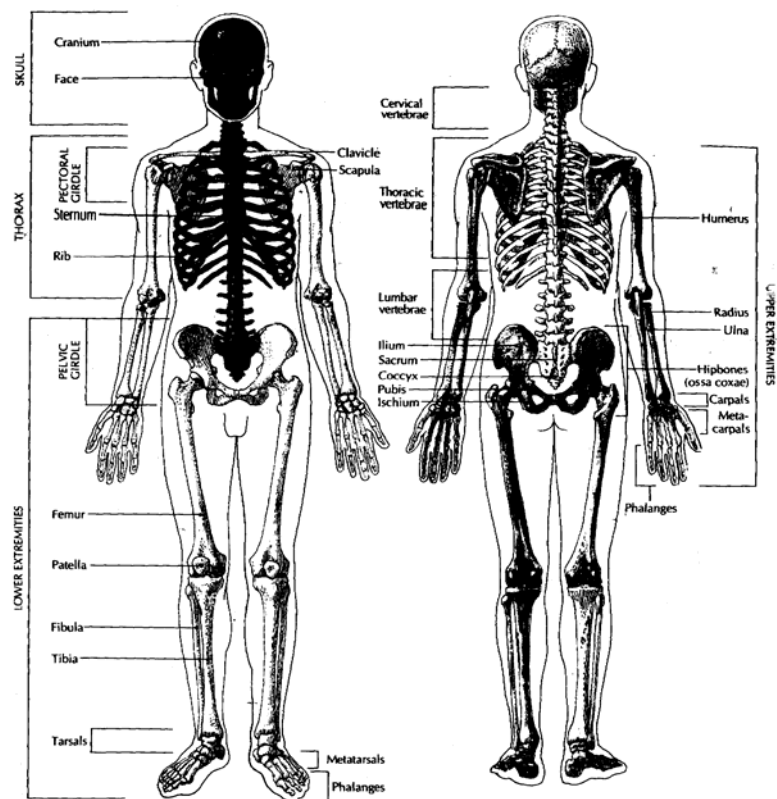
*Line*: it is a less prominent ridge than a crest.

*Spinous process (spine)* is a sharp, slender process. Example Ischeal spin

*Epicondyle* is a prominence above condyle. Example medial Epicondyle of Femur

**5.2.2 Division of the skeletal system**

The Adult human skeletons have 206 named bones that are grouped in to two principal parts. These are the axial and appendicular skeleton. *The Axial skeleton* consist bones that lie around the axis. And *the appendicular skeleton* consist bones of the body out of the axial group. These are appendages. Upper & lower extremities and bones of girdles are grouped under appendicular skeleton.



**Figure: 5.4 Axial and Appendicular skeleton** (Source: Carola, R., Harley, J.P., Noback R.C., (1992), Human anatomy and physiology, Mc Graw hill inc, New York, 2<sup>nd</sup> ed, pp 166)

**Table 5.2** Divisions of The Adult Skeleton (206 Bones)

AXIAL SKELETON		APPENDICULAR SKELETON	
<b>Skull (29 bones)*</b>		<b>Upper extremities (64 bones)</b>	
Cranium	8	Pectoral (shoulder) girdle	4
Parietal (2)		Clavicle (2)	
Temporal (2)		Scapula (2)	
Frontal (1)		<b>Arm #</b>	2
Ethmoid (1)		Humerus (2)	4
Sphenoid (1)		<b>Forearm</b>	
Occipital (1)		Ulna (2)	
<b>Face</b>	14	Radius (2)	
Maxillary (2)		<b>Wrist</b>	16
Zygomatic (molar) (2)		Carpals (16)	
Lacrimal (2)		<b>Hand and fingers</b>	38
Nasal (2)		Metacarpals (10)	
Inferior nasal conchii (2)		Phalanges (28)	
Palatine (2)		<b>Lower extremities (62 bones)</b>	
Mandible (1)		Pelvic girdle	2
Vomer (1)		(Fused ileum, ischium, pubis)	
<b>Ossicles of ear</b>	6	<b>Thigh</b>	4
Malleus (hammer) (2)		Femur (2)	
Incus (anvil) (2)		Patella (2)	
Stapes (stirrup) (2)		<b>Leg</b>	4
Hyoid	1	Tibia (2)	
<b>Vertebral column (26 bones)</b>		Fibula (2)	
Cervical vertebrae	7	<b>Ankle</b>	14
Thoracic vertebrae	12	Tarsals (14)	
Lumbar vertebrae	5	<b>Foot and toes</b>	38
Sacrum (5 fused bones)	1	Metatarsals (10)	
Coccyx (3- 5 fused bones)	1	Phalanges (28)	
<b>Thorax (25bones)</b>			
Ribs	24		
Sternum	1		
Total axial bones	80	Total Appendicular bones	126

\* The number of skull bones is sometimes listed as 22, when the Ossicles of the ears (6 bones) and the single hyoid bone is counted separately. Technically, the hyoid bone is not part of the skull.

+The thoracic vertebrae are sometimes included in this category.

# Technically, the term arm refers to the upper extremity between the shoulder and elbow; the forearm is between the elbow and wrist. The upper part of the lower extremity, between the pelvis and knee, is the thigh; the leg is between the knees and ankle.

### **5.2.3 The Axial skeleton**

#### **5.2.3.1 The skull**

It contains 22 bones. The skull rests on the superior of vertebral column. It is composed of cranial and facial bones.



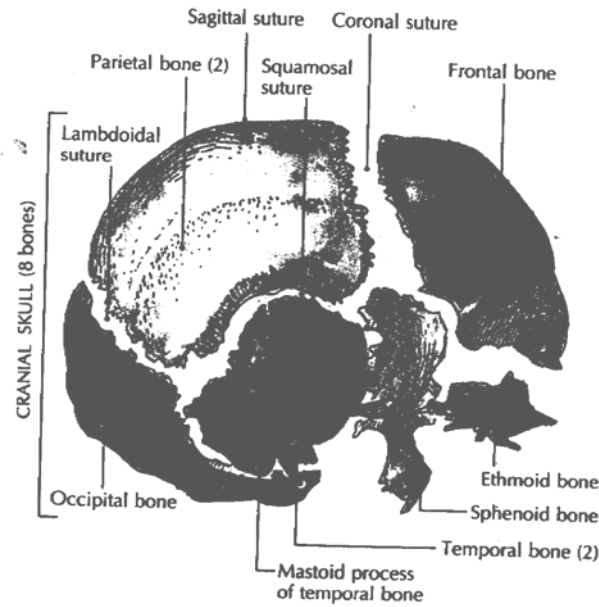
**Table 5.3 Description and function of Cranial Bones**

(Source: Carola, R., Harley, J.P., Noback R.C., (1992), Human anatomy and physiology, Mc Graw hill inc, New York, 2<sup>nd</sup> ed, pp 170)

<b>Bone</b>	<b>Description and function</b>
Ethmoid (1)	Base of cranium, anterior to body of sphenoid. Made up of horizontal, cribriform plate, median perpendicular plate, paired lateral masses; contains ethmoidal sinuses, crista galli, superior and middle conchae. Forms roof of nasal cavity and septum, part of cranium floor; site of attachment for membranes covering brain.
Frontal (1)	Anterior and superior parts of cranium, forehead, brow areas. Shaped like large scoop; frontal squama forms forehead; orbital plate forms roof of orbit; supraorbital ridge forms brow ridge; contains frontal sinuses, supraorbital foramen. Protects front of brain; contains passageway for nerves, blood vessels.
Occipital (1)	Posterior part of cranium, including base. Slightly curved plate, With turned- up edges; made up of squamous, base, and two lateral parts; contains foramen magnum, occipital condyles, hypo-glossal canals, atlanto-occipital joint, external occipital crest and protuberance. Protects posterior part of brain; forms foramina for spinal cord and nerves; site of attachment for muscles, ligaments.
Parietal (2)	Superior sides and roof of cranium, between frontal and occipital bones. Broad, slightly convex plates; smooth exteriors and internal depressions. Protect top, sides of brain, passageway for blood vessels.
Sphenoid (1)	Base of cranium, anterior to occipital and temporal bones. Wedge-shaped; made up of body, greater and lesser lateral wings, pterygoid processes; contains sphenoidal sinuses, sella turcica, optic foramen, superior orbital fissure, foramen

ovale, foramen rotundum, foramen spinosum Forms anterior part of base of cranium; houses pituitary gland; contains foramina for cranial nerves, meningeal artery to brain.

Temporal (2) Sides and base of cranium at temples. Made up of squamous, petrous, tympanic, mastoid areas; contain zygomatic process, mandibular fossa, ear Ossicles, mastoid sinuses. Form temples, part of cheekbones; articulate with lower jaw; protect ear ossicles; site of attachments for neck muscles.



**Figure: 5.5 Lateral view of cranial skull** (source: Carola, R., Harley, J.P., Noback R.C., (1992), Human anatomy and physiology, Mc Graw hill inc, New York, 2<sup>nd</sup> ed, pp 170)

### **Sutures**

Meaning to stitch, are immovable joint found between skull bones. There are four main sutures in the skull.

- a) *Coronal suture*: between the frontal & the two-parital bone.
- b) *Sagital suture*: between the two parietal bones.
- c) *Lambdoidal suture*: between parietal & occipital bone.
- d) *Squamosal suture*: between parietal bone and temporal bone.

### **Fontanels**

The skeleton of a newly formed embryo consist cartilage or fibrous membrane structures, which gradually replaced by bone the process is called *ossification*. At birth membrane filled spaces on the skull are called fontanel. They are found between cranial bones.

#### *Function*

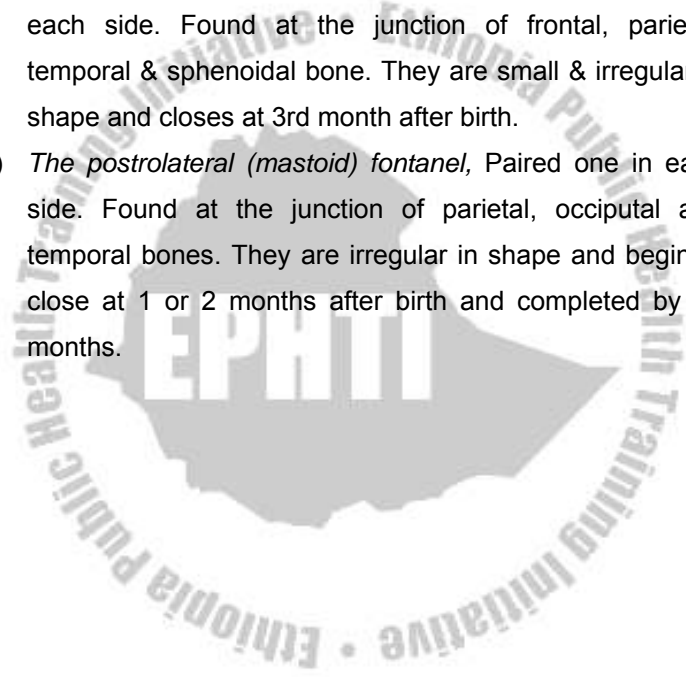
- They enable skull of the fetus to compress as it pass through the birth canal
- Permit rapid growth of brain during infancy
- Serves as a landmark (anterior fontanel) for withdrawal of blood from the superior sagital sinus
- Aid in determination of fetal position prior to birth.

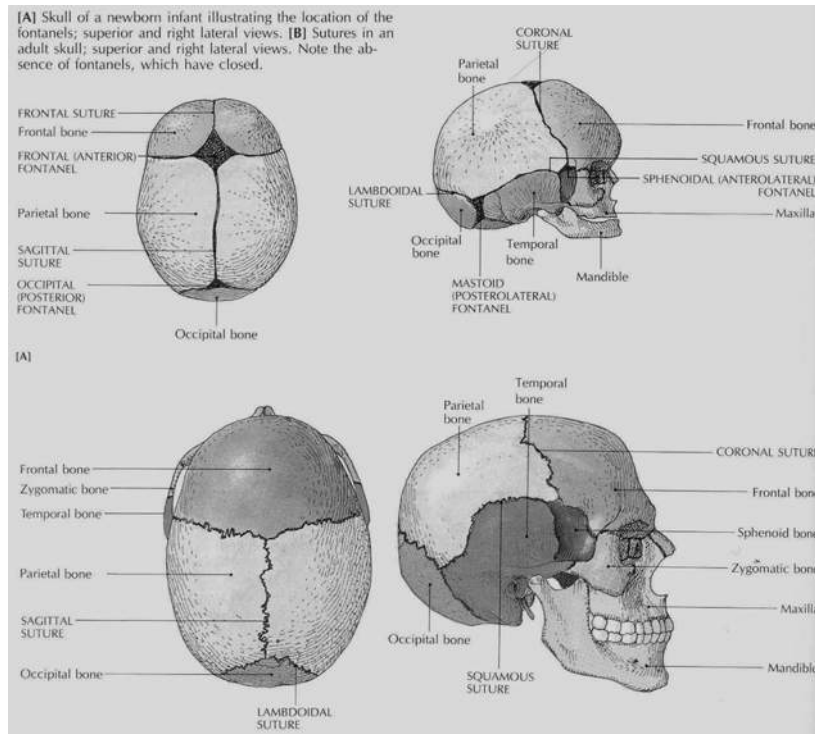
In the skull of the fetus there are 6 prominent fontanels:

- a) *The Anterior (frontal) fontanel*, between angle of two parietal bones & segment of the frontal bone. It is diamond

shaped and is the largest fontanel. It closes 18 to 24 months after birth.

- b) *The posterior (occipital) fontanel*, between parietal & occipital bone. It is also diamond shaped but smaller than the anterior fontanel. It closes 2 months after birth.
- c) *The Antrolateral (sphenoidal) fontanel*, they are pair, one in each side. Found at the junction of frontal, parietal, temporal & sphenoidal bone. They are small & irregular in shape and closes at 3rd month after birth.
- d) *The postrolateral (mastoid) fontanel*, Paired one in each side. Found at the junction of parietal, occipital and temporal bones. They are irregular in shape and begin to close at 1 or 2 months after birth and completed by 12 months.





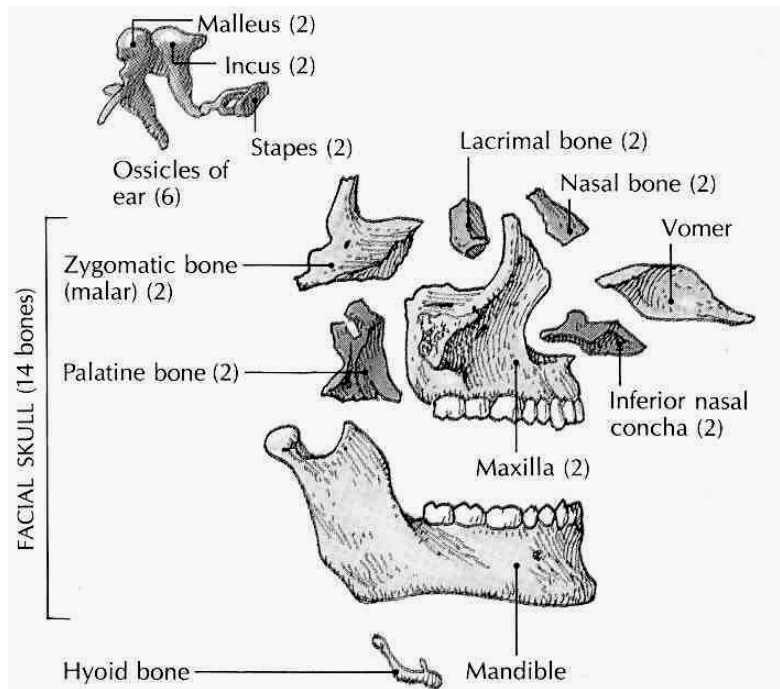
**Figure: 5.6 Sutures and Fontanels** (Source: Carola, R., Harley, J.P., Noback R.C., (1992), Human anatomy and physiology, Mc Graw hill inc, New York, 2<sup>nd</sup> ed, pp 172)

**Table 5.4: Description and function of Facial bones**

(source: Carola, R., Harley, J.P., Noback R.C., (1992), Human anatomy and physiology, Mc Graw hill inc, New York, 2<sup>nd</sup> ed, pp 171)

<b>Bone</b>	<b>Descriptions and function</b>
Inferior nasal	Lateral walls of nasal cavities, below superior and middle
Conchii (2)	conchae of Ethmoid bone. Thin, cancellous, shaped like curved leaves.
Lacrimal (2)	Medial wall of orbit, behind frontal process of maxilla. Small, thin, rectangular; contains depression for lacrimal sacs, nasolacrimal tear duct.
Mandible (1)	Lower jaw, extending from chin to mandibular fossa of temporal bone. Largest, strongest facial bone; horseshoe-shaped horizontal bony with two perpendicular rami; contains tooth sockets, coronoid, condylar, alveolar processes, mental foramina. forms lower jaw, part of temporomandibular joint; site of attachment for muscles.
Maxillae (2)	Upper jaw and anterior part of hard palate. Made up of zygomatic, frontal, palatine, alveolar processes; contain infraorbital foramina, maxillary sinuses, tooth sockets. Form upper jaw, front of hard palate, part of eye sockets.

Nasal (2)	Upper bridge of nose between frontal processes of maxillae. Small, oblong; attached to a nasal cartilage. Form supports for bridge of upper nose.
Palatine (2)	Posterior part of hard palate, floor of nasal cavity and orbit; posterior to maxillae. L-shaped, with horizontal and vertical plates; contain greater and lesser palatine foramina. Horizontal plate forms posterior part of hard palate; vertical plate forms part of wall of nasal cavity, floor of orbit.
Vomer (1)	Posterior and inferior part of nasal septum. Thin, shaped like plowshare. Forms posterior and inferior nasal septum dividing nasal cavities.
Zygomatic (2)	Cheekbones below and lateral to orbit. Curved lateral part of (molar) cheekbones; made up of temporal process, zygomatic arch; contain zygomatico-facial and zygomatico-temporal foramina. form cheekbones, outer part of eye sockets.
Hyoid(1)	Below root of tongue, above larynx. U-shaped, suspended from styloid process of temporal bone; site of attachment for some muscles used in speaking, swallowing.
Ossicles of ear (6)	Inside cavity of petrous portion of temporal bone. Tiny bones Incus(2) shaped like anvil, hammer, stirrup, articulating with one another malleus (2) and attached to tympanic membrane. Convey sound vibrations stapes (2) from eardrum to oval window (see Chapter 16).



**Figure: 5.7 Lateral separated view of facial skull, ear ossicles and hyoid bone** (source: Carola, R., Harley, J.P., Noback R.C., (1992), Human anatomy and physiology, Mc Graw hill inc, New York, 2<sup>nd</sup> ed, pp 171)

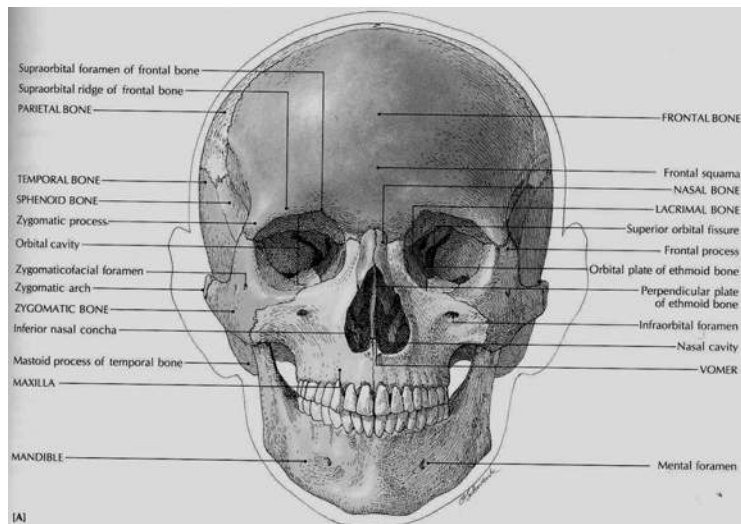
### Orbits

A pyramid shaped space that contains the eyeball & associate structures. It is formed by bones of the skull. Orbit has four walls and apex:



- The roof of the orbit consists of parts of the frontal & sphenoid bone.
- The lateral wall is formed by portions of zygomatic and sphenoid bone.
- The floor of the orbit is formed by parts of the maxilla, zygomatic and palatine bone.
- The medial wall is formed by portion of the maxilla, lacrimal, ethmoid & sphenoid bone.

In the orbit there are openings that pass structures. Some of the principal openings and the structures passing through are: *Optic foramen (canal)* passes optic nerve. *Superior orbital fissure* passes supra orbit nerve and artery. *Inferior orbital fissure* passes maxillary branch of trigeminal and zygomatic nerve and infra orbital vessel. *Supra orbital foramen (notch)* passes oculomotor, trochlear, ophthalmic branch of trigeminal and abducent nerves. *Canal for naso lacrimal duct* passes naso lacrimal duct.



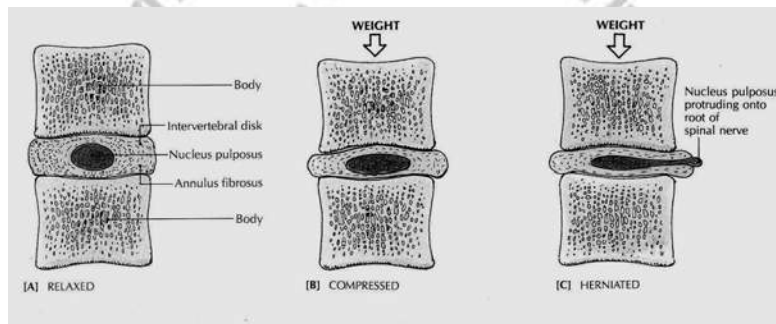
**Figure: 5.8 Skull anterior views, and the orbital cavity** (source: Carola, R., Harley, J.P., Noback R.C., (1992), Human anatomy and physiology, Mc Graw hill inc, New York, 2<sup>nd</sup> ed, pp 173)

### The vertebral column

The vertebral column together with the sternum & ribs constitutes the skeleton of the trunk of the body. It composes 2/5th of the height of the body and has average length in male of 71 c.m. and in female 61 c.m. The adult vertebral column contains 26 vertebrae. Prior to fusion of sacral & coccygeal vertebrae the total number is 33. It is a strong and flexible to either direction & rotated on it self. Encloses & protect spinal cord, supports the head and serves as a point of attachment for the ribs & muscles of the back.

### Inter vertebral discs

Between adjacent vertebrae from 1<sup>st</sup> to sacrum there are inter vertebral discs. They are fibro-cartilaginous. Each disc is composed of the outer fibrous ring consisting fibro-cartilage called *annulus fibrosis* and the inner soft, pulpy highly elastic structure called the *nucleus pulposus*. The disc permits various movement of the vertebral column, absorb shock and form a strong joint.



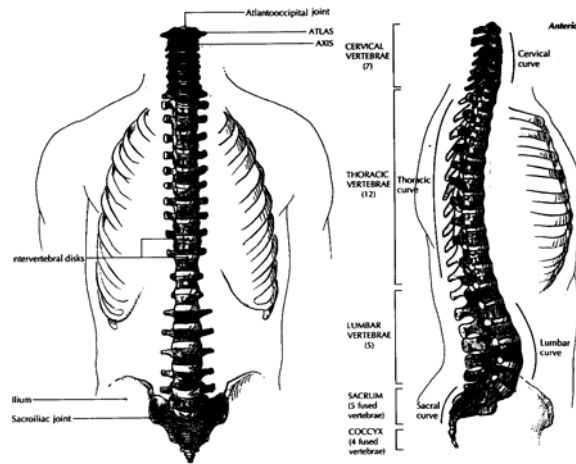
**Figure: 5.9 Intervertebral disc, compressed and ruptured disc** (source: Carola, R., Harley, J.P., Noback R.C., (1992), Human anatomy and physiology, Mc Graw hill inc, New York, 2<sup>nd</sup> ed, pp 196)

### Normal curves

The vertebral column when viewed from side is not a straight line rather have bandings. These are normal curves of the vertebral column. There are 4 normal curves formed by vertebrae, two are concave and the other two are convex. The presences of the curve have several functions; these are absorption of shock, maintenance of balance, protection of

column from fracture and increasing the strength of the column.

In the age of the fetus there is only a single anterior concave curve, but approximately the third post natal month, when the child begin to hold head erect, the cervical curve develops. Later when the child sits up, stands and walks the lumbar curve develops. The cervical & lumbar curves are an anteriorly convex and because they are modification of the fetal position they are called *secondary curves*. The thoracic and sacral curves are anteriorly concave, since they retain the anterior concavity of the fetal curve they are referred *primary curves*.



**Figure: 5.10. The vertebral column and vertebral curves** (source: Carola, R., Harley, J.P., Noback R.C., (1992), Human anatomy and physiology, Mc Graw hill inc, New York, 2<sup>nd</sup> ed, pp 186)

### **Typical vertebra**

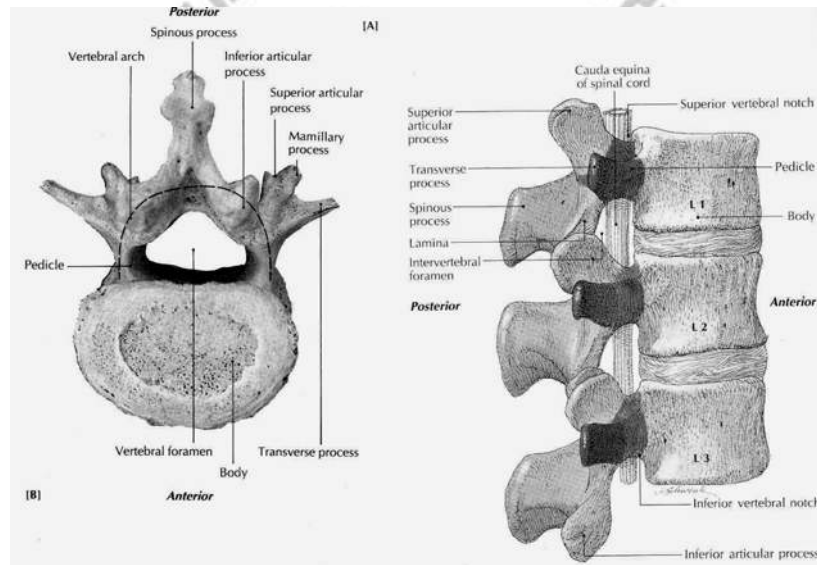
Although there are variations in size and shape, the vertebrae of the different regions have basically similar structure. They consist of the body, vertebral arch and seven processes.

*The body (Centrum)*, thick, disc shaped, anterior part. It has superior and inferior roughened areas for attachment with intervertebral discs.

*The vertebral (neural) arch* extends posterior from the body of the vertebrae. With the body it surrounds the spinal cord. It is formed by two short, thick processes called *pedicles*. It projects posteriorly to meet at *laminae*. The laminae are flat parts that join to form the posterior portion of the vertebral arch. The space that lies between the vertebral arch and body contains the spinal cord called *vertebral foramina*. The vertebral foramina of all vertebrae together form the vertebral (spinal) canal. The pedicles are notched superiorly & inferiorly to form an opening between vertebrae on each side of the column called *Intervertebral foramen*. Intervertebral foramen is an opening between the vertebrae that serves as passage of nerves that come out of spinal cord to supply the various body parts.

*There are seven processes that* arise from the vertebral arch at the point where the lamina and pedicle joins.

- The transverse processes on both side extends laterally.
- The Spinous processes extends posteriorly & inferiorly from the junction of the laminae.
- Both the transverse & spinous processes are muscle attachments. The remaining four processes form joints with other vertebra. Two of them articulate with the immediate superior vertebra. And the other two articulate with the immediate inferior vertebra.



**Figure: 5.11 Typical vertebra** (source: Carola, R., Harley, J.P., Noback R.C., (1992), Human anatomy and physiology, Mc Graw hill inc, New York, 2<sup>nd</sup> ed, pp 188)

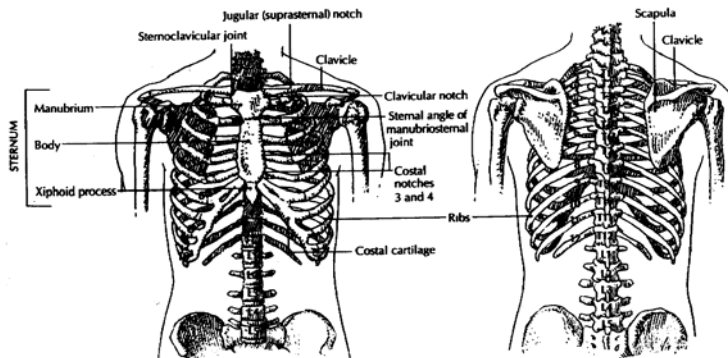
**Table 5.5 Description and function of bones of the vertebral column (26 bones), (source: Carola, R., Harley,J.P., Noback R.C., (1992), Human anatomy and physiology, Mc Graw hill inc, New York, 2<sup>nd</sup> ed, pp 187)**

<b>Bones</b>	<b>Description and function</b>
Cervical vertebrae (7)	First (atlas), second (axis), and seventh vertebrae are C1-C7 modified; third through sixth are typical; all contain transverse foramina. Atlas supports head, permits "yes" motion of head at joint between skull and atlas; axis Permits "no" motion at joint between axis and atlas.
Thoracic vertebrae (12)	Bodies and transverse processes have facets that articulate T1-T12 with ribs; laminae are short, thick, and broad. Articulate with ribs; allow some movement of spine in thoracic area.
Lumbar vertebrae(5)	Largest, strongest vertebrae; adapted for attachment of back L1-L5 muscles. Support back muscles; allow forward and backward bending of spine.
Sacrum	Wedge-shaped, made up of five fused bodies united by four (5 fused bones) intervertebral disks. Support vertebral column; give strength and stability to pelvis.
Coccyx	Triangular tailbone, united with sacrum by intervertebral (3 to 5 fused bones) disk. Vestige of an embryonic tail.

- In a child there are 33 separate vertebrae, the 9 in the sacrum and coccyx not yet being fused.

## The Thorax

Refers to the chest. Thorax is a bony cage formed by sternum (breast bone), costal cartilage, ribs and bodies of the thoracic vertebra.



**Figure: 5.12 Skeleton of the thorax** (source: Carola, R., Harley, J.P., Noback R.C., (1992), Human anatomy and physiology, Mc Graw hill inc, New York, 2<sup>nd</sup> ed, pp 193)

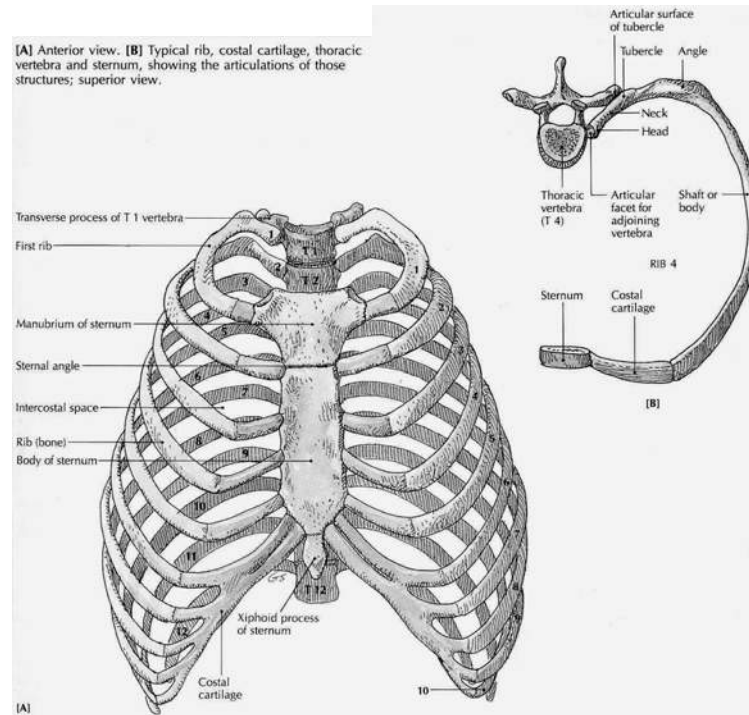
### Sternum (breast bone)

Sternum is flat, narrow bone measuring about 15 c.m. (6 inch) located in the median line of anterior thoracic wall. It consists 3 basic portions: the manubrium (superior portion), the body (middle & largest portion) and the xiphoid process (inferior & smallest portion). The junction of the manubrium and the body forms the *sternal angle*. The manubrium on its superior portion has a depression called jugular (supra sternal) notch.



On each side of the jugular notch are clavicular notch that articulates with medial end of clavicle.

The manubrium also articulates with the 1<sup>st</sup> and 2<sup>nd</sup> rib. The body of the sternum articulates directly or indirectly with 2<sup>nd</sup> to 10<sup>th</sup> rib. The xiphoid process consists hyaline cartilage during infancy and child hood and do not ossify completely up to the age of 40.



**Figure: 5.13 The ribs and sternum** ( source: Carola, R., Harley,J.P., Noback R.C., (1992), Human anatomy and physiology, Mc Graw hill inc, New York, 2<sup>nd</sup> ed, pp 194)

## Ribs

Human being contains 12 Pair of ribs that make up the side of thoracic cavity. Ribs increase in length from 1<sup>st</sup> through 7<sup>th</sup> and they decrease in length through 12<sup>th</sup>. Each ribs posteriorly articulates with the body of its corresponding thoracic vertebra.

Anteriorly the 1<sup>st</sup> seven ribs have direct attachment to sternum by costal cartilage hence they are called *true (vertebro – sternal) ribs*. The remaining 5 ribs are called *false ribs*. The 8<sup>th</sup> – 10<sup>th</sup> ribs, which are groups of the false ribs are called *vertebro chondrial ribs* because their cartilage attach one another and then attaches to the cartilage of the 7<sup>th</sup> rib. The 11th & 12th ribs are designated as floating ribs because their anterior part even doesn't attach indirectly to sternum.

Although there is variation when we examine a typical rib (3<sup>rd</sup> to 9<sup>th</sup>) contains a head, neck and body parts.

*The Head* is a projection at posterior end of the rib. It consist one or two facet that articulate with facet of the vertebra.

*The neck* is constricted portion just lateral to the head. One or two knob like structures on the posterior end where the neck joins the body is *the tubercles*, which articulate with the

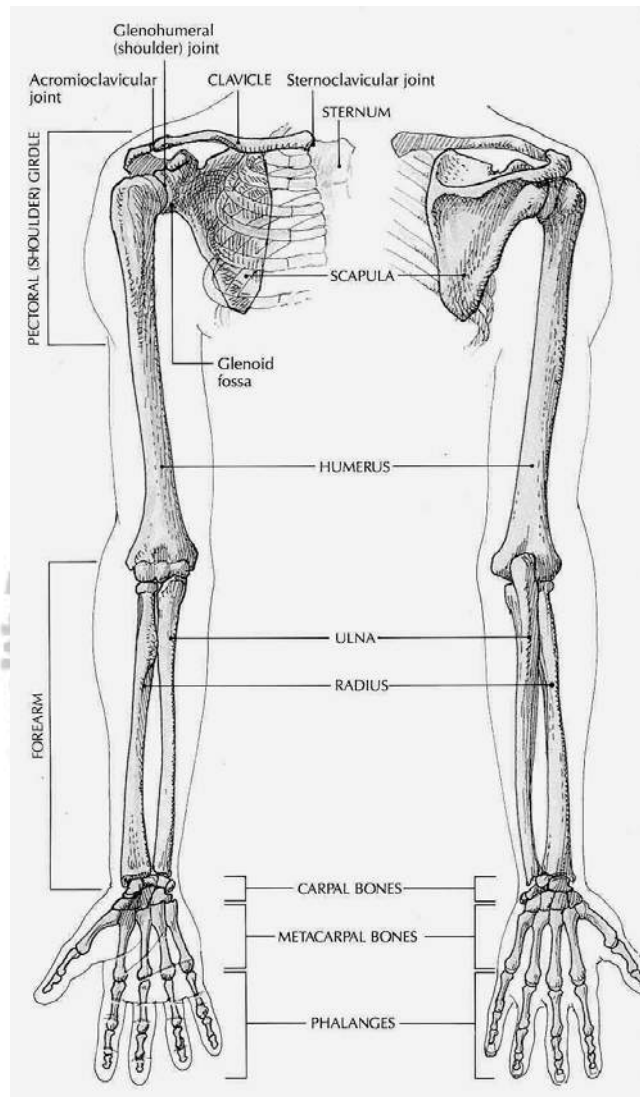
transverse process of the vertebra and to attach with muscles of the trunk.

*The body (shaft)* is main part of the rib. . *The costal angle* is the site where the rib changes its direction. The inner side of the costal angle is costal groove. Where thoracic nerves and blood vessels are protected.

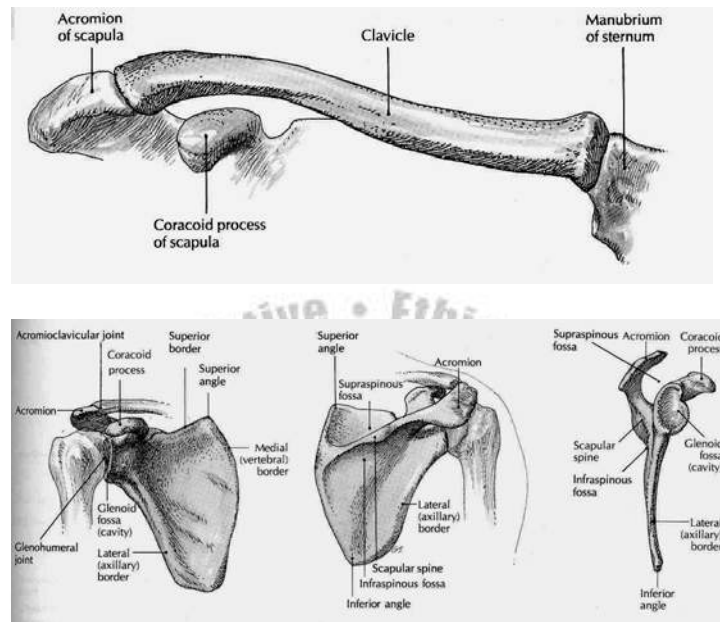
## **5.2.4 The Appendicular skeleton**

### **The upper extremities (limbs)**

The upper extremities consists of 64 bones. Connected and supported by the axial skeleton with only shoulder joint and many muscle from a complex of suspension bands from the vertebral column, ribs and sternum to the shoulder girdle.



**Figure: 5.14 The upper extremity** (source: Carola, R., Harley, J.P., Noback R.C., (1992), Human anatomy and physiology, Mc Graw hill inc, New York, 2<sup>nd</sup> ed, pp 204)



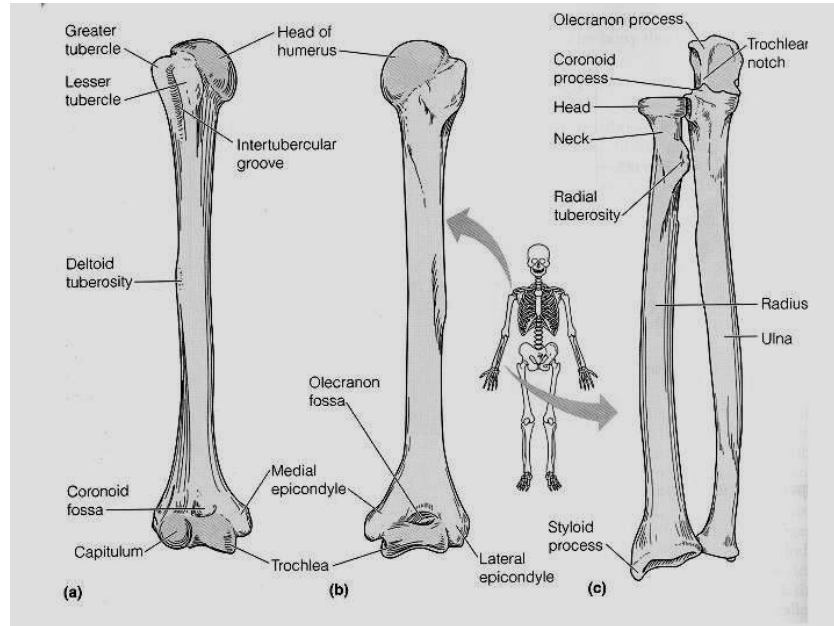
**Figure: 5.15** Shoulder girdle (source: Carola, R., Harley, J.P., Noback R.C., (1992), Human anatomy and physiology, Mc Graw hill inc, New York, 2<sup>nd</sup> ed, pp 205)

**Table 5.6: Description and function of bones of the upper extremity** (source: Carola, R., Harley, J.P., Noback R.C., (1992), Human anatomy and physiology, Mc Graw hill inc, New York, 2<sup>nd</sup> ed, pp 204)

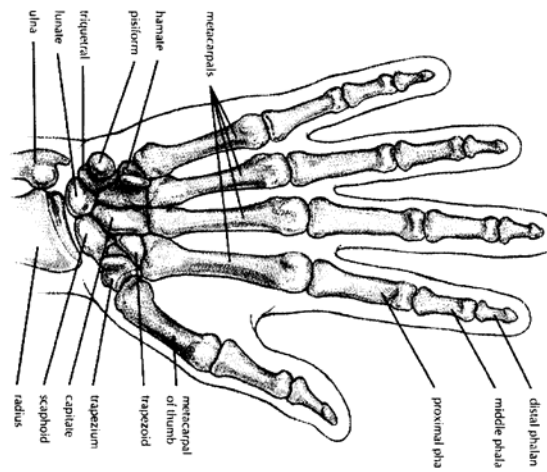
<b>Bone</b>	<b>Description and function</b>
<b>Shoulder (Pectoral) Girdle</b>	
CLAVICLE (2)	Collarbone; double-curved, long bone with rounded medial end and flattened lateral end; held in place by ligaments. Holds shoulder joint and arm away from thorax so upper limb can swing freely.
Scapula (2)	Shoulder blade; flat, triangular bone with horizontal spine separating fossae. Site of attachment for muscles of arm and chest.
<b>Arm</b>	
Humerus (2)	Longest, largest bone of upper limb; forms ball of ball-and socket joint with glenoid fossa of scapula. Site of attachment for muscles of shoulder and arm, permitting arm to flex and extend at elbow.
<b>Forearm</b>	
Radius (2)	Larger of two bones in forearm; large proximal end consists of olecranon process (prominence of elbow). Forms hinge joint at elbow.
<b>Wrist</b>	
Carpals (16)	Small short bones; in each wrist, 8 carpals in 2 transverse rows of 4. With attached ligaments, allow slight gliding movement.
<b>Hands and Fingers</b>	
Metacarpals (10)	Five miniature long bones in each hand in fanlike arrangement; articulate with fingers at metacarpophalangeal joint (the Knuckle). Aid opposition movement of thumb; enable cupping of hand.

Phalanges (28)

Miniature long bones, 2 in each thumb, 3 in each finger; articulate with each other at interphalangeal joint. Allow fingers to participate in stable grips.



**Figure: 5.16 Humerus, radius and ulna** (source: Elaine n. MARIEB, (2000), Essentials of human anatomy and physiology, Addison welsey longman inc., San Francisco, 6<sup>th</sup> Ed)

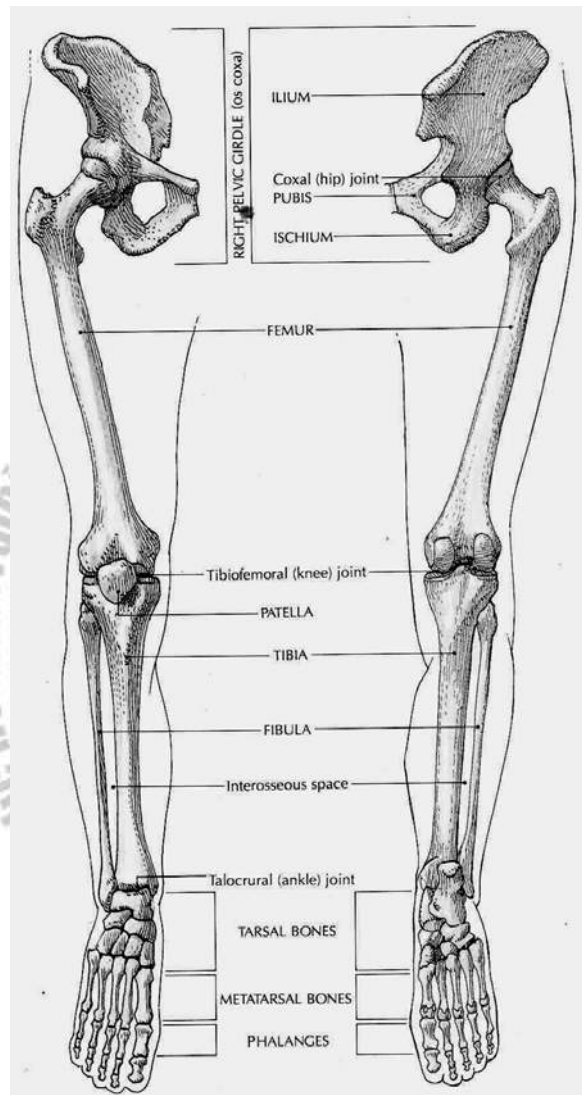


**Figure: 5.17 Bones of the hand** (source: Memmler, Ruth Lundeen, Barbara Jansen Cohen and Dena Lin Wood (1996), *The Human Body in Health and Disease*, 8<sup>th</sup> Ed, pp 100)

### The lower extremity

It consist 62 bones. The lower extremity is connected to the axial skeleton with the hip girdle.



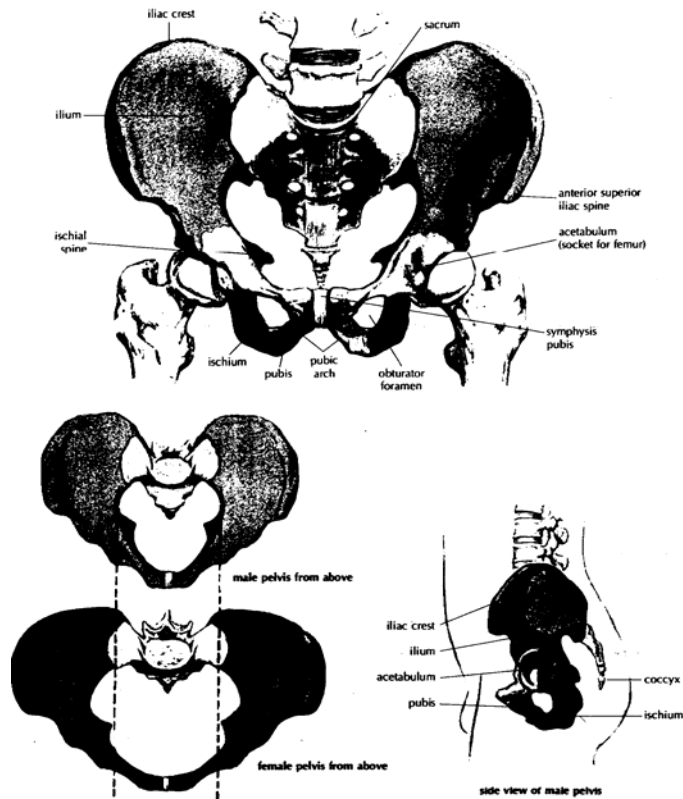


**Figure: 5.18 The lower extremity** (source: Carola, R., Harley, J.P., Noback R.C., (1992), Human anatomy and physiology, Mc Graw hill inc, New York, 2<sup>nd</sup> ed, pp 210)

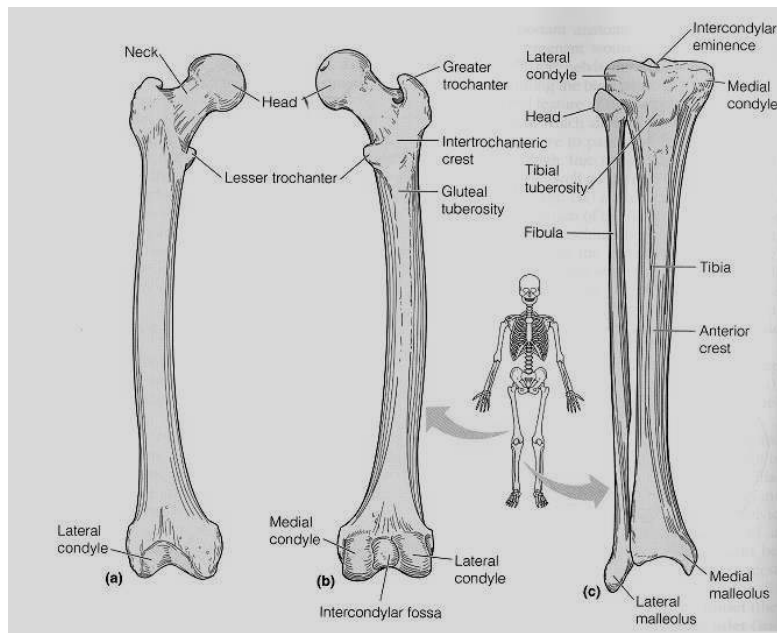
**Table 5.7 description and function of bones of the lower extremity** (source: Carola, R., Harley, J.P., Noback R.C., (1992), Human anatomy and physiology, Mc Graw hill inc, New York, 2<sup>nd</sup> ed, pp 210)

<b>Bone</b>	<b>Description and function</b>
<b>Pelvic Girdle</b>	
Hipbone	Irregular bone formed by fusion of ilium, ischium, pubis; with (Coxal) (2) sacrum and coccyx forms pelvis; forms socket of ball-and- socket joint with femur. Site of attachment for trunk and lower limb muscles; transmits body weight to femur.
<b>Thigh</b>	
Femur (2)	Thighbone; typical long bone; longest, strongest, heaviest bone; forms ball of ball-and-socket joint with pelvic bones; provides articular surface for knee. Supports body.
Patella (2)	Kneecap; sesamoid bone within quadriceps femoris tendon. Increases leverage for quadriceps muscle by keeping tendon away from axis of rotation.
<b>Leg</b>	
Fibula (2)	Smaller long bone of lower leg; articulates proximally with tibia and distally with talus. Bears little body weight, but gives strength to ankle joint.
Tibia (2)	Larger long bone of lower leg; articulates with femur fibula, talus. Supports body weight, transmitting it from femur to talus.
<b>Ankle</b>	
Tarsals (14)	Ankle, heel bones; short bones; 7 in each ankle including talus, calcaneus, cuboid, navicular, 3 cuneiforms; with metatarsals, form arches of foot. Bear body weight; raise body and transmit thrust during running and walking.
<b>Foot and Toes</b>	
Metatarsals (10)	Miniature long bones; 5 in each foot; form sole; with tarsal, form arches of feet. Improve stability while standing; absorb shocks; bear weight; aid in locomotion.

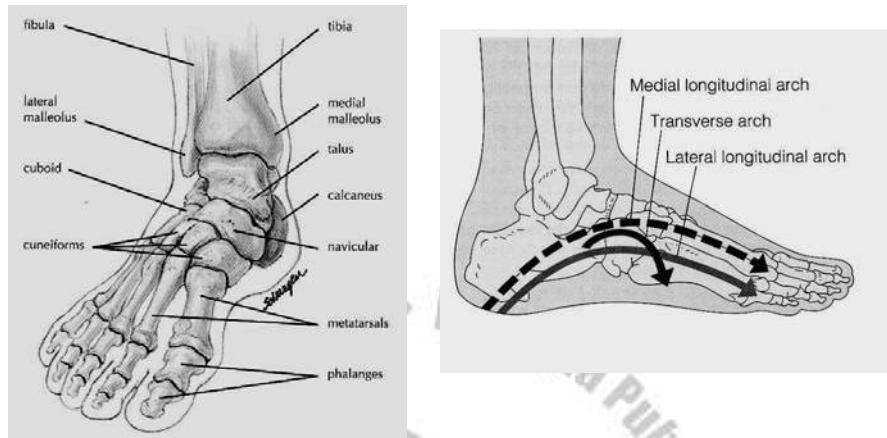
Phalange (28) Toes; miniature long bones; 2 in each big toe, 3 in each other toe; arranged as in hand. Provide stability during locomotion.



**Figure: 5.19 The hip bone(coxal bone), Male and female pelvis** (source: Memmler, Ruth Lundeen, Barbara Jansen Cohen and Dena Lin Wood (1996), *The Human Body in Health and Disease*, 8<sup>th</sup> ed, pp 101)



**Figure: 5.20** The femur, the tibia and fibula here you can see where the patella is located. (Source: Elaine n. MARIEB, (2000), Essentials of human anatomy and physiology, Addison welsey longman inc., San Francisco, 6<sup>th</sup> Ed)



**Figure: 5.21 Bones and arches of the foot** (source: Memmler, Ruth Lundeen, Barbara Jansen Cohen and Dena Lin Wood (1996), *The Human Body in Health and Disease*, 8<sup>th</sup> ed, pp 103)

### **Arches of the foot**

The sole of your foot is arched for the same reason that your spine is curved. Beside its function of absorbing shock it prevents nerves and blood vessels in the sole of the foot from being crushed.

There are three arches in the foot, two longitudinal (medial & lateral) and one transverse.

### **5.7 Articulations**

Bones being structural framework, muscles give it power. But movable joints provide the mechanism that allows the body to move.

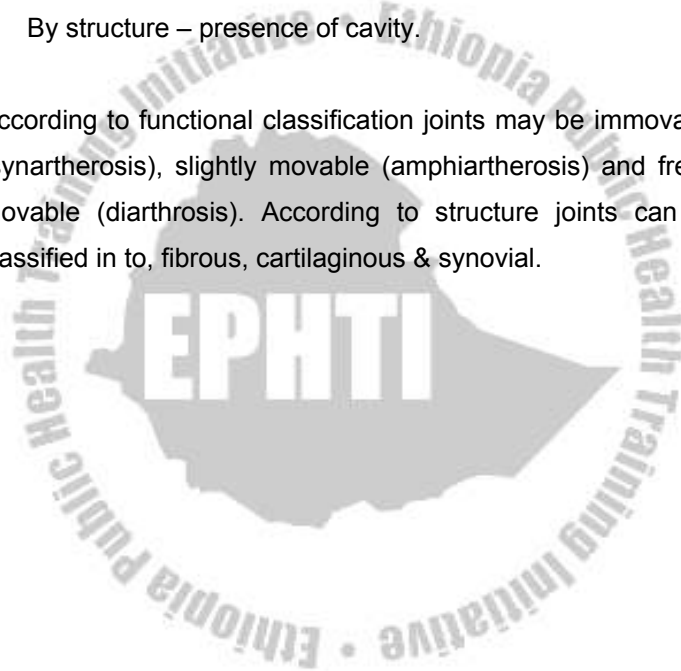
*Articulations (joints)* are places where two adjacent bones or cartilages meet.

### **Classifications**

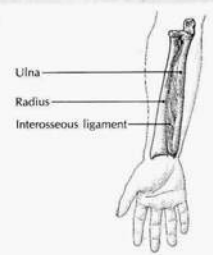
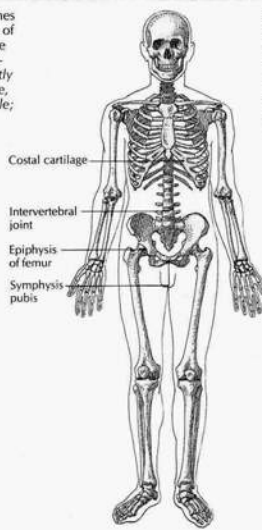
Joints are classified by two methods

- By function-degree of movement
- By structure – presence of cavity.

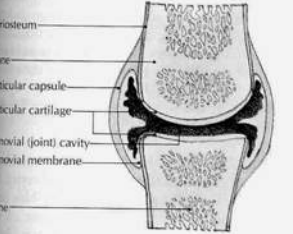
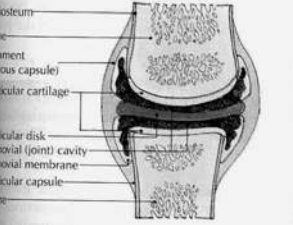


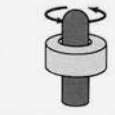



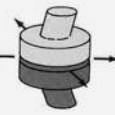

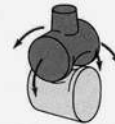



According to functional classification joints may be immovable (synarthrosis), slightly movable (amphiarthrosis) and freely movable (diarthrosis). According to structure joints can be classified in to, fibrous, cartilaginous & synovial.



**Table 5.8: Classifications of joints** (source: Carola, R., Harley, J.P., Noback R.C., (1992), Human anatomy and physiology, Mc Graw hill inc, New York, 2<sup>nd</sup> ed, pp 226)

Structural and functional classification*	Type of structure and movement†	Examples
<b>FIBROUS</b>		
<p>Fibrous connective tissue unites articulating bones; no joint cavity. <i>Mostly immovable, some slightly movable; usually synarthroses.</i></p>  <p>Ulna Radius Interosseous ligament</p>	<p><b>Suture:</b> found only in skull; fibrous tissue between articulating bones in children, but permanently fused in adults. <i>Some movement in fetuses and young children; immovable in adults.</i></p> <p><b>Syndesmosis:</b> articulating bones held together (but not touching) by fibrous or interosseous ligaments. <i>Slight movement: twisting of forearm (pronation, supination).</i></p> <p><b>Gomphosis:</b> a peg fitting into a socket. <i>Mostly immovable; very slight movement of teeth in their sockets.</i></p>	<p>Cranial sutures, such as coronal suture between frontal and parietal bones.</p> <p>Inferior tibiofibular joint; interosseous ligament between shafts of radius and ulna.</p> <p>Roots of teeth in alveolar processes of mandible and maxillae.</p>
<b>CARTILAGINOUS</b>		
<p>Articulating bones united by plate of hyaline cartilage or fibrocartilaginous disk. <i>Mostly slightly movable, some immovable; usually amphiarthroses.</i></p>  <p>Costal cartilage Intervertebral joint Epiphysis of femur Symphysis pubis</p>	<p><b>Synchondrosis:</b> temporary joint composed of hyaline cartilage joining diaphysis and epiphysis of growing long bones. <i>Immovable; permits growth of long bones.</i></p> <p><b>Symphysis:</b> bony surfaces bridged by flattened plates or disks of fibrocartilage. <i>Slight movement.</i></p>	<p>Epiphyseal plate of femur; union of manubrium and body of sternum.</p> <p>Symphysis pubis, manubriosternal joint, intervertebral joints between bodies of vertebrae.</p>

... Continued

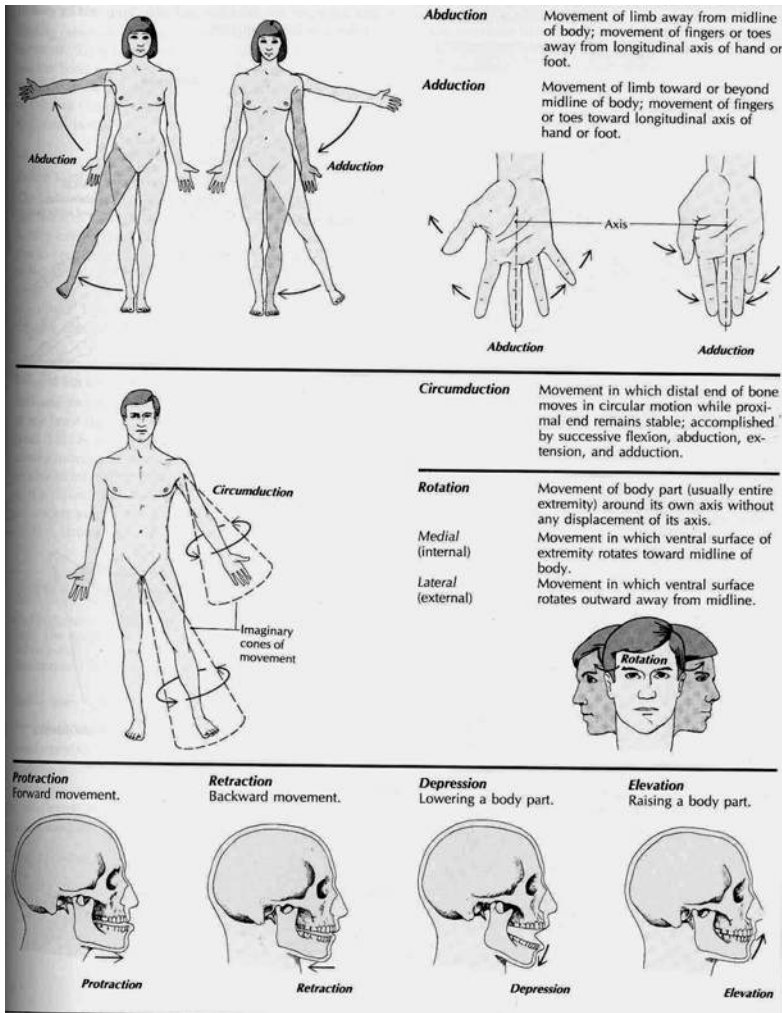
Structural and functional classification*	Type of structure and movement	Examples
<b>SYNOVIAL</b>		
<p>Articulating bones moving freely along smooth, lubricated articular cartilage; enclosed within flexible articular capsule. <i>Freely movable; usually diarthroses.</i></p>		
		
<b>SYNOVIAL JOINT WITHOUT ARTICULAR DISK</b>		
		
<b>SYNOVIAL JOINT WITH ARTICULAR DISK</b>		
<b>UNIAXIAL: movement of bone about one axis of rotation.</b>		
<p><b>Hinge:</b> convex surface of one bone fitted into concave surface of other. <i>Flexion, extension.</i></p>		<p>Elbow, interphalangeal joints, knee, ankle.</p> 
<p><b>Pivot:</b> central bony pivot surrounded by collar of bone and ligament. <i>Supination, pronation, rotation.</i></p>		<p>Proximal radioulnar joint, atlantoaxial joint.</p> 
<b>BIAXIAL: movement of bone about two axes of rotation.</b>		
<p><b>Condyloid</b> (ellipsoidal): modified ball-and-socket. <i>Flexion, extension, abduction, adduction, circumduction.</i></p>		<p>Metacarpophalangeal (knuckle) joints, except thumb.</p> 
<b>MULTIAXIAL: movement of bone about three axes.</b>		
<p><b>Gliding:</b> essentially flat articular surfaces. <i>Simple gliding movement within narrow limits.</i></p>		<p>Between articular processes of vertebrae, acromioclavicular joint, some carpal and tarsal bones.</p> 
<p><b>Saddle:</b> opposing articular surfaces with both concave and convex surfaces that fit into one another. <i>Abduction, adduction, opposition, reposition.</i></p>		<p>Carpometacarpal joint of thumb.</p> 
<p><b>Ball-and-socket:</b> globelike head of one bone fitted into cuplike concavity of another bone. <i>Flexion, extension, internal rotation, lateral rotation, abduction, adduction, circumduction.</i></p>		<p>Shoulder joint, hip joint.</p> 



**Table 5.9: Types of movements by synovial joints** (source: Carola, R., Harley, J.P., Noback R.C., (1992), Human anatomy and physiology, Mc Graw hill inc, New York, 2<sup>nd</sup> ed, pp 232)

	<p><b>Flexion</b> Bending motion in which angle between two bones is decreased.</p> <p><b>Extension</b> Straightening motion in which angle between two bones is increased.</p> <p><b>Hyperextension</b> Extension beyond straight (anatomical) position.</p> <p><b>Dorsiflexion*</b> Flexion of foot at ankle joint.</p> <p><b>Palmar flexion</b> Flexion of hand at wrist.</p> <p><b>Plantar flexion*</b> Extension of foot at ankle.</p> <p>* At the ankle, where the normal position is angular; dorsiflexion and plantar flexion are equivalent to flexion and extension.</p>
	<p><b>Inversion</b> Movement of sole of foot inward (medially).</p> <p><b>Eversion</b> Movement of sole of foot outward (laterally).</p>
	<p><b>Supination</b> Pivoting movement of forearm in which radius is "rotated" to become parallel to ulna.</p> <p><b>Pronation</b> Pivoting movement of forearm in which radius is "rotated" diagonally across ulna.</p> <hr/> <p><b>Opposition</b> Angular movement in which thumb pad is brought to touch and to oppose a finger pad of the extended fingers; occurs only at carpometacarpal joint of thumb.</p> <p><b>Reposition</b> Movement that returns thumb to anatomical position; opposite of opposition.</p>

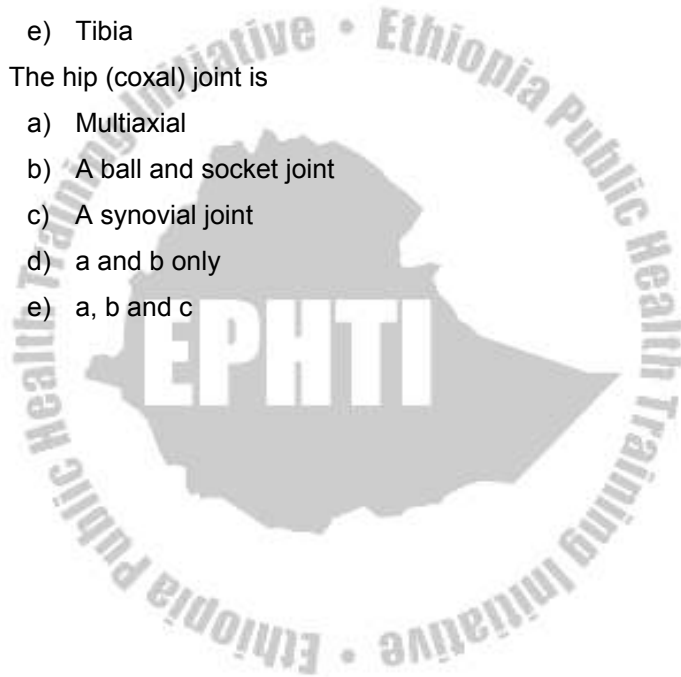
... Continued



## Review Questions

1. The main function of the skeletal system is:
  - a) Protection
  - b) Storage of minerals
  - c) Support
  - d) Producing motion
  - e) All of the above
  
2. The two type of ridged connective tissue found in the human skeleton are: -
  - a) Spongy & compact bone
  - b) Bone & cartilage
  - c) Periosteum & endosteum
  - d) Metaphysis & Diaphysis
  - e) Cancellous & bone plate
  
3. The major bone at the posterior aspect of the base of the skull is: -
  - a) Sphenoid
  - b) Occipital
  - c) Temporal
  - d) Lacrimal
  - e) Zygomatic

4. Which of the following is not part of the appendicular skeleton?
- a) Scapula
  - b) Clavicle
  - c) Radius
  - d) Ribs
  - e) Tibia
5. The hip (coxal) joint is
- a) Multiaxial
  - b) A ball and socket joint
  - c) A synovial joint
  - d) a and b only
  - e) a, b and c



# CHAPTER SIX

## THE MUSCULAR SYSTEM

### Chapter Objectives

At the end of this chapter, the student should be able to:

- List the general characteristics and functions of skeletal muscle tissue.
- Describe the structure of a muscle
- Describe the connective tissue components of skeletal muscles
- Briefly describe how muscles contract
- List the substances needed in muscle contraction and describe the function of each
- Differentiate between isotonic and isometric contractions
- Define the following terms: origin, insertion, synergist, antagonist, and prime mover
- Define the different bases employed in naming skeletal muscles Identify the principal skeletal muscle in different regions of the body by name, action, and innervations.

## **Selected key terms**

### **The following terms are defined in the glossary**

Action	Origin
Antagonist	Oxygen debt
Aponeurosis	Prime mover
Contraction	Synergist
Epimysium	Sarcomere
Insertion	Sliding filament mechanism
Innervation	Tendon
Myosin	Tone

### **The muscular system**

The term muscle tissue refers to all the contractile tissues of the body: skeletal, cardiac, and smooth muscle. The muscular system, however, refers to the skeletal muscle system: the skeletal muscle tissue and connective tissues that makeup individual muscle organs, such as the biceps brachii muscle. Cardiac muscle tissue is located in the heart and is therefore considered part of the cardiovascular system. Smooth muscle tissue of the intestines is part of the digestive system, whereas smooth muscle tissue of the urinary bladder is part of the urinary system and so on. In this chapter, we discuss only the muscular system. We will see how skeletal system

produce movement and we will describe the principal skeletal muscles of the human body; their action and innervation.

### **Functions of muscle tissue**

Through sustained contraction or alternating contraction and relaxation, muscle tissue has three key functions: producing motion, providing stabilization, and generating heat.

1. **Motion:** Motion is obvious in movements such as walking and running, and in localized movements, such as grasping a pencil or nodding the head. These movements rely on the integrated functioning of bones, joints, and skeletal muscles.
2. **Stabilizing body positions and regulating the volume of cavities in the body:** Besides producing movements, skeletal muscle contractions maintain the body in stable positions, such as standing or sitting. Postural muscles display sustained contractions when a person is awake, for example, partially contracted neck muscles hold the head upright. In addition, the volumes of the body cavities are regulated through the contractions of skeletal muscles. For example muscles of respiration regulate the volume of the thoracic cavity during the process of breathing.
3. **Thermo genesis** (generation of heat). As skeletal muscle contracts to perform work, a by-product is heat.

Much of the heat released by muscle is used to maintain normal body temperature. Muscle contractions are thought to generate as much as 85% of all body heat.

### **Physiologic Characteristics of muscle tissue**

Muscle tissue has four principal characteristics that enable it to carry out its functions and thus contribute to homeostasis.

1. **Excitability (irritability)**, a property of both muscle and nerve cells (neurons), is the ability to respond to certain stimuli by producing electrical signal called action potentials (impulses). For example, the stimuli that trigger action potentials are chemicals-neurotransmitters, released by neurons, hormones distributed by the blood.
2. **Contractility** is the ability of muscle tissue to shorten and thicken (contract), thus generating force to do work. Muscles contract in response to one or more muscle action potentials.
3. **Extensibility** means that the muscle can be extended (stretched) without damaging the tissue. Most skeletal muscles are arranged in opposing pairs. While one is contracting, the other not only relaxed but also usually is being stretched.
4. **Elasticity** means that muscle tissue tends to return to its original shape after contraction or extension.



## Muscle structure

### A. Connective Tissue Component

A skeletal muscle is an organ composed mainly of striated muscle cells and connective tissue. Each skeletal muscle has two parts; the connective tissue sheath that extend to form specialized structures that aid in attaching the muscle to bone and the fleshy part the **belly** or **gaster**. The extended specialized structure may take the form of a cord, called a **tendon**; alternatively, a broad sheet called an **aponeurosis** may attach muscles to bones or to other muscles, as in the abdomen or across the top of the skull. A connective tissue sheath called **facia** surrounds and separates muscles (Figure 6-1). Connective tissue also extends into the muscle and divides it into numerous **muscle bundles** (fascicles). There are three connective tissue components that cover a skeletal muscle tissue. These are:

1. Epimysium—a connective tissue sheath that surrounds and separates muscle.
2. Perimysium—a connective tissue that surrounds and holds fascicles together.
3. Endomysium—a connective tissue that surrounds each muscle fibre.

## B. Microscopic structures

The muscle bundles are composed of many elongated muscle cells called muscle fibres. Each **muscle fibre** is a cylindrical cell containing several nuclei located immediately beneath the cell membrane (**sarcolemma**). The cytoplasm of each muscle fibre (**sarcoplasm**) is filled with myofibrils. Each myofibril is a thread-like structure that extends from one end of the muscle fibre to the other. Myofibrils consist of two major kinds of protein fibres: **actins** or thin **myofilaments**, and **myosin** or thick **myofilaments**.

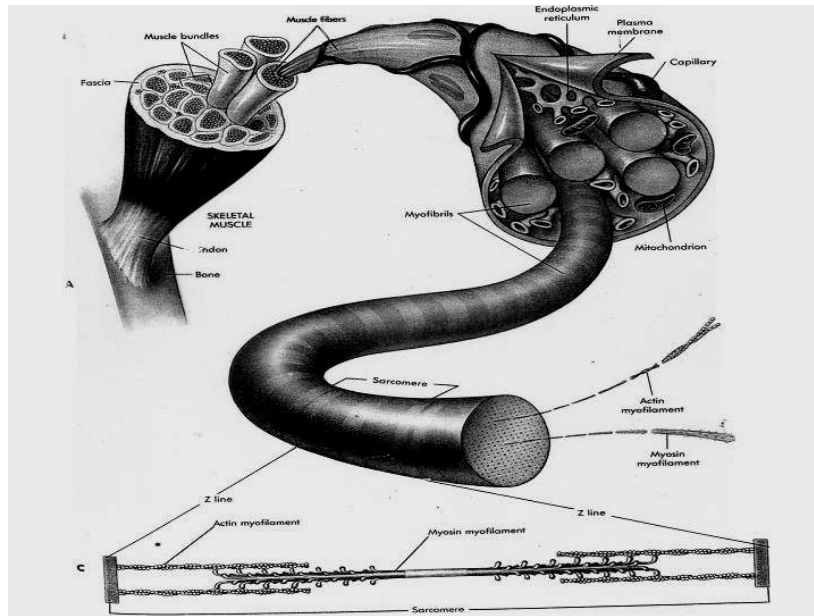
The actins and myosin myofilaments form highly ordered units called **sarcomers**, which are joined end-to-end to form the myofibrils (see Figure 6-1). Sarcomere is a structural and functional unit of muscle tissue. The ends of a sarcomere are a network of protein fibres, which form the **Z-lines** when the sarcomere is viewed from side. The Z-lines form an attachment site for actins myofilaments. The arrangement of the actin and myosin myofilaments in a sarcomere gives the myofibril a banded appearance because the myofibril appears darker where the actin and myosin myofilaments overlap. The alternating light (**I-band**) and dark (**A-band**) areas of the sarcomers are responsible for striation (banding pattern) seen in skeletal muscle cells observed through the microscope.

The sarcolemma of a muscle fibre forms blind-ended sacs or **T-tubules** which penetrate the cell and lie in the spaces between the myofibrils. The T-tubules contain interstitial fluid and do not open into the interior of the muscle fibre. Within the sarcoplasm of the muscle fibre there is an extensive network of branching and anastomosing channels, which forms the sarcoplasmic reticulum (this structure is a modified endoplasmic reticulum). The channels of the sarcoplasmic reticulum lay in close contact around the ends of T-tubules, and contain stores of calcium.

### **Muscle contractions**

The thick myofilaments are composed of a protein called myosin. Each myosin filament has small regular projections known as **crossbridges**. The crossbridges lie in a radial fashion around the long axis of the myofilament. The rounded heads of the crossbridges lie in apposition to the thin myofilaments.

The thin myofilaments are composed of a complex protein called actin, arranged in a double stranded coil. The actin filaments also contain two additional proteins called **tropoin** and **tropomyosin**.



**Figure 6-1. Structure of a skeletal muscle** (From Memmler, Ruth Lundeen et al: The human body in Health and disease, ed. 8, New York, 1996, Lippincott.)

In a resting muscle fibre the myosin crossbridges are prevented from combining with the actin filaments by the presence of troponin and tropomyosin. When a nerve impulse reaches a muscle fibre it is conducted over the sarcolemma and in to the T-tubules, then to the sarcoplasmic reticulum. The sarcoplasmic reticulum releases calcium ions into the sarcoplasm. The liberated calcium ions combine with troponin causing it to push tropomyosin away from the receptor sites on the actins filaments. The myosin crossbridges interact

with the actin receptor sites and pull the actin myofilaments toward the centre (H-zone) of each sarcomere. The bond between the myosin crossbridges and actin breaks down under the influence of enzymes and the crossbridges are then free to rejoin with other actin receptor sites. The actin filaments do not shorten but slide past the myosin filaments overlapping them so that the Z lines are drawn toward each other, shortening the sarcomere. As each sarcomere shortens the whole muscle fibre contracts.

Relaxation of the muscle fibres occurs when the calcium ions are actively reabsorbed by the sarcoplasmic reticulum thus allowing troponin and tropomyosin to again inhibit the interaction of the actins and myosin filaments (see Table 6-1 for summary of events in the contraction of a muscle fibre).

### **Energy Requirements for Muscle Contraction**

Contraction of skeletal muscle requires adenosine triphosphate (ATP). The ATP releases energy when it breaks down to adenosine diphosphate (ADP) and a phosphate (P), some of the energy is used to move the crossbridges and some of the energy is released as heat.

***ATP → ADP + P + Energy (for crossbridge movement) + Heat***

The ATP required for muscle contraction is produced primarily in numerous mitochondria located within the muscle fibres. Because ATP is a very short-lived molecule and rapidly degenerates to the more stable ADP, it is necessary for muscle cells to constantly produce ATP.

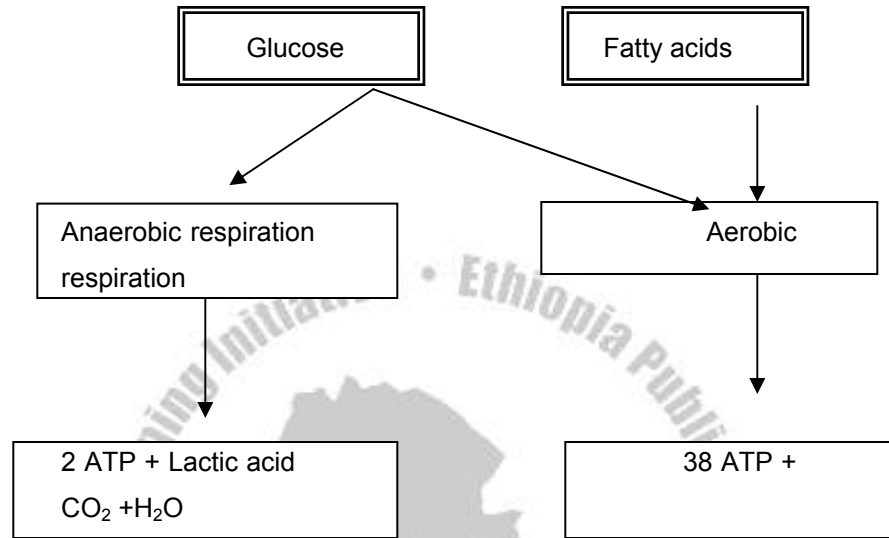
ATP is produced by anaerobic or aerobic respiration. **Anaerobic respiration**, which occurs in the absence of oxygen, results in the breakdown of glucose to yield ATP and lactic acid. **Aerobic respiration** requires oxygen and breaks down glucose to produce ATP, carbon dioxide, and water (figure 6-2). Compared with anaerobic respiration, aerobic respiration is much more efficient. The breakdown of glucose molecule by aerobic respiration theoretically can produce 19 times as much ATP as is produced by anaerobic respiration. In addition, aerobic respiration can utilize a greater variety of nutrient molecules to produce ATP than can anaerobic respiration. For example, aerobic respiration can use fatty acids to generate ATP. Although anaerobic respiration is less efficient than aerobic respiration, it can produce ATP when lack of oxygen limits aerobic respiration. By utilizing many glucose molecules, anaerobic respiration can rapidly produce much ATP, but only for a short period.

Resting muscles or muscles undergoing long-term exercise such as a long-distance bicycling on level ground depend

primarily on aerobic respiration for ATP synthesis. Although some glucose is used as an energy source, fatty acids are a more important energy source during sustained exercise as well as during resting conditions. On the other hand, during intense exercise such as riding a bicycle up a steep hill, anaerobic respiration provides enough ATP to support intense muscle

**Table 6-1.** Summary of events in the contraction of a muscle fibre

Nerve impulse is transmitted via a motor nerve to the motor end plate
Nerve impulse crosses neuromuscular junction by causing release of acetylcholine which depolarizes sarcolemma.
Sarcoplasmic reticulum releases calcium ions into the sarcoplasm.
Impulse is conducted into T-tubules and to the sarcoplasmic reticulum.
Myosin cross-bridges interact with actin receptor sites and thin myofilaments are drawn towards the centre of each sarcomere.
Calcium ions combine with troponin which pushes tropomyosin away from action receptor sites.
Enzymic action breaks the bond between myosin crossbridges and actin receptor sites.
Myosin crossbridges rejoin other actin receptor sites, each rejoining drawing the thin filaments closer to the centre of the sarcomere.
As each sarcomere shortens the whole muscle fibre contracts
Calcium ion is reabsorbed by the sarcoplasmic reticulum. Troponin and tropomyosin again inhibit the interaction of myosin and actin myofilaments, and the muscle fibre relaxes.



**Figure 6-2. Anaerobic and aerobic respiration**

Contractions for approximately 1 to 2 minutes. Anaerobic respiration is ultimately limited by depletion of glucose and a build up of lactic acid within the muscle fibre. Lactic acid can also irritate muscle fibres, causing short-term muscle pain. Muscle pain that lasts for a couple of days following exercise, however, results from damage to connective tissue and muscle fibres within the muscle.

Muscle fatigue results when ATP is used during muscle contraction faster than it can be produced in the muscle cells, and lactic acid builds up faster than it can be removed. As a



consequence, ATP levels are too low to sustain crossbridge movement and the contractions become weaker and weaker. For most of us, however, complete muscle fatigue is rarely the reason we stop exercising. Instead, we stop because of psychological fatigue, the feeling that the muscles have tired. A burst of activity in a tired athlete as a result of encouragement from spectators is an example of how psychological fatigue can be overcome.

After intense exercise, the respiration rate remains elevated for a period. Even though oxygen is not needed for anaerobic production of ATP molecules for contraction, oxygen is needed to convert the lactic acid produced by anaerobic respiration back to glucose. The increased amount of oxygen needed in chemical reactions to convert lactic acid to glucose is the oxygen debt. After the oxygen debt is paid, respiration rate returns to normal.

### **Types of muscle contraction**

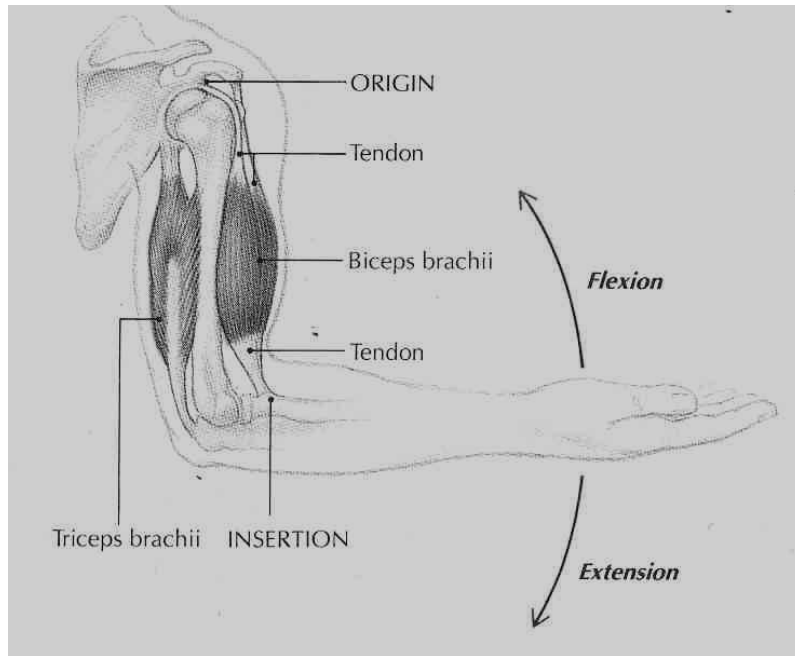
Muscle contractions are classified as either isotonic or isometric. In **isotonic contractions**, the amount of tension produced by the muscle is constant during contraction, but the length of the muscle changes; for example, movement of the fingers to make fist. In **isometric contractions**, the length of the muscle does not change, but the amount of tension increases during the contraction process. Clenching the fist

harder and harder is an example. Most movements are a combination of isometric and isotonic contractions. For example, when shaking hands, the muscles shorten some distance (isotonic contractions) and the degree of tension increases (isometric contractions).

Isometric contractions are also responsible for muscle tone, the constant tension produced by muscles of the body for long periods. Muscle tone is responsible for posture; for example, keeping the back and legs straight, the head held in upright position, and the abdomen from bulging.

### **Muscle attachments**

Most muscles extend from one bone to another and cross at least one movable joint. Muscle contraction causes most body movements by pulling one of the bones towards the other across the movable joint. Some muscles are not attached to bone at both ends. For example, some facial muscles attach to the skin, which moves as the muscles contract.



**Figure 6-3 Diagram of a muscle showing attachments to bones—origins and insertion** (Source: Carola, R., Harley, J.P., Noback R.C., (1992), Human anatomy and physiology, Mc Graw hill inc, New York, 2<sup>nd</sup> ed.)

The points of attachment of each muscle are its **origin** and **insertion** (Figure 6-3). At these attachment points, the muscle is connected to the bone by a tendon. The origin is the most stationary end of the muscle and the insertion is the end of the muscle attached to the bone undergoing the greatest movement. Some muscles have more than one origin, but the principle is the same—the origin act to anchor or

hold the muscle so that the force of contraction causes the insertion to move. For example, the biceps brachii causes the radius to move, resulting in flexion of the forearm. The triceps brachii muscle has three origins; two on the humerus and one on the scapula. The insertion of the triceps brachii is on the ulna and contraction results in extension of the forearm.

Several muscles contract while others relax to produce almost any movement you can imagine. Of all the muscles contracting simultaneously, the one mainly responsible for producing a particular movement is called the prime mover for that movement. The other muscles that help in producing the movement are called synergists. As prime movers and synergist muscles at a joint contract, other muscles called antagonists, relax. When those antagonist muscles contract, they produce a movement opposite to that of those prime movers and their synergist muscles.

### **Naming skeletal muscles**

Most of the skeletal muscles are named according to one or more of the following basis:

1. **Direction** of muscle fibres relative to the midline of the body or longitudinal axis of a structure

**Rectus** means the fibres run parallel to the midline of the body or longitudinal axis of a structure. Example, rectus abdominis

**Transverse** means the fibres run perpendicular to the midline longitudinal axis of a structure. Example, transverse abdominis

**Oblique** means the fibres run diagonally to the midline longitudinal axis of a structure. Example, external oblique

2. **Location**—structure to which a muscle is found closely related

Example: Frontalis, a muscle near the frontal bone Tibialis anterior, a muscle near the front of tibia

3. **Size**—relative size of the muscle

**Maximus** means largest. Example, gluteus maximus

**Minimus** means smallest. Example, gluteus minimus

**Longus** means longest. Example, Adductor longus

**Brevis** means short. Example, Peroneus brevis

4. **Number of origins**—number of tendons of origin Biceps means two origins. Example, biceps brachii Triceps means three origins. Example, triceps brachii Quadriceps means four origins. Example, quadriceps femoris

5. **Shape**—relative shape of the muscle

**Deltoid** means triangular. Example, deltoid

**Trapezius** means trapezoid. Example, trapezius

**Serratus** means saw-toothed. Example, serratus anterior

**Rhomboideus** means rhomboid or diamond shape. Example, Rhomboideus major

6. **Origin and insertion**—sites where muscles originates and inserts

Example, sternocleidomastoid—originates on sternum and clavicle and inserts on mastoid process of temporal bone.

**7. Action**—principal action of the muscle

**Flexor:** decrease the angle at a joint. Example, flexor carpiradialis

**Extensor:** increases the angle at a joint. Example, extensor carpiulnaris

**Abductor:** moves a bone away from the midline. Example, abductor policis brevis

**Adductor:** moves a bone closer to the midline. Example, adductor longus

**Levator:** produces an upward movement. Example, levator labii superioris

**Depressor:** produces a downward movement. Example, depressor labii inferioris

**Supinator:** turns the palm upward or anteriorly. Example, supinator

**Pronator:** turns the palm downward or posteriorly. Example, pronator teres

**Sphincter:** control the size of an opening. Example, external anal sphincter

**Tensor:** makes a body part more rigid. Example, tensor fasciae latae

**Rotator:** moves a bone around its longitudinal axis. Example, obturator externus

**Principal skeletal muscles**

Although there are over 700 individual skeletal muscles in the human body, an appreciation and understanding of skeletal muscles can be accomplished by concentrating on the large superficial muscles and muscle groups. Table 6-1 through Table 6-4 summarizes the origin, insertion, and action of these muscles. Refer to Figures 6-4 and 6-5 as you study the attachments and action of these muscles, and try to figure out why each has the name that it does.

**Table 6-1. Head and neck muscles**

Muscle	Origin	Insertion	Action
<b>Muscles of facial expression</b>			
Occipitofrontalis	Occipital bone	Skin of eye brow	Elevates eye brows
orbicularis oculi	Maxilla & frontal	Skin around the eye	Closes eye
Orbicularis oris	Maxilla & mandible	Skin around the lips	Closes lip
Buccinator	Mandible & maxilla	Corner of mouth	Flattens cheeks
Zygomaticus muscles	Zygomatic bone	Corner of mouth	Elevates corner of mouth
Levator labii superioris	Maxilla	Upper lip	Elevates upper lip
Corrugator supercilli	Frontal bone	Skin of eye brow	Lowers and draws together eye brows
Depressor anguli oris	Mandible	Lower lip near corner of mouth	Depresses corner of the mouth

Muscles of mastication	Temporal region on side of the skull	Mandible	Closes jaw
Temporalis			
Masseter	Zygomatich arch	Mandible	Closes jaw
Muscles that move the head	Occipital bone and vertebrae	Scapula and Clavicle	Extends head and neck
rapezius			
Sternocleidomas toid	Sternum & clavicle	Mastoid process of temporal bone	Rotates head and flexes neck

**Table 6-2. Trunk muscles**

Muscle	Origin	Insertion	Action
<b>Muscles that move the vertebral column</b>			
Erector spinae	Ilium, sacrum, vertebrae	Superior vertebrae	Extend, abduct, and rotate vertebrae
Deep back muscles	Vertebrae	Ribs Vertebrae	Extend, abduct, and rotate vertebrae
Rectus abdominis	Pubis	Xiphoid process of sternum & lower ribs	Flexes vertebrae; compress abdomen
External abdominal oblique	Rib cage	Iliac crest & fascia of rectus abdominis	Flexes & rotates vertebral column; compress abdomen
Internal abdominal oblique	Iliac crest and vertebrae	Lower ribs and fascia of rectus abdominis	Flexes & rotates vertebral column; compress abdomen
Transversus abdominis	Ribcage, vertebrae and iliac crest	Xiphoid process of sternum, fascia of rectus, abdominis and pubis	Compress abdomen



**Table 6-3. Upper limb muscles**

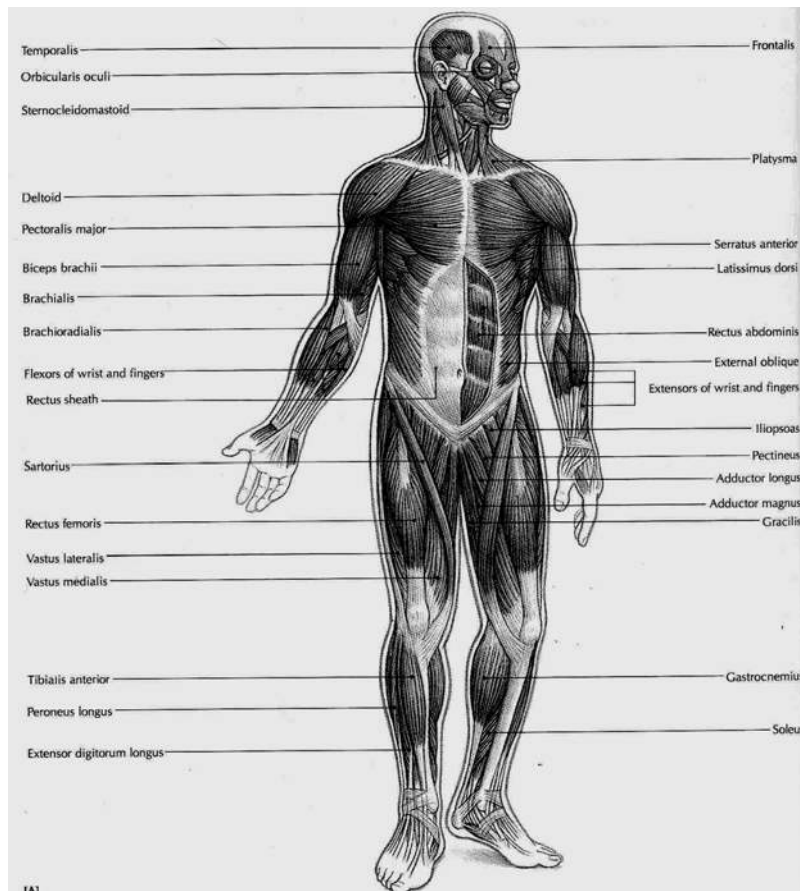
Muscle	Origin	Insertion	Action
<b>Muscles that move the scapula</b>			
Trapezius	Occipital bone and vertebrae	Scapula clavicle	holds scapula in place rotates scapula
Serratus anterior	Ribs	Medial border of the scapula	Rotates scapula and pulls anteriorly
<b>Muscles that move the arm</b>			
Pectoralis major	Sternum, ribs, and clavicle	Tubercle of humerus	Adducts and flexes arm
Lattismus dorsi	Vertebrae	Tubercle of humerus	Adducts and extends arm
Deltoid	Scapula and clavicle	Shaft of humerus	Abducts, flexes, and extends arm
Teres major	Scapula	Tubercle of humerus	Adducts and extends arm
Infraspinalis	Scapula	Tubercle of humerus	Extends arm
<b>Muscles that move the forearm</b>			
Brachialis	Shaft of humerus	Coracoids process of ulna	Flexes forearm
Biceps brachii	Coracoids process of scapula	Radial tuberosity	Supinates forearm
Triceps brachii	Shaft of humerus and lateral border of scapula	Olecranon process of ulna	Extends forearm
<b>Muscles that move the wrist and fingers</b>			

Anterior forearm muscles	Medial epicondyle	Carpals, metacarpals, and phalanges	Flex wrist, fingers and thumb; pronate forearm
Posterior forearm muscles	Lateral epicondyle	Carpals, metacarpals, and phalanges	Extend wrist, fingers and thumb; supinate forearm
Intrinsic hand muscles	Carpals metacarpals	Phalanges	Abduct, adduct, flex, and extend fingers and thumb

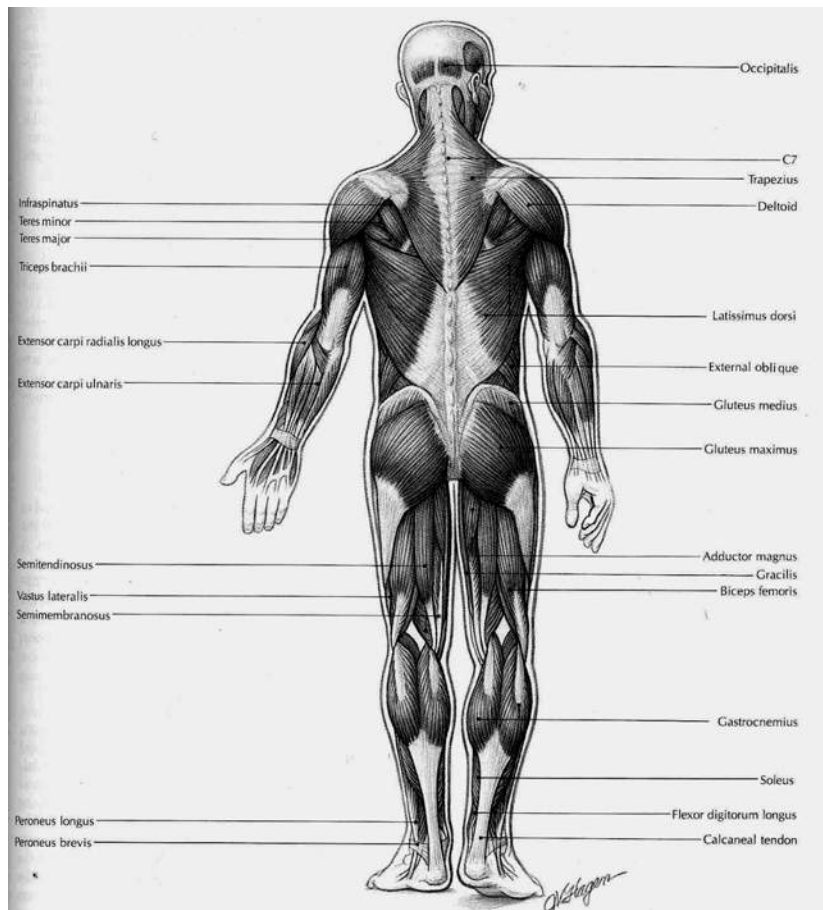
**Table 6-4. Lower limb muscles**

Muscle	Origin	Insertion	Action
<b>Muscles that move the thigh</b>			
Iliopsoas	Ilium and vertebrae	Trochanter of femur	Flexes thigh
Tensor fasciae latae	Anterior superior iliac spine	Lateral condyle of tibia	Abducts thigh
Gluteus maximus	Ilium, sacrum, and coccyx	Lateral side of femur	Extends and abducts thigh
Gluteus medius	Ilium	Trochanter of femur	Abducts thigh
Adductor muscles of thigh	Pubis	Femur	Adduct thigh
<b>Muscles that move the leg</b>			
Quadriceps femoris Rectus femoris	Anterior superior iliac spine	Tibial tuberosity	Extends leg and flexes thigh
Vastus lateralis	Femur	Tibial tuberosity	Extends leg
Vastus medialis	Femur	Tibial tuberosity	Extends leg

Vastus intermedius (not shown in illustration)	Femur	Tibial tuberosity	Extends leg
Sartorius	Anterior superior iliac spine	Tibia	Flexes leg and thigh
Hamstring muscles Biceps femoris	Ischium and femur	Fibula	Flexes leg and extends thigh
Semimembranosus	Ischium	Tibia	Flexes leg and extends thigh
Semitendinosus	Ischium	Tibia	Flexes leg and extends thigh
<b>Muscles that move the ankle and toes</b>			
Tibialis anterior	Tibia	Tarsal and first metatarsal	Dorsiflexes foot
Deep anterior leg muscles	Tibia or fibula	Phalanges, metatarsals, tarsals	Extend toes
Gastrocnemius	Medial and lateral epicondyle of femur	Calcaneus	Plantar flexes foot
Soleus	Tibia and fibula	Calcaneus	Plantar flexes foot
Deep posterior leg muscles	Tibia of fibula	Phalanges, metatarsals, tarsals	Evert foot
Peroneus muscle Intrinsic foot muscles	Fibula and tibia Tarsals or metatarsals	Tarsals and metatarsals Phalanges	Evert foot Abduct, adduct, flex, and extend toes



**Figure 6-6 Superficial muscles, anterior (front view)** (Source: Carola, R., Harley, J.P., Noback R.C., (1992), Human anatomy and physiology, Mc Graw hill inc, New York, 2<sup>nd</sup> ed,)



**Figure 6-7 Superficial muscles, posterior (back) view.** (Source: Carola, R., Harley, J.P., Noback R.C., (1992), Human anatomy and physiology, Mc Graw hill inc, New York, 2<sup>nd</sup> ed.)

## Review Questions

1. What is meant by the muscular system?
2. What are the three basic physiological functions of the muscular system?
3. Define the four physiological characteristics of muscle tissue.
4. Define fascia, muscle bundle, muscle fibre, myofibril, myofilament, and sarcomere.
5. Discuss the sliding filament mechanism of muscle contraction. How does a muscle relax?
6. Explain the role of each of the following in muscle contraction: actin and myosin, calcium, ATP, glycogen.
7. Differentiate the term in each of the following pairs:
  - a. Tendon and aponeurosis
  - b. Muscle origin and muscle insertion
  - c. Prime mover and antagonist
  - d. Isometric and isotonic contraction
8. When does oxygen debt occur? What is the role of lactic acid in oxygen debt? How is oxygen debt eliminated?
9. Name and describe the major actions and innervations of the principal muscles of the head and neck, upper extremities, trunk, and lower extremities.
10. List different basis according to which muscle are named.

# CHAPTER SEVEN

## THE NERVOUS SYSTEM

### Chapter Objectives:

**At the end of this chapter, the student should be able to:**

- Describe the generalized functions of the system as a whole
- Describe how the nervous tissue is organized
- Identify the major types of cells in the nervous system and discuss the function of each
- Identify types of neurons
- Briefly describe the mechanisms of transmission of a nerve impulse
- Briefly describe transmission at a synapse
- Define neurotransmitter and give several examples of them.
- List the components of a reflex arc
- List the divisions of the nervous system
- Identify the major anatomical components of the brain and spinal cord and briefly comment in the function of each.
- Identify and discuss the coverings and fluid spaces of the brain and spinal cord.
- Discuss spinal and cranial nerves

- Discuss the anatomical and functional characteristics of the two divisions of the autonomic nervous system
- Classify sense organs as special or general and explain the basic differences between the two groups.
- Discuss how a stimulus is converted into sensation.
- List the major senses.
- Describe the structure of the eye and the function of its components.
- Discuss the anatomy of the ear and its sensory function in hearing and equilibrium.
- Discuss the chemical receptors and their functions.
- Discuss the general sense organs and their functions.

### **Selected Key Terms**

The following terms are defined in the glossary:

Accommodation	Midbrain
Acetylcholine	Nerve
Action potential	Nerve impulse
Afferent	Nucleus
Autonomic nervous system	Neuron
Axon	Neurotransmitter
Brain stem	Ossicle
Cerebellum	Plexus



Cerebral cortex	Pons
Cerebrum	Proprioceptor
Choroid	Receptor
Cochlea	Reflex
Conjunctiva	Refraction
Cornea	Retina
Dendrite	Sclera
Diencephalons	Semicircular canal
Effector	Spinal cord
Efferent	Stimulus
Epinephrine	Synapse
Ganglion	Thalamus
Gray matter	Tract
Hypothalamus	Tympanic membrane
Lacrimal	Ventricle
Medulla oblongata	Vestibule
Meninges	White matter

### **General Function**

None of the body system is capable of functioning alone. All are interdependent and work together as one unit so that normal conditions within the body may prevail. Control of the body's billions of cells is accomplished mainly by two communication systems: the nervous system and the endocrine system. Both systems transmit information from

one part of the body to another, but they do it in different ways. The nervous system transmits information very rapidly by nerve impulses conducted from one body area to another. The endocrine system transmits information more slowly by chemicals secreted by ductless glands into blood stream and circulated from glands to other parts of the body. The nervous system serves as the chief coordinating agency. Conditions both within and outside the body are constantly changing; the purpose of the nervous system is to respond to these internal and external changes (known as stimuli) and so cause the body to adapt to new conditions. It is through the nerve impulse sent to the various organs by the nervous system that a person's internal harmony and the balance between the person and the environment are maintained. The nervous system has been compared to a telephone exchange, in that the brain and the spinal cord act as switching centres and the nerve trunks act as cables for carrying messages to and from these centres.

### **Cells of nervous system and their functions**

The two types of cells found in the nervous system are called **neurons** or nerve cells and **neuroglia**, which are specialized connective tissue cells. Neurons conduct impulses, whereas neuroglia supports neurons.

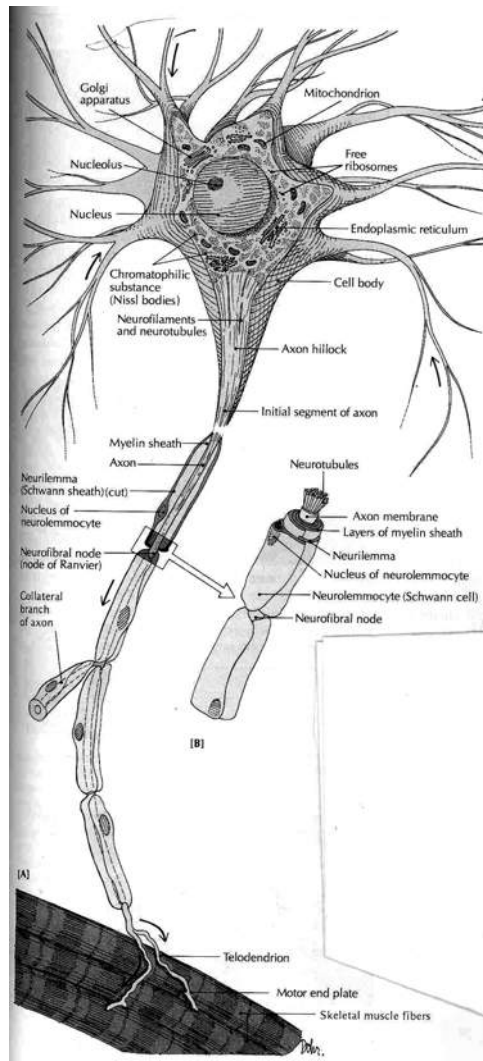
## Neurons

Each neuron consists of three parts: a main part called the neuron cell body, one or more branching projections called dendrites, and one elongated projection known as an axon. Identify each part on the neuron shown in figure 7-1. Dendrites are the processes or projections that transmit impulses to the neuron cell bodies, and axons are the processes that transmit impulses away from the neuron cell bodies.

Neurons can be classified structurally and functionally. The three types of functional classification of neurons are according to the direction in which they transmit impulses. These are: sensory neurons, motor neurons, and interneurons. Sensory neurons transmit impulses to the spinal cord and brain from all parts of the body. Motor neurons transmit impulses in the opposite direction-away from the brain and spinal cord. They do not conduct impulses to all parts of the body but only to two kinds of tissue-muscle and glandular epithelial tissue. Interneurons conduct impulses from sensory neurons to motor neurons. Sensory neurons are also called afferent neurons; motor neurons are called efferent neurons, and interneurons are called central or connecting neurons.

The axon shown in Figure 7-1, B, is surrounded by a segmented wrapping of a material called myelin sheath. Myelin sheath is a white, fatty substance formed by Schwann cells that wrap around some axons outside the central nervous system. Such fibers are called Myelinated fibers. In Figure 7-1, B, one such axon has been enlarged to show additional detail. Nodes of Ranvier are indentions between adjacent Schwann cells.

The outer cell membrane of a Schwann cell is called the neurilemma. The fact that axons in the brain and cord have no neurilemma is clinically significant because it plays an essential part in the regeneration of cut and injured axons. Therefore the potential for regeneration in the brain and spinal cord is far less than it is in the peripheral nervous system.



**Figure 7-1 Diagram of a typical neuron showing dendrites, a cell body, and an axon.** (Source: Carola, R., Harley, J.P., Noback R.C., (1992), Human anatomy and physiology, Mc Graw hill inc, New York, 2<sup>nd</sup> ed.)

### **Neuroglia**

Neuroglia does not specialize in transmitting impulses. Instead, they are special types of connective tissue cells. Their name is appropriate because it is derived from Greek word glia meaning "glue." One function of neuroglia cells is to hold the functioning neurons together and protect them.

### **Impulse Generation and Conduction**

#### **The Nerve Impulse**

The cell membrane of an unstimulated (resting) neuron carries an electric charge. Because of positive and negative ions concentrated on either side of the membrane, the inside of the membrane at rest is negative as compared with the outside. A nerve impulse is a local reversal in the charge on the nerve cell membrane that then spreads along the membrane like an electric current. This sudden electrical change in the membrane is called an action potential. A stimulus, then, is any force that can start an action potential. This electric change results from rapid shifts in sodium and potassium ions across the cell membrane. The reversal occurs very rapidly (in less than one thousandth of a second) and is followed by a rapid return of the membrane to its original state so that it can be stimulated again.

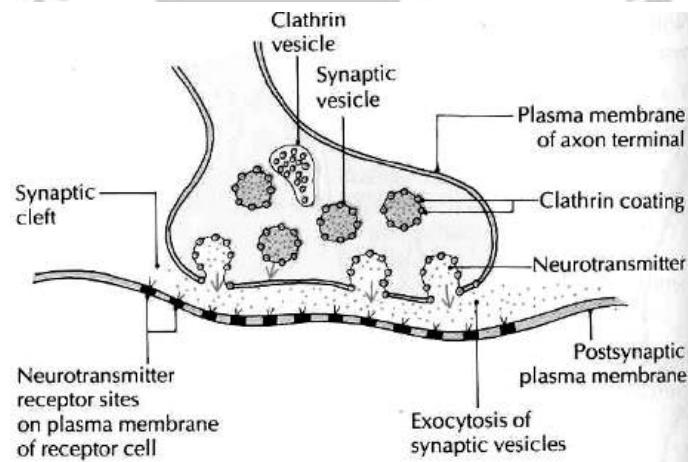
A myelinated nerve fiber conducts impulses more rapidly than an unmyelinated fiber of the same size because the electrical impulse "jumps" from node (space) to node in the myelin sheath instead of traveling continuously along the fiber.

### **The Synapse**

Each neuron is a separate unit, and there is no anatomic connection between neurons. How then is it possible for neurons to communicate? In other words, how does the axon of one neuron make functional contact with the membrane of another neuron? This is accomplished by the synapse, from a Greek word meaning "to clasp." Synapses are points of junction for the transmission of nerve impulses (Fig 7-3).

Within the branching endings of the axon are small bubbles (vesicles) containing a type of chemical known as a neurotransmitter. When stimulated, the axon releases its neurotransmitter into the narrow gap, the synaptic cleft, between the cells. The neurotransmitter then acts as a chemical signal to stimulate the next cell, described as the postsynaptic cell. On the receiving membrane, usually that of a dendrite, sometimes another part of the cell, there are special sites, or receptors, ready to pick up and respond to specific neurotransmitters. Receptors in the cell membrane influence how or if that cell will respond to a given neurotransmitter.

Although there are many known neurotransmitters, the main ones are epinephrine, also called adrenaline; a related compound, norepinephrine, or noradrenaline; and acetylcholine. Acetylcholine (ACh) is the neurotransmitter released at the neuromuscular junction, the synapse between a neuron and a muscle cell. All three of the above neurotransmitters function in the autonomic nervous system. It is common to think of neurotransmitters as stimulating the cells they reach; in fact, they have been described as such in this discussion. Note, however, that some of these chemicals act to inhibit the postsynaptic cell and keep it from reacting.



**Figure 7-2 Close-up view of a synapse. The axon ending has vesicles containing neurotransmitter, which is released across the synaptic cleft to the membrane of the next cell** (Source: Carola, R., Harley, J.P., Noback R.C., (1992), Human anatomy and physiology, Mc Graw hill inc, New York, 2<sup>nd</sup> ed.)



### **The Reflex Arc**

As the nervous system functions, both external and internal stimuli are received, interpreted, and acted on. A complete pathway through the nervous system from stimulus to response is termed a reflex arc (Fig. 7-3). This is the basic functional pathway of the nervous system. The parts of a typical reflex arc are:

1. Receptor-the end of a dendrite or some specialized receptor cell, as in a special sense organ, that detects a stimuli.
2. Sensory neuron, or afferent neuron-a cell that transmits impulses toward the CNS.
3. Central neuron-a cell or cells within the CNS. These neurons may carry impulses to and from the brain, may function within the brain, or may distribute impulses to different regions of the spinal cord.
4. Motor neuron, or efferent neuron-a cell that carries impulses away from the CNS.
5. Effector-a muscle or a gland outside the CNS that carries out a response.

At its simplest, a reflex arc can involve just two neurons, one sensory and one motor, with a synapse in the CNS. There are very few reflex arcs that require only this minimal number of neurons. The knee jerk reflex is one of the few examples in humans. Most reflex arcs involve many more, even hundreds, of connecting neurons within the central nervous system.

### **Division of the Nervous System**

The nervous system as a whole consists of two principal divisions called the central nervous system and peripheral nervous system (Figure 7-4). Because the brain and spinal cord occupy a midline or central location in the body, they are together called the central nervous system or CNS. Similarly, the usual designation for the nerves of the body is the peripheral nervous system or PNS. Use of the term peripheral is appropriate because nerves extend to outlying or peripheral parts of the body. A subdivision of the peripheral nervous system called the autonomic nervous system (ANS) consists of structures that regulate the body's autonomic or involuntary functions (for example, the heart rate, the contractions of the stomach, and intestines, and the secretion of chemical compounds by glands).

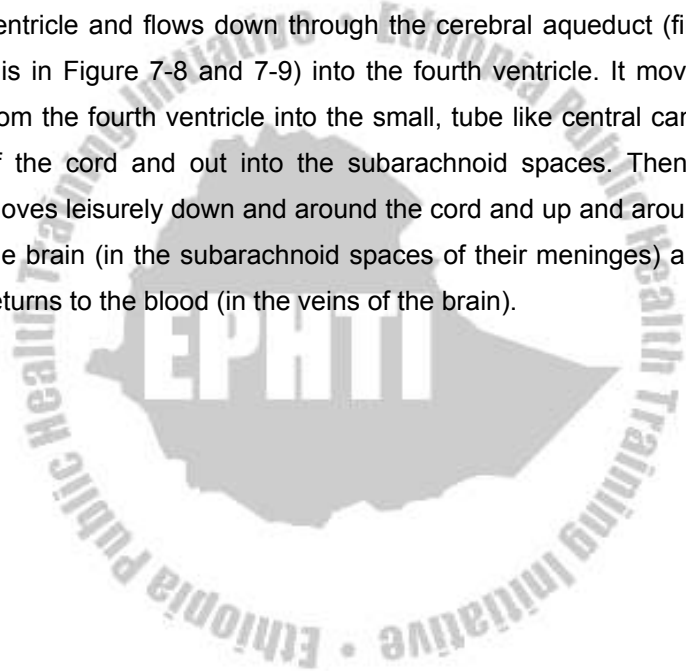
### **Central Nervous System**

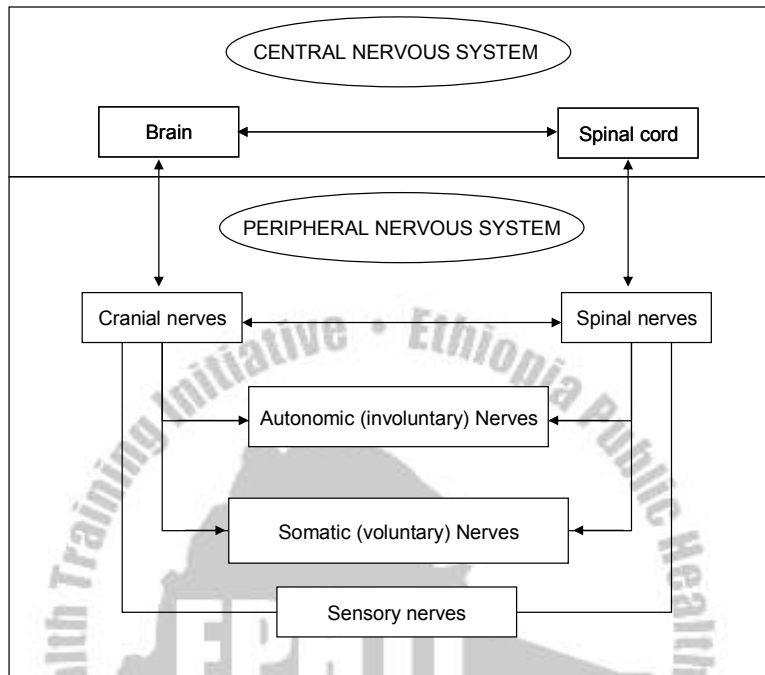
The CNS as its name implies, is centrally located. Its two major structures, the brain and spinal cord, are found along the midsagittal plane of the body. The brain is protected in the cranial cavity of the skull, and the spinal cord is surrounded in the spinal column. In addition, protective membranes called **meninges** cover the brain and spinal cord.

### **Covering and Fluid Spaces Of the Brain and Spinal Cord**

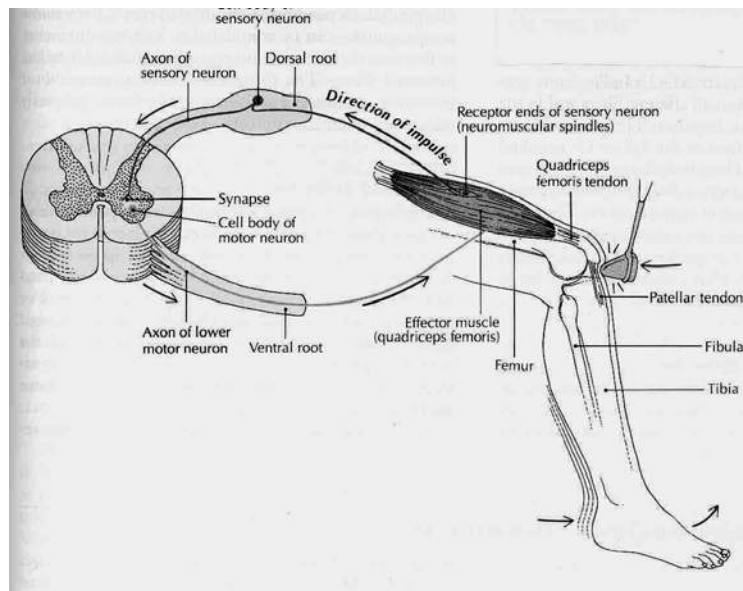
Nervous tissue is not a sturdy tissue. Even moderate pressure can kill nerve cells, so nature safeguards the chief organs made of this tissue—the spinal cord and the brain—by surrounding them with three fluid-containing membranes called the meninges. The meninges are then surrounded by bone. The spinal meninges form tube like covering around the spinal cord and line the bony vertebral foramen of the vertebrae that surround the cord. Look at Figure 7-7, and you can identify the three layers of the spinal meninges. They are the dura mater, which is the tough outer layer that lines the vertebral canal, the pia mater, which is the innermost membrane covering the spinal cord itself, and the arachnoid, which is the membrane between the dura and pia mater. The term arachnoid means "cobweblike." It comes from arachne, which is the Greek word for spider. The meninges that form the protective covering around the spinal cord also extend up and around the brain to enclose it completely. Fluid fills the subarachnoid spaces between the pia mater and arachnoid in the brain and spinal cord. This fluid is called cerebrospinal fluid (CSF). Cerebrospinal fluid also fills spaces in the brain called cerebral ventricles. In Figure 7-8, you can see the irregular shapes of the ventricles of the brain. These illustrations can also help you visualize the location of the ventricles if you remember that these large spaces lie deep inside the brain and that there are two lateral ventricles. One

lies inside the right half of the cerebrum (the largest part of the human brain), and the other lies inside the left half of the cerebrum. CSF is one of the body's circulating fluids. It forms continually from fluid filtering out of the blood in a network of brain capillaries known as the choroid plexus and into the ventricles. CSF seeps from the lateral ventricles into the third ventricle and flows down through the cerebral aqueduct (find this in Figure 7-8 and 7-9) into the fourth ventricle. It moves from the fourth ventricle into the small, tube like central canal of the cord and out into the subarachnoid spaces. Then it moves leisurely down and around the cord and up and around the brain (in the subarachnoid spaces of their meninges) and returns to the blood (in the veins of the brain).





**Figure 7-4 Divisions of the Nervous system** (From Thibodeau, Gary A. and Kevin T. The Human Body in Health and Disease, ed. 6, Philadelphia, 1987, J.B.Lippincot Company)



**Figure 7-3 Reflex arc showing the pathway of impulses and a cross section of the spinal cord** (Source: Carola, R., Harley, J.P., Noback R.C., (1992), Human anatomy and physiology, Mc Graw hill inc, New York, 2<sup>nd</sup> ed.)

### Divisions of the Brain

The brain, one of our largest organs, consists of the following major divisions, named in ascending order beginning with most inferior part:

- I. Brain stem
  - A. Medulla oblongata
  - B. Pons
  - C. Midbrain
- II. Cerebellum
- III. Diencephalon

A. Hypothalamus

B. Thalamus

IV. Cerebrum

Observe in Figure 7-5 the location and relative sizes of the medulla, pons, cerebellum, and cerebrum. Also identify the midbrain.

### **Brain Stem**

The lowest part of the brain stem is the medulla oblongata. Immediately superior to the medulla lies the pons and superior to that the midbrain. Together these three structures are called the brain stem (Figure 7-5).

The medulla oblongata is an enlarged, upward extension of the spinal cord. It lies just inside the cranial cavity superior to the large hole in the occipital bone called the foramen magnum. Like the spinal cord, the medulla consists of gray and white matter, but their arrangement differs in the two organs. In the medulla, bits of gray matter mix closely and intricately with white matter to form the reticular formation (reticular means "netlike"). In the spinal cord, gray and white matter does not intermingle; gray matter forms the interior core of the cord, and white matter surrounds it. The pons and midbrain, like the medulla, consist of white matter and scattered bits of gray matter.

All three parts of the brain stem function as two-way conduction paths. Sensory fibers conduct impulses up from the cord to other parts of the brain, and motor fibers conduct impulses down from the brain to the cord. The cardiac, respiratory, and vasomotor centers (collectively called the vital centers) are located in the medulla. Impulses from these centers control heartbeat, respirations, and blood vessel diameter (which is important in regulating blood pressure). In addition, many important reflex centers lie in the brain stem.

### **Diencephalon**

The diencephalon is a small but important part of the brain located between the midbrain inferiorly and the cerebrum superiorly. It consists of two major structures: the hypothalamus and the thalamus. The ventricles of the diencephalon is the 3<sup>rd</sup> ventricle.

**Hypothalamus.** The hypothalamus, as its name suggests, is located inferior to the thalamus. The posterior pituitary gland, the stalk that attaches it to the undersurface of the brain, and areas of gray matter located in the sidewalls of a fluid-filled space called the third ventricle are extensions of the hypothalamus. Identify the pituitary gland and the hypothalamus in Figure 7-5.

The old adage, "Don't judge by appearances," applies well to appraising the importance of the hypothalamus. Measured by



size, it is one of the least significant parts of the brain, but measured its contribution to healthy survival; it is one of the most important brain structures. Impulses from neurons whose dendrites and cell bodies lie in the hypothalamus are conducted by their axons to neurons located in the spinal cord, and many of these impulses are then relayed to muscles and glands all over the body. Thus the hypothalamus exerts a major control over virtually all-internal organs. Among the vital functions that it helps control are the heartbeat, constriction and dilation of blood vessels, and contractions of the stomach and intestines.

Some neurons in the hypothalamus function in a surprising way; they make the hormones that the posterior pituitary gland secretes into the blood. Because of one of these hormones (called antidiuretic hormone or ADH) affects the volume of urine excreted, the hypothalamus plays an essential role in maintaining the body's water balance.

Some of the neurons in the hypothalamus function as endocrine glands. Their axons secrete chemicals called releasing hormones into the blood, which then carries them to the anterior pituitary gland. Releasing hormones, as their name suggests, control the release of certain anterior pituitary hormones. These in turn influence the hormone secretion of other endocrine glands. Thus the hypothalamus indirectly helps control the functioning of every cell in the body.

The **hypothalamus** is a crucial part of the mechanism for maintaining body temperature. Therefore a marked elevation in body temperature in the absence of disease frequently characterizes injuries or other abnormalities of the hypothalamus. In addition, this important center is involved in functions such as the regulation of water balance; sleep cycles, and the control of appetite and many emotions involved in pleasure, fear, anger, sexual arousal, and pain.

**Thalamus.** Just superior to the hypothalamus is a dumbbell-shaped section or largely gray matter called the thalamus. Each enlarged end of the dumbbell lies in a lateral wall of the third ventricle. The thin center section of the thalamus passes from left to right through the third ventricle. The thalamus is composed chiefly of dendrites and cell bodies of neurons that have axons extending up to the sensory areas of the cerebrum. It performs the following functions :

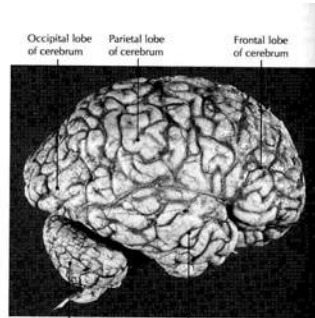
1. It helps produce sensations. Its neurons relay impulses to the cerebral cortex from the sense organ of the body.
2. It associates sensations with emotions. Almost all sensations are accompanied by a feeling of some degree of pleasantness or unpleasantness. The way that these pleasant and unpleasant feelings are produced is unknown except that they seem to be associated with the arrival of sensory impulses in thalamus.
3. It plays a part in the so -called arousal or alerting

mechanism.

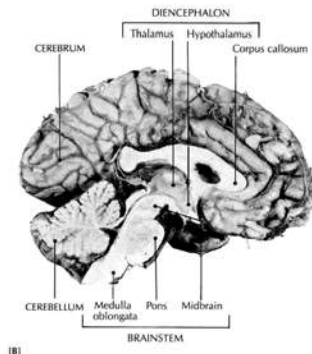
- It contains important nuclei such as medial geniculate which is responsible for auditory sense and lateral geniculate which is responsible for vision.

[A] Right lateral view of the external surface of the brain, showing the cerebellum and four of the six cerebral lobes. [B] Right sagittal section. [C] Right sagittal section showing the major subdivisions of the brain and its connection to the spinal cord.

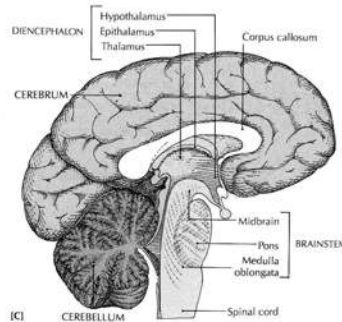
THE FOUR MAJOR DIVISIONS OF THE BRAIN	
BRAINSTEM	<ul style="list-style-type: none"> <li>Midbrain</li> <li>Pons</li> <li>Medulla oblongata</li> </ul>
CEREBELLUM	
CEREBRUM	
DIENCEPHALON	<ul style="list-style-type: none"> <li>Thalamus</li> <li>Hypothalamus</li> <li>Epithalamus</li> <li>Ventral thalamus</li> </ul>



[A] Cerebellum Temporal lobe of cerebrum



[B]



[C]

**Figure 7-5 Major regions of the Central Nervous System.** A, Sagittal sections of the brain and spinal cord. B, Section of preserved brain (Source: Carola, R., Harley, J.P., Noback R.C., (1992), Human anatomy and physiology, Mc Graw hill inc, New York, 2<sup>nd</sup> ed.)

## Cerebellum

**Structure.** Look at Figure 7-5 to find the location, appearance, and size of the cerebellum. The cerebellum is the second largest part of the human brain. It lies under the occipital lobe of the cerebrum. In the cerebellum, gray matter composes the outer layer, and white matter composes the bulk of the interior.

**Function.** Most of our knowledge about cerebellar functions has come from observing patients who have some sort of disease of the cerebellum and from animals who have had the cerebellum removed. From such observations, we know that the cerebellum plays an essential part in the production of normal movements. Perhaps a few examples will make this clear. A patient who has a tumor of the cerebellum frequently loses balance and may topple over and reel like a drunken person when walking. It may be impossible to coordinate muscles normally. Frequent complaints about being clumsy and unable to even drive a nail or draw a straight line are typical. With the loss of normal cerebellar functioning, the ability to make precise movements is lost. The general functions of the cerebellum, then, are to produce smooth coordinated movements, maintain equilibrium, and sustain normal postures.

## **Cerebrum**

The cerebrum is the largest and uppermost part of the brain. If you were to look at the outer surface of the cerebrum, the first features you would notice might be its many ridges and grooves. The ridges are called convolutions or gyri, and the grooves are called sulci. The deepest sulci are called fissures; the longitudinal fissure divides the cerebrum into right and left halves or hemispheres. These halves are almost separate structures except for their lower midportions, which are connected by a structure called the corpus callosum (Figure 7-5). Two deep sulci subdivide each cerebral hemisphere into four major lobes and each lobe into numerous convolutions. The lobes are named for the bones that lie over them: the frontal lobe, the parietal lobe, the temporal lobe, and the occipital lobe. Identify these in Figure 7-6, A.

A thin layer of gray matter, made up of neuron dendrites and cell bodies, composes the surface of the cerebrum. Its name is the cerebral cortex. White matter made up of bundles of neuronal fibers (tracts), composes most of the interior of the cerebrum. Within this white matter, however, are a few islands of gray matter known as the basal ganglia, whose functioning is essential for producing automatic movements and postures. Parkinson's disease is a disease of the basal ganglia. Because shaking or tremors are common symptoms of Parkinson's disease, it is also called "shaking palsy."

The nerve fibres of the white matter of the cerebral hemispheres are of three groups: **commissural**, **association** and **projection**.

**Commissural fibres** unite corresponding areas of the cortex of the two hemispheres across the midline. They comprise the **corpus callosum**, and the anterior and fornix commissures.

The corpus callosum is a broad band of fibres passing between corresponding cortical areas of the two hemispheres. It lies at the base of the median longitudinal fissure and above the diencephalons and midbrain. In midsagittal section it is the shape of a hook lying horizontally with its bend anteriorly and its point downwards. The pointed portion is known as the rostrum, the bend as genu, the horizontal part as the body and the expanded posterior end as the splenium. The callosum extends laterally into each hemisphere; the anterior fibres pass forwards into the frontal pole and are known as the forceps major, passes backwards into the occipital poles. The rostrum of the corpus callosum fuses inferiorly with the lamina terminalis. A bundle of fibres within the lamina, the anterior commissure, unites the piriform areas and the olfactory tracts of the two sides. The fornix (hippocampal) commissure is found on the undersurface of the corpus callosum where the two crura meet and form the fornix. Fibres here pass across the midline between the two hippocampi.

**Association fibres** may be long or short, uniting adjacent or widely separated gyri of the same hemisphere.

**Projection fibres** ascend from or descend to lower lying parts of the central nervous system. Many form a well defined layer, the internal capsule, between the lentiform nucleus laterally and the thalamus and caudate nucleus medially. Superiorly its fibres fan out as the corona radiata interdigitating with the fibres of the corpus callosum. In horizontal section the capsule is V-shaped. It possesses an anterior limb (between the caudate nucleus and the lentiform nucleus and crossed by fibres and grey matter uniting the two structures), an apex (the genu) pointing medially, and a posterior limb lying between the thalamus and the lentiform nucleus.

The anterior limb carries (a) frontopontine fibres from the frontal lobe to the pons, and (b) fibres from the thalamus (medial and ventro-anterior nuclei) to the frontal lobe. The posterior limb carries from before backwards, (a) pyramidal fibres from the motor cortex which pass to the cranial nerve nuclei (corticospinal fibres), (b) somatosensory fibres passing from thalamus (ventroposterior nucleus) to the postcentral (somatosensory) cortex, (c)temporopontine fibres from the temporal lobe to the pons, (d) the auditory radiations passing from the medial geniculate body under the lentiform nucleus, to the superior temporal gyrus, (e) the visual radiations

passing from the lateral geniculate body around the lateral aspect of the posterior horn of the lateral ventricle to the visual cortex.

The course of the fibres is such that many cross the midline (decussate) and end on the opposite (contralateral) side. Some fibres however end on the same (ipsilateral) side. The motor areas of each hemisphere control the voluntary muscles of the contralateral side of the body and the sensory areas receive information from the contralateral side.

What functions does the cerebrum perform? This is a hard question to answer briefly because the neurons of the cerebrum do not function alone. They function with many other neurons in many other parts of the brain and in the spinal cord. Neurons of these structures continually bring impulses to cerebral neurons and continually transmit impulses away from them. If all other neurons were functioning normally and only cerebral neurons were not functioning, here are some of the things that you could not do. You could not think or use your will. You could not remember anything that has ever happened to you. You could not decide to make the smallest movement, nor could you make it. You would not see or hear. You could not experience any of the sensations that make life so rich and varied. Nothing would anger or frighten you, and nothing would bring you joy or



sorrow. You would, in short, be unconscious. These terms, then sum up cerebral functions: Consciousness, thinking, memory, sensations, emotions, and willed movements. Figure 7- 6, B, shows the areas of the cerebral cortex essential for willed movements, general sensations, vision, hearing, and normal speech.

It is important to understand that very specific areas of the cortex have very specific functions. For example, the temporal lobe's auditory areas interpret incoming nervous signals from the ear as very specific sounds. The visual area of the cortex in the occipital lobe helps you identify and understand specific images. Localized areas of the cortex are directly related to specific functions, as shown in Figure 7-6, B. This explains the very specific symptoms associated with an injury to localized areas of the cerebral cortex after a stroke or traumatic injury to the head. Table 7-1 summarizes the major components of the brain and their main functions.

## **Spinal Cord**

### **Location of the Spinal Cord**

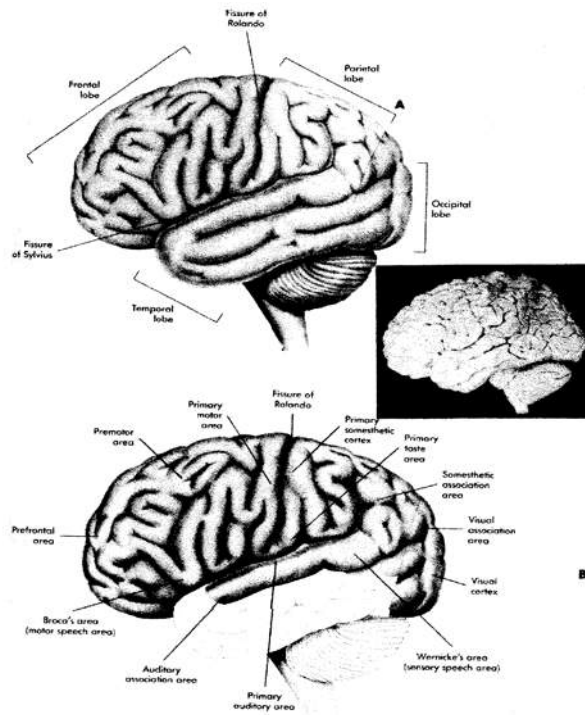
In the embryo, the spinal cord occupies the entire spinal canal and so extends down into the tail portion of the vertebral column. However, the column of bone grows much more rapidly than the nerve tissue of the cord, so that eventually the

end of the cord no longer reaches the lower part of the spinal canal. This disparity in growth continues to increase; in the adult the cord ends in the region just below the area to which the last rib attaches (between the first and the second lumbar vertebrae).

### **Structure of the Spinal Cord**

The spinal cord lies within the vertebral canal and extends from the foramen magnum to the level of the second lumbar vertebrae after which a fibrous remnant, the filum terminale, descends to be attached to the back of the coccyx. The cord is about 45 cm long. It is cylindrical in shape, flattened slightly anteroposteriorly, and has cervical and lumbar enlargements where the nerves supplying the upper and lower limb originate. The enlargements lie opposite the lower cervical and lower thoracic vertebrae. Since the spinal cord is shorter than the vertebral canal, the nerves descend with increasing obliquity before leaving the canal through the intervertebral foramina. The collection of lower lumbar, sacral and coccygeal nerves below the spinal cord, with the filum terminale, is known as the **cauda equina**. The cord has an **anterior median fissure** and a **posterior median sulcus**. On its sides the rootlets of the spinal nerves emerge from **anterolateral** and **posterolateral sulci**.

The spinal cord (see Figure 7-3) has a small, irregular shaped internal section that consists of gray matter (nerve cell bodies) and a larger area surrounding this gray part that consists of white matter (nerve cell fibers). The gray matter is so arranged that a column of cells extend up and down dorsally, one on each side; another column is found in the ventral region on each side. These two pairs of columns, called the dorsal and ventral horns, give the gray matter an H-shaped appearance in cross section. In the center of the gray matter is a small channel, central canal that contains cerebrospinal fluid, the liquid that circulates around the brain and spinal cord. The white matter consists of thousands of nerve cell fibers arranged in three areas external to the gray matter on each side.



**Figure 7-6 The cerebrum. A, the lobes of the cerebrum. B, Functional regions of the cerebral cortex.** (From Thibodeau, Gary A. and Kevin T. The Human Body in Health and Disease, ed. 6, Philadelphia, 1987, J.B.Lippincot Company)

### Functions of the Spinal Cord

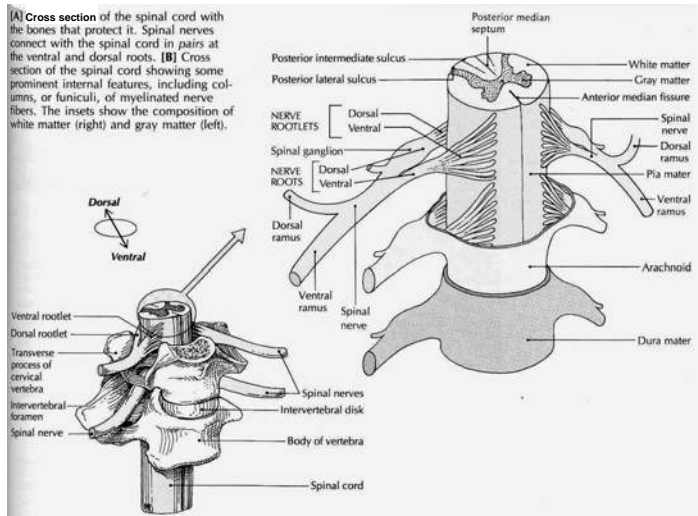
The spinal cord is the link between the spinal nerves and the brain. It is also a place where simple responses, known as reflexes can be coordinated even without involving the brain. The functions of the spinal cord may be divided into three categories:

1. Conduction of sensory impulses upward through ascending tracts to the brain
2. Conduction of motor impulses from the brain down through descending tracts to the efferent neurons that supply muscles or glands
3. Reflex activities. A reflex is a simple, rapid, and automatic response involving very few neurons.

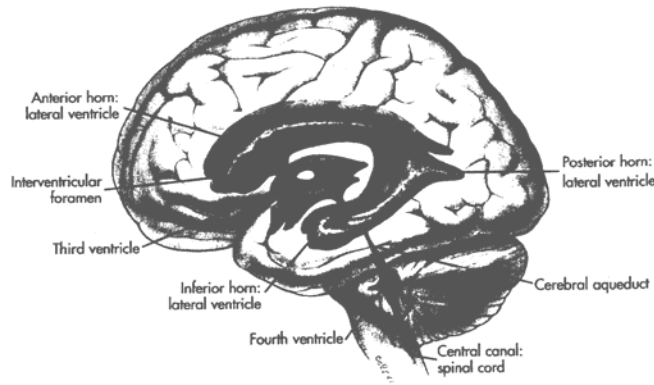
When you fling out an arm or leg to catch your balance, withdraw from a painful stimulus, or blink to avoid an object approaching your eyes, you are experiencing reflex behaviour. A reflex pathway that passes through the spinal cord alone and does not involve the brain is termed a spinal reflex. The stretch reflex, in which a muscle is stretched and responds by contracting, is one example. If you tap the tendon below the kneecap (the patellar tendon), the muscles of the anterior thigh (quadriceps femoris) contracts, eliciting the knee jerk. Such stretch reflexes may be evoked by appropriate tapping of most large muscles (such as the triceps brachii in the arm and the gastrocnemius in the calf of the leg). Because reflexes occur automatically, they are used in physical examinations to test the condition of the nervous system.

**Table 7-1** Functions of Major Divisions of the Brain

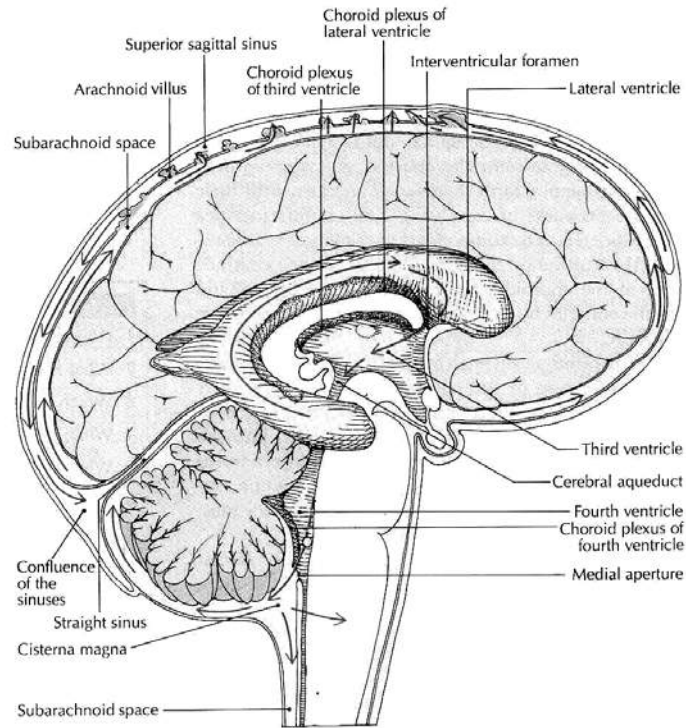
BRAIN AREA	FUNCTION
<b>Brain stem</b>	
Medulla oblongata	Two-way conduction pathway between the spinal cord and higher brain centers; cardiac, respiratory, and vasomotor control center
Pons	Two-way conduction pathway between areas of the brain and other regions of the body; Influences respiration
Midbrain	Two-way conduction pathway; relay for visual and auditory impulses
<b>Diencephalon</b>	
Hypothalamus	Regulation of body temperature, water balance, sleep cycle control appetite, and sexual arousal
Thalamus	Sensory relay station from various body areas to cerebral cortex; emotions and alerting or arousal mechanisms
<b>Cerebellum</b>	Muscle coordination; maintenance of equilibrium and posture
<b>Cerebrum</b>	Sensory perception, emotions willed movements, consciousness, and memory



**Figure 7-7 Spinal cord.** The meninges, spinal nerves, and sympathetic trunk are visible in the illustration (Source: Carola, R., Harley, J.P., Noback R.C., (1992), Human anatomy and physiology, Mc Graw hill inc, New York, 2<sup>nd</sup> ed,)



**Figure 7-8 Fluid spaces of the brain** (From Thibodeau, Gary A. and Kevin T. The Human Body in Health and Disease, ed. 6, Philadelphia, 1987, J.B.Lippincot Company)



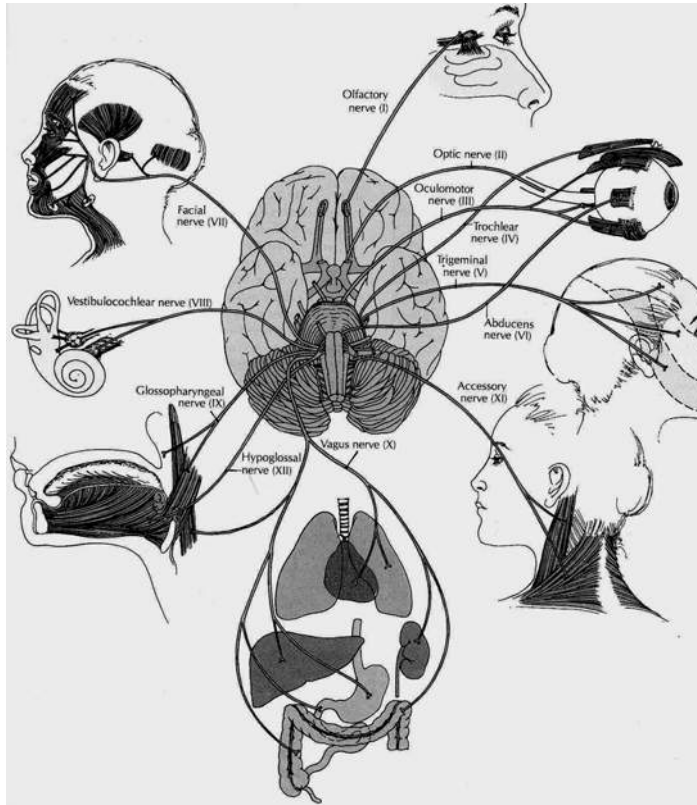
**Figure 7-9 Flow of cerebrospinal fluid** (Source: Carola, R., Harley, J.P., Noback R.C., (1992), Human anatomy and physiology, Mc Graw hill inc, New York, 2<sup>nd</sup> ed.)

### Peripheral Nervous System

The nerves connecting the brain and the spinal cord to other parts of the body constitutes the peripheral nervous system (PNS). This system includes cranial and spinal nerves that connect the brain and spinal cord, respectively, to peripheral structures such as the skin surface and the skeletal muscles.



In addition, other structures in the autonomic nervous system (ANS) are considered part of the PNS. These connect the brain and spinal cord to various glands in the body and to the cardiac and smooth muscle in the thorax and abdomen.



**Figure 7-10 Base of the brain showing cranial nerves** (Source: Carola, R., Harley, J.P., Noback R.C., (1992), Human anatomy and physiology, Mc Graw hill inc, New York, 2<sup>nd</sup> ed,)

## **Nerves**

A nerve is a bundle of nerve cell fibers located outside the CNS. Bundles of nerve cell fibers within the CNS are tracts. Tracts are located within the brain and also within the spinal cord to conduct impulses to and from the brain. A nerve or tract can be compared to an electric cable made up of many wires. As with muscles, the "wires," or nerve cell fibers in a nerve, are bound together with connective tissue.

A few of the cranial nerves have only sensory fibers for conducting impulses toward the brain. These are described as sensory, or afferent, nerves. A few of the cranial nerves contain only motor fibers for conducting impulses away from the brain and are classified as motor, or efferent, nerves. However, the remainder of the cranial nerves and all of the spinal nerves contain both sensory and motor fibers and are referred to as mixed nerves.

## **Cranial Nerves**

### **Location of the Cranial Nerves**

Cranial nerves are nerves that are attached to the brain. There are 12 pairs of cranial nerves (henceforth, when a cranial nerve is identified, a pair is meant). They are numbered according to their connection with the brain;

beginning at the front and proceeding back (Figure 7-10). The first 9 pairs and the 12th pair supply structures in the head.

### **General Functions of the cranial nerves**

From the functional point of view, we may think of the kinds of messages the cranial nerves handle as belonging to one of four categories:

1. Special sensory impulses, such as for smell, taste, vision, and hearing
2. General sensory impulses, such as those for pain, touch, temperature, deep muscle sense, pressure, and vibrations
3. Somatic motor impulses resulting in voluntary control of skeletal muscles
4. Viscera motor impulses producing involuntary control of glands and involuntary muscles (cardiac and smooth muscle). These motor pathways are part of the autonomic nervous system, parasympathetic division.

### **Names and Functions of the Cranial Nerves**

The 12 cranial nerves are always numbered according to the traditional Roman style. A few of the cranial nerves—I, II, and VIII—contain only sensory fibers; some—III, IV, VI, XI and XII—contain all or mostly motor fibers. The remainder—V, VII, IX, and X—contain both sensory and motor fibers; they are known as mixed nerves. All 12 nerves are listed below:

- I. The **olfactory nerve** they supply the olfactory mucous membrane in the upper part of the nasal cavity. The nerve fibres originate in the bipolar olfactory cells of the mucosa and join to form 15-20 olfactory bundles which pass through the cribriform plate of the ethmoid bone to reach the olfactory bulb.
- II. The **optic nerve** it is the sensory nerve of the retina. Its fibres originate in the ganglion layer and converge on the posterior part of the eye ball. The nerve passes backwards through the orbit and optic canal into the middle cranial fossa where it unites with the nerve of opposite side of the optic chiasma.
- III. The **oculomotor nerve** this nerve has somatic motor and general visceral (parasympathetic) motor fibres. The somatic fibres supply the bulbar muscles, except superior oblique and lateral rectus. The parasympathetic fibres synapse in the ciliary ganglion and supply the sphincter pupillae and ciliary muscle. The nuclei of the nerve are situated in the upper midbrain in the periaqueductal grey matter. The nerve fibres pass forwards through the midbrain and leave it between the cerebral peduncles. The nerve passes through the posterior and middle cranial fossae and divides into superior and inferior divisions near the superior orbital fissure.
- IV. The **trochlear nerve** this is the somatic motor nerve

supply to the superior oblique. Its nucleus lies in the lower midbrain in the peri-aqueductal grey matter. The fibres pass posteriorly and undergo a dorsal decussation with the nerve of the opposite side caudal to the inferior colliculi the nerve then passes forwards through the posterior and middle cranial fossae, enters the orbit through the superior orbital fissure and supplies superior oblique.

- V. The **trigeminal nerve** is the great sensory nerve of the face and head. It has three branches that transport general sense impulses (e.g., pain, touch, temperature) from the eye, the upper jaw, and the lower jaw. The third branch is joined by motor fibers to the muscles of mastication (chewing).
- VI. The **abducens nerve** is a somatic motor nerve supplying lateral rectus. Its nucleus is situated in the lower pons. The nerve leaves the inferior border of the pons near the midline, passes forwards through the posterior and middle cranial fossae, the cavernous sinus and the orbit, and supplies lateral rectus.
- VII. The **facial nerve** is largely motor. Branches from the facial nerve supply all the muscles of facial expression. This nerve also includes special sensory fibers for taste (anterior two thirds of the tongue), and it contains secretory fibers to the smaller salivary glands (the submandibular and sublingual) and to the lacrimal gland

- VIII. The **vestibulocochlear nerve** contains special sensory fibers for hearing as well as those for balance from the semi circular canals of the internal ear. This nerve is also called the auditory or acoustic nerve.
- IX. The **glossopharyngeal nerve** contains general sensory fibers from the back of the tongue and the pharynx (throat). This nerve also contains sensory fibers for taste from the posterior third of the tongue, secretory fibers that supply the largest salivary gland (parotid), and motor nerve fibers to control the swallowing muscles in the pharynx.
- X. The **vagus nerve** is the longest cranial nerve. (Its name means "wanderer. ") It supplies most of the organs in the thoracic and abdominal cavities. This nerve also contains motor fibers to the larynx (voice box) and pharynx, and to glands that produce digestive juices and other secretions.
- XI. The **accessory nerve** (formerly called the spinal accessory nerve) is a motor nerve with two branches. One branch controls two muscles of the neck, the trapezius and sternocleidomastoid ; the other supplies muscles of the larynx
- XII. The **hypoglossal nerve**, the last of the 12 cranial nerves, carries impulses controlling the muscles of the tongue.

## **Spinal Nerves**

### **Location and Structure of Spinal Nerves**

Spinal nerves arise from spinal cord. There are 31 pairs of spinal nerves, each pair numbered according to the level of the spinal cord from which it arises (Figure 7-11). Each nerve is attached to the spinal cord by two roots; the dorsal root and the ventral root (see Figure 7-3). The roots are formed from a number of rootlets which emerge from the anterolateral and posterolateral sulci of the spinal cord. The ventral root carries efferent (motor) fibres from the cord and the dorsal root, afferent (sensory) fibres to the cord. The cell bodies of the sensory fibres are situated in a ganglion on the dorsal root. The spinal nerves are therefore a mixture of motor and sensory fibres. Each nerve leaves the vertebral canal through an intervertebral foramen and soon divides into a large ventral and smaller dorsal ramus (branch).

The adjacent ventral rami of most regions communicate to form plexuses (cervical, brachial and lumbosacral) while those of the thoracic region become the intercostals and subcostal nerves. The dorsal rami pass backwards into the postvertebral muscles and divide into medial and lateral branches. These rami supply the muscles and skin over the posterior aspect of the body but give no branches to the limbs. The ventral rami

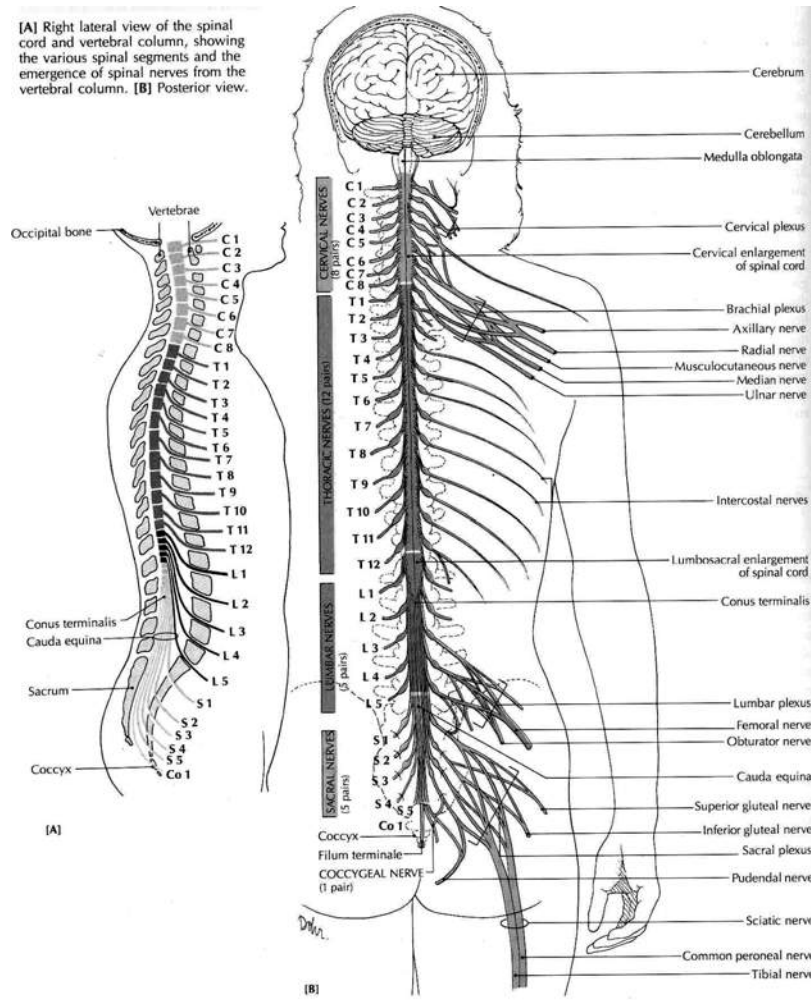
supply the anterior and lateral wall of the back and the lower limbs.

### **Branches of the Spinal Nerves**

Each spinal nerve continues only a very short distance away from the spinal cord and then branches into small posterior divisions and rather large anterior divisions. The larger anterior branches interlace to form networks called plexuses, which then distribute branches to the body parts. The three main plexuses are described as follows:

1. The cervical plexuses supplies motor impulses to the muscles of the neck and receive sensory impulses from the neck and the back of the head. The phrenic nerve, which activates the diaphragm, arises from this plexus.
2. The brachial plexus sends numerous branches to the shoulder, arm, forearm, wrist, and hand. The radial nerve emerges from the brachial plexus.
3. The lumbosacral plexus supplies nerves to the lower extremities. The largest of these branches is the sciatic nerve, which leaves the dorsal part of the pelvis, passes beneath the gluteus maximus muscle, and extends down the back of the thigh. At its beginning it is nearly 1 inch thick, but it soon branches to the thigh muscles; near the knee it forms two subdivisions that supply the leg and the foot.





**Figure 7-11 Spinal cord and spinal nerves** (Source: Carola, R., Harley, J.P., Noback R.C., (1992), Human anatomy and physiology, Mc Graw hill inc, New York, 2<sup>nd</sup> ed.,)

## The Autonomic Nervous System

### Parts of the Autonomic Nervous System

Although the internal organs such as the heart, lungs, and stomach contain nerve endings and nerve fibers for conducting sensory messages to the brain and cord, most of these impulses do not reach consciousness. These *afferent* impulses from the viscera are translated into reflex responses without reaching the higher center of the brain; the sensory neurons from the organs are grouped with those that come from the skin and voluntary muscles. In contrast, the *efferent* neurons, which supply the glands and the involuntary muscles, are arranged very differently from those that supply the voluntary muscles. This variation in the location and arrangement of the visceral efferent neurons has led to their classification as part of a separate division called the ***autonomic nervous system*** (ANS) (Figure 7-13). The ANS itself is comprised of ***sympathetic*** and ***parasympathetic*** divisions.

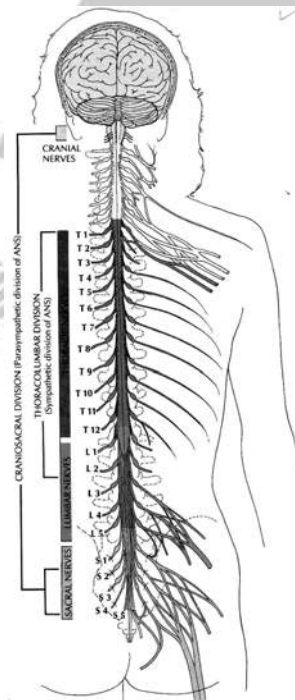
The autonomic nervous system has many ganglia that serve as relay stations. In these g~ each message is transferred at a synapse from the first neuron to a second one and from there to the muscle or gland cell. This differs from the voluntary (somatic nervous system, in which each motor

nerve fiber extends all the way from the spinal cord to the skeletal muscle with no intervening synapse.

Some of the autonomic fibers are within the spinal nerves; some are within the cranial nerves. The distribution of the two divisions of the ANS is as follows:

1. The sympathetic pathways begin in the spinal cord with cell bodies in the thoracic and lumbar regions, the **thoracolumbar area**. The sympathetic fibers arise from the spinal cord at the level of the first thoracic nerve down to the level of the second lumbar spinal nerve. From this part of the cord, nerve fibers extend to ganglia where they synapse with a second set of neurons, the fibers of which extend to the glands and involuntary muscle tissues. Many of the sympathetic ganglia form the **sympathetic chains**, two cord like strands of ganglia that extend along either side of the spinal column from the lower neck to the upper abdominal region. The nerves that supply the organs of the abdominal and pelvic cavities synapse in three single ganglia farther from the spinal cord. The second neurons of the sympathetic nervous system act on the effectors by releasing the neurotransmitter epinephrine (adrenaline). This system is therefore described as **adrenergic**, which means "activated by adrenaline."

- The parasympathetic pathways begin in the **craniosacral** areas, with fibers arising from cell bodies of the midbrain, medulla, and lower (sacral) part of the spinal cord. From these centers the first set of fibers extends to autonomic ganglia that are usually located near or within the walls of the effector organs. The pathways then continue along a second set of neurons that stimulate the involuntary tissues. These neurons release the neuro transmitter acetylcholine, leading to the description of this system as **cholinergic** (activated by acetylcholine).



### **Functions of the Autonomic Nervous System**

The autonomic nervous system regulates the action of the glands, the smooth muscles of the hollow organs and vessels, and the heart muscle. These actions are all carried on automatically; whenever any changes occur that call for a regulatory adjustment, the adjustment is made without conscious awareness. The sympathetic part of the autonomic nervous system tends to act as an accelerator for those organs needed to meet a stressful situation. It promotes what is called the ***fight-or-flight response***. If you think of what happens to a person who is frightened or angry, you can easily remember the effects of impulses from the sympathetic nervous system:

1. Stimulation of the central portion of the adrenal gland. This produces hormones, including epinephrine, that prepare the body to meet emergency situations in many ways. The sympathetic nerves and hormones from the adrenal gland reinforce each other.
2. Dilation of the pupil and decrease in focusing ability (for near objects)
3. Increase in the rate and force of heart contractions
4. Increase in blood pressure due partly to the more effective heartbeat and partly to constriction of small arteries in the skin and the internal organs
5. Dilation of blood vessels to skeletal muscles, bringing more blood to these tissues

6. Dilation of the bronchial tubes to allow more oxygen to enter
7. Increase in metabolism.

The sympathetic system also acts as a brake on those systems not directly involved in the response to stress, such as the urinary and digestive systems. If you try to eat while you are angry, you may note that your saliva is thick and so small in amount that you can swallow only with difficulty. Under these circumstances, when food does reach the stomach, it seems to stay there longer than usual.

The parasympathetic part of the autonomic nervous system normally acts as a balance for the sympathetic system once a crisis has passed. The parasympathetic system brings about constriction of the pupils, slowing of the heart rate, and constriction of the bronchial tubes. It also stimulates the formation and release of urine and activity of the digestive tract. Saliva, for example, flows more easily and profusely and its quantity and fluidity increase.

Most organs of the body receive both sympathetic and parasympathetic stimulation, the effects of the two systems on a given organ generally being opposite. Table 7-2 shows some of the actions of these two systems

**Table 7-2 Effects of the sympathetic and Parasympathetic Systems on Selected Organs**

<b>Effector</b>	<b>Sympathetic system</b>	<b>Parasympathetic System</b>
Pupils of eye	Dilation	Constriction
Sweat glands	Stimulation	None
Digestive glands	Inhibition	Stimulation
Heart	Increased rate and strength of beat	Decreased rate and strength of beat
Bronchi of lungs	Dilation	Constriction
Muscles of digestive system	Decreased contraction (peristalsis)	Increased contraction
Kidneys	Decreased activity	None
Urinary bladder and emptying	Relaxation	Contraction
Liver	Increased release of glucose	None
Penis	Ejaculation	Erection
Adrenal medulla	Stimulation	None
Blood vessels to skeletal muscles	Dilation	Constriction
Skin	Constriction	None
Respiratory system	Dilation	Constriction
Digestive organs	Constriction	Dilation

## **Sense Organs**

### **Classification of sense organs**

The sense organs are often classified as special sense organs and general sense organs. Special sense organs, such as the eye, are characterized by large and complex organs or by localized groupings of specialized receptors in areas such as the nasal mucosa or tongue. The general sense organs for detecting stimuli such as pain and touch are microscopic receptors widely distributed through out the body. Other general sense organs include receptors that indicate the tension on our muscles and tendons so that we can maintain balance and muscle tone and be aware of the positions of our body parts. Table 7-3classifies the special sense organs.

### **Converting stimulus into a sensation**

All sense organs, regardless of size, type, or location, have in common some important functional characteristics. First, they must be able to sense or detect a stimulus in their environment. Of course, different sense organs detect and respond to different types of stimuli in different ways. Whether it is light, sound, temperature change, mechanical presence, or the presence of chemicals identified as taste or smell, the stimulus must be changed into an electrical signal or nerve impulse. This signal is then transmitted over a nervous



system "pathway" to the brain, where the sensation is perceived.

**Table 7-3. Special Sense Organs**

<b>SENSE ORGAN</b>	<b>SPECIFIC RECEPTOR</b>	<b>TYPE OF RECEPTOR</b>	<b>OF SENSE</b>
<i>Eye</i>	Rods and Cons	Photoreceptor	Vision
<i>Ear</i>	Organ of Corti	Mechanoreceptor	Hearing
	Cristae ampularis	Mechanoreceptor	Balance
<i>Nose</i>	Olfactory cells	Chemoreceptor	Smell
<i>Taste buds</i>	Gustatory cells	Chemoreceptor	Taste

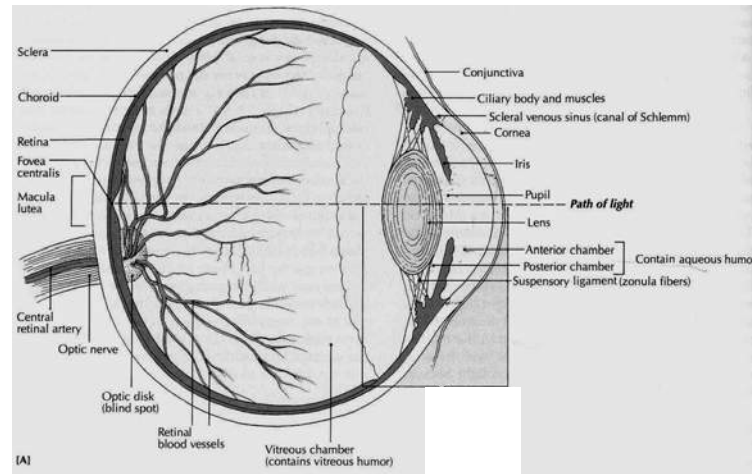
### Special sense organs

#### The Eye

When you look at a person's eye you see only a small part of the whole eye. Three layers of tissue form the eye ball: the sclera, the choroids, and the retina (Figure 7-14). The outer layer of sclera consists of tough fibrous tissue. The white of the eye is part of the front surface of the sclera. The other part of the front surface of the sclera is called the cornea and is sometimes spoken of as the window of the eye because of its transparency. At a casual glance, however, it does not look

transparent but appears blue, brown, gray, or green because it lies over the iris, the colored part of the eye. A mucous membrane known as the conjunctiva lines the eyelids and covers the sclera in front. The conjunctiva is kept moist by tears formed in the lacrimal gland located in the upper lateral portion of the orbit.

The middle layer of the eyeball, the choroid, contains a dark pigment to prevent the scattering of incoming light rays. Two involuntary muscles make up the front part of the choroids. One is the iris, the colored structure seen through the cornea, and the other is the ciliary muscle (Figure 7-14). The black center of the iris is really a hole in this doughnut-shaped muscle; it is pupil of the eye. Some of the fibers of the iris are arranged like spokes in a wheel. When they contract the pupils dilate, letting in more light rays. Other fibers are circular. When they contract, the pupils constrict, letting fewer light rays. Normally, the pupils constrict in bright light and dilate in dim light. When we look at distant objects, the ciliary muscle is relaxed, and the lens has only a slightly curved shape.



**Figure 7-13. Horizontal Section through the Left Eyeball. The eye is viewed from above** (Source: Carola, R., Harley, J.P., Noback R.C., (1992), Human anatomy and physiology, Mc Graw hill inc, New York, 2<sup>nd</sup> ed.)

To focus on near objects, however, the ciliary muscle contract. As it contracts, it pulls the choroids coat forward toward the lens, thus causing the lens to bulge and curve even more. Most of us become more farsighted as we grow older and lose the ability to focus on close objects because our lenses lose their elasticity and can no longer bulge enough to bring near objects into focus. Presbyopia or oldightedness is the name for this condition.

The retina or innermost layer of the eyeball contains microscopic receptor cells, called rods and cones because of their shapes. Dim light can stimulate the rods, but fairly bright

light is necessary to stimulate the cones. In other words, rods are the receptors for night vision and cones for daytime vision. There are three kinds of cones; each is sensitive to a different colour: red, green, or blue. Scattered throughout the central portion of the retina, these three types of cones allow us to distinguish between different colours.

Fluids fill the hollow inside of the eyeball. They maintain the normal shape of the eyeball and help refract light rays; that is, the fluids bend light rays to bring them to focus on the retina. Aqueous humor is the name of the watery fluid in front of the lens (in the anterior cavity of the eye), and vitreous humor is the name of the jellylike fluid behind the lens (in the posterior cavity). Aqueous humor is constantly being formed, drained, and replaced in the anterior cavity. If drainage is blocked for any reason, the internal pressure within the eye will increase, and damage that could lead to blindness will occur. This condition is called glaucoma.

The lens of the eye lies directly behind the pupil. It is held in place by a ligament attached to the ciliary muscle. In most young people, the lens is transparent and somewhat elastic so that it is capable of changing shape. Exposure to ultraviolet (UV) radiation in sunlight may cause cataracts or milky spots on the lens. Large or numerous cataracts may cause

blindness. Cataracts can be removed surgically and replaced with artificial lenses.

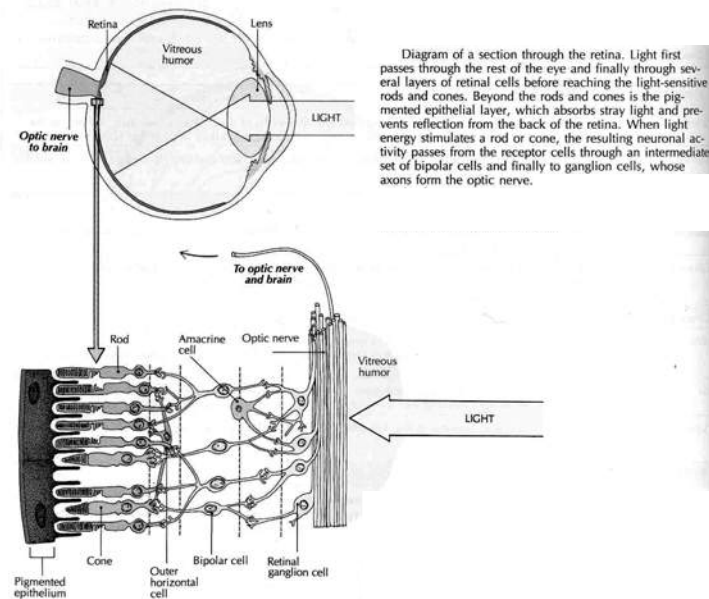
### **Visual Pathway**

Light is the stimulus that results in vision (that is our ability to see objects as they exist in our environment). Light enters the eye through the pupil and is refracted or bent so that it is focused on the retina. Refraction occurs as light passes through the cornea, the aqueous humor, the lens, and the vitreous humor on its way to the retina.

The innermost layer of the retina contains the rods and cones, which are the photoreceptor cells of the eye (Figure 7-15). They respond to a light stimulus by producing a nervous impulse. The rod and cone photoreceptor cells synapse with neurons in the bipolar and ganglionic layers of the retina. Nervous signals eventually leave the retina and exit the eye through the optic nerve on the posterior surface of the eyeball. no rods or cones are present in the area of the retina where the optic nerve fibers exit. The result is a "blind spot" known as the optic disc (Figure 7-13).

After leaving the eye, the optic nerves enter the brain and travel to the visual cortex of the occipital lobe. In this area of the brain, visual interpretation of the nervous impulses that

were generated by light stimuli in the rods and cones of the retina result in "seeing".



**Figure 7-14. Cells of the Retina** (Source: Carola, R., Harley, J.P., Noback R.C., (1992), Human anatomy and physiology, Mc Graw hill inc, New York, 2<sup>nd</sup> ed.)

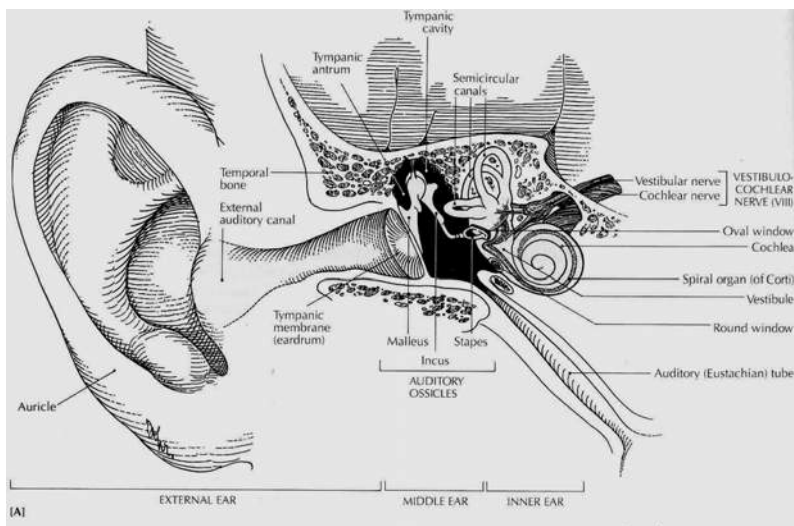
### The Ear

In addition to its role in hearing, the ear also functions as the sense organ of equilibrium and balance. As we shall later see, the stimulation or "trigger" that activates receptors involved with hearing and equilibrium is mechanical, and the receptors themselves are called mechanoreceptors. Physical forces that

involve sound vibrations and fluid movements are responsible for initiating nervous impulses eventually perceived as sound and balance.

The ear is much more than a mere appendage on the side of the head. A large part of the ear, and by far its most important part, lies hidden from view deep inside the temporal bone. It is divided into the following anatomical areas (Figure 7-15).

1. External ear
2. Middle ear
3. Inner (internal) ear



**Figure 7-15. The Ear. External, middle and inner ear** (Source: Carola, R., Harley, J.P., Noback R.C., (1992), Human anatomy and physiology, Mc Graw hill inc, New York, 2<sup>nd</sup> ed,)

### **External ear**

The external ear has two parts: the auricle or pinna and the external auditory canal. The auricle is the appendage on the side of the head surrounding the opening of the external auditory canal. The canal itself is a curve about 2.5 cm (1 inch) in length. It extends into the temporal bone and ends at the tympanic membrane or eardrum, which is a partition between the external and middle ear. The skin of the auditory canal, especially in its outer one third, contains many short hairs and ceruminous glands that produce a waxy substance called cerumen that may collect in the canal and impair hearing by absorbing or blocking the passage of sound waves. Sound waves travelling through the external auditory canal strike the tympanic membrane and cause it to vibrate.

### **Middle Ear**

The middle ear is a tiny and very thin epithelium lined cavity hollowed out of the temporal bone. It houses three very small bones. The names of these ear bones, called ossicles, describe their shapes – malleus (hammer), incus (anvil), and stapes (stirrup). The "handle" of the malleus attaches to the inside of the tympanic membrane, and the "head" attaches to the incus. The incus attaches to the stapes, and the stapes presses against a membrane that covers a small opening, the oval window. The oval window separates the middle ear from the inner ear. When sound waves cause the eardrum to



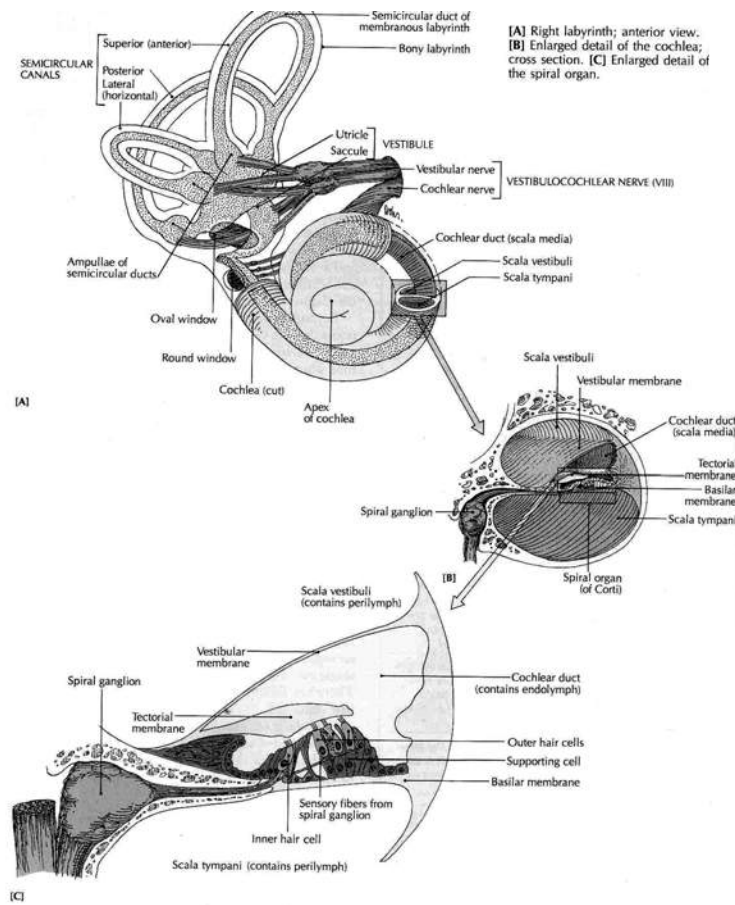
vibrate, that movement is transmitted and amplified by the ear ossicles as it passes through the middle ear.

Movement of the stapes against the oval window causes movement of fluid in the inner ear. A point worth mentioning, because it explains the frequent spread of infection from the throat to the ear, is the fact that a tube— the auditory or eustachian tube— connects the throat with the middle ear. The epithelial lining of the middle ears, auditory tubes, and throat are extensions of one continuous membrane. Consequently a sore throat may spread to produce a middle ear infection called otitis media.

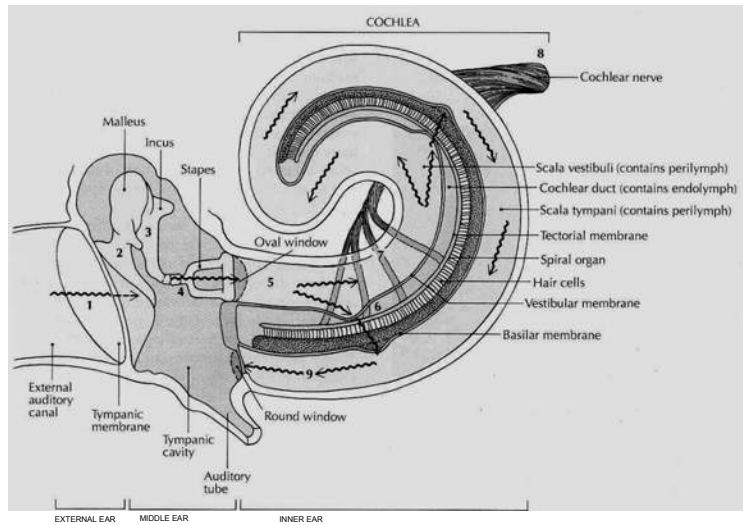
### **Inner Ear**

The activation of specialized mechanoreceptors in the inner ear generates nervous impulses that result in hearing and equilibrium. Anatomically, the inner ear consists of three spaces in the temporal bone, assembled in a complex maze called the bony labyrinth. This odd shaped bony space is filled with a watery fluid called perilymph and is divided into the following parts: vestibule, semicircular canals, and cochlea. The vestibule is adjacent to the oval window between the semicircular canals and the cochlea (Figure 7-16). Note in Figure 7-16 that a ballonlike membranous sac is suspended in the perilymph and follows the shape of the bony labyrinth

much like a "tube within a tube." This is a membranous labyrinth, and it is filled with a thicker fluid called endolymph.



**Figure 7-16 The Inner ear** (Source: Carola, R., Harley, J.P., Noback R.C., (1992), Human anatomy and physiology, Mc Graw hill inc, New York, 2<sup>nd</sup> ed.)



**Figure 7-17 Effect of Sound Wave on Cochlear Structure** (Source: Carola, R., Harley, J.P., Noback R.C., (1992), Human anatomy and physiology, Mc Graw hill inc, New York, 2<sup>nd</sup> ed.)

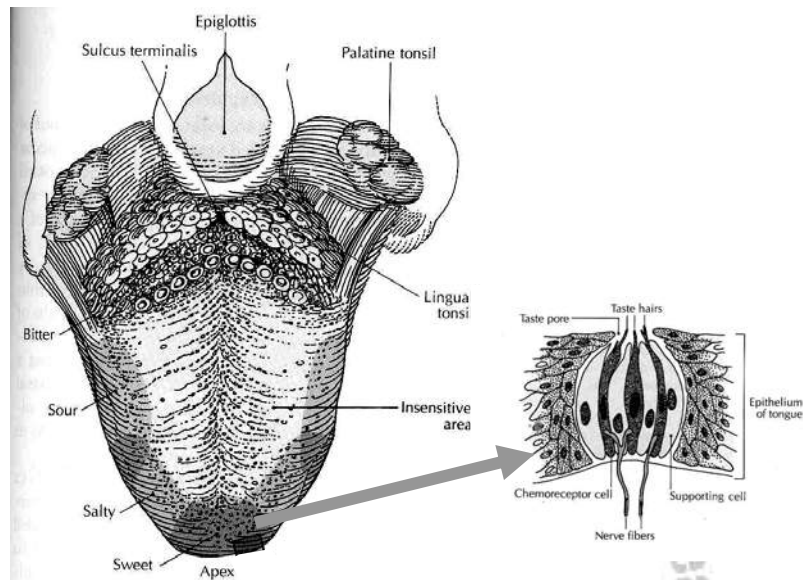
The specialized membranoreceptors for balance and equilibrium are located in the three semicircular canals and the vestibule. The three half-circle semicircular canals are oriented at right angles to one another (Figure 7-16). Within each canal is a specialized receptor called a crista ampullaris, which generates a nerve impulse when you move your head. The sensory cells in the cristae ampullares have hair like extensions that are suspended in the endolymph. The sensory cells are stimulated when movement of the head causes the endolymph to move, thus causing the hairs to bend. Nerves from other receptors in the vestibule join those from the

semicircular canals to form the vestibular nerve, a division of the acoustic nerve or cranial nerve VIII (Figure 7-16). Eventually, nervous impulses passing through this nerve reach the cerebellum and medulla. Other connections from these areas result in impulses reaching the cerebral cortex.

The organ of hearing, which lies in the snail shaped cochlea, is the organ of Corti. It is surrounded by endolymph filling the membranous cochlea or cochlear duct, which is the membranous tube within the bony cochlea. Specialized hair cells on the organ of Corti generate nerve impulses when they are bent by the movement of endolymph set in motion by sound waves (Figures 7-16 and 7-17).

### **The Taste Receptors**

The chemical receptors that generate nervous impulses resulting in the sense of taste are called taste buds. About 10,000 of these microscopic receptors are found on the sides of much larger structure on the tongue called papillae and also as portions of other tissues in the mouth and throat. Nervous impulses are generated by specialized cells in taste buds, called gustatory cells. They respond to dissolved chemicals in the saliva that bathe the tongue and mouth tissues (Figure 7- 18).



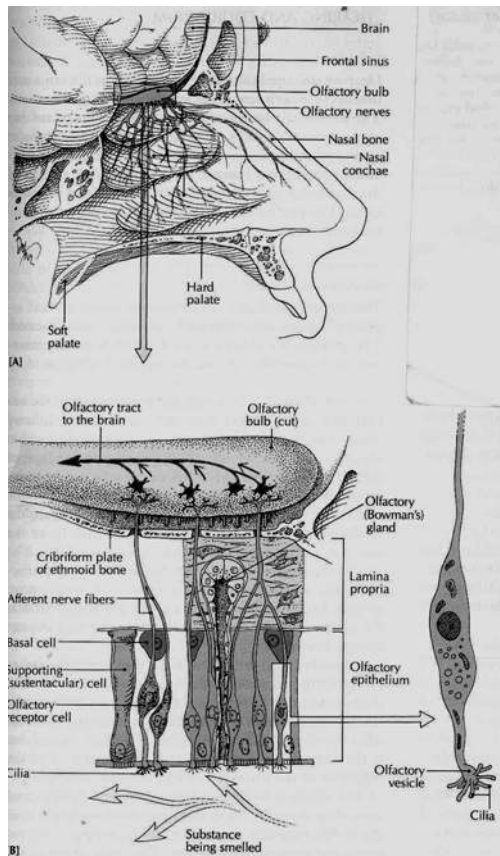
**Figure 7-18. The Tongue. A, Dorsal surface and regions sensitive to various tastes. B, Enlarged view of a section through a taste bud.** (Source: Carola, R., Harley, J.P., Noback R.C., (1992), Human anatomy and physiology, Mc Graw hill inc, New York, 2<sup>nd</sup> ed.)

Only four kinds of taste sensations—sweet, sour, bitter, and salty—result from stimulation of taste buds. All other flavors result from a combination of taste bud and olfactory receptor stimulation. In other words, the myriads of tastes recognized are not tastes alone but tastes plus odors. For this reason a cold that interferes with the stimulation of the olfactory receptors by odors from foods in the mouth markedly dulls taste sensations. Nervous impulses generated by stimulation

of taste buds travel primarily through two cranial nerves (VII and IX) to end specialized taste area of the cerebral cortex.

### **The Smell Receptors**

The chemical receptors responsible for the sense of smell are located in a small area of epithelial tissue in the upper part of the nasal cavity (Figure 7-19). The location of the olfactory receptors is somewhat hidden, and we are often forced to forcefully sniff air to smell delicate odors. Each olfactory cell has a number of specialized cilia that sense different chemicals and cause the cell to respond by generating a nervous impulse. To be detected by olfactory receptors, chemicals must be dissolved in the watery mucus that lines the nasal cavity.



**Figure 7-19. Olfactory structures** (Source: Carola, R., Harley, J.P., Noback R.C., (1992), Human anatomy and physiology, Mc Graw hill inc, New York, 2<sup>nd</sup> ed.)

Although the olfactory receptors are extremely sensitive (that is, stimulated by even very slight odors), they are also easily fatigued—a fact that explains why odors that are at first very noticeable are not sensed at all after a short time. After the olfactory cells are stimulated by odor-causing chemicals, the resulting nerve impulse travels through the olfactory nerves in the olfactory bulb and tract and then enters the thalamic and olfactory centers of the brain, where the nervous impulses are

interpreted as specific odors. The pathways taken by olfactory nerve impulses and the area where these impulses are interpreted are closely associated with areas of the brain important in memory and emotion. For this reason, we may retain vivid and long-lasting memories of particular smells and odors.

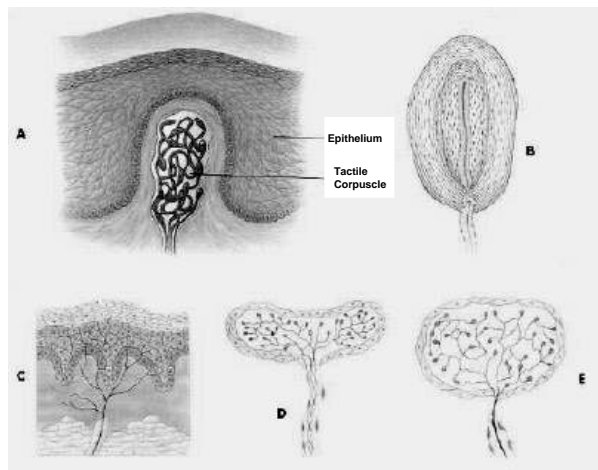
Temporary reduction of sensitivity to smells often results from colds and other nasal infections. Progressive reduction of the sense of smells often seen in smokers because of the damaging effects the pollutants in tobacco smoke. In olfaction, as with all the special senses, advancing age often brings a structural degeneration that result in reduced function. It is no wonder that many older adults become isolated and depressed when their contact with the outside world, the special senses, is gradually lost. Caring health professionals recognize these signs of aging and provide assistance needed by their aged patients to enjoy life.

### **General Sense Organs**

Groups of highly specialized and localized receptors are typically associated with the special senses. In the sense organs, however, receptors are found in almost every part of the body. To demonstrate this fact, try touching any point of your skin with the tip of a toothpick. You can hardly miss stimulating at least one receptor and almost instantaneously

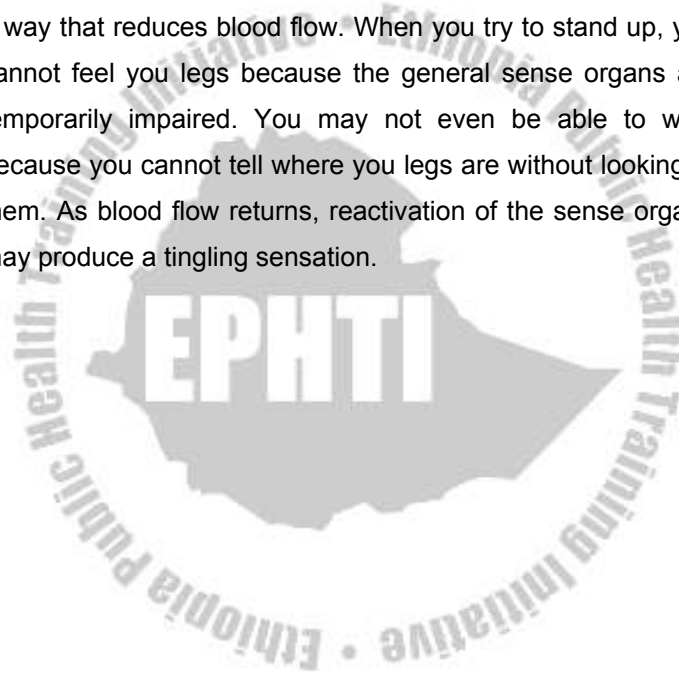


experiencing a sensation of touch. Stimulation of some receptors leads to the sensation of heat; Stimulation of others gives the sensation of cold, and stimulation of still others gives the sensation of pain or pressure. General sense receptors are illustrated in Figure 7-20. When special receptors in the muscles and joints are stimulated, you sense the position of the different parts of the body and know whether they are moving and in which direction they are moving without even looking at them. Perhaps you have never realized that you have this sense of position and movement a sense called proprioception or kinaesthesia.



**Figure 7-20. General Sense Receptors. A, Meissner's corpuscle. B, Pacinian corpuscle. C, Free nerve ending. D, Ruffini's corpuscle. E, Krause's end-bulb.** (From Thibodeau, Gary A. and Kevin T. The Human Body in Health and Disease, ed. 6, Philadelphia, 1987, J.B.Lippincot Company)

Disruption of general sense organs can occur by a variety of mechanisms. For example, third degree burns can completely destroy general sense receptors throughout the affected area. Temporary impairment of general sense receptors occurs when the blood flow to them is slowed. This commonly occurs when you put your legs in a position that presses your legs in a way that reduces blood flow. When you try to stand up, you cannot feel your legs because the general sense organs are temporarily impaired. You may not even be able to walk because you cannot tell where your legs are without looking at them. As blood flow returns, reactivation of the sense organs may produce a tingling sensation.



## Review Questions

1. What general function does the nervous system perform?
2. What other system performs the same general function as the nervous system?
3. Describe a nerve impulse. How does conduction along a myelinated fiber differ from conduction along an unmyelinated fiber?
4. What are neurotransmitters? Give several examples of neurotransmitters.
5. Differentiate between the terms in each of the following pairs:
  - a. axon and dendrite
  - b. gray matter and white matter
  - c. receptor and effector
  - d. afferent and efferent
  - e. sensory and motor
  - f. nerve and tract
6. What is a mixed nerve? Give several examples.
7. Name the components of a reflex arc.
8. Name and locate the main parts of the brain, and briefly describe the main functions of each.
9. Name the four surface lobes of the cerebral hemispheres and describe functions of the cortex in each.
10. Describe the thalamus; where is it located? What are its functions?

11. What activities does the hypothalamus regulate?
12. Name and locate three divisions of the brain stem.
13. Locate and describe the spinal cord. Name three of its functions.
14. Differentiate between the dorsal and ventral roots of a spinal nerve.
15. Define a plexus. Name the three main plexuses of the spinal nerves.
16. Name four general functions of the cranial nerves.
17. Name and describe the functions of the 12 cranial nerves.
18. Name the covering of the brain and the spinal cord. Name and describe its three layers.
19. What is the purpose of the cerebrospinal fluid? Where and how is the cerebrospinal fluid formed?
20. What are the functions of the sympathetic part of the autonomic nervous system, and how do these compare with those of the parasympathetic nervous system? '

# CHAPTER EIGHT

## THE ENDOCRINE SYSTEM

### Chapter Objectives

At the end of the chapter the student should be able to:

- Compare the effects of the nervous system and the endocrine system in controlling the body
- Compare protein and steroid hormones with respect to position and method of action and give examples of each type
- Describe three methods for regulating the release of hormone
- Identify the glands of the endocrine system on a diagram
- List the hormones produced by each endocrine gland and describe the effects of each on the body
- Describe how the hypothalamus controls the anterior and posterior pituitary
- Explain why the anterior pituitary is called the master gland
- Explain how the endocrine system responds to stress

### **Selected key terms**

The following terms are defined in the glossary:

Endocrine

Hormone

Hypothalamus

Pituitary (hypophysis)

Prostaglandin

Receptor

Steroid

Target tissue

### **General Function**

The nervous system and the endocrine system are the two main coordinating and controlling systems of the body. There are several differences between these two systems. For example, the nervous system acts by means of electric impulses and chemical stimuli; where as the endocrine system has more widespread, slower, and longer lasting effects. The endocrine system also has more generalized effects on such activities as growth, metabolism, and reproduction. Despite this difference, however, the two systems are closely interrelated.

## **Hormones**

The chemical messengers released by the glands of the endocrine system are called hormones. Hormones are released directly into the bloodstream and carried to the tissues they affect. These tissues may be far from where the hormone is produced.

The blood reaches all cells of the body, but only certain cells respond to specific hormones; these responding cells are unique in that they have receptors to which the hormones attach. Only cells that have receptors for a given hormone will respond to that hormone; these cells make up what is called the target tissue.

## **Chemistry**

Hormones fall chemically in two categories:

1. Proteins. Most hormones are proteins or related compounds composed of aminoacids. All hormones except those of the adrenal cortex and the sex glands are proteins.
2. Steroids are hormones derived from lipids and produced by the adrenal cortex and the sex glands.

All hormones are extremely potent, that is, they are effective in very small amounts.

### **The Endocrine Glands and Their Hormones**

The endocrine system consists of the glands that secrete hormones. These glands are also called the ductless glands because they secrete directly into the blood stream, in contrast to the endocrine glands, which secrete into body cavities.

Most endocrine glands, like exocrine glands, are made of epithelial tissue. Although they have no ducts, they have an extensive blood vessel network. Operations on endocrine glands, for example on the thyroid, require care in the control of bleeding. The organs believed to have the very richest blood supply of any in the body are the tiny adrenal, or suprarenal, glands, which are located near the upper part of the kidneys.

Some of the glands included in this system, such as the pancreas and the sex glands, have other nonendocrine functions as well, but hormone secretion is one of their main functions. In addition, some body organs, such as the stomach, small intestine, and kidney, produce hormones, but since their main function is not hormone production, they are not discussed in this unit. This unit deals with the endocrine gland. Refer to Figure 8-1 to locate each of the glands as you study it.



## **The Pituitary Gland**

The pituitary gland or hypophysis, formerly called the "Master gland", secretes several polypeptide hormones that directly or indirectly regulate a wide variety of metabolic and physiologic processes essential to normal growth and development as well as to the maintenance of homeostasis. Many of the hormones secreted by the pituitary gland are critical to the activity of target glands, including the thyroid, adrenal and gonads.

### **Anatomy**

The pituitary gland (hypophysis cerebri) is located at the base of the brain, resting within the sella turcica of the sphenoid bone. The pituitary gland maintains elaborate neural and vascular connections with the hypothalamus of the brain, which plays a central role in the integration of neuroendocrine activity (Figure 8-1).

The pituitary gland has two major divisions: The anterior lobe (**adenohypophysis**) and the posterior lobe (**neurohypophysis**). The hormones released from each lobe are shown in Figure 8-2.

### **Adenohypophysis**

The adenohypophysis is served by an elaborate vascular system, including the hypothalamohypophyseal portal system,

which transports hypothalamic regulating hormones (hypophyseotropic hormones) to the glandular cells of the adenohypophysis. The classification of cells in the adenohypophysis is based on specific immunohistochemical techniques. Accordingly, there are at least five recognized cell types.

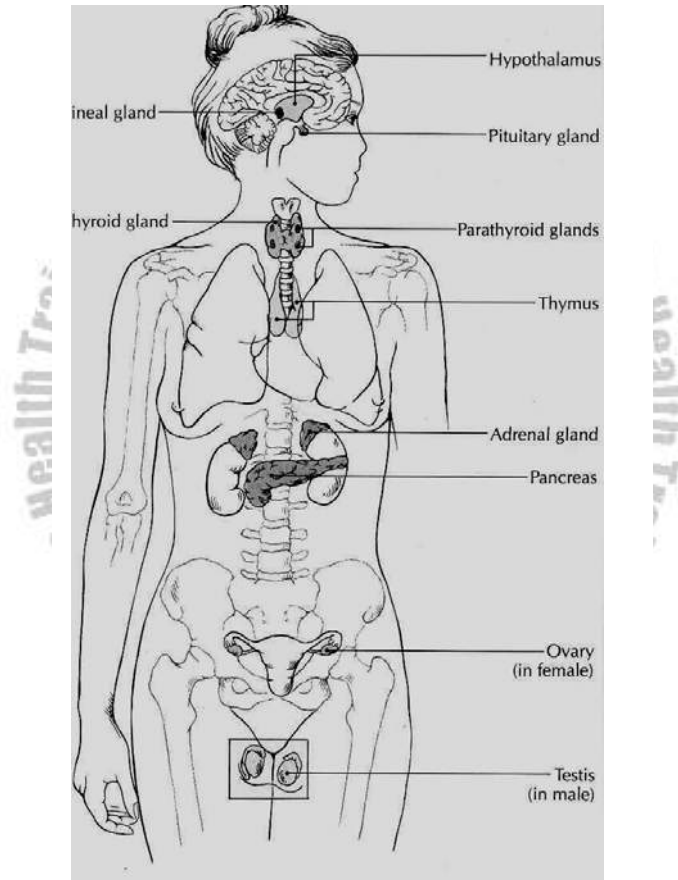
1. **Somatotrophs**, which secrete growth hormone (hGH) or somatotropin.
2. **Lactotrophs**, which secrete prolactin (PRL).
3. **Corticotrophs**, which produce corticotropin (ACTH) and beta-lipotropin (beta-LPH)
4. By splitting a large peptide pro-hormone, pro-opiomelanocortin (POMC).
5. **Thyrotrophs**, which secrete thyrotropin (TSH).
6. **Gonadotrophs**, which produce follicle stimulating hormone (FSH) and luteinizing hormone (LH)

### **Neurohypophysis**

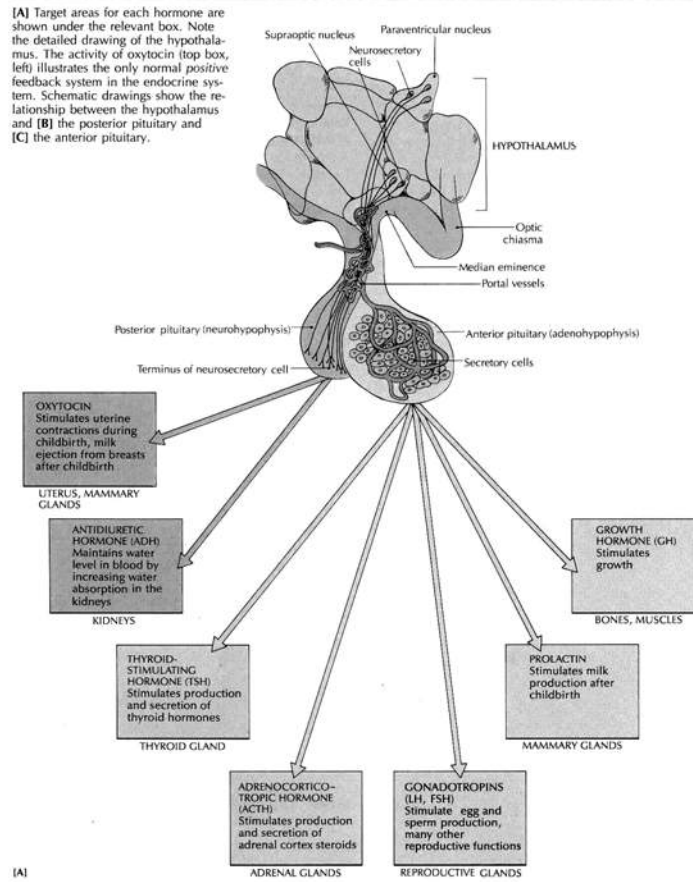
The neurohypophysis, which is connected directly to the hypothalamus by the infundibular (Pituitary) stalk, is rich in nerve fibers of hypothalamic origin (the hypothalamohypophyseal tract).

Neurosecretory cells in the supraoptic and paraventricular nuclei of the hypothalamus produce two hormones: **antidiuretic hormone** (ADH or Vasopressin) and **oxytocin**.

These hormones are then transported along the axons of the hypothalamo hypophyseal tract to the posterior lobe of the pituitary gland for storage and ultimate release under hypothalamic control.



**Figure 8-1. Glands of the endocrine system** (Source: Carola, R., Harley, J.P., Noback R.C., (1992), Human anatomy and physiology, Mc Graw hill inc, New York, 2<sup>nd</sup> ed.)



**Figure 8-2. The pituitary gland and its relationship with the brain and target tissues.** (Source: Carola, R., Harley, J.P., Noback R.C., (1992), Human anatomy and physiology, Mc Graw hill inc, New York, 2<sup>nd</sup> ed.)

### **Hormones of the Adenohypophysis**

The secretion of hormones by the adenohypophysis is controlled by hypothalamic regulatory (hypophyseotropic) hormones that are transported to the pituitary gland by the hypothalamohypophyseal portal system illustrated in Figure 8`-2. There are six recognized hypophyseotropic hormones secreted from the median eminence of the hypothalamus:

- Growth hormone-releasing hormone (GHRH; somatocrinin)
- Growth hormone-inhibiting hormone (GHIH; somatostatin)
- Corticotropin-releasing hormone (CRH)
- Thyrotropin-releasing hormone (TRH)
- Gonadotropin-releasing hormone (GnRH)
- Prolactin-inhibiting hormone (PIH)

It is probable that a prolactin-releasing hormone (PRH) also exists; however, the exact substance has yet to be clearly identified. Some hypophyseotropic hormones influence the secretion of more than one adenohypophyseal hormone. GnRH stimulates secretion of FSH and LH. TRH stimulates the secretion of TSH and prolactin. Somatostatin inhibits the secretion of growth hormone and TSH.

#### **1. Growth Hormone (GH); Somatotropin (STH)**

Human growth hormone (hGH) is a peptide hormone composed of 191 aminoacids, and is secreted by the

somatotrophs of the adenohypophysis primarily under hypothalamic control. The wide variety of factors that may affect GH secretion is summarized below.

### **Control of Secretion**

#### **Factors Promoting GH Secretion**

- GHRH (Somatotropin)
- Hypoglycemia and fasting
- Elevated plasma levels of amino acids (e.g., arginine)
- Stress (physical or psychological)
- Exercise
- Deep sleep
- Levodopa
- Glucagon

#### **Factors Inhibiting GH Secretion**

- GHIH (Somatostatin)
- Hyperglycemia
- Elevated plasma levels of free fatty acids
- REM sleep
- Cortisol
- Alpha-adrenergic blocking agents
- GH (negative feedback mechanism): GH secretion in response to hypoglycemia, fasting, and exercise appears to be reduced by obesity.

### **Actions**

**Effects on Growth:** Growth is a complex phenomenon influenced by genetic, nutritional, and hormonal factors. In addition to growth hormone, the thyroid hormones, insulin, androgens, and estrogens play important roles in normal human growth and development at various times of the life cycle. GH accelerates overall body growth by increasing the mass of both skeletal and soft body tissues through hyperplasia (increased cell number) and hypertrophy (increased cell size).

The effects of GH are particularly evident in skeletal tissues where chondrogenesis (cartilage formation) and osteogenesis (bone formation) are enhanced, leading to an increase in linear growth and stature before epiphyseal closure and increased bone thickness following closure of the epiphyses.

Growth hormone stimulates certain tissues, notably the liver, to produce somatomedins or insulinlike growth factors (IGF-I and IGF-II). These low-molecular-weight peptides mediate the growth-promoting effects of GH, including the stimulation of collagen synthesis and chondrogenesis.

### **Metabolic Effects**

**Protein metabolism:** GH increases protein synthesis and nitrogen retention by enhancing the incorporation of amino acids into protein. The protein anabolic action results from 1) accelerated entry of amino acids into cells and 2) increased ribonucleic acid (RNA) synthesis. In muscle and liver, the protein anabolic effects are attributed directly to GH. However, in cartilage, bone, and other body tissues, the protein anabolic and growth-promoting actions are mediated by insulinlike growth factors (somatomedins).

**Lipid metabolism:** GH stimulates the mobilization and utilization of fats by promoting lipolysis in adipose tissue, thus enabling the body to use stored fats as an energy source. The elevation of plasma levels of free fatty acids resulting from the hydrolysis of triglycerides (stored neutral fats) is potentially ketogenic.

**Carbohydrate metabolism:** GH elevates blood glucose levels by increasing the hepatic output of glucose (gluconeogenesis) and impairing glucose transport into muscle and adipose tissue ("anti-insulin" action). Excessive secretion of GH may precipitate or increase the severity of clinical diabetes mellitus ("diabetogenic" effect).



## 2. Prolactin (PRL)

### Control of Secretion

Prolactin (PRL) is a peptide hormone composed of 199 amino acids. Its secretion by the lactotrophs of the adenohypophysis is tonically suppressed by dopamine (also known as PIH) of hypothalamic origin. Dopamine antagonists (eg, antipsychotic drugs) promote PRL secretion by blocking dopamine receptors, whereas dopamine agonists (eg, bromocriptine) inhibit PRL secretion by activating dopamine receptors.

Secretion of PRL increases during pregnancy, peaking near the time of parturition. Sucking and tactile stimulation of the nipple increase PRL secretion.

Prolactin facilitates the secretion of dopamine in the hypothalamus, thereby regulating its own secretion by a negative feedback mechanism.

### Actions

Prolactin initiates and maintains milk secretion from breasts primed for lactation by other hormones such as estrogens, progesterone, and insulin. It also appears to inhibit the effects of the gonadotropins and may prevent ovulation in lactating women. Excessive production of PRL (hyperprolactinemia), which may accompany some pituitary tumors, may cause an

ovulation and amenorrhea in women, and may lead to impotence and infertility in men.

### **3. Follicle-Stimulating Hormone (FSH)**

#### **Control of Secretion**

Follicle-stimulating hormone (FSH) is a glycoprotein gonadotropic hormone whose secretion is stimulated by hypothalamic GnRH. Inhibit, a polypeptide produced by testicular sertoli cells in the male and follicular granulosa cells in the female, acts directly on the adenohypophysis to inhibit FSH secretion.

#### **Actions**

Follicle-stimulating hormone directly stimulates the sertoli cells in testicular seminiferous tubes, there by promoting spermatogenesis in the male. In the female, FSH stimulates follicular growth and development within the ovaries. The actions of FSH are mediated by cyclic AMP.

### **4. Luteinizing Hormone (LH; Interstitial Cell Stimulating Hormone; ICSH)**

#### **Control of Secretion**

Like FSH, LH is a glycoprotein hormone whose secretion is stimulated by GnRH. Testosterone inhibits LH secretion

through a direct action on the adenohypophysis, as well as indirectly by inhibiting hypothalamic GnRH production.

The effects of female hormones on LH secretion are more complex. Constant, moderate levels of estrogen (without progesterone) have a negative feedback effect on LH, whereas high estrogen levels exert a positive feedback that leads to a surge in LH production. High levels of progesterone and estrogen (luteal phase of the ovulatory cycle) inhibit LH secretion.

### **Actions**

In the male, this hormone stimulates testosterone production by testicular interstitial cells (of Leydig); hence the alternate name, interstitial cell stimulating hormone (ICSH).

In the female, LH promotes maturation of ovarian follicles and sustains their secretion of estrogens. LH is also responsible for ovulation and the formation of the corpus luteum. The actions of LH are mediated by cyclic AMP.

## **5. Thyroid-Stimulating Hormone (Thyrotropin; TSH)**

### **Control of Secretion**

Thyrotropin-releasing hormone (TRH) and cold (especially in infants) promote secretion of TSH by the thyrotrophs of the

adenohypophysis. Elevated plasma levels of free thyroid hormones (T3 and T4) inhibit thyrotropin secretion. Stress also inhibits TSH secretion.

### **Actions**

Thyroid-stimulating hormone maintains the structural integrity of the thyroid gland and promotes the synthesis and release of thyroid hormones thyroxine (T4) and triiodothyronine (T3). The actions of TSH on the thyroid gland are mediated by cyclic AMP, and they are detailed in the section on the thyroid gland.

## **6. Adrenocorticotrophic Hormone (Corticotropin; ACTH)**

### **Control of Secretion**

Adrenocorticotrophic hormone (ACTH) is secreted in irregular bursts that follow a diurnal circadian rhythm, with peak production in the early morning. ACTH secretion is regulated by the hypophyseotropic hormone corticotropin-releasing hormone (CRH) the increased production of ACTH in response to many stressors appears to be mediated through the hypothalamus and CRH.

Elevated plasma free glucocorticoid (cortisol) levels inhibit both CRH and ACTH secretion.

### **Action**

Adrenocorticotrophic hormone exerts its tropic effects on the adrenal glands, promoting structural integrity and steroidogenesis in the adrenal cortex. The stimulation of corticosteroid production (Steroidogenesis) in response to ACTH is mediated by the second messenger, cyclic AMP.

### **Hormones of the Neurohypophysis**

#### **1. Antidiuretic Hormone (ADH; Vasopressin)**

##### **Control of Secretion**

Antidiuretic hormone (ADH) is a polypeptide hormone of hypothalamic origin that is stored in and released from the neurohypophysis in response to a variety of stimuli. Included among these are increased plasma osmolality, reduced extracellular fluid (ECF) volume, pain, emotional stress, and such pharmacologic agents as morphine, nicotine, barbiturates, and certain general anesthetics.

Decreased plasma osmolality, increased ECF volume, and alcohol inhibit ADH secretion. Osmoreceptors found in the anterior hypothalamus monitor changes in plasma osmolality, whereas ECF volume changes are detected by volume ("Stretch") receptors located in the wall the left atrium. The osmoreceptors and volume receptors work in concert to exert

precise control over ADH secretion, thus forming a delicate homeostatic feedback mechanism for the regulation of ECF volume and concentration.

### **Actions**

The principal physiologic role of ADH is to regulate extracellular fluid volume and osmolality by controlling the final volume and concentration of urine. ADH increases the permeability of the distal nephron (late distal convoluted tubules and collecting ducts) to water. The enhanced reabsorption of water from the renal tubules results in the production a concentrated urine that is reduced in volume. Pharmacologic amounts of ADH produce a pressor (hypertensive) effect that results from a direct constrictor action of the hormone on vascular smooth muscle. The early observations that posterior pituitary extracts produce a marked elevation of arterial blood pressure led to the initial naming of this hormone as vasopressin.

## **2. Oxytocin**

### **Control of Secretion and Actions**

The two major physiologic actions of oxytocin are exerted on the female breast and uterus. Oxytocin binds to a G-protein coupled receptor that ultimately brings about elevated intracellular calcium levels.

**Galactokinetic Action (Milk Ejection Reflex).** The ejection of milk from a primed, lactating mammary gland follows a neuroendocrine reflex in which oxytocin serves as the efferent limb. The reflex is normally initiated by sucking, which stimulates cutaneous receptors in the areola of the breast. Afferent nerve impulses travel to the supraoptic and paraventricular nuclei of the hypothalamus to effect the release of oxytocin from the neurohypophysis. Oxytocin is carried by the blood to the mammary gland, where it causes contraction of myoepithelial cells surrounding the alveoli and lactiferous ducts to bring about the ejection of milk (milk letdown). In lactating women, tactile stimulation of the breast areola, emotional stimuli, and genital stimulation may also lead to oxytocin release and activate the ejection of milk.

**Oxytocic Action.** Oxytocin acts directly on uterine smooth muscle to elicit strong, rhythmic contractions of the myometrium. Uterine sensitivity to oxytocin varies with its physiologic state and with hormonal balance. The gravid (Pregnant) uterus is highly sensitive to oxytocin, particularly in the late stages of gestation. Uterine sensitivity to oxytocin is greatly enhanced by estrogen and inhibited by progesterone.

Oxytocin release appears to follow a neuroendocrine reflex initiated by genital stimulation. It has been suggested that

oxytocin may facilitate sperm transport through the female genital tract.

### **The Thyroid Gland**

The hormones of the thyroid gland exert a wide spectrum of metabolic and physiologic actions that affect virtually every tissue in the body.

#### **Anatomy**

The thyroid gland is a bilobed organ overlying the trachea anteriorly. The thyroid gland is composed of numerous closely packed spheres or follicles. Each follicle consists of a simple cuboidal epithelium (follicular cells) enclosing a lumen or cavity containing a viscous hyaline substance termed colloid. The chief constituent of the colloid is the iodinated glycoprotein thyroglobulin. Interspersed among the follicles are small clusters of parafollicular (C) cells, which secrete calcitonin, a hormone affecting calcium metabolism.

#### **Thyroid Hormones**

The follicular cells of the thyroid gland secrete two hormones, thyroxine (3, 3', 5, 5'-tetraiodothyronine or T<sub>4</sub>) and 3, 3', 5-triiodothyronine (T<sub>3</sub>). The plasma levels of these hormones are regulated by the hypothalamopituitary axis as outlined in Figure 8-2. Intrinsic (intrathyroidal) mechanisms, as well as bioavailability of iodine, influence thyroid hormone production.



### **Biosynthesis of Thyroid Hormones**

1. Iodide uptake: Ingested iodine is readily absorbed from the GI tract in the reduced iodide state. Iodide ions are actively transported from the blood into the thyroid follicles by an energy-requiring "trapping" mechanism often called the iodide pump. The normal thyroid: serum ratio of iodide is 25:1. The uptake of iodide is enhanced by TSH and may be blocked by anions such as perchlorate and thiocyanate.
2. Oxidation to iodine: On entering the colloid, iodide is rapidly oxidized to iodine in the presence of peroxidase enzymes. Thiouracil appears to inhibit peroxidase activity.
3. Iodination of tyrosine: Free molecular iodine spontaneously combines with tyrosine residues on the thyroglobulin (TGB) to form 3-monoiodotyrosine (MIT) and 3, 5-diiiodotyrosine (DIT). This organic iodination is enhanced by TSH and blocked by agents such as propylthiouracil and methimazole. Goitrogens found in cabbage, kale, and turnips, as well as cobalt and phenylbutazone, also block organification of iodine.
4. Coupling reaction: Two iodinated tyrosines combine to form either T3 or T4. The coupling occurs within the thyroglobulin molecule, and the reaction appears to be promoted by TSH.
5. Storage and release of thyroid hormones: T3 and T4 remain stored within the colloid bound to thyroglobulin

until a stimulus for secretion arrives. On stimulation by TSH, portions of the TGB (colloid) are engulfed by microvilli that extend from the apical surface of the follicular cells. Droplets of the engulfed colloid fuse with lysosomes, and proteolytic enzymes release T<sub>3</sub> and T<sub>4</sub> from the TGB. The lipophilic hormones (T<sub>3</sub> and T<sub>4</sub>) readily diffuse to nearby capillaries and enter the bloodstream.

Thyroid-stimulating hormone, acting through cyclic AMP, increases the production of thyroid hormones by promoting virtually every step in the biosynthetic process, including the synthesis of TGB and the eventual release of T<sub>3</sub> and T<sub>4</sub> from storage.

### **Transport**

Circulating thyroid hormones bind specifically with thyroxine-binding globulin and thyroxine-binding prealbumin, and non-specifically with serum albumin. The extent of plasma protein binding can be measured as protein-bound iodine (PBI).

Only the small fraction of circulating thyroid hormones that is in the free (unbound) form is physiologically active and inhibitory to TSH secretion.

Several drugs, including phenytoin and the salicylates, compete for plasma protein-binding sites, thus lowering the

PBI and increasing the percentage of free, active hormones. High levels of estrogen, such as those occurring in pregnancy or during oral contraceptive therapy, elevate plasma protein levels, thereby increasing PBI levels.

### **Fate**

Thyroid hormones are inactivated by deiodination, deamination, decarboxylation, or conjugation with glucuronic acid or sulfate. Much of the iodine released during biodegradation is recycled and reused for synthesis of new hormones. The remainder is excreted in the urine. Metabolism occurs chiefly in the liver, and excretion is mainly through the kidneys. The conjugated hormones are excreted through the bile and eliminated in the stool.

### **Actions**

The thyroid hormones increase the rate of metabolism, total heat production, and oxygen consumption in most body tissues. Exceptions include the adult brain, spleen, lymph nodes, uterus, and testes. The thyroid hormones promote normal physical growth and development, and they are essential for normal myelination and development of the nervous system in early life. Hypothyroid infants exhibit severe mental retardation and defective myelination of nerve fibers.

The thyroid hormones increase the number and affinity of beta-adrenergic cardiac receptors for catecholamines, thereby increasing heart rate, myocardial contractile force, and cardiac output.

The metabolic actions of the thyroid hormones are somewhat complex, being dependent on the level of the thyroid hormones, as well as on the presence of other hormones, for example, catecholamines and insulin. In normal physiologic amounts, the thyroid hormones stimulate protein synthesis, increase lipid turnover, lower plasma cholesterol, and promote GI absorption of glucose. T<sub>3</sub> is more potent and more rapidly active than T<sub>4</sub>; in fact, the latter may be considered a prohormone, since most target cells convert T<sub>4</sub> into T<sub>3</sub>.

### **The Parathyroid Glands**

The parathyroid glands, usually four in number, are embedded in the dorsal surface of the thyroid gland. In response to hypocalcemia (low plasma calcium), the chief cells of the parathyroid glands secrete a single 84- amino-acid polypeptide hormone known as parathyroid hormone (PTH).

Parathyroid hormone regulates serum calcium levels by exerting its effects on the following target tissues:

- Bone: PTH stimulates bone resorption by activating the bone-destroying osteoclasts. The demineralization of bone elevates plasma calcium and phosphate levels;

however, the renal actions of PTH lead to a net decrease in plasma phosphate levels.

- Kidneys: PTH promotes renal tubular reabsorption of calcium and increases urinary excretion of phosphate by blocking its reabsorption. PTH also stimulates the activity of a renal enzyme that catalyzes the formation of calcitriol, an active metabolite of vitamin D (see chapter 75). Calcitriol elevates plasma calcium and phosphate levels primarily by promoting the intestinal absorption of both ions, but also by increasing renal tubular reabsorption of calcium and phosphate.

The major actions of PTH are mediated by cyclic AMP.

### **The Pancreas**

The endocrine functions of the pancreas are performed by the islets of Langerhans (also called pancreatic islets) –small, highly vascularized masses of cells scattered throughout the pancreas and representing only 1% to 3% of the entire organ.

The Islets of Langerhans contain four types of secretory cells, as follows:

- Alpha (A) cells, which secrete glucagons
- Beta (B) cells, which secrete insulin
- Delta (D) cells, which secrete somatostatin
- PP (F) cells, which secrete pancreatic polypeptide

Insulin-secreting beta cells are the most numerous, making up to 75% of the islet cell population. The A cells containing glucagons comprise approximately 20% of islet cell mass, whereas the somatostatin-containing D cells account for 3% to 5% of pancreatic islet cells. The F cells make up less than 2% of islet cells and secrete a polypeptide that slows food absorption in humans, but whose exact physiologic significance is unclear.

The paracrine relationship exists within the pancreatic islets, with one hormone affecting the secretion of other pancreatic hormones. Somatostatin inhibits the secretion of insulin, glucagons, and pancreatic polypeptide. Insulin inhibits the secretion of glucagons, whereas glucagon stimulates the secretion of insulin and somatostatin.

### **1. Glucagon**

Glucagon is a 29-amino-acid polypeptide hormone secreted by the alpha cells of the pancreatic islets primarily in response to hypoglycemia (low blood sugar). Glucagon is essentially a catabolic hormone that decreases carbohydrate and lipid energy stores and increases the amount of glucose and fatty acids available for oxidation.

### **Control of Secretion**

The plasma glucose concentration is the major physiologic regulator of glucagons secretion. In addition to hypoglycemia and fasting, the following factors promote glucagons secretion: amino acids, exercise, stress, gastrin, cortisol, CCK, acetylcholine, and beta-adrenergic stimulation. The rate of glucagons secretion is inhibited by elevated blood levels of glucose and free fatty acids, and by somatostatin, insulin, secretin, phenytoin, and alpha-adrenergic stimulation.

### **Major Actions**

- Carbohydrate metabolism: Glucagon stimulates hepatic glycogenolysis, thereby promoting the release of glucose from liver glycogen stores. The action is mediated by cyclic AMP, which stimulates protein kinase activity, leading to the activation of phosphorylase, the glycogenolytic enzyme. Glucagon also interacts with hormone receptors coupled to the activation of phospholipase C, which eventually leads to calcium influx and stimulation of glycogenolysis. In addition to stimulating hepatic glycogenolysis, glucagon inhibits glycogenesis and raises the rate of hepatic gluconeogenesis. The net effect is an elevation of blood glucose ( hyperglycemia).
- Lipid metabolism: Glucagon stimulates lipolysis, thereby increasing the release of free fatty acids and glycerol from

adipose tissue. Glucagon also enhances hepatic ketogenesis by facilitating conversion of fatty acids to ketone bodies.

- Protein metabolism: Glucagon exerts a catabolic action on hepatic proteins and inhibits the incorporation of amino acids into hepatic protein.
- Cardiac effects: large amounts of exogenous glucagons produce appositive inotropic effect on the heart by increasing myocardial levels of cyclic AMP.

## 2. Insulin

### Structure, Biosynthesis, and Secretion

Insulin is a polypeptide hormone composed of 51 amino acids arranged in two chains (A and B), linked by disulfide bridges. Insulin is derived from a large polypeptide precursor-proinsulin which is synthesized in the endoplasmic reticulum of beta cells and packaged into membrane-bounded granules within the Golgi complex.

Insulin secretion occurs through exocytosis (emiocytosis), a calcium-dependent process that is enhanced by cyclic AMP and potassium. On entering the circulation, insulin is transported largely in free molecular form, not bound to plasma proteins.



### **Control of Secretion**

The secretion of insulin is regulated primarily by the blood glucose level, with an elevation of blood glucose (hyperglycemia), increasing both production and release of insulin. Ingested glucose effects a far greater secretion of insulin than an equivalent amount of intravenously administered glucose because several gastrointestinal hormones, including gastrin, secretin, CCK, gastric inhibitory polypeptide (GIP), and glucagons, stimulate insulin secretion. Insulin secretion is also increased by mannose, certain amino acids, vagal stimulation (acetylcholine), cyclic AMP, betaadrenergic stimulation, potassium, and oral hypoglycemic drugs such as tolbutamide. Hyperglycemia, somatostatin, alpha-adrenergic stimulation, thiazide diuretics, phenytoin, and diazoxide inhibit insulin secretion.

### **Major Actions**

- Cellular membrane permeability: Insulin facilitates the transport of glucose across selected cell membranes, thereby accelerating the entry of glucose into muscle, adipose tissue, fibroblasts, leukocytes, mammary glands, and the anterior pituitary. The transport of glucose into the liver, brain, renal tubules, intestinal mucosa, and erythrocytes is independent of insulin. Exercise and hypoxia mimic the effect of insulin on cellular permeability to glucose in skeletal muscle. The insulin requirements of

diabetics engaging in strenuous exercise may be reduced substantially and therefore must be monitored carefully to avoid hypoglycemia. Insulin also increases cellular permeability to amino acids, fatty acids, and potassium, particularly in muscle and adipose tissue.

- Carbohydrate metabolism: Insulin effectively lowers the level of blood glucose by enhancing the transport and peripheral utilization of glucose. Insulin increases muscle and liver glycogen while inhibiting those that produce glycogenolysis. Glycolytic enzymes are also activated by insulin, whereas several enzymes involved in gluconeogenesis are inhibited.
- Protein metabolism: Insulin is strongly anabolic, increasing protein synthesis and inhibiting protein catabolism. Insulin increases the incorporation of amino acids into protein by accelerating the entry of amino acids into the cell and possibly by increasing RNA synthesis.
- Lipid metabolism: Insulin stimulates formation of triglycerides (lipogenesis) and inhibits their breakdown (lipolysis). Insulin accelerates synthesis of fatty acid and glycerol phosphate and enhances cellular permeability to fatty acids, leading to increased deposition of triglycerides in adipose tissue.

### 3. Pancreatic Somatostatin

Unlike glucagons and insulin, pancreatic somatostatin does not directly regulate intermediary metabolism. Rather, it slows digestion and absorption of nutrients by exerting several inhibitory effects on digestive processes (eg, reduced gastric acid secretion decreased gastric emptying and inhibition of CCK secretion and gallbladder contraction).

Pancreatic somatostatin secretion is stimulated by elevations and gastrointestinal hormones (eg, CCK). The paracrine actions of somatostatin in the pancreatic islets have been discussed previously.

### The Adrenal Glands

The adrenal (suprarenal) glands are paired yellowish masses of tissue situated at the superior pole of each kidney. Each gland consists of two distinct entities—an outer adrenal cortex and an inner adrenal medulla—that differ in embryologic origin, character, and function.

### Adrenal Medulla

The adrenal medulla develops from the embryonic ectoderm. It remains functionally associated with the sympathetic nervous system, being essentially a modified sympathetic ganglion whose postganglionic neurons have lost their axons and become secretory.

Histologically, the adrenal medulla contains large, ovoid cells arranged in clumps or irregular cords around numerous blood vessels. The medullary cells, often termed chromaffin cells because their granules possess affinity for chromium salts, secrete the catecholamine hormones epinephrine (adrenaline) and norepinephrine (noradrenalin). The principal secretory product is epinephrine, with norepinephrine normally accounting for only 20% of the total secretion.

Adrenal medullary secretion of the catecholamines is physiologically controlled by the posterior hypothalamus. The hormones are stored in cellular granules, bound to adenosine triphosphate (ATP) and protein, and are released in response to the following stimuli: sympathetic nervous system activation, hypoglycemia, pain, hypoxia, hypotension, cold, emotional stress, acetylcholine, histamine, and nicotine.

#### **Actions of Adrenal Medullary Hormones**

Epinephrine and norepinephrine mimic the effects of sympathetic nerve discharge, producing the following effects:

- Direct increase in cardiac rate and myocardial force of contraction
- Dilation of coronary and skeletal muscle blood vessels
- Constriction of the cutaneous and visceral vasculature
- Relaxation of respiratory smooth muscle
- Inhibition of GI motility

- Pupillary dilation (mydriasis)
- Glycogenolysis in liver and muscle
- Lipolysis

The cardiac excitatory effects and the metabolic actions of lipolysis and glycogenolysis are mediated by cyclic AMP, the latter involving the activation of phosphorylase enzyme by protein kinase.

The catecholamines also elevate the metabolic rate (calorigenic action), stimulate the central nervous system, increase alertness, and stimulate respiration.

### **Adrenal Cortex**

The adrenal cortex develops from the mesoderm during embryonic life. The cells of the adrenal cortex, which are arranged in continuous cords separated by capillaries, are characterized by an abundance of mitochondria, endoplasmic reticulum, and accumulation of lipid.

Adrenal cortical tissue is structurally arranged into three concentric regions or zones: a thin outer zona glomerulosa, a thick middle zona fasciculata, and an inner zona reticularis bordering on the adrenal medulla.

Chemically, the steroid hormones of the adrenal cortex, the adrenocorticoids, are all derivatives of cholesterol. The adrenocorticoid hormones are usually divided into three functional groups: the mineralocorticoids, such as aldosterone, which regulate electrolyte and water balance; the glucocorticoids, such as cortisol, which affect carbohydrate, protein, and fat metabolism; and the adrenogenital steroids or sex hormones.

The adrenogenital steroids are of three types: androgens (such as dehydroepiandrosterone), estrogens (such as estradiol), and progestins (such as progesterone).

Under normal physiologic conditions the adrenogenital steroids are secreted (under ACTH control) in minute amounts, and therefore they exert minimal effects on reproductive functions. Excessive secretion of adrenal androgens results in precocious pseudopuberty in boys, and causes masculinization of females (adrenogenital syndrome).

### **1. Mineralocorticoids**

#### **Control of Secretion and Actions.**

Aldosterone is the principal physiologic mineralocorticoid secreted by the zona glomerulosa. Its secretion is regulated primarily by the reninangiotensin mechanism. The plasma

concentrations of sodium and potassium are involved in the control of aldosterone secretion. Hyperkalemia (elevated plasma potassium) exerts a direct stimulating effect on the zona glomerulosa, whereas hyponatremia (low plasma sodium) activates the rennin-angiotensin mechanism. Atrial natriuretic hormone (ANH) inhibits rennin secretion, and it also reduces the responsiveness of the cells in the zona glomerulosa to angiotensin II. Other factors contributing to the control of aldosterone secretion include blood volume and ACTH, the latter exerting a limited, nonselective stimulatory effect.

Aldosterone plays a major physiologic role in the maintenance of electrolyte and fluid balance by promoting the renal tubular reabsorption of sodium and the secretion of potassium and hydrogen. Aldosterone binds to nuclear receptors and stimulates DNA-directed RNA synthesis leading to increased formation of specific proteins involved in sodium and potassium transport.

A similar sodium-retaining, potassium-excreting action is exerted on other target tissues, including salivary glands and sweat glands. A similar sodium-retaining, potassium-excreting action is exerted on other target tissues, including salivary glands and sweat glands.

## 2. Glucocorticoids

### Control of Secretion and Actions.

Glucocorticoid secretion, which occurs primarily in the zona fasciculata, is controlled by ACTH. A variety of stressful stimuli, including anxiety, fear, hypoglycaemia, hypotension, and haemorrhage, increase secretion of adrenocorticotropic hormone-releasing hormone (CRH) from the hypothalamus. CRH promotes ACTH secretion by the adenohypophysis, and ACTH stimulates adrenal cortical secretory activity, thereby elevating blood levels of cortisol (the principal physiologic glucocorticoid). Elevated blood levels of free cortisol normally exert a negative feedback control over further secretion of CRH and ACTH. Prolonged ACTH secretion results in hypertrophy and hyperplasia of the adrenal cortex and excessive secretion of all adrenocorticoid hormones. The metabolic and physiologic actions of the glucocorticoids are summarized below.

- Carbohydrate metabolism: Glucocorticoids stimulate hepatic gluconeogenesis and inhibit peripheral uptake and utilization of glucose by skeletal muscle and adipose tissue, thereby promoting hyperglycemia. Hepatic glycogenesis is also enhanced.
- Protein metabolism: Glucocorticoids exert protein catabolic and antianabolic actions, promoting the breakdown of existing proteins while inhibiting the



incorporation of amino acids into new proteins.

- Lipid metabolism: Glucocorticoids inhibit lipogenesis and favor mobilization of fats from adipose tissues. When present in large amounts, these hormones favor redistribution of adipose stores by promoting loss of fat from the extremities, and accumulation of fat depots in central body regions (e.g., “moon face” and “buffalo hump” formation).
- Permissive Actions: Glucocorticoids are essential for normal vascular reactivity to the catecholamines. Other permissive effects include support for the metabolic actions (particularly lipolysis) of the catecholamines and glucagons.
- Blood and immunologic effects: Glucocorticoids inhibit the immune response, cause involution of lymphoid tissue, and reduce blood levels of lymphocytes, eosinophils, and basophils. These hormones also stimulate erythropoiesis and elevate circulating levels of platelets and neutrophils.
- GI tract effects: Glucocorticoid hormones stimulate gastric acid and pepsin secretion and inhibit the production of protective mucus, thereby favouring development of gastric ulcers.

### **The Sex Glands**

The sex glands, the ovaries of the female and the testes of the male, not only produce the sex cells but are also important

endocrine organs. The hormones produced by these organs are needed in the development of the sexual characteristics, which usually appear in the early teens and for the maintenance of the reproductive apparatus once full development has been attained. The main androgen produced by the male sex glands, testosterone, is responsible for the growth of and functioning of the male reproductive tract. Those structures directly concerned with reproduction are considered primary sex characteristics. Testosterone is also responsible for male secondary sex characteristics such as a deep voice and facial hair.

In the female, the hormones that most nearly parallel testosterone in their actions are the estrogens. Estrogens contribute to the development of the female secondary sex characteristics and stimulate the development of the mammary glands, the onset of menstruation, and the development and functioning of the reproductive organs.

The other hormone produced by the female sex glands, called progesterone, assists in the normal development of pregnancy. All of the sex hormones are discussed in more detail in unit 14.

### **The Thymus Gland**

The thymus gland lies in the upper part of the chest above the heart. Through the production of a hormone called thymosin, it helps in the development of certain white blood cells, called T-lymphocytes that help protect the body against foreign organisms. Because this gland is most active before birth and early in life, it is large during childhood but gradually shrinks in size as one reach adulthood.

### **The Pineal Gland**

The pineal gland, a small, flattened, cone-shaped structure located between the two parts of the thalamus, produces a hormone called melatonin in a number of animals and also in humans. Melatonin, or some other hormone from the pineal, is thought to regulate the release of certain substances from the hypothalamus, which may in turn regulate the secretion of gonadotropins from the pituitary. There is evidence from animal studies that the production of melatonin is regulated by the amount of light in the environment.

## Review Questions

1. Name some general functions of hormones.
2. Give three examples of protein hormones; of steroid hormones.
3. Why are certain cells the target tissue for a given hormone?
4. Name the two divisions of the pituitary and describe the effects of the hormones from each.
5. What type of system connects the anterior pituitary with the hypothalamus? What is carried to the pituitary by this system?
6. Where is the thyroid gland located? What is its main hormone, what does it do?
7. What is the main purpose of PTH? What are the effects of removal of the parathyroid glands? Of excess secretion?
8. Name the two divisions of the adrenal glands and describe the effects of the hormones from each.
9. What is the main purpose of insulin in the body? Name and describe the condition characterized by insufficient production of insulin.

# CHAPTER NINE

## CARDIOVASCULAR SYSTEM

### Chapter Objectives

At the end of the chapter, the student should be able to:

- Describe the primary functions of blood.
- List the formed elements of blood and identify the most important function of each.
- Explain the steps involved in blood clotting.
- Describe ABO and Rh blood typing.
- Describe the three layers of the heart.
- Name the four chambers of the heart.
- Name the valves at the entrance and exit of each ventricle.
- Briefly describe blood circulation through the myocardium.
- Name the components of the heart's conduction system.
- Briefly describe the cardiac cycle.
- Explain what produces the two heart sounds.
- Differentiate among the three main types of vessels in the body with regard to structure and function.
- Compare the locations and functions of the pulmonary and systemic circuits.
- Describe the three coats of the blood vessels.

- Name the four sections of aorta.
- Name the main branches of the aorta.
- Name the main vessels that drain into the superior and inferior venae cavae.
- Describe the structure and function of the hepatic portal system.
- Define pulse and list factors that affect the pulse rate.
- Explain how blood pressure is commonly measured.

### **Selected Key Terms**

**The following key terms are defined in the Glossary:**

Anastomosis	Diastole	Leukaemia	Systole
Aorta	Endocardium	Leukocyte	Valve
Arteriole	Endothelium	Murmur	Vein
Artery	Epicardium	Myocardium	Vena cava
Atrium	Erythrocyte	Pericardium	Ventricle
Capillary	Fibrin	Plasma	Venule
Coagulation	Haemoglobin	Platelet	
Coronary	Hematocrit	Pulse	
Septum	Hemolysis	Serum	

The cardiovascular system is the transport system of the body by which food, oxygen, water and all other essentials are carried to the tissue cells and their waste products are carried away. It consists of three parts:

1. **The blood**, Which is the fluid in which materials are carried to and from the tissue
2. **The heart**, which is the driving force which propels the blood
3. **The blood vessels**, the routes by which the blood travels to and through the tissues and back to the heart.

### **The Blood**

Blood is classified as a connective tissue, since nearly half of it is made up of cells. However, it differs from other connective tissues in that its cells are not fixed in position, instead they move freely in the liquid portion of the blood, the **plasma**.

Blood is a viscous (thick) fluid that varies in colour from bright to dark red, depending on how much oxygen it is carrying. Its quantity differs with the size of the person; the average adult male, weighing 70 kg has about 5-6 litres of blood. This volume accounts for about 8% of the total body weight. It is carried through a closed system of vessels pumped by the heart. The circulating blood is of fundamental importance in maintaining the internal environment in a constant state (homeostasis).

## Functions of the Blood

### 1. Transportation

- A. Oxygen- from inhaled air diffuses into the blood through the thin lung membranes and is carried to all the tissue of the body. Carbon dioxide, a waste product of cell metabolism, is carried from the tissues to the lungs, where it is breathed out.
- B. The blood transports foods and other needed substances such as minerals and vitamins, to the cells. These materials may enter the blood from the digestive system or may be released into the blood from body stores.
- C. The blood transports waste products from the cells to the sites from which they are released. The kidney removes excess water, minerals, and urea from protein metabolism and maintains the acid-base balance of the blood. The liver removes bile pigments and drugs.
- D. The blood carries hormones from their sites of origin to the organs they affect.

### 2. Regulation

- A. Buffers in the blood help keep the PH of body fluids at about 7.4
- B. The blood serves to regulate the amount of fluid in the tissues by means of substances (mainly proteins) that maintain the proper osmotic pressure



- C. The blood transports heat that is generated in the muscles to other parts of the body thus aiding in the regulation of body temperature by the blood, thus aiding in the regulation of body temperature.

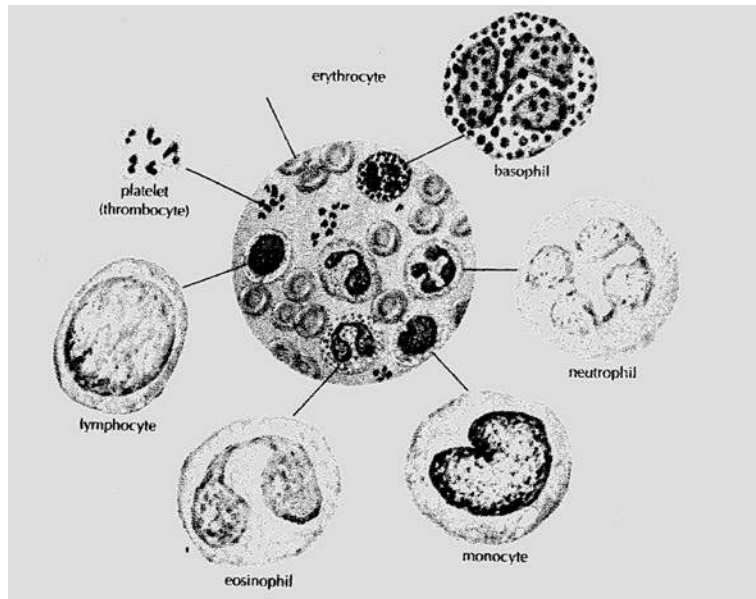
### **3. Protection**

- A. The blood carries the cells that are among the body's defenders against pathogens. It also contains substances (antibodies) that are concerned with immunity to disease.
- B. The blood contains factors that protect against blood loss.

### **Composition of Blood**

The blood is composed of two prime elements: as already mentioned, the liquid element is called plasma; the cells and fragments of cells are called formed elements or corpuscles (Figure 9-1). The formed elements are classified as follows:

1. Erythrocytes, from erythro, meaning "red," are the red blood cells, which transport oxygen.
2. Leukocytes, from leuko, meaning "white," are the several types of white blood cells, which protect against infection.
3. Platelets, also called thrombocytes, are cell fragments that participate in blood clotting.



**Figure 9-1. Blood cells** (From Memmler and Wood: *The Human Body in Health and Disease*, ed 6, Philadelphia, 1987, J. B. Lippincott co.)

### **Blood Plasma**

Over half of the total volume of blood is plasma. The plasma itself is 90% water. Many different substances dissolved or suspended in the water, make up the other 10%. The plasma content varies somewhat, since the substances carried by the blood to and from the organs get used and added to. However, the body tends to maintain a fairly constant level of these substances. For example, the level of glucose, a simple sugar,

is maintained at a remarkably constant level of about one tenth of a 1% solution.

After water, the next largest percentage of material in the plasma is protein. Proteins are the principal constituents of cytoplasm and are essential to the growth and the rebuilding of body tissues. The plasma proteins include the following:

1. Albumin, the most abundant protein in plasma, is important for maintaining the osmotic pressure of the blood. This protein is manufactured in the liver.
2. The antibodies combat infection.
3. The blood clotting factors are also manufactured in the liver.
4. A system of enzymes made of several proteins, collectively known as complement, helps antibodies in their fight against pathogens.

Nutrients are also found in the plasma. One group of nutrients is the **carbohydrates**. The principal form of carbohydrate found in the plasma is glucose, which is absorbed by the capillaries of the intestine following digestion. Glucose is stored mainly in the liver as glycogen and released as needed to supply energy. **Amino acids**, the products of protein digestion, are also found in the plasma. These are also absorbed into the blood through the intestinal capillaries. **Lipids** constitute a small percentage of blood plasma. Lipids include fats. They may be stored as fat for reserve energy or carried to the cells as a source of energy. The

mineral salts in the plasma appear primarily as chloride, carbonate, or phosphate salts of sodium, potassium, and magnesium. These salts have a variety of functions, including the formation of bone (calcium and phosphorus), the production of hormones by certain glands (iodine for the production of thyroid hormone), the transportation of the gases oxygen and carbon dioxide (iron), and the maintenance of the acid base balance (sodium and potassium carbonates and phosphates). Small amounts of other elements also help maintain homeostasis. Many other materials, such as waste products and hormones, are also transported in the plasma.

### The Formed Elements

#### Erythrocytes

**Erythrocytes**, the red cells, are tiny, disk-shaped bodies with a central area that is thinner than the edges. They are different from other cells in that the mature form found in the circulating blood does not have a nucleus. These cells, like almost all the blood cells, live a much shorter time (120 days) than most other cells in the body, some of which last a lifetime. One purpose of the red cells is to carry oxygen from the lungs to the tissues. The oxygen is bound in the red cells to **haemoglobin**, a protein that contains iron. Haemoglobin combined with oxygen gives the blood its characteristic red color. The more oxygen carried by the haemoglobin, the brighter is the red color of the blood.

Therefore, the blood that goes from the lungs to the tissues is a bright red because it carries a great supply of oxygen; in contrast, the blood that returns to the lungs is a much darker red, since it has given up much of its oxygen to the tissues. Haemoglobin that has given up its oxygen is able to carry hydrogen ions; in this way, haemoglobin acts as a buffer and plays an important role in acid-base balance. The red cells also carry a small amount of carbon dioxide from the tissues to the lungs for elimination in exhalation.

Carbon monoxide is a harmful gas that combines with haemoglobin to form a stable compound. It displaces the oxygen that is normally carried by the haemoglobin and reduces the oxygen-carrying ability of the blood. Carbon monoxide may be produced by the incomplete burning of various fuels, such as gasoline, coal, wood, and other carbon containing materials. It also occurs in automobile exhaust fumes and in cigarette smoke.

The erythrocytes are by far the most numerous of the corpuscles, averaging from 4.5 to 5 million per cubic millimetre of blood.

### **Leukocytes**

The leukocytes, or white blood cells, are very different from the erythrocytes in appearance, quantity, and function. They contain

nuclei of varying shapes and sizes; the cells themselves are round. Leukocytes are outnumbered by red cells by 700 to 1, numbering 5,000 to 10,000 per cubic millimetre of blood. Whereas the red cells have a definite color, the leukocytes tend to be colorless.

The different types of white blood cells are identified by their size, the shape of the nucleus, and the appearance of granules in the cytoplasm when the cells are stained, usually with Wright's blood stain. **Granulocytes** include **neutrophils**, which show lavender granules; **eosinophils**, which have beadlike, bright pink granules; and **basophils**, which have large, dark blue granules that often obscure the nucleus. The neutrophils are the most numerous of the white cells, constituting up to 60% of all leukocytes.

Because the nuclei of the neutrophils are of various shapes, they are also called **polymorphs** (meaning "many forms") or simply polys.

The **agranulocytes**, so named because they lack easily visible granules, are the **lymphocytes** and **monocytes**. The ratio of the different types of leukocytes is often a valuable clue in arriving at a diagnosis (see Figure 9-1).

The most important function of the leukocytes is to destroy pathogens. Whenever pathogens enter the tissues, as through a wound, certain white blood cells (neutrophils and monocytes) are attracted to that area. They leave the blood vessels and proceed by **ameboid** or ameba-like motion to the area of infection. There they engulf the invaders by a process called **phagocytosis**. If the pathogens are extremely strong or numerous, they may destroy the leukocytes. A collection of dead and living leukocytes, forms **pus**. A collection of pus localized in one area is known as **abscess**. The Lymphocytes destroy foreign invaders by attacking the cells directly or by producing antibodies that circulate in the blood and help destroy the cells.

### **Platelets**

Of all the formed elements, the blood platelets (thrombocytes) are the smallest (Figure 9-1). These tiny structures are not cells in themselves, but fragments of cells. The number of platelets in the circulating blood has been estimated at 200,000 to 400,000 per cubic millimeter. Platelets are essential to blood coagulation (clotting). When, as a result of injury, blood comes in contact with any tissue other than the lining of the blood vessels, the platelets stick together and form a plug that seals the wound. They then release chemicals that take part in a series of reactions that eventually results in the formation of a clot. The last step in these reactions is the conversion of

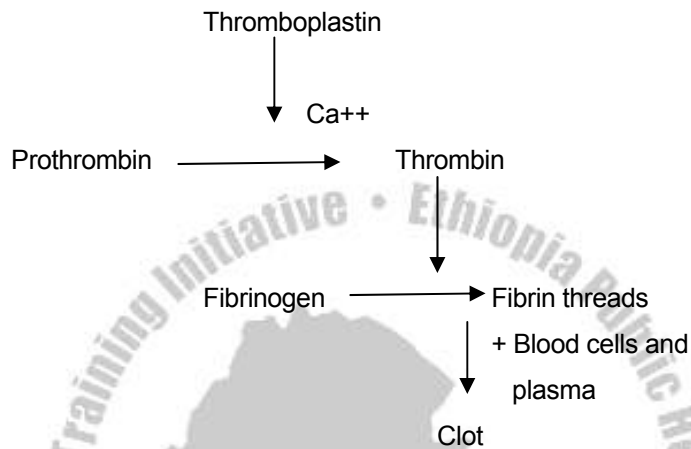
a plasma protein called fibrinogen into solid threads of fibrin, which form the clot.

### **Blood Clotting**

Blood clotting, or coagulation, is a protective device that prevents blood loss when a blood vessel is ruptured by an injury. The many substances necessary for clotting are normally inactive in the blood stream. A balance is maintained between compounds that promote clotting, known as procoagulants, and those that prevent clotting known as anticoagulants. In addition, there are also chemicals in the circulation that act to dissolve clots. Under normal conditions the substances that prevent clotting prevail. However, when an injury occurs, the procoagulants are activated and a clot is formed. Basically, the clotting process consists of the following essential steps (Figure 9-2):

1. The injured tissues release thromboplastin, a substance that triggers the clotting mechanism.
2. Thromboplastin reacts with certain protein factors and calcium ions to form prothrombin activator, which in turn reacts with calcium ions to convert the prothrombin to thrombin.
3. Thrombin, in turn, converts soluble fibrinogen into insoluble fibrin. Fibrin forms a network of threads that entraps red blood cells and platelets to form clot.



**Figure 9-2. Formation of a clot.**

## Blood Typing and Transfusions

### Blood Groups

If for some reason the amount of blood in the body is severely reduced, through **haemorrhage** or disease, the body cells suffer from lack of oxygen and food. The obvious measure to take in such an emergency is to inject blood from another person into the veins of the patient, a procedure called **transfusion**.

The patient's plasma may contain substances called antibodies that can cause the red cells of the donor's blood to become clumped, a process called **agglutination**. Alternatively, the

donor's red blood cells may rupture and release their haemoglobin; such cells are said to be **haemolysed**, and the resulting condition can be very dangerous.

These reactions are determined largely by certain proteins, called antigens, on the surface membrane of the red blood cells. There are many types of these proteins but only two groups are particularly likely to cause a transfusion reaction, the so-called A and B antigens and the Rh factor. Four blood types involving the A and B antigens have been recognized: A, B, AB, and O. These letters indicate the types of antigen present on the red cells, with O indicating that neither A nor B antigen is present. It is these antigens on the donor's red cells that react with the antibodies in the patient's plasma and cause a transfusion reaction.

Blood serum containing antibodies that can agglutinate and destroy red cells that have A antigens on the surface is called **anti-A serum**; blood serum containing antibodies that can destroy red cells with B antigen on the surface is called **anti-B serum**. These sera are used to test for blood type.

Persons with type O blood are said to be **universal donors** because they lack the AB red cell antigens and in an emergency their blood can be given to anyone. Type AB individuals are called **universal recipients**, since their blood contains no

antibodies to agglutinate red cells and they can therefore receive blood from most donors (Table 9-1).

Usually a person can safely give blood to any person with the same blood type. However, because of other factors that may be present in the blood, determination of blood type must be accompanied by additional tests (cross matching) for compatibility before a transfusion is given.

### **The Rh factor**

Rh factor is another red cell antigen that determines the blood group. Those individuals who possess this antigen in their red cell surface are said to be **Rh positive**. Those who lack this antigen are said to be **Rh negative**. If Rh positive blood is given to an Rh negative person, he or she may become sensitized to the protein in the Rh positive blood. The sensitized person's blood cells may then produce antibodies to the "foreign" Rh antigens and destroy the transfused red cells.

A pregnant woman who is Rh negative may become sensitized by proteins from her Rh positive fetus (this factor having been inherited from the father) if these proteins enter the mother's circulation before or during childbirth. During a subsequent pregnancy with an Rh positive fetus, some of the anti Rh antibodies may pass from the mother's blood in to the blood of her fetus and cause destruction of the fetus's red cells. This

condition is called **erythroblastosis fetalis**, or **haemolytic disease of the newborn**.

Erythroblastosis fetalis may be prevented by administration of immune globulin Rho (D), or RhoGAM, to the mother shortly after delivery. This destroys the Rh positive fetal cells in the mother's blood and prevents her sensitization.

**Table 9-1 The ABO Blood Group System**

Blood Type	RBC Antigen	Plasma Antibodies	Can take from	Can donate to
A	A	Anti-B	A, O	A, AB
B	B	Anti-A	B, O	B, AB
AB	A, B	None	AB, A, B, O	AB
O	None	Anti-A, Anti-B	O	O, A, B, AB

**The Heart**

The heart is a muscular pump that drives the blood through the blood vessels. Slightly bigger than a fist, this organ is located between the lungs in the center and a bit to the left on the midline of the body. The importance of the heart has been recognized for centuries. The fact that its rate of beating is affected by the emotions may be responsible for the very frequent references to the heart in song and poetry. However, the vital functions of the heart and its disorders are of more practical importance to us.

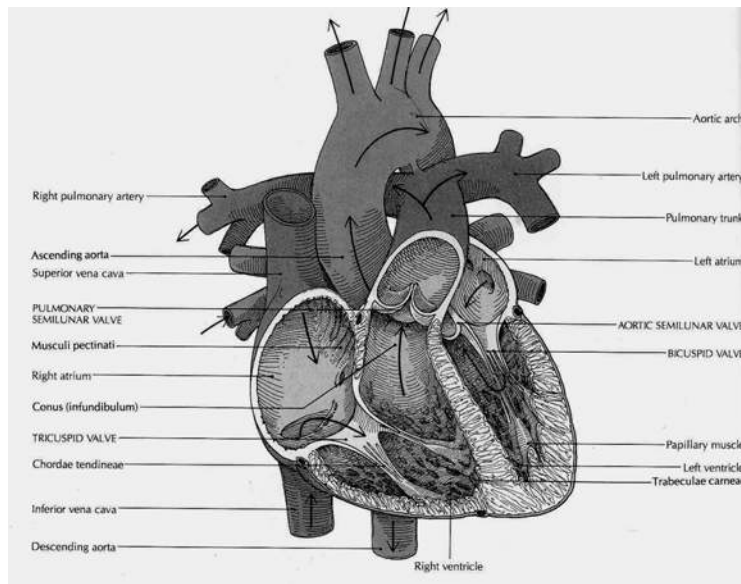
### Structure of the Heart

The heart is a hollow organ the walls of which are formed of three different layers. The heart wall has three tissue layers (Figure 9-3).

1. The **endocardium** is a very thin smooth layer of cells that resembles squamous epithelium. This membrane lines the interior of the heart. The valves of the heart are formed by reinforced folds of this material.
2. The **myocardium**, the muscle of the heart, is the thickest layer.
3. The **epicardium** forms the thin outermost layer of the heart wall and is continuous with the serous lining of the fibrous sac that encloses the heart. These membranes together make up the pericardium. The serous lining of the pericardial sac is separated from the epicardium on the heart surface by a thin fluid- filled space.

### Two Hearts and a Partition

Physicians often refer to the right heart and the left heart. This is because the human heart is really a double pump. The two sides are completely separated from each other by a partition called the **septum**. The upper part of this partition is called **interatrial septum**; while the larger the lower portion is called **interventricular septum**. The septum, like the heart wall, consists largely of myocardium.



**Figure 9-3. Heart and great vessels** (Source: Carola, R., Harley, J.P., Noback R.C., (1992), Human anatomy and physiology, Mc Graw hill inc, New York, 2<sup>nd</sup> ed,)

### Four Chambers

On either side of the heart are two chambers, one a receiving chamber (atrium) and the other a pumping chamber (ventricle):

1. The **right atrium** is a thin-walled chamber that receives the blood returning from the body tissues. This blood, which is low in oxygen, is carried in the veins, the blood vessels leading to the heart from the body tissues.

2. The **right ventricle** pumps the venous blood received from the right atrium and sends it to the lungs.
3. The **left atrium** receives blood high in oxygen content as it returns from the lungs.
4. The **left ventricle**, which has the thickest walls of all, pumps, oxygenated blood to all parts of the body. This blood goes through the arteries, the vessels that take blood from the heart to the tissues.

#### **Four Valves**

Since the ventricles are the pumping chambers, the valves, which are all one way, are located at the entrance and the exit of each ventricle. The entrances valves are the **atrioventricular valves**, while the exit valves are the **semilunar valves**. Semilunar means “resembling a half moon.” Each valve has a specific name, as follows:

1. The **right atrioventricular valve** also is known as the **tricuspid valve**, since it has three cusps, or flaps, that open and closes. When this valve is open, blood flows freely from the right atrium into the right ventricle. However, when the right ventricle begins to contract, the valve closes so that blood cannot return to the right atrium; this ensures forward flow into the pulmonary artery.
2. The **left atrioventricular valve** is the bicuspid valve, but it is usually referred to as the **mirtal valve**. It has two rather heavy cusps that permit blood to flow freely from the left

atrium into the left ventricle. However, the cusps close when the left ventricle begins to contract; this prevents blood from returning to the left atrium and ensures the forward flow of blood into the **aorta**. Both the tricuspid and mitral valves are attached by means of thin fibrous threads to the wall of the ventricles. The function of these threads, called the **chordae tendineae** (see Figure 9-6), is to keep the valve flaps from flipping up into the atria when the ventricles contract and thus causing a backflow of blood.

3. The **pulmonic** (semilunar) **valve** is located between the right ventricle and the pulmonary artery that leads to the lungs. As soon as the right ventricle has finished emptying itself, the valve closes in order to prevent blood on its way to the lungs from returning to the ventricle.
4. The **aortic** (semilunar) **valve** is located between the left ventricle and the aorta. Following contraction of the left ventricle, the aortic valve closes to prevent the flow of blood back from the aorta to the ventricle.


The appearance of the heart valves in the closed position is illustrated in Figure 9-4.

### **Blood Supply to the Myocardium**

Although blood flows through the heart chambers, only the endocardium comes into contact with it. Therefore, the myocardium must have its own blood vessels to provide oxygen and nourishment and to remove waste products. The arteries



that supply blood to the muscle of the heart are called the **right** and **left coronary arteries** (Figure 9-5). These arteries, which are the first branches of the aorta, arise just above the aortic semilunar valve (see Figure 9-4). They receive blood when the heart relaxes. After passing through capillaries in the myocardium, blood drains into the cardiac veins and finally into the coronary (venous) sinus for return to the right atrium.



**Figure 9-4. Valves of the heart, seen from above, in the closed position** (From Memmler and Wood: *The Human Body in Health and Disease*, ed 6, Philadelphia, 1987, J. B. Lippincott co.)

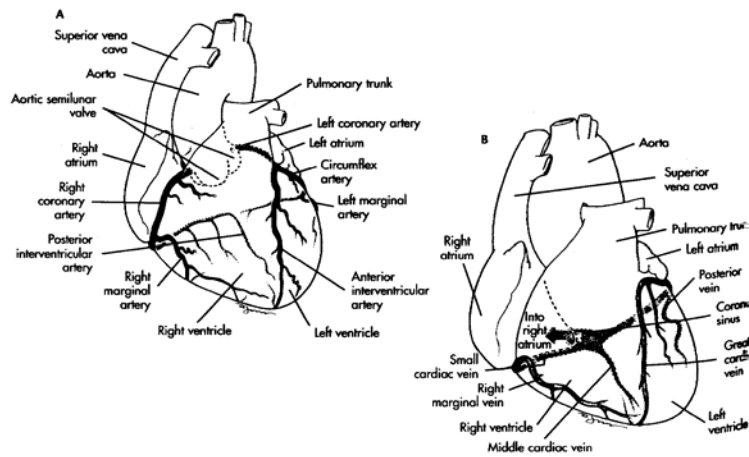
## Physiology of the Heart

### The Work of the Heart

Although the right and left side of the heart are separated from each other, they work together. The blood is squeezed through the chambers by a contraction of heart muscle beginning in the thin-walled upper chambers, the atria, followed by a contraction of the thick muscle of the lower chambers, the ventricles. This

active phase is called **systole**, and in each case it is followed by a resting period known as **diastole**. The contraction of the walls of the atria is completed at the time the contraction of the ventricles begins. Thus, the resting phase (diastole) begins in the atria at the same time as the contraction (systole) begins in the ventricles. After the ventricles have emptied, both chambers are relaxed for a short period of time as they fill with blood. Then another beat begins with contraction of the ventricles. This sequence of heart relaxation and contraction is called the **cardiac cycle**. Each cycle takes an average of 0.8 seconds.

Cardiac muscle tissue has several unique properties. One of these is the interconnection of the muscle fibers. The fibers are interwoven so the stimulation that causes the contraction of one fiber results in the contraction of the whole group. This plays an important role in the process of conduction and the working of the heart muscle.



**Figure 9-5. Coronary arteries and cardiac veins.** (Left) Anterior view. (Right) Posterior view. (source David T. Lindsay, Functional human Anatomy, Missouri, USA, Masby, 1996, pp 398)

Another property of heart muscle is its ability to adjust contraction strength to the amount of blood received. When the heart chamber is filled and the wall stretched (within limits), the contraction is strong. As less blood enters the heart, the contraction becomes weaker. As more blood enters the heart, as occurs during exercise, the muscle contracts, with greater strength so push the larger volume of blood out into the blood vessels.

The volume of blood pumped by each ventricle in 1 minute is termed the **cardiac output**. It is determined by the volume of blood ejected from the ventricle with each beat—the **stroke**

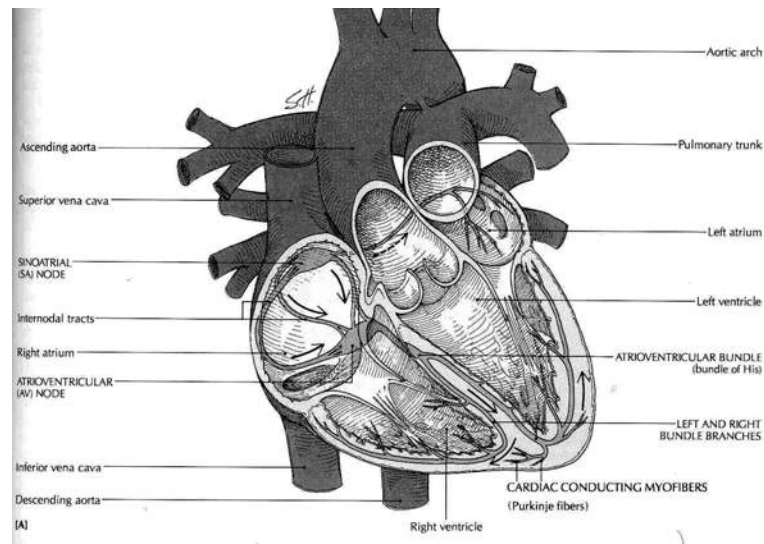
**volume**—and the number of beats of the heart per minute—the **heart rate**. The cardiac output averages 5 litres/minute for an adult at rest.

### **The Conduction System of the Heart**

The cardiac cycle is regulated by specialized areas in the heart wall that forms the conduction system of the heart. Two of these areas are tissue mass called **nodes**; the third is a group of fibers called the **atrioventricular bundle**. The sinoatrial node, which is located in the upper wall of the right atrium and initiates the heart beat, is called the pacemaker. The second node, located in the interatrial septum at the bottom of the right atrium, is called the atrioventricular node. The atrioventricular bundle, also known as the bundle of His, is located at the top of the interventricular septum; it has branches that extend to all parts of the ventricle walls. Fibers travel first down both sides of the interventricular septum in groups called the right and left bundle branches. Smaller Purkinje fibers then travel in a branching network throughout the myocardium of the ventricles (Figure 9-6). The order in which the impulses travel is as follows:

1. The sinoatrial node generates the electric impulse that begins the heart beat.
2. the excitation wave travels throughout the muscle of each atrium, causing it to contract.

3. the atrioventricular node is stimulated. The relatively slower conduction through this node allows time for the atria to contract and complete the filling of the ventricles.
  4. The excitation wave travels rapidly through the bundle of His and then throughout the ventricular walls by means of the bundle branches and Purkinje fibers. The entire musculature of the ventricles contracts practically at once.
- As a safety measure, a region of the conduction system other than the sinoatrial node fails, but it does so at a slower rate.



**Figure 9-6. Conduction system of the heart** (Source: Carola, R., Harley, J.P., Noback R.C., (1992), Human anatomy and physiology, Mc Graw hill inc, New York, 2<sup>nd</sup> ed.)

### Control of the Heart Rate

Although the fundamental beat of the heart originates within the heart itself, the heart rate can be influenced by the nervous system and by other factors in the internal environment. Recall from chapter 7 that stimulation from the sympathetic nervous system increases the heart rate and the stimulation from the parasympathetic nervous system decreases the heartrate. These influences allow the heart to meet changing need rapidly. The heart rate is also affected by such factors as hormones, ions, and drugs in the blood.

### Heart Rates

1. **Bradycardia** is a relatively slow heart rate of less than 60 beats/minute. During rest and sleep, the heart may beat less than 60 beats/minute but usually does not fall below 50 beats/minute.
2. **Tachycardia** refers to a heart rate over 100 beats/minute.
3. **Sinus arrhythmia** is a regular variation in heart rate due to changes in the rate and depth of breathing. It is normal phenomenon.
4. **Premature beats**, also called extrasystoles are beats that come in before the the expected normal beats. They may occur in normal persons initiated by caffeine, nicotine, or psychologic stresses. They are also common in persons with heart disease.

### **Heart Sounds and Murmurs**

The normal heart sounds are usually described by the syllables “lubb” and “dupp.” The first is a longer, lower pitched sound that occurs at the start of ventricular systole. It is probably caused by a combination of things, including closure of the atrioventricular valves. The second, or “dupp,” sound is shorter and sharper. It occurs at the beginning of ventricular relaxation and is due in large part to sudden closure of the semilunar valves. Some abnormal sounds called **murmurs** are usually due to faulty action of the valves. For example, if the valves fail to close tightly and blood leaks back, a murmur is heard. Another condition giving rise to an abnormal sound is the narrowing (stenosis) of a valve opening. The many conditions that can cause abnormal heart sounds include congenital defects, disease, and physiological variations. A murmur due to rapid filling of the ventricles is called a **functional (flow) murmur**; such a murmur is not abnormal. An abnormal sound caused by any structural change in the heart or the vessels connected with the heart is called an **organic murmur**.

### **Blood Vessels**

#### **Functional classification**

The blood vessels, together with the four chambers of the heart, form a closed system for the flow of blood; only if there

is an injury to some part of the wall of this system does any blood escape. On the basis of function, blood vessels may be classified into three groups:

1. **Arteries** carry blood from the ventricles (pumping chambers) of the heart out to the capillaries in organs and tissue. The smallest arteries are called **arterioles**.
2. **Veins** drain capillaries in the tissues and organs and return the blood to the heart. The smallest veins are the **venules**.
3. **Capillaries** allow for exchanges between the blood and body cells, or between the blood and air in the lung tissues. The capillaries connect the arterioles and venules.

#### **Structure of blood vessels**

Arteries, veins and capillaries differ in structure. Three coats or layers are found in both arteries and veins (Figure 9-7). The outer most layer is called the tunica externa. Note smooth muscle is found in the middle layer or tunica media of arteries and veins. However, the muscle layer is much thicker in arteries than in veins. Why is this important? Because the thicker muscle layer in the artery wall is able to resist great pressures generated by ventricular systole. In arteries, the tunica media plays a critical role in maintaining blood pressure and controlling blood distribution in the body. This is



a smooth muscle, so it is controlled by the autonomic nervous system.

A thin layer of elastic and white fibrous tissue covers an inner layer of endothelial cells called the tunica interna in arteries and veins. The tunica interna is actually a single layer of squamous epithelial cells called endothelium that lines the inner surface of the entire circulatory system.

As you can see in Figure 9-7, veins have a unique structural feature not present in arteries. They are equipped with one-way valves that prevent the backflow of blood. When a surgeon cuts into the body, only arteries, arterioles, veins, and venules can be seen. Capillaries cannot be seen because they are microscopic. The most important structural feature of capillaries is their extreme thinness—only one layer of flat, endothelial cells composes the capillary membrane. Instead of three layers or coats, the capillary wall is composed of only one—the tunica interna. Substances such as glucose, oxygen, and wastes can quickly pass through it on their way to or from the cells. Smooth muscle cells that are called precapillary sphincters guard the entrance to the capillary and determine into which capillary blood will flow.

## **Location of common arteries and veins**

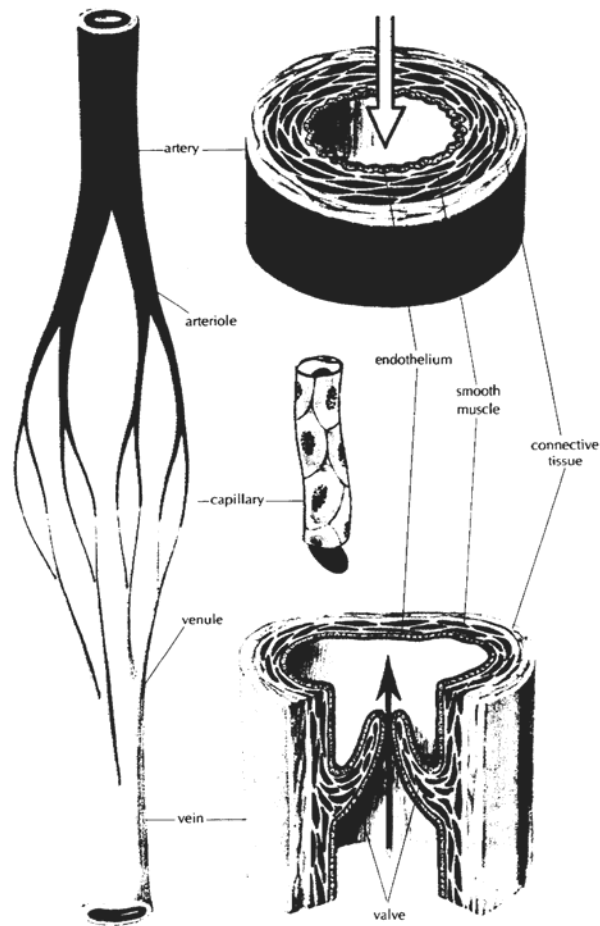
### **Names of systemic arteries**

#### **The Aorta and Its Parts**

The aorta is the largest artery in the body. It extends upward and to the right from the left ventricle. Then it curves backward and to the left. It continues down behind the heart just in front of the vertebral column, through the diaphragm, and into the abdomen (Figure 9-8 and 9-9). The aorta is one continuous artery, but it may be divided into sections:

1. The ascending aorta is near the heart and inside pericardial sac.
2. The aortic arch curves from the right to the left and also extends backward.
3. The thoracic aorta lies just in front of the vertebral column behind the heart and in the space behind the pleura.
4. The abdominal aorta is the longest section of the aorta, spanning the abdominal cavity.

The thoracic and abdominal aorta together makes up the descending aorta



**Figure 9-7. Sections of small blood vessels showing the thick arterial walls and the thin walls of veins and capillaries. Venous valves also are shown. The arrows indicate the direction of blood flow. (From Memmler and Wood: The Human Body in Health and Disease, ed 6, Philadelphia, 1987, J. B. Lippincott co.)**

### **Branches of the Ascending Aorta**

The first, or ascending, part of the aorta has two branches near the heart, called the left and right coronary arteries that supply the heart muscle. These form a crown around the base of the heart and give off branches to all parts of the myocardium.

### **Branches of the Aortic Arch**

The arch of aorta, located immediately beyond the ascending aorta, gives off three large branches.

1. The brachiocephalic trunk is a short artery formerly called the innominate. Its name means that it supplies the head and the arm. After extending upward somewhat less than 5 cm (2 inches), it divides into the right subclavian artery, which supplies the right side of the head and the neck.
2. The left common carotid artery extends upward from the highest part of the aortic arch. It supplies the left side of the neck and the head.
3. The left subclavian artery extends under the left collar bone (clavicle) and supplies the left upper extremity. This is the last branch of the aortic arch.

### **Branches of the Thoracic Aorta**

The third part of the aorta supplies branches to the chest wall, to the esophagus, and to the bronchi and their tree-like subdivisions in the lungs. There are usually nine to ten pairs of intercostal

arteries that extend between the ribs, sending branches to the muscles and other structures of the chest wall.

### **Branches of the Abdominal Aorta**

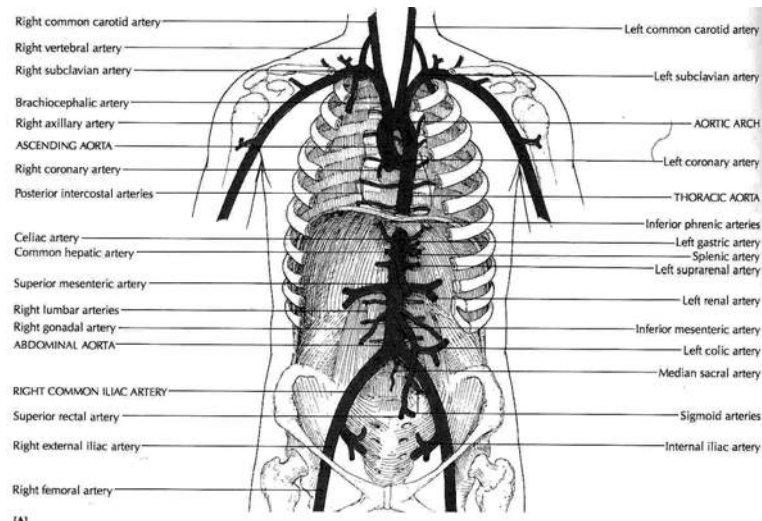
As in the case of the thoracic aorta, there are unpaired branches extending forward and paired arteries extending toward the side. The unpaired vessels are large arteries that supply the abdominal viscera. The most important of these visceral branches are listed below:

1. The celiac trunk is a short artery about 1.25 cm long that subdivides into three branches: the left gastric artery goes to the stomach, the splenic artery goes to the spleen, and the hepatic artery carries oxygenated blood to the liver.
2. The superior mesenteric artery, the largest of these branches, carries blood to most of the small intestine as well as to the first half of the large intestine.
3. The much smaller inferior mesenteric artery, located below the superior mesenteric and near the end of the abdominal aorta, supplies the second one half of the large intestine.

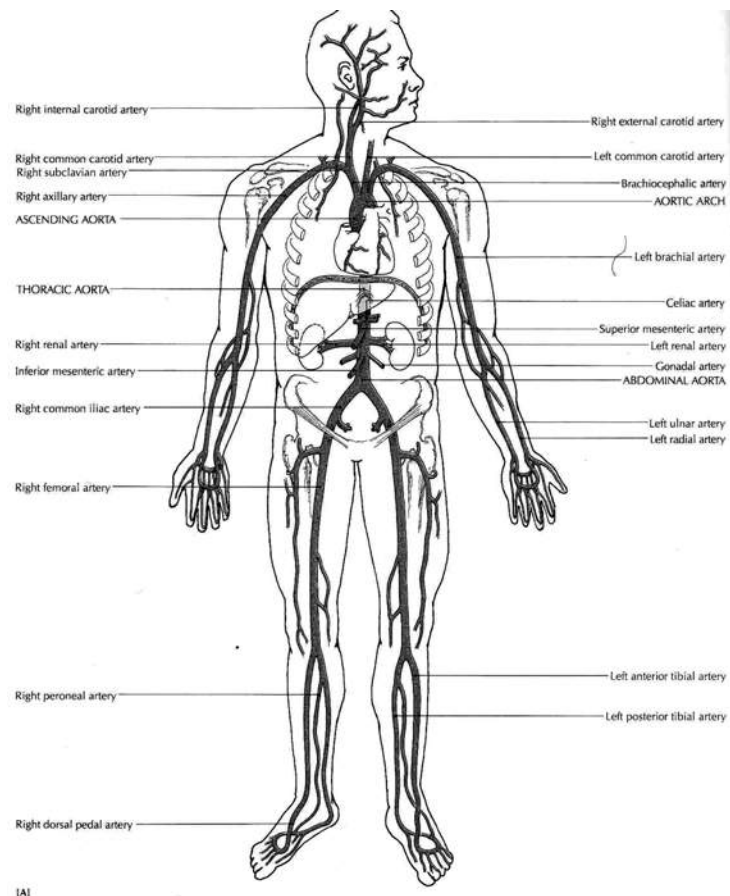
The lateral (paired) branches of the abdominal aorta include the following right and left divisions:

1. The phrenic arteries supply the diaphragm.
2. The suprarenal arteries supply the adrenal (suprarenal) glands.

3. The renal arteries, the largest in this group, carry blood to the kidneys.
4. The ovarian arteries in the female and testicular arteries in the male (formerly called the spermatic arteries), supply the sex glands.
5. Four pairs of lumbar arteries extend into the musculature of the abdominal wall.



**Figure 9-8. Aorta and its branches. The arrows indicate the flow of blood. The pulmonary veins carry oxygenated blood from the lungs to the left atrium of the heart.** (Source: Carola, R., Harley, J.P., Noback R.C., (1992), Human anatomy and physiology, Mc Graw hill inc, New York, 2<sup>nd</sup> ed.)



**Figure9-9 Principal arteries** (Source: Carola, R., Harley,J.P., Noback R.C., (1992), Human anatomy and physiology, Mc Graw hill inc, New York, 2<sup>nd</sup> ed.)

### Iliac Arteries and Their Subdivisions

The abdominal aorta finally divides into two common **iliac arteries**. Both of these vessels, about 5 cm long, extend into

the pelvis, where each one subdivides into an internal and an external iliac artery. The internal iliac vessels then send branches to the pelvic organs, including the urinary bladder, the rectum, and some of the reproductive organs. The external iliac arteries continue into the thigh as the femoral arteries. These vessels give off branches in the thigh and then become the popliteal arteries, which subdivide below the knee. The subdivisions include the tibial arteries and dorsalis pedis, which supply the leg and the foot.

### **Other Subdivisions of Systemic Arteries**

Just as the larger branches of a tree give off limbs of varying sizes, so the arterial tree has a multitude of subdivisions. Hundreds of names might be included, but we shall mention only a few. For example, each common carotid artery gives off branches to the thyroid gland and other structures in the neck before dividing into the external and internal carotid artery, which supplies parts of the head. The hand receives blood from the subclavian artery, which becomes the axillary in the axilla (armpit). The longest part of this vessel, the brachial artery, is in the arm proper. It subdivides into two branches near the elbow: the radial artery, which continues down the thumb side of the forearm and wrist, and the ulnar artery, which extends along the medial or little finger side into the hand.



### **Anastomosis**

A communication between two arteries is called an anastomosis. By this means, blood reaches vital organs by more than one route. Some examples of such unions of end arteries are described below:

1. The circle of Willis receives blood from the two internal carotid arteries as well as from the basilar artery, which is formed by the union of two vertebral arteries. This arterial circle lies just under the center of the brain and sends branches to the cerebrum and other parts of the brain.
2. The volar arch is formed by the union of the radial and ulnar arteries in the hand. It sends branches to the hand and fingers.
3. The mesenteric arches are made of communications between branches of the vessels that supply blood to the intestinal.
4. Arterial arches are formed by the union of branches of the tibial arteries in the foot, and similar anastomoses are found in various parts of the body.

Arteriovenous anastomoses are found in a few parts of the body, including the external ears, the hands, and the feet. Vessels that have muscular walls connect arteries directly with veins and thus bypass the capillaries. This provides a more rapid flow and a greater volume of blood to these areas than elsewhere, thus protecting these exposed parts from freezing in cold weather.

## **Names of Systemic Veins**

### **Superficial Veins**

Whereas most arteries are located in protected and rather deep areas of the body, many veins are found near the surface. The most important of these superficial veins are in the extremities.

These include the following:

1. The veins on the back of the hand and at the front of the elbow. Those at the elbow are often used for removing blood samples for test purposes, as well as for intravenous injections. The largest of this group of veins are the cephalic, the basilic, and the median cubital veins.
2. The saphenous veins of the lower extremities, which are the longest veins of the body. The great saphenous vein begins in the foot and extends up the medial side of the leg, the knee, and the thigh. It finally empties into the femoral vein near the groin.

### **Deep Veins**

The deep veins tend to parallel arteries and usually have the same names as the corresponding arteries. Examples of these include the femoral and the iliac vessels of the lower part of the body and the brachial, axillary, and subclavian vessels of the upper extremities. However, exceptions are found in the veins of the head and the neck. The jugular veins drain the areas supplied by the carotid arteries. Two brachiocephalic

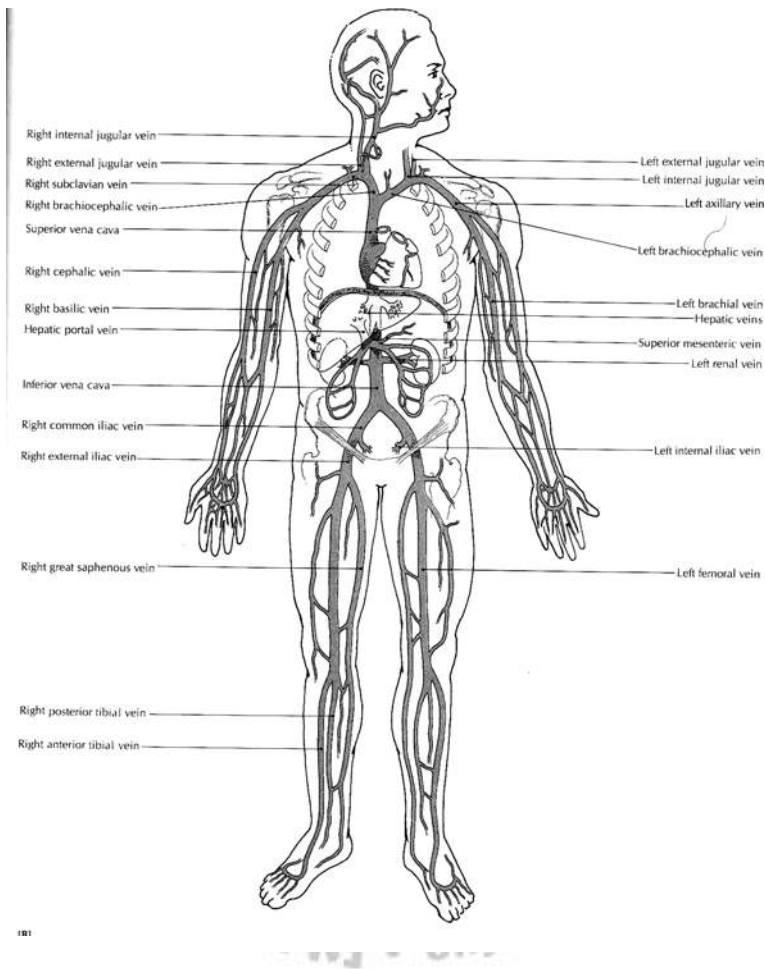
(innominate) veins are formed, one on each side, by the union of the subclavian and the jugular veins. (Remember there is only one brachiocephalic artery).

### **Superior Vena Cava**

The veins of the head, neck, upper extremities, and chest all drain into the superior vena cava, which goes to the heart. It is formed by the union of the right and left brachiocephalic veins, which drain the head, neck, and upper extremities. The azygos vein drains the veins of the chest wall and empties into the superior vena cava just before the latter empties into the heart (Figure 9-10).

### **Inferior Vena Cava**

The inferior vena cava, which is much longer than the superior vena cava, returns the blood from the parts of the body below the diaphragm. It begins in the lower abdomen with the union of the two common iliac veins. It then ascends along the back wall of the abdomen, through a groove in the posterior part of the liver, through the diaphragm, and finally through the lower thorax to empty into the right atrium of the heart.



**Figure 9-10. Principal veins** (Source: Carola, R., Harley, J.P., Noback R.C., (1992), Human anatomy and physiology, Mc Graw hill inc, New York, 2<sup>nd</sup> ed.)

Drainage into the inferior vena cava is more complicated than drainage into the superior vena cava. The large veins below the diaphragm may be divided into two groups:

1. The right and left veins that drain paired parts and organs. They include the iliac veins from near the groin, four pairs of lumbar veins from the dorsal part of the trunk and from the spinal cord, the testicular veins from the testes of the male and the ovarian veins from the ovaries of the female, the renal and suprarenal veins from the kidneys and adrenal glands near the kidneys, and finally the large hepatic veins from the liver. For the most part, these vessels empty directly into the inferior vena cava. The left testicular in the male and the left ovarian in the female empty into the left renal vein, which then take this blood to the inferior vena cava; these veins thus constitute exceptions to the rule that the paired veins empty directly into vena cava.
2. Unpaired veins that come from the spleen and from parts of the digestive tract (stomach and intestine) and empty into a vein called the portal vein. Unlike other veins, which empty into the inferior vena cava, the hepatic portal vein is part of a special system that enables blood to circulate through the liver before returning to the heart.

### **Circulatory Routes or Circuits**

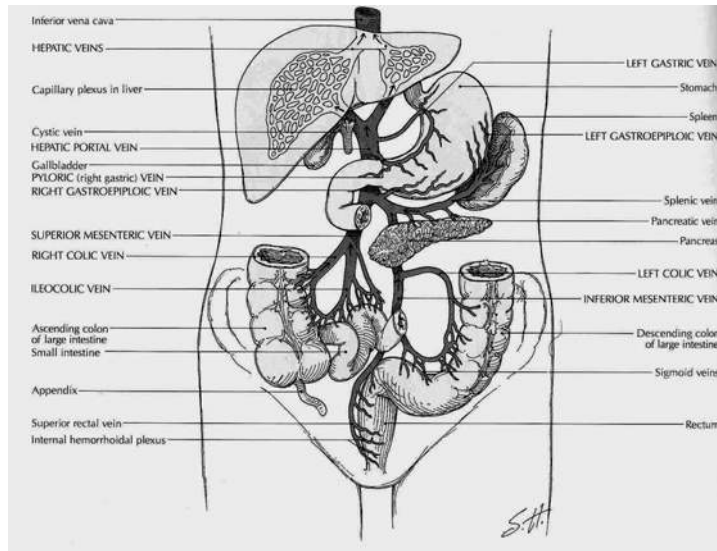
All the vessels together may be subdivided into two groups or circuits: pulmonary and systemic.

1. Pulmonary circulation: carry blood to and from the lungs. They include the pulmonary artery and its branches to the capillaries in the lungs, as well as the veins that drain those capillaries. The pulmonary arteries carry blood low in oxygen from the right ventricle, while the pulmonary veins carry blood high in oxygen from the lungs into the left atrium. This circuit functions to eliminate carbon dioxide from the blood and replenish its supply of oxygen.
2. Systemic circulation: it is the largest circulatory route. It takes oxygenated blood from the left ventricle through the aorta to all parts of the body, including some lung tissue (not air sac or alveolus) and returns the deoxygenated blood to the right atrium, through the systemic veins; the superior vena cava, the inferior vena cava, and the coronary sinus. It has several subdivisions. Two of the several subdivisions are the coronary circulation and the hepatic portal system or circulation.

### **Hepatic Portal System**

Almost always, when blood leaves a capillary bed it returns directly to the heart. In a portal system, however, blood circulates through a second capillary bed, usually in a second organ, before returning to the heart. Thus, a portal system is a kind of detour in the pathway of venous return that can transport materials directly from one organ to another. The portal system between the hypothalamus and the anterior pituitary has already been described. The largest portal system in the body is the hepatic portal system, which carries blood from the abdominal organs to the liver.

The hepatic portal system includes the veins drains blood from capillaries in the spleen, stomach, pancreas, and intestine. Instead of emptying their blood directly into the inferior



**Figure 9-11. Hepatic portal circulation** (Source: Carola, R., Harley, J.P., Noback R.C., (1992), Human anatomy and physiology, Mc Graw hill inc, New York, 2<sup>nd</sup> ed.)

vena cava, they deliver it by way of the hepatic portal vein to the liver. The largest tributary of the portal vein is the superior mesenteric vein it is joined by the splenic vein just under the liver. Other tributaries of the portal circulation are the gastric, pancreatic, and inferior mesenteric veins.

Upon entering the liver, the portal vein divides and subdivides into ever smaller branches. Eventually, the portal blood flows into a vast network of sinuslike vessels called sinusoids. These are enlarged capillaries that serve as blood channels within the



tissues of the liver, spleen, thyroid gland, and other structures. After leaving the sinusoids, blood is finally collected by the hepatic veins, which empty into the inferior vena cava (Figure 9-11).

The purpose of the portal system of veins is to the liver sinusoids so the liver cells can carry out their functions. For example, when food is digested, most of the end products are absorbed from the small intestine into the blood stream and transported to the liver by the portal system. In the liver, these nutrients are processed, stored, and released as needed into the general circulation.

### **Pulse and Blood Pressure**

#### **Pulse**

The ventricles pump blood into the arteries regularly about 70 to 80 times a minute. The force of the ventricular contraction starts a wave of increased pressure that begins at the heart and travels along the arteries. This wave, called the pulse, can be felt in any artery that is relatively close to the surface, particularly if the vessel can be pressed down against a bone. At the wrist the radial artery passes over the bone on the thumb side of the forearm, and the pulse is most commonly obtained here. Other vessels sometimes used for obtaining the pulse are the carotid artery in the neck and the dorsalis pedis on the top of the foot.

Normally, the pulse rate is the same as the heart rate. Only if a heart beat is abnormally weak, or if the artery is obstructed, may the beat not be detected as a pulse. In checking the pulse of another person, it is important to use your second or third finger. If you use your thumb, you may find that you are getting your own pulse. When taking a pulse, it is important to gauge the strength as well as the regularity and the rate.

Various factors may influence the pulse rate, we will enumerate just a few:

1. The pulse is somewhat faster in small persons than in large persons usually slightly faster in women than in men.
2. In a newborn infant the rate may be from 120 to 140 beats/minute. As the child grows, the rate tends to become slower.
3. Muscular activity influences the pulse rate. During sleep the pulse may slow down to 60 a minute, while during strenuous exercise the rate may go up to well over 100 a minute. In a person in good condition, the pulse does not remain rapid despite continued exercise.
4. Emotional disturbances may increase the pulse rate.
5. In many infections, the pulse rate increases with the increase in temperature.
6. An excessive amount of secretion from the thyroid gland may cause a rapid pulse. The pulse rate may serve as a partial guide for persons who must take thyroid extract.

### **Blood Pressure**

Since the pressure inside the blood vessels varies with the condition of the heart, the blood, and the vessels, as well as with other factors, the measurement and careful interpretation of blood pressure may prove a valuable guide in the care and evaluation of a person's health. Because blood pressure decreases as the blood flows from arteries into capillaries and finally into veins, measurements ordinarily are made of arterial pressure only. The instrument used is called a sphygmomanometer, and two variables are measured:

1. **Systolic pressure**, which occurs during heart muscle contraction, averages around 120 and is expressed in millimetres of mercury (mm Hg).
2. **Diastolic pressure**, which occurs during relaxation of the heart muscle, averages around 80 mm Hg.

### **The Lymphatic System**

The lymphatic system communicates with the blood circulatory system and is closely associated with it. It consists of:

1. **Lymphatic capillaries** made of endothelium (simple squamous epithelium)
2. **Lymphatic vessels** made of three layers like veins; also they have valves.
3. **Lymphatic ducts** are ducts that drains different parts of the body and includes:

- a. **Right lymphatic duct** drains upper right part of the body and empties in to right subclavian vein
  - b. **Thoracic duct** drains remainder part of the body and empties into left subclavian vein.
- 4. **Lymph** is the fluid within the lymphatic capillaries and vessels; which is derived from tissue fluid. Tissue fluid is derived from the blood plasma. A certain amount of this fluid and waste products from the cells is returned to the venous capillaries, but with in the tissue spaces fine capillary vessels known as lymphatic capillaries begin, which help to drain the waste products and water from the interstitial spaces. Also larger sized materials or substances of the result of phagocytosis of pathogenic micro-organisms are drained away in the lymphatic capillaries and vessels.
- 5. **Lymphoid tissues** are distributed through out the body. These are:
  - a. **Lymph nodes** help for filtration of lymph
  - b. **Tonsils** also help for filtration of tissue fluids
  - c. **Thymus** for processing of T-lymphocytes and hormone (thymosin) secretion to stimulate T-lymphoid tissues.
  - d. **Spleen** helps for filtration of blood, and destruction of old red cells.

## Review Questions

1. How does the color of blood vary with the amount of oxygenation?
2. Name the three main purposes of blood.
3. Name the two prime components of blood.
4. Name four main ingredients of blood plasma. What are their Purposes?
5. What is the main function of erythrocytes? Leukocytes? Platelets?
6. What are the names usually given to the four main blood groups? What determines the different groupings?
7. Describe the three basic steps involved in the clotting process.
8. What are the three layers of the heart wall?
9. What is a partition in the heart called? Name two.
10. Name the chambers of the heart and tell what each does.
11. Name the valves of the heart and explain the purpose of each valve.
12. Why the myocardium need its own blood supply? Name the arteries that supply blood to the heart.
13. Explain systole and diastole and tell how these phases are related to each other in the four chambers of the heart.
14. How does the heart's ability to contract differ from that of other muscles? What is required to maintain an effective rate of heart beat?

15. What are the parts of the conduction system of the heart's called and where are these structures located?
16. What two syllables are used to indicate normal heart sounds, and at what time in the heart cycle can they be heard?
17. Distinguish between tachycardia and bradycardia.
18. Define cardiac output. What determines cardiac output?
19. Name the three main groups of blood vessels and describe their functions. How has function affected structure/
20. What large vessels drain the blood low in oxygen from most of the body into the right atrium/ what vessels carry blood high in oxygen into the left atrium?
21. What is meant by pulse? Where the pulse is usually determined?
22. What are some factors that cause an increase in the pulse rate?
23. What instrument is used for obtaining blood pressure? What are the two values usually obtained called, and what is the significance of each?

# CHAPTER TEN

## RESPIRATORY SYSTEM

### Chapter Objectives

*At the end of the chapter, the student should be able to:*

- Describe the purpose of the respiratory system
- Differentiate between external and internal respiration
- Name all of the structures of the respiratory system
- Explain how food and foreign materials are kept out of the respiratory tract
- Explain the mechanism for the pulmonary ventilation
- List and define five breathing volumes
- Describe in which respiration is regulated

### Selected Key Terms

**The following key terms are defined in the Glossary:**

Alveolus	Hilus	Pleura
Bronchiole	Hypoxia	Respiration
Bronchus	Larynx	Surfactant
Chemoreceptor	Lung	Trachea
Diaphragm	Mediastinum	Ventilation
Epiglottis	Pharynx	

### **General Function**

A primary requirement for all body cell activities and growth is oxygen, which is needed to obtain energy from food. The fundamental purpose of the respiratory system is to supply oxygen to the individual tissue cells and to remove their gaseous waste product, carbon dioxide. Breathing, or ventilation, refers to the inhalation and exhalation of air. Air is a mixture of oxygen, nitrogen, carbon dioxide and other gases; the pressure of these gases varies, depending on the elevation above sea level. The first, called external expiration, takes place only in the lungs, where oxygen from the outside air enters the blood and carbon dioxide leaves the blood to be breathed into the outside air (Figure 10-1). In the second, called internal respiration, gas exchanges take place between the blood and the body cells, with oxygen leaving the blood and entering the cells at the same time that carbon dioxide leaves the cells and enters the blood.

The respiratory system is an intricate arrangement of spaces and passageways that conduct air into the lungs. These spaces include the nasal cavities; the pharynx, which is common to the digestive and respiratory systems; the voice box, or larynx; the windpipe, or trachea; and the lungs themselves, with their conducting tubes and air sacs. The entire system might be thought of as a pathway for air between the atmosphere and the blood (Figure 10-2).



## Structure and Function of Respiratory Pathways

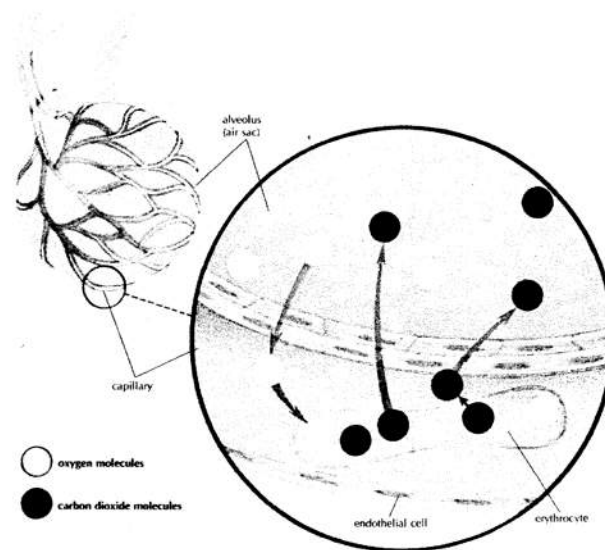
### The Nasal Cavities

Air makes its initial entrance into the body through the openings in the nose called the nostrils. Immediately inside the nostrils, located between the roof of the mouth and the cranium, are the two spaces known as the nasal cavities. These two spaces are separated from each other by a partition, the nasal septum. The septum and the walls of the nasal cavities are constructed of bone covered with mucous membrane. From the lateral (side) walls of each nasal cavity are three projections called the conchae. The conchae greatly increase the surface over which air must travel on its way through the nasal cavities.

The lining of the nasal cavities is a mucous membrane, which contains many blood vessels that bring heat and moisture to it. The cells of this membrane secrete a large amount of fluid. It is better to breathe through the nose than through the mouth because of changes produced in the air as it comes in contact with the lining of the nose:

1. Foreign bodies, such as dust particles and pathogens, are filtered out by the hairs of the nostrils or caught in the surface mucus.
2. Air is warmed by the blood in the vascular membrane.
3. Air is moistened by the liquid secretion

The sinuses are small cavities lined with mucous membrane in the bones of the skull. The sinuses communicate with the nasal cavities, and they are highly susceptible to infection.



**Figure 10-1. Diagram of external respiration showing the diffusion of gas molecules through the cell membranes and throughout the capillary blood and air in the alveolus.** (From Memmler and Wood: *The Human Body in Health and Disease*, ed 6, Philadelphia, 1987, J. B. Lippincott co.)

### The Pharynx

The muscular pharynx (throat) carries air into the respiratory tract and foods and liquids into the digestive system. The upper portion located immediately behind the nasal cavity is called the nasopharynx, the middle section located behind the mouth is called the oropharynx, and the lowest portion is

called the laryngeal pharynx. This last section opens into the larynx toward the front and into the oesophagus toward the back.

### **The Larynx**

The larynx (voice box) is located between the pharynx and the trachea. It has a framework of cartilage that protrudes in the front of the neck and some times is referred to as the Adam's apple. The larynx is considerably larger in the male than in the female; hence, the Adam's apple is much more prominent in the male. At the upper end of the larynx are the vocal cords, which serve in the production of speech. They are set into vibration by the flow of air from the lungs. A difference in the size of the larynx is what accounts for the difference between the male and female voices; because a man's larynx is larger than a woman's, his voice is lower in pitch. The nasal cavities, the sinuses, and the pharynx all serve as resonating chambers for speech, just as the cabinet does for a stereo speaker.

The space between these two vocal cords is called the glottis, and the little leaf-shaped cartilage that covers the larynx during swallowing is called the epiglottis. The epiglottis helps keep food out of the remainder of the respiratory tract. As the larynx moves upward and forward during swallowing, the epiglottis moves downward, covering the opening into the

larynx. You can feel the larynx move upward toward the epiglottis during this process by placing the flat ends of your fingers on your larynx as you swallow.

The larynx is lined with ciliated mucous membrane. The cilia trap dust and other particles, moving them upward to the pharynx to be expelled by coughing, sneezing, or blowing the nose.

### **The Trachea (Windpipe)**

The trachea is a tube that extends from the lower edge of the larynx to the upper part of the chest above the heart. It has a framework of cartilages to keep it open. These cartilages, shaped somewhat like a tiny horseshoe or the letter C, are found along the entire length of the trachea. All the open sections of these cartilages are at the back so that the esophagus can bulge into this section during swallowing. The purpose of the trachea is to conduct air between the larynx and the lungs.

### **The Bronchi and Bronchioles**

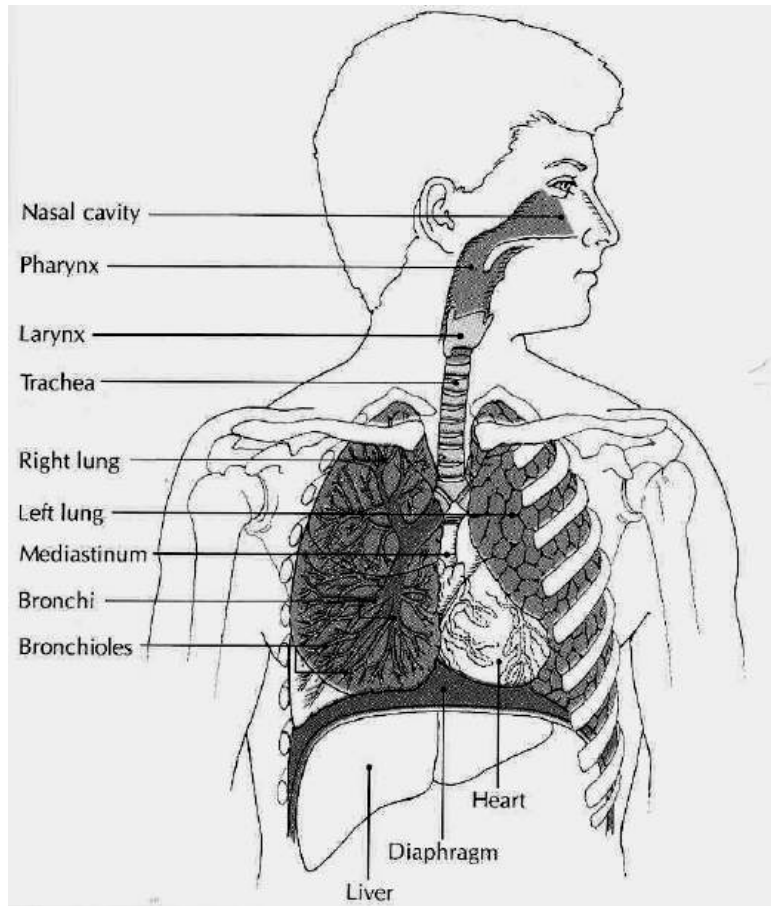
The trachea divides into two bronchi which enter the lungs. The right bronchus is considerably larger in diameter than the left and extends downward in a more vertical direction. Therefore, if a foreign body is inhaled, it is likely to enter the right lung. Each bronchus enters the lung at a notch or

depression called the hilus or hilum. The blood vessels and nerves also connect with the lung in this region.

### **The Lungs**

The lungs are the organs in which external respiration takes place through the extremely thin and delicate lung tissues. The two lungs, set side by side in the thoracic cavity, are constructed in the following manner:

Each bronchus enters the lung at the hilus and immediately subdivides. Because the subdivision of the bronchi resembles the branches of a tree, they have been given the common name bronchial tree. The bronchi subdivide again and again, forming progressively smaller divisions, the smallest of which are called bronchioles. The bronchi contain small bits of cartilage, which give firmness to the walls and serve to hold



**Figure 10-2. Respiratory system.** (Source: Carola, R., Harley, J.P., Noback R.C., (1992), Human anatomy and physiology, Mc Graw hill inc, New York, 2<sup>nd</sup> ed.)

the passageways open so that air can pass in and out easily. However, as the bronchi become smaller, the cartilage decreases in amount. In the bronchioles there is no cartilage at all; what remains is mostly smooth muscle, which is under the control of the autonomic nervous system.

At the end of each of the smallest subdivisions of the bronchial tree, called terminal bronchioles, is a cluster of air sacs, resembling a bunch of grapes. These sacs are known as alveoli. Each alveolus is a single-cell layer of squamous (flat) epithelium. This very thin wall provides easy passage for the gases entering and leaving the blood as it circulates through millions of tiny capillaries of the alveoli. Certain cells in the alveolar wall produce surfactant, a substance that prevents the alveoli from collapsing by reducing the surface tension ("pull") of the fluids that line them. There are millions of alveoli in the human lung. Because of the many air spaces, the lung is light in weight; normally a piece of lung tissue dropped into a glass of water will float.

As mentioned the pulmonary circuit brings blood to and from the lungs. In the lungs blood passes through the capillaries around the alveoli, where the gas exchange takes place.

### **The Lung Cavities**

The lungs occupy a considerable portion of the thorax cavity, which is separated from the abdominal cavity by the muscular partition known as the diaphragm. Each lung is enveloped in a double sac of serous membrane called the pleura. The portion of the pleura that is attached to the chest wall is called parietal pleura, while the portion that is reflected onto the surface of the lung is called visceral pleura.

The pleural cavity around the lungs is an air-tight space with a partial vacuum, which causes the pressure in this space to be less than atmospheric pressure. Because the pressure inside the lungs is higher than that in the surrounding pleural cavity, the lungs tend to remain inflated. The entire thoracic cavity is flexible, capable of expanding and contracting along with the lungs. The region between the lungs, the mediastinum, contains the heart, great blood vessels, esophagus, trachea, and lymph nodes.

### **Physiology of Respiration**

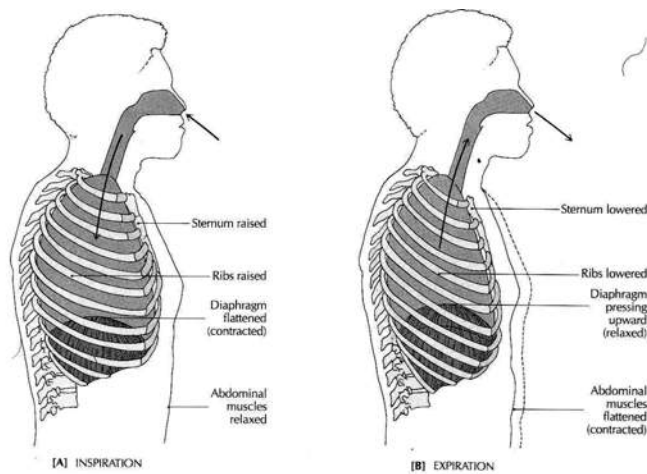
#### **Pulmonary Ventilation**

Ventilation is the movement of air into and out of the lungs, as in breathing. There are two phases of ventilation (Figure10-3):

1. **Inhalation** is the drawing of air into the lungs.
2. **Exhalation** is the expulsion of air from the lungs.



In **inhalation**, the active phase of breathing, the respiratory muscles contract to enlarge the thoracic cavity. The diaphragm is a strong dome-shaped muscle attached around the base of the rib cage. The contraction and relaxation of the diaphragm cause a piston-like downward motion that result in an increase in the vertical dimension of the chest. The rib cage is also moved upward and outward by contraction of the external intercostals muscles and, during exertion, by contraction of other muscles of the neck and chest. During quiet breathing, the movement of the diaphragm accounts for most of the increase in thoracic volume.



**Figure 10-3. (A) Inhalation. (B) Exhalation** (Source: Carola, R., Harley, J.P., Noback R.C., (1992), Human anatomy and physiology, Mc Graw hill inc, New York, 2<sup>nd</sup> ed.)

As the thoracic cavity increases in size, gas pressure within the cavity decreases. When the pressure drops to slightly below atmospheric pressure, air is drawn into the lungs.

In exhalation, the passive phase of breathing, the muscles of respiration relax, allowing the ribs and diaphragm to return to their original positions. The tissues of the lung are elastic and recoil during exhalation. During forced exhalation, the internal intercostals muscles and the muscles of the abdominal wall contracts, pulling the bottom of the rib cage in and down. The abdominal viscera are also pushed upward against the diaphragm.

### **Air Movement**

Air enters the respiratory passages and flows through the ever-dividing tubes of the bronchial tree. As the air traverses this passage, it moves more and more slowly through the great number of bronchial tubes until there is virtually no forward flow as it reaches the alveoli. Here the air moves by diffusion, which soon equalizes any differences in the amounts of gases present. Each breath causes relatively little change in the gas composition of the alveoli, but normal continuous breathing ensures the presence of adequate oxygen and the removal of carbon dioxide.

Table 10-1 gives the definition of and average values for some of the breathing volumes that are important in any evaluation of respiratory function.

**Table 17-1 Breathing Volumes**

<b>Volume</b>	<b>Definition</b>	<b>Average value</b>
Tidal volume	The amount of air moved into or out of the lungs in quiet, relaxed breathing	500 cc
Vital capacity	The volume of air that can be expelled from the lungs by maximum exhalation following maximum inhalation	4800 cc
Residual volume	The volume of air that remains in the lungs after maximum exhalation	1200 cc
Total lung capacity	The total volume of air that can be contained in the lungs after maximum inhalation	6000 cc
Functional residual capacity	The amount of air remaining in the lungs after normal exhalation	2400 cc

### **Regulation of respiration**

Regulation of respiration is a complex process that must keep pace with moment-to-moment changes in cellular oxygen requirements and carbon dioxide production. Regulation

depends primarily on the respiratory control centers located in the medulla and pons of the brain stem. Nerve impulses from the medulla are modified by the centers in the pons. Respiration is regulated so that the levels of oxygen, carbon dioxide, and acid are kept within certain limits. The control centers regulate the rate, depth, and rhythm of respiration.

From the respiratory center in the medulla, motor nerve fibers extend into the spinal cord. From the cervical (neck) part of the cord, these nerve fibers continue through the phrenic nerve to the diaphragm. The diaphragm and the other muscles of respiration are voluntary in the sense that they can be regulated by messages from the higher brain centers, notably the cortex. It is possible for a person to deliberately breathe more rapidly or more slowly or to hold his breath and not breathe at all for a time. Usually we breathe without thinking about it, while the respiratory centers in the medulla and pons do the controlling.

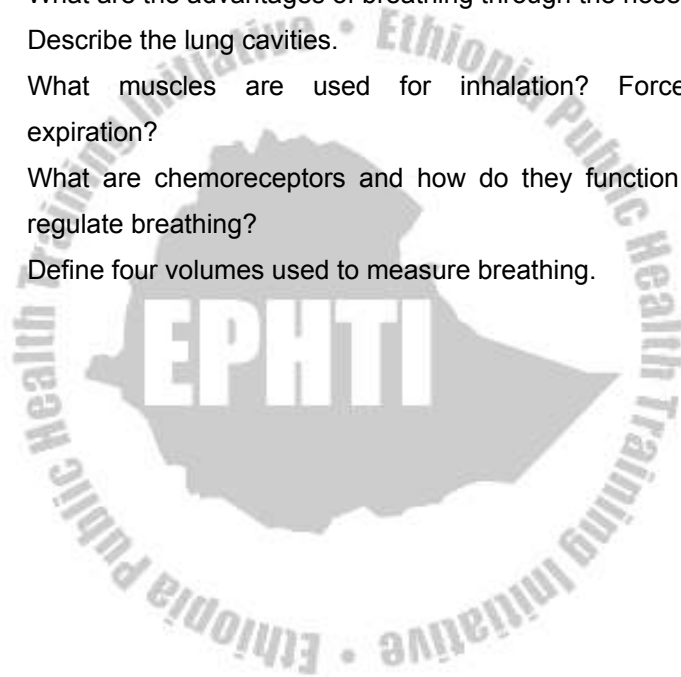
Of vital importance in the control of respiration are the chemoreceptors. These receptors are found in structures called the carotid and aortic bodies, as well as outside the medulla of the brain stem. The carotid bodies are located near the bifurcation of the common carotid arteries, while the aortic bodies are located in the aortic arch. These bodies contain many small blood vessels and sensory neurons, which are

sensitive to decreases in oxygen supply as well as to increases in carbon dioxide and acidity ( $H^+$ ). Impulses are sent to the brain from the receptors in the carotid and aortic bodies. The receptor cells outside the medulla are affected by the concentration of hydrogen ion in cerebrospinal fluid (CSF) as determined by the concentrations of carbon dioxide in the blood.



## Review Questions

1. What is the purpose of respiration and what are its two components?
2. Trace the pathway of air from the outside into the blood.
3. What are the advantages of breathing through the nose?
4. Describe the lung cavities.
5. What muscles are used for inhalation? Forceful expiration?
6. What are chemoreceptors and how do they function to regulate breathing?
7. Define four volumes used to measure breathing.



# CHAPTER ELEVEN

## DIGESTIVE SYSTEM

### Chapter Objectives

At the end of the chapter, the student should be able to:

- Name the two main functions of the digestive system
- Describe the four layers of the digestive tract wall
- Describe the peritoneum
- Name and describe the organs of the digestive tract
- Name and describe the accessory organs of digestion and biliary apparatus
- List the functions of each organ involved in digestion
- Explain the role of enzymes in digestion and give examples of enzymes
- Name the end products of fats, proteins, and carbohydrates digestion
- Define absorption
- Define villi and state how villi function in absorption
- Describe how bile functions in digestion
- List the main functions of the liver
- Explain the use of feedback in regulating digestion and give several examples

### Selected Key Terms

The following key terms are defined in the Glossary:

Absorption	Chyle	Peritoneum
Enzyme	Hydrolysis	Digestion
Accessory organ	Colon	Saliva
Bile	Mastication	Duodenum
Esophagus	Defecation	Sphincter
Chyme	Peristalsis	Emulsify
Lacteal	Deglutition	Villi

### General Function

Every body cell needs a constant supply of nutrients to provide energy and building blocks for the manufacture of body substances. Food as we take it in, however, is too large to enter the cells. It must first be broken down into particles small enough to pass through the cell membrane. This process is known as **digestion**. After digestion, food must be carried to the cells in every part of the body by the circulation. The transfer of food into the circulation is called **absorption**. Digestion and absorption are the two chief functions of the digestive system.



## **Structure and Function of Organs of Digestion and Accessory Organs**

For our purpose the digestive system may be divided into two groups of organs:

1. The **digestive tract**, a continuous passageway beginning at the mouth, where food is taken in, and terminating at the anus, where the solid waste products of digestion are expelled from the body
2. The accessory organ, which are necessary for the digestive process but are not a direct part of the digestive tract. They release substances into the digestive tract through ducts.

### **The Walls of the Digestive Tract**

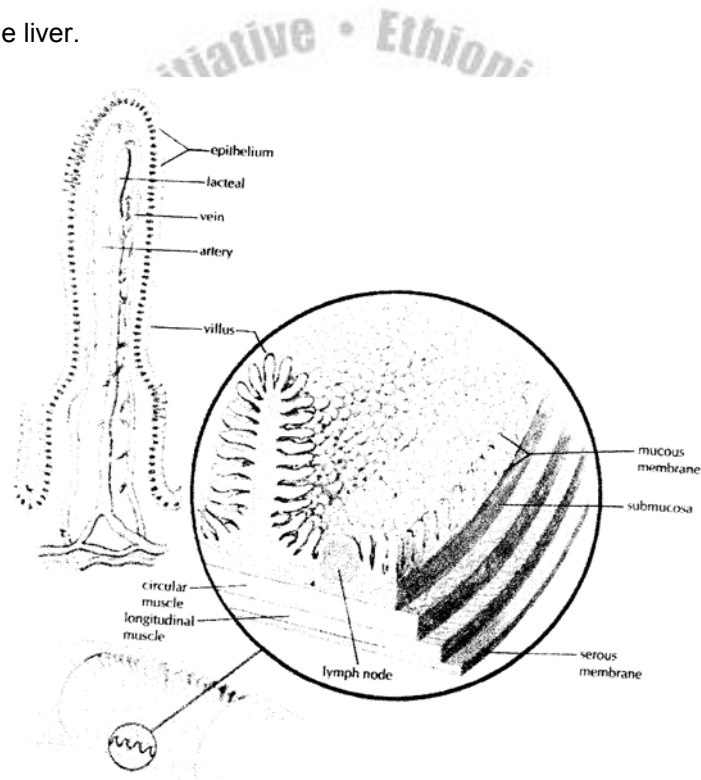
Although specified for specific tasks in different organs, the wall of the digestive tract, from the esophagus to the anus, is similar in structure throughout. Follow the diagram of the small intestine in Figure 11-1 as we describe the layers of this wall from the innermost to the outermost surface. First is the **mucous membrane**, so called because its epithelial layer contains many mucus-secreting cells. The type of epithelium is simple columnar. The layer of connective tissue beneath this, the **submucosa**, contains blood vessels and some of the nerves that help regulate digestive activity. Next are two layers of **smooth muscle**. The inner layer has circular fibers,

and the outer layer has longitudinal fibers. The alternate contractions of these muscles create the wavelike movement that propels food through the digestive tract and mixes it with digestive juices. This movement is called **peristalsis**. The outermost layer of the wall consists of fibrous connective tissue. Most of the abdominal organs have an additional layer of **serous membrane** that is part of the peritoneum.

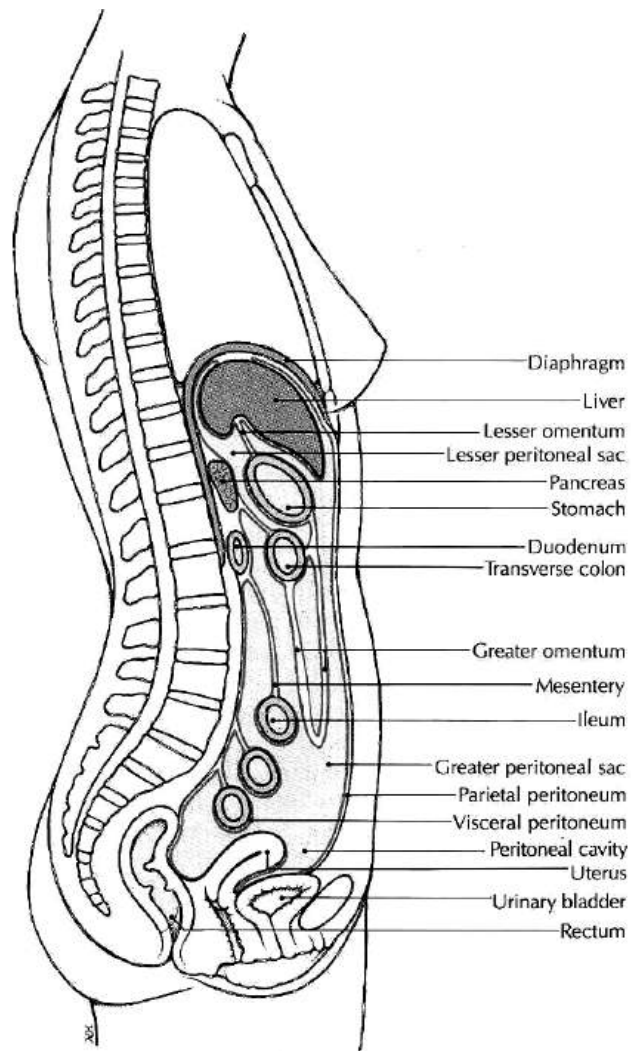
### **The Peritoneum**

The abdominal cavity is lined with a thin, shiny serous membrane that also covers most of the abdominal organs (Figure 11-2). The portion of this membrane that lines the abdomen is called the **parietal peritoneum**; that covering the organ is called the **visceral peritoneum**. In addition to these single layered portions of the peritoneum there are a number of double-layered structures that carry blood vessels, lymph vessels, and nerves, and sometimes act as ligaments supporting the organs. The **mesentery** is a double-layered portion of the peritoneum shaped somewhat like a fan. The handle portion is attached to the back wall, and the expanded long edge is attached to the small intestine. Between the two layers of membrane that form the mesentery are the blood vessels, lymphatic vessels, and nerves that supply the intestine. The section of the peritoneum that extends from the colon to the back wall is the mesocolon.

A large double layer of the peritoneum containing much fat hangs like an apron over the front of the intestine. This greater omentum extends from the lower border of the stomach into the pelvic part of the abdomen and then loops back up to the transverse colon. There is also a smaller membrane, called the lesser omentum that extends between the stomach and the liver.



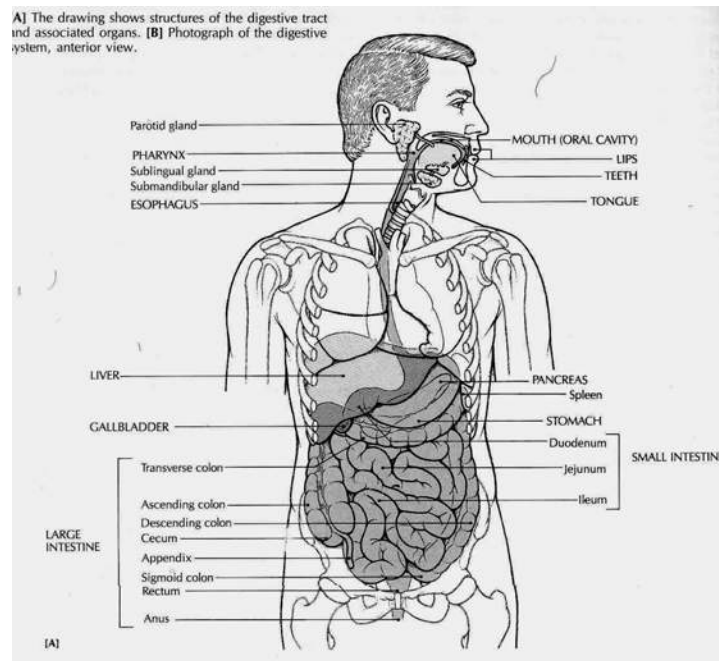
**Figure 11-1. Diagram of the wall of the small intestine showing the numerous villi.** (From Memmler, Ruth Lundeen et al: The human body in Health and disease,ed. 8, New York, 1996,Lippincott.)



**Figure 11-2. Diagram of the abdominal cavity showing the peritoneum**  
(Source: Carola, R., Harley, J.P., Noback R.C., (1992), Human anatomy and physiology, Mc Graw hill inc, New York, 2<sup>nd</sup> ed.)

## The Digestive Tract

The digestive tract, (Figure 11-3), is a muscular tube extending through the body. It is composed of several parts: the mouth, pharynx, esophagus, stomach, small intestine, and large intestine. The digestive tract is sometimes called the alimentary tract, derived from a Latin word that means "food". It is more commonly referred to as the gastrointestinal (GI) tract because of the major importance of the stomach and intestine in the process of digestion.



**Figure 11-3. Digestive system** (Source: Carola, R., Harley, J.P., Noback R.C., (1992), Human anatomy and physiology, Mc Graw hill inc, New York, 2<sup>nd</sup> ed.)

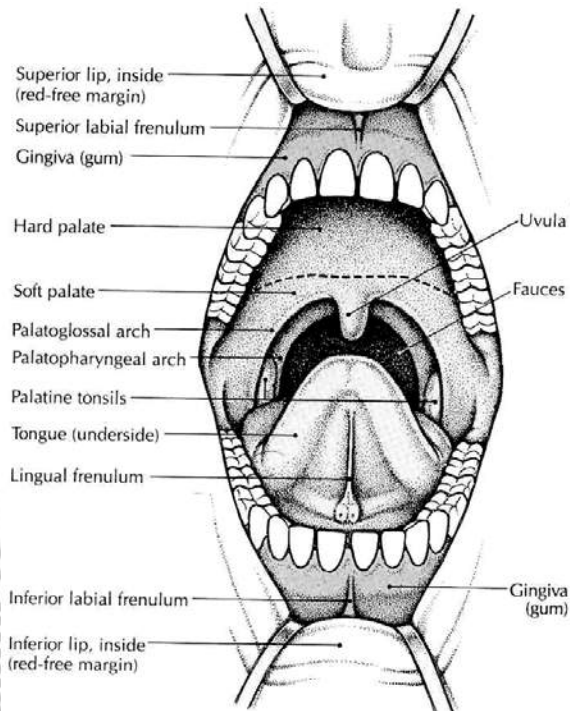
### **The Mouth**

The mouth, also called the **oral cavity**, is where a substance begins its travels through the digestive tract (Figure 11-4). The mouth has three digestive functions:

1. To receive food, a process called **ingestion**
2. To prepare food for digestion
3. To begin the digestion of starch.

In to this space projects a muscular organ, the tongue, which is used for chewing and swallowing, and is one of the principal organs of speech. The tongue has on its surface a number of special organs, called **taste buds**, by means of which taste sensations (bitter, sweet, sour, or salty) can be differentiated.

The oral cavity also contains the teeth. A child between 2 and 6 years of age has 20 teeth; an adult with a complete set of teeth has 32. Among these, the cutting teeth, or incisors, occupy the front part of the oral cavity, whereas the larger grinding teeth, the molars, are in the back.



**Figure 11-4. The mouth, showing the teeth and tonsils** (Source: Carola, R., Harley, J.P., Noback R.C., (1992), Human anatomy and physiology, Mc Graw hill inc, New York, 2<sup>nd</sup> ed.)

### **Deciduous, or Baby Teeth**

The first eight deciduous teeth to appear through the gums are the incisors. Later the canines (eye teeth) and molar appear. Usually, the 20 baby teeth have all appeared by the time a child has reached the age of 2 or 2<sup>1/2</sup> years. During the first 2 years the permanent teeth develop within the jawbones

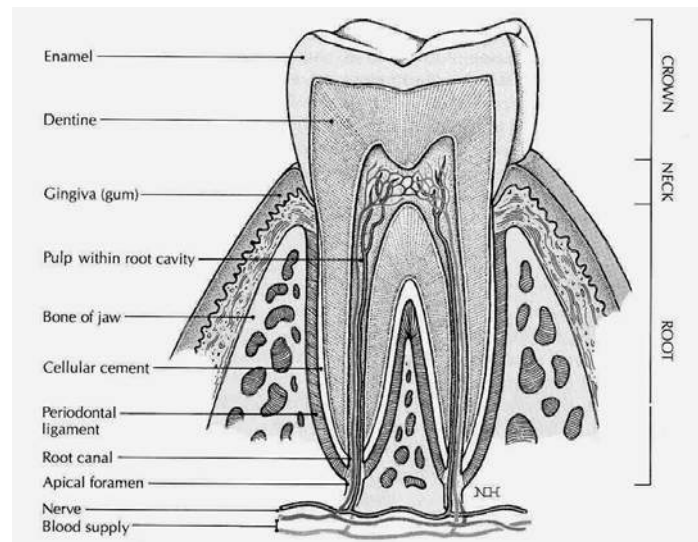
from buds that are present at birth. The first permanent tooth to appear is the important 6-year molar. This permanent tooth comes in before the baby incisors are lost. Because decay and infection of adjacent deciduous molars may spread to and involve new, permanent teeth, deciduous teeth need proper care.

### **Permanent Teeth**

As a child grows, the jawbones grow, making space for additional teeth. After the 6-year molars have appeared, the baby incisors loosen and are replaced by permanent incisors. Next, the baby canines (cuspids) are replaced by permanent canines, and finally, the baby molars are replaced by the bicuspid (premolars) of the permanent teeth.

Now the larger jawbones are ready for the appearance of the 12-year, or second, permanent molar teeth. During or after the late teens, the third molars, or so-called wisdom teeth, may appear. In some cases the jaw is not large enough for these teeth or there are other abnormalities, so that the third molars may have to be removed. Figure 11-5 shows the parts of the molar.





**Figure 11-5. A molar tooth** (Source: Carola, R., Harley, J.P., Noback R.C., (1992), Human anatomy and physiology, Mc Graw hill inc, New York, 2<sup>nd</sup> ed.)

### The Salivary Glands

While food in the mouth, it is mixed with **saliva**, one purpose of which is to moisten the food and facilitate the processes of chewing, or **mastication**, and swallowing, or **deglutition**. Saliva also helps keep the teeth and mouth clean and reduce bacterial growth.

This watery mixture contains mucus and an enzyme called salivary amylase, which begins the digestive process by converting starch to sugar. It is manufactured mainly by three pairs of glands that function as accessory organs:

1. The parotid glands, the largest of the group, are located below and in front of the ear.
2. The submandibular, or submaxillary, glands are located near the body of the lower jaw
3. The sublingual glands are under the tongue.

All these glands empty by means of ducts into the oral cavity.

### **The Pharynx and Esophagus**

The pharynx is commonly referred to as the throat. The oral part of the pharynx is visible when you look into an open mouth and depress the tongue. The palatine tonsils may be seen at either side. The pharynx also extends upward to the nasal cavity and downward to the level of the larynx. The soft palate is tissue that forms the back of the roof of the oral cavity. From it hangs a soft, fleshy, V-shaped mass called the uvula.

In swallowing, a small portion of chewed food mixed with saliva, called a bolus, is pushed by the tongue into the pharynx, swallowing occurs rapidly by an involuntary reflex action. At the same time, the soft palate and uvula are raised to prevent food and liquid from entering the nasal cavity, and the tongue is raised to seal the back of the oral cavity. The entrance of the trachea is guarded during swallowing by a leaf-shaped cartilage, the epiglottis, which covers the opening of the larynx. The swallowed food is then moved by peristalsis

into esophagus, a muscular tube about 25cm (10 inches) long that carries food into the stomach. No additional digestion occurs in the esophagus.

Before joining the stomach, the esophagus must pass through the diaphragm. It passes through a space in the diaphragm called the esophageal hiatus. If there is a weakness in the diaphragm at this point, a portion of the stomach or other abdominal organ may protrude through the space, a condition called hiatal hernia.

### **The Stomach**

The stomach is an expanded J-shaped organ in the upper left region of the abdominal cavity (Figure 11-6). In addition to the two muscle layers already described, it has a third, inner oblique (angled) layer that aids in grinding food and mixing it with digestive juices. The left-facing arch of the stomach is the **greater curvature**, whereas the right surface forms the **lesser curvature**. Each end of the stomach is guarded by a muscular ring, or **sphincter**, that permits the passage of substances in only one direction.

Between the esophagus and the stomach is the **lower esophageal sphincter (LES)**. This valve has also been called **cardiac sphincter** because it separates the esophagus from the region of the stomach that is close to the heart. We

are sometimes aware of the existence of this sphincter; sometimes it does not relax as it should, produce a feeling of being unable to swallow past that point. Between the distal, or far, end of the stomach and the small intestine is the **pyloric sphincter**. The region of the stomach leading into this sphincter, the pylorus, is important in regulating how rapidly food moves into the small intestine.

The stomach serves as a storage pouch, digestive organ, and churn. When the stomach is empty, the lining forms many folds called **rugae**. These folds disappear as the stomach expands. (It may be stretched to hold one half of a gallon of food and liquid.) Special cells in the lining of the stomach secrete substances that mix together to form gastric juice, the two main components of which are:

1. Hydrochloric acid (HCL), a strong acid that softens the connective tissue in meat and destroys foreign organisms
2. Pepsin, a protein-digesting enzyme. This enzyme is produced in an inactive form and is activated only when food enters the stomach and HCL is produced.

The semi-liquid mixture of gastric juice and food that leaves the stomach to enter the small intestine is called **chyme**.

### The Small Intestine

The small intestine is the longest part of the digestive tract. It is known as the small intestine because, although it is longer than the large intestine, it is smaller in diameter, with an average width of about 2.5 cm (1 inch). When relaxed to its full length, the small intestine is about 6 m (20 feet) long. The first 25 cm (10 inches) or so of the small intestine make up the **duodenum**. Beyond the duodenum are two more divisions: the **jejunum**, which forms the next two fifths of the small intestine, and the **ileum**, which constitutes the remaining portion.

The wall of the duodenum contains glands that secrete large amounts of mucus to protect the small intestine from the strongly acid chyme entering from the stomach. Cells of the small intestine also secrete enzymes that digest proteins and carbohydrates. In addition, digestive juices from the liver and pancreas enter the small intestine through a small opening in the duodenum. Most of the digestive process takes place in the small intestine under the effects of these juices.

Most absorption of digested food also occurs through the walls of the small intestine. To increase the surface area of the organ for this purpose, the mucosa is formed into millions of tiny, finger-like projections, called villi (see Figure 11-1), which give the inner surface a velvety appearance. In

addition, each epithelial cell has small projecting folds of the cell membrane known as microvilli. These create a remarkable increase in the total surface area available in the small intestine for the absorption of nutrients.

### **The Large Intestine**

Any material that cannot be digested as it passes through the digestive tract must be eliminated from the body. In addition, most of the water secreted into the digestive tract for proper digestion must be reabsorbed into the body to prevent dehydration. The storage and elimination of undigested waste and the reabsorption of water are the functions of the large intestine.

The large intestine is about 6.5 cm (2.5 inches) in diameter and about 1.5 m (5 feet) long. The outer longitudinal muscle fibers form three separate bands on the surface. These bands draw up the wall of the organ to give it its distinctive puckered appearance.

The large intestine begins in the lower right region of the abdomen. The first part is a small pouch called the **cecum**. Between the ileum of the small intestine and the cecum is a sphincter, the **ileocecal valve** that prevents food from traveling backward into the small intestine. Attached to the cecum is a small, blind tube containing lymphoid tissue; it is

called the vermiform appendix (vermiform means "wormlike"). Inflammation of this tissue as a result of infection or obstruction is **appendicitis**.

The second portion, the **ascending colon**, extends upward along the right side of the abdomen toward the liver. The large intestine then bends across the abdomen, forming the **transverse colon**. At this point it bends sharply and extends downward on the left side of the abdomen into the pelvis, forming the **descending colon**. The lower part of the colon bends posteriorly in an S shape and continues downward as the **sigmoid colon**. The sigmoid colon empties into the **rectum**, which serves as a temporary storage area for indigestible or unabsorbable food residue (see Figure 11-3). Enlargement of the veins in this area constitutes **haemorrhoids**. A narrow portion of the distal large intestine is called the **anal canal**. This leads to the outside of the body through an opening called the **anus**.

Large quantities of mucus, but no enzymes, are secreted by the large intestine. At intervals, usually after meals, the involuntary muscles within the walls of the large intestine propel solid waste material, called **feces** or stool, toward the rectum. This material is then eliminated from the body by both voluntary and involuntary muscle actions, a process called **defecation**.

While the food residue is stored in the large intestine, bacteria that normally live in the colon act on it to produce vitamin K and some of the B-complex vitamins. As mentioned systemic antibiotic therapy may destroy these bacteria and others living in the large intestine, causing undesirable side effects.

### **The Accessory Structures**

#### **The Liver**

The liver, often referred to by the word root *hepat*, is the largest glandular organ of the body (Figure 11-7). It is located in the upper right portion of the abdominal cavity under the dome of the diaphragm. The lower edge of a normal-sized liver is level with the lower margin of the ribs. The human liver is the same reddish brown color as the animal liver seen in the supermarket. It has a large right lobe and a smaller left lobe; the right lobe includes two inferior smaller lobes. The liver is supplied with blood through two vessels: the portal vein and the hepatic artery. These vessels deliver about 1½ quarts of blood to the liver every minute. The hepatic artery carries oxygenated blood, whereas the portal system of veins carries blood that is rich in the end products of digestion. This most remarkable organ has so many functions that only some of its major activities can list here:

1. The storage of glucose (simple sugar) in the form of glycogen, in animal starch. When the blood sugar level



falls below normal, liver cells convert glycogen to glucose and release it into the bloodstream; this serves to restore the normal concentration of blood sugar.

2. The formation of blood plasma proteins, such as albumin, globulins, and clotting factors
3. The synthesis of urea, a waste product of protein metabolism. Urea is released into the blood and transported to the kidneys for elimination.
4. The modification of fats, so cells all over the body can use them more efficiently
5. The manufacture of bile
6. The destruction of old red blood cells. The pigment released from these cells in both the liver and the spleen is eliminated in the bile. This pigment (bilirubin) gives the stool its characteristic dark color.
7. The detoxification (removal of the poisonous properties) of harmful substances such as alcohol and certain drugs
8. The storage of some vitamins and iron

The main digestive function of the liver is the production of bile. The salts contained in bile act like a detergent to emulsify fat, that is, to break up fat into small droplets that can be acted on more effectively by digestive enzymes. Bile also aids in the absorption of fat from the small intestine. Bile leaves the lobes of the liver by two ducts that merge to form the common hepatic duct. After collecting bile from the gallbladder, this

duct, now called common bile duct, delivers bile into the duodenum.

### **The Gallbladder**

The gallbladder is a muscular sac on the inferior surface of the liver that serves as a storage pouch for bile. Although the liver may manufacture bile continuously, the body is likely to need it only a few times a day. Consequently, bile from the liver flows into the hepatic ducts and then up through the cystic duct connected with the gallbladder. When chyme enters the duodenum, the gallbladder contracts, squeezing bile through the cystic duct and into the common bile duct leading to the duodenum.

### **The Pancreas**

The pancreas is a long gland that extends from the duodenum to the spleen. The pancreas produces enzymes that digest fats, proteins, carbohydrates, and nucleic acids. The protein digesting enzymes are produced in inactive forms, which must be converted to active forms in the small intestine by other enzymes. The pancreas also produces large amounts of alkaline fluid, which neutralizes the chyme in the small intestine, thus protecting the lining of the digestive tract. These juices collect in a main duct that joins the common bile duct or empties into the duodenum near the common bile

duct. Most persons also have an additional smaller duct that opens into the duodenum.

Because they are usually confined to proper channels, pancreatic enzymes do not damage body tissues. However, if the bile ducts become blocked, pancreatic enzymes back up into the pancreas. Also, in some cases of gallbladder disease, infection may extend to the pancreas and cause abnormal activation of the pancreatic enzymes. In either circumstance, the pancreas suffers destruction by its own juice, and the outcome can be fatal; this condition is known as acute pancreatitis.

The pancreas also functions as an endocrine gland, producing the hormones insulin and glucagons that regulate sugar metabolism. These secretions of the islets cells are released directly into the blood.

### **Digestion and Absorption of Carbohydrates, Fats, and Proteins**

#### **Digestion**

Digestion, a complex process that occurs in the alimentary canal, consists of physical and chemical changes that prepare food for absorption. **Mechanical digestion** breaks food into tiny particles, mixes them with digestive juices, moves them

along the alimentary canal, and finally eliminates the digestive wastes from the body. Chewing or mastication, swallowing or deglutition, peristalsis, and defecation are the main processes of mechanical digestion. **Chemical digestion** breaks down large, nonabsorbable food molecules—molecules that are able to pass through the intestinal mucosa into blood and lymph. Chemical digestion consists of numerous chemical reactions catalyzed by enzymes in saliva, gastric juice, pancreatic juice, and intestinal juice.

### **Carbohydrate Digestion**

Very little digestion of carbohydrates (starches and sugars) occurs before food reaches the small intestine. Salivary amylase usually has little time to do its work because so many of us swallow our food so fast. Gastric juice contains no carbohydrate-digesting enzymes. But after the food reaches the small intestine, pancreatic and intestinal juice enzymes digest the starches and sugars. A pancreatic enzyme (amylase) starts the process by changing starches into a double sugar, namely, maltose. Three intestinal enzymes—maltase, sucrase, and lactase—digest double sugars by changing them into simple sugars, chiefly glucose (dextrose). Maltase digests maltose (malt sugar), sucrase digests sucrose (ordinary cane sugar), and lactase digests lactose (milk sugar). The end product of carbohydrate

digestion is the so-called simple sugar; the most abundant is glucose.

### **Protein Digestion**

Protein digestion starts in the stomach. Two enzymes (renin and pepsin) in the gastric juice cause the giant protein molecules to break up into somewhat simpler compounds. Pepsinogen, a component of gastric juice, is converted into active pepsin enzyme by hydrochloric acid (also in gastric juice). In the intestine, other enzymes (trypsin in the pancreatic juice and peptidases in the intestinal juice) finish the job of protein digestion. Every protein molecule is made up of many amino acids joined together. When enzymes have split up the large protein molecule into its separate amino acids, protein digestion is completed. Hence the end product of protein digestion is amino acids. For obvious reasons, the amino acids are also referred to as *protein building blocks*.

### **Fat Digestion**

Very little carbohydrate and fat digestion occurs before food reaches the small intestine. Most fats are undigested until after emulsification by bile in the duodenum (that is, fat droplets are broken into very small droplets). After this takes place, pancreatic lipase splits up the fat molecules into fatty acids and glycerol (glycerine). The end products of fat digestion, then, are fatty acids and glycerol.

Table 11-1 summarizes the main facts about chemical digestion. Enzyme names indicate the type of food digested by the enzyme. For example, the name amylase indicates that the enzyme digests carbohydrates (starches and sugars), protease indicates a protein- digesting enzyme, and lipase means a fat-digesting enzyme. When carbohydrate digestion has been completed, starches (polysaccharides) and double sugars (disaccharides) have been changed mainly to glucose, a simple sugar (monosaccharide). The end products of protein digestion, on the other hand, are amino acids. Fatty acids and glycerol are the end products of fat digestion.

### **Absorption**

After food is digested, it is absorbed; that is, it moves through the mucous membrane lining of the small intestine into the blood and lymph. In other words, food absorption is the process by which molecules of amino acids, glucose, fatty acids, and glycerol goes from the inside of the intestines into the circulating fluids of the body. Absorption of foods is just as essential as digestion of foods. The reason is fairly obvious. As long as food stays in the intestines, it cannot nourish the millions of cells that compose all other parts of the body. Their lives depend on the absorption of digested food and its transportation to them by the circulating blood.

Structural adaptations of the digestive tube, including folds in the lining mucosa, villi, and micro villi, increase the absorptive surface and the efficiency and speed of transfer of materials from the intestinal lumen to body fluids. Many salts such as sodium are actively transported through the intestinal mucosa. Water follows by osmosis. Other nutrients are also actively transported into the blood of capillaries in the intestinal villi. Fats enter the lymphatic vessels or lacteals found in intestinal villi.

**Table 11-1 Chemical Digestion**

Digestive juices and enzymes	Substance Digested (or hydrolysed)	Resulting Products*
<b>Saliva</b> Amylase	Starch (Polysaccharide)	Maltose (disaccharide)
<b>Gastric Juice</b> Protease (Pepsin) plus hydrochloric acid	Proteins	Partially digested proteins
<b>Pancreatic Juice</b> Protease (trypsin) and Lipase Amylase	Proteins (intact or partially digested) Fats emulsified by bile Starch	Peptides <u>Fatty acids, amino acids</u> and <u>glycerol</u> Maltose
<b>Intestinal Juice</b> Peptidases Sucrase Lactase Maltase	Peptides Sucrose (cane sugar) Lactase (Milk sugar) Maltase (malt sugar)	<b>Amino acids</b> Glucose and fructose (simple sugars) <u>Glucose</u> and <u>galactose</u> (Simple sugars <u>Glucose</u> )


\*Substances underlined are end products of digestion (that is, completely digested foods ready for absorption)

## Review Questions

1. What organs form the gastrointestinal tract?
2. Trace the jejunum, cecum, colon, duodenum, and ileum.
3. If you inserted 9 inches of an enema tube through the anus, the tip of the tube would probably be in what structure?
4. What is the peritoneum? Name the two layers and describe their locations. Name four double-layered peritoneal structures.
5. Differentiate between deciduous and permanent teeth with respect to kinds and numbers.
6. What is peristalsis? Name some structures in which it occurs.
7. Name two purpose of the acid in gastric juice.
8. Name the principal digestive enzymes. Where is each formed? What does each do?
9. Where does absorption occur, and what structures are needed for absorption?
10. What types of digested materials are absorbed into the blood?
11. What types of digested materials are absorbed into the lymph?
12. Name the accessory organs of digestion and the functions of each.
13. Name five non-digestive functions of the liver.



14. Which digestive juice emulsifies fats?
15. What juices digest carbohydrates? Proteins? Fats?
16. Where are simple sugars and amino acids absorbed into blood capillaries? Where are lipids absorbed into lacteals?
17. Where is most of the water absorbed from the lumen of the digestive tract?



# CHAPTER TWELVE

## THE URINARY SYSTEM

### Chapter objective

- Discuss the structure & functions of the kidney
- Explain Accessory excretory structures of the urinary system
- Explain Urine and urination

### Selected key terms

The following terms are defined in the glossary

Cortex

Filtrate

Juxta-medullary nephron

Medulla

Nephron

Cortical nephron

Renal pelvis

Renal tubules

Trigone

Urinalysis

Urine

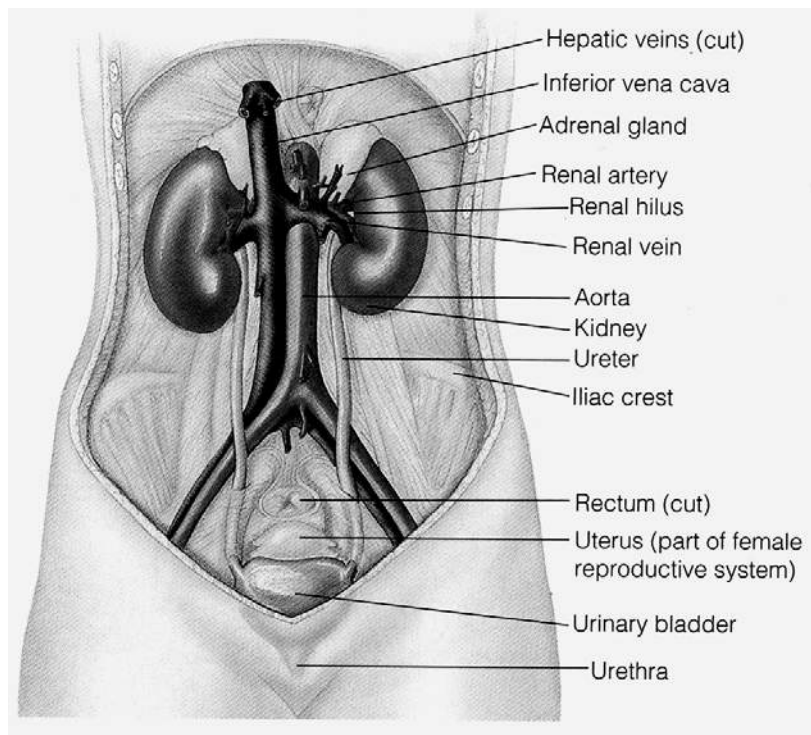
The urinary system is also called the excretory system of the body because one of its functions is to remove waste products from the blood and eliminate them from the body.

The urinary system consists of:

- Two kidneys: this organ extracts wastes from the blood, balance body fluids and form urine.
- Two ureters: this tube conducts urine from the kidneys to the urinary bladder.
- The urinary bladder: this reservoir receives and stores the urine brought to it by the two ureters.
- The urethra: this tube conducts urine from the bladder to the out side of the body for elimination.

**Major functions of the urinary system:**

1. Excretion of wastes
2. Hormonal production (rennin-angiotensin and erythropoietin)
3. Acid base balancing



**Figure: 12.1 The urinary system** (source: Grollman Sigmund, (1969), The human body it's structure and physiology, London, The Macmillan company, 2<sup>nd</sup> ed)

## 12.1 The kidney

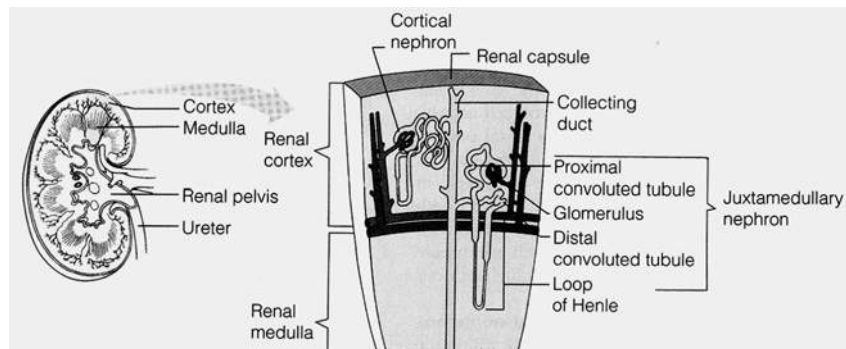
### 12.1.1 External Anatomy of the kidney

A pair of reddish brown, bean shaped organ located in the posterior wall of the abdominal region, one in each side of the vertebral column. They usually span between T<sub>12</sub> to L<sub>3</sub>. They

are protected at least partially by the last pair of ribs and capped by the adrenal gland. The bean shape of the kidney is medially concave and laterally convex. On the medial concave border is the **hilus** (small indented area) where blood vessels, nerves & ureters enter and leave the kidney.

Covering and supporting each kidney are three layers of tissue:

- Renal capsule – innermost, tough, fibrous layer
- Adipose capsule – the middle layer composed of fat, giving the kidney protective cushion.
- Renal fascia – is outer sub-serous membrane, connective tissue layer.



**Figure: 12.2 Internal structure of the kidney** (source: Grollman Sigmund, (1969), The human body it's structure and physiology, London, The Macmillan company, 2<sup>nd</sup> ed)

### 12.1.2 Internal Anatomy of the kidney

A sagittal section of the kidney reveals three distinct regions called pelvis, medulla and cortex (from inside out).

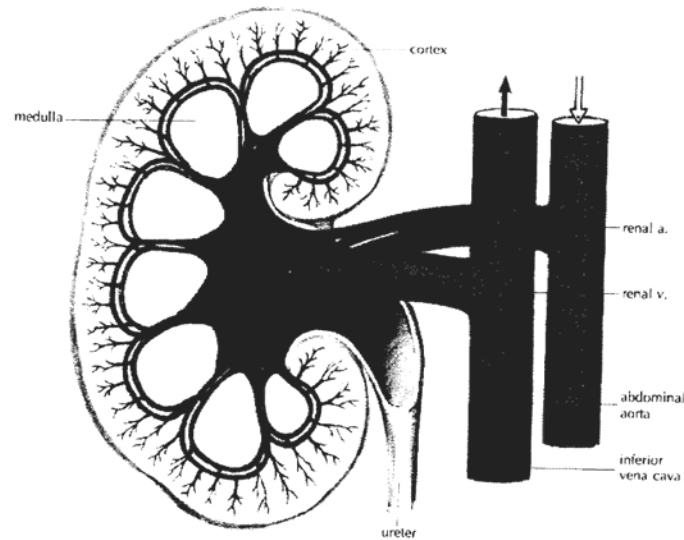
The renal pelvis is the large collecting space within the kidney formed from the expanded upper portion of the ureters. The pelvis branches into two cavities, these are 2-3 major calyces and 8 to 18 minor calyces.

The Renal medulla is the middle portion of the kidney. It consists of 8 to 18 renal pyramids, which are longitudinally striped, one cone shaped area. The base of each pyramid is adjacent to the outer cortex. The apex of each renal pyramid ends in papilla, which opens to a minor calyx. Pyramids contain tubules and collecting ducts of the nephron. Tubules involved in transportation and re-absorption of filtered materials.

The renal cortex is the outermost portion of the kidney. It is divided into two regions the outer cortical and the inner juxtamedullary region. The cortical tissue that penetrates between pyramids forms **Renal Columns**. The renal columns composed of mainly collecting tubules.

### 12.1.3 Blood circulation:

Blood is supplied to the kidneys by renal artery and drainage is by renal vein.



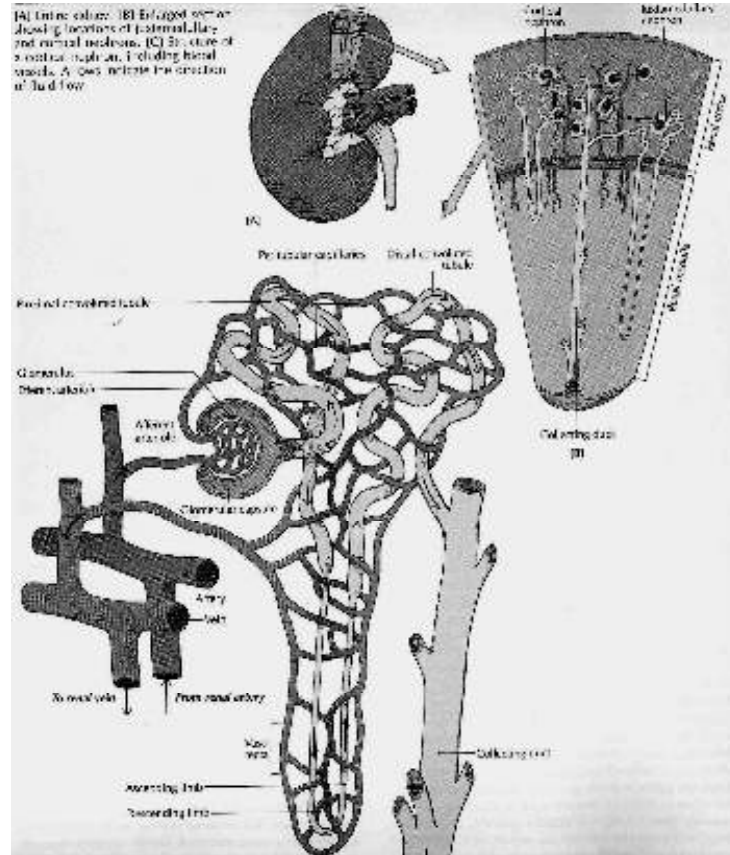
**Figure: 12.3 Circulatory pathways through the kidney**  
(source: Memmler, Ruth Lundeen, Barbara Jansen Cohen and Dena Lin Wood (1996), The Human Body in Health and Disease, 8<sup>th</sup> Ed, pp 342)

### 12.1.4 Nerve supply

- By renal plexus of autonomic nervous system.

### 12.1.5 The nephron

The basic functional unit of the kidney is the nephron. Each nephron is an independent urine-forming unit. Each kidney contains approximately one million nephrons.



**Figure: 12.4 Nephron** (source: Carola, R., Harley, J.P., Noback R.C., (1992), Human anatomy and physiology, Mc Graw hill inc, New York, 2<sup>nd</sup> ed, pp 854) **Table 12.1** The main structural components of a



nephron and their function. (source: Carola, R., Harley, J.P., Noback R.C., (1992), Human anatomy and physiology, Mc Graw hill inc, New York, 2nd ed, pp 855)

Structure	Major functions
Glomerulus	Vascular (capillary) component of renal corpuscle. Filters (by hydrostatic pressure) water, dissolved substances (minus most plasma proteins, blood cells) from blood plasma.
Glomerular capsule	Initial tubular component of nephron. Transports glomerular filtrate to proximal tubule.
Proximal convoluted tubule	Reabsorbs (by active transport) $\text{Na}^+$ , $\text{K}^+$ , $\text{Ca}^{2+}$ , amino acids, uric acid, ascorbic acid, ketone bodies, glucose. Reabsorbs (as a result of active $\text{H}^+$ secretion) $\text{HPO}_4^{2-}$ , $\text{Cl}^-$ , $\text{SO}_4^{2-}$ , $\text{HCO}_3^-$ . Reabsorbs (by osmosis) water. Reabsorbs (by diffusion) urea. Actively secretes substances such as penicillin, histamine, organic acids, organic bases.
Descending loop of the nephron	Reabsorbs (by active transport) $\text{Na}^+$ . Reabsorbs (by electrochemical gradient) $\text{Cl}^-$ , $\text{SO}_4^{2-}$ . Reabsorbs (by osmosis) water. Reabsorbs (by diffusion) urea.
Ascending loop of the nephron	Reabsorbs (by active transport) $\text{Na}^+$ , $\text{Cl}^-$ . Reabsorbs (by electrochemical gradient) $\text{HCO}_3^-$ .
Distal convoluted tubule	Reabsorbs (by active transport) $\text{Na}^+$ . Reabsorbs (by electrochemical gradient) $\text{PO}_4^{3-}$ , $\text{Cl}^-$ , $\text{SO}_4^{2-}$ , $\text{HCO}_3^-$ . Reabsorbs (by osmosis) water. Reabsorbs (by diffusion) urea. Actively secretes $\text{H}^+$ .
Collecting duct	Reabsorbs (by active transport) $\text{Na}^+$ . Reabsorbs (by osmosis, under control of ADH) water. Actively secretes $\text{H}^+$ and $\text{K}^+$ . Actively reabsorbs $\text{K}^+$ .

The major functions of the kidneys are:

All the functions are directly or indirectly related to the formation of urine. The series of events leads to:

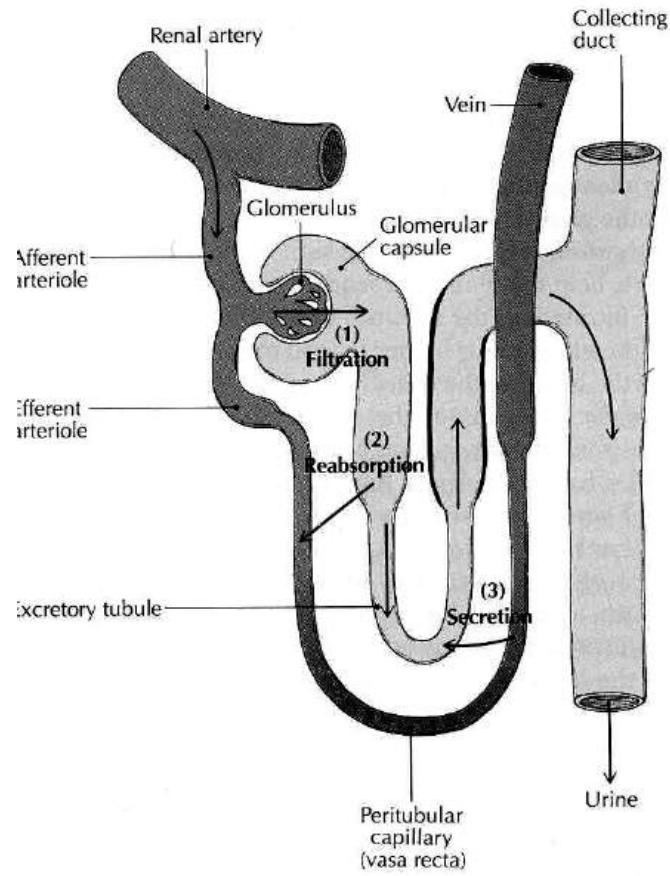
- To the elimination of wastes
- Regulation of total body water balance.
- Control of the chemical composition of the blood and other body fluid
- Control of acid base balance

The processes in urine formation are: -

1. Blood filtration, every day the kidneys filter 1700 Liter of blood
2. Tubular re-absorption
3. Tubular secretion

Average Comparison of filtration, re-absorption and excretion, here variation in urine composition will occur during variation in the daily diet, fluid intake, weather and exercise. **(source:** Carola, R., Harley, J.P., Noback R.C., (1992), Human anatomy and physiology, Mc Graw hill inc, New York, 2<sup>nd</sup> ed, pp 861)

Substance	Amount Filtered in gram	Percentage reabsorbed	Amount Excreted in grams
Glucose	170 g.	100	0.0 g.
Water	150 l.	99	1.5 l.
Calcium	17.0 g.	98.8	0.2g.
Sodium chloride	700 g.	98	15 g.
Phosphate	5.1 g.	80	1.2g.
Urea	50 g	40	30 g.
Sulfate	3.4 g.	33	2.7 g.



**Figure: 12.5** Urine productions in the nephron (source: Carola, R., Harley, J.P., Noback R.C., (1992), Human anatomy and physiology, Mc Graw hill inc, New York, 2<sup>nd</sup> ed, pp 859)

## 12.2 Accessory Excretory structures

Urine is formed in the kidney, but accessory structures are required to transfer, store and eventually eliminate urine from the body. These structures are the two ureters, urinary bladder and urethra.

### 12.2.1 Ureters

Attached to each kidney is a tube called the ureters. Ureters transport urine from the renal pelvis to the urinary bladder. The ureters pass between the parietal peritoneum and the body wall to the pelvic cavity, where they enter the pelvic cavity. It is narrow at the kidney and widens near the bladder.

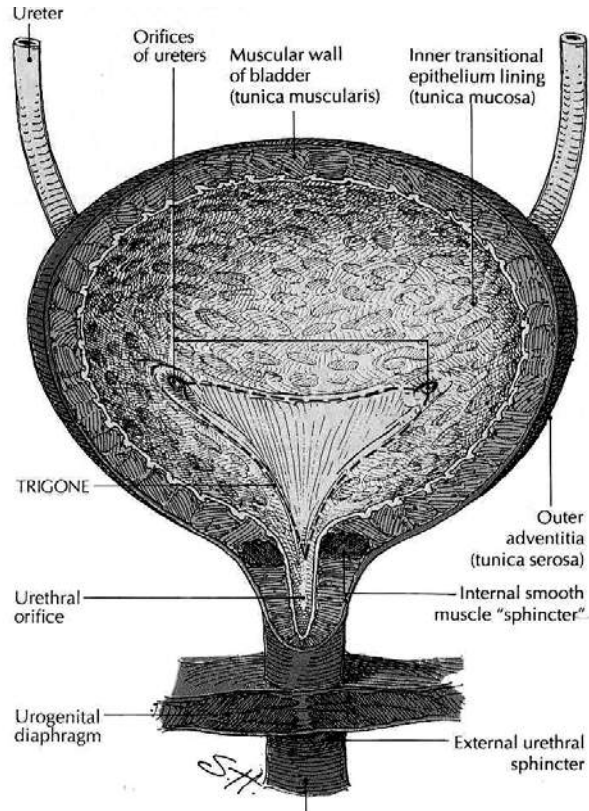
The lumen of the ureters is composed of three layers:

- Innermost, Tunica Mucosa
- The middle, Tunica Muscularis (made of smooth muscle)
- The outer, Tunica Adventitia

### 12.2.2 Urinary bladder

Urinary bladder is a hollow, muscular organ that collects urine from the ureters and stores it until it is excreted. It usually accumulates 300 to 400 m.l. of urine but it can expand as much as twice. It is located on the floor of the pelvic cavity and

like the kidneys and ureters. It is ***Retroperitoneal***. In males it is anterior to the rectum and above the prostate gland. In females, it is located somewhat lower, anterior to the uterus and upper vagina.



**Figure: 12.6 Urinary bladder and urethra** (source: Memmler, Ruth Lundeen, Barbara Jansen Cohen and Dena Lin Wood (1996), *The Human Body in Health and Disease*, 8<sup>th</sup> Ed, pp 350)

The wall of urinary bladder is composed of three layers:

- 1) Tunica mucosa, the innermost layer lined with transitional epithelium.
- 2) Tunica muscularis, the middle layer, three layers of smooth muscle. This collectively called detrusor muscles.
- 3) Tunica serosa (Adventitia), the outer layer derived from peritoneum and covers only the upper and lateral surfaces of the bladder.

The opening of ureters and urethra in the cavity of the bladder outline triangular area called the **trigone**. At the site where the urethra leaves the bladder, the smooth muscle in the wall of the bladder forms spiral, longitudinal and circular bundles which contract to prevent the bladder from emptying prematurely. These bundles function as a sphincter called **Internal Urethral Sphincter** (Involuntary). Far there along the urethra in the middle membranous portion a circular sphincter of voluntary skeletal muscle form the external urethral sphincter.

### 12.2.3 Urethra

Urethra is a tube of smooth muscle lined with mucosal layer. It joins the bladder at its inferior surface and transport urine out side the body during urination. It is 4 C.M in female and 12 C.M.

in length in male. In females it opens between vagina and clitoris. In male it pass through prostate, membranous portion (pelvic diaphragm muscle), spongy portion (that pass through corpus spongosus) and open at the tip of penis. The spongy portion joined by ducts from bulbo-urethral gland (Mucus secreting gland).

### 12.3 Urine & urination

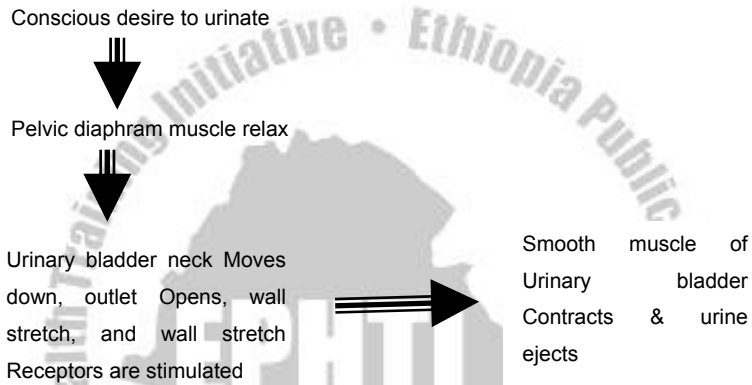
Composition of urine varies depending on the diet, exercise, water consumption and other factors. However, it is composed of mainly water, urea, chloride, potassium, sodium, creatinin, phosphate, sulfates and uric acid. Proteins, glucose, casts (decomposed blood) and calculi from minerals are abnormal if present in urine.

The P<sup>H</sup> of urine is 5.0 to 8.0 (mostly acidic) and has translucent (clear, not cloudy) color. To maintain the proper osmotic concentration of the extra cellular fluid to excrete wastes and to maintain proper kidney function the body must excrete at least 450ml of urine per day. A healthy person excretes 1000 to 1800 ml of urine daily. The volume and concentration of urine is controlled by:

- Antidiuretic hormone
- Aldestrone
- The Renin – angiotensin mechanism

### 12.3.1 Urination

Urination is emptying of the bladder; it is the process of conscious and unconscious nerve control. Steps of urination are:





## Study Questions

1. The apex of each renal pyramid end in the
  - a) Cortical region
  - b) Papilla
  - c) Juxta medullary region
  - d) Capsule
  - e) Tubule
2. The inner most layer of the ureters is the
  - a) Mucosa
  - b) Muscularis
  - c) Adventitia
  - d) Longitudinal layer
  - e) Circular layer
3. The kidney function in all of the following **except**
  - a) Acid – base balance
  - b) An endocrine organ
  - c) By removing metabolic waste
  - d) By removing excess carbon dioxide
  - e) By maintaining osmotic concentration
4. An increased volume of urine formation would follow:-
  - a) Inhibition of tubular sodium re-absorption
  - b) A fall in plasma osmolarity
  - c) A fall in plasma volume
  - d) a and b
  - e) a, b and c
5. Urine passé through the ureters by:
  - a) Gravity
  - b) Hydrostatic pressure
  - c) Filtration
  - d) Peristalsis
  - e) a, b and d

# CHAPTER THIRTEEN

## FLUID AND ELECTROLYTE BALANCE

### Chapter objective

At the end of this chapter, the students should be able to:

- Explain the most abundant elements in the body
- Discuss movement of water across body compartments
- Explain about electrolytes of the body
- Explain acid base balance

### Selected key terms:

The following terms are defined in the glossary

Buffer system

Electrolyte

Extra cellular fluid

Hydrostatic pressure

Intracellular fluid

Osmotic pressure

The composition of body fluids is an important factor in homeostasis. The volume or chemical makeup of these fluids whenever deviates even slightly from normal, disease results. The constancy of body fluids is maintained in ways that include the following:

1. The thirst mechanism, which maintains the volume of water at a constant level.
2. Kidney activity, which regulates the volume and composition of body fluids.
3. Hormones, which serve to regulate fluid volume and electrolytes.
4. Regulators of PH, including buffers, respiration and kidney function.

### **13.1 Elements of the body**

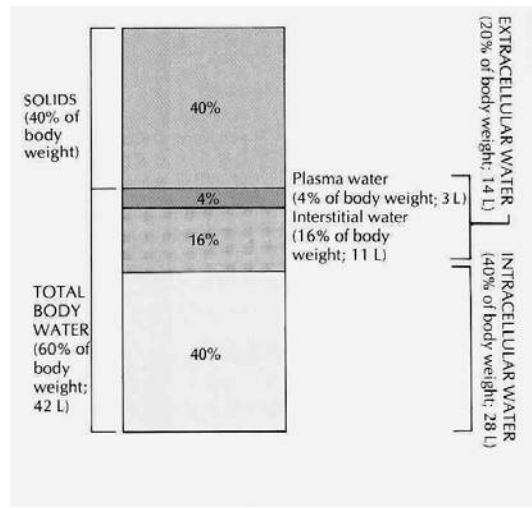
The largest single constituent of the body is water, which is 60 % of the total body weight. The correct proportion of water and electrolytes in the water and proper acid base balance are necessary for life to exist. Loss of 10% of total body water usually produce lethargy, fever and dryness on mucous membrane and a 20% loss is fatal.

#### **13.1.1 Body fluids**

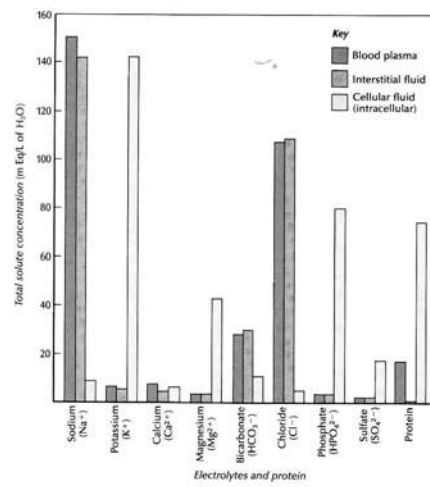
All body fluids are either intracellular (inside the cell) or extra

cellular (out of the cell) fluids. Intracellular fluid constitutes 2/3 of all body fluid. Extra cellular fluids found as interstitial fluid (the immediate environment of body cells), blood plasma and lymph, cerebrospinal, synovial, fluids of the eye & ear, pleural, pericardial, peritoneal, gastrointestinal and glomerular filtrate of the kidney. The most important and abundant fluids are the interstitial & blood plasma. The interstitial fluid occupies the space around body cells. It is derived from blood plasma.

- The most important difference between the plasma and interstitial fluid is the presence of soluble protein in plasma and they're near absence in the interstitial fluid. Under normal condition capillaries are impermeable to proteins. The concentration of water in the interstitial fluid is slightly higher than the concentration of water in plasma. The plasma proteins are responsible for this difference



A



B

**Figure: 13.1A** proportion of water to the body weight, **13.1B** concentration of electrolytes and protein in the body fluids (source: Carola, R., Harley, J.P., Noback R.C., (1992), Human anatomy and physiology, Mc Graw hill inc, New York, 2<sup>nd</sup> ed, pp 884/85)

### 13.1.2 Movement of water

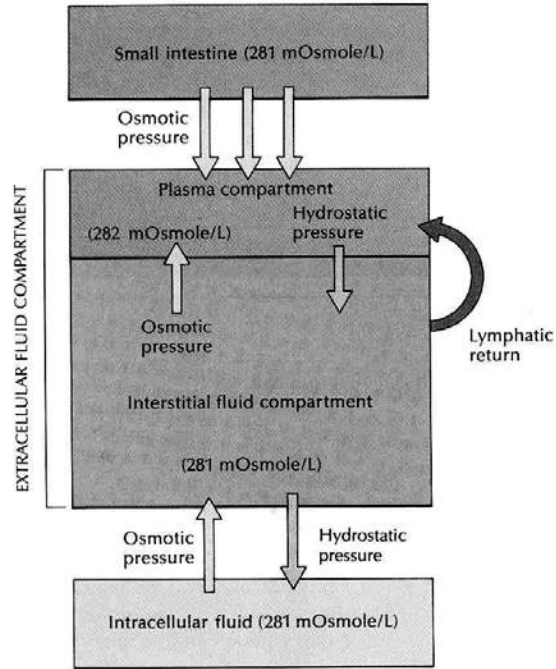
Movement of water from one body part to another is controlled by two forces hydrostatic pressure & Osmotic pressure.

*Hydrostatic pressure:* it is the force exerted by a fluid against the surface of the compartment containing fluid.

*Osmotic pressure:* Is the pressure that must be applied to a solution on one side of a selectively permeable membrane to prevent the Osmotic flow of water across the membrane from a compartment of pure water.

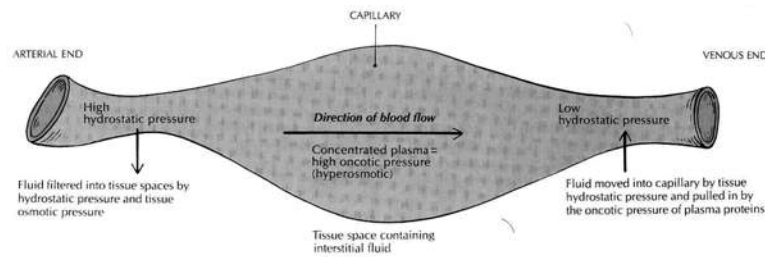
When there is shift in the pressure of water to wards the interstitial space, accumulation of fluid in the space occur. This phenomenon is called *edema*. Edema is abnormal accumulation of water with in the interstitial compartment. Such accumulation of water produces distention of the tissue which appears as puffiness on the surface of the body. Causes of edema may be plasma protean leakage decreased protein synthesis, increased capillary or venous hydrostatic pressure, obstructed lymphatic vessels and inflammatory reaction.

Arrows indicate the direction of water movement. Fluids are absorbed from the small intestine into the interstitial compartment in tissue spaces. Ordinarily, there is a state of equilibrium between the extracellular fluid and intracellular fluid (bottom two arrows). If there is excessive sodium in the interstitial fluid, it is hyperosmotic to the cells (which are hypoosmotic) and has a higher osmotic pressure. Water moves by osmosis from the cells, and the cells lose their shape. As water leaves cells, solutes within the cells become more concentrated (hyperosmotic), and essential electrolytes diffuse from the cells into the interstitial fluid.



**Figure: 13.2 Movements of fluid in responses to osmotic pressure.**

(source:Carola, R., Harley,J.P., Noback R.C., (1992), Human anatomy and physiology, Mc Graw hill inc, New York, 2<sup>nd</sup> ed, pp 886)



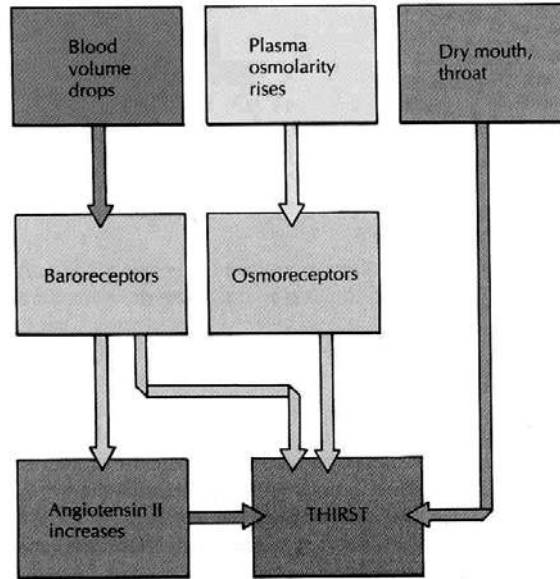
**Figure: 13.3 Movement of fluid between plasma and interstitial fluid**  
(source: Carola, R., Harley, J.P., Noback R.C., (1992), Human anatomy and physiology, Mc Graw hill inc, New York, 2<sup>nd</sup> ed, pp 887)

### 13.1.3 Water intake & out put

Most water is taken in to the body by drinking and a smaller amount enters as part of food and an even smaller amount is the product of oxidation of food in cells.

The important mineral solutes (electrolytes) of the body enter the body through food or drink. Under normal condition water is taken in to and excreted from the body, so it matches to maintain homeostasis. Drinking of water is regulated by nervous mechanism (thirst center in the brain) together with hormonal mechanism (Antidiuretic hormone). Kidneys are the organs regulated by homeostatic feed back response they are responsible for excreting most of the water from the body.





**Figure: 13.4 Thirst regulation** (source: Carola, R., Harley, J.P., Noback R.C., (1992), Human anatomy and physiology, Mc Graw hill inc, New York, 2<sup>nd</sup> ed, pp 888)

## 13.2 Electrolytes

Electrolytes are compounds that dissociate into ions when in solutions. Acids, bases & salts are electrolytes. Most electrolytes are dissolved in the body fluids. However, some are found attached to proteins and other places.

The most physiologically important electrolytes are the cations ( $\text{Na}^+$ ,  $\text{k}^+$ ,  $\text{ca}^{2+}$   $\text{mg}^{2+}$  and  $\text{H}^+$ ) and anions bicarbonates ( $\text{HCO}_3^-$ ), chloride ( $\text{cl}^-$ ) phosphate ( $\text{HP0}_4^{2-}$ ) & sulfate ( $\text{SO}_4^{2-}$ )

Functions:

- Necessary for cell metabolism & contribute to body structure.
- Facilitate movement of water between the body compartments
- Together with the soluble proteins, they maintain the hydrogen ion
- Concentration (acid-base balance)
- Sodium, potassium, chlorides and magnesium are crucial to the production and maintenance of membrane potentials (nerve & muscle potentials)

Sodium, potassium and chloride ions present in the highest concentration in the body. These three electrolytes are particularly important in maintaining body function and normal water distribution among the fluid compartment.

### **13.3 Acid –Base Balance**

Acid – base balance mean the regulation of hydrogen ion in the body fluids, especially in the extra cellular fluids. Any molecule that dissociates in solution to release a hydrogen ( $H^+$ ) ion is called an acid. Any molecule capable of accepting a hydrogen ion is a base. The hydrogen ion concentration is measured by  $P^H$  scale. It affects every chemical reaction and process in the body. Enzymes, hormones and the distribution

of ions can all be affected by the concentration of hydrogen ion. The  $P^H$  of the blood and interstitial fluid is maintained between 7.35 and 7.45. An increase or decrease of  $P^H$  by a few tenths of unit can be disastrous.

Homeostatic maintenance of an acceptable  $P^H$  range in the extra cellular fluid is accomplished by three mechanisms:

1. Specific chemical buffer system of the body fluids (react very rapidly, in less than a second)
2. Respiratory regulation (reacts rapidly in seconds to minutes)
3. Renal regulation (reacts slowly, in minutes to hours)

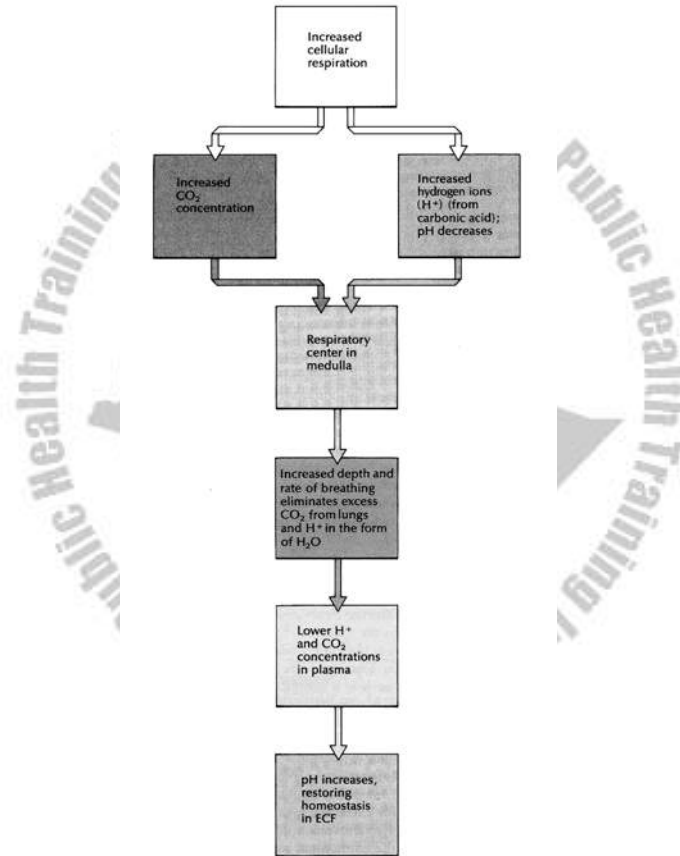
### **13.3.1 Buffer system**

To buffer mean to neutralize. Weak acids and weak bases act as a buffer system. Buffering agents acts rapidly. In this case addition of  $H^+$  result an equilibrium shift. The most common are:

- Acid – base buffer system.
- Bicarbonate buffer system.
- Phosphate buffer system.
- Protein buffer system: - The most abundant & important in body cells and with in plasma because of it's high concentration

### 13.3.2 Respiratory Regulation


An increase in carbon dioxide concentration in the body varies  $P^H$  of the body. Therefore, the respiratory regulation works by elimination of carbon dioxide from the body.



**Figure: 13.5 Respiratory control of  $P^H$**  (source: Carola, R., Harley, J.P., Noback R.C., (1992), Human anatomy and physiology, Mc Graw hill inc, New York, 2<sup>nd</sup> ed, pp 892)

### 13.3.3 Renal Regulation

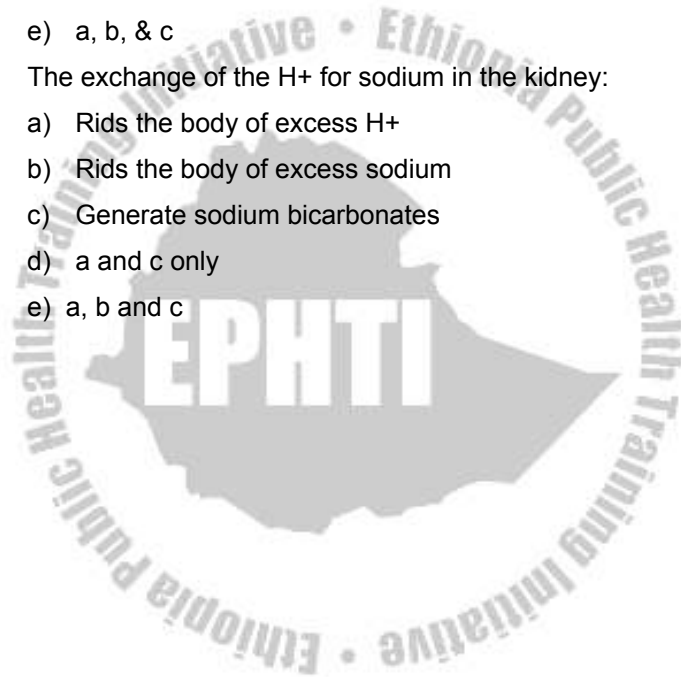
The body normally consumes more acid producing food than base producing therefore; it must not only adjust  $P^H$  but also excrete  $H^+$ . This task is accomplished in renal tubules, where hydrogen & ammonium ions are secreted in to urine, when  $H^+$  is excreted sodium is exchanged.



## Study Questions

1. Which of the following are the most similar in composition?
  - a) Plasma & interstitial fluid
  - b) Plasma & intercellular fluid
  - c) Lymph & plasma
  - d) Lymph & intracellular fluid
  - e) Intracellular & extra cellular fluid
2. Which of the following solutes present in blood plasma but not in intestinal fluid?
  - a) Calcium
  - b) Sodium
  - c) Potassium
  - d) Magnesium
  - e) Protein
3. Movement of water from one body compartment to another is controlled by
  - a) Atmospheric pressure
  - b) Hydrostatic pressure
  - c) Osmotic pressure
  - d) a & c only
  - e) b & c only

4. The function of electrolytes in the body include
  - a) Contributing to body structure
  - b) Facilitating the movement of water between body compartments
  - c) Maintaining acid – base balance
  - d) a and b only
  - e) a, b, & c
5. The exchange of the H<sup>+</sup> for sodium in the kidney:
  - a) Rids the body of excess H<sup>+</sup>
  - b) Rids the body of excess sodium
  - c) Generate sodium bicarbonates
  - d) a and c only
  - e) a, b and c



# CHAPTER FOURTEEN

## THE REPRODUCTIVE SYSTEM

### Chapter Objective

At the end of the chapter, the students should be able to:

- Discuss the male and female reproductive system
- Explain the formation of sex cells
- Explain conception and mechanism of contraception

### Selected key terms:

The following terms are defined in the glossary

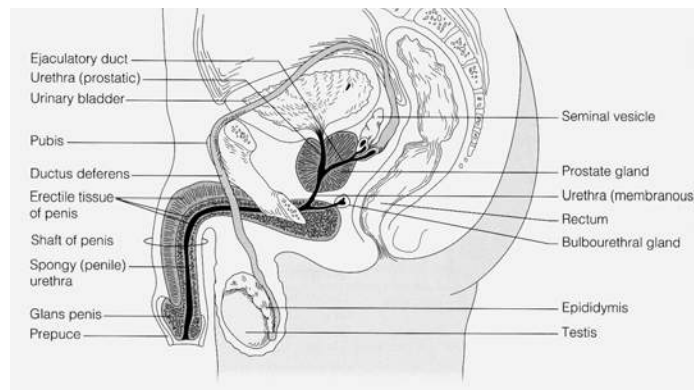
Accessory sex ducts	Ovulation
Accessory sex glands	Penis
Conception	Perineum
Contraception	Semen
Gametogenesis	Sperm
Mammary gland	Testis
Menstruation	Uterine tube/ fallopian tube
Mons pubis	Uterus
Ovary	Vagina



The function of reproductive system is replication. Reproduction by means of sexual intercourse produces new human beings and hereditary traits to be passed from both parents to their children's. The reproductive role of male is to produce and deliver sperm to the female reproductive tract. But the reproductive role of females is to produce ova and carrying the developing embryo. The sex hormones play an important role both in the development and function of the reproductive organ and in sexual behavior & drives.

### 14.1 Male reproductive system

The male's reproductive role is to produce sperm and deliver to the vagina. These functions require four different structures. These are the: Testes, Accessory glands, Accessory ducts and penis.



**Figure: 14.1 Male reproductive system** (source: Elaine n. MARIEB, (2000), Essentials of human anatomy and physiology, Addison welsey longman inc., San Francisco, 6<sup>th</sup> Ed)

## 14.1.1 Male internal reproductive organs

Male internal reproductive organs include the testes, series of ducts and accessory glands.

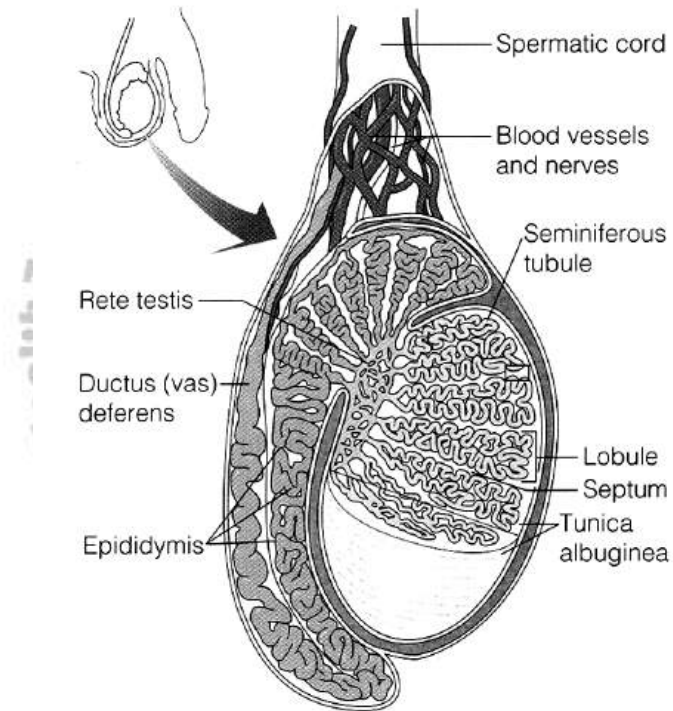
### 14.1.1.1 Testes

Testes are paired male reproductive organs (gonads), which produce sperm. During fetal life, testes are formed just below the kidneys inside the abdomino-pelvic cavity. By third fetal month it starts to descend and by the seventh month of fetal life it passes through the inguinal canal. The inguinal canal is a passageway leading to scrotum.

Scrotum is a pouch of skin that hangs between the thighs. The testes complete their descent into the scrotum shortly before or after birth. Because the testes hang outside the body their temperature is cooler than the body temperature by 3 Degree Fahrenheit. This lower temperature is needed for sperm production and survival. Under the skin of scrotum, **Cremaster** muscle elevates testes during cold weather. The interior of the scrotum is divided into two by median septum. One testis in each compartment.

Each testis is oval-shaped measuring 4.5 c.m. long, 2.5 c.m wide in adult. It is enclosed in fibrous sac called **Tunica**

**Albuginea.** The sac extends in to a test to divide the test in to lobules. Next to tunica albuginea is **Tunica Vaginalis**, which is a continuation of membrane of abdomino-pelvic cavity. Each test contain 800 lightly coiled **Seminiferous Tubules** which produce thousands of sperm each second.



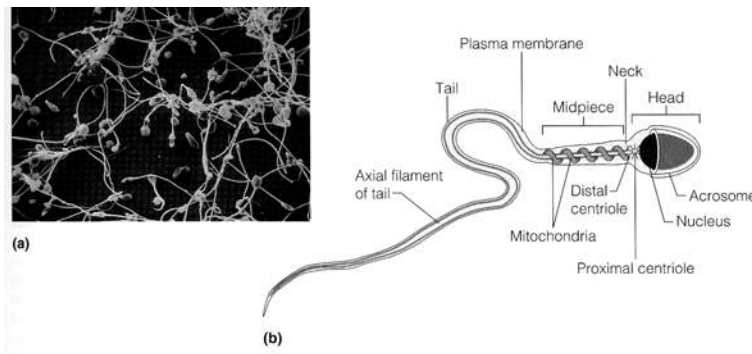
**Figure: 14.2 Testis** (source: Elaine n. MARIEB, (2000), Essentials of human anatomy and physiology, Addison welsey longman inc., San Francisco, 6<sup>th</sup> Ed)

The walls of the seminiferous tubes are lined with **germinal tissue**. The germinal tissue contains two types of cells: **spermatogenic cell** producing or developing the sperm cell and the **sustentacular cell**, which provide nourishment for the germinal sperm.

Between the seminiferous tubules clusters of endocrine cells called **interstitial endocrinocytes (Leydig cell)** secrete male sex hormone (**Androgens**) where **testosterone** is the most important.

### Sperm

The male genetic carrying cell is the sperm. Matured spermatozoa have head, middle piece, and tail



**Figure: 14.3 Sperm** (source: Elaine n. MARIEB, (2000), Essentials of human anatomy and physiology, Addison welsey longman inc., San Francisco, 6<sup>th</sup> Ed)

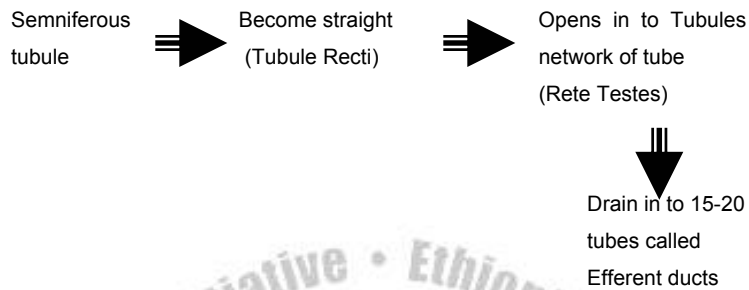
At the tip of the head is **acrosome** containing several enzymes that help the sperm to penetrate the egg. In the center of head is a nucleus-containing chromosome. This is a genetic constitution. The middle piece consist mainly coiled mitochondria for energy production for tail motility.

Sperm is one of the smallest cells in the body. For complete development each sperm need 2 months. Normally 300 to 500 million sperms are released during ejaculation. A male who releases 20 to 30 million normal sperms tends to be infertile.

#### **14.1.1.2 Accessory Ducts**

The sperm produced in the testes are carried to the point of ejaculation from penis by a system of ducts. These are epididymis, ductus deference, ejaculatory duct and the urethra.

**Epididymis:** - The seminiferous tubules merge in the central posterior portion of the testes as epydidimis.



The efferent ducts extend up ward in to a convoluted mass of tubes that forms a crescent shape along its side. This coiled tube is epididymis. It has three main functions.

- Store sperm until maturity
- Passage way of sperm
- Propel sperm to next duct system

Epididymis has head, body & tail. The head join with efferent duct and tail continues as vas deference (ductus deference).

**Ductus deferens:**

It is the dilated continuation of epididymis. It is located easily over the spermatic cord; hence male permanent (surgical) contraceptive method (vasectomy) is usually performed over it. As it passes from tail of epididymis it is covered by spermatic cord containing testicular artery, vein, autonomic nerves, lymphatic and connective tissue. After the ducts deferens pass through the inguinal canal it free from spermatic cord and pass behind the urinary bladder, where it

travels along side an accessory gland, the seminal vesicle and becomes ejaculatory duct. Just before reaching the seminal vesicle, it widens in to an enlarged portion, **Ampulla**. Ampulla is sperm storage sites before ejaculation. It transports sperm by peristalsis during peak stimulation.

**Ejaculatory duct:**

The ducts deference joins to the duct of seminal vesicle at ejaculatory duct. It is about 2 c.m. long. They receive secretion from the seminal vesicles and pass through the prostate where they receive additional secretion.

**Urethra**

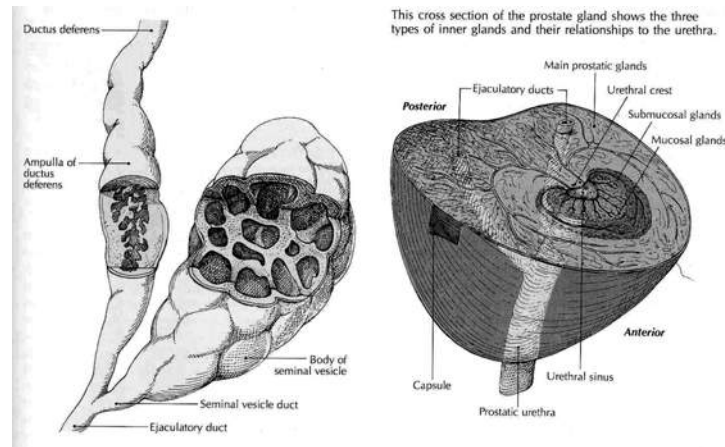
It is the final section of the reproductive system. It leads from the urinary bladder through the prostate gland and to the tip of the penis. Its reproductive function is to transport semen out of penis.

**14.1.1.2 Accessory Glands**

These are seminal vesicles, prostate and bulbo-uretral glands.

**Seminal vesicles**

Seminal vesicles are paired; secretory sacs lie next to the Ampulla of the ducts deference. It produces alkaline secretion. It contains mostly water, fructose, prostaglandin & vit. C.



**Figure: 14.4 Seminal vesicles and the prostate gland** (source: Carola, R., Harley, J.P., Noback R.C., (1992), Human anatomy and physiology, Mc Graw hill inc, New York, 2<sup>nd</sup> ed, pp 913)

### Prostate gland

Prostate gland lies inferior to the urinary bladder surrounding the first portion of urethra. It is a rounded mass about the size of chestnut. The secretion of prostate makes sperm motile and neutralizes vaginal acidity. A thin but firm capsule of fibrous connective tissue surrounds the prostate. The secretion of prostate mainly contains water, acid phosphate & cholesterol.

### Bulbo-urethral gland

Bulbo urethral glands are pair; one in each side of the urethra. Each gland is about shape & size of pea. They lie directly below prostate. Bulbo urethral glands secretes clearly alkaline



fluid to neutralize the acidity of urine during the onset of sexual excitement and it also act as a lubricant.

## 14.1.2 Male external reproductive organ

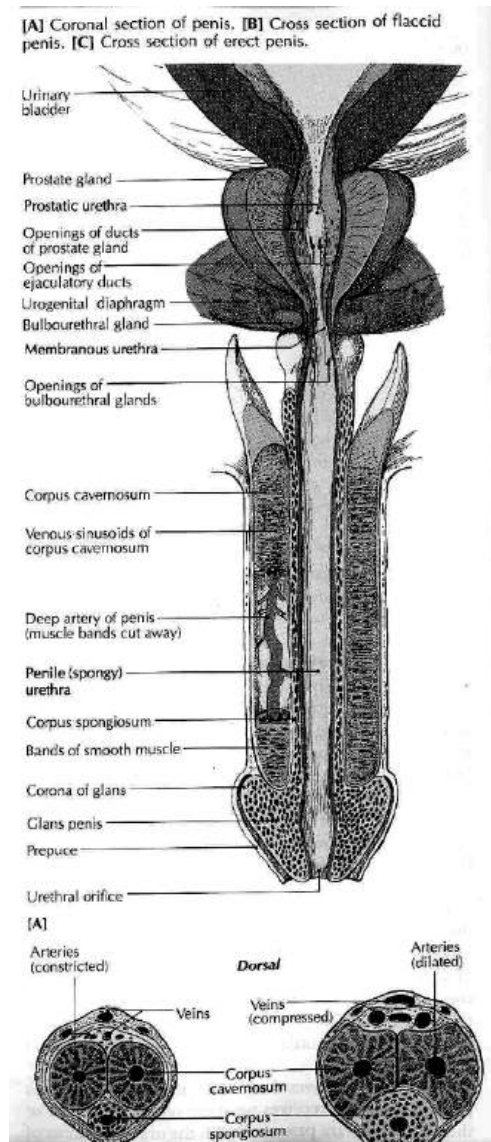
### 14.1.2.1 Penis

Penis is an extension from the perineal area of male. It is soft and erectile tissue.

Has two main function, It carries urine through urethra to the out side during urination and it transports semen through the urethra during ejaculation. In addition to urethra penis contains three cylindrical strands of erectable tissue.

- Two corpora cavernosa, which run parallel to the dorsum of penis.
- Corpus spongiosum which contain urethra

The corpora cavernosa are surrounded by a dense, relatively inelastic connective tissue called tunica albuginea. It also contains numerous vascular cavities called **venous sinusoids**.



**Figure: 14.5 Penis** (source: Carola, R., Harley, J.P., Noback R.C., (1992), Human anatomy and physiology, Mc Graw hill inc, New York, 2<sup>nd</sup> ed, pp 914)

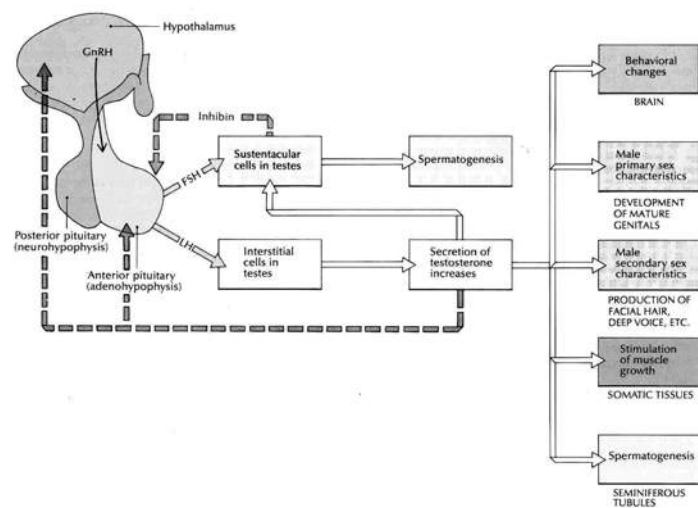
The corpus spongiosum extends distally beyond the corpora cavernosa & becomes expanded at the tip of the penis, which is called **glans penis**. The loosely fitting skin of the penis is folded forward over the glans to form the **prepuce or foreskin**, which usually excised during circumcision. Corona of the glans is a ridge at behind margin of glans.

### **14.1.3 Semen**

Secretions from epididymis, seminal vesicles, prostate and bulbourethral gland together with sperm make up semen. Sperm make up only 1% of semen. The rest is a fluid secretion from accessory glands, which provide fructose to nourish sperm and alkaline medium to neutralize urethral (acidity because of urine) & vaginal acidity. It also contains vitamin C, and trace elements like calcium, Zinc, magnesium, Copper and sulfur.

### **14.1.4 Hormonal regulation in the male**

Follicular Stimulating Hormone (FSH) and Leutinizing Hormone (LH) produced by the anterior pituitary gland are chiefly responsible for stimulating spermatogenesis and testosterone secretion. Follicular Stimulating Hormone (FSH) and Leutinizing Hormone (LH) affect only tests whereas; Testosterone affects not only spermatogenesis but also sex organ development and appearance of secondary male sexual characteristics.



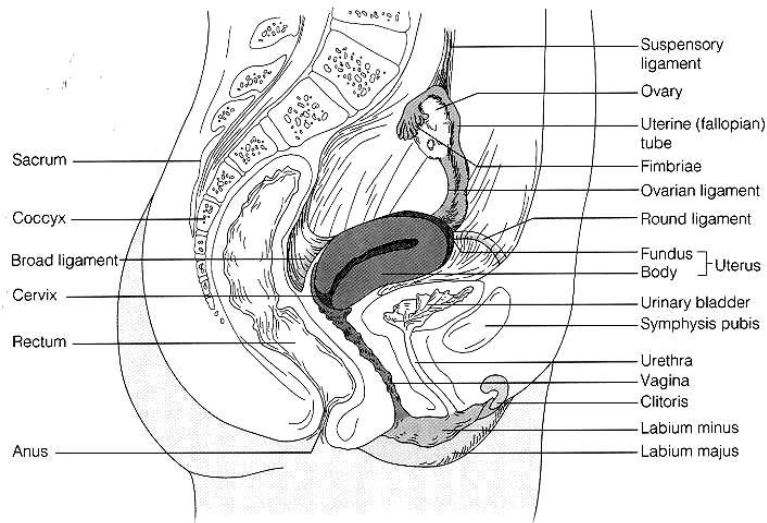
**Fig 14.6 Hormonal control of sperm production** (source: Carola, R., Harley, J.P., Noback R.C., (1992), Human anatomy and physiology, Mc Graw hill inc, New York, 2<sup>nd</sup> ed, pp 916)

## 14.2 Female Reproductive System

The reproductive role of females is far more complex than that of male. They

- Produce egg
- After fertilization they also carry and protect the developing embryo.
- Production of milk by mammary glands

The female reproductive system consists of ovaries, uterine tube, uterus, vagina, external genital organ (vulva) and mammary glands.



**Fig 14.7 Female reproductive system** (source: Elaine n. MARIEB, (2000), Essentials of human anatomy and physiology, Addison welsey longman inc., San Francisco, 6<sup>th</sup> Ed)

### 14.2.1 Females internal reproductive organs

Females' internal reproductive organs include the ovary, the uterine tube, the uterus, and the vagina.

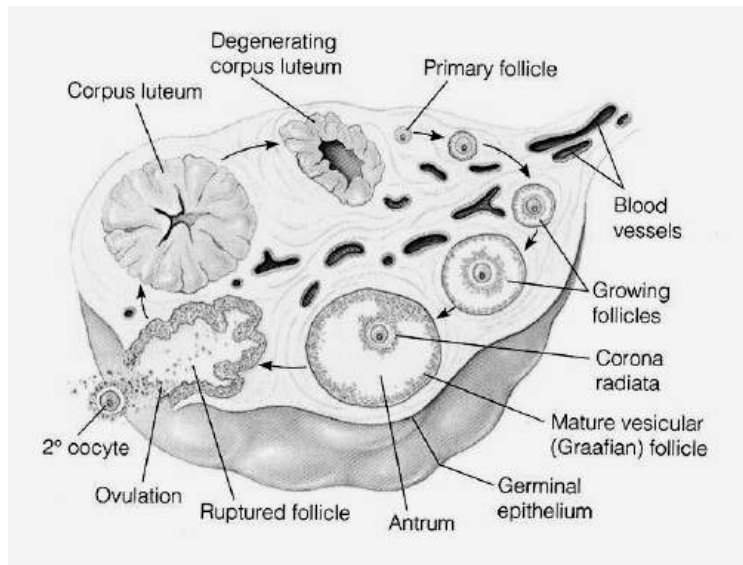
#### 14.2.1.1 Ovaries

Ovaries are females' gonads that produce ova and female hormones. It is about the size of unshelled almond. The ovaries are located in the pelvic cavity one in each side of the uterus. Each ovary is attached by a mesentery called

**mesovarium** to the backside of each **broad ligament**. A thickening border of the mesovarium called **ovarian ligament** extends from the ovary to the uterus. The ovary is suspended from the pelvic wall by the **suspensory ligament**.

A layer of specialized epithelial cells called **germinal layer** covers the ovaries. Beneath it, is the stroma mass of connective tissue, which contains ova in various stage of maturity.

A cross section of ovary reveals **a cortex** and **a vesicular medulla**. The cortex contains round epithelial vesicle or **follicles**; follicles are actual center of ovum production or **oogenesis**. Follicles are usually located directly beneath the cortex of the ovary. They secrete estrogen. But once they begin to mature they migrate towards the inner medulla. The medulla consists of layers of soft stromal tissue. The stromal tissue contains rich supply of blood vessels, nerves and lymph vessels. After ovulation the lining of the follicles grows inward, forming corpus luteum (yellow body), which temporarily functions as endocrine tissue. It secretes estrogen & progesterone which stops additional ovulation, thickening of uterine wall & stops additional mammary glands in anticipating pregnancy. If pregnancy does not occur within 14 days corpus luteum degenerates and menstruation follows. If pregnancy occurs it continues to work for 2 to 3 months & eventually degenerates when placenta takes the duty.



**Figure: 14.8 The Ovary** (source: Elaine n. MARIEB, (2000), Essentials of human anatomy and physiology, Addison welsey longman inc., San Francisco, 6<sup>th</sup> Ed)

### 14.2.1.2 Ovulation

Ovulation is the process by which the mature ova rupture from the follicle and eventually travel to the fallopian tube. In response to high concentration of FSH & LH from anterior pituitary, the mature follicle ruptures this process. About 20 ovarian follicles mature each month beginning at puberty. However, only one ruptures to release ova (oocyte).

### **14.2.1.3 Uterine tubes**

Uterine tubes are a pair of tubes one in each side of the uterus. The uterine tube (fallopian tube) conveys the oocyte to the uterus. One of the paired tubes receives the oocyte from the ovary to take to the uterus. The tubes are not directly connected to ovary. But it opens in abdominal cavity very close to ovary.

It has 3 distinct portions.

- Infundibulum: - funnel shaped, near the ovary
- Ampulla: - thin walled middle portion
- Isthmus: - opens in to the uterus

The tube is made of three layers, the outer serous membrane, the middle muscular (smooth muscle) and the inner mucous membrane.

The Infundibulum is fringed with feathery fimbriae, which may overlap the ovary. Unlike sperm the oocyte is unable to move by its own instead it is carried along the uterine tube towards uterus by peristaltic contraction of the fallopian tube.

### **14.2.1.4 Uterus**

The uterine tubes terminate in the uterus. A hollow muscular organ located in front of the rectum and behind the urinary



bladder. It is like an inverted pear when viewed anterior and is pear size as well, during pregnancy it increases 3-6 times.

Round ligament help the uterus tilted forward over the bladder. It is attached to the lateral wall of the pelvis by two broad ligaments. Two utero-sacral ligaments extend from the upper part of the cervix to the sacrum. The posterior & anterior ligaments attach uterus to rectum and urinary bladder respectively.

Uterus has three parts:

- Fundus: - the upper, dome shaped part
- Body: - the tapering middle portion
- Cervix: the body terminate to narrow portion

The constricted region between the body and cervix is the isthmus. The interior of the cervix is the cervical canal, which opens in to vagina.

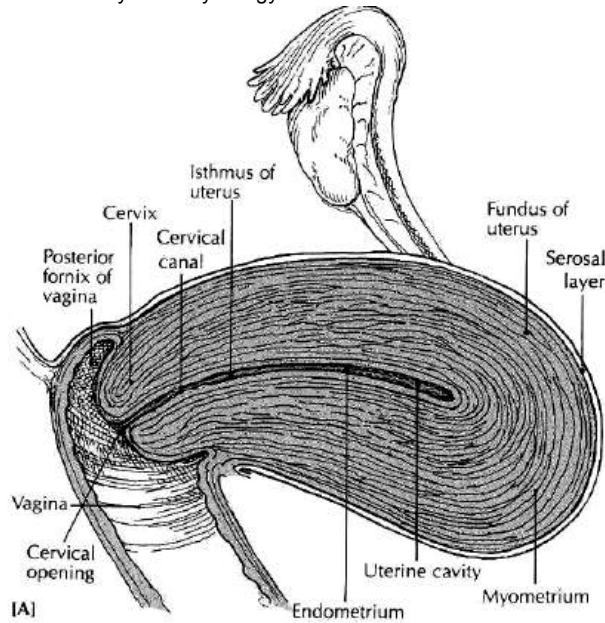


Fig. (1992), Human anatomy and physiology, Mc Graw hill inc, New York, 2<sup>nd</sup> ed, pp 921)

The uterus is made up of three layers of tissue. The outer serosa layer, the middle muscular layer called myometrium which make the bulky uterine wall composed of 3 layers of smooth muscle and the innermost, composed of specialized mucous membrane, endometrium. The endometrium contains abundant blood supply. It is composed of two layers. These are stratum functionalis that shed during every menstruation and if pregnancy occurs it continues to be site of attachment and nourishment for morrula (fertilized zygote) and the second layer of endometrium is stratum basale that attaches to myometrium.

### **14.2.1.5 Vagina**

A muscle lined tube 8 to 10 c.m long. It is the site where semen deposits during sexual intercourse; it is a canal for menstrual flow and a birth canal during childbirth. It lies behind urinary bladder and rectum & anterior to rectum and anus. Its wall is mainly composed of smooth muscle & fibro-elastic connective tissue. It is lined with mucous membrane containing many rugae. Stratified squamous non-Keratinized epithelium covers the mucosal layer of the vagina.

The mucous that lubricates the vagina comes from glands in the cervix and the acidic environment is because of the fermentation action of bacteria. A fold of vaginal mucosa called hymen that partially blocks the vaginal entrance in virgin.

### **14.2.2 Females External reproductive organs**

This includes mons pubis, labia majora, labia minora, vestibular glands, clitoris and vestibule of vagina, which collectively called **vulva**.

#### **14.2.2.1 The mons pubis**

Mound of fatty tissue covers symphysis pubis. It is covered with hair at puberty.

#### **14.2.2.2 Labia majora**

Labia majora are two longitudinal folds of skin that forms the outer border of vulva. It contains fat, smooth muscle, areolar tissue, sebaceous glands & sensory receptors. At puberty covered with hair.

#### **14.2.2.3 Labia minora**

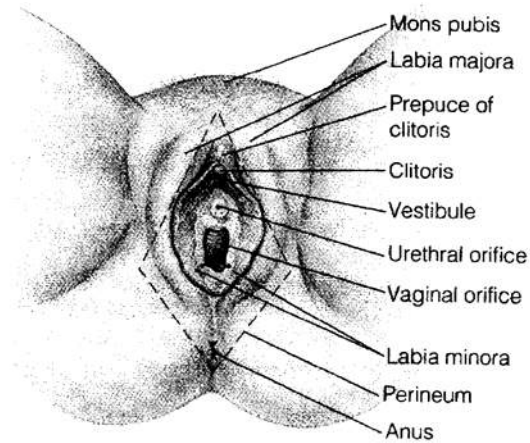
Labia minora is a smaller fold of skin that lies between the labia majora. Labia minora and labia majora surround vaginal & urethral orifices. The labia merge at the top to form the foreskin or prepuce called the *clitoris*.

#### **14.2.2.4 The clitoris**

Clitoris is a small erectile organ at the upper end of vulva below the mons pubis, where the two folds of labia minora meet. Like the penis it contain many nerve endings, hence it is very sensitive part.

#### **14.2.2.5 The vestibule**

Vestibule is a space between the labia minora. Its floor contains the greater vestibular glands and the opening for the urethra & vagina. During sexual arousal the greater and lesser vestibular gland secrete alkaline mucous for lubrication to aid penetration.



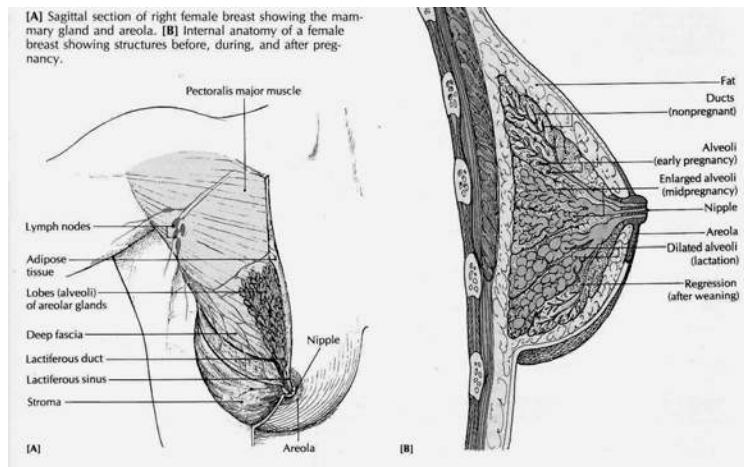
**Figure: 14.10 Vulva** (source: Elaine n. MARIEB, (2000), Essentials of human anatomy and physiology, Addison welsey longman inc., San Francisco, 6<sup>th</sup> Ed)

#### 14.2.2.6 Perineum

Perineum is a diamond shaped region bounded anteriorly by symphysis pubis, posteriorly by coccyx and laterally by ischeal tuberosity.

### 14.3 Mammary Glands

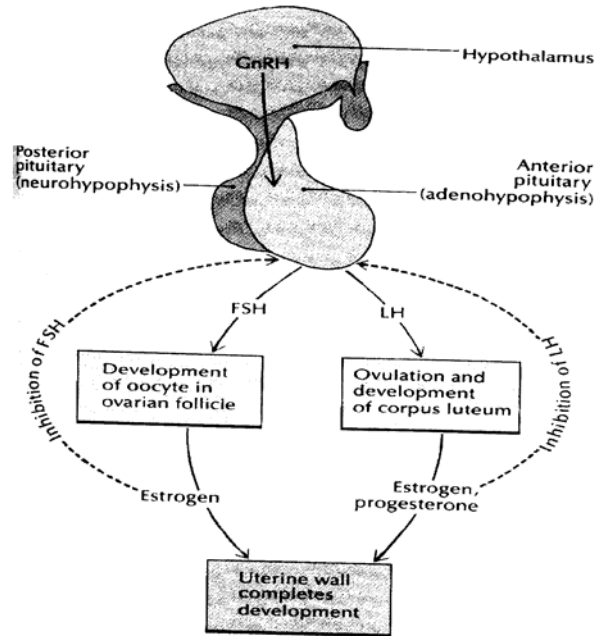
With in the paired breasts of women are modified sweat glands that produce and secrete milk. Each breast extends from the lateral surface of sternum to middle of axilla. It is held in place by suspensory ligaments of breast. The amount of adipose tissue matters the size of the breast not the mammary cells. Each breast is composed of 15-20 lobes of areolar gland that radiate from the nipple. This cluster of glands with lactiferous ducts that carry milk from the gland look like bunches of grapes. **Lactiferous sinuses** are dilated portion of **lactiferous ducts**. **Areola** is the pigmented area around the nipple. It enlarges & darkness during pregnancy.



**Figure: 14.11 Breast and mammary glands** (source: Tortora, G.J. (1995), Principles of human Anatomy and Physiology, Harper Collins, New York, 7<sup>th</sup> Ed, pp 755)

## 14.2 Hormonal regulation

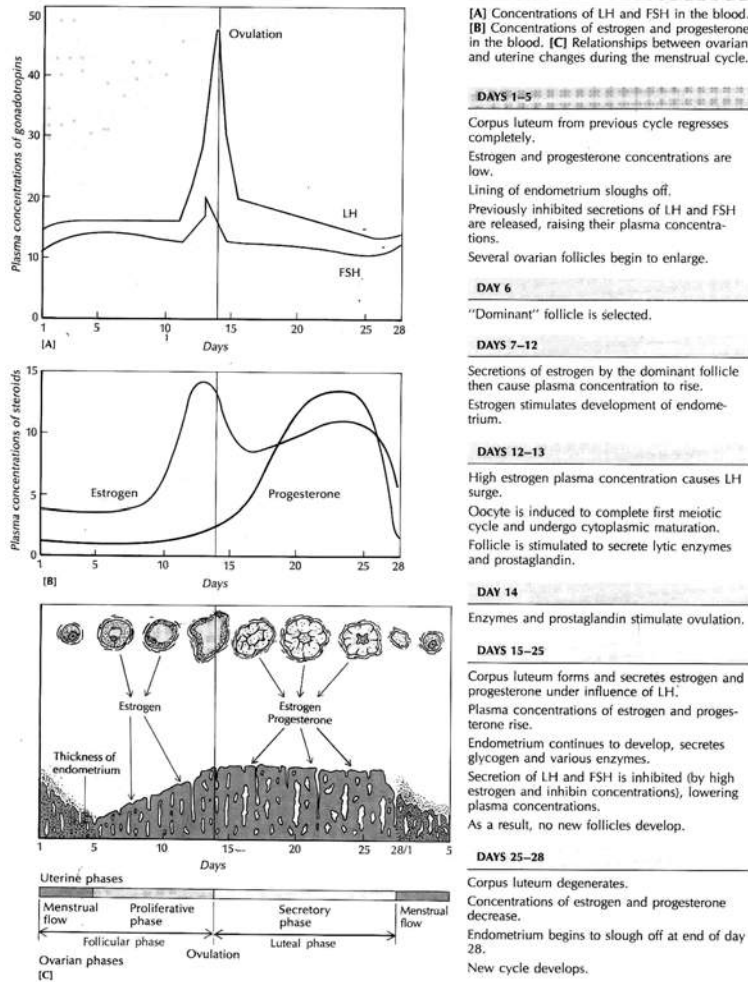
Females are fertile a few days each month by the action of Gonadotrophin Releasing Hormone (GnRH) and FSH & LH. In pregnant women additional hormone called Human Chorionic Gonadotrophin (HCG), which affects uterine and other body metabolism is released by placenta.



**Figure: 14.12 Hormonal regulation of follicle and ovum development**  
 (source: Carola, R., Harley, J.P., Noback R.C., (1992), Human anatomy and physiology, Mc Graw hill inc, New York, 2<sup>nd</sup> ed, pp 925)

## 14.4 The menstrual cycle

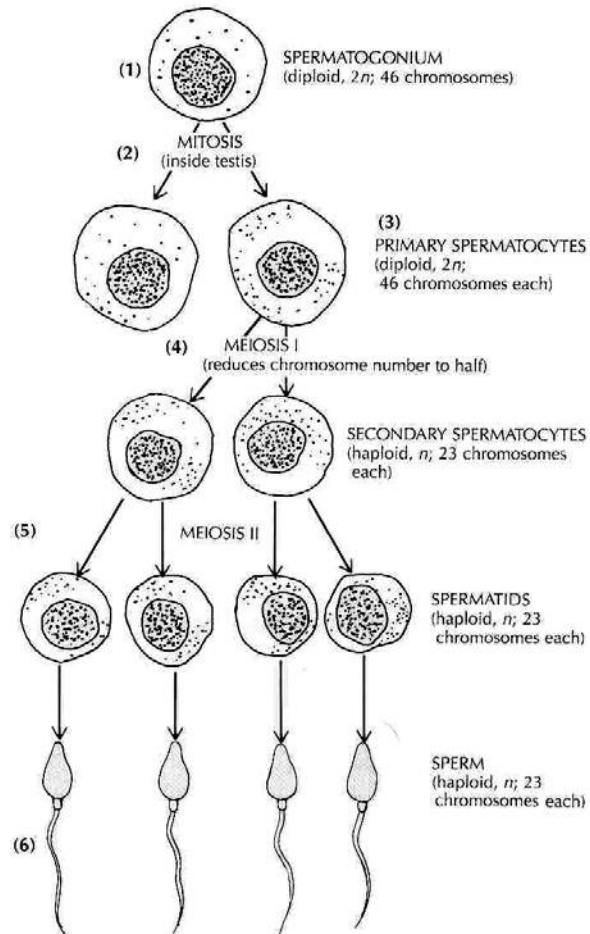
**Table 14.1: Illustration of the menstrual cycle** (source: Carola, R., Harley, J.P., Noback R.C., (1992), Human anatomy and physiology, Mc Graw hill inc, New York, 2<sup>nd</sup> ed, pp 926)



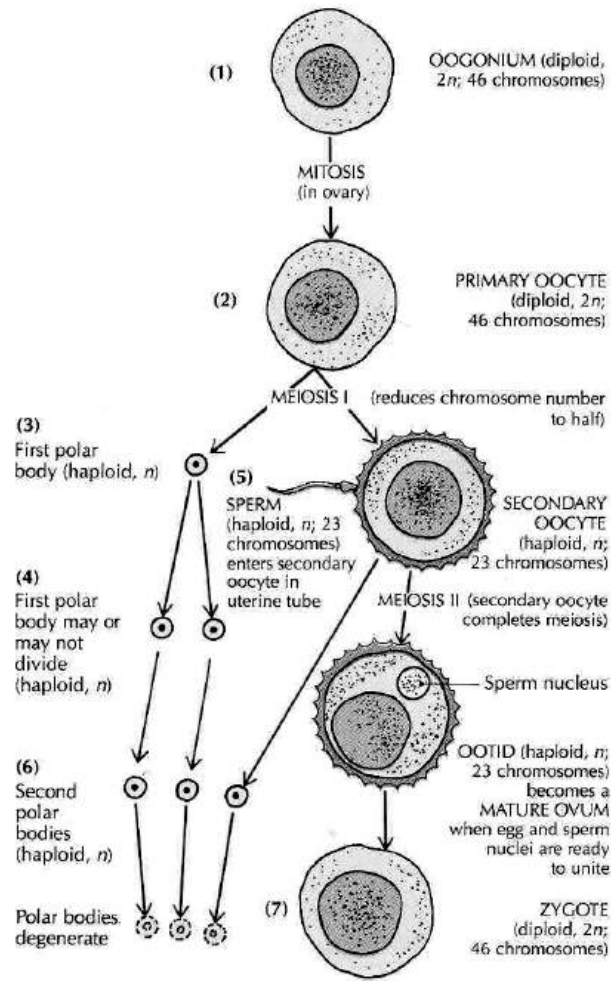


## 14.5 Gametogenesis

Gametogenesis is the process of formation of sex cells. It is said spermatogenesis in male & oogenesis in females. Both involve meiosis, a form of nuclear division.



A



B

**Figure: 14.13 Gametogenesis; A- Spermatogenesis, B- Oogenesis**  
 (source: Carola, R., Harley, J.P., Noback R.C., (1992), Human anatomy and physiology, Mc Graw hill inc, New York, 2<sup>nd</sup> ed, pp 929/30)

## 14.6 Conception

Conception is the process of fertilization and subsequent establishment of pregnancy. Pregnancy begins with fertilization of an ovum and ends with delivery of the fetus after birth. When sperm is deposited in the vagina, the many spermatozoa wriggle about in all direction. Some travel in to the uterus and oviduct to meet the ova. If ova and sperm join this is called fertilization. From the day of fertilization onwards pregnancy starts.

## 14.7 Contraception

Contraception means protection. It has one aim, preventing pregnancy. This aim can be achieved by preventing sperm or ova not to function. It can be achieved by:

- Preventing production
- Preventing meeting of sperm & ova
- Preventing implantation

Several methods are available, but can be grouped in to permanent & temporally methods.

**Permanent methods:** in this type of contraception, once the method is used fertility is not possible. The usual method is surgery. The type of surgery in females is called Tubal-ligation whereby both fallopian tubes are ligated and transmission of

the released ova from the ovary to the uterus is prevented. And in males the surgical intervention for the purpose of contraception is called vasectomy. In this case both vas deferences are cut or ligated and after production the transmission of sperm from the testes to the tip of the penis is prevented.

**Temporary methods:** condoms, tablets, Intra Utern Devices (IUD's), calendar methods and others. These types of contraception are reversible types. This means fertility is possible if the person no longer uses the method.

**Table 14.2: Summary of major reproduction hormones** (source: Carola, R., Harley, J.P., Noback R.C., (1992), Human anatomy and physiology, Mc Graw hill inc, New York, 2<sup>nd</sup> ed, pp 924)

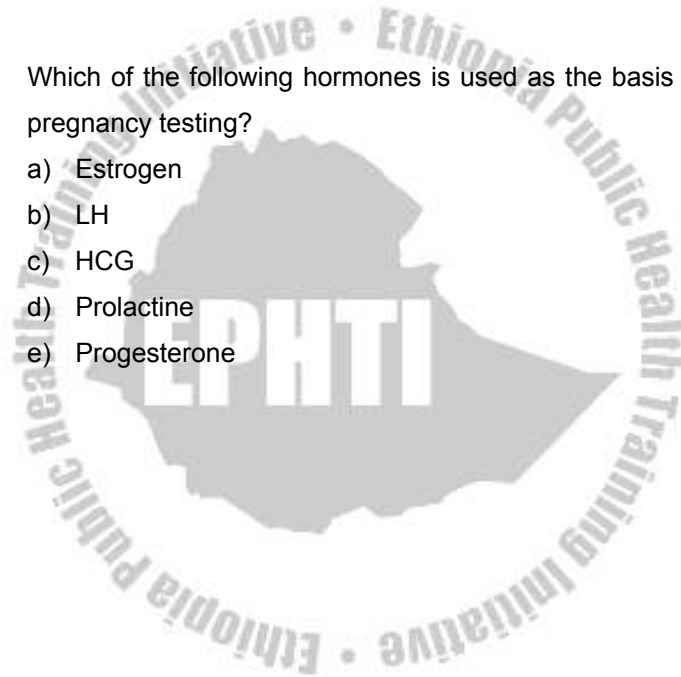
Hormone	Function	Source
FEMALE Estrogen	Stimulates thickening of uterine wall, stimulates maturation of oocyte, stimulates development of female sex characteristics, inhibits FSH secretion, increases LH secretion.	Ovarian follicle, corpus luteum (controlled by FSH)
FSH (follicle-stimulating hormone)	Causes immature oocyte and follicle to develop increases estrogen secretion, stimulates new gamete formation and development of uterine wall after menstruation.	Pituitary gland (controlled by hypothalamus)
GnRH (Gonadotrophin Releasing Hormone)	Controls pituitary secretion.	Hypothalamus

HCG (Human Chorionic Gonadotropin)	Prevents corpus luteum from disintegrating, stimulates estrogen and progesterone secretion from corpus luteum.	Embryonic membranes placenta
LH (luteinizing hormone)	Stimulates further development of oocyte and follicle, stimulates ovulation, increases progesterone secretion, aids development of corpus luteum.	Pituitary gland (controlled by hypothalamus)
Progesterone	Stimulates thickening of uterine wall, stimulates formation of mammary ducts.	Corpus luteum (controlled by LH)
Prolactine	Promotes milk production by mammary glands after child birth	Pituitary gland (controlled by hypothalamus)
<b>MALE</b> FSH	Increases testosterone production, aids sperm maturation	Pituitary gland (controlled by hypothalamus)
GnRH	Controls pituitary secretion.	Hypothalamus
Inhibin	Inhibits FSH secretion	Sustentacular (sertoli) cell of Testes
LH	Stimulates testosterone secretion	Pituitary gland (controlled by hypothalamus)
Testosterone	Increases sperm production, stimulates development of male primary and secondary sex characteristics, and inhibits LH secretion.	Interstitial endocrinocytes (Leydig cells) in testes (controlled by LH)

## Study Question

1. The cells that provide nourishment for maturing sperm are:
  - a) Interstitial cell
  - b) Interstitial endocrinocytes
  - c) Sustentacular cells
  - d) Tube cells
  - e) Nuclear cells
  
2. Which of the following is the function of epididymis: -
  - a) Stores sperm
  - b) Serve as duct system
  - c) Cause peristaltic contraction
  - d) a & b only
  - e) a, b and c
  
3. The corpus luteum secretes
  - a) Estrogen
  - b) Progesterone
  - c) LH
  - d) a & b only
  - e) a, b & c

4. In female, production of FSH is inhibited by
- a) Estrogen
  - b) LH
  - c) Progesterone
  - d) Prolactin
  - e) a & c only
5. Which of the following hormones is used as the basis for pregnancy testing?
- a) Estrogen
  - b) LH
  - c) HCG
  - d) Prolactin
  - e) Progesterone



## GLOSSARY

**Absorption** passage of a substance through a membrane such as skin or mucosa, into blood

**Accessory sex ducts** series of ducts leading sperm from testis out.

**Accessory sex glands** glands that add secretion to sperm.

**Acetylcholine** chemical neurotransmitter

**Actin** contractile protein found in the thin myofilaments of skeletal muscle

**Action potential** nerve impulse

**Active movement** passage of substance across cell membrane using energy

**Afferent** carrying or conveying toward the center (for example, an afferent neuron carries nerve impulses toward the central nervous system)

**Alveolus** one of the millions of tiny air sacs in the lungs through which gases is exchanged between the outside air and the blood.

**Antagonist muscle** those having opposing actions; for example, muscles that flex the upper arm are antagonists to muscles that extend it

**Anastomosis** communication between two structures such as blood vessels

**Anatomy** Study of body structure

**Anatomical position** a starting positional reference



**Antidiuretic hormone (ADH)** Hormone released from the posterior pituitary gland that increases the reabsorption of water in the kidneys, thus decreasing the volume of urine excreted.

**Aorta** large artery that carries blood out of the left ventricle of the heart

**Appendicular skeleton** Part of the skeleton that includes the bones of the upper extremities, lower extremities, shoulder girdle, and hips.

**Arteriole** vessel between a small artery and a capillary

**Artery** vessel that carry blood away from the heart

**Articulations** formation of joints

**Atrium** one of the two upper chambers of the heart

**Autonomic nervous system** division of the human nervous system that regulates involuntary actions

**Axial** towards the midline of the body

**Axon** nerve cell process that transmits impulses away from the cell body

**Buffer system** a weak base or acid in the body that serves as neutralizing agent

**Bile** substance that reduces large fat globules into smaller droplets of fat that is more easily broken down

**Body cavities** spaces in the body holding internal organs

**Body plans** imaginary flat lines dividing the body in to sections.

**Bone cell** cellular part of a bone

**Brain stem** portion of the brain that connects the cerebrum with the spinal cord; contains the midbrain, pons, and medulla oblongata.

**Bronchiole** one of the small subdivisions of the bronchi that branch through the lung

**Bronchus** one of the large air tubes in the lung

**Cancer** cells growing with out normal body control mechanism

**Capillary** microscopic vessel through exchanges take place between the blood and the tissues

**Cartilage** a firm but delicate connective tissue

**Cell** the basic structural and functional unit of the body

**Cell inclusions** divers group of substances produced and stored inside the cell

**Cerebellum** the second largest part of the human brain that plays an essential role in the production of normal movements

**Cerebral cortex** a thin layer of gray matter made up of neuron dendrites and cell bodies that compose the surface of the cerebrum

**Cerebrum** the largest and upper part of the human brain that controls consciousness, memory, sensations, emotions, and voluntary movements

**Chemoreceptor** receptor that detects chemical changes

**Coagulation** clotting, as of blood

**Connective tissue** tissues specialized for connecting and supporting the body

**Coronary** referring to the heart or to the arteries supplying blood to the heart

**Corpus luteum** Yellow body formed from ovarian follicle after ovulation; produces progesterone.

**Chyme** partially digested food mixture leaving the stomach

**Chyle** milky-appearing fluid absorbed into the lymphatic system from the small intestine. It consists of lymph and droplets of digested fat.

**Colon** intestine

**Conception** the process of fertilization and subsequent establishment of pregnancy

**Contraception** protection against pregnancy

**Cortex, renal** the outer, red part of the kidney

**Cortical nephron** the nephron locating inside the renal cortex

**Cranium** a bony cavity holding the brain

**Cytoplasm** substances surrounding organelle out of the nucleus

**Defecation** act of eliminating undigested waste from the digestive tract

**Deglutition** swallowing

**Dendrite** branching or tree like; a nerve cell process that transmits impulse towards the body

**Dermis** part of the skin next beneath to epidermis

**Diaphragm** dome-shaped muscle under the lungs that flattens during inhalation; membrane or structure that serves to separate

**Diaphysis** the shaft of long bone

**Diastole** relaxation phase of the cardiac cycle

**Diencephalons** “between” brain; parts of the brain between the cerebral hemispheres and the mesencephalon or midbrain

**Diffusion** Movement of molecules from a region where they are in higher concentration to a region where they are in lower concentration.

**Digestion** the break down of food materials either mechanically (that is chewing) or chemically (that is digestive enzymes)

**Directional terms** terms used in anatomy to state direction of body parts

**Duodenum** the first subdivision of the small intestine where most chemical digestion occurs

**Effector** responding organ; for example, voluntary and involuntary muscle, the heart, and glands

**Efferent** carrying from, as neurons that transmit impulses from the central nervous system to the periphery; opposite of afferent

**Electrolytes** compounds that dissociate in to ions when in solution

**Emulsify** in digestion, when bile breaks up fat

**Endocardium** lining of the heart

**Endocrine** referring to a gland that releases its secretion directly into the bloodstream

**Endothelium** epithelium that lines the heart, blood vessels, and lymphatic vessels

**Endosteum** connective tissue layer covering the inner hollow of bone

**Erythrocyte** red blood cells

**Enzyme** biochemical catalyst allowing chemical reaction to take place Epidermis the outer layer of skin

**Epiglottis** leaf-shaped cartilage that covers the larynx during swallowing

**Epimysium** sheath of fibrous connective tissue that encloses muscle

**Epinephrine** adrenaline; secretion of the adrenal medulla

**Epithelial** tissue tissues covering body surface and lining cavities

**Esophagus** the muscular, mucus-lined tube that connects the pharynx with the stomach; also known as the food pipe

**Essential organs** reproductive organs that must be present for reproduction to occur and are known as gonads

**Endosteum** Epithelium that lines the heart, blood vessels, and lymphatic vessels.

**Epiphysis** End of a long bone.

**Epiphysial** plate a plate between diaphysis and epiphysis

**Eponychem** thin flap of skin covering the proximal end of the nail

**Extra cellular fluid** all fluid existing out of a cell

**Filtrate** the primary filtered substance in the renal tubule

**Fibrin** blood protein that forms a blood clot

**Follicle-Stimulating Hormone (FSH)** Hormone produced by the anterior pituitary that stimulates development of ova in the ovary and spermatozoa in the testes

**Fontanelle** Area in the infant skull where bone formation has not yet occurred; "soft spot"

**Foreskin** a loose-fitting, retractable casing located over the glans of the penis; also known as the prepuce

**FSH** See Follicle-stimulating hormone

**Gametogenesis** the process of formation of sex cell

**Glandular tissue** forming the secretory portion of a gland

**Gamete** Reproductive cell; ovum or spermatozoon.

**Ganglion** collection of nerve cell bodies located outside the central nervous system

**Haemoglobin** iron-containing protein in red blood cells that functions mainly to transport oxygen

**Hematocrit** test that measures the volume percentage of red blood cells in whole blood

**Hemolysis** rupture of red blood cells

**Hilus** Area where vessels and nerves enter or leave an organ

**Hormone** secretion of an endocrine gland

**Hydrolysis** splitting of large molecules by addition of water, as in digestion

**Hydrostatic pressure** a pressure exerted by a fluid on the side of the surface

**Hypodermis** the layer of connective tissue between dermis and the deeper tissue

**Hyponychium** thin flap of skin covering the under surface of nail

**Hypothalamus** portion of the floor lateral wall of the third ventricle of the brain

**Hypoxia** reduced oxygen supply to the tissues

**Insertion** attachment of a muscle to the bone that it moves when contraction occurs (as distinguished from its origin)

**Intracellular fluid** a fluid inside the cell

**Intervertebral discs** cartilaginous structure between the vertebral bones

**Juxta medullary nephron** nephrons whose tubule extend to the medulla of the kidney

**Lacteal** a lymphatic vessel located in each villus of the intestine; serves to absorb fat materials from the chyme passing through the small intestine

**Larynx** voice box; structure between the pharynx and the trachea that contains the vocal cords

**Leukaemia** malignant blood disease

**Leukocyte** white blood cells

**Lung** one of the two organs of respiration

**Luteinizing hormone** Hormone produced by the anterior pituitary that induces ovulation and formation of the corpus luteum in females; in males it stimulates cells in the testes to produce testosterone and is called interstitial cell-stimulating hormone (ICSH).

**Lunula** the whitish proximal part of the nail

**Mammary gland** referring to breast

**Mastication** chewing

**Mediastinum** region between the lungs and the organs and vessels it contains

**Medulla oblongata** the lowest part of the brain stem; an enlarged extension of the spinal cord; the vitals centers are located within this area

**Medulla, renal** the inner part of kidney

**Meiosis** nuclear division in which the numbers of chromosomes are reduced to half their original number; produce gametes

**Menarche** beginnings of the menstrual function

**Meninges** fluid containing membranes surrounding the brain and spinal cord

**Menustration** a monthly bleeding form the female genitalia

**Metaphysis** part of the bone between diaphysis and epiphysis

**Midbrain** one of the three parts of the brain stem

**Mitochondria** Cell organelles that manufacture ATP with the energy released from the oxidation of nutrients



**Mitosis** indirect cell division involving complex changes in the nucleus

**Mons pubis** skin covered pad of fat over the symphysis pubis in the female

**Mucus membrane** a membrane that line body cavities opening to the exterior

**Muscle tissue** a tissue forming the muscle

**Murmur** abnormal heart sound

**Myloid tissue** a fatty tissue inside spongy bone

**Myocardium** middle layer of the heart; heart muscle

**Myometrium** muscle layer in the uterus

**Myosin** contractile protein found in the thick filaments of skeletal muscle

**Nephron** the functional part of the kidney

**Nerve** collection of nerve fibers

**Nerve impulse** signals that carry information along the nerves

**Nervous tissue** a tissue specialized for nerve impulse conduction

**Neurotransmitter** chemicals by which neurons communicate

**Oocyte** immature stage of the female sex cell

**Orbit** the socket of the eye

**Origin** the attachment of a muscle to the bone, which does not move when contraction occurs, as distinguished from the insertion

**Organelle** Specialized subdivision within a cell

**Osmotic pressure** a pressure exerted by pure water on a surface

**Osmosis** Movement of water through a semi-permeable membrane

**Osseous tissue** a bone tissue

**Ossicles** bones of the inner ear

**Ossification** Process of bone formation.

**Ovaries** female gonads that produce ova (sex cells)

**Ovulation** the process of releasing ovum from ovary to the fallopian tube

**Oxygen debt** continued increased metabolism that occurs in a cell to remove excess lactic acid that resulted from exercise

**Passive movement** a movement across cell membrane without the use of energy

**Physiology** study of the function of living organisms

**Penis** forms part of the male genitalia; when sexually aroused, becomes stiff to enable it to enter and deposit sperm in the vagina

**Pericardium** fibrous sac lined with serous membrane that surrounds the heart

**Perichondrium** a connective tissue layer surrounding a cartilage

**Perineum** pelvic floor; external region between the anus and genital organs

**Periosteum** connective tissue membrane covering a bone

**Peristalsis** wavelike, rhythmic contractions of the stomach and intestines that move food material along the digestive tract

**Peritoneum** large, moist, slippery sheet of serous membrane that lines the abdominopelvic cavity (parietal layer) and its organs (visceral layer)

**Pharynx** throat; passageway between the mouth and the oesophagus

**Pituitary (hypophysis)** endocrine gland located under and controlled by the hypothalamus; releases hormones that control other glands

**Plasma** liquid portion of the blood

**Plasma membrane** a membrane bounding the entire cell

**Platelet** cell fragment that forms a plug to stop bleeding and acts in blood clotting

**Pleura** serous membrane that lines the pleural cavity and covers the lungs

**Plexus** network of vessels or nerves

**Pons** the part of the brain stem between the medulla oblongata and the midbrain

**Prime mover** the muscle responsible for producing a particular movement

**Prostaglandin** group of hormones, produced by many cells of the body, that has a variety of effects

**Pulse** wave of increased pressure in the vessels produced by contraction of the heart

**Receptor** peripheral beginning of a sensory neuron's dendrites

**Reflex** involuntary action

**Renal pelvis** a large space in the kidney formed by the extension of the expanded portion of the ureter

**Renal tubule** a series of ducts conducting urine from the point of formation to minor calyx

**Respiration** exchange of oxygen and carbon dioxide between the outside air and body cells

**Saliva** secretion of the salivary glands; moistens food and contains an enzyme that digests starch

**Sarcomere** contractile unit of muscle; length of a myofibril between two Z bands

**Semen** male reproductive fluid

**Septum** dividing wall, as between the chambers of the heart

**Serosa** Serous memberane; epithelial membrane that secretes a thin, atery fluid

**Serum** liquid portion of blood without clotting factors; liquid that remains after blood has clotted

**Sinusoid** Enlarged capillary that serves as a blood channel

**Skull** a structure formed of cranial and facial bones

**Sperm** the male spermatozoon; sex cell

**Spermatozoon** male reproductive cell or gamete; pl., spermatozoa

**Sphincter** ring-shaped muscle

**Steroid** category of lipids that includes the hormones of the sex glands and the adrenal cortex

**Subcutaneous glands** are oil producing glands

**Sudoriferous glands** are sweat glands

**Surfactant** substance in the alveoli that prevents their collapse by reducing surface tension of the fluids within  
Suture immovable joints between cranial bones

**Synapse** junction between adjacent neurons

**Synergist** muscles that assists a prime mover

**Systole** contraction phase of the cardiac cycle

**Sphincter** Muscular ring that regulates the size of an opening

**Sudoriferous** Producing sweat; referring to the sweat glands

**Synovial** Pertaining to a thick lubricating fluid found in joints, bursae, and tendon sheaths; pertaining to a freely movable (diarthrotic) joint

**Target tissue** tissue that is capable of responding to a specific hormone

**Tendon** Cord of fibrous connective tissue that attaches a muscle to a bone

**Testis** Male reproductive gland; pl., testes (TES-teze)

**Testosterone** Male sex hormone produced in the testes; promotes the development of male characteristics

**Thalamus** located just above the hypothalamus; its functions are to help produce sensations, associate sensations with emotions, and play a part in the arousal mechanism

**Thorax** Chest; adj., thoracic (tho-RAS-ik)

**Tissue** Group of similar cells that performs a specialized function

**Tone** partially contracted state of muscle

**Trachea** windpipe; tube that extends from the larynx to the bronchi

**Tract** bundle of neuron fibers within the central nervous system

**Trigone** a triangularly arranged area inside the urinary bladder

**Urine** Liquid waste excreted by the kidneys

**Urination** the process of voiding urine

**Uterus** Muscular, pear-shaped organ in the female pelvis within which the fetus develops during pregnancy.

**Uterine tube/fallopian tube** a tube leading from ovary to uterus

**Vagina** Lower part of the birth canal that opens to the outside of the body; female organ of sexual intercourse

**Valve** structure that keeps blood

**Vascular tissue** a fluid tissue constituting blood

**Vasectomy** Surgical removal of part or all of the ductus (vas) deferens; usually done on both sides to produce sterility

**Vein** vessel that carries blood toward the heart

**Vena cava** one of the two large veins that carry blood into the right atrium of the heart

**Ventilation** movement of the air into and out of the lungs

**Ventricle** cavity or chamber; one of the two lower chambers of the heart

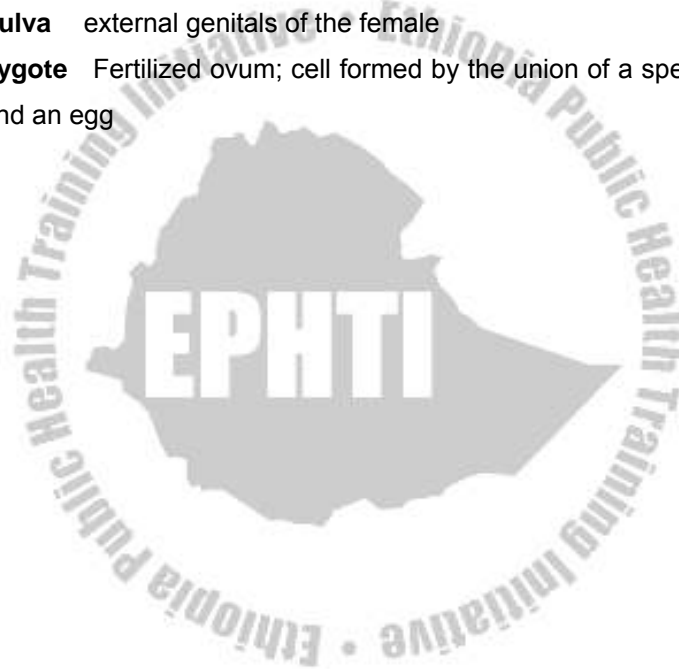
**Venule** vessel between a capillary and a small vein

**Vertebra** A bone of the spinal column; pl., vertebrae (VER-the-bre)

**Villi** finger like folds covering the plicae of the small intestine

**Vulva** external genitals of the female

**Zygote** Fertilized ovum; cell formed by the union of a sperm and an egg



**Answer to the study questions:**

**CHAPTER ONE:**

1. C
2. C
3. B
4. B
5. C

**CHAPTER FOUR**

1. D
2. E
3. E
4. E
5. A

**CHAPTER TWO**

1. A
2. A
3. C
4. A
5. C

**CHAPTER FIVE**

1. E
2. B
3. B
4. D
5. E

**CAPTER THREE**

1. C
2. B
3. D
4. B
5. C

**CHAPTER TWELVE**

1. B
2. A
3. D
4. D
5. E




**CHAPTER THIRTEEN**

1. A
2. E
3. E
4. E
5. D

**CHAPTER FOURTEEN**

1. C
2. E
3. D
4. E
5. C



## References:

1. Carola, R., Harley, J.P., Noback R.C., (1992), Human anatomy and physiology, Mc Graw hill inc, New York, 2<sup>nd</sup> ed.
2. David T. Lindsay, 1996, Functional human anatomy, Mosby, St. Louis
3. De Loris Wenzel and David, (1996), T. Lindawy Study guide, Functional human anatomy, St. Louis, Mosby.
4. Elaine n. MARIEB, (2000), Essentials of human anatomy and physiology, Addison welsey longman inc., San Francisco, 6<sup>th</sup> ed.
5. Grollman Sigmund, (1969), The human body it's structure and physiology, London, The Macmillan company, 2<sup>nd</sup> ed.
6. Jackson, M., Shella (1986), Anatomy and Physiology for Nurses, 9<sup>th</sup> ed.
7. John Bullock & et.al. (1995), NMS Physiology, Lipincott Williams and wilkins co., Baltimor, 3<sup>rd</sup> ed.

8. Lumley, J.S.P, J.L. Craven and J.T. Atiken (1980), Essential Anatomy and Some Clinical Application, 3<sup>rd</sup> edition.
9. Memmler, Ruth Lundeen and Dena Lin Wood (1987), The Human Body in Health and Disease, Lippincott, Philadelphia, 6th ed.
10. Memmler, Ruth Lundeen, Barbara Jansen Cohen and Dena Lin Wood (1996), The Human Body in Health and Disease, Lippincott, Philadelphia, 8th edition.
11. Romanes, G.J. (1992), Cunningham's manual of practical anatomy, vol-1/2, Thorax and Abodomen, England, ELBS, 5<sup>th</sup> ed.
12. Seeley Stephens, (1995), Anatomy and physiology, St. louis, Mosby, 3<sup>rd</sup> ed.,
13. Steven, I. Subotanick, (1999), Sports medicine of lower extremities, Churchillivingsten, New York, 2<sup>nd</sup> Ed.
14. Thibodeau, Gary A. and Kevin T. Patton (1992), The Human Body in Health and Disease.

15. Tortora, G.J. (1987), Principles of Anatomy and Physiology, Harper Collins, New York, 4<sup>th</sup> Ed.
16. Tortora, G.J. (1995), Principles of human Anatomy and Physiology., Harper Collins, New York, 7<sup>th</sup> ed
17. Winwood, R.S. (1985), Anatomy and Physiology for Nurses, 6<sup>th</sup> edition.

