



We would be interested to hear your opinion about this publication. You can let us know at <http://www.kingfishergroup.nl/questionnaire/>

Anatomy
*Morphological Anatomy
from a Phenomenological
Point of View*

Guus van der Bie MD



About the Louis Bolk Institute

The Louis Bolk Institute has conducted scientific research to further the development of organic and sustainable agriculture, nutrition, and health care since 1976. Its basic tenet is that nature is the source of knowledge about life. The Institute plays a pioneering role in its field through national and international collaboration by using *experiential knowledge* and by considering data as part of a greater whole. Through its groundbreaking research, the Institute seeks to contribute to a healthy future for people, animals, and the environment. For the Companions, the Institute works together with the Kingfisher Foundation.

Publication number GVO 03

ISBN/EAN: 978-90-74021-30-1

Price € 10

Postage € 7,50

KvK 41197208

Triodos Bank 212185764

IBAN: NL77 TRIO 0212185764

BIC code/Swift code: TRIONL 2U

For credit card payment visit our website at

www.louisbolk.nl/companions

For further information:

Louis Bolk Institute

Hoofdstraat 24

NL 3972 LA Driebergen, Netherlands

Tel: (+31) (0) 343 - 523860

Fax: (+31) (0) 343 - 515611

www.louisbolk.nl

g.vanderbie@kingfishergroup.eu

Colofon:

©Louis Bolk Instituut, 2002, reprint 2012

Cover: www.fingerprint.nl

Coversculpture: Discobolus of Monnot, Capitol, Rome

Translation: Sandy Reijnhart

LOUIS BOLK
I N S T I T U T E



Anatomy

*Morphological Anatomy
from a Phenomenological Point of View*

Guus van der Bie MD

BOLK'S COMPANIONS
FOR THE STUDY OF MEDICINE

About the Author

Guus van der Bie MD (1945) worked as a lecturer at the Department of Medical Anatomy and Embryology at Utrecht State University, Holland from 1967 to 1976. Next to his practice as a general practitioner since 1976, he continued to educate physicians and therapists, and medical students at Utrecht State University and the University of Witten/Herdecke, Germany. He is a member of the Medical Section of the School of Spiritual Science at the Goetheanum, Dornach, Switzerland.

About the Project

The project *Renewal of Medical Education* aims to produce Companions that demonstrate how the insights of current biomedical science can be broadened by using the Goethean phenomenological method. This method innovates current concepts and expands the understanding of biochemical, physiological, psychological, and morphological factors in living organisms and their development in time and space, and in health, illness, and therapy. The project is commissioned by the Kingfisher Foundation, which aspires the development, application, and publication of the Goethean phenomenological research method in the widest

sense, to complement and innovate the accepted scientific view and research method.

BOLK'S COMPANIONS FOR THE STUDY OF MEDICINE complement current medical education, specifically disclosing human qualities in the fundamental biomedical sciences of today.

BOLK'S COMPANIONS FOR THE PRACTICE OF MEDICINE contribute to a scientific phenomenological basis for integrative medicine and integral psychiatry.

Contents

Acknowledgments	8
Preface	9
1. Introduction	10
2. General Aspects concerning the Module Morphological Anatomy	11
2.1. The Anatomical Approach	11
2.2. The Existence of a Blueprint	12
2.3. The Reality of the Blueprint	12
2.4. About the Module	13
3. Morphological Characteristics based on the Skeleton	14
3.1. Introduction	14
3.1.1. The Shape of the Skull	14
3.1.2. The Desmoid and Endochondral Ossification Centers of the Skull	15
3.1.3. Ossification Process of the Neurocranium	17
3.1.4. Joining of Cranial Bones: Synostoses and Sutures	18
3.1.5. The Exoskeleton	19
3.1.6. Morphological Characteristics of the Head	20
3.2. The Limbs	21
3.2.1. The Form of the Limbs	21
3.2.2. The Dynamic Morphology of the Extremities	22
3.2.3. Enchondral Ossification	22
3.2.4. The Ossification of the Long Bones	22
3.2.5. The Connection between the Skeletal Parts of the Long Bones: The Joints	24
3.2.6. The Divergent Configuration of the Long Bones	25
3.2.7. The Endoskeleton	26
3.2.8. Form and Movement	27
3.2.9. Morphological Characteristics of the Extremities	27
3.3. The Thorax	28
3.3.1. The Form of the Torso	28
3.3.2. The Rhythmic Structure of the Thorax: Repetition and Metamorphosis	29
3.3.3. The Bony Connections of the Thorax and the Spinal Column	29
3.3.4. From Exoskeleton to Endoskeleton	30
3.3.5. Morphological Characteristics of the Thorax	31
3.4. Summary and Conclusions	32
3.5. Goethean Aspects	32
3.5.1. Form and Dynamic	32
3.5.2. Centripetal Dynamic and the Spherical Form	33

3.5.3.	Centrifugal Dynamic and the Radial Form	35
3.5.4.	Rhythmical Dynamic and Rhythmical Form	36
3.6.	Once again, the Blueprint	37
4.	The Morphology of the Spinal Column	38
4.1.	Introduction	38
4.2.	Metamorphosis in the Spinal Column	38
4.2.1.	The Blueprint of the Vertebrae in Relation to the Ribs	38
4.2.2.	Cervical Region	40
4.2.3.	Lumbar and Sacral Region	41
4.2.4.	Thoracic Region	42
4.3.	Goethean Aspects	42
4.3.1.	Morphological Characteristics of the Spinal Column	42
4.3.2.	Morphological Characteristics of the Ribs	43
5.	The Morphology of the Nervous System	44
5.1.	Introduction	44
5.2.	The Central Nervous System	44
5.2.1.	Early Development	44
5.2.2.	The Telencephalon	45
5.2.3.	The Diencephalon	47
5.2.4.	The Cerebellum	47
5.2.5.	Mesencephalon, Metencephalon, and Myelencephalon	47
5.3.	The Peripheral Nervous System	48
5.3.1.	Radial Structure and Plexus Formation	48
5.4.	The Spinal Cord	49
5.4.1.	Introduction	49
5.4.2.	The Segmental Structure of the Spinal Nerves	49
5.5.	Nervous System and Consciousness	50
5.5.1.	The Consciousness of the Head	50
5.5.2.	The Consciousness of the Metabolic Organs, the Skeleton, and the Muscles	50
5.5.3.	The Consciousness of the Rhythmic Organs	51
5.6.	Goethean Aspects	51
5.6.1.	The Intracranial Nervous System: Sphere and Plane	51
5.6.2.	The Peripheral Nervous System: Radial Structure	52
5.6.3.	The Spinal Cord: the Rhythmic nervous System	52



6. The Morphology of the Airways	54
6.1. Introduction	54
6.2. Development of the Airways	54
6.2.1. The Paranasal Sinuses	55
6.2.2. The Alveolar Areas of the Lung	56
6.2.3. The Trachea and the Bronchial Tree: Rhythmic Air	57
6.2.4. The Larynx	57
6.3. Goethean Aspects	58
6.3.1. Intracranial Air: Spherical Form and Centripetal Dynamic	58
6.3.2. Alveolar Air: Centrifugal (Divergent) Dynamic	58
6.3.3. Rhythmic Air Movements	59
7. The Morphology of the Digestive Tract	60
7.1. Introduction	60
7.2. The Foregut: Digestion and Perception	60
7.2.1. The Digestive Organs	60
7.2.2. The Pharyngeal Gut	61
7.2.3. The Perception of Food	61
7.3. The Hindgut	62
7.3.1. Stasis, Absorption, and Bacterial Colonization	62
7.4. The Midgut	62
7.4.1. The Rhythmical Aspect	62
7.5. Goethean Aspects	63
7.5.1. Introduction	63
7.5.2. The Foregut	64
7.5.3. The Hindgut	64
7.5.4. The Midgut	64
8. Comparative Morphology	65
8.1. Introduction	65
8.2. The Comparative Morphology of the Head	65
8.2.1. The Form of the Head	65
8.2.2. Comparative Morphology of the Position and Carriage of the Head	66
8.3. The Comparative Morphology of the Limbs	67
8.3.1. Morphology of the Form of the Limbs	67
8.3.2. The Position of the Limbs	68
8.3.3. Quadrupedal and Bipedal	68
8.4. The Thorax	68
8.4.1. Comparative Morphology of the Form of the Thorax	68
8.4.2. Comparative Morphology of the Position of the Thorax in Relation to Respiration	69

9. Polarization and What is in Between	71
9.1. Introduction	71
9.2. The Head	71
9.2.1. The Neurocranium	71
9.2.2. The Splanchnocranium	72
9.2.3. The Pneumocranium	72
9.2.4. The Large Blood Vessels	73
9.3. The Trunk	73
9.3.1. The Nervous System and the Trunk	73
9.3.2. The Digestive System and the Trunk	73
9.3.3. The Pneumatic Cavity and the Trunk	73
9.4. The Limbs	74
9.4.1. The Polarization of the Extremities	74
9.4.2. The Human Hand and Foot	75
9.4.3. The Difference between Humans and Mammals	76
Literature	77



Acknowledgments

This module was written at the Louis Bolk Instituut, Driebergen Holland. It is a result of the stimulating exchange of ideas with my colleagues F. Amons, A. Bos, W. Schad, E. Schoorel, Chr. van Tellingen, G. Verhaagen, and J. van der Wal. I am most grateful to them for their valuable comments.

This project was made possible financially by gifts from Iona Stichting, Stichting Phoenix, Stichting ter Bevordering van de Heilpedagogie, Mahle Stiftung, and Evidenz Gesellschaft.

Guus van der Bie, Driebergen, November 2002.

Preface

In his book *Lifelines* Steven Rose states: "The challenge to the opponents of biological determinism is that, while we may have been effective in our critique of its reductionist claims, we have failed to offer a coherent alternative framework within which to interpret living processes".

We have the same challenge with regard to morphology. It is imperative to offer a satisfactory alternative framework. In trying to remedy this problem we have striven for two goals: first, to indicate an 'alternative framework' in morphology, and second, to show that the alternative framework opens new possibilities for interpreting morphological facts.

We used a Goethean approach that allows us to position the detailed knowledge of Anatomy in the context of the whole of the organism. In this method, a careful description is followed by portraying the dynamic quality of the studied part, for instance the humerus. Comparison of different parts of the skeleton helps us to see patterns in what we have observed. We become aware of a blueprint that can eventually show us the role the humerus plays in the whole of the skeleton from a dynamic viewpoint.

We chose *the dynamic quality in morphology* for this purpose since it allows us to see coherence in the facts. *The dynamic quality in morphology* can be shown to refer to functional processes in biology.

This results in new concepts in morphology. These new concepts recapture an understanding of morphologic facts in living organisms. This gives us, for instance, a possibility of understanding the relation between consciousness and behavior to the shape of the body.

We hope that this framework will be helpful for medical students, who have to learn and remember many anatomical details.

Experience has taught us that an overview of the whole makes remembering the details easier. We present this module in an effort to aid medical students and others to take in the wonderful world of anatomical morphology and remember it better in later study and work. We want to emphasize that this module does not replace the textbook on anatomy. The information in the module is compact and presupposes the knowledge contained in regular textbooks.

1. Introduction

The module *Morphological Anatomy* in the series 'BOLK'S COMPANIONS FOR THE STUDY OF MEDICINE' is intended for medical students, physicians, paramedics, nurses and others employed in health care. The special character of this series lies in its phenomenological approach to the human organism. This phenomenological approach offers the possibility to develop a vision of the human organism that complements the usual analytic approach. The particular phenomenological method we have chosen, as introduced by Goethe, offers the possibility for a dynamic view of the human organism. By arranging and interpreting the facts in a new way, a different view on the human organism originates which provides novel insights into the significant connections between various morphological details.

The essence of Goethe's method is, fundamentally, based on the participatory attitude of the researcher. Because of this fundamental attitude, the observation is transformed into *empathetic observation* such that the observed object is dynamically perceived. This *dynamic aspect* leads to the introduction of a new, dynamic framework in morphology that can be linked also to dynamic aspects of consciousness. This way of working does not only concern physical phenomena, but also offers leads for investigating the relation between organism and consciousness.

Morphology and psychology can be studied in their relationship to each other based on the phenomenological insights that have been gained. Using a morphological approach, the form, the function and the effect of anatomical structures can be described based on the relation they have to each other.

2. General Aspects concerning the Module Morphological Anatomy

2.1. The Anatomical Approach

The *anatomical approach* of the organism illuminates a tremendous amount of detailed information. The skeleton, the muscles, the senses, the nerves, and the internal organs are laid open and made available for study.

Knowledge of details does not, however, provide us with *insight* into the *form of the organism in its totality* and the topographical relationship and morphological specificity of the various details.*

If, after an anatomical dissection, we want to reassemble the parts we have found into a whole organism, that would only be possible if we have the original form in mind. Knowledge of the details, as such, does not provide any insight into the external form or the *blueprint* of the organism. Someone who has never observed a human organism *in toto* will not be able to come up with a meaningful combination of the separate parts. It appears, therefore, that the blueprint - or the 'Gestalt'- of the organism has, by rights, its own identity and that the details can be seen as additions to that identity.

Knowledge of the whole is the basis for all morphological insights. With the aid of Goethe's methodology one is able to create a cognitive process in which typical morphological characteristics provide an overall insight into the morphology of the whole organism.

* Neither does modern genetics provide us here with an answer to the question of the true nature of morphological structures. The protein chemistry of genetics has no explanation for the macroscopic form of the various parts of the organism or of the organism as a whole.

2.2. The Existence of a Blueprint

Comparative anatomy shows, in a way that is immediately visible, that organisms develop according to a specific blueprint. Thus, the organisms of higher mammals always have a distinguishable head, a torso and limbs. This structure can be found as far back as the fossils, and the **trilobites** even owe their name to this *trichotomy*.

In the head, we find the nervous system concentrated in the form of brains, the limbs are moved by the muscles and the torso contains the internal organs. The *head, torso, and limbs* - the macroscopic form of the mammalian organism - can always be distinguished. This is not exclusive to mammals. Birds, amphibians, reptiles, and many insects display the same blueprint in their organisms.

2.3. The Reality of the Blueprint

In order to be able to recognize the blueprint of an organism, a comparative, descriptive research method is necessary. That research may include a wide range of organisms in order to be able to recognize the similarities and differences in their morphology.

A second possibility is to study the morphological characteristics of the various systems within one organism in order to discover how the blueprint manifests itself within diverse tissue types and organ systems.

In this module, we will, in particular, adhere to the latter method. Our objective is to be able to recognize and describe *generally active morphological dynamics*. Once the general morphological characteristics have been found, the variations in the details of the various systems can be described.

The reality of a blueprint can be derived from macromorphology, the morphology of organs and organisms as a whole. The problem that arises here is that each individual organism is a variation of the blueprint. Therefore, it goes without saying that the blueprint could be rejected in favor of the existence of the individually developing organisms. However, the possibility of a division in, for example, species and families, already demonstrates that morphology has always recognized the existence of general principles of shape and form. For example, the division of the animal kingdom into mollusks, coelenterates, invertebrates,

vertebrates, etc. is an example of the recognition of *species specificity based on morphological characteristics*. The fact that, alongside of the clearly typically formed organisms, there are also morphological 'borderline cases' does not rule out the existence of blueprints.

→ *In this module Morphological Anatomy, we use capita selecta to search for and demonstrate the underlying blueprint of the human organism. A descriptive, phenomenological method is used for this.*

2.4. About the Module

In this module, anatomical/morphological aspects of the human organism are described. It is not our goal here to be as thorough as would be expected of an anatomy textbook. There are a great number of anatomy textbooks and many are of excellent quality. The anatomy subjects discussed here have been selected because of their value in learning about the blueprint that pervades the entire organism and because they lend themselves to a phenomenological approach. This does not imply that other anatomical details or systems would not be suitable for such an approach. A conscious decision has been made for a selection because this is about *teaching the reader to develop his or her phenomenological skills*. We have not limited ourselves to the discussion of only one area of anatomy - for example, the skeleton - because a comparison of the blueprint across various systems provides us with a better idea of what precisely is repeated and what precisely has metamorphosized among these systems. The reader could, of course, do a phenomenological study himself of those anatomical systems that we have not discussed.

3. Morphological Characteristics based on the Skeleton

3.1. Introduction

In many natural history museums, one finds displays of skeletons of existing and extinct animals. For both the educated and the uneducated visitor, the *form of the entire organism* becomes clear from simply looking at the skeleton. This expressiveness and the relationship to the true form is so powerful that even paleontology sees the skeleton as *representative of the form of the entire organism*. In paleontology, reconstructions of organisms are made using skeletons - and parts of skeletons - that have been found. These reconstructions are considered to be extremely reliable because the parts of the skeleton have a relationship to the macroscopic form of the entire organism.

Therefore, the skeleton occupies a unique position among all the organ systems:

*the skeleton is the most characteristic expression of the specific **form** of the entire organism.*

The skeleton forms an extremely reliable basis for a scientific study of the morphology of the human organism. This is why this module begins with a study of the human skeleton.

3.1.1. The Shape of the Skull

Morphologically, the most characteristic portion of the human skull is the spherical, domed crown of the skull. From the eyebrows to the foramen magnum, the neurocranium has, within a certain variation, a nearly perfectly spherical form. The base of the skull and a portion of the maxilla and mandible effortlessly fill in the missing segment of the sphere so that the head *as a whole* (the bones of the neurocranium and the bones of the base of the skull and the face) give the impression of being spherical.

When we study the growth of the skull of a small child up through adulthood (fig. 3.1.), keeping the spherical form in mind, it is striking that the characteristic, spherical form remains intact during the development of the skull. The growth of the skull displays, therefore, a specific growth dynamic: on the inside of the skull, bone disappears while, on

the outside, apposition of bone tissue occurs. This applies, in particular, to the neurocranium. During their development and growth, the cranial bones maintain an equal distance from an imaginary midpoint of a sphere.

The flat bones of the skull, that develop through membranous ossification, provide the growth of the skull as a whole with a dynamic of all-round growth. As appears from figure 3.1., the development of the face also adjusts itself to this dynamic and, therefore, places itself within the morphological dynamic of this spherical development. The human head maintains the characteristic spherical shape from early development until the end of life.

It is striking that only the head - within the blueprint of the body - develops and maintains the spherical form at the macroscopic level during further growth (fig. 3.2.). This aspect becomes particularly clear for the dynamic, comparative view when the development of the skull is compared to that of the extremities (Chapter 3.2.).

3.1.2. The Desmoid and Endochondral Ossification Centers of the Skull

The bones of the *neurocranium* originate primarily through *membranous (desmoid) ossification* or through a combination of desmoid and endochondral ossification, as is the case with the sphenoid bone, the temporal bone and the occipital bone. Of these bones, the parts that belong to the base of the skull tend to be endochondral and those that are a part of the neurocranium tend to be desmoid. The connective tissue around the primitive

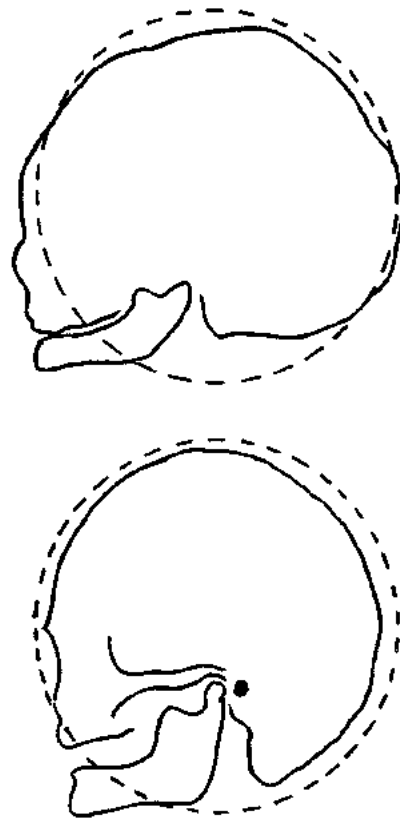


Fig. 3.1. Spherical form of the head during lifetime

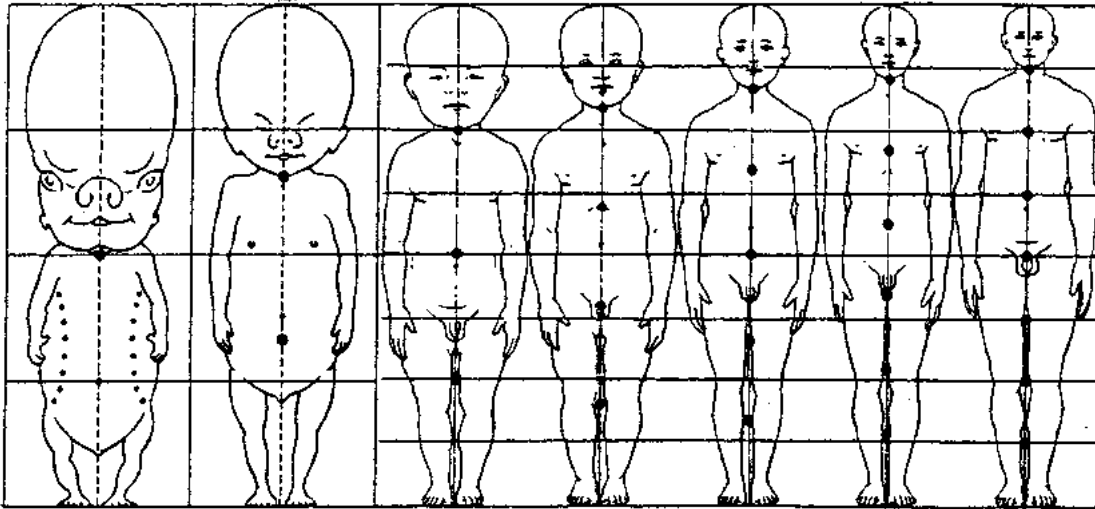


Fig. 3.2. Development of the shape of the body and the head during lifetime (Husemann 1982)

brain functions as the preliminary stage for the desmoid bone that grows in the form of rounded, flat plates of interstitial tissue (fig. 3.4.). The cells for these interstitial plates develop from the *ectoderm (neural crest)* and *not*, as is the case in the remaining bone tissue, from the mesoderm. In membranous ossification, the osteoblasts develop directly from mesenchymal cells. They occupy a special position in the skeletal development process, which originates through endochondral ossification nearly everywhere else. The occipital bone and the elements that will form the base of the skull and the jaw develop from mesodermal tissue. For the base of the skull, that is mesoderm from the paraxial somites and the pharyngeal arches (fig. 3.3.). The osteogenesis of these parts of the skull shows a relationship to the osteogenesis that occurs in the extremities (Chapter 3.2.3.).

3.1.3. Ossification Process of the Neurocranium

The way in which ossification takes place in the bones of the neurocranium is unique in the organism. In every cranial bone, there is a centrally located ossification center. From these ossification centers, primitive bone trabeculae develop centrifugally toward the periphery. The ossification takes place via *radial and centrifugal* growth (fig. 3.4.) in the flat area of the bone primordium. In this form of ossification, we recognize the circle with a midpoint and the accompanying rays as the archetype.

In this form of ossification, we recognize the circle with a midpoint and the accompanying rays as the archetype.

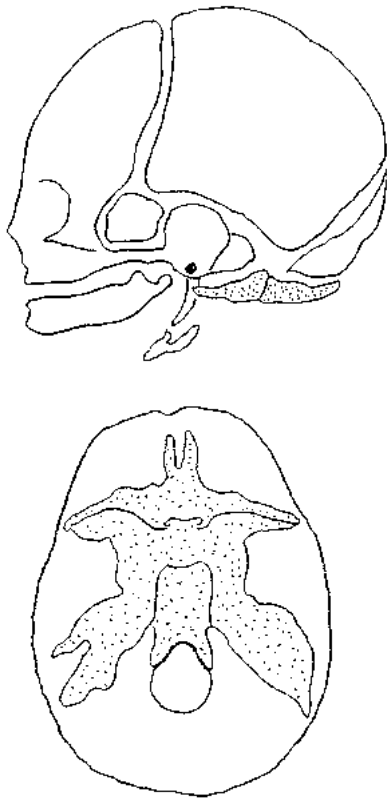


Fig. 3.3. Membranous (white) and endochondral ossification (dotted area) of the skull

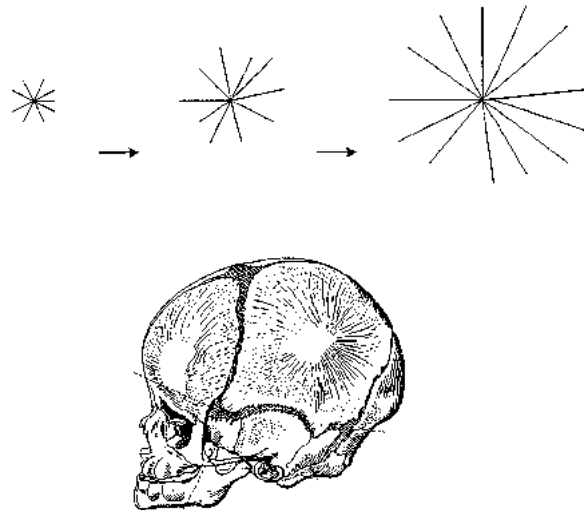


Fig. 3.4. Diagram of radial form of ossification of the cranial bones (Benninghof and Goertler 1964)

3.1.4. Joining of Cranial Bones: Synostoses and Sutures

The joining of various parts of the skeleton to each other varies greatly according to their topography within the body. The most intensive connection of the skeletal parts can be found in the skull, in particular in the neurocranium. In the adult, the frontal bone is made up of one piece, where there were originally two frontal bones. The original suture between the frontal bones (fig. 3.5.) disappears completely. This osteoid connection is, therefore, called a *synostosis*. The connection with the parietal bones is the coronal *suture*. The anatomical construction of the sutures leads to a near immobilization of the bones of the skull with respect to each other. The morphological association that is expressed here can be characterized as a tendency towards *convergence and immobility*.

Joints that allow any free movement between the bones of the skull are not present in the neurocranium. The joints and articulating sections of bone that do occur in the head, such as the temporomandibular joint and the joints of the auricular bones, are derived from the branchial arches and are, in the restricted sense, not seen as part of the development of the cranium.

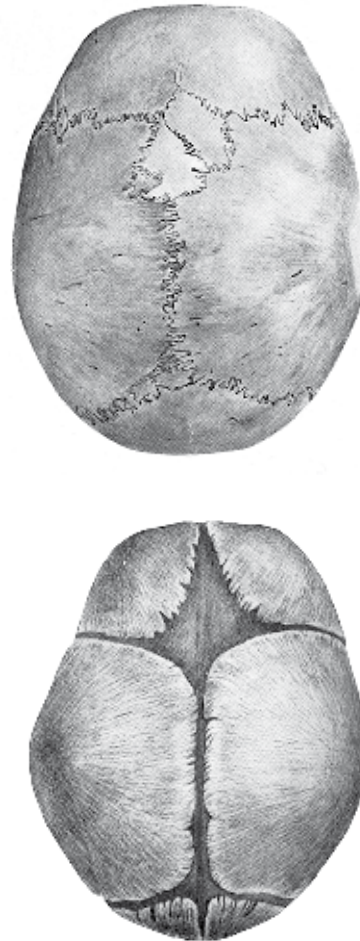


Fig. 3.5. Skull of newborn infant and adult (Woerdeman 1954)

3.1.5. The Exoskeleton

In the head, the brain, the large blood vessels, and the points of origin of the cranial nerves, lie within the neurocranium. The bone lies directly underneath the skin and is immediately observable. The head - in particular, the neurocranium - is, therefore, essentially an *exoskeleton*.

The eye appears to be the exception to this general rule because it is outside the skull but, nonetheless, inside the orbit.

The eyes are, however, not immobile sense organs as are the auditory organ, the organ of balance, and the olfactory organ. Due to the presence of the eye muscles, the eyes have an added element of movement which is comparable to that of the limbs: the eyes can move in the same manner as the arms and legs. In this sense, the eyes are also strongly related to the limbs which follow different morphological laws, since they have endoskeletons. The orbits display characteristics of both cranial and limb systems. The orbit partially encloses the eyes and surround them with bone, as is characteristic of the neurocranium. At the same time, they are not part of the cranial cavity. The orbits also form the points of attachment of the eye muscles as the pelvis does for the muscles of the leg, thereby fulfilling the function of an endoskeleton.

At the base of the skull, we find two structures that function as endoskeleton: the styloid process and the pterygoid process.

Both of these are, however, typically structures that have arisen from the base of the skull, the portion of the skull that originally displayed such a close relationship to the extremities see the desmoid and enchondral ossification (Chapter 3.1.2.). The styloid process and the pterygoid process function as points of attachment for the chewing and swallowing muscles and the muscles of the nasal pharynx. Thus it becomes clear that, within one part of the body - in this case, the head - a polarizing principle can be retraced consistently and in great detail (Chapter 9.).

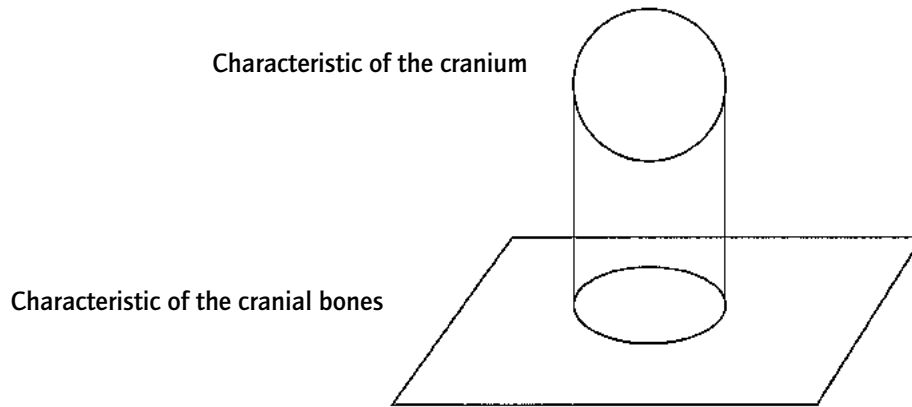


Fig. 3.6. Spheres and planes in the morphology of the cranium

3.1.6. Morphological Characteristics of the Head

The human head has the characteristic *spherical form* that is primarily constructed from the *planes* of the neurocranial bones. This morphological tendency is displayed in many ways. In the macroscopic appearance of the human head, this tendency is immediately observable and finds its maximal expression in the formation of the neurocranium. Microscopically the form of the ossification centers (Chapter 3.1.3.) can be placed within the geometry of planes and spheres, since the circle with its midpoint and corresponding rays can be seen as the projection of the sphere onto a flat surface (fig. 3.6.). The *plane* (mathematically, a sphere with an infinitely long radius) and the *sphere* are the forms that are the foundation of the form and the development of the cranium in the human being.

→ *The plane and the sphere are characteristic for the morphology of the head and the cranium.*

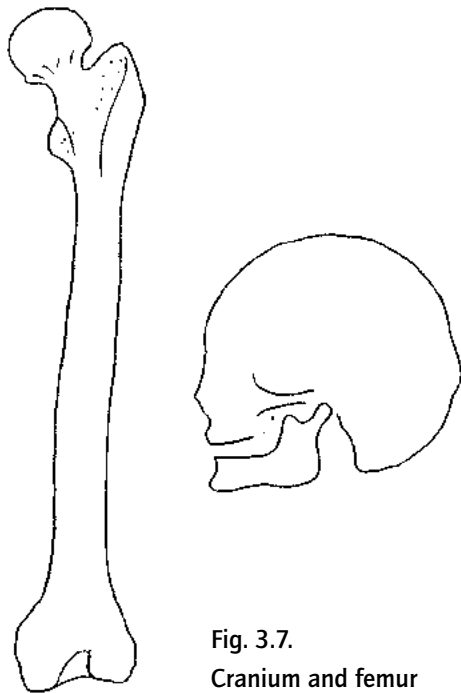


Fig. 3.7.
Cranium and femur

Fig. 3.8. Radial aspect
and parallelism as
characteristic of the
extremities



3.2. The Limbs

3.2.1. The Form of the Limbs

The skeleton of the limbs is primarily formed by the long (cylindrical) bones. The term 'long bone' was perfectly chosen by ancient anatomists. An upper arm or an upper leg is, however, hardly tubular in the true meaning of the word. It is clear that the ancient anatomists chose their nomenclature based on a natural feeling for the morphological dynamic. Long bones have a *radial and parallel structure*, are hollow and have, when cross-sectioned, a nearly circular shaft.

When compared with the cranium, the differences in morphological characteristics between the cranium and the long bones are immediately apparent (fig. 3.7).

3.2.2. The Dynamic Morphology of the Extremities

The shape of the long bones displays a completely different dynamic than the shape of the cranium. The form of the cranium has the characteristic of a sphere, the long bones have a *radial and parallel* structure. Just as the cranium is not a perfect sphere, neither are the long bones perfectly radial. One must, therefore, use the term *morphological characteristic*. In those places where several bones in the arm or leg are positioned next to each other, there is a clear parallel aspect: the bones of the lower leg, the forearm, the metacarpal bones and metatarsal bones, the fingers, and the toes run practically *parallel* to each other (fig. 3.8.).

→ *The characteristic of the long bones is that they are radial in form and run parallel to each other*

3.2.3. Enchondral Ossification

The long bones are created by the ossification of *cartilaginous skeleton*, which functions as the precursor of the definitive skeleton. It is of *mesodermal* origin and the ossification occurs by the replacement of cartilage by bone. In enchondral ossification, the mesoderm first develops into cartilage and then into bone (in the neurocranium, mesenchyme from the neural crest is converted directly into bone).

3.2.4. The Ossification of the Long Bones

The ossification of the long bones occurs from two ossification centers: the epiphyseal ossification centers in the proximal and distal parts of the bone and the ossification from the periost of the diaphysis. Between the epiphysal centers and the diaphysis are ring-shaped discs of cartilage (the epiphyseal plates) that continue to produce cartilage for a long period of time.

The bone spicules that originate from enchondral ossification are *parallel* and are situated

lengthwise in the direction of the bone. The bone increases in thickness because it is built up peripherally and is dissolved in the center of the shaft such that the bone marrow cavity is created. This type of skeletal forming has a direct connection with the impact of gravity on the organism. The morphology and the degree of calcification of the long bones are, to a great degree, determined by the effect of gravity. Research on the structure of the bone spicules in relation to the effect of gravity is unequivocal in this. Bone spicules are formed in accordance with the lines of gravity that are operative in the skeleton (fig. 3.9.). In a weightless situation, the skeleton of the torso and the extremities is particularly threatened by decalcification because of the effect of insufficient gravity.

Enchondral ossification of the skeletal bones in the head also occurs in that portion of the cranium that develops from the branchial arches and the paraxial sclerotomes (fig. 3.3.). The architecture of the bone spicules in this portion of the skeleton displays the same characteristics as the architecture of the extremities (fig. 3.10.).

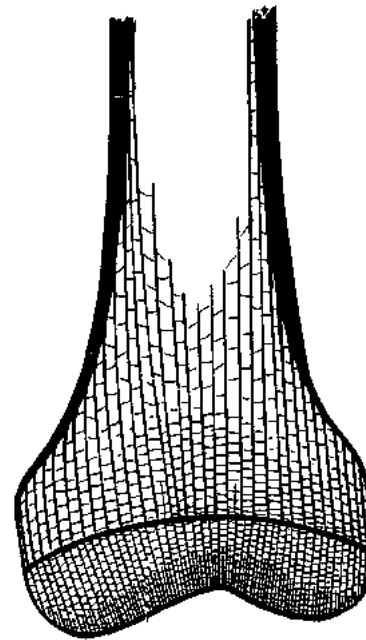


Fig. 3.9. Bone spicules in the skeleton of the extremities (Kiss 1964)

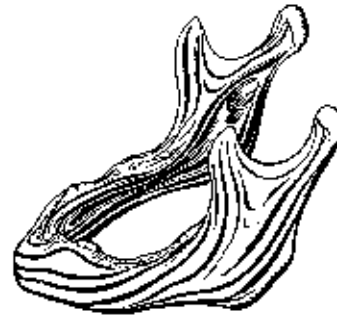

Fig. 3.10. Bone spicules in the skeleton of the developing branchial arch (Benninghof 1964)

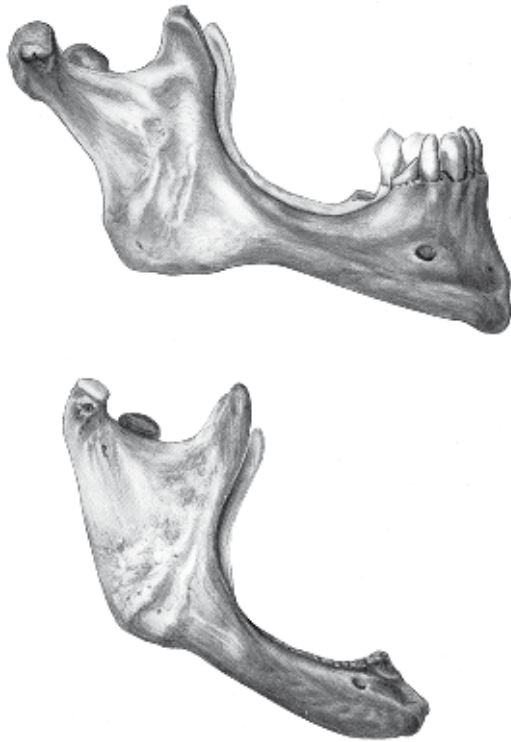


Fig. 3.11. Skeletal decline through loss of teeth (Woerdeman 1954)

In this area, we also find the forces that are exerted on the skeleton by the chewing musculature. Most of the bone tissue disappears from those areas where these forces can no longer influence the skeleton. This is particularly the case after the loss of teeth, which normally transfer these mechanical forces onto the skeleton. (fig. 3.11.).

3.2.5. The Connection between the Skeletal Parts of the Long Bones: the Joints

One outstanding example of a connection between the skeletal parts of the extremities is the *synovial joint*. This type of joint is characterized by a total discontinuance of skeletal continuity. In a synovial joint, the continuity is provided by tendons and ligaments and not by bone or cartilage. This type of joint, creates a maximum possibility for movement of the skeletal parts in the extremities with respect to each other and, therefore, of the body as a whole.

Thus, the greatest possible polarity is obtained with respect to what is found in the neurocranium where synostoses and sutures are formed (3.1.4.).

A synovial joint consists of a ball and a socket surrounded by ligaments. Both the ball and the socket are covered by a layer of *cartilage*. Nowhere the cartilaginous sections are connected to each other. This is one of the reasons why it is possible for a synovial joint to have optimum freedom of movement. Cartilage is not found anywhere in the skeleton of the neurocranium.

3.2.6. The Divergent Configuration of the Long Bones

One striking phenomenon in the morphology of the extremities is the principle of *divergence*. If we trace the parts of the skeleton of the limbs from proximal to distal, we find an increasing number of bones.

Upper arm/upper leg 1
Forearm/lower leg 2
Carpal bones: proximal 3
Tarsal bones: proximal 3
Carpal bones: distal 4
Tarsal bones: distal 4
Metacarpal bones/metatarsal bones 5
Finger/toe bones: per hand/foot 14

One can find this tendency towards *divergence* not only in the number of skeletal parts but also in the morphology of the skeletal parts themselves. It can be seen, for example, on the dorsal side of the femur and the humerus: on the femur, we find the divergence of the linea aspera (fig. 3.12.) and on the humerus, we find the broadening and division of the medial and lateral margins that surround the olecranon fossa. The two condyles of the femur and the humerus develop out of these diverging lines.

This tendency towards divergence then continues in the shape of the lower leg and forearm which both consist of two bones: the tibia and the fibula, and the ulna and the radius. These skeletal parts also display a divergence in their form as a duo which, in the lower leg, leads to the formation of both malleoli and, in the forearm, to the styloid processes.



Fig. 3.12. Divergence in the structure of the upper leg (Benninghof 1964)

3.2.7. The Endoskeleton

The bones of the extremities are generally completely surrounded by muscles, tendons and ligaments in contrast to the neurocranial bones. The large blood vessels and the nerves are also part of the surrounding structures of the skeleton (3.1.4.). In the neurocranium, the bones are on the outside and are clearly visible. Because of their structure, the bones of the extremities are, for the most part, hidden from view.

Therefore, the form of the extremities has, topographically, an architecture that is diametrically opposed to that of the cranium and, in particular, to that of the neurocranium.

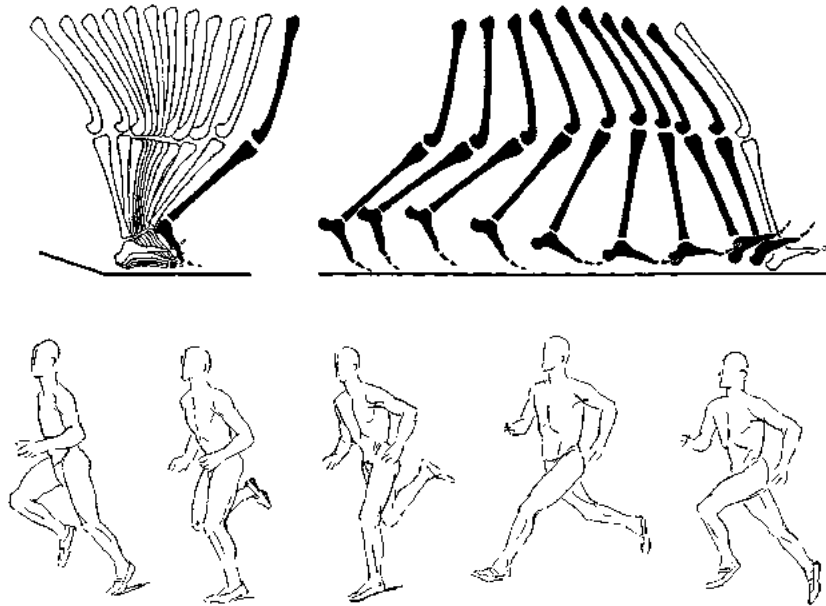


Fig. 3.13. Form change through movement (Benninghof and Goerttler 1964)

3.2.8. Form and Movement

When watching a human or an animal in motion, we experience a continuous *process of metamorphosis*. When the limbs move (change in posture and facial expression) the body configuration dissolves, only to settle down again when we stand still. During movement, the various forms flow smoothly into each other. The number of forms adapted by the human or animal during movement is infinitely large, because of the fluid character of these movements.

This applies both to the individual extremities and to the body as a whole (fig. 3.13.). The only exception to this is the neurocranium, which does not change in form. Here, the polarity between head and limbs once again becomes visible.

3.2.9. Morphological Characteristics of the Extremities

The configuration of the extremities displays a completely opposite dynamic, in comparison to the cranium. The morphological characteristic of the extremities displays a *radial and parallel configuration*. The number of bones in limb sections increases progressively towards the periphery which creates a clearly *divergent architecture* of the bones. The ossification process leads to an inner bone structure in which the *spicules* run primarily *parallel* to each other.

There is no question of solid connections among the bone sections themselves, the *synovial joints* rather allow a maximum amount of *freedom of movement*.

In the extremities, the skeleton becomes an *endoskeleton*, with muscles, tendons, blood vessels, lymphatic vessels, and nerves arranged around it.

When the organism as a whole moves, it is *in constant change*: one position flows into another and there is no longer any question of a fixed form.

3.3. The Thorax

3.3.1. The Form of the Torso

One large and characteristic portion of the torso is formed by the thorax. The shape of the thorax can be seen as a combination of the skull shape on the one hand, and the shape of the long bones, on the other. On the cranial side, the first pairs of ribs display a close connection to the shape of the neurocranium. The upper ribs are relatively flat and broad in comparison to the lower ribs which, in shape, are more closely related to the long bones. The upper ribs are nearly horizontal in position.

The clavicle, which is among the determinates of the external human form, has both types of ossification. Distally, there is desmoid ossification that is reminiscent of the neurocranium; proximally, there is enchondral ossification that is a preview of the situation in the extremities.

The form of the top of the thorax is continued in the parietal pleura. The portion of the parietal pleura that protrudes over the first rib is called the *pleural cupula*. The tendency towards the formation of spherical surfaces is clearly expressed in this term and accentuates the morphological tendency that is characteristic for the skull shape.

The vertebrae and the sternum contribute to the development of the form of the thorax. It is striking that, in the cranial portion of the thorax, the joints only allow limited movement. Both the costovertebral joints and the sternocostal joints are stiff in nature. The components of the joints, that consist of connective tissue and cartilage are partially responsible - due to their form - for the limited movement. Here we see another relationship to the dynamic of the cranial bones with respect to the *restricted and limited movement*.

The lower thorax and the lower ribs display an opposing dynamic. From cranial to caudal, mobility becomes increasingly greater, with an increasing range of movement in relationship to the sternum. The floating ribs hang free from the spine and no longer have a cartilaginous connection with each other or with the sternum. The possibilities for movement are relatively large and here the costovertebral joint allows the necessary movement.

The nearly vertical position in space and the radial or nearby tubular form of the lower ribs complete their similarity to the long bones.

→ *Cranially, the thorax closes itself in a rounded arch, caudally it 'opens up' in a more radial gesture.*

3.3.2. The Rhythmic Structure of the Thorax: Repetition and Metamorphosis

If we survey all twelve ribs in their relation to each other, it then appears that there is a true series of metamorphoses. This means that, in the configuration of the ribs, in their position in space, and in their possibilities for movement from cranial to caudal, metamorphosis is clearly manifested (fig. 3.14.).

3.3.3. The Bony Connections of the Thorax and the Spinal Column

The connections between the bones of the thorax and the spinal column are, to a large degree, determined by the presence of cartilage. That is, of course, also true of the extremities, but the role of cartilage is in each situation entirely different. At the front of the thorax, cartilage forms the fixed connection between the ribs and the sternum. At the spinal column, we find cartilage on the costal capitulae, where the ribs articulate with the

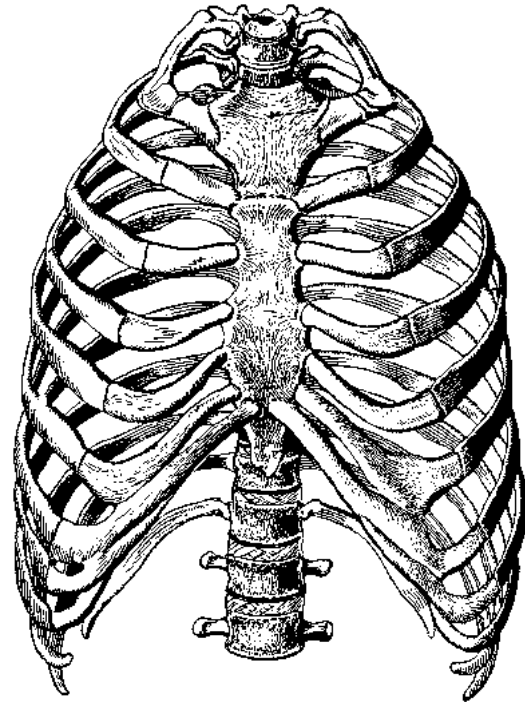


Fig. 3.14. Overview of metamorphosis of the ribs (Vogel 1979)

vertebrae, and on the intervertebral discs, which allow articulation between vertebrae. Therefore, at the front, the bony connection is more closely related to the morphology of the cranium where immovable connections are characteristic. At the spinal column, however, there are synovial joints such as are characteristic for the extremities. In all cases, there is some mobility in both front and back albeit it to a limited degree.

→ *In the skeleton, we find, in the direction from cranial to caudal, a metamorphosis in the structure and function of cartilage at the places where the bones are connected to each other.*

- 1. In the cranium: no cartilage between the bone sections of the neurocranium, so that an immovable bone connection is created. The cartilage that is present in the cranium is related to the development of the branchial arches (maxillary joint, nasal cavity and surroundings, ears).*
- 2. In the thorax and the spinal column: cartilage is part of a fixed bone connection with limited movement.*
- 3. In the extremities: a layer of cartilage covers the bones in the synovial joints with a high degree of free movement in all directions.*

3.3.4. From Exoskeleton to Endoskeleton

Topographically, the sternum, the clavicle and the *upper* ribs occupy the position of an exoskeleton, as we know from the neurocranium. The sternum lies directly under the skin and, together with the ribs, surrounds the organs situated in the thorax. The intercostal muscles are attached to the cranial and caudal sides of the ribs and leave the ventral and dorsal sides free.

The *lower* ribs surround the vital organs of the thorax cavity, and here the intercostal musculature, blood vessels, and nerves surround more and more the ribs. Once again, it is striking that the *upper* ribs have more the character of an exoskeleton and the *lower* ribs more the character of an endoskeleton. The ribs occupy a middle position between exoskeleton and endoskeleton.

Topographically, the spinal column occupies the typical position of an endoskeleton. In

the cervical, thoracic, and lumbar regions, the spinal column is surrounded by powerful muscles such as the short and long muscles that are connected dorsally and ventrally to it. The characteristic morphological 'mid-position' of the thorax between the dynamic of the cranium and that of the extremities is also expressed here.

3.3.5. Morphological Characteristics of the Thorax

Characteristic for the morphology of the thorax is the *rhythmic configuration* and the *metamorphosis* of the form of the ribs and vertebrae (Chapter 4). Metamorphosis is a phenomenon in which, in the one hand, there is repetition of a morphological item, such as a rib or a vertebra but, at the same time, a change becomes visible within that repetition. The change in the repetition can be further clarified morphologically. In a cranial direction, it tends to the characteristic form of the cranium (3.1.6.) and, in a caudal direction, of the extremities.

The rhythmical aspect does not only affect the ribs and the vertebrae, but also the organs in the thorax. The trachea, the sympathetic trunk, the intercostal musculature, the intercostal arteries and nerves, the dermatomes and the segmented structure of the spinal column, all display the same principles of rhythm and metamorphosis: *repetition and change*.

The thoracic organs that are not rhythmically structured, such as the heart, lungs, and diaphragm, display the rhythmical element at the *functional* level: systole and diastole for the heart, inhaling and exhaling for the lungs and contraction and relaxation for the diaphragm.

→ *The thorax is the center for rhythmic phenomena: in space through its morphology and in time through its functionality.*

In the thorax, the morphological tendencies of the cranium and the extremities reach a synthesis that results in a morphological space that is free from one-sidedness. The tendency towards the specific forms on the cranial and caudal sides of the organism create, in mutual harmony, a morphological center in which the human being can 'breathe freely.'

3.4. Summary and Conclusions

The morphology of the skeleton displays two dynamic, polar processes represented by the form of the cranium and of the long bones. Spherical surfaces dominate in the cranium, while the radial formations dominate in the extremities.

The rhythmical structure of the thorax occupies a position that is midway between the skull and the extremities, in which change and repetition permeate each other. In the metamorphosis resulting from this, the polar dynamic of the cranium and the long bones is still recognizable in rudimentary form as morphological processes; these processes permeate each other but do not lead to a one-sided morphological dynamic.

All rays of a sphere intersect each other at the center point. As far as the human skull is concerned, the center lies behind the base of the nose, intracranially between the two temporal bones.

As for the parallel rays of the extremities, their point of intersection lies at an infinitely distant peripheral point.

The thorax displays a series of metamorphoses in which both poles permeate each other.

In relation to movement a polarity is created between the immobile spherical cranium and the mobile extremity bones. In the thorax, we find an accentuation of immobility on the cranial end and an accentuation of free mobility on the caudal end, and rhythm of movement is characteristic in this part.

3.5. Goethean Aspects

3.5.1. Form and Dynamic

A living organism possesses its own *form*. This form is, for each organism, subject to the

blueprint and possibilities offered to that species. Just how one form (or species) can develop from another form (or species) is the primary question of every theory of evolution. The singular form of an organism is created in the course of its development. When studying this development, it becomes evident that organisms and organs evolve out of moving streams of fluid, through the migration of cell groups, and through the changes in form of the cells involved. At the cellular level, it is evident that every form change in a cell is preceded by movement, either in the cell plasma, or in the cell organelles and cell compartments at the sub-cellular and molecular biological level. These observations justify the formulation of a basic law in morphology:

Form arises from movement

For a phenomenological viewpoint, one can differentiate between characterizing the *form* and characterizing the *dynamic*. The dynamic can be derived by characterizing the *movements* that have led to the development of the form. A specific dynamic will lead to a specific form, as was described in the previous chapter.

The phenomenological characterization of the morphology of the skeleton, therefore, makes a conscious distinction between form and dynamic. The relationship that dynamic and form have to each other can then be more clearly expressed.

3.5.2. Centripetal Dynamic and the Spherical Form

The sphere and the circle are, dynamically seen, determined by the *orientation to a center*. This orientation can, from a dynamic perspective, be experienced as a centripetal tendency. Centripetally active forces come to rest in the center. The result of this process is that there is a lasting cohesion among the various points. Morphogenetically this leads to the existence of immobile continuity of form. The head, specifically the neurocranium of the human, is the prime example of a settling process coming to rest, leading to an *immobile, fixed form*. The cranial bones have become, to a large extent, an immovable object. The forming of synostoses and sutures between the cranial bones is proof of this.

Functionally, the centripetal tendency can be experienced in our own process of perception

and reflection.

The world can be experienced through the senses to become part of one's *conscious perception* and, through this, the world becomes the content of inner *cognitive processes*.

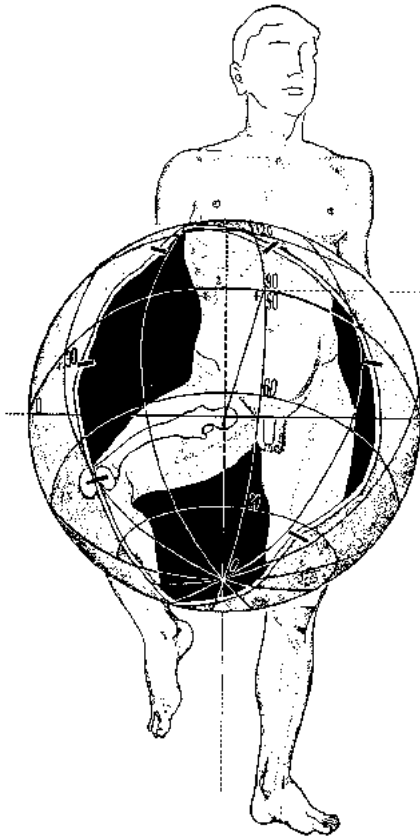


Fig. 3.15. Range of movement of the femur as a spherical segment (Benninghof and Goettler 1964)

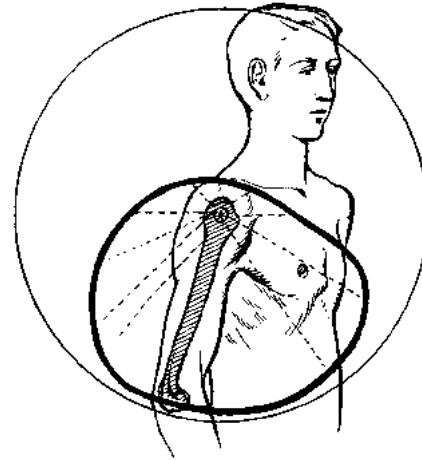
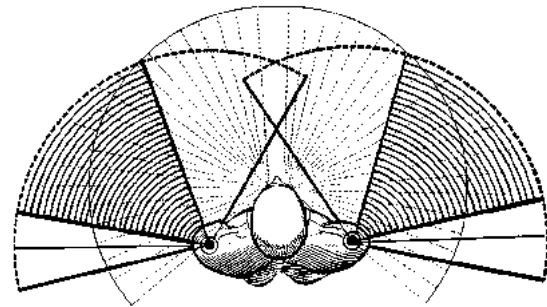


Fig. 3.16. Range of movement of the humerus as a spherical segment (Benninghof and Goettler 1964)



3.5.3. Centrifugal Dynamic and the Radial Form

The limbs have a radial form and, in contrast to the skull, *have their point of orientation in the periphery*. The limbs are not aligned towards one point, but to a multitude of points in the periphery. Just as the form of the cranium is aligned towards a center, the form of the extremities is aligned towards a nearly infinite number of points in the periphery. Those peripheral points could, in theory, be thought of as (part of) a sphere. It is possible to show the range of movement of an extremity as part of a spherical segment.

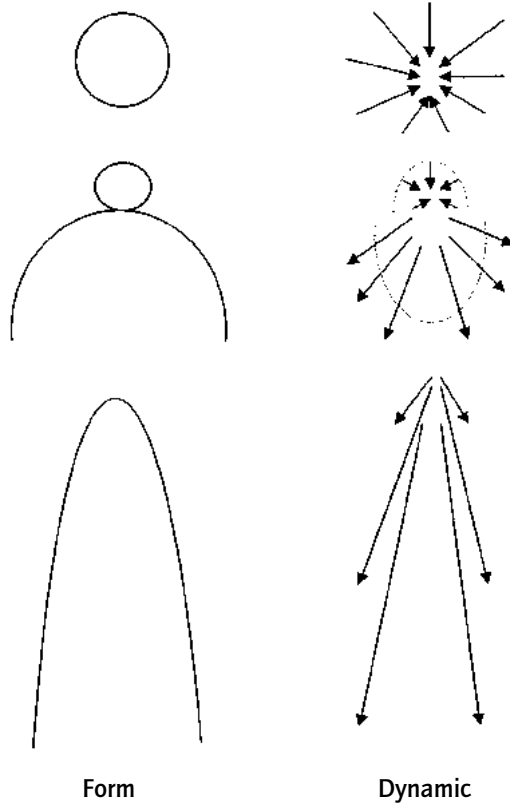
The structure of the extremities does not only display an increase in the number of bones towards the periphery, there is also an increase in free mobility. The orientation of movement is *directed towards the periphery*. The range of movement can then be expressed in the number of degrees of a segment of the sphere within which that particular bone can move (fig. 3.15. and 3.16.).

Functionally, the limbs have the ability to change the surrounding world. Ultimately, all of our actions are based on motor activity. The entire cultural legacy originates from human actions. The spoken or written word is certainly no exception to this.

3.5.4. Rhythmical Dynamic and Rhythmical Form

The entire human thorax displays a *rhythmical form* that is particularly clear in the structure of the spinal column and the ribs.

The thorax form is, within certain boundaries, both fixed and changeable. The immobile and fixed is more characteristic of the vertebrae, which are dynamically comparable to the cranium, while the changeable is more typical of the ribs, which display a relationship to the extremities. The rhythmical center contains the centripetal and centrifugal in a state of equilibrium.



Rhythm as the merging of the centrifugal and the centripetal dynamic can be seen as an enhanced combination of both. Another consideration is, however, that the rhythmical center can be seen as something separate that already contains the centripetal and centrifugal within itself (see also: 4.3.2.). In that case, the opposing poles originate from the center in the course of development. In chapter 9, which deals with polarization and the role of the center in polarization, this will be further explained using developmental phenomena from comparative anatomy.

Fig. 3.17. Dynamic outline

3.6. Once Again, the Blueprint

We may characterize the dynamic outline of an organism from its blueprint. There are, essentially, three dynamic processes: the pursuit of spherical form through a centripetal dynamic, the pursuit of radial form through a centrifugal radial dynamic and a harmonizing, rhythmical dynamic which contains both of these dynamics as a potential. The dynamic outline of the blueprint that can be seen as basic to the skeleton as a whole repeats itself, upon closer examination, in different parts of the skeleton as well as in organs and organ systems. This will be discussed in the following chapters.

4. The Morphology of the Spinal Column

4.1. Introduction

The ability to form a calcified internal skeleton is a developmental characteristic of the higher animal organism. The spinal column - and with it, the vertebrae - occupy a pivotal place in morphological classification of animals. Higher forms of animal life (the chordates) are subdivided into vertebrates and invertebrates. The first group possesses a spinal column in the organism itself, the second group does not. That difference is determining for the ranking of their position on the evolutionary ladder.

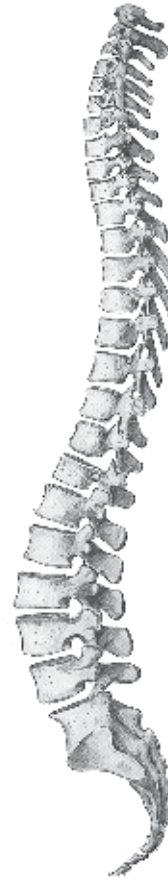The internal support system of many of the lower vertebrates consists of cartilage rather than bone.

4.2. Metamorphosis in the Spinal Column

4.2.1. The Blueprint of the Vertebrae in Relation to the Ribs

We can differentiate among the various parts of the vertebra (fig. 4.1.): the vertebral body, the vertebral arch, and the transverse and spinous processes. The most typical vertebral structure can be found at the level of the 6th thoracic vertebra.

The thoracic vertebrae have a close relationship to the ribs. Together they form a functional unit (fig. 4.2.). Upon further consideration this relationship also exists in vertebrae which are not attached to any ribs, such as the cervical, lumbar and sacral vertebrae. It appears that these vertebrae have *rudimentary ribs* in their blueprint. That is how the transverse foramen develops in cervical vertebrae and the accessory process (processus costarius) on lumbar vertebrae (fig. 4.3.).



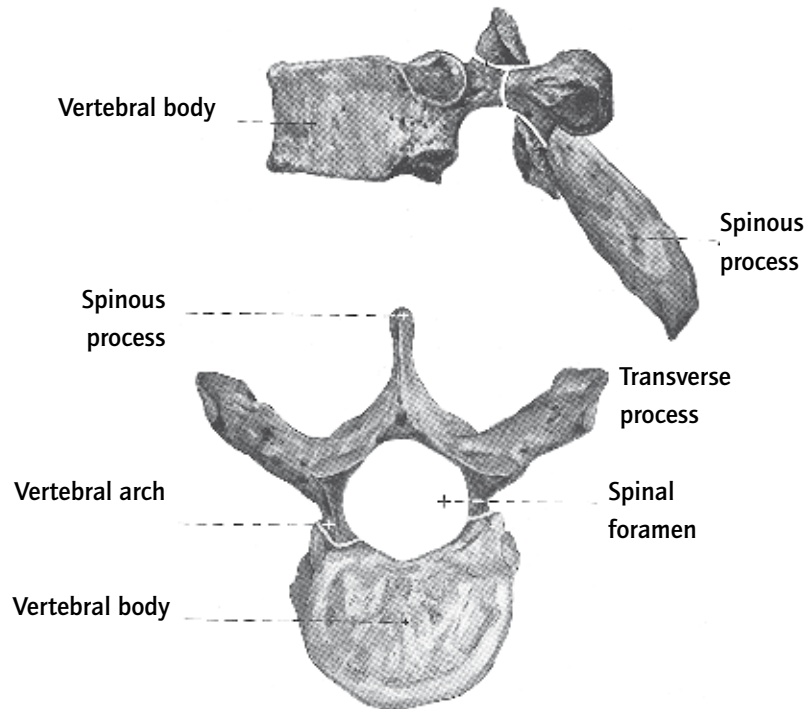


Fig. 4.1. A typical vertebra (Woerdeman 1954)

It is important to consider the fact that the variation in external form of the vertebrae including the ribs is determined by a metamorphosis of different parts. In the cervical, lumbar, and sacral regions, the ribs 'disappear' as a separate part of the skeleton but they add, rudimentarily, to the form of the cervical and lumbar vertebrae and the sacral bone. This implies that the metamorphosis of the vertebrae must be considered in the light of their relationship to the ribs.

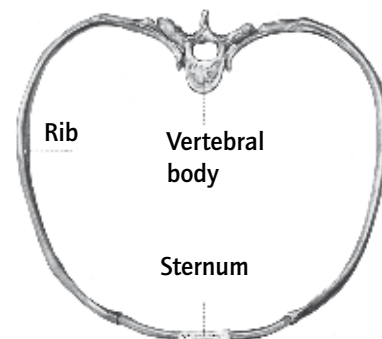


Fig. 4.2. Rib and vertebra (Woerdeman 1954)

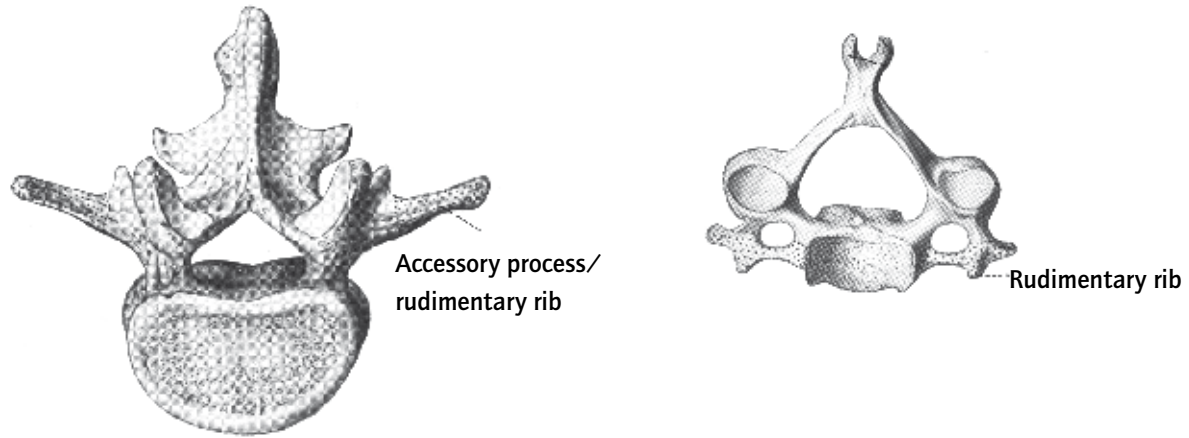


Fig. 4.3. Cervical vertebra and lumbar vertebra (Benninghof and Goerttler 1964)

4.2.2. Cervical Region

We may gain an understanding of the metamorphosis of the vertebrae by comparing the atlas vertebra, the fifth lumbar vertebra, and the sixth thoracic vertebra to each other (fig. 4.4.).

The *first cervical vertebra (atlas)* consists, for the most part, of a vertebral arch enclosing a relatively large lumen, which holds the central nervous system (the spinal cord).

The body of the atlantic vertebra hardly exists at all. The vertebral body is present in early development, but ultimately fuses with the vertebral body of C2, which results in the odontoid process. Of the spinous process, only the posterior tubercle remains.

The atlas, therefore, represents the ultimate reduction of the archetypal vertebra to a *vertebral arch*.

Three phenomena are of great significance when we look at the cervical vertebrae:

- the large, rounded space that is enclosed by the posterior arches of C1 and the other cervical vertebrae which provides space for the central nervous system
- their nearly horizontal position within the space

- the principle of forming planes dominates in their morphology.

It is not difficult to trace these characteristics back to the morphology of the skull. The conclusion appears justified that the cervical vertebrae are morphologically related to the morphological dynamic of the skull, if we realize that the spherical form of the skull, when projected onto a flat surface, is converted into a circular form (fig. 3.6.).

4.2.3. Lumbar and Sacral Region

The lumbar vertebrae display a completely different morphology than the thoracic and, particularly, the cervical vertebrae. The heavy vertebral body is nearly round and, because of its height, gives the impression of being cylindrical. There is clearly a cortical layer of bone and a spongy section of bone marrow, as can also be found in the long bones. There is no longer a transverse process; in its place we find the accessory process (processus costarius), a rudimentary equivalent of the ribs (Chapter 4.1.1.).

The vertebral arch surrounds a limited area in which there is no more central nervous system, but the roots of the spinal nerves: the cauda equina. The spinous process is short and robust.

The sacrum is a portion of the skeleton that

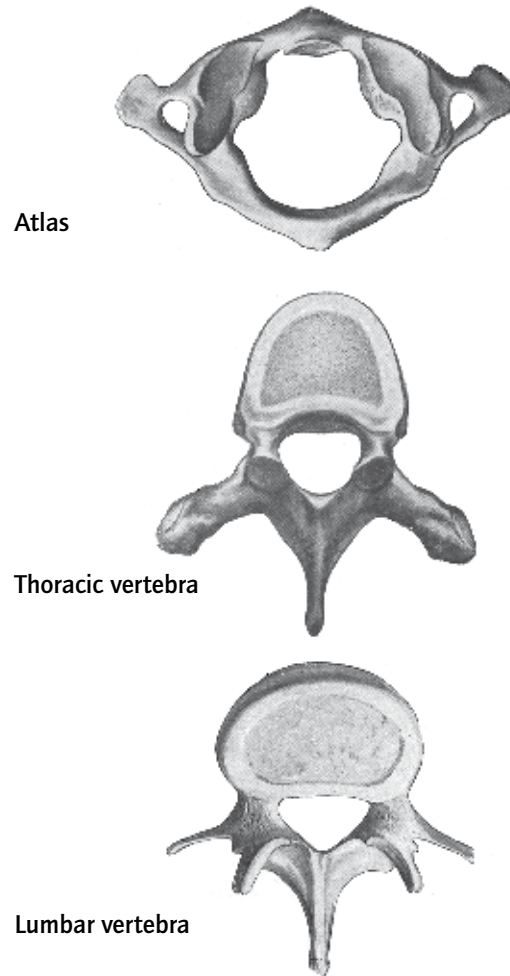


Fig. 4.4. Atlas, Th6 and L5 (Kiss 1964)

is composed of five vertebral elements. Because of the fusion of these elements, a quickly narrowing sacral canal develops a clearly *hollow vertical structure*.

4.2.4. Thoracic Region

The thoracic vertebrae come closest to a general blueprint of the vertebra: all parts are well developed and the vertebral body and vertebral arch are in balance. The spinous processes follow the dynamic of the ribs, in their position in space: the uppermost spinous processes are nearly *horizontal* but caudally they tend to become increasingly *vertical*. Cranially, the spinous processes are not robust but they become increasingly heavy in the lumbar direction. The vertebral body is heart-shaped.

4.3. Goethean Aspects

4.3.1. Morphological Characteristics of the Spinal Column

In the spinal column, two morphological forces appear to permeate each other and keep each other in balance: the morphological tendency of the head and the morphological tendency of the extremities. In the cervical spinal column, the former dominates and in the lumbar region, the latter. The thoracic region incorporates both tendencies harmoniously.

The morphological tendency of the skull had been characterized as a process generating an exoskeleton that surrounds the central nervous system by means of flat skeletal parts. The morphological tendencies of the long bones had been characterized as generating an endoskeleton that functions in the human movement system. The spinal column incorporates, as a true rhythmic center structure, both tendencies.

4.3.2. Morphological Characteristics of the Ribs

As was discussed above (Chapter 3.3.5.), the *metamorphosis of the ribs occurs parallel to the metamorphosis of the vertebrae*. It is clear from this that the development and structure of the spinal column must be seen as related to that of the ribs. The polar dynamic of head and limbs is, once again, visible here.

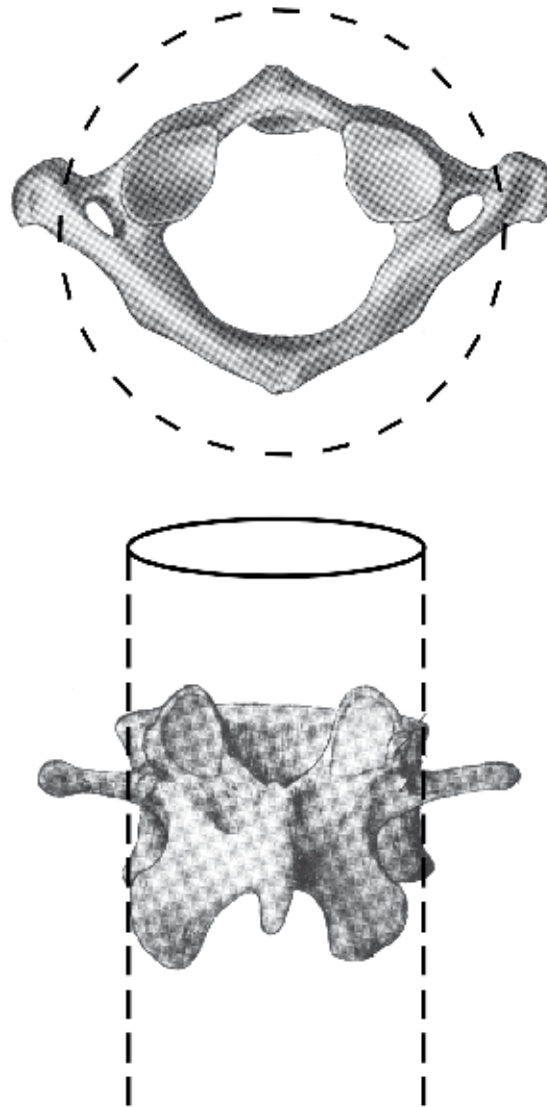


Fig. 4.5. Atlas as a circle and L5 as a cylinder



5. The Morphology of the Nervous System

5.1. Introduction

The nervous system is divided into a central nervous system, consisting of brain and spinal cord, (located within the cranium and the spinal column) and a peripheral nervous system that is formed by the spinal and peripheral nerves (located outside of the cranium and the spinal column).

5.2. The Central Nervous System

5.2.1. Early Development

The first developmental phase of the part of the central nervous system that develops intracranially is characterized by the creation of *brain vesicles*. The cranial portion of the original neural tube dilates vigorously in all directions, so that the - initially tubular - brain develops a wide lumen with a very thin wall (fig. 5.1). In this spherically-shaped dilation

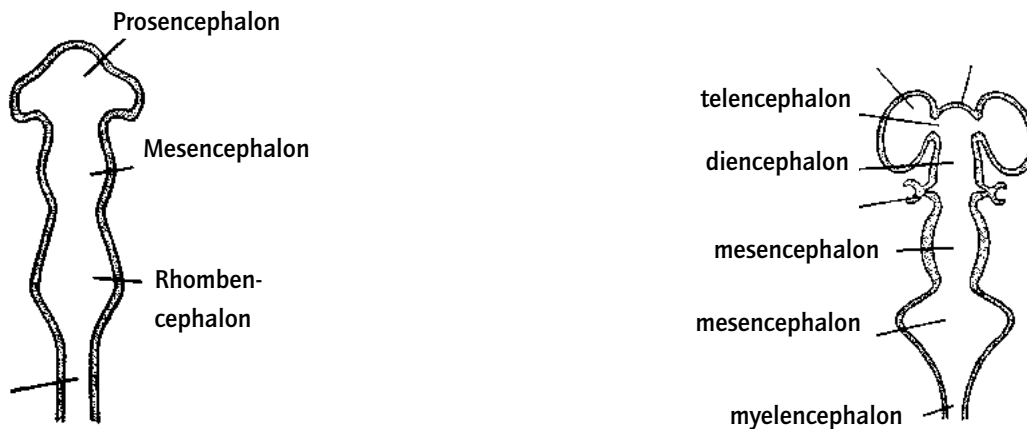
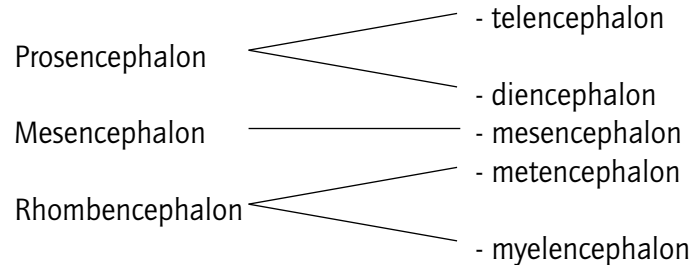


Fig. 5.1. Brain vesicles (Langman 1995)

of the neural tube, three areas can be distinguished from cranial to caudal: the prosencephalon, the mesencephalon and the rhombencephalon.

From these three brain vesicles, the definitive portions of the brain will develop as follows (fig. 5.1.):



5.2.2. The Telencephalon

On the telencephalic *vesicles* spherical bulges develop bilaterally into the two hemispheres of the cerebrum. Literally, the word 'hemisphere' means 'half a sphere.' This is an indication of the fact that the cerebrum, as a whole, can be seen as a complete *sphere*. Morphologically, we recognize the same characteristics as have been described for the skull in chapter 3.1.6.

The Development of Gray Matter

A second characteristic of the development of the cerebrum is the development of the *cerebral cortex* which mainly consists of neural cell bodies and is called the gray matter. Through extensive proliferation and folding, an extensive *surface* area of gray matter is formed. In the cerebral cortex are projection areas (such as the primary and secondary sensory cortex and the auditory and visual cortex) in which afferent fibers end and those where efferent filaments originate (such as the primary and secondary motor cortex). Projection areas are cortical areas that are via nerve fibers connected to specific areas of the body.

The entire body is represented in caricature form, but recognizable in overall shape, as it is

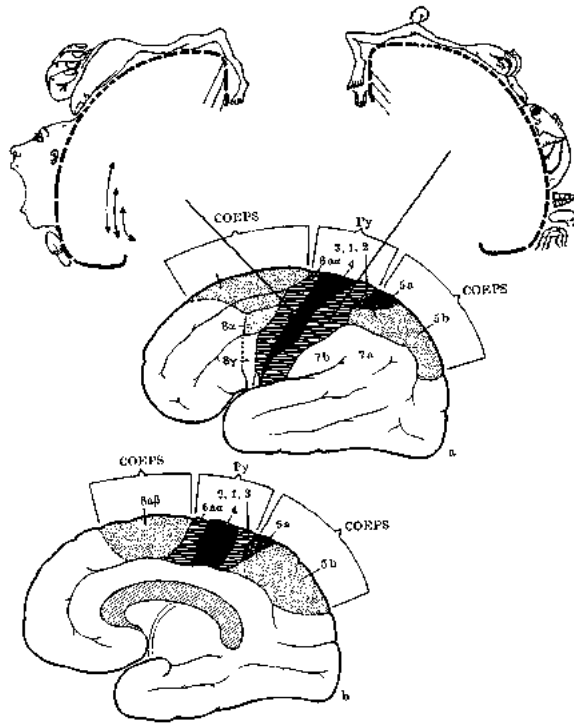


Fig. 5.2. Projection areas of the cerebral cortex (Rohrer)

projected onto the motor and sensory cortex (fig. 5.2.). The relatively large surface areas that are allocated to the sensory and motor projection of the face, the mouth, the tongue, the senses, and the hand is particularly striking. The areas for the remaining regions of the body are notably small. This indicates a direct relationship between the density of innervation of the various regions of the body and the size of the corresponding projections areas (for example, mouth, tongue and hands).

Spheres and planes are morphologically characteristic of the cerebrum

The White Matter

The white matter of the cerebrum serves the *coordinating and integrative* functions of the nervous system, in particular the cerebrum

itself. Association fibers connect various centers of the same side of the brain with each other (for example the longitudinal fasciculus and the cingulum). Commissures connect equivalent centers in the opposite brain halves with each other (for example the corpus callosum, the commissura anterior and the fornices).

The connection that is created between the cerebrum, the senses and lower portions of the central nervous system determines the *coordination and integration* of sensory and motor functions. They are, therefore, responsible for the ability of the human body to function as a whole, as a perceptive and reactive organism.

5.2.3. The Diencephalon

The diencephalon develops from the median portion of the prosencephalon which connects both primitive hemispheres with each other (fig. 5.1.).

The gray matter of the diencephalon develops as the main portion, consisting of thalamus, hypothalamus and neurohypophysis.

All three of these parts of the brain have *coordinating and integrating* functions: the thalamus with respect to the sensory/motor system, the hypothalamus with respect to autonomic functions, and the hypophysis integrates the activity of the metabolic organs regulated by endocrine glands, with the state of the autonomic nervous system in the organism. The pituitary gland is made up of two parts: the neurohypophysis which produces releasing factors, and the adenohypophysis which secretes hormones stimulating endocrine organs such as the thyroid (TSH), the gonads (gonadotropin hormones) and the adrenals (ACTH).

The hypothalamus regulates the integration of metabolism, via the pituitary gland.

5.2.4. The Cerebellum

In the cerebellum, the onset of a spherical configuration is also recognizable, albeit it on a smaller scale than in the cerebrum. We also find cortical *projection areas* in the cerebellum, comparable to those of the cerebrum, but now serving the *coordination* of movement. The cerebellum is connected to all pathways that are important to the motor system of the body.

5.2.5. Mesencephalon, Metencephalon, and Myelencephalon

Morphologically, these three areas of the brain are closely related to the structure of the spinal cord. They only determine, to a slight degree, the macroscopic form of the intracranial nervous system.

The larger number of the cranial nerves originate with their afferent and efferent nerve

fibers in the metencephalon and the myelencephalon. The first through fourth cranial nerves are either sensory afferent or motor efferent. Starting at the trigeminal nerve (V), the cranial nerves (with the exception of the abducent nerve VI) become increasingly mixed. Thus, in the cranial nerves, there is a development from caudal to cranial in which the cranial nerves become increasingly 'alienated' from the structure of the segmental spinal nerve: a mixed nerve containing both sensory and motor fibers.

The reticular formation is extended throughout the entire brainstem. This part of the nervous system occupies a central place in *regulating and coordinating* autonomic functions such as sleeping and waking, breathing, blood pressure, and temperature, and the regulation of the internal organs.

→ *There is a morphological parallel between the head as a whole and the intracranial nervous system. Cranially, there is an accentuation of the spherical morphology in the neurocranium and the hemispheres of the cerebrum and the cerebellum; caudally, there is an accentuation of the morphology typical of the limbs and the peripheral nervous system.*

5.3. The Peripheral Nervous System

5.3.1. Radial Structure and Plexus Formation

Spinal nerves form plexuses. Plexus formation is a morphological characteristic of the peripheral nervous system. The cervicobrachial plexus and the lumbosacral plexus form the areas of origin of the peripheral nerves for arm and leg. From the plexus, the path of the nerves has a radial expansion. In a peripheral direction, the bifurcation and divergence of nerve fibers increases and reaches its maximum at the surface of the body. In the arms and legs, the rhythmical segmental structure of the spinal nerves loses its rigidity through plexus formation. The origin of metamerism can indeed be traced, but the nerves have been metamorphosed and recombined by plexus formation.

The autonomic peripheral nervous system has a comparable morphology. We also find plexus formation for the internal organs. In the autonomic nervous system (sympathetic as

well as parasympathetic), the plexus is the passageway for all nerve fibers. Only those fibers that are linked in a peripheral ganglion and which develop from preganglionic fibers into postganglionic fibers, become effective as autonomic efferent fibers.

→ *The peripheral nervous system shows morphological plexus formation and the peripheral nerves have a radial structure. The relationship to the dynamics of the limbs is not only topographical, but also morphological.*

5.4. The Spinal Cord

5.4.1. Introduction

The configuration of the spinal cord is, morphologically, directly related to the structure of the spinal column in its location in the spinal canal and its segmental morphology. The spinal cord with the spinal nerves and the spinal column with the ribs are both examples of metamerism: the anatomical form in which segmental elements are repeated and metamorphosed.

→ *The blueprint and the relationships, such as are found between the vertebrae and the ribs, reoccur morphologically in the spinal cord and the segmental nerves.*

5.4.2. The Segmental Structure of the Spinal Nerves

In contrast to the cerebrum, the spinal cord is structured such that the gray matter is located centrally, for the most part and the white matter is located peripherally. White matter consists of long projection paths and in the gray matter the neurons are situated in which the connections occur. Because the afferent pathway (via the posterior spinal root) and the efferent pathway (via the anterior root) of each segment are situated close to each other, the anatomic condition for the *reflex arc* is created. From a neurophysiological

point of view, there is a continuous steering circuit that regulates the input and output of the afferent and efferent pathways in the reflex arc.

→ *The rhythmic principle regulates systole and diastole in the heart and inhalation and exhalation in breathing. The same rhythmic principle governs the regulation of the reflex arc in which sensory (afferent) and motor (efferent) impulses regulate posture and movement.*

5.5. Nervous System and Consciousness

5.5.1. The Consciousness of the Head

The awareness of animals when they are awake and the self-consciousness of humans are directly related to the degree of development of the cerebrum. In this respect the relative weight of the human brain in comparison to the body weight, puts the human being in a unique position. The ability to be *aware of oneself* in observing one's surroundings (sensory) and the ability to be aware of oneself in activity (motor skills) are expressions of self-consciousness.

→ *The intracranial nervous system is connected to conscious perception and intention, which occur during the waking state of consciousness. At this time in humans thinking occurs.*

5.5.2. The Consciousness of the Metabolic Organs, the Skeleton, and the Muscles

Neither animals nor humans consciously experience the processes of the metabolic organs, the muscles and the skeleton. Digestion, the mutual regulation of organ functions, and the use of muscle groups in movement, all of these functions occur completely unconsciously. It is normally impossible to influence this voluntarily. These bodily functions are primarily regulated by the autonomic nervous system.

Moving we are aware of the fact *that* we move, not *how* we move our muscles.

→ *The autonomic nervous system is connected to the unconscious life of the organism, such as the functioning of the internal organs, muscles, and skeleton. This is the domain of metabolism. The form of consciousness corresponds to dreamless sleep or coma.*

5.5.3. The Consciousness of the Rhythmic Organs

In the thorax, we find a third form of consciousness: partially conscious, partially unconscious. The activity of the heart and breathing regulate themselves as internal organs. The activity of our heart can, however, be consciously perceived and, to some degree, we can even consciously influence our breathing. These rhythmic organs in particular, react to inner processes that have an effect at the organic level: moods and emotions.

→ *The area of the rhythmic nervous system is related to a changing state of consciousness. This state of consciousness corresponds to the moments of light sleep in which emotions and events become, to a certain degree, conscious: dreaming. While awake, emotional life has its origin here.*

5.6. Goethean Aspects

Comparable to what has been said concerning the characteristic morphology of the skeleton, we can also find three different morphological qualities in the nervous system.

5.6.1. The Intracranial Nervous System: Sphere and Plane

Morphologically, we find a metamorphosis of the pursuit of a spherical structure in the

intracranial nervous system. The dilation of the neural tube into ventricles, the formation of the cerebral and cerebellar hemispheres, and the blueprint of the intracranial portion of the nervous system strive for the spherical form. The cortical projection areas develop with the characteristics of a plane. Just as with the skull, the relation between the cranial form (spherical) and the cranial bone (flat) can be seen in relation to the formation of the hemispheres and the projection areas.

Dynamically/functionally, perception via the senses, consciousness of the intent to move, and the integration of functions in waking consciousness are the most important.

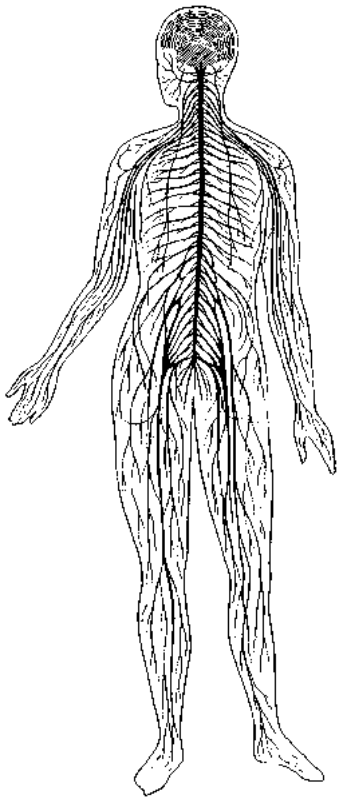


Fig. 5.3. Diagram of the nervous system (Vogel 1979)

5.6.2. The Peripheral Nervous System: Radial Structure

Morphologically, characteristic for the peripheral nervous system are its radial structure and its function in peripheral sensory and motor activity. The extremities, skin, and internal organs are innervated by nerves that originate from a plexus to reach their final destination. It is striking that, just as has been said about the structure of the limbs, this section of the nervous system also subdivides in a peripheral direction.

Dynamically/functionally, the metabolic aspect of action occurs in this area where we are unconscious.

5.6.3. The Spinal Cord: the Rhythmic Nervous System

Morphologically, the entire spinal cord has a segmental structure. The segmental nerves are ordered according to the metameric principle. The metameric structures are here in morphological concordance with the spinal column and the thorax: they are *rhythmical*.

Morphologically, we find centripetal afferent fibers alongside centrifugal efferent fibers. The reflex arc is regulated by a rhythmic principle.
Dynamically/functionally, the reflex arc is basic for this portion of the nervous system.

→ *Morphological and dynamical characteristics of the nervous system display a close relationship to the morphology and the dynamic of the skeletal parts they are connected to.*

6. The Morphology of the Airways

6.1. Introduction

The airways have a unique physiological position within the organism: it is the only organ system through which substances from the outside world enter the organism essentially unchanged. In contrast to the intestines, the airways can take air in without digesting it. In the healthy situation, oxygen can be directly absorbed from the alveolar air into the blood system during gas exchange. The intestines, however, meet ingested nutrients with a destructive digestive process before it is allowed to enter the internal milieu of the organism.

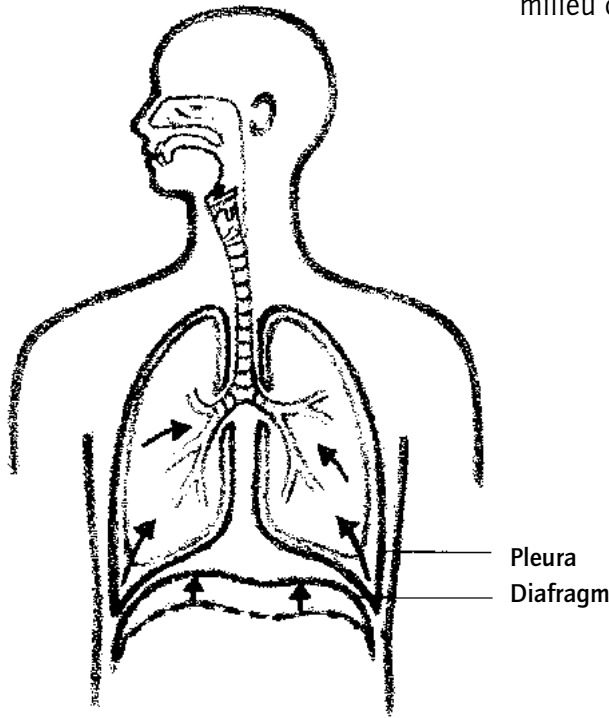


Fig. 6.1. The airways (Rohen 1998)

6.2. Development of the Airways

The airways (figure 6.1.) start their development during the embryonic stage but continue to grow until puberty. This applies particularly to the respiratory units, alveoli, and, to a lesser extent to the paranasal sinuses. The primitive airways of the organism begin their development in the rhymic area of the human organism (primitive lung buds) and later extend into the cranial (sinuses) and caudal (alveolar) areas.

6.2.1. The Paranasal Sinuses

The paranasal sinuses (fig 6.2.) develop primarily postnatally. The aeration of the paranasal sinuses occurs during the first years of life. The frequently occurring ear, nose, and throat problems among young children are often the result of an insufficient aeration of the paranasal sinuses and the tympanic cavity.

The total capacity of the paranasal sinuses in the adult cranium is surprisingly large. If we include not only the paranasal sinuses, but also the nasal cavity, the tympanic cavity, and the mastoid cells as part of the airways, the volume becomes even more impressive.

The maxillary sinus, the ethmoidal air cells, the mastoid cells, and the tympanic cavity are comparable in shape: they are like air bubbles in a fluid. *Morphologically*, we can speak once again of the dynamic of the spherical form that is characteristic for the head.

The air from the sinuses is absorbed by their mucus membranes.

Functionally, the paranasal sinuses are essential for the healthy functioning of the senses, such as the organ of smell and that of hearing, and for the nervous system in its function for thinking. In a more general sense, free air in the cranium is important for healthy, conscious mental activity. An active sinusitis will significantly hinder the ability to think.

→ *The upper airways are morphologically and functionally related to the morphological and functional characteristics of the head.*

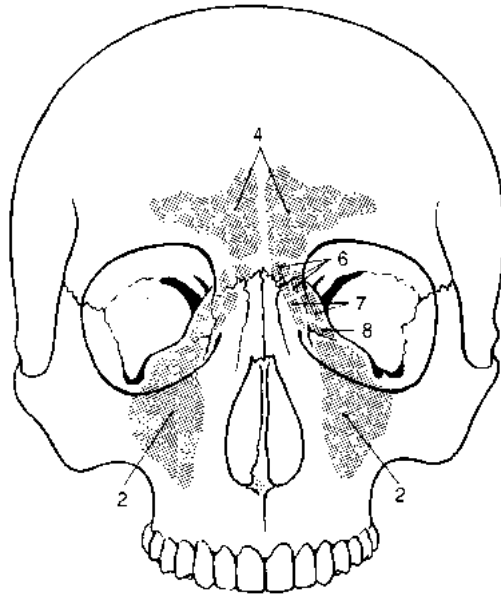


Fig. 6.2. The paranasal sinuses (Feneis 1983)

6.2.2. The Alveolar Areas of the Lung

The most caudal portion of the airways is formed by the respiratory units (fig. 6.3). It is important to note the maturation process and the growth pattern of the respiratory units. The so-called alveolar period of development of the lung *continues far into puberty*. Until this time, new respiratory bronchioles and primitive alveoli are developed which mature and become functional in gas exchange. Postnatal growth forms the major part of lung development.

This process corresponds to the development and maturation of the limbs far into puberty: the dynamic of *divergence towards the periphery*.

The *morphology* of the alveolar space is adapted to the purpose of *gas exchange*. There is hardly a more beautiful example of an organ which is so literally *involved in metabolism* in the sense of the exchange of physical substances. The removal of carbon dioxide from the blood and the absorption of oxygen into the body is pure *metabolic activity*.

By breathing, the surrounding world is changed: oxygen disappears from the atmosphere and carbon dioxide and water vapor are added to it. If breathing were to be limited to that portion of the airways that extends up to the respiratory units, there would be no change in the surroundings. Through the exhalation of alveolar air, the atmospheric surroundings undergo a change in temperature, humidity and carbon dioxide concentration. The exhaled air flows into the world and changes it.

The alveolar space is *constantly moved* by the diaphragm and the thoracic wall, and gas exchange results from this.

A third characteristic of the lower airways is the *dichotomous branching* of the bronchial tree. In the extremities, we could still express this divergence in the increasing number of bones from proximal to distal. In the bronchial tree this can hardly be expressed in numbers anymore. The bronchial tree subdivides in the peripheral direction into a multitude of bronchioles (24 generations).

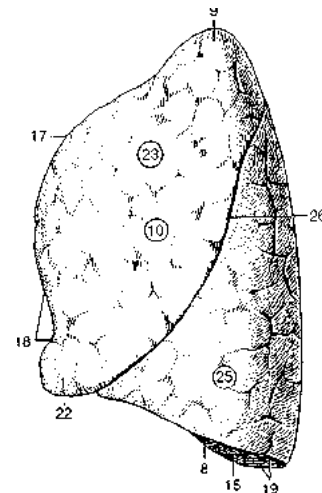


Fig. 6.3. The alveolar space of the lung (Feneis 1983)

→ The alveolar region is morphologically en functionally related the characteristics of the limbs.

6.2.3. The Trachea and the Bronchial Tree: Rhythmic Air

The mid-section of the airways is formed by the trachea and the bronchial tree. *Morphologically* characteristic is here, once again, the *metameric* structure of the trachea and the bronchial tree which is manifested in the presence of, among other things, the horseshoe-shaped tracheal rings. In this case, the rings are not numerically related to the spinal column, as is the case with the spinal cord, but have their own structure and number. The cartilage of the tracheal rings originates from mesoderm.

The characteristic mobility of the bronchial tree and the trachea is related to the smooth muscles that are present which are autonomously innervated. The bronchial tree and the trachea have a *rhythmically* variable width, influenced by the breathing: in the chest they dilate upon inhalation and constrict upon exhalation; in the neck the trachea constricts upon inhalation and dilates upon exhalation. The air shuttles rhythmically back and forth. In this part of the airways, there is no gas exchange.

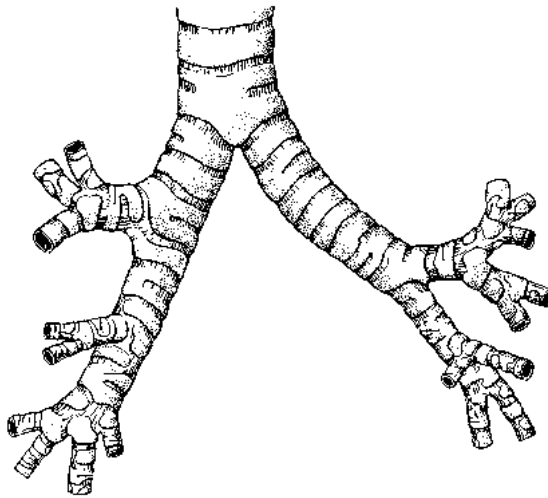


Fig. 6.4. The trachea and the bronchial tree (Feneis 1983)

6.2.4. The Larynx

The skeleton of the larynx consists *morphologically* of cartilage originating from *ectoderm* (*neural crest cells*). The larynx musculature is innervated by the *recurrent nerves* which originate in the *somatomotoric* core of the vagal nerve. The larynx

develops from the fourth, the fifth and sixth branchial arches and forms the entrance to the trachea, thereby becoming the *most cranial portion of the mid-section of the airways*. The human larynx has an important *function* in the human organism. It is the central organ of speech and singing. When talking - and even more, when singing - all movement of the speaking or singing human being converges in the dynamic of the larynx. The laryngeal musculature and skeleton allow an elegance of movement that is unparalleled at any other place in the organism. In this function, the larynx has a close relationship to consciousness. With the aid of the larynx we can express thoughts and feelings. Ultimately, the healthy functioning of the larynx depends upon the vocal cords. They can adopt infinite variations of movement, and can bring air into a great variety of states of *vibration*. The larynx combines, in a unique manner, the integrative and formative effects that we know as part of the dynamic of the head and the intracranial nervous system with the rhythmic activity that we recognize as part of the dynamic of the thorax

6.3. Goethean Aspects

6.3.1. Intracranial Air: Spherical Form and Centripetal Dynamic

The *morphology* and physiology of the air compartments of the skull are an *integrated* part of the morphology of the skull and the physiology of the *senses* (smell, taste and hearing). In particular the paranasal sinuses, the tympanic cavity, and the nasal cavity strive, morphologically, for a spherical shape. The air in the sinuses is practically immobile and there is no gas exchange.

The *centripetal dynamic* that is so typical of the morphological characteristic of the head can be recognized in the slow absorption of air in the sinuses and middle ear.

6.3.2. Alveolar Air: Centrifugal (Divergent) Dynamic

In the area of the airways that is most peripheral, the respiratory units, we find true gas exchange. Gas exchange changes the human organism and the surrounding world equally.

In this part of the airways the lung excursions occur which are connected with the *active movements* of the thoracic wall and the diaphragm.

6.3.3. Rhythmic Air Movements

Starting at the larynx, rhythmic phenomena dominate the trachea and the greater bronchi, both functionally and structurally.

→ *In the morphology and in the dynamic qualities, the respiratory tract displays a morphological and functional trichotomy related to the trichotomy that is seen in the skeleton.*

7. The Morphology of the Digestive Tract

7.1. Introduction

On the basis of embryological development, the intestine is divided into a *foregut*, a *midgut* and a *hindgut*. The transitions are located in the duodenum just passed the opening of the bile duct and in the transverse colon at $\frac{1}{3}$ of the lienal flexure (fig. 7.1.). This trichotomy reappears in the motor activity, and at the functional level. In the foregut, we find peristaltic propulsion and digestion; in the midgut, pendular movement and absorption and in the hindgut stasis, inspissation and bacterial colonization.

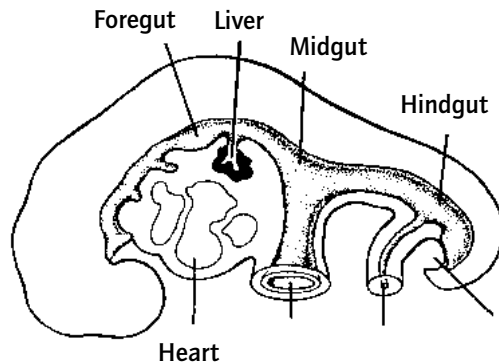


Fig. 7.1. Primitive intestine (Langman 1995)

7.2. The Foregut: Digestion and Perception

7.2.1. The Digestive Organs

A special morphological aspect of the foregut is the presence of *large excretory glands*, such as the salivary glands, the liver, and the pancreas, which all originate from the primitive intestine. These glands all have a more or less spherical shape, are located at a

certain distance from the alimentary canal and are connected to the intestine via excretory ducts. The microscopic glands of the stomach have a tubular structure and display a comparable morphology.

The mucus membrane of the foregut does not have any intestinal villi, as does the small intestine.

7.2.2. The Pharyngeal Gut

The proximal portion of the foregut (the pharyngeal gut) belongs, topographically, to the area of the branchial arches which are innervated by the cranial nerves. From the mouth to the upper third of the esophagus, we find striated muscle tissue, which can be used consciously and matches the relatively high degree of consciousness in this portion of the intestine. The movements in the area of the facial and chewing musculature of the alimentary tract, are completely voluntary, initiated by the facial and chewing muscles. This is in contrast to the movements in the distal parts of the intestine which are unconscious, rhythmical, peristaltic movements.

7.2.3. The Perception of Food

The foregut is functionally geared towards the perception and digestion of the food that has been taken in. Nutrients, such as carbohydrates, proteins, and fats are mechanically, chemically and physically reworked into smaller components.

The production and content of the digestive juices is geared towards the nutrients. A meal that is rich in fats, for example, will stimulate the production of bile. The sensory aspects of the organs of the foregut are important for this to occur and thus for the functioning of the intestines.

The *taste buds* on the tongue and the *olfactory organ* in the nasopharynx are directly related to the ability to consciously perceive the taste and smell of the food. Through the tactile receptors in the lips, tongue, palate and esophageal entrance and the receptors for warm and cold, *conscious perception* reaches from the mouth all the way into the stomach. The mouth is the only place in the organism where the secretion of digestive juices is consciously perceived in a healthy person.

The morphology and topography as well as the dynamic and function of the foregut clearly shows a relationship to cranial characteristics, consciousness, and cranial nerves.

7.3. The Hindgut

7.3.1. Stasis, Absorption, and Bacterial Colonization

The primary, distinctive sections of the hindgut are the descending colon, the sigmoid colon, and the rectum. Anatomically, the configuration is of a rather primitive character.

Macroscopically, the colon has the ability to retain intestinal content.

The primary function of the distal portion of the intestine is the absorption of water and the stasis and solidification of the food bolus. The hindgut is one of the few places in the body where bacterial colonization is normal.

The movement of the large intestine has a direct *relationship to the movements of the legs*. Activities such as walking and playing sports have a directly stimulating effect on defecation.

Defecation creates a relationship to the environment. Feces add new substances to the biological environment which can be used as fertilizers, such as in agriculture. They can add to the destruction of ecosystems, such as is the case in questionable over-fertilization.

7.4. The Midgut

7.4.1. The Rhythmical Aspect

The midgut develops into the distal duodenum, the jejunum, the ileum, the cecum with the appendix and the ascending colon.

The configuration of the midgut remains morphologically simple and is histologically, barely differentiated, in comparison with, for example, the brain or the kidneys. The most significant developments take place in the morphology and function of the intestinal mucus membranes. A rich network of intestinal villi develops extending into the intestinal

lumen. The mucus membranes display, along with intestinal villi that *extend* into the intestine, *receding* structures in the intestinal wall, as well, where absorption of nutrients and secretion of intestinal juices occurs. These are aspects of the rhythmical character of the midgut.

The rhythmical character of the midgut is expressed in two more ways:

The movements of the small intestine are primarily *rhythmic and pendular*. Because of this, food is moved back and forth in the distal and proximal direction.

Along with the *secretion* of digestive juices, the *absorption* of food elements is one of the principle functions. The balanced relationship between secretion and absorption is characteristic for this part of the intestine.

7.5. Goethean Aspects

7.5.1. Introduction

A morphological Goethean assessment of the digestive system is not simple and deserves introductory remarks.

Morphological differentiation expresses itself in complexity of tissue and organ structure.

Macroscopic examples of a high degree of differentiation can be found, for example, in the brain, the sensory organs, or the kidneys. A low degree of macroscopic differentiation can be found in the liver, the intestine, or the skin.

Examples of a high degree of *microscopic* differentiation can be found in neurons, retinal cells, muscle tissue, or erythrocytes; a low degree of differentiation in intestinal cells, liver cells or skin cells: their structure is less complex.

There is a reciprocal relationship between the ability for cell-division in tissues and the degree of morphological differentiation. A high degree of differentiation goes hand in hand with fewer cell-divisions; a low degree of differentiation with many cell-divisions.

The development of malignant tumors is directly connected to this phenomenon: low differentiation means a high chance of malignancy; high differentiation means a low chance of malignancy.

The development of the intestine from the yolk sac is coupled with little morphological differentiation: the tissue retains a primitive structure. Phenomenology is limited when faced with a dearth of notable morphological phenomena, both macroscopic and microscopic.

7.5.2. The Foregut

From the mouth through the duodenum, *morphologically*, relatively *highly differentiated* organs have developed. *Functionally* the contribution from the intracranial nervous system is the possibility of *conscious perception* in of this part of the intestines.

7.5.3. The Hindgut

As has been stated above, the hindgut has a *relationship to the limbs* through its motor system, and its connection with the biological environment.

7.5.4. The Midgut

Everything in the midgut emphasizes the singular characteristic of *rhythm: morphologically in* the structure of the intestinal wall and the meandering course of the intestines in the abdomen, *functionally in* absorption and secretion and the pendular movements.

→ *In the digestive system, we have a morphological and functional trichotomy. Anatomically, the differences are limited. This is connected to the low morphological degree of differentiation in the gastrointestinal tract. Functionally, digestion, resorption, secretion, and, finally, excretion occur in succession.*

8. Comparative Morphology

8.1. Introduction

In this chapter, two aspects of comparative morphology will be examined

- The typical comparative *morphological characteristics* of a body part, organ or organ system
- The *comparative topography* of an organ or organ system in the organism and its relationship with the blueprint as a whole

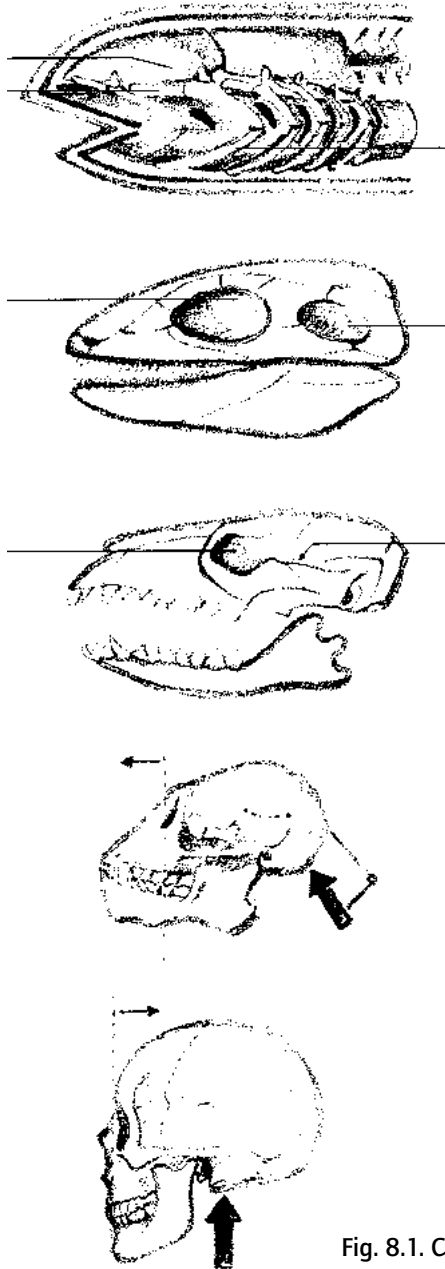
The area of study is limited to the vertebrates, specifically mammals and primates.

8.2. The Comparative Morphology of the Head

8.2.1. The Form of the Head

In the course of evolution, the form of the head and, in particular of the skull in adult vertebrates, has gradually developed into the spherical shape that we recognize in the human being. The distinction between trunk and head in connection with the development of the neck becomes, during the course of evolution, ever more prominent. Among lower animals - such as for example, fish - there is no external, anatomically recognizable division between trunk and head. Simultaneous with the appearance of the neck, we find an increasingly spherical form of the skull (fig. 8.1.). During this process, the head becomes free and develops a separate position within the architecture of the organism.

During this development, the skull becomes the part of the organism in which the most important part of the central nervous system is located: the cerebrum and the cerebellum, the diencephalon, and the brain stem.



8.2.2. Comparative Morphology of the Position and Carriage of the Head

A second aspect of the development of the skull shape is directly connected with the above and is related to the position of the skull within the blueprint of the body.

The human skull is unique in that it rests on the atlanto-occipital joint in a pure *position of balance*. The skulls of all apes and lower mammals maintain partial limb characteristics (Chapter 9.4.3.) and display, a robust forward growth of the area of the face and jaw (prognathism) by which the head does not balance on the atlanto-occipital joint but inclines sharply forwards and downwards. At the same time, there is a relative shifting of the foramen magnum in the dorsal direction (fig. 8.2.). Not only among the apes, also among a great number of mammals do we find thick neck muscles that, to some extent, keep the skull balanced and prevent the head from slipping forward off the spine.

→ *The head develops gradually into the domain of the central nervous system*

Fig. 8.1. Comparative morphology of the head (Rohen 1975)

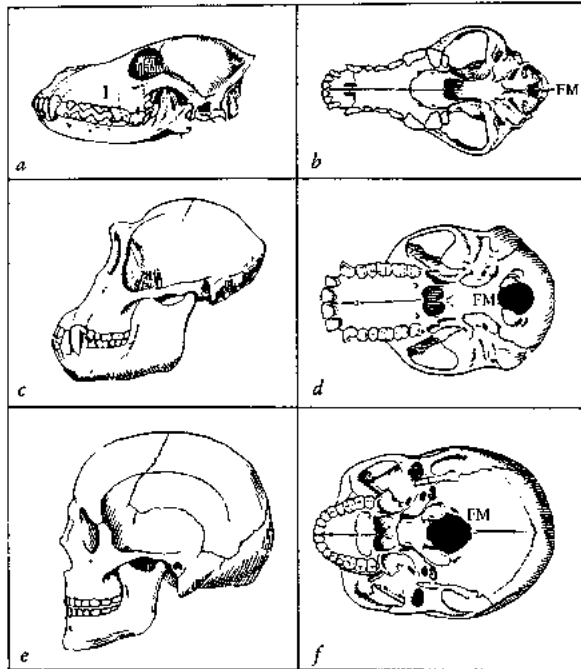


Fig. 8.2. The skulls of humans and of various animals: dog and chimpanzee

Legend: FM = Foramen Magnum (Verhulst 1999)

8.3. The comparative Morphology of the Limbs

The evolution of land animals also displays two developmental steps or 'tendencies' with respect to limb development: one is connected to their morphology, and the other to their topographical position.

8.3.1. Morphology of the Form of the Limbs

The development of the form of the limbs occurs through stretching. Originally, the extremities are situated close to the trunk. As the organisms develop further, we may see the extremities stretching towards the periphery. We also see the round form of the proximal portion of the extremity bones develop more and more, which then leads to the

formation of the ball portion of the ball and socket joint. The morphogenetic dynamic of the head that is expressed here, is also expressed in the nomenclature (*caput humeri*, *caput femoris*, etc).

Another striking phenomenon in the phylogenetic development of the bones of the extremities with respect to each other, is that the stretching is more pronounced proximally than distally. In humans, however, this development is exactly the opposite: it is the forearm and the lower leg which are relatively long compared to the upper arm and upper leg.

8.3.2. The Position of the Limbs

The legs are placed sideways in lower animals, but come to be under the torso, in higher animals. This makes it possible for the torso to become free from the ground and for the crawling movement (such as that of salamanders) to be transformed into a walking movement. The front extremity will function as a leg as long as the scapula occupies a lateral position. It is only when the scapula becomes dorsally situated, that the free mobility of the arm can develop (Chapter 9).

8.3.3. Quadrupedal and Bipedal

The torso becomes erect against the pull of gravity, as the quadruped develops into the biped. The balanced, upright gait of humans has its center of gravity in the pelvic region. Only in humans is the center of gravity situated within the boundaries of the body and are the joints of the occiput, shoulders, hips, knees, and the ankles connected by one straight, vertical line.

For skeletal formation, this means that the characteristic of parallelism of the long bones is acquired only among humans (Chapter 3.2.4.).

8.4. The Thorax

8.4.1. Comparative Morphology of the Form of the Thorax

Characteristic for the evolution of higher organisms is the development of distinct compartments within the organism in which organs are located for specific functions. What we described in chapter 8.2.1. with respect to the development of the skull in relation to the central nervous system, also applies to the thorax with respect to the heart and lungs.

The morphological development of the thorax can be understood as a cross between the development of the form of the skull and that of the limbs, as described in chapter 3.3.

The enveloping structures of the thorax do not only consist of skeletal parts. The muscular thoracic diaphragm is essential for the development of the thoracic cavity: it provides a definitive separation of the body cavities of the rhythmically active organs and the organs of digestion and reproduction.

8.4.2. Comparative Morphology of the Position of the Thorax in Relation to Respiration

The development of the thorax has, in comparative morphology, a direct relationship to the development of pulmonary respiration and the development of the extremities. This process generally runs parallel to the process described above concerning the development of the neck (Chapter 8.2.1.), in which the head and trunk come to be functionally separated. A descensus of the portions of the lung that have a rhythmic or metabolic character occurs in the course of further development.

In fish, oxygen can only be absorbed from water through respiration via the gills. The gills and the heart in fish are located in an area that, among higher animals, corresponds to the neck. It is not until later in evolution that organisms evolve with a pulmonary respiration in which the specialization of the lung is closely related to the development of the heart. It is during this development that the heart takes up its ultimate position in the thorax.

→ *The thorax gradually develops into its own domain for heart and lungs.*

→ *The development of the thorax as the location for the lungs as a gas exchange organ appears, in the first instance, amazing from the point of view of efficiency and functionality. There is no more economical manner of gas exchange than via the gills, when a stream of water with high oxygen saturation enters through the mouth and is brought into contact with the blood which has a low oxygen and a high carbon dioxide saturation.*

The development of the thorax and, in particular the descensus and stretching of the trachea and bronchial tree, creates the so-called 'dead space'. In this dead space, the air

only shuttles back and forth; there is no gas exchange. From the point of view of gas exchange, a marked loss of functional space is created. This dead space is, however, a structure that is made functional for speech. The production of sound with the aid of respiration can occur because of the development of the larynx and the trachea in the anatomical and physiological dead space of the airways.

9. Polarization and What is in Between

9.1. Introduction

We have seen that *polarization* is an important morphological principle in human morphology. During the discussion of the skeleton, we established that the head and the limbs display a strikingly different and polar morphology. The skull, the thorax, the spinal column, and the extremities each display polar aspects. The spherical tendency dominates the form cranially and the radial tendency dominates on the caudal end. In between the two, a rhythmical principle arises that both divides and connects the poles. In this chapter, we will further study how polarization manifests itself in the various regions of the human organism.

The **ascensus** and **descensus** of developing organs and tissues in the embryonic development of all organisms, is a phenomenon that indicates the direction of polarization. The principle of polarization provides insight into the meaning of the ascensus and descensus of organs and tissues. The general tendency that can be observed in this is that topographical migrating of the organs and tissues is connected to the function they have in the blueprint of the organism. Descending organs, such as the neurohypophysis, the thyroid, and the gonads have more the character physiologically, of the metabolic system. Ascending organs, such as the adrenal gland, the spinal cord, and the adenoypophysis are physiologically more closely related to the nervous system. There appears to be a relationship between the topographical position within the blueprint and the physiology of organs or organ systems.

9.2. The Head

9.2.1. The Neurocranium

Within the blueprint of the organism, the dominant feature of the head is the central nervous system.

Within the architecture of the head itself, the neurocranium is the domain of the central

nervous system. The cerebrum, the mesencephalon, the cerebellum, and the brain stem are all intracranial. Also, important sensory organs such as the organ of smell, the eyes, the organ of balance, the auditory organ, and the cranial nerves which belong to them are, for the most part, situated intracranially. Topographically, the upper dorsal-side is the location of the *central nervous system*, both in the blueprint of the organism as a whole and in the blueprint of the head.

9.2.2. The Splanchnocranium

Under the base of the skull and surrounded by the lower jaw and the hyoid bone (evolved from the branchial arches) we find the *splanchnocranium* at the *lower-frontal* side of the head (for the correlation with the organism as a whole, see Chapter 9.3.2.). Here is the starting point of the digestive organs. Mouth, oral cavity, teeth, and tongue, the salivary glands, the muscles for chewing, and the swallowing muscles of the pharynx are, within the blueprint of the digestive system, understood to be its cranial portion. Here we find conscious processes such as seeing, smelling, tasting, and touching with the tongue, which actually set the digestive process in motion.

9.2.3. The Pneumocranium

The nasal cavity and the corresponding paranasal sinuses form the center of the aerated structure of the head. The total air content takes up a considerable amount of space. The nasal cavity, the maxillary, sphenoid, and the frontal sinuses, and the air cells in the ethmoid and the mastoid bones together form the *pneumocranium*. The Eustachian tube, the tympanic cavity and the external auditory meatus are also considered to be part of the pneumocranium. These structures lie, topographically between the neurocranium and the splanchnocranium and, therefore, occupy a *mid-position* within the architecture of the head.

9.2.4. The Large Blood Vessels

The position of the large blood vessels deserves to be mentioned separately. The main arteries (the common carotid artery, the internal and external carotid arteries) are found in the narrow area between the neurocranium and the pneumocranium. Therefore, the middle part of the skull, that has thus far been termed the pneumocranium, can be divided into an air domain (lower frontal area of the middle part) and a blood vessel area (upper dorsal area of the middle part), a blueprint that we recognize from the thorax.

9.3. The Trunk

9.3.1. The Nervous System and the Trunk

The nervous system of the trunk is formed by the spinal cord, the sympathetic trunk, the vagal nerve, and the sympathetic ganglia surrounding the celiac artery, the adrenal glands, and the superior and inferior mesenteric arteries. Nerve tissue is again concentrated in the upper dorsal area.

9.3.2. The Digestive System and the Trunk

The majority of the *digestive system* is found in the *lower frontal area* of the trunk. The stomach, the duodenum, the small and large intestines, and the large accessory digestive organs are also located in the abdominal cavity. At the upper front, the digestive system is related to the nervous system and consciousness.

9.3.3. The Pneumatic Cavity and the Trunk

Topographically the lungs are situated in the upper part of the mid-section of the trunk, just as the paranasal sinuses are situated in the mid-section of the skull. In the thorax, the

relationship between the organization of air and the system of blood vessels once again becomes evident. The large arteries and blood vessels (the aorta and the pulmonary arteries) are situated between the area in which the nerve tissue is concentrated along the spine and the aerated organs in the thorax. In the thorax, we also find that the mid-section is divided into an aerated portion (lower front) and a blood vessel portion (upper back). Thus, we see that a repetition of morphological elements in the blueprint of the head was already visible.

The airways themselves also undergo a polarization. The alveolar space for gas exchange 'descends' in the course of development and the aeration of the nasal sinuses 'ascends.' In between the two, the dead space of the trachea and the bronchial tree are created in which the larynx can develop freely into the organ of speech due to its relationship to rhythmic functioning air.

9.4. The Limbs

9.4.1. The Polarization of the Extremities

Comparative anatomy of the extremities has clearly demonstrated that complete polarization is unique to the human being.

Among ruminants, predators, and rodents we see no actual differentiation between the front and hind extremities. The number of persistent rays of the embryonic limb

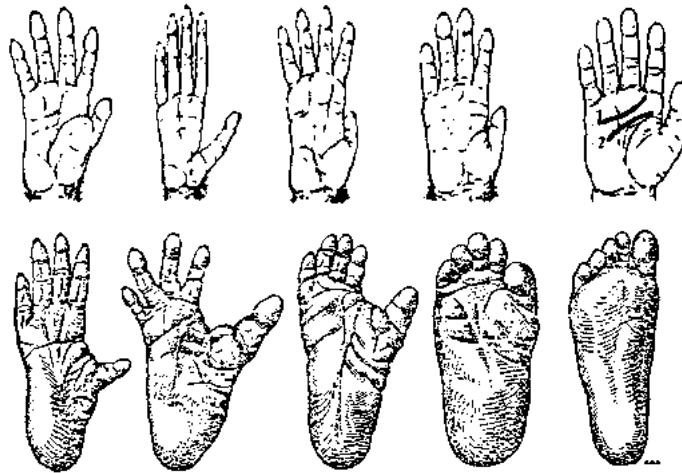


Fig. 9.1. The hands and feet of apes and the human being (Verhulst 1999)

bud is identical for both the front and the back and the macroscopic anatomy also displays large similarities. Here, the polarity between the hand and the foot, as is seen in humans, is reduced to *quadrupedalism*.

Even among the most highly developed apes, the polarization is incomplete. The position of the foot is one of slight supination, so that the ape leans more on the lateral side of the foot than on the whole sole of the foot, as humans do. Also, the foot of the ape has an opposable big toe which allows it to function as a grasping organ, comparable to the hand.

However, in comparison to the human hand, the ape's thumb is much less opposable, so that free mobility becomes limited. During walking, the ape's hand - to a high degree - is used as an organ of support. The natural position of the ape hand is slightly pronated. The polarity between hand and foot is reduced here to '*quadrumanualism*' (fig 9.1.).

9.4.2. The Human Hand and Foot

Morphologically, the human hand and foot are an exception to the rule with respect to the primates and other mammals. Anatomically the human foot is completely pronated. The big toe is non-opposable and the ankle joint is anterior. Humans stand with the soles of their feet parallel to the surface of the earth. The arch of the foot is, architecturally, optimally structured to conduct the force of gravity and with a minimum of bone material and a maximum of mechanical perfection is achieved.

Anatomically the hand is completely supinated, and the ulna and radius are parallel to each other. The thumb is maximally opposable and there is free mobility to the greatest possible degree. That is why, in ancient nomenclature, the upper extremity was called the "*extremitas libera*".

We emphasized that, in humans, polarization is maximized. The hands and feet of mammals and even primates have a great resemblance to each other. In this respect too, humans can be differentiated, morphologically, from all mammals.

9.4.3. The Difference between Humans and Mammals


The long bones of all the higher mammals display a tendency towards curvature. This is true for each individual bone as well as for the position of the extremities: no mammal stretches its extremities during standing or walking. The front and back legs always remain slightly bent. Within the blueprint of the organism, *that tendency belongs to the dynamic of the cranium.*

At the same time the higher mammals develop a radial and parallel dynamic in the facial portion of the skull - in particular, in maxilla and mandible - that is more *specific for the limbs*. Because of this, maxilla and mandible develop into the form of a snout, as is seen in predators, ruminants, rodents, and many other types of animals. The snout in animal kingdom, specifically the mandible, is used as if it were an *extremity for grabbing*.

In the human being, evolution achieves, for the first time, complete polarization in the morphology: the head displays few or no dominant morphological characteristics that are typical of the limbs and the limbs display few or no tendencies in form, anymore, that are considered to be specific to the skull.

→ In the animal world the morphological dynamic still remains mixed, and the animal body is an instrument for instinct determined behavior.

The human body can be understood as an instrument of freedom, because morphology is completely and essentially polarized.




Literature

- Benninghof-Goerttler.** Lehrbuch der Anatomie des Menschen, Urban & Schwarzenberger, München-Berlin, 1964.
- Bie GH van der.** Embryology, from a phenomenological point of view, Louis Bolk Instituut, Driebergen, 2001.
- Bortoft H.** Goethe's Scientific Consciousness. Institute for Cultural Research, 1986, ISBN 3-7725-1544-4.
- Feneis H.** Anatomisches Bildwörterbuch der internationalen nomenklatur, Thieme Verlag, Stuttgart, New York, 1983.
- Husemann F and Wolff, O.** The Anthroposophical Approach to Medicine: An Outline of a Spiritual Scientifically Oriented Medicine, vols. 1-3. Anthroposophic Press, 1982.
- Kiss/Szentagothay.** Atlas of human Anatomy, Pergamon press, Oxford, London, New York Paris, 1964.
- Langman.** Medical Embryology, Lippincot Williams & Wilkins, 1995.
- Moore K.** Clinically oriented Anatomy, Williams & Wilkins, 1999.
- Netter FH.** The Ciba collection of medical illustrations, Ciba, New York, 1967.
- Poppelbaum H.** Mensch und Tier, Rudolf Gering Verlag, Basel, 1933.
- Rohen JW.** Morphologie des menschlichen Organismus, Verlag Freies Geistesleben & Urachhaus GmbH, 1998.
- Rohen J.** Funktionelle Anatomie des Nervensystems, F.K. Schattauer Verlag, Stuttgart-New York, 1975.
- Schoorel EP.** De eerste zeven jaar, Christofoor, Zeist, 1999.
- Steiner R.** Goethes Weltanschauung, 1. Auflage, Weimar, 1897 (GA 6).
- Verhulst G.** Der Erstgeborene, Mensch und höhere Tiere in der Evolution. Verlag Freies Geistesleben, Stuttgart, 1999.
- Vogel L.** Der dreigliedrige Mensch, Philosophisch-antroposphischer Verlag, Dornach/Schweiz, 1979.
- Woerdeman MW.** Standard Atlas of human Anatomy, Scientific publishing company, Amsterdam, 1954.

BOLK'S COMPANIONS FOR THE STUDY OF MEDICINE

Other publications in the series:



Embryology
Early Development from a
Phenomenological Point of View

Guus van der Bie, M.D.
Publicationnumber GVO 01

Can we give a scientific basis to our feeling that humans have unique human features? Are the human mind and the human organism 'nothing but' another variation of animal life? Can we find answers for the questions that satisfy both head and heart?

How these questions are answered depends on the scientific method we use: the current scientific method to learn about biological facts and the phenomenological method to understand more about the meaning of these facts.

Early embryological development can teach us about the unique and characteristic qualities of the human being.

The result is, for example, a possibility to understand the relation between consciousness, psychology, and behavior and the shape of the body.



Biochemistry
Metabolism from a
Phenomenological Point of View

Christina van Tellinggen, M.D.
Publicationnumber GVO 02

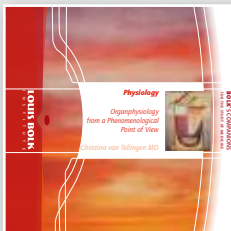Biochemistry offers insight into the continuous changes within the human organism. But can we maintain awareness of the coherence of the (changing) organism as we study the details? How can the many processes be understood as prototypical aspects of a unique organism?

The scope of the answers to these questions can be enhanced by using a combination of the current scientific method and a phenomenological method developed specifically to research the coherence of processes within living organisms. The current scientific method is used to discover biological facts. The phenomenological approach helps us in finding the meaning of the facts.

What emerges is a new grasp of the interrelations between biological processes, consciousness, psychology, and behavior.

BOLK'S COMPANIONS FOR THE STUDY OF MEDICINE

Other publications in the series:



Physiology Organophysiology from a Phenomenological Point of View

Christina van Tellinggen, M.D.
Publicationnummer GVO 04

Can physiology give more insight into the living human organism than the mere facts reveal at first? Is the level of activity the same for all organs? Are the vital qualities at work in organs unique for organisms and limited to biological activity? Can we find a scientific basis to research the coherence between organ systems?

By enhancing the current scientific method with phenomenological points of view we can find meaning in the facts and understand them as an expression of life itself. The phenomenological method makes the relation between organs visible and comprehensible. It approaches scientific facts from the point of view of their coherence and can give totally new insights this way.

What emerges is a grasp of the interrelations between biological processes, consciousness, and nature.



Immunology Self and Non-self from a Phenomenological Point of View

Guus van der Bie MD
Publicationnummer GVO 05

Why write this new booklet on immunology when there are already so many excellent texts on the subject? This Companion is about questions such as: why is it that the immune system functions as one organ? What coordinates the immunological functions?

Here, an attempt is made to develop a viewpoint to answer these questions. By using a phenomenological approach, the factual knowledge obtained through reductionism is placed in a larger perspective.

The concept that is presented in this Companion is derived from the functioning of organisms, observed in the way that was introduced by Goethe in his phenomenological method. This also includes the acquisition of insight into the holistic concept behind the immune system. Moreover, the organism as a whole can then be seen as an expression of the same concept.

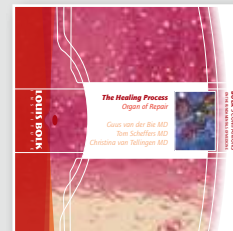


Pharmacology Selected Topics from a Phenomenological Point of View

Christina van Tellinggen MD
Publicationnummer GVO 06

Pharmacology gives us insight into the way organic processes change when foreign compounds are introduced into the organism. Pharmacology is a changeable subject, depending on the needs and knowledge of the time. Can we find an inner coherence in the manifold ways compounds influence organisms? What should such a framework be based on? How can we understand the effect on human consciousness that most compounds have?

We can enhance the scope of the answers to these questions by using a combination of the current scientific method and a phenomenological method. It illuminates the known facts about the activity of compounds in organisms, and provides the means to find their significance.




The Healing Process Organ of Repair

Guus van der Bie MD
Tom Scheffers MD
Christina van Tellinggen MD
Publicationnummer GVO 07

After finalizing the series Bolk's Companions for the Study of Medicine for the moment, this module on The Healing Process introduces a new series of Bolk's Companions that studies the Practice of Medicine. In it, we research the healing process itself. There proved to be an enormous volume of scientific literature on the subject. It is easy to lose oneself in the countless details included in the descriptions of this process.

The phenomenological method of systems biology makes it possible to examine physiological and pathological processes in terms of the processes themselves. This results in a characterization of the various phases of the wound healing process. Out of this, new insights into the origin of health and disease emerged that also offer possible leads for medical practice.



Respiratory System Disorders and Therapy

From a New, Dynamic Viewpoint

Christina van Tellingen MD
Guus van der Bie MD (eds.)
Publicationnummer GVO 08

In this Companion, the experience of three of our own patients with asthma and pneumonia is used as backdrop for our study of airway disorders. Nearly all of us have had some experience with respiratory disease, given that colds, flus, sinusitis, and bronchitis are so common. Most physicians and therapists know people with asthma and pneumonia from own experience and will readily recognize the descriptions we provide.

The experience with these patients leads us through a study of airway disease which eventually opens up to a wider view with new insights and innovative avenues of treatment for respiratory disorders in general.

Our research has alerted us to the part rhythm plays in the healthy respiratory tract and in the treatment of its disease. Rhythm, consequently, is the subject of the final paragraphs of this Companion.




Depressive Disorders An Integral Psychiatric Approach

Marko van Gerven MD
Christina van Tellingen MD
Publicationnummer GVO 09

The treatment of depressive disorders is increasingly under scrutiny. We classified the risk factors of depressive disorders according to the scientific method applied in systems biology and phenomenology. The ordering in four biological levels that resulted from this, helps clarify the causes of the disorder. Together with the developmental history, it can lead to an individualized treatment of the patient, tailored to his or her specific situation. The treatment aims at restoring the deficient forces of self-healing.

This Companion presents a working model based on this methodological approach, as well as a variety of case histories to illustrate how applying this model can aid diagnosis and treatment in practice. Tables are added ordering well-researched regular and integral treatment methods according to the four biological levels.



Wholeness in Science A Methodology for Pattern Recognition and Clinical Intuition

Guus van der Bie MD

How do you develop clinical intuition? How do physicians gain practical knowledge about disease?

The above questions are vital for medicine. Diseases do not merely concern a partial defect, they recreate the life of the patient. At the hand of Pfeiffer's disease, the author shows that experienced physicians conceive of diseases as integrated concepts, which they can apply to the individual situation of the patient. Their clinical intuition is a form of pattern recognition and pattern recognition supports the ability to recognize an integrated 'whole.'

The practical exercises of this Companion allow readers to train and expand their ability of pattern recognition through Goethe's methodology. Clinical intuition, as experiential knowledge, appears to be a skill that can be actively developed.

Anatomy

Morphological Anatomy from a Phenomenological Point of View

Can we give a scientific basis to our feeling that the human being has unique human features? Are the human mind and the human body 'nothing but' another variation of animal life? Can we find answers for these questions that satisfy both our head and our heart?

How these questions are answered depends on the scientific method we use. In this publication two methods are used: the current scientific method to learn about anatomical facts and the phenomenological method to understand the meaning of these facts.

Human morphology can then be understood as an expression of the unique and characteristic qualities of the human being. This results in new possibilities for understanding the relation between consciousness, psychology, behavior, and morphological aspects of the body.