

# **LECTURE NOTES**

For Health Officers

# *Oral Health*



**Ethiopia Public Health  
Training Initiative**

Banchiamlak Demissie

Addis Ababa University

In collaboration with the Ethiopia Public Health Training Initiative, The Carter Center,  
the Ethiopia Ministry of Health, and the Ethiopia Ministry of Education

2006



Funded under USAID Cooperative Agreement No. 663-A-00-00-0358-00.

Produced in collaboration with the Ethiopia Public Health Training Initiative, The Carter Center, the Ethiopia Ministry of Health, and the Ethiopia Ministry of Education.

### **Important Guidelines for Printing and Photocopying**

Limited permission is granted free of charge to print or photocopy all pages of this publication for educational, not-for-profit use by health care workers, students or faculty. All copies must retain all author credits and copyright notices included in the original document. Under no circumstances is it permissible to sell or distribute on a commercial basis, or to claim authorship of, copies of material reproduced from this publication.

**©2006 by Banchiamlak Demissie**

All rights reserved. Except as expressly provided above, no part of this publication may be reproduced or transmitted in any form or by any means, electronic or mechanical, including photocopying, recording, or by any information storage and retrieval system, without written permission of the author or authors.

*This material is intended for educational use only by practicing health care workers or students and faculty in a health care field.*

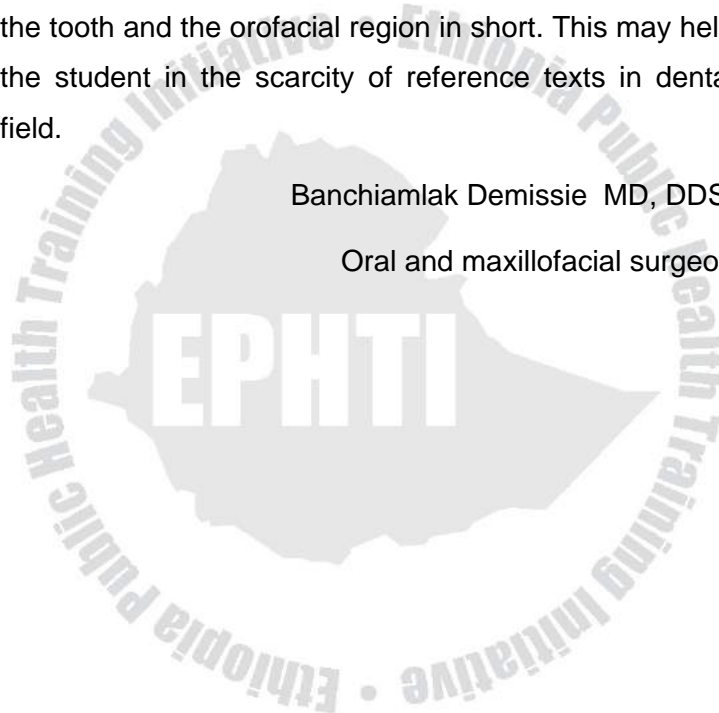
## **PREFACE**

I have been using this material for the last 13 years for teaching health officer students in Gondar University, Dilla College, Almaya University, and Debub University. During the process the material developed from time to time. I believe that transfer of scientific knowledge in oral health could be beneficiary to the needy population where oral health is found in a low standard. In our country there is no enough qualified human resource in dental profession, however the need for dental service is increasing. Teaching oral health care to health officer students even to other health science students will definitely will help the people get better service in the area. Majority of the Ethiopian population has no proper dental service; they are getting help by the local practitioners. Even though not to be appreciated, it is undeniable that the local practitioners, had contributed and are contributing a lot to the people, in areas where there is no dental service. Mal practice, lack of knowledge and un sterile instruments had resulted in bad outcomes like fracture of the mandible, dislocation of the temperomandibular joint, Fracture of tooth and roots etc. Bacterial plaque which is the result of poor

oral hygiene results in an unnecessary tooth loss. Even though it is not within the scope of this material to cover all dental related problems, I have tried to include the common dental problem, their management and prevention precisely. I have also included anatomy of the tooth and the orofacial region in short. This may help the student in the scarcity of reference texts in dental field.

Banchiamlak Demissie MD, DDS.

Oral and maxillofacial surgeon



## ACKNOWLEDGEMENT

First and most, I would like to give thanks to Supreme Power God for giving me health, energy, courage and inspiration to accomplish my work.

I would like to acknowledge The Carter Center (EPHTI) for the initiation and drive for the preparation of this manual.

I would like to acknowledge Dr Mesfin Addise for the information, supports and useful suggestions which were useful for the preparation.

It is a pleasure to make a special acknowledgement of

1. Dr. Wondewossen Fantaye DDS. PhD.(Oral community health specialist)
2. Dr Shiferaw Degu DDS. M.Phil.Dent.(Orthodontist)
3. Dr Mekonnen Neway MD. DDS, Oral and Maxillofacial Surgeon
4. Dr Haregewoin Eshetu DDS, Head, Dental Unit, Armed Force Hospital, Addis Ababa

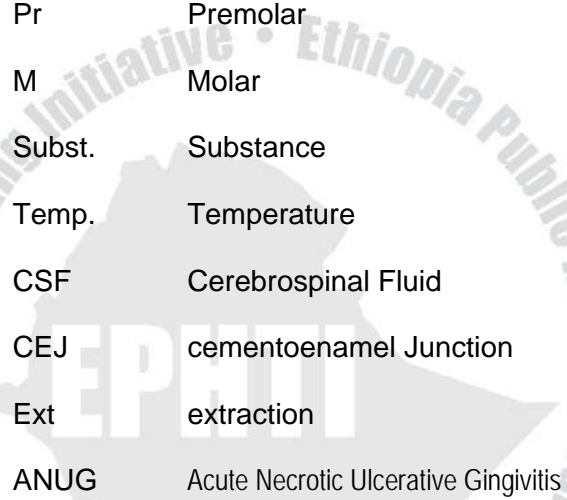
My acknowledgement goes to Nib Public Transport Private Owners Association, especially to Captain Belete Admassie, the general manager of the Association.

I would like to acknowledge W/t Seblewongel Nigussie, the secretary of the general manager of the Association.

My special acknowledgement goes to the Authors of Texts, Journals, and Articles which I referred and used their work.

Finally my incredible acknowledgement goes to all my friends, family members, and especially to my daughters, Eden Bekele, Mariam Bekele, Ruth Bekele, Tigist Alemayehu, and Fikiraddis Abate.

## LIST OF ABBREVIATIONS



I	Incisor
C	Canine
Pr	Premolar
M	Molar
Subst.	Substance
Temp.	Temperature
CSF	Cerebrospinal Fluid
CEJ	cementoenamel Junction
Ext	extraction
ANUG	Acute Necrotic Ulcerative Gingivitis

## TABLE OF CONTENTS

Preface .....	i
Acknowledgments .....	iii
List of abbreviations .....	v
Table of content .....	vi
List of figures and tables .....	ix
<b>Chapter 1: Introduction .....</b>	<b>1</b>
Historical development of oral health ....	2
Introduction to Dentistry.....	3
Course objective and course content ....	5
<b>Chapter 2: Anatomy of the oral cavity.....</b>	<b>7</b>
Anatomy of the tooth .....	8
Artery of the tooth and the oral cavity....	12
Nerve supply of the tooth and the oral cavity .....	16
The muscles of the face and the oral cavity.....	22
Chronology of tooth development .....	25
<b>Chapter 3: Nomenclature.....</b>	<b>28</b>
Tooth surface designation .....	33
<b>Chapter 4: Examination of dental patients.....</b>	<b>35</b>
Clinical techniques of Examination.....	37
Systemic examination of patients .....	38



<b>Chapter 5: Disease of the hard tissue of the tooth ..</b>	<b>41</b>
Dental caries.....	41
Regressive alteration of the teeth (Non caries diseases).....	47
<b>Chapter 6: Disease of the dental pulp.....</b>	<b>49</b>
Pulpitis .....	49
<b>Chapter7: Periodontal diseases (Gingivitis and periodontitis)</b>	<b>52</b>
Anatomical consideration .....	52
Defense mechanism of the oral cavity .	54
Classification of periodonta disease .....	59
Gingivitis .....	60
Periodontits.....	64
<b>Chapter 8: Anesthetic consideration in dental practice</b>	<b>67</b>
Techniques of local anesthesia .....	67
Block Methods of anesthesia.....	68
<b>Chapter 9: Tooth extraction.....</b>	<b>78</b>
Indication and contraindication .....	78
Complication of tooth extraction .....	80
Instruments of tooth extraction .....	81
Position of patient and operator during tooth extraction.....	88
Steps of tooth extraction.....	89
Dental instrumemnts for minor surgery .	90

<b>Chapter10: Odontogenic infections.....</b>	<b>92</b>
Osteomyelitis of the jaws.....	92
Cellulitis .....	95
Indication and principles of incision and drainage	
Medical supportive care .....	100
<b>Chapter 11: Trauma of the teeth and orofacial region</b>	<b>103</b>
Soft tissue injury .....	103
Dental Trauma.....	105
Fracture of the orofacial region.....	107
Maxillary fracture .....	114
<b>Chapter 12: Congenital malformation .....</b>	<b>119</b>
Cleft lip and palate.....	119
<b>Chapter 13: Principles of preventive dentistry (oral health)...</b>	<b>122</b>
Microbes of the oral cavity.....	122
Principles of preventive dentistry.....	124
Prevention of periodontal diseases .....	129
Reference.....	131

## LIST OF FIGURES AND TABLES

### List of figures

Figure 1: Anatomy of the oral cavity .....	7
Figure 2: Dental anatomy.....	9
Figure 3: Branches of maxillary artery .....	15
Figure 4: Branches of maxillary nerve .....	18
Figure 5: Anatomy of the trigeminal nerve (mandibular branch).....	21
Figure 6: Tooth surface designation .....	34
Figure 7: Clinical techniques of dental patients	40
Figure 8: Schematic drawing of the gingiva and gingival junction.....	53
Figure 9: Techniques of infraorbital block .....	71
Figure 10: Techniques of greater palatine block	73

Figure 11: Techniques of mandibular block .....	75
Figure 12: Bionet forceps .....	83
Figure 13: Wisdom forceps for the upper jaw ..	84
Figure 14: Different elevators (alb) .....	86

**List of tables**

Table 1: Chemical compositions of tooth .....	10
Table 2: Number of teeth and their roots in the jaws in both dentitions .....	11
Table 3: Chronology of human dentition .....	26
Table 4: Differential diagnosis of pulpitis and deep caries	51

# CHAPTER ONE

## INTRODUCTION

Oral health has been given less priority in Africa, because of other health problems of the continent which are life threatening and communicable. In the past all Africans were assumed to have good teeth, therefore the need for oral health was not given priority. According to WHO, dental caries is a problem of growing concern to most African countries. Dentistry was practiced in Ethiopia in 1923 in Dire Dawa by a Reussian female doctor. She was attending about 10 patients a day, out of which 6 of them were workers of the train station. In 1953 the first Ethiopian qualified dentist started to work. At present there are about 55 dentists including specialists in some of the special fields of dentistry. These dentists were trained in 19 different countries. There are also 55 dental therapists who were trained in the first dental health service and training center in Addis Ababa, established in 1990 by NGO called Medicus Mundi in collaboration with the Italian Government. At present the center is upgraded to a dental school and training students in bachelor of dental

science, Jimma University has recently started training Doctor of Dental Medicine. Ten dental technicians are practicing in the country, all of them have got their training abroad. Preliminary studies done in the past showed that the Ethiopians have good teeth with low rate of caries prevalence; however caries is on the increase because of the replacement of none carious foods of developing countries by sugar rich western foods. Even though in recent years in Ethiopia research works are not done, however, the need for dental service is growing, the resource are scarce and maldistributed, skilled human resource in the country is very few. Thus training of other health science students in oral health is un questionable issue. I hope this type of training in oral health care will contribute in prevention of infections which may be transmitted through mal practices by untrained practitioners. This may include transmission of HIV/AIDS, hepatitis, etc. diseases which are among other main health problems of our country at present.

At the time of cold war the world was devided into two blocks, East and West. This had influenced peoples' mind and caused differences in many conditions not

excluding medical field. In the field of dentistry, differences in medical terminologies like Dentistry or stomatology, Oral surgery or surgical stomatology were the results of those times. Eastern countries used the term stomatology while Dentistry is used in the western blocks.

Stomatology - derived from Greek Word

Stoma- Organ of Oral Cavity

Logos- Study

i. e Study of oral cavity.

In Boucher's Dictionary of Clinical Dental Terminology, the definition of terminologies is given as follows:

**Stomatology** is the study of the morphology, structure, function and diseases of the contents and lining of the oral cavity.

Dentistry is the science and art of preventing, diagnosing, and treating, diseases, injuries and malformations of the teeth, jaws and mouth and of replacing lost or absent teeth and associated structures.

Stomatology/ Dentistry has two divisions

- a. General stomatology/Dentistry
- b. Subspecialities

**a. General stomatology/Dentistry**

1. Conservative/Restorative/operative/ stomatology/  
Dentistry
2. Surgical Dentistry
3. Pediatric Dentistry/pedodontics
  - conservative Pediatric Dentistry
  - Surgical Pediatric Dentistry
  - Orthodontics Pediatric Dentistry

**b. Special fields of stomatology /Dentistry**

1. Prosthodontics
2. Endodontics
3. Paradontics/ periodontics
4. Oral surgery
5. Maxillo- facial surgery
6. Pedodontics/Pediatrics dentistry
7. Dental public health
8. Oral medicine
9. Oral pathology
10. Oral microbiology



## 11. Dental and maxillofacial radiology

### **Course Objective**

After the completion of the course the student will be able to:

- Identify and treat common oral and dental diseases
- Plan, promote and organize preventive oral health

### **Course content**

1. Anatomy of the oral cavity
2. Nomenclature
3. Examination of dental patients
4. Disease of the hard tissue of the teeth
5. Disease of the dental pulp
6. Gingivitis and periodontal disease
7. Extraction of teeth:- indication, contraindication, technique, instruments, complication...

8. Anesthetic considerations (Advantages, methods..)
9. Trauma of tooth, soft tissue and jaws
10. Odontogenic infections
11. Congenital malformations:- cleft Lip and palate
12. Oral health care

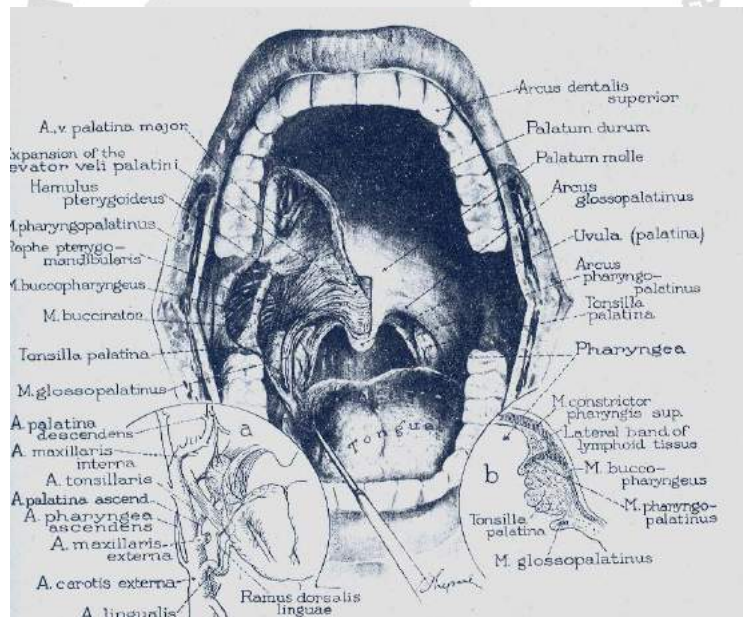

## CHAPTER 2

### ANATOMY OF THE ORAL CAVITY

In the chapter the muscles, blood supply, innervation of oral structures like the lip, teeth, palate, oral mucosa, gum which are pertinent to the course will be overviewed by the following figure.

**Figure 1: Anatomy of the oral cavity**



## **Anatomy of the teeth**

Tooth is made up of enamel, dentine, pulp and cement.

Enamel is the hardest part of the tooth with the greater part of it covering the crown. This helps us in the process of chewing food.

### **Dentin**

This sensitive ivory like substance that forms the body of the whole teeth

### **Pulp**

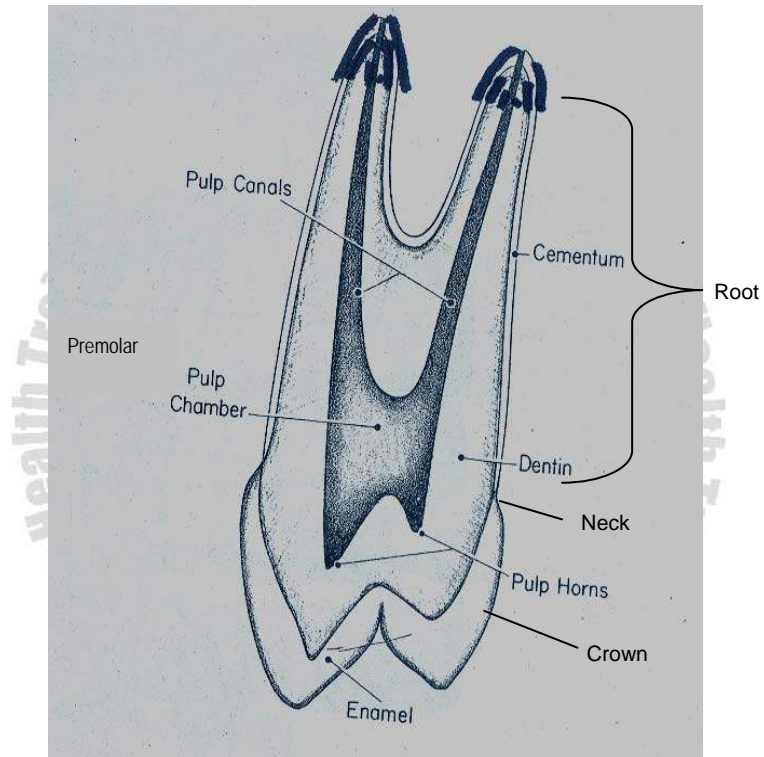
This is an extremely sensitive mass of thin nerve and blood vessels which enter through apical canal at the apex of each root.

### **Cement**

This is a thin hard bone-like layer which covers the roots.

The main parts of the teeth are crown, Neck and Root.

**Figure 2:** Dental anatomy



**Table 1:** Chemical composition of tooth

	<b>Enamel</b>	<b>Dentine</b>	<b>Pulp</b>
Inorganic subst.	95%	69%	1%
Organic subst.	4%	20%	4%
Water	1%	11%	95%

### **Classification of teeth and their numbers in the jaws.**

They are classified according to their function and development.

According to their development- Deciduous and permanent

According to their function -- Incisors, Canines, premolars and molars.

**Table 2:** Number of teeth and roots in the jaws in both dentitions

Number of roots& teeth		I	R	C	R	Pr	R	M	R
Deciduous	Upper Jaw	4	1	2	1	0	0	4	3
	Lower Jaw	4	1	2	1	0	0	4	2
Permanent	Upper Jaw	4	1	2	1	4	1,2	6	3
	Lower Jaw	4	1	2	1	4	1	6	2

I = incisor, R=Root, C= canine, Pr=Premolar, M=Molar

## Function of the tooth

**Incisors:** Biting of the food initially

**Canines:** Tearing of tough pieces of food.

**Premolars and Molars:** Grinding the food in to small pieces before swallowing

### Arterial Supply to the Teeth and oral cavity

The arteries and nerve branches to the teeth are mere terminals of the central systems. This manual will only confine to dental anatomy and the parts immediately associated structures, therefore reference be made only to those branches that supply the teeth and the supporting structures.

#### Internal Maxillary Artery

The arterial supply to the jaw bones and the teeth comes from the *maxillary artery*, which is a branch of the *external carotid artery*. The *branches* of the maxillary



artery which feed the teeth directly are the *inferior alveolar artery* and the *superior alveolar arteries*.

### **Inferior Alveolar Artery**

The *inferior alveolar artery* branches from the maxillary artery medial to the ramus of the mandible .It gives off the *mylohyoid branch*, it supplies:

- the premolar and molar teeth
- the chin
- the anterior teeth
- the mandible and teeth.
- the pulp and of the periodontal membrane at the root apex.

### **Superior Alveolar Arteries**

The *posterior superior alveolar artery* branches from the maxillary artery superior to the maxillary tuberosity to enter the alveolar canals along with the posterior superior alveolar nerves and supplies:

- the maxillary teeth,
- Alveolar bone and membrane of the sinus.

- The gingiva, alveolar mucosa, and cheek.

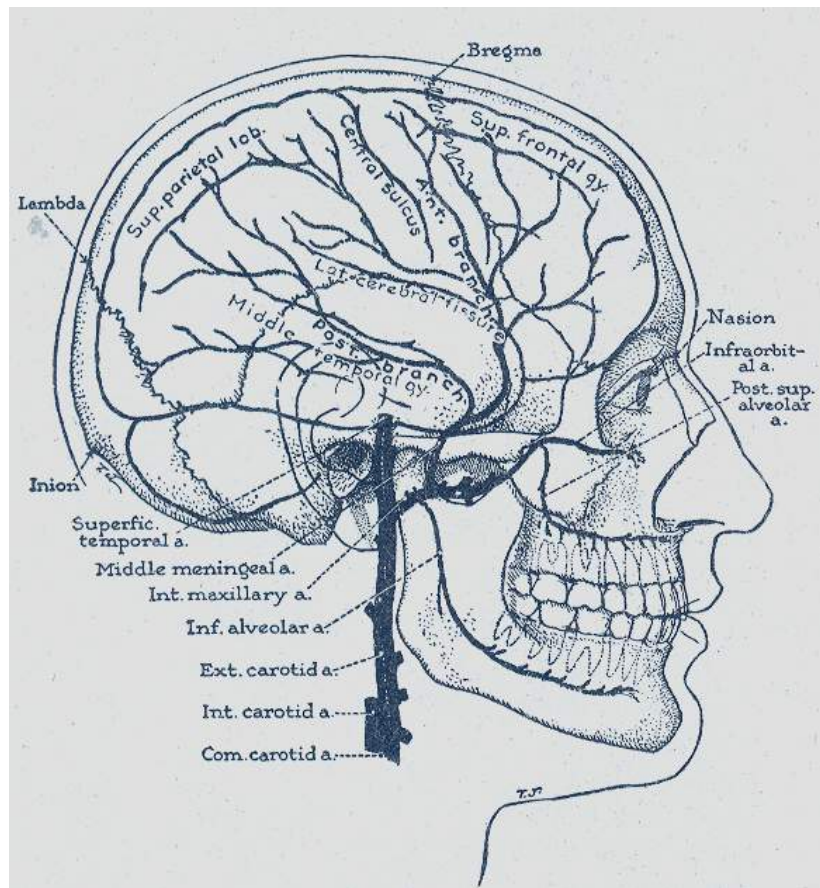
**A middle superior alveolar branch** is usually given off by the infraorbital continuation of the maxillary artery. It joins the *posterior* and *anterior alveolar vessels*. Its main distribution is to the maxillary premolar teeth.

**Anterior superior alveolar branches** arise from the infraorbital artery. It supplies

- the maxillary anterior teeth and their supporting tissues

Branches to the teeth, periodontal ligament, and bone are derived from the superior alveolar

**Figure 3: Branches of maxillary artery**



## **Nerve Supply**

The sensory nerve supply to the jaws and teeth is derived from the *maxillary* and *mandibular* branches of the *fifth cranial*, or *trigeminal*, nerve, whose ganglion, the *trigeminal*, is located at the apex of the petrous portion of the temporal bone. The trigeminal has three main branches.

- Ophthalmic
- Maxillary
- Mandibular

Ophthalmic branch will not be discussed as it has no direct relation with the oral cavity.

## **Maxillary Nerve**

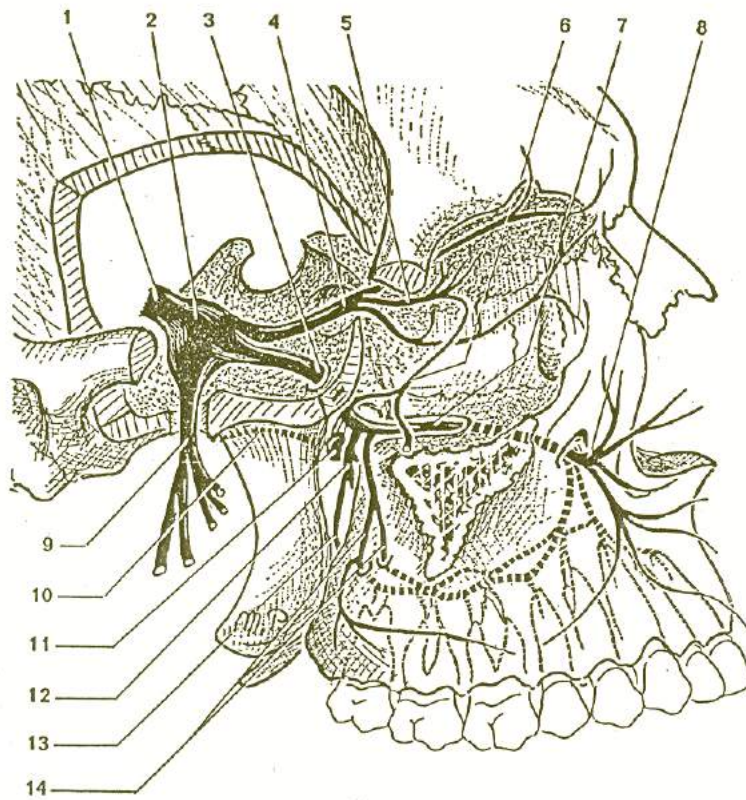
The *maxillary* nerve crosses forward through the wall of the cavernous sinus and leaves the skull through the foramen rotundum. The branches of clinical significance include:

- **a greater palatine branch** that enters the hard palate through the greater palatine foramen and

is distributed to the hard palate and palatal gingivae as far forward as the canine tooth;

- a **lesser palatine branch** from the ganglion that enters the soft palate through the lesser palatine foramina; and
- a **nasopalatine branch** of the posterior or superior lateral nasal branch of the ganglion that runs downward and forward on the nasal septum. Entering the palate through the incisive canal, it is distributed to the incisive papilla and to the palate anterior to the anterior palatine nerve.
- a **posterior superior alveolar** branch from its pterygopalatine portion and is distributed to the molar teeth and the supporting tissues.

**Figure 4:** Branches of maxillary nerve



**Key**

1. Trigeminal nerve
2. Ganglion of gasser
3. Foramen rotundu

4. Ophthalmic nerve
5. Lacrimal nerve
6. Anastmosis of the ophthlmic and maxillary nerve
7. Infraorbital nerve
8. Branches of Infraorbital nerve
9. Maxillares inferior nerve
10. Vividiano nerve
11. Ganglion Sphenopalatine nerve
12. Sphenopalatine nerve
13. Palatine nerve
14. Posterior superior alveolaris nerve

### **Mandibular Nerve**

The *mandibular nerve* leaves the skull through the foramen ovale and almost immediately breaks up into its several branches. The chief branches;

- **the *inferior alveolar nerve***, it gives off branches to the molar and premolar teeth and their supporting bone and soft tissues. It

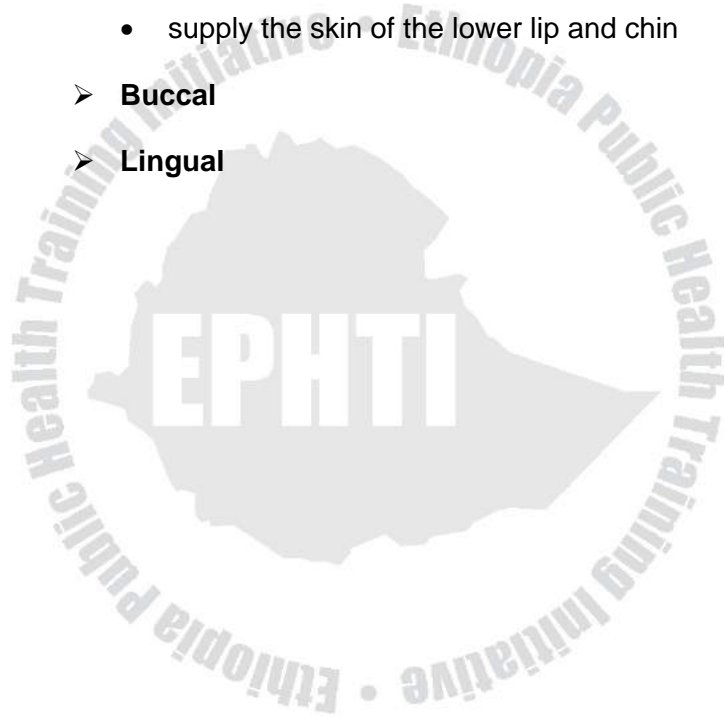
supplies alveolar bone, periodontal membrane, and gingivae.

➤ **a larger mental branch**

- supply the anterior teeth and bone
- supply the skin of the lower lip and chin

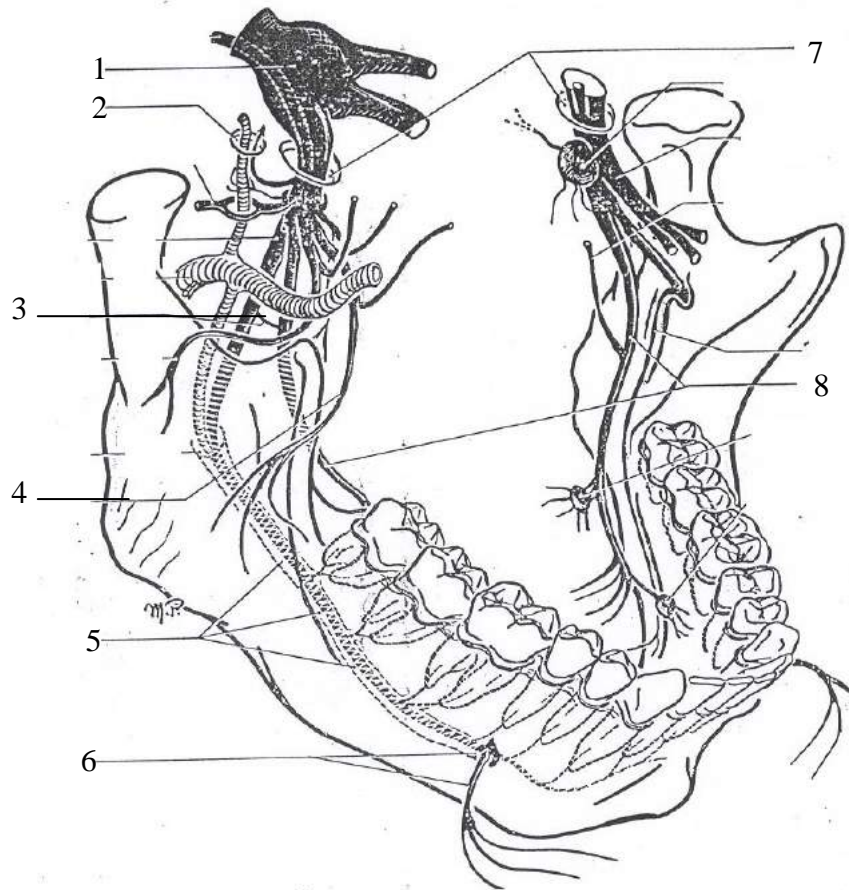
➤ **Buccal**

➤ **Lingual**





**Figure 5:** Anatomy of the trigeminal nerve (mandibular branch)



**Key**

1. Ganglion of gasser
2. Foramen rotundum

3. Anastomose of inferior dental nerve and lingual nerve
4. buccal nerve
5. Dental canal
6. Foramen mentale
7. Foramen ovale
8. Lingual nerve

### **Muscles**

The masticatory muscles concerned with mandibular movements include

- the lateral pterygoid,
- digastric,
- masseter,
- medial pterygoid,
- temporalis muscles.
- Also, the mylohyoid and geniolyoid muscles are involved in masticatory functions.

## **Lateral Pterygoid Muscle**

The lateral pterygoid muscle has functions of:

- closing
- opening
- protrusion movements
- the lateral pterygoid is anatomically suited for protraction, depression, and contra lateral abduction.
- It may also be active during other movements for joint stabilization.

## **Masseter Muscle**

The masseter muscle has a function of :

- clenching
- sometimes active in facial expression
- active during forceful jaw closing
- may assist in protrusion of the mandible

### **Medial Pterygoid Muscle**

The medial pterygoid muscle arises from the medial surface of the lateral pterygoid plate and from the palatine bone. The principal functions of the medial pterygoid muscle are:

- Elevation and lateral positioning of the mandible.
- It is active during protrusion

### **Temporalis Muscle**

The temporalis muscle is fan-shaped and originates in the temporal fossa.. The temporal muscle is:

- The principal positioner of the mandible during elevation.
- The posterior part is active in retruding the mandible and act as an antagonist of the masseter in retruding the jaw.
- The anterior part is active in clenching, may act as a synergist with the masseter in clenching.,

## Chronology of tooth development

A knowledge of the development of the teeth and their emergence into the oral cavity is applicable to clinical practice. Historically the term *eruption* has been used to denote emergence of the tooth through the gingiva although it denotes more completely continuous tooth movement from the dental bud to occlusal contact. Calcification or mineralization (most often visualized radio graphically) of the organic matrix of a tooth, root formation, and tooth eruption are important indicators of dental age. Dental age can reflect an assessment of physiologic age comparable to age based on skeletal development, weight, or height.

**Table 3: Chronology of Human Dentition**

Dentition	Tooth	First Evidence of Calcification (Weeks in Utero)	Crown completed (Months)	Eruption (months)	Root Completed (Years)
Primary (Upper)	i1	14(13-16)	1½	10 (8-12)	1½
	i2	16(14 <sup>2</sup> / <sub>3</sub> 16½)	2½	11 (9-13)	2
	C	17(15-18)	9	19 (16-22)	3¼
	m1	15½(14½-17)	6	16 (13-19)	2½
	m2	19 (16-23½)	11	29 (25-33)	3
Primary (lower)	i1	14(13-16)	2½	8 (6-10)	1½
	i2	16(14 <sup>2</sup> / <sub>3</sub> -)	3	13 (10-16)	1½
	C	17 (16-)	9	20 (17-23)	3¼
	m1	15½ (14½-17)	5½	16 (14-18)	2¼
	m2	18 (17-19½)	10	27 (23-31)	3

Permanent (upper)	11	3-4 mo.	4-5 yr.	7-8 yr.	10
	12	10-12 mo.	4-5 yr.	8-9 yr.	11
	C	4-5 mo.	6-7 yr.	11-12 yr.	13-15
	P1	1½-1¾yr	5-6 yr.	10-11 yr.	12-13
	P2	2-2¼ yr.	6-7 yr.	10-12 yr.	12-14
	M1	at birth	2½-3 yr.	6-7 yr.	9-10
	M2	2½-3 yr.	7-8 yr.	12-13 yr.	14-16
	M3	7-9 yr.	12-16 yr.	17-21 yr.	18-25
Permanent (lower)	11	3-4 mo.	4-5 yr.	6-7 yr.	9
	12	3-4 mo.	4-5 yr.	7-8 yr.	10
	C	4-5 mo.	6-7 yr.	9-10 yr.	12-14
	P1	1¾-2 yr.	5-6 yr.	10-12 yr.	12-13
	P2	2¼-2½yr.	6-7 yr.	11-12 yr.	13-14
	M1	at birth.	2½-3 yr.	6-7 yr.	9-10
	M2	2½-3 yr.	7-8 yr.	11-13 yr.	14-15
	M3	8-10 yr.	12-16 yr.	17-21 yr.	18-25

# CHAPTER 3

## NOMENCLATURE (TOOTH NUMBERING)

### 1. Deciduous/The Primary teeth

The formation of teeth, development of dentition, and growth of the craniofacial complex are closely related in the prenatal as well as the postnatal development period. At birth there are usually no teeth visible in the mouth. The number of primary teeth present in the child is 20, if none are congenitally missing.

#### A. The “Universal” system notation

The primary teeth in the maxillary arch, beginning with the right second molar, are designated by letters **A** through **J**. Beginning with the left mandibular second molar, the teeth are designated by letters **K** through **T**.



A	B	C	D	E	F	G	H	I	J
T	S	R	Q	P	O	N	M	L	K

**A1. Palmer Zigmonds/Quadrant notation system**

E	D	C	B	A	A	B	C	D	E
E	D	C	B	A	A	B	C	D	E

This type nomenclature is commonly used in Japan.

**A2. Roman number**

V	IV	III	II	I	I	II	III	IV	
V	IV	III	II	I	I	II	III	IV	V

In the quadrant notation system, beginning with the central incisors, the teeth are numbered I through V. The palmer notation is used when there is a need to indicate the individual tooth and its place in the jaws,

they use a grid line. For example the upper left first molar will be denoted as follows:



This type nomenclature is commonly used in Europe.

### C. The FDI system/Indexing

5					6				
5	4	3	2	1	1	2	3	4	5
5	4	3	2	1	1	2	3	4	5
8					7				

In the FDI system for the primary teeth the upper right quadrant is indexed as number 5, upper left number 6, lower left number 7 and lower right number 8, such that the upper right central incisor will be noted as 51.

## 2. Permanent teeth/permanent dentition

### A. Palmer- Zsigmondy/ Quadrant notation System

8	7	6	5	4	3	2	1		1	2	3	4	5	6	7	8
8	7	6	5	4	3	2	1		1	2	3	4	5	6	7	8

In the quadrant notation system, beginning with the central incisors, the teeth are numbered 1 through 8. The palmer notation is used when there is a need to indicate the individual tooth and its place in the jaws. For example the upper right first molar will be denoted as follows:

6

## B. The FDI system/Indexing

Upper right	upper left
<b>1</b>	<b>2</b>
8 7 6 5 4 3 2 1	1 2 3 4 5 6 7 8
8 7 6 5 4 3 2 1	1 2 3 4 5 6 7 8
<b>4</b>	<b>3</b>
Lower right	Lower left

In the FDI system for the permanent teeth the upper right quadrant is indexed as number 1, upper left number 2, lower left number 3 and lower right number 4, such that the upper right central incisor will be noted as 11.

### C. The 'Universal' system notation

1	2	3	4	5	6	7	8		9	10	11	12	13	14	15	16
<hr/>									<hr/>							
32	31	30	29	28	27	26	25		24	23	22	21	20	19	16	17

The Universal system is acceptable to computer system.

### Tooth Surface Designation

Tooth Surface towards the face is known as facial.

Tooth Surface towards the cheek ----- Buccal

Tooth Surface towards the lip ----- Labial

Tooth Surface towards the palate----- palatal

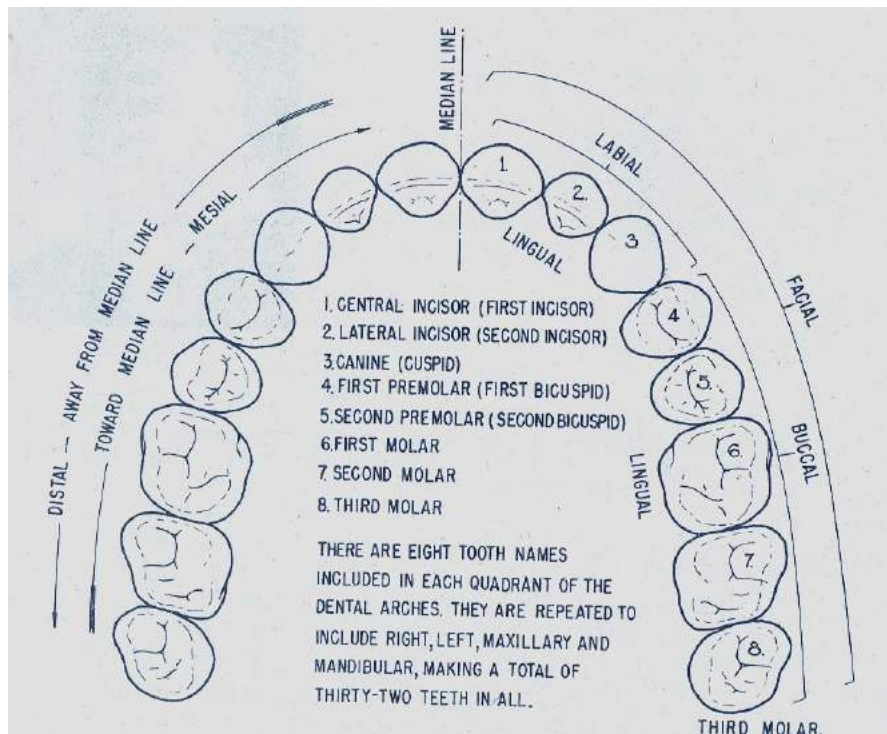
Tooth Surface towards the Midline ----- mesial

Tooth Surface towards the tongue----- lingual

Masticating surface of the tooth is ----- occlusal

Surface of the tooth away from the midline is ---- Distal.

**Figure 6: Tooth surface designation**



# CHAPTER 4

## EXAMINATION OF DENTAL PATIENT

### Dental medical history

Full name, Age, Sex, Date of birth, Occupation

1. Family history cleft lips, any abnormalities
  - a. Malocclusions,
  - b. Food habits
  - c. Common diseases
2. General history
  - a. disease of childhood, operation and accidents, allergic diseases, Gynecological anamnesis
  - b. social anamnesis, habits, occupation, emotional adjustment
  - c. common anamnesis, appetite, stool, urination, using of alcohol, nicotin, coffee.
  - d. present illness
    - Beginning of the symptoms, mode, kind of the symptoms

- Suspect cases of the symptoms
- Date of the first treatment
- Kind of treatment & medication
- Who?, what?, why?, when?, How?

## Main symptoms

### 1. Pain

- beginning
- Duration
- character-intermittent, periodic
- Intensity. Quality, site of pain
- perverted sensation (paresthesia)

### 2. Swelling: beginning

- oedema, (soft, impressible)
- abscess (fluctuation)
- hematoma
- tumor- duration, rapidity of growth
- salivary gland- intermittent swelling during



3. creptation: fracture of jaw bone, rubbing or creptant sound
4. parchent, crackling i.e. palpation of cyst walls
5. emphysema, air in the soft tissue during fracture of maxillary bones

### **Clinical techniques of examination**

1. Inspection: swelling, wounds, scars, wrinkles, color (cyanosis pigmentation, localizations, borderlines.)
2. Palpation: quality of swelling (character of swelling), soft, hard, resistant, fluctuant, creptant. Lymphnodes: abnormal movements, attachment, relation with the surrounding structure.
3. percussion: teeth, jaw bone
4. Transluminatation: of sinus Maxillaris
5. Vitality of pulpodentes: with the use of odontosensimeter, temperature probe (cold, hot).

## **Systemic examination of dental patients.**

### **1. extraoral examination**

- Form and size of skull and face
- Evaluation of skin and visual mucosa
- Control of mimic muscles (n.facialis, VII)
- Control of sensitivity of the skin of the face (trigeminal nerve V)
- Touching of the prominent parts of the bone
- Checking the function of TMJ (temperomandibular joint).
- Examination of the ears
- Examination of the nose
- Inspection and palpation of the physiologic & anatomic structure, form, position, function, color and texture of the lip. Palpation is done bimanually and bidigital.
- Examination of the sinus maxillires
- Examination of the eye

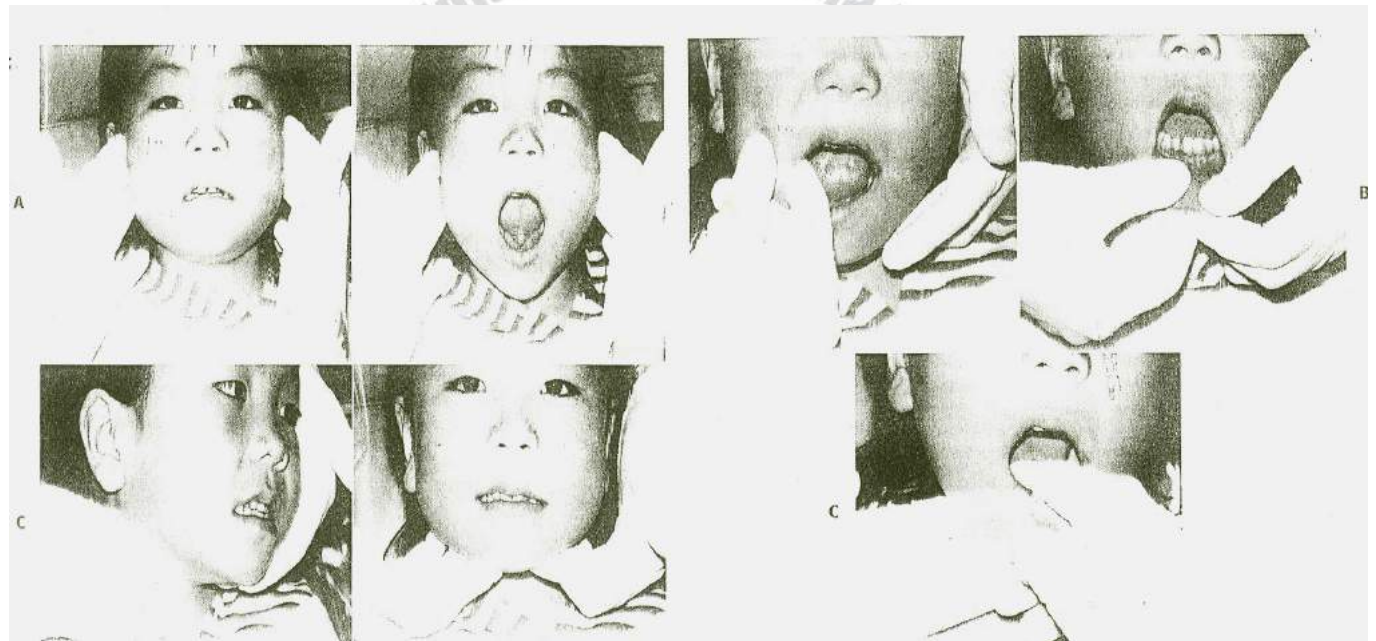
## **2. Intra oral examination**

- Inspection of the vestibulum oris.
- Examination of the tongue: dorsum linguae, movement, function, form & size.
- Examination of floor of the mouth, sublingual glands, pathological resistance.
- Examination of isthmus faucium, hard palate, soft palate, tonsils, uvula.
- Examination of teeth contact relation, number, color, form, size, erosion, attrition, occlusion or articulation
- Examination of periodontal tissue.
- Examination of gingival: color, form, level of epithelial attachment, depth of gingival crevices.

## **3. Examination of the neck**

- Lymphnodes: scar, lesions, swelling, tenderness, pulsation deviation of the midline.

**Figure 7 :** Clinical techniques of examination of dental patients



## CHAPTER 5

# DISEASE OF THE HARD TISSUE OF THE TEETH.

Disease of the hard tissue is disease which affects the enamel and dentine part of the tooth. They are classified as dental caries and none caries diseases

None caries diseases include: attrition, erosion, abrasion and fluorosis

### **Dental caries**

Definition: Dental caries is a pathological condition which appears after eruption of tooth and destroys enamel and dentine and forms cavity.

**Etiology:** Bacteria

- ❖ G<sup>+</sup> Staphilococcus,
- ❖ Streptococcus

- ❖ Bacteriodes
- ❖ Spirochets
- ❖ Fusibacteria.

Microorganisms are found in the oral cavity attached to the teeth, mucus membrane and to the tissue.

Different types of floras are found in the oral cavity in the different stages of life.

### **Micro-floras in early life**

- ❖ Streptococci,
- ❖ Streptomutans,
- ❖ Streptosalvarius,
- ❖ Streptosangius.
- ❖ Diplococci
- ❖ Diphtheriodes
- ❖ Lactobacilli

### **When tooth erupts**

In addition to what was in early life + spirochete

### **During puberty**

Bacteriodes

Fuso- bacteria

### **In adult**

- ❖ Actynomyces
- ❖ Yeasts,
- ❖ Candida,
- ❖ Protozoa,
- ❖ Rickettsia,
- ❖ Viruses.

### **Classification of dental caries.**

Dental caries may be classified in many ways. May be classified by the anatomical structure by the depth of the cavity, by its stage. Example of anatomical classification: pits and fissure cavity (occlusal cavity), smooth surface cavity.

## **G.V. Black's classification**

Dr. G.V Black's classification is based on the location of the carious lesion on the tooth. It was formulated 150 years ago and it is one that is widely used today.

**Class I.** It occurs in pits and fissures of all teeth. This classification is essentially intended for bicuspid and molars.

**Class II.** A cavity occurring on the proximal surface of a posterior tooth. It can involve both mesial and distal surfaces or only one surface tooth and is referred as MO, DO or MOD (mesio-occlusal, disto-occlusal, or mesio-occlusal-distal) cavity.

**Class III** A cavity occurring on the mesial or distal surface of any incisor or bicuspid. The shape of the cavity is circular.

**Class IV.** A lesion on the proximal surface of an anterior tooth from which the incisal edge is also missing.



**Class V.** It is gingival cavity or smooth surface cavity. It can occur on with the facial or lingual surfaces, the predominant occurrence of the lesion is the buccal and labials surface of the tooth. It can also involve cementum as well as enamel.

**Class VI.** This cavity is found on the tips of cusps or along the cutting edge of incisors. This classification is additional to the original Black's classification.

Treatment is restoration with the use of restorative materials and dental instruments.

Restorative materials may be temporary, permanent and pulp-protecting.

Dental instruments are dental chair, hand piece, dental burs, operative, shaping, cutting etc instruments.

### **Sites of attacks of dental caries**

1. Fissures, pits ,grooves, occlusal surfaces.
2. Proximal surfaces

3. At the gingival junction on the facial and lingual surfaces.
4. Near the junction of the enamel and cement after recession of gum.

### **Treatment of dental caries**

The treatment depends on the class or depth of the cavity

- Restoration is done if the resources are accessible and there is a professional skilled in the clinic. Recently there is a treatment developed for dental caries especially for developing countries like Ethiopia. This type of treatment is known as atraumatic restorative treatment (ART). This just to clean and curette the diseased part of the enamel and dentin with hand instruments and seal the cavity with simple restorative material in order to avoid further advancement of the caries. This treatment does not need complex instruments and professionals.

- If the above restoration is not possible and referral is not accepted by the patient for some reason extraction will be done after clear \explanation of all versions.

### **Regressive alteration of the teeth (Non caries diseases)**

Regressive alteration the teeth include Abrasion, attrition and Erosion.

1. Abrasion is apathologic wearing away of the tooth substance through some abnormal mechanical process.

Site:- Exposed root surface

Cause:-

- Use of abrasive dentifrices
- Habit of opening pins
- Occupation

2. Attrition:- is the wearing of teeth during function. This is normal wearing of the teeth during contact with opposing teeth in occlusion. It has relation with aging.
3. Erosion:- is defined as a loss of tooth substance by a chemical process that does not involve known bacterial action.

Etiology:- Unknown

Some scientists think that, decalcification due to local acidosis, obvious decalcification, beverages, lemon juice, gastric acid decalcification industries which produces beverages, chemicals may be factors for the erosion.

Site:- Labial and buccal surface of the teeth.

CF:- Shallow, broad, smooth, highly polished, scooped-out depression on the enamel surface adjacent to the cemento-enamel junction.

# CHAPTER 6

## DISEASE OF THE DENTAL PULP

### **Pulpitis**

It is the inflammation of the dental pulp.

#### **Main causes**

1. Infection: spread of dental caries to the pulp,
2. Trauma.
3. Physical irritation: excessive heat during cavity preparation.
4. Chemical irritation i.e. filling materials.
5. Mixed microorganisms which are found in the oral cavity.

### **Classification**

There are different classifications pulpitis. Some of them are as follows.

1. Acute closed
2. Acute open
3. Chronic closed
4. Chronic open

All acute pulpitis are known as vital pulpitis.

All chronic pulpitis are known as non-vital pulpitis.

### **Clinical pictures of vital pulpitis**

- Self initiated pain
- Pain which radiates to the ear and to that side of the face.
- Severe pain which wakes you up from sleep.
- If by chance the pain was stimulated, no relief on removal of the stimuli.
- Stays more than 20 minutes
- No edema of the gum or mobility of the tooth involved.

### **Clinical pictures of non vital pulpitis**

- No response to stimuli
- Fistula at the gum around the root of the affected tooth and pussy discharge.
- Bluish red or black discoloration
- Intermittent and throbbing pain.

Diagnosis is made by clinical pictures and dental x-ray.

**Treatment:**

- Root canal therapy
- Tooth extraction if no alternative treatment

**Table 4:**Differential diagnosis of deep dental caries and pulpitis

	Pain	Temp.probe	Duration
Deep Caries	+ or -	Cold or hot	Short
Pulpitis	Self initiated	Cold	Long
	Radiated		

# CHAPTER 7

## PERIODONTAL DISEASES (GINGIVITIS AND PERIODONTITIS).

### Anatomical consideration

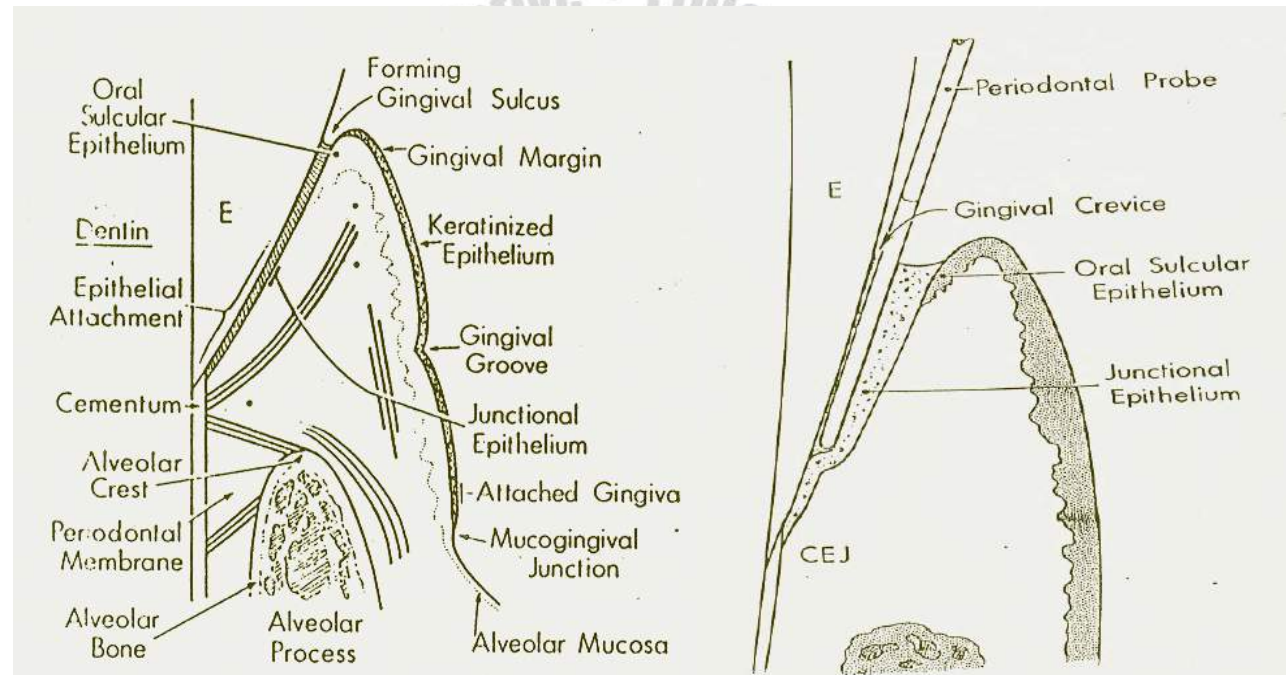
The normal gum is pink, firm stippled with well formed papillae and gingival crevices. The gingival sulcus should be shallow in depth and without exudates.

### Parts of the normal gingiva

1. Free gingival (inter-dental papillae)
2. Attached gingiva 3.0 mm – 4.00 mm (stippled surface like orange peel)
3. Alveolar mucosa: loosely attached to the bone refracting away from the bone.



**Figure 8:** Schematic drawing of the gingiva and dento gingival junction



## **Defence mechanism of the oral cavity:**

The junctional epithelium is a unique structure, but in the presence of plaque, affords little protection to the underlying connective tissue.

The oral environment together with the hosts' defence mechanism provides a degree of protection to the dentoginval area.

The defence mechanisms include saliva, crevicular (gingival) fluid, polymorph nuclear leukocyte and perhaps certain micro-organisms.

Saliva: Saliva production and secretion play a vital role, due to the flushing action, which helps to remove bacteria in maintaining oral health. Thus, only those bacteria that have the capacity to adhere to the teeth surface will play a role in plaque development. It contains the secretory immunoglobulin IgA, agglutinins, lysozyme, viable PMNs and lactoferrin, which interferes with bacterial adhesion and growth.

**Crevice (gingival) fluid:** this fluid percolates through the tissues and junctional epithelium into the gingival crevice, providing a continuous flushing action, which may serve to reduce bacterial colonization of the crevice. Production and flow of crevicular fluid increases in relation to the level of inflammation in the gingival tissues.

**Polymorphonuclear neutrophils:** PMNs are now considered to be the primary of first line of defence in the protection of the gingival tissues from bacterial plaque. These cells have an important role in preventing and development of gingivitis, the formation of the pockets, and the progression of periodontal disease.

**Development of Gingivitis:** The development of clinical features of gingivitis is related to plaque accumulation and the inflammation. Inflammation resolves when the plaque is removed.

**Periodontitis:** is an inflammatory disease of the periodontal tissues. The features of periodontitis include loss of the connective tissue attachment to the root surface and exposure of cementum; apical migration of junctional epithelium, which can result in gingival

recession or pocket formation; and alveolar bone loss and an increase in tooth mobility. The formation of pocket allows plaque to colonize the root surface and the layer of the necrotic cementum. The pocket environment facilitates the growth of anaerobic micro-organisms.

**Plaque:** Dental plaque plays a central role as a major etiological factor in the pathogenesis of dental caries and periodontal disease. Dental plaque has been defined as a bacterial agression on the teeth and other solid structures in the mouth. Clinically, plaque may be difficult to identify with the naked eye. Only when the deposit has reached a certain thickness can it be seen as a yellowish substance in the vicinity of the free gingival margin.

**Calculus:** Dental calculus is a hard, calcified deposit that is found on teeth and other solid structures in the mouth. It is classified according to its location related to the marginal gingiva. Depending upon its location with respect to the gingival margin, calculus may be characterized as supra gingival or sub gingival.

Hard deposits on the crowns of the teeth are also known as supra gingival calculus. This is crumbly in texture and yellowish-white in color, although staining is not uncommon, particularly in smokers.

Sub gingival calculus is often visible to the naked eye as a narrow, dark-green, or black band located just apical to the free gingival margin. Such deposits are very hard and partially resistant to removal by scaling instruments.

### **Immunologic features of gingivitis/periodontitis**

Bacterial plaque induces inflammation with bacterial cyto-toxic and proteolytic nature. Host inflammatory response to plaque micro-organisms + substances they release humoral and cellular immunity then additional damage to periodontal tissue.

### **Local response**

- ❖ Complement activation
- ❖ Infiltration of leukocytes
- ❖ Release of lysosomal enzymes + cytokines

- ❖ Production of a serous gingival crevicular exudates (IgA, IgG, , Ig M)
- ❖ Dentobacterial plaque contains :
  - Acinomyces
  - Streptococcus mutans + sanguis
  - Bacteides melaniogencis

## **Periodontum**

It is supporting apparatus of the teeth. It includes the gum, alveolar bone, various tissue components of the gingiva, ligaments, blood vessels, periodontal space, root and cementum.

### **Periodontal Diseases (Gingivits and Periodontitis)**

Periodontal disease is a disease of the supporting structure of the teeth.(perdidontal ligament, cementum, alveolar bone and the various tissue components of the gingiva).

## Classification

### A **Gingivits**

- ❖ Acute gingivitis
- ❖ Chronic gingivitis

### B. **Prepubertal**

- ❖ Juvinale
- ❖ Rapidly progressive
- ❖ Chronic (adult)
- ❖ Refractory

### C. **Periodontitis**

- ❖ Acute periodontitis
- ❖ Chronic periodontitis
- ❖ (Apical, marginal)

### D. **Dystrophic disease**

- ❖ Hyperplasic condition
- ❖ Atrophic condition
- ❖ Degenerative condition

## Gingivitis

It is an inflammatory lesion confined to the tissue of the marginal gingiva.

**Cause:** accumulation of bacterial plaque at or near the gingival margin.

The bacterial component of plaque produces and releases variety of enzymes and toxins (e.g. lipopolysaccharides and lipotechoic acid) which diffuse through the junctional epithelium and initiate inflammatory changes in the gingival connective tissues.

### Clinical feature

- Redness of the gum
- Gum bleeding
- Oedema of the gum
- Tenderness of the gum



### **Treatment:**

- Oral hygiene
- Plaque control
- Oraldine mouth wash
- Administration of antibiotics

### **Acute Necrotizing Ulcerative Gingivitis (ANUG)**

Definition: is an inflammatory destructive gingival condition which exhibits characteristics clinical signs and symptoms. The other names for ANUG are "Vincent's gingivitis" or "Vincents gingivostomatitis", 'Trench mouth" and" Ulceromembraneous gingivitis"

Cause: -

- Fusiform bacteria
- Treponema vincenti
- Treponema denticola
- T-macrodentium
- Fusobacterium nucleatum
- Prevotella intermedia
- Porphyromonas gingivalis

**NB.** These bacteria are found in large numbers in the slough and necrotic tissues at the surface of the ulcer.

### **Clinical features**

- Inter proximal ulcers covered with a yellowish - white or grayish debris
- Easily bleeding
- Necrosis develops rapidly
- Linear erythema
- Bleeding
- Pain
- FOETOR EX ORE: Halitosis
- Lymphadenitis
- Fever and malaise

### **Treatment aim**

- Control of the acute phase
- Management of the residual condition

## Control of the acute phase

- Antibacterial cleaning
- Irrigation of the wound with 3% hydrogen peroxide solution
- Scaling of the affected teeth
- Metronidazole
- Antibiotics
- 2% Chloxydine mouth wash

## Management of the residual condition

- Supra and subgingival scaling
- Gingivoplasty
- Regular follow up for maintenance of oral health

**NB:** Patients with recurrence should undergo medical examination and screening for predisposing factors.

## **Modification for suspected or verified HIV positive patients**

- Use of antibiotics or chemotherapeutics may cause over growth of opportunistic microorganisms.
- Chlorhexidine mouth wash
- Amphotercine lozenges
- Nystatine
- Antibiotics

**NB:** Use of antibiotics should be combined with antifungal tdrugs.

### **Periodontitis**

Periodontitis is host inflammatory response.

**Cause:**

**A Local**

- Microbial components of plaque,
- Food impaction,
- Mouth breathing,
- Chemical irritation.
- Trauma
- Drug toxicity

**B. Systemic**

- Pregnancy
- Diabetes mellitus
- Allergy
- Hereditary

**Clinical features**

It is consequence of an interaction of bacterial plaque and its production with the hosts' inflammatory and immune response. Inflammation and various immunological changes are the features of periodontal diseases.

- Pain on mastication
- Tenderness of the gum
- Feeling of elongation of the tooth
- Tenderness to percussion

**X-ray result** shows widening of the periodontal space in chronic cases.

#### Treatment

- Scaling – removal of calculus
- Treatment of dental caries
- Oral hygiene
- Extraction, if hopelessly diseased

# CHAPTER 8

## ANESTHETIC CONSIDERATION IN DENTAL PRACTICE

### Techniques of Local Anesthesia or methods

#### 1. Topical anesthesia

- ❖ Spray
- ❖ Ointment
- ❖ Solution form
- ❖ Gel

#### 2. Parenteral anesthesia

- ❖ Infiltration
- ❖ Block anesthesia

## **Desirable characteristics of ideal anesthesia**

1. Low toxicity
2. Reduction of blood flow
3. Long duration of action
4. Rapid speed of onset
5. Good anesthetic efficacy

## **Some of the anesthetic agents**

1. Lidocaine
2. Tetracaine
3. Cocaine
4. Butacaine phosphate
5. Diclonine
6. Ethyl aminobenzoate ( Benzocaine)

## **Block methods of anesthesia**

1. Zygomatic /tuberal
2. Infra orbital block
3. Inscival (Nasoplatine)
4. Palatal (posterior palatine)



5. Mandibular

6. Mental

## **Techniques**

### **1. Zygomatic block**

- The mouth half opened
- The cheek is retracted with the help of mouth mirror.
- Injection made between the first and 2<sup>nd</sup> upper molars of the side of the tooth to be extracted
- The needle is forwarded upward and inward and advanced about 1.5cm.
- About 2 ml are released,

Time Wait about 5-10 minutes

### **Area of anesthesia for zygomatic method**

Upper molars, periostium of the alveolar bone, mucus membrane, posterior and external wall of the maxillary sinus. The effect of the anesthesia may reach up to the 1<sup>st</sup> premolar

## 2. Infraorbital block

- Find out the site for infraorbital foramen
- palpate the infraorbital foramen, and don't remove the finger
- The mouth nearly closed injection made between the upper premolars of that side of the tooth to be extracted and advanced to the infraorbital foramen
- The syringe is brought parallel to the premolars and the needle is advanced under the palpating finger about 1 cm
- Aspirate to check that the needle is not in the blood vessel.
- 2 ml of the anesthetic solution is released.

Time to wait 3-5 min.

### Area of anesthesia

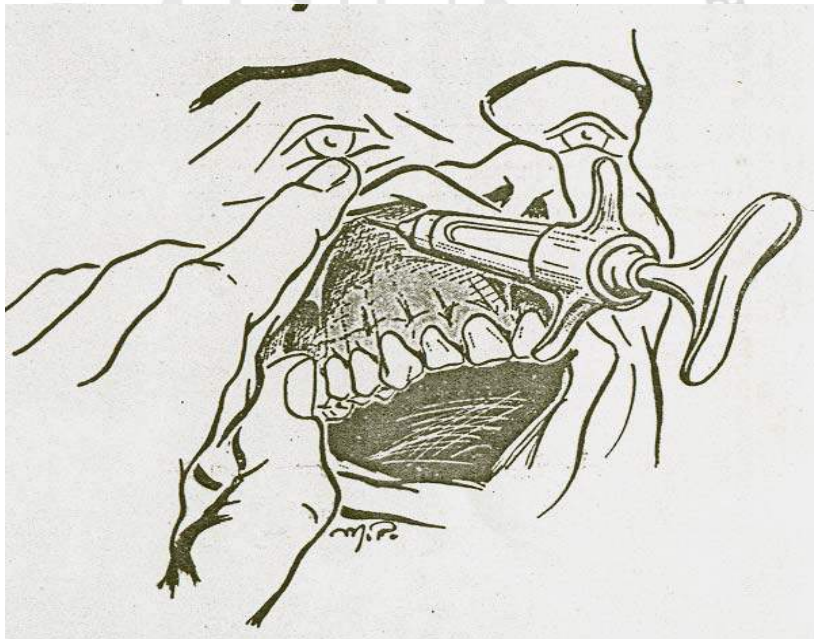- Upper anterior teeth, canines, premolars
- Periosteum, mucous membrane
- Lower and upper wall of the maxillary sinus
- Skin around the infraorbital region,

- Lower eye lid, half of the nose, skin and mucous membrane of the upper lip of that side.

### Complications

1. Trauma to the nerve and blood vessel
2. Ptosis in case of the involvement of the ophthalmic nerve
3. Hematoma in case of trauma to the blood vessel

**Figure 9:** techniques of infraorbital block



### 3. Incisival block

- The mouth widely opened
- Injection made just below the gingival papilla of the central incisors
- Try to find out the incisival canal
- Aspirate to check that the needle is not in the blood vessel.
- 2ml of anesthetic solution is released

Time to wait 3-5 min

### Area of anesthesia

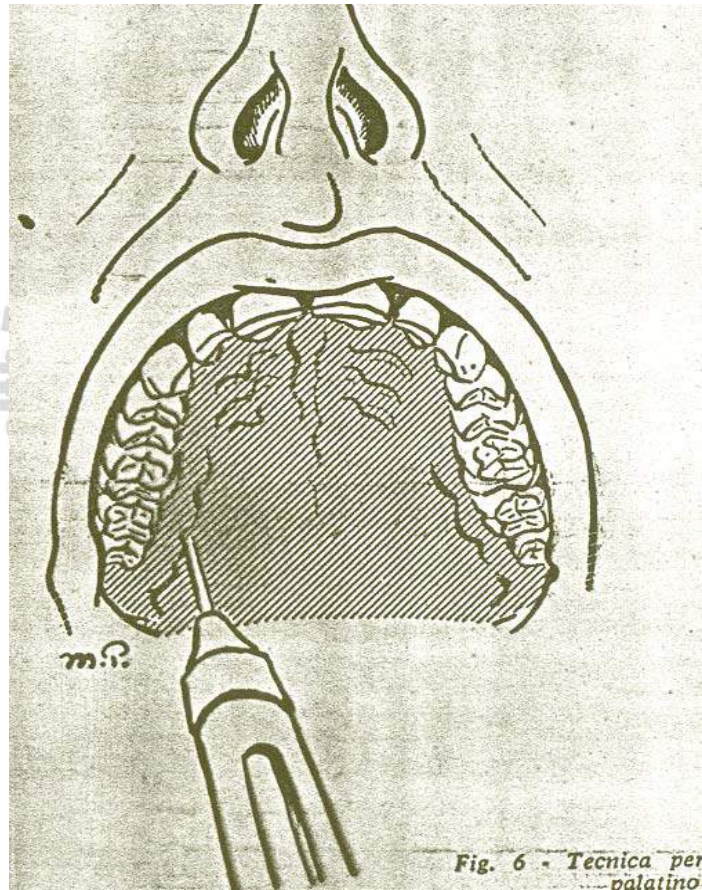
- The upper lip
- The Mucous membrane
- The periostium of the alveolar bone.

### 4. Palatal (Greater palatine) block

- Mouth wide open
- Injection is made between the root of 2<sup>nd</sup> and 3<sup>rd</sup> upper molars palatally.
- Find out the greater palatine foramen
- Aspirate to check for blood

- About 0.5ml of anesthetic solution is released  
Time to wait 3-5min

**Figure10:** Technique of Greater palatine block

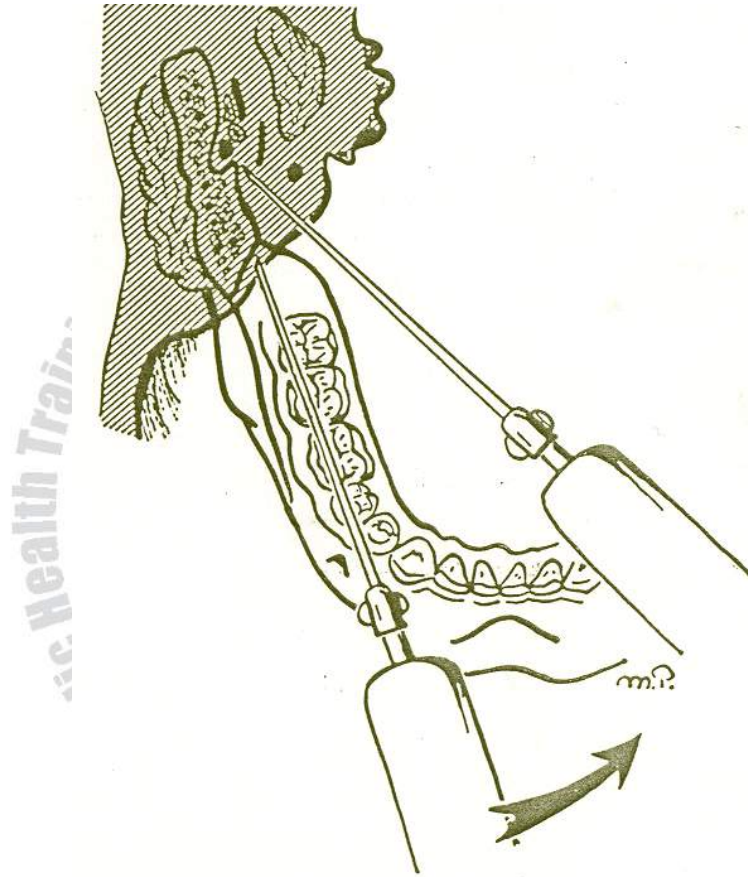


## 5. Mandibular block

- Mouth wide opened
- Palpate the pterigoid raphae
- Syringe placed opposite to the side of the tooth to be extracted
- Injection made on the site of palpating finger and the needle rested on the bone the syringe is brought // to the occlusal surface of the tooth to be extracted
- Needle is advanced about 2cm and 2ml sol. released after aspiration, then on the way back release about 1and1/2ml sol.

Time to wait 5-10 min.

**Figure 11:** techniques of mandibular block



## 6. Mental block

The mouth nearly closed

The needle at an angle of 45 degree, injection made between the roots of lower premolars labially. The direction of the needle is towards the 1<sup>st</sup> premolar.

**Block method is advantageous than the other methods.**

Advantages of block over the other methods are as follows:

- Injection far away from an infected site
- More profound anesthesia
- Less penetration(Decreased injection site)
- Maximal anesthetized field with minimal drug.

### **Complication of anesthesia**

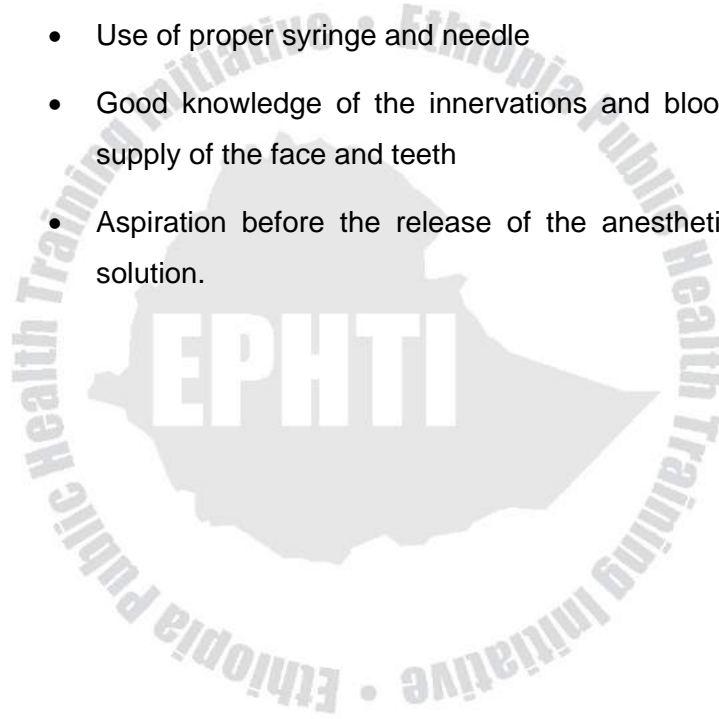
- Trauma to the nerve
- Trauma to the blood vessels
- Injection directly to the blood vessel dropping of the anesthetic solution to the blood vessel.



- Allergic reaction

### **Prevention of complications**

- Use of proper technique
- Use of proper syringe and needle
- Good knowledge of the innervations and blood supply of the face and teeth
- Aspiration before the release of the anesthetic solution.



# CHAPTER 9

## TOOTH EXTRACTION

Tooth extraction is defined as the process of taking out of tooth from its socket. The procedure is carried out with the help of different types of instruments.

### Indication of tooth extraction

1. Teeth that are hopelessly diseased, where restoration is impossible
2. Acute/chronic pulpitis, necrosis and gangrene of the pulp when root canal therapy is impossible.
3. All forms of apical periodontitis, when conservative treatment is impossible
4. Retained root, retained primary teeth (delayed eruption)
5. Severe marginal periodontal diseases (moveable teeth)
6. Impacted teeth, mal-erupted,
7. Misplaced teeth.
8. Supernumerary (extra tooth)

9. Fractured teeth with opened pulp chamber,
10. Fractured root.
11. Teeth that are localized on the line of fracture.
12. Mal-positioned teeth not movable by orthodontic treatment.
13. Radical surgery of tumors.
14. Preparation for radiotherapy.
15. Paradontsis.
16. Tooth which is moved out of its socket because of loss of antagonist.

### **Contraindications to tooth extraction**

There is no absolute contraindication for tooth extraction. But there are relative contra indications which are listed below. When ever a patient comes to the clinic with one of the conditions listed below, the management should be multidisciplinary.

1. Cardiovascular diseases in their acute stage.
2. Diseases of the liver, kidney, pancreases.
3. Disorder of the blood.
4. Acute infectious diseases
5. Diseases of the nervous system

6. Psychologically ill patients if they are in the exacerbation period.
7. Diseases of the oral cavity.
8. Acute febrile illnesses.

### **Complications following dental extraction**

Complications following dental extraction are commonly local. These are:

1. Fracture of tooth
2. Fracture of the jaw
3. Damage to the soft tissue
4. Penetration to the maxillary sinus.
5. Lose of the tooth (aspiration, swallowed, Entrance to the sot tissue).
6. Fracture of the maxillary tuborosity.
7. Removal of the wrong tooth, (during extraction of milk tooth)
8. Excessive bleeding
9. Local infection, (dry socket)
10. Loss of the root in the antrum.
11. Syncope

## Instruments for tooth extraction

Main instruments of extraction are:

1. Dental forceps
2. Elevators
3. Burs

### Dental forceps

*Dental forceps has three parts:*

1. Beaks : part which rests over the crown during extraction
2. Handle: part where the hands and fingers of the operator rests.
3. Hinge: part where the beaks and the handle joins.

### **Types of forceps**

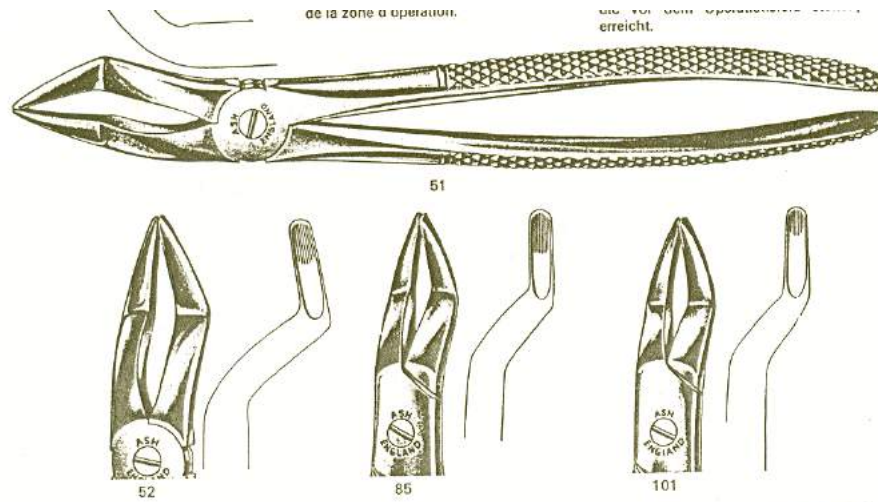
Dental forceps are made in such a way that, they fit the anatomical structure of each individual tooth and for each dentition (Deciduous and permanent teeth).

1. Forceps for upper teeth with crown and they are also classified according to the class of tooth to be extracted and their beaks are with cleft.
2. Forceps for upper tooth without crown and their beaks are without cleft.
3. Forceps for lower teeth with crown and they are known as sagittal forceps.
4. Forceps for extraction of lower teeth without crown, their beaks are without cleft.

### **Special forceps for roots in the upper jaw**

Bayonet-forceps is a specially designed for extraction of retained roots of upper wisdom tooth and roots of all classes of the upper teeth.

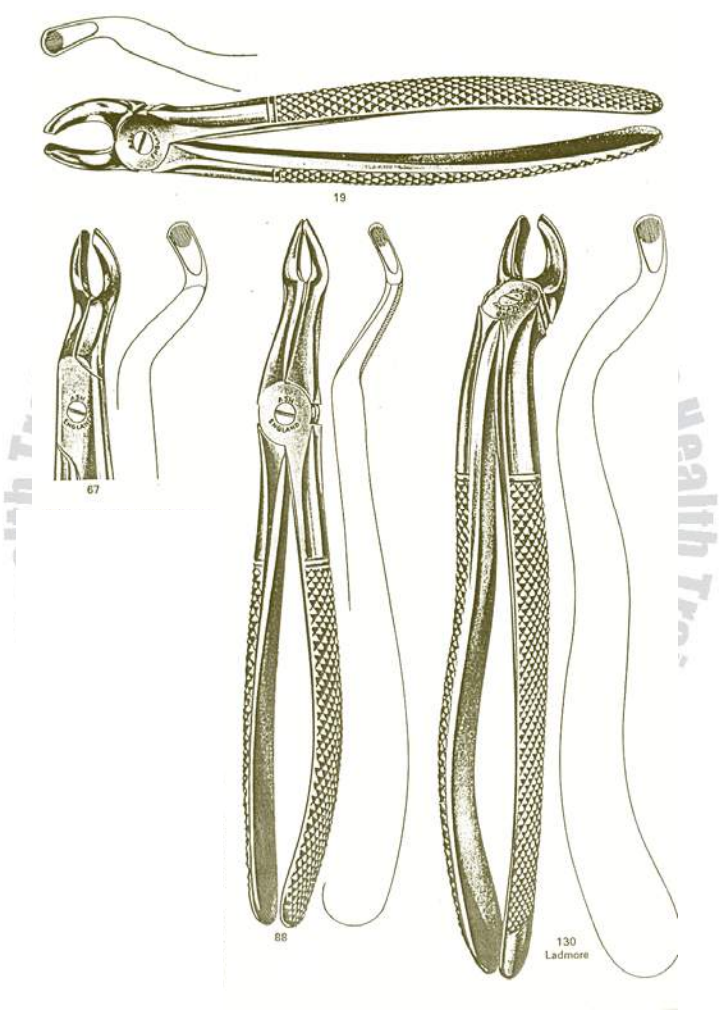
**Figure 12: Bionet forceps**



**Special forceps for wisdom teeth**

1. Deep Grasped forceps
2. Saggittal forceps
3. Wisdom teeth forceps for the upper jaw

**Figure 13:** wisdom forceps for the upper jaw





### **Special beaks of the forceps**

They are designed in such a way that, they are suitable for extraction of

- Misplaced or partly erupted teeth,
- Where mouth is small,
- For bicuspid to be able to extract standing in front of the patient,
- To remove retained roots, etc.

### **Elevators**

Purposes of elevators

1. For dislocation of tooth
2. For extraction of retained roots.

### **Types of Elevators**

Elevators may be- straight or curved

- Group of cross bar handled elevators
- Winter elevators
- Elevators of LE CLUSE

**Figure 14:** different elevators (a)

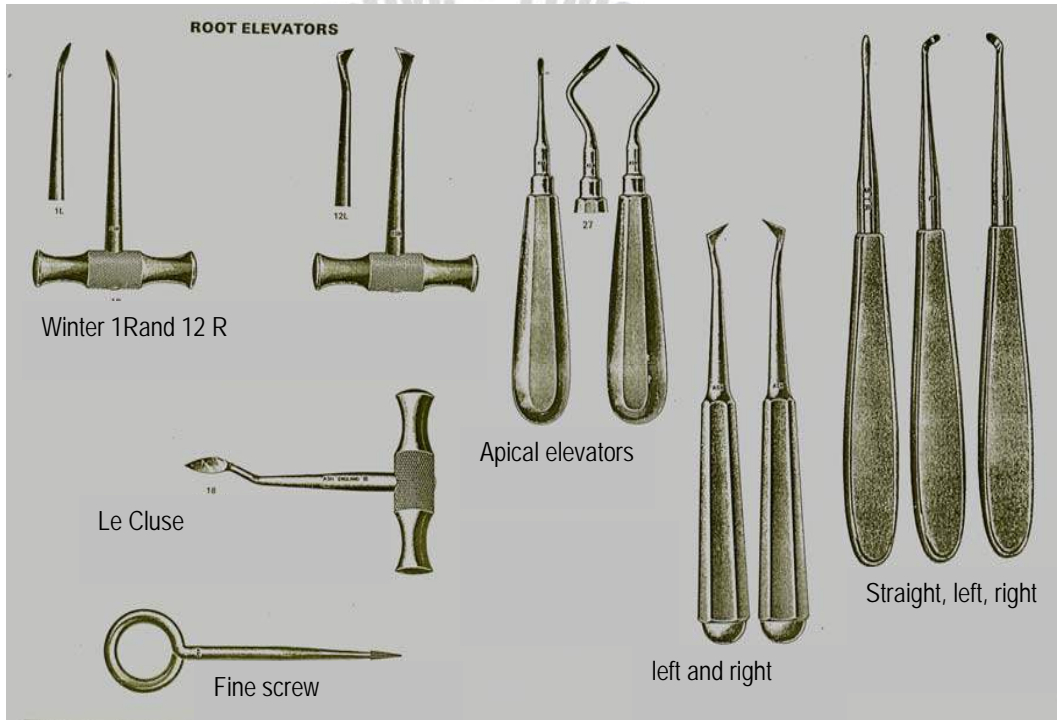
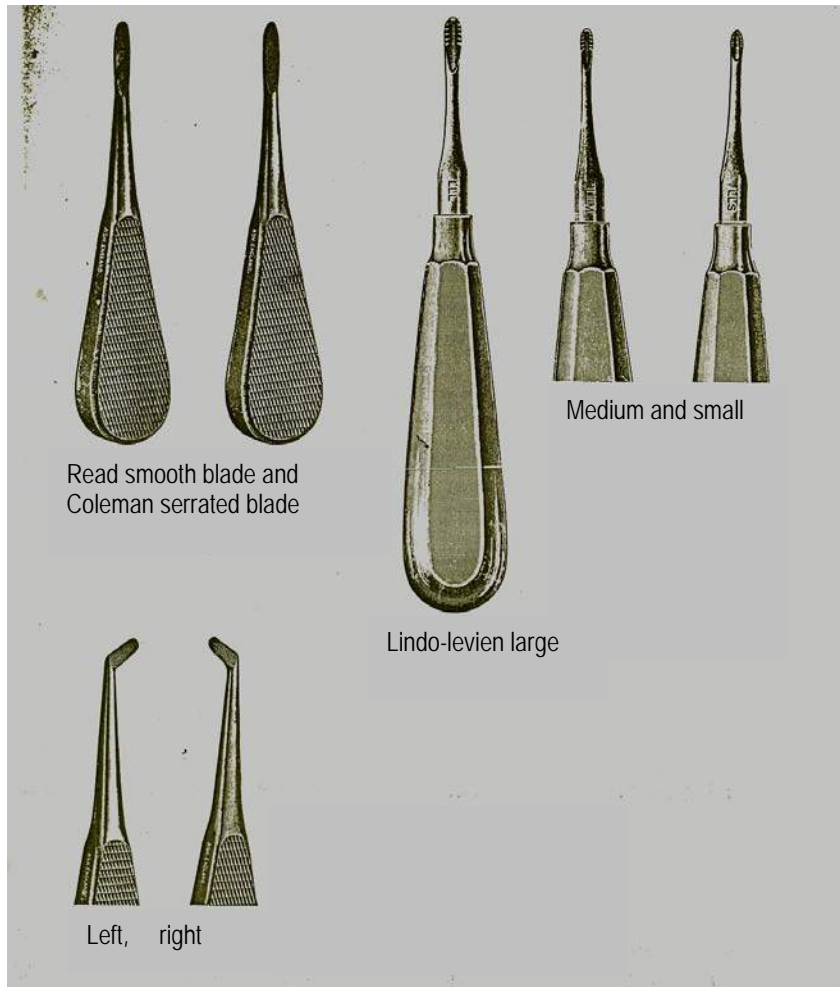


Figure 14 different elevators (b)



## **Work principles in the use of elevators**

1. As a wedge
2. As a lever
3. As wheel and axel

## **Position of the patient**

Position of the patient may be sitting, semi sitting or lying according to the condition of the patient.

- During extraction of the upper teeth the tooth to be extracted (head) should be at the level of shoulder joint of the doctor.
- During extraction of lower teeth the tooth to be extracted (head) should be at the level of the elbow joint.

## **Position of Operator**

For extraction upper teeth the doctor stands in front of the patient, the arm of the dental chair raised for the upper left side.

- For extraction of lower teeth to the right side, the doctor should stand at the right side of the patient lightly at the back, supporting.

- For extraction of lower left teeth, the doctor should stand in front of the patient, the arm of the dental chair raised.

### **Step of tooth Extraction**

1. Detached the gum from the crown part of the tooth
2. Put the beaks of the forceps on the crown
3. Push the forceps down under the gum
4. Fix the forceps
5. Dislocation of the tooth(Luxation)
6. Apply traction

The pressure which should be applied to dislocate should depend on the thickness of the jaw i.e

**Maxilla:** Buccal side of the alveolar bone is thinner than the palatal side. Therefore the pressure should be applied to the buccal aspect of the maxilla for extraction of premolars and molars of upper teeth.

**Mandible:** for extraction of lower teeth 5-4/4-5 the buccal side is thinner than the lingual side

- Ext. of 8-7/7-8 the lingual aspect is thinner
- Ext. of 6/6 - the thickness is the same on both sides

### **Dental instruments for minor surgical operations**

1. Scalpel (knife)
2. Periosteal elevator
3. Retractor: Mippleldorph  
Langenbeack
4. Surgical bur
5. Hand piece
6. Chisel and Mallet
7. Side cutting bone forceps (bone cutter)
8. Blant-nosed rongeur (Leur forceps)
9. Rasp or bone file (dental)
10. Double ended curette

11. Tampon-stop
12. Suture materials (non absorbable)
13. Needles
14. Needle holder
15. Scissors
16. Tissue forceps
17. Surgical forceps
18. Sponge forceps
19. dental forceps (foil carrier, cotton pliers)
20. Hemostat (curved, straight, Mosquito)
21. Mouth opener: Heister

Roger-Kong

# CHAPTER 10

## ODONTOGENIC INFECTION

### Acute Osteomyelitis of the jaw

#### Cause:-

Due to local infection  
i.e from teeth & gingival margins  
(staphylococcus ..& streptococci)

#### Sources of infection:-

- Acute peri apical infection
- Fracture of the jaw
- Acute pericoronitis or acute gingivitis

#### Clinical Features:-

- Thorough history
- Headache
- Severe toothache & Hx of dental  
Extraction (throbbing & deep seated pain)



- Swelling
- Redness, tenderness, hotness of the gum
- The teeth in the area are tender to percussion, palpation & sometimes loosened.
- Enlarged and tender Lymph nodes
- Difficulty of opening of the Mouth
- Fever and malaise

**Diagnosis:-**

Para clinical examinations (X-ray )

**Rx:-**

- Administration of Antibiotics
- Analgesics
- Vitamins
- Incision and Drainage
- Removal of sequestrum
- Oral hygiene

### **COMPLICATION:-**

- Involvement of inferior dental nerve
- Pathological fracture
- Cellulitis

### **CHRONIC OSTEOMYELITIS**

If inadequately treated or if not treated early the acute osteomyelitis will be complicated to chronic osteomyelitis.

#### **CF:**

- Localized infection
- Pus discharge
- Mild or intermittent pain
- Shed of sequestra

#### **Dx:-**

**X-ray**

**Rx:**

- Extraction of causative teeth
- Drainage & Removal of Sequestra
- Antibiotics
- Analgesics
- Vitamins
- Balance diet.

**CELLULITIS**

It is spreading infection of connective tissue, characterized by gross inflammatory Exudates & edema. The spread of the infection is through the various spaces of the face. The various spaces cellulitis will be difficult to be discussed here but the only ones which are more serious and which should be given attention as they may cause air way distress will be discussed as follows:

**General**

1. Etiology:- Beta - Hemolytic streptococcus.

*Source of infection:-*

Region of Lower molars

Osteomyelitis (as a complication)

**CF:-**

- Headache
- Diffused brown swelling - Hard, tender, hot
- Pain
- Fever
- Malaise
- Difficulty of opening the mouth & swallowing
- The regional LNs are swollen & tender
- If not early treated sepsis

**TREATMENT AIM:-**

- Localization of infection
- Relieve of tension

**Rx:-**

- Incision & Drainage
- Administration of Antibiotics
- Analgesics
- Vitamins
- Oral Hygiene

## **SUBLINGUAL CELLULITIS (sublingual space)**

*Source of infection:-*

- Mandibular Molars, Frontal teeth (lower)
- Surgical trauma  
Inflammation of sublingual glands and its duct system.

**CF:-**

- Swelling of the floor of the mouth
- Mucus membrane is red or purplish
- Difficulty of swallowing
- Displacement of the tongue superiorly and posteriorly
- Disphagia
- Sialorrhoea

## **Submandibular space infection**

*Source of infection:-*

From 2nd / 3rd molars (Lower)

**CF:-**

- Swelling of the submandibular triangle
- Mucus membrane is red or purplish
- Difficulty of swallowing
- Cervical lymphadenopathy

**NB:** Infection may spread into the sublingual & parapharyngeal space.

**Ludwig's Angina**

It is more serious type of infection.

**Etiology:**

- Virulent strains of streptococci.
- Abscess of mandibular molars can cause it in a compromised patient

**Sign and symptoms:**

- Brown-board like cellulitis involves
  - The mental space
  - Bilateral sublingual space
  - Bilateral submandibular space

- Rapid onset of involvement of the spaces
- Edema of the neck, floor of the mouth and epiglottis
- Dysphagia
- Odynophagia
- Dyspnea with rapid loss of patent airway
- Headache
- Fever
- Malaise

**Treatment:**

- Admission
- Early diagnosis
- Early treatment
- Secure airway
- Administration of antibiotics
- Antipyretics

**NB.** There could be an involvement of parapharyngeal space if note early.

## **Indication of Incision and drainage**

1. A diagnosis of cellulitis or abscess
2. Significant clinical sign of infection (i.e. fever, dehydration, pain, loss of function etc.)
3. Infection in a facial plane that threatens the air way, chest, orbit, or intracranial- extension.

## **The principles of Incision and drainage**

1. Only the shortest and most direct and dependent route to the abscess cavity or cellulitis, with preservation of anatomical structures and placement of the incision in esthetically acceptable area.
2. Place the incision in the healthy skin or mucosa, over the most fluctuant area.
3. Use blunt dissection with hemostats advancing into all areas of involved space to ensure that all loculi of pus have been allowed to drain.

NB. Remain cognizant of regional anatomical structures.



4. Use latex, silicone, or red rubber catheters and suture them in place.

NB. Gauze drain will clot and act as plugs!!

5. Clean drains in a sterile fashion daily, advance them gradually, and remove them when the drainage stops or becomes minimal.

### **Medical supportive care**

The patients who need hospitalization are with all the following conditions:

1. Immunocompromise: a patient with poorly controlled diabetes, malnourishment, alcoholism, other immunodeficiency (Acquired Immunodeficiency Syndrome{AIDS}, steroid dependency or collagen vascular diseases.)
2. Significant clinical presentations, high fever (>101°F), dehydration, malaise, inability to take fluids, trismus, neurological changes, or lower cervical and deep space involvement.

3. history – rapid onset and progression of symptoms, swelling, extension to the other spaces, or tissues slough or discoloration
4. Compliance- a patient who is unreliable or incapable of properly caring for him or herself.
5. Need for parenteral antibiotics: based on presentation of the patient, previous culture and sensitivity testing or acute illness.
6. Other considerations need for other medical or surgical consultation for patient management; organisms resistant to oral antibiotics, bone involvement, or need for surgical debridement.

# CHAPTER 11

## TRAUMA OF THE OROFACIAL REGION

### **Soft tissue injury**

Although the soft tissues of the face are extremely vascular, uncontrolled hemorrhage secondary to injury is rare. During the initial examination, ligation of obvious bleeding vessels and application of occlusive pressure dressings may be necessary to control the bleeding. The pressure dressings also provide temporary immobilization of the hard and soft tissues. The lip should be examined bimanually and bidigitally in order to avoid missing penetrating wound of the lip.

The wound should be inspected for:

- Foreign bodies and
- Cleaned thoroughly

Wound healing depends on the following:

- Minimal tissue damage
- Debridement of necrotic tissue
- Maximal tissue perfusion and oxygenation
- Proper nutrition and moist environment

**Rx:-**

- Careful cleansing of the skin and wounds is an essential preliminary step in the care of all facial injuries.
- Antibiotics active against gram-positive organisms, are considered drugs of choice in facial soft tissue injuries.
- Clindamycin should be considered when allergies to penicillins or cephalosporins exist.

Soft tissue wounds heal in three general ways:-

- Primary intention refers to the reapproximated tissues. This type of healing is seen with surgical incisions that are closed with sutures or well approximated by adhesive plasters.

- Secondary intention is a spontaneous healing of an open wound. This happens when the edges of the wound are not well approximated.
- Tertiary healing is important in contaminated or infected wounds.

## **Dental trauma**

1. Intrusion: it is when tooth enters beyond its socket due to trauma.
2. Extrusion: it is partially pulled out tooth due to trauma.
3. Avulsion/ Luxation: it is when tooth totally comes out of its socket.
4. Fracture of teeth
  - a) Fracture of crown (only enamel)
  - b) Fracture of crown (enamel and dentine)
  - c) Fracture of crown (with exposure of the pulp)
  - d) Fracture of roots, (oblique horizontal, apical and vertical)

### **Cause**

- ❖ Car accident
- ❖ Fall accident
- ❖ Homicidal injury

### **Common sites of trauma of teeth:**

- ❖ Upper frontal teeth
- ❖ Lower frontal teeth in order of priority.

### **Diagnosis:**

- ❖ History
- ❖ Physical examination
- ❖ Dental X-ray

### **Treatment**

- ❖ If patient comes to the hospital within 6-12 hours inter-dental fixation and administration of antibiotics (for intrusion and extrusion)
- ❖ If Fracture of crown, Restoration
- ❖ If Fracture of crown with exposed pulp, root canal therapy or extraction depending on the availability of the dental facilities.

Fracture of root the treatment depends on human and material resources, if there is no resource and skilled staff, extraction.

- ❖ If Apical fracture observation (heals by itself, if the apex is not exposed)

NB. Healing of pulp takes about 3 months.

## **Fracture of the oro-facial region**

### **Signs of fracture**

#### ***A) Certain***

- deformity,
- dislocation,
- abnormal movement
- Creptation
- Post X-ray pictures

#### ***B) Uncertain***

- Pain,
- heamatoma,
- loss of function

## Systematic examination

1. Inspect for deformity of the face.
  - ❖ Heamatoma,
  - ❖ Bleeding, from the nose, ear, mouth etc
2. Manual investigation, pain on pressure or push
  - Palpation of deformities,
  - creptation,
  - Sensitivity of the trigeminal nerve.
3. Intra-oral examination,
  - Ability to open the mouth,
  - Disturbance of the occlusion,
  - Deviation of the jaw (upper/lower)
  - Inspect for the posterior displacement or swelling of the tongue
  - Inspect for the presence of broken tooth or denture



## General management and treatment

### 1. First aid measures

- Clearing of air way
- Stopping of bleeding
- Treatment of pain
- Treatment of shock
- Prophylaxis of tetanus

Once air way obstruction is recognized or the patient's condition is predictive of impending respiratory difficulties, the air way should be cleared and a systemic air way management established. Clearing the air way is best accomplished by the following steps.

- Establish the degree and the cause of air way obstruction
- Clear the oral cavity of debris, blood, secretions, foreign bodies
- Observe for the likely cause(s) of the obstruction
- Reposition the patient consistent with the potential for further servical spine or lower spine injury.

- Establish the effectiveness of steps 1-4 by inspection, listening, and palpation of the upper and lower air ways.

## 2. Methods of treatment

Intra-oral splinting and wiring

### **Operative treatment**

- Circumferential wiring
- Intra-osseous wiring
- Osteo-synthesis or plating

### **Extra oral treatment**

- Head –chin cap
- Head-chin cap of gypsum
- Immobilization using bandage
- External fixation

## **FRACTURE OF THE MANDIBLE**

### **CAUSE:**

- Road accidents
- Falls
- Homicidal injury
- Destructive dental extraction

### **CLINICAL FEATURES**

- History
- Pain
- Swelling
- Deformity
- Abnormal Mobility of the jaws
- Tenderness over the site of fracture
- Ecchymosis (Bleeding under the skin/mucous membrane.
- Creptation

### **X-RAY Findings:**

- Shows severity of the fracture
- Relation of the teeth with the Fracture
- the direction of the Fracture line

### **COMMON SITES OF MANDIBULAR FRACTURE**

- The angle of the mandible
- The neck of the condyle
- The body of the mandible (canine region)

### **Principles of management**

- Clear airway
- Stop hemorrhage
- Treat shock
- Prevent infection

## AIMS OF TREATMENT

1. Reduction of displacement and Immobilization
  - Internal wiring
  - Cast metal cap splints
  - Intra-osseous wiring
  - Plating
  - Pin fixation (extraoral fixation)
2. Reduction of infection

## TREATMENT AND MANAGEMENT

- ❖ Interdental fixation (maxillar–mandibular fixation MMF)
- ❖ Extraction of teeth which are on the line of fracture
- ❖ Administration of Antibiotics
- ❖ Administration of Analgesics
- ❖ Encourage Liquids diet

**NB:** The fixation is kept for 5-6 weeks

## COMPLICATIONS OF FRACTURE OF THE JAW {Mandible}

- ❖ Delayed union
- ❖ Non- union

### CAUSE:-

- ❖ Infection
- ❖ Teeth in the fracture line
- ❖ Poor immobilization
- ❖ Wide separation of fragments
- ❖ Foreign body or bone fragments
- ❖ Systemic conditions
  - TB. Of the bone
  - Syphilis
  - Age - - etc

### Maxillary fracture

The maxilla forms the frame work of the midface, and it supports or is closely associated with the appurtenances of the face.

It supports the bones of the lateral face or cheek

- The orbit and orbital bone
- The nasal bone
- It has intimate relation with bones forming the cranial base (ethmoid).
- It contains wholly or in part
  - The maxillary sinuses
  - The nasal apertures
  - The orbit
  - The superior aspect of the oral cavity.
- It is boundary for sphenomaxillary, pterigomaxillary fissures and contributes to the zygomatic and sphenomaxillary fossae.
- It articulates with the nasal, zygomatic, lacrimal, inferior turbinate, palatal, opposite maxillary and vomer bone.

Majority of maxillary fractures displacement follows the direction of the force they receive and they tend to stay in that position until reduced.

### **Classification of maxillary (midface fracture)**

Maxillary fractures can be classified by the L Forte .Le Fort classification was described by Rene Le Fort in 1900.

**Le forte I-** it involves only the maxilla.

It extends horizontally through the maxilla above the palate and through the lateral wall of the sinus and nasal aperture and septum.

If there is displacement, that is by the traction of internal and external pterygoid muscles.

**Le forte II** – the pyramidal fracture involves several bone of the midface in extending obliquely or vertically, through the lateral and posterior sinus walls, walls of the maxilla through the infraorbital foramen, floor of the orbit, and across the nose, usually through the nasal lacrimal and ethmoidal components down and back through the pterygoid area.



This fracture may extend superiorly to the cribriform plate.

This fracture can produce an open bite and dramatic periorbital edema.

### **Leforte III**

High level supra zygomatic fracture.

- ◆ Fracture line through the base of the nose ethmoid , neck of pterygoid plate , the inferior orbital fissures and disrupts attachments of the zygomatic bones, through the edge of the wing of the sphenoid and near fronto-zygomatic suture .The zygomatic arch is broken .The face is driven backward and downward.

### **CF**

- Gross edema of the face
- Long face
- Haemorrhage to the tissue (ecchymosis)
- Displacement of the eye
- CSF rhinorrhoea

- Mobility of the maxilla
- Area of anesthesia if infraorbital bone is affected.

### **Management**

- Clear airway
- Stop bleeding and treat shock
- Inspect for any other injuries
- Examine the face CSF escaping
- Care of the wound.

### **Diagnosis**

- Hx
- General examination
- Local examination
- Radiological examination

### **RX**

- ◆ Admission
- ◆ Reduction of the displacement
- ◆ Immobilization
- ◆ Infraorbital fixation
- ◆ Extraoral fixation
- ◆ Administration of Antibiotic and analgesics

# CHAPTER 12

## CONGENITAL MALFORMATION

### Cleft palate and lip

By 35 days of uterine age, the lip is normally fused, a failure to fuse causes cleft. A failure of lip fusion may impair the subsequent closure of the palatal shelves. Thus cleft lip is a frequent association with cleft lip. Cleft lip, with or without cleft palate, occurs more frequently than cleft palate alone. Cleft lip is the most common significant craniofacial anomaly.

Etiology:- Usually unknown

It is more likely to occur in the male.

### Classification

1. Unilateral complete Cleft palate
2. Unilateral incomplete Cleft palate
3. Bilateral complete Cleft palate
4. Bilateral partial Cleft palate

## 1. Primary cleft lip

Unilateral complete

- Malposition of the nostril skin on the lip
- Retraction of labial skin
- Alteration in the white roll
- Abnormalities in neighbouring mucosa

## 2. Premaxilla palate

Unilateral cleft

- The premaxilla is under developed on both sides (clefted / nonclefted)
- Deviation of the interincisive suture
- Septal deviation, causes an internal rotation of the ascending pillar of the maxilla and
- Attendant lateral displacement of the medial canthus on the cleft side
- Thereby disturbing the entire symmetry of the face

## **Classification of Cleft Palate**

1. Class I :- the defect is only on the soft palate]
2. Class II:- the defect involves the soft palate and the hard palate up to the incisival foramen
3. Class III:- the defect involves both the soft and hard palate up to the anterior alveolus.

**CF:-** Cleft lip can be easily identified by the mother as soon as the baby is born

Cleft palate is diagnosed later, when the child develops

- Vomiting
- Frequent aspiration
- Weight loss

Treatment:- Surgical closure of the defect

### **Social problem of the child with such defects**

- Speech defect
- Aesthetic problem
- Psychological problem

## CHAPTER 13

### PREVENTION OF DENTAL CARIES

#### Microbes of the oral cavity

In the oral cavity there are more than 100 species of microbes.

These are- Natural inhabitants such as acidophilic bacillus, trepanoma microdentium, diplococci, streptococcus salvarius, entoameba gingivalis act and those which are in the environment ingested together with food, water and air.

Pathogenic and conditionally pathogenic microbes are found on the mucus membrane of the mouth.

The oral cavity is a favorable medium for many microbes.

It has an optimal temperature, a sufficient amount of food substances and has a weakly alkaline reaction.

Increasing the amount of micro floras in the oral cavity depends up on the:

1. Type of food we eat
2. Rate of flow of saliva
3. General state of our health and health state of the oral cavity
4. Frequency of cleaning of the oral cavity

Great amount of microbes are found at the neck of teeth and in the space between teeth (interdental space).

Streptococci and diplococci are found on the tonsils.

There are many microbes in other parts of the oral cavity which are in accessible to the bathing action of saliva and the action of lysozyme.

The presence of carious teeth is a condition for increasing the micro flora in the oral cavity, for the appearance of decaying process and unpleasant odors.

Draft of basic statements on oral hygiene is defined as the practice of habits which tend to preserve healthy teeth in healthy gums through out life.

## **Principles of preventive Dentistry (Oral Health Care)**

### **I. Prevention of Dental caries**

Four things to be encouraged for the prevention of dental caries

1. See the children eat balanced diet which reduces the desire to eat sweet, sticky or soft foods between meals.
2. Remove food particles from the mouth after meals and especially last things at night by means of a tooth brush and tooth pastes or local sticks stimulate and harden the gum by a correct brushing and massage.
3. Finish the meal with a hard naturally cleaning food such as an apple carrot or rinse the mouth vigorously with water when tooth brushing is not possible



4. See the dentist and take the children too at list every six months.

**The principles may be grouped in to four:**

1. Oral hygiene
2. Dietary measures
3. Topical fluoride application
4. Ingestion of fluoride in tablet, milk slats, fluoridation of drinking water etc

**Oral hygiene**

1. Home care of the child
  - ❖ It is important to stress the necessity of cleaning of the teeth after every meal, or snack and before going to bed.
  - ❖ Teach children how to clean their teeth early in life (2 yrs)
  - ❖ Encourage the use of floss
  - ❖ Encourage the use of local sticks(specially for those who cannot afford the use of floss and tooth pastes)

## **Principles of methods of cleaning of teeth**

1. Tooth brushing
2. Oral rinsing
3. Eating detensive food stuffs

### **Tooth brushing**

#### **Tooth brush for children:**

6 inches long –Handle

1 and 1/2 inches- Head with several tufts (filaments).

Tufts shouldn't be hard. They should be nylon.

N.B. Tooth brush should be changed every 3 months.

### **Methods of tooth brushing**

Direction: For both jaws from the gum to the teeth.

Start from the upper left buccal region then to labial surface of the anterior teeth then to the right buccal region -> then to the lingual and palatal of the anterior teeth. Then down to the lower left buccal surface of the posterior teeth, then to the labial surface of anterior

teeth, then to the labial surface of the right lower posterior teeth, then to the lingual aspect of the anterior and posterior teeth. Attention should be given to the interdental (proximal spaces) which are favorable place for food impaction. Finally the occlusal surface should be scrubbed back ward and forward.

### **Tooth pastes**

#### **Purpose:**

- ❖ Removes fermentable carbohydrates from tooth
- ❖ Interferes with bacterial activities on the carbohydrates.
- ❖ Protects the enamel and strengthen the tooth itself
- ❖ Provides favorable odor to the oral cavity.

### **Oral rinsing**

It is recommended when the condition is not favorable for tooth brushing. Oral rinsing should be done after every snack.

## **Defensive food stuffs**

Apple removes soft food debris from the mouth and teeth efficiently. Other food stuffs such as carrots, sliced oranges are more efficient than tooth brushing in removing yeasts from the mouth after ingestion of a yeast cakes.

## **Dietary measures**

- ❖ Avoid foods with high carbohydrate contents as much as possible. Use apples, oranges after carbohydrate their foods.
- ❖ Rinse mouth after their usage.

## **Topical flourid (concentratio 0.1-4 % )**

Topical application of fluoride to teeth surface is a proven method of prevention of caries.

## **Method of application**

1. Fluoride solution applied on the teeth by the dentist.

2. Fluoride sol. brushed on the teeth by the children.
3. Incorporation of fluoride in a polishing pastes.

**NB:** Application is made for 20 min. every day for 15 days.

## **2. Prevention of periodontal diseases**

Normal gum is pink, firm, stippled with well formed papilla and gingival crevices, shallow in depth with out exudates.

### **Preventive measures**

1. Good oral hygiene
2. Avoid all predisposing factors
3. Prevention and treatment of calculus
4. Treat disorders of occlusion ( Extraction of extra tooth, avoid overcrowding)
5. Extract decayed deciduous teeth, avoid gingival irritation
6. Restorations should be carefully inserted, contoured and polished
7. Avoid food impaction and gingival damage.

**Recommendation:**

- 1 Proper use of local sticks (Mefakia) is very important. This topic has been always under discussion with the students who had taken this course and finally we used to agree on one point that is to preach the people to use the local stick (Mefakia) properly as it is not costly and easily available almost to everybody. A study was made in 1978 by Bent Olson in Arussi province on oral health and the study has confirmed that the local stick (Mefakia) is as effective as tooth brush if it is used properly in all the surfaces of the tooth.
- 2 Incorporation of oral health as part of health programs in schools
- 3 Including oral health in primary health care programs
- 4 Frequent use of mass media to teach the people about oral health is the relevant points for our country.

## REFERENCES

1. Philip L.McCarthy, A.B MD, Diseases of the oral mucosa , 1980
2. Collie and Crane , Internal Medicine In Dental practice
3. J.V. Saomes and Southam, Practical Oral Surgery
4. R.A. Cawson, Essentials of Dental Sugery and Pathology
5. Steiner and Thompson , Oral Surgery and Anesthesia
6. J.V. and J.C. Southam, Oral pathology
7. LordZuckerman, A System of practical Anatomy for Dental Students
8. Thomas J. Zwemer, Boucher's Clinical Dental Terminology,

9. Schwartz/ Lamster / Fine , Clinical Guide To periodontics , 1995
10. Baum Philips Lunds ,Textbook Of Operative Dentistry , 1981
11. Wheeler's, Dental Anatomy, Physiology and Occlusion, 1993
12. Pegamon serious on density vol. 1
13. Prof. T.G. Rustovaya texts of Surgical Stomatology for medical students of faculty of stotmatolgy ( In Russian language), 1990
14. N.N.Bazsanof , Text book of Stomatolgy for medical students, (In Russian language), 1990
15. Benit Olson, Periodontal disease and Oral hygiene in Arussi province, Ethiopia 1978, studies on dental in Ethiopia,



16. Raymond J. Fonseca and Robert V. Walker, Oral and Maxillofacial trauma, 1991
17. Raymond J. Fonseca , Oral and maxillofacial surgery, 2000
18. Sandra L.Melnick, A guide to epidemiological studies of oral manifestations of HIV infection, WHO, Geneva,1993

