


**Natalia Caproș, Tatiana Dumitraș, Svetlana Nichita,  
Nelea Draguța, Lilia Vlasov, Olga Corlățeanu**

# **DIFFERENTIAL DIAGNOSIS IN INTERNAL MEDICINE**



Chișinău • 2019

Nicolae Testemițanu State University of Medicine and Pharmacy  
of the Republic of Moldova

**Natalia Caproș, Tatiana Dumitraș, Svetlana Nichita,  
Nelea Draguța, Lilia Vlasov, Olga Corlăteanu**

# DIFFERENTIAL DIAGNOSIS IN INTERNAL MEDICINE

Chișinău • 2019

The textbook "Differential Diagnosis in Internal Medicine" was discussed and approved by the Internal Medicine Methodical Committee at the meeting of May, 7, 2018, Proceedings No 1 and by the Council of Quality Management of Nicolae Testemițanu State University of Medicine and Pharmacy of the Republic of Moldova at the meeting of September, 18, 2018, Proceedings No 1.

**Reviewers:**

*Ion Țibirnă* – MD, PhD, University Professor

*Livi Grib* – MD, PhD, University Professor

**Language Editor:**

*Nadejda Șamșurina* – Nicolae Testemițanu State University of Medicine and Pharmacy of the Republic of Moldova

---

Descrierea CIP a Camerei Naționale a Cărții

**Diferential Diagnosis in International Medicine:** [pentru uzul studenților] / Natalia Caproș, Tatiana Dumitraș, Svetlana Nichita [et al.]; Nicolae Testemitanu State Univ. of Medicine and Pharmacy of the Republic of Moldova. – Chișinău: S. n., 2019 (Tipogr. "Print Caro"). – 447 p.: fig., tab.

Bibliogr. la sfârșitul temelor. – 150 ex.

ISBN 978-9975-56-705-3.

616-07(075.8)

D 41

---

# Differential Diagnosis in Internal Medicine

Edited by

**Natalia Caproș**, MD, PhD,

Professor, Discipline of Internal Medicine – Clinical synthesis,  
Department of Internal Medicine, Nicolae Testemițanu State  
University of Medicine and Pharmacy of the Republic of Moldova

**Tatiana Dumitraș**, MD, PhD,

Associate Professor, Discipline of Internal Medicine – Clinical  
synthesis, Department of Internal Medicine, Nicolae Testemițanu  
State University of Medicine and Pharmacy of the Republic of  
Moldova

## Authors

**Natalia Caproș**, MD, PhD,

Professor, Discipline of Internal Medicine – Clinical synthesis,  
Department of Internal Medicine, Nicolae Testemițanu State University  
of Medicine and Pharmacy of the Republic of Moldova

**Tatiana Dumitraș**, MD, PhD,

Associate Professor, Discipline of Internal Medicine – Clinical synthesis,  
Department of Internal Medicine, Nicolae Testemițanu State University  
of Medicine and Pharmacy of the Republic of Moldova

**Svetlana Nichita**, MD, PhD,

Associate Professor, Discipline of Internal Medicine – Clinical synthesis,  
Department of Internal Medicine, Nicolae Testemițanu State University  
of Medicine and Pharmacy of the Republic of Moldova

**Nelea Draguța**, MD, PhD,

Associate Professor, Discipline of Internal Medicine – Clinical synthesis,  
Department of Internal Medicine, Nicolae Testemițanu State University  
of Medicine and Pharmacy of the Republic of Moldova

**Lilia Vlasov**, MD, PhD,

Associate Professor, Discipline of Internal Medicine – Clinical synthesis,  
Department of Internal Medicine, Nicolae Testemițanu State University  
of Medicine and Pharmacy of the Republic of Moldova

**Olga Corlăteanu**, MD,

Assistant Professor, Discipline of Internal Medicine – Clinical synthesis,  
Department of Internal Medicine, Nicolae Testemițanu State University  
of Medicine and Pharmacy of the Republic of Moldova

## PREFACE

The textbook „Differential Diagnosis in Internal Medicine” is intended for the sixth-year medical students and represents a comprehensive view over the main syndromes in Internal Medicine. In fact, this is the first work written in the Republic of Moldova which is entirely dedicated to the problem of differential diagnosis.

The topics in this textbook corresponds to the Curriculum for the Discipline of Internal Medicine – Clinical synthesis and include Differential diagnosis of chest pain, Differential diagnosis of pulmonary consolidation syndrome, Differential diagnosis of edema etc. Each topic is described according to a certain plan: introduction, definition, pathophysiology, classification, diagnostic approach, differential diagnosis (with a brief description of the most important clinical and paraclinical features of every disease) and bibliography.

Since the differential diagnosis is the first clinical exercise after obtaining the clinical history and the results of the basic and complementary examinations, this book has a sharp focus on essential information with a goal of providing clear answers to clinical questions in internal medicine. As many diseases have similarities in clinical presentation differential diagnosis becomes crucial for making the right clinical diagnosis. For example, physical signs of pulmonary consolidation are present in several conditions involving not only lungs but also cardiovascular system, i.e. pneumonia, primary and metastatic lung cancer, congestive heart failure etc. The importance of differential diagnosis is emphasized by the fact that the right diagnosis is the key for the efficient treatment.

The authors strongly believe that this manual would be useful not only for medical students but also for medical residents of different specialities and practitioners.

# CONTENTS

<b>Differential diagnosis of chest pain</b> .....	16
Natalia Caproș	
<b>Differential diagnosis of heart failure</b> .....	27
Natalia Caproș	
<b>Differential diagnosis of arterial hypertension</b> .....	43
Natalia Caproș	
<b>Differential diagnosis of cardiac arrhythmias</b> .....	56
Natalia Caproș	
<b>Differential diagnosis of non-ischemic cardiomyopathies</b> .....	74
Natalia Caproș	
<b>Differential diagnosis of pericardial diseases</b> .....	87
Natalia Caproș	
<b>Differential diagnosis of pulmonary consolidation</b> .....	97
Tatiana Dumitraș	
<b>Differential diagnosis of broncho-obstructive syndrome</b> .....	109
Tatiana Dumitraș	
<b>Differential diagnosis of diffuse interstitial lung diseases</b> .....	121
Olga Corlăteanu	
<b>Differential diagnosis of pleural effusion</b> .....	139
Olga Corlăteanu	
<b>Differential diagnosis of mediastinal syndrome</b> .....	156
Olga Corlăteanu	
<b>Differential diagnosis of allergic diseases</b> .....	168
Tatiana Dumitraș	
<b>Differential diagnosis of acute and chronic abdominal pain</b> .....	188
Svetlana Nichita	
<b>Differential diagnosis of constipation</b> .....	205
Svetlana Nichita	

<b>Differential diagnosis of diarrhea</b> .....	220
Svetlana Nichita	
<b>Differential diagnosis of malabsorbtion</b> .....	236
Svetlana Nichita	
<b>Differential diagnosis of dysphagia</b> .....	261
Tatiana Dumitraș	
<b>Differential diagnosis of hepatomegaly</b> .....	276
Tatiana Dumitraș	
<b>Differential diagnosis of jaundice</b> .....	290
Tatiana Dumitraș	
<b>Differential diagnosis of portal hypertension and its complications</b> .....	303
Olga Corlăteanu, Lilia Vlasov	
<b>Differential diagnosis of arthritis</b> .....	318
Nelea Draguța	
<b>Differential diagnosis of back pain</b> .....	338
Nelea Draguța	
<b>Differential diagnosis of connective tissue diseases</b> .....	358
Nelea Draguța	
<b>Differential diagnosis of fever of unknown origin</b> .....	374
Nelea Draguța	
<b>Differential diagnosis of fibromyalgia syndrome</b> .....	390
Nelea Draguța	
<b>Differential diagnosis of multivisceral syndrome in connective tissue diseases</b> .....	399
Nelea Draguța	
<b>Differential diagnosis of acute kidney failure</b> .....	410
Lilia Vlasov	
<b>Differential diagnosis of edema</b> .....	424
Lilia Vlasov	
<b>Differential diagnosis of nephrotic syndrome</b> .....	435
Lilia Vlasov	



## LIST OF ABBREVIATIONS

<b>AAE</b>	Acquired angioedema
<b>ABG</b>	Arterial blood gases
<b>ABL</b>	Acute basophilic leukemia
<b>ABPA</b>	Allergic bronchopulmonary aspergillosis
<b>ACE</b>	Angiotensin-converting enzyme
<b>ACPA</b>	Anti-citrullinated protein antibodies
<b>ACS</b>	Acute coronary syndrome
<b>ACTH</b>	Adrenocorticotrophic hormone
<b>AD</b>	Allergic diseases
<b>ADHD</b>	Attention Deficit Hyperactivity Disorder
<b>AD-PKD</b>	Autosomal dominant polycystic kidney disease
<b>AF</b>	Atrial flutter
<b>AFB</b>	Acid-fast bacillus
<b>AFb</b>	Atrial fibrillation
<b>AGL</b>	Alfa-glucosidase
<b>AGN</b>	Acute glomerulonephritis
<b>AHF</b>	Acute heart failure
<b>AIDS</b>	Acquired immune deficiency syndrome
<b>Ang II</b>	Angiotensin II
<b>AKI</b>	Acute Kidney Injury
<b>AKIN</b>	Acute Kidney Injury Network
<b>AL</b>	Amyloidosis
<b>ALAT</b>	Alaninaminotransferase
<b>AMA</b>	Anti-mitochondrial antibody
<b>ANA</b>	Antinuclear antibodies
<b>ANCA</b>	Antineutrophil cytoplasmic antibody
<b>ANP</b>	Atrial natriuretic peptide
<b>Anti-CCP</b>	Anti-cyclic citrullinated protein peptide
<b>Anti-RNP</b>	Antibody to Ribonucleoprotein
<b>APS</b>	Antiphospholipid syndrome
<b>ARF</b>	Acute renal failure
<b>ARVC</b>	Arrhythmogenic right ventricular cardiomyopathy
<b>ASAT</b>	Aspartataminotransferase
<b>ASLO</b>	Antistreptolysine antibodies

<b>AT</b>	Atrial tachycardia
<b>AV</b>	Atrio-ventricular
<b>AVNRT</b>	Atrioventricular nodal re-entrant tachycardia
<b>AVRT</b>	Atrioventricular re-entrant tachycardia
<b>BAL</b>	Bronchoalveolar lavage
<b>BBB</b>	Bundle branch blocks
<b>BNP</b>	Brain natriuretic peptide
<b>BOOP</b>	Bronchiolitis obliterans organizing pneumonia
<b>BOS</b>	Broncho-obstructive syndrome
<b>BUN</b>	Blood urea nitrogen
<b>cANCA</b>	Cytoplasmic antineutrophil cytoplasmic antibodies
<b>CASQ2</b>	Gene that encodes for calcium-binding calsequestrin protein
<b>CBCD</b>	Complete Blood Count with Differential
<b>CCC<sub>s</sub></b>	Cholangiocarcinomas
<b>CD</b>	Crohn's disease
<b>CEA</b>	Carcinoembryonic antigen
<b>CF</b>	Cystic fibrosis
<b>CFTR</b>	Cystic fibrosis transmembrane conductance regulator
<b>CGN</b>	Chronic glomerulonephritis
<b>CJD</b>	Creutzfeldt-Jakob disease
<b>CKD</b>	Chronic kidney disease
<b>CK</b>	Creatine kinase
<b>CMV</b>	Cytomegalovirus
<b>CN</b>	Cranial nerve
<b>CNS</b>	Central nervous system
<b>COP</b>	Cryptogenic organizing pneumonia
<b>COPD</b>	Chronic obstructive pulmonary disease
<b>C1-INH</b>	C1 inhibitor
<b>CPPD</b>	Calcium pyrophosphate dihydrate
<b>CPE</b>	Cardiogenic pulmonary edema
<b>CRF</b>	Chronic renal failure
<b>CRP</b>	C-reactive protein
<b>CT</b>	Computed tomography
<b>CTD</b>	Connective tissue disease
<b>CV</b>	Cardiovascular

<b>CVDs</b>	Collagen vascular diseases
<b>CXR</b>	Chest X-ray
<b>DBP</b>	Diastolic blood pressure
<b>DCM</b>	Dilated cardiomyopathy
<b>DJS</b>	Dubin-Johnson syndrome
<b>DILD</b>	Diffuse interstitial lung diseases
<b>DIP</b>	Desquamative interstitial pneumonia
<b>DISH</b>	Diffuse idiopathic skeletal hyperostosis
<b>DLCO</b>	Diffusing capacity for carbon monoxide
<b>DNA</b>	Deoxyribonucleic acid
<b>DNP</b>	Deoxyribonucleoprotein
<b>DVT</b>	Deep vein thrombosis
<b>EBUS</b>	Endobronchial ultrasound
<b>EBV</b>	Epstein-Barr virus
<b>ECG</b>	Electrocardiogram
<b>EF</b>	Ejection fraction
<b>EGD</b>	Esophagogastroduodenoscopy
<b>ELISA</b>	Enzyme-linked immunosorbent assay
<b>ENA</b>	Extractable nuclear antigen
<b>ERCP</b>	Endoscopic retrograde cholangiopancreatography
<b>ESR</b>	Erythrocyte sedimentation rate
<b>EUS</b>	Endoscopic ultrasonography
<b>FAPS</b>	Functional abdominal pain syndrome
<b>FBC</b>	Full blood count
<b>FcMRI</b>	Functional connectivity magnetic resonance imaging
<b>FEV1</b>	Forced expiratory volume in the first second
<b>FEF</b>	Forced expiratory flow
<b>FNA</b>	Fine needle aspiration
<b>FMF</b>	Familial Mediterranean fever
<b>FMS</b>	Fibromyalgia syndrome
<b>FNH</b>	Focal nodular hyperplasia
<b>FOBT</b>	Fecal occult blood test
<b>FSH</b>	Follicle stimulating hormone
<b>FUO</b>	Fever of unknown origin
<b>FVC</b>	Forced vital capacity
<b>GABA</b>	Gamma-Aminobutyric Acid

<b>GBM</b>	Glomerular basement membrane
<b>GFR</b>	Glomerular filtration rate
<b>GERD</b>	Gastroesophageal reflux disease
<b>GPI</b>	Glycoprotein Iib/IIIa inhibitor
<b>GRA</b>	Glucocorticoid-remediable aldosteronism
<b>G6PD</b>	Glucose-6-phosphate dehydrogenase deficiency
<b>GU</b>	Gastric ulcer
<b>GVHD</b>	Graft-versus-host disease
<b>H2RA</b>	H2-receptor antagonist
<b>HAE</b>	Hereditary angioedema
<b>HAV</b>	Hepatitis A virus
<b>Hb</b>	Hemoglobin
<b>HBV</b>	Hepatitis B virus
<b>HCC</b>	Hepatocellular carcinoma
<b>HCMP</b>	Hypertrophic cardiomyopathy
<b>Hct</b>	Hematocrit
<b>HCV</b>	Hepatitis C virus
<b>HCW</b>	Health care worker
<b>HD</b>	Hemodialysis
<b>HDL</b>	High-density lipoprotein
<b>HDV</b>	Hepatitis D virus
<b>HE</b>	Hepatic encephalopathy
<b>HEV</b>	Hepatitis E virus
<b>HIDS</b>	Hyper-immunoglobulinemia D syndrome
<b>HBIG</b>	Hepatitis B immunoglobulin
<b>HIV</b>	Human immunodeficiency virus
<b>HLA</b>	Human leukocyte antigen
<b>HOA</b>	Hypertrophic osteoarthropathy
<b>HPS</b>	Hepatopulmonary syndrome
<b>HSP</b>	Henoch-Schönlein purpura
<b>HRCT</b>	High-resolution computed tomography
<b>HRS</b>	Hepatorenal syndrome
<b>HS</b>	Hereditary spherocytosis
<b>IBD</b>	Irritable bowel disease
<b>IBS</b>	Irritable bowel syndrome
<b>IE</b>	Infective endocarditis

<b>NIE</b>	Nosocomial infective endocarditis
<b>ILD</b>	Interstitial lung disease
<b>INR</b>	International normalized ratio
<b>IPF</b>	Idiopathic pulmonary fibrosis
<b>IPH</b>	Idiopathic pulmonary hemosiderosis
<b>IVDAE</b>	Intravenous drug abuse endocarditis
<b>KDIGO</b>	Kidney Disease Improving Global Outcomes
<b>LAM</b>	Lymphangioliomyomatosis
<b>LAV1</b>	Left atrial volume index
<b>LBB</b>	Left bundle branch blocks
<b>LBP</b>	Low back pain
<b>LC</b>	Lymphangitis carcinomatosa
<b>LCH</b>	Langerhans cell histiocytosis
<b>LDH</b>	Lactate dehydrogenase
<b>LH</b>	Luteinizing hormone
<b>LIP</b>	Lymphoid interstitial pneumonia
<b>LV</b>	Left ventricular
<b>LVEDP</b>	Left ventricular end diastolic pressure
<b>LVEF</b>	Left ventricle ejection fraction
<b>MAHA</b>	Microangiopathy chemolytic anaemia
<b>MAT</b>	Multifocal atrial tachycardia
<b>MCHC</b>	Mean corpuscular hemoglobin concentration
<b>MCTD</b>	Mixed connective tissue disease
<b>MHC</b>	Major histocompatibility complexes
<b>MEN</b>	Multiple endocrine neoplasia
<b>MRCPP</b>	Magnetic resonance cholangiopancreatography
<b>MRI</b>	Magnetic resonance imaging
<b>MRSA</b>	Methicillin-resistant Staphylococcus aureus
<b>MTC</b>	Medullary thyroid carcinoma
<b>MWS</b>	Muckle–Wells syndrome
<b>NAA</b>	N-acetyl-aspartate
<b>NAG</b>	N-acetyl- $\beta$ -glucosaminidase
<b>NADP</b>	Nicotinamide adenine dinucleotide phosphate
<b>NADPH</b>	Nicotinamide adenine dinucleotide phosphate
<b>NAFLD</b>	Non-alcoholic fatty liver disease
<b>NCGS</b>	Non-celiac gluten sensitivity

<b>NDNA</b>	Nuclear Deoxyribonucleic acid
<b>NO</b>	Nitric oxide
<b>NOS</b>	Nitric oxide synthase
<b>NS</b>	Nephrotic syndrome
<b>NSAIDs</b>	Nonsteroidal anti-inflammatory drugs
<b>NSCLC</b>	Non-small cell lung cancer
<b>NSIP</b>	Nonspecific interstitial pneumonia
<b>NVE</b>	Native valve endocarditis
<b>PAH</b>	Pulmonary arterial hypertension
<b>PAN</b>	Polyarteriitis nodosa
<b>PAP</b>	Pulmonary alveolar proteinosis
<b>PBC</b>	Primary biliary cirrhosis
<b>PCWP</b>	Pulmonary capillary wedge pressure
<b>PD</b>	Parkinson's disease
<b>PFAPA</b>	Periodic Fever, Adenitis, Pharyngitis, and Aphthous stomatitis Syndrome
<b>PEFR</b>	Peak expiratory flow rate
<b>PET</b>	Positron emission tomography
<b>PGE, PGI</b>	Prostaglandins
<b>PJC</b>	Premature junctional complex
<b>PLA<sub>2</sub>R</b>	Phospholipase A <sub>2</sub> receptor
<b>PMY/DMY</b>	Polymyositis/Dermatomyositis
<b>PO</b>	Plasma osmolarity
<b>PPFE</b>	Pleuropulmonary fibroelastosis
<b>PPH</b>	Portopulmonary hypertension
<b>PSS</b>	Progressive systemic sclerosis
<b>PSVC</b>	Premature supraventricular contractions
<b>PT</b>	Prothrombin time
<b>PTH</b>	Parathyroid hormone
<b>PTT</b>	Partial thromboplastin time
<b>PVC</b>	Premature ventricular contraction
<b>PVE</b>	Prosthetic valve endocarditis
<b>PVT</b>	Portal vein thrombosis
<b>RA</b>	Rheumatoid arthritis
<b>RAST</b>	Radioallergosorbent test
<b>RBC</b>	Red blood cell

<b>RBF</b>	Renal blood flow
<b>RB-ILD</b>	Respiratory bronchiolitis – interstitial lung disease
<b>RCM</b>	Restrictive cardiomyopathy
<b>RNA</b>	Ribonucleic acid
<b>RNP</b>	Ribonucleoprotein
<b>RP</b>	Raynaud phenomenon
<b>RPGN</b>	Rapidly Progressive Glomerulonephritis
<b>RT-PCR</b>	Reverse transcription polymerase chain reaction
<b>RV</b>	Residual volume
<b>SA</b>	Sino-atrial
<b>SBP</b>	Systolic blood pressure
<b>SCD</b>	Sickle cell disease
<b>SLE</b>	Systemic lupus erythematosus
<b>SCLC</b>	Small cell lung cancer
<b>SCr</b>	Serum creatinine
<b>SSS</b>	Severity Scale Symptom
<b>STC</b>	Slow transit constipation
<b>SE</b>	Subcutaneous emphysema
<b>SMS</b>	Superior mediastinal syndrome
<b>STEMI</b>	ST segment elevation myocardial infarction
<b>SVCS</b>	Superior vena cava syndrome
<b>SVT</b>	Supraventricular tachyarrhythmias
<b>TIBC</b>	Total iron-binding capacity
<b>TINU</b>	Thrombosis tubulo-interstitial nephritis and uveitis syndrome
<b>TLC</b>	Total lung capacity
<b>TNF</b>	Tumor necrosis factor
<b>TOS</b>	Thoracic outlet syndromes
<b>TRAPS</b>	Tumor Necrosis Factor Receptor associated Periodic Fever Syndrome
<b>TSH</b>	Thyroid-stimulating hormone
<b>UDA</b>	Urticaria-deafness-amyloidosis syndrome
<b>UDPGT</b>	Uridine-diphosphoglucuronate glucuronosyltransferase
<b>UES</b>	Upper esophageal sphincter
<b>UO</b>	Urinary osmolarity
<b>VCD</b>	Vocal cord dysfunction

<b>WBC</b>	White blood cell
<b>VFb</b>	Ventricular fibrillation
<b>VT</b>	Ventricular tachycardia
<b>WPW</b>	Wolf-Parkinson-White preexcitation syndrome
<b>WPI</b>	Widespread pain index



## DIFFERENTIAL DIAGNOSIS OF CHEST PAIN

**INTRODUCTION.** Chest pain is a syndrome that can be in different pathologies and is considered a medical emergency. Chest pain of cardiac or noncardiac origin – this is often a diagnosis of exclusion made after ruling out more serious causes of the pain. The list includes 440 causes of chest pain that range from non-serious to life-threatening. *Chest pain can originate from all organs of the thorax.* The most common causes of chest pain in adults include: gastrointestinal (42%), coronary artery (31%), musculoskeletal disease (28%), pericarditis (4%) and pulmonary embolism (2%).

### **Common causes of chest pain:**

**Cardiovascular causes:** acute myocardial infarction, acute coronary ischemia, aortic dissection, cardiac tamponade, unstable angina, coronary spasm, Prinzmetal's angina, cocaine-induced chest pain, pericarditis, myocarditis, valvular heart disease, aortic stenosis, mitral valve prolapse, hypertrophic cardiomyopathy.

**Pulmonary causes:** pulmonary embolus, pneumothorax, pleuritis, tumor, mediastinitis, pneumomediastinum.

**Gastrointestinal causes:** esophageal rupture (Boerhaave's syndrome), esophageal tear (Mallory-Weiss syndrome), cholecystitis, pancreatitis, esophageal spasm, esophageal reflux, peptic ulcer, biliary colic, dyspepsia, splenic infarction.

**Musculoskeletal causes:** muscle strain, costochondritis, nonspecific chest wall pain, arthritis, tumor, rib fracture, cervical disk disease, fibromyalgia.

**Neurologic causes:** spinal root compression, Herpes zoster, postherpetic neuralgia, thoracic outlet.

**Other causes:** psychologic, hyperventilation.

**Less common causes include:** lung cancer and aortic aneurysms.

More than 50% of people presenting to emergency facilities with unexplained chest pain will have coronary disease ruled out. In the coronaries the prevalence of typical ischemic chest pain was reported in 14% and atypical chest pain – 24%.

**PATHOPHYSIOLOGY.** The inner chest organs: heart, blood vessels, esophagus and visceral pleura are innervated by visceral fibers, that enter the spinal cord at several levels leading to poorly localized, poorly charac-

terized pain (discomfort). As dorsal fibers can overlap three levels above or below, thoracic pain can be produced and irradiate from the jaw to the epigastria. In contrast to visceral pain, parietal pain, is sharp and can be localized to the dermatome superficial to the site of the painful stimulus. The dermis and parietal pleura are innervated by parietal fibers.

## **CLASSIFICATION OF CHEST PAIN**

### **I. Cardiac chest pain (heart-related)**

- ischemic chest pain
- non-ischemic chest pain

### **II. Non-cardiac chest pain.**

## **DIFFERENTIAL DIAGNOSIS of ischemic cardiac and non-cardiac chest pain**

**Ischemic cardiac pain.** Symptoms of acute chest pain, those with a higher intensity of pain had a higher likelihood of developing acute myocardial infarction. Patients with acute coronary syndrome mostly describe their pain as diffuse over a wide area of the anterior chest wall and not localized. The pain might radiate to the left and/or right arm as well as to the neck and back. History and symptom evaluation should be based on type, severity, reference, response to posture/movement, response to food/fluid, tenderness, response to nitroglycerin and associated symptoms in order to decide whether a patient with chest pain has a dangerous condition.

**Non-cardiac chest pain** is a chest pain without evidence of coronary heart disease in conventional diagnostic evaluation. The prevalence of non-cardiac chest pain is up to 70%. These are musculoskeletal in 40%, gastrointestinal in 20%, psychiatric in 10% and pulmonary and mediastinal diseases in 5% of cases. The gastroenterological spectrum includes: gastroesophageal reflux disease (GERD) in 60%, hypercontractile esophageal motility disorders, achalasia in 20% and other esophagitis in 30%.

**Associated symptoms:** Chest pain that occurs in acute coronary syndrome is generally accompanied by autonomic nervous system stimulation. The patient often appears pale, diaphoretic and cool to touch. Acute pain with associated vegetative symptoms should put the patient on the fast track with any diagnosis. Associated symptoms should be assessed together with signs of other diseases, such as infection, fever, anxiety and nervousness.

*Differential diagnosis of chest pain by localization* includes important skin areas for referral of chest pain:

**Retrosternal**

- Myocardial ischemic pain
- Pericardial pain
- Esophageal pain
- Aortic dissection
- Mediastinal lesions
- Pulmonary embolism

**Arms**

- Myocardial ischemic pain
- Pericarditis
- Subdiaphragmatic abscess
- Diaphragmal pleurisy
- Cervical spine disease
- Acute musculoskeletal pain
- Thoracic outlet syndrome

**Interscapular**

- Myocardial ischemic pain
- Musculoskeletal pain
- Gallbladder pain
- Pancreatic pain

**Epigastric**

- Myocardial ischemic pain
- Pericardial pain
- Esophageal pain
- Duodenal/gastric pain
- Gallbladder pain
- Pancreatic pain
- Distention of the liver
- Diaphragmatic pleurisy
- Pneumonia/pleurisy

**Right lower chest**

- Gallbladder pain
- Distention of the liver
- Subdiaphragmatic abscess
- Pneumonia/pleurisy
- Gastric or duodenal penetrating ulcer
- Pulmonary embolism
- Acute myositis

- Injuries

**Left lower chest**

- Intercostal neuralgia
- Pulmonary embolism
- Myositis
- Pneumonia/pleurisy
- Splenic infarction
- Splenic flexure syndrome
- Subdiaphragmatic abscess
- Precordial catch syndrome
- Injuries.

Variables indicating a *very low risk* of development of unstable angina pectoris or myocardial infarction are sharp or stabbing pain, no history of angina pectoris or myocardial infarction, pain with pleuritic or positional components and pain that was reproduced by palpation of the chest wall.

**Diagnostic tests in acute chest pain**

In patients with acute chest pain the diagnostic procedure should serve two major purposes:

- 1) to identify quickly high risk patients for the fast track;
- 2) to delineate patients in whom there is little or no suspicion of a life-threatening disease.

**12-lead ECG** is a readily available and is considered a standard of care and always be recorded in patients suffering from acute chest pain if the cause of the pain is not sufficiently clear from the patients' history and physical examination.

**Biochemical markers**, particularly troponins in combination with CK-MB serves as markers of myocardial necrosis.

**Imaging techniques** (chest radiography, 2D-echocardiography, radio-nuclide imaging, angiocoronarography) are helpful in identifying low-risk patients, who can be eligible for early discharge or undergo early stress testing.

**Life-threatening causes of chest pain** include:

1. Acute coronary syndromes
2. Pericarditis with tamponade
3. Aortic dissection
4. Pulmonary embolus
5. Tension pneumothorax
6. Esophageal rupture.

## DIFFERENTIAL DIAGNOSIS OF LIFE THREATENING CAUSES OF CHEST PAIN

### 1. Acute coronary syndrome (ACS)

ACS refers to *life*-threatening conditions: acute myocardial ischemia and/or infarction that are due to an acute decrease in coronary blood flow.

**Classification.** ACS includes the clinical picture of coronary artery disease: chest pain, ECG changes and increase in cardiac biochemical markers. The spectrum spans from unstable angina pectoris to transmural myocardial infarction. ACS is divided into two large categories, each of which requires a specific treatment strategy.

- **ACS with ST segment elevation** (ST segment elevation myocardial infarction, STEMI) or new, left bundle branch block (LBBB): in these patients the coronary artery is most likely totally occluded.

- **ACS without ST segment elevation** (NSTEMI): the ECG changes include transient ST segment elevation, ST segment depression, T wave inversions, and other changes of repolarization. This category also includes patients who do not show any ECG changes despite ischemic chest pain and, conversely, patients who show ischemic ECG changes but do not complain of chest discomfort. NSTEMI can be further subdivided on the basis of cardiac biomarkers of necrosis. If cardiac biomarkers are elevated and the clinical context is appropriate, the patient is considered to have NSTEMI, the patient is deemed to have unstable angina. ST depression, transient ST-elevation, and/or prominent T-wave inversions may be present but are not required for a diagnosis of NSTEMI. Abnormalities on the ECG and elevated troponins in isolation are insufficient to make the diagnosis of ACS but must be interpreted in the appropriate clinical context.

**Evaluation and diagnosis** are based on the history of pain, physical examination, electrocardiogram, and cardiac biochemical markers. The leading symptom of ACS is chest pain, most commonly as a pressure-type chest pain that typically occurs at rest or with minimal exertion. The pain most frequently starts in the retrosternal area and can radiate to either or both arms, the neck, or the jaw. The pain may also occur in these areas independent of chest pain. Associated symptoms are: diaphoresis, dyspnea, nausea, abdominal pain, or syncope. Unexplained new-onset or increased exertional dyspnea is the most common angina equivalent. Less common presentations include nausea and vomiting, diaphoresis, unexplained fatigue, and syncope.

The factors that increase the probability of acute coronary syndrome are older age, male sex, positive family history of coronary artery disease, and the presence of peripheral arterial disease, diabetes mellitus, renal insufficiency, prior myocardial infarction, and prior coronary revascularization. Although older male patients ( $\geq 75$  years) and females usually present with typical symptoms of acute coronary syndrome, the frequency of atypical presentations is increased in these groups as well as in patients with diabetes mellitus, impaired renal function, and dementia. Atypical symptoms, including epigastric pain, indigestion, stabbing or pleuritic pain, and increased dyspnea in the absence of chest pain should cause concern of ACS.

**Resting ECG.** The ST-segment elevation (measured at the J-point) is considered suggestive of ongoing coronary artery acute occlusion in the following cases: at least two contiguous leads with ST-segment elevation  $\geq 2.5$  mm in men  $< 40$  years,  $\geq 2$  mm in men  $\geq 40$  years, or  $\geq 1.5$  mm in women in leads  $V_2$ - $V_3$  and/or  $\geq 1$  mm in the other leads [in the absence of left ventricular (LV) hypertrophy or left bundle branch block LBBB]. The ST-segment depression in leads  $V_1$ - $V_3$  suggests myocardial ischaemia, especially when the terminal T-wave is positive (ST-segment elevation equivalent), and confirmation by concomitant ST-segment elevation  $\geq 0.5$  mm recorded in leads  $V_7$ - $V_9$  should be considered as a means to identify posterior myocardial infarction.

**Non-diagnostic ECG.** Some patients with an acute coronary occlusion may have an initial ECG without ST-segment elevation, sometimes because they are seen very early after the symptom onset (in this case, one should look for hyperacute T-waves, which may precede ST-segment elevation). It is important to repeat the ECG or monitor for dynamic ST-segment changes. In addition, there is a concern that some patients with acute occlusion of the coronary artery and ongoing MI, as well as those with an occluded circumflex coronary artery, acute occlusion of a vein graft, or left main disease, may present without ST-segment elevation and be denied reperfusion therapy, resulting in a larger infarction and worse outcomes. Extending the standard 12-lead ECG with  $V_7$ - $V_9$  leads may identify some of these patients. In any case, suspicion of ongoing myocardial ischaemia is an indication for a primary PCI strategy even in patients without diagnostic ST-segment elevation.

**The exercise ECG** is recorded during exercise on a bicycle or a treadmill. The test is clinically positive if angina pectoris occurs. It is electro-

cardiographically positive if there is either an ST segment depression of at least 0.1 mV (subendocardial ischemia) or a transient monophasic ST segment elevation (transmural ischemia). Extensive ST segment depressions in several leads, simultaneous with a drop in blood pressure, or the occurrence of anginal symptoms at a low exercise level, are indications of a severe coronary artery disease.

**Echocardiography** allows the visualization of heart wall motion abnormalities caused by chronic or acute ischemia, and scars of old infarcts. In chronic stable angina pectoris, stress echocardiography is used to look for stress-induced heart wall motion abnormalities as a sign of a significant ischemic coronary artery disease. Dobutamin in increased doses is infused to stress the heart in a stress echocardiography.

**Myocardial scintigraphy.** Radionuclide tracers allow the visualization of regional differences in coronary flow during exercise. Thallium 201, technetium 99 mTc-labeled sestamibi and 99 mTc-labeled tetrofosmin are radionucleotide tracers currently in use. The tracers are taken up by myocardial cells in proportion to coronary flow. A fixed defect is recorded in regions of an old infarct. Regions with exercise-induced ischemia exhibit reversible uptake deficits. Thallium 201 has the property to accumulate in the myocardial cells over several hours. This allows to test whether the myocardium in the area of a defect is still viable. Late accumulation of thallium (12-24 hours after initial test) is an indication for viability of the myocardium, despite reduced coronary flow.

**Positron Emission Tomography (PET).** Myocardial scintigraphy detects only relative differences in perfusion. PET allows the measurement of absolute coronary flows. In addition to the detection of perfusion deficits, viability can be tested with tracers that are incorporated in metabolic pathways of the myocardial cells. Therefore, PET has become the „gold standard” to test for viability in hypoperfused, hypocontractile myocardial areas. In addition, PET can now be combined with high resolution computed tomography. Thus, a coronary stenosis can be visualized and the physiological effect of the stenosis can be assessed simultaneously.

**Magnetic Resonance Imaging (MRI).** MRI not only discloses the anatomical structures of the heart and coronary arteries, it is also capable of measuring absolute coronary blood flow. Changes in MR properties of ischemic myocardium allow the detection of a significant number of coronary artery diseases. In addition, scar tissue can be unequivocally identified and precisely quantified.

**Coronary angiography.** In case of proven or suspected myocardial ischemia, coronary angiography is indispensable for visualization of the coronary anatomy and stenoses. The anatomic severity of a coronary stenosis is, however, not always predictive of its physiologic effect. In a stenosis of unclear significance the physiologic effect, and therefore the clinical relevance, can be assessed by measuring the fractional coronary flow reserve. This is done by measuring the drop in pressure and/or flow over the stenosis at rest and after maximal vasodilation with adenosine. In chronic stable angina pectoris a coronary angiography is performed if a coronary revascularization is considered. A diagnostic coronary angiography should also be performed if the noninvasive tests are not equivocal in all patients with heart failure. In patients with unstable angina pectoris a timely invasive evaluation is advisable.

**2. Aortic dissection.** An aortic dissection has to be considered in case of acute substernal tearing sensation, with radiation to interscapular region of the back; pain may migrate with the propagation of the dissection in the back or radiating to the back; stroke; acute myocardial infarction, due to the obstruction of aortic branches; dyspnoea due to acute aortic regurgitation; hypotension due to cardiac tamponade. Aortic dissection occurs most commonly in the sixth or seventh decade of life. Hypertension, aortic atherosclerosis which are present in 80% of the patients and previous surgery of the aorta: coronary bypass operation or aortic valve replacement are predisposing factors. Aortic dissection may, however, occur in other patients. The main risk factor in the young is aortic diseases with medial degeneration: Marfan syndrome, Ehlers-Danlos syndrome, coarctation of the aorta, or fibromuscular dysplasia. In younger women, about 50% of cases of aortic dissection occur during pregnancy in the third trimester. Aortic dissections can also be caused by trauma or iatrogenic injuries, by catheters, or an intra-aortic balloon pump.

Aortic dissection results from a tear in the intima, such that blood penetrates between the intimal layer and the media of the aortic wall. This creates a false lumen in the arterial wall. Typically a second tear of the intima creates the exit for the blood. This exit site can be located in the ascending aorta, in the descending aorta, or the iliac vessels. Compression of the truncus brachiocephalicus results in a pulse deficit and blood pressure difference between the right and the left arm. Less frequent complications are: the compression of the coronary arteries resulting in myocardial infarction, rupture of the dissection into the pericardial space with pericardial tam-



ponade, hemothorax, rupture of the descending aorta with bleeding into the mediastinum or abdomen, a compression of the renal arteries with subsequent acute renal failure, mesenteric infarction with an acute abdomen due to the compression of the celiac and/or superior mesenteric artery, and acute limb ischemia secondary to the obstruction of the flow in the arteria iliaca. The rupture of the aorta is the most common cause of death. Aortic dissection must be suspected in patients presenting with widened mediastinum on chest radiograph. The diagnosis is confirmed by transesophageal echocardiography: false lumen or flap in the ascending or descending aorta; new aortic regurgitation or pericardial tamponade. **Chest CT with contrast or MRI angiography confirms** false lumen or flap in the ascending or descending aorta.

**3. Pericardial tamponade.** The main clinical sign of pericardial tamponade is persistent, sharp, severe, stabbing, tearing, varying with respiration, position, and motion (increasing pain in recumbency and with deep inspiration or coughing), precordial chest pain. The associated signs are: hypotension, distended jugular veins, distended liver, and pulsus paradoxus. The tamponade of the pericardium occurs with a rupture of the free wall after myocardial infarction, tuberculosis, iatrogenic (invasive procedure-related, post-cardiac surgery), trauma, neoplasm, malignancy, collagen vascular diseases, radiation induced, uraemia, aortic dissection, bacterial infection and pneumopericardium. The diagnosis is made by echocardiography: pericardial effusion causing collapse of great vessels, atria, and ventricles.

**4. Pulmonary embolism.** Chest pain is sharp and pleuritic in nature; dyspnoea; haemoptysis may occur if pulmonary infarction develops; syncope. Risk factors: history of immobilisation, orthopaedic procedures, oral contraceptive use, previous pulmonary embolism, fever, deep venous thrombosis. Associated signs: tachycardia, loud P2, right-sided S4 gallop, jugular venous distention, hypotension, tachypnea. The ECG shows a rotation of the frontal QRS axis to the right, S1, Q3, and T3 pattern. The chest radiograph may show decreased perfusion in a segment of pulmonary vasculature; wedge-shaped or linear opacities of any size or shape, pleural effusion, or an elevated hemidiaphragm. Blood gases show low PaO<sub>2</sub> and low PaCO<sub>2</sub>. D-dimers are elevated in the plasma (500 ng/L). **Echocardiography** may show acute right ventricular dilation or hypokinesis. The diagnosis of pulmonary embolism is most often confirmed by a **CT pulmonary angiography**— may identify thrombus in the pulmonary artery.

**5. Tension pneumothorax** is a life-threatening complication of pneumothorax with sudden onset of sharp, tearing, acute, pleuritic, unilateral chest pain, variable with respiration, accompanied by increasing dyspnoea and shock. Spontaneous tension pneumothorax is an extremely rare event and usually occurs in the lungs with a distinct underlying pathology: COPD, traumatic due to acute trauma or iatrogenic. If the pressure inside the pneumothorax rises above the atmospheric, as it may occur with a one-way leak into the pleural space or it occurs as a complication of positive pressure ventilation, a tension pneumothorax is present. The mediastinum shifts toward the unaffected side, and cardiac output may be severely compromised due to the positive intrathoracic pressure decreasing venous return to the heart. The exam reveals: absent breath sounds, increased resonance to percussion, jugular venous distention, trachea deviation, and hypotension due to the compromise of the great vessels. **The diagnosis is confirmed by chest radiography:** air in the pleural space, visible pleural line from collapsed lung, or mediastinal shift.

**6. Esophageal rupture** is characterized by an excruciating, sharp precordial pain, radiating to back, usually after vomiting, followed by fever and shock. The most common cause of esophageal perforation is postemetic with high mortality trauma, including postoperative trauma, medical instrumentation for diagnostic and therapeutic endeavors. The mediastinal pleura often ruptures, and gastric fluid is drawn into the pleural space by the negative intrathoracic pressure. This pleural effusion usually is on the left but can be bilateral. Double-contrast esophageal barium studies are recommended as the initial imaging study.

## BIBLIOGRAPHY

1. Amsterdam E., Wenger N., Brindis R., et al. 2014 AHA/ACC Guideline for the Management of Patients With Non-ST-Elevation Acute Coronary Syndromes A Report of the American College of Cardiology/American Heart Association Task Force on Practice Guidelines Developed in Collaboration With the Society for Cardiovascular Angiography and Interventions and Society of Thoracic Surgeons Endorsed by the American Association for Clinical Chemistry. *Circulation*. 2014; 130: e344-e426.
2. Antman E.M., Anbe D.T., Armstrong P.W., et al. ACC/AHA guidelines for the management of patients with ST-elevation myocardial infarction: executive summary: a report of the ACC/AHA Task Force on Practice Guidelines. *Circulation* 2004; 110: 588-636.

3. Braunwald E., Antman E.M., Beasley J.W., et al. ACC/AHA guideline update for the management of patients with unstable angina and non-ST segment elevation myocardial infarction: a report of the American College of Cardiology/American Heart Association Task Force on Practice Guidelines (Committee on the Management of Patients With Unstable Angina). 2002. Available at [www.acc.org/clinical/guidelines/unstable/unstable.pdf](http://www.acc.org/clinical/guidelines/unstable/unstable.pdf) (accessed 08.11.2017).
4. Braunwald E., Zipes D.P., Libby P. Heart Disease. A Textbook of Cardiovascular Medicine. 6th ed. Philadelphia: Saunders Company 2001.
5. Erhardt L., Herlitz J., Bossaert L., Chest Pain (Management of). ESC Clinical Practice Guidelines. *European Heart Journal* (2002) 23, 1153–1176 doi:10.1053/euhj.2002.3194.
6. Ibanez B., James S., Agewall S. et al. 2017 ESC Guidelines for the management of acute myocardial infarction in patients presenting with ST-segment elevation: The Task Force for the management of acute myocardial infarction in patients presenting with ST-segment elevation of the European Society of Cardiology (ESC). *European Heart Journal*, ehx393. 2017, <https://doi.org/10.1093/eurheartj/ehx393> (accessed 08.11.2017).
7. Kasper D., Hauser S., Fauci A., et al. Disorders of the heart. In: Harrison's principles of internal medicine. 19<sup>th</sup> edition. McGraw-Hill Professional's MediaCenter. 2015. 2758pps.
8. Miksad R., Delamora P., Meyer G., et al. Last Minute Internal medicine. 2008. The McGraw-Hill Companies. 535 pps.
9. Roffi M., Patrono C., Collet J., et al. 2015 ESC Guidelines for the management of acute coronary syndromes in patients presenting without persistent ST-segment elevation. *Rev Esp Cardiol* 2015; 68(12):1125. doi:10.1016/j.rec.2015.10.00
10. Siegenthaler W. with contributions by Aeschlimann A., Baechli E., Bassetti C. et al. Differential diagnosis in internal medicine from symptom to diagnosis. 2007, Georg Thieme Verlag, 1104 pps.
11. [www.infogalactic.com/info/Chest\\_pain](http://www.infogalactic.com/info/Chest_pain) (accessed 08.11.2017).

# DIFFERENTIAL DIAGNOSIS OF HEART FAILURE

**INTRODUCTION.** The prevalence of heart failure (HF) depends on the definition applied, but is approximately 1–2% of the adult population in developed countries, rising to  $\geq 10\%$  among people  $>70$  years of age.

**DEFINITION.** Heart failure is a clinical syndrome characterized by typical symptoms (e.g. breathlessness, ankle swelling and fatigue) that may be accompanied by signs (e.g. elevated jugular venous pressure, pulmonary crackles and peripheral oedema) caused by a structural and/or functional cardiac abnormality, resulting in a reduced cardiac output and/or elevated intracardiac pressures at rest or during stress.

**PATHOPHYSIOLOGY.** HF with a reduced ejection fraction (EF) appears when there is decreased left ventricular (LV) stroke volume. The pumping capacity of the heart on three interrelated factors:

- preload or venous return,
- myocardial contractility,
- afterload (impedance to forward flow).

Any condition that impairs one or more of these factors can produce heart failure. A number of compensatory mechanisms become activated in the presence of cardiac injury and/or LV dysfunction allowing patients to sustain and modulate LV function for a period of months to years.

The compensatory mechanisms include:

- activation of the renin-angiotensin-aldosterone (RAA) and adrenergic nervous systems, which are responsible, respectively, for maintaining cardiac output through increased retention of salt and water,
- increased myocardial contractility.

There is an activation of vasodilatory molecules, including the atrial and brain natriuretic peptides (ANP and BNP), prostaglandins (PGE and PGI), and nitric oxide (NO), that counterpoise the excessive peripheral vascular vasoconstriction. Before clinical symptoms become apparent, patients can present with asymptomatic structural or functional cardiac abnormalities (systolic or diastolic LV dysfunction) which are precursors of HF.

**The list of clinical syndromes for the differential diagnosis of heart failure based on left ventricle ejection fraction (LVEF) includes:**

1. normal LVEF [typically considered as  $\geq 50\%$ ; HF with preserved EF (HFpEF)] ;

2. reduced LVEF [typically considered as <40%; HF with reduced EF (HFrEF)];
3. mid-range LVEF [typically considered as 40–49% represent a ‘grey area’; HF with mid-range EF (HFmrEF)].

1. Patients with **HFpEF** do not have a dilated LV, increase in LV wall thickness and/or increased left atrial (LA) size as a sign of increased filling pressures. Patients have an additional ‘evidence’ of impaired LV filling or suction capacity (diastolic dysfunction), which is generally considered as the likely cause of HF in these patients (hence the term ‘diastolic HF’).

**Diastolic dysfunction** is characterized by an inability of one or both ventricles to fill normally with blood. The mechanisms include: alterations in ventricular-arterial coupling, impaired hemodynamic response to exercise, elevated blood pressure during the episode of increased filling pressure. The findings are: obesity, lack of tachycardia, older age, normal radiographic heart size, normal LVEF, S4 (stiff ventricle). The causes include: hypertension, valvular (aortic stenosis), cardiomyopathy (restrictive, hypertrophic), presence of the metabolic syndrome and pericardial disease. Other comorbidities associated in HFPEF include atrial fibrillation (AF), sleep apnea, chronic obstructive pulmonary disease, renal dysfunction, alcohol, inherited, dyslipidemia, systemic inflammatory diseases, such as rheumatoid arthritis, and certain medications, including antineoplastic agents, amyloidosis, sarcoidosis, hemochromatosis, hypo- or hyperthyroidism.

2. Patients with **HFrEF** (previously referred to as ‘systolic HF’) also have diastolic dysfunction, and abnormalities of systolic function have been shown. Hence the preference for stating preserved or reduced LVEF over preserved or reduced ‘systolic function’. The mechanisms of **systolic dysfunction** include decreased contractility and increased afterload. In patients with systolic dysfunction, the heart is unable to contract normally, leading to exercise intolerance and decreased peripheral blood flow. The findings are: dyspnea, previous infarction, edema and increased jugular venous pressure, and abnormal apical impulse (especially if sustained), tachycardia, decreased blood pressure or pulse pressure, S3, rales, radiograph (cardiomegaly, redistribution), anterior Q waves, LBBB, LVEF <45% (dilated ventricle with volume overload). The causes include MI, cardiomyopathy (dilated, infiltrative), valvular (aortic stenosis, aortic regurgitation, mitral regurgitation), arterial hypertension and myocarditis.

3. Patients with **HFmrEF** have primarily mild systolic dysfunction with features of diastolic dysfunction. Compared with HFrEF, the patients with

HFpEF are older, more often women and more commonly have a history of hypertension and atrial fibrillation (AF), with less common history of myocardial infarction. The characteristics of patients with HFmrEF are between those with HFrEF and HFpEF.

**LV diastolic dysfunction** is thought to be the underlying pathophysiological abnormality in patients with **HFpEF** and perhaps **HFmrEF**, and additional extracardiac mechanisms, such as increased vascular stiffness, impaired renal function and others.

**The list of common pathophysiological causes for the differential diagnosis of chronic heart failure includes:**

**1. Impaired contractility**

- myocardial ischemia, coronary heart disease
- cardiomyopathies (e. g., dilatative, drug-induced)
- myocarditis

**2. Cardiac arrhythmias**

- tachycardic arrhythmias
- bradycardic arrhythmias (e. g., AV block, sick sinus syndrome)

**3. Pressure overload**

- arterial and pulmonary hypertension
- aortic stenosis
- pulmonic stenosis

**4. Volume overload**

- mitral, tricuspid and aortic insufficiency
- pulmonary insufficiency
- shunt defects (atrial, ventricular)
- increased peripheral demand (high output failure)

**5. Impaired filling**

- mitral and tricuspid stenosis
- tumors (e. g., atrial myxoma)
- pericardial tamponade, constrictive pericarditis
- hypertrophic cardiomyopathy
- restrictive cardiomyopathy (e. g., myocardial fibrosis, amyloidosis, sarcoidosis, Fabry disease)

**The list of clinical syndromes for the differential diagnosis of chronic heart failure:**

- **Asymptomatic LV systolic dysfunction** – the absence of the typical symptoms and/or signs of HF and with a reduced LVEF;
- **Chronic HF** – the presence of typical symptoms and signs of HF for some time;

- **Stable HF** – unchanged symptoms and signs of HF for at least 1 month;
- **Decompensated chronic HF**– deteriorated symptoms and signs of HF;
- **Advanced HF** – severe symptoms, recurrent decompensation and severe cardiac dysfunction;
- **Left ventricular failure.** Symptoms and signs of orthopnea, paroxysmal, nocturnal dyspnoea, bilateral pulmonary rales, left– sided S3, wheezes, tachypnea;
- **Right ventricular failure.** Symptoms and signs of jugular vein enlargement, right– sided S3, hepatomegaly, hepatojugular reflux, ascites, symptoms of intestinal congestion, bilateral peripheral edema;
- **Hypoperfusion.** Clinical symptoms and signs of hypoperfusion: sweaty and cold extremities, oliguria, confusion, dizziness, diminished peripheral pulse. Laboratory data: metabolic acidosis, increase serum levels of lactate and creatinine. Hypoperfusion is not synonymous with hypotension, but its often associated with hypotension.

**The list of grades of severity for the differential diagnosis of chronic heart failure (NYHA):**

- FC I – no symptoms with ordinary physical activity;
- FC II – mild symptoms with normal activity (walking >2 blocks or 1 flight of stairs) ;
- FC III – symptoms with minimal exertion;
- FC IV – symptoms at rest.

**The list of stages based on structural changes and symptoms for the differential diagnosis of chronic heart failure (ACCF/AHA):**

- Stage A – At high risk for HF but without structural heart disease or symptoms of HF;
- Stage B – Structural heart disease but without signs or symptoms of HF;
- Stage C – Structural heart disease with prior or current symptoms of HF;
- Stage D – Refractory HF requiring specialized interventions.

A variety of heart diseases and mechanisms can lead to heart failure.

The underlying cardiac causes are: **diseased myocardium**: coronary artery disease (CAD), toxic damage, immune-mediated and inflammatory damage, infiltration, metabolic derangements, genetic abnormalities; **abnormal loading conditions** and **arrhythmias**.



**Diagnosis of chronic HF** should first be evaluated based on the patient's prior clinical history [CAD, arterial hypertension, diuretic use], presenting symptoms (e.g. dyspnoea, orthopnoea), physical examination (e.g. bilateral edema, increased jugular venous pressure, displaced apical beat) and resting electrocardiogram (ECG).

**Natriuretic peptide diagnosis.** If at least one element is abnormal, plasma natriuretic peptides (NPs) should be measured, to identify those who need echocardiography (an echocardiogram is indicated if the NP level is above the exclusion threshold or if circulating NP levels cannot be assessed). Elevated NPs help establish an initial working diagnosis, identifying those who require further cardiac investigation; patients with values below the cut-point for the exclusion of important cardiac dysfunction do not require echocardiography. In addition to heart failure, BNP is also elevated with pulmonary embolism, pulmonary hypertension, left ventricle hypertrophy, acute coronary syndrome, atrial fibrillation, renal failure, overload, and sepsis.

**An abnormal ECG** suggests of the diagnosis of HF. Some abnormalities on the ECG provide information on aetiology (e.g. myocardial infarction, AF, pacing for bradycardia). HF is unlikely in patients presenting with a completely normal ECG.

**Transthoracic echocardiography**, that includes two-dimensional echocardiography, pulsed and continuous wave Doppler, colour flow Doppler, tissue Doppler contrast echocardiography and deformation imaging (strain and strain rate) is the elected method for the assessment of myocardial systolic and diastolic function of both left and right ventricles. For the assessment of LV EF the modified biplane Simpson's method is indicated. Pulsed and continuous wave Doppler, colour flow Doppler allow the estimation of haemodynamic data, based on the velocity time at the LV outflow tract area. Tissue Doppler contrast echocardiography and deformation imaging (strain and strain rate) may detect abnormalities in the preclinical stage.

Echocardiographic data in patients with **HFpEF/HFmrEF** may be: a left atrial volume index (LAVI)  $>34$  mL/m<sup>2</sup> or a left ventricular mass index (LVMI)  $\geq 115$  g/m<sup>2</sup> for males and  $\geq 95$  g/m<sup>2</sup> for females. Key functional alterations are an  $E/e' \geq 13$  and a mean  $e'$  septal and lateral wall  $<9$  cm/s. Other (indirect) echocardiographically derived measurements are longitudinal strain or tricuspid regurgitation velocity (TRV).

**A stress test** or invasively measured elevated LV filling pressure – in



case of uncertainty. A diastolic stress test can be performed with echocardiography, typically using a semi-supine bicycle ergometer exercise protocol with assessment of LV ( $E/e'$ ) and pulmonary artery pressures (TRV), systolic dysfunction (longitudinal strain), stroke volume and cardiac output changes with exercise. Different dynamic exercise protocols are available, with semi-supine bicycle ergometry and echocardiography at rest and sub-maximal exercise being used most often. Exercise-induced increases in  $E/e'$  beyond diagnostic cut-offs (i.e.  $>13$ ), and also other indirect measures of systolic and diastolic function, such as longitudinal strain or TRV, are used.

Alternatively, **invasive haemodynamics** at rest with assessment of filling pressures [pulmonary capillary wedge pressure (PCWP)  $\geq 15$  mmHg or left ventricular end diastolic pressure (LVEDP)  $\geq 16$  mmHg] followed by exercise haemodynamics if below these thresholds, with assessment of changes in filling pressures, pulmonary artery systolic pressure, stroke volume and cardiac output, can be performed.

**A chest X-ray** is useful in identifying an alternative, pulmonary explanation for a patient's symptoms and signs, i.e. pulmonary malignancy and interstitial pulmonary disease. For the diagnosis of asthma or chronic obstructive pulmonary disease (COPD), pulmonary function testing with spirometry is needed. The chest X-ray may, however, show pulmonary venous congestion or edema in a patient with HF in the acute setting. It is important to note that significant LV dysfunction may be present without cardiomegaly on the chest X-ray.

**Coronary angiography** should be considered in patients with HF and intermediate to high pre-test probability of CAD and the presence of ischaemia in non-invasive stress tests in order to establish the ischaemic aetiology and CAD severity. Coronary angiography is recommended in patients with HF and angina pectoris recalcitrant to medical therapy, provided the patient is otherwise suitable for coronary revascularization. Coronary angiography is also recommended in patients with a history of symptomatic ventricular arrhythmia or aborted cardiac arrest. Coronary angiography should be considered in patients with HF and intermediate to high pre-test probability of CAD and the presence of ischaemia in non-invasive stress tests in order to establish the ischaemic aetiology and CAD severity.

**Cardiac computer tomography (CT)** in patients with HF is as a non-invasive means to visualize the coronary anatomy in patients with HF with low intermediate pre-test probability of CAD or those with equivocal non-invasive stress tests in order to exclude the diagnosis of CAD.

**Cardiac magnetic resonance (CMR)** is acknowledged as the gold standard for the measurements of volumes, mass and EF of both the left and right ventricles. It is the best alternative cardiac imaging modality for patients with non-diagnostic echocardiographic studies (particularly for imaging of the right heart) and is the method of choice in patients with complex congenital heart diseases.

**Single-photon emission computed tomography and radionuclide ventriculography (SPECT)** may be useful in assessing ischaemia and myocardial viability. Gated SPECT can also yield information on ventricular volumes and function, but exposes the patient to ionizing radiation. 3,3-diphosphono-1,2-propanodicarboxylic acid (DPD) scintigraphy may be useful for the detection of transthyretin cardiac amyloidosis.

**Positron emission tomography (PET)** (alone or with CT) may be used to assess ischaemia and viability, but the flow tracers (N-13 ammonia or O-15 water) require an on-site cyclotron. Rubidium is an alternative tracer for ischaemia testing with PET, which can be produced locally at relatively low cost. Limited availability, radiation exposure and cost are the main limitations.

**Molecular genetic** analysis in patients with cardiomyopathies is recommended when the prevalence of detectable mutations is sufficiently high and consistent to justify routine targeted genetic screening.

## ACUTE HEART FAILURE (AHF)

**Definition.** AHF refers to rapid onset or worsening of symptoms and/or signs of HF. It is a life-threatening medical condition requiring urgent evaluation and treatment, typically leading to urgent hospital admission.

AHF may present as a first occurrence (*de novo*) or, more frequently, as a consequence of acute decompensation of chronic HF, and may be caused by primary cardiac dysfunction or precipitated by extrinsic factors: acute myocardial dysfunction (ischaemic, inflammatory or toxic), acute valve insufficiency or pericardial tamponade are among the most frequent acute primary cardiac causes of AHF. Decompensation of chronic HF can occur without known precipitant factors, but more often with one or more factors, such as infection, uncontrolled hypertension, rhythm disturbances or non-adherence with drugs/diet.

**Diagnosis of AHF:** history of assessing symptoms, prior cardiovascular history and potential cardiac and non-cardiac precipitants, as well as on the assessment of signs/symptoms of congestion and/or hypoperfusion

by physical examination and further confirmed by appropriate additional investigations such as ECG (rapid atrial fibrillation, acute myocardial ischaemia), chest X-ray (pulmonary venous congestion, pleural effusion, interstitial or alveolar oedema and cardiomegaly), immediate echocardiography (mechanical complications, acute valvular regurgitation, aortic dissection) and laboratory assessment with specific biomarkers. Laboratory tests should include: a plasma NP level (BNP, NT-proBNP), cardiac troponin, blood urea nitrogen (BUN) (or urea), creatinine, electrolytes (sodium, potassium), liver function tests, thyroid-stimulating hormone (TSH), glucose and complete blood count; D-dimer is indicated in patients with a suspicion of acute pulmonary embolism. Arterial blood gas may be useful when a precise measurement of O<sub>2</sub> and CO<sub>2</sub> partial pressures is needed.

Acute heart failure may be caused by an acute pressure or volume overload on the systemic or pulmonary circulation, impaired cardiac filling, an acute decrease in myocardial contractility, or cardiac arrhythmias.

**The list of clinical syndromes for the differential diagnosis of acute heart failure:**

1. Acute decompensation of chronic heart failure;
2. Cardiogenic shock;
3. Acute coronary syndrome and heart failure;
4. Pulmonary edema;
5. Hypertensive AHF;
6. HF through increased cardiac output;
7. Right heart failure.

**1. Acute decompensation of chronic heart failure.** The common symptoms and signs are: dyspnea, orthopnea, weight gain due to a volume overload and increased peripheral edema. The most frequent causes of cardiac decompensation are a new myocardial ischemia or arrhythmia, systemic infection, discontinuation of chronic medication, or adding medications that may cause decompensation due to fluid retention (e. g., non-steroid anti-inflammatory drugs, steroids), use of medications that have a negative inotropic effect (calcium channel blockers or alcohol), refracterity to oral therapies, poorly controlled hypertension, anemia, hyperthyroidism. The leading cause, myocardial ischemia or pulmonary embolism should first be confirmed or excluded by ECG and enzyme assays.

**The list of diseases for the differential diagnosis of acute decompensation of heart failure includes:**

**Cardiac causes** (see Chapters Differential diagnosis of Chest pain, Pericardial diseases, Cardiac arrhythmias):

- Myocardial (coronary artery disease, toxic damage, immune-mediated and inflammatory damage, infiltration, metabolic derangements, genetic abnormalities);
- Pericardial (Cardiac tamponade);
- Arrhythmia;
- Valvular (aortic stenosis, acute aortic regurgitation, mitral regurgitation/stenosis, endocarditis).

#### B. Non-cardiac causes:

**Respiratory diseases** (see Chapters Differential diagnosis of Broncho-obstructive syndrome, Pulmonary consolidation, Diffuse interstitial pneumopathies, Allergic diseases):

- Airway—chronic obstructive pulmonary disease exacerbation, asthma exacerbation, acute bronchitis, bronchiectasis, foreign body obstruction;
- Parenchymal: pneumonia, cryptogenic organizing pneumonia, acute respiratory distress syndrome, interstitial lung disease exacerbation;
- Pleural: pneumothorax, pleural effusion;
- Vascular: pulmonary embolism, pulmonary hypertension.

**Systemic:** sepsis, metabolic acidosis, anemia, neuromuscular.

**Psychogenic:** anxiety.

**2. Cardiogenic shock** is defined as the evidence of inadequate tissue perfusion, after appropriate correction of prelude and severe rhythm disorders. Signs of tissue hypoperfusion and pulmonary congestion are rapidly developing. Cardiogenic shock is usually characterized by low blood pressure (SBP < 90 mm Hg or a decrease in mean blood pressure > 30 mm Hg) and/or low urinary flow rate (<0.5 ml/kg/h). The development of cardiogenic shock is associated with evidences of sympathetic nervous system activation with peripheral vasoconstriction (cold extremities) and signs of inadequate organ perfusion, reduced blood pressure, tachycardia, oliguria, anuria, coma, metabolic acidosis and urine output less than 20 mL/hour.

**The list of diseases for the differential diagnosis of cardiogenic shock includes:**

**Cardiac causes** (see Differential diagnosis of chest pain, Differential diagnosis of pericardial diseases, Differential diagnosis of non-ischemic cardiomyopathies):

- Acute coronary syndrome;
- Valvular insufficiencies;
- Dilated cardiomyopathy;

- Restrictive cardiomyopathy;
- Pericarditis and cardiac tamponade;
- Papillary muscle rupture;
- Acute valvular dysfunction.

**Non-cardiac causes** (see Differential diagnosis of pulmonary consolidation):

- Systemic inflammatory response syndrome
- Hypovolemic shock
- Septic shock

**Less frequent causes of circulatory shock are** (see Differential diagnosis of allergic diseases):

- anaphylaxis
- drug overdose
- Addison crisis
- myxedema.

**3. Acute coronary syndrome and heart failure.** The most frequent cause of cardiogenic shock is ACS with left ventricular pump failure that complicates approximately 5% of all myocardial infarctions. Approximately 1-3% of acute MIs are associated with ventricular septal rupture. Most septal ruptures occur within the week following MI. Patients with left ventricular pump failure or papillary muscle rupture present initially with holosystolic murmur and left parasternal thrill, dyspnea, pulmonary edema, tachycardia and hypotension. Patients with a predominantly right ventricular infarction or ruptured ventricular septum present initially with signs of low cardiac output and right-sided heart failure. Doppler ECG findings: a left-to-right intracardiac shunt.

**Valvular insufficiencies** are the most common diseases leading to cardiogenic shock. Severe mitral insufficiency may result from a partial or complete chordae tendineae rupture due to a myxomatous mitral valve or infectious endocarditis. Acute aortic insufficiency may develop as a consequence of endocarditis or an aortic dissection. In patients with a prosthetic heart valve, valvular dysfunction is assumed to be the cause of cardiogenic shock until proven otherwise. The decompensation of severe aortic stenosis or mitral stenosis or the mechanical obstruction of ventricular filling by an atrial myxoma are other potential causes of cardiogenic shock.

### **Non-cardiogenic shock**

**Systemic inflammatory response syndrome** is a clinical response to ischemia, inflammation, trauma and infection. The common symptoms and

signs are: fever of more than 38°C or less than 36°C (96.8°F), heart rate of more than 90 beats per minute, respiratory rate of more than 20 breaths per minute or arterial carbon dioxide tension ( $\text{PaCO}_2$ ) of less than 32 mm Hg and abnormal white blood cell count ( $>12,000/\mu\text{L}$  or  $<4,000/\mu\text{L}$  or  $>10\%$  immature forms).

**Hypovolemic shock** following the trauma, burns, bone fractures, and copious diarrhea or vomiting is generally easy to recognize, based on the associated conditions. If hypovolemic shock is suspected but there are no external signs of bleeding, the patient should be examined for intestinal bleeding or other internal hemorrhage.

**Septic shock** is most commonly caused by infection with Gram-negative bacteria. The examination often reveals a warm periphery, hematologic signs of infection, and metabolic acidosis, suggesting the correct diagnosis.

It is important to consider that the pumping ability of the heart may be impaired to some degree, even in noncardiogenic shock. This is probably due to the release of cytokines (such as  $\text{TNF-}\alpha$ ), NO or endotoxins.

**4. Pulmonary edema** is a life-threatening event in patients with left ventricular heart failure. Pulmonary edema develops when fluid extravasation outstrips the reabsorption by the capillaries and exceeds the drainage capacity of the lymphatics. The rate of fluid reabsorption is determined by the intravascular and interstitial oncotic pressure. The normal pulmonary capillary pressure is 8-12 mmHg, and the normal oncotic pressure of the plasma is approximately 25 mmHg. This pressure differential ensures the complete reabsorption of the fluid. When the hydrostatic intravascular (pulmonary capillary) pressure rises and approaches 18-25 mmHg, interstitial edema occurs initially, and alveolar edema develops at higher pressures. Pulmonary edema may also result from the damage to the alveolar capillary membrane or from a fall in the oncotic pressure. Insufficient lymphatic drainage is rarely a cause of pulmonary edema. The typical symptoms are the development of very severe dyspnea and a cough productive of frothy white, pink, or blood tinged sputum. Other common features are cold sweats, pallor, and cyanosis. Auscultation of the chest reveals coarse, moist bubbling rales and wheezing. The lung sounds make cardiac auscultation difficult, but it may be possible to hear the third heart sound and a prominent second heart sound (increased pulmonic component).

Laboratory tests can provide the evidence of an infection, electrolyte disorders, possible renal failure, and hypoproteinemia. A blood gas analysis is important in assessing the extent of hypoxemia. Echocardiography

and right heart catheterization will usually make it possible to confirm or exclude a cardiac cause of pulmonary edema. Right heart catheterization, usually with a Swan-Ganz balloon-tipped catheter, can measure the pulmonary capillary wedge pressure in order to determine whether the edema stems from an elevated pulmonary venous pressure, which would most likely indicate a cardiac cause. Oximetry and pressure measurements in all cardiac chambers also make it possible to detect a specific cardiac cause.

**The list of diseases for the differential diagnosis of pulmonary edema includes:**

- Acute mitral regurgitation
- Noncardiogenic pulmonary edema
- High-altitude pulmonary edema
- Neurogenic pulmonary edema
- Preeclampsia or eclampsia
- Heroin overdose
- General anesthesia

**Acute mitral regurgitation** is associated with inferior myocardial infarction of the papillary muscle and posteromedial papillary muscle is involved more frequently than anterolateral muscle. It is recognized by holosystolic regurgitant murmur of mitral insufficiency. The murmur may be absent if papillary muscle rupture has occurred, creating a condition known as „silent mitral insufficiency.” Acute mitral insufficiency usually happens 2-7 days after acute myocardial infarction. Echocardiography findings shows the malfunctioning mitral valve, and Doppler study – the severity of mitral regurgitation.

**Non-cardiac pulmonary edema** is caused by a number of viral, bacterial, and parasitic infections. Infectious lung edema is usually preceded by fever, cough, malaise, and gastrointestinal symptoms. The clinical features are similar to those with cardiogenic pulmonary edema, but there is no jugular venous distention and an S<sub>3</sub> gallop. Chest radiograph shows the infiltrates of more peripheral than perihilar distribution. Oximetry: large intrapulmonary shunt volume. Natriuretic peptide is negative. Pulmonary capillary wedge pressure is less than 18 mm Hg.

**High-altitude pulmonary edema** occurs in otherwise healthy, usually young individuals who ascend rapidly to an altitude of more than 2500 m and then engage in strenuous physical activity. The hypoxia-induced rise in pulmonary arterial pressures is an important pathogenic factor and genetic predisposition and immunological factors must play a role.



**Neurogenic pulmonary edema** occurs in a number of cerebral disorders (epilepsy, trauma, subarachnoid hemorrhage). It is assumed that central stimulation of the sympathetic nervous system causes a redistribution of blood flow from the systemic to the pulmonary circulation, leading secondarily to a rise in the pulmonary capillary pressure.

**Pulmonary edema in a setting of preeclampsia or eclampsia** is found in approximately 3% of eclampsia women. It is more common in older multiparous women with preexisting hypertension.

**Pulmonary edema after a heroin overdose** is a result of membrane injury. Other narcotics that may cause pulmonary edema are methadone, morphine, cocaine, and dextropropoxyphene.

**Pulmonary edema after general anesthesia** may be a side effect of the anesthetic agents, but is more likely due to other causes such as laryngospasm, hypoxia, or a hyperadrenergic state.

**5. Hypertensive AHF:** Signs and symptoms of AHF are accompanied by high blood pressure and preserved LV function in the presence of signs of increased sympathetic tone tachycardia and vasoconstriction.

**6. HF through increased cardiac output** usually develops with increased heart rate (in arrhythmias, thyrotoxicosis, anemia, Paget's disease, iatrogenous or other mechanisms), with warm periphery, pulmonary congestion, and changes in blood pressure.

**7. Right heart failure** is characterized by low cardiac output syndrome, increased jugular vein pressure, hepatomegaly, hypotension and lack of lung congestion, abdominal syndrome with nausea, vomiting, right-sided abdominal pain (as a sign of liver congestion), bloating, anorexia, and significant weight loss. In advanced cases, patients can appear jaundiced because of cardiac cirrhosis. Constipation is a common complaint among patients with heart failure, and it can be a manifestation of decreased intestinal transit secondary to poor perfusion.

**The list of diseases for the differential diagnosis of right heart failure includes** the following causes (see Chapters Differential diagnosis of Hepatomegaly, Nephrotic syndrome, Pericardial diseases, Non-ischemic cardiomyopathies):

- Liver cirrhosis
- Nephrotic syndrome
- Pericardial disease
- Right ventricular infarction
- Pulmonary hypertension



- Myocarditis
- Non-ischemic cardiomyopathies

**Liver cirrhosis:** causes jaundice, fatigue, nausea, peripheral oedema, ascites, bruising and prolonged bleeding, gynaecomastia, and haematemesis. Liver functional tests are abnormal. Ultrasound may detect ascites and liver abnormalities. Liver biopsy shows characteristic cirrhotic changes and may reveal the underlying cause.

**Nephrotic syndrome:** typically causes peripheral oedema, fatigue, dyspnoea, and loss of appetite. Urinalysis shows proteinuria: >3.5 g protein in twenty-four-hour urine collection and serum albumin is reduced. Serum urea and creatinine clearance may be abnormal in later stages. Serum cholesterol and triglyceride levels may be raised. Kidney ultrasound and biopsy may reveal the underlying cause.

**Pericardial disease:** may present with chest pain, typically worse on lying down, swallowing or coughing, tachycardia, dyspnoea, cough, oedema, fatigue, and low-grade fever. Pericardial friction rub may be heard at the left sternal border or apex. ECG may show electrical alternans or ST elevation and T wave flattening or inversion. Echocardiography may detect pericardial effusion, tamponade, and pericardial fibrosis. CT scan or MRI may show thickened pericardium.

**Right ventricular infarction.** The diagnosis is made by identifying an ST-segment elevation in the right precordial leads ( $V_3$  or  $V_4$  R) and/or typical hemodynamic findings after right heart catheterization. These are elevated right atrial and right ventricular end-diastolic pressures with normal to low pulmonary artery wedge pressure and low cardiac output.

**Pulmonary hypertension.** The causes of lung small arteries obstruction are: left heart disease, hereditary, hematological, lung disease, connective tissue and metabolic disease, drug-related, HIV infection and pulmonary capillary haemangiomas. The main symptoms include: chest pain, dyspnea, syncope. The clinical signs are: left parasternal lift, accentuated pulmonary component of second heart sound, systolic murmur of tricuspid regurgitation, diastolic murmur of pulmonary insufficiency, hepatomegaly, ascites and peripheral edema. ECG findings: right heart (atrium and ventricular) dilatation, T wave negative in the V1-V3 leads. Chest radiography data: enlarged right hilum, decrease in retrosternal air space, indicating right ventricular cardiomegaly. Echocardiography: right ventricular hypertrophy, right atria and ventricular dilatation, interventricular septal flattening, or a D-shaped LV. Right heart catheterisation: increase in mean pulmonary arterial pressure > 25 mmHg at rest.

**BIBLIOGRAPHY**

1. Braunwald's Heart Disease. A Textbook of Cardiovascular Medicine, 7th edition, edited by Douglas Zipes, Peter Libby, Robert Bonow, Eugene Braunwald: Heart Failure. Volume I, Chapters 19-26, 2005; p.457-652.
2. Crespo-Leiro M. G., et al. European Society of Cardiology Heart Failure Long-Term Registry (ESC-HFLT): 1-year follow-up outcomes and differences across regions. *European Journal of Heart Failure* (2016) 18, 6 13–625.
1. Jawad A., Heresi G., Tonelli A., et al. Pulmonary arterial hypertension. Cleveland Clinic. Center for Continuing Education |1950 Richmond Road, TR204, Lyndhurst, OH 44124. 2017. <http://www.clevelandclinicmeded.com/medical-pubs>, (accessed 20.01.2018).
2. Eberli F.R. Chronic Heart Failure. In: Siegenthaler W. With contributions by Aeschlimann A., Baechli E., Bassetti C. et al. *Differential diagnosis in internal medicine from symptom to diagnosis*. 2007, Georg Thieme Verlag, 1104 pps.
3. Kasper D., Hauser S., Fauci A. et al. Disorders of the heart. In: *Harrison's principles of internal medicine*. 19<sup>th</sup> edition. McGraw-Hi11 Professional's Media-Center. 2015. 2758 pps.
4. Kuehn S. Heart failure. In: Schmitz P., Miller M. K. *Internal Medicine Just the Facts*. The McGraw-Hill Companies. 2008.10pps.
5. McMurray J., Adamopoulos S., Anker SD., et al. ESC Guidelines for the diagnosis and treatment of acute and chronic heart failure 2012: The Task Force for the Diagnosis and Treatment of Acute and Chronic Heart Failure 2012 of the European Society of Cardiology. Developed in collaboration with the Heart. *Eur J Heart Fail*. 2012; 14: 803– 869.
6. Miksad R., Delamora P., Meyer G., et al. *Last Minute Internal medicine*. 2008. The McGraw-Hill Companies. 535 pps.
7. Peyster E., Norman J., Domanski M., et al. Prevalence and predictors of heart failure with preserved systolic function: community hospital admissions of a racially and gender diverse elderly population. *J Card Fail* 2004; 10: 49– 54.
8. Physician Consortium for Performance Improvement. ACC/AHA Clinical Performance Measures for Adults with Heart Failure. Tools Developed by Physicians for Physicians. 2005. American Medical Association. <http://www.americanheart.org> (accessed 20.01.2018).
9. Ponikowski P., Voors A., Anker S., et al. 2016 ESC Guidelines for the diagnosis and treatment of acute and chronic heart failure: The Task Force for the diagnosis and treatment of acute and chronic heart failure of the European Society of Cardiology (ESC) Developed with the special contribution of the Heart Failure Association (HFA) of the ESC. *Eur Heart J* 2016; 37(27): 2129–2200. DOI: <https://doi.org/10.1093/eurheartj/ehw128>. (accessed 20.01.2018).
10. Yancy C., Jessup M., Bozkurt B., et al. 2013 ACCF/AHA Guideline for the Management of Heart Failure A Report of the American College of Cardiol-

ogy/American Heart Association Task Force on Clinical Practice Guidelines. *Circulation*. 2013; 128: 1810-1852.

11. Yancy C., Jessup M., Bozkurt B., et al. 2017 ACC/AHA/HFSA Heart Failure Focused Update 2017 ACC/AHA/HFSA Focused Update of the 2013 ACCF/AHA Guideline for the Management of Heart Failure A Report of the American College of Cardiology/American Heart Association Task Force on Clinical Practice Guidelines and the Heart Failure Society of America Developed in Collaboration With the American Academy of Family Physicians, American College of Chest Physicians, and International Society for Heart and Lung Transplantation. *Circulation*, 2017; 136: e137-e16.
12. [www.clinmedjournals.org/articles/ijccem](http://www.clinmedjournals.org/articles/ijccem) (accessed 20.01.2018).

# DIFFERENTIAL DIAGNOSIS OF ARTERIAL HYPERTENSION

**INTRODUCTION.** The prevalence of hypertension in different countries appears to be around 30–45% of the general population, with a steep increase with ageing. There also appear to be noticeable differences in the average BP levels across countries, with no systematic trends towards BP changes in the past decade.

**DEFINITION.** According to 2017 ACC /AHA /AAPA /ABC /ACPM /AGS /APhA /ASH/ASPC/NMA/PCNA Guideline for the Prevention, Detection, Evaluation, and Management of High Blood Pressure in Adults, arterial hypertension is defined as values  $\geq 130$  mmHg systolic blood pressure (SBP) and/or  $\geq 80$  mmHg diastolic blood pressure (DBP), based on the evidence from Randomized Controlled Trials that in patients with these BP values treatment-induced BP reductions are beneficial.

## **CLASSIFICATION of office BP levels (mmHg):**

1. Normal SBP/ DBP  $< 120 / < 80$  mmHg
2. Elevated SBP/ DBP 120-129 /  $< 80$  mmHg
3. Hypertension Stage 1 – SBP/ DBP 130-139 / 80-89 mmHg
4. Hypertension Stage 2 – SBP/ DBP  $\geq 140 / \geq 90$  mmHg.

## **Categories of BP in adults**

- „White coat” hypertension – the presence of elevated BP ( $\geq 135/85$  mmHg) levels at medical institutions (as a conditional response to the unusual situation), but normal BP levels during self-measurements,
- ‘White-coat-’ or ‘isolated office-’ or ‘isolated clinic hypertension’ – the presence of elevated BP in the office at repeated visits and normal out of the office,
- ‘Masked-’ or ‘isolated ambulatory hypertension’ – the presence of normal BP in the office and abnormally high (BP  $\geq 130/80$  mmHg) out of the medical environment.

## **Classification of arterial hypertension by aetiology:**

**I. PRIMARY OR ESSENTIAL HYPERTENSION** refers to hypertension without demonstrable cause. It accounts for 95% of all cases of hypertension and is a diagnosis of exclusion.

**II. SECONDARY HYPERTENSION** has a clearly determined pathophysiology.

## I. PRIMARY (ESSENTIAL) HYPERTENSION

**Pathophysiology.** Primary hypertension is present in more than 90 % of patients with hypertension. The underlying pathology is unknown. There are, however, several hereditary forms of hypertension (e.g., cellular ion channel defects) and acquired forms (e.g., obesity and high sodium intake) that contribute, at least in part, to the development of hypertension.

**Diagnosis of hypertension.** Primary analysis that includes recognition of secondary forms of hypertension and risk assessment is recommended for patients with confirmed elevated blood pressure levels, either by repetitive measurements at primary care facilities or during ambulatory blood pressure monitoring.

Most patients with primary hypertension have no symptoms. Some patients complain of unspecific symptoms, such as headache, dizziness, impaired vision, or dyspnea.

The symptoms and signs of organ damage include:

- cerebrovascular system: transient ischemic attack, ischemic stroke, hemorrhagic stroke; motor or sensory defects;
- retina: fundulosopic abnormalities;
- heart: angina pectoris, myocardial infarction, congestive heart failure; 3rd or 4th heart sound, heart murmurs, arrhythmias, location of apical impulse, pulmonary rales, peripheral oedema;
- kidneys: nephrosclerosis with proteinuria and renal failure;
- peripheral vasculature: atherosclerotic stenosis and occlusion, absence, reduction, or asymmetry of pulses, cold extremities, ischemic skin lesions;
- carotid arteries: systolic murmurs;
- evidence of obesity ( $BMI \geq 30$ ).

**Risk assessment** is essential for the evaluation of indication for treatment and treatment goals. The recommendations on prevention of coronary heart disease (CHD) in clinical practice should be related to quantification of total cardiovascular (CV) risk. The concept is based on the fact that only a small fraction of the hypertensive population has an elevation of BP alone, with the majority exhibiting additional CV risk factors. When concomitantly present, and other CV risk factors may potentiate each other, leading to a total CV risk that is greater than the sum of its individual components. Although the relative risk of incident CVD associated with higher SBP and DBP is smaller at older ages, the corresponding high

BP-related increase in absolute risk is larger in older persons ( $\geq 65$  years) given the higher absolute risk of CVD at an older age.

## II. SECONDARY HYPERTENSION

The rate of secondary forms of hypertension ranges between 4 and 8% in different patient populations (primary care, secondary care clinics or specialized cardiovascular centers).

**DIFFERENTIAL DIAGNOSIS OF SECONDARY HYPERTENSION** includes:

1. renal disease,
2. endocrine,
3. cardiovascular,
4. neurogenic,
5. pregnancy,
6. toxic agent-induced and drug-induced hypertension
7. obstructive sleep apnea.

The list of causes of **renal hypertension** includes:

- acute and chronic glomerulonephritis;
- chronic interstitial nephritis;
- cystic kidney disease;
- diabetic nephropathy;
- collagen-vascular disorders;
- congenital hypoplasia;
- vesicoureteral reflux;
- unilateral hydronephrosis;
- postradiation nephritis;
- renovascular disease (unilateral or bilateral);
- atherosclerotic renal artery stenosis;
- fibromuscular dysplasia;
- renin-producing tumor;
- kidney transplantation.

The list of causes of **endocrine hypertension** includes:

- mineralocorticoid hypertension;
- Cushing syndrome;
- pheochromocytoma;
- hyperthyroidism;
- hypothyroidism;
- primary hyperparathyroidism;

- acromegaly;
- neuroendocrine tumor (carcinoid).

The list of causes of **cardiovascular hypertension** includes:

- aortic sclerosis;
- coarctation of the aorta;
- aortic regurgitation;
- complete atrioventricular block.

The list of causes of **neurogenic hypertension** includes:

- increased intracranial pressure;
- sleep apnea syndrome;
- acute porphyria;
- lead intoxication.

The list of categories of **hypertension in pregnancy** includes:

- chronic hypertension;
- preeclampsia-eclampsia;
- preeclampsia superimposed on chronic hypertension;
- gestational hypertension.

The list of **toxic agent-induced and drug-induced hypertension** includes:

- contraceptives;
- nonsteroidal antiinflammatory drugs;
- sympathicomimetics;
- erythropoietin;
- cyclosporine;
- alcohol;
- amphetamine;
- cocaine;
- anabolic steroids.

**Diagnosis. Secondary hypertension** forms can be suspected or diagnosed by accurate evaluation of the history, clinical examination, and routine laboratory tests.

**The medical history** should include the information about the family history of:

- kidney disease CKD (polycystic kidney);
- urinary tract infection, haematuria;
- analgesic abuse (parenchymal renal disease);
- drug/substance intake, e.g. gluco- and mineralocorticosteroids, non-steroidal anti-inflammatory drugs, oral contraceptives, liquo-

- rice, carbenoxolone, vasoconstrictive nasal drops, cocaine, amphetamines, erythropoietin, cyclosporine;
- repetitive episodes of sweating, headache, anxiety, palpitations (pheochromocytoma);
  - episodes of muscle weakness and tetany (hyperaldosteronism);
  - symptoms suggestive of thyroid disease;
  - snoring, sleep apnoea (information also from partner).

**Signs suggesting secondary hypertension**

- Features of Cushing syndrome;
- Skin stigmata of neurofibromatosis (pheochromocytoma);
- Palpation of enlarged kidneys (polycystic kidney);
- Auscultation of abdominal murmurs (renovascular hypertension);
- Auscultation of precordial or chest murmurs (aortic coarctation, aortic disease, upper extremity artery disease);
- Diminished and delayed femoral pulses and reduced femoral blood pressure compared to simultaneous arm BP (aortic coarctation, aortic disease, lower extremity artery disease);
- Left–right arm BP difference (aortic coarctation, subclavian artery stenosis).

**Laboratory tests** should include:

**Routine tests:**

- Haemoglobin and haematocrit;
- Fasting plasma glucose;
- Serum total cholesterol, low-density lipoprotein cholesterol, high-density lipoprotein cholesterol, fasting serum triglycerides;
- Serum potassium and sodium;
- Serum uric acid;
- Serum creatinine (with estimation of glomerular filtration rate -GFR);
- Urine analysis: microscopic examination, urinary protein by dipstick test;
- 12-lead ECG.

**Additional tests:**

- Haemoglobin A1c [(if fasting plasma glucose is >5.6 mmol/L (102 mg/dL) or previous diagnosis of diabetes];
- Quantitative proteinuria (if dipstick test is positive);
- Urinary potassium and sodium concentration and their ratio;
- Home and 24-h ambulatory BP monitoring;



- Echocardiogram;
- Holter monitoring in case of arrhythmias;
- Exercise testing;
- Carotid ultrasound;
- Peripheral artery/abdominal ultrasound;
- Pulse wave velocity;
- Ankle-brachial index;
- Fundoscopy.

### **1. Renal hypertension**

**Renal parenchymal disease** accounts for approximately 5% of hypertension cases.

The most common causes of secondary renal parenchymal hypertension are:

- Acute and chronic glomerulonephritis,
- Chronic interstitial nephritis,
- Cystic kidney disease,
- Diabetic nephropathy
- Polycystic kidney disease.

**Diagnosis.** Physical examination may reveal: abdominal masses (in case of polycystic kidney disease), oedema, or change in urine output. Laboratory investigations denote: the presence of protein, erythrocytes, or leucocytes in the urine, decreased glomerular filtration rate, high serum creatinine, chronic anaemia, abnormal urine analysis. First-line test: renal ultrasound may identify sclerotic or polycystic kidneys.

**Renovascular hypertension** is the most common, curable form but it accounts for less than 1% of hypertension cases.

The most common causes of secondary renovascular hypertension are:

- atherosclerotic renal artery stenosis,
- fibromuscular dysplasia.

The rare causes include:

- renal artery embolism,
- renal artery aneurysm,
- arteriovenous fistula,
- arteriitis,
- coarctation of the abdominal aorta,
- neurofibromatosis.

Hemodynamically significant stenosis is defined as a 70% diameter narrowing of the renal artery that results in significant reduction of renal blood

flow (70%), decreased intraglomerular pressure, activation of the renin-angiotensin system to increase BP, and decreased kidney size. Increases in plasma AII levels result in vasoconstriction and increase BP. A key role for angiotensin II (AII) is to maintain perfusion pressure within the intraglomerula through constriction of efferent arterioles and increases in systemic BP. Increases in intrarenal AII also cause transient sodium retention, through AII effects on proximal tubules, which culminates in pressure natriuresis secondary to increases in BP over time and reestablishes sodium balance. When stenosis is bilateral, the mechanism of hypertension is through volume expansion. Renal artery stenosis is often located at the origin of the renal artery from the abdominal aorta and in the proximal part of the artery.

Several findings from the medical history and clinical examination may raise the suspicion of renal artery stenosis: abdominal bruit may be present, acute or subacute onset of hypertension.

Atherosclerotic renal artery stenosis is more common in males and coincides with lesions of the aorta and iliac arteries. It is associated with hypertension of abrupt onset, worsening or increasingly difficult to treat.

Fibromuscular dysplasia is more common in younger women with early onset hypertension. The right renal artery is involved more often than the left renal artery, and typical lesions are found in the middle and distal parts of the renal artery. Angiographically, the „beaded string” sign helps to make the diagnosis. The typical angiographic appearance reflects dysplasia and proliferation of the fibromuscular components of the media. Discrete fibromuscular stenosis or long and smooth lesions are less common. Fibromuscular dysplasia is seen not only in the renal arteries but similarly in the carotid, mesenteric, or iliac arteries.

On renal duplex ultrasound or magnetic resonance angiogram of renal arteries the difference of  $>1.5$  cm in length between the two kidneys confirms the diagnosis. Color-coded Doppler ultrasound allows both localization and exact hemodynamic determination of the degree of stenosis. Multislice computed tomography angiography permits imaging of the renal arteries by means of intravenous injection of iodine contrast material and has a low interobserver variability. Magnetic resonance angiography is the imaging modality of choice for patients with severe renal failure because it requires no iodine contrast dye. Conventional angiography remains the „gold standard” for diagnosing or excluding renal artery stenosis.

## 2. Endocrine hypertension

**Primary aldosteronism (Conn syndrome)** prevalence varies from 1% to 11%, increases according to hypertension severity, and cross-sectional and prospective studies report primary aldosteronism in 10% of patients with hypertension, with approximately 70% caused by adrenal adenomas. The adenoma is usually unilateral and comprised of glomerulosa cells in the adrenal cortex. Rarely, primary aldosteronism is caused by adrenal carcinoma or hyperplasia. Adrenal hyperplasia is more prevalent among older men, and both adrenals are overactive without adenoma. The symptoms and signs: muscle weakness, family history of early onset hypertension and cerebrovascular events at old age, arrhythmias (in case of severe hypokalemia). Diagnosis is suspected in patients with hypertension with unprovoked hypokalemia confirmed by elevated plasma aldosterone levels and low plasma renin activity, aldosterone–renin ratio under standardized conditions (correction of hypokalemia and withdrawal of drugs affecting RAA system). Nuclear imaging of the adrenal glands is another option to localize excessive aldosterone production.

**Pheochromocytoma.** Approximately 15% of pheochromocytoma cases are familial, often they are bilateral, at multiple sites, and 10% of cases are malignant. Pheochromocytomas produce catecholamines and are usually localized in the adrenal medulla. In addition, catecholamine-producing tumors may origin from extra-adrenal chromaffin cells (paragangliomas), e. g., from the glomus caroticum, and in postganglionic sympathetic neurons (ganglioneuromas). On physical examination: skin stigmata of neurofibromatosis, blood pressure values may be continuously elevated. In one-third of the patients, typical paroxysmal hypertension or a crisis superimposed to sustained hypertension may occur. Typical symptoms include headaches, sweating, palpitations and pallor, positive family history of pheochromocytoma. In severe forms, proteinuria, retinopathy, or encephalopathy may occur. In addition, tremor, chest or abdominal pain, vomitus can accompany the crisis. Angina pectoris with or without ECG changes, myocardial infarction, pulmonary edema, or seizures may occur. Screening is performed by measuring urinary fractionated metanephrines or plasma-free metanephrines, incidental discovery of adrenal (or in some cases, extra-adrenal) masses. Imaging tests are required to localize the site of hormone production. Ultrasound may be used because tumors are often large. CT, however, is the routine imaging modality. MR imaging is advantageous because it helps in the differential diagnosis of adrenal tumors.

Nuclear imaging is helpful for identifying extra-adrenal tumors or metastases. MR imaging is helpful in excluding pheochromocytoma in patients with adenoma on CT scan.

**Cushing syndrome.** The cause of the Cushing syndrome or hypercortisolism is excessive adrenal production of glucocorticosteroids. Systemic arterial hypertension is found in 80% of patients with the endogenous Cushing syndrome. Excessive corticosteroid production may be due to increased pituitary or ectopic production of adrenocorticotrophic hormone (ACTH), or due to ACTH-independent, adrenal cortisol production. Classic symptoms and signs include rapid weight gain, polyuria, polydipsia, psychological disturbances, moon face, dorsicocervical fat pad, abdominal striae, and easy bruisability. In patients with typical symptoms, the diagnosis is confirmed by the measurement of substantially elevated levels of cortisol from 24-hour urine samples. Screening for endogenous hypercortisolism is especially useful in patients with typical signs, including typical redistribution of subcutaneous tissue, obvious padding in temporal and subclavicular depressions, as well as nuchally, skin atrophy, or muscle weakness. The measurement of free cortisol from a 24-hour urine sample is the „gold standard” for the diagnosis of Cushing syndrome. Screening may also be performed using dexamethasone suppression, which includes intake of 1 mg of dexamethasone at midnight and measurement of the serum cortisol level at 08:00 the next morning. In outpatients late-night salivary cortisol can be assessed at midnight. At midnight, cortisol levels are low in healthy, unstressed individuals.

**Acromegaly** is caused by excessive production of growth hormone in adults and is associated with hypertension in half of cases. Hypertension is more common among the elderly in whom small, slow-growing tumors are found. It is less common in younger patients who usually have developed symptoms more recently, and tumors often are large and fastgrowing. Psychosocial factors, such as stress or depression, may have an unfavorable effect on the cardiovascular system through increased release of catecholamines or glucocorticoids. The main signs are: acral enlargement in the face (supraorbital bulging, nose, chin), hands (digits, rings do not fit), and feet (increase in shoe size), subcutaneous swelling, visceromegaly, macroglossia, skin thickening, hyperhidrosis, arthropathy, neuropathy, carpal tunnel syndrome, snoring, sleep apnea, insulin resistance, hypertriglyceridemia, hyperglycemia (diabetes mellitus), cardiomegaly and cardiomyopathy (often associated with hypertension). The diagnosis is confirmed by ele-

vated levels of growth hormone and insulin-like growth factor 1. Growth hormone levels after oral glucose tolerance testing are used to confirm the diagnosis. If the clinical diagnosis of acromegaly is confirmed by laboratory testing, MRI reveals pituitary adenoma in most cases. In rare circumstances, acromegaly is caused by excessive hypothalamic or pancreatic production of growth hormone releasing factor.

### 3. Cardiovascular Hypertension

The common causes of **cardiovascular hypertension** include:

- aortic atherosclerosis;
- coarctation of the aorta.

**Aortic atherosclerosis.** Systolic hypertension of the elderly has cardiovascular origin. The aorta receives the pressure wave and the bolus of blood with less resilience, hence the systolic rise found in the brachial artery. This was thought to be a condition of aging that caused no damage; more recent studies have found an association with strokes and other hypertensive complications. Isolated systolic hypertension is also associated with an increased risk of cardiovascular events.

**Aortic coarctation** is a congenital, cardiovascular malformation and is classified depending on the localization of stenosis in relation to the ductus arteriosus: preductal form in infants and postductal form in adults. Hypertension is present in vascular regions that are localized proximally to the coarctation, and hypotension is present distally to the coarctation. Elevated blood pressure values (using an upper arm cuff) are found on the right arm if the origin of the left subclavian artery is involved in the coarctation. The clinical examination reveals the radial to femoral pulse delay, on bilateral pulse palpation, absent femoral pulses, and on auscultation: systolic or systolo-diastolic murmur that is interscapular and often left of the thoracic spinal column. The following imaging modalities are useful: chest radiograph: costal notching due to the presence of collaterals; occasional notching of the descending aorta and ECG: left ventricle hypertrophy, echocardiography, three-dimensional MR angiography.

**Aortic regurgitation and complete atrioventricular block** can cause increased cardiac output and hypertension. The diagnosis can be established clinically using the clinical examination, electrocardiogram, and echocardiography.

### 4. Hypertension in pregnancy

**Hypertension in pregnancy** is the most common medical problem encountered during pregnancy, complicating up to 10% of pregnancies.

Hypertensive disorders during pregnancy are classified into 4 categories, as recommended by the National High Blood Pressure Education Program Working Group on High Blood Pressure in Pregnancy:

- **Chronic hypertension:** blood pressure exceeding 140/90 mm Hg before pregnancy or before 20 weeks' gestation.
- **Preeclampsia-eclampsia:** new onset of elevated blood pressure readings after 20 weeks' gestation. Preeclampsia is defined as the presence of a systolic blood pressure (SBP) greater than or equal to 140 mm Hg or a diastolic blood pressure (DBP) greater than or equal to 90 mm Hg or higher, on two occasions at least 4 hours apart in a previously normotensive patient, an SBP greater than or equal to 160 mm Hg or a DBP greater than or equal to 110 mm Hg or higher. In addition to the blood pressure criteria, proteinuria of greater than or equal to 0.3 grams in a 24-hour urine specimen. American College of Obstetricians and Gynecologists has eliminated the dependence of the diagnosis on proteinuria in recognition of preeclampsia. In the absence of proteinuria, preeclampsia is diagnosed as hypertension in association with thrombocytopenia (platelet count less than 100,000/microliter), impaired liver function (elevated blood levels of liver transaminases to twice the normal concentration), the new development of renal insufficiency (elevated serum creatinine greater than 1.1 mg/dL or a doubling of serum creatinine in the absence of other renal disease), pulmonary edema, or new-onset cerebral or visual disturbances.
- **Preeclampsia superimposed on chronic hypertension** (or superimposed preeclampsia) is chronic hypertension in association with preeclampsia.
- **Gestational hypertension.** Detected after 20 weeks' gestation in a previously normotensive patient in the absence of proteinuria or the aforementioned systemic findings. Gestational hypertension goes away after delivery.

### 5. Toxic agent-induced and drug-induced hypertension

Several medications and toxic agents can induce hypertension through various mechanisms. A common scenario is hypertension induced by non-steroidal anti-inflammatory drugs (NSAIDs). NSAIDs can cause an increase in intravascular volume via inhibition of prostaglandin synthesis. Oral contraceptives can induce hypertension by stimulation of the renin-angiotensin-aldosterone system. Often, substitution of the NSAID

with another analgesic medication or introduction of an alternative form of contraception solves the problem. Toxic agents, including alcohol, amphetamines, and cocaine, can induce hypertension. The mechanism is sympathetic overactivation. Cocaine is particularly dangerous because it can induce profound hypertensive attacks and vasospasm that may cause myocardial infarction and stroke. There may be signs of acute intoxication, withdrawal, or cravings with cocaine or sympathomimetics use.

History of these patients may include treatment with or ingestion of non-steroidal anti-inflammatory drugs, oral contraceptive pills, sympathomimetics, herbal medications (e.g., black cohosh, capsicum, ma huang), liquorice, immunosuppressants (cyclosporin, tacrolimus), erythropoietin, higher dose steroids, or chemotherapeutic anti-endothelial growth factor agents (bevacizumab). Drug toxicology screen may detect an illicit substance.

### **6. Obstructive sleep apnea**

Approximately 30% of adults with hypertension have obstructive sleep apnea and its prevalence more than doubles for each 10-year increase in age in both sexes. Obstructive sleep apnea is associated with a high prevalence of isolated diastolic hypertension, and there is a significant association between the incidence of combined systolic and diastolic hypertension and obstructive sleep apnea. Typically obese patients complain of daytime somnolence, snoring, or choking during sleep. Polysomnography shows nocturnal oxygen desaturation.

## **BIBLIOGRAPHY**

1. Aronow W., Fleg J., Pepine C., et al. ACCF/AHA 2011 Expert Consensus Document on Hypertension in the Elderly. A Report of the American College of Cardiology Foundation Task Force on Clinical Expert Consensus Documents Developed in Collaboration With the American Academy of Neurology, American Geriatrics Society, American Society for Preventive Cardiology, American Society of Hypertension, American Society of Nephrology, Association of Black Cardiologists, and European Society of Hypertension. *Circulation*. 2011; 123: 2434-2506.
2. Kaplan N.M. *Kaplan's Clinical Hypertension*, 8th ed. Philadelphia: Lippincott Williams & Wilkins 2002.
3. Mann D., Zipes P., Libby P., Bonou R. *Braunwald's Heart disease: A Textbook of Cardiovascular Medicine*, 10<sup>th</sup> Edition. Saunders. 2015. 2040 pps.
4. Mancia G., Fagard R., Narkiewicz C., et al. 2013 ESH/ESC Guidelines for the management of arterial hypertension The Task Force for the management

- of arterial hypertension of the European Society of Hypertension (ESH) and of the European Society of Cardiology (ESC) Authors/Task Force Members: *European Heart Journal* 2013; 34: 2159–2219 doi:10.1093/eurheartj/ehh151
5. Kluwer W., Roberts J., Druzin M., August P., et al. American College of Obstetricians and Gynecologists, Task Force on Hypertension in pregnancy. Hypertension in pregnancy. Report of the American College of Obstetricians and Gynecologists. Task Force on Hypertension in pregnancy. *Obstet. Gynec.* 2013, 122(5): 1122-3.
  6. Greminger P., Schmid C., Wuethrich R. Systemic Arterial Hypotension. In: Siegenthaler W. With contributions by Aeschlimann A., Baechli E., Bassetti C. et al. *Differential diagnosis in internal medicine from symptom to diagnosis.* 2007, Georg Thieme Verlag, 1104pps.
  7. Whelton P., Carey R., Aronov W., et al. 2017ACC/AHA/AAPA/ABC/ACPM/AGS/ APhA/ASH/ASPC/NMA/PCNA Guideline for the Prevention, Detection, Evaluation, and Management of High Blood Pressure in Adults: A Report of the American College of Cardiology/American Heart Association Task Force on Clinical Practice Guidelines for the Prevention, Detection, Evaluation, and Management of High Blood Pressure in Adults. Hypertension. 2017 Nov 13. pii: HYP.0000000000000065. doi: 10.1161/HYP.0000000000000065.
  8. <https://journals.lww.com/jhypertension> (accessed 26.09.2018).



# DIFFERENTIAL DIAGNOSIS OF CARDIAC ARRHYTHMIAS

**INTRODUCTION.** The prevalence of supraventricular arrhythmias in the adults is 6 to 8 per 1000 of population. Arrhythmias may occur at any age, but are more common among older people. Female had a two-fold greater relative risk of supraventricular tachyarrhythmias compared to males. Atrial fibrillation affects about 2% to 3% of the population.

**DEFINITION.** Cardiac arrhythmias are abnormality or perturbation in the normal activation sequence of the myocardium.

**PATHOPHYSIOLOGY.** Cardiac arrhythmias result from abnormalities of electrical impulse formation, conduction, or both. Bradyarrhythmias typically arise from disturbances in impulse formation at the level of the sinoatrial node or from disturbances in impulse propagation at any level, including exit block from the sino-atrial node (SA), conduction block in the atrio-ventricular node (AVN) and impaired conduction in the His-Purkinje system.

The tachyarrhythmias mechanisms are:

- enhanced automaticity (spontaneous depolarization of atrial, junctional, or ventricular pacemakers);
- triggered arrhythmias (initiated by after depolarizations occurring during or immediate after cardiac repolarization, during phase 3 or 4 of the action potential);
- re-entry (circus propagation of a depolarizing wavefront).

In case of sinoatrial block sinus pauses and sinus arrest result from the failure of the SA node to discharge producing a pause without P waves visible on the ECG. Sinus pauses of up to 3 seconds are common in awake athletes and pauses of this duration or longer may be observed in asymptomatic elderly subjects. Intermittent failure of conduction from the SA node produces sinus exit block. Second-degree SA block will produce intermittent conduction from the SA node and a regularly irregular atrial rhythm. The function of the sinus node can be impaired (sick sinus syndrome) particularly in elderly patients. This is usually expressed by the absence of heart rate increase as a response to physical exercise (chronotropic incompetence), sinus node pauses of over 3 seconds, or a marked increase in beat to beat variation (over 15% of cycle length). A secondary sinus node dysfunction can result from hypothyroidism, drugs, electrolyte imbalances, sleep apnea

syndrome, after conversion of atrial fibrillation or flutter because of prolonged sinus node recovery time.

### CLASSIFICATION

1. **Arrhythmia classification by rate:** bradycardia < 60 bpm and tachycardia >100 bpm.
2. **Arrhythmia classification by site of origin:** supraventricular or ventricular.
  - a. **Supraventricular tachyarrhythmias (SVT):**
    - Premature supraventricular contractions (PSVC);
    - Atrioventricular nodal re-entrant tachycardia (AVNRT);
    - Atrioventricular re-entrant tachycardia (AVRT);
    - Atrial tachycardia (AT);
    - Multifocal atrial tachycardia (MAT);
    - Atrial fibrillation (AFb);
    - Atrial flutter (AF).
  - b. **Ventricular:**
    - Premature ventricular contraction (PVC);
    - Ventricular tachycardia (VT), ventricular fibrillation (VFb).
  - c. **Blocks:**
    - Sino-atrial (SA);
    - Atrio-ventricular (AV);
    - Bundle branch blocks (BBB).

### CLINICAL FEATURES

**Predisposing or precipitating factors for patients with palpitations** are: excessive caffeine, alcohol, nicotine intake, recreational drugs, antiarrhythmic, antidepressant, antibiotic drugs, stimulants, antihistamines, appetite suppressants, hyperthyroidism, electrolyte disturbance, anemia, fever, infection, lack of sleep, physical or mental stress.

**Signs and symptoms:** palpitations, angina pectoris, loss of consciousness or sudden cardiac death. Complaints such as light headedness, dyspnea, dizziness, and forceful or painful extra beats are commonly reported with various arrhythmias. More severe symptoms are more likely to occur in the presence of structural heart disease (e. g., myocardial infarction, cardiomyopathy). Premature beats are described as pauses or nonconducted beats followed by a sensation of a strong heartbeat, or as irregularities in heart rhythm.

Sinus tachycardia accelerates and terminates gradually. Paroxysmal supraventricular tachycardias have a sudden onset and a sudden end, and

are often accompanied by diuresis provoked by release of atrial natriuretic peptide. Termination by vagal maneuvers further suggests a re-entrant tachycardia involving AV nodal tissue (e.g., AVNRT, AVRT). In atrial tachycardia a gradual acceleration (warming up) and deceleration (cooling down) of the arrhythmia can be observed. Irregular palpitations may be due to premature depolarizations, AF, or MAT. Syncope in the presence of structural heart disease is a life-threatening condition.

**Family history.** The family history can reveal inherited causes of sudden cardiac death (long QT syndrome, Brugada syndrome, arrhythmogenic right ventricular cardiomyopathy, hypertrophic obstructive cardiomyopathy, etc.).

**Clinical examination.** In the arrhythmic patient counting the pulse can provide information of pulse deficit and hemodynamic relevance, the synchronicity of atrial and ventricular contraction. If the atrium and ventricle are not synchronized, as during VT, the first heart sound varies in intensity and character. A regular resting pulse with single pauses is a sign of extrasystoles leading to a compensatory pause, which are generally insignificant. The diagnosis of atrial fibrillation can be made if an absolute pulse arrhythmia is present, together with a pulse deficit (i. e., a higher pulse at heart auscultation than at palpation of the radial artery). Although VT are often fast and can lead to syncope, particularly in patients with structural heart disease, they can also be slower and hemodynamically well tolerated over hours and days. Conversely, supraventricular tachycardias, especially in patients with a normal heart, are usually better tolerated and may be terminated by the patient with coughing, pressure, or carotid sinus massage.

**Carotid sinus massage.** Gentle pressure on the carotid sinus in the middle of the neck, provokes vagotonic stimulation, which slows impulse frequency from the sinus and AV node. This has diagnostic significance and is also a therapeutic maneuver, which can stop an arrhythmia (e. g., during supraventricular tachycardia where the AV node is part of the reentrant circuit). Focal arrhythmias can be slowed (atrial tachycardia) or flutter waves unmasked by slowing conduction over the AV node. Carotid sinus massage should also be performed in syncopal patients to detect bradycardia-induced AV block, a dangerous condition with a poor prognosis.

### PARACLINICAL EXAMINATIONS

**A resting 12-lead electrocardiogram (ECG)** should be recorded and evaluated for the presence of abnormal rhythm, pre-excitation, prolonged QT interval, sinus tachycardia, segment abnormalities, or evidence

of underlying heart disease. The systematic analysis of the ECG begins with the analysis of the frequency of atrial (P waves) and ventricular (QRS complex) excitations and their relation. Then the size, width, and axis of P waves and QRS complexes should be analyzed. The repolarization phase (ST and T segments) and the presence of U waves can provide important information on the origin of arrhythmias. The duration of the longest QT interval should also be measured and corrected for the heart rate.

**Holter ECG.** Continuous ECG monitoring over 24 or 48 hours can diagnose intermittent (paroxysmal) arrhythmias, provided that symptomatic arrhythmia actually appears again during this time. The Holter ECG can give information about the function of the sinus node, detect pauses and the heart rate variability.

**Stress ECG.** A continuous ECG recording during physical exercise (treadmill, bicycle) can provoke stress-induced arrhythmias or provide important information about increased sinus node rates (chronotropic competence) and the conduction properties of accessory pathways (delta waves in Wolff-Parkinson-White [WPW] syndrome).

**An echocardiographic examination** should be considered in patients with documented sustained SVT to exclude the possibility of structural heart disease.

**Signal-averaged electrocardiogram and T wave alternans.** The presence of low-amplitude late potentials, indicating a positive signal-averaged ECG, suggests an underlying abnormality in ventricular repolarization seen with a discrete scar and can be associated with ventricular ectopy and spontaneous VT. T wave alternans may have an important role for risk stratification in patients with LV dysfunction and complex ventricular arrhythmias.

**Electrophysiological investigation.** The electrophysiologic study is an invasive procedure for the diagnosis of unclear arrhythmias and patients with syncope. It is also employed therapeutically for radiofrequency ablation treatment of supraventricular and ventricular arrhythmias (i. e., thermal ablation of the responsible focus or reentrant circuit). Electrophysiologic testing has become an important standard for identifying high-risk patients who have nonsustained VT or inducible, sustained, monomorphic VT as a predictor for sustained VT and ventricular fibrillation. Electrophysiologic testing is the gold standard for evaluating patients with recurrent syncope and can help identify underlying His-Purkinje disease, inducible VT, SVT, and sinus node dysfunction.

A **Tilt test**, which suddenly shifts the patient from a recumbent to an upright position, can provoke a neurocardiogenic syncope, which if correlated with the clinical symptoms, has diagnostic significance. Further analysis of ECG intervals can noninvasively identify patient groups at increased risk for arrhythmias or sudden death (e. g., heart rate variability as a measure of autonomic innervation, signal-averaged ECG, T-wave alternans, etc.).

### DIFFERENTIAL DIAGNOSIS OF EXTRASYSTOLES

**Extrasystoles** are single beats caused by abnormal impulse generation anywhere in the heart (atria, ventricles, conduction system). Extrasystoles are frequently observed in healthy hearts. In most patients extrasystoles are asymptomatic. Rarely, they can evoke disturbing symptoms such as palpitations, panic attacks, dyspnea, or hyperventilation.

**Supraventricular extrasystoles** originate in the atrium, in the atrial myocardium, or in the AV node. They manifest as an early P wave, which has a morphology corresponding to the origin of the focus (negative if lower atrial focus, biphasic if left atrial, etc.). The QRS complex can be normal or widened because of aberrancy. Frequently, the conduction of the supraventricular extrasystoles is blocked, so that a pause occurs, which is further extended by the subsequent sinus pause. Supraventricular extrasystoles have no prognostic significance but can induce sustained arrhythmias. The most frequent cause of pauses is supraventricular extrasystoles with physiologic block. The symptoms are caused by the pause rather than the extrasystole.

**Premature junctional complex (PJC)** occurs when an irritable site within the AV node fires an impulse before the SA node. This impulse interrupts the sinus rhythm. The QRS complex is narrow, usually measured at 0.10 sec or less.

**Ventricular extrasystoles** can be differentiated from supraventricular extrasystoles by the following: no preceding P wave (no constant PQ interval), different QRS morphology, width, and axis, altered repolarization (T wave opposite to QRS vector) and compensatory pause. Single ventricular extrasystoles have no proven prognostic value, especially in the absence of structural heart disease. They can occur as single beats, alternating with one normal sinus beat (bigeminy) or two sinus beats (trigeminy) or can occur in series of two (couplet) or three (triplet) beats. More than three ventricular extrasystoles in a row define nonsustained VT.

## DIFFERENTIAL DIAGNOSIS OF NARROW QRS-COMPLEX TACHYCARDIA

An **initial differentiation** of tachyarrhythmias is based on the duration of the QRS complex during the tachycardia. If QRS is narrow (less than 120 milliseconds [ms]), then the tachycardia is almost always supraventricular and the differential diagnosis relates to its mechanism.

### **Diagnostic maneuvers:**

- Vagal maneuvers (Valsalva, carotid massage);
- Intravenous adenosine with 12-lead ECG recording;
- Esophageal pill electrodes (if P waves are not visible).

**In sinus tachycardia** the morphology and axis of the P wave are similar to that observed during sinus rhythm. The rhythm typically speeds up and slows down gradually. Sinus tachycardia is a common finding and is typically secondary to other causes, such as heart failure, pain, pulmonary emboli, as well as central nervous system and other disturbances, which are associated with increased adrenergic stimulation. In addition, some drugs (e. g., antihypertensives) or withdrawal of some drugs (e. g., beta-blockers) may cause sinus tachycardia. Rarely, the sinus node may show a hypersensitive response to endogenous catecholamines, causing inappropriate sinus tachycardia. This is a diagnosis of exclusion when other possible causes for sinus tachycardia are eliminated and when the sinus node reacts very rapidly after minimal exercise (e. g., pulse 150 bpm after 10 knee bends).

**In atrial tachycardia (AT)** the atrial rate is usually 150-250 beats/min and the P wave morphology is different from that observed during sinus rhythm. The ECG derivation with a negative initial P wave suggests the origin of the tachycardia (V1 right atrium; aVL left atrium). Atrial tachycardia may show some irregularity and patients with this arrhythmia usually have atrial ectopic beats originating from the same focus with similar P-wave morphology.

Atrial tachycardia may be a sustained arrhythmia and may have a single or multiple origins. In the latter case, the so-called MAT, there are often secondary causes, and the atria are often dilated due to pressure or volume overload of the atria, hypertension, or hyperthyroidism. Atrial tachycardia can also arise from the pulmonary veins and may trigger AFb. In this case, short bursts of fast, irregular beats arising from the pulmonary veins are commonly observed.

**Atrial flutter (AF)** often coexists with or precedes atrial fibrillation. The ventricular rate can be variable (usual ratio of atrial to ventricular con-

traction 4:1 to 2:1, in rare cases 1:1) and macro-re-entrant tachycardias may be missed in stable 2:1 conduction. Vagal stimulation or intravenous adenosine can therefore be helpful to unmask AF. The atrial rate during AF is usually 220-350 beats/min, and the atrial rhythm is more or less regular. The mechanism of atrial flutter is always abnormal pulse propagation (macroreentry), which in 80% of cases involves the entire right atrium. The flutter waves typically have a saw-tooth appearance and since some parts of the atria are constantly electrically active, there is no isoelectric line in between these waves, as opposed to the flat isoelectric line observed in atrial tachycardia. In the most common form of AF, the flutter waves are negative in inferior derivations (II, III, aVF) suggesting a caudo-cranial (counterclockwise) activation pattern along the atrial septum.

In patients who have surgical scars in the atria, the reentry may occur around these scars and different flutter wave patterns may arise. The conduction over the AV node to the ventricles is usually 2:1. Therefore, the typical pulse during AF is usually 130-150 bpm.

Under catecholaminergic influence or in patients receiving class I antiarrhythmic therapy (e. g., flecainide), the tachycardia may show 1:1 conduction, usually with wide complexes due to rate-dependent aberration, and become life-threatening due to its rapid rate. Conversely, the AV conduction may slow down (e. g., 3:1 or 4:1) with carotid massage or by application of various drugs (adenosine) resulting in the unmasking of the flutter waves. The ventricular rate during AF has a certain regularity, differentiating it from AFb, which has a totally irregular rhythm.

**Atrial fibrillation (AFb).** The ventricular rate during AFb is absolutely irregular due to the chaotic fibrillatory activity in the atria at very high rates (300 beats/min). However, the arrhythmia may become somewhat regular at rapid ventricular rates. Every absolutely irregular rhythm is considered AFb until proven otherwise, even in the absence of identifiable P waves and even with wide QRS complexes.

Based on the **presentation, duration, and spontaneous termination** of AFb episodes, five types of AFb are traditionally distinguished:

- first diagnosed,
- paroxysmal,
- persistent,
- long-standing persistent, and
- permanent AFb.

Atrial fibrillation is classified as being:



- paroxysmal (self-terminating),
- persistent (sustained AFb that can only be returned to sinus rhythm by cardioversion),
- or permanent (sustained AFb that is either resistant to, or not appropriate for cardioversion).

Commonly, AFb, AF, and AT occur in the same patient and can induce one another.

**AV nodal reentrant tachycardia (AVNRT)** is the most common regular, paroxysmal, supraventricular tachycardia, which represents approximately 60% of cases. The mechanism is re-entry that occurs in the region of the AV node using the so-called slow pathway, a second structure that is considered to be physiologic in many individuals and conducts at a lower rate as compared the fast pathway. Typically, the tachycardia causes simultaneous contraction of the atria and the ventricles. Since the atrial contraction occurs as the atrioventricular valves are closed, patients commonly feel pulsation in the neck veins during the tachycardia and commonly report increased diuresis following the arrhythmia. In the ECG, retrograde P waves may be identified within or shortly after the QRS complex.

If no P waves or evidence of atrial activity is apparent and the RR interval is regular, then AVNRT is the most common mechanism. P-wave activity in AVNRT may be only partially hidden within the QRS complex and may deform the QRS to give a pseudo-R wave in lead V1 and/or a pseudo-S wave in inferior leads. In the V1 lead this pattern may mimic the presence of an incomplete right bundle branch block. Therefore, it is important to compare the QRS complexes during the tachycardia with those obtained during sinus rhythm.

The P waves during the tachycardia are usually small and negative in inferior derivations due to the simultaneous activation of both atria from the region of the AV node. In the less commonly observed atypical form of AVNRT, the re-entry occurs in the opposite direction and the P waves can be readily identified with RP intervals longer than the PR interval. Some patients with AVNRT may have PQ intervals less than 120 ms in sinus rhythm, is catecholamine-dependent and can typically be terminated with vagal maneuvers (Valsalva, carotid massage) or adenosine injection.

**AV reentrant tachycardia (AVRT) with antegrade conduction over the AV node.** Patients with AVRT have, in addition to the AV node, an accessory electrical conduction between the atria and the ventricles. These accessory pathways may be found in the left or right atrioventricular groove



or may even be multiple in the same patient. Approximately 60 % of these connections have only the ability for retrograde conduction (from the ventricles to the atria). The conduction is bidirectional in 30 % and only antegrade in 10 %. In WPW syndrome, there is antegrade conduction over the accessory pathway during sinus rhythm, which results in preexcited QRS complexes (delta waves). Physiologically, an AVRT using the AV node as the antegrade pathway and the accessory bundle as the retrograde pathway is far more common. If a P wave is present in the ST segment and separated from the QRS by 70 ms, then AVRT is most likely. These tachycardias have a normal QRS.

**Junctional rhythms.** The AV junction can serve as a secondary pacemaker in case of sinus arrest or can generate accelerated junctional rhythms faster than the sinus rate. The latter is mostly due to abnormal impulse formation (digoxin, excessive catecholamines, fibrinolysis and reperfusion, cardiac surgery). Retrograde P waves are grounds to assume a junctional rhythm. A gradual deceleration is observed after carotid sinus massage and an acceleration is possible. Accelerated junctional rhythms may also be observed, particularly in adolescents. However, the diagnosis can be confirmed only by electrophysiologic studies. Retrograde P waves are typically narrow and negative in inferior leads (II, III, aVF).

**Junctional tachycardia.** This abnormal rhythm originates in the bundle of His. It is observed as three or more premature junctional complexes (PJC's) appearing in a row. Heart rate is over 100 bpm.

## DIFFERENTIAL DIAGNOSIS OF WIDE-COMPLEX TACHYCARDIA

**Wide-QRS tachycardia** can be divided into three groups:

- SVT with bundle-branch block (BBB) or aberration;
- SVT with AV conduction over an accessory pathway;
- VT.

**Wide-QRS tachycardia** due to SVT with aberration, pre-existing bundle branch block, or preexcitation (WPW syndrome) is diagnosed in 20% of cases.

**Supraventricular tachycardia with bundle-branch block or aberration.** Bundle-branch block may be pre-existing or may occur only during tachycardia when one of the bundle branches is refractory due to the rapid rate. Most BBBs are not only rate-related, but are also due to a long-short sequence of initiation. Bundle-branch block can occur with any supraventricular arrhythmia. If a rate-related BBB develops during orthodromic

AVRT, then the tachycardia rate may slow if the BBB is ipsilateral to the bypass tract location.

**AV reentrant tachycardia with antegrade conduction over the accessory pathway.** This tachycardia with antegrade conduction over the accessory pathway occurs in patients with WPW syndrome. Conduction is antegrade over the accessory pathway and retrograde over the AV node. Maximal preexcitation is observed since the activation of the whole ventricle occurs solely over the accessory pathway. QRS complexes are very wide since the origin of the accessory activation is epicardial and morphologically this arrhythmia may electrically mimic a ventricular tachycardia originating from the area of initial activation.

Termination is sometimes possible by carotid sinus massage or vagal maneuvers, which block the retrograde conduction over the AV node. In the differential diagnosis, AF or other supraventricular tachycardias with accessory pathway conduction but without macroreentry must be considered. A previous ECG can be very useful for identifying delta waves and possibly preexisting intraventricular conduction disturbances, bundle branch block.

**Ventricular tachycardia (VT)** is diagnosed in 80% of wide-complex tachycardias.

**Criteria for the diagnosis of VT:**

- Ventriculoatrial dissociation;
- Fusion beats or capture beats due to antegrade or retrograde conduction over the AV node;
- QRS width 140 ms (140ms with a right bundle branch block pattern and 160 ms in left bundle branch block pattern);
- QRS axis: northwest axis ( $180^{\circ}$ - $270^{\circ}$ );
- Absence of an RS complex in V1 and V6;
- RS interval 100 ms in precordial derivations.

**Diagnosis:**

- Stable vital signs during tachycardias are not helpful for distinguishing SVT from VT;
- Carotid sinus massage: slowing or interrupting the retrograde conduction over the AV node demonstrates independent rhythm in the ventricles and the atria;
- Intravenous medications given for the treatment of SVT, particularly verapamil or diltiazem, may be deleterious because they may precipitate hemodynamic collapse for a patient with VT.

**The basic considerations** in the interpretation of the QRS width in the context of the medical history are:

- a rise in the heart rate (sinus tachycardia or atrial tachycardia) in a diseased heart causes widening of the QRS complex (aberration);
- a ventricular tachycardia in an otherwise healthy heart (idiopathic VT) can have a relatively narrow QRS complex (up to 110 ms);
- QRS widening can appear physiologically with irregular beat sequences (long-short) or after extrasystoles, and can then be propagated through retrograde invasion of the conduction system;
- VT with a narrow QRS complex (even narrower than that during sinus rhythm) may occur due to the arrhythmia originating from the ventricular septum.

**Ventricular tachycardia** has two variations: **monomorphic and polymorphic**.

**Monomorphic VT** has a constant rate and morphology and occurs due to abnormal impulse conduction (reentrant) in the area of an anatomic substrate. Monomorphic VT occurs when the electrical impulse originates in one of the ventricles. The QRS complex is wide. The rate is above 100 bpm.

These are potentially life-threatening arrhythmias, particularly in patients with a structural heart disease. VT in coronary heart disease patients usually shows Q waves in the region of the scar. The vector of the tachycardia should therefore correspond to the region of the infarct. A negative concordance (negative QRS complexes in leads V1-V6) is diagnostic for VT originating from an apical infarct scar. The activation of the left ventricle, which does not proceed over the normal pulse propagation system, shows usually a conduction delay during the tachycardia (R wave to maximum S over 100 ms). VT commonly occurs due to reentry around anatomic substrates (e. g., old infarction scars) and the possibility of residual tachyarrhythmias is high.

Idiopathic VT occurs in patients with normal hearts. These arrhythmias are usually monomorphic and arise from anatomically defined foci (e. g., from the right ventricular outflow tract [left bundle branch block pattern with inferior axis, or from the posterior fascicle of the left ventricle [right bundle branch block pattern and superior axis]). The rate of these tachycardias is partially associated with physical exertion and vagal tone and may vary depending on autonomic influences.

**Polymorphic VT and torsade de pointes.** Polymorphic VT has a con-

stantly varying morphology and intervals and occurs usually as a result of ischemia. If the QRS vector turns (torsade) about a point (pointes) and if a long QT interval is present, the arrhythmia is, by definition, a torsade de pointes. This arrhythmia usually begins with a short interval following a long pause (long-short pattern) due to dispersion of refraction times in the ventricles.

**Ventricular fibrillation and sudden cardiac death.** Ventricular fibrillation can be diagnosed on ECG if no distinct QRS complexes can be identified. Ventricular fibrillation can be preceded by VT, but it can also manifest spontaneously in the context of the diseases.

## DIFFERENTIAL DIAGNOSIS OF BRADYARRHYTHMIAS

**Atrial bradycardias** are divided into three types:

**1. Extrinsic (functional) bradycardia.** Respiratory sinus arrhythmia is usually found in young and healthy adults. Heart rate increases during inhalation and decreases during exhalation. This is thought to be caused by changes in the vagal tone during respiration. If the decrease during exhalation drops the heart rate below 60 bpm on each breath, this type of bradycardia is usually deemed benign and a sign of good autonomic tone.

**2. Sinus bradycardia** is a sinus rhythm of less than 60 bpm. It is a common condition found in both healthy individuals and athletes. The heart muscle of athletes has become conditioned to have a higher stroke volume, so it requires fewer contractions to circulate the same volume of blood.

**3. Sick sinus node (SA node dysfunction).**

**The electrocardiographic manifestations of SA node dysfunction** include:

- severe sinus bradycardia,
- sinus pauses,
- sinus arrest,
- sinus exit block,
- bradycardia-tachycardia syndrome (atrial fibrillation, flutter, and paroxysmal supraventricular tachycardia),
- chronotropic incompetence.

**The sinoatrial exit block classification:**

- **Type I second degree (Wenkebach) SA exit block:** the P-P interval progressively shortens prior to the pause,
- **Type II second degree SA exit block:** the pause equals approximately 2-4 times the preceding PP interval,
- **Third degree SA exit block:** absence of P waves (can only be diag-

nosed with an sinus node electrode, during electrophysiological evaluation).

**The diagnosis of bradyarrhythmia** is usually based on a standard ECG when persistent, and on a standard ECG or more prolonged ECG recordings [ambulatory monitoring or implantable loop recorder (ILR)] when intermittent. Provocative testing (Carotid sinus massage, Tilt table test) or an electrophysiological study (EPS) may be required when a bradycardia is suspected but not documented.

**Tilt table testing and carotid sinus massage** are indicated when reflex syncope is suspected in the setting of an atypical (non-diagnostic per se) presentation.

**Exercise testing** is indicated in patients who experience syncope during or shortly after exertion.

**Autonomic nervous system testing** is useful in diagnosing carotid sinus hypersensitivity; pauses >3 seconds are consistent with the diagnosis but may be present in asymptomatic elderly subjects. A low intrinsic heart rate (IHR) is indicative of SA disease and may distinguish SA node dysfunction from slow heart rates that result from high vagal tone.

**Electrophysiologic testing** is used to rule out more malignant etiologies of syncope, such as VT and AV conduction block. There are several ways to assess SA node function invasively. They include the sinus node recovery time (SNRT), defined as the longest pause after cessation of overdrive pacing of the right atrium near the SA node (normal: < 1 500 ms or, corrected for sinus cycle length, < 550 ms), and the sinoatrial conduction time (SACT), defined as one-half the difference between the intrinsic sinus cycle length and a noncompensatory pause after a premature atrial stimulus (normal < 125 ms). The combination of an abnormal SNRT, abnormal SACT, and low IHR is a sensitive and specific indicator of intrinsic SA node disease.

## DIFFERENTIAL DIAGNOSIS OF ATRIOVENTRICULAR (AV) BLOCKS

Atrioventricular conduction block is classified according to three degrees.

**First degree AV block.** On ECG in first degree AV block the PQ interval is prolonged over 0.20 sec and every P wave is being followed by a QRS complex. First degree AV block is present in 16% of > 90-year olds and is mostly caused by a degeneration of the conduction system. First degree AV block is relatively harmless.

Intermittent first degree AV block can be observed with increased vagal tone, in advanced age, and with drugs. If first degree AV block persists during sympathetic activation (exercise), then pathologic AV node function or a congenital anomaly must be suspected. First degree AV block, especially with coincident bundle branch block, can be a sign of severe conduction system disease below the AV node. If the PQ interval becomes very long (up to 300 ms) the atrial systole can occur during ventricular systole, against closed AV valves, leading to palpitations, fainting, and limited exercise tolerance.

**Second degree AV block.** In second degree AV block fewer QRS complexes than P waves are seen, but an association between the two is maintained. Depending upon the origin, and particularly for prognostic reasons, second degree AV block is classified into two types:

**Type 1. In second degree AV block type 1 (Wenckebach type)** there is a progressive prolongation of PQ intervals, until a single P wave block. The diagnostic criterion is the shortened PQ interval after the blocked P wave. The progressive reduction of the RR intervals, which is known as Wenckebach periodicity, results from the slowed progression of the PQ prolongation. The place of origin is generally the AV node, which has a conduction delay due to increased vagal tone. Progression to a higher degree AV block is rare.

**Type 2. Second degree AV block (Mobitz).** In second degree AV block type 2 (Mobitz) P waves are blocked in a more or less fixed ratio (2:1, 3:1, or 4:1) without prolongation of the PQ interval and without shortening of the PQ interval after the pause. As the origin of type 2 Mobitz block is below the atrioventricular node, usually within the His-Purkinje system, progression to complete AV block is frequent. The PQ intervals are usually short because of increased sympathetic tone.

In the case of second degree AV block with 2:1 conduction, a differential diagnosis of the two types can be difficult and usually becomes possible only when the beginning and end of the block, as well as further signs are taken into consideration. In Wenckebach type 1 nodal block there are frequently signs of increased vagal activity (sinus bradycardia), while in Mobitz type 2 infranodal block there is, on the contrary, increased sympathetic tone (sinus tachycardia).

**Third degree AV block.** Third degree AV block is defined by the absence of atrioventricular conduction. The P-waves and QRS complexes have no temporal relationship, which is called AV dissociation. Absent ventricular

rhythm results in asystole. The patient develops syncope due to asystole (Adams-Stokes) and death. Fortunately, in most cases an escape rhythm below (nodal, idioventricular) the AV node takes over. Escape rhythms are usually regular and are narrow if they arise high in the His bundle, wider if they arise more distally in the Purkinje system. If they have typical left bundle branch block morphology, they arise from the right bundle and vice versa.

### **DIFFERENTIAL DIAGNOSIS OF BUNDLE BRANCH BLOCKS**

Intraventricular conduction disturbances in the right or the left bundle system lead to the prolongation of the QRS interval.

#### **Bundle branch blocks classification by QRS interval duration:**

- Incomplete bundle branch blocks, the QRS interval is 100 – 120 ms,
- Complete bundle branch blocks, the QRS interval is >120 ms in duration.

#### **Bundle branch blocks classification by delayed depolarization:**

- Right bundle branch block
- Left bundle branch block
- Partial blocks (fascicular or "hemiblocks")
- Left anterior fascicular block
- Left posterior fascicular block.

**Right bundle branch block.** In right bundle branch block, the terminal QRS vector is oriented to the right and anteriorly (rSR' in V<sub>1</sub> and qRS in V<sub>6</sub>, typically). The LV is activated by the LBB and these impulses travel through the LV's myocardium to the RV and activate the RV. The prevalence of RBBB increases with age.

Bundle branch block may occur in a variety of conditions. In subjects without structural heart disease, right bundle branch block is seen more commonly than left bundle branch block. Right bundle branch block also occurs with heart disease, both congenital (e.g., atrial septal defect) and acquired (e.g. valvular, ischemic).

**Left bundle branch block.** Left bundle branch block alters both early and later phases of ventricular depolarization. The major QRS vector is directed to the left and posteriorly. The normal early left-to-right pattern of septal activation is disrupted such that septal depolarization proceeds from right to left as well. As a result, left bundle branch block generates wide, predominantly negative (QS) complexes in lead V<sub>1</sub> and entirely positive (R) complexes in lead V<sub>6</sub>.

A pattern identical to that of left bundle branch block, preceded by



a sharp spike, is seen in most cases of electronic right ventricular pacing because of the relative delay in left ventricular activation. Left bundle branch block is often a marker of one of four underlying conditions associated with increased risk of cardiovascular morbidity and mortality rates: coronary heart disease (frequently with impaired left ventricular function), hypertensive heart disease, aortic valve disease, and cardiomyopathy. Bundle branch blocks may be chronic or intermittent and rate-related, it often occurs when the heart rate exceeds some critical value.

### **Differential diagnosis of repolarization abnormalities of bundle branch blocks and primary repolarization abnormalities**

In bundle branch blocks the QRS vector usually is oriented in the direction of the myocardial region where depolarization is delayed. The T wave is typically opposite in polarity to the last deflection of the QRS. This discordance of the QRS-T-wave vectors is caused by the altered sequence of repolarization that occurs secondary to altered depolarization.

In contrast, primary repolarization abnormalities are independent of QRS changes and are related instead to actual alterations in the electrical properties of the myocardial fibers themselves (e.g., in the resting membrane potential or action potential duration), not just to changes in the sequence of repolarization. Ischemia, electrolyte imbalance, and drugs such as digitalis all cause such primary ST-T-wave changes. Primary and secondary T-wave changes may coexist.

**Partial blocks (fascicular or "hemiblocks")** in the left bundle system (left anterior or posterior fascicular blocks) generally do not prolong the QRS duration substantially but instead are associated with shifts in the frontal plane QRS axis (leftward or rightward, respectively).

**Left anterior fascicular block** (QRS axis more negative than  $-45^\circ$ ) is probably the most common cause of marked left axis deviation in adults. The clinical conditions associated with left anterior fascicular block are: myocardial infarction, arterial hypertension, aortic valvulopathy, cardiomyopathy and cardiac fibrosis.

**Left posterior fascicular block** (QRS axis more rightward than  $+110$ – $120^\circ$ ) is extremely rare as an isolated finding and requires the exclusion of other factors causing right axis deviation mentioned earlier. The clinical conditions associated with left posterior fascicular block are: normal, COPD, pulmonary embolism, ascites, abdominal tumor, left ventricular hypertrophy, septal atrial defect, hyperK-emia, Inferior MI, WPW syndrome and presence of pacemaker.



More complex **combinations of fascicular and bundle branch blocks** may occur that involve the left and right bundle system.

**Bifascicular block** includes:

- right bundle branch block and left posterior fascicular block,
- right bundle branch block with left anterior fascicular block
- complete left bundle branch block.

Chronic bifascicular block in an asymptomatic individual is associated with a relatively low risk of progression to high-degree AV heart block. In contrast, new bifascicular block with acute anterior myocardial infarction carries a much greater risk of complete heart block. Alternation of right and left bundle branch block is a sign of trifascicular disease. The presence of a prolonged PR interval and bifascicular block does not indicate trifascicular involvement, since this combination may arise with AV node disease and bifascicular block. Intraventricular conduction delays can also be caused by extrinsic (toxic) factors that slow ventricular conduction: hyperkalemia or drugs (class I antiarrhythmic agents, tricyclic antidepressants, phenothiazines).

## BIBLIOGRAPHY

1. Adan V., Crown L.A. Diagnosis and treatment of sick sinus syndrome. *Am Fam Physician* 2003; 67: 1725–32.
2. Blomström-Lundqvist C., Scheinman M., Antman E., et al. ACC/AHA/ESC Guidelines for the Management of Patients With Supraventricular Arrhythmias. A Report of the American College of Cardiology/American Heart Association Task Force and the European Society of Cardiology Committee for Practice Guidelines. 2003. ACC – [www.acc.org](http://www.acc.org). (accessed 09.08.2017)
3. Brignole M., Auricchio A., Baron-Esquivias G., et al. 2013 ESC Guidelines on cardiac pacing and cardiac resynchronization therapy. *European Heart Journal* 2013; 34: 2281–2329 doi:10.1093/eurheartj/eht150.
4. Collins K.K., Dubin A.M. Detecting and diagnosing arrhythmias in adults with congenital heart disease. *Curr Cardiol Rep* 2003; 5:331–5.
5. Harrigan R.A., Pollack M.L., Chan T.C. Electrocardiographic manifestations: bundle branch blocks and fascicular blocks. *J Emerg Med* 2003; 25:67–77.
6. Hayden G.E., Brady W.J., Pollack M., et al. Electrocardiographic manifestations: diagnosis of atrioventricular block in the Emergency Department. *J Emerg Med* 2004; 26: 95–106.
7. Hudson K.B., Brady W.J., Chan T.C., et al. Electrocardiographic manifestations: ventricular tachycardia. *J Emerg Med* 2003; 25: 303–14.
8. Kass R.S., Moss A.J. Long QT<sup>+</sup> syndrome: novel insights into the mechanisms of cardiac arrhythmias. *J Clin Invest* 2003; 112: 810–5.

9. Kasper D., Hauser S., Fauci A., et al. Disorders of rhythm. Disorders of the heart. In: Harrison's principles of internal medicine. 19<sup>th</sup> edition. McGraw-Hill Professional's MediaCenter. 2015. 2758 pps.
10. Kirchof P., Benussi S., Kotecha D., et al. 2016 ESC Guidelines for the management of atrial fibrillation developed in collaboration with EACTS Eur Heart J 2016; 37 (38): 2893-2962.
11. Mann D., Zipes P., Libby P., Bonou R. Braunwald's Heart disease: A Textbook of Cardiovascular Medicine, 10<sup>th</sup> Edition. Saunders. 2015. 2040 pps.
12. Miksad R., Delamora P., Meyer G., et al. Last Minute Internal medicine. 2008. The McGraw-Hill Companies. 535 pps.
13. Scharf C., Duru F. Arrhythmias. In: Siegenthaler W. with contributions by Aeschlimann A., Baechli E., Bassetti C. et al. Differential diagnosis in internal medicine from symptom to diagnosis. 2007, Georg Thieme Verlag, 1104 pps.
14. Zipes D., Camm J., Borggrefe M., et al. ACC/AHA/ESC 2006 Guidelines for Management of Patients With Ventricular Arrhythmias and the Prevention of Sudden Cardiac Death A Report of the American College of Cardiology/American Heart Association Task Force and the European Society of Cardiology Committee for Practice Guidelines. Circulation. 2006; 114: e385-e484.
15. [www.sciencedirect.com/topics/](http://www.sciencedirect.com/topics/) (accessed 26.09.2018).

## DIFFERENTIAL DIAGNOSIS OF NON-ISCHEMIC CARDIOMYOPATHIES

**INTRODUCTION.** Dilated cardiomyopathy accounts for approximately 60% of all cardiomyopathies, hypertrophic cardiomyopathy for approximately 30%, restrictive and arrhythmogenic cardiomyopathy of the right ventricle for 10–20%, and nonclassifiable cardiomyopathies for 1–2%.

**DEFINITION.** Non-ischemic cardiomyopathies are defined by structural and functional abnormalities of the ventricular myocardium that are unexplained by flow limiting coronary artery disease or abnormal loading conditions.

**CLASSIFICATION.** The first classification divided *non-ischemic* cardiomyopathies into five categories based on anatomical and physiological criteria (1980):

1. Dilated cardiomyopathy;
2. Hypertrophic cardiomyopathy;
3. Restrictive cardiomyopathy;
4. Arrhythmogenic right ventricular cardiomyopathy;
5. Unclassified cardiomyopathies.

New classification schemes based on genomics such as the classification proposed by the AHA divided *non-ischemic* cardiomyopathies into 2 major groups based on predominant organ involvement. Primary cardiomyopathies (i.e., genetic, mixt: genetic/non-genetic non-genetic and acquired) were defined as those solely or predominantly confined to heart muscle.

**Classification of *non-ischemic* cardiomyopathies based on etiological criteria** (AHA Scientific Statement, 2006):

### I. PRIMARY

#### 1.1 Genetic

- 1.1.1 Hypertrophic cardiomyopathy
- 1.1.2 Right ventricular arrhythmogenic cardiomyopathy
- 1.1.3 Noncompact left ventricle
- 1.1.4 Conduction system disease
- 1.1.5 Mitochondrial myopathies
- 1.1.6 Ionic channelopathy
  - 1.1.6.1 Long QT syndrome
  - 1.1.6.2 Short QT syndrome
  - 1.1.6.3 Brugada syndrome

- 1.1.6.4 Catecholaminergic polymorphic ventricular tachycardia
- 1.1.6.5 Idiopathic ventricular fibrillation
- 1.2 Mixed: genetic/non-genetic
  - 1.2.1 Dilated cardiomyopathy
  - 1.2.2 Restrictive cardiomyopathy
- 1.3 Acquired
  - 1.3.1 Myocarditis
  - 1.3.2 Stress („Tako-Tsubo”) cardiomyopathy
  - 1.3.3 Peripartum cardiomyopathy
  - 1.3.4 Tachycardia-induced cardiomyopathy

II. SECONDARY (infiltrative, storage, consequence of cancer therapy, toxicity, endocrine, autoimmune/collagen vascular diseases, cardiofacial, nutritional deficiencies, neuromuscular/neurological, endomyocardial, inflammatory, electrolyte imbalance).

## I. PRIMARY *NON-ISCHEMIC* CARDIOMYOPATHIES

### 1.1. GENETIC CARDIOMYOPATHIES

**1.1.1 Hypertrophic cardiomyopathy** (HCM) is defined by a hypertrophied, nondilated left ventricle (LV) in the absence of another systemic or cardiac disease that is capable of producing the magnitude of wall thickening evident (e.g., systemic hypertension, aortic valve stenosis).

HCM is a clinically heterogeneous but relatively common autosomal dominant genetic heart disease (1:500 of the general population for the disease phenotype recognized by echocardiography) that probably is the most frequently occurring cardiomyopathy and cause of sudden cardiac death in the young (including trained athletes) and is an important substrate for heart failure disability at any age. In up to 60% of adolescents and adults with HCM, the disease is an autosomal dominant trait caused by mutations in cardiac sarcomere protein genes. Five to ten percent of adult cases are caused by other genetic disorders including inherited metabolic and neuromuscular diseases, chromosome abnormalities and genetic syndromes.

**Pathophysiology.** HCM is caused by a variety of mutations encoding contractile proteins of the cardiac sarcomere. Currently, mutant genes are associated with HCM, most commonly-myosin heavy chain (the first identified) and myosinbinding protein C. The other 9 genes appear to account for far fewer cases of HCM and include troponin T and I, regulatory and essential myosin light chains, titin, tropomyosin, actin, myosin heavy chain,

and muscle LIM protein. This genetic diversity is compounded by considerable intragenic heterogeneity, with 400 individual mutations now identified. Most HCM patients have the propensity to develop dynamic obstruction to LV outflow under resting or physiologically provokable conditions, produced by systolic anterior motion of the mitral valve with ventricular septal contact.

**Diagnostic criteria:** forceful pulse and the marked change in the ejection murmur that occur at different degrees of ventricular filling. Auscultation in the standing and squatting positions makes it possible to differentiate the murmur from that of aortic stenosis and mitral insufficiency. It should be noted that the nonobstructive form of HCM is also frequently associated with a systolic ejection murmur. Sudden cardiac death from ventricular arrhythmia in HCM typically occurs in adolescents during or after very strenuous athletic activity.

Risk factors for the occurrence of sudden cardiac death are the following:

- history of surviving cardiac arrest or of persistent ventricular tachycardia,
- repeated syncopal attacks, unfavorable genotype and a positive family history,
- exercise-induced hypotension,
- non-sustained ventricular tachycardia on Holter ECG,
- massive left ventricular hypertrophy.

ECG shows: prominent pseudoinfarction Q waves in II, III, aVF and T-inversions in I, aVL, V2 through V6 are present, reflecting septal depolarization of the hypertrophic myocardium. The apical form of HCM is characterized by ST-segment depression and large deep negative T waves in the anterior leads.

Echocardiography findings: left ventricular hypertrophy  $\geq 15$  mm in one or more LV myocardial segments and the subvalvular dynamic pressure gradient at rest and after provocative stress, the systolic anterior motion of the mitral valve leaflet and possible mitral insufficiency.

A rapid genetic test, analysing by direct DNA sequencing mutations in the most common HCM causing genes is now available.

**DIFFERENTIAL DIAGNOSIS of hypertrophic cardiomyopathy includes:**

*Common disease:*

- Hypertensive heart disease

- Aortic stenosis
- Hypertrophic cardiomyopathy in athletes
- Isolated basal septal hypertrophy (sigmoid septum) in elderly people

*Less common diseases:*

- Restrictive cardiomyopathy (primary, infiltrative and storage types)
- Noncompaction cardiomyopathy.

**Hypertensive heart disease** may lead to hypertrophy of the left ventricle with asymmetrical septal hypertrophy and obstruction of the left ventricular outflow tract that is morphologically indistinguishable from HCM. A diagnosis of HCM should be made only in normotensive patients. Imaging increased LV mass, determined by echocardiography, is present in 30% of hypertensive patients. The degree of hypertrophy is influenced by ethnicity, neurohumoral factors, and genetic variants. The majority of patients with hypertensive LVH have a maximal interventricular septal thickness of 15mm, but in black patients can be between 15 and 20 mm. Echocardiography with Doppler may distinguish the two entities: diastolic abnormalities and LA dilation, seen in HCM and hypertension, but severe diastolic dysfunction is more typical of HCM.

**In aortic stenosis** echocardiography can demonstrate the thickened and calcified aortic valve and define the structure of the pressure gradient across that valve, thereby distinguishing it from HCM. However, a significant percentage of patients with aortic stenosis also have asymmetrical septal hypertrophy and show a certain subvalvular pressure gradient.

**Hypertrophic cardiomyopathy in athletes.** Physiological adaptation to regular intense physical training is associated with LV wall thickness of <15 mm and enlarged cardiac chamber size due to increased vagal tone. Female athletes presenting LV wall thickness of 13–15 mm (and normal cavity size) are most likely to have HCM. In athletes mitral valve systolic anterior motion (SAM) is absent, since SAM is inconsistent with athlete's heart and strongly suggests HCM. LV cavity dimension is useful in distinguishing athlete's heart from HCM. LV dimensions of > 55 mm are common in trained athletes, but rare in HCM in which the cavity size is often < 45 mm and dimensions of > 55 mm usually occur only in the end stage phase with progressive heart failure and systolic dysfunction. The athletes invariably demonstrate normal LV filling patterns. The absence of fibrosis may be helpful in differentiating HCM from physiological adaptation in athletes.

**Isolated basal septal hypertrophy (sigmoid septum) in elderly people.** Some elderly people have mild basal septal hypertrophy (sometimes

referred to as a sigmoid septum or septal bulge) associated with increased angulation between the aorta and LV cavity. Many have a history of hypertension and some have calcification of the mitral valve annulus. The limited data suggest that individuals with this pattern of ventricular remodeling are less likely to have familial disease or a mutation in a cardiac sarcomeric protein gene. Advice on family screening in this group is challenging, but should be guided by the implications for family members and the presence of suspicious symptoms in relatives.

**1.1.2. Arrhythmogenic right ventricular cardiomyopathy (ARVC)**, formerly called arrhythmogenic right ventricular dysplasia) is a rare form of cardiomyopathy. It is characterized by a regional or global replacement of right ventricular muscle cells by fat and fibrous tissue. The most frequent sites of fibrofatty replacement are the apex, inflow tract, and outflow tract of the right ventricle. Occasionally the left ventricle is also affected. ARVC predominantly affects men, and several genetic defects have been identified. ARVC remains asymptomatic for years and occasionally is detected incidentally on chest radiographs. Ventricular arrhythmias are complications that often occur as the earliest symptom, and there are unfortunate cases in which the first sign of ARVC is sudden cardiac death. Arrhythmias have a right ventricular origin. The ECG shows widening of the QRS complex, a complete or incomplete right bundle branch block, and precordial T-wave inversions. Approximately 30 % of patients have an epsilon wave (a wave immediately following the QRS complex in V1). Echocardiography may show localized dyskinesia or mild to severe right ventricular dilatation, depending on the stage of the disease. Fat deposits in the right ventricle can generally be identified on MR images.

**1.1.3. Noncompaction of the left ventricle** is a rare, unclassified congenital cardiomyopathy that results from a failure of normal myocardial compaction during embryonic development. Morphologically, left ventricular noncompaction is characterized by multiple trabeculations and deep intratrabecular recesses that communicate with the ventricular cavity. The trabeculations are most pronounced in the apical part of the left ventricle. This cardiomyopathy often occurs with heart failure or ventricular arrhythmias. A large percentage of patients suffer thromboembolic complications. The diagnosis is made with 2-dimensional echocardiography, cardiac magnetic resonance imaging, or LV angiography. The angiography displays a double contour with contrast medium outlining the trabeculae and the contracting ventricle.

**1.1.4. Conduction system disease.** Lenegre disease, also known as progressive cardiac conduction defect, is characterized by primary progressive development of cardiac conduction defects in the His-Purkinje system, leading to widening of the QRS complex, long pauses, and bradycardia that may trigger syncope. Sick sinus syndrome is phenotypically similar to progressive cardiac conduction defect. Familial occurrence of both syndromes with an autosomal dominant pattern of inheritance has been reported. Wolff-Parkinson-White syndrome is familial in some cases, but information about the genetic causes is unavailable.

**1.1.5 Ionic channelopathies.** There is a growing list of uncommon inherited and congenital arrhythmia disorders caused by mutations in genes encoding defective ionic channel proteins, governing cell membrane transit of sodium and potassium ions. These ion channel disorders include LQTS, short-QT syndrome (SQTS), Brugada syndrome, and catecholaminergic polymorphic ventricular tachycardia (CPVT).

**1.1.5.1 Long-QT Syndrome.** This condition, probably the most common of the ion channelopathies, is characterized by prolongation of ventricular repolarization and QT interval (corrected for heart rate) on the standard 12-lead ECG, a specific form of polymorphic ventricular tachycardia (torsade des pointes), and a risk for syncope and sudden cardiac death. Phenotypic expression (on the ECG) varies considerably, and 25% to 50% of affected family members may show borderline or even normal QT intervals. Two patterns of inheritance have been described in LQTS: a rare autosomal recessive disease associated with deafness (Jervell and Lange-Nielsen syndrome), which is caused by 2 genes that encode for the slowly activating delayed rectifier potassium channel (KCNQ1 and KCNE1 [minK]), and much more common autosomal dominant disease unassociated with deafness (Romano-Ward syndrome), which is caused by mutations in 8 different genes.

**1.1.5.2. Brugada syndrome** is a relatively new clinical entity associated with sudden cardiac death in young people. The syndrome is identified by a distinctive ECG pattern consisting of right bundle-branch block and coved ST-segment elevation in the anterior precordial leads (V1-V3). The characteristic ECG pattern is often concealed and may be unmasked with the administration of sodium channel blockers, including ajmaline, flecainide and procainamide. Familial autosomal dominant and sporadic forms have been linked to mutations in a subunit of the cardiac sodium channel gene SCN5A (the same gene responsible for LQT3) in 20% of



patients. Some cases of sudden unexplained nocturnal death syndrome resulting from SCN5A gene mutations and Brugada syndrome have been shown to be phenotypically, genetically, and functionally the same disorder.

**1.1.5.3. Short-QT Syndrome.** First described in 2000, the SQTs is characterized by a short QT interval (330 ms) on an ECG and a high incidence of sudden cardiac death resulting from ventricular tachycardia/fibrillation. Another distinctive ECG feature of SQTs is the appearance of tall peaked T waves similar to those encountered with hyperkalemia. The syndrome has been linked to gain-of-function mutations in KCNH2 (HERG, SQT1), KCNQ1 (KvLQT1, SQT2), and KCNJ2 (Kir2.1, SQT3), causing an increase in the intensity of *IKr*, *Iks*, and *Ikl*, respectively.

**1.1.5.4. Catecholaminergic polymorphic ventricular tachycardia (CPVT)** is characterized by syncope, sudden death, polymorphic ventricular tachycardia triggered by vigorous physical exertion or acute emotion (usually in children and adolescents), a normal resting ECG, and the absence of structural cardiac disease. Family history of 1 or multiple sudden cardiac deaths is evident in 30% of cases. The resting ECG is unremarkable, except for sinus bradycardia and prominent U waves in some patients. The most typical arrhythmia of CPVT is bidirectional ventricular tachycardia presenting with an alternating QRS axis. The autosomal dominant form of the disease has been linked to the RyR2 gene encoding for the cardiac ryanodine receptor, a large protein that forms the calcium release channel in the sarcoplasmic reticulum that is essential for regulation of excitation–contraction coupling and intracellular calcium levels. An autosomal recessive form has been linked to CASQ2, a gene that encodes for calsequestrin, a protein that serves as a major calcium-binding protein in the terminal cisternae of the sarcoplasmic reticulum. Calsequestrin is bound to the ryanodine receptor and participates in the control of excitation–contraction coupling.

**1.1.5.5. Idiopathic ventricular fibrillation** frequently is associated with sudden death. Idiopathic ventricular fibrillation is a condition with normal gross and microscopic findings in which arrhythmic risk derives from molecular abnormalities, most likely ion channel mutations.

## 1.2 MIXED (GENETIC/NON-GENETIC) CARDIOMYOPATHIES

**1.2.1 Dilated cardiomyopathy.** The term dilated cardiomyopathy (DCM) refers to a spectrum of heterogeneous myocardial disorders that are characterized by ventricular dilation and depressed myocardial per-

formance in the absence of hypertension, valvular, congenital, or ischemic heart disease. Dilated cardiomyopathy is characterized by the dilatation of one or both ventricles, whose walls may be normal or thinned and whose contractility is severely impaired.

Dilated cardiomyopathy may be caused by a number of diseases. In approximately 50% of cases the etiology remains unknown and the DCM is classified as idiopathic. A large percentage of other cardiomyopathies have a genetic cause or result from viral myocarditis. Hereditary forms of DCM are based on autosomal dominant gene mutations that affect the cytoskeleton and myocytes (e. g., dystrophin, lamin A and C, emerin, and metavinculin).

**The pathophysiology** is based on the impaired systolic pumping function of the heart. Histologic examination shows a loss of myocytes, increased interstitial fibrosis, and often nonspecific inflammatory cells.

**Diagnostic criteria.** Patients have typical symptoms of right-sided and left-sided heart failure. Symptoms of pulmonary congestion (dyspnea on exertion, orthopnea, paroxysmal nocturnal dyspnea) and exercise intolerance reflecting the low cardiac output are the most prominent features. Many patients also manifest systemic venous congestion and anorexia as signs of right-sided heart failure. Thromboembolic complications are usual and arrhythmias leading to dizziness, syncope, or even sudden death are a feared complication. Signs of biventricular heart failure are noted on examination. Auscultation usually discloses a third and fourth heart sound, and it is common to find mitral insufficiency and tricuspid insufficiency. Mitral insufficiency is sometimes severe and results from dilatation of the mitral valve annulus. It may occasionally raise problems of differential diagnosis. There may also be signs of decreased peripheral blood flow with cool skin and peripheral cyanosis, depending on the severity of the heart failure.

**Diagnostic studies.** ECG frequently shows a left bundle branch block or other conduction abnormalities. The 24-hour ECG and stress ECG may show dangerous ventricular arrhythmias in some patients. Chest radiograph: the dominant radiographic signs are cardiomegaly and pulmonary congestion. Echocardiography can reveal ventricular dilatation, pulmonary hypertension, pump failure, and the extent of mitral and tricuspid insufficiency. Cardiac catheterization can detect the low cardiac output, the increased peripheral resistance, and pulmonary hypertension. Biopsy usually indicates nonspecific fibrosis.

**The list of diseases for the differential diagnosis of dilated cardiomyopathy includes:**

*Common diseases*

- Coronary heart disease;
- Pericardial diseases;
- Mitral insufficiency;
- Hyperthyroidism and thyrotoxicosis;
- Myocarditis.

*Less common diseases*

- Heavy metal toxicity;
- Thiamine deficiency;
- Cocaine or amphetamine toxicity;
- Cocaine – related cardiomyopathy;
- Restrictive cardiomyopathy;
- Hypertrophic cardiomyopathy.

**Coronary heart disease.** Severe triple-vessel coronary disease or main trunk disease may occasionally cause a diffuse global impairment of left ventricular function that is morphologically indistinguishable from dilated cardiomyopathy. Approximately 5% of patients with unexplained dilated cardiomyopathy and risk factors for coronary heart disease are found on invasive examination to actually have severe coronary disease. Occasionally the degree of pump dysfunction is not proportional to the severity of existing coronary disease (e. g., single-vessel disease). In this case it is more likely that dilated cardiomyopathy coexists with coronary heart disease.

**Mitral insufficiency.** Left ventricular dilatation leads to the dilatation of the mitral valve annulus, and occasionally this may cause severe mitral insufficiency. In many cases, it is impossible to determine whether the patient has dilated cardiomyopathy with secondary mitral insufficiency or severe mitral insufficiency causing a secondary decline in ventricular function. Significant improvement of mitral insufficiency in response to afterload-reducing therapy would support a diagnosis of secondary mitral insufficiency.

**Pericardial effusion** (see Differential diagnosis of pericardial diseases).

**1.2.2 Restrictive cardiomyopathy.** In restrictive cardiomyopathy (RCM), the disease of the myocardium or endocardium leads to the impaired filling of one or both ventricles. Most cases show no cardiac dilatation or hypertrophy. Systolic function is usually intact, at least at the start of the disease. Restrictive cardiomyopathy is most frequently caused by infiltrative diseases and storage diseases. The most important causative diseases are amyloidosis, prior radiotherapy, sarcoidosis, hemochromatosis,

and Fabry disease. Idiopathic RCM is very rare. Restrictive cardiomyopathy may also result from scarring of the endomyocardium, which usually affects both ventricles.

The mitral and tricuspid valves are usually involved as well. The principal diseases that cause this obliterative form of RCM are endomyocardial fibrosis and eosinophilic parietal endocarditis (Löffler endocarditis). The impairment of ventricular filling gives rise to a volume and pressure overload and dilatation of the atria. The symptoms are: dyspnea on exertion and orthopnea and right-sided heart failure. Auscultation often reveals a third and/or fourth heart sound and regurgitant murmurs indicating mitral and tricuspid insufficiency.

**Diagnostic studies.** The common findings are: arrhythmias, peripheral low voltage, nonspecific ST-wave and T-wave changes, and conduction delays. Chest radiograph may show pulmonary congestion with a slightly enlarged left ventricle and dilated atria. Doppler echocardiography can demonstrate the restrictive filling pattern. Laboratory tests: laboratory findings may provide important clues to the etiology of the cardiomyopathy (hypercalcemia in sarcoidosis, high iron levels in hemochromatosis).

**The list of diseases for the differential diagnosis of restrictive cardiomyopathy includes:**

- Constrictive pericarditis (see Pericardial diseases);
- Cardiac tamponade (see Pericardial diseases);
- Hypertrophic cardiomyopathy (see *Non-ischemic* cardiomyopathies);
- Dilated cardiomyopathy (see *Non-ischemic* cardiomyopathies).
- Heart failure (see Heart failure);
- Hypertensive heart disease (see Arterial hypertension);
- Aortic stenosis (see Aortic stenosis).

### 1.3. ACQUIRED *NON-ISCHEMIC* CARDIOMYOPATHIES

**1.3.1. Myocarditis (Inflammatory cardiomyopathy)** is an acute or a chronic inflammatory process affecting the myocardium produced by a wide variety of toxins and drugs or infectious agents, most commonly including viral (eg, Coxsackie virus, adenovirus, parvovirus, HIV), bacterial (eg, diphtheria, meningococcus, psittacosis, streptococcus), rickettsial (eg, typhus, Rocky Mountain spotted fever), fungal (eg, aspergillosis, candidiasis), and parasitic (Chagas disease, toxoplasmosis), as well as Whipple disease (intestinal lipodystrophy), giant cell myocarditis, and hypersensitivity reactions to drugs such as antibiotics, sulfonamides, anticonvulsants, and

antiinflammatories. Endocardial fibroelastosis is a dilated cardiomyopathy in infants and children that is a consequence of viral myocarditis in utero (mumps). Myocarditis typically evolves through active, healing, and healed stages characterized progressively by inflammatory cell infiltrates leading to interstitial edema and focal myocyte necrosis and ultimately replacement fibrosis. These pathological processes create an electrically unstable substrate predisposing to the development of ventricular tachyarrhythmias. An episode of viral myocarditis (frequently subclinical) can trigger an autoimmune reaction that causes immunologic damage to the myocardium or cytoskeletal disruption, culminating in DCM with LV dysfunction. The symptoms and signs are: chest pain, exertional dyspnea, fatigue, syncope, palpitations, ventricular tachyarrhythmias, and conduction abnormalities or acute congestive heart failure or cardiogenic shock associated with LV dilatation and/or segmental wall motion abnormalities and ST-T changes on ECG. When myocarditis is suspected from the clinical profile, an endomyocardial biopsy may denote inflammatory (leukocyte) infiltrate and necrosis. The diagnostic yield of myocardial biopsies can be enhanced substantially by molecular analysis with DNA-RNA extraction and polymerase chain reaction amplification of the viral genome.

**1.3.2. Stress („Tako-Tsubo”) cardiomyopathy** is characterized by acute but rapidly reversible LV systolic dysfunction in the absence of atherosclerotic coronary artery disease, triggered by profound psychological stress. This distinctive form of ventricular stunning typically affects older women and preferentially involves the distal portion of the LV chamber („apical ballooning”), with the basal LV hypercontractile. Although the presentation often mimics ST-segment-elevation myocardial infarction, the outcome is favorable with appropriate medical therapy.

**1.3.3. Peripartum (postpartum) cardiomyopathy** is a rare and dilated form associated with LV systolic dysfunction and heart failure of unknown cause that manifests clinically in the third trimester of pregnancy or the first 5 postpartum months. It is regarded as a clinical entity distinct from preexisting cardiomyopathies that may be adversely affected by the stress of pregnancy. Peripartum cardiomyopathy most frequently occurs in obese, multiparous women of 30 years of age with preeclampsia. This cardiomyopathy is associated with complete or nearly complete recovery within 6 months in 50% of cases but may result in progressive clinical deterioration, heart failure, death, or transplantation.

**1.3.4. Tachycardia-induced cardiomyopathy** is a reversible dilated

cardiomyopathy with LV contractile dysfunction that occurs secondary to prolonged periods of supraventricular or ventricular tachycardia. Systolic function normalizes without residual impairment on cessation of the tachycardia.

## BIBLIOGRAPHY

1. Alpert J.S., Dalen J.E., Rahimtoola S.H. Valvular Heart Disease. 3rd ed. Lippincott Williams & Wilkins 2000. Alpert JS, Ewy GA. Manual of Cardiovascular Diagnosis and Therapy. 5th ed. Lippincott Williams & Wilkins 2002.
2. Bonow R.O., Carabello B., de Leon A.C., et al. Guidelines for the management of patients with valvular heart disease. *Circulation* 2006; 114: 450-527.
3. Bozkurt B., Colvin M., Cook J., et al. Current Diagnostic and Treatment Strategies for Specific Dilated Cardiomyopathies. A Scientific Statement from the American Heart Association. *Circulation*. 2016; 134: e579–e646. DOI: 10.1161/CIR.0000000000000455.
4. Braunwald E., Zipes D.P., Libby P. Heart Disease. A Textbook of Cardiovascular Medicine. 6th. ed. Philadelphia: Saunders 2001.
5. Eberli F.R., Zimmerli M., Karadag B. Mitral Regurgitation. In: Roffi M, Meier B, Topol EJ (eds.): CVMstatR-A Comprehensive Handheld Based Approach to Cardiovascular Medicine. Handheldmed Inc., Little Rock, AR, USA, 2004.
6. Elliott A., Borger M., Borggrefe M., et al. 2014 ESC Guidelines on diagnosis and management of hypertrophic cardiomyopathy The Task Force for the Diagnosis and Management of Hypertrophic Cardiomyopathy of the European Society of Cardiology (ESC). *European Heart Journal* 2014; 35: 2733–2779 doi:10.1093/eurheartj/ehu284.
7. Gersh B. J., Maron B., Bonow R., et al. 2011 ACCF/AHA Guideline for the Diagnosis and Treatment of Hypertrophic Cardiomyopathy: Executive Summary A Report of the American College of Cardiology Foundation/American Heart Association Task Force on Practice Guidelines Developed in Collaboration With the American Association for Thoracic Surgery, American Society of Echocardiography, American Society of Nuclear Cardiology, Heart Failure Society of America, Heart Rhythm Society, Society for Cardiovascular Angiography and Interventions, and Society of Thoracic Surgeons. *Circulation* 2011; 124: 2761-2796.
8. Haslet C., Chilves E.R., Boon N.A., Colledge N.R., Hunter J.A.A. Davidson's Principles and Practice of Medicine. 19th ed. Edingburgh: Churchill Livingstone 2002.
9. Kasper D., Hauser S., Fauci A., et al. Disorders of the heart. In: Harrison's principles of internal medicine. 19<sup>th</sup> edition. McGraw-Hill Professional's MediaCenter. 2015. 2758pps.
10. Maron B. J., Towbin J. A., Thiene G., et al. Contemporary Definitions and

Classification of the Cardiomyopathies. An American Heart Association Scientific Statement From the Council on Clinical Cardiology, Heart Failure and Transplantation Committee; Quality of Care and Outcomes Research and Functional Genomics and Translational Biology Interdisciplinary Working Groups; and Council on Epidemiology and Prevention. *Circulation*. 2006; 113: 1807-1816. doi:10.1161/circulationaha.106.174287

11. Siegenthaler W. with contributions by Aeschlimann A., Baechli E., Bassetti C. et al. *Differential diagnosis in internal medicine from symptom to diagnosis*. 2007, Georg Thieme Verlag, 1104 pps.
12. [www.onlinejacc.org/content/58/22/2329](http://www.onlinejacc.org/content/58/22/2329) (accessed 26.09.2018).

## DIFFERENTIAL DIAGNOSIS OF PERICARDIAL DISEASES

**INTRODUCTION.** The incidence of acute pericarditis has been reported as 27.7 cases per 100,000 population per year. Pericarditis is responsible for 0.1% of all hospital admissions and 5% of emergency room admissions for chest pain. The data from the Framingham cohort suggest that pericardial effusion may be present in up to 6.5% of the adult population.

**ETIOLOGICAL CLASSIFICATION** for pericardial diseases is to consider infectious and non-infectious causes:

### **Idiopathic**

**Viral:** *cytomegalovirus, Coxsackie, echo Epstein-Barr, Influenza, adeno, varicella, rubella, mumps, human herpes virus, Parvovirus B19;*

**Bacterial:** tuberculosis, staphilococcus, streptococcus, pneumococcus, haemophilus, neisseria chlamydia, mycoplasma, legionella, leptospira, listeria, borreliosis;

**Fungal:** aspergillus, candida;

**Parasites:** histoplasmosis, blastomycosis, aspergillus, candida, echinococcus, toxoplasma, entamoeba;

**Vascular:** post MI acute inflammation, cardiac rupture post MI, aortic dissection;

**Neoplastic:** a) metastatic (lung, breast, lymphoma, leukemia), b) primary – mesothelioma;

**Drugs:** lupus-like syndrome: hydralazine, isoniazid, procainamide, phenytoin, methyldopa, penicillins (hypersensitivity pericarditis with eosinophilia), doxorubicin, daunorubicin (cardiomegaly, pericardiopathy);

**Toxin:** asbestos, scorpion, fish;

**Iatrogenic:** radiation acute or many yrs late. procedure: cardiac surgery, central line;

**Autoimmune:** systemic scleroderma, rheumatoid arthritis, connective tissue disease, vasculitises, sarcoid, familial Mediterranean fever, Whipple's, rheumatic fever, Behcet's, post myocardial infarct or post pericardial injury;

**Trauma:** blunt (steering wheel), sharp (bullet);

**Endocrine:** uremia, hypothyroid, myxedema, ovarian hyperstimulation syndrome.

**Pericardial syndromes** include:



- Pericarditis,
- Pericardial effusion,
- Cardiac tamponade,
- Constrictive pericarditis.

### **Clinical classification**

Pericarditis can be classified by duration of inflammation as well as by etiology and complications/sequelae.

**A. Acute pericarditis** (new onset, < 4-6 weeks)

**B. Incessant pericarditis:** Signs and symptoms lasting > 4-6 weeks but < 3 months without remission.

**C. Recurrent pericarditis:** Recurrence of signs and symptoms after an initial documented episode of acute pericarditis with an intervening symptom-free interval of  $\geq$  4-6 weeks.

**D. Chronic pericarditis:** Signs and symptoms persisting for > 3 months.

**Subtypes:** constrictive (due to chronically thickened pericardium); effusive-constrictive (combination of tense effusion in the pericardial space and constriction by the thickened pericardium) and adhesive (nonconstrictive).

**I. Acute pericarditis.** The pericardium may be affected by different categories of diseases, including infectious, neoplastic, autoimmune, iatrogenic, traumatic, and metabolic.

**Pathophysiology.** Cardiotropic viruses can cause pericardial inflammation via direct cytolytic or cytotoxic effects and/or subsequent immune-mediated mechanisms. Such mechanisms are especially involved in cases associated with connective tissue diseases, inflammatory bowel diseases and radiation-induced, drug-induced or vaccine-associated pericardial involvement.

### **Diagnostic criteria of acute pericarditis.**

- Inflammatory pericardial syndrome associated with at least 2 of the following 4 criteria:
  - Pericarditic chest pain,
  - Pericardial friction rubs,
  - New diffuse electrocardiographic ST-elevations or PR depressions,
  - New or worsening pericardial effusion.
- **Additional supporting findings include:**
  - Elevated inflammatory markers (i.e., CRP, ESR, WBC count),
  - Evidence of pericardial inflammation by advanced imaging techniques (i.e., cardiac CT or MRI),

- Possible associations: pericardial effusion that is fibrinous or effusive (serous or serosanguinous).

A chest X-ray is generally normal in patients with acute pericarditis since an increased cardiothoracic ratio occurs only with pericardial effusions exceeding 300 ml.

Transthoracic echocardiography is used to detect the presence, size and haemodynamic importance of the pericardial effusion.

## **DIFFERENTIAL DIAGNOSIS OF ACUTE PERICARDITIS**

**The list of diseases for the differential diagnosis of acute pericarditis includes:**

- Esophageal perforation
- Esophageal spasm
- Esophagitis
- Gastroesophageal reflux disease
- Acute gastritis
- Peptic ulcer disease
- Aortic stenosis
- Myocardial infarction

**Esophageal perforation.** The esophagus lacks a serosal layer, it is more vulnerable to rupture or perforation and gastric contents may enter the mediastinum. The most common cause of esophageal perforation is postemetic, medical instrumentation for diagnostic and therapeutic aims. The mediastinal pleura often ruptures and gastric fluid is drawn into the pleural space by the negative intrathoracic pressure. This pleural effusion usually is on the left but can be bilateral. Double-contrast esophageal barium studies are recommended as the initial imaging study.

**Esophageal spasm.** Hypercontractile esophagus is a prolonged extreme hypertensive contractions of very high amplitude, involving a majority of the esophagus. The symptoms can include chest pain dysphagia, regurgitation. High-resolution manometry denotes the esophagus jackhammer-type appearance.

**Esophagitis.** The common forms of esophagitis include reflux esophagitis, infectious esophagitis, pill esophagitis, eosinophilic esophagitis, and radiation and chemoradiation esophagitis. The typical symptoms include the following: retrosternal discomfort dysphagia or odynophagia, dyspepsia. Double-contrast esophageal barium studies are recommended as the initial imaging study for dysphagia though a case can be made for initial upper gastrointestinal endoscopy.

**Gastroesophageal reflux disease** occurs when the amount of gastric juice that refluxes into the esophagus, causing symptoms with or without associated esophageal mucosal injury: heartburn, regurgitation, dysphagia, and extraesophageal symptoms (noncardiac chest pain coughing and/or wheezing, hoarseness, sore throat, otitis media, enamel erosion or other dental manifestations).

**Acute gastritis** is a inflammation in the gastric mucosa: erosive and nonerosive, caused by *Helicobacter pylori*. The most common symptoms nondescript epigastric discomfort, nausea, vomiting, loss of appetite, belching, and bloating. The diagnosis is usually made during endoscopy and can be confirmed histologically by biopsy specimens taken during endoscopy.

**Peptic ulcer disease.** Epigastric pain is characterized by a gnawing or burning sensation and occurs after meals, classically, shortly after meals with gastric ulcer and 2-3 hours afterward with duodenal ulcer. In peptic ulcer disease the clinical findings include dysphagia or odynophagia, recurrent vomiting. Patients with perforated peptic ulcer disease usually present with a sudden onset of severe, sharp abdominal pain. Endoscopy provides an opportunity to visualize the ulcer, to determine the presence and degree of active bleeding.

**Aortic stenosis** is a valvulopathy with the obstruction of blood flow across the aortic valve. The classic symptoms are: chest pain precipitated by exertion and relieved by rest, heart failure and syncope upon exertion when systemic vasodilatation in the presence of a fixed forward stroke volume causes the arterial systolic blood pressure to decline. The classic crescendo-decrescendo systolic murmur of aortic stenosis begins shortly after the first heart sound; the intensity increases toward midsystole and then decreases, with the murmur ending just before the second heart sound. Paradoxical split S2, pulsus parvus et tardus (the pulse wave comes much later than the heartbeat) and sustained apical impulse. ECG: left ventricle hypertrophy. Echocardiogram: shows obstructed aortic orifice.

**Myocardial infarction.** The signs and symptoms: retrosternal pain, no variation with respiration or positional changes, no response to nitroglycerin. ECG may show convex ST elevations in the distribution of coronary arteries; Q-waves may be present; PR segment depression is rare; inverted T-waves when ST segments are still elevated. There is a significant elevation of serum troponin and other cardiac enzymes. Echocardiography: wall motion abnormalities consistent with coronary flow distribution.

## II. Pericardial effusion

The normal pericardial sac contains 10–50 ml of pericardial fluid as a plasma ultrafiltrate that has a low protein concentration and low specific gravity. Any pathological process usually causes an inflammation with the possibility of increased production of pericardial fluid. An alternative mechanism of accumulation of pericardial fluid may be decreased reabsorption due to a general increase in systemic venous pressure as a result of congestive heart failure or pulmonary hypertension. Pericardial effusion may be classified according to its onset (acute or subacute vs. chronic when lasting >3 months), distribution (circumferential or loculated), haemodynamic impact (none, cardiac tamponade, effusive-constrictive), composition (exudate, transudate, blood, rarely air, or gas from bacterial infections) and, in particular, by its size based on a simple semiquantitative echocardiographic assessment as mild (<10 mm), moderate (10–20 mm) or large (>20 mm).

Classic symptoms include dyspnoea on exertion progressing to orthopnoea, chest pain and/or fullness. Additional occasional symptoms due to local compression may include nausea (diaphragm), dysphagia (oesophagus), hoarseness (recurrent laryngeal nerve) and hiccups (phrenic nerve). Non-specific symptoms include cough, weakness, fatigue, anorexia and palpitations, and reflect the compressive effect of the pericardial fluid on contiguous anatomic structures or reduced blood pressure and secondary sinus tachycardia. On physical examination the classic signs are neck vein distension with elevated jugular venous pressure at bedside examination, pulsus paradoxus and diminished heart sounds on cardiac auscultation in cases of moderate to large effusions. Pericardial friction rubs are rarely heard; they can usually be detected in patients with concomitant pericarditis.

The diagnosis of pericardial effusion is generally performed by echocardiography, which also enables semiquantitative assessment of the pericardial effusion size and its haemodynamic effects. Large idiopathic chronic effusions (>3 months) have a 30–35% risk of progression to cardiac tamponade. Also, subacute (4–6 weeks) large effusions not responsive to conventional therapy and with echocardiographic signs of collapse of the right chambers may have an increased risk of progression.

## III. Cardiac tamponade

The common causes of cardiac tamponade are: pericarditis, tuberculosis, iatrogenic (invasive procedure-related, post-cardiac surgery), trauma, neo-

plasm, malignancy. Uncommon causes: collagen vascular diseases (systemic lupus erythematosus, rheumatoid arthritis, scleroderma), radiation induced, postmyocardial infarction, uraemia, aortic dissection, bacterial infection and pneumopericardium. Cardiac tamponade occurs when pericardial pressure increases and limits cardiac filling. The severity of tamponade is determined by its effect on cardiac output and hemodynamics, but even when hypotension is not present, tamponade is a serious condition that may rapidly progress and requires urgent evaluation. Effusions that are small and thought to be transudative are unlikely to be clinically significant. Echocardiography is the single most useful diagnostic tool to identify pericardial effusion and estimate its size, location and degree of haemodynamic impact. Echocardiography is also used to guide pericardiocentesis with excellent safety and efficacy. Signs of tamponade can be identified by echocardiography: swinging of the heart, early diastolic collapse of the right ventricle, late diastolic collapse of the right atrium, abnormal ventricular septal motion, exaggerated respiratory variability (>25%) in mitral inflow velocity, inspiratory decrease and expiratory increase in pulmonary vein diastolic forward flow, respiratory variation in ventricular chamber size, aortic outflow velocity (echocardiographic pulsus paradoxus) and inferior vena cava plethora.

### **DIFFERENTIAL DIAGNOSES OF PERICARDIAL EFFUSION AND CARDIAC TAMPONADE**

**The list of diseases for the differential diagnosis of pericardial effusion and cardiac tamponade includes:**

- Pneumotorax
- Tension pneumopericardium
- Post-cardiac injury syndromes
- Cardiogenic pulmonary edema
- Dilated cardiomyopathy
- Pulmonary embolism
- Pneumonia
- Costochondritis

**Pneumotorax.** The signs and symptoms: sudden onset shortness of breath, tachycardia, and chest pain. Pericarditis pain may be more positional in nature. Physical examination reveals absence of breath sounds, generally unilaterally.

**Tension pneumopericardium.** Hemodynamic changes in tension pneumopericardium simulate acute cardiac tamponade. Clinically, distant heart sounds, bradycardia, and shifting tympany occur over the precordium,

and a characteristic murmur, termed *bruit de la roue de moulin*. Tracheal deviation may also be present. Chest x-ray shows lung collapse.

**Post-cardiac injury syndromes** are a group of inflammatory pericardial syndromes including post-myocardial infarction pericarditis, post-pericardiotomy syndrome and post-traumatic pericarditis. Such syndromes are presumed to have an autoimmune pathogenesis triggered by initial damage to pericardial and/or pleural tissues caused by either myocardial necrosis (late post-myocardial infarction pericarditis or Dressler syndrome), surgical trauma, accidental thoracic trauma (traumatic pericarditis) or iatrogenic trauma with or without bleeding (pericarditis after invasive cardiac interventions).

**Cardiogenic pulmonary edema (CPE)** is defined as pulmonary edema due to increased capillary hydrostatic pressure secondary to elevated pulmonary venous pressure and reflects the accumulation of fluid with a low-protein content in the lung interstitium and alveoli as a result of cardiac dysfunction. Increased hydrostatic pressure leading to pulmonary edema may result from many causes, including excessive intravascular volume administration, pulmonary venous outflow obstruction (e.g., mitral stenosis or left atrial myxoma), and left ventricle failure secondary to systolic or diastolic dysfunction of the left ventricle. CPE leads to progressive deterioration of alveolar gas exchange and respiratory failure. Findings on chest x-ray are vascular redistribution, indistinct hilar and alveolar infiltrates.

**Dilated cardiomyopathy** is a disease of heart muscle that is characterized by ventricular chamber enlargement and progressive heart failure. The symptoms and signs: dyspnea on exertion, jugular venous distension, pulmonary edema, hepatomegaly, ascites or peripheral edema, cardiomegaly, heart murmurs, arrhythmias and gallops. Echocardiography confirms the ventricular cavities enlargement and low ejection fraction.

**Pulmonary embolism.** The signs and symptoms: chest pain can be anterior, posterior, or lateral in location. It is in phase with respiration (no chest pain when the patient ceases breathing) and is not positional in nature. Pericardial friction rub is rarely present. A pleural friction rub can be detected in 3% of patients. ECG may show ST-segment elevations limited to leads III, aVF, and V1; no PR depressions; Q-waves in leads III and/or aVF; inverted T-waves in leads II; aVF, anterior precordial leads while ST segments are elevated.

**Pneumonia** is associated with cough and fever. The presence of pneumonia may also be related to the presence of concomitant pericarditis.

Chest x-ray may show evidence of infiltrates.

**Costochondritis.** The signs and symptoms are:

- reproducible tenderness with palpation of the costochondral junctions;
- the pain is exacerbated by moving the trunk;
- normal physical examination;
- ECG and echocardiography.

**IV. Constrictive pericarditis.** The common causes of constrictive pericarditis are: idiopathic or viral (42–49%) post-cardiac surgery (11–37%), post-radiation therapy (9–31%) (mostly for Hodgkin's disease or breast cancer), connective tissue disorder (3–7%), post-infectious causes (tuberculosis or purulent pericarditis in 3–6%) and miscellaneous causes (malignancy, trauma, drug-induced, asbestosis, sarcoidosis, uraemic pericarditis in <10%). Constrictive pericarditis is characterized by impaired diastolic filling of the ventricles due to pericardial disease. The classic clinical picture is characterized by signs and symptoms of right heart failure with preserved right and left ventricular function in the absence of previous or concomitant myocardial disease or advanced forms. Patients complain about fatigue, peripheral oedema, breathlessness and abdominal swelling. The delay between the initial pericardial inflammation and the onset of constriction is variable and is possibly a direct evolution from subacute/chronic pericarditis to constrictive pericarditis. Venous congestion, hepatomegaly, pleural effusions and ascites may occur. Haemodynamic impairment of the patient can be additionally aggravated by a systolic dysfunction due to myocardial fibrosis or atrophy in more advanced cases. Diagnosis of constrictive pericarditis is based on the association of signs and symptoms of right heart failure and impaired diastolic filling due to pericardial constriction by one or more imaging methods, including echocardiography, CT, CMR, and cardiac catheterization. Specific diagnostic echocardiographic criteria for the diagnosis of constrictive pericarditis are: septal bounce or ventricular septal shift with either medial  $e'$  >8 cm/s or hepatic vein expiratory.

## DIFFERENTIAL DIAGNOSIS OF CONSTRICTIVE PERICARDITIS

**The list of diseases for the differential diagnosis of constrictive pericarditis includes:**

- Restrictive cardiomyopathy
- Systolic or diastolic congestive heart failure
- Tricuspid stenosis or tricuspid regurgitation



- Right-sided atrial tumors
- Superior vena cava syndrome and nephrotic syndrome
- Primary liver disease
- Ovarian carcinoma

**Restrictive cardiomyopathy** is a form of cardiomyopathies in which the walls are rigid, and the heart is restricted from stretching and filling with blood properly. Secondary causes of restrictive cardiomyopathy are: infiltrative processes sarcoidosis, amyloidosis, and hemochromatosis and cardiac fibrosis. The main symptoms and signs are the same as in constrictive pericarditis, and special investigations yield similar findings. The differentiating parameter is the systolic pressure changes in the right and left ventricle upon respiration: both pressures show concordant changes. The two pressures show discordant patterns in constrictive pericarditis: the systolic pressure rises in the right ventricle and falls in the left ventricle during inspiration, and it rises in the left ventricle and falls in the right ventricle during expiration.

This is different from the pattern seen in **restrictive cardiomyopathy**, in which during inspiration and expiration. Invasive pressure measurements in both conditions show rapid ventricular filling followed by a diastolic plateau. In constrictive pericarditis, the diastolic pressures are equal in all cardiac chambers and the systolic right ventricular pressure is 40 mmHg. In restrictive cardiomyopathy, the diastolic pressures are higher on the left side than on the right (5 mmHg), and generally the systolic right ventricular pressure is well above 40 mmHg. Moreover, the ejection fraction may be decreased in restrictive cardiomyopathy while it is generally preserved in constrictive pericarditis.

**Systolic or diastolic congestive heart failure:** from a number of causes, including pressure-overload and myocardial, valvular, or atherosclerotic disease.

**Tricuspid stenosis or tricuspid regurgitation** are right-sided valvular abnormalities that increase venous pressure and often have similar findings to constriction on physical examination. Holosystolic murmur increase with inspiration (Carvallo's sign) is characteristic. Echocardiography should readily identify these conditions.

**Right-sided atrial tumors, such as myxomas:** constriction by compressing the tricuspid valve can be distinguished with echocardiography, CT scan, cytology of pericardial fluid and eventually biopsies. Primary tumours of the pericardium, either benign (lipomas and fibromas) or malignant (mesotheliomas, angiosarcomas, fibrosarcomas) are very rare.



**Superior vena cava syndrome and nephrotic syndrome** can produce gross edema and ascites.

**Primary liver disease:** cirrhosis may present similarly to constriction.

**Ovarian carcinoma:** patients present with ascites and edema.

## BIBLIOGRAPHY

1. Adler Y., Charron Ph., Imazio M., et al. 2015 ESC Guidelines for the diagnosis and management of pericardial diseases: The Task Force for the Diagnosis and Management of Pericardial Diseases of the European Society of Cardiology (ESC). *European Heart Journal*, 2015; 36: 2921–2964 <https://doi.org/10.1093/eurheartj/>.
2. Bhardwaj R., Berzinger C., Miller C. Differential diagnosis of acute pericarditis from normal variant early repolarization and left ventricular hypertrophy with early repolarization: an electrocardiographic study. *Am J Med Sci* 2013; 345: 28–32.
3. Buiatti A., Merlo M., Pinamonti B., et al. Clinical presentation and long-term follow-up of perimyocarditis. *J Cardiovasc Med (Hagerstown)*. 2013; 14: 235–241.
4. Cosyns B., Plein S., Nihoyanopoulos P. on behalf of the European Association of Cardiovascular Imaging (EACVI) and European Society of Cardiology Working Group (ESC WG) on Myocardial and Pericardial diseases. European Association of Cardiovascular Imaging (EACVI) position paper: multimodality imaging in pericardial disease. *Eur Heart J Cardiovasc Imaging* 2014; 16: 12–31.
5. Imazio M. Pericardial involvement in systemic inflammatory diseases. *Heart* 2011; 97: 1882–1892.
6. Imazio M., Gaita F. Diagnosis and treatment of pericarditis. *Heart* 2015; 101: 1159–1168.
7. Klein A.L., Abbara S., Agler D.A., et al. American Society of Echocardiography clinical recommendations for multimodality cardiovascular imaging of patients with pericardial disease: endorsed by the Society for Cardiovascular Magnetic Resonance and Society of Cardiovascular Computed Tomography. *J Am Soc Echocardiogr* 2013; 26: 965–1012.e15.
8. Ristić A.D., Imazio M., Adler Y., et al. Triage strategy for urgent management of cardiac tamponade: a position statement of the European Society of Cardiology Working Group on Myocardial and Pericardial Diseases. *Eur Heart J* 2014; 35: 2279–2284.
9. Syed F.F., Schaff H.V., Oh J.K. Constrictive pericarditis—a curable diastolic heart failure. *Nat Rev Cardiol* 2014; 11: 530–544.
10. Welch T.D., Ling L.H., Espinosa R.E., et al. Echocardiographic diagnosis of constrictive pericarditis: Mayo Clinic criteria. *Circ Cardiovasc Imaging* 2014; 7: 526–534.
11. [www.mayoclinic.pure.elsevier.com/en/publication](http://www.mayoclinic.pure.elsevier.com/en/publication) (accessed 26.09.2018).
12. [www.academic.oup.com/eurheartj](http://www.academic.oup.com/eurheartj) (accessed 26.09.2018).

## DIFFERENTIAL DIAGNOSIS OF PULMONARY CONSOLIDATION

**DEFINITION.** Syndrome of pulmonary consolidation (infiltrate) represents a sum of symptoms and signs caused by loss of alveolar air and localized decrease of lung elasticity.

### **PATHOPHYSIOLOGY**

The loss of alveolar air commonly happens due to:

#### 1. *Substitution with*

- Inflammatory infiltrate (infection, e.g. pneumonia)
- Tumour tissue (cancer)
- Blood (pulmonary embolism, diffuse alveolar haemorrhage)
- Connective tissue (idiopathic or secondary pulmonary fibrosis)
- Parasite invasion (hydatid cyst)

#### 2. *Atelectasis* (segmental, lobar).

**The signs of pulmonary consolidation** include dyspnoea, tachypnoea, occasionally cyanosis and delay of the affected part of chest during breathing. If a large enough segment of parenchyma is involved, it can alter the transmission of air and sound. In the presence of consolidation, vocal fremitus becomes more pronounced on chest palpation. Localized subdull or dull percussion sound is commonly found on percussion. On chest auscultation localized pathological bronchial sound or decreased vesicular murmur with crackles or locally decreased vesicular murmur can be revealed.

### **Radiologic signs of lung consolidation**

Pulmonary opacities are characterized by their size, pattern and distribution.

Based on their size and extension, localized opacities (such as those found in lobar pneumonia or tuberculoma) are differentiated from diffuse opacities (such as those found in pulmonary edema, diffuse alveolar haemorrhage).

With regard to the pattern of infiltrates, infiltrates may occur with an acinar (alveolar) or interstitial pattern. Acinar (alveolar) infiltrates have the following characteristics: homogeneous density, tendency for confluence (Felson sign), air bronchograms and absence of lung volume loss. Interstitial infiltrates have the following characteristics: ground-glass opacity, inhomogeneous density, linear and reticular densities (Kerley A, B, and C lines), nodules, „honey combing” and loss of lung volume.

**The list of diseases for the differential diagnosis of lung consolidation includes:**

*Common diseases*

- Pneumonia
- Tuberculosis
- Malignancy (lung cancer, metastases)
- Lung abscess
- Pulmonary infarction due to pulmonary embolism
- Congestive heart failure (pulmonary edema)

*Less common diseases*

- Drug-induced lung disease
- Eosinophilic pneumonia
- Radiation pneumonitis
- Aspergillosis
- Cryptogenic organizing pneumonia
- Diffuse alveolar haemorrhage syndromes
- Atelectasis

**Pneumonia.** It is the most frequent cause of lung consolidation and represents an acute exsudative alveolitis of various infectious origin (bacterial, viral, fungal, protozoal) and of various setting (community-acquired, hospital-acquired, due to aspiration and in immunocompromised host). The clinical presentation of pneumonia usually starts with sudden onset, high fever, chills, dyspnoe, pleuritic chest pain, cough with or without sputum, tachycardia, and hypotension. Physical findings include: cyanosis, localized increased vocal fremitus, dullness on percussion, and bronchial breath sounds, end-inspiratory rales on auscultation.

General blood analysis reveals leukocytosis with pronounced left shift, lymphopenia (especially in viral pneumonia) and elevated erythrocyte sedimentation rate. Microscopic examination of the sputum reveals Gram-positive or Gram-negative microorganisms. Abundant amounts of Gram-positive diplococci identified in sputum are diagnostic for *Streptococcus pneumoniae*. Sputum culture allows to diagnose the causative pathogen of pneumonia and its *in vitro* sensitivity to antibacterials in case if the titer of microorganism is more than  $10^6$ . In hospitalized patients blood cultures are positive in one-fourth of cases, especially in severe pneumonia. Cultures from pleural effusion are positive in case of complicated pneumonia (pleural empyema). A rapid urinary antigen test (immunochromatographic test) can be performed to detect *Legionella* bacteria or *Streptococ-*

*cus pneumoniae* antigen (performed mostly in intensive care unit). Reverse transcription polymerase chain reaction test (RT-PCR) detects respiratory viruses, *Chlamydophila* spp., *Mycoplasma pneumoniae*, *Legionella pneumophila* in nasopharyngeal secretion samples and blood. The serologic assay showing increase of IgM 2-4 weeks after pneumonia onset is useful in case of *Chlamydophila pneumoniae*, *Chlamydophila psitaci*, *Mycoplasma pneumoniae*, *Legionella pneumophila* and protozoal pneumonia. Induced sputum or biopsy (e.g., transbronchial) and subsequent histopathologic demonstration of organism is necessary for the diagnosis of *Pneumocystis jiroveci* or other fungi, e.g., *Aspergillus* spp. C-reactive protein is increased (more than 6 mg/ml) and procalcitonin is usually higher than 2 ng/l in severe pneumonia.

Arterial blood gases examination reveals hypoxia, hypercapnia, respiratory acidosis. On the chest radiograph the infiltrates are dense, homogeneous, and clearly delineated with air bronchograms. Chest computered tomography is indicated in slowly/nonresolving pneumonia or in a rapid deterioration of patients condition. Fiberoptic bronchoscopy and biopsy are usefull in case of suspicion of endobronchial tumor and subsequent retrostenotic pneumonia, for obtaining aspirates to diagnose respiratory pathogens (especially in case of immunocompromised patients), for obtaining bronchoalveolar lavages (in case of suspicion of noninfectious origin of infiltrate, e.g., interstitial pneumopathies, sarcoidosis). Fiberoptic bronchoscopy with endobronchial ultrasound (EBUS) is necessary for transbronchial biopsy of lung tissue (e.g., neoplasia, idiopatic or secondary interstitial pneumopathies). It is important to mention that there is a positive clinical response and radiological resorption of pneumonia under antibacterial treatment. The resolution of infiltrates takes place within 4 to 8 weeks. Delayed resorption of infiltrates may indicate several possible conditions: 1) another diagnosis (e.g., tuberculosis, neoplasia, interstitial pneumonitis), 2) a complication (lung abscess), 3) a resistant microorganism (e.g., meticillin-resistant *Staphylococcus aureus*), 4) patients comorbidities (alcohol abuse, diabetes mellitus, chronic obstructive airway disease etc.).

**Tuberculosis.** Patients' epidemiological anamnesis may be consistent with risk factors for pulmonary tuberculosis:

- history of known close contact with someone who has active tuberculosis;
- immunocompromised status (e.g., those with an HIV infection, cancer, transplanted organs, and prolonged high-dose corticosteroid therapy);

- substance abuse (intravenous or injection drug users and alcoholics);
- presence of comorbidities (e.g., diabetes mellitus, chronic renal failure, malnourishment, hemodialysis, or transplanted organ);
- any person without an adequate health care (e.g., the homeless); institutionalization (e.g., long-term care facilities, psychiatric institutions, prisons);
- a health care worker performing high-risk activities (administration of aerosolized pentamidine and other medications, sputum induction procedures, bronchoscopy, suctioning, coughing procedures, caring for the immunosuppressed patient and administering anesthesia and related procedures (e.g., intubation, suctioning)).

Patients complain of subfebrile temperature, general malaise, weight loss, prolonged cough (more than 3 weeks), night sweats, blood streaked sputum, hemoptysis, regional lymphadenitis, and rarely erythema nodosum. There is a discrepancy between the lack of findings on chest examination and the presence of opacity on chest X-ray.

In active pulmonary TB chest X-ray findings usually include upper lobe infiltrates or cavitary lesions, although other pattern and localization may be seen. There is a non-resolving lung infiltrate under a nonspecific antibacterial treatment, or a recurrent infiltrate (an infiltrate that reappears after a discontinuation of fluoroquinolone therapy of pneumonia). Sputum, fluid, or biopsy of the involved tissue should be sent for appropriate stains (acid-fast, fluorescent and auramine-rhodamine) and cultures. The sputum should be obtained early in the morning and a minimum of 3 separate samples should be taken. Bronchoscopy with a bronchial lavage and biopsy may be required if the sputum fails to yield the diagnosis. Fine-needle aspiration of an affected area may reveal epithelioid cells and granuloma, but acid-fast bacillus (AFB) stains are frequently negative. Mycobacterial culture (gold standard) requires only 10 to 100 organisms to produce a positive result, and thus cultures can be revealing even in the presence of a negative smear. Genetic tests are able to confirm rapidly the presence of *Mycobacterium tuberculosis* (ex., GeneExpert MTB). In the presence of adenopathy, a lymph node biopsy should be considered as it may reveal caseating granulomas, positive acid-fast smears, and positive cultures. A purified protein derivative (PPD) skin test is useful in screening for prior mycobacterial infection.

**Lung cancer.** There are two types of lung cancer: small cell lung cancer (SCLC) and non-small cell lung cancer (NSCLC). NSCLC accounts for approximately 85% of all lung cancers. The three main cell types of NSCLC are squamous cell carcinoma, adenocarcinoma, and large-cell carcinoma.

Adenocarcinomas and large-cell cancers are predominantly peripheral, and squamous cell carcinomas are central tumors.

In patients with lung cancer the clinical symptoms and signs result from: 1) the local tumor growth, 2) tumor metastasis, and 3) paraneoplastic syndromes.

1. Clinical manifestations of lung cancer caused by local tumor growth and intrathoracic spread include cough, dyspnoea, chest pain, prolonged subfebrile fever, hemoptysis, loss of weight and retrosternal recurrent pneumonia. Vocal cord paralysis and superior vena cava syndrome are the symptoms of locally advanced disease. The presence of Pancoast syndrome typically results when a malignant neoplasm of the superior sulcus of the lung leads to destructive lesions of the thoracic inlet and the involvement of the brachial plexus and cervical sympathetic nerves accompanied by the following: severe pain in the shoulder region radiating toward the axilla and scapula, with later extension along the ulnar aspect of the arm to the hand, atrophy of hand and arm muscles, Horner syndrome (ptosis, miosis, hemianhidrosis, enophthalmos) and compression of the blood vessels with edema.

2. The most common sites of metastases are mediastinal lymph nodes, pleura, bones, liver, adrenal glands and brain. The signs and symptoms resulting from CNS involvement range from headaches or mental status changes to focal or generalized seizures.

3. The major categories of paraneoplastic syndromes include endocrine, neurologic, and cutaneous manifestations. In patients with lung cancer the most common paraneoplastic syndrome is the syndrome of inappropriate secretion of antidiuretic hormone, most frequently reported in patients with SCLC and manifesting as hyponatremia (<130 mmol/l). Humoral hypercalcemia of malignancy results from the secretion of a parathyroid hormone (PTH)-related protein. Eaton-Lambert syndrome (from SCLC) is a pseudomyasthenic syndrome, which presents with proximal limb muscle weakness and fatigue. Hypertrophic pulmonary osteoarthropathy is characterized by the formation of new periosteal bone in the digits and clubbing of the digits.

Physical examination may reveal loss of weight, pale skin, cyanosis (advanced stage), axillary, cervical, supraclavicular, and scalene regions lymphadenopathy. The signs of airway obstruction (localized dry rales) or pleural effusion (localized dullness on percussion, no transmission of vesicular murmur) and hepatomegaly can be found additionally to physical findings of lung consolidation.

Chest radiograph can present as a mass, peripheral nodule, hilar or mediastinal changes, pleural effusions, or metastatic disease. Previous chest

X-rays are needed to see the temporal progression of the lesions (a nodule that is stable over a period of 2 years is unlikely to be malignant). Chest X-ray may reveal areas of atelectasis which suggest an endobronchial growth of cancer. Computed tomography offers better visualization of the nodule and more sensitive detection of mediastinal lymph node involvement and it can also help identify local invasion of the chest wall and pleura. Positron emission tomography (PET) is a useful to complete the staging workup in patients with recently diagnosed NSCLC. Magnetic resonance imaging (MRI) of the chest is helpful in the setting of suspected spinal cord, vascular, or chest wall involvement. Sputum cytologic examination is most useful in patients with centrally located tumors. Flexible fiberoptic bronchoscopy is helpful in determining the endobronchial extent of disease and biopsy, brushings and bronchioloalveolar lavage. Endobronchial ultrasound is used to biopsy some of the mediastinal lymph nodes and left-sided lesions.

Both Hodgkin's and Non-Hodgkin's lymphoma and metastatic cancer (malignant melanoma, adenocarcinoma of the breast or gastrointestinal tract, or Kaposi's sarcoma) can present with pulmonary involvement. Loss of weight and/or hilar, mediastinal or peripheral adenopathy should prompt further investigation. Fiberoptic bronchoscopy and transbronchial biopsy are necessary for the diagnosis.

**Lung abscess** is defined as necrosis of the pulmonary tissue and formation of cavities containing necrotic debris or fluid caused by microbial infection. The suspicion for lung abscess should be raised in case of persistence of high fever in pneumonia treated with antibacterials, especially in immunocompromised host and in alcohol abuse. The formation of multiple small (<2 cm) abscesses is occasionally referred to as necrotizing pneumonia. Both lung abscess and necrotizing pneumonia are manifestations of a similar pathologic process. The usual symptoms are fever, cough with sputum production, night sweats, anorexia, and weight loss. The expectorated sputum characteristically is foul smelling and bad tasting. Patients may develop hemoptysis or pleurisy. Physical examination findings of a patient with lung abscess are variable: temperatures higher than 38.5°C, patients have evidence of gingivitis and/or periodontal disease and digital clubbing. Clinical findings of concomitant consolidation (e.g., decreased breath sounds, dullness to percussion, bronchial breath sounds, inspiratory crackles) may be present. Dullness on percussion, contralateral shift of the mediastinum, and absent breath sounds over the effusion are associated with pleural effusion, empyema, and pyopneumothorax.



Confirmatory laboratory and instrumental findings include:

- general blood analysis (leukocytosis, anemia, elevated erythrocyte sedimentation rate);
- chest X-ray (opacity with central cavitation);
- sputum gram's stain (1 predominant gram-positive or -negative organism and neutrophils in aerobic infections;
- mixed flora with many neutrophils in anaerobic infections);
- sputum culture (growth of normal respiratory flora in polymicrobial etiology);
- blood culture (positive for infecting organism in aerobic infection);
- empyema fluid culture (may be negative in polymicrobial anaerobic infections;
- growth of infecting organism in aerobic infections);
- CT chest (thick-walled, usually round cavity with irregular margins forming an acute angle with chest wall, no signs of compression of surrounding lung);
- bronchoscopy (proximal airway obstruction by a tumour or foreign body);
- quantitative cultures of protected specimen brushings (> 1000 colony-forming units/ml of fluid);
- quantitative cultures of protected bronchoalveolar lavage samples (> 10 000 or 100 000 colony-forming units/ml);
- percutaneous needle aspiration and culture (growth of infecting organism);
- sputum cytology (malignant cells in underlying malignancy);
- lung ultrasound (hypoechoic lesion with irregular outer wall and cavity appearing as a hyperechoic ring);
- echocardiogram (vegetations on the affected valve in bacterial endocarditis);
- chest angioCT (intraluminal filling defects in pulmonary embolism).

**Pulmonary infarction due to pulmonary embolism.** Infarction pneumonia corresponds to secondary infection of pulmonary infarction. The cause of pulmonary embolization, including the source of the emboli (e. g., deep vein thrombosis in the lower extremities, myxoma of the right atrium) and risk factors for thrombosis (immobility, recent surgery, neoplasms) should always be taken into consideration.

The following signs are consistent with infarction pneumonia: rapid



deterioration of general condition, persisting fever and tachycardia, sudden dyspnea associated with a feeling of oppression, tachycardia, pleuritic chest pain, purulent sputum, with or without hemoptysis, progressive leukocytosis, a cavitation of the pulmonary infiltrate, an accentuated second pulmonary heart sound, and gallop rhythm. Extensive pulmonary emboli may cause hypotension and cyanosis. As the chest wall excursions on the corresponding side may be reduced, rales and pleural rub may not be pronounced or appear only later in the course of the disease.

The levels of blood bilirubin, lactate dehydrogenase (LDH), ALAT, ASAT may be elevated due to right-sided heart failure with congestion of the liver. Serum D-dimer (a product of fibrin degradation) is increased. ECG may reveal right branch block, S1Q3T3, sinus tachycardia, paroxysm of atrial fibrillation or atrial flutter. Pulmonary function tests reveal a restrictive ventilatory defect and reduced diffusing capacity. Arterial blood gas analysis shows hypoxemia and respiratory alkalosis (due to hyperventilation). A typical wedge-shaped infiltrate extending from the hilum to the chest wall with or without pleural effusion is not always seen and the infiltrates may be similar to pneumonia of other origin. Echocardiography demonstrates increased systolic pressure in the pulmonary artery, dilatation of the right atrium and ventricle. Spiral-angio-CT demonstrates the intravascular emboli and confirms the diagnosis.

**Congestive heart failure.** Patients may have cough with mucous or pink sputum, dyspnoe, ortopnoe, acrocyanosis, pitting peripheral edema. The anamnesis is consistent with chronic cardiovascular disease and factors leading to heart failure (e.g., acute myocardial infarction, hypertensive crisis, arrhythmias etc.). Auscultation reveals predominantly basal pulmonary rales. Chest X-ray shows localized unilateral or bilateral reticular infiltrates due to pulmonary interstitial edema, cardiomegaly, redistribution of the pulmonary circulation from predominantly lower zones to lower and upper zones, increased caliber of pulmonary veins, Kerley A and B lines, and right-sided or bilateral pleural effusions. There is a rapid radiological resolution of infiltrates (48-72 hours) following the treatment of heart failure, diuretics inclusively. Sputum examination with Berlin blue staining reveals hemosiderine-containing macrophages. There are elevated levels of seric BNP (brain natriuretic peptide), decreased ejection fraction and dilated cardiac cavities on echocardiography, and changes on ECG (e.g., ST elevation in acute myocardial infarction).

**Drug-induced pneumonitis.** A number of drugs (e.g., amiodarone,

methotrexate, bleomycin) can cause pulmonary consolidation. Illicit drugs associated with pulmonary disease include heroin (smoked or injected) and crack cocaine. Fever, nonproductive cough and dyspnoea are the usual presentation of drug-induced pneumonitis and occur within weeks or months of initiating therapy/illicit drug use. Chest radiograph abnormalities may be absent early on but infiltrates usually develop and may localize to mimic pneumonia. A detailed drug history should be obtained from all patients and/or their relatives at presentation. High-resolution CT scan of the chest and fiberoptic bronchoscopy are helpful to exclude the possibility of an infectious or other non-infectious aetiology as an alternative diagnosis. Drug-induced infiltrate is commonly resolved after the discontinuation of the drug and corticosteroid administration.

**Eosinophilic pneumonia.** *Acute eosinophilic pneumonia* usually presents with an acute history of nonproductive cough, dyspnoea, and fever. Diffuse parenchymal opacities, rather than localized consolidation, are typically seen on chest radiograph. Initial full blood count shows a neutrophilic leucocytosis but patients with severe progressive disease may develop an eosinophilia. Diagnosis is made by fiberoptic bronchoscopy with bronchioalveolar lavage demonstrating a significant eosinophilia. The patients develop progressive respiratory failure without treatment. The treatment with glucocorticoids results in rapid improvement.

*Transient eosinophilic pulmonary infiltrates (Löffler).* Transient eosinophilic pulmonary infiltrates may be due to larvae of three types of worms passing the pulmonary vessels on their way to the gastrointestinal tract: *Ascaris lumbricoides*, hook worms, and *Strongyloides stercoralis*. Patients complain of nonproductive cough and general malaise. The radiologic infiltrates are typically transient and disappear over the course of approximately two weeks. Blood eosinophilia varies between 7–70%. The total leukocyte count is not significantly elevated. Maximal eosinophilia lags a few days behind the pulmonary infiltrates. As transient pulmonary infiltrates are most commonly caused by *Ascaris* infection, these eggs may be identified in stools, and not at the time of the pulmonary infiltrates but about two months later.

**Radiation pneumonitis.** It occurs after radiation therapy of cancers of the breast, lungs, esophagus, and mediastinum (thymoma, Hodgkin and non-Hodgkin lymphoma). Radiation therapy of breast or lung cancer leads to alterations in the chest radiograph in about one-third of patients, and in 10% of patients it causes clinical symptoms. Radiation pneumonitis is observed between one and six months after the end of treatment. It is asso-

ciated with a slowly progressive cough, fever, and dyspnea. After duration of up to one month, spontaneous restitution usually occurs. Radiation therapy of breast cancer may cause bronchiolitis obliterans organizing pneumonia (BOOP), a syndrome associated with dyspnea, fatigue, and varying unilateral and bilateral infiltrates. Pulmonary function tests reveal a restrictive ventilatory defect and reduced diffusing capacity. The chest radiograph shows focal or confluent, patchy or reticular infiltrates.

**Aspergillosis.** Aspergillosis is the most common invasive mold infection and is caused by *Aspergillus* spp. The main route of infection is inhalation of spores which colonize the lungs, nose, and paranasal sinuses. *Aspergillus* spp. cause disease in humans by tissue invasion, colonization, and subsequent allergic reaction (allergic bronchopulmonary aspergillosis); and colonization of preexisting cavities (fungus ball or aspergilloma).

The main risk factors that promote invasive aspergillosis are: prolonged and profound neutropenia ( $< 500 \times 10^9/l$ ) especially in bone marrow transplant recipients; high dose corticosteroid therapy; broad-spectrum antibiotic therapy; chronic granulomatous disease; acquired immune deficiency syndrome (AIDS) with CD4 counts  $< 50$  cells/mm<sup>3</sup>; and treatment with immunosuppressive agents.

Invasive aspergillosis with pulmonary involvement may present as acute bronchopneumonia with symptoms like dyspnoea, cough, hemoptysis, fever and cavitation on imaging, or slowly progressive bronchopneumonia. Invasive aspergillosis may also present with extrapulmonary involvement of the central nervous system, heart, bone, or skin. Peripheral blood eosinophilia, and elevated serum IgE levels, anti-*Aspergillus* IgM, IgG can be revealed. The diagnosis of invasive aspergillosis is ideally established based on a combination of culture results and histologic proof of tissue invasion. *Ex juvantibus* criteria include positive clinical and radiological response to the treatment with voriconazole, amphotericin B, or caspofungin.

**Cryptogenic organizing pneumonia.** Cryptogenic organizing pneumonia (COP) is the idiopathic form of organizing pneumonia and is from the group of idiopathic interstitial lung diseases. Patients are usually in their fifties or sixties and present with dyspnoea, cough and fever. The chest radiograph features of COP are typically bilateral with areas of patchy or diffuse consolidation or ground glass infiltrates. It is necessary to exclude known causes of COP such as drugs and rheumatic diseases (rheumatoid arthritis, systemic lupus erythematosus). The diagnosis requires high resolution chest computerized tomography, transbronchial lung biopsy and sub-

sequent histology or video-assisted thoracoscopy with biopsy. *Ex juvantibus* criterion: treatment with glucocorticoids usually results in clinical and radiological improvement.

**Diffuse alveolar haemorrhage.** The diffuse alveolar haemorrhage syndromes are characterised by bleeding into the alveolar spaces and may result from a number of causes (e.g., prolonged anticoagulant therapy, Wegener granulomatosis, Goodpasture syndrome). Haemoptysis is the usual predominant symptom but it may be absent. General examination may reveal features of a vasculitic or rheumatological disorder. The chest radiograph often shows diffuse bilateral opacities. The diagnosis is made by fiberoptic bronchoscopy and sequential bronchioalveolar lavage.

**Atelectasis.** Atelectasis is defined as lung parenchyma not containing air, which is due to obstruction (e.g., endobronchial cancer, foreign body) or compression (e.g., pneumothorax, pleural effusion). The main symptom is dyspnoea. Physical examination allows the detection of relatively large atelectases. Radiologically, the most important radiologic characteristics are: localized opacity, volume loss, absence of air bronchograms, displacement of a fissure, elevation of the diaphragm, displacement of the mediastinum including the trachea, displacement of the hilum, reduced intercostal space. The diagnosis of the cause of atelectasis requires CT of the chest and fiber-bronchoscopy.

## BIBLIOGRAPHY

1. Haroon A., Higa F., Haranaga S., et al. Differential diagnosis of non-segmental consolidation. *J Pulmon Resp Med* 2013, S8. <http://dx.doi.org/10.4172/2161-105X.S8-001> (accessed 30.08.2017)
2. Reynolds J.H., Banerjee A.K. Imaging pneumonia in immunocompetent and immunocompromised individuals. *Curr Opin Pulm Med* 2012; 8: 194-201.
3. Jeong Y.J., Kim K.I., Seo I.J., et al. Eosinophilic lung diseases: a clinical, radiologic, and pathologic overview. *Radiographics* 2007; 27: 617-637.
4. Franquet T. Imaging of pneumonia: trends and algorithms. *Eur Respir J* 2001; 18: 196-208.
5. Ito I., Ishida T., Togashi K., et al. Differentiation of bacterial and non-bacterial community-acquired pneumonia by thin-section computed tomography. *Eur J Radiol* 2009; 72: 388-395.
6. Black A.D. Non-infectious mimics of community-acquired pneumonia. *Pneumonia* 2016; 8:2. DOI 10.1186/s41479-016-0002-1 <https://pneumonia.biomedcentral.com/articles/10.1186/s41479-016-0002-1> (accessed 08.09.2017)

7. Musher D.M., Thorner A.R. Community-acquired pneumonia. *N Engl J Med* 2014; 371:1619–1628.
8. Sialer S., Liapikou A., Torres A. What is the best approach to the nonresponding patient with community-acquired pneumonia? *Infect Dis Clin North Am* 2013; 27:189–203.
9. Müller B., Harbarth S., Stolz D., et al. Diagnostic and prognostic accuracy of clinical and laboratory parameters in community-acquired pneumonia. *BMC Infect Dis* 2007; 7:10. PMID:17335562, <http://dx.doi.org/10.1186/1471-2334-7-10>.
10. Bhatt M.L.B., Kant S., Bhaskar R. Pulmonary tuberculosis as differential diagnosis of lung cancer. *South Asian J Cancer* 2012; 1 (1): 36-42.
11. Xu K., Tang X., Song Y., Chen Z. The diagnosis dilemma between pulmonary embolism with positive chest imaging and pneumonia: a case report and literature review. *J Transl Med Epidemiol* 2015; 3 (1): 1039. [www.jscimedcentral.com/TranslationalMedicine/translationalmedicine-3-1039.pdf](http://www.jscimedcentral.com/TranslationalMedicine/translationalmedicine-3-1039.pdf) (accessed 20.09.2017)
12. Paparoupa M., Spineli L., Framke T., Ho H., Schuppert F., Gillissen A. Pulmonary embolism in pneumonia: still a diagnostic challenge? Results of a case-control study in 100 patients. Hindawi Publishing Corporation. *Disease Markers*, Volume 2016, Article ID 8682506. <http://dx.doi.org/10.1155/2016/8682506> (accessed 20.09.2017)
13. <http://online.epocrates.com/diseases/1735/community-acquired-pneumonia/Differential-Diagnosis> (accessed 25.09.2017)

## DIFFERENTIAL DIAGNOSIS OF BRONCHO-OBSTRUCTIVE SYNDROME

**DEFINITION.** Broncho-obstructive syndrome (BOS) is the collective term including a symptom-complex of outlined clinical implications of disturbance of bronchial permeability, having in the basis narrowing or an occlusion of respiratory tracts.

**PATHOPHYSIOLOGY.** *Basic mechanisms of bronchial obstruction include:*

- 1) bronchial muscle spasm;
- 2) edema and infiltration of bronchial mucosa and submucosa;
- 3) overproduction of sputum and dyskrinia (viscous sputum);
- 4) sclerosis of bronchial wall;
- 5) expiratory collapse of bronchi;
- 6) mechanical factors (a foreign body in the lumenus of bronchus, compression of bronchus from outside).

### CLINICAL PRESENTATION

Symptoms commonly include dyspnea (expiratory and/ or insiratory), chronic cough, (initially intermittent, then become daily and often whole day and only rarely at night) and chronic expectoration of sputum.

*Physical examination.* Inspection reveals cyanosis, finger clubbing, barrel-like chest (in case of emphysema) and pitting edema (in case of right heart failure). Chest palpation reveals diffusely decreased tactile fremitus in case of emphysema. On chest percussion there is hyperresonant sound (in emphysema or asthma attack), moving the upper limit of the lungs upwards and lowering the lower limit of the lungs and limitation of lower lung border mobility. Chest auscultation can reveal the following changes: wheezes and/ or rhonchi (as a hallmark) or diffusely decreased vesicular murmur (in emphysema) or unchanged (in a controlled bronchial asthma).

**Spirometry** is an obligatory method to confirm the presence of broncho-obstructive syndrome. In a typical case, an obstructive defect is present in the form of normal or reduced forced vital capacity (FVC), reduced FEV<sub>1</sub>, ratio FEV<sub>1</sub>/FVC < 70%, documentation of reversibility (>12% of FEV<sub>1</sub> improvement after 20 minutes of a short-acting bronchodilator administration) of airway obstruction, reduced forced expiratory flow over 25-75% of the FVC (FEF 25-75) and the flow-volume loop can be concave.

Body plethysmography: increased residual volume (RV) and increased total lung capacity (TLC) in case of emphysema.

*Common causes of bronchial obstruction:*

- Bronchial asthma
- Chronic obstructive pulmonary disease (COPD)
- Acute bronchitis
- Left heart failure
- Gastroesophageal reflux disease
- Chronic sinusitis
- Bronchiectasis
- Pulmonary embolism

*Less common causes of bronchial obstruction:*

- Alpha1-antitrypsin deficiency
- Aspergillosis
- Cystic fibrosis
- Tuberculosis of bronchi
- Local obstruction by tumor or foreign body aspiration
- Bronchiolitis
- Vocal cord dysfunction
- Sarcoidosis
- Tracheomalacia
- Carcinoid syndrome
- Churg-Strauss syndrome

**Bronchial asthma.** The symptoms and signs include: increased night-time cough, cough or wheezing with physical activity, tiredness with activities, restless sleep or waking up tired, worsening allergy symptoms (allergic rhinitis, dark circles under eyes or skin allergy). Anamnestic clues for the diagnosis: episodes may be exacerbated by exposure to irritants such as tobacco smoke or fumes from chemicals. Attacks may occur seasonally, attacks may occur upon exposure to pets and onset is in the childhood, adolescence or youth. Physical examination may be normal. The examination of the nasal passages reveals nasal polyposis or nasal congestion. Chest auscultation reveals expiratory wheezes. In severe asthma the wheezes are audible without the use of a stethoscope. In patients with severe exacerbations, status asthmaticus, the lung examination reveals diffusely decreased vesicular murmur, patients may use accessory muscles of respiration. Pulmonary function testing in bronchial asthma includes: decreased forced expiratory volume in the first second (FEV1), normal forced vital capacity

(FVC) and decreased FEV1/FVC ratio less than 70%. The diagnosis of asthma is confirmed by demonstrating reversibility of airflow obstruction (usually defined as improvement in FEV1 by at least 12% and 200 mL) to short-acting bronchodilator.

Peak expiratory flow rate (PEFR) in bronchial asthma demonstrates:

- Diurnal variability (defined as  $[\text{evening PEFR} - \text{morning PEFR}] / 0.5x [\text{evening PEFR} + \text{morning PEFR}]$ );
- The diagnosis of asthma is supported if PEFR varies by at least 20% for 3 days a week over several weeks;
- PEFR increases by at least 15% in response to asthma treatment (reversibility).
- In a patient with bronchial asthma sputum contains eosinophyles, Charcot – Leiden crystals and Kurshman spirals.

**Chronic obstructive pulmonary disease (COPD)** is a disorder in which subsets of patients may have dominant features of chronic bronchitis or emphysema and the onset is in the middle age in a patient with a history of smoking. The result is airflow obstruction that is not fully reversible. Chronic bronchitis is defined clinically as the presence of chronic productive cough for 3 months during each of 2 consecutive years (other causes of cough being excluded). Emphysema is defined pathologically as an abnormal, permanent enlargement of the air spaces distal to the terminal bronchioles, accompanied by destruction of their walls and without obvious fibrosis.

Patients typically present with a combination of signs and symptoms of chronic bronchitis, emphysema, and reactive airway disease: cough, usually worse in the mornings and productive of a small amount of colorless sputum, expiratory dyspnea and wheezing. During exertion and exacerbations the symptoms worsen, e.g., there is an increase of amount and purulency of sputum. Physical examination reveals the following: tachypnea and respiratory distress (in exacerbation), use of accessory respiratory muscles and paradoxical indrawing of lower intercostal spaces (Hoover sign), cyanosis, elevated jugular venous pulse, peripheral edema, hyperinflation (barrel chest), hyperresonance on percussion, diffusely decreased breath sounds and wheezes.

Certain characteristics allow differentiation between a disease that is predominantly emphysema (type A) and that which is predominantly chronic bronchitis (type B). Type A characteristics include the following: patients may be very thin with a barrel chest, little or no cough or expectoration, breathing may be assisted by pursed lips and use of accessory respira-



tory muscles, patients may adopt the tripod sitting position, the chest may be hyperresonant and heart sounds are very distant. Type B characteristics include the following: obesity, frequent cough and expectoration, use of accessory muscles of respiration, coarse rhonchi and wheezing on auscultation and signs of right heart failure due to cor pulmonale such as jugular vein distension, edema, hepatomegaly and cyanosis. Systemic extrapulmonary manifestations of COPD include: systemic inflammation, skeletal muscles wasting, erythrocytosis, anemia, osteopenia and osteoporosis.

In COPD the pulmonary function tests are as follows: obstructive pattern on a flow volume loop, reduction in forced expiratory flow in the first second (FEV<sub>1</sub>), reduction of FEV<sub>1</sub>/forced vital capacity (FVC) ratio < 70%, increased residual volume (RV), increased total lung capacity (TLC) and partial or complete irreversibility of bronchial obstruction (< 12% of FEV<sub>1</sub> improvement after 20 minutes of a short-acting bronchodilator administration). Chest radiographs reveal the following: flattening of the diaphragm, increased retrosternal air space, a long, narrow heart shadow, rapidly tapering vascular shadows accompanied by hyperlucency of the lungs; increased bronchovascular markings and cardiomegaly (in bronchitic phenotype). HRCT scans show small subpleural areas of hyperlucency characteristic of paraseptal emphysema and a phenomenon of air trapping seen on CT performed in expiration. Arterial blood gas (ABG) findings are as follows: moderate hypoxemia without hypercapnia; as the disease progresses, hypoxemia worsens and hypercapnia may develop, pH usually is near normal; a pH below 7.3 generally indicates acute respiratory compromise.

**Acute bronchitis.** The disease has an acute onset and is a part of upper respiratory tract infection with concomitant rhinitis, pharyngitis, laryngitis, fever up to 38° C, myalgias, arthralgias and occasionally chills, dry cough, mucopurulent sputum, expiratory dyspnoe, wheezes and rhonchi on lung auscultation. Chest X-ray (performed to exclude the presence of lung consolidation) is usually unchanged or reveals increased bronchial markings. Full blood count demonstrates leukocytosis with the left shift and moderately elevated ESR. The manifestations of bronchial obstruction in acute bronchitis are usually fully reversible after the administration of short-course glucocorticosteroids and bronchodilators.

**Left heart failure.** About 25% of patients with left heart failure may present with wheezing, expiratory dyspnoe, wheezes and rhonchi with or without bilateral basal crackles on lung auscultation. It is important to take

a detailed patient's history (e.g., coronary artery disease, arterial hypertension, valvular heart defect). Suggestive physical findings are acrocyanosis, orthopnoea, dependent oedema, elevated jugular venous pressure, elevated blood pressure, decreased  $S_1$  on apex, pathological  $S_3$ , different arrhythmias (e.g., atrial fibrillation), hepatomegaly, anasarca. An important biological marker is BNP (brain natriuretic peptide) which is elevated in serum. ECG demonstrates the presence of arrhythmias, ST elevation, signs of hypertrophy of the left ventricle. Chest X-ray shows increased alveolar markings, fluid in fissures, Kerley A and B lines, pleural effusions, rapid clearing after treatment of underlying disease, especially with diuretics. The echocardiogram reveals reduced left ventricular ejection fraction, dilatation of cardiac cavities (especially the left ones), presence of hypokinesia zones, presence of valvular heart defects etc.

**Gastroesophageal reflux disease** (see Differential diagnosis of dysphagia)

**Chronic sinusitis.** Chronic sinusitis may present with nocturnal and morning cough and dyspnoea from post-nasal discharge. It may co-exist with bronchial asthma. Anterior rhinoscopy and nasal endoscopy reveal inflammation, purulent discharge, oedema and polyps. Computed tomography shows mucosal thickening of the respective sinus and air-fluid level.

**Bronchiectasis.** The suggestive clinical features are as follows: dyspnoea, cough with abundant mucopurulent or purulent sputum, wheezing, occasionally hemoptysis, and recurrent pulmonary infections (*Meticillin-resistant Staphylococcus aureus*, *Pseudomonas aeruginosa*, *Aspergillus spp.*) 3 per year or more. High-resolution CT chest shows dilated airways, bronchial wall thickening and ring sign (the diameter of bronchus is more than the diameter of the adjacent artery). Fiberoptic bronchoscopy is helpful for the detection of bronchiectasis, obtaining secretions for culture and treatment.

**Allergic bronchopulmonary aspergillosis (ABPA)** is a hypersensitivity reaction resulting in the formation of IgE and IgG antibodies to *Aspergillus fumigatus* that has colonized bronchi of patients with asthma or cystic fibrosis. The main clinical features include: expiratory dyspnea, wheezing, fever, malaise, expectoration of brownish mucus plugs and haemoptysis. Full blood count usually reveals eosinophilia. Serological tests are positive for anti-*Aspergillus* Ig G, Ig E. To obtain the evidence of *Aspergillus* infection the sediment from bronchoalveolar lavage should be centrifuged and processed as a cell block. The sections stained with Hematoxylin and Eosin and with PAS-diastase reveal septate fungal hyphae with dichotomous branching, characteristic of *Aspergillus*. Chest CT shows multiple

thickwalled cavitory pulmonary nodules. *Ex juvantibus* criterion: ABPA may regress under control measures, corticosteroids, and itraconazole.

**Alpha1-antitrypsin deficiency** is a relatively common genetic condition, characterized by the absence of protein in the alpha1 region of the SPEP. The main clinical features are slowly progressive dyspnea, cough, sputum production, wheezing and concomitant liver disease. The family history of the patient is consistent with parents or grandparents dying of lung/ liver disease. Confirmatory diagnostic test: decreased serum alpha-1 antitrypsin. Computed tomography of the chest shows emphysematous bullae in the lower lung lobes, there is also increased lung density in the areas with compression of lung tissue by the bullae. The genotype testing demonstrates the presence of the Z or M (Malton) alleles. *Ex juvantibus* criterion: intravenous augmentation therapy with alpha1-antitrypsin benefits some patients.

**Cystic fibrosis (CF).** CF is an autosomal recessive genetic disease of abnormal secretions from exocrine glands that involves multiple organ systems caused by a defect in the gene which codes for cystic fibrosis transmembrane conductance regulator (CFTR). Respiratory symptoms and signs usually start in childhood and may include the following: cough, recurrent wheezing, recurrent pneumonias, dyspnea on exertion, chest pain, nasal polyps, tachypnea, respiratory distress with retractions, wheeze or crackles, cough, mucoid or purulent sputum, digital clubbing, cyanosis, increased anteroposterior chest diameter, hyperresonant sound on percussion. The gastrointestinal symptoms include the following: meconium ileus, abdominal distention, intestinal obstruction, increased frequency of stools, flatulence, steatorrhea, recurrent abdominal pain, dry skin, jaundice, gastrointestinal bleeding, abdominal distention, hepatosplenomegaly and rectal prolapse. The genitourinary symptoms include undescended testicles or hydrocele, delayed secondary sexual development and amenorrhea. The requirements for CF diagnosis include either positive genetic testing or positive sweat chloride test findings and 1 of the following: typical course of chronic obstructive pulmonary disease, documented exocrine pancreatic insufficiency (e.g., decreased level of fecal elastase) and positive family history (usually an affected sibling). The parameters for the sweat chloride test are as follows: the reference value is less than 40 mmol/l, a value higher than 60 mmol/l of chloride is consistent with CF, a value of 40-60 mmol/l is considered borderline, and the test must be repeated. Imaging studies that may be helpful include the following: X-rays (chest, sinus, abdomen),

CT of the chest, abdominal ultrasound and contrast barium enema. Chest X-ray and CT findings: atelectasis (discoid, segmental, lobar with right upper lobe predominance), mucoid impaction (nodular and fingerlike densities along bronchovascular bundle), cylindrical bronchiectasis or cysts, hilar adenopathy, pulmonary arterial hypertension, recurrent pneumothorax and cor pulmonale. Additional tests that may be warranted are as follows: genotyping, nasal potential difference measurement, pulmonary function testing, bronchoalveolar lavage, sputum microbiology (recurrent respiratory infections with *Staphylococcus aureus*, *Pseudomonas aeruginosa*).

**Tuberculosis of bronchi.** Bronchial obstruction may be caused by the accumulation of caseous masses in the lumen of bronchi. The clinical picture of tuberculosis (see Differential diagnosis of pulmonary consolidation) is accompanied by expiratory dyspnoea and wheezes on lung auscultation. Chest CT and fiberbronchoscopy with biopsy and culture are necessary to confirm the diagnosis.

**Local obstruction by tumor or foreign body aspiration.** The main features include: wheezing, shortness of breath and occasional stridor. If the foreign body is in the peripheral airway, localized one-sided wheezing or collapse of the distal lung tissue is found. Chest X-rays and CT chest show sign of atelectasis. CT chest or bronchoscopy shows the foreign body or endobronchial tumor.

**Vocal cord dysfunction.** Vocal cord dysfunction (VCD), or paradoxical vocal fold motion, is characterized as an abnormal adduction of the vocal cords during the respiratory cycle (especially during the inspiratory phase) that produces airflow obstruction at the level of the larynx without an organic basis. The larynx receives very extensive sensory and motor innervation. In repeated stimulation and excitation by noxious intrinsic and extrinsic irritants, these nerve fibers may become hyperexcitable and hyperresponsive and the threshold for activation of the reflex responsible for vocal cords closure is lowered. VCD frequently mimics persistent bronchial asthma with the symptoms of wheezing, cough, and dyspnea often being treated with corticosteroids and bronchodilators. It is important that patients with VCD often seem to have refractory asthma with poor response to beta-agonists or inhaled corticosteroids and they do not usually report nocturnal awakening due to breathlessness. Flow-volume loops obtained during spirometry show a limitation of inspiratory flow suggestive of variable extrathoracic obstruction (inspiratory loop flattening). The paradoxical vocal cord motion can be confirmed on laryngoscopy performed

when patients are symptomatic. The hallmark of diagnosis is noted on direct laryngoscopy: a glottic chink is present along the posterior portion of the vocal cords, while the anterior portion of the vocal cords is adducted.

**Tracheomalacia.** Expiratory stridor and a barking cough, and wheezing with additional breath sound at the end of expiration are accompanied by the occasional extension of the neck with breathing, inspiratory stridor, episodes of holding of breath, anoxia, recurrent respiratory infections, retraction of intercostal and subcostal muscles, failure to thrive, and respiratory and cardiac arrest. The symptoms are usually positionally dependent and occur within the first weeks or months of life. Confirmatory methods of diagnosis include laryngoscopy, bronchoscopy, barium esophagography (useful for evaluating associated tracheoesophageal fistula and reflux disease).

**Carcinoid syndrome (due to carcinoid neuroendocrine tumors).** Malignant carcinoid syndrome occurs in fewer than 10% of patients with a carcinoid tumor of neuroendocrine origin. These tumors follow the so-called rule of one third, which states as follows: one third of these tumors are multiple, one third of those in the gastrointestinal tract are located in the small bowel, one third of patients have a second malignancy and one third of these tumors metastasize.

It is known that carcinoids may produce: serotonin, gastrin, adrenocorticotrophic hormone, histamine, acid phosphatase,  $\alpha$ -glycoprotein,  $\alpha$ 1-antitrypsin, amylin, atrial natriuretic polypeptide, catecholamines, chromogranin A and B, dopamine, fibroblast growth factor, gastrin, gastrin-releasing peptide (bombesin), glucagon/glicentin, 5-hydroxyindoleacetic acid (5-HIAA), 5-hydroxytryptamine (5-HT), insulin, kallikrein, motilin, A-Neuropeptide, K-Neuropeptide, neurotensin, pancreastatin, pancreatic polypeptide, platelet-dermal growth factor, prostaglandins, secretin, somatostatin, substance P, somatotropin release-inhibiting factor, tachykinins,  $\beta$ -transforming growth factor ( $\beta$ -TGF) and vasoactive intestinal polypeptide (VIP).

Malignant carcinoid syndrome is characterized by hot, red flushing of the face, severe diarrhea and asthma attacks caused by vasoactive hormones secreted by metastases from carcinoid tumors. Flushing is a phenomenon in which transient vasodilation causes reddening of the face, head, neck, and the upper chest and epigastric areas. Flushing is the most frequent symptom and may be brief (2-5 min) or may last for several hours, usually in later disease stages. Flushing may be accompanied by tachycardia, while the blood pressure usually falls or does not change. Some patients

also develop telangiectasia on the face and neck. Right heart problems may develop because of the development of tricuspid valve insufficiency. Bronchial constriction, which accounts for the asthma-like attacks, seems related to the tumoral tachykinins. Carcinoid crisis is a dangerous life-threatening condition that can occur at the time of surgery. It is characterized by a sudden and profound drop in blood pressure causing shock, sometimes accompanied by tachycardia, high blood glucose, and severe bronchospasm.

Carcinoid tumors can be found by endoscopy, barium small intestinal X-ray studies, capsule enteroscopy. Their diagnosis requires a biopsy to provide a tissue sample. Metastatic carcinoid tumors can be diagnosed by CT or MRI scans, indium 111 octreotide scans, and bone scans. The biochemical diagnosis of carcinoid tumors is based on the measurement of the serotonin metabolite 5-HIAA in a 24-hour urine collection (normal value = 0-8.9 mg/d, a urinary excretion of 5-HIAA of 25 mg/d is diagnostic of carcinoid) and elevated Chromogranin A in blood.

**Acute bronchiolitis** is a leading cause of hospital admission in infants under 1 year of age and Respiratory syncytial virus is the most common aetiological agent. Most cases are mild and self-limited, and supportive care is the only indicated therapy. Recurrent wheezing is a common complication, and it can be treated with inhaled corticosteroids and leukotriene antagonists.

**Sarcoidosis** is a multisystem inflammatory disease of unknown etiology that manifests as noncaseating granulomas, predominantly in the lungs and intrathoracic lymph nodes. The presentation in sarcoidosis varies with the extent and severity of organ involvement, as follows: systemic complaints (fever, anorexia), pulmonary complaints (dyspnea on exertion, cough, chest pain, and rare hemoptysis), Löfgren syndrome (fever, bilateral hilar lymphadenopathy, and polyarthralgias). On physical examination the pulmonary findings are as follows: no changes, crackles or wheezes may be audible, exertional oxygen desaturation. Dermatologic manifestations may include the following: erythema nodosum, a lower-extremity panniculitis with painful, erythematous nodules (often with Löfgren syndrome), lupus pernio, and violaceous rash on the cheeks or nose. Ocular involvement, which may lead to blindness if untreated, may manifest as follows: anterior or posterior granulomatous uveitis, conjunctival lesions and scleral plaques. Other possible manifestations are as follows: bone involvement, heart failure from cardiomyopathy, heart block and sudden death, lymphocytic meningitis, cranial nerve palsies and hypothalamic/pituitary dysfunction.

Laboratory and imaging studies for sarcoidosis are as follows: 1) laboratory abnormalities (elevated ESR, hypercalcemia, hypercalciuria, elevated alkaline phosphatase level and elevated angiotensin-converting enzyme (ACE) levels); 2) Chest radiography which is central to the evaluation of the disease staging (*Stage 0*: Normal chest radiographic findings; *Stage I*: Bilateral hilar lymphadenopathy; *Stage II*: Bilateral hilar lymphadenopathy and infiltrates; *Stage III*: Infiltrates alone; *Stage IV*: Fibrosis); 3) High-resolution CT (HRCT) scanning of the chest (identifies active alveolitis versus fibrosis, and findings correlate with biopsy yield); 4) pulmonary function tests (a restrictive pattern is usually seen and 15-20% of patients have obstructive pattern), a decreased carbon monoxide diffusion capacity (DLCO); 5) bronchoscopy with transbronchial biopsy (the main histologic finding is the presence of noncaseating granulomas with special stains negative for fungus and mycobacteria). *Ex juvantibus* criterion: systemic corticosteroids usually effective until stage IV of the disease.

**Churg-Strauss syndrome.** Churg-Strauss syndrome, or eosinophilic granulomatosis with polyangiitis, is a rare systemic necrotizing antineutrophil cytoplasmic antibody (ANCA)-associated vasculitis that affects small-to-medium-sized vessels and is associated with severe asthma and blood and tissue eosinophilia. The American College of Rheumatology proposed the following six criteria for the diagnosis of Churg-Strauss syndrome (CSS): asthma (wheezing, expiratory rhonchi), eosinophilia of more than 10% in peripheral blood, paranasal sinusitis, transient pulmonary infiltrates, histological proof of vasculitis with extravascular eosinophils and mononeuritis multiplex or polyneuropathy. CSS has three phases, as follows: 1) allergic rhinitis and asthma; 2) eosinophilic infiltrative disease (e.g., eosinophilic pneumonia or gastroenteritis); 3) systemic medium- and small-vessel vasculitis with granulomatous inflammation. The vasculitic phase usually develops within 3 years of the onset of asthma, although it may be delayed for several decades. The most prominent symptoms and signs are those related to pulmonary, cardiac, dermatologic, renal, and peripheral nerve involvement. The following symptoms and signs of the disease were reported: constitutional symptoms (malaise, fatigue, flu-like symptoms, weight loss, fever and myalgias), respiratory symptoms (persistent expiratory dyspnea even treated with corticosteroids, nasal discharge due to paranasal sinusitis, allergic rhinitis or nasal polyposis, cough and hemoptysis), arthralgias, skin manifestations (skin nodules, urticarial rash, necrotic bulla, digital ischemia), cardiac manifestations (heart failure, myo-



carditis, pericarditis and myocardial infarction), gastrointestinal symptoms due to eosinophilic gastritis or colitis (abdominal pain, diarrhea and gastrointestinal bleeding). Laboratory findings include: eosinophilia, usually with at least 10% eosinophils (or 5000-9000 eosinophils/ $\mu$ L), anemia and elevation of ESR in complete blood cell count; proteinuria, microscopic hematuria, and red blood cell casts in urinalysis; elevated blood urea nitrogen (BUN) and serum creatinine levels in case of renal involvement; the presence of antineutrophil perinuclear antimyeloperoxidase cytoplasmic antibodies (p-ANCA); elevated serum IgE levels, hypergammaglobulinemia, positive results for rheumatoid factor at low titer, elevated levels of ECP – eosinophil cationic protein and sIL-2R – soluble interleukin-2 receptor (indicate an immunoregulatory defect associated with vasculitis and eosinophilia); elevated sTM – soluble thrombomodulin (a marker of endothelial cell damage). Bronchoscopy with bronchoalveolar lavage reveals eosinophilia. CT chest may reveal small (< 10 mm) centrilobular nodules, ground-glass opacities, bronchial wall thickening, bronchial dilatation, consolidation, interlobular septal thickening and unilateral or bilateral pleural effusion. Other imaging studies are: abdominal CT scanning for pancreatitis, coronary angiography for myocardial ischemia and infarction, and echocardiography for congestive heart failure.

## BIBLIOGRAPHY

1. Price D.P., Yawn B.P., Jones R.C.M. Improving the differential diagnosis of chronic obstructive pulmonary diseases in primary care. *Mayo Clin Proc* 2010; 85 (12): 1122-1129.
2. Mosenifar Z. Differentiating COPD from asthma in clinical practice. *Postgrad Med* 2009; 121(3):105-112.
3. O'Donnell A.E. Bronchiectasis. *Chest* 2008; 134: 815–823.
4. Stoller J.K., Aboussouan L.S. A review of  $\alpha$ 1-antitrypsin deficiency. *Am J Respir Crit Care Med* 2012; 185(3): 246-59.
5. Borowitz D., Parad R.B., Sharp J.K., et al. Cystic Fibrosis Foundation practice guidelines for the management of infants with cystic fibrosis transmembrane conductance regulator-related metabolic syndrome during the first two years of life and beyond. *J Pediatr* 2009; 155 (Suppl 6): S106-16.
6. Savant A.P., McColley S.A. Cystic fibrosis year in review 2016. *Pediatr Pulmonol* 2017; 52 (8):1092-1102.
7. Bendelow J., Apps E., Jones L.E., et al. Carcinoid syndrome. *Eur J Surg Oncol* 2008; 34(3): 289-96.



8. Bahrainwala A.H., Simon M.R. Wheezing and vocal cord dysfunction mimicking asthma. *Curr Opin Pulm Med* 2001; 7(1): 8-13.
9. Groh M., Pagnoux C., Baldini C., et al. Eosinophilic granulomatosis with polyangiitis (Churg-Strauss) (EGPA) Consensus Task Force recommendations for evaluation and management. *Eur J Intern Med* 2015; 26 (7): 545-53.
10. Polverino E., Goeminne P.C., McDonnell M.J., et al. European Respiratory Society guidelines for the management of adult bronchiectasis. *Eur Respir J* 2017; 50: 1700629 [<https://doi.org/10.1183/13993003.00629-2017>].
11. Lowe S. T. Eosinophilic Granulomatosis with Polyangiitis (Churg-Strauss Syndrome) Clinical Presentation. <https://emedicine.medscape.com/article/333492-clinical> (accessed 15.09.2017)

## DIFFERENTIAL DIAGNOSIS OF DIFFUSE INTERSTITIAL LUNG DISEASES

**DEFINITION.** Diffuse interstitial lung diseases (DILD) are a group of diseases that have the common characteristic of involving the pulmonary parenchyma diffusely. DILD are numerous, there are some 150 different entities that qualify for the group. Most of these diseases are diagnosed according to common algorithm, but the etiology, prognosis and therapy are quite different. Idiopathic pulmonary fibrosis (IPF) is defined as a specific form of chronic, progressive fibrosing interstitial pneumonia of unknown cause, occurring primarily in older adults, and limited to the lungs.

**PATHOPHYSIOLOGY.** A large and diverse group of pathologic conditions manifests clinically and radiologically as diffuse parenchymal lung disease. In practice, this group of disorders has been categorized on the basis of clinical dysfunction (“restrictive lung disease”) or radiologic appearance (“interstitial lung disease (ILD)”), neither of which accurately reflects the pathologic processes involved. Diffuse ILDs encompass mainly inflammatory processes that involve the structural elements of this organ. Some ILDs are caused by infections, but most are the result of immunologic, environmental, or toxic mechanisms. These diseases are discussed together because they have in common the tendency to produce bilateral abnormalities on chest imaging studies and are mainly nonneoplastic conditions. A small number of diffuse inflammatory conditions came to light that exclusively involved the lungs and did not seem to be caused by infection, toxin, sarcoidosis, pneumoconiosis, or neoplasm.

*The known causes* are diverse inorganic agents leading to pneumoconioses (asbestos, silica, etc.), organic, causing hypersensitivity pneumonitis (farmer’s lung, bird fancier’s lung, etc.), drugs, irradiation, toxic gases and fumes, bacteria, fungi, viruses, protozoa, and parasitic infections or infestations. The inflammatory process is limited specifically to the area between the alveolar epithelium. This group of pulmonary disorders frequently involves: alveolar epithelium, alveolar space, pulmonary microvasculature, respiratory bronchioles, larger airways and capillary endothelial basement membranes. There are also many other causes of interstitial lung disease. In some cases, the cause of interstitial disease is also unknown. Occasionally, interstitial disease is associated with a familial cause or specific genetic disease. All the possible etiologic factors, including environmental or occupational, have to be excluded for a DILD to be considered idiopathic.

**Classification of Diffuse Interstitial Lung Disease (DILD)***DILD OF KNOWN CAUSE*

- Anorganic particles – pneumoconiosis
- Organic particles – hypersensitivity pneumonitis
- Gases
- Fumes
- Irradiation
- Microbes

*IDIOPATHIC INTERSTITIAL PNEUMONIAS*

- Idiopathic pulmonary fibrosis (IPF)
- Non – specific interstitial pneumonia (NSIP)
- Organizing pneumonia (OP)
- Desquamative interstitial pneumonia (DIP)
- Respiratory bronchiolitis – interstitial lung disease (RB – ILD)
- Lymphoid interstitial pneumonia (LIP)
- Pleuropulmonary fibroelastosis (PPFE)

*GRANULOMATOSIS*

- Sarcoidosis
- Granulomatosis with polyangitis ( Wegener’s granulomatosis)
- Churg – Strauss syndrome
- Necrotizing sarcoid granuloma
- Lymphomatoid granulomatosis
- Bronchocentric granulomatosis
- Langerhans cell histiocytosis (LCH)
- Erdheim – Chester disease

*RARE DPLD*

- Alveolar proteinosis
- Alveolar mikrolithiasis
- Amyloidosis
- Eosinophilic pneumonia
- Lymphangiomyomatosis (LAM)
- Idiopathic pulmonary hemosiderosis
- Pulmonary manifestation of connective tissue diseases

Idiopathic interstitial pneumonias according to new classification comprise of several entities, among them there is a new entity called pleuropulmonary fibroelastosis. The inclusion of a category of unclassifiable group of DILD is also, of great help to practicing physicians. The everyday life experience resulted in this change, because almost 30% of these diseases

even after the most complete and thorough examination, stay unclassifiable. The third group consists of diseases that histologically show the pattern of granuloma, like sarcoidosis. And finally, the fourth group consists of diverse, mostly rare diseases. Among them are diffuse connective tissue diseases (systemic lupus erythematosus, rheumatoid arthritis, systemic sclerosis, ankylosing spondylitis, mixed connective tissue), lymphangioloiomatosis, alveolar proteinosis and alveolar microlythiasis. Some of these diseases are benign and self-limiting, others are chronic, progressive, irreversible, and fatal. The lung manifestation may be the one manifestation of a systemic process. Or it may be the only organ affected. All DPLDs, however, have certain common clinical, imaging, and physiologic features that should be recognized.

*Revised ATS/ERS classification of idiopathic interstitial pneumonias (IIPs)*

#### MAJOR Idiopathic Interstitial Pneumonia

- Idiopathic pulmonary fibrosis
- Idiopathic nonspecific interstitial pneumonia
- Respiratory bronchiolitis – interstitial lung disease
- Desquamative interstitial pneumonia
- Cryptogenic organizing pneumonia
- Acute interstitial pneumonia

#### RARE Idiopathic Interstitial Pneumonia

- Idiopathic lymphoid interstitial pneumonia
- Idiopathic pleuroparenchymal fibroelastosis

#### UNCLASSIFIABLE Idiopathic Interstitial Pneumonia

**Causes of unclassifiable idiopathic interstitial pneumonia include:** inadequate clinical, radiologic, or pathologic data and major discordance between clinical, radiologic, and pathologic findings that may occur in the following situations: previous therapy resulting in substantial alteration of radiologic or histologic findings (e.g., biopsy of desquamative interstitial pneumonia after steroid therapy, which shows only residual nonspecific interstitial pneumonia; new entity, or unusual variant of recognized entity, not adequately characterized by the current American Thoracic Society/European Respiratory Society classification (variant of organizing pneumonia with supervening fibrosis); and multiple high-resolution computed tomography and/or pathologic patterns that may be encountered in patients with idiopathic interstitial pneumonia.

## COMMON CLINICAL FEATURES

The most common symptoms of diffuse interstitial lung disease are shortness of breath and dry cough. As the disease progresses, weight loss, exercise limitation, retrosternal chest pain (in sarcoidosis), myalgias, arthralgias, and fatigue may also occur. At a more advanced stage, patients may develop right heart failure, finger clubbing, and cyanosis. Auscultation of the lungs reveals end inspiratory crackle and velcro crackles. Wheezing is present in 20% of the patients with hypersensitivity pneumonitis as well as the squawk, the ominous auscultatory sign, typical for advanced pulmonary hypertension. Pulmonary hypertension and cor pulmonale become evident when the signs include a loud P2, right-sided precordial lift, jugulovenous distension with a prominent A wave, and right-sided gallop.

Some extrapulmonary signs can be useful in differential diagnosis:

- Digital clubbing – for idiopathic pulmonary fibrosis (IPF) and asbestosis;
- A maculopapular rash – for connective-tissue diseases or drug-induced lung disease;
- Erythema nodosum – for sarcoidosis;
- Raynaud phenomenon – for connective-tissue diseases, especially in scleroderma;
- Teleangiectasia – for scleroderma;
- Peripheral lymphadenopathy, salivary gland enlargement and hepatosplenomegaly – for sarcoidosis;
- Uveitis – for sarcoidosis and ankylosing spondylitis;
- Palpable purpura – for vasculitis.

## DIAGNOSTIC APPROACH

The most helpful diagnostic procedures are radiographic imaging, chest X-ray and high resolution computed tomography (HRCT), bronchoscopy with bronchoalveolar lavage and transbronchial lung biopsy. To determine the cause of interstitial lung disease, a physician may perform a physical examination and administer diagnostic tests, including:

**Chest X-rays.** The patterns of lung damage associated with various types of interstitial lung disease are often identifiable on chest x-rays. Chest x-rays may also be used to track the progression of interstitial lung disease.

**Chest HRCT** (high resolution computed tomography) is the most important imaging method for the assessment of ILD owing to its sensitivity and specificity. In addition, it plays a specific role, such as assessment

of disease activity and potential reversibility, prediction and evaluation of response to therapy.

**Spirometry** reveals decreased FEV1 (forced expiratory volume in 1 second) and FVC (forced vital capacity), consecutively, an increased FEV1/FVC ratio.

**Body plethysmography** is absolutely necessary to observe a reduced RV (residual volume) and reduced total lung capacity (TLC).

**DLCO** (the measurement of the diffusing capacity for carbon monoxide), an indicator of the adequacy of the alveolar-capillary membrane, is helpful to differentiate chest bellows (DLCO normal) from parenchymal disease (DLCO decreased).

**Bronchoalveolar lavage** (BAL) has expanded the understanding of the pathogenesis of many interstitial lung diseases. The minimally invasive bronchoalveolar lavage (BAL) procedure is an important diagnostic instrument that can facilitate the diagnosis of various diffuse parenchymal lung diseases (DPLD). BAL fluid white blood cell profiles are analyzed, malignant cells looked for, and in certain circumstances particular stains are performed to detect yet other cell types. Additionally, BAL can play a very important role in the diagnosis of respiratory tract infections.

**Surgical biopsy:** A surgical biopsy may be needed to obtain a larger tissue sample than it is possible with bronchoscopy. During this procedure, surgical instruments and a small camera are inserted through two or three small incisions between ribs, allowing a physician to see and remove tissue samples from the lungs.

**Serum and BAL biomarkers.** There are limited retrospective data on the predictive value of serum and BAL biomarkers in IPF. KL-6 is a high-molecular-weight glycoprotein, classified as human MUC1 mucin that is produced by regenerating type II pneumocytes. Serum levels of KL-6 have been shown to be elevated in patients with IPF, and these levels may correlate with increased risk of subsequent mortality. Serum levels of surfactant protein A and D are also elevated. Alternative diagnostic hypotheses should be in patients with IPF and are predictive of survival.

## DIFFERENTIAL DIAGNOSIS

**Idiopathic interstitial pneumonias (IIPs)** are a heterogeneous group of non-neoplastic lung diseases in which the lung parenchyma is damaged by varying patterns of inflammation and/or fibrosis. The American Thoracic Society/European Respiratory Society classification of IIPs, published in

2002 (and currently under revision), defines the morphological patterns on which clinical, radiological and pathological diagnosis of IIPs is found in 50–70% of the biopsy-proven cases. When present, it allows a noninvasive diagnosis to be made with other IIPs, a confident diagnosis requires biopsy.

**Idiopathic pulmonary fibrosis** The term IPF refers to a distinct type of chronic fibrosing pneumonia of unknown cause. It is the most common of the IIPs, accounting for about 50–60% of IIP cases. The prognosis is usually dismal, with a median survival time of 2–4 years from diagnosis. On chest HRCT, IPF is characterized by the UIP pattern, which is predominantly subpleural with an apical–basal gradient. Specific findings of UIP pattern include honeycombing, peripheral reticular opacities that determine irregular interfaces between the lung and pleura, intralobular interstitial thickening with minimal abnormality, traction bronchiectasis and bronchiolectasis. Lower lobe volume loss is also a common finding.

**Nonspecific interstitial pneumonia** is a pathological term used to describe interstitial inflammation and fibrosis with temporal and spatial uniformity that does not fulfil the clinical–pathological criteria. NSIP can be observed in a number of conditions, such as collagen vascular diseases, inhalation of organic/inorganic antigens, hypersensitivity pneumonitis, drug toxicity or slowly resolving acute lung injury. When no associated process can be found in a patient with a histological and radiological pattern of NSIP, the diagnosis of idiopathic NSIP is made. On HRCT, the disease is usually distributed bilaterally with basal and peripheral predominance. The most common feature is peripheral irregular linear or reticular opacities in 50% of cases. Consolidation occurs in 20% of patients. Traction bronchiectasis and micronodules can also be present. The differentiation between fibrotic NSIP and UIP requires surgical lung biopsy. At present, there is no single feature or combination of HRCT features that have high specificity for a histological diagnosis of NSIP. The features of UIP and organising pneumonia may overlap with fibrotic and cellular NSIP.

**Cryptogenic organizing pneumonia (COP)** is often secondary to a known cause such as collagen vascular disease, viral pneumonia or drug reactions. The term COP, which refers to idiopathic organizing pneumonia, better defines the disease previously known as bronchiolitis obliterans with organizing pneumonia (BOOP), as the main abnormality is the organizing pneumonia whereas the bronchiolar obstruction may be absent in up to one-third of the cases. HRCT features of COP are represented by multiple areas of consolidations, which are commonly bilateral, patchy and

asymmetric, peripheral, and migrating (in up to 90% of cases). The lower lung zones are more frequently affected. Other HRCT findings include small centrilobular nodules, irregular lines, and the 'atoll sign' or 'reversed halo sign' representing peripheral consolidation. The lung volumes are generally preserved. COP tends to involve preferentially the subpleural and bronchovascular regions of the lung parenchyma. Bronchial dilation and air bronchogram associated with regions of consolidation can also be present. The imaging findings in these cases can often be mistaken for pneumonic consolidation. However, the foci of consolidation generally involve the lower lung zones and have a tendency to migrate, especially in the case of relapses, reported in one-third of cases. Few cases progress to irreversible fibrosis, probably representing the overlap between organizing pneumonia and NSIP.

**Respiratory bronchiolitis-associated ILD** is a part of the spectrum of smoking-related lung diseases. It is a distinct histopathological lesion found in the lungs of virtually all cigarette smokers. It usually represents an incidental finding and, as such, is of little clinical significance. Much less often, patients who are heavy smokers develop RB-ILD, a clinical-pathological entity characterized by pulmonary symptoms, abnormal pulmonary function test (PFT) results and imaging abnormalities, with respiratory bronchiolitis being the histological lesion on surgical lung biopsy. It is possible that RB-ILD and DIP are similar processes but at the opposite ends of the disease spectrum. The most common HRCT findings are centrilobular nodules, patchy and thickening of the bronchial walls, which predominate in the upper lobes accumulation in the distal airspaces. Upper lobe emphysema is also commonly present as a result of smoking. Air trapping is frequently seen in expiratory scans. A small percentage of patients has a reticular pattern in the absence of honeycombing and traction bronchiectasis. The differential diagnosis of RB-ILD includes acute hypersensitivity pneumonitis, DIP and NSIP. An important finding that may help to distinguish RB-ILD from DIP is the presence of centrilobular nodules and unusual presence of cyst formations in RB-ILD.

**Desquamative interstitial pneumonia** is a rare form of ILD. DIP is strongly associated with cigarette smoking and is considered to represent the end of a spectrum of RB-ILD. DIP may also occur in nonsmokers and has been related to a variety of conditions, including lung infections, exposure to organic dust and marijuana smoke inhalation. For the majority of patients, the onset of symptoms is between 30 and 40 years of age.



Males are affected about twice as commonly as females. The prognosis is good with smoking cessation and corticosteroid therapy. On HRCT, DIP is characterized by diffuse or patchy GGOs, which is caused by diffuse macrophage infiltration of the alveoli, and thickening of the alveolar septa with peripheral and basal lung predominance. Lung biopsy is required for a definite diagnosis.

**Lymphoid interstitial pneumonia** can be idiopathic, exceedingly rare, or secondary to systemic disorders, in particular Sjogren's syndrome, HIV infection and variable immunodeficiency syndromes. LIP is more common in females than in males, and patients are usually in their fifth decade of life at presentation. HRCT shows bilateral abnormalities that are diffuse or have lower lung predominance. Another frequent finding is thin-walled perivascular cysts. They are the only finding that may be irreversible. In contrast to the subpleural, lower lung cystic changes in UIP, the cysts of LIP are usually within the lung parenchyma throughout the mid-lung zones and presumably result from air trapping due to peribronchiolar cellular infiltration. Occasionally, centrilobular nodules and septal thickening are seen.

**Acute interstitial pneumonia** is acute respiratory distress syndrome (ARDS) of unknown cause. The disease commonly has a symmetric, bilateral distribution with lower lobe predominance. Areas of consolidation are also present but usually they are less extensive and limited to the dependent area of the lung. In the early phase, airspace consolidation results from intra-alveolar oedema and haemorrhage. However, consolidations are also present in the fibrotic phase, thus resulting from intra-alveolar fibrosis. In the late phase of AIP, architectural distortion, traction bronchiectasis within consolidation and honeycombing are the most striking CT features and represent fibrotic change. They are more severe in the non-dependent areas of the lung. This can be explained by the 'protective' effect of atelectasis and consolidation on the dependent areas of the lung during the acute phase of disease, which attenuate the potential damage associated with mechanical ventilation.

**Hypersensitivity pneumonitis** is an immunologically induced inflammatory disease involving the lung parenchyma and terminal airways secondary to repeated inhalation of a variety of organic dusts and other agents in a sensitized host. Classically, it can be separated into three phases: acute, subacute and chronic, depending on the temporality relative to initial exposure. A significant clinical and radiological overlap can often occur

between these phases. Acute hypersensitivity pneumonitis presents within a few hours of substantial antigen exposure. HRCT scans, rarely obtained at this stage, demonstrate diffuse or geographic distribution, and mosaic perfusion areas due to air trapping (better or only recognized on expiratory scans). Subacute hypersensitivity pneumonitis occurs in response to intermittent or low-dose antigen exposure. HRCT is particularly helpful at this stage of diseases and is characterised by varying proportions with poorly defined centrilobular nodules and areas of decreased attenuation, due to constrictive bronchiolitis with expiratory air trapping. Chronic hypersensitivity pneumonitis occurs after long-term, low-dose antigen exposure and usually shows a fibrotic pattern resembling UIP or fibrotic NSIP. HRCT findings include irregular reticular opacities, small nodules, honeycombing and traction bronchiectasis as well as areas of air trapping and spared lobules, with a heterogeneous appearance, called the 'head cheese sign'. Open lung biopsy is required to make a definite diagnosis in borderline cases.

**Sarcoidosis** (see Differential diagnosis of Broncho – Obstructive Syndrome)

**Eosinophilic pneumonia** (see Differential diagnosis of pulmonary consolidation)

**Pneumoconiosis** is a lung condition that is caused by inhaling particles of mineral dust, usually while working in a high-risk, mineral-related industry. Initially, irritating mineral dust can trigger lung inflammation, which causes areas of the lung to be temporarily damaged. Over time, these areas can progress to form tough, fibrous tissue deposits (fibrosis). Fibrosis stiffens the lungs and interferes with the lung's normal exchange of oxygen and carbon dioxide.

There are several different types of pneumoconiosis.

**Asbestosis** is the general name for a family of irritating fibrous minerals that are mined from underground deposits and used in the manufacture of home insulation, fireproof materials, tiles for floors and ceilings, and other products. Workers with the highest asbestos exposure include miners, construction workers, demolition workers, shipbuilders and those who work with brakes. Asbestos exposure can also affect people who live or work in buildings where asbestos-containing building products are deteriorating. In most cases, signs of asbestosis do not develop for 20 or more years after a person is first exposed to asbestos dust.

**Silicosis** affects people who work with silica, usually in the form of quartz that is found in sand, sandstone, slate, some clays, granite and other

ores. Workers with the highest exposure to silica include sandblasters, miners, tunnel builders, silica millers, quarry workers, foundry workers and those who make ceramics or glass. Silicosis can cause progressive fibrosis in the lung with a significant decrease in lung function, especially in cigarette smokers.

**Coal worker's pneumoconiosis** is caused by inhaling carbon particles from coal, graphite, black lamp or black carbon. It most often affects people who mine, process or ship coal; graphite miners; and workers who manufacture synthetic graphite, black lamp or black carbon. Coal worker's pneumoconiosis, like silicosis can cause significant fibrosis, primarily in miners who have worked for decades without protective equipment.

**Talc pneumoconiosis** is caused by exposure to talc dust, usually during talc mining or milling. Talc pneumoconiosis can also lead to lung fibrosis.

**Siderosis of the lung** is caused by inhaling iron particles. Although welder's lung often looks abnormal on a chest X-ray, it usually does not cause any symptoms.

Less often, pneumoconiosis can be caused by inhaling barium sulfate, tin oxide, compounds containing hard metal (cobalt and tungsten carbide) or other forms of mineral dust.

The diagnosis of pneumoconiosis requires the recognition of occupational exposure, the existence of an adequate latency period, the exclusion of extraprofessional causal factors, and the presence of compatible clinical, radiological and functional respiratory aspects. The CT scan performed with high-resolution technique (HRCT) shows – small opacity with regular or irregular shape which also defines the location and profusion, large opacities, ground glass, honeycombing and emphysema.

The pathological diagnosis of asbestosis is made in the presence of a diffuse pulmonary fibrosis with a particular pattern of asbestos bodies and/or fibers attesting a relevant exposure. In asbestosis the interstitial fibrosis is located in the basilar and subpleural regions as in idiopathic pulmonary fibrosis (IPF) which is the main differential diagnosis. In addition to the presence of asbestos bodies and fibers, histologically asbestosis differs from IPF in the poor inflammatory component and the lesser presence of fibroblastic foci. The very early stages, characterized by bronchiolitis, pose a difficult diagnostic problem because lesions are very similar to those smoked-related. In any case, peribronchiolar fibrosis does not represent asbestosis. The most common form of silicosis (chronic simple silicosis) occurs after a latency period of at least 10 years and can be as long as 40

years. A more rapid onset is caused by intense exposure: the clinical appearance is similar, but the latency is shorter (5–10 years). In asbestosis and silicosis the most important factor in determining fibrosis is the cumulative dose.

Idiopathic pulmonary fibrosis complete workup and environmental history reveals an absence of history of significant exposure to mineral dust or metal. There are no other differentiating signs and symptoms. CXR imaging or HRCT show lower lobe linear fibrosis. There is a negative beryllium lymphocyte proliferation test (BeLPT). Lung biopsy does not show increased mineral content.

**Pulmonary vasculitis** may occur as a part of one of the connective tissue disorders or in the course of a systemic granulomatous or hypersensitivity vasculitis.

**Wegener's granulomatosis** is an uncommon autoimmune disease characterized by small vessel inflammation, most often involving the respiratory or renal systems. The etiology is currently unknown, evidence suggests that environmental factors and a genetic predisposition interact to create an inappropriate autoimmune response. Wegener's granulomatosis is characterized by the presence of anti-neutrophil cytoplasmic antibodies (ANCA) which have long been suspected of the involvement in disease pathology and by necrotizing vasculitis initially described as involving three organ systems: the lung, the upper respiratory tract, and the kidneys.

Lung involvement usually takes the form of single or multiple nodular lesions that have a propensity to cavitate. In the limited form of Wegener's granulomatosis, patients have a similar pathology but are free of renal disease. Both diseases respond well to cyclophosphamide. Lymphomatoid granulomatosis resembles Wegener's but differs in three important features: there is frequent central nervous system involvement; more than 15% develop malignant lymphoma, and although cyclophosphamide may achieve remission, relapses are very common.

In hypersensitivity vasculitis, pulmonary involvement is a less prominent part of systemic disease. The disorders in which this is most commonly seen are anaphylactoid purpura, essential mixed cryoglobulinemia, and vasculitis associated with malignancy, infection, or drugs.

**Goodpasture syndrome** There is a similarity between the two, because each is initially a respiratory disorder complicated by glomerulonephritis. In each the glomerular lesions vary from deposits of fibrinoid material through exudative and proliferative reactions towards complete oblite-

ration of all glomeruli. Pulmonary lesions, however, differ markedly. The typical lesion in Goodpasture's syndrome is hæmorrhage into the lungs giving rise eventually to pulmonary siderosis, whereas in Wegener's syndrome there is replacement of the lining of bronchi and accessory nasal sinuses by necrotizing granulomatous tissue which may simulate carcinoma or tuberculosis. Widespread arteritis is a constant feature of Wegener's granulomatosis, but it is seldom found in Goodpasture's syndrome. Although renal biopsy cannot distinguish between the two conditions, it is helpful in directing attention to these disorders. Biopsy of the upper air passages, however, may be diagnostic in Wegener's granulomatosis. In Goodpasture's syndrome, corticosteroids may have caused some mitigation of the disorder, but in the case of Wegener's granulomatosis in which corticosteroids were used, any benefit was only temporary. Patients are tested for serum anti-GBM antibodies by indirect immunofluorescence testing or, when available, direct enzyme-linked immunosorbent assay (ELISA) with recombinant or human NC-1  $\alpha$ 3. The presence of these antibodies confirms the diagnosis. Antineutrophil cytoplasmic antibodies (ANCA) testing is positive (in a peripheral pattern) in only 25% of patients with Goodpasture syndrome. If anti-GBM antibodies are absent and patients have evidence of glomerulonephritis (hematuria, proteinuria, red cell casts detected with urinalysis, renal insufficiency, or a combination of these findings), renal biopsy is indicated to confirm the diagnosis. Immunofluorescence staining of renal or lung tissue classically shows linear IgG deposition along the glomeruli. These disorders are nonspecific and do not occur in linear patterns.

**Churg-Strauss syndrome** (see Differential diagnosis of broncho-obstructive syndrome).

**Collagen-vascular diseases (CVDs)** involve the lungs either directly or as a complication of treatment of CVD. Several different components of the respiratory system may be involved, including the airways, vessels, parenchyma, pleura, and respiratory muscles. Interstitial lung diseases (ILD) are common pulmonary complications of the CVDs. Approximately 15% of patients with interstitial lung disease have an underlying connective tissue disease.

The lungs are involved in more than 50% of patients with systemic sclerosis. Diffuse interstitial and alveolar fibrosis may appear with variable fibrous thickening of small pulmonary vessels. Pleuritis and pleural effusions are the most common pulmonary manifestations of SLE. Less

commonly, the evidence of alveolar injury in the form of edema and hemorrhage is present. In some cases, chronic interstitial fibrosis is noted. Infections and venous thromboembolic disease are also common pulmonary complications of SLE.

In patients with rheumatoid arthritis (RA) the most common interstitial pathologic pattern is diffuse fibrosis with inflammation. Follicular bronchiolitis (development of lymphoid follicles with germinal centers) can be associated with significant airway obstruction. Other common thoracic disorders associated with RA include rheumatoid nodules and pleural effusions. Vasculitis and pulmonary hypertension have been reported.

Pulmonary complications of polymyositis/dermatomyositis (PM/DM) are frequent, occurring in 40% of patients. The manifestations include ILD, aspiration, pneumonia, and ventilator muscle weakness. Pulmonary disease can be seen in patients without overt muscle abnormalities. Patients may also develop pulmonary arterial hypertension, vasculitis, and diffuse alveolar hemorrhage.

**Drug-induced lung disease** (see Differential diagnosis of pulmonary consolidation).

**Idiopathic pulmonary hemosiderosis (IPH)** is characterized by repeated episodes of intra-alveolar bleeding that lead to abnormal accumulation of iron as hemosiderin in alveolar macrophages and subsequent development of pulmonary fibrosis and severe anemia. IPH can occur as a primary disease of the lungs or it can be secondary to cardiovascular or systemic disease. In children, primary pulmonary hemosiderosis is more common than secondary types.

Three variants of primary pulmonary hemosiderosis are recognized: pulmonary hemosiderosis associated with antibody to the basement membrane of the lung and kidney (e.g., Goodpasture syndrome), pulmonary hemosiderosis associated with hypersensitivity to proteins in cow's milk (Heiner syndrome), and idiopathic pulmonary hemosiderosis (IPH).

Goodpasture syndrome is characterized by linear immunofluorescence deposition of immunoglobulin and complement along the basement membrane of the lung tissue and the kidney glomeruli and is associated with vascular damage and diffuse defragmentation of the basement membrane on electron microscopy or is immune complex disease. Idiopathic pulmonary hemosiderosis is morphologically characterized by intra-alveolar hemorrhage and subsequent abnormal accumulation of iron in the form of hemosiderin inside pulmonary macrophages. Recurrent episodes of hem-

orrhage lead to thickening of the alveolar basement membrane and interstitial fibrosis.

**Pulmonary alveolar proteinosis (PAP)** is a rare lung disorder of unknown etiology characterized by alveolar filling derived from surfactant phospholipids and protein. There are two forms of PAP *primary* (idiopathic) and *secondary*. PAP develops due to lung infections, hematologic malignancies and inhalation of mineral dusts such as silica, titanium oxide, aluminum, indium-tin oxide and insecticides. The incidence of PAP is increased in patients with hematologic malignancies and AIDS, suggesting a relationship with immune dysfunction. In pulmonary alveolar proteinosis (PAP) the alveoli are filled with proteinaceous material, which has been analyzed extensively and determined to be normal surfactant composed of lipids and surfactant-associated proteins A, B, C, and D (SP-A, SP-B, SP-C, SP-D). Patients with pulmonary alveolar proteinosis (PAP) typically present with a gradual onset of symptoms. About 30% of patients are asymptomatic, with diffuse chest radiograph abnormalities. The symptoms include the following: persistent dry cough, progressive dyspnea, fatigue, weight loss, fever and/or night sweats.

Serologic studies are generally not useful for pulmonary alveolar proteinosis (PAP). Flexible bronchoscopy with bronchoalveolar lavage (BAL) remains the standard criteria. Elevated levels of the proteins SP-A and SP-D in serum and BAL fluid may be useful. Elevated titer of neutralizing autoantibody. Chest radiography in pulmonary alveolar proteinosis (PAP) shows bilateral perihilar infiltrates with consolidation in a "bat-wing" configuration, which may mimic pulmonary edema, although with a typical absence of cardiomegaly or pleural effusion. Unilateral involvement occurs occasionally, and lymphadenopathy is rarely present.

High-resolution computed tomography (HRCT) scan of the chest demonstrates areas of patchy ground-glass opacification with smooth interlobular septal thickening and intralobular interstitial thickening, which produces a polygonal pattern referred to as "crazy paving." The crazy-paving pattern can also be observed in exogenous lipoid pneumonia, sarcoidosis, mucinous bronchoalveolar cell carcinoma, and acute respiratory distress syndrome (ARDS). Lung biopsy findings are typical for PAP. Alveoli are filled with nonfoamy material. Transbronchial biopsies are adequate, and open lung biopsy is not required.

**Genetic diseases: Gaucher disease** is a lipid storage disease characterized by the deposition of glucocerebroside in cells of the macrophage-mono-



cyte system. The disorder results from the deficiency of a specific lysosomal hydrolase, glucocerebrosidase. The disease is characterized by a continuum of phenotypes. The severity widely varies. Some patients present with virtually all the complications of Gaucher disease in childhood, whereas others remain asymptomatic into the eighth decade of life.

Gaucher disease has traditionally been divided into the following 3 clinical subtypes, delineated by the absence or presence of neurologic involvement and its progression:

- Type 1 – Nonneuronopathic form
- Type 2 – Acute neuronopathic form
- Type 3 – Chronic neuronopathic form

Glucosylceramide, the accumulated glycolipid, is primarily derived from the phagocytosis and degradation of senescent leukocytes and, to a lesser extent, from erythrocyte membranes. The glycolipid storage gives rise to the characteristic Gaucher cells, macrophages engorged with lipid with a crumpled–tissue–paper appearance and displaced nuclei. The factors that contribute to the neurologic involvement in patients with types 2 and 3 disease are still unknown but may be related to the accumulation of a cytotoxic glycolipid, glucosylsphingosine, in the brain due to the severe deficiency of glucocerebrosidase activity or to neuroinflammation.

Glucosylceramide accumulation in the bone marrow, liver, spleen, lungs, and other organs contributes to pancytopenia, massive hepatosplenomegaly, and, at times, diffuse infiltrative pulmonary disease. The diagnosis can be confirmed through the measurement of glucocerebrosidase activity in peripheral blood leukocytes. A finding of less than 15% of mean normal activity is diagnostic. MRI may be useful in delineating the degree of marrow infiltration and evaluating spinal involvement. Skeletal radiography can be used to detect and evaluate skeletal manifestations of Gaucher disease. Chest radiography is done to evaluate pulmonary manifestations. Dual-energy x-ray absorptiometry (DEXA) is useful in evaluating osteopenia. Bone scans may be useful in diagnosing bone crises.

**Newmann-Pick disease** refers to autosomal recessive lysosomal storage disorders due to acid sphingomyelinase deficiency (Niemann–Pick disease, types A and B) or defective cholesterol esterification (Niemann–Pick disease, types C and D). The Niemann–Pick disease group is now divided into two distinct entities: (1) acid sphingomyelinase-deficient Niemann–Pick disease (ASM-deficient NPD) resulting from mutations in the *SMPD1* gene and encompassing type A and type B as well as intermediate forms;



(2) Niemann–Pick disease type C (NP-C) including also type D, resulting from mutations in either the *NPC1* or the *NPC2* gene. Both Niemann–Pick diseases have an autosomal recessive inheritance and are lysosomal lipid storage disorders, with visceral (type B) or neurovisceral manifestations. The diagnosis of NP-C is often delayed due to the wide spectrum of clinical phenotypes. Systemic manifestations, if present, always precede the onset of neurological manifestations. The most common neurological signs are vertical supranuclear gaze palsy, cerebellar ataxia, dysarthria, dysphagia, and progressive dementia. Cataplexy, seizures, and dystonia are other common features of NP-C. For both ASM-deficient NPD and NP-C, strategies for laboratory diagnosis of patients and prenatal diagnosis are discussed. Recent progress towards enzyme replacement therapy in type B patients and management of the neurological disease in type C patients are finally highlighted.

**Hermansky-Pudlak syndrome** is a heterogeneous group of autosomal recessive disorders characterized by tyrosinase-positive oculocutaneous albinism, bleeding tendencies, and systemic complications associated to lysosomal dysfunction. Pulmonary fibrosis and granulomatous colitis are associated diseases. Patients with the syndrome have a wide variety of phenotypic appearance. Patients with this disease have blindness, nystagmus, strabismus, iris transillumination, foveal hypoplasia, and albinotic retinal mid-periphery. Skin biopsies reveal a normal number of melanocytes. Melanosomes are reduced in both melanocytes and keratinocytes. Patients with Hermansky-Pudlak syndrome usually present with the following: bleeding diathesis, pulmonary symptoms associated to pulmonary fibrosis, such as dyspnea upon exertion, a history of previous pulmonary function tests, and steroid therapy. Symptoms such as abdominal pain, diarrhea, upper and lower gastrointestinal bleeding, can also occur. The family history of patients with Hermansky-Pudlak syndrome should include the following: nationality, parental consanguinity, and the incidence of this syndrome in other family members. Hair bulb incubation test classifies patients with OCA into tyrosinase negative or tyrosinase positive. All patients with Hermansky-Pudlak syndrome have Ty-pos OCA.

**Pulmonary function tests:** Mutations in the *HPS-1* gene are associated with fatal pulmonary fibrosis. Patients with HPS should be evaluated using pulmonary function tests. Forced vital capacity (FVC), forced expiratory volume (FEV), mean total lung capacity, mean vital capacity, and mean diffusing capacity of the lung for carbon monoxide fall as interstitial lung disease progress in patients with the syndrome.

**Lymphangitis carcinomatosa (LC)** is a diffuse infiltration and obstruction of pulmonary parenchymal lymphatic channels by tumor. Various neoplasms can cause lymphangitic carcinomatosis, but 80% of them are adenocarcinomas. The most common primary sites are the breasts, lungs, colon, and stomach. Other sources include the pancreas, thyroid, cervix, prostate, and larynx. LC can also arise from choriocarcinoma, melanoma, or metastatic adenocarcinoma from an unknown primary cancer. In a patient with a known malignancy, the usual presenting complaint is breathlessness. Occasionally, patients have dry cough or hemoptysis. On radiographs, LC appears as reticular or reticulonodular opacification, often with associated septal lines (Kerley A and B lines), peribronchial cuffing, pleural effusions, and mediastinal and/or hilar lymphadenopathy. HRCT scan findings include irregular, nodular, and/or smooth, interlobular septal thickening of the fissures as a result of the involvement of the lymphatics concentrated in the subpleural interstitium; preservation of normal parenchymal architecture at the level of the secondary pulmonary lobule; peribronchovascular thickening; centrilobular peribronchovascular thickening, which predominates over interlobular septal thickening in a minority of patients; polygonal arcades or polygons with prominence of the centrilobular bronchovascular bundle in association with interlobular septal thickening; mediastinal and/or hilar lymphadenopathy and pleural effusions. Findings may be unilateral or bilateral, focal or diffuse, and symmetrical or asymmetrical.

**Chronic uremia** is a clinical condition associated with fluid, electrolyte, and hormone imbalances and metabolic abnormalities, which develop in parallel with deterioration of renal function. Uremia more commonly develops with chronic kidney disease (CKD), especially the later stages of CKD, but it also may occur with acute kidney injury (AKI) if loss of renal function is rapid. Urea itself has both direct and indirect toxic effects on a range of tissues. A number of substances with toxic effects, such as parathyroid hormone (PTH), beta2 microglobulin, polyamines, advanced glycosylation end products, and other middle molecules, are thought to contribute to the clinical syndrome. Severe complications of untreated uremia include seizure, coma, cardiac arrest, and death. Spontaneous bleeding can occur with severe uremia and may include gastrointestinal (GI) bleeding, spontaneous subdural hematomas, increased bleeding from any underlying disorder, or bleeding associated with trauma. Cardiac arrest may occur from severe underlying electrolyte abnormalities, such as hyperkalemia, metabolic acidosis and hypocalcemia. As regards the lungs, fluid retention may

result in pulmonary edema and corresponding crackles in the lungs. Pleural rubs occur in the setting of uremic lungs.

## BIBLIOGRAPHY

1. Travis W.D., Hunninghake G., King T.E. Jr, Lynch D.A., Colby T.V., Galvin J.R., Brown K.K., Chung M.P., Cordier J.-F., du Bois R.M., et al. Idiopathic nonspecific interstitial pneumonia: report of an American Thoracic Society project. *Am J Respir Crit Care Med* 2008; 177: 1338–1347.
2. American Thoracic Society, European Respiratory Society. American Thoracic Society/European Respiratory Society international multidisciplinary consensus classification of the idiopathic interstitial pneumonias. *Am J Respir Crit Care Med* 2002; 165: 277–304.
3. Aziz Z.A., Wells A.U., Hansell D.M., Bain G.A., Copley S.J., Desai S.R., Ellis S.M., Gleeson F.V., Grubnic S., Nicholson A.G., et al. HRCT diagnosis of diffuse parenchymal lung disease: inter-observer variation. *Thorax* 2004; 59: 506–511.
4. Ryu J.H., Olson E.J., Midthun D.E., Swensen S.J. Diagnostic approach to the patient with diffuse lung disease. *Mayo Clin Proc* 2002; 77:1221.
5. Collard H.R., King T.E. Jr. Demystifying idiopathic interstitial pneumonia. *Arch Intern Med* 2003; 163:17.
6. King T.E. Jr. Clinical advances in the diagnosis and therapy of the interstitial lung diseases. *Am J Respir Crit Care Med* 2005; 172:268.
7. King T.E., Jr. Interstitial Lung Diseases: General Approaches. In: *Pulmonary and Respiratory Therapy Secrets*, Parsons PE, Heffner JE (Eds), Handley & Belfus Inc, Philadelphia 1997. p.231.
8. [www.ncbi.nih.gov](http://www.ncbi.nih.gov) (accessed 07.11.2017).
9. [www.journals.lww.com/thoracicimaging](http://www.journals.lww.com/thoracicimaging) (accessed 07.11.2017).
10. [www.ersjournals.com](http://www.ersjournals.com) (accessed 07.11.2017).

## DIFFERENTIAL DIAGNOSIS OF PLEURAL EFFUSION

**DEFINITION.** Pleural effusion is an abnormal collection of fluid in the pleural space. It develops because of excessive filtration or defective absorption of accumulated fluid. Pleural effusion may be a primary manifestation or a secondary complication of many pulmonary and extrapulmonary disorders.

**PATHOPHYSIOLOGY.** The pleural space normally contains between 7 and 16 ml of pleural fluid. Any accumulation of fluid in the pleural space is the result of an increased production exceeding the rate of fluid removal.

Pleural fluid is being formed and absorbed constantly. Normally, transudation and absorption of fluid within the pleural cavity follow the Starling law of capillary exchange and depend on a combination of hydrostatic pressure, colloid osmotic pressure, and tissue forces. Since hydrostatic pressure is significantly greater in parietal pleural capillaries, which arise from the systemic circulation, in healthy individuals the Starling forces favor filtration of fluid from the systemic capillaries in the parietal pleura and absorption of fluid by the pulmonary capillaries in the visceral pleura.

An abnormal fluid accumulation in the pleural cavity occurs as a result of one or more of the following mechanisms:

- 1) increase in hydrostatic pressure in the systemic circulation (congestive heart failure, constrictive pericarditis);
- 2) decrease in colloid osmotic pressure of plasma (hypoalbuminemia of any cause);
- 3) increase in pleural capillary permeability (inflammation, malignancy);
- 4) increase in lymphatic pressure (hepatic hydrothorax, lymphatic obstruction caused by tumor, inflammation, or parasites).

### ETIOLOGICAL CLASSIFICATION

*Causes of transudative effusions:*

- Congestive heart failure
- Cirrhosis (hepatic hydrothorax)
- Atelectasis (may be due to occult malignancy or pulmonary embolism)

- Hypoalbuminemia
- Nephrotic syndrome
- Peritoneal dialysis
- Myxedema
- Constrictive pericarditis
- Urinothorax (usually due to obstructive uropathy)
- Cerebrospinal fluid leaks to the pleura (in the setting of ventriculo-pleural shunting or of trauma/surgery to the thoracic spine)
- Duropleural fistula (rare, but may be a complication of spinal cord surgery)
- Extravascular migration of central venous catheter
- Glycinothorax (rare complication of bladder irrigation with glycine solution following urologic surgery)

*Causes of exudates effusions:*

- Parapneumonic causes
- Malignancy (most commonly lung or breast cancer, lymphoma, and leukemia; less commonly ovarian carcinoma, stomach cancer, sarcomas, melanoma)
- Pulmonary embolism
- Collagen-vascular conditions (rheumatoid arthritis, systemic lupus erythematosus)
- Tuberculosis
- Pancreatitis
- Trauma
- Postcardiac injury syndrome
- Esophageal perforation
- Radiation pleuritis
- Sarcoidosis
- Fungal infection
- Pancreatic pseudocyst
- Intra-abdominal abscess
- Status post coronary artery bypass graft surgery
- Pericardial disease
- Meig's syndrome (benign pelvic neoplasm with associated ascites and pleural effusion)
- Ovarian hyperstimulation syndrome
- Drug-induced pleural disease
- Asbestos-related pleural disease

- Yellow nail syndrome (yellow nails, lymphedema, pleural effusions)
- Uremia
- Trapped lung (localized pleural scarring with the formation of a fibrin peel prevents incomplete lung expansion, at times leading to pleural effusion)
- Chylothorax (acute illness with elevated triglycerides in pleural fluid)
- Pseudochylothorax (chronic condition with elevated cholesterol in pleural fluid)
- Fistula (ventriculopleural, biliopleural, gastropleural)

### CLINICAL FEATURES

Dyspnea is a major respiratory symptom which accompanies pleural effusion, commonly with progressive worsening. The pathogenesis of dyspnea includes a decrease in the compliance of the chest wall, contralateral shifting of the mediastinum, decrease in ipsilateral lung volume, and reflex stimulation from the lungs and chest wall. The presence of chest pain may be helpful diagnostically as it implies a degree of inflammatory process suggestive of exudate such as pleural infection, mesothelioma, or pulmonary infarction. Hemoptysis may also help in the diagnosis of associated endotracheal and/or endobronchial lesions or pulmonary embolism. Cough is a nonspecific symptom that may involve both the lungs and pleura. Constitutional nonspecific symptoms, such as fever, night sweats, weight loss, anorexia and restriction of daily activity, may be associated suggesting an infectious process (parapneumonic pleural effusion, empyema), malignancy and collagen-vascular disease (e.g., pleural effusion in lupus).

History may also provide useful information, such as exposure to asbest suggesting mesothelioma or drug-induced pleural effusion. Drugs may also occasionally be a cause of misdiagnosed pleural effusion.

The intercostal spaces are the level and the involved side lags in the respiratory excursion. Vocal fremitus and bronchophony are decreased on the involved side. The percussion sounds are dull. The superior border of dullness is an arch with the upper point in the region between the interscapular and posterior axillary lines (Damoiseau's curve). No respiration sounds can be heard over the area of dullness.

## DIAGNOSTIC APPROACH

### Chest Radiography

The postero anterior chest radiography is abnormal when pleural fluid is >200 ml. In addition, the lateral radiography may show blunting of the posterior costo diaphragmatic angle when the fluid exceeds 50 ml. The presence of massive effusion will lead to a malignant etiology. Furthermore, chest radiography may show additional lesions, either pleural (pleural thickening, plaques, masses), pulmonary parenchymal (consolidation, atelectasis, tumor, diffuse reticulonodular), or mediastinal (enlargement), that will direct diagnosis.

### Chest Ultrasound

Chest ultrasonography will detect the presence of as little as 5–50 ml of pleural fluid. The superiority of Chest ultrasonography is particularly apparent for small or loculated effusions. Effusions with loculations and fibrous septa may appear as mass lesions on the chest radiograph as the fluid climbs into the fissure.

### Chest Computed Tomography

Computed tomography (CT) of the chest is unequalled in its ability to image the entire pleural space. CT also has the advantage of simultaneously imaging the pulmonary parenchyma and mediastinum. CT is more sensitive than both conventional chest radiography and US for differentiating pleural fluid from pleural thickening and for the identification of focal masses involving the pleura or the chest wall. When more detailed information about the pleural space in relation to other intrathoracic structures is required, CT is superior to Chest ultrasonography.

### Pleural thoracentesis

Not all patients with pleural effusion should undergo thoracentesis. Obviously patients presenting with transudative effusion according to the history and clinical assessment, such as heart, renal and hepatic failure, should not undergo thoracentesis unless the adequate treatment fails. Upon presentation, patients with diseases that may express exudative effusion, such as pulmonary infarction, pancreatitis and connective tissue disorders, should not undergo pleural fluid analysis.

When thoracentesis is considered, pleural fluid must be analyzed for pleural lactate dehydrogenase (LDH) and proteins in order to determine whether it is an exudate or transudate according to Light's criteria (table 1). Pleural pH, Gram, acid-fast bacilli stains and cultures, are analyzed and cytological analysis is done. It is important to note the appearance of the

fluid that may give important information about the origin of the effusion together with the analysis of pleural fluid.

*Table 1.*

**Light's Criteria: determination of transudate versus exudate source of pleural effusion**

<b>Fluid is exudate if one of the following Light's criteria is present:</b>
<ul style="list-style-type: none"> <li>• Effusion protein/serum protein ratio greater than 0.5</li> <li>• Effusion lactate dehydrogenase (LDH)/serum LDH ratio greater than 0.6</li> <li>• Effusion LDH level greater than two-thirds the upper limit of the laboratory's reference range of serum LDH</li> </ul>

### **Appearance**

The appearance of the pleural fluid might be useful. Massive and hemorrhagic or sero-hemorrhagic pleural effusions are likely to be malignant. Pus is characteristic of pleural empyema and cloudy fluid may be due to parapneumonic pleural effusion and/or to empyema. An underlying disease such as lung carcinoma should be systematically studied. A chocolate or gelatinous pleural fluid may be the consequence of paragonimiasis. A green-colored fluid may indicate rheumatoid effusion and a 'milky' appearance – chylothorax. Normal transudate is limpid, clear yellow-colored fluids.

### **Pleural fluid biochemical analysis**

The presence of transudate or exudate should be, first of all, confirmed by the measurement of fluid protein. Exudates have a higher protein concentration ( $>30$  g/l) due to an increase in capillary permeability and/or impaired lymphatic drainage. Pleural fluid protein measurements should be interpreted in the light of serum protein. In cases with abnormal serum protein or pleural fluid protein levels close to 30 g/l, the ratio pleural/serum LDH according to Light's criteria (table 1) is highly sensitive (98%) for the diagnosis of exudates, with 83% specificity. In case of heart or renal failure patients treated with diuretics pleural fluid cholesterol determination have been recommended. A value of  $>60$  mg/dl (1.55 mmol/L) is indicative of exudates.

A low pleural fluid pH ( $<7.3$ ) may follow bacterial metabolism and is often associated with a reduced pleural fluid glucose ( $<3.3$  mmol/L) or pleural fluid/serum glucose ratio of  $<0.5$ . This combination is relatively specific for parapneumonic pleural effusions and/or empyemas, but may also be seen in case of connective tissue diseases or in malignant pleural effusions due to tumor cell metabolism. A pleural fluid/serum rheumatoid factor ratio of  $\geq 1$  can confirm the diagnosis of rheumatoid effusion in patients



with clinical symptoms of the disease. Patients with pleural effusions caused by systemic lupus erythematosus usually have pleural fluid/serum antinuclear antibody ratios of  $>1$ . The levels of complement in pleural fluid are low in both rheumatoid and lupus pleural effusions. Pleural effusion of rheumatoid arthritis and systemic lupus erythematosus commonly resolves after adequate treatment of the disease.

An increase of amylase is characteristic of pleural effusion due to pancreatitis or esophageal rupture. The disruption or obstruction of the thoracic duct by a tumor or trauma may result in a chylothorax with the characteristic 'milky' pleural fluid. The confirmation of chylothorax is made by determining the levels of triglycerides in the fluid, which must be  $>110$  mg/dL, and contain chylomicrons but not cholesterol crystals.

### **Pleural fluid microbiologic analysis**

Pneumonia is associated with an exudative pleural effusion in up to 57% of cases and is the most common cause of pleural effusion in young patients. The bacteriology of pleural infection varies as there are significant differences between community- and hospital-acquired infections.

Thoracentesis is essential for diagnosis of pleural infection. Aspiration may be difficult in empyema or loculated effusions. In such cases chest ultrasonography should be used to localize pleural fluid. The appearance of the fluid must be noted and samples must be taken for Gram's stain and culture. The diagnosis is confirmed with a frankly purulent pleural fluid and/or the presence of microbes on Gram's stain or culture. When those criteria are not met, the patient's clinical presentation associated with a pH of  $<7.20$  is suggestive of pleural infection. In pleural infections with multiple loculations and/or a *Proteus mirabilis* infection, the possibility of aspirating fluid from a compartment that has a pH of  $>7.20$  should not exclude a complicated parapneumonic effusion, which may also be supported by increased pleural LDH ( $>1,000$  IU/L) and low glucose ( $<35$  mg/dl).

Common causes of community-acquired infection include the *Streptococcus milleri*, *Streptococcus pneumoniae* and staphylococci, sometimes with associated anaerobes. Less common responsible organisms include other streptococci, enterobacteria, *Haemophilus influenzae*, *Pseudomonas* spp., tuberculosis and *Nocardia*. Hospital-acquired infection, mostly due to pneumonia, surgery, trauma or pleural procedures, is frequently caused by methicillin-resistant *Staphylococcus aureus* or enterobacteria.

In tuberculous effusions, fluid smears and culture have a low yield (10–20 and 25–50%, respectively). The culture of pleural fluid and biopsy

improve the diagnostic yield to about 90%. Pleural fluid adenosine deaminase (ADA) may be raised but is nonspecific or negative in HIV infection and is of value in high endemic areas. In association with increased lymphocytes, ADA has 95% sensitivity and 89% specificity in tuberculous pleurisy. Anti-TB treatment is reasonable to consider in the undiagnosed recurrent effusion with a positive tuberculin test (positive in 70% of TB effusions) with a lymphocytic exudate.

### **Pleural fluid cytological analysis**

Differential cell counting adds little diagnostic information. Pleural lymphocytosis is common in malignant and tuberculous effusions but can also be attributable to rheumatoid disease, lymphoma, sarcoidosis, and chylothorax. Eosinophilic (>10% eosinophils) pleural effusions are often benign and associated with blood or air in the pleural space, but can be attributable to underlying malignancy in up to 10% of cases and therefore still need to be investigated fully. Causes of pleural eosinophilia include parapneumonic effusion, benign asbestos pleural effusion, Churg-Strauss syndrome, pulmonary infarction, parasitic disease, and drugs. Coronary artery bypass grafting may also cause early left-sided, hemorrhagic, eosinophilic pleural effusions followed later by small lymphocyte predominant effusions.

Morphologic analysis of the cells recovered from an effusion may not be sufficient for a diagnosis of malignancy. Commonly, the distinction between atypical mesothelial cells and metastatic carcinoma is impossible because of the notorious reactivity of mesothelial cells. When considering the primary site of a metastatic malignancy three factors are crucial:

- the type of cells present in the effusion;
- the location of the effusion in relation to the age and sex of the patient,
- the presence and nature of a tumor in a distant site.

If any of these data is missing, the matter may be resolved by immunocytochemistry.

Pleural fluid cytology is the simplest definitive method to obtain a diagnosis of malignant pleural effusion. Immunohistochemical epithelial and glandular markers may help to confirm epithelial malignancy and differentiate mesothelioma from adenocarcinoma.

### **Tumor markers**

Several tumor markers, such as carcinoembryonic antigen, CA-125, CA-19-9, CYFRA 21-1, nonspecific enolase, have been tested in patients

with malignant pleural effusion. Although the results seem to be controversial as to the usefulness of these tumor markers in the differential diagnosis of pleural effusions, even between malignant and nonmalignant, ones some authors propose specific tumor markers for the diagnosis of pleural effusions due to bronchogenic carcinoma.

**Pleural biopsy.** The diagnostic yield of closed pleural biopsy alone in malignant pleural effusions is about the same as pleural cytology. A combination of both techniques seems to improve the diagnostic yield. The low diagnostic yield of closed pleural biopsy is due to factors such as early stage disease with small pleural extension, location of tumors in areas of the pleura unreachable by the needle, including the visceral pleura, as well as the inexperience of the physician. The diagnostic yield of blind biopsy increases with the number of specimens taken in malignant pleural effusion; at least 4 biopsy samples are needed for accurate diagnosis. As pleural invasion is preferentially located at the base of the hemithorax, it is recommended the sample to be taken from the lowest part of the costal pleura in order to achieve a higher diagnostic success.

**Thoracoscopy** is very important as there is a significant likelihood of malignancy in patients with undiagnosed pleural effusions. Thoracoscopy also provides information on the extent of underlying diseases such as lung carcinoma and mesothelioma. In case of lung cancer, thoracoscopy is performed not only to diagnose but also to detect pleural infiltration and, for non-small-cell lung carcinoma, to determine T4 stage disease, which excludes surgical resection and indicates a poor prognosis for the patient. The role of thoracoscopy in early stage mesothelioma is essential to determine the use of multimodality treatment based on extrapleural pneumonectomy. Thoracoscopy in mesothelioma is also necessary in advanced stage disease to diagnose and map lesions of the pleural cavity in order to evaluate the possible treatment response.

**Bronchoscopy** is indicated when an endotracheal and/or endobronchial lesion is suspected.

*Table 2.*

**Diagnosis based on pleural fluid analysis**

<b>Diagnosis</b>	<b>Criteria</b>
Tuberculosis	Exudate, lymphocytic predominance, positive acid-fast bacillus smear or cultures, ADA > 50 U/L
Empyema	Exudate with PMN predominance/pus, positive Gram stains or cultures, LDH > 1000, glucose < 40 mg%, pH < 7.2

Malignancy	Exudate, lymphocytic predominance, positive cytology
Hemothorax	Hemorrhagic, hematocrit > 50% of blood
Esophageal rupture	pH < 7, high salivary amylase
Urinothorax	pH < 7, transudate, pleural fluid-to-serum creatinine ratio > 1
Chylothorax	Triglycerides > 110 mg/dL, chylomicrons, cholesterol/triglyceride ratio < 1
Rheumatoid pleurisy	Exudate, lymphocytic predominance, rheumatoid factor positive > 1:320, low glucose < 40 mg%, ADA > 50 U/L
Lupus pleuritis	Exudate with PMN predominance, LE cells positive, ANA positive > 1:160
Pancreatitis	Exudate with PMN predominance, plenty of RBC
	Acute: increased serum and pleural amylase
	Chronic: increased pleural fluid amylase, serum amylase normal
Fungal infection	Black-colored, fungal smear, culture positive

## DIFFERENTIAL DIAGNOSIS

**Pleural effusion associated with congestive heart failure.** Patients with congestive heart failure and pleural effusion present with orthopnea, paroxysmal nocturnal dyspnea, and fine bibasal crackles on chest auscultation. Chest X-ray shows bilateral pleural effusions (the right effusion being larger than the left one) and cardiomegaly. These are transudative effusions and serum and pleural fluid NT-proBNP levels are significantly elevated. The effusions usually improve quickly once diuretic therapy is started. Therapeutic tapping is needed only if the patient has respiratory embarrassment.

**Pleural effusion associated with liver cirrhosis.** Hepatic hydrothorax is caused by the passage of ascitic fluid from the peritoneal cavity into the pleural space through diaphragmatic defects. The clinical signs of liver cirrhosis are usually present. Effusions may be unilateral or bilateral, it is usually a serous or hemorrhagic transudate, with predominantly lymphocytes and mesothelial cells. Pleural fluid and ascitic fluid have similar biochemistry. Increasing effusion is often associated with a decrease in ascitic fluid. Diagnostic tests that should be performed include cell count, Gram stain and culture, serum and fluid protein, albumin, LDH, and bilirubin. Other tests on pleural fluid that may be useful depending upon the clinical

suspicion include triglyceride level, pleural pH, adenosine deaminase and polymerase chain reaction (PCR) for mycobacterium, amylase, and cytology to exclude chylothorax, empyema, tuberculosis, pancreatitis, and malignancy. In uncomplicated hepatic hydrothorax, the cell count is low (<500 cells), and the total protein concentration is less than 2.5 g/dL. The serum albumin-pleural gradient is usually >1.1 g/dL. The diagnostic criteria for spontaneous bacterial empyema are: 1) positive pleural fluid culture and a polymorphonuclear count >250 cells/mm<sup>3</sup>; 2) negative pleural fluid culture and a polymorphonuclear count >500 cells/mm<sup>3</sup> and 3) no evidence of pneumonia on a chest X-ray.

**Pleural effusion associated with nephrotic syndrome.** Effusions result from severe hypoalbuminemia, which leads to decreased oncotic pressure. They are bilateral effusions, serous in nature with proteins <1 g/dL, with normal glucose and pH > 7.4.

**Parapneumonic effusion and empyema.** Pneumonia is the most common cause of pleural effusion in young patients. The majority of cases resolve with antibiotic treatment, but a certain number will progress to an infected pleural liquid. Pleural fluid progresses through an exudative phase (simple parapneumonic effusion) to a fibrinopurulent stage, eventually resulting in an organizing stage with fibrotic scar tissue formation (see Table 3). In the early fibrinopurulent stage the fluid is termed 'complicated parapneumonic effusion', and the presence of pus in the pleural cavity is termed 'empyema'.

Table 3.

**Characteristics of parapneumonic effusions and empyema**

Type of pleural effusion	Description	Biochemistry/ microbiology	Response to treatment
Simple parapneumonic effusion	Uninfected fluid with clear appearance	Normal pH Normal LDH Normal glucose No organisms	Majority resolve with antibiotics alone Drainage not usually required
Complicated parapneumonic effusion	Infected but non-purulent fluid. Fluid clear or turbid	pH <7.2 glucose <2.2 mmol/L LDH >1000 IU/L Gram stain/culture may be positive	Drainage required for resolution
Empyema	Pus in pleural space	Gram stain/culture may be positive	Drainage required for resolution

A chest radiograph showing effusion and consolidation should raise the possibility of empyema. Patients with pneumonia not responding to antibiotics should be assessed for the presence of pleural infection. CT scanning can help differentiate empyema from intra parenchymal masses, abscess and pleural thickening. Empyema may present as an indolent illness with constitutional symptoms and be confused with malignancy. The bacteriology of community-acquired infection include *Streptococcus intermedius*, *Streptococcus constellatus*, *Streptococcus inonia*, *Streptococcus pneumoniae* and staphylococci, sometimes with associated anaerobes, enterobacteria, *Haemophilus influenzae*, *Pseudomonas* spp., tuberculosis and *Nocardia*. Hospital-acquired infection is represented by methicillin-resistant *Staphylococcus aureus* (MRSA), staphylococci, enterobacteria or *Enterococcus*.

**Pleural effusion associated with malignancy.** Malignant pleural effusion can result from primary malignancies of the pleurae or with intrathoracic and extrathoracic malignancies that reach the pleural space by hematogenous, lymphatic, or contiguous spread. More than 75% of malignant pleural effusions are caused by neoplasms of the lung, breast, or ovary, or by lymphoma. Metastatic adenocarcinoma is the most common tumor type. Patients present with a nonspecific history and with cough and dyspnea. About 60% of patients with malignant pleural effusion experience a constant dull or occasionally localized pleuritic chest pain. It is an exudative effusion with lymphocytic predominance, and often hemorrhagic. It is defined by the presence of malignant cells in the pleural space, for which fluid needs to be sent for cytology (200 units of heparin in 20 mL of fluid).

Patients with cancer can develop pleural effusion as an indirect effect of cancer, even when cancer cells are absent from the pleural space. These effusions are known as paraneoplastic or paramalignant pleural effusions. They can result from mediastinal lymph node tumor infiltration, bronchial obstruction, radiochemotherapy, pulmonary embolism, superior vena cava syndrome, or decreased oncotic pressure. Chest radiography showing massive pleural effusion increases the probability of a malignant etiology. Radiographic signs of a malignant pleural effusion include circumferential lobulated pleural thickening, crowding of the ribs, and elevation of the hemidiaphragm or ipsilateral mediastinal shift consistent with lung atelectasis due to airway obstruction by a tumor. Thoracoscopy has a 90% sensitivity for malignant pleural effusion. The management of malignant pleural effusions begins with therapeutic thoracentesis. If symptoms do not improve with large-volume thoracentesis, alternative causes of dyspnea should be

considered. These could be microtumor emboli, lymphangitic cancer, the effects of chemotherapy or radiotherapy, or pulmonary thromboembolism. The removal of a large volume of pleural fluid could rapidly expand atelectatic lung regions beyond their capacity to reinflate and cause alveolar capillary injury, resulting in reexpansion pulmonary edema. Although the symptoms can improve after thoracentesis, 98% of patients with malignant pleural effusion experience reaccumulation of fluid and recurrence of symptoms within 30 days.

**Mesothelioma.** Mesothelioma is a malignant tumour of the pleura and peritoneum, usually caused by previous asbestos exposure. There is a lag time of 15–40 years between exposure and disease presentation. The diagnosis should be considered in all patients with pleural effusions, especially in the context of pleural thickening, pleural plaques or chest pain. The initial history must include a thorough occupational history, as this may have subsequent medicolegal implications. A history of asbestos exposure is elicited in up to 90% of patients; hence absence of exposure history does not exclude the diagnosis.

Dyspnea and nonpleuritic chest wall pain are the most common presenting symptoms of malignant pleural mesothelioma, with at least 1 of these occurring in 60–90% of patients. Other common accompanying symptoms are as follows: chest discomfort, pleuritic pain, easy fatigability, fever, sweats and weight loss.

The patients may also be asymptomatic, with evidence of a pleural effusion noted incidentally on physical examination or by chest radiograph. *Thoracentesis:* More than 90% of patients with pleural mesothelioma present with pleural effusion that decreases after thoracentesis, typically, the pleural fluid findings are nondiagnostic, with < 1000 leukocytes/ $\mu$ L, few erythrocytes, elevated protein levels, and normal lactate dehydrogenase levels. Pleural fluid cytologic findings are diagnostic in only 32% of patients and are suggestive in 56% of patients to distinguish malignant mesothelioma from reactive mesothelial cells in effusions had a 79% sensitivity. *Thoracoscopically guided biopsy:* it is indicated if mesothelioma is suggested and it is diagnosed in 98% of cases. Diagnostic features that distinguish malignant mesothelioma from adenocarcinoma include the following: negative results for periodic acid-Schiff stain, mucicarmine stain, carcinoembryonic antigen, and Leu M1, positive test results for calretinin, vimentin, and cytokeratin. *Serum biomarkers:* soluble mesothelin (the current reference biomarker); megakaryocyte potentiating factor. *Chest radiographs* findings



in malignant pleural mesothelioma include one or more of the following: obliteration of the diaphragm, nodular thickening of the pleura, decreased size of the involved chest, radiolucent, sheet like encasement of the pleura, loculated effusion (> 50% of patients), with opacification of a major portion of the pleura. The prognosis is poor, with median survival of 8–14 months.

**Pleural effusion associated with tuberculosis.** Tuberculous pleuritis is thought to represent primarily a hypersensitivity reaction to tuberculous protein, and the bacillary burden in the pleural space is low. The patients usually present with an acute illness. The most frequent symptoms are cough, which is nonproductive and associated with chest pain, which is usually pleuritic in nature. The pain usually precedes the cough. Most patients are febrile, but approximately 15% will be afebrile. Dyspnea may be present if the effusion is large and related to mechanical dysfunction of the diaphragm due to inversion. Effusions are usually unilateral and can be of any size. On rare occasions, pleural tuberculosis can present with pleural-based nodules and thickening.

The fluid is serous or hemorrhagic with formation of coagulum. Pleural fluid is an exudate with proteins frequently >5 g/dL and lymphocytic predominance. Pleural fluid glucose may be reduced, but is usually similar to the serum level. The pH is usually above 7.3, but it may be reduced in some cases. The lactate dehydrogenase level in pleural fluid is usually higher than that in serum. The presence of eosinophils or mesothelial cells is unlikely. Intense lymphocytic infiltration covers both pleural surfaces and prevents the mesothelial cells from entering the pleural space. Various studies have confirmed that the pleural fluid from patients with tuberculosis rarely contains more than 5% of mesothelial cells. Patients infected with human immunodeficiency virus (HIV) with tuberculous pleuritis may have mesothelial cells in their pleural fluid, a feature common with peripheral blood CD4 counts below 100 mm<sup>3</sup>.

Pleural fluid smears for acid-fast bacilli should be obtained in HIV-positive patients and they are positive in 10%–20% of effusions, with 20%–50% being positive on pleural fluid cultures. Pleural biopsy shows caseating granuloma. Histopathology and pleural tissue culture for acid-fast bacilli improve the diagnostic rate to about 90%. *Adenosine deaminase* levels > 50 IU/L support the diagnosis in high prevalence areas, but do not exclude tuberculosis under other conditions. Adenosine deaminase activity is found to be higher in tuberculous pleural effusions than in other exudates; overall sensitivity in the diagnosis of tuberculous pleural effusions is 99% and



specificity is 93%. However, these are superior to adenosine deaminase in the diagnosis of tuberculous pleuritis and can be used as a routine test in the diagnostic workup of patients with pleural effusions in areas with a high prevalence of tuberculosis. Adenosine deaminase may not be raised in patients with concomitant HIV infection. The tuberculin test may be negative initially due to compartmentalization of lymphocytes at the site of infection. More than 8 weeks after the development of symptoms, the skin test is almost always positive. The skin test may become negative in patients with immunosuppression and HIV infection. Without treatment, tuberculous pleuritis usually resolves spontaneously, but the patient frequently develops active tuberculosis at a later date.

#### *Pleural effusion in connective tissue diseases*

**Pleural effusion associated with rheumatoid arthritis** affects the pleura in up to 5% of cases and, in keeping with other extra-articular manifestations of the disease, is more common in males. The fluid may be of various colours including green, turbid and haemorrhagic. Rheumatoid effusions characteristically have a low glucose and pH. If the pleural fluid glucose is  $>1.6$  mmol/l, rheumatoid is an unlikely cause. The measurement of rheumatoid factor is unhelpful as pleural fluid levels reflect serum levels and, although it is often raised in rheumatoid effusions, it may also be increased in other aetiologies. Effusion and pleuritis secondary to rheumatoid arthritis often do not require any treatment, resolving spontaneously over a period of months. Non-steroidal anti-inflammatory drugs can be used, and one case report supports the use of intrapleural corticosteroids in resistant cases.

**Pleural effusion associated with systemic lupus erythematosus.** Pleural involvement occurs during the course of systemic lupus erythematosus in 50%–75% of patients and can be the presenting manifestation. One mechanism suggested for the production of pleural effusion is the deposition of remotely generated immune complexes in the pleural capillaries. These complement fragments increase vascular permeability, allowing the fluid and proteins to escape into the pleural space. The fluid is exudative, with a polymorphonuclear predominance and  $\text{pH} > 7.36$ , glucose  $>60$  mg%, and lactate dehydrogenase  $\leq 600$  U/L. The diagnosis of lupus is likely if the fluid is positive for lupus erythematosus cells, antinuclear antibody is  $>1:160$ , and the pleural fluid/serum antinuclear antibody ratio is more than 1.

*Chylothorax* results from disruption of the thoracic duct, usually because of malignancy or trauma, and results in a 'true' chylous effusion. Pseudochy-

lothorax (also known as cholesterol pleurisy) results from the accumulation of cholesterol in a long-standing effusion of any cause, and is usually seen in rheumatoid or tuberculous pleurisy.

In chylothorax the triglyceride level is high ( $>1.24$  mmol/L and not  $<0.56$  mmol/L) and the presence of chylomicrons confirms this. In pseudochylothorax the cholesterol level is high ( $>5.18$ ) and cholesterol crystals are often seen.

The treatment of chylothorax can be difficult and depends upon aetiology. Intercostal drainage and bowel rest (sometimes using parenteral nutrition) are used in cases of traumatic chylothorax, whereas chylothorax secondary to malignancy may respond to systemic chemotherapy or radiotherapy. Chylothorax in postoperative patients can be particularly difficult to manage and it is associated with high mortality. Chylothorax is seen in patients with pulmonary lymphangiomyomatosis (LAM). In this context effusion may also respond to a medium-chain fatty acid diet, although this is often unpalatable.

**Hydatid disease.** In the developing world and in patients from rural farming communities, pleural effusion and infection secondary to hydatid disease should be considered. Hydatid is caused by infection with larva of the tapeworm *Echinococcus granulosus* and *Echinococcus multilocularis*, the adult form of which lives in dogs and sheep. In humans, hydatid cysts are most often found in the liver (60–70%) and lungs (30–40%). Lung cysts may be associated with pleural abnormalities, and cyst rupture may result in hydropneumothorax and empyema. Hence pleural involvement and frank empyema are rare in hydatid disease, but it should remain in the differential diagnosis given its high prevalence.

The diagnosis is based upon the combination of imaging and serology, with lung cysts well visualized on thoracic CT. Several serological tests are available, but tend to have low sensitivity for lung involvement (65% of lung cysts associated with positive serology). Aspiration and biopsy under image guidance are possible, but carry the risk of spilling highly antigenic content into the systemic circulation.

**Pleural effusion associated with pancreatitis.** Pancreatic ascites and pleural effusion may develop following the disruption of the pancreatic duct, leading to fistula formation in the abdomen or chest, or rupture of a pseudocyst with tracking of pancreatic juice into the peritoneal cavity or pleural space. Mechanisms involved in the pathogenesis include direct contact of pancreatic enzymes with the diaphragm, giving rise to sympa-

thetic effusion, transfer of ascitic fluid via transdiaphragmatic lymphatics or diaphragmatic defects, communication of a fistulous tract between a pseudocyst and pleural space, and retroperitoneal movement of fluid into the mediastinum with mediastinitis or rupture into the pleural space. The pleural effusion associated with acute pancreatitis is usually small and left-sided in 60% of cases; however, 30% are right-sided and 10% are bilateral. The fluid is a hemorrhagic exudate with polymorphonuclear predominance. The pH is 7.32–7.5 and the glucose concentration is similar to the serum glucose level. In acute pancreatitis, effusions are small, with an increase in both serum and pleural fluid amylase. These effusions resolve rapidly once the pancreatitis resolves. There is massive effusion in chronic pancreatitis due to rupture of pseudocyst with pancreaticopleural fistula. There is also an increase in pleural fluid amylase in chronic pancreatitis, but serum amylase is normal.

**Pleural effusion associated with esophageal perforation.** In spontaneous esophageal rupture the pleural fluid findings will depend on the degree of perforation and the timing of thoracocentesis in relation to the injury. Early thoracocentesis without mediastinal perforation will show sterile serous exudates with polymorphonuclear predominance. Pleural fluid amylase and pH will be normal. Once the mediastinal pleura tears, amylase of salivary origin will appear with higher concentration. As anaerobes from the mouth are disseminated throughout the pleural space, the pH may reduce to approximately 6.0. Squamous epithelial cells and food particles will be present.

**Pleural effusion associated with Meigs syndrome.** This syndrome can occur with tumors of the ovary. When the ovarian tumor is removed, the ascites and pleural effusion resolve. The fluid moves into the pleural space through small diaphragmatic lymphatics, because of the pressure gradient across the diaphragm. The fluid is a yellow-colored exudate with a paucity of mononuclear cells.

**Urinothorax.** Pleural effusion secondary to obstructive uropathy is known as urinothorax. Pleural fluid can be right-sided or left-sided, depending on the side of obstructive hydronephrosis. Urinothorax occurs due to perinephric urine leak, which passes through diaphragmatic defects to pleura. It smells like urine. Patients with urinothorax have a pleural fluid creatinine to serum creatinine ratio of >1.0. Effusion resolves with treatment of the primary problem.

**Viral infection.** Patients present with acute symptoms of febrile illness,

dry cough, and chest pain. Radiological findings may show associated pneumonia. These are small effusions, serous exudates with few mononuclear cells. However, acute viral pleurisy may present with polymorphonuclear predominance. Effusions are self-limiting, and usually resolve within 2 weeks.

## BIBLIOGRAPHY

1. Rahman N.M., Chapman S.J., Davies R.J. Pleural effusion: a structured approach to care. *Br Med Bull* 2004; 72:31–47.
2. Miserocchi G. Physiology and pathophysiology of pleural fluid turnover. *Eur Respir J* 1997; 10: 219–225.
3. Maskell N.A. Undiagnosed pleural effusions. In: *Textbook of Pleural Diseases*, 2nd, Light, RW, Lee, YCG (Eds), Arnold Press, London 2008. p.491.
4. Yilmaz U., Polat G., Sahin N., et al. CT in differential diagnosis of benign and malignant pleural disease. *Monaldi Arch Chest Dis* 2005; 63:17.
5. Porcel J.M., Madroñero A.B., Pardina M., et al. Analysis of pleural effusions in acute pulmonary embolism: radiological and pleural fluid data from 230 patients. *Respirology* 2007; 12:234.
6. Toaff J.S., Metser U., Gottfried M., et al. Differentiation between malignant and benign pleural effusion in patients with extra-pleural primary malignancies: assessment with positron emission tomography-computed tomography. *Invest Radiol* 2005; 40:204.
7. Light R.W.: The undiagnosed pleural effusion. *Clin Chest Med* 2006; 27: 309–319.
8. Ferrer J., Roldan J. Clinical management of the patient with pleural effusion. *Eur J Radiol* 2000; 34: 76–86.
9. Davies C.W., Gleeson F.V., Davies R.J. BTS guidelines for the management of pleural infection. *Thorax* 2003; 58(suppl 2): ii18–ii28.
10. Dixit R., Agarwal K C, Gokhroo A., Patil CB, Meena M, Shah NS, Arora P. Diagnosis and management options in malignant pleural effusions. *Lung India* 2017; 34: 160–6.
11. [www.thehealthscience.com/](http://www.thehealthscience.com/) (accessed 08.11.2017).
12. [www.karger.com/](http://www.karger.com/) (accessed 08.11.2017).
13. [www.academic.oup.com/bmb/article](http://www.academic.oup.com/bmb/article) (accessed 08.11.2017).

## DIFFERENTIAL DIAGNOSIS OF MEDIASTINAL SYNDROME

**INTRODUCTION.** In 1757 William Hunter described first the syndrome in a patient with syphilitic aortic aneurysm. In 1954, Schechter reviewed 274 well-documented cases of superior vena cava syndrome (SVCS) reported in the literature; 40% of them were due to syphilitic aneurysms or tuberculous mediastinitis.

**DEFINITION.** Mediastinal syndrome is a group of disorders characterized by infiltration, entrapment or compression of mediastinal structures.

**ETIOLOGY.** The most frequent lesions encountered in the mediastinum are thymoma, neurogenic tumours and benign cysts, altogether representing 60% of patients with mediastinal masses. Neurogenic tumours, germ cell neoplasms and foregut cysts made 80% of childhood lesions, whereas primary thymic neoplasms, thyroid masses and lymphomas are the most common in adults. Anterior mediastinal tumours account for 50% of all mediastinal masses, including thymoma, teratoma, thyroid disease and lymphoma. Masses of the middle mediastinum are typically congenital cysts while those arising in the posterior mediastinum are often neurogenic tumours.

More than 80% of cases of SVCS are caused by malignant mediastinal tumors. Bronchogenic carcinomas account for 75% of all these cases, with most of these being small-cell carcinomas. Non-Hodgkin lymphoma (especially the large-cell type) accounts for 15%.

**PATHOPHYSIOLOGY** The mediastinum is anatomically divided into the anterior, medium and posterior regions. The symptoms of the syndrome are associated with the anatomic structures involved. The compression of the trachea results in dyspnea and respiratory insufficiency, whereas the compression of the esophagus results in dysphagia.

In case of superior vena cava syndrome, the superior vena cava (SVC) and nerves can become trapped, resulting in vein distention, edema of the face or upper extremities, and nervous system symptoms. The SVC is the major drainage vessel for venous blood from the head, neck, upper extremities, and upper thorax. It is located in the middle mediastinum and is surrounded by relatively rigid structures such as the sternum, trachea, right bronchus, aorta, pulmonary artery, and the perihilar and paratracheal lymph nodes. It extends from the junction of the right and left innominate

veins to the right atrium, at a distance of 6-8 cm. Obstruction of the SVC may be caused by neoplastic invasion of the venous wall associated with intravascular thrombosis or, by extrinsic pressure of a tumor mass against the relatively thin-walled SVC.

Complete SVC obstruction is the result of intravascular thrombosis in combination with extrinsic pressure. Incomplete SVC obstruction is more often secondary to extrinsic pressure without thrombosis. Other causes include compression by intravascular arterial devices. An obstructed SVC initiates collateral venous return to the heart from the upper half of the body through four principal pathways. The first and most important pathway is the azygous venous system, which includes the azygos vein, the hemiazygos vein, and the connecting intercostal veins. The second pathway is the internal mammary venous system plus tributaries and secondary communications to the superior and inferior epigastric veins. The long thoracic venous system, with its connections to the femoral veins and vertebral veins, provides the third and fourth collateral routes, respectively. Despite these collateral pathways, the venous pressure is almost always elevated in the upper compartment if the obstruction of the SVC is present. The venous pressure as high as 200-500 cm H<sub>2</sub>O has been recorded in patients with severe SVCS.

### CLASSIFICATION

Causes of mediastinal syndromes are classified according to the anatomic division of the mediastinum, including the anterior, medium and posterior regions (Table 4).

*Table 4.*

**Causes of mediastinal syndrome based on anatomical divisions of the mediastinum**

<b>Anterior mediastinum</b>	<b>Medium mediastinum</b>	<b>Posterior mediastinum</b>
Aortic aneurism	Bronchogenic cyst	Aortic aneurysm
Angiomatous tumor	Bronchogenic tumor	Bronchogenic tumor
Goiter	Lymph node hyperplasia	Esophageal diverticuli
Lipoma	Lymphoma	Esophageal tumor
Lymphoma	Pleuropericardial cyst	Neurogenic tumor
Morgagni hernia	Vascular masses	Parathyroid tumor
Pericardial cyst		
Teratoma		
Thymoma		
Thyroid tumor		

## CLINICAL FEATURES

The usual symptoms at presentation are cough, chest pain, fever, chills and dyspnea. Localized symptoms are secondary to tumour invasion (respiratory compromise; paralysis of the limbs, diaphragm and vocal cords; Horner syndrome; superior vena cava syndrome), while systemic symptoms are typically due to the release of excess hormones, antibodies or cytokines.

Superior vena cava syndrome is suspected in a patient with engorgement of veins of the upper part of the body with resultant edema and suffusion in the head, face and neck. There may be orthopnea and elevation of jugular venous pressure (JVP). Dyspnea is the most common symptom, observed in these patients. Other symptoms include facial swelling, head fullness, cough, arm swelling, chest pain, dysphagia, orthopnea, distorted vision, hoarseness, stridor, headache, nasal stuffiness, nausea, pleural effusions, and light-headedness. The characteristic physical findings of superior vena cava syndrome include venous distention of the neck and chest wall, facial edema, upper-extremity edema, mental changes, plethora, cyanosis, papilledema, stupor, and even coma. Central nervous system symptoms are caused by impeded venous return and resultant cerebral edema; the patient may have lethargy, confusion, headache, irritability, blurred vision or syncope. Clinically, the important parameters of severity of superior mediastinal syndrome (SMS) include the degree, as well as rapidity of obstruction. In patients with non-Hodgkin lymphoma involving the mediastinal nodes, there may be rapid enlargement of the nodes in size. A very rapidly progressive obstruction does not provide adequate duration for the development of collateral channels for venous drainage. These patients tend to be more symptomatic than those with a similar degree of obstruction that has developed gradually, with sufficient period for the formation of collaterals.

## DIAGNOSTIC APPROACH

**Chest radiography** is required to confirm the presence of the mediastinal mass. Location is an important indicator of underlying etiology. Other findings that may coexist include pleural effusion, cardiomegaly suggesting pericardial effusion, and compression of the tracheobronchial tree. On frontal radiographs, the SVC forms an interface along the upper right mediastinal border that fades above the medial end of the clavicle. A widening of this interface suggests SVC dilatation or a mediastinal mass in this location, such as lymphadenopathy, bronchogenic cyst, or malignancy arising from the lung, pleura, or trachea. A round or oval opacity at the right tracheobronchial angle marks the terminal portion of the azygos vein



and is an important landmark for detection of central line malposition. Abnormal dilatation of the azygos vein can be seen as a secondary sign of central venous obstruction or a congenital anomaly such as interruption of the inferior vena cava with azygos continuation.

**CT chest** provides information regarding the exact location and size of mass, infiltration into surrounding structures and vascularity. It aids in planning tissue diagnosis.

**Nonenhanced CT** images can demonstrate SVC duplication, narrowing, and enlargement; central vena cava position; and calcifications along the superior vena cava that could be caused by calcified thrombi, fibrin sheaths, or retained catheter or implantable cardioverter-defibrillator lead fragments. Contrast-enhanced CT of the chest, performed 60–75 seconds after injecting contrast agent into a peripheral vein, achieves excellent uniform enhancement of the superior vena cava.

**Magnetic resonance imaging (MRI)** more accurately distinguishes between cystic and solid lesions than CT.

**Ultrasonography of the chest** may be useful when a CT scan cannot be performed due to concerns of transporting a sick patient, in younger children who are not cooperative for a CT scan in absence of sedation, or if the patient cannot lie supine.

**Echocardiography** may be required if there is a suspicion of pericardial effusion or infiltration by the mass into the pericardial cavity. Echocardiography is useful in diagnosing cardiac tamponade, constrictive pericarditis, cardiac tumours, right-sided heart failure (see Table 2).

**Conventional venography** has the advantage of demonstrating the location and extent of strictures, collateral pathways, endoluminal thrombus, tumor proliferation, the hemodynamic significance of the lesion, and any congenital variants that should be considered when planning stent placement.

**Blood investigations.** Complete blood count presence of blasts in the peripheral blood film would confirm the diagnosis of acute leukemia without any invasive investigations. The presence of any cytopenia or leukoerythroblastic picture would indicate bone marrow involvement and provide an opportunity to confirm the diagnosis by bone marrow examination. Non-Hodgkin lymphoma may be suspected clinically and the peripheral blood examination may be unremarkable. In such a situation, a bone marrow examination may be an option, as it may indicate a diagnosis, if the marrow is involved. The bone marrow examination can be performed safely with underlying thrombocytopenia. Metabolic profile, including uric acid levels is used to determine co-existing complications of tumor lysis syn-



drome and renal dysfunction. Serum  $\alpha$  fetoprotein and  $\beta$ -HCG ( $\beta$ -Human chorionic gonadotropin) levels are determined if there is a suspicion of germ cell tumor in a patient with an anterior mediastinal mass.

**Tissue diagnosis.** The least invasive procedure should be performed to confirm the diagnosis, to reduce the possibility of an adverse cardio respiratory event. A peripheral pathological lesion (enlarged cervical lymph node or skin nodule) is the preferred site for biopsy. In the presence of pleural or pericardial effusion, the fluid should be submitted for general analysis, work up for tuberculosis and for malignant cytology.

Table 5.

### Approach to differential diagnosis in some mediastinal diseases

Condition	Differentiating signs/ symptoms	Investigations
Cardiac tamponade	Absence of facial and upper-extremity oedema. Variation of jugular venous pressure (JVP) with respiration (prominent x-descent). Presence of pulsus paradoxus.	Pericardial effusion is seen on CT chest. Echocardiography shows bouncing septum, marked respiratory variation in the early left ventricular filling velocity (>25%), and right ventricular diastolic collapse.
Constrictive pericarditis	Elevated JVP with prominent negative descents (x- and y-descent). Presence of Kussmaul's sign (increase in JVP with inspiration).	Echocardiography may show thickened pericardium and marked respiratory variation in the early left ventricular filling velocity (>25%). MRI shows pericardial thickening and ventricular interdependence. Cardiac catheterisation shows discordance of left and right ventricular pressures with respiration, which has high specificity for diagnosis.
Exacerbation of COPD	Extensive bilateral expiratory wheezing, hypoxia, and hypercarbia.	Peak flow, spirometry, and bronchodilator response help in differentiating. Presence of obstructive defect on pulmonary function testing is seen.
Right-sided heart failure	Preserved respiratory variation in JVP, prominent negative descents, and sometimes increased v wave due to tricuspid regurgitation.	Echocardiography will show right ventricular dysfunction and dilated inferior vena cava with lack of inspiratory collapse.
Pulmonary embolism	Upper extremity oedema is usually absent.	CT chest with contrast will show presence of thrombus inside the pulmonary artery.
Cardiac tumour	Upper extremity oedema is usually absent.	Echocardiography or cardiac MRI will show presence of a mass, usually inside the right side of the heart.

## Mediastinal masses

**Thymoma** is the most common primary neoplasm of the anterior mediastinum but accounts for less than 1% of all adult malignancies. Thymomas typically occur in patients older than 40 years of age, being rare in children, and affecting men and women equally. Myasthenia gravis associated with thymoma occurs most frequently in women. The role of imaging is to initially diagnose and properly stage thymoma, with emphasis on the detection of local invasion and distant spread of the disease. Between 45% and 80% of thymomas are visible by chest radiography. On CT scans, thymomas usually appear as homogeneous solid masses with soft tissue attenuation and well-demarcated borders, located anywhere from the thoracic inlet to the cardiophrenic angle. Thymomas may be oval, round or lobulated and when they are large, cystic or necrotic degeneration may be shown. Calcification may be present in the capsule or throughout the mass. Certain findings, such as encasement of mediastinal structures, infiltration of fat planes, irregular interface between the mass and lung parenchyma, and direct signs of vascular involvement are highly suggestive of invasion. Pleural dissemination („drop metastases”) manifests as one or more pleural nodules or masses, and they are almost always ipsilateral to the tumour. Thymoma rarely presents with metastatic lymphadenopathy, metastatic pulmonary nodules or pleural effusion.

**Thymic carcinoma** accounts for about 20% of thymic epithelial tumours with a mean age of 50 years. The typical appearance is a multilobulated and heterogeneous mass that may contain areas of calcification or haemorrhage. Distant metastases are present at the initial diagnosis in half of the patients with irregular contour, necrotic or cystic components, heterogeneous enhancement, lymphadenopathy and great vessel invasion.

**Thymic hyperplasia** can be divided into two distinct histological types. *True thymic hyperplasia* is defined as the enlargement of the thymus, which generally retains its normal shape. This disease is observed when a patient is recovering from chemotherapy, corticosteroid therapy, irradiation or thermal burns. The phenomenon known as rebound hyperplasia is defined as a greater than 50% increase in thymic volume over baseline after the above mentioned conditions. *Thymic lymphoid (follicular) hyperplasia* of the thymus refers to the presence of an increased number of lymphoid follicles. It is commonly associated with autoimmune diseases, being seen in up to 65% of cases with myasthenia gravis and it has been reported to occur in the early stages of human immunodeficiency virus infection. On CT it may

appear normal, enlarged or as a focal thymic mass. It is important for radiologists to be able to distinguish thymic hyperplasia from neoplasm. Diffuse symmetric enlargement of the gland, smooth contour and normal vessels are the key morphological features of hyperplasia, whereas neoplasm tends to manifest as a focal mass with nodular contour and necrotic or calcified foci. Detecting fat in the thymus is particularly relevant in these situations.

**Teratoma** is the most common mediastinal germ cell tumour. Mature teratomas are composed of well-differentiated benign tissues with predominant ectodermal element. If a teratoma contains fetal tissue or neuroendocrine tissue, it is defined as immature and malignant with a poor prognosis. On chest CT teratoma appears as a well-defined unilocular or multilocular cystic lesion containing fluid, soft tissue and fat attenuation. Calcifications may be focal, rim-like or representative of teeth or bone. On MRI teratomas typically demonstrate heterogeneous signal intensity, representing various internal elements (e.g., fat-fluid levels within the lesion). Ruptured teratomas show an adjacent consolidation, atelectasis and pleural or pericardial effusion.

**Intrathoracic goiter** is typically a multinodular benign disease, that may become a life-threatening condition when it causes the obstruction of respiratory and neurovascular structures. It is known that 80% of intrathoracic goiters are located in the anterior mediastinum, whereas 10–15% of goiters are situated in the posterior mediastinum. Mediastinal syndrome in case of goiter can be a life threatening condition due to severe tracheal lumen compression, which leads to acute respiratory insufficiency. Following thyroidectomy, patients usually experience rapid clinical benefit, and dyspnea and respiratory insufficiency cease. Short-term complications of intrathoracic goiter include the development of severe acute respiratory failure that may require intubation, whereas long-term complications include the development of thyroid cancer.

**Hodgkin disease** (HD) has a bimodal distribution of incidence peaking in young adulthood and again after the age of 50 years. Most patients experience constitutional symptoms. Four subtypes of HD are described: nodular sclerosis, lymphocyte-rich, mixed cellularity and lymphocyte depleted HD. Chest X-ray shows enlargement of the prevascular and paratracheal nodes. Characteristic features on imaging are a homogeneous soft-tissue anterior mediastinal mass with mild to moderate contrast enhancement, irregular contours, surface lobulation, absence of vascular involvement, and high prevalence of associated mediastinal lymphadenopathy.

**Non-Hodgkin disease** (NHD) has the two most common forms: diffuse large B-cell lymphoma and T-cell lymphoblastic lymphoma. T-cell lymphoblastic lymphoma mainly occurs in children and adolescents. The most common CT appearance includes a large mediastinal mass representing thymic and lymph node enlargement, which compresses the airway and cardiovascular structures and low attenuation areas reflecting necrosis. Primary mediastinal diffuse large B-cell lymphomas occur in young to middle-aged adults and account for 7% of all cases of NHD and about 10% of all cases of high-grade NHD. The tumours appear as a large, smooth or lobulated, anterior mediastinal mass in nearly all patients. On CT the tumours show low attenuation areas, representing haemorrhage, necrosis or cystic degeneration and heterogeneous enhancement.

**Cystic masses.** Mediastinal primary cysts make 15–20% of all primary mediastinal masses. A smooth or oval mass with a homogeneous attenuation, with no enhancement of cyst contents and no infiltration of adjacent structures are the usual CT features of benign mediastinal cyst. Any cyst may have a higher attenuation due to its calcic, proteinaceous, mucous or haemorrhagic content.

**Bronchogenic cysts** result from abnormal ventral budding or branching of the tracheobronchial tree during embryologic development. They are lined with respiratory epithelium and their capsule contains cartilage, smooth muscle and mucous gland tissue. They are stable in size, except when complicated by infection or haemorrhage. Approximately 40% of bronchogenic cysts are symptomatic, resulting in cough, dyspnea or chest pain. Bronchogenic cyst is commonly located in the near carina and in the paratracheal region. Air within the cyst is suggestive of secondary infection and communication with the tracheobronchial tree.

**Pericardial cyst** is a benign lesion accounting for 5–10% of all mediastinal tumours. Most pericardial cysts are unilocular and commonly located in the right cardiophrenic space.

**Thymic cyst** represents 1% of all mediastinal masses. Congenital cysts derive from remnants of the thymopharyngeal duct, they are typically unilocular and contain clear fluid. Acquired thymic cysts are much more common, tend to be multilocular and may arise in association with neoplasms such as thymomas, lymphomas or germ cell tumours. Thymic cysts may also be seen in the anterior mediastinum after radiation therapy of Hodgkin's disease, after inflammatory processes and occasionally in patients with AIDS.

**Pancreatic pseudocyst** can extend into the mediastinum via the oesophageal or aortic hiatus. CT shows a thin-walled, fluid-containing cyst within the posterior mediastinum which may be in continuity with the intrapancreatic or peripancreatic fluid collections.

**Lymphangioma** is a rare benign lesion of lymphatic origin that makes 0.7–4.5% of all mediastinal tumours in adult population. Lymphangiomas involve the neck or the axillary region in more than 80% of the cases and the thorax in 10% of the cases.

**Neurogenic tumors** are among the most common causes of posterior mediastinal mass and account approximately 20% of all adults and 35% of all paediatric mediastinal tumours. *Peripheral nerve tumours* are the most common mediastinal neurogenic tumours and originate from spinal or proximal intercostal nerve. Schwannomas are the most common (50%) mediastinal neurogenic tumours and frequently affect patients aged from 20 to 30 years. They are usually solitary and encapsulated masses, but multiple schwannomas may be associated with neurofibromatosis type 2. The tumour may grow through the adjacent intervertebral foramen and spinal canal to produce a „dumbbell” or „hourglass” configuration. Cystic changes and haemorrhage are more common in schwannomas than in neurofibromas. Neurofibromas are non-encapsulated soft tissue tumours and account for approximately 20% of mediastinal neurogenic tumours. A sudden increase in the size of a previously stable neurofibroma and the presence of neurological symptoms suggests malignant transformation to malignant peripheral nerve tumour.

**Paraganglioma** is a rare neuroendocrine tumour of chromaffin cell origin. One to two percent of extra-adrenal paragangliomas occur in the thorax. Aortopulmonary paragangliomas are usually asymptomatic, while aortosympathetic paragangliomas (along the sympathetic chain in the posterior mediastinum) occur in symptomatic patients related to the functional activity of the tumour. These masses commonly enhance brightly at enhanced CT. A characteristic MRI finding of paragangliomas is the presence of multiple curvilinear and punctate signal voids, which reflect high velocity flow in the intratumoral vessels, described as „salt-and-pepper” appearance.

**Ganglioneuromas** are the most benign and differentiated of the autonomic ganglionic tumours. Radiographically, the tumours are well-margined, occurring along the anterolateral aspect of the spine and spanning three to five vertebrae. The „whorled appearance” is due to curvilinear bands

of low signal intensity that reflects collagenous fibrous tissue in the mass on T2-weighted images. Most ganglioneuromas show gradual and heterogeneous contrast enhancement. Ganglioneuroblastomas are the least common type of neurogenic tumour and show intermediate features in cellular maturity between neuroblastoma and ganglioneuroma. Neuroblastomas are highly aggressive and readily metastasising tumours of neuroectodermal origin and it takes on average 22 months to diagnose it. They are heterogeneous and non-encapsulated lesions, often exhibiting haemorrhage, necrosis, calcification or cystic degeneration.

### **Less common mediastinal masses**

*Parathyroid adenomas* may be seen in ectopic locations, the mediastinum being the most commonly site. High-resolution ultrasonography is recognized as a tool for detecting cervical parathyroid lesions. As it enlarges, an abnormal gland appears as a hypoechoic, and often anechoic, lesion, often posterior in location to the thyroid. As the gland enlarges, it can develop lobularity and foci of echogenicity. Colour Doppler assessment of parathyroid lesions is a useful integration of grey-scale. These tumours tend to be small and may show calcifications on CT.

*Haematoma.* High attenuation of haematomas can be observed on unenhanced CT scans during the first 72 h. When the hematoma ages its attenuation decreases on CT in a centripetal fashion.

*Haemangiomas* in the mediastinum are rare and they may be associated with Rendu–Osler syndrome.

*Sarcomas* of other than vascular or neural origin, including fibrosarcomas, osteosarcomas and chondrosarcomas, are also very uncommon.

**Mediastinitis** most commonly occurs following cardiovascular surgery, external cardiac compression (conventional cardiopulmonary resuscitation), obesity, postoperative shock, prolonged bypass, reoperation, esophageal perforation; trauma, especially blunt trauma to the chest or abdomen, tracheobronchial perforation, due to either penetrating or blunt trauma or during bronchoscopy; descending infection following surgery of the head and neck, great vessels, or vertebrae. Vital signs generally may show tachycardia and fever. In more advanced cases of sepsis, septic shock may be present requiring large volumes of crystalloid or vasopressor medication for support. The Hamman sign is a crunching sound heard with a stethoscope over the precordium during systole. Its presence should alert the clinician to possible mediastinitis. Sternal pain, instability, or click; local cellulitis; and drainage can also be observed.

A complete blood count shows leukocytosis, often with a left shift on the white blood cell count differential. The hematocrit value decreases if bleeding has occurred. The platelet count increases in the early stages of sepsis or decreases as sepsis worsens or disseminated intravascular coagulation (DIC) occurs. Bacteremia can be observed, as well as elevation of serum procalcitonin more than 2 ng/mL. Samples of any sternal drainage should be sent for Gram stain and culture. Chest radiography findings include pneumomediastinum and air-fluid levels within the mediastinum. Air-fluid levels are often best seen on lateral films. Mediastinal widening is not a reliable sign of mediastinitis, especially postoperatively. Computed tomography is more accurate for helping to identify air-fluid levels and pneumomediastinum. A CT scan may demonstrate sternal separation and substernal fluid collections.

Chronic fibrosing mediastinitis, occurs as a complication of granulomatous infections, most commonly *Histoplasma capsulatum*. Rupture of mediastinal lymph nodes and the release of caseous material generate an intense inflammatory reaction. The patient becomes symptomatic from obstruction of major mediastinal structures, especially the superior vena cava.

**Superior vena cava syndrome** is the obstruction of the vena cava superior caused by malignant mediastinal tumors (bronchogenic small-cell carcinomas, non-Hodgkin lymphoma, Hodgkin lymphoma, metastatic cancers, primary leiomyosarcomas of the mediastinal vessels, and plasmocytomas and nonmalignant conditions (mediastinal fibrosis, aortic aneurism, tuberculosis, syphilis, histoplasmosis, teratoma, thymoma, dermoid cyst, pericarditis, atrial myxoma and thrombosis related to the presence of central vein catheters). Chest radiography may reveal a widened mediastinum or a mass in the right side of the chest. Computed tomography has the advantage of providing more accurate information on the location of the obstruction and may guide attempts at biopsy by mediastinoscopy, bronchoscopy, or percutaneous fine-needle aspiration. Invasive contrast venography, the most conclusive diagnostic method, precisely defines the etiology of obstruction.

**BIBLIOGRAPHY**

1. Wilson L.D., Detterbeck F.C., Yahalom J. Superior vena cava syndrome with malignant causes. *N Engl J Med* 2007; 356: 1862–9.
2. Chapman S., Nakielny R. Respiratory tract. In: Chapman S., Nakielny R., eds., *Aids to Radiological Differential Diagnosis*. 4th ed. London: Saunders; 2003. pp. 180–187.
3. Wilson L.D., Detterbeck F.C., Yahalom J. Superior vena cava syndrome with malignant causes. *N. Engl. J Med* 2007; 356: 1862–9.
4. Schechter M.M. The superior vena cava syndrome. *Am J Med Sci* 1954; 227 (1): 46–56.
5. Abner A. Approach to the patient who presents with superior vena cava obstruction. *Chest* 1993; 103 (4 Suppl): 394S–397
6. Cheng S. Superior Vena Cava Syndrome: A contemporary review of a historic disease. *Cardiol Rev* 2009; 17:16–23.
7. Ricketts R.R. Clinical management of anterior mediastinal tumors in children. *Semin Pediatr Surg* 2001; 10: 161–8.
8. Markman M. Diagnosis and management of superior vena cava syndrome. *Cleve Clin J Med* 1999; 66: 59–61.
9. Zardi E.M., Pipita M.E., Afeltra A. Mediastinal syndrome: A report of three cases. *Exp Ther Med* 2016; 12(4): 2237–2240.
10. Petersdorf S.H., Wood D.E. Lymphoproliferative disorders presenting as mediastinal neoplasms. *Semin Thorac Cardiovasc Surg* 2000; 12: 290–300.
11. <https://www.ncbi.nlm.nih.gov/pubmed> (accessed 08.12.2017).
12. <https://www.resmedjournal.com/article/> (accessed 08.12.2017).



## DIFFERENTIAL DIAGNOSIS OF ALLERGIC DISEASES

**INTRODUCTION.** Some allergic diseases are known to mankind since ancient times. The first information about the „hay fever” dates back to the 9th century. Later allergic diseases (AD) were singled out by English physician John Bostock in 1819, his reasoning was based on only three clinical cases. The prevalence of AD has grown enormously and has increased hundreds of times over the past centuries. Currently, in the general population, the number of patients with these diseases varies from 10 to 25%, generally and about 500 million people in the world suffer from AD.

**DEFINITION.** Allergy is a hyperreactivity of an organism, the mechanism of which is the development of an immunologically mediated allergen-specific reaction, carried out through cellular and humoral processes.

*Table 6.*

**Pathogenetic classification of hypersensitivity reactions  
(according to Coombs and Gell)**

Immune reactant	Hypersensitivity types			
	Type I Ig E	Type II IgG or IgM	Type III IgG or IgM	Type IV T cells
Antigen form	Soluble antigen	Cell-bound antigen	Soluble antigen	Soluble antigen or cell-bound antigen
<i>Mechanism of activation</i>	Allergen-specific IgE antibodies bind to mast cells via their Fc receptor. When the specific allergen binds to the IgE, cross-linking of IgE induces degranulation of mast cells.	IgG or IgM binds to cellular antigen, leading to complement activation or cell lysis.	Antigen-antibody complexes are deposited in tissues. Complement activation provides inflammatory mediators and recruits neutrophils. Enzymes released from neutrophils damage tissue.	T <sub>H</sub> cells secrete cytokines which activate macrophages and cytotoxic T cells.
<i>Examples of hypersensitivity reactions</i>	Anaphylaxis Urticaria Angioedema Allergic rhinitis and conjunctivitis Drug reactions Food allergies	Transfusion reactions Drug reactions Haemolytic anemia Immune Thrombocytopenic purpura	Serum sickness Post-streptococcal acute glomerulonephritis Rheumatoid arthritis Systemic lupus erythematosus Drug reactions	Contact dermatitis Atopic dermatitis Drug reactions Graft-versus-host disease

## ANAPHYLAXIS

**Definition.** Anaphylaxis is an acute, severe and potentially life-threatening type 1 allergic systemic reaction, during which all or some of the following are present: urticaria/angioedema, upper airway obstruction, bronchospasm, and hypotension. In some cases, these manifestations may be accompanied by cardiovascular and/or gastrointestinal disturbances.

**Classification:**

- a) Immunologic Anaphylaxis: IgE (e.g., from penicillin) or non-IgE (e.g., infusion of aggregates of heterologous immunoglobulin that cause complement activation).
- b) Nonimmunologic Anaphylaxis (eg. radiocontrast media).

**Etiology** includes: foods (peanuts, tree nuts, shellfish, fish), drugs (e.g., antibiotics, nonsteroidal anti-inflammatory drugs), insect stings (bees; wasps; yellow jackets; hornets), latex, exercise and idiopathic.

**Pathophysiology.** In IgE-mediated anaphylaxis prior exposure to the allergen promotes specific IgE antibodies to the allergen during a sensitization period which is not usually associated with symptoms. After a sufficient amount of allergen-specific IgE becomes bound to membranes of mast cells and basophils, re-exposure to an allergen results in crosslinking of adjacent IgE antibodies and activation of inflammatory mediators. Since the integrity of the vascular endothelium is disrupted by the effects of histamine and other mediators, loss of intravascular volume via third spacing plays a major role in the development of hypotension.

**Clinical presentation.** The most frequent symptoms and signs of anaphylaxis are categorized in:

1. *Involvement of skin, subcutaneous tissue, and mucosa* (flushing, itching, urticaria (hives), angioedema, morbilliform rash, pilor erection, peri-orbital itching, erythema and edema, conjunctival erythema, tearing, itching of lips, tongue, palate, and external auditory canals; swelling of lips, tongue, and uvula, itching of genitalia, palms, and soles);
2. *Respiratory* manifestations (nasal itching, congestion, rhinorrhea, sneezing, throat itching and tightness, dysphonia, hoarseness, stridor, dry staccato cough; tachypnea, shortness of breath, chest tightness, deep cough, wheezing/bronchospasm, decreased peak expiratory flow, cyanosis, respiratory arrest);
3. *Gastrointestinal* manifestations (abdominal pain, nausea, vomiting, diarrhea, dysphagia);
4. *Cardiovascular* manifestations (chest pain, tachycardia, bradycardia

- (less common), other arrhythmias, hypotension, feeling faint, urinary or fecal incontinence, shock, cardiac arrest);
5. *Central nervous system involvement* (aura of impending doom, uneasiness (in infants and children, sudden behavioral change, eg. irritability, cessation of play, clinging to parent); throbbing headache, altered mental status, dizziness, confusion, tunnel vision);
  6. *Other* (metallic taste in the mouth, cramps and bleeding due to uterine contractions in females).

Clinical course can embrace 2 forms: immediate (anaphylaxis develops within minutes (parenteral allergens) to an hour of exposure (after ingestion of oral allergens) and biphasic (patients seem to have fully recovered when a severe recurrence suddenly develops, usually 4–6 hours after an initial reaction). Bronchospasm during these recurrences is typically refractory to standard therapy and often requires intubation and mechanical ventilation.

**Diagnostic criteria of anaphylaxis** (*World Allergy Organization, 2011*)

Anaphylaxis is highly likely when any one of the following **three criteria** is fulfilled:

**1. Acute onset of an illness** (minutes to several hours) with involvement of the skin, mucosal tissue, or both (e.g., generalized urticaria, itching or flushing, swollen lips-tongue-uvula)

AND AT LEAST ONE OF THE FOLLOWING:

- Respiratory compromise (e.g., dyspnea, wheezes, stridor, reduced peak expiratory flow, hypoxemia);
- Reduced blood pressure or associated symptoms of end-organ dysfunction (e.g., hypotonia, syncope, incontinence);

OR

**2. Two or more of the following** that occur rapidly after exposure to a *likely allergen* for that patient (minutes to several hours):

- Involvement of the skin-mucosal tissue (e.g., generalized urticaria, itch-flush, swollen lips-tongue-uvula);
- Respiratory compromise (e.g., dyspnea, wheezes, stridor, reduced PEF, hypoxemia);
- Reduced blood pressure or associated symptoms (e.g., hypotonia, syncope, incontinence);
- Persistent gastrointestinal symptoms (e.g., crampy abdominal pain, vomiting);

OR

**3. Reduced blood pressure** after exposure to known allergen for that patient (minutes to several hours):

- a) Infants and children: low systolic blood pressure (age-specific) or greater than 30% decrease in systolic blood pressure. Low systolic blood pressure for children is defined as less than 70 mm Hg from 1 month to 1 year, less than  $(70 \text{ mm Hg} + [2 \times \text{age}])$  from 1 to 10 years, and less than 90 mm Hg from 11 to 17 years;
- b) Shock in infants is more likely to be manifested initially by tachycardia than by hypotension. Normal heart rate ranges from 80-140 beats/min at the age of 1-2 years; from 80-120 beats/min at the age of 3 years; and from 70-115 beats/min after the age of 3 years;
- c) Adults: systolic blood pressure of less than 90 mm Hg or greater than 30% decrease from that person's baseline.

### **Laboratory Tests in the Diagnosis of Anaphylaxis**

- a) *Sensitization to the trigger* suggested by the history should be confirmed by using allergen skin tests and/or measurement of allergen-specific IgE levels in serum. The optimal time for testing is generally stated to be 3-4 weeks after an acute anaphylactic episode. Patients with a convincing history of anaphylaxis and negative tests should therefore be retested weeks or months later.
- b) *Total tryptase* (pro- and mature forms of alpha/beta tryptases), obtained from blood sample within 15 minutes to 3 hours of symptom onset. It is important to measure levels in accurately timed serial blood samples during the anaphylactic episode and to compare levels measured during the episode with a baseline level, obtained either 24 hours after resolution of the acute episode or on frozen serum. If tryptase level is  $> 11.4 \text{ ng/mL}$  in baseline serum, the diagnosis of mastocytosis or clonal mast cell disorder should be considered; if tryptase level is higher during the acute anaphylactic episode than in baseline serum, the diagnosis of anaphylaxis is confirmed; if tryptase level is within normal limits during a clinically diagnosed acute anaphylactic episode, the normal tryptase level cannot be used to rule out the diagnosis.
- c) *Histamine* measurement – from blood sample within 15 minutes to 1 hour of symptom, as well as histamine and its metabolite *N*-methylhistamine in a 24-hour urine sample.

### **DIFFERENTIAL DIAGNOSIS OF ANAPHYLAXIS**

1. Common diseases (bronchial asthma, syncope, anxiety/panic attack, acute generalized urticaria, aspiration of a foreign body, myocardial infarction, pulmonary embolus, seizure, cerebrovascular event)

2. Postprandial syndromes (scombroid poisoning, pollen-food allergy syndrome, monosodium glutamate syndrome, adverse reactions to sulphites, food poisoning)
3. Flush syndromes (perimenopause syndrome, carcinoid syndrome, autonomic epilepsy, medullary carcinoma of the thyroid)
4. Shock (hypovolemic, cardiogenic, distributive, obstructive)
5. Excess endogenous histamine (mastocytosis/clonal mast cell disorders, acute basophilic leukemia)
6. Nonorganic disease (vocal cord dysfunction, hyperventilation, psychosomatic episode)
7. Others (nonallergic angioedema, hereditary angioedema types I, II, and III, ACE inhibitor-associated angioedema, systemic capillary leak syndrome, red man syndrome (vancomycin), pheochromocytoma).

### 1. Common diseases

**Bronchial asthma.** A severe asthma episode can cause diagnostic confusion because wheezing, coughing, and shortness of breath can occur in both asthma and anaphylaxis; however, itching, urticaria, angioedema, abdominal pain, and hypotension are unlikely in acute asthma.

**Syncope.** It can cause diagnostic confusion because hypotension can occur in both syncope and anaphylaxis; however, syncope is relieved by recumbency and is usually associated with pallor and sweating, and absence of urticaria, flushing, respiratory symptoms and gastrointestinal symptoms

**Anxiety/panic attack.** An anxiety/panic attack can cause diagnostic confusion because a sense of impending doom, breathlessness, flushing, tachycardia, and gastrointestinal symptoms can occur in both anxiety/panic attacks and in anaphylaxis; however, urticaria, angioedema, wheezing, and hypotension are unlikely during an anxiety/panic attack.

**Acute generalized urticaria** (see Differential diagnosis of urticaria)

**Aspiration of a foreign body** (see Differential diagnosis of broncho-obstructive syndrome)

**Cardiovascular diseases (myocardial infarction)** – (see Differential diagnosis of chest pain), **pulmonary embolism** – (see Differential diagnosis of lung consolidation)

**Neurologic events (seizure, cerebrovascular event)** should be differentiated from neurological manifestations of anaphylaxis by a complete neurological examination to reveal pathological neurological signs (e.g., Babinsky, signs of oral automatism) as well as by instrumental examina-

tions (cerebral CT – for stroke and tumor, Electroencephalogram – for epilepsy).

## 2. Postprandial syndromes

**Scombroid poisoning** occurs after the ingestion of fresh, canned or smoked fish with high histamine levels due to improper processing or storage. Histamine produced by the decarboxylation of histidine in the muscle of the fish is primarily responsible for the condition. The decarboxylation process is induced by enzymes produced by enteric gram-negative bacteria (e.g., *Morganella morganii*, *Escherichia coli*, *Klebsiella* species and *Pseudomonas aeruginosa*) found in fish cuts and intestines. Symptoms of scombroid poisoning include: flushing, urticaria, palpitations, burning of the mouth and throat, headache, sweating, abdominal cramps, nausea, vomiting, diarrhea, expiratory dyspnea, respiratory distress and shock. The symptoms start within 10 to 90 minutes after eating the implicated fish. The rash lasts 2–5 hours, and the other symptoms usually disappear within 3–36 hours. The diagnosis is clinical and can be confirmed by measurement of the patient's histamine level in plasma or the level of histamine metabolites (N-methyl-histamine) in urine and histamine in incriminated spoiled food.

**Pollen-food allergy syndrome.** It is elicited by fruits and vegetables containing various plant proteins that cross-react with airborne allergens. Typical symptoms include itching, tingling and angioedema of the lips, tongue, palate, throat, and ears after eating raw, but not cooked, fruits and vegetables.

**Monosodium glutamate syndrome.** Monosodium glutamate is a flavor enhancer commonly added to Chinese food, canned vegetables, soups and processed meats. The reports of adverse reactions to foods containing monosodium glutamate – known as monosodium glutamate syndrome – include: headache, flushing, sweating, facial pressure or tightness, numbness, tingling or burning in the face, neck and other areas, palpitations, chest pain, nausea and weakness.

**Adverse reactions to sulphites.** Sulphites are widely used as preservative and antioxidant additives in the food and pharmaceutical industries. Exposure to sulphites has been reported to induce a range of adverse clinical effects in sensitive individuals, ranging from dermatitis, urticaria, flushing, hypotension, abdominal pain and diarrhoea to life-threatening anaphylactic and asthmatic reactions. The possibility of sulphite sensitivity should be considered when individuals demonstrate adverse reactions to a range of exposures, with no obvious pattern, particularly when these individuals

experience a worsening of asthma symptoms following the consumption of foods such as dried fruits and wines, or adverse skin reactions following the use of cosmetics or medicated creams.

**Food poisoning.** Most food poisoning is caused by bacteria, viruses, and parasites rather than toxic substances in the food. The symptoms of food poisoning include upset stomach, abdominal cramps, nausea and vomiting, diarrhea, fever, and dehydration. The symptoms may range from mild to severe. The disease usually affects several people.

### 3. Flush syndromes

**Perimenopause syndrome.** It is a defined period of time beginning with the onset of irregular menstrual cycles until the last menstrual period, and is marked by fluctuations in reproductive hormones. This period is characterized by menstrual irregularities; prolonged and heavy menstruation intermixed with episodes of amenorrhea, decreased fertility, vasomotor symptoms (hot flashes) and insomnia. Some of these symptoms may emerge 4 years before menses ceases. During the menopausal transition, estrogen levels decline and levels of FSH and LH increase. The menopausal transition is characterized by variable cycle lengths and missed menses, whereas the postmenopausal period is marked by amenorrhea. *Ex juvantibus* criterion for differentiation is a disappearance of flushes after very-low-dose estrogen therapy.

**Carcinoid syndrome** (see Differential diagnosis of broncho-obstructive syndrome)

**Autonomic epilepsy.** The symptoms frequently occur during epileptic seizures either as an accompaniment to other seizure symptoms or as the predominant seizure manifestation mediated by an activation of the central autonomic network. Autonomic symptoms can be divided into cardiovascular changes (sinus tachycardia of > 120 beats per minute, cardiogenic syncope known as „ictal bradycardia syndrome” in male patients suffering from temporal lobe epilepsy, chest pain associated with radiation of the pain to the jaw or left arm, diaphoresis, shortness of breath), respiratory manifestations (dyspnoe, hyperventilation, stridor, coughing, choking, apnea and potentially fatal neurogenic pulmonary edema), gastrointestinal symptoms (epigastric auras, paroxysmal pain of abrupt onset and brief duration of a few minutes or less and is localized to the midline or upper abdomen, ictal vomiting, ictal spitting) cutaneous manifestations (flushing, pallor, sweating and piloerection, which may be accompanied by feelings of warmth, cold and pain), pupillary symptoms (bilateral mydriasis, bilateral



ictal miosis accompanied by internal ophthalmoplegia), genital and sexual manifestations (sexual auras, genital auras, sexual automatism and genital automatism) and urinary symptoms (urinary incontinence). The diagnosis is confirmed by Electroencephalogram, computerized tomography and MRI.

**Medullary carcinoma of the thyroid (MTC)** is a distinct thyroid carcinoma that originates in the parafollicular C cells producing calcitonin. Sporadic MTC accounts for 75% of cases and inherited MTC constitutes the rest. Inherited MTC occurs in association with multiple endocrine neoplasia (MEN) type 2A and 2B syndromes, but non-MEN familial MTC also occurs. In MTC one or more of the following symptoms may be observed: a lump at the base of the neck, which may interfere with or become more prominent during swallowing, hoarseness, dysphagia, and respiratory difficulty; various paraneoplastic syndromes, including Cushing or carcinoid syndrome; diarrhea due to increased intestinal electrolyte secretion secondary to high plasma calcitonin levels; distant metastases (e.g., lung, liver, bone), resulting in weight loss, lethargy, and bone pain. The diagnosis of MTC is usually made by a fine needle aspiration biopsy of a thyroid nodule, or after the nodule is surgically removed. Patients in whom the results of a fine needle aspiration biopsy are suggestive or indicative of MTC should be further evaluated with measurement of calcitonin and carcinoembryonic antigen (CEA) in the blood, which are typically elevated in patients with MTC. The familial MTC can be determined by a blood test for the RET protooncogene.

#### **4. Shock (see Differential diagnosis of heart failure)**

#### **5. Excess endogenous histamine**

**Mastocytosis/clonal mast cell disorders** (see differential diagnosis of urticaria)

**Acute basophilic leukemia (ABL)** is a rare and poorly characterized form of leukemia presenting with dizziness, maculopapular skin lesions, epigastric pain and occasionally melena. The gastric and skin manifestations of ABL may be associated with excessive histamine release from basophilic cells. The diagnosis of ABL is determined due to characteristic cytomorphological features, the myeloid immunophenotype of the blast cells (identified to be positive for cluster of differentiation CD25 and CD123) in addition to the absence of the Philadelphia chromosome and a c-kit D816V mutation. The fibroesophagogastroscopy reveals signs of erosions or gastric antral ulcer.

#### **6. Other causes**



**Nonallergic angioedema, hereditary angioedema types I, II, and III** (see Differential diagnosis of angioedema)

**ACE inhibitor-associated angioedema** represents nonimmunologic adverse effects of angiotensin-converting enzyme (ACE) inhibitors which are thought to stem from an accumulation of bradykinin and other vasoactive peptides. Angioedema can occur within several weeks of commencing a drug course but may develop after many months of use. Angioedema usually involves the face and oropharyngeal tissue and can result in life-threatening upper airway obstruction. For patients with ACE-inhibitor-induced angioedema that is unresponsive to usual measures, fresh frozen plasma administration has been reported to be beneficial in case reports. Intolerance to one ACE inhibitor usually predicts intolerance to all drugs of this class.

**Systemic capillary leak syndrome**, also known as Clarkson's disease and spontaneous periodic edema, is a very rare condition of middle age patients caused by unexplained episodic capillary hyperpermeability and is a potentially fatal disorder characterized by stereotypic recurrent episodes of edema, hypovolemic shock, hypoalbuminemia, hemoconcentration, and persistence of serum M protein, frequently associated with a monoclonal gammopathy predominantly of the IgG- $\kappa$  type. The degree of albumin decrement during an attack correlates with the development of rhabdomyolysis.

**Red man syndrome.** Vancomycin infusions are commonly associated with the red man syndrome (skin flushing, erythema, pruritus, hypotension, and pain or muscle spasms of the chest and back). These reactions are caused by non-IgE-mediated histamine release that is more likely with rapid infusion rates (>10 mg/min). Tolerance of readministration is promoted by reduction of the infusion rate and pretreatment with H1 antihistamines.

**Pheochromocytoma.** It is a rare, catecholamine-secreting tumor that may precipitate life-threatening hypertension. Clinical signs associated with pheochromocytomas include the following: hypertension, which is paroxysmal in 50% of cases, postural hypotension, hypertensive retinopathy, weight loss, pallor, fever, tremor, neurofibromas, tachyarrhythmias, pulmonary edema, cardiomyopathy, ileus and *café au lait* spots. Laboratory and instrumental confirmatory findings include: plasma metanephrine testing, 24-hour urinary collection for catecholamines and metanephrines, abdominal CT scanning (accuracy of 85-95% for detecting adrenal masses with a spatial resolution of 1 cm or greater), MRI (preferred over CT scanning

in children and pregnant or lactating women; it has a sensitivity of up to 100% in detecting adrenal pheochromocytomas).

## URTICARIA

**Definition.** Urticaria is a type I hypersensitivity disease characterized by the development of wheals (hives), angioedema, or both. The common inciting agents include: foods, drugs, contact allergy, insect bites, infections (bacterial and viral), cold, cholinergic (hot baths, emotions), sun and physical exercise.

**Pathophysiology.** Urticaria is a mast-cell-driven disease. Histamine and other mediators, such as platelet-activating factor and cytokines are released from activated mast cells, and there is a triple response: vasodilatation (erythema), increased vascular permeability (wheal), axon reflex (flare). Skin affected by wheals virtually always exhibits upregulation of endothelial cell adhesion molecules and a mixed inflammatory perivascular infiltrate of variable intensity, consisting of neutrophils and/or eosinophils, macrophages, and T cells, but without vessel-wall necrosis.

**Clinical presentation.** In urticaria the lesions are extremely pruritic, slightly raised that appear suddenly. The lesions are not vesicular, have a red with white halo, or white with red halo, last 2–12 hours before resolving, have a changing shape, and/or shifting to new sites. It has a fleeting nature, with the skin returning to its normal appearance, usually within 1–24 h. If it involves subcutaneous tissue the patient should be evaluated for angioedema (check complement levels). If urticaria is chronic (> 6 weeks), the patient should be evaluated for chronic infection (hepatitis, sinusitis), connective tissue disorders or autoimmune disorders.

### Paraclinical investigations

**Skin testing** identifies allergen-specific IgE. Diluted allergen is introduced into the skin (either percutaneously or intradermally) and interacts with mast cell-bound IgE. Cross-linking of IgE antibodies causes histamine release, resulting in a wheal and flare reaction within 15–20 minutes of testing. This test is usually performed on the volar aspect of the arms or upper back. Antihistamines (including H<sub>2</sub> blockers) and tricyclic antidepressants can produce false negative results, and should be withheld for at least 48–72 hours prior to testing. Topical steroids used at the injection site can also suppress skin test results. Inhaled corticosteroids and short-term systemic corticosteroids do not have any effect on skin testing. Skin testing should not be performed directly on actively eczematous skin.

**Measurement of serum levels of allergen-specific IgE.** Commonly used methods include the radioallergosorbent test (RAST) and enzyme-linked immunosorbent assay (ELISA). These tests are generally not as sensitive as skin testing in defining clinically pertinent allergens, and are indicated for patients who are not candidates for skin testing. Examples include patients who suffer from severe skin disease, cannot discontinue medications that interfere with skin testing, or have experienced severe anaphylaxis (skin testing can, in rare cases, cause anaphylaxis).

**Patch testing** is used to identify patients with contact dermatitis (e.g., from nickel or latex). A suspected agent is applied to the skin with an occlusive dressing and the area is evaluated 72–96 hours after application. The test is positive when the agent interacts with sensitized Langerhans cells in the skin, with subsequent T cell activation, resulting in erythema, induration, and vesiculation of the involved area.

**Skin biopsy** is necessary to differentiate from urticarian vasculitis and other chronic pruritic skin diseases.

## DIFFERENTIAL DIAGNOSIS OF URTICARIA

**Atopic dermatitis (ADer)** is a chronic, relapsing inflammatory Th2-cell-mediated skin disorder most frequent in patients with a personal or family history of atopic disease. Exacerbating factors include dehydration from frequent bathing or low humidity, infections, emotional stress and hormonal changes. ADer presents with pruritus, sometimes with concomitant allergic rhinitis, allergic conjunctivitis and/or asthma. On physical examination xerosis, erythema, vesicles, papules, keratosis pilaris, lichenification and hyper/hypopigmentation can be revealed. Superinfection complicating excoriation may occur. In infants the most characteristic localization are the cheeks, forehead, scalp, and extensor surfaces; in children – flexures (wrists, ankles, and antecubital and popliteal fossae), in adults – chronic ADer affects the neck, upper back, arms, the hands and feet; with concomitant dermatographism. The diagnosis is confirmed by: allergy testing (elevated IgE blood levels), skin biopsy (findings consistent with atopic dermatitis), *ex juvantibus* criterion (positive response to local treatment with corticosteroids and calcineurin inhibitors (tacrolimus and pimecrolimus).

**Allergic contact dermatitis** is a recurrent dermatitis in areas of exposure to potential allergens (e.g., skin cosmetic products). The lesions occur at site of jewelry/button/watch, one eyelid (nail polish allergy), forehead and both eyelids (shampoo allergy). Patch testing: is positive for allergens.

**Drug eruptions.** The main mechanisms of drug reactions include: over-dosage, pharmacologic side effect, altered metabolism, drug-drug interactions, secondary/indirect effects (e.g., disturbance of microbial flora from antibiotics; Jarisch-Herxheimer reaction in syphilis treatment), genetic predisposition (e.g., glucose-6-phosphate dehydrogenase (G6PD) deficiency), immediate hypersensitivity (IgE mediated), antibody-dependent cytotoxicity (e.g., hemolytic anemia with penicillin), immune complex mediated, delayed T cell mediated (e.g., contact dermatitis, morbilliform rashes, erythema multiforme/Stevens-Johnson syndrome) and direct mast cell activation.

There are mostly macules and papules of trunk and extremities, commonly with centrifugal spread, their onset is usually 1 to 2 weeks after start of new medication, lesions do not resolve with antihistamines. On skin biopsy: signs of inflammation with mononuclear/lymphocytic cell infiltrate, often with mild perivascular component and erythrocyte extravasation. It is important to mention that drug reactions can result in systemic involvement involving multiple internal organs, even in the absence of concomitant cutaneous reactions. Examples include renal disease (e.g., interstitial nephritis), hepatic reactions (e.g., hepatocellular, cholestatic, granulomatous), lung involvement (nonproductive cough, chest discomfort, and migratory infiltrates, without or with peripheral eosinophilia), myocarditis, generalized lymphadenopathy and vasculitis. Drug rash with eosinophilia and systemic symptom (DRESS) is a potentially fatal disorder associated with antiseizure drugs that presents with cutaneous reactions, eosinophilia, fever, and multiple internal organ dysfunction. Aseptic meningitis can occur from nonsteroidal anti-inflammatory drugs (NSAIDs), radiocontrast media, and other agents. Cerebrospinal fluid studies may resemble findings of viral meningitis or demonstrate minimal elevation of neutrophils.

**Eruptions after insect bite.** The lesions are localized on exposed areas of skin, often after outdoor exposure and recent insect bites. On skin examination: nodules of the lower extremities in the summer suggestive of mosquito bites, flea bites (type IV reaction). The presence of accompanying angioedema is suggestive of Hymenoptera allergy (type I reaction). Hymenoptera allergy RAST testing is positive in Hymenoptera allergy.

In **viral exanthema** rash occurs concurrently with symptoms of viral infection but can precede symptoms or occur during the resolution of the viral illness. Rash can present in various forms (urticarial, maculopapular, morbilliform, scarlatiniform or dermatomal). Viral studies are positive for a specific virus.

**Urticarian vasculitis** is usually a secondary disease due to Epstein-Barr virus infection, hepatitis B, C, lupus erythematosus, Sjogren's syndrome, multiple myeloma, colon carcinoma). The skin lesions are often painful, recurrent lasting longer than 24 hours, sometimes after a recent ingestion of drugs (e.g., non-steroidal anti-inflammatory drugs). Arthralgias, arthritis, malaise, fever, abdominal pain, diarrhoea, wheezing, dyspnoea, and Raynaud phenomenon are usually present. On skin examination there are crops of lesions, incomplete blanching on diascopy or dermoscopy and post-inflammatory discolorations of resolved lesions. Skin biopsy of active lesions reveals signs of leukocytoclastic vasculitis (edema of the upper and mid-dermis, with dilatation of the postcapillary venules and lymphatic vessels of the upper dermis, mixed inflammatory perivascular infiltrate of variable intensity, consisting of neutrophils and/or eosinophils, macrophages, and T cells with vessel-wall necrosis).

**Scabies.** The disease is caused by infestation by the mite *Sarcoptes scabiei* which burrow into epidermis and transmission is via skin-to-skin contact or through fomites. Pruritus results from hypersensitivity to mite feces that can persist for several weeks after therapy. There is a generalized severe pruritus with papules, excoriations distributed on wrists, periumbilical area, genital region, buttocks, axillae, nipples and burrows are prominent in web spaces. The diagnosis is based on skin examination, mite preparation (place drop of mineral oil on burrow and scrape onto slide for microscopic examination) and disappearance of lesions and pruritus after local Permethrin 5% cream and decontamination of clothing and bedding.

**Pediculosis.** It is caused by infestation with blood sucking lice: *Pediculus humanus capitis* (head lice), *Pediculus humanus corporis* (body lice), *Phthirus pubis* (pubic lice). The transmission is via direct person-to-person contact or indirect contact through fomites. Head lice are seen in all ages and socioeconomic groups while body lice are associated with poor living conditions, indigence, refugee-camp populations and pubic lice are sexually transmitted. On skin and hair examination papules, pruritus, excoriations, lice and nits are visible to naked eye. Pediculosis frequently coexists with scabies. In some cases secondary skin infections caused by *Staphylococcus aureus*, *Streptococcus pyogenes* are possible. The diagnosis is based on clinical criteria (head lice: live adult lice, nymphs, or nits adherent to hair close to scalp; body lice: lice and eggs found in seams of clothing; pubic lice: live adult lice, nymphs, or nits found in pubic area, axillae, or eyelashes) and positive clinical response to topical insecticides: permethrin, or malathion.

**Urticaria due to systemic causes** of (15% of patients) include: endocrine diaseses (diabetes mellitus, hyper/hypothyroidism), chronic renal failure, malignancy (lymphoma, leukemia, multiple myeloma, cholangiocarcinoma), iron-deficiency anemia, polycythemia vera (exacerbated by hot water), psychiatric diseases (e.g., depression) and pregnancy.

**Mastocytosis.** The disease is characterized by pruritic skin lesions, accompanied by diarrhoea, wheezing, bone pain (in adults). In 50% of cases the onset is in the first 2 years of life and administration of polymyxin B increases swelling blistering of lesions. In adults symptoms of mast cell leukaemia (pruritus, fatigue, wasting, fever, chills, night sweats, swollen/bleeding gums, excess bleeding, headache, frequent infections, and amigdalitis), lymphadenopathy and hepatosplenomegaly may happen. On physical examination: single or multiple papules urticating with pressure (Darier sign) and persisting for longer than 24 hours and do not blanch; the lesions leave pigmentations after resolution. The diagnosis is confirmed by: skin biopsy with Giemsa stains (mononuclear cells with typical granules); CD 117, CD 25 testing of skin biopsy specimen (positive in mastocytosis); C-kit codon 816 mutations testing in blood (positive in mastocytosis); alpha and beta-tryptase in blood and urine (elevated if mast cell numbers excessively increased); histamine and 1,4-methylimidazole acetic acid levels in urine: elevated in direct correlation with extent of disease; bone marrow biopsy: excess mast cells in mast cell proliferative disease (including leukaemia).

**Erythema multiforme.** The onset of rash is usually after drugs (e.g., penicillins), after infection with virus (e.g., herpes), bacteria and mycoplasma. The rash consists of erythematous papules with central clearing. The skin biopsy reveals satellite cell necrosis, vacuolar degeneration of the basement membrane, severe papillary oedema, lymphocytic infiltration and nonspecific immune deposits. Immunofluorescence biopsy is positive for IgM and C3 on the basement membrane and perivascularly.

**Stevens-Johnson syndrome** is a severe, potentially lethal reaction. Initial skin lesions are similar to erythema multiforme rash (erythematous papules with central clearing), but progresses into widespread areas of erythema; bullous formation and necrosis of the epidermal layer, oral mucosa and other mucosal surfaces may be involved. Ocular involvement usually includes conjunctivitis. There is a history of medication use such as allopurinol, sulfa drugs and NSAIDs. Skin biopsy reveals keratinocyte apoptosis with detachment of the epidermal layer of the skin from the dermal layer and immunofluorescence biopsy is negative.

**Bullous pemphigoid.** A severe disease in which the common age of onset is 60-70 years with prodromal non-bullous phase of pruritus and non-bullous rash (urticaria-like), subsequent development of blisters; rash affects face, hands, feet and genitalia, and the rash heals spontaneously. The drugs commonly implicated are NSAIDs, captopril, penicillamine, systemic antibiotics and furosemide. On skin examination large, tense, subepidermal bullae in the groin, axillae, trunk, thighs, and flexor surfaces of forearms, often erythematous or urticarial plaques, some with localized disease on shins, bullae and erosions can be observed. Asboe-Hansen sign (extension of a blister to adjacent unblistered skin when pressure is put on the top of the bulla) is absent. The following investigations confirm the diagnosis: skin biopsy reveals subepidermal blister with eosinophil-rich inflammatory infiltrate; skin biopsy direct immunofluorescence (linear deposition of IgG and C3 at dermal-epidermal junction); skin biopsy indirect immunofluorescence: anti-basement membrane zone antibodies directed against 2 hemidesmosomal antigens, bp230 and bp180; immunoblot assay: target antigens BP Ag1 (230 kD) and BP Ag2 (180 kD).

**Transfusion reactions.** The onset is during or up to 1 hour after blood transfusion, usually with fever, hypotension, pruritis, wheezing and anxiety. Confirmatory investigations include: inspection of plasma in centrifuged, anticoagulated venous blood sample (clear and pink red within first few hours of haemoglobinaemia); inspection of centrifuged urine: clear red in haemoglobinaemia; ABO typing: no discrepancy to blood used for transfusion; direct antiglobulin (Coombs) test (IgG anti-A, anti-B, or anti-AB detected on circulating erythrocytes).

**Serum sickness.** The onset is 7 to 10 days after injection of protein or drug with the earliest symptoms: fever, malaise, headache; subsequently: rash at the site of injection or symmetrically spreading from the abdomen, joint pain, oedema and gastrointestinal symptoms (nausea, vomiting, abdominal pain). On physical examination urticaria of several weeks' duration, joint swellings (knees, ankles, shoulders, wrists, spine, temporomandibular joint) and lymphadenopathy can be found. The following paraclinical investigations are necessary: general blood analysis (leukocytosis/leukopenia, eosinophilia, or mild thrombocytopenia, erythrocyte sedimentation rate is usually slightly elevated); C-reactive protein (slightly elevated); urinalysis (albuminuria, haematuria, active sediment); blood urea and creatinin (transiently elevated); C3, C4, CH50 (depressed complement levels due to complement consumption); C1q binding or Raji cell assays (elevated levels of immune complexes).



**Auriculotemporal syndrome** is characterized by swelling and erythema in facial area after eating spicy or sour foods in a patient with history of trauma to sympathetic and parasympathetic fibres around parotid gland (e.g., from forceps birth). CT scan parotid area usually confirms the diagnosis and evaluates the degree of damage.

**Cryopyrin-associated periodic syndromes** are characterized by urticarial rash, recurrent fever attacks, arthralgia or arthritis, eye inflammation, fatigue and headaches) and include: familial cold autoinflammatory syndrome, Muckle–Wells syndrome or neonatal onset multisystem inflammatory disease, Schnitzler’s syndrome (recurrent urticarial rash, monoclonal gammopathy, recurrent fever attacks, bone and muscle pain, arthralgia or arthritis and lymphadenopathy), Gleich’s syndrome (episodic angioedema with eosinophilia) and Well’s syndrome (granulomatous dermatitis with eosinophilia).

**Muckle-Wells syndrome.** The disease is from the group of periodic fever syndromes and develops due to CIAS1 (cryopyrin) mutation. The clinical symptoms and signs include fever, rash, arthritis, abdominal pain, attacks usually lasting 1–2 days. The differences from familial Mediterranean fever are: sensorineural hearing loss, optic disk swelling, urticarial rash and amyloidosis in 25% of cases. The diagnosis is based on the presence of familial cases, elevated ESR, elevated WBC and positive genetic test for cryopyrin mutation.

## ANGIOEDEMA

**Definition.** Angioedema is defined as a severe life-threatening disease due to vascular reaction of the deep dermis or subcutaneous/submucosal tissues with localized dilatation and increased permeability of blood vessels resulting in tissue swelling.

**Pathophysiology.** Angioedema can be mediated by bradykinin or mast cell mediators including histamine. Bradykinin-mediated angioedema can occur either on a hereditary or acquired basis, due to a deficiency/defect of C1 inhibitor (C1-INH) or not.

### Classification

#### 1. Familial

##### 1.1. Hereditary angioedema (HAE) due to C1-INH deficiency

###### 1.1.1. HAE Type I (caused by mutation of SERPING 1 gene leading

###### 1.1.2. to diminished levels of C1-INH protein; bradykinin medi-



- ated)
- 1.1.3. HAE Type II (caused by mutation of SERPING 1 gene leading to
  - 1.1.4. dysfunctional forms of C1-INH protein; bradykinin mediated)
  - 1.1.5. HAE Type III (caused by mutations in FXII gene which encodes coagulation protein factor FXII; likely bradykinin mediated)
2. Sporadic
    - 2.1. Acquired angioedema (AAE) due to C1-INH deficiency type I (caused by increased consumption of C1-inhibitor, usually occurs in patients with lymphoproliferative diseases)
    - 2.2. AAE Type II (caused by inactivation of C1 inhibitor by autoantibodies to C1-INH, associated with autoimmune disease)
    - 2.3. ACE-related (caused by decreased catabolism of bradykinin; likely bradykinin mediated)
    - 2.4. Allergic (caused by mast cell degranulation involving specific IgE)
    - 2.5. Idiopathic (caused by Ig E-dependent or Ig E-independent mast cell degranulation)

**Clinical manifestations of angioedema** are consistent with swelling of the tongue, lips, pharynx, larynx and viscera (e.g., acute abdomen). The episodes of angioedema may persist for several months after withdrawal of the ACE inhibitor. In *hereditary angioedema* there is positive family anamnesis in 70–80% of cases (over 3–4 and even more generations). The features of the edema include: pale, very dense, non-pitting edema, often with the same localization („cyclic edema”), with a clear border with healthy skin, capturing from 3–4 cm in diameter to large areas; without hyperemia („cold edema”), with a sense of „tension” and „bursting of tissues”. There is a clear relationship between swelling of the skin and /or mucous membranes, abdominalgia and triggers (mechanical trauma varying from slight compression of clothing to bone fracture, physical exertion, cooling, psychoemotional overload tooth extraction, surgical operations, diagnostic manipulations of an invasive nature, menstruation, oral contraceptives administration and pregnancy).

The edemas are localized in the distal parts of the extremities (40%), upper respiratory tract (more than 20% of cases) and gastrointestinal tract (more than 40% of cases). The terms of development and dynamics of

edema change: edema is formed over several hours (from 1 to 36 hours) and regresses either self-restraintly or after treatment for 10-72 hours (maximum up to 7-14 days). Remissions from 7-10 days to 12 months are characteristic, continuous attacks, as well as a latent course, are possible. Annular erythema develops in more than 50% of cases. Hives, local hyperemia and itching are not characteristic. The diagnosis is based on the presence of qualitative or quantitative deficiency of C1inh at the time of an attack of edema and / or abdominal pain, as well as decrease of C4-, C2-, C1-components of complement in peripheral blood. Peripheral eosinophilia, increased total IgE, positive scarification (or prik-) allergic tests with domestic, epidermal, pollen and food allergens are not detected. There is a clear positive effect of treatment with intravenous injection of purified C1-INH, native plasma, epsilon-aminocaproic acid, danazol, stanzol, methyltestosterone and ineffectiveness of antihistamines, glucocorticosteroids (weak or absent effect), noradrenaline, antibiotics, antiparasitic drugs, enzymes.

**The list of differential diagnosis of angioedema** includes:

- Allergic contact dermatitis (see Differential diagnosis of urticaria)
- Superior vena cava syndrome (see Differential diagnosis of mediastinal syndrome)
- Myxedema, deep vein thrombosis (see Differential diagnosis of edema)
- Dermatomyositis, scleroderma (see Differential diagnosis of multivisceral syndrome in connective tissue diseases)
- Cellulitis
- Melkersson-Rosenthal syndrome
- Cheilitis granulomatosa
- Trichinellosis
- Subcutaneous emphysema

**Cellulitis** is a non-necrotizing inflammation of the skin and subcutaneous tissues, usually due to acute infection (*Staphylococcus aureus*, *Streptococcus spp.*, *Vibrio vulnificus*). Nonpurulent cellulitis is associated with local erythema, pain, swelling and warmth. In severe cases malaise, chills, fever, anorexia, lymphangitic spread, violaceous bullae, cutaneous hemorrhage, skin sloughing, skin anesthesia, rapid progression, gas in the tissue and hypotension are observed.

**Melkersson-Rosenthal syndrome** is a rare neurological disorder characterized by recurring facial paralysis, swelling of the face and lips (usually

the upper lip) and the development of furrows and folds in the tongue. The cause of this syndrome is unknown and the syndrome can be symptomatic of Crohn's disease or sarcoidosis. The onset is in childhood or early adolescence. After recurrent attacks (ranging from days to years in between), swelling may persist and increase, eventually becoming permanent. The lips may become hard, cracked and fissured with a reddish-brown discoloration.

**Cheilitis granulomatosa** is a subset of orofacial granulomatosa characterized by persistent idiopathic swelling of the lip. Orofacial granulomatosis represents a spectrum of diseases characterized by granulomatous inflammation of the oral and maxillofacial region in the absence of systemic disease like Crohn's disease. *Ex juvantibus criterion*: improvement with implementation of a cinnamon- and benzoate-free diet and intralesional corticosteroids in combination with metronidazole.

**Trichinellosis** results from the infection by a parasitic nematode *Trichinella spiralis*. Humans are infected when they ingest inadequately cooked meat, mainly wild game meat or pork that contains larvae of *Trichinella* species. Symptomatic infections develop when a large number of larvae are ingested and are characterized by diarrhea, myositis, fever, and periorbital edema. Serology results are not positive until 2-3 weeks after infection. They peak around the third month and may persist for years.

**Subcutaneous emphysema** (SE) occurs when air gets into the tissues under the skin and in the soft tissues. It can result from blunt or penetrating trauma, pneumothorax barotrauma, infection, malignancy or as a complication of surgical procedures. The most common sign and symptom of SE is swelling around the neck accompanied with chest pain. Other signs and symptoms include tender sore throat, aching neck, dysphagia, breathlessness and wheezing. If SE involves the deeper tissues of the thoracic outlet, chest, and abdominal wall, it will be a severe and life-threatening condition. It can be complicated by restriction of full lung re-expansion and can lead to high airway pressure, severe respiratory acidosis, ventilator failure, pacemaker malfunction, airway compromise, and tension phenomena. The diagnosis is made based on crepitation on palpation and radiological studies indicating air in the involved area.

**BIBLIOGRAPHY**

1. Arnold J.J., Williams P. M. Anaphylaxis: Recognition and Management. *Am Fam Physician* 2011; 84 (10):1111-1118. <https://www.aafp.org/afp/2011/1115/p1111.html> (accessed 21.07.2018)
2. Criado P.R., Criado R.F., Maruta C.W., Machado F.C. Histamine, histamine receptor and antihistamines: new concepts. *An Bras Dermatol* 2010; 85 (2): 195–210.
3. Ohsawa Y., Hirasawa N. The role of histamine H1 and H4 receptors in atopic dermatitis: from basic research to clinical study. *Allergol Int* 2014; 63 (4): 533–542.
4. Yanai K., Rogala B., Chugh K., et al. Safety considerations in the management of allergic diseases: focus on antihistamines. *Curr Med Res Opin* 2012; 28 (4): 623–642.
5. Kanani A., Schellenberg R., Warrington R. Urticaria and angioedema. *Allergy Asthma Clin Immunol* 2011; 10 (7) Suppl 1. doi: 10.1186/1710-1492-7-S1-S9.
6. Muraro A., Werfel T., Hoffmann-Sommergruber K., et al. EAACI Food Allergy and Anaphylaxis Guidelines: diagnosis and management of food allergy. *Allergy* 2014; 69: 1008–1025.
7. Zuberbier T., Aberer W., Asero R., et al. The EAACI/GA(2)LEN/EDF/WAO Guideline for the definition, classification, diagnosis, and management of urticaria: the 2013 revision and update. *Allergy* 2014; 69(7):868-887.
8. Bernstein J.A., Lang D.M., Khan D.A., et al. The diagnosis and management of acute and chronic urticaria: 2014 update. *Allergy Clin Immunol.* 2014; 133(5):1270-1277.
9. Simons E., Ebisawa M., Sanchez-Borges M., et al. 2015 update of the evidence base: World Allergy Organization anaphylaxis guidelines. *World Allergy Organization Journal* 2015 8: 80 <https://doi.org/10.1186/s40413-015-0080-1> (accessed 21.07.2017).
10. Powell R. J., Leech S. C., Till S., et al. BSACI guideline for the management of chronic urticaria and angioedema. *Clinical and Experimental Allergy* 2015; 45: 547–565.
11. Stratta P., Badino G. Scombroid poisoning. *CMAJ* 2012; 184 (6): 674.
12. Vally H., Misso N.L.A. Adverse reactions to the sulphite additives. *Gastroenterol Hepatol Bed Bench* 2012; 5 (1): 16-23.

## DIFFERENTIAL DIAGNOSIS OF ACUTE AND CHRONIC ABDOMINAL PAIN

**INTRODUCTION.** Acute abdominal pain is a common emergency department complaint but for many reasons it is often diagnostically challenging. The nature and quality of abdominal pain may be difficult for the patient to convey and physical examination findings are variable and can be misleading. The location and severity of the pain may change over time. Initially benign symptoms and presentations may evolve into life-threatening conditions. Conversely, patients with severe symptoms may carry a relatively benign diagnosis.

Abdominal pain is the presenting complaint in 1.5% of office-based visits and in 5% of emergency department visits. Although most abdominal pain is benign, as many as 10% of patients in the emergency department setting and a lesser percentage in the outpatient setting have a severe or life-threatening cause or require surgery.

Chronic abdominal pain persists for more than 3 month either continuously or intermittently. Nearly all patients with chronic abdominal pain have had a prior medical evaluation that did not yield a diagnosis after history, physical, and basic testing.

**PATHOPHYSIOLOGY.** Pathology in the gastrointestinal and genitourinary tracts remains the most common source of pain perceived in the abdomen. Also, the pain can arise from a multitude of other intra-abdominal and extra-abdominal locations. Abdominal pain is derived from one or more of the three distinct pain pathways: visceral, somatic, and referred.

**Visceral pain** comes from the abdominal viscera, which are innervated by autonomic nerve fibers and respond mainly to the sensations of distention and muscular contraction – not to cutting, tearing, or local irritation. Visceral pain is typically vague, dull, and nauseating. If the involved organ is affected by peristalsis, the pain is often described as intermittent, crampy, or colicky. It is poorly localized and tends to be referred to the areas corresponding to the embryonic origin of the affected structure as follows:

- *Foregut* structures (stomach, duodenum, liver, and pancreas) are associated with *upper abdominal pain*.
- *Midgut* derivatives (small bowel, proximal colon, and appendix) are associated with *periumbilical pain*.
- *Hindgut* structures (distal colon and genitourinary tract) are associated with *lower abdominal pain*.

The type and density of visceral afferent nerves makes the localization of visceral pain imprecise. However, a few general rules are useful at the bedside:

- Most digestive tract pain is perceived in the midline because of bilaterally symmetric innervation. The pain that is clearly lateralized most likely arises from the ipsilateral kidney, ureter, ovary, or somatically innervated structures, which have predominantly unilateral innervation. Exceptions to this rule include the gallbladder and ascending and descending colons which, although bilaterally innervated, have predominant innervation located on their ipsilateral sides.
- Visceral pain is perceived in the spinal segment at which the visceral afferent nerves enter the spinal cord.

Visceral pain can be perceived in a location remote from the actual disease process. Localization occurs with the extension of the disease process beyond the viscera.

**Somatic pain** occurs with irritation of the parietal peritoneum. This is usually caused by infection, chemical irritation, or another inflammatory process. Sensations are conducted by the peripheral nerves and are better localized. Somatic pain is often described as intense and constant. As disease processes evolve to peritoneal irritation with inflammation, better localization of the pain to the area of pathology generally occurs. Table 7 shows some more typical pain locations corresponding to specific disease entities.

*Table 7.*

**Causes of Abdominal Pain by Location**

<b>Right upper quadrant pain</b>	<b>Left upper quadrant pain</b>
Hepatitis / Hepatomegaly	Splenic abscess
Cholecystitis / Cholangitis	Splenic infarct
Biliary colic	Pancreatitis
Pancreatitis	Gastritis
Gastritis	Gastric ulcer
Perforated ulcer	Myocardial ischemia
Appendicitis in pregnancy and retro-cecal	Myocarditis
Budd-Chiari syndrome	Pericarditis
Right lower lobe pneumonia/empyema	Left lower lobe pneumonia / pleural effusion
pleurisy	
Subdiaphragmatic abscess	

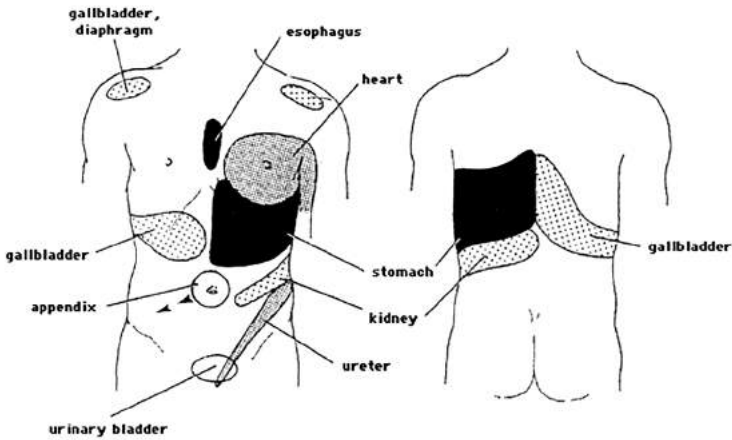
<p style="text-align: center;"><b>Epigastric pain</b></p> Peptic ulcer disease Gastroesophageal disease Gastritis Pancreatitis Myocardial infarction Pericarditis Ruptured aortic aneurysm	<p style="text-align: center;"><b>Periumbilical pain</b></p> Early appendicitis Gastroenteritis Bowel obstruction Ruptured aortic aneurysm
<p style="text-align: center;"><b>Right lower quadrant pain</b></p> Appendicitis Diverticulitis Salpingitis / ovarian torsion or cyst	<p style="text-align: center;"><b>Left lower quadrant pain</b></p> Salpingitis / ovarian torsion or cyst Ectopic pregnancy Inguinal hernia
Ectopic pregnancy Inguinal hernia Nephrolithiasis Inflammatory bowel disease Mesenteric adenitis ( <i>Yersinia</i> ) Ureteral calculi Pelvic inflammatory disease	Nephrolithiasis Inflammatory bowel disease Sigmoid diverticulitis Ureteral calculi Pelvic inflammatory disease Mittelschmerz
<p><b>Diffuse pain</b></p>	
Acute pancreatitis Peritonitis (any cause) Gastroenteritis Mesenteric ischemia, thrombosis Metabolic (eg. diabetic ketoacidosis, porphyria) Malaria Dissecting or ruptured aneurysm	Familial Mediterranean fever Bowel obstruction Peritonitis Irritable bowel syndrome Sickle cell crisis Inflammatory bowel disease Diabetes mellitus

**Referred pain** is a pain perceived distant from its source and results from convergence of nerve fibers at the spinal cord. This makes interpretation of the location of noxious stimuli difficult for the brain. Both visceral pain and somatic pain can manifest as referred pain. Figure 1 illustrates the important skin areas for referral of visceral pain.

**Extra-abdominal causes of abdominal pain.** Pain perceived as originating in the abdomen may arise from extra-abdominal sites or from acute systemic illness (*Table 8*).

**Functional abdominal pain syndrome (FAPS)** is a pain that persists more than 6 month without evidence of physiologic disease, that shows no relationship to physiologic events (eg, meals, defecation, menses), and

interferes with daily functioning. FAPS is poorly understood but seems to involve altered nociception. Sensory neurons in the dorsal horn of the spinal cord may become abnormally excitable and hyperalgesic due to a combination of factors. Cognitive and psychological factors (e.g., depression, stress, culture, secondary gain, coping and support mechanisms) may cause efferent stimulation that amplifies pain signals, resulting in perception of pain with low-level inputs and persistence of pain long after the stimulus has ceased. Additionally, the pain itself may function as a stressor, perpetuating a positive feedback loop.



**Figure 1. Referred pain patterns. Important skin areas for referral of visceral pain**  
 (Source: Snell, RS. Clinical anatomy for medical students, 6<sup>th</sup> ed., Lippincott Williams and Wilkins, Philadelphia 2000).

*Table 8*

**Important extra-abdominopelvic causes of abdominal pain**

<b>Thoracic</b>	<b>Systemic</b>
Myocardial ischemia and infarction	Diabetic ketoacidosis / alcoholic ketoacidosis
Myocarditis / pericarditis / endocarditis	Uremia
Congestive heart failure	Sickle cell disease
Pneumonia	Porphyria
Pulmonary embolism and infarction	Systemic lupus erythematosus / vasculitis
Pneumothorax	Diabetes mellitus
	Hyperthyroidism / hyperparathyroidism



<b>Neurologic</b>	<b>Toxic</b>
Neuralgia / radiculitis Abdominal epilepsy Tabes dorsalis	Hypersensitivity reactions: insect bites, reptile venoms Methanol poisoning Heavy metal toxicity
<b>Infectious</b>	<b>Miscellaneous</b>
Herpes zoster Osteomyelitis Typhoid fever Mononucleosis	Abdominal wall (muscular contusion, hematoma or tumor) Narcotic withdrawal Psychiatric disorders Heat stroke

## DIAGNOSTIC APPROACH

Although location of abdominal pain guides the initial evaluation, associated signs and symptoms are predictive of certain causes of abdominal pain and can help narrow the differential diagnosis.

**1.** A thorough **history** usually suggests the diagnosis. The following data are of particular importance: pain chronology, rapidity of onset of pain (is usually a sign of its severity and significance and sudden sharp pain are likely secondary to an intra-abdominal catastrophe as mesenteric infarction, perforated viscus, ruptured aortic aneurysm), progression of pain, duration of the pain (the longer the duration of pain the less likely that it will be related to an acute event), pain location, intensity and character, aggravating and alleviating factors, past medical history (previous similar symptoms, systemic illnesses, use of medications and alcohol, family and social history, associated symptoms:

- Constitutional symptoms (fever, night sweat, chills, weight loss, myalgia, arthralgia).
- Digestive function (nausea, vomiting, anorexia, heartburn, hematemesis, diarrhea, constipation, melena).
- Symptoms from another systems (hematuria, jaundice).
- Pregnancy.

### **2. Physical examination:**

- Complete systemic examination
  - Patient's appearance, ability to converse, breathing pattern, position in bed, posture, degree of discomfort, and facial expression.
  - Vital signs should be obtained to exclude conditions such as hypovolemia, tachypnea related to metabolic acidosis, or atrial fibrillation as a cause of mesenteric arterial embolus.

- Examination of the extremities may provide evidence for inadequate perfusion.
- Abdominal examination
  - Inspection: for distension, scars, hernias, splinting during respiration, ecchymosis, and visible hyperperistalsis peritoneal.
  - Palpation: light, gentle palpation is superior to deep palpation in the identification of peritoneal irritation, degree of tenderness, guarding, and rigidity should be determined, palpable masses (organs hematoma, tumors).
  - Percussion: may elicit tympanic sound from the excess of abdominal gas, whether it is intraluminal (as it occurs with intestinal obstruction) or extraluminal (as it occurs with perforated viscus), for free fluid as well.
  - Auscultation: Hyperperistalsis in intestinal obstruction or enteritis. Generalized peritonitis usually causes diminished peristalsis. Bruits may point to a vascular stenosis.
- Rectal examination is important as well as pelvic examination in some cases.

### **3. Laboratory tests**

- All patients with acute abdominal pain should have complete blood count with differential count and urinalysis
- Serum electrolyte, blood urea nitrogen, creatinine, and glucose concentrations are useful in ascertaining fluid status, acid-base status, renal function, and metabolic state but is not necessary for every patient.
- Liver function tests and serum amylase determination should be ordered in patients with upper abdominal pain
- Urine or serum pregnancy testing should be performed in all women of reproductive age with lower abdominal pain
- Others according to presentation.

### **4. Radiology investigations**

- Plain Abdominal series (two views–supine, erect, or lateral decubitus on left side down for patients unable to stand) may identify abnormal gas patterns.
- Three views of the abdomen are important but only 10% of them will lead to the diagnosis.
- Chest x-ray: basal pneumonia, air under the diaphragm.
- Ultrasound.

- Computed tomography scan of the abdomen and pelvis is probably the most useful test.

### 5. Other tests

- Peritoneal lavage in trauma patients.
- Laparoscopy.
- Laparotomy.
- Endoscopy.

## DIFFERENTIAL DIAGNOSIS

**Upper abdominal pain syndromes** – the different pain syndromes typically, but not always, have characteristic locations (Table 7).

**Biliary disease.** The biliary tract syndromes are classified according to the source of pain and the pathogenesis of the disorder (eg. distention of the duct, inflammation, or infection).

*Cholelithiasis* refers to the presence of gallstones within the gallbladder; it is often asymptomatic.

*Biliary colic* is usually caused by the gallbladder contracting in response to a fatty meal and pressing a stone against the gallbladder outlet or cystic duct opening, leading to increased intragallbladder pressure and pain. The term biliary colic is a misnomer, since the pain is not typically colicky. It is entirely visceral in origin, without true gallbladder wall inflammation. Affected patients typically complain of deep and gnawing pain that is occasionally sharp and severe. The pain is localized in the right upper quadrant or epigastrium. As the gallbladder relaxes, the stones often fall back from the cystic duct. As a result, the attack reaches a crescendo over a number of hours and then resolves completely; it may recur multiple times. Biliary colic may be mistaken for irritable bowel syndrome, acute myocardial infarction, and peptic ulcer disease.

*Prolonged or recurrent cystic duct blockage* can progress to total obstruction, causing acute cholecystitis. Patients with acute cholecystitis typically complain of abdominal pain, most often in the right upper quadrant or epigastrium with possible radiation to the right shoulder or back. The pain is characteristically steady and severe. Associated complaints may include nausea, vomiting, and anorexia. There is often a history of fatty food ingestion about one hour or more before the initial onset of pain. An episode of prolonged right upper quadrant pain (more than four to six hours), especially if associated with fever, should arouse suspicion for acute cholecystitis as opposed to an attack of simple biliary colic.

*Acute cholangitis* occurs when a stone becomes impacted in the biliary or hepatic ducts, causing dilation of the obstructed duct and bacterial superinfection. It is characterized by fever, jaundice, and abdominal pain, although this classic triad occurs in only 50 to 75 % of cases. The abdominal pain is typically vague and located in the right upper quadrant.

*Gallstone pancreatitis* occurs when a gallstone becomes impacted within the ampulla of Vater, occluding drainage of the pancreatic duct. This is a very common cause of acute pancreatitis. The pain of gallstone pancreatitis is typical of acute pancreatitis.

***Acute pancreatitis.*** Almost all patients with acute pancreatitis have acute upper abdominal pain at the onset. The pain is steady and may be in the mid-epigastrium, right upper quadrant, diffuse, or, infrequently, confined to the left side. Biliary colic, which may herald or progress to acute pancreatitis, may occur postprandially, while acute pancreatitis related to alcohol frequently occurs one to three days after a binge or cessation of drinking. Unlike biliary colic, which lasts a maximum of six to eight hours, the pain of pancreatitis lasts days. Its onset is rapid, but not as abrupt as that with a perforated viscus; in many cases, the pain of pancreatitis reaches maximum intensity within 10 to 20 minutes. One characteristic of the pain that is present in about one-half of patients and suggests a pancreatic origin is band-like radiation to the back. Painless disease is uncommon (5 to 10 %) but may be complicated and fatal. The abdominal pain is typically accompanied (approximately 90 %) by nausea and vomiting that may persist for many hours. Restlessness, agitation, and relief on bending forward are other notable symptoms. Patients with fulminant attacks may present in shock or coma.

***Dyspepsia.*** The international committee of clinical investigators developed the following definition of dyspepsia for research purposes, which can also be applied to clinical practice: «Dyspepsia is a persistent or recurrent abdominal pain or abdominal discomfort centered in the upper abdomen. Discomfort refers to a subjective, negative feeling that does not reach the level of pain according to the patient. Centering refers to pain or discomfort mainly localized to the upper abdomen; it does not exclude patients who have pain or discomfort elsewhere unless they only have pain elsewhere». The differential diagnosis of dyspepsia includes gastroesophageal reflux disease, biliary disease, irritable bowel syndrome, chronic pancreatitis, gastric cancer, drug-induced dyspepsia, psychiatric disease, diabetic gastroparesis, metabolic diseases, gastrointestinal and pancreatic malignancies,

ischemic heart disease, and abdominal wall pain.

***Pneumonia.*** Pneumonia involving the lower lobes of the lung is a common cause of abdominal pain syndromes, presumably related to diaphragmatic irritation, and may be confused with acute cholecystitis or, rarely, an acute abdomen. Abdominal pain is occasionally the sole presenting complaint in a patient with lower lobe pneumonia.

***Myocardial infarction.*** Upper abdominal pain can be the presenting symptom of an acute myocardial infarction. Any patient with cardiac risk factors should have an electrocardiogram.

***Splenic abscess and infarction.*** Left upper quadrant pain often arises from diseases of the spleen:

- Splenic abscesses typically are associated with fever and tenderness in the left upper quadrant.
- Splenic infarction presents with severe left upper quadrant pain. This syndrome should be considered in any patient with atrial fibrillation or other conditions associated with peripheral embolism.

### **Lower abdominal pain syndromes**

***Appendicitis.*** Acute appendicitis is a major consideration in the assessment of any patient with acute abdominal disease. Acute appendicitis typically presents with periumbilical pain initially that radiates to the right lower quadrant; however, occasionally patients present with epigastric or generalized abdominal pain. The pain localizes to the right lower quadrant when the appendicular inflammation begins to involve the peritoneal surface.

***Diverticular disease.*** Uncomplicated diverticulosis is often asymptomatic and an incidental finding on colonoscopy or sigmoidoscopy. Some of these patients complain of symptoms such as cramping, bloating, flatulence, and irregular defecation. Diverticulitis represents microscopic or macroscopic perforation of a diverticulum. The clinical presentation of diverticulitis depends upon the severity of the underlying inflammatory process and whether or not complications are present. Left lower quadrant pain is the most common complaint in Western countries, occurring in 70% of patients. Right-sided diverticulitis occurs in only 1.5% of patients. In contrast, right-sided disease is more common in Asians (accounting for as many as 75% of cases of diverticulitis), and affected patients may present with right lower quadrant pain, often leading to a misdiagnosis of acute appendicitis. Pain is often present for several days prior to presentation, which aids in the differentiation of diverticulitis from other causes of acute

abdominal symptoms. Only 17% in one series had symptoms for less than 24 hours. Another helpful diagnostic finding is that up to one-half have had one or more previous episodes of similar pain.

***Kidney stones*** – usually cause symptoms when the stone passes from the renal pelvis into the ureter. Pain is the most common symptom and varies from a mild and barely noticeable ache, to discomfort that is so intense it requires hospitalization and parenteral medications. The pain typically waxes and wanes in severity and develops in waves or paroxysms that are related to movement of the stone in the ureter and to associated ureteral spasm. Paroxysms of severe pain usually last from 20 to 60 minutes.

The site of obstruction determines the location of pain. Upper ureteral or renal pelvic obstruction lead to flank pain or tenderness, whereas lower ureteral obstruction causes pain that may radiate to the ipsilateral testicle, tip of the penis, or labia. The location of the pain may change as the stone migrates; a variable location of pain can be misleading and occasionally mimics an acute abdomen or dissecting aneurysm. In addition, some patients present with abdominal pain in the absence of flank pain. Computed tomography scan is the gold standard to confirm the diagnosis.

***Bladder distension.*** Patients with bladder outlet obstruction leading to acute bladder distension, as may occur in some patients with benign prostatic hypertrophy, can present with lower abdominal pain.

***Pelvic pain.*** Lower abdominal pain in women is frequently due to disorders of the reproductive organs.

***Diffuse abdominal pain syndromes*** – often represent severe and potentially life-threatening disease. Examples include mesenteric ischemia and infarction, ruptured abdominal aortic aneurysm, and diffuse peritonitis.

***Mesenteric ischemia and infarction.*** Mesenteric infarction presents with the acute and severe onset of diffuse and persistent abdominal pain, while chronic mesenteric ischemia may be manifested by a variety of symptoms including abdominal pain after eating ("intestinal angina"), weight loss, nausea, vomiting, and diarrhea. Ischemia that involves the celiac territory causes epigastric or right upper quadrant pain. Mesenteric ischemia and infarction are important considerations in elderly patients presenting with acute abdominal pain and in all patients with acute diffuse abdominal pain. These disorders are thought to occur in up to 1 to 2% of all patients presenting with severe acute gastrointestinal illness. Infarction typically occurs in patients with known cardiovascular, ischemic, or arteriosclerotic disease. Mesenteric ischemia may be a manifestation of systemic vasculitis

involving the gastrointestinal tract. Mesenteric venous thrombosis rarely is a cause of abdominal pain and may occur in previously healthy individuals. Angiography or Magnetic resonance angiography of the celiac artery or mesenteric vessels are the diagnostic tests of choice. Sigmoidoscopy can also suggest the diagnosis in patients with ischemic colitis but is usually not required

***Ruptured aneurysm.*** A ruptured abdominal aortic aneurysm can present with diffuse or localized abdominal symptoms and can mimic other acute conditions such as renal colic, diverticulitis, pancreatitis, inferior wall coronary ischemia, mesenteric ischemia, or biliary tract disease. The patient with a ruptured abdominal aortic aneurysm who survives long enough to reach the emergency room classically presents with abdominal or back pain, hypotension, and a pulsatile abdominal mass. Aneurysm rupture typically causes exsanguinating hemorrhage and profound, unstable hypotension.

***Peritonitis.*** Patients with peritonitis attempt to minimize abdominal pain by lying still, often in a supine position with the knees flexed. The pain may be greatest over the region of the abdomen near the abdominal viscera from which the pain originated (as in acute cholecystitis) but may spread rapidly to involve the entire abdomen as inflammation progresses. Physical examination may reveal fever and evidence for hypovolemia (tachycardia and hypotension). Abdominal examination should be performed gently, since it can worsen pain. It is usually unnecessary to elicit rebound tenderness (sudden severe pain caused by rapid release of the hand following abdominal palpation), since peritonitis can usually be suspected from more gentle palpation. A similar approach (elicitation of pain after bumping against the bed) is also usually unnecessary. Abdominal wall rigidity (involuntary guarding) may be present due to activation of primary afferent visceral and cutaneous pain receptors.

***Intestinal obstruction.*** Severe, acute diffuse abdominal pain can be caused by either partial or complete obstruction of the intestines. The commonest causes in adults are an incarcerated hernia, adhesions, intussusception, and volvulus; these syndromes account for as many as 96% of cases. Occasionally, severe constipation leading to fecal impaction can cause large bowel obstruction as can an obstructing colonic carcinoma. Intestinal obstruction should be considered when the patient complains of pain, vomiting, and constipation. Physical findings of abdominal distention and tenderness to palpation are common.

**Abdominal pain in special populations.** Special populations of

patients, including women, the elderly, patients with AIDS, hemophiliacs, and patients with sickle cell disease, may present with unusual causes of abdominal pain or may have unusual presentations of common disorders.

**Women.** Lower abdominal pain (pelvic pain) in women is frequently caused by disorders of the internal female reproductive organs. The major etiologies of acute pain are: pelvic inflammatory disease; adnexal cysts or masses with bleeding, torsion, or rupture; ectopic pregnancy; and uterine pain due to infection (endomyometritis) or due to degeneration, infarction, or torsion of leiomyomas. Chronic pelvic pain in women is discussed separately.

**Pelvic inflammatory disease.** Lower abdominal pain is the cardinal presenting symptom in women with pelvic inflammatory disease, although the character of the pain may be quite subtle. Recent onset of pain that occurs during menses or coitus or with jarring movement may be the only presenting symptom of pelvic inflammatory disease; the new onset of pain during or shortly after menses is particularly suggestive. The abdominal pain is usually bilateral and rarely of more than two to three weeks duration. Fever is present in 50 %, and abnormal uterine bleeding occurs in one-third of patients with pelvic inflammatory disease. New vaginal discharge, urethritis, proctitis, and chills can be associated signs but they are neither sensitive nor specific for the diagnosis. The presence of pelvic inflammatory disease is less likely if symptoms referable to the bowel or urinary tract predominate.

**Adnexal pathology.** Cysts and neoplasms of the ovary, fallopian tube, or paraovarian or paratubal areas can cause pain due to rupture, bleeding, or torsion. Large size alone, even with compression of adjacent structures, usually does not result in acute pain.

- The new onset of mid-cycle pain in premenopausal women suggests the presence of a physiologic cyst (follicular or corpus luteum).
- Pain immediately following intercourse is suggestive of a ruptured cyst.
- The sudden onset of severe pain, often associated with nausea and vomiting, is suggestive of ovarian torsion or a degenerating leiomyoma. Acute severe pain simulating appendicitis or peritonitis may also result from perforation, infarction, or hemorrhage into or from an ovarian neoplasm.
- Pain accompanied by fever suggests an infection such as pelvic inflammatory disease, appendicitis, or diverticulitis, but it may be associated with torsion (ovary or leiomyoma) or degeneration (leiomyoma).



Common symptoms of endometriosis include chronic pelvic pain (which is often more severe during menses), dysmenorrhea, dyspareunia, abnormal menstrual bleeding, and infertility. Acute pain may also occur due to rupture of an endometrioma.

**Ectopic pregnancy.** Abdominal pain, menstrual cycle abnormalities (missed or late menstrual period), and vaginal bleeding are the classic symptoms of ectopic pregnancy. Clinical manifestations typically appear six to eight weeks after the last normal menstrual period, but they can occur later. Vital signs may reveal orthostatic changes and, occasionally, fever. Findings on physical examination may include adnexal, cervical motion, and/or abdominal tenderness, an adnexal mass, and mild uterine enlargement. The physical examination is often unremarkable in a woman with a small, unruptured ectopic pregnancy, but a sensitive test for human chorionic gonadotropin will always be positive and serves to distinguish ectopic pregnancy from other causes of lower abdominal pain in women.

**Endometritis.** Endometritis refers to inflammation of the endometrium, the inner lining of the uterus. It is characterized by uterine pain, vaginal bleeding, and fever. Sexually transmitted infections and invasive gynecologic procedures are the most common predecessors of acute endometritis in the non-obstetric population. Postpartum infection, usually after a labor concluded by cesarean delivery or after prolonged labor or rupture of membranes with multiple vaginal examinations, is the most frequent antecedent of acute endometritis in the obstetric population.

**Leiomyomas.** Leiomyomas (fibroids) infrequently cause acute pain from degeneration (eg, carneous or red degeneration) or torsion of a pedunculated tumor. Pain may be associated with a low grade fever, uterine tenderness on palpation, elevated white blood cell count, or peritoneal signs. The discomfort resulting from degenerating leiomyomas is self-limited, lasting from days to a few weeks, and it usually responds to nonsteroidal anti-inflammatory drugs.

**Elderly.** Elderly patients often do not present with the same signs and symptoms of disease characteristic of younger individuals. This was illustrated in a retrospective review of 231 patients over the age of 64 who presented to an emergency department with acute (less than one week) nontraumatic abdominal pain. The presence or absence of abnormal test values (hemoglobin, alkaline phosphatase, aspartate aminotransferase, bilirubin, lactate, and leukocytosis) did not distinguish those who were admitted and did not require surgery from patients with surgical disease; clinical

suspicion was a more important distinguishing feature. Normal laboratory tests at presentation occurred in 13% of patients who ultimately required surgery. Biliary tract disease and small bowel obstruction were common disorders in elderly patients presenting with acute abdominal pain.

In the second review of 168 elderly patients presenting to an emergency department with acute cholecystitis (confirmed later by surgery), 84% had neither epigastric nor right upper quadrant pain, and 5% had no pain at all. Common presenting symptoms were nausea (57%) and vomiting (38%). Many patients were afebrile (56%), and 13% had no fever and normal laboratory studies.

***Human immunodeficiency infection.*** Gastrointestinal and hepatobiliary symptoms are among the most frequent complaints in patients with human immunodeficiency virus (HIV) infection and acquired immunodeficiency syndrome (AIDS). The frequency of abdominal pain as a symptom in patients with AIDS is unknown; however, acute abdominal pain is often a serious finding. In the majority of patients with AIDS, abdominal pain is directly related to HIV and its consequences, but the more common causes of abdominal pain in the general population also need to be considered. Many studies of abdominal pain in patients with AIDS stress the broad spectrum of potential causes for this symptom

***Hemophilia.*** Hemophiliacs may spontaneously develop hematomas of the bowel wall, which can cause symptoms that mimic acute appendicitis. The diagnosis of "pseudoappendicitis" can usually be made with Computed tomography imaging; at times, surgery is required to confirm the diagnosis.

***Sickle cell disease.*** Patients with sickle cell disease may have abdominal pain as part of a vasoocclusive crisis. Such a pain may be difficult to distinguish from an acute surgical abdomen (eg. appendicitis, cholecystitis) and may be due to such conditions as cholelithiasis, splenic infarction, pancreatitis, ischemic colitis, and nonsurgical genitourinary disorders.

Right upper quadrant symptoms are common in the setting of hepatic involvement.

**Rare Causes of Abdominal Pain** should be considered in the following circumstances:

- Patients with repeated visits to physicians or emergency rooms for the same complaint without a definite diagnosis
- An ill looking patient with minimal or nonspecific findings
- Pain out of proportion to clinical findings
- Immunocompromised, HIV-infected, or elderly patients (see above)

***Celiac artery compression syndrome.*** The celiac artery compression syndrome is a rare condition that typically occurs in otherwise healthy young and middle-aged individuals. It presents as chronic, epigastric abdominal pain that typically occurs after eating and may be associated with an epigastric bruit and weight loss. The diagnosis is suggested by narrowing or occlusion of the celiac axis on angiography.

***Painful rib syndrome.*** The painful rib syndrome is an increasingly common condition characterized by discomfort in the lower chest or upper abdomen, tenderness over the costal margins, and reproduction of the pain by pressure on the ribs. This syndrome accounts for as many as 3% of new referrals to surgeons for the evaluation of upper abdominal pain. It is most common in women. The syndrome has a benign outcome and is important to recognize and diagnose to avoid unnecessary testing and treatment and to provide reassurance to the patient. In one review, 8 of 76 patients underwent noncurative cholecystectomy.

***Wandering spleen syndrome.*** The wandering spleen syndrome is a rare cause of acute abdominal pain that is most typically seen in younger adolescents and children, although it can occur in adults. Patients typically present with acute left upper quadrant pain associated with an abdominal mass. CT imaging confirms the diagnosis. The treatment of choice is splenopexy; splenectomy may be required if the spleen is infarcted and there is torsion and absence of splenic blood flow.

***Abdominal wall pain.*** Pain emanating from the abdominal wall may be difficult to distinguish from deep visceral pain. The pain can originate from a hernia, hematoma, or the abdominal wall musculature. Abdominal wall hernias can be difficult to diagnosis clinically, and CT scan of the abdomen and the abdominal wall are often required. Hematomas of the abdominal wall occur spontaneously or after unrecognized trauma. Abdominal pain originating from the abdominal musculature can be diagnosed by finding a focal area of abdominal tenderness that remains unchanged or increases with abdominal muscle contraction (Carnett's sign).

***Abdominal migraine.*** Recurrent abdominal pain may occur in patients with abdominal migraine. These patients usually also suffer from typical migraine headaches, although occasional patients present with gastrointestinal symptoms only.

***Eosinophilic gastroenteritis.*** Eosinophilic gastroenteritis is a rare condition that may present with variable symptoms including abdominal pain, nausea, vomiting, and diarrhea. The signs and symptoms are related

to the layer(s) and extent of bowel involved with eosinophilic infiltration: mucosa, muscle, and/or subserosa. The diagnosis is suspected in patients with abdominal pain, diarrhea, and peripheral eosinophilia; it may be confused with the irritable bowel syndrome.

***Epiploic appendagitis.*** Epiploic appendagitis is a benign and self-limited condition of the epiploic appendages that occurs secondary to torsion or spontaneous venous thrombosis of a draining vein. Patients most commonly present with acute abdominal pain. Symptoms can mimic an acute abdomen, frequently leading patients to be misdiagnosed as having acute appendicitis or diverticulitis.

***Fitz-Hugh-Curtis syndrome.*** The Fitz-Hugh-Curtis syndrome, or perihepatitis, is a cause of right upper quadrant pain in young women. It occurs in approximately 10% of patients with pelvic inflammatory disease caused by *Chlamydia trachomatis* or *Neisseria gonorrhoeae*. Physical examination typically reveals marked right upper quadrant tenderness.

***Familial Mediterranean fever.*** The typical manifestations of familial Mediterranean fever are recurrent attacks of severe pain (due to serositis at one or more sites) and fever, lasting one to three days, and then resolving spontaneously. Between attacks, patients feel entirely well. The pain and fever are usually abrupt and reach their peak soon after onset, although some patients tend to have a stereotypic, mild prodromal component of their attacks.

**Other causes.** Abdominal pain can be caused by myriad illnesses including metabolic disorders ranging from diabetic ketoacidosis to acute intermittent porphyria; abdominal malignancies; lactose intolerance; and helminthic and other tropical infectious diseases. Functional disorders are a common cause of chronic abdominal pain. Aortic dissection involving the descending aorta can produce abdominal pain. Abdominal pain may also be psychogenic in origin; this is most common in adolescents.

## BIBLIOGRAPHY

1. Woodwell D.A., Cherry D.K. National Ambulatory Medical Care Survey: 2002 summary Adv Data. 2004; 26 (346): 1–44.
2. Kamin R.A., Nowicki T.A., Courtney D.S., Powers R.D. Pearls and pitfalls in the emergency department evaluation of abdominal pain. Emerg Med Clin North Am. 2003; 21 (1): 61–72.
3. Purcell, T. Nonsurgical and extraperitoneal causes of abdominal pain. Emerg Med Clin North Am 1989; 7 (3): 721–740.

4. Beeson M.S. Splenic infarct presenting as acute abdominal pain in an older patient. *J Emerg Med* 1996; 14 (3): 319-322.
5. Fischer M.G., Farkas A.M. Diverticulitis of the cecum and ascending colon. *Dis Colon Rectum* 1984; 27 (7): 454-458.
6. Sugihara K., Muto T., Morioka Y., et al. Diverticular disease of the colon in Japan. A review of 615 cases. *Dis Colon Rectum* 1984; 27 (8): 531-537.
7. Schneider T.A., Longo W.E., Ure T., Vernava A.M., 3rd Mesenteric ischemia. Acute arterial syndromes. *Dis Colon Rectum* 1994; 37 (11): 1163-1174.
8. Mock J.N., Orsay E.M. Primary mesenteric venous thrombosis: an unusual cause of abdominal pain in a young, healthy woman. *Ann Emerg Med* 1994; 23: 352-355.
9. Silen W. (ed) *Cope's Early Diagnosis of the Acute Abdomen: 20<sup>th</sup> Edition*. NY: Oxford University Press, 2000, 268 p.
10. Ahmed, S, Siddiqui, AK, Siddiqui, RK, et al. Acute pancreatitis during sickle cell vasoocclusive painful crisis. *Am J Hematol* 2003; 73 (3): 190-193.
11. Pearigen P. Unusual causes of abdominal pain. *Emerg Med Clin North Am* 1996; 14:593-613.
12. Bugliosi T.F., Meloy T.D., Vukov L.F. Acute abdominal pain in the elderly. *Ann Emerg Med* 1990; 19 (12): 1383-1386.
13. Thuluvatn P.J., Connolly G.M., Forbes A., Gazzard B.G. Abdominal pain in HIV infection. *QJ Med* 1991; 78 (287): 275-285.
14. Snell R.S. *Clinical anatomy for medical students*, 6th ed., Lippincott Williams and Wilkins, Philadelphia 2000, 898 p.
15. Gavin R. Budhram, Rimon N. Bengiamin. Abdominal pain. <https://clinical-gate.com/abdominal-pain-4/> (accessed 20.07.2017).
16. Mary B. Fishman, Mark D. Aronsan. Differential diagnosis of abdominal pain in adults. <https://www.scribd.com/document/97457458/Differential-Diagnosis-of-Abdominal-Pain-in-Adults> (accessed 20.07.2017)

# DIFFERENTIAL DIAGNOSIS OF CONSTIPATION

**INTRODUCTION.** Constipation is one of the most common chronic gastrointestinal disorders in adults. In a 1997 epidemiology of constipation study that surveyed 10,018 persons, 12% of men and 16% of women met criteria for constipation. Annually, constipation accounts for 2.5 million physician visits and 92,000 hospitalizations in the United States of America. Constipation compromises quality of life, social functioning, and the ability to perform activities of daily living.

Universal criteria for the definition of constipation have not been established. In fact, the meaning of the term "constipation" may differ significantly when used by medical personnel than when used by patients. A widely accepted criterion among physicians is less than 3 bowel movements per week associated with hard stools. In the same time, patients may define constipation as straining to stool, hard stools, pain or difficulty associated with stooling, or may associate constipation with more generalized symptoms such as malaise.

## CLASSIFICATION

### **Types of constipation:**

*Primary constipation:* due to disordered regulation of colonic and anorectal neuromuscular functions as well as brain-gut neuroenteric function. Using symptom-based criteria, an international panel of experts has classified constipation into:

- Functional defecation disorders:
  - Dyssynergic defecation: paradoxical contraction or inadequate relaxation of the pelvic floor muscles during attempted defecation (pelvic floor dysfunction)
  - Slow transit constipation: inadequate defecatory propulsion (inadequate propulsive forces during attempted defecation)
- Irritable bowel syndrome-constipation (IBS-C).

*Secondary constipation:* constipation secondary to another condition such as diet, drugs, or behavioral, endocrine, metabolic, neurologic, and primary diseases of the colon (stricture, cancer, anal fissure, proctitis).

## PATHOPHYSIOLOGY

The process of defecation involves the propulsion of stool through the colon to the rectum, the recognition of stool within the rectum, and the conscious act of defecation.

The colon terminates in the rectum, which, in turn, passes through the levatorani muscles and becomes the anal canal. Two groups of muscles encircle the anal canal: the internal anal sphincter (involuntary control) and the external anal sphincter (voluntary control). The nearly 90-degree angle formed at the junction of the rectum and the anal canal is also important. This junction straightens with flexion of the hips, which explains the physiologic advantage of squatting for defecation.

Within three to four hours after ingestion, food enters the cecum; after several more hours, it reaches the rectum. When the rectal wall is distended by stool, reflex contraction of the rectum occurs, the internal anal sphincters relax, and fecal material is pushed into the anal canal. At this point, the stretch receptors of the anoderm perceive the stool, and a decision is made on whether to expel the stool by relaxing the external anal sphincter, squatting, and increasing intra-abdominal pressure with the Valsalva maneuver, or to postpone defecation by contracting the external anal sphincter and the gluteal muscle.

Slow transit constipation (STC) is related to primary dysfunction of colonic smooth muscle (myopathy) or its innervation (neuropathy), or both. Studies have confirmed that patients with STC exhibit significantly impaired phasic colonic motor activity, and gastrocolonic and morning waking responses, although the diurnal variation of colonic motility is preserved. Periodic motor activity in the rectosigmoid area is increased, serving as a brake for colonic food propulsion. Additionally, there is a significant decrease not only in the number of high-amplitude propagated contractions but also in the velocity of propagation and amplitude, leading to premature abortion of these waves in constipated patients.

Dyssynergia seems to be an acquired behavioral disorder of defecation in two-thirds of adult patients with difficult defecation, stemming from faulty toilet training, behavioral problems, or parent-child conflicts. In a prospective study, most patients with dyssynergic defecation showed the inability to coordinate the abdominal, rectoanal, and pelvic floor muscles during attempted defecation. Failure of rectoanal coordination consists of either paradoxical anal contraction, inadequate anal relaxation, or impaired rectal/abdominal propulsive forces. Additionally, two-thirds of these patients exhibit rectal hyposensitivity.

Patients with irritable bowel syndrome-constipation may have altered autonomic regulation or release of neurotransmitters such as serotonin or altered functions of gut receptors. Recently, familial aggregation and twin studies have reported the existence of genetic susceptibility for irritable bowel syndrome (IBS). Although several candidate genetic markers are associated with IBS, the occurrence of significant genetic polymorphism makes an etiologic or pathogenetic relevance less likely. Dietary factors such as fructose intolerance may also lead to IBS symptoms, particularly in those with gas and bloating and IBS-diarrhea (IBS-D). Recently, small-intestinal bacterial overgrowth has been implicated, and its eradication with rifaximin seems to improve symptoms in some patients. IBS has also been reported in a subset of patients following gastroenteritis, and this postinfectious IBS may be related to upregulation of intestinal cytokines and/or antecedent psychiatric problems. Recent studies of brain-gut interactions reveal that abnormal cortical perception, hypervigilance, and either impaired inhibition of descending efferent signals or dysregulation in the brain stem may play a role.

## ETIOLOGY

Awareness of the potential etiologies can help direct the history, physical exam and subsequent work-up for the presenting individual. Broadly, etiologies are considered to be normal variation, endocrine, metabolic, pharmacologic, luminal/intestinal disorders (including congenital), irritable bowel syndrome, systemic, psychological, neurogenic, and physiologic and pelvic floor dysfunctions.

### **Selected causes of constipation:**

#### I. Normal Variation

Pregnancy

Dietary factors:

- Low fiber intake
- Low fluid intake
- Malnutrition

Sedentary lifestyle

#### II. Endocrine conditions

Hypothyroidism

Diabetes Mellitus

Hyperparathyroidism

Hypopituitarism



- Carcinomatosis
- Porphyria
- Pheochromocytoma
- Glucagonoma
- III. Metabolic conditions
  - Hypokalemia
  - Hypercalcemia
  - Uremia
  - Milk-alkali syndrome
- IV. Immunologic conditions
  - Celiac disease
  - Cystic fibrosis
- V. Pharmacologic (see below)
- VI. Luminal/intestinal disorders
  - Anorectal disorders:
    - Anal or perianal fissures
    - Anal stenosis
    - Rectal prolapse
    - Rectocele
    - Thrombosed hemorrhoids
  - Colonic disorders:
    - Diverticulosis
    - Ischemic colitis
    - Radiation therapy
    - Adenocarcinoma
    - Pseudo-obstruction
    - Megacolon
    - Idiopathic megarectum
- VII. Irritable Bowel Syndrome
- VIII. Systemic conditions
  - Systemic sclerosis
  - Renal failure
- IX. Myopathic conditions
  - Amyloidosis
  - Scleroderma
  - Dermatomyositis
  - Myotonic dystrophy
- X. Psychological conditions

- Depression
- Anorexia nervosa
- Bulimia nervosa
- XI. Neurological – CNS conditions
  - Multiple Sclerosis
  - Parkinson's disease
  - Stroke/Ischemia
  - Paraplegia
  - Trauma
  - Tumors
  - Cauda Equina tumor
  - Meningocele
  - Tabes dorsalis
  - Shy-Drager syndrome
- XII. Neurological – peripheral conditions
  - Autonomic neuropathy
  - Autonomic dysfunction
  - Hirschsprung's disease
  - Chagas' disease
  - Hypoganglionosis
  - Multiple endocrine neoplasia, Type 2B
  - Von Recklinghausen's disease
- XIII. Chronic Idiopathic constipation
  - Slow colonic transit
  - Pelvic floor dysfunction
    - Rectocele
    - Enterocele
    - Cystocele
    - Uterine prolapse
    - Pelvic floor trauma
    - Menopause without estrogen replacement

## DIFFERENTIAL DIAGNOSIS

### Major causes:

**Normal variation.** Although defecation three times a week is a commonly accepted criterion, some persons may defecate less frequently as a normal variant. If stools are soft and painless, if there are no systemic symptoms, and there is a family history of infrequent stools, this may be a normal variant.

Pregnancy is frequently associated with constipation, especially complaints of hard stools. Many aspects of pregnancy may contribute to the development of constipation including decreased fluid intake secondary to nausea, decreased activity, and hormonal changes including evidence for decreased motilin serum levels.

**Endocrine causes.** Hypothyroidism is classically associated with constipation. Gastrointestinal symptoms are often the presenting feature of mild disease. The constipation is generally attributed to metabolic influences leading to decreased gut motility. The pathophysiology, however, is incompletely understood. Decreased transit times in the setting of hypothyroidism have been demonstrated. Myxedematous infiltration of the gut is possible, with megacolon as a possible result.

Diabetes mellitus has a well-known association with decreased gastrointestinal motility. Type II diabetics appear twice as likely to suffer constipation than non-diabetics. Diabetics with severe constipation were shown to have no spike in post-prandial colonic activity. However, when given neostigmine, a cholinergic agonist, the colonic components responded. These findings suggest that autonomic neural dysfunction may contribute to diabetic constipation. There is also some evidence that hyperglycemia blunts gastrocolonic mechanoreceptor responses.

**Metabolic causes.** Hypercalcemia may present with constipation. The mechanism is probably related to decreased contractility of the muscle walls of the gastrointestinal tract. Such hypercalcemia may be the result of hyperparathyroidism. It may be a sign of malignancy that involves bone or demonstrates a paraneoplastic component. Sarcoid can produce hypercalcemia and secondary constipation.

Hypokalemia may also result in constipation. Hypokalemia, as a cause of constipation, must be particularly considered in a patient on diuretic therapy.

**Pharmacologic causes.** A multitude of pharmacologic agents have been associated with constipation. The most commonly used culprits are antihypertensives (especially calcium channel blockers), opiates, iron supplements, and aluminum and calcium-based antacids. Medications causing or aggravating constipation:

- Analgesics (especially opioid derivatives, but also aspirin and other NSAIDs)
- Antacids (both aluminum- and calcium-based antacids)
- Anticholinergics

- Anticonvulsants
- Antispasmodics
- Antidepressants (including Selective Serotonin Reuptake Inhibitors)
- Antipsychotics
- Antiparkinsonian drugs
- Antihypertensives (especially calcium-channel blockers, Clonidine)
- Barium sulfate
- Calcium supplements
- Chemotherapeutic agents (especially Vinca alkaloids)
- Diuretics
- Iron supplements
- Laxative abuse
- Metallic intoxication (including lead, mercury or arsenic)
- Cholestyramine

Discovering a pharmacological etiology can be problematic as most patients who present are over 65 and may be treated with polypharmacy for a variety of chronic conditions. Physicians, understandably, are reluctant to withdraw or change chronic therapies that may, or may not, be the cause of constipation. Patient compliance with medications may be considerably improved if consideration is given to symptomatic treatment of constipation.

**Luminal/intestinal disorders.** A possibility that must be considered in the differential diagnosis of constipation is some form of physical blockage to the defecation process. The possibility of colon cancer or polyp, particularly in the presence of painless guaiac-positive stools, a family history of colon cancer or in persons over fifty is of concern. Such conditions should prompt a more thorough investigation including barium enema, sigmoidoscopy or colonoscopy. In persons over age 50, a complaint of constipation should be enough reason to go ahead with a sigmoidoscopy and fecal occult blood test (FOBT), as the minimum work-up. Such testing conforms to the cancer screening recommendations of the American Gastrointestinal Association and the American Cancer Society, which include a sigmoidoscopy every 3-5 years in all persons age 50 or older and FOBT annually in all persons over age 40.

Another consideration is the patient's surgical history. Pelvic surgery and hysterectomy, in particular, have been associated with an increase in straining and incomplete evacuation. The pathogenesis of this observation

is not clear since the anorectal inhibitory reflex and rectal sensation may appear unchanged.

A chronic course generally speaks against obstruction but severe abdominal pain, a family history of the same, and multiple work-ups to rule out obstruction suggest the possibility of pseudo-obstruction. A pseudo-obstruction is often found to be secondary to myopathy of colonic muscle.

Megacolon and megarectum are potential causes of constipation. Many of these conditions will be acquired rather than congenital. Chagas' disease is caused by the parasite *Trypanosoma cruzi* that is prevalent in Central and South America and that may destroy ganglion cells of the colon. Neurologic associations with megacolon and megarectum include spinal chord injuries, Parkinsonism and schizophrenia. Other potential etiologies include amyloidosis, scleroderma and myxedema secondary to hypothyroidism. Narcotic medications also increase the risk of megacolon. Chronic idiopathic megacolon is considered to be psychogenic.

Hirschsprung's disease, a congenital narrowing of the colon due to an aganglionic segment, is rarely first diagnosed in adulthood. Such cases are associated with severe lifelong constipation and may be associated with an unusually short aganglionic segment.

**Irritable bowel syndrome.** Constipation may be a single symptom in a constellation of complaints that represents irritable bowel syndrome (IBS). The most frequently cited diagnostic criteria are the Manning criteria (see Rome IV criteria below). Women are more often affected than men; prevalence decreases with age and is similar in whites and African Americans. Hispanics are less affected. IBS should be considered frequently, especially in younger patients without other medical problems because of its widespread prevalence. There are some patients who suffer from constipation-predominant IBS and who have slow or delayed transit through their colon. There is also a clear association between IBS and psychological co-morbidity. Associated symptoms may include, among others, depressive symptoms, somatization, anxiety or phobias.

*Systemic.* Systemic sclerosis can affect not just esophageal transit, but colonic transit as well. Total and right colonic transit times and anal sphincter function have been shown to be impaired when compared to controls with idiopathic constipation.

*Psychological.* There is some evidence that constipation may appear or worsen with the onset of a major depression, the reason has not been elucidated. Anorexia nervosa and bulimia nervosa have been associated with constipation as well.

**Neurologic: Central Nervous System.** Multiple sclerosis may result in constipation, sometimes associated with fecal urgency.

*Parkinson's disease* is associated with gastrointestinal motility disorders including constipation. Constipation may be a result of a depletion of dopaminergic neurons in the myenteric plexus, similar to that which occurs in the central nervous system. A likely second factor is striated muscle contraction leading to pelvic outlet obstruction.

*Spinal cord lesions* may also result in constipation. Sacral and cauda equina lesions can result in decreased contractions of the left colon as well as decreased rectal sensation. Autonomic as well as perianal sensory innervation may be involved. Spinal cord lesions above the sacrum result in a depressed post-prandial colonic motor stimulus. In general, the mechanism of constipation in spinal chord injuries appears to be a prolonged colonic transit time.

**Chronic idiopathic constipation** is often divided into two broad etiologic categories: colonic transit vs. pelvic outlet obstruction (formerly termed anismus), although they may occur concurrently. Prolonged colonic transit is of unknown etiology but may be quantified through testing.

*Pelvic outlet obstruction* (pelvic floor dysfunction) involves disorders of the muscular movements of defecation, or their innervation. Normal defecation requires relaxation of the puborectalis muscle and external anal sphincter while increasing intra-abdominal pressure. Paradoxical puborectalis contraction or a generalized descent of the pelvic floor may be the result of the pudendal nerve damage (a common etiology is trauma during vaginal delivery) or psychological conditions. Pelvic floor descent results in a widening of the anorectal angle making defecation more difficult because the stool must pass through an angled and narrowed lumen. The result is an obstruction, which combined with straining, can lead to intrarectal mucosal intussusception or rectal prolapse.

**Functional constipation** is defined by the Rome IV diagnostic criteria (see below) and can be further divided into normal transit, slow transit, and outlet constipation.

*Normal transit constipation* is defined as a perception of constipation on patient self-report; however, stool movement is normal throughout the colon. Other symptoms reported by patients with normal transit constipation include abdominal pain and bloating. Normal transit constipation has been associated with increased psychosocial stress, and usually responds to medical therapy, such as fiber supplementation or laxatives.

*Slow transit constipation* is defined as prolonged transit time through the colon. This can be confirmed with radiopaque markers that are delayed on motility study. A prolonged colonic transit time is defined as more than six markers still visible on a plain abdominal radiograph taken 120 hours after ingestion of one Sitzmarks capsule containing 24 radiopaque markers. Patients with slow transit constipation have normal resting colonic motility, but do not have the increase in peristaltic activity that should occur after meals. In addition, the administration of bisacodyl and cholinergic agents does not cause an increase in peristaltic waves as it does in persons without constipation. Typical symptoms of slow transit constipation include an infrequent „call to stool,” bloating, and abdominal discomfort. Patients with severe slow transit constipation tend not to respond to fiber supplementation or laxatives.

*Outlet constipation*, also known as pelvic floor dysfunction, is defined as incoordination of the muscles of the pelvic floor during attempted evacuation. Outlet constipation is not caused by muscle or neurologic pathology, and most patients have normal colonic transit. In patients with outlet constipation, stool is not expelled when it reaches the rectum. Common features include prolonged or excessive straining, soft stools that are difficult to pass, and rectal discomfort. It is not uncommon for patients to require manual aid to evacuate stool from the rectum. The exact etiology of outlet constipation remains unclear. Defecation disorders do not respond to traditional medical treatment, but may respond to biofeedback and relaxation training.

*Constipation in older adults.* Constipation is not a normal part of aging. The prevalence of constipation peaks after 70 years of age, reaching between 8 and 43%, depending on the population studied. The older persons perceive constipation as straining during defecation and difficulty in evacuation, rather than decreased frequency of bowel movements. In community-dwelling adults older than 65 years, about 20% have rectal outlet delay with need to self-evacuate. Other causes of functional constipation in older adults may result from autonomic neuropathies, such as diabetes mellitus and Parkinson disease, or from use of medications, such as opioids and anticholinergics. A prospective study in nursing home residents found that independent risk factors for constipation included poor consumption of fluids, pneumonia, Parkinson disease, immobility, use of more than five medications, dementia, hypothyroidism, white race, allergies, arthritis, and hypertension. Frail older persons may not be able to report bowel-related

symptoms because of communication or cognitive impairment. They may also have impaired rectal sensation and inhibited urge to evacuate, and therefore may not be aware of fecal impaction. As a result, these patients may experience nonspecific symptoms, such as delirium, anorexia, and functional decline.

Important presentations of constipation in older persons include fecal impaction and fecal incontinence secondary to paradoxical diarrhea. Patients with fecal impaction may present with nonspecific symptoms of clinical deterioration, or more specific symptoms, such as anorexia, vomiting, and abdominal pain. Paradoxical diarrhea may occur when liquid stools from the proximal colon bypass the impacted stool. The impaction can lead to diminished rectal sensation and resultant fecal incontinence. Fecal impaction can cause bowel obstruction and ulceration. Risk factors for fecal impaction include prolonged immobility, cognitive impairment, spinal cord disorders, and colonic neuromuscular disorders. Excessive straining from constipation can also lead to hemorrhoids, anal fissures, and rectal prolapse. In some cases, straining can cause syncope or cardiac ischemia.

## DIAGNOSTIC APPROACH

A thorough investigation of constipation may be indicated for one of the two reasons:

- 1) to exclude systemic disease or a structural disorder of the intestines,  
or
- 2) to elucidate the underlying pathophysiologic process when constipation does not respond to simple treatment.

Acute constipation is more often associated with organic disease than long-standing constipation is. It is important to determine whether the patient has a history or signs and symptoms of a neurologic, endocrine, or metabolic disorder. The patient must be asked about *red flags* that suggest the presence of an underlying gastrointestinal organic disorder. The important *red flags* include abdominal pain, nausea, cramping, vomiting, unintended weight loss of 4.5 kg or more, melena, rectal bleeding, rectal pain, fever, iron deficiency anemia and family history of colon cancer.

### **Rome IV criteria of functional bowel disorders**

*Diagnostic criteria for functional constipation* (criteria fulfilled for the last 3 months with symptom onset at least 6 months prior to diagnosis):

- Must include 2 or more of the following:
  - Straining during at least 25% of defecations



- Lumpy or hard stools at least 25% of defecations
- Sensation of incomplete evacuation at least 25% of defecations
- Sensation of anorectal obstruction/blockage at least 25% of defecations
- Manual maneuvers to facilitate at least 25% of defecations (e.g., digital evacuation, support of the pelvic floor)
- Less than 3 defecations per week.
- Loose stools are rarely present without the use of laxatives.
- There are insufficient criteria for irritable bowel syndrome (IBS).

*Diagnostic criteria for IBS-constipation:*

- Recurrent abdominal pain, on average, at least 1 day per week in the last 3 months, associated with 2 or more of the following:
  - Improvement with defecation
  - Onset associated with a change in frequency of stool
  - Onset associated with a change in the form (appearance) of stool.
- Criteria fulfilled for the last 3 months with symptom onset at least 6 months before diagnosis.

*Diagnostic criteria for functional defecation disorders* (criteria fulfilled for the last 3 months with symptom onset at least 6 months prior to diagnosis):

- The patient must satisfy diagnostic criteria for functional constipation.
- During repeated attempts to defecate, there must be at least 2 of the following:
  - Evidence of impaired evacuation, based on balloon expulsion test or imaging
  - Inappropriate contraction of the pelvic floor muscles (i.e., anal sphincter or puborectalis) or less than 20% relaxation of basal resting sphincter pressure by manometry, imaging, or electromyography
  - Inadequate propulsive forces, assessed by manometry or imaging.

I. Dyssynergic defecation

Inappropriate contraction of the pelvic floor or less than 20% relaxation of basal resting sphincter pressure with adequate propulsive forces during attempted defecation.

II. Inadequate defecatory propulsion

Inadequate propulsive forces with or without inappropriate contraction or less than 20% relaxation of the anal sphincter during attempted defecation.

## Diagnostic Tests

Laboratory studies and colorectal imaging are appropriate when constipation is persistent and fails to respond to conservative treatment, or when a particular disorder is suspected. Laboratory tests may include a complete blood cell count and thyroid-stimulating hormone, calcium, glucose, potassium, and creatinine levels. The stool should be tested for occult blood.

Flexible sigmoidoscopy and colonoscopy are excellent for identifying lesions that narrow or occlude the bowel. Colonoscopy, if readily available, is the examination of choice in adult patients with constipation who have iron deficiency anemia, a positive guaiac stool test, or a first-degree relative with colon cancer. An alternative examination is barium enema and flexible sigmoidoscopy, a combination that can demonstrate potentially diagnostic features such as colonic dilatation and strictures.

If extracolonic and mechanical causes of constipation are excluded by laboratory studies and colorectal imaging, a complete physiologic evaluation is warranted. Possible tests include anal manometry, balloon insertion, defecography, and colonic transit studies.

Anal manometry is performed to assess the anal sphincter, pelvic floor, and associated nerves. A special pressure-sensitive catheter is inserted into the anus to measure resting and squeeze pressures of the sphincter. Increased anal sphincter pressures are often associated with pelvic floor dysfunction. The principal purpose of anorectal manometry in the setting of chronic constipation is to exclude adult-onset or short-segment Hirschsprung's disease (congenital megacolon), which should be suspected in the absence of the rectoanal inhibitory reflex.

Balloon insertion is the simplest and perhaps most physiologic test to demonstrate rectal evacuation. Studies have found that healthy volunteers can expel the balloon, whereas most patients with pelvic floor dysfunction cannot.

Defecography and colonic transit studies are particularly useful in patients with intractable constipation or pelvic floor disorders. Videodefecography is specifically designed to evaluate evacuatory disorders such as rectal prolapse and rectocele. The patient's rectum is filled with thickened barium (to simulate the consistency of stool) for this study. The patient is then seated on a water-filled commode and examined from a lateral view with fluoroscopy. Views are obtained with the patient at rest, squeezing to defer a bowel movement, and straining to evacuate the rectum.

To study colonic transit, serial abdominal radiographs are obtained after

the patient swallows a capsule filled with radiopaque markers. In normal persons, most of the markers should pass by day 5; in a patient with slow colonic transit, the markers will be scattered throughout the colon. If the patient has pelvic outlet obstruction, more than 20% of the markers will be held up in the rectum.

Physiologic testing can be used to divide "idiopathic constipation" into two distinct categories, those suffering from colonic inertia (disorders of colonic transit) and those suffering from pelvic obstruction. The distinction is important because the treatments are very different. Although they may be seen in combination, they are still treated distinctly and sequentially.

## BIBLIOGRAPHY

1. Higgins P.D., Johanson J.F. Epidemiology of constipation in North America: a systematic review. *Am J Gastroenterol.* 2004; 99 (4): 750–759.
2. Stewart W.F., Liberman J.N., Sandler R.S., et al. Epidemiology of constipation (EPOC) study in the United States: relation of clinical subtypes to sociodemographic features. *Am J Gastroenterol.* 1999; 94 (12): 3530–3540.
3. Singh G., Lingala V., Wang H., et al. Use of health care resources and cost of care for adults with constipation. *Clin Gastroenterol Hepatol.* 2007; 5 (9): 1053–1058.
4. Bharucha A.E., Wald A., Enck P., et al. Functional anorectal disorders. *Gastroenterology.* 2006; 130 (5): 1510–1518.
5. Rao S.S. Dyssynergic defecation and biofeedback therapy. *Gastroenterol Clin North Am.* 2008; 37 (3): 569–586. <https://www.ncbi.nlm.nih.gov/pmc/articles/PMC2575098/> (accessed on 10.08.2017).
6. Bharucha A.E., Dorn S.D., Lembo A., et al. American Gastroenterological Association medical position statement on constipation. *Gastroenterology.* 2013; 144 (1): 211–217.
7. Di Lorenzo C. Childhood constipation: finally some hard data about hard stools! *J Pediatr.* 2000; 136: 4–7.
8. Bassotti G., de Roberto G., Castellani D., et al. Normal aspects of colorectal motility and abnormalities in slow transit constipation. *World J Gastroenterol.* 2005; 11 (18): 2691–2696.
9. Rao S.S., Tuteja A.K., Vellema T., et al. Dyssynergic defecation: demographics, symptoms, stool patterns, and quality of life. *J Clin Gastroenterol.* 2004; 38: 680–685.
10. Crowell M.D., Harris L., Jones M.P., et al. New insights into the pathophysiology of irritable bowel syndrome: implications for future treatments. *Curr Gastroenterol Rep.* 2005; 7 (4): 272–279.
11. Wilder-Smith C.H., Schindler D., Lovblad K., et al. Brain functional mag-

- netic resonance imaging of rectal pain and activation of endogenous inhibitory mechanisms in irritable bowel syndrome patient subgroups and healthy controls. *Gut*. 2004; 53 (11): 1595-1601.
12. Enck P, Rathmann W, Spiekermann M., Czemer D., Tschöpe D., Zeigler D., et al. Prevalence of gastrointestinal symptoms in diabetic patients and non-diabetic subjects. *Z Gastroenterol*. 1994; 32 (11): 637-641.
  13. Anthony S. Fauci et al. eds. *Harrison's Principles of Internal Medicine*, 17th Ed. New York: McGraw-Hill, 2008, 2748 p.
  14. Chun A.B., Sokol M.S., Kaye W.H., Hutson W.R., Wald A. Colonic and anorectal function in constipated patients with anorexia nervosa. *Am J Gastroenterol*. 1997; 92 (10): 1879-1883.
  15. De Looze D.A., De Muynck Mc, Van Laere M., De Vos M.M., Elewaut A.G. Pelvic floor function in patients with clinically complete spinal cord injury and its relation to constipation. *Dis Colon Rectum*. 1998; 41: 778-786.
  16. Rao S.S. Constipation: evaluation and treatment of colonic and anorectal motility disorders. *Gastroenterol Clin North Am*. 2007; 36 (3): 687-711.
  17. Bassotti G., Chistolini F., Sietchiping-Nzopa F., de Roberto G., Morelli A., Chiarioni G. Biofeedback for pelvic floor dysfunction in constipation. *BMJ*. 2004; 328 (7436): 393-396.
  18. De Lillo A.R., Rose S. Functional bowel disorders in the geriatric patient: constipation, fecal impaction, and fecal incontinence. *Am J Gastroenterol*. 2000; 95 (4): 901-905.
  19. Brian E. Lacy, Fermín Mearin, Lin Chang, William D. Chey, Anthony J. Lembo, Magnus Simren, Robin Spiller. Bowel disorders. *Gastroenterology* 2016; 150: 1393-1407

## DIFFERENTIAL DIAGNOSIS OF DIARRHEA

**INTRODUCTION.** Diarrheal diseases accounts for 2.5 million deaths per year worldwide. In the United States of America, an estimated 48 million foodborne diarrheal illnesses occur annually, resulting in more than 128,000 hospitalizations and 3,000 deaths. In the developing world, infectious causes of acute diarrhea are largely related to contaminated food and water supplies.

**DEFINITION.** The term „diarrhea” derived from Greek „to flow through” and means an increase in the frequency of bowel movements (3 or more stool daily is generally abnormal), an increase in the looseness of stool (increased stool water content/fluidity, increased stool weight >200 gram/d) or both.

Diarrhea can be clinically classified into:

- Acute diarrhea is defined as stool with increased water content, volume, or frequency that lasts less than 14 days.
- Persistent diarrhea is defined as an episode that lasts longer than 14 days till four weeks.
- Chronic diarrhea is defined as a decrease in stool consistency continuing for more than four weeks.

The distinction has implications not only for classification and epidemiologic studies but also from a practical standpoint, because protracted diarrhea often has different etiologies, poses different management problems, and has a different prognosis.

**PATHOPHYSIOLOGY.** Diarrhea is the reversal of the normal net absorptive status of water and electrolyte absorption to secretion. The augmented water content in the stools (above the normal value of approximately 10 mL/kg/d in the infant and young child, or 200 g/d in the teenager and adult) is due to an imbalance in the physiology of the small and large intestinal processes involved in the absorption of ions, organic substrates, and thus water.

### **Normal stool fluids processing:**

- About 8-9 liters of fluids enter daily in the gastrointestinal system:
  - Ingest 1-2 liters
  - Secretions 7 liters (saliva 1,5 L, gastric juice 2,5 L, pancreatic juice 1,5 L, bile 0,5 L, intestinal secretion 1 L)
- The small bowel reabsorbs 6-7 liters per day

- The large bowel absorbs 2-3 liters
- 100-200 ml remain in stool

Diarrhea occurs when small bowel/colon solute loads exceed their absorptive capacities. Reduction of water absorption, due to a decrease in absorption or increase in secretion (as little as 1%) can lead to diarrhea.

**The main mechanisms of diarrhea:**

- Secretory diarrhea
- Osmotic diarrhea
- Increased bowel motility
- Decreased bowel surface area

*Secretory diarrhea.* A problem of excess input of electrolytes (NaCl) with water following. Electrolyte transportation is disordered (net secretion of anions as chloride or bicarbonate and net inhibition of sodium absorption). We have the following clinical manifestations as a result: large volume, water diarrhea; little response to fasting; stool composition is similar to plasma; dehydration and plasma electrolyte imbalance; no white or red blood cells in stool.

Causes of intestinal secretion:

- I. Stimulation of NaCl secretion
  - Bacterial toxins (*Cholera*, *E.coli*, *Shigella*, etc)
  - Inflammatory mediators (prostaglandins)
  - Circulating hormones (gastrin, vasoactive intestinal polypeptide)
- II. Malabsorbed compounds that reach the colon and stimulate secretion (bile acids, fatty acids)
- III. Laxatives that stimulate secretion (ricinoleic acid, senokot)
- IV. Lack of mature villus/surface absorptive cells reducing absorption (viral gastroenteritis/ceeliac sprue).
- V. Absence of ion transporter (congenital chloridorrhea)

*Osmotic Diarrhea* is caused by the presence of poorly absorbed luminal osmotic active substance that retains fluid within the lumen. It can be because of:

- Ingestion of non-absorbable compounds  
carbohydrates or sugar alcohols as mannitol, sorbitol, lactulose, magnesium salts (antacids – Maalox, laxatives – milk of magnesia)
- Malabsorption of specific carbohydrates (disaccharidase deficiency)
- Generalized malabsorption of nutrients

Osmotic principles:

- The driving force of fluid movement is ion or solute transport

- Solutes may be actively transported through cell membranes
- Solutes may move passively through cells following concentration and/or electrical gradients
- Water movement follows solute movement by osmosis
- Water may move between cells (tight junctions) or through cell membrane channels (aquaporins)

Gastrointestinal epithelia cannot maintain an osmotic gradient and cannot generate as high a Na or other ion gradient. Thus osmotic diarrhea is due to three factors:

- Amount of ingested material containing non-absorbed solute.
- Volume of extra water needed to dilute the ingested material to isotonicity.
- Volume of water accompanying the Na, Cl and other ions those equilibrate across the gut epithelia.

Clinical Manifestations of osmotic diarrhea:

- Moderate volume of stool
- Improves/disappears when oral intake stops
- Moderately water/soft stool
- Are often associated with increased flatus if due to carbohydrate malabsorption
- No white or red blood cells in stool.

*Diarrhea due to increased bowel motility.* Rapid intestinal motility may result in diarrhea due to the reduction of contact time between luminal content and bowel mucosa. Examples include anxiety, hyperthyroidism, irritable bowel syndrome, postvagotomy diarrhea (dumping syndrome), and bowel infection (viral gastroenteritis).

Clinical characteristics of diarrhea induced by increased bowel motility are:

- Moderate diarrhea – usually watery
- It often occurs after meals – accentuated gastro-colic reflex
- No white or red blood cells in stool
- Recently eaten food visible in stools
- Louder bowel sounds often apparent
- No diagnostic tests– often must rule-out secretory/osmotic/inflammatory causes.

*Diarrhea due to loss of bowel surface area* is a functional equivalent to increased bowel motility. Underlying process causing loss of surface area may produce additional symptoms. The main important causes of this

type of diarrhea include surgical intestinal resection, disease of intestinal mucosa, intestinal fistulas.

**CLINICAL CLASSIFICATION.** Clinically diarrhea may be divided into three basic categories: watery, fatty (malabsorption), and inflammatory. However, not all chronic diarrheas are strictly watery, malabsorptive, or inflammatory, because some categories overlap.

**Watery diarrhea** may be subdivided into osmotic, secretory, and functional (hypermotility) types. The most important causes of water diarrhea are:

I. Secretory (often nocturnal; unrelated to food intake; fecal osmotic gap less than 50 mOsm per kg)

Alcoholism

Bacterial enterotoxins

Bile acid malabsorption

Brainerd diarrhea (epidemic secretory diarrhea)

Congenital syndromes

Crohn disease (early ileocolitis)

Endocrine disorders

Medications

Microscopic colitis (lymphocytic and collagenous subtypes)

Neuroendocrine tumors (e.g., gastrinoma, vipoma, carcinoid tumors, mastocytosis)

Postsurgical (e.g., cholecystectomy, gastrectomy, vagotomy, intestinal resection)

Vasculitis

II. Osmotic (fecal osmotic gap less than 125 mOsm per kg)

Carbohydrate malabsorption syndromes

Celiac disease

Osmotic laxatives and antacids

Sugar alcohols

III. Functional (distinguished from secretory types by hypermotility, smaller volumes, and improvement at night and with fasting)

Irritable bowel syndrome

**Fatty diarrhea** (steatorrhea) may be triggered by two mechanisms:

I. Malabsorption or inadequate mucosal transport of digestion products

Amyloidosis

Carbohydrate malabsorption (lactose intolerance)

Celiac sprue (gluten enteropathy)



Gastric bypass

Lymphatic damage (e.g., congestive heart failure, some lymphomas)

Medications (e.g., orlistat, acarbose)

Mesenteric ischemia

Noninvasive small bowel parasite (e.g., *Giardia*)

Postresection diarrhea

Short bowel syndrome

Small bowel bacterial overgrowth (> 10<sup>5</sup> bacteria per mL)

Tropical sprue

Whipple disease (*Tropheryma whippelii* infection)

## II. Maldigestion or inadequate breakdown of triglycerides

Hepatobiliary disorders

Inadequate luminal bile acid

Loss of regulated gastric emptying

Pancreatic exocrine insufficiency

## **Inflammation-induced diarrhea** results from several mechanisms:

- Stimulated secretion and inhibited absorption
- Stimulation of enteric nerves causing propulsive contractions and stimulated secretion
- Mucosal destruction and increased permeability
- Nutrient maldigestion malabsorption

The most important causes of inflammatory diarrhea are:

### I. Inflammatory bowel diseases

Crohn disease (ileal or early Crohn disease may be secretory)

Ulcerative colitis

Ulcerative jejunoileitis

Diverticulitis

### II. Invasive infectious diseases

*Clostridium difficile* (pseudomembranous) colitis

Invasive bacterial infections (e.g., tuberculosis, yersiniosis)

Invasive parasitic infections (e.g., *Entamoeba*)

Ulcerating viral infections (e.g., *cytomegalovirus*, *Herpes simplex virus*)

### III. Neoplasia

Colon carcinoma

Lymphoma

Villous adenocarcinoma

### IV. Radiation colitis

Clinical manifestations of inflammatory diarrhea:

- Fever and systemic signs of inflammation (in case of an invasive organism)
- Small to moderate volume of diarrhea
- Bloody diarrhea and/or white/red blood cells in stool (except in mild inflammation like viral/microscopic colitis)
- Are often accompanied by rapid motility/abdominal cramps
- Urgency/tenesmus if rectum is involved

## DIAGNOSTIC APPROACH

**History.** The onset, duration, severity, and frequency of diarrhea should be noted, with particular attention to stool character (e.g., watery, bloody, mucus-filled, purulent, bilious, undigested food particles). The patient should be evaluated for signs of dehydration, including decreased urine output, thirst, dizziness, and change in mental status. Vomiting is more suggestive of viral illness or illness caused by ingestion of a preformed bacterial toxin. Symptoms more suggestive of invasive bacterial (inflammatory) diarrhea include fever, tenesmus, and grossly bloody stool.

A food and travel history is helpful to evaluate potential exposures. Children in day care, nursing home residents, food handlers, and recently hospitalized patients are at high risk of infectious diarrheal illness. Pregnant women have a 12-fold increased risk of listeriosis, which is primarily contracted by consuming cold meats, soft cheeses, and raw milk. Recent sick contacts and use of antibiotics and other medications should be noted in patients with acute diarrhea (see Table 9). Sexual practices that include receptive anal and oral-anal contact increase the possibility of direct rectal inoculation and fecal-oral transmission.

The history should also include gastroenterological disease or surgery; endocrine disease; radiation to the pelvis; and factors that increase the risk of immunosuppression, including human immunodeficiency virus infection, long-term steroid use, chemotherapy, and immunoglobulin A deficiency.

**Physical examination.** The primary goal of the physical examination is to assess the patient's degree of dehydration. Generally ill appearance, dry mucous membranes, delayed capillary refill time, increased heart rate, and abnormal orthostatic vital signs can be helpful in identifying more severe dehydration. Fever is more suggestive of inflammatory diarrhea. The abdominal examination is important to assess for pain and acute abdominal processes. A rectal examination may be helpful in assessing for blood, rectal tenderness, and stool consistency.

**Drugs associated with diarrhea**

<b>Type of Diarrhea</b>	<b>Medications</b>
Osmotic	Citrates, phosphates, sulfates Magnesium-containing antacids and laxatives Sugar alcohols (e.g., mannitol, sorbitol, xylitol)
Secretory	Antiarrhythmics (e.g., quinine) Antibiotics (e.g., amoxicillin/clavulanate) Antineoplastics Biguanides Calcitonin Cardiac glycosides (e.g., digitalis) Colchicine Nonsteroidal anti-inflammatory drugs (may contribute to microscopic colitis) Prostaglandins (e.g., misoprostol) Ticlopidine
Motility	Macrolides (e.g., erythromycin) Metoclopramide (Reglan) Stimulant laxatives (e.g., bisacodyl, senna)
Malabsorption	Acarbose Aminoglycosides Orlistat Thyroid supplements Ticlopidine
Pseudomembranous colitis ( <i>Clostridium difficile</i> )	Antibiotics (e.g., amoxicillin, cephalosporins, clindamycin, fluoroquinolones) Antineoplastics Immunosuppressants

The most important **diagnostic testings** in diarrhea are:

1. Complete blood count with differential (Hematocrit, Mean corpuscular volume, White blood cell count)
2. Electrolytes, blood urea nitrogen test, glucose, Liver function tests, calcium, albumin
3. Thyroid stimulating hormone, vitamin B12, vitamin D, prothrombin time, erythrocyte sedimentation rate, iron, C-reactive protein, Amoeba Ab, anti-transglutaminase IgA Ab, anti-endomyseal IgA Ab, Human immunodeficiency virus.
4. Stool studies:
  - Stool culture more useful only for acute but the indiscriminate use of stool cultures in the evaluation of acute diarrhea is inefficient (results are positive in only 1.6 % to 5.6 % of cases) and expensive. Obtaining cultures only in patients with screening tests positive for leukocytes

decreases the cost. Obtaining cultures only in patients with grossly bloody stools increases the yield for positive culture results to greater than 30 %. Although there is no consensus on which patients need a culture, it is reasonable to perform a culture if the patient has grossly bloody stool, severe dehydration, signs of inflammatory disease, symptoms lasting more than three to seven days, or immunosuppression.

- *Clostridium difficile* testing. Testing for *Clostridium difficile* toxins A and B is recommended for patients who develop unexplained diarrhea after three days of hospitalization; the test will be positive in 15% to 20% of these patients
- Fecal leukocytes (or marker for neutrophils: lactoferrin or calprotectin)
- Fecal occult blood (is 71% sensitive and 79% specific for inflammatory diarrhea in developed countries, but the sensitivity drops to 44 % and specificity to 72% in developing countries.)
- Stool electrolytes for osmolar gap =  $290 - 2[\text{Na} + \text{K}]$
- Stool pH (less than 6 suggests carbohydrate malabsorption due to colonic bacterial fermentation to  $\text{CO}_2$ ,  $\text{H}_2$ , and short chain fatty acids)
- Fat content (48 hours or 72 hours quantitative or Sudan stain)
- Laxative screen
- Ova and parasites tests (for patients with chronic diarrhea)

#### 5. Additional tests:

- Imaging (small bowel series, Computed tomography / Magnetic resonance imaging or Computed tomography / Magnetic resonance enterography)
- Endoscopy with push enteroscopy with small bowel biopsy
- Colonoscopy with Flexible Sigmoidoscopy, including random biopsies.

## DIFFERENTIAL DIAGNOSIS

### Major causes:

**Infectious enteritis.** Infectious causes of diarrhea are commonly seen in the etiology of acute diarrhea. Ingestion of contaminated food or water is the typical culprit; recent travel, exposure to other ill persons, recent hospitalization, child care center attendance, and nursing home residence should all raise the index of suspicion (see Table 10). Common bacterial agents include *Campylobacter*, *Salmonella*, and *Shigella* species, as well as *E. coli*. Viral infections may be caused by rotavirus, Norwalk virus, cytomegalovirus, herpes simplex virus, and viral hepatitis. In developed countries, parasitic diarrhea is generally only a concern among travelers and those

Table 10

**Etiology of infectious diarrhea and associated symptoms**

<b>Agents</b>	<b>Symptoms</b>
<i>Campylobacter jejuni</i>	fever, headache and muscle pain followed by diarrhea (sometimes bloody), abdominal pain and nausea that appear 2-5 days after eating; may last 7-10 days
<i>Clostridium perfringens</i>	diarrhea and gas pains may appear 8-24 hours after eating; usually last about one day, but less severe symptoms may persist for 1-2 weeks
<i>Escherichia coli</i>	diarrhea or bloody diarrhea, abdominal cramps, nausea, and malaise; can begin 2-5 days after food is eaten, lasting about eight days; very young patients can develop hemolytic uremic syndrome and acute kidney failure; thrombotic thrombocytopenic purpura may occur in older adults
<i>Listeria monocytogenes</i>	fever, chills, headache, backache, sometimes abdominal pain and diarrhea; onset from 7-30 days after eating, but most symptoms are reported 48-72 hours after consumption of contaminated food; primarily affects pregnant women and their fetuses, newborns, the elderly, people with oncopathology, and with impaired immune systems; can cause fetal and infant death
<i>Salmonella</i>	stomach pain, diarrhea, nausea, chills, fever and headache usually appear 8-72 hours after eating; may last 1-2 days; all age groups are susceptible, but symptoms are most severe for the elderly, the infirm and infants
<i>Shigella</i>	diarrhea containing blood and mucus, with fever, abdominal cramps, chills and vomiting; 12-50 hours from ingestion of bacteria; can last from a few days to two weeks
<i>Staphylococcus aureus</i>	severe nausea, abdominal cramps, vomiting and diarrhea occur 1-6 hours after eating; recovery within 2-3 days – longer if severe dehydration occurs
<i>Vibrio parahaemolyticus</i>	diarrhea, abdominal cramps, nausea, vomiting, headache, fever, and chills; onset from four hours to four days after eating; lasts about 2.5 days
<i>Cyclospora cayentanensis</i>	nausea, vomiting, loss of appetite, and diarrhea; onset within two days; lasts from one week to two months
<i>Cryptosporidium parvum</i>	profuse watery diarrhea, abdominal pain, appetite loss, vomiting, and low-grade fever; onset within 1-12 days
<i>Giardia lamblia</i>	sudden onset of explosive watery stools, abdominal cramps, anorexia, nausea, and vomiting; onset within 1-3 days
Viral gastroenteritis ( <i>Norwalk and Norwalk-like viruses</i> )	vomiting, diarrhea, abdominal pain, headache, and low-grade fever; onset within 1-2 days; lasts about 36 hours

with prolonged diarrhea. Parasites that cause diarrhea include *Giardia lamblia*, *Entamoeba histolytica*, and *Cryptosporidium*. Signs and symptoms

such as bloody diarrhea, weight loss, diarrhea leading to dehydration, fever, prolonged diarrhea (3 or more unformed stools per day, persisting several days), neurologic involvement (such as paresthesias, motor weakness, cranial nerve palsies), and/or severe abdominal pain may suggest infectious causes and drive the need for laboratory testing, especially in young, elderly, or immunocompromised patients.

**Irritable bowel syndrome (functional)** is the most common cause of functional diarrhea in the developed world. IBS is a symptom complex of crampy abdominal pain accompanied by altered bowel habits, either with diarrhea or constipation. Usually watery diarrhea occurs while awake, often following meals. Discomfort is alleviated by defecation, and stool mucus is noted in one-half of patients. Women are diagnosed twice as often as men. „Alarm” symptoms such as nocturnal diarrhea, progressive pain, weight loss, or blood in the stool suggest another diagnosis. IBS is exacerbated by emotional stress or eating, but it may also be a response to recent infection. IBS symptoms subsequent to a bout of traveler's diarrhea (postinfectious IBS) may take months to resolve, despite a negative workup. Two sets of useful diagnostic criteria exist for IBS:

- Manning criteria

- Onset of pain linked to more frequent bowel movements
- Looser stools associated with onset of pain
- Pain relieved by passage of stool
- Noticeable abdominal bloating
- Sensation of incomplete evacuation more than 25% of the time
- Diarrhea with mucus more than 25% of the time

- Rome IV criteria

Recurrent abdominal pain, on average, at least 1 day per week in the last 3 months, associated with 2 or more of the following:

- Improvement with defecation
- Onset associated with a change in frequency of stool
- Onset associated with a change in the form (appearance) of stool.

Criteria fulfilled for the last 3 months with symptom onset at least 6 months before diagnosis.

Although IBS is usually considered a diagnosis of exclusion, it is unnecessary to perform an exhaustive evaluation in healthy young patients meeting Rome IV criteria if they respond to fiber, exercise, and dietary modification. Screening for celiac disease and iron deficiency anemia is recommended, but routine colonoscopy is not cost-effective unless alarm

symptoms are present. Screening for celiac disease is justifiable because patients with IBS may have four times the incidence of celiac disease compared with the general population. All laboratory test results are normal in patients with IBS.

**Inflammatory bowel disease** is a general term that refers to illnesses that cause chronic inflammation in the intestines, typically causing diarrhea and abdominal cramps. The two major types of inflammatory bowel disease are Crohn's disease and ulcerative colitis. Both often involve blood and pus in the stool, with the onset between 15 and 40 years of age. Early cases are often confused with IBS, but the symptoms inevitably progress.

Early *ulcerative colitis*, distal colitis, and proctitis result in episodes of rectal bleeding, diarrhea, pain, and tenesmus. Moderate (left-sided) and severe (extensive) colitis are associated with bloody diarrhea, weight loss, fever, and anemia.

*Crohn disease* typically causes ileitis but later affects the entire gastrointestinal tract to become exudative. Early symptoms can be subtle, leading to a long delay in diagnosis. Abdominal pain, diarrhea, fever, perianal fistulae, and stools positive for blood are common, although bloody diarrhea is unusual.

The diagnosis of inflammatory bowel disease is usually supported by colonoscopy. Laboratory testing should include a complete blood count, fecal leukocyte level, erythrocyte sedimentation rate, and fecal calprotectin level. An elevated fecal calprotectin level is emerging as a reliable way to make the diagnosis of inflammatory bowel disease as distinguished from IBS, and to monitor its activity once diagnosed. Fecal calprotectin level is a newer stool screen that reflects fecal leukocyte activity; the stool sample can be collected by the patient at home because calprotectin is stable in stool samples for up to seven days at room temperature. In adults, fecal calprotectin level is 93% sensitive and 96% specific for inflammatory bowel disease, although specificity is less (76%) in children and teenagers. Routine screening with fecal calprotectin level could result in a 67% reduction in the use of colonoscopies for inflammatory bowel disease diagnosis in adults, because only those with a positive result would need them.

**Microscopic colitis** is characterized by intermittent, secretory diarrhea in older patients, although persons of all ages can be affected. It should be suspected in older patients with persistent, often nocturnal diarrhea that does not respond to fasting. It is thought to be fairly common, comprising 10% of chronic diarrhea cases. The cause is unknown, but there is some evi-

dence that more than six months of nonsteroidal anti-inflammatory drug use increases the risk. Despite microscopic inflammation, there are no systemic symptoms, and blood and white blood cells are absent from the stool. Colonoscopy is normal, but biopsy from the transverse colon confirms the diagnosis. Two histologic patterns are found: lymphocytic colitis (lymphocytic infiltrate of the lamina propria) and collagenous colitis (in which the subepithelial collagen layer is also increased to more than 10 mm).

**Malabsorptive and maldigestive diarrhea** results from impaired nutrient absorption and impaired digestive function, respectively. Celiac disease (gluten-sensitive enteropathy), intestinal bypass, mesenteric ischemia, small bowel bacterial overgrowth, Whipple disease, and giardiasis can all cause loss of absorptive capacity. Absent pancreatic enzymes or bile acids can cause maldigestion. Classic symptoms include abdominal distention with foul-smelling, large, floating, pale, fatty stools (steatorrhea) and weight loss.

**Celiac disease** or sprue is small intestine malabsorption provoked by gluten (wheat) ingestion in genetically susceptible patients, often of European descent. It is suspected that diagnosed celiac disease cases represent only a fraction of patients with this condition. Although predominantly a malabsorptive condition, celiac disease can also initially present as a watery diarrhea that may be confused with IBS. Patients most commonly present with chronic diarrhea, fatigue, iron deficiency anemia, and weight loss, but this classic constellation is often absent. In the United States, more than 2 million persons have celiac disease, or about one in 133 persons, and this increases to as many as one in 22 persons if a first-degree relative is affected. A high index of suspicion is essential to diagnose celiac disease in most adults. A positive celiac panel, typically consisting of immunoglobulin A (IgA) antigliadin, antiendomysium, and antitissue transglutaminase antibodies, is usually followed by duodenal biopsy for confirmation. IgA antiendomysium and antitissue transglutaminase antibodies have much better accuracy than native gliadin antibodies (IgA antigliadin antibodies). The deamidated gliadin peptide antibody test is a more accurate second-generation IgA antigliadin antibody test but is not yet routinely included in panels. It should be noted that use of gluten-free diets before testing can give false-negative results, as can IgA deficiency or age younger than two years.

Testing should be expanded to include all patients with unexplained chronic diarrhea, IBS, iron deficiency anemia, chronic fatigue, weight loss, infertility, and elevated liver transaminase levels. Symptomatic patients with



type 1 diabetes mellitus and thyroid disease should be tested, because these conditions may predispose to celiac disease. Asymptomatic patients with a family history of celiac disease generally should not be tested, although physicians should remain open to discussing testing.

**Ischemic bowel disease** should be considered in adults with abdominal pain, especially if they are older than 50 years or have a history of peripheral vascular disease. Most patients with acute mesenteric ischemia will present with severe abdominal pain, although there can be a paucity of physical findings. The abdominal pain may be followed by a rapid and forceful bowel movement. Other patients may have chronic mesenteric ischemia with chronic intermittent abdominal pain of up to several months' duration (intestinal angina) followed by an acute attack of pain. These patients may experience weight loss, as well as occasional diarrhea and bloating. Occult fecal blood is present in up to 75% of patients. Bloody diarrhea may occur in those with ischemic colitis (inflammation of the colon caused by insufficient blood flow to the colon); those with small bowel ischemia will have voluminous diarrhea. Individuals at increased risk for ischemic bowel disease include patients with hypovolemia, sepsis, cardiac arrhythmias, congestive heart failure, and those using vasoconstrictive medications or drugs (e.g., digitalis, pseudoephedrine, cocaine, amphetamines). Ischemia may progress to infarct unless detected and treated early.

**Chronic infections (primarily inflammatory).** Most microbial gastrointestinal infections cause acute self-limited diarrhea, but others persist, resulting in inflammation (invasive bacteria and parasites) or occasionally malabsorption (giardiasis). A history of travel and antibiotic use is important. Bacterial causes include *Aeromonas*, *Campylobacter*, *C. difficile*, *Plesiomonas*, and *Yersinia*. Parasitic diarrhea may be caused by *Cryptosporidium*, *Cyclospora*, *Entamoeba*, *Giardia*, *Microsporida*, and *Strongyloides*. *Giardia*, the most common of these, is best diagnosed with fecal antigen testing. Brainerd diarrhea is an epidemic form of long-lasting secretory diarrhea associated with consumption of unpasteurized milk or contaminated water. The suspected infectious agent has never been identified.

*Clostridium difficile*, the cause of pseudomembranous colitis, has emerged as a major infection in U.S. hospitals. This gram-positive anaerobic bacillus is easily spread through ingestion of spores, rapidly colonizing the colon following antibiotic therapy. A history of using fluoroquinolones, clindamycin, penicillins, or cephalosporins in the past three months is often associated. Approximately 3% of healthy adults may be asymptomatic carriers, but this increases to at least 40% in hospitalized patients.

Proton pump inhibitors and inflammatory bowel disease further increase the risk of *C. difficile* infection. Older, sicker patients are more likely to develop clinical disease. As inflammatory bowel disease and *C. difficile* infection produce similar symptoms, it is necessary to exclude the latter in ill patients. A new hypervirulent *C. difficile* strain (NAP1/BI/027) produces a binary toxin in addition to the usual A and B toxins. Outbreaks are characterized by severe watery diarrhea, often complicated by toxic megacolon. *C. difficile* infection is best diagnosed by diarrheic stool cytotoxin assay. Colonoscopy is unnecessary with a positive stool toxin.

**Drug-induced diarrhea.** Although *C. difficile* infection is induced by antibiotics, drugs can directly cause diarrhea. Laxatives, antacids, proton pump inhibitors, and antineoplastic agents are medications that can lead to diarrhea; other examples of drugs associated with diarrhea are listed above. Laxative or antacid abuse is a common cause. Diarrhea may be osmotic (from magnesium, phosphates, sulfates, or sorbitol) or secretory following use of stimulant laxatives. The symptoms resolve when the offending agent is eliminated.

**Radiation enteritis.** Radiation therapy is used to treat a number of urologic, gynecologic, and colorectal cancers. During the radiation treatment period, most patients experience tenesmus, bleeding, and diarrhea. Malabsorption from mucosal damage and bacterial overgrowth are two factors that contribute to these symptoms. The symptoms can start within hours of initial treatment and usually resolve two or three months after treatment cessation, although some patients may develop chronic problems necessitating surgery. The rectum is the most commonly inflamed site given its proximity to the irradiated tissue; the terminal ileum can also be irradiated in patients undergoing treatment for pelvic malignancies.

**Appendicitis.** Patients with appendicitis can have vomiting as well as loose stools. Rectal irritation by an inflamed pelvic appendix can produce small amounts of watery diarrhea, as compared to the voluminous amounts produced as a consequence of gastroenteritis. In Rothrock et al. study of 181 children younger than 13 years who were ultimately found to have appendicitis, 27% were initially misdiagnosed. In this group patients were more likely to be younger, have vomiting before pain, and have diarrhea (in addition to constipation, dysuria, and upper respiratory tract symptoms). A retrospective case series review of 63 children younger than 3 years ultimately diagnosed with appendicitis found that 57% were initially misdiagnosed; diarrhea was commonly reported. A retrospective review of 87

patients with appendicitis revealed that six patients (7%) required more than one emergency department visit before their diagnosis was established. The initial diagnosis in two of these patients was gastroenteritis. These six patients were more likely to have a normal appetite, to have diarrhea, and to be afebrile. While most patients with appendicitis present with right lower quadrant abdominal pain, 15% of appendices are in atypical locations, causing pain in locations other than the right lower quadrant. Gastroenteritis can present with fevers higher ( $> 39,5^{\circ}\text{C}$ ) than those seen with appendicitis and in general, vomiting and diarrhea precede abdominal pain, whereas vomiting follows abdominal pain in appendicitis. As appendicitis will steadily worsen, while uncomplicated gastroenteritis generally resolves with fluids, a period of observation can help identify patients with appendicitis if the diagnosis is unclear.

### **Endocrine and other types of diarrhea (secretory/hypermotility).**

Endocrine causes of chronic secretory diarrhea include Addison disease, carcinoid tumors, vipoma, gastrinoma (Zollinger-Ellison syndrome), and mastocytosis. Hyperthyroidism increases motility. Serum peptide concentrations (e.g., gastrin, calcitonin, vasoactive intestinal peptide) and urinary histamine level should be obtained only when these conditions are suspected. Neoplastic diarrhea is associated with colon carcinoma, villous adenocarcinoma, and lymphoma.

## **BIBLIOGRAPHY**

1. Kosek M., Bern C., Guerrant R.L. The global burden of diarrheal disease, as estimated from studies published between 1992 and 2000. *Bull World Health Organ* 2003; 81 (3): 197–204.
2. Scallan E., Hoekstra R.M., Angulo F.J., et al. Foodborne illness acquired in the United States. *Emerg Infect Dis* 2011; 17 (1): 7–15.
3. Guerrant RL, Van Gilder T, Steiner TS, et al.; Infectious Diseases Society of America. Practice guidelines for the management of infectious diarrhea. *Clin Infect Dis* 2001; 32 (3): 331–351.
4. Fine K.D., Schiller L.R. AGA technical review on the evaluation and management of chronic diarrhea. *Gastroenterology* 1999; 116 (6): 1464–1486.
5. DuPont H.L. Guidelines on acute infectious diarrhea in adults. The Practice Parameters Committee of the American College of Gastroenterology. *Am J Gastroenterol* 1997; 92 (11): 1962–1975.
6. Janakiraman V. Listeriosis in pregnancy: diagnosis, treatment, and prevention. *Rev Obstet Gynecol* 2008; 1 (4): 179–185.
7. Gill C.J., Lau J., Gorbach S.L., Hamer D.H. Diagnostic accuracy of stool

- assays for inflammatory bacterial gastroenteritis in developed and resource-poor countries. *Clin Infect Dis* 2003; 37 (3): 365–375.
8. Ford A.C., Chey W.D., Talley N.J., Malhotra A., Spiegel B.M., Moayyedi P. Yield of diagnostic tests for celiac disease in individuals with symptoms suggestive of irritable bowel syndrome: systematic review and meta-analysis. *Arch Intern Med* 2009; 169 (7): 651–658.
  9. Schoepfer A.M., Beglinger C., Straumann A., et al. Fecal calprotectin correlates more closely with the Simple Endoscopic Score for Crohn's disease (SES-CD) than CRP, blood leukocytes, and the CDAI. *Am J Gastroenterol* 2010; 105 (1): 162–169.
  10. VanRheenen P.F., Van de Vijver E., Fidler V. Faecal calprotectin for screening of patients with suspected inflammatory bowel disease: diagnostic meta-analysis. *BMJ* 2010; 341: c3369.
  11. Abdo A.A., Beck P. Diagnosis and management of microscopic colitis. *Can Fam Physician* 2003; 49: 1473–1478.
  12. Sleisenger M.H., Feldman M., Friedman L.S., Brandt L.J., eds. *Sleisenger & Fordtran's Gastrointestinal and Liver Disease: Pathophysiology, Diagnosis, Management*. 9th ed. Philadelphia, Pa.: Saunders; 2010, 2480 p.
  13. Nelson D.A. Jr. Gluten-sensitive enteropathy (celiac disease): more common than you think. *Am Fam Physician* 2002; 66 (12): 2259–2266
  14. Hookman P., Barkin J.S. *Clostridium difficile* associated infection, diarrhea and colitis. *World J Gastroenterol* 2009; 15 (13): 1554–1580.
  15. Gregory Juckett, Rupal Trivedi. Evaluation of chronic diarrhea. *Am Fam Physician* 2011; 84 (10): 1119–1126.
  16. Wendy Barr, Andrew Smith. Acute diarrhea in adults. *Am Fam Physician* 2014; 89(3): 180–188.
  17. Brian E. Lacy, Fermín Mearin, Lin Chang, William D. Chey, Anthony J. Lembo, Magnús Simren, Robin Spiller. Bowel disorders. *Gastroenterology* 2016; 150: 1393–1407.

# DIFFERENTIAL DIAGNOSIS OF MALABSORPTION

## INTRODUCTION

In Europe and the United States of America the prevalence of malabsorption ranges from 1:250 to 1:133 people. The disorder is very rarely reported in people with African, Caribbean, Chinese or Japanese origin. Malabsorption is far more frequent in women than men, while no age predilection has been reported.

**DEFINITION.** Malabsorption is defined as a gastrointestinal alteration which seriously affects the ability to digest, absorb and transport nutrients across the gastrointestinal wall. These disorders of absorption constitute a broad spectrum of conditions with multiple etiologies and varied clinical manifestations.

According to World Gastroenterology Organization Practice Guideline maldigestion is impaired breakdown of nutrients (carbohydrates, protein, fat) to absorbable split-products (mono-, di-, or oligosaccharides; aminoacids; oligopeptides; fatty acids; monoglycerides) and malabsorption is defective mucosal uptake and transport of adequately digested nutrients including vitamins and trace elements. But digestive and absorptive processes are so inextricably linked, that a third term, malassimilation has been coined in order to reflect this situation. Despite these distinctions, reflecting the underlying pathophysiology, malabsorption is still widely used as the global term for all aspects of impairment of digestion and absorption.

## PATHOPHYSIOLOGY

**Principles of normal absorption.** The normal physiology of nutrient absorption is complex as specific molecular mechanisms have evolved for each of the various types of nutrient. Understanding the principals involved in normal absorption enables different causes of malabsorption to be appreciated, appropriate differential diagnoses to be made, and investigations planned accordingly.

**Absorptive capacity.** The overall efficiency of intestinal absorption varies for each of the classes of nutrients. Some compounds, such as components of dietary fibre, are not absorbed even in healthy persons. Others are normally almost completely absorbed, but in disease, absorption is insufficient to cope with the load, giving symptoms of diarrhea from excess faecal water, or steatorrhea from excess faecal fat.

The principal determinants of the maximum absorptive capacity are the area of the intestinal mucosa, increased by surface folding, villi, and microvilli to about 200 m<sup>2</sup>, and the function of the individual cellular transporting mechanisms. As part of the total absorptive process, the intestine also has to reabsorb endogenous secretions produced to aid digestion. Approximately 7 liters of digestive fluids from salivary, gastric, biliary, pancreatic, and intestinal sources add significantly to the absorptive requirements for water, electrolytes, protein, and fat. Secretory diarrhea and protein-losing enteropathy are conditions where endogenous output exceeds the absorptive capacity of the bowel.

**Sites of absorption.** Gastrointestinal motility mixes food with digestive secretions and propels them from the mouth to the anus. During this passage, nutrients are exposed to specialized areas of the gut with specific digestive or absorptive functions. The duodenum and proximal jejunum are mostly involved with digestion and fluid secretion. The more acidic pH in this area means the solubility and hence the absorption of polyvalent cations such as iron and calcium is high. The bulk of nutrient absorption takes place in the more distal jejunum and ileum. The terminal ileum is specialized for absorption of cobalamin (vitamin B<sub>12</sub>) and bile salt. The colon salvages fluid and electrolytes not absorbed by the small intestine and absorbs short-chain fatty acids produced by colonic bacteria from poorly digested carbohydrates. Loss of specialized areas by surgical resection or disease activity can produce specific patterns of malabsorption.

The intestinal epithelial cells differentiate as they move from the crypt to villus tip. The older villus-tip enterocytes perform most of the absorptive functions, though some digestive enzymes are found in less mature cells. Fluid secretion probably occurs from the crypts. Goblet cells secrete mucus, trapping an unstirred water layer which is a relative barrier to the diffusion of large molecules but allows the smaller products of digestion to reach the surface of the epithelium. Other epithelial cells secrete various hormones or have immunological functions.

**Mechanisms of absorption.** Absorption occurs by transcellular and paracellular pathways. The paracellular pathway is through the tight junctions which link the epithelial cells. In case of this pathway, passive absorption of small molecules occurs by diffusion down electrical and concentration gradients. 'Solvent drag' is the term used to describe movement down concentration gradients, which are themselves created by the movement of water. Active transport takes place through the epithelial cell against these gradients and necessitates the expenditure of energy generated within the cell.

Three steps are involved in transcellular absorption: entry to the cell at the apical (brush border) membrane; passage through the cytoplasm; and exit from the cell at the basolateral membrane. Polarization of the enterocyte produces differences in structure and function of the apical and basolateral membranes. Specific carrier molecules are present in one of these membranes but not the other; this asymmetry generates vectorial flow in a single direction through the cell. The molecular basis for absorption of most types of nutrients has now been defined.

Digestion and absorption occur in four phases:

- Intraluminal hydrolysis of fats, proteins, and carbohydrates by enzymes – bile salts enhance the solubilization of fat in this phase
- Digestion by brush border enzymes and uptake of end-products
- Transepithelial transport
- Lymphatic transport of nutrients

The term malabsorption is commonly used when any of these phases is impaired, but, strictly speaking, the impairment of phase 1 is maldigestion rather than malabsorption.

**Digestion of fats.** Pancreatic enzymes (lipase and colipase) split long-chain triglycerides into fatty acids and monoglycerides, which combine with bile acids and phospholipids to form micelles that pass through jejunal enterocytes. Absorbed fatty acids are resynthesized and combined with protein, cholesterol, and phospholipid to form chylomicrons, which are transported by the lymphatic system. Medium-chain triglycerides are absorbed directly.

Unabsorbed fats trap fat-soluble vitamins (A, D, E, K) and possibly some minerals, causing deficiency. Bacterial overgrowth results in deconjugation and dehydroxylation of bile salts, limiting the absorption of fats. Unabsorbed bile salts stimulate water secretion in the colon, causing diarrhea.

**Digestion of carbohydrates.** The pancreatic enzyme amylase and brush border enzymes on microvilli lyse carbohydrates and disaccharides into constituent monosaccharides. Colonic bacteria ferment unabsorbed carbohydrates into carbon dioxide, methane, hydrogen, and short-chain fatty acids (butyrate, propionate, acetate, and lactate). These fatty acids cause diarrhea. The gases cause abdominal distention and bloating.

**Digestion of proteins.** Gastric pepsin initiates digestion of proteins in the stomach (and also stimulates release of cholecystokinin that is critical to the secretion of pancreatic enzymes). Enterokinase, a brush border enzyme, activates trypsinogen into trypsin, which converts many pancre-



atic proteases into their active forms. Active pancreatic enzymes hydrolyze proteins into oligopeptides, which are absorbed directly or hydrolyzed into amino acids.

## ETIOLOGY AND CLASSIFICATION

Malabsorption has many causes (see Table 11). Some malabsorptive disorders (e.g., celiac disease) impair the absorption of most nutrients, vitamins, and trace minerals (global malabsorption); others (e.g., pernicious anemia) are more selective.

Pancreatic insufficiency causes malabsorption if more than 90% of function is lost. Increased luminal acidity (e.g., Zollinger-Ellison syndrome) inhibits lipase and fat digestion. Cirrhosis and cholestasis reduce hepatic bile synthesis or delivery of bile salts to the duodenum, causing malabsorption.

Acute bacterial, viral, and parasitic infections may cause transient malabsorption, probably as a result of temporary, superficial damage to the villi and microvilli. Chronic bacterial infections of the small bowel are uncommon, apart from blind loops, systemic sclerosis, and diverticula. Intestinal bacteria may use up dietary vitamin B<sub>12</sub> and other nutrients, perhaps interfere with enzyme systems, and cause mucosal injury.

*Factors that may increase the chance of having malabsorption include:*

- Medical conditions affecting the intestine
- Excessive use of antibiotics
- Drugs causing malabsorption:
  - Colchicine – inhibits crypt cell division and lactase
  - Neomycin – precipitation of bile salts in the gut, inhibition of lactase
  - Methotrexate – folic acid antagonist causing inhibition of crypt cell division
  - Cholestyramine – binding bile salts
  - Laxatives
- Intestinal surgery
- Excessive use of alcohol
- Travel to countries with high incidence of intestinal parasites.
- Systemic diseases associated with malabsorption:
  - Addison's disease
  - Thyrotoxicosis
  - Hypothyroidism
  - Diabetes mellitus
  - Collagen vascular disease



Table 11

**Causes of malabsorption**

<b>Mechanisms</b>	<b>Causes</b>
Inadequate gastric mixing, rapid emptying, or both	Gastrocolic fistula Gastroenterostomy Billroth II gastrectomy
Insufficient digestive agents	Biliary obstruction and cholestasis Cirrhosis Chronic pancreatitis Cholestyramine-induced bile acid loss Cystic fibrosis Lactase deficiency Pancreatic cancer Pancreatic resection Sucrase-isomaltase deficiency
Abnormal milieu	Secondary abnormal motility (diabetes, scleroderma, hypothyroidism, or hyperthyroidism) Bacterial overgrowth due to blind loops (deconjugation of bile salts), diverticula in the small intestine Zollinger-Ellison syndrome (low duodenal pH)
Acutely abnormal epithelium	Alcohol Neomycin Acute intestinal infections
Chronically abnormal epithelium	Amyloidosis Celiac disease Crohn disease Ischemia Radiation enteritis Tropical sprue Whipple disease
Short bowel	Intestinal resection Jejunioileal bypass for obesity
Impaired transport	Abetalipoproteinemia Addison disease Blocked lacteals due to lymphoma or tuberculosis Intrinsic factor deficiency (e.g. pernicious anemia) Lymphangiectasia

**Etiological classification:**

- I. Disorders of intraluminal digestion
  - Pancreatic insufficiencies:
  - Cystic fibrosis
    - Chronic pancreatitis
    - Carcinoma of pancreas
  - Bile salt insufficiency:
  - obstructive jaundice
    - bacterial overgrowth
  - Enzyme inactivation (Zollinger-Ellison syndrome)
  - Rapid transit of food through the gut
    - gastroenterostomy
    - partial gastrectomy
  - Increased bile salt loss in faeces
    - terminal ileal disease (Crohn's disease)
    - terminal ileal resection
  - Lack of intrinsic factor (pernicious anaemia)
- II. Disorders of transport in the intestinal mucosal cell
  - Defect in brush border hydrolysis (lactase deficiency)
  - Defect in epithelial transport
    - Coeliac disease
    - Tropical sprue
    - Lymphoma
    - Whipple's disease
- III. Disorders of transport from mucosal cell
  - Lymphatic obstruction
    - abdominal lymphoma
    - tuberculosis
    - lymphangiectasia
  - Defect in epithelial processing (abetalipoproteinaemia)
- IV. Systemic diseases associated with malabsorption
- V. Drug-induced malabsorption

**CLINICAL PRESENTATION**

The effects of unabsorbed substances, especially in global malabsorption, include diarrhea, steatorrhea, abdominal bloating, and gas. Other symptoms result from nutritional deficiencies. The main effects of the presence of unabsorbed substances in the gastrointestinal tract are indicated as follows:

*Diarrhea.* Chronic diarrhea appears as the most common malabsorption symptom and is what usually prompts evaluation of the patient. It is the result of the presence of unabsorbed fluids in the gastrointestinal tract that gives the stools a watery appearance. Diarrhea is worsened by the bacterial action, which produces hydroxyl fatty acids and increases the net fluid secretion.

*Steatorrhea.* The unabsorbed fats are then secreted giving the stools a classical fatty appearance, in a condition known as steatorrhea. It occurs when more than 7 g/day of fat are excreted. Usually, the stools are pale, bulky, greasy, and foul-smelling.

*Abdominal bloating and flatulence.* The unabsorbed food is digested through fermentation by the bacterial flora in the gastrointestinal tract, producing gaseous products such as hydrogen and methane which cause flatulence. This might also result in abdominal distention and cramps.

*Weight loss.* Weight loss is very common, although it can frequently be concealed by food consumption increase.

*Nutritional deficiencies.* The most common are the severe vitamin and mineral deficiencies, which appear especially in advanced cases of malabsorption. The related symptoms depend on the specific nutrient concerned. For example, iron deficiency might cause anemia, deficiency might cause bone disorders, while calcium deficiency might cause hyperparathyroidism. In any case, the patient finds him/herself in a general status of weakness, where bone pain and fractures can also be observed. Other possible symptoms due to nutrient deficiencies include motor weakness (pantothenic acid), peripheral neuropathy (thiamine), a sense of loss (cobalamin), night blindness (vitamin A), seizure (biotin), and bleeding (vitamin K). Electrolyte deficiencies, like hypocalcemia and hypomagnesaemia, which frequently lead to tetany might also be very severe. Anemia also results from vitamin B<sub>12</sub> deficiency, and for this reason, it can be either microcytic (due to iron deficiency) and macrocytic (due to vitamin B<sub>12</sub> deficiency).

## DIAGNOSTIC APPROACH

The steps for diagnosis are as follows:

- Diagnosis typically clinically apparent from a detailed patient history
- Blood tests to screen for consequences of malabsorption
- Stool fat testing to confirm malabsorption (if unclear)
- Cause diagnosed with endoscopy, contrast X-rays, or other tests based on findings

Malabsorption is suspected in a patient with chronic diarrhea, weight loss, and anemia. The etiology is sometimes obvious. For example, patients with malabsorption due to chronic pancreatitis usually have prior bouts of acute pancreatitis. Patients with celiac disease can present with classic lifelong diarrhea exacerbated by gluten products and may have dermatitis herpetiformis. Patients with cirrhosis and pancreatic cancer can present with jaundice. Abdominal distention, excessive flatus, and watery diarrhea occurring 30 to 90 min after carbohydrate ingestion suggest deficiency of a disaccharidase enzyme, usually lactase. Previous extensive abdominal operations suggest short bowel syndrome.

If the history suggests a specific cause, testing should be directed to that condition. If no cause is readily apparent, blood tests can be used as screening tools (e.g., complete blood count, red blood cell indices, ferritin, vitamin B<sub>12</sub>, folate, calcium, albumin, cholesterol, prothrombin time). Test results may suggest a diagnosis and direct further investigation.

Macrocytic anemia should prompt the measurement of serum folate and B<sub>12</sub> vitamin levels. Folate deficiency is common in mucosal disorders involving the proximal small bowel (eg. celiac disease, tropical sprue, Whipple disease). Low B<sub>12</sub> vitamin levels can occur in pernicious anemia, chronic pancreatitis, bacterial overgrowth, and terminal ileal disease. A combination of low B<sub>12</sub> vitamin and high folate levels is suggestive of bacterial overgrowth, because intestinal bacteria use vitamin B<sub>12</sub> and synthesize folate.

Microcytic anemia suggests iron deficiency, which may occur with celiac disease. Albumin is a general indicator of nutritional state. Low albumin can result from poor intake, decreased synthesis in cirrhosis, or protein wasting. Low serum carotene (a precursor of vitamin A) suggests malabsorption if the intake is adequate.

Prior to the development of advanced endoscopic and imaging techniques for abdominal organs (ultrasound, endosonography, X-ray, computed tomography, magnetic resonance imaging, etc.) functional testing for the digestive activities of gastric juice, bile and pancreatic secretion and for the capacity of intestinal absorption of numerous nutrients had a prominent place in the diagnostic approach to malabsorption. This situation has changed and today it is not recommended to apply a multitude of tests in every patient with suspected malabsorptive disorder for practical reasons. Instead the diagnostic approach aims primarily to make a diagnosis of underlying diseases rather than to prove or exclude the "malabsorption syndrome".

The following diagnostic algorithm is based on practical experience and

integrates arbitrarily pathophysiological concepts, modern function tests and morphological investigations.

Table 12

### Diagnostic algorithm of malabsorption

(World Gastroenterology Organization Practice Guideline: Malabsorption, 2006)

Take careful history including drug intake, travelling and special foods, drinks or sweets  
 Consider family history  
 Notice hints for malabsorption from physical examination  
 Look at stool for volume, appearance, admixtures of mucus, blood, parasites  
 Draw blood for screening laboratory examination to find additional hints

→ **If the case warrants further exploration, go on with:**

H<sub>2</sub>-breath tests for carbohydrate malabsorption (lactose, fructose) endomysial-, antigliadin- and/or tissue transglutaminase-antibodies (celiac disease) search for giardia lamblia, enteropathogenic bacteria, parasites and ova.

Abdominal ultrasound (gallbladder; liver; pancreas; intestinal wall aspects; adenopathy; etc.)

Oesophago-Gastro-Duodenoscopy including biopsies from stomach (autoimmunegastritis? H. pylori?) and duodenum (celiac disease?, inflammatory bowel diseases? Especially duodenojejunal involvement is associated with malabsorption)

Ileocolonoscopy including biopsies of colon and ileum (ileal disease? bile salts? , vit. B<sub>12</sub>?)

→ **If pancreatic disease with secretory insufficiency is suspected,**

**Consider:**

- tests for secretory function e.g. elastase or chymotrypsin in stool
- computer tomography; magnetic resonance imaging of pancreatic duct-systems or ERCP

The gold standard still is the secretin-pancreozymin-test; this test is not really necessary for routine examination but may be helpful in individual cases; likewise the quantitative determination of fecal fat excretion is hardly needed any more for clinical judgement of pancreatic diseases. Moreover when in doubt a therapeutic trial with pancreatic enzyme suppletion therapy may be considered.

**If small bowel disease is still within the differential diagnostic scope,**

**Consider:**

- Schilling-test (Vit B<sub>12</sub>)
- Glucose-H<sub>2</sub>-test (bacterial overgrowth)
- Alfa-1-antitrypsin clearance (intestinal protein loss)
- Small bowel X-ray (fistulae, diverticula, blind loops, short bowel, etc.)
- Angiography of celiac and mesenteric arteries (ischemic bowel damage)

**Confirming malabsorption.** Tests to confirm malabsorption are appropriate when symptoms are vague and the etiology is not apparent. Most tests for malabsorption assess fat malabsorption because it is relatively easy to measure. Confirmation of carbohydrate malabsorption is not helpful once steatorrhea is documented. Tests for protein malabsorption are rarely used because fecal nitrogen is difficult to measure.

*Quantitative test.* Direct measurement of fecal fat from a 72 hours stool collection is the gold standard test for the detection of steatorrhea but unnecessary with gross steatorrhea of obvious cause. Stool is collected for a 3 day period during which the patient consumes  $\geq 100$  g fat/day. Total fat in the stool is measured. Fecal fat more than 7 g/day is abnormal. Although severe fat malabsorption (fecal fat  $\geq 40$  g/day) suggests pancreatic insufficiency or small-bowel mucosal disease, this test cannot determine the specific cause of malabsorption. As the test is messy, unpleasant, and time consuming, it is unacceptable to most patients and difficult to do.

*Qualitative tests:*

- *Sudan III staining of a stool smear* is a simple and direct, but non-quantitative, screening test for fecal fat. Detect clinically significant steatorrhea in more than 90% cases.
- *Acid steatocrit* is a gravimetric assay done on a single stool sample; it has a reported high sensitivity and specificity (using 72 hours collection as the standard). Sensitivity – 100%, specificity – 95%, Positive predictive value – 90%.
- *Near-infrared reflectance analysis (NIRA)* simultaneously tests stool for fat, nitrogen, and carbohydrates and may become the preferred test in the future; this test is currently available in only a few centers. It is equally accurate with 72 hours stool fat test.

*Measurement of elastase and chymotrypsin* in the stool can also help differentiate pancreatic and intestinal causes of malabsorption; both are decreased in pancreatic exocrine insufficiency, whereas both are normal in intestinal causes.

*The d-xylose absorption test* can be done if the etiology is not obvious; however, it is currently rarely used because of the advent of advanced endoscopic and imaging tests. Although it can noninvasively assess intestinal mucosal integrity and help differentiate mucosal from pancreatic disease, an abnormal d-xylose test result requires an endoscopic examination with biopsies of the small-bowel mucosa. As a result, small-bowel biopsy has replaced this test to establish intestinal mucosal disease. D-xylose is

absorbed by passive diffusion and does not require pancreatic enzymes for digestion. A normal d-xylose test result in the presence of moderate to severe steatorrhea indicates pancreatic exocrine insufficiency rather than small-bowel mucosal disease. Bacterial overgrowth syndrome can cause abnormal results because the enteric bacteria metabolize pentose, thus decreasing the d-xylose available for absorption. After fasting, the patient is given 25 g of d-xylose in 200 to 300 mL of water per os. Urine is collected over 5 hours, and a venous sample is obtained after 1 hour. Serum d-xylose < 20 mg/dL or < 4 g in the urine sample indicates abnormal absorption. Falsely low levels can also occur in renal diseases, portal hypertension, ascites, or delayed gastric emptying time.

**Diagnosing the cause of malabsorption.** More specific diagnostic tests (eg. upper endoscopy, colonoscopy, barium x-rays) are indicated to diagnose several causes of malabsorption.

*Upper endoscopy with small-bowel biopsy* is done when mucosal disease of the small bowel is suspected or if the d-xylose test result is abnormal in a patient with massive steatorrhea. Endoscopy allows visual assessment of small-bowel mucosa and helps direct biopsies to affected areas. An aspirate from the small bowel can be sent for bacterial culture and colony count to document bacterial overgrowth if there is clinical suspicion. Video capsule endoscopy can now be used to examine areas of the distal small intestine that are beyond the reach of a regular endoscope. Histologic features on small-bowel biopsy can identify the specific mucosal disease (see Table 13).

Table 13

#### Small-bowel mucosal histology in malabsorptive disorders

Disorders	Histologic characteristics
Normal	Finger-like villi with a villous: crypt ratio of about 4:1; columnar epithelial cells with numerous regular microvilli (brush border); mild round cell infiltration in the lamina propria
<b>Diffuse, specific</b>	
Whipple disease	Lamina propria densely infiltrated with periodic acid-Schiff-positive macrophages; villous structure possibly obliterated in severe lesions
Agammaglobulinemia	No plasma cells; either normal or absent villi („fat mucosa”)
Abetalipoproteinemia	Normal villi; epithelial cells vacuolated with fat postprandially

<b>Patchy, specific</b>	
Intestinal lymphoma	Malignant cells in lamina propria and submucosa
Intestinal lymphangiectasia	Dilation and ectasia of the intramucosal lymphatics
Eosinophilic gastroenteritis	Eosinophil infiltration of lamina propria and mucosa
Amyloidosis	Amyloid deposits
Crohn's disease	Noncaseating granulomas
Mastocytosis	Mast cell infiltration of lamina propria
<b>Diffuse, nonspecific</b>	
Celiac disease (untreated)	Virtual absence of villi and elongated crypts; increased intraepithelial lymphocytes and round cells (especially plasma cells) in the lamina propria; cuboidal epithelial cells with scanty, irregular microvilli
Tropical sprue	Range from minimal changes in villous height and moderate epithelial cell damage to virtual absence of villi and elongated crypts with lymphocyte infiltration in the lamina propria
Bacterial overgrowth	Patchy damage to villi; lymphocyte infiltration
Folate deficiency, Vitamin B <sub>12</sub> deficiency, Radiation enteritis	Short villi; decreased mitosis in crypts; megalocytosis
Zollinger-Ellison syndrome	Mucosal ulceration and erosion from acid

*Small-bowel x-rays* (eg, small-bowel follow-through, enteroclysis, computed tomography enterography) can detect anatomic conditions that predispose to bacterial overgrowth. These include jejunal diverticula, fistulas, surgically created blind loops and anastomoses, ulcerations, and strictures. Abdominal flat plate x-rays may show pancreatic calcifications indicative of chronic pancreatitis. Barium contrast studies of the small bowel are neither sensitive nor specific but may show findings suggestive of mucosal disease (e.g., dilated small-bowel loops, thinned or thickened mucosal folds, coarse fragmentation of the barium column). computed tomography, magnetic resonance cholangiopancreatography, and Endoscopic retrograde cholangiopancreatography can make the diagnosis of chronic pancreatitis.

*Tests for pancreatic insufficiency* (e.g., secretin stimulation test, bentiromide test, pancreolauryl test, serum trypsinogen, fecal elastase, fecal chymotrypsin) are done if the history is suggestive but are not sensitive for mild pancreatic disease.

*The <sup>14</sup>C-xylose breath test* helps diagnose bacterial overgrowth. <sup>14</sup>C-xylose



is given orally, and the exhaled  $^{14}\text{CO}_2$  concentration is measured. Catabolism of ingested xylose by the overgrowth of flora causes  $^{14}\text{CO}_2$  to appear in exhaled breath.

*The hydrogen ( $\text{H}_2$ ) breath test* measures the exhaled hydrogen produced by the bacterial degradation of carbohydrates. In patients with disaccharidase deficiencies, enteric bacteria degrade nonabsorbed carbohydrates in the colon, increasing exhaled hydrogen. The lactose-hydrogen breath test is useful only to confirm lactase deficiency and is not used as an initial diagnostic test in the evaluation of malabsorption.

The  $^{14}\text{C}$ -xylose and hydrogen breath tests have replaced bacterial cultures of aspirates taken during endoscopy for the diagnosis of bacterial overgrowth syndrome.

*The Schilling test* assesses malabsorption of vitamin  $\text{B}_{12}$ . Its 4 stages determine whether the deficiency results from pernicious anemia, pancreatic exocrine insufficiency, bacterial overgrowth, or ileal disease.

- Stage 1: The patient is given 1 mcg of radiolabeled cyanocobalamin per os concurrent with 1000 mcg of nonlabeled cobalamin intramuscular to saturate hepatic binding sites. A 24-hours urine collection is analyzed for radioactivity; urinary excretion of less than 8 % of the oral dose indicates malabsorption of cobalamin.
- Stage 2: If stage 1 is abnormal, the test is repeated with the addition of intrinsic factor. Pernicious anemia is present if intrinsic factor normalizes absorption.
- Stage 3: Stage 3 is done after adding pancreatic enzymes; normalization in this stage indicates cobalamin malabsorption secondary to pancreatic insufficiency.
- Stage 4: Stage 4 is done after antimicrobial therapy with anaerobic coverage; normalization after antibiotics suggests bacterial overgrowth.

Cobalamin deficiency secondary to ileal disease or ileal resection results in abnormalities in all stages.

*Tests for less common causes of malabsorption* include serum gastrin (Zollinger-Ellison syndrome), intrinsic factor and parietal cell antibodies (pernicious anemia), sweat chloride (cystic fibrosis), lipoprotein electrophoresis (abetalipoproteinemia), and serum cortisol (Addison disease).

To diagnose bile acid malabsorption, which may occur with diseases of the terminal ileum (eg., Crohn disease, extensive resection of terminal ileum), patients can be given a therapeutic trial of a bile acid binding resin

(eg., cholestyramine). Alternatively, the selenium homocholic acid taurine (SeHCAT) test can be done. In this test,  $^{75}\text{Se}$ -labeled synthetic bile acid is given orally and, after 7 days, the retained bile acid is measured with a whole-body scan or gamma camera. If bile acid absorption is abnormal, retention is less than 5%.

## DIFFERENTIAL DIAGNOSIS

### Major causes:

**Cystic fibrosis (CF)** is an inherited disease of the exocrine glands affecting primarily the gastrointestinal and respiratory systems. It leads to chronic lung disease, exocrine pancreatic insufficiency, hepatobiliary disease, and abnormally high sweat electrolytes. Cystic fibrosis is the most common life-threatening genetic disease in the white population. In the United States, it occurs in about 1:3,300 white births, 1:15,300 black births, and 1:32,000 Asian American births.

CF is carried as an autosomal recessive trait by about 3% of the white population. The responsible gene has been localized on the long arm of chromosome 7. It encodes a membrane-associated protein called the cystic fibrosis transmembrane conductance regulator (CFTR). CFTR is an adenosine 3',5'-monophosphate (cAMP) regulated chloride channel, regulating chloride and sodium transport across epithelial membranes. A number of additional functions are considered likely. The disease manifests only in homozygotes. Heterozygotes may show subtle abnormalities of epithelial electrolyte transport but are clinically unaffected.

Nearly all exocrine glands are affected in varying distribution and degree of severity. The glands may:

- become obstructed by viscid or solid eosinophilic material in the lumen (pancreas, intestinal glands, intrahepatic bile ducts, gallbladder, and submaxillary glands);
- appear histologically abnormal and produce excessive secretions (tracheobronchial and Brunner glands);
- appear histologically normal but secrete excessive sodium and chloride (sweat, parotid, and small salivary glands).

On the gastrointestinal level:

- Pancreas – the absence of CFTR limits function of chloride-bicarbonate exchanger to secrete bicarbonate that leads to retention of enzymes in the pancreas, destruction of pancreatic tissue.
- Intestine – the decrease in water secretion leads to thickened mucus

and desiccated intraluminal contents; obstruction of small and large intestines.

- Biliary tree – the retention of biliary secretion; focal biliary cirrhosis; bile duct proliferation; chronic cholecystitis, cholelithiasis.

*Gastrointestinal manifestations of cystic fibrosis*

*Meconium ileus* due to obstruction of the ileum by viscid meconium may be the earliest sign and is present in 13 to 18% of CF-affected neonates. It typically manifests with abdominal distention, vomiting, and failure to pass meconium. Some infants have intestinal perforation, with signs of peritonitis and shock. Infants with this syndrome have a delayed passage of meconium. They can have similar signs of obstruction or very mild and transient symptoms that go unnoticed. Older patients may have episodes of constipation or develop recurrent and sometimes chronic episodes of partial or complete small- or large-bowel obstruction (distal intestinal obstruction syndrome). The symptoms include crampy abdominal pain, change in stooling pattern, decreased appetite, and sometimes vomiting.

In infants without meconium ileus, the disease onset may be heralded by a delay in *regaining birth weight* and inadequate weight gain at 4 to 6 weeks of age.

Occasionally, infants who are undernourished, especially if on hypoallergenic formula or soy formula, present with generalized edema secondary to *protein malabsorption*.

*Pancreatic insufficiency* is usually clinically apparent early in life and may be progressive. Manifestations include the frequent passage of bulky, foul-smelling, oily stools; abdominal protuberance; and poor growth pattern with decreased subcutaneous tissue and muscle mass despite a normal or voracious appetite. The clinical manifestations may occur secondary to the deficiency of fat-soluble vitamins.

*Rectal prolapse* occurs in 20% of untreated infants and toddlers. Gastroesophageal reflux is relatively common among children and adults.

*Diagnosis:*

- Universal newborn screening when feasible
- May also be suggested by a positive prenatal screening test result, family history, or symptomatic presentation
- Confirmed by the sweat test showing elevated sweat chloride on  $\geq 2$  occasions
- Identifying 2 CF-causing mutations (1 on each chromosome) is consistent with the diagnosis

- May rarely be confirmed, in atypical cases, by demonstrating abnormal ion transport across the nasal epithelium.

Universal newborn screening for CF is now standard in the US; > 90% of cases are first identified by newborn screening, but up to 10% are not diagnosed until adolescence or early adulthood. Despite advances in genetic testing, the sweat chloride test remains the standard for confirming CF diagnosis in most cases because of its sensitivity and specificity, simplicity, and availability.

**Bacterial overgrowth syndrome.** Small-bowel bacterial overgrowth can result from alterations in intestinal anatomy or gastrointestinal motility, or lack of gastric acid secretion.

Under normal conditions, the proximal small bowel contains  $< 10^5$  bacteria/mL, mainly gram-positive aerobic bacteria. This low bacterial count is maintained by normal peristalsis, normal gastric acid secretion, mucus, secretory IgA, and an intact ileocecal valve.

Anatomic alterations of the stomach and/or small intestine promote stasis of intestinal contents, leading to bacterial overgrowth. Conditions that cause or require anatomic alterations include small-bowel diverticulosis, surgical blind loops, postgastrectomy states (especially in the afferent loop of a Billroth II), strictures, or partial obstruction. Intestinal motility disorders associated with diabetic neuropathy, systemic sclerosis, amyloidosis, hypothyroidism, and idiopathic intestinal pseudo-obstruction can also impair bacterial clearance. Achlorhydria and idiopathic changes in intestinal motility may cause bacterial overgrowth in elderly people.

The excess bacteria consume nutrients, including carbohydrates and vitamin B<sub>12</sub>, leading to caloric deprivation and vitamin B<sub>12</sub> deficiency. However, because the bacteria produce folate, this deficiency is rare. The bacteria deconjugate bile salts, causing failure of micelle formation and subsequent fat malabsorption. Severe bacterial overgrowth also damages the intestinal mucosa. Fat malabsorption and mucosal damage can cause diarrhea.

*Symptoms and signs.* Many patients are asymptomatic and present with only weight loss or nutrient deficiencies. The most frequent symptoms are abdominal discomfort, diarrhea, bloating, and excess flatulence. Some patients have significant diarrhea or steatorrhea.

*Diagnosis:*

- <sup>14</sup>C-xylose breath test or quantitative culture of intestinal aspirate
- Sometimes upper gastrointestinal series with small-bowel follow-through

Some clinicians advocate response to empiric antibiotic therapy as a diagnostic test. However, because bacterial overgrowth can mimic other malabsorptive disorders (e.g., Crohn disease) and adverse effects of the antibiotics can worsen symptoms, establishing a definitive etiology is preferred.

The standard for the diagnosis of bacterial overgrowth syndrome is quantitative culture of intestinal fluid aspirate showing a bacterial count  $>10^5$ /mL. This method requires endoscopy. Breath tests, using substrates like glucose, lactulose, and xylose, are noninvasive and easy to do. The  $^{14}\text{C}$ -xylose breath test seems to perform better than the other breath tests.

If the anatomic alterations are not due to previous surgery, an upper gastrointestinal series with small-bowel follow-through should be done to identify predisposing anatomic lesions.

**Carbohydrate intolerance.** Carbohydrate intolerance is the inability to digest certain carbohydrates due to a lack of one or more intestinal enzymes.

Disaccharides are normally split into monosaccharides by disaccharidases (e.g., lactase, maltase, isomaltase, sucrase) located in the brush border of small-bowel enterocytes. Undigested disaccharides cause an osmotic load that attracts water and electrolytes into the bowel, causing watery diarrhea. Bacterial fermentation of carbohydrates in the colon produces gases (hydrogen, carbon dioxide, and methane), resulting in excessive flatus, bloating and distention, and abdominal pain.

Enzyme deficiencies can be:

- Congenital (e.g., rare deficiencies of lactase or sucrase-isomaltase)
- Acquired (primary)
- Secondary

Acquired lactase deficiency (primary adult hypolactasia) is the most common form of carbohydrate intolerance. Lactase levels are high in neonates, permitting digestion of milk; in most ethnic groups (80% of blacks and Hispanics,  $> 90\%$  of Asians), the levels decrease in the post-weaning period rendering older children and adults unable to digest significant amounts of lactose. However, 80 to 85% of whites of Northwest European descent produce lactase throughout life and are thus able to digest milk and milk products. It is unclear why the normal state of more than 75% of the world's population should be labeled a „deficiency.”

Secondary lactase deficiency occurs in conditions that damage the small-bowel mucosa (e.g., celiac disease, tropical sprue, acute intestinal infections). In infants, temporary secondary disaccharidase deficiency may

complicate enteric infections or abdominal surgery. Recovery from the underlying disease is followed by an increase in activity of the enzyme.

*Symptoms and signs* of carbohydrate intolerance are similar in all disaccharidase deficiencies. A child who cannot tolerate lactose develops diarrhea after ingesting significant amounts of milk and may not gain weight. An affected adult may have watery diarrhea, bloating, excessive flatus, nausea, borborygmi, and abdominal cramps after ingesting lactose. The patient often recognizes early in life that dairy causes gastrointestinal problems and avoids eating dairy products. Symptoms typically require ingestion of more than the equivalent of 250 to 375 mL (8 to 12 oz) of milk. Diarrhea may be severe enough to purge other nutrients before they can be absorbed. Symptoms may be similar to and can be confused with irritable bowel syndrome. Most people with lactase deficiency can tolerate up to 250 to 375 mL of milk; symptoms that occur after consuming much smaller amounts of milk may suggest another diagnosis.

#### *Diagnosis*

- Clinical diagnosis
- Hydrogen breath test for confirmation

Lactose intolerance can usually be diagnosed with a careful history supported by dietary challenge. Patients usually have a history of diarrhea and/or gas after ingestion of milk and dairy foods; other symptoms, such as rash, wheezing, or other anaphylactic symptoms (particularly in infants and children), suggest a cow's milk allergy. Milk allergy is rare in adults and also may cause vomiting and symptoms of esophageal reflux, which are not manifestations of carbohydrate intolerance. The diagnosis is also suggested if the stool from chronic or intermittent diarrhea is acidic ( $\text{pH} < 6$ ) and can be confirmed by an  $\text{H}_2$  breath test or a lactose tolerance test.

In the hydrogen breath test, 50 g of lactose is given orally and the hydrogen produced by bacterial metabolism of undigested lactose is measured with a breath meter at 2, 3, and 4 h postingestion. Most affected patients have an increase in expired hydrogen of  $> 20$  ppm over baseline. Sensitivity and specificity are  $> 95\%$ .

The lactose tolerance test is less sensitive, about 75%, although specificity is  $> 95\%$ . Oral lactose (1.0 to 1.5 g/kg body weight) is given. Serum glucose is measured before ingestion and 60 and 120 min after. Lactose-intolerant patients develop diarrhea, abdominal bloating, and discomfort within 20 to 30 min, and their serum glucose levels do not rise to  $> 20$  mg/dL ( $< 1.1$  mmol/L) above the baseline.

**Celiac disease** is an immunologically mediated disease in genetically susceptible people caused by intolerance to gluten, resulting in mucosal inflammation and villous atrophy, which causes malabsorption. Celiac disease is a hereditary disorder caused by sensitivity to the gliadin fraction of gluten, a protein found in wheat; similar proteins are present in rye and barley. In a genetically susceptible person, gluten-sensitive T cells are activated when gluten-derived peptide epitopes are presented. The inflammatory response causes characteristic mucosal villous atrophy in the small bowel.

Celiac disease mainly affects people of northern European descent. Prevalence estimates based on serologic screens among blood donors (sometimes confirmed by biopsy) indicate the disorder may be present in about 1:150 in Europe, especially in Ireland and Italy, and perhaps 1:250 in some parts of the US. Current prevalence estimates in some regions are as high as 1:100. The disease affects about 10 to 20% of 1st-degree relatives. Female:male ratio is 2:1. Onset is generally in childhood but may occur later.

Patients who have other immune diseases and certain genetic disorders are at risk of developing celiac disease.

Risk factors for celiac disease:

- Lymphocytic colitis,
- Down syndrome,
- Turner syndrome,
- Type 1 diabetes mellitus,
- Autoimmune thyroiditis (Hashimoto thyroiditis),
- Rheumatoid arthritis,
- Addison's disease,
- Sjogren's disease,
- Lupus,
- Lactose intolerance,
- Intestinal lymphoma.

*The clinical presentation* varies; no typical presentation exists. Some patients are asymptomatic or have only signs of nutritional deficiency. Others have significant gastrointestinal symptoms.

Celiac disease can manifest in infancy and childhood after introduction of cereals into the diet. The child has failure to thrive, apathy, anorexia, pallor, generalized hypotonia, abdominal distention, and muscle wasting. Stools are soft, bulky, clay-colored, and offensive. Older children may present with anemia or failure to grow normally.

In adults, lassitude, weakness, and anorexia are most common. Mild



and intermittent diarrhea is sometimes the presenting symptom. Steatorrhea ranges from mild to severe (7 to 50 g of fat/day). Some patients have weight loss, rarely enough to become underweight. Anemia, glossitis, angular stomatitis, and aphthous ulcers are usually seen in these patients. Manifestations of vitamin D and calcium deficiencies (eg., osteomalacia, osteopenia, osteoporosis) are common. Both men and women may have reduced fertility; women may not have menstrual periods.

About 10% of patients have dermatitis herpetiformis, an intensely pruritic papulovesicular rash that is symmetrically distributed over the extensor areas of the elbows, knees, buttocks, shoulders, and scalp. This rash can be induced by a high-gluten diet.

*Diagnosis:*

- Serologic markers
- Small-bowel biopsy
- Genetic testing

The diagnosis of celiac disease is suspected clinically and by laboratory abnormalities suggestive of malabsorption. Family incidence is a valuable clue. Celiac disease should be strongly considered in a patient with iron deficiency without obvious gastrointestinal bleeding.

Confirmation requires a small-bowel biopsy from the second portion of the duodenum. Findings include lack or shortening of villi (villous atrophy), increased intraepithelial cells, and crypt hyperplasia. Such findings can also occur in tropical sprue, severe intestinal bacterial overgrowth, eosinophilic enteritis, infectious enteritis (e.g., giardiasis), and lymphoma.

As biopsy lacks specificity, serologic markers can aid the diagnosis. Anti-tissue transglutaminase antibody (tTG) and anti-endomysial antibody have sensitivity and specificity more than 90%:

- IgA and IgG antigliadin antibodies
- IgA endomysial antibodies
- IgA and IgG tissue transglutaminase antibodies
- Anti-reticulin antibodies (no longer used)

These markers can also be used to screen populations with high prevalence of celiac disease, including 1st-degree relatives of affected patients and patients with diseases that occur at a greater frequency in association with celiac disease. If either test is positive, the patient should have a diagnostic small-bowel biopsy. If both are negative, celiac disease is extremely unlikely. These antibodies decrease in titer in patients on a gluten-free diet and thus are useful in monitoring dietary adherence. All diagnostic serologic testing should be done with patients following a gluten-containing diet.



HLA-DQ2 and -DQ8 testing has been useful for exclusion of celiac disease in patients with either equivocal small-bowel histological finding or those following a gluten-free diet and for exclusion of genetic risk for celiac disease development among close relatives.

Other laboratory abnormalities often occur and should be sought. They include anemia (iron-deficiency anemia in children and folate-deficiency anemia in adults); low albumin, calcium, potassium, and sodium; and elevated alkaline phosphatase and prothrombine time.

Malabsorption tests are not specific for celiac disease. Common findings include steatorrhea of 10 to 40 g/day, abnormal results with d-xylose and (in severe ileal disease) positive Schilling tests.

Complications of celiac disease include refractory disease, collagenous sprue, and intestinal lymphomas. Intestinal lymphomas affect 6 to 8% of patients with celiac disease, usually manifesting after 20 to 40 years of disease. The incidence of other gastrointestinal cancers (eg, squamous-cell carcinoma of the esophagus or oropharynx, small-bowel adenocarcinoma, non-Hodgkin's lymphoma) also increases. Adherence to a gluten-free diet can significantly reduce the risk of cancer. If people who have been doing well on a gluten-free diet for a long time once again develop symptoms of celiac disease, physicians usually do upper endoscopy with small bowel biopsy to check for signs of intestinal lymphoma.

Small-bowel biopsy should be repeated after 3 to 4 months of a gluten-free diet. If abnormalities persist, other causes of villous atrophy (eg, lymphoma) should be considered. Lessening of symptoms and improvement in small-bowel morphology are accompanied by a decrease in anti-tissue transglutaminase antibody and anti-endomysial antibody titers.

If a patient responds poorly to gluten withdrawal, either the diagnosis is incorrect or the disease has become refractory. Corticosteroids can control symptoms in refractory disease.

**Intestinal lymphangiectasia** is a rare disorder characterized by obstruction or malformation of the intramucosal lymphatics of the small bowel. Malformation of the lymphatic system is congenital or acquired. Congenital cases usually manifest in children (typically diagnosed before age 3 years) and less frequently in adolescents or young adults. Males and females are equally affected. In acquired cases, the defect may be secondary to retroperitoneal fibrosis, constrictive pericarditis, pancreatitis, neoplastic tumors, and infiltrative disorders that block the lymphatics.

Impaired lymphatic drainage leads to increased pressure and leakage

of lymph into the intestinal lumen. The impairment of chylomicron and lipoprotein absorption results in malabsorption of fats and protein. As carbohydrates are not absorbed through the lymphatic system, their uptake is not impaired.

Early *manifestations* of intestinal lymphangiectasia include massive and often asymmetric peripheral edema, intermittent diarrhea, nausea, vomiting, and abdominal pain. Some patients have mild to moderate steatorrhea. Chylous pleural effusions (chylothorax) and chylous ascites may be present. Growth is retarded if the onset is in the first decade of life.

*Diagnosis:*

- Endoscopic small-bowel biopsy
- Sometimes contrast lymphangiography

The diagnosis of intestinal lymphangiectasia usually requires endoscopic small-bowel biopsy, which shows marked dilation and ectasia of the mucosal and submucosal lymphatic vessels. Alternatively, contrast lymphangiography (injection of contrast material via the pedal lymphatics) can show abnormal intestinal lymphatics.

Laboratory abnormalities include lymphocytopenia and low levels of serum albumin, cholesterol, IgA, IgM, IgG, transferrin, and ceruloplasmin. Barium studies may show thickened, nodular mucosal folds that resemble stacked coins. D-xylose absorption is normal. Intestinal protein loss can be shown by using chromium-51-labeled albumin.

**Short bowel syndrome** is a malabsorption resulting from extensive resection of the small bowel (usually more than two-thirds of the length of the small intestine).

Common reasons for extensive resection are Crohn disease, mesenteric infarction, radiation enteritis, cancer, volvulus, and congenital anomalies.

As the jejunum is the primary digestive and absorptive site for most nutrients, jejunal resection leads to loss of absorptive area and significantly reduces nutrient absorption. In response, the ileum adapts by increasing the length and absorptive function of its villi, resulting in gradual improvement of nutrient absorption.

The ileum is the site of vitamin B<sub>12</sub> and bile acid absorption. Severe diarrhea and bile acid malabsorption result when > 100 cm of the ileum is resected. Notably, there is no compensatory adaptation of the remaining jejunum (unlike that of the ileum in jejunal resection). Consequently, malabsorption of fat, fat-soluble vitamins and vitamin B<sub>12</sub> occurs. In addition, unabsorbed bile acids in the colon result in secretory diarrhea. Preservation

of the colon can significantly reduce water and electrolyte losses. Resection of the terminal ileum and ileocecal valve can predispose to bacterial overgrowth.

**Tropical sprue** is a rare acquired disease, probably of infectious etiology, characterized by malabsorption and megaloblastic anemia.

Tropical sprue occurs chiefly in the Caribbean, southern India, and Southeast Asia, affecting both natives and visitors. The illness is rare in visitors spending < 1 month in areas where the disease is endemic. Although etiology is unclear, it is thought to result from chronic infection of the small bowel by toxigenic strains of coliform bacteria. Malabsorption of folate and vitamin B<sub>12</sub> deficiency result in megaloblastic anemia. Tropical sprue has rarely been reported in the US, and the incidence worldwide has been decreasing in recent decades, perhaps because of increasing use of antibiotics for acute traveler's diarrhea.

Patients commonly have acute diarrhea with fever and malaise. A chronic phase of milder diarrhea, nausea, anorexia, abdominal cramps, and fatigue follows. Steatorrhea is common. Nutritional deficiencies, especially of folate and vitamin B<sub>12</sub>, eventually develop after several months to years. The patient may also have weight loss, glossitis, stomatitis, and peripheral edema.

*Diagnosis:*

- Endoscopy with small-bowel biopsy
- Blood tests to screen for consequences of malabsorption

Tropical sprue is suspected in people who live in or have visited areas where the disease is endemic and who have megaloblastic anemia and symptoms of malabsorption. The definitive test is upper GI endoscopy with small-bowel biopsy. Characteristic histologic changes usually involve the entire small bowel and include blunting of the villi with infiltration of chronic inflammatory cells in the epithelium and lamina propria. Celiac disease and parasitic infection must be ruled out. Unlike in celiac disease, anti-tissue transglutaminase antibody (tTG) and anti-endomysial antibody (EMA) are negative in patients with tropical sprue.

Additional laboratory studies (e.g., Complete blood count; albumin; calcium; prothrombine time; iron, folate, and B<sub>12</sub> levels) help evaluate nutritional status. Barium small-bowel follow-through may show segmentation of the barium, dilation of the lumen, and thickening of the mucosal folds. D-Xylose absorption is abnormal in > 90% of cases.

**Whipple disease** is a rare systemic illness caused by the bacterium *Tro-*

*pheryma whipplei*. Whipple disease predominately affects white men aged 30 to 60. Although it affects many parts of the body (e.g., heart, lung, brain, serous cavities, joints, eye, gastrointestinal tract), the mucosa of the small bowel is almost always involved. Affected patients may have subtle defects of cell-mediated immunity that predispose to infection with *T. whipplei*. About 30 % of patients have HLA-B27.

*Clinical presentation* varies depending on the organ systems affected. The four cardinal symptoms of Whipple disease are: arthralgia, diarrhea, abdominal pain and weight loss. Usually, the first symptoms are arthritis and fever. Intestinal symptoms (e.g., watery diarrhea, steatorrhea, abdominal pain, anorexia, weight loss) usually manifest later, sometimes years after the initial complaint. Gross or occult intestinal bleeding may occur. Severe malabsorption may be present in patients diagnosed late in the clinical course. Other findings include increased skin pigmentation, anemia, lymphadenopathy, chronic cough, serositis, peripheral edema, and central nervous system symptoms.

*The diagnosis* is confirmed by endoscopy with small-bowel biopsy. The diagnosis of Whipple disease may be missed in patients without prominent gastrointestinal symptoms. Whipple disease should be suspected in middle-aged white men who have arthritis and abdominal pain, diarrhea, weight loss, or other symptoms of malabsorption. Such patients should have upper endoscopy with small-bowel biopsy; the intestinal lesions are specific and diagnostic. The most severe and consistent changes are in the proximal small bowel. Light microscopy shows periodic acid-Schiff-positive macrophages that distort the villus architecture. Gram-positive, acid fast-negative bacilli (*T. whipplei*) are seen in the lamina propria and in macrophages. If *T. whipplei* are not seen but Whipple disease is still clinically suspected, PCR testing and immunohistochemistry should be done.

Whipple disease should be differentiated from intestinal infection with *Mycobacterium avium-intracellulare* (MAI), which has similar histologic findings. To confirm the response to treatment, Polymerase Chain Reaction testing can be done on stool, saliva, or other tissue. Relapses are common and may occur years later. If relapse is suspected, small-bowel biopsies or Polymerase chain reaction testing should be done (regardless of affected organ systems) to determine the presence of free bacilli.

**BIBLIOGRAPHY**

1. Holt P.R. Diarrhea and malabsorption in the elderly. *Gastroenterol Clin North Am* 2001; 30 (2): 427-444.
2. Potter G.D. Bile acid diarrhea. *DigDis*. 1998; 16 (2): 118-124.
3. Savvidou S., Goulis J., Gantzaru A., Ilonidis G. Pneumobilia, chronic diarrhea, vitamin K malabsorption: a pathognomonic triad for cholecystocolonic fistulas. *World J Gastroenterol*. 2009; 15 (32): 4077-4082.
4. Schiller L.R. Diarrhea and malabsorption in the elderly. *Gastroenterol Clin North Am*. 2009; 38 (3): 481-502.
5. Juckett G., Trivedi R. Evaluation of chronic diarrhea. *Am Fam Physician*. 2011; 84 (10): 1119-1126.
6. Bhat D.S., Thuse N.V., Lubree H.G., et al. Increases in plasma holotranscobalamin can be used to assess vitamin B-12 absorption in individuals with low plasma vitamin B-12. *J Nutr*. 2009; 139 (11): 2119-2123.
7. Sleisenger and Fordtran's *Gastrointestinal and Liver Disease*, 9th ed, Feldman M., Friedman L., Brandt L. (Eds), Saunders, Philadelphia, PA 2010, 2480 p.
8. Choi Y.K., Johlin F.C. Jr, Summers R.W., et al. Fructose intolerance: an under-recognized problem. *Am J Gastroenterol* 2003; 98 (6): 1348-1353.
9. Rubio-Tapia A., Barton S.H., Rosenblatt J.E., Murray J.A. Prevalence of small intestine bacterial overgrowth diagnosed by quantitative culture of intestinal aspirate in celiac disease. *J Clin Gastroenterol* 2009; 43 (2): 157-161.
10. Walters J.R., Tasleem A.M., Omer O.S., et al. A new mechanism for bile acid diarrhea: defective feedback inhibition of bile acid biosynthesis. *Clin Gastroenterol Hepatol* 2009; 7 (11): 1189-1194.
11. Habba S.F. Chronic diarrhea: identifying a new syndrome. *Am J Gastroenterol* 2000; 95 (8): 2140-2141.
12. Leeds J.S., Oppong K., Sanders D.S. The role of fecal elastase-1 in detecting exocrine pancreatic disease. *Nat Rev Gastroenterol Hepatol* 2011; 8 (7): 405-415.
13. World Gastroenterology Organization (WGO-OMGE) Practice Guideline: Malabsorption, 2006, 8 p. [www.omge.org](http://www.omge.org) (accessed 10.06.2017)
14. American Gastroenterological Association medical position statement: guidelines for the evaluation and management of chronic diarrhea. *Gastroenterology* 1999; 116 (6): 1461-1436.
15. Tischendorf J.J., Wopp K., Streetz K.L., et al. The value of duodenal biopsy within routine upper endoscopy: a prospective study in 1000 patients. *Z Gastroenterol* 2008; 46 (8): 771-775.
16. Atenodoro R. Ruiz. Overview of malabsorption. <https://www.msmanuals.com/professional/gastrointestinal-disorders/malabsorption-syndromes/overview-of-malabsorption> (accessed 10.06.2017)
17. Charles K. Mansbach. Diseases producing malabsorption and maldigestion. <http://hungacp.blogspot.com/2011/08/0411-diseases-producing-malabsorption.html> (accessed 10.06.2017).

## DIFFERENTIAL DIAGNOSIS OF DYSPHAGIA

**DEFINITION.** Dysphagia is defined as a sensation of „sticking” or obstruction of the passage of food through the mouth, pharynx, or esophagus.

**PATHOPHYSIOLOGY.** Swallowing begins with a voluntary (oral) phase that includes preparation during which food is masticated and mixed with saliva. This is followed by a transfer phase during which the bolus is pushed into the pharynx by the tongue. The bolus entry into the hypopharynx initiates the pharyngeal swallow response, which is centrally mediated and involves a complex series of actions, the net result of which is to propel food through the pharynx into the esophagus while preventing its entry into the airway. To accomplish this, the larynx is elevated and pulled forward, actions that also facilitate upper esophageal sphincter (UES) opening. Tongue pulsion then propels the bolus through the UES, followed by a peristaltic contraction that clears residue from the pharynx and through the esophagus. The lower esophageal sphincter relaxes as the food enters the esophagus and remains relaxed until the peristaltic contraction has delivered the bolus into the stomach. Peristaltic contractions elicited in response to a swallow are called primary peristalsis and involve sequenced inhibition followed by contraction of the musculature along the entire length of the esophagus. The inhibition that precedes the peristaltic contraction is called deglutitive inhibition. Local distention of the esophagus anywhere along its length activates secondary peristalsis that begins at the point of distention and proceeds distally. Tertiary esophageal contractions are nonperistaltic, disordered esophageal contractions that may be observed to occur spontaneously during fluoroscopic observation.

Dysphagia can be secondary to defects in any of the 3 phases of swallowing, which are as follows: oral phase (involves the oral preparatory phase and the oral transit phase), pharyngeal phase, and esophageal phase. The oropharyngeal swallow response consists of the temporal arrangement of oropharyngeal structures from a respiratory to a digestive pathway, the transfer of the bolus from the mouth to the esophagus, and the recuperation of the respiratory configuration. Sensory input by physicochemical properties of the bolus is required during bolus preparation and trigger and modulate the swallow response. Taste, pressure, temperature, nociceptive, and general somatic stimuli from the oropharynx and larynx are

transported through cranial nerves V, VII, IX and X to the central pattern generator, within the nucleus tractus solitarius, where they are integrated and organized with information from the cortex. Swallowing has a multiregional and asymmetrical cerebral representation in the caudal sensorimotor and lateral premotor cortex, insula, temporopolar cortex, amygdala, and cerebellum. Once activated, the central pattern generator triggers a swallow motor response involving motor neurons in the brainstem and axons traveling through the cervical spinal cord ( $C_1$ - $C_2$ ) and cranial nerves (V, VII, IX, to XII).

A lesion in the cerebral cortex or the brainstem can cause swallowing disorders as a result of the following: decrease in range of motion of muscles of mastication and bolus propulsion, especially those responsible for buccal, labial, and lingual strength and the cricopharyngeal muscle; decreased sensation; delayed or absent pharyngeal swallowing and reductions in pharyngeal peristalsis; delayed or absent laryngeal adduction and elevation.

Pocketing of food in the mouth, circumoral leakage, and early pharyngeal spill can occur with weakness and poor coordination of the lips, cheeks, and tongue. Weak posterior tongue can lead to abnormal tongue thrusting. Aspiration of food or drink, especially during inhalation, can occur before pharyngeal swallowing due to premature pharyngeal spillage. Changes in mental status with cognitive deficits also may affect the initiation of swallowing, increasing the tendency to pocket food in the lateral sulci and leading to possible aspiration. If pharyngeal clearance is severely impaired, a patient may be unable to ingest sufficient amounts of food and drink to sustain life. In people without dysphasia, small amounts of food commonly are retained in the valleculae or pyriform sinus after swallowing. If there is weakness in or a lack of coordination of the pharyngeal muscles or if there is a poor opening of the upper esophageal sphincter, patients may retain excessive amounts of food in the pharynx and experience overflow aspiration after swallowing.

**CASSIFICATION OF DYSPHAGIA (according to location and associated conditions):**

1. *Oropharyngeal dysphagia* appears within swallowing and is associated with nasal regurgitation, hypersalivation, cough after swallowing, recurrent pneumonias, difficulties with liquids, loss of weight.

2. *Esophageal dysphagia* appears after swallowing and is associated with heartburn, retrosternal pain, cough, dyspnea, recurrent pneumonias, hypersalivation, vomiting, bleeding and loss of weight.



**CLASSIFICATION OF DYSPHAGIA (according to etiology)****1. Mechanical narrowing**

## 1.1. Intrinsic narrowing

- A. *Inflammatory condition causing edema and swelling* (stomatitis, pharyngitis, epiglottitis and esophagitis)
- Viral (Herpes simplex, Varicella-zoster, Cytomegalovirus)
  - Bacterial
  - Fungal (candidal)
  - Mucocutaneous bullous diseases
  - Caustic, chemical, radiation, thermal injury (GERD, radiation esophagitis)
  - Allergic (eosinophylic esophagitis)
- B. *Webs and rings*
- Pharyngeal (Plummer-Vinson syndrome)
  - Esophageal (congenital, inflammatory)
  - Lower esophageal mucosal ring (Schatzki ring)
- C. *Benign strictures*
- Peptic
  - Caustic and pill-induced
  - Inflammatory (Crohn's disease, candidal, mucocutaneous lesions)
  - Ischemic
  - Postoperative, postirradiation
  - Congenital
- D. *Malignant tumors* (squamous cell carcinoma, adenocarcinoma, sarcoma, lymphoma, melanoma, Kaposi's sarcoma, metastatic carcinoma)
- E. *Benign tumors* (leiomyoma, lipoma, angioma, inflammatory fibroid polyp, epithelial papilloma)

1.2. Extrinsic compression (cervical spondylitis, vertebral osteophytes, retropharyngeal abscess and masses, enlarged thyroid gland, Zenker's diverticulum, aberrant right subclavian artery, right-sided aorta, left atrial enlargement, aortic aneurysm, posterior mediastinal masses, pancreatic tumor, pancreatitis, postvagotomy hematoma and fibrosis)

**2. Motor dysphagia**

## 2.1. Difficulty in initiating swallowing reflex

- Paralysis of the tongue
- Oropharyngeal anesthesia
- Lack of saliva (e.g., Sjogren's syndrome)
- Lesions of sensory components of vagus and glossopharyngeal nerves



- e) Lesions of swallowing center (tumour, trauma, CNS infection)
- 2.2. Disorders of pharyngeal and esophageal *striated* muscle
  - 2.2.1. Lower motor neuron lesion (bulbar paralysis)
    - a) Cerebrovascular accident
    - b) Poliomyelitis, postpoliomyelitis syndrome
    - c) Polyneuritis
    - d) Amyotrophic lateral sclerosis
  - 2.2.2. Neuromuscular autoimmune disorders (Myasthenia gravis, multiple sclerosis)
  - 2.2.3. Muscle disorders (polymyositis, dermatomyositis, inflammatory myopathies)
  - 2.2.4. Nonperistaltic contractions or impaired deglutitive inhibition
- A. Pharynx and upper esophagus
  - a) Rabies
  - b) Tetanus
  - c) Parkinson disease
  - d) Upper motor neuron lesions (pseudobulbar paralysis)
  - e) Other neurodegenerative disorders (severe Alzheimer's disease, Huntington disease, Prion diseases)
- B. Upper esophageal sphincter (UES)
  - a) Paralysis of suprahyoid muscles
  - b) Cricopharyngeal achalasia
- 2.3. Disorders of esophageal *smooth* muscle:
  - a) Scleroderma and related collagen vascular diseases
  - b) Hollow visceral myopathy
  - c) Metabolic neuromyopathy (amyloid, alcohol, diabetes, Cushing syndrome, hyperthyroidism, hypothyroidism, B<sub>12</sub>-deficiency anemia)
  - d) Diffuse esophageal spasm
  - e) Achalasia: primary and secondary (Chagas' disease, infection with *Trypanosoma cruzi*, carcinoma, lymphoma, toxins and drugs)
  - f) Lower esophageal muscular (contractile) ring
- 3. Dysphagia as a side drug effect (cholinolitics, H<sub>1</sub>-antihistaminics, spasmolytics, tetracyclines, antidepressants etc.)
- 4. Congenital causes (choanal atresia, cleft lip and palate, unilateral vocal cord paralysis, laryngeal cleft, tracheoesophageal fistula, esophageal atresia, vascular rings).
- 5. Dysphagia due to medical procedures (endotracheal intubation, tra-

cheostomy, laryngectomy pharyngectomy, esophagectomy reconstructed by gastric pull-up, head and neck surgery, surgery involving the pharyngeal plexus during cervical fusion or carotid endarterectomy)

6. Psychogenic dysphagia (anxiety, depression, hypochondriasis, conversion disorders, eating disorders).

## DIAGNOSTIC APPROACH

In *oropharyngeal dysphagia* patients have difficulty in initiating a swallow, and they usually identify the cervical area as the area presenting a problem. In neurological patients, oropharyngeal dysphagia is a comorbid condition associated with adverse health outcomes including dehydration, malnutrition, pneumonia, increased anxiety and fear, malnutrition, depression and isolation. Frequent accompanying symptoms include: difficulty initiating a swallow, repetitive swallowing, nasal regurgitation, coughing, recurrent pneumonia, nasal speech, drooling, diminished cough reflex, choking, dysarthria and diplopia (in neurologic diseases) and halitosis (in patients with a large, residue-containing Zenker diverticulum or in patients with advanced achalasia or long-term obstruction, with luminal accumulation of decomposing residue).

*Esophageal dysphagia*, also called „low” dysphagia, refers to a probable location in the distal esophagus. Dysphagia that occurs equally with solids and liquids often involves an esophageal motility problem. This suspicion is reinforced when intermittent dysphagia for solids and liquids is associated with chest pain. Dysphagia that occurs only with solids but never with liquids suggests the possibility of mechanical obstruction, with luminal stenosis to a diameter of < 15 mm. If the dysphagia is progressive, peptic stricture or carcinoma should be considered in particular. It is also important to mention that patients with peptic strictures usually have a long history of heartburn and regurgitation, but no weight loss. Conversely, patients with esophageal cancer tend to be older men with marked weight loss. In case of intermittent dysphagia with food impaction, especially in young men, eosinophilic esophagitis should be suspected (see Figure 2).

The clinical history is the cornerstone of evaluation and should be considered first. A major concern with esophageal dysphagia is to exclude malignancy. Malignancy is likely if there is a short duration (less than 4 months), disease progression, dysphagia more for solids than for liquids and weight loss. Achalasia is more likely if: there is dysphagia for both solids and liquids, dysphagia for liquids strongly suggests the diagnosis;

there is passive nocturnal regurgitation of mucus or food; there is a problem that has existed for several months or years; the patient takes additional measures to promote the passage of food, such as drinking or changing body position. Eosinophilic esophagitis is more likely if there is intermittent dysphagia associated with occasional food impaction.

**Physical examination.** Examination of the patient may play a strong role in determining the cause of dysphagia. This is particularly true in patients with a suspected neuromuscular cause of difficulty swallowing. A simple examination of cranial nerves should be performed, which can easily be accomplished in a brief time. More generalized involvement of these disorders should be sought, such as proximal or asymmetric extremity weakness, dysarthria, fasciculations, tremor, and cognitive dysfunction. Precise diagnosis is possible when there is a definite neurological condition accompanying the oropharyngeal dysphagia, such as:

- Hemiparesis following an earlier cerebrovascular accident
- Ptosis of the eyelids and fatigability, suggesting myasthenia gravis
- Stiffness, tremors, and dysautonomia, suggesting Parkinson disease

An oral examination is also necessary. Clues to the cause of dysphagia might include poor dentition, buccal lesions such as lichen planus, tongue fasciculations, asymmetric palate elevation, and labial droop. A neck examination may be helpful if a mass or adenopathy is detected, such as a Virchow's node associated with esophageal cancer. Some patients with scleroderma and secondary peptic strictures may also present with CREST syndrome (calcinosis, Raynaud phenomenon, esophageal involvement, sclerodactyly, and telangiectasia).

**Bedside testing by water swallow test** is a useful basic screening test alongside the evidence obtained from the clinical history and physical examination. It involves the patient drinking 150 mL of water from a glass as quickly as possible, with the examiner recording the time taken and number of swallows. The speed of swallowing and the average volume per swallow can be calculated from these data and it may be complemented by a „food test” using a small amount of pudding placed on the dorsum of the tongue. Patients commonly underestimate their degree of difficulty, but it may be revealed by observations such as multiple swallows required for a single bolus, the use of small sips of fluid or small bites of a solid, post-deglutitive throat clearing, and a general fear of swallowing.

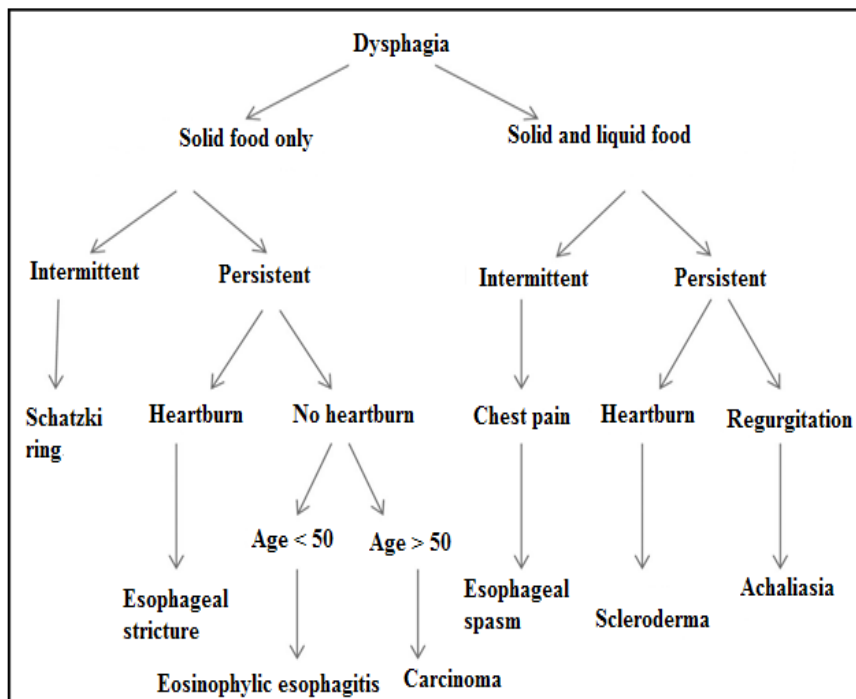


Figure 2. Diagnostic algorithm of dysphagia according to symptoms

(according to Abdel Jalil A.A., Katzka D.A., Castell D.O. Approach to the patient with dysphagia. The American Journal of Medicine 2015; 128: 1138.e17-1138.e23)

### *Instrumental investigations*

**X-ray of the esophagus with barium swallow** reveals pharyngeal paralysis, cricopharyngeal achalasia, diffuse esophageal spasm, esophageal achalasia, esophageal rings, scleroderma esophagus, typical annular narrowing with overhanging margins and destruction of the mucosa in malign tumors and a smooth filling defect and right angles of origin from the esophageal wall in benign tumors and peptic strictures.

**Video fluoroscopy**, also known as the „modified barium swallow” is the gold standard for evaluating oropharyngeal dysphagia. Swallowing is recorded on video during fluoroscopy, providing details of the patient’s swallowing mechanics and helps predict the risk of aspiration pneumonia

**Nasoendoscopy** is the gold standard for evaluating structural causes of dysphagia and inspection of pooled secretions or food material. This is not a sensitive means of detecting abnormal swallowing function. It fails to

identify aspiration in 20–40% of cases when followed up with video fluoroscopy, due to the absence of cough reflex.

**Fiberoptic endoscopic evaluation of swallowing** is a modified endoscopic approach that involves visualizing the laryngeal and pharyngeal structures through a transnasal flexible fiberoptic endoscope while food and liquid boluses are given to the patient.

**Esophagogastroscopy** allows direct visualization of esophageal mucosa and obtaining biopsy in case of a tumor.

**Endoscopic ultrasound** is used for a stage-dependent treatment:

1. To differentiate mucosal from submucosal invasion in early (stage T1) esophageal cancer in which setting local therapy (laser, or minimally invasive surgery) may be considered.

2. To stratify patients who have local lymph node metastases (N1) for preoperative chemotherapy and radiation therapy.

3. To diagnose reliably stage T4 esophageal cancer in which tumor infiltrates into adjacent organs and structures, such as the aorta, heart, lung, and spine. Removal of these tumors is not curative and poses significant surgical risks.

4. To obtain reliable diagnosis of celiac axis lymph nodes that are staged as M1, thus precluding patients from curative surgery or preoperative chemoradiation.

**Esophageal pH measurement** is the gold standard for gastroesophageal reflux disease and has the following indications: assessment of suspected or established gastroesophageal reflux disease; in a patient with atypical symptoms, e.g. asthma, non-cardiac chest pain; poorly controlled reflux disease and prior to antireflux procedure. *Measurements*: percentage of time pH < 4, number of reflux episodes, number of episodes longer than 5 minutes, duration of the longest reflux episode, correlation between symptoms and reflux episodes.

**Esophageal manometry** is the gold standard for dysmotility disorders) and has the following indications: to determine the position of lower esophageal sphincter in 24h pH monitoring; prior to antireflux procedure and assessment of motility disorder giving rise to dysphagia or non-cardiac chest pain. *Measurements*: upper and lower sphincter and body basal pressure, peak pressure, duration, frequency and pattern of contraction. Esophageal manometry in achalasia of the cardia shows lack of peristalsis and a non-relaxing lower oesophageal sphincter. Esophageal manometry in diffuse esophageal spasm shows synchronous multipeaked high pressure waves.

**High-resolution impedance manometry** is a modern adaptation of traditional esophageal manometry but with greater accuracy and visualization based on 32 pressure transducers measurements that span the esophagus more accurately than the simple esophageal manometry. As a result, a clear panesophageal pressure tracing can be generated and then described through a colorimetric graphic presentation. This gives a clearer reading on peristaltic and sphincter function. Impedance measurement has also been added to this technique such that catheter based electrodes measure the conductivity of a substance based on the characteristics and speed of the bolus. A swallow of a liquid-based bolus will conduct electricity better and therefore generate a low impedance signal concordant with esophageal peristalsis. As the direction of flow is measured easily, reflux of content from the stomach into the esophagus may be easily seen as well. Ideally, this combination of manometry and impedance measurement is suited for assessing esophageal motility disorders.

**Tc <sup>99m</sup> scintigraphy** shows hyperaccumulation of Tc <sup>99m</sup> in case of dysmotility disorders of the esophagus.

## DIFFERENTIAL DIAGNOSIS

**Gastroesophageal reflux disease (GERD).** Chronic symptoms of the disease are produced by the abnormal reflux of gastric contents into the esophagus. Patients who have endoscopically documented mucosal damage are said to have reflux esophagitis. Patients who have typical symptoms of GERD due to reflux of acid into the esophagus but do not have any mucosal damage are said to have nonerosive reflux disease. Clinical features include heartburn and acid regurgitation more frequent after meals and in the supine position, water brash (excessive salivation in response to acid reflux), dysphagia, odynophagia, belching (caused by reflux of air), chest pain, cough (due to reflux of acid into the respiratory tract), wheezing (due to acid irritation of the bronchi leading to bronchospasm) and hoarseness (due to acid injuring of the vocal cords).

Endoscopy is not considered a primary diagnostic tool due to its low sensitivity and should be considered in select cases: long-standing symptoms (more than 5–10 years), failure of empiric proton pump inhibitor therapy, presence of alarm signs for complications (odynophagia, dysphagia, hematemesis, melena, and weight loss). A 24-to-48 hours of pH monitoring with event marking (heartburn, meals, and body position) is a useful test to document acid exposure and to correlate it with symptoms. Impedance

testing is a new diagnostic tool that allows for the detection of gas and fluid reflux through the esophagus independent of acid measurement. It can be helpful in those who have classic symptoms with negative endoscopy and pH monitoring.

**Barrett esophagus**, usually caused by chronic GERD, results in replacement of the squamous epithelium at the distal esophagus by columnar intestinal epithelium and is associated with an increased risk of developing esophageal adenocarcinoma.

**Eosinophilic esophagitis** manifests typically in adults with years of dysphagia, sometimes punctuated by food impactions. Its pathophysiology is based on a T-helper 2-mediated food allergy of the esophagus, which leads to chronic eosinophilic infiltration, inflammation, and fibrogenesis. *Ex juvantibus* criterion is the improvement of patient's condition after elimination of causative foods or medical control of the allergic response by using topical or systemic steroids.

**Webs and rings.** Esophageal webs are typically thin, eccentric mucosal projections into the esophageal lumen. They usually arise from the anterior wall of the proximal esophagus. Esophageal webs may be idiopathic, congenital, or related to inflammatory processes. They are often asymptomatic, but patients may present with dysphagia. An esophagogram classically reveals an anterior shelf-like filling defect. The association of postcricoid dysphagia, upper esophageal webs, and iron deficiency anemia is known as Plummer-Vinson syndrome in the United States and Paterson-Brown Kelly syndrome in the United Kingdom. Plummer-Vinson syndrome is associated with a 15% chance of oropharyngeal or esophageal squamous cell cancer.

A lower esophageal ring (Schatzki ring) is a mucosal membrane at the junction of esophageal and gastric mucosa. An important symptom is intermittent dysphagia with solid food or a sudden obstruction from a food bolus („steak house syndrome”). Barium swallow X-ray shows a thin annulus at the junction of the esophagogastric mucosa.

**Esophageal strictures** can be classified as simple or complex, based on their diameter and associated anatomic abnormalities. A simple stricture is defined as a short stricture with a symmetric or concentric lumen and a diameter of  $\geq 12$ mm that can be traversed easily with an endoscope. A complex stricture is usually longer than 2 cm, may be angulated or irregular, and has a diameter of  $< 12$ mm. It may be associated with a large hiatal hernia, esophageal diverticula, or tracheoesophageal fistula. Complex strictures



have a higher rate of recurrence and an increased risk for dilation-related adverse events, compared with simple strictures. The severity of a stricture can be estimated by the resistance encountered with the passage of the diagnostic endoscope, which has a typical external diameter of 9mm. A mild stricture allows passage of the endoscope without resistance; a moderate stricture offers increased resistance, whereas a severe stricture may not be traversable. The diameter of a stricture can be objectively measured on barium radiography or by determining the maximal sized barium tablet that can pass through the lumen.

**Esophageal cancer.** Dysphagia is the most common symptom. Other symptoms include anorexia, weight loss, fatigue, cough, sore throat, heartburn, hoarseness, and odynophagia. The gold standard to make the diagnosis is endoscopy with biopsy of a suspicious lesion. CT of the chest and abdomen is useful to stage the disease. Endoscopic ultrasound helps to evaluate the depth of the lesion and the involvement of regional lymph nodes. Positron emission tomography scanning is applied for cancer staging and bronchoscopy is needed, if tumor is at or above the carina, to help exclude invasion of the trachea or bronchi.

**Achalasia** is an idiopathic reduction or absence of nitric oxide-producing inhibitory neurons in the esophageal muscles, leading to heightened tone of the lower esophageal sphincter and failure of esophageal body peristalsis. The clinical features include dysphagia with solids, and more than in half of patients experience dysphagia with liquids. Regurgitation, possible aspiration pneumonia, chest pain, weight loss are due to the gradual dilatation of the esophagus and food retention in the esophageal lumen. Barium swallow X-ray usually reveals a dilated esophagus with air fluid levels. The lower end of the esophagus tapers down acutely giving the appearance of a bird's beak. Manometric studies of the esophagus measuring pressure in different areas of the esophageal body and the lower esophageal sphincter during swallowing reveal the typical findings necessary for diagnosis (absence of complete relaxation of lower esophageal sphincter and absence of peristalsis). Endoscopy is a valuable tool to investigate the presence of pseudoachalasia, which is a tumor at the gastroesophageal junction that causes partial obstruction and mimics the clinical, radiographic, and manometric picture of achalasia.

**Diffuse esophageal spasm** is a disease developing due to an imbalance between excitatory and inhibitory motor neurons. It can present as dysphagia and/or chest pain. Barium esophagogram reveals an irregular eso-



phageal border in a classical appearance known as „corkscrew” esophagus. Definitive diagnosis is obtained by manometric studies which reveal simultaneous pressure waves suggesting simultaneous contractions.

**Myasthenia gravis** is due to the production of antibodies against acetylcholine receptors in muscles. The symptoms include weakness increasing with physical activity, muscular weakness in limbs, respiratory muscles, diplopia, dysphagia, ptosis, dysarthria. Chest CT demonstrates the presence of thymoma. Serological tests may reveal the presence of antibodies against acetylcholine receptors. Electromyography shows the decrease of muscle response on repetitive stimulation. The edrophonium test is useful for the diagnosis: administration of short-acting anticholinesterase improves weakness.

**Diverticulum.** Zenker diverticulum is an „out-pouching” of mucosa above the cricopharyngeal muscle at a point of relative weakness in the posterior muscle wall of the hypopharynx. Small diverticulae of this type tend to cause dysphagia, whereas larger diverticulae cause regurgitation of food, occasionally complicated by aspiration. Gurgling in the throat on swallowing and halitosis may be present.

A Killian-Jamieson diverticulum occurs in the upper cervical esophagus and protrudes from the anterolateral aspect of the esophagus through an area inferior to the cricopharyngeus muscle. It may cause dysphagia, cough, or aspiration. In contrast to pulsion diverticulae (e. g., Zenker), traction diverticulae develop because of pulling from adjacent inflammatory changes and are found in the mid to lower esophagus and rarely cause symptoms. Traction diverticulae are most commonly observed in patients with esophageal dysmotility, increased contraction pressure, and a thickened esophageal muscle wall. Both forms of diverticulae are recognized by characteristic appearance on radiological investigation.

**Scleroderma** esophagopathy is due to the partial replacement of the esophageal smooth muscle (lower two thirds) by collagenous tissue and is a part of CREST syndrome (calcinosis, Raynaud syndrome, esophagopathy, sclerodactylia, teleangiectasia). This leads to a decrease or absence of peristalsis in the affected area and a significant decrease in the lower esophageal sphincter resting tone. Patients complain of dysphagia and acid reflux symptoms and complications. The diagnosis is identified through manometric studies. Endoscopy is indicated to investigate and treat complications of acid reflux. Tc <sup>99m</sup> scintigraphy shows hyperaccumulation of Tc <sup>99m</sup> in the lower third of esophagus.

**Parkinson's disease (PD)** is an idiopathic progressive neurodegenerative disease characterized by tremor, muscular rigidity, and bradykinesia. The prevalence of oropharyngeal dysphagia is at least in a third of individuals with PD, and people with PD are three times more likely to have swallowing disorders than healthy controls. Cognitive impairment is a complication as the disease progresses and aspiration pneumonia is considered a leading cause of death. Positron emission tomography (PET) and single-photon emission CT may show findings consistent with Parkinson disease (an approximately 30% decrease in  $^{18}$ Fluorodopa uptake on PET imaging in the contralateral putamen), and olfactory testing can reveal hyposmia, which may precede the motor signs of Parkinson disease by several years. A substantial and sustained response to dopamine agonists helps confirm the diagnosis of Parkinson disease.

**Amyotrophic lateral sclerosis** is the most common form of motor neuron disease with both upper and lower motor neuron involvement. Oropharyngeal dysphagia is characterized by weakness, and fatigue of oropharyngeal and laryngeal muscles with aspiration. Drooling is common due to difficulty in swallowing saliva. Respiratory involvement results in a weakened cough reflex with an inability to prevent laryngeal penetration and aspiration. Aspiration is a term referring to the passive entry of any food item into the trachea (e.g., during inhalation). Penetration refers to the active entry of any food item into the trachea (e.g., during swallowing), although the term often is used to denote the entry of any bolus into the laryngeal vestibule.

**Huntington's disease** is an inherited neurodegenerative disease characterized by motor, behavioral and cognitive disturbances. Oropharyngeal dysphagia in this population suggests that there is an incoordination of swallowing and choreic tongue movements with delay in initiation of the pharyngeal swallow. Difficulty with self-feeding due to choreic movements and the existence of cognitive impairment as the disease progresses exacerbates oropharyngeal dysphagia. Aspiration pneumonia is reported to be a leading cause of death.

**Prion diseases** are a group of neurodegenerative disorders that includes sheep scrapie, bovine spongiform encephalopathy and Creutzfeldt-Jakob disease (CJD). Oropharyngeal dysphagia in CJD is characterized by an accumulation of abnormal prion-like proteins in the central nervous system affecting the cerebral cortex primarily and confirmed usually at autopsy. Oropharyngeal dysphagia can be one of the initial signs of the dis-

ease in association with a bulbar or pseudobulbar palsy with rapid progression. Cognitive impairment can be a significant factor also in the disease. The clinical presentations of oropharyngeal dysphagia vary: progressive dysphagia characterized by poor bolus control, delay in initiation of the pharyngeal swallow and residue in the vallecula and pyriform sinus post swallow. The common feature of all cases described is the rapid evolution of oropharyngeal dysphagia as the disease progresses with imminent death.

**Multiple sclerosis** is an immune-mediated inflammatory disease that attacks myelinated axons in the central nervous system, destroying the myelin and the axon in variable degrees. The clinical presentation includes sensory loss (paresthesias), dysphagia, muscle cramping secondary to spasticity, bladder, bowel, and sexual dysfunction, Charcot triad of dysarthria (scanning speech), nystagmus, intention tremor, optic neuritis, trigeminal neuralgia, facial myokymia (irregular twitching of the facial muscles), diplopia on lateral gaze, heat intolerance, cognitive difficulties with regard to attention span, concentration, memory, and judgment, and depression. Multiple sclerosis is diagnosed on the basis of clinical findings and ancillary tests: magnetic resonance imaging to confirm and monitor disease progression in the CNS; evoked potentials to identify subclinical lesions; lumbar puncture to evaluate cerebrospinal fluid for oligoclonal bands and intrathecal IgG production.

## BIBLIOGRAPHY

1. Dodds WJ. Physiology of swallowing. *Dysphagia* 1989; 3(4): 171-8.
2. Kawaguchi S., Takeuchi T., Inoue Y., et al. Exploratory Research on Latent Esophageal Motility Disorders in Dysphagia Patients. *Digestion* 2017; 95 (4): 269-74.
3. Palmer J.B., Drennan J.C., Baba M. Evaluation and treatment of swallowing impairments. *Am Fam Physician* 2000; 61(8): 2453-62.
4. Spieker M.R. Evaluating dysphagia. *Am Fam Physician* 2000; 61 (12): 3639-48.
5. Roden D.F., Altman K.W. Causes of dysphagia among different age groups: a systematic review of the literature. *Otolaryngol Clin North Am* 2013; 46: 965-987.
6. Clavé P., Terré R., De Kraa M., Serra M. Approaching oropharyngeal dysphagia. *Rev Esp Enferm Dig* 2004; 96: 119-131.
7. Rofes L., Arreola V., Almirall J., Cabre M., Campins L., Garcia-Peris P., Speyer R., Clave P. Diagnosis and Management of Oropharyngeal Dysphagia and Its Nutritional and Respiratory Complications in the Elderly.

Gastroenterology Research and Practice, volume 2011, article ID 818979. doi:10.1155/2011/818979. <http://www.hindawi.com> (accessed 20.05.2018)

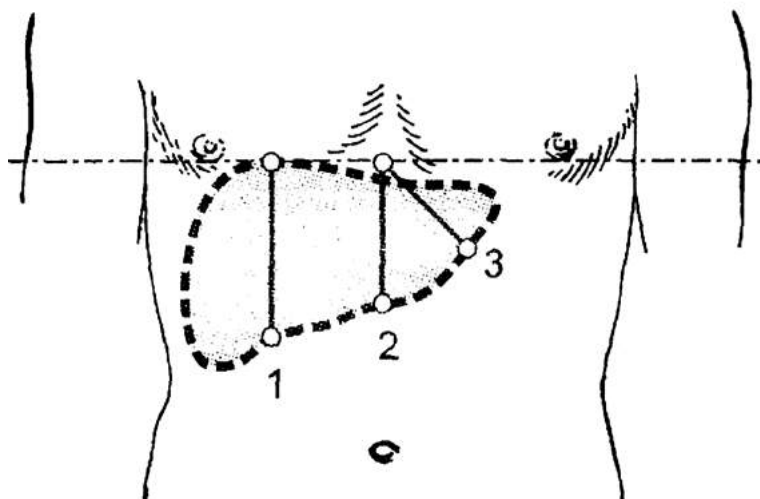
8. Roy N., Stemple J., Merrill R. M., Thomas L. Dysphagia in the elderly: preliminary evidence of prevalence, risk factors, and socioemotional effects. *Ann Otol Rhinol Laryngol* 2007; 116: 858–865.
9. Martino R. Dysphagia after stroke: incidence, diagnosis, and pulmonary complications. *Stroke* 2005; 36: 2756–2763.
10. Marik P. E., Kaplan D. Aspiration pneumonia and dysphagia in the elderly. *Chest* 2003; 124: 328–336.
11. Dusick A. Investigation and management of dysphagia. *Semin Pediatr Neurol* 2003; 10: 255–264.
12. Abdel Jalil A.A., Katzka D.A., Castell D.O. Approach to the patient with dysphagia. *The American Journal of Medicine* 2015; 128: 1138.e17-1138.e23.
13. Pasha S.F., Acosta R.D., Chandrasekhara V., et al. The role of endoscopy in the evaluation and management of dysphagia. *Gastrointestinal Endoscopy* 2014; 79 (2): 191-201.

## DIFFERENTIAL DIAGNOSIS OF HEPATOMEGALY

**DEFINITION.** Hepatomegaly, or enlargement of the liver, usually refers to a liver span of larger than 12 cm at the right midclavicular line or a palpable left lobe in the epigastrium. Liver size on physical exam is only an approximation and should be accurately measured with an abdominal ultrasound, CT scan, or MRI. Abnormalities such as a low-lying liver (e.g., lung emphysema) or other abdominal masses must be considered.

**PATHOPHYSIOLOGY.** The mechanism of hepatomegaly consists of vascular swelling, inflammation (due to infectious or non-infectious causes) and deposition of non-hepatic cells or increased cell contents (e.g., iron in hemochromatosis, fat in steatosis).

In liver examination percussion precedes palpation and allows to determine 3 liver sizes (*Figure 3*).



*Figure 3.* Liver percussion sizes

(size 1 =  $9\text{ cm} \pm 3\text{ cm}$ , size 2 =  $8\text{ cm} \pm 3\text{ cm}$ , size 3 =  $7\text{ cm} \pm 3\text{ cm}$ )

During liver palpation the following features should be assessed:

- Tenderness;
- Margin of the liver;
- Consistency of the liver;
- Surface of the liver.

The soft margins of the liver with moderately dense consistency, rounded and smooth surface of the liver are observed in acute and chronic hepatitis, heart failure, hepatosis, and liver echinococcosis. The sharp margins, dense consistency, rough and microtubercular surface of the liver determine liver cirrhosis, amyloidosis of liver. Very dense consistency (stone-like) and rough, macrotubercular surface indicate liver cancer.

Hepatomegaly is a clinical sign which is usually associated with other signs and symptoms.

*Hepatomegaly with jaundice* suggests hemolytic anemias, toxic or infectious hepatitis, bile duct obstruction due to stones, carcinoma of the pancreas, or ampulla of Vater, biliary cirrhosis.

*Hepatomegaly with fever* suggests viral hepatitis, infectious mononucleosis, ascending cholangitis (sepsis), liver abscess and other infectious diseases.

*Hepatomegaly and splenomegaly* suggest alcoholic cirrhosis, sepsis, amyloidosis, various hemolytic anemias, biliary cirrhosis, myeloid metaplasia.

*Hepatomegaly and massive splenomegaly* are possible in Gaucher's disease and myeloid metaplasia.

*Hepatomegaly and the presence of another abdominal mass* suggest metastatic carcinoma.

*Tenderness of the liver* during palpation suggests viral hepatitis, toxic hepatitis, congestive heart failure, ascending cholangitis.

*Hepatomegaly* associated with shortness of breath, pitting edema and jugular veins distension suggests congestive heart failure.

*Hepatomegaly*, chronic cough, wheezing, jugular vein distention and pitting edema suggest Cor pulmonale.

*Tender hepatomegaly plus fever plus jaundice* suggest viral hepatitis or cholangitis.

*Hepatomegaly* plus splenomegaly plus ascites, caput medusae, spider angiomas, hemorrhoids, testicular atrophy suggest liver cirrhosis.

*Non-tender hepatomegaly* in a patient of middle age with obesity, diabetes mellitus, hyperlipidemia suggests non-alcoholic steatohepatitis.

*Hepatomegaly, bronzed skin color*, diabetes, infertility, arthritis, cardiomegaly, increased serum iron suggest hemochromatosis.

*Hepatomegaly, progressive liver failure*, neurologic signs of lenticular degeneration, Kayser-Fleischer rings in cornea, increased serum copper, decreased serum ceruloplasmin suggest Wilson's disease.

*Hepatomegaly, anemia*, gross or occult blood in the stool suggest metastases in liver (most commonly colon cancer).

*Hepatomegaly, cough, dyspnea, hilar lymphadenopathy, lung, skin, eye involvement in women aged 30–40 suggest sarcoidosis.*

### **Paraclinical investigations**

Initial workup:

- A. General blood analysis (anemia, leukopenia, thrombocytopenia suggesting hypersplenism; leukocytosis suggests infection; severe anemia and elevated ESR suggest neoplasm)
- B. Urinalysis (search for biliary pigments),
- C. Liver function tests (ALAT, ASAT, GGTP, albumin) and coagulation tests (PT [Prothrombin Time], PTT [Partial Thromboplastin Time], INR [International normalized ratio])
- D. Viral hepatitis profile
- E. Chest x-ray (assessment of concomitant lung, heart disease, metastases, pleural effusion)
- F. ECG
- G. Ultrasonography of the abdomen (liver size and echodensity, spleen size, vena portae size, vena lienalis size)

### ***Detailed blood biochemistry (laboratory syndromes):***

- *Syndrome of hepatic citolysis* (↑ALAT, ASAT, 4,5-LDH, Fe)
- *Syndrome of mesenchymal inflammation* (↑limphocytes, ESR, syalic acids, haptoglobine, C3 fraction of complement, gamma-globuline)
- *Syndrome of cholestasis* (↑ bilirubine, alkaline phosphatase, cholesterol, triglycerids)
- *Syndrome of liver failure* (↓ total protein, albumins, prothrombin, coagulation factors, fibrinogen)
- *Dyshormonal syndrome* (↓ tolerance of glucose, ↑ T3, T4, TSH etc.).

*Advanced investigations:*

- CT scan (primary and metastatic tumor, liver abscess)
- Endoscopic retrograde cholangiopancreatography (to examine intra- and extrahepatic bile ducts)
- Blood smears, sickle cell prep, serum haptoglobins, and hemoglobin electrophoresis (for hemolytic anemias)
- Stool for ova and parasites (amebic abscess, cysticercosis and other parasites)
- Bone marrow examination (hemolytic anemias, leukemia, myeloid metaplasia)
- GI series and barium enema (metastatic neoplasm)
- Laparoscopy (cirrhosis, primary or metastatic neoplasm)

- Liver biopsy (cirrhosis, hepatitis, metastatic carcinoma)
- Serum  $\alpha$ -fetoprotein (hepatocellular carcinoma)
- Mitochondrial antibody titer (primary biliary cirrhosis)
- Fibrotest (to assess the degree of liver fibrosis and indications for antiviral therapy of hepatitis)
- Febrile agglutinins (typhoid fever, brucellosis)
- Monospot test (infectious mononucleosis)
- Serum iron and iron-binding capacity (hemochromatosis)
- Serum copper and ceruloplasmin (Wilson disease)
- ANA analysis (lupoid hepatitis, collagen vascular disease)
- Stool for occult blood (metastatic malignancy).

**The list of diseases for the differential diagnosis of hepatomegaly (abbreviation VINDICATE):**

**V – vascular causes** (portal vein thrombosis, right-sided heart failure, hepatic vein thrombosis (Budd-Chiari syndrome), constrictive pericarditis);

**I – infectious causes** (viral hepatitis, infectious mononucleosis, amebiasis, tuberculosis, leptospirosis, actinomycosis, syphilis, brucellosis, hydatid cyst, liver abscess, cholangitis, septicemia);

**N – neoplastic causes** (hemangioma, hepatocellular carcinoma, sarcoma, Hodgkin disease, ampullary carcinoma, pancreatic carcinoma, cholangiocarcinoma, metastatic carcinoma);

**D – degenerative causes** (steatohepatitis, steatohepatosis, amyloidosis);

**I – intoxication causes** (alcoholism [steatosis, hepatitis, fibrosis, cirrhosis], drugs (oral contraceptives, NSAIDs, tetracyclines, statins, methotrexate);

**C – congenital causes** (Wilson disease, hemochromatosis, polycystic liver disease, glycogen storage disease, Gaucher disease, congenital haemolytic anemias, Dubin-Johnson syndrome, cystic fibrosis,  $\alpha$ -1-antitrypsin deficiency);

**A – autoimmune causes** (autoimmune hepatitis, primary biliary cirrhosis, primary sclerosing cholangitis);

**T – traumatic causes** (contusion of the liver)

**E – endocrine causes** (diabetes mellitus, hyperthyroidism, acromegaly, pregnancy).

## DIFFERENTIAL DIAGNOSIS

### *Vascular causes of hepatomegaly*

**Portal vein thrombosis (PVT).** The causes of PVT include: liver cirrhosis, hepatocellular carcinoma, pancreatic cancer, appendicitis, diverticu-



litis, pancreatitis, inflammatory bowel disease, primary sclerosing cholangitis, leukemias, polycythemia vera, paroxysmal nocturnal hemoglobinuria, hypercoagulable states (factor V Leiden mutation, antithrombin III deficiency, protein C deficiency, protein S deficiency, lupus anticoagulant syndrome, oral contraceptives, pregnancy and postpartum period, disseminated intravascular coagulation, sepsis, burns), trauma. Cirrhosis and neoplasms are the major causes of portal vein thrombosis.

There are 2 phases of PVT: acute and chronic. In acute phase patients can present with sudden onset of right upper quadrant pain, nausea, fever, progressive ascites and intestinal ischemia resulting from the propagation of the thrombus. Variceal bleeding can occur acutely with the development of portal vein thrombosis, particularly in the setting of preexisting varices with cirrhosis. Spontaneous resolution of acute thrombosis is a common situation and symptoms abate. In chronic phase the patients most often present with complications related to portal hypertension. Variceal bleeding is the presenting complaint. Ascites is less frequent, and hepatic encephalopathy is rare in the absence of preexisting cirrhosis. Splenomegaly is the most presenting sign in the chronic phase. Stigmata of chronic liver disease, such as spider angiomas or palmar erythema, are usually found in the presence of an underlying liver disease.

Abdominal ultrasonography reveals the following: hepatosplenomegaly, increased diameter of portal and splenic veins. Doppler ultrasound is helpful in the detection of portal vein flow and the diagnosis of portal vein obstruction, the thrombus is observed as an echogenic lesion within the portal vein. Contrast-enhanced CT scanning shows a thrombus as a non-enhanced intraluminal-filling defect. MRI is helpful if hepatic parenchymal detail is required (in hepatic malignancies), and, unlike CT scan, MRI can also quantitate portal and hepatic vessel flow, which is required in the planning of interventions, such as shunt surgery, transjugular intrahepatic portosystemic shunt or liver transplantation.

**Right-sided heart failure.** The acutely congested liver is often painful, especially upon palpation, and enlarged. Transaminase and bilirubin levels can rise significantly. Clinical signs of right-sided heart failure (congested neck veins, edema of lower extremities or anasarca), dilatation of the hepatic veins on ultrasound examination, absence of an inspiratory collapse of the inferior vena cava suggest the correct diagnosis. Echocardiography is helpful in demonstrating increased systolic pressure in pulmonary artery, enlarged right ventricle and right atrium with or without enlargement of the left cardiac cavities.

**Constrictive pericarditis** occurs months or years after the primary disease (tuberculosis, trauma, neoplastic invasion, purulent pericarditis). The findings suggesting the diagnosis include: distension of neck veins, narrow pulse, pulsus paradoxus, distant heart sounds on auscultation, pericardial friction rub, hepatomegaly and ascites.

**Budd-Chiari syndrome** is a condition induced by thrombotic or nonthrombotic obstruction of the hepatic venous outflow. The causes of Budd-Chiari syndrome include the following: hematologic disorders, inherited thrombotic diathesis, pregnancy and postpartum, oral contraceptives, chronic infections (hydatid cysts, aspergillosis, amebic abscess, syphilis, tuberculosis), chronic inflammatory diseases (Behcet disease, inflammatory bowel disease, sarcoidosis, systemic lupus erythematosus, Sjogren syndrome, mixed connective tissue disease), tumors, congenital membranous obstruction, hepatic venous stenosis, hypoplasia of the suprahepatic veins, postsurgical obstruction, posttraumatic obstruction, total parenteral nutrition, alfa-1-antitripsin deficiency. The disease is characterized by hepatomegaly, ascites, abdominal pain, jaundice, ascites, splenomegaly, ankle edema, prominence of collateral veins. Examination of ascitic fluid provides useful clues to the diagnosis, including the following: high protein concentrations ( $> 2$  g/dL); the white blood cell (WBC) count is usually less than  $500/\mu\text{L}$ ; the serum ascites-albumin gradient is usually less than 1.1.

Thrombi inside the lumen of hepatic veins can be visualized on color-flow Doppler ultrasonography. MRI may assist in differentiating acute from chronic Budd-Chiari syndrome, because it is able to provide a larger image of the vasculature, as well as determine if edema of the parenchyma is present (acute form). Catheterization and venography can clearly delineate the nature and severity of an obstruction. Pathologic findings in liver biopsy are high-grade venous congestion and centrilobular liver cell atrophy, thrombi within the terminal hepatic venules and fibrosis of various extent. The most severe findings can include fulminant hepatic failure with massive centrilobular necrosis.

#### *Infectious causes of hepatomegaly*

**Viral hepatitis A, B, C, D, E.** There is an unfavorable epidemiological anamnesis (contact with a patient with hepatitis A, E), data of blood transfusion and its preparations, parenteral manipulations, repeated injections (hepatitis B, C, D) and characteristic duration of latent period of the disease (in hepatitis A, E it lasts from 1.5-3 weeks, in hepatitis B, C, D up to 7-8 weeks). The preicteric period is characterized by subfebrile fever,

dyspeptic syndrome, catarrhal syndrome, intoxication syndrome (weakness, pain in joints and bones), astenovegetative syndrome (general weakness, muscular weakness, and decreased working ability), tender hepatomegaly and dark urine. In icteric period the following abnormalities are found: syndrome of hepatocellular insufficiency, dark urine, acholic stool, jaundice, itching, hepatomegaly, nasal bleeding, increased activity of transaminases (ALT, AST, LDH3– lactate dehydrogenase fraction 3), hyperbilirubinemia (increased conjugated and nonconjugated serum bilirubin), and dysproteinemia (increased alpha-2 and beta globulins and hypoalbuminemia). The final diagnosis is based on the detection of serological markers of viral hepatitis: Anti HAV IgM (hepatitis A virus), HBs Ag, HBeAg, Anti HBc IgM, and DNA-polymerase (hepatitis B virus), Anti HCV IgM and HCV-RNA (hepatitis C virus), Anti HDV IgM, HDV– RNA positive markers of HBV (hepatitis D virus), Anti HEV IgM (hepatitis E virus).

**Liver cirrhosis of viral origin** develops after chronic viral hepatitis B, C, D. In the replication phase pain and heaviness in the right hypochondrium appear very early after an error in diet and physical exercise. The rest of the symptoms and signs include: nasal bleeding, hepatic smell from mouth, teleangiectasia, palmary erythema, testicular atrophy, gynecomasty, red colored tongue, jaundice, fever, hepatic encephalopathy (from sleep disturbances up to hepatic coma) and portal hypertension (variceal esophageal veins, ascites, splenomegaly). Laboratory findings include anemia, thrombocytopenia, leukopenia, dysproteinemia (hypoalbuminemia, hyperalpha-2 and gamma – globulinemia), increased of activity of transaminase ALAT, hyperbilirubinemia, hypocholesterinemia, hypoprothrombinemia, positive serological markers of viral hepatitis; urobilinuria, acholic stools. On abdominal ultrasound there are signs of increased different echodensity, macronodular structure of liver, increased size of liver and spleen, increased size of vena portae and vena lienalis; dilated esophageal veins on fibroesophagogastroduodenoscopy (with or without signs of bleeding) and signs of disturbed liver architectonics, necrosis of hepatocytes on liver biopsy.

**Liver abscess** is a limited purulent inflammation of the liver tissue and can be single and multiple. According to etiology, abscesses can be bacterial (staphylococci, streptococci, *Escherichia coli*, *Proteus spp.*, *Salmonella spp.*, anaerobic microorganisms), protozoal (amebiasis) and parasitic (ascariasis). The source of infection is most often the biliary tract. The process is localized more often in the right lobe. The characteristic features are gradual onset, malaise, weakness, nausea, fever, pain in the right upper quadrant,

permanent, radiating to the chest, shoulder, increasing with respiratory movements, coughing. The examination reveals an increase and soreness of the liver, protective muscle tension in the right hypochondrium, reduction in respiratory excursions of the right lung. A right-sided effusion in the pleural cavity is possible. Further, the clinical picture of sepsis develops with hectic fever, chills, hyperhydrosis and weight loss. Laboratory findings include neutrophilic leukocytosis with a leftward shift, an increase in ESR, moderate anemia, elevated alkaline phosphatase. Ultrasound of the liver shows cavity without clear outlines, in most cases the content is represented as a „veil”. Liver abscess may be complicated by perforation into the pleural cavity, lung, and abdominal cavity.

**Infectious mononucleosis** is caused by Epstein-Barr virus and leads to hepatomegaly in about 30% of cases. Accompanying features include fever, sore throat, headache, nausea, vomiting, splenomegaly, lymphadenopathy, especially in the posterior cervical region, petechia at the junction of the hard and soft palate. General blood analysis shows atypical lymphocytes. Heterophilic antibody test (e.g., Monospot test) is positive.

**Tuberculosis** may be the cause of hepatomegaly by isolated or disseminated hematogenous spread. Chest X-ray is necessary to identify the primary lesion in the lungs. Liver biopsy reveals tuberculous granulomatous lesion of liver.

**Brucellosis** is an antropozoonosis caused by *Brucella spp.* and is responsible for hepatomegaly in association with splenomegaly and lymphadenopathy. Additional features include hectic fever, myalgia, chills, diaphoresis, arthralgia, arthritis, meningitis, meningoencephalitis and endocarditis. Brucella agglutination test shows titers over 1:160 in acute illness.

**Leptospirosis** is an infectious disease characterized by the involvement of liver and kidney. The symptoms include tender hepatomegaly, jaundice, upper quadrant abdominal pain, hematuria, oliguria, petechia, fever, chills, myalgia, nausea, vomiting and prostration. Laboratory findings reveal hyperbilirubinemia, elevated ALAT, ASAT, proteinuria, azotemia, casts in urinalysis, increased hematocrit. The diagnosis of infection is based on the identification of *Leptospira* in body fluids and by serological test.

**Septicemia** is responsible for hepatomegaly with multisystem involvement. It should be suspected in case of prolonged unexplained fever, chills, splenomegaly, acute respiratory distress syndrome, shock, acute kidney failure, ileus, mental confusion, disseminated intravascular coagulation, polyserositis, presence of focus of infection (abscess, pneumonia, meningitis,

osteomyelitis, endocarditis). The diagnosis is confirmed by positive blood cultures and/ or procalcitonin serum levels higher than 2 ng/mL.

***Neoplastic causes of hepatomegaly.*** Common malignant liver tumors include the following: hepatocellular carcinoma, intrahepatic cholangiocarcinoma, hepatoblastoma, angiosarcoma and metastases. Common benign liver tumors include the following: hemangioma, hepatic adenoma, focal nodular hyperplasia.

**Hepatocellular carcinoma (HCC)** occurs predominantly in patients with underlying chronic liver disease and infection with hepatitis B and C virus. Typically, the pattern of HCC spread is local expansion, but it can also metastasize via the hematogenous route and it can be multifocal. These tumors are discovered either during routine screening in cirrhotic patients or when the lesions are symptomatic (pain in the right hypochondrium, ascites, and loss of weight). Serum alfa-fetoprotein values greater than 400 ng/mL are considered diagnostic of HCC. Abdominal ultrasound reveals a round or oval mass of liver with sharp, smooth boundaries. The lesions have a range of echogenicity, from hypoechoic to hyperechoic, depending on the surrounding parenchyma and the degree of fatty infiltration. Classic triple-phase CT findings of HCC include a hypervascular pattern with arterial enhancement and rapid washout during the portal venous phase. In patients with 1- to 2-cm lesions, a biopsy should be performed.

**Hepatic metastases** are far more common than primary liver tumors and colorectal liver metastases are the most prevalent. Hepatic metastases may appear in a multitude of ways on CT scans. The majority of these lesions are hypoattenuating in comparison with the surrounding parenchyma.

**Hepatic hemangioma** (or, hepatic venous malformations, hepatic cavernous hemangiomas) are the most common benign tumors of the liver, usually solitary, that have a female preponderance (5:1) and are associated with some genetic syndromes (e.g., Osler-Weber-Rendu disease). Most of these lesions are asymptomatic and discovered incidentally on imaging studies. Triple-phase CT scanning or MRI can accurately characterize these tumors and differentiate them from other lesions.

**Focal nodular hyperplasia (FNH)** is generally found incidentally and affects women more often than men. Although patients are rarely symptomatic, FNH can cause abdominal pain and vague upper gastrointestinal symptoms. With regard to imaging studies for FNH, MRI is more sensitive and specific than conventional ultrasonography or CT scanning,

but Doppler ultrasonography and contrast-enhanced ultrasonography can greatly improve the accuracy of the diagnosis.

**Hepatic adenoma**, or hepatocellular adenoma, is a rare, usually benign tumor that occurs mostly in women of childbearing age; it is strongly associated with the use of oral contraceptives. In men, hepatic adenoma is associated with the use of anabolic steroids. The clinical presentation may vary from an incidental finding on imaging studies to hemoperitoneum from rupture. There is a potential for malignant transformation to HCC, and the risk is higher for tumors larger than 5 cm. Hepatic adenoma may be differentiated from other lesions with the use of triple-phase CT scanning or MRI.

#### *Degenerative causes of hepatomegaly*

**Non-alcoholic steatohepatitis** (or non-alcoholic fatty liver disease, NAFLD) is often asymptomatic, develops in patients with obesity, diabetes, hypertension, dyslipidemia (high triglyceride level, low HDL cholesterol). Rarely patients present with fatigue, malaise, dull pain in the right upper quadrant, pruritus. In advanced disease hepatosplenomegaly, ascites, spider angioma, oesophageal or intestinal varices develop. Laboratory tests reveal: high direct bilirubin, ASAT, ALAT, and alkaline phosphatase, elevated fasting blood glucose, elevated serum triglycerides, elevated LDL cholesterol. Abdominal ultrasound reveals hypoechoic areas (ovoid, round, or linear) within a hyperechoic liver. CT with contrast shows no mass effect or contour deformation, intrahepatic vessels follow the normal course through the fatty lesions, without deformity. Liver biopsy demonstrates the presence of fat droplets, inflammatory cells, absent Mallory hyaline, fibrosis staging, and presence of cirrhotic change. MRI (T1-weighted images) confirms the presence of areas of fatty infiltration with increased signal intensity.

**Amyloidosis** is a deposition of a proteinaceous material (amyloid) causing liver, spleen, kidney, tongue enlargement, especially in patients with chronic diseases (bronchiectasis, rheumatoid arthritis etc.). There may be no symptoms other than abdominal discomfort. Liver function tests remain either normal or only minimally affected. Rectal biopsy reveals the presence of amyloid.

#### *Hepatomegaly due to toxic causes*

**Alcoholic liver disease (steatosis, hepatitis, fibrosis, cirrhosis).** Patient's history is consistent with 5 to 10 years of alcohol abuse (>50 to 60 g/day for men and 20 to 30 g/day for women). The CAGE questionnaire score is more than 2 points by asking the following questions:

1. Have you ever felt you needed to **C**ut down on your drinking?
2. Have people **A**nnoyed you by criticizing your drinking?
3. Have you ever felt **G**uilty about drinking?
4. Have you ever felt you needed a drink first thing in the morning (**E**ye-opener) to steady your nerves or to get rid of a hangover?

The clinical features include abdominal pain, pruritus, generalized malaise, weight loss, fatigue, anorexia, cachexia, pale stool, dark urine, melena, or haematemesis. Physical examination reveals parotid gland enlargement, Dupuytren's contracture, generalized wasting, gynaecomastia, altered sensorium, asterixis or altered deep tendon reflexes, echymosis or petechiae, spider angioma, thenar eminence loss, palmar erythema, caput medusae, ascites, hepatosplenomegaly or small liver, pleural effusion, positive rectal examination (blood). Blood biochemistry reveals elevated ASAT, ALAT (ASAT to ALAT ratio is greater than 2:1; the elevated ASAT to ALAT ratio is due to the deficiency of pyridoxal-6-phosphate, which is required in the ALAT enzyme synthetic pathway), elevated gamma-gutamyltranspeptidase, increased bilirubine (both direct and indirect), low albumin, elevated urea, elevated prothrombin time, elevated INR. Full blood count demonstrates low platelet count (reflects hypersplenism) associated with anemia and leucopenia (in alcoholic liver cirrhosis), or red blood cell macrocytosis (mean corpuscular volume > 100) as a result of reduced folate level in alcoholic patients due to decreased intestinal absorption, or leukocytosis which reflects the severity of liver injury. Abdominal ultrasound shows hepatosplenomegaly, increased diameter of the portal vein and the splenic vein, hyperechoic or mixed echogenicity (in cirrhotic patients). Histologic findings include Mallory bodies (condensations of cytokeratin components in the hepatocyte cytoplasm), giant mitochondria, hepatocyte necrosis, and neutrophil infiltration at the perivenular area.

**Drug-induced liver disease** (see Differential diagnosis of jaundice)

#### *Congenital causes of hepatomegaly*

**Gaucher's disease** is an autosomal recessive lipid storage disease characterized by the deposition of glucocerebroside in cells of the macrophage-monocyte system (brain, liver, spleen, bone marrow and other organs) as a result of the deficiency of a specific lysosomal hydrolase, glucocerebroside. It is characterized by rapidly progressive visceral enlargement, including hepatomegaly, and mental retardation (infantile type) or rapid development of hepatosplenomegaly without brain involvement (juvenile type).



**Glycogen storage disease**, type I (Von Gierke disease) is due to the deficiency of enzyme glucose-6-phosphatase and is characterized by massive hepatomegaly, doll-like face, stunted growth, hyperuricemia, episodes of hypoglycemia with convulsions, episodes of bleeding, ketonuria, and development of gout after puberty. The diagnosis is confirmed by liver biopsy (the deposition of glycogen) and absence of glucose-6-phosphatase in blood.

**Polycystic liver disease** is an inherited disorder (mutations in two genes, one on the short arm of chromosome 19 and one on the long arm of chromosome 6) characterized by many cysts of various sizes (from a few millimeters to over 15 cm in diameter) scattered throughout the liver. Occasionally cysts are found in the liver in association with the presence of autosomal dominant polycystic kidney disease (AD-PKD). About half of the people who have AD-PKD experience liver cysts. Abdominal discomfort from swelling of the liver may occur; however, most affected individuals do not have any symptoms. Fever may also occur if the cysts break, due to infection or bleeding. Jaundice may occur if the bile ducts are compressed by a cyst and portal hypertension occurs only if the portal vein is compressed by a cyst. Abdominal ultrasound, computed tomography scan and magnetic resonance imaging are used for the diagnosis.

**Wilson's disease.** The onset of disease is in adolescence and early adulthood with tremor, clumsy gait, slurred speech, abdominal pain, pruritus, generalized malaise and weakness, weight loss, anorexia, pale stool, dark urine, irritability, depression, dementia, psychosis, easy bruising. Kayser-Fleischer rings, parkinsonian-like tremor, rigidity, clumsy gait, poor balance, impaired co-ordination, abnormal postures, repetitive movements, bradykinesia (tongue, lips, and jaw), dysarthria, dysphonia (hoarse voice), inappropriate and uncontrollable grinning (risus sardonicus), drooling, generalized wasting, gynaecomastia, ascites, altered sensorium, hepatosplenomegaly, hypermelanotic pigmentation, bruises. Laboratory tests reveal high direct bilirubin, ASAT and ALAT, normal alkaline phosphatase, low or normal platelet count. Specific tests include: decreased serum ceruloplasmin, increased urinary copper excretion. Wilson's disease genetic test demonstrates positive pattern of di- and trinucleotide repeats around ATP7B. Liver biopsy shows increased copper concentration.

**Haemochromatosis** is a genetic disease which is usually asymptomatic or found after screening in patients with a positive family history of liver disease; jaundice occurs in decompensated disease with established cirrho-



sis; rarely patients present with symptoms of diabetes mellitus, bronze skin, gynaecomastia, ascites, altered sensorium and cachexia. In decompensated disease signs of chronic liver disease plus associated arthropathy and cardiomyopathy develop. Laboratory findings are as follows: high direct bilirubin, alkaline phosphatase and gamma-glutamyltranspeptidase, increased prothrombine time and INR, low or normal platelet count, high serum iron, high serum ferritin, low TIBC (total iron-binding capacity), serum transferrin saturation test >45%. Genetic test for haemochromatosis is positive for HFE gene mutation. Liver biopsy confirms increased iron stores.

**Cystic fibrosis, alfa-1-antitripsin deficiency** (see Differential diagnosis of broncho-obstructive syndrome)

*Autoimmune causes of hepatomegaly*

**Autoimmune hepatitis** manifestations include fatigue, abdominal pain, arthralgias, pruritus, nausea and vomiting, moderate jaundice, pale stool, dark urine; associated haemolytic anaemia, thyroiditis, ulcerative colitis, diabetes, and/or Sjogren's syndrome; ascites, hepatomegaly, cirrhosis, spider angioma, mental confusion in advanced disease. Laboratory tests reveal: elevated transaminases, high direct bilirubin, high alkaline phosphatase, low albumin, low leukocyte count and platelets, elevated ESR, positive ANA (antinuclear antibodies), positive anti-smooth muscle antibodies, positive anti-LKM-1 antibodies, positive anti-SLA antibodies.

**Primary biliary cirrhosis** is an autoimmune disease of intrahepatic bile ducts typically developing in female patients. Pruritus with or without evident jaundice, fatigue, abdominal pain, generalized malaise, weight loss, anorexia, pale stool, dark urine, keratoconjunctivitis, xerostomia, xanthelasma, hepatosplenomegaly, right upper quadrant pain and fatty subcutaneous deposits are among the main clinical features. Laboratory findings are as follows: high direct bilirubin, alkaline phosphatase and gamma-glutamyltranspeptidase, increased prothrombine time and INR, low or normal platelet count, positive serum antimitochondrial antibody. Liver biopsy reveals florid bile duct lesion with granuloma formation.

**Primary sclerosing cholangitis** is an autoimmune disorder, often asymptomatic, patients may have history of ulcerative colitis or Crohn's disease. The clinical manifestations include chills, night sweats, abdominal pain that suggest infection, pruritus, skin excoriations, generalized malaise, weight loss, fatigue, anorexia, jaundice, pale stool, dark urine. Laboratory tests are as follows: high direct bilirubin, alkaline phosphatase and gamma-glutamyltranspeptidase, increased prothrombine time and INR, low or

normal platelet count, elevated ANA (antinuclear antibodies). MRCP and ERCP demonstrate the presence of both intra- and extrahepatic biliary strictures.

### *Endocrine causes of hepatomegaly*

**Diabetes mellitus** is known to cause the enlargement of liver in long-standing course. Hepatomegaly is explained by fatty infiltration.

**Pregnancy induced hepatomegaly** (see Differential diagnosis of jaundice).

## BIBLIOGRAPHY

1. O'Shea R.S., Dasarathy S., McCullough A.J. Alcoholic liver disease: AASLD Practice Guidelines. *Hepatology* 2010; 51 (1): 307–328.
2. Rodriguez-Castro K.I., Hevia-Urrutia F.J., Sturniolo G.C. Wilson's disease: A review of what we have learned. *World J Hepatol* 2015; 7 (29): 2859–70.
3. Bacon B.R., Adams P.C., Kowdley K.V., et al. Diagnosis and management of hemochromatosis: 2011 practice guideline by the American Association for the Study of Liver Diseases. *Hepatology* 2011; 54 (1): 328–43.
4. Grabowski G.A. Phenotype, diagnosis, and treatment of Gaucher's disease. *Lancet* 2008; 372 (9645): 1263–71.
5. Valla D.C. Primary Budd-Chiari syndrome. *J Hepatol* 2009; 50(1): 195–203.
6. Llovet J.M., Fuster J., Bruix J. The Barcelona approach: diagnosis, staging, and treatment of hepatocellular carcinoma. *Liver Transpl* 2004; 10 (2 Suppl 1): S115–20.
7. Bugianesi E. Non-alcoholic steatohepatitis and cancer. *Clin Liver Dis* 2007; 11(1): 191–207.
8. Chen S.L., Morgan T.R. The natural history of hepatitis C virus (HCV) infection. *Int J Med Sci* 2006; 3 (2): 47–52.
9. Adams L.A., Lymp J.F., St Sauver J., et al. The natural history of nonalcoholic fatty liver disease: a population-based cohort study. *Gastroenterology* 2005; 129 (1): 113–21.
10. Tsochatzis E.A., Bosch J., Burroughs A.K. Liver cirrhosis. *Lancet* 2014; 383 (9930): 1749–61.

## DIFFERENTIAL DIAGNOSIS OF JAUNDICE

**DEFINITION.** Jaundice is a yellowish staining of the skin, sclera, and mucous membranes by bilirubin, a yellow-orange bile pigment. The classic definition of jaundice is a serum bilirubin level greater than 2.5 to 3 mg/dL (42.8 to 51.3  $\mu\text{mol/L}$ ) in conjunction with a clinical picture of yellow skin and sclera. The word „jaundice” comes from the French word „jaune”, which means yellow.

Pseudojaundice can occur with excessive ingestion of foods rich in beta-carotene (e.g., squash, melons, and carrots). Unlike true jaundice, carotenemia does not result in scleral icterus or elevation of the bilirubin level.

**PATHOPHYSIOLOGY.** Bilirubin is formed by a breakdown product of heme rings, usually from metabolized red blood cells. The discoloration typically is detected clinically once the serum bilirubin level rises above 3 mg/dL (51.3  $\mu\text{mol/L}$ ). Bilirubin metabolism takes place in three phases: prehepatic, intrahepatic, and posthepatic.

*Prehepatic phase.* The human body produces about 4 mg per kg of bilirubin per day from the metabolism of heme. Approximately 80 % of the heme comes from the catabolism of red blood cells, with the remaining 20 % resulting from ineffective erythropoiesis and breakdown of muscle myoglobin and cytochromes. Bilirubin is transported from the plasma to the liver for conjugation and excretion.

*Intrahepatic phase.* Unconjugated bilirubin is insoluble in water but soluble in fats. Therefore, it can easily cross the blood-brain barrier or enter the placenta. In the hepatocyte, the unconjugated bilirubin is conjugated with a sugar via the enzyme glucuronosyltransferase and is then soluble in aqueous bile.

*Posthepatic phase.*

Once soluble in bile, bilirubin is transported through the biliary and cystic ducts to enter the gallbladder, where it is stored, and then it passes through Vater's ampulla to enter the duodenum. Inside the intestines, some bilirubin is excreted in the stool, while the rest is metabolized by the gut flora into urobilinogens and then it is reabsorbed. The majority of urobilinogens are filtered from the blood by the kidney and excreted in the urine. A small percentage of the urobilinogens are reabsorbed in the intestines and re-excreted into the bile.

Dysfunction of any of these 3 phases can lead to jaundice.

**CLASSIFICATION**

1. *Prehepatic jaundice* (overproduction of unconjugated bilirubin)
  - 1.1. Extravascular hemolysis
    - 1.1.1. Inherited intracellular defects:
      - A. Membrane abnormalities (hereditary spherocytosis)
      - B. Enzyme abnormalities (glucose-6-phosphate-dehydrogenase deficiency, pyruvate kinase deficiency)
      - C. Hemoglobinopathies:
        - C1. Alteration of globin gene expression (thalassemia)
        - C2. Changes in physical properties of the globins (sickle cell disease)
    - 1.1.2. Extracellular defects
      - A. Autoimmune hemolytic anemias (cold or warm autoimmune anemias, drug-induced anemias)
      - B. Infection (malaria, babesiosis, bartonellosis)
      - C. Microangiopathy (disseminated intravascular coagulation, hemolytic-uremic syndromes, thrombotic thrombocytopenic purpura)
      - D. Other (hypersplenism)
  - 1.2. Intravascular hemolysis
    - A. Acquired (paroxysmal nocturnal hemoglobinuria)
    - B. Microangiopathic (aortic stenosis, prostatic valve)
    - C. Infection (clostridial sepsis, severe malaria)
    - D. Transfusion reaction
    - E. Snake bite
2. *Intrahepatic jaundice*
  - 2.1. Deficient bilirubin binding (drug-induced, reduced circulation through the sinusoids (e.g., portosystemic anastomoses, porta-caval shunt or transjugular intrahepatic portosystemic shunt)
  - 2.2. Deficient bilirubin conjugation
    - A. Congenital (Gilbert, Crigler-Najar syndromes)
    - B. Neonatal physiological jaundice
  - 2.3. Deficient bilirubin excretion
    - A. Congenital (Dubin-Johnson, Rotor syndromes)
    - B. Acquired (acute and chronic hepatitis, liver cirrhosis, drug-induced hepatitis, pregnancy, postoperative jaundice)
3. *Posthepatic jaundice*
  - 3.1. Cholangiopathy (cholelithiasis, biliary stricture, primary sclerosing cholangitis, primary biliary cirrhosis)

- 3.2. Infection (AIDS cholangiopathy, colangitis in sepsis, cytomegalovirus, *Cryptosporidium* spp., parasitic infection with *Ascaris lumbricoides*)
- 3.3. Acute and chronic pancreatitis
- 3.4. Tumors (cholangiocarcinoma, pancreatic carcinoma, ampullary carcinoma, metastases)

**CLINICAL PRESENTATION.** Patients with jaundice may present with no concomitant symptoms at all or they may present with a life-threatening condition. Patients presenting with acute illness, which is frequently caused by infection, may seek medical care because of fever, chills, abdominal pain, and flu-like symptoms. Patients with noninfectious jaundice may complain of weight loss or pruritus. Abdominal pain is the most common presenting symptom in patients with pancreatic or biliary tract cancers or stones. Occasionally, patients may present with jaundice and some extrahepatic manifestations of liver disease (e.g., pyoderma gangrenosum, polyarthralgias). The physical examination should focus primarily on signs of liver disease other than jaundice, including bruising, spider angiomas, gynecomastia, testicular atrophy, and palmar erythema. An abdominal examination to assess liver size and tenderness is important. The presence or absence of ascites also should be noted.

**Laboratory and instrumental examination.** The initial workup of the patient with jaundice depends on whether the hyperbilirubinemia is conjugated (direct) or unconjugated (indirect). A urinalysis that is positive for bilirubin indicates the presence of conjugated bilirubinemia. Conjugated bilirubin is water soluble and therefore able to be excreted in urine. In a patient presenting with jaundice the first-line testing should include a full blood count (FBC) and determination of bilirubin (total and direct fractions), ASAT, ALAT, gamma-glutamyl transpeptidase, and alkaline phosphatase levels.

A FBC is useful in detecting hemolysis, which is indicated by the presence of fractured red blood cells (schistocytes) and increased reticulocytes on the smear. ASAT and ALAT are markers of hepatocellular injury. Alkaline phosphatase and gamma-glutamyltransferase are markers for cholestasis. As bile obstruction progresses, the levels of these two markers rise several times above the normal limits. Elevated serum LDH and a reduced haptoglobin level are highly specific for the diagnosis of hemolysis. The second-line serum investigations may include tests for hepatitis A IgM antibody, hepatitis B surface antigen and core antibody, hepatitis C anti-

body, and autoimmune markers such as antinuclear, smooth muscle, and liver-kidney microsomal antibodies. Patients with primary biliary cirrhosis are almost always positive for antimitochondrial antibody, and the majority of those affected by primary sclerosing cholangitis have antineutrophil cytoplasmic antibodies. An elevated amylase level would corroborate the presence of pancreatitis when this condition is suspected based on the history or physical examination.

Ultrasonography and computed tomographic scanning are useful in distinguishing an obstructing lesion from hepatocellular disease in the evaluation of a jaundiced patient. While ultrasonography is the most sensitive imaging technique for detecting biliary stones, CT scanning can provide more information about liver and pancreatic parenchymal diseases. Endoscopic retrograde cholangiopancreatography (ERCP) and magnetic resonance cholangiopancreatography (MRCP) are necessary to diagnose biliary tract disease (e.g., primary sclerosing cholangitis, biliary stricture) or tumors (e.g., cholangiocarcinoma). Liver biopsy provides information on the architecture of the liver diagnosis if serum and imaging studies do not lead to a firm diagnosis and is used mostly for determining prognosis. Liver biopsy can be particularly helpful in diagnosing autoimmune hepatitis or biliary tract disorders (e.g., primary biliary cirrhosis, primary sclerosing cholangitis).

**Features of prehepatic jaundice** include: mild jaundice of skin and mucosa, no pruritis, no or slight hepatomegaly, splenomegaly, anemia, reticulocytosis, normal ALAT, ASAT, increased serum indirect bilirubin, urobilinogenuria, increased erythropoiesis on bone marrow examination.

**Features of intrahepatic jaundice** include: the presence of liver stigmata (palmar erythema, gynecomastia, testicular atrophy, spider angiomas), moderate pruritis, hepatomegaly with or without splenomegaly, signs of portal hypertension, increased bilirubin level (predominantly a direct one), increased ALAT, ASAT, biopsy findings consistent with hepatitis or cirrhosis.

**Features of posthepatic jaundice** include: patient's age > 40 years, pain usually precedes jaundice, 40% of jaundice are caused by lithiasis, 40% of jaundice are caused by neoplasm, intensive pruritis with or without fever and chills, no splenomegaly, considerable hyperbilirubinemia (predominantly a direct one), dark urine (due to direct bilirubin), acholic stools with or without steatorrhea, moderately increased ALAT, ASAT, increased markers of cholestasis (alkaline phosphatase, GGTP, 5-nucleotidase).

***Diseases characterized by prehepatic jaundice***

**Hereditary spherocytosis (HS)** is a familial hemolytic disorder associated with a variety of mutations that lead to defects in red blood cell (RBC) membrane proteins. The morphologic hallmark of HS is the microspherocyte, which is caused by diminished RBC membrane surface area and has abnormal osmotic fragility *in vitro*.

HS shows marked heterogeneity, ranging from an asymptomatic condition to fulminant hemolytic anemia. Patients with severe cases may present as neonates, while those with mild HS may not come to medical attention until adulthood, when an environmental stressor uncovers their disorder. The major complications of HS are aplastic or megaloblastic crisis, hemolytic crisis, cholecystitis and cholelithiasis. The typical laboratory features of HS include: mild to moderate anemia, reticulocytosis, increased mean corpuscular hemoglobin concentration (MCHC), spherocytes on the peripheral blood smear, indirect hyperbilirubinemia and abnormal results on the incubated osmotic fragility test.

**Glucose-6-phosphate dehydrogenase deficiency (G6PD)** is the most common enzyme deficiency in humans; it is inherited as an X-linked recessive disorder. G6PD deficiency is polymorphic, with more than 300 variants. G6PD deficiency can present as neonatal hyperbilirubinemia. Persons with this disorder can experience episodes of brisk hemolysis after ingesting fava beans or being exposed to certain infections or drugs. Many individuals with G6PD deficiency are asymptomatic. G6PD deficiency confers partial protection against malaria. During remission, specific testing should include the Beutler test and a quantitative assay of GPD activity. The Beutler test is a semi-quantitative rapid fluorescent spot test that detects the generation of nicotinamide adenine dinucleotide phosphate (NADPH) from nicotinamide adenine dinucleotide phosphate (NADP); the test is positive if the blood spot fails to fluoresce under ultraviolet light. The Beutler test is not reliable in females. A quantitative analysis of G6PD activity in a leukocyte-depleted sample is definitive. Testing for enzyme activity should be performed when patients are in remission, as results may be falsely negative during acute hemolysis. The reason is that older erythrocytes have been destroyed, because their diminished G6PD levels leaves them vulnerable to hemolysis while there is a compensatory increase of immature erythrocytes and reticulocytes that have increased G6PD levels.

**Pyruvate kinase deficiency (PKD)** is one of the most common enzymatic defects of the erythrocyte. The following symptoms and signs are



evident in PKD: mild to severe normochromic and normocytic anemia, reticulocytosis, symmetrical growth delay, failure to thrive, cholelithiasis (usually after the first decade of life but possibly in childhood), frontal bossing, hyperbilirubinemia in the newborn, icteric sclera, mild to moderate splenomegaly, upper-right-quadrant tenderness, Murphy sign, chronic leg ulcers (adults). The birth history of patients with PKD includes severe anemia, severe jaundice, kernicterus (bilirubin-induced encephalopathy), and a history of exchange transfusion. Laboratory tests include: normochromic, normocytic, or macrocytic anemia, reticulocytosis, a negative Coombs test result to exclude immune hemolysis. The measurement of the intermediates (2,3-diphosphoglycerol and glucose-6-phosphate) proximal to the enzyme defect helps to confirm the diagnosis.

**Thalassemias** are inherited disorders of hemoglobin (Hb) synthesis. Their clinical severity widely varies, ranging from asymptomatic forms to severe or even fatal entities. Signs and symptoms of different types of thalassemia include the following: pallor, slight scleral icterus in more severe forms, enlarged abdomen. In rare types of  $\beta$ -thalassemia trait there is severe hemolytic process requiring management, such as thalassemia intermedia or thalassemia major. Patients with Hb E/ $\beta$  thalassemia may have severe symptoms and clinical course identical to that of  $\beta$ -thalassemia major. Heterozygous/homozygous Hb E patients are usually slightly anemic and usually asymptomatic. A-Thalassemia manifests by clearly evident hematologic abnormalities in newborns with mild or moderate forms of the disease. B-Thalassemia patients have extreme pallor and enlarged abdomen due to hepatosplenomegaly. Severe bony changes due to ineffective erythroid production (e.g., frontal bossing, prominent facial bones, dental malocclusion), hypermetabolism from ineffective erythropoiesis, gout due to hyperuricemia, iron overload, growth retardation, failure to thrive, metabolic symptoms that suggest diabetes, thyroid disorder, neuropathy/paralysis in patients with severe anemia not receiving transfusion therapy were described. Hb electrophoresis confirms the diagnosis.

**Sickle cell disease (SCD)** and its variants are genetic disorders resulting from the presence of a mutated form of hemoglobin, hemoglobin S (HbS). The symptoms may include the following: acute and chronic pain (the most common clinical manifestation of SCD is vaso-occlusive crisis); bone pain (due to bone marrow infarction); hemolytic anemia; aplastic crisis (serious complication due to infection with B19V); splenic sequestration (the onset of life-threatening anemia with rapid enlargement of the spleen and high



reticulocyte count); infection (encapsulated respiratory bacteria, particularly *Streptococcus pneumoniae*; *Salmonella* spp. infection in adults); growth retardation, delayed sexual maturation, being underweight; hand-foot syndrome (dactylitis presenting as bilateral painful and swollen hands and/or feet in children); acute chest syndrome (chest pain, fever, cough, tachypnea, leukocytosis, and pulmonary infiltrates in the upper lobes); pulmonary hypertension; avascular necrosis of the femoral or humeral head; CNS involvement (stroke); ophthalmologic involvement (ptosis, retinal vascular changes, proliferative retinitis), cardiac involvement (dilation of both ventricles and the left atrium), gastrointestinal involvement (cholelithiasis); genitourinary involvement (kidneys lose concentrating capacity, priapism), dermatologic involvement (chronic leg ulcers). The main diagnostic test is a blood test that checks for hemoglobin S, which is part of routine newborn screening done at the hospital in the United States.

**Autoimmune hemolytic anemia** is a group of disorders characterized by a malfunction of the immune system that produces autoantibodies against red blood cells. These disorders affect women more often than men and are frequently associated with other autoimmune disorders (systemic lupus erythematosus, autoimmune thyroiditis etc.) or a lymphoma or it can be induced by drugs (e.g., penicillins). In warm antibody hemolytic anemia the autoantibodies attach to and destroy erythrocytes at normal body temperature. In cold antibody hemolytic anemia (cold agglutinin disease) the autoantibodies become most active and attack red blood cells only at temperatures well below normal body temperature. The symptoms of severe or rapid destruction of red blood cells may include jaundice, fever, chest pain, fainting, heart failure, and even death (due to massive hemoglobinuria and renal failure). When destruction persists for a few months or longer, there is a considerable splenomegaly and abdominal discomfort. In patients with cold antibody hemolytic anemia, the hands and feet may be cold or cyanotic. Patients with paroxysmal cold hemoglobinuria (a form of cold hemolytic anemia) may have severe pain in the back and legs, headache, vomiting, and diarrhea. The diagnosis of hemolysis is sustained by anemia, reticulocytosis, indirect hyperbilirubinemia, decreased serum haptoglobin. Autoimmune origin of hemolytic anemia is confirmed by detection of increased amounts in blood of antibodies, either attached to red blood cells (direct antiglobulin or direct Coombs test) or in the liquid portion of the blood (indirect antiglobulin or indirect Coombs test).

***Diseases characterized by intrahepatic jaundice***

**Viral hepatitis.** Hepatitis A is usually a self-limited illness that presents with acute onset of jaundice. Hepatitis B, C and D infections often do not cause jaundice during the initial phases but can lead to progressive jaundice when chronic infection has progressed to liver cirrhosis. Epstein-Barr virus infection (infectious mononucleosis) occasionally causes transient hepatitis and jaundice that resolve as the illness clears.

**Physiologic neonatal jaundice.** The peak total serum bilirubin level is 5–6 mg/dL (86–103  $\mu\text{mol/L}$ ). It occurs at the age of 48–120 hours and does not exceed 17–18 mg/dL (291–308  $\mu\text{mol/L}$ ).

**Breast milk jaundice.** Bilirubin may increase to levels as high as 20 mg/dL, necessitating the need for phototherapy and the discontinuation of breastfeeding.

**Gilbert syndrome** is a hereditary disorder due to a mutation in the UGT1A1 gene which results in decreased activity of the bilirubin uridine diphosphate glucuronosyltransferase enzyme and causes an increase in the indirect fraction of serum bilirubin. Gilbert syndrome is typically an incidental finding on routine liver function tests, when the bilirubin level is slightly increased and all other liver function values are within normal limits. Jaundice and further elevation of the bilirubin level may occur during periods of stress, fasting, or illness. These changes are usually transient, and have good prognosis. Blood smear and reticulocyte count are normal. Fasting bilirubin test demonstrates two- to threefold rise in unconjugated bilirubin if patients consume a diet of  $\leq 400$  kcal within 48 hours of initiating the fast. The test with nicotinic acid shows that administration of 50 mg of nicotinic acid intravenously results in a 2- to 3-fold rise of unconjugated bilirubin level in plasma within 3 hours. The phenobarbital test reveals that phenobarbital induces activity of the uridine-diphosphoglucuronate glucuronosyltransferase (UDPGT) enzyme system, leading to normalization of bilirubin level within 1 to 2 weeks after initiation. Polymerase chain reaction (PCR) can be used to identify mutations and genetic polymorphisms (e.g., UDPGT-1A1\*28) found in the TATAA promoter region of the UDPGT-1A1 gene.

**Crigler-Najar syndrome (type 1 and type 2)** is a hereditary disorder characterized by severe jaundice within first few days after birth (type 1), abdominal pain, pruritus, generalized malaise, weight loss, fatigue, anorexia, pale stool (normal in type 1), dark urine, kernicterus (type 1), encephalopathy (type 1, rare in type 2), oculomotor palsy. Laboratory findings involve: high indirect bilirubin; normal ASAT and ALAT, increased prothrombine time and INR, low or normal platelet count. In type 1 Crigler-Najar syndrome

the phenobarbital test does not reveal any change in bilirubin and there is a decreased bilirubin in type 2 of the syndrome. Chromatographic analysis of bile shows absent conjugated bilirubin in type 1 Crigler-Najar syndrome and large amount of conjugated bilirubin in type 2 of the syndrome.

**Dubin-Johnson syndrome (DJS)** is an inherited, autosomal-recessive, relapsing, benign disorder of bilirubin metabolism which develops due to a defect in the multiple drug-resistance protein 2 gene (*ABCC2*) located on chromosome 10. This rare autosomal recessive condition is characterized by conjugated hyperbilirubinemia with normal liver transaminases, a unique pattern of urinary excretion of heme metabolites (coproporphyrins), and the deposition of a pigment that gives the liver a characteristic black color. Patients with DJS tend to develop nonpruritic jaundice during their teenaged years, but in most cases, DJS is asymptomatic. The diagnosis can be confirmed by demonstrating normal total urine coproporphyrin and an increase in the ratio of urinary coproporphyrin I to coproporphyrin III: type I makes up 80%, rather than the usual 25%, of the urinary coproporphyrin content in these patients (normal urine contains more of isomer 3 than isomer 1).

**Rotor syndrome** is a relatively mild autosomal-recessive disorder caused by mutations in genes *SLCO1B1* and *SLCO1B3* and is characterized by elevated blood levels of direct bilirubin. The main difference from DJS is elevated total urine coproporphyrin and less than 70% of it accounts coproporphyrin I.

**Drug-induced hyperbilirubemia.** Patient's history is consistent with paracetamol overuse or overdose, use of highly active antiretroviral therapy for HIV infection, isoniazid, ethambutol, amiodarone, NSAIDs, herbal preparations (kava, comfrey, black cohosh, cascara), antibiotics (especially amoxicillin-clavulanate, gentamicin, erythromycin, novobiocin, rifampin), calcium-channel blockers, ACE inhibitors, chlorpromazine, halothane, oestrogenic or anabolic steroids, statins, oral contraceptives, ascorbic acid, theophylline, methyl dopa, phenelzine, isoproterenol, aminophenol, epinephrine. The main clinical features are: right upper quadrant pain, pruritus, mild jaundice, generalized malaise, weight loss, fatigue, anorexia, pale stool, dark urine, tender hepatosplenomegaly. Laboratory tests reveal an increase of predominantly direct bilirubin, elevated ALAT, ASAT, elevated serum paracetamol if overdose.

**Cholestasis of pregnancy.** The clinical presentation includes pregnant or recently delivered women, pruritus, hyperemesis gravidarum (first trimester), HELLP syndrome (haemolysis, elevated liver enzymes, low platelets) in the second and third trimesters and post-partum, abdominal pain, pru-

ritus, generalized malaise, weight loss, elevated blood pressure (preeclampsia and eclampsia), tender hepatomegaly, splenomegaly, lymphadenopathy, fatigue, anorexia, pale stool, dark urine. Laboratory findings include: high direct bilirubin, elevated alkaline phosphatase, gamma-glutamyltranspeptidase, ALAT and ASAT, anemia, thrombocytopenia. Abdominal ultrasound does not reveal any changes.

**Postoperative jaundice.** It appears after gallbladder or bile duct surgery and is characterized by abdominal pain, pruritus, fatigue, anorexia, pale stool, dark urine. Association of fever suggests the development of cholangitis. Laboratory findings are high direct bilirubin, alkaline phosphatase and gamma-glutamyltranspeptidase. MRCP demonstrates the presence of biliary stricture.

*Diseases characterized by posthepatic jaundice*

**Cholelithiasis** is the presence of gallstones in the gallbladder or bile ducts and it is a common finding in adult patients. Obstruction within the biliary duct system may lead to cholecystitis, or inflammation of the gallbladder, as well as cholangitis or infection. The clinical presentation includes severe pain in the right hypocondrium, radiating to the back and neck, jaundice, nausea, vomiting, positive Murphy sign, positive Blumberg sign (particularly in empyema of gallbladder and peritonitis). Full blood count reveals leukocytosis and elevated ESR. Abdominal ultrasound shows stones in the gallbladder or bile ducts and biliary ducts dilation.

**Cholangitis** is diagnosed clinically by the classic symptoms of fever, pain, and jaundice, known as Charcot's triad. Cholangitis most commonly occurs because of an impacted gallstone. Laboratory findings include leukocytosis, elevated ESR, elevated direct bilirubin, high procalcitonin, positive hemoculture (if sepsis). Instrumental methods (abdominal ultrasound and MRCP) demonstrate dilated bile ducts, the presence of obstacles (stones, strictures).

**AIDS colangiopathy** manifestations include right upper quadrant pain, pruritus, generalized malaise, weight loss, prolonged fever, fatigue, anorexia, pale stool, dark urine. Patient's anamnesis is consistent with high-risk sexual activity (many partners, unprotected intercourse, intercourse with HIV-infected), HIV-positive state, diarrhea for more than 4 weeks. Blood biochemical tests reveal high direct bilirubin, alkaline phosphatase, gamma-glutamyltranspeptidase, increased INR.

ERCP is necessary for the documentation of papillary stenosis and/or biliary strictures.

**IgG4-cholangiopathy** typically develops in men aged 50 to 60 years with a history of new onset diabetes mellitus or diarrhoea associated with pancre-

atic insufficiency. The clinical manifestations are epigastric and abdominal pain, jaundice, weight loss, epigastric tenderness, jaundice, lymphadenopathy, bibasal crepitation related to multisystemic manifestation. Laboratory tests include: high direct bilirubin, gamma-glutamyltranspeptidase and alkaline phosphatase, mildly elevated ASAT and ALAT, serum IgG4 level is  $\geq 1.35$  g/L ( $\geq 135$  mg/dL). Abdominal ultrasound or CT scan reveals simultaneous intra- and extrahepatic biliary duct dilation. MRCP shows simultaneous strictures and the evidence of associated pancreatitis. Endoscopic ultrasound is useful in obtaining tissue for histology and it may reveal vascular involvement of the splenic, portal, and superior mesenteric veins. ERCP demonstrates bile duct obstruction and pus draining from the biliary tree.

**Parasitic infection.** Patient's history is consistent with travel to endemic areas, abdominal pain, pruritus, generalised malaise, weight loss, fatigue, anorexia, pale stool, dark urine. Physical examination reveals cachexia, muscle wasting, tender abdomen, hepatomegaly and jaundice. Stool is positive for ova and parasites. Abdominal ultrasound in case of *Ascaris lumbricoides* infection shows: long, linear, echogenic structures; 4-line sign or non-shadowing echogenic strips with central tube. MRCP and ERCP reveal parasite visualized in the bile duct.

**Pancreatitis.** The most common causes of pancreatitis are gallstones (obstruction of the common duct that drains the biliary and pancreatic systems) and alcohol use. Even without duct obstruction from a stone, pancreatitis can lead to secondary bile duct compression from pancreatic edema. The main clinical features include: severe epigastric pain radiating to the right and left hypocondrium, to the back, moderate jaundice, nausea, severe vomiting, subsequent dehydration, hypovolemic shock, acute prerenal failure and acute respiratory distress syndrome in severe pancreatitis. Biochemical markers are elevated serum pancreatic amylase and urine diastase, elevated serum lipase, elevated direct bilirubin, alkaline phosphatase and gamma-glutamyltranspeptidase, markers of inflammation (leukocytosis, elevated ESR, increased C-reactive protein, increased procalcitonin). Ultrasonography of the abdomen shows increased dimensions of the pancreas (particularly the head of the pancreas), zones of hypodensity inside the pancreas, the presence of stones in bile ducts, reactive ascitis, accumulation of liquid in the peripancreatic bursae. Abdominal CT more accurately assesses the presence of pancreonecrosis, dilatation of bile ducts and the presence of liquid in the peripancreatic space.

**Pancreatic carcinoma.** It is often asymptomatic until late disease. The clinical presentation includes weight loss, early satiety, new-onset diabetes, abdominal pain, pruritus, jaundice, generalised malaise, fatigue, anorexia,

pale stool, dark urine, positive Courvoisier's sign (palpable gallbladder), cachexia. Laboratory findings are: high direct bilirubin, elevated alkaline phosphatase and gamma-glutamyltranspeptidase, elevated CEA (carcinoembryonic antigen) and CA 19-9. Abdominal ultrasound reveals pancreatic mass and dilated common bile duct and pancreatic duct. Abdominal CT demonstrates more precisely the presence of pancreatic mass, dilatation of bile ducts and pancreatic ducts, presence of metastases. ERCP shows bile ducts and pancreatic duct strictures.

**Cholangiocarcinomas (CCs)** are malignancies of the biliary duct system that may originate in the liver and extrahepatic bile ducts, which terminate at the ampulla of Vater. CCs are encountered in three anatomic regions: intrahepatic, extrahepatic (i.e., perihilar), and distal extrahepatic. Perihilar tumors are the most common CCs, and intrahepatic tumors are the least common. Perihilar tumors, also called Klatskin tumors, occur at the bifurcation of the right and left hepatic ducts. Distal extrahepatic tumors are located from the upper border of the pancreas to the ampulla. More than 95% of these tumors are ductal adenocarcinomas. Many patients present with unresectable or metastatic disease. CCs are typically manifested with jaundice, intensive pruritus, weight loss, and abdominal pain. Laboratory findings are: high direct bilirubin, alkaline phosphatase, and gamma-glutamyltranspeptidase, low or normal platelet count, Hb, and hematocrit. MRCP and ERCP demonstrate the presence of biliary stricture. Endoscopic ultrasonography (EUS) enables both bile duct visualization and nodal evaluation. This technique also has the capability to aspirate for cytologic studies. EUS-guided fine-needle aspiration results may be positive when other diagnostic tests are inconclusive.

**Ampullary carcinoma** is a rare malignant tumor originating at the ampulla of Vater, in the last centimeter of the common bile duct, where it passes through the wall of the duodenum and ampullary papilla. Patients typically present with symptoms related to biliary obstruction. Oncological serum markers (CA 19-9 and CEA) are not specific and may have a role in assessing response to therapy and/or predicting tumor recurrence. Abdominal ultrasound is the initial study to evaluate dilatation of the common bile duct or pancreatic duct. CT scan often demonstrates a mass but is not helpful in differentiating ampullary carcinoma from tumors of the head of the pancreas or periampullary region. Both ultrasound and CT can help reveal metastatic disease in the liver or regional lymph nodes. Endoscopic ultrasound allows visualization of the duodenal wall, ampulla, bile duct, and pancreatic duct, regional lymph nodes, celiac and superior mesenteric vessels to evaluate for vascular invasion. It can facilitate biopsy of the tumor

via fine needle aspiration (FNA) and is also used to evaluate regional lymph nodes for lymph node metastasis. ERCP findings to suggest pancreatic cancer are as follows: irregular pancreatic duct narrowing, displacement of the main pancreatic duct, destruction or displacement of the side branches of the duct, pooling of contrast material in necrotic areas of tumor.

## BIBLIOGRAPHY

1. Bolton-Maggs P.H., Langer J.C., Iolascon A., et al. Guidelines for the diagnosis and management of hereditary spherocytosis – 2011 update. *Br J Haematol* 2012; 156(1): 37-49.
2. Darwin P. E. Cholangiocarcinoma. <https://emedicine.medscape.com/article/277393-overview> (accessed 12.11.2017)
3. Fargo M.V., Groan S.T.P., Saguil A. Evaluation of jaundice in adults. *Am Fam Physician* 2017; 95 (3):164-168.
4. Jansen P.L. Diagnosis and management of Crigler-Najjar syndrome. *Eur J Pediatr* 1999; 158 (Suppl 2): S89-94.
5. Memon N., Weinberger B.I., Hegyi T., Aleksunes L.M. Inherited disorders of bilirubin clearance. *Pediatr Res* 2016; 79(3): 378-386.
6. Monaghan G., Ryan M., Seddon R., et al. Genetic variation in bilirubin UPD-glucuronosyltransferase gene promoter and Gilbert's syndrome. *Lancet* 1996; 347(9001): 578–81.
7. Olsson R., Bliding A., Jagenburg R., et al. Gilbert's syndrome—does it exist? A study of the prevalence of symptoms in Gilbert's syndrome. *Acta Med Scandinavia* 1988; 224 (5): 485–490.
8. Pashankar D., Schreiber R.A. Jaundice in older children and adolescents. *Pediatr Rev* 2001; 22: 219–26.
9. Radoi V.E., Ursu R.I., Poenaru E., et al. Frequency of the UGT1A1\*28 polymorphism in a Romanian cohort of Gilbert syndrome individuals. *J Gastrointestin Liver Dis* 2017; 26 (1): 25-28.
10. Roche S.P., Kobos R. Jaundice in the adult patient. *Am Fam Physician* 2004; 69(2): 299-304. <https://www.aafp.org/afp/2004/0115/p299.html> (accessed 14.11.2017)
11. Roy-Chowdhury J., Roy-Chowdhury N., Listowsky I., Wolkoff A.W. Drug- and drug abuse-associated hyperbilirubinemia: experience with atazanavir. *Clin Pharmacol Drug Dev* 2017; 6(2):140-146.



## DIFFERENTIAL DIAGNOSIS OF PORTAL HYPERTENSION AND ITS COMPLICATIONS

**DEFINITION.** Portal hypertension is defined as an increase in blood pressure in the portal venous system. The portal pressure is estimated indirectly by the hepatic venous pressure gradient (HVPG) — the gradient between the wedged (or occluded) hepatic venous pressure (WHVP) and the free hepatic venous pressure (FHVP). A normal hepatic venous pressure gradient is less than 5 mm Hg. A catheter should be placed by either a transjugular or transfemoral approach into the hepatic vein. Then a free hepatic vein pressure (FHVP) is measured. A balloon is then used to wedge the catheter in the hepatic vein and a second pressure is taken. This wedged hepatic vein pressure (WHVP) is the sinusoidal pressure and in most cases a good reflection of the portal pressure. The HVPG is then the difference between WHVP and FHVP.

A **direct** measurement of portal pressure can be obtained by:

- laparotomy and direct placement of a catheter into the portal vein
- passing a catheter through the liver into the portal system
- splenic pulp pressure (passing a needle percutaneously into the spleen)
- umbilical vein catheterization.

An **indirect** way to assess for portal hypertension is to perform an upper endoscopy. The presence of esophageal varices and/or portal gastropathy indicates the presence of portal hypertension. Clinically significant portal hypertension is when HVPG is more than 10mmHg.

**PATHOPHYSIOLOGY.** As pressure increases, blood flow decreases and the pressure in the portal system is transmitted to its branches. This results in dilation of venous tributaries. Increased blood flow through collaterals and subsequently increased venous return cause an increase in cardiac output and total blood volume and a decrease in systemic vascular resistance. Blood pressure usually falls with the progression of disease.

Pathophysiology of portal hypertension is complex and involves resistance to portal flow at the level of sinusoids and an increase in portal flow caused by hyperdynamic circulation. The increased resistance to portal flow at the level of the sinusoids is caused by contraction of vascular smooth muscle cells and myofibroblasts, and disruption of blood flow by scarring and the formation of parenchymal nodules. Alterations in sinusoidal



endothelial cells that contribute to the intrahepatic vasoconstriction associated with portal hypertension include a decrease in nitric oxide (NO) production, and increased release of endothelin-1 (ET-1), angiotensinogen, and eicosanoids.

Another major factor in the development of portal hypertension is an increase in portal venous blood flow resulting from a hyperdynamic circulation. This is caused by arterial vasodilation, primarily in the splanchnic circulation. The increased splanchnic arterial blood flow in turn leads to increased venous efflux into the portal venous system. While various mediators such as prostacyclin and TNF have been implicated in the causation of the splanchnic arterial vasodilation, NO emerges as the most significant one.

The vasodilators liberated in portal hypertension (glucagon, VIP, substance P, prostacyclins, NO, etc.) also lead to a fall in systemic blood pressure. This will cause a compensatory rise in cardiac output, resulting in hyperperfusion of the abdominal organs and the collateral (bypass) circuits.

Thus, the main pathogenetic mechanisms of PHT include:

1. Increased intrahepatic vascular resistance and portal–splanchnic blood flow
2. Splanchnic and systemic arterial vasodilation
3. Splanchnic arterial vasodilation leads to increased portal blood flow and thus elevated portal hypertension
4. An increased hepatic venous pressure gradient leads to the formation of portosystemic venous collaterals.

**CLASSIFICATION** (based on the location of the increased resistance):

*Prehepatic causes*

- Portal vein thrombosis
- Splenic vein thrombosis
- Congenital atresia or stenosis of portal vein
- Extrinsic compression (tumors)
- Splanchnic arteriovenous fistula

*Intrahepatic predominantly presinusoidal causes*

- Schistosomiasis (early stage)
- Primary biliary cirrhosis (early stage)
- Myeloproliferative diseases – via direct infiltration by malignant cells
- Polycystic disease
- Hepatic metastasis

- Granulomatous diseases (sarcoidosis, tuberculosis)

*Intrahepatic predominantly sinusoidal causes*

- Hepatic cirrhosis
- Acute alcoholic hepatitis
- Schistosomiasis (advanced stage)
- Primary biliary cirrhosis (advanced stage)
- Acute and fulminant hepatitis
- Congenital hepatic fibrosis
- Vitamin A toxicity
- Sclerosing cholangitis
- Wilson disease
- Hemochromatosis
- Alpha-1 antitrysin deficiency
- Chronic active hepatitis

*Intrahepatic postsinusoidal obstruction*

- Veno – occlusive disease of liver

*Posthepatic causes*

- Thrombosis of the inferior vena cava
- Right – sided heart failure
- Constrictive pericarditis
- Severe tricuspid regurgitation
- Budd – Chiari syndrome
- Arterial – portal venous fistula

**Complications of portal hypertension** include:

- Ascites
- Hepatic encephalopathy
- Variceal hemorrhage
- Spontaneous bacterial peritonitis
- Hepatorenal syndrome
- Portal hypertensive gastropathy
- Hepatic hydrothorax
- Hepatopulmonary syndrome
- Portopulmonary hypertension
- Cirrhotic cardiomyopathy

**Ascites** is the accumulation of fluid within the peritoneal cavity. The first step leading to fluid retention and ultimately ascites in patients with cirrhosis is the development of portal hypertension. Ascites usually becomes clinically detectable when at least 500 mL have been accumulated. The

fluid is generally serous, having less than 3 gm/dL of protein (largely albumin), and a serum to ascites albumin gradient of  $\geq 1.1$  gm/dL.

Although the mechanisms responsible for the development of ascites are not completely understood, several factors seem to contribute to fluid accumulation, including an increase in hydrostatic capillary pressure due to portal hypertension and obstruction of venous flow through the liver (hydrostatic mechanism), salt and water retention by the kidney (osmotic mechanism), decreased oncotic pressure due to impaired synthesis of albumin by the liver (hypoalbuminemic mechanism), impairment of lymphatic drainage (lymphostatic mechanism) and direct increased permeability of vessel walls (membranous mechanism).

The effective blood volume may be reduced because of loss of fluid into the peritoneal cavity as well as edema or because of vasodilatation caused by the presence of circulating vasodilating substances. Arterial vasodilation in the splanchnic circulation tends to reduce arterial blood pressure. This triggers the activation of vasoconstrictors, including the renin-angiotensin system, and also increases the secretion of antidiuretic hormone. The combination of portal hypertension, vasodilation, and sodium and water retention increases the perfusion pressure of interstitial capillaries, causing extravasation of fluid into the abdominal cavity.

**Differential diagnosis of ascites.** In 80-85% of cases of ascites are related to underlying chronic liver disease, but cardiac failure, tuberculosis, malignancy-related ascites and other less common causes should always be considered. Careful evaluation of the patient, including the clinical history, physical examination and diagnostic paracentesis should routinely be performed to determine the cause of ascites. Fluid should be sent for cell count and albumin along with simultaneous determination of serum albumin to determine the serum: ascites albumin gradient.

*Ascites in heart failure.* It is a common and late stage complication of both high- and low-output heart failure. Accompanying symptoms and signs include pitting edema, dyspnea, jugular vein distension and hepatomegaly.

*Ascites in nephrotic syndrome* is a rare cause of ascites in adults. This includes massive proteinuria ( $>3.5$  g/24h), hypoalbuminemia, hyperlipidemia, and massive edemas (anasarca). Other symptoms may include weight gain, and foamy urine. The complications may include thromboembolic events, infections, and hypertension. The main causes of nephritic syndrome include focal segmental glomerulosclerosis, membranous

nephropathy, minimal change disease, malignancies and diabetes mellitus. The diagnosis is typically based on urine testing and sometimes a kidney biopsy. Nephrotic syndrome edema initially appears in parts of the lower body (such as the legs) and in the eyelids. In the advanced stages it also extends to the pleural cavity and peritoneum (ascites) and can even develop into a generalized anasarca.

*Nephrogenous ascites* is a poorly understood condition that develops with hemodialysis; its optimal treatment is undefined and its prognosis is poor. Continuous ambulatory peritoneal dialysis is an iatrogenic form of ascites that takes advantage of the rich vascularity of the parietal peritoneum to promote elimination of endogenous toxins and control fluid balance. Urine may accumulate in the peritoneum in newborns or as a result of trauma or renal transplantation in adults.

*Ascites in malignancy* signifies advanced disease in most cases and is associated with a dismal prognosis. Exceptions are ovarian carcinoma and lymphoma, which may respond to debulking surgery and chemotherapy, respectively. The mechanism of ascites formation depends on the location of the tumor. Peritoneal carcinomatosis produces exudation of proteinaceous fluid into the peritoneal cavity, whereas liver metastases or primary hepatic malignancy induces ascites likely by producing portal hypertension, either from vascular occlusion by the tumor or arteriovenous fistulae within the tumor. Malignancy-related ascites in patients with underlying liver disease is usually due to hepatocellular carcinoma (HCC) rather than liver metastases. The development of ascites may be the first indication of a primary HCC.

Ascites is a common complication of certain malignancies including cancer of the ovary, breast, colon, lung, pancreas, and liver. Lymphoma can be complicated by chylous ascites. There is no single laboratory test (other than positive ascitic fluid cytology) that can make the diagnosis of malignancy-related ascites. The diagnosis is based upon the clinical setting, ascitic fluid analysis, and imaging tests, testing serum for CA 125 levels since the results may be misleading and result in unnecessary evaluation. The diagnosis of ovarian cancer should be made based upon cytology. In patients with portal hypertension due to massive liver metastases, cirrhosis with hepatocellular carcinoma, or malignant Budd-Chiari syndrome, a serum-ascites albumin gradient is  $\geq 1.1$  g/dL.

*Ascites in malabsorption.* Hypoalbuminemia due to chronic protein malabsorption or loss of protein in the intestinal lumen causes peripheral

edema. Extensive obstruction of the lymphatic system, as seen in intestinal lymphangiectasia, can cause protein loss, leading to ascites.

*Ascites in sepsis* is commonly a part of polyserositis including also bilateral pleurisy and pericardial effusion (15% of patients), presumably because of decreased ascitic fluid opsonic activity. The following studies help to detect a clinically suspected focal infection, the presence of a clinically occult focal infection, and complications of sepsis and septic shock:

- Complete blood count with differential diagnosis
- Coagulation studies (e.g., prothrombin time, activated partial thromboplastin time, fibrinogen levels)
- Blood chemistry (e.g., sodium, chloride, magnesium, calcium, phosphate, glucose, lactate)
- Renal and hepatic function tests (e.g., creatinine, blood urea nitrogen, bilirubin, alkaline phosphatase, alanine aminotransferase, aspartate aminotransferase, albumin, lipase)
- Blood cultures
- Urinalysis and urine cultures
- Gram stain and culture of secretions and tissue
- Elevated serum procalcitonin (more than 2 ng/mL)

**Spontaneous bacterial peritonitis** is a complication in patients with both cirrhosis and ascites. Presumably, the peritoneal fluid is seeded with bacteria from the blood or lymph or from translocation of bacteria through the bowel wall. Spontaneous bacterial peritonitis (SBP) is an infection of preexisting ascitic fluid without evidence for an intra-abdominal secondary source, such as a perforated inner organ (e.g., stomach). Clinical manifestations include fever, abdominal pain, abdominal tenderness, and altered mental status. Some patients are asymptomatic and present with only mild laboratory abnormalities. It is diagnosed by a neutrophil count of 250 cells/mm<sup>3</sup> or higher and a protein concentration of 1 g/dL or less in the ascitic fluid. The diagnosis is made by positive ascitic fluid bacterial culture and/or elevated ascitic fluid absolute polymorphonuclear leukocyte placed in patients with hepatic hydrothorax.

**Hepatic encephalopathy.** Hepatic encephalopathy (HE) refers to the totality of central nervous system manifestations of liver failure. In acute liver failure there is a characteristic sudden change in consciousness with increased intracranial pressure and massive cerebral edema which can lead to cerebral herniation and death. Chronic hepatic failure is characterized by neural disturbances ranging from a lack of mental alertness to confusion,

coma, and convulsions. A very early sign of hepatic encephalopathy is the flapping tremor called asterixis. *Asterixis* is manifested as non-rhythmic, rapid extension-flexion movements of the head and extremities, best seen when the arms are held in extension with dorsiflexed wrists. Various degrees of memory loss, coupled with personality changes such as euphoria, irritability, anxiety, and lack of concern about personal appearance and self may occur. Speech may be impaired, and the patient may be unable to perform certain purposeful movements. Encephalopathy may progress to decerebrate rigidity and then to a terminal deep coma. Hepatic encephalopathy develops in approximately 10% of persons with portosystemic shunts.

Ammonia is considered a key pathogenic factor in development of HE. In 90% of patients with HE the level of ammonia in the blood is elevated. A particularly important function of the liver is the conversion of ammonia, by a product of protein and amino acid metabolism, to urea. The ammonium ion is produced in abundance in the intestinal tract, particularly in the colon, by the bacterial degradation of luminal proteins and amino acids. Normally, these ions diffuse into the portal blood and are transported to the liver, where they are converted to urea before entering the general circulation. When the blood from the intestine bypasses the liver or the liver is unable to convert ammonia to urea, ammonia moves directly into the general circulation and from there to the cerebral circulation. Hepatic encephalopathy may become worse after a large protein meal or gastrointestinal tract bleeding. The diagnosis requires the detection of signs suggestive of HE in a patient with severe liver insufficiency and/or portosystemic shunting, who does not have obvious alternative causes of brain dysfunction. The recognition of precipitating factors for HE (e.g. infection, bleeding, constipation) supports the diagnosis of HE. The differential diagnosis should consider common disorders altering the level of consciousness.

The neurological manifestations of HE are nonspecific. Therefore, concomitant disorders have to be considered as an additional source of central nervous system dysfunction in any patient with chronic liver disease. Renal dysfunction, hyponatremia, diabetes mellitus, sepsis and thiamine deficiency (Wernicke's encephalopathy), are the most important noteworthy intracranial bleeding is also. Neurological symptoms are observed in 21–33% of patients with cirrhosis with sepsis and in 60–68% of those with septic shock. Rare but difficult cases may be due to Wilson disease. Patients with alcohol disorder and no clinical liver disease have been shown to

exhibit deficits in episodic memory, working memory and executive function and lower limb motor skills. Patients with primary biliary cholangitis and primary sclerosing cholangitis may have severe fatigue and impairment of attention, concentration and psychomotor function irrespective of the grade of liver disease.

*Differential diagnosis in uremic encephalopathy.* It develops in patients with acute or chronic renal failure, usually when the estimated glomerular filtration rate (eGFR) falls and remains below 15 mL/min. Manifestations of this syndrome vary from mild symptoms (e.g., lassitude, fatigue) to severe signs (e.g., seizures, coma). Severity and progression depend on the rate of decline in renal function; thus, symptoms are usually worse in patients with acute kidney injury. The clinical manifestations of uremic encephalopathy include fatigue, muscle weakness, malaise, headache, restless legs, asterixis, polyneuritis, mental status changes, muscle cramps, seizures, stupor, and coma. More severe signs and symptoms of uremic encephalopathy include the following: vomiting, emotional volatility, decreased cognitive function, disorientation, confusion, stupor, coma.

*The differential diagnosis in alcoholic coma.* The onset of polyneuropathy is insidious and prolonged, but some cases are associated with acute, rapidly progressive onset. Severe cases of alcoholic neuropathy can lead to the development of symptoms in the proximal lower extremities and distal upper extremities. Patients with alcoholic neuropathy typically present with a history of chronic consumption of alcohol and an insidious onset of distal lower extremity paresthesias, dysesthesias, or weakness. The most common presenting complaint seems to be paresthesias in the feet and toes. Over time, these symptoms usually progress proximally and symmetrically. Less commonly, patients present with a more rapid, acute onset of symptoms. Serum ethanol levels are as follows Negative: no alcohol detected, lower limit of detection is 10 mg/dL >80 mg/dL (>17.4 mmol/L) and it is considered positive for driving under the influence in most states >300-400 mg/dL (65.1-86.8 mmol/L) coma, potentially fatal.

The differential diagnosis in *hypoglycemia coma* is characterized by a reduction of glucose concentration in plasma to a level that may induce symptoms or signs such as altered mental status and/or sympathetic nervous system stimulation. This condition typically arises from abnormalities in the mechanisms involved in glucose homeostasis. The glucose level at which an individual becomes symptomatic is highly variable (threshold generally at < 50 mg/dL). Carefully review the patient's medication and



drug history for potential causes of hypoglycemia (e.g., new medications, insulin usage or ingestion of an oral hypoglycemic agent, possible toxic ingestion). Neurogenic or neuroglycopenic symptoms of hypoglycemia may be categorized as follows: neurogenic (adrenergic) (sympathoadrenal activation) symptoms including sweating, shakiness, tachycardia, anxiety, and a sensation of hunger. Neuroglycopenic symptoms: weakness, tiredness, or dizziness; inappropriate behavior (sometimes mistaken for inebriation), difficulty with concentration; confusion; blurred vision; and, in extreme cases, coma and death.

*Differential diagnosis in diabetic coma.* It is a complex disordered metabolic state characterized by hyperglycemia, ketoacidosis, and ketonuria. The symptoms of hyperglycemia associated with diabetic ketoacidosis (DKA) may include increased polydipsia and polyuria. Malaise, generalized weakness, and fatigability can also present as the symptoms of DKA. Nausea and vomiting usually occur and may be associated with diffuse abdominal pain, decreased appetite, and anorexia. A history of rapid weight loss is a symptom in patients who are newly diagnosed with type 1 diabetes. Patients may present with a history of failure to comply with insulin therapy or missed insulin injections due to vomiting or psychological reasons. Altered consciousness in the form of mild disorientation or confusion can occur. Although frank coma is uncommon, it may occur when the condition is neglected or if dehydration or acidosis is severe.

*The differential diagnosis in stroke* patients with intracerebral hemorrhage are more likely than those with ischemic stroke to have headache, altered mental status, seizures, nausea and vomiting, and/or marked hypertension. Even so, none of these findings reliably distinguishes between hemorrhagic and ischemic stroke. *Focal neurologic deficits:* the type of deficit depends on the area of brain involved. If the dominant (usually the left) hemisphere is involved, a syndrome consisting of the following may result: right hemiparesis, right hemisensory loss, left gaze preference, right visual field cut and aphasia. If the nondominant (usually the right) hemisphere is involved, a syndrome consisting of the following may result: left hemiparesis, left hemisensory loss, right gaze preference, left visual field cut. Either noncontrast computed tomography scanning or magnetic resonance imaging is the modality of choice.

*Differential diagnosis in hyponatremia.* Serum sodium concentration and serum osmolarity normally are maintained under precise control by homeostatic mechanisms involving stimulation of thirst, secretion of antidiuretic hormone (ADH), and renal handling of filtered sodium. Hyponatremia is



physiologically significant when it indicates a state of extracellular hyposmolarity and tendency for free water to shift from the vascular space to the intracellular space. Although cellular edema is well tolerated by most tissues, it is not well tolerated within the rigid confines of the bony calvarium. Therefore, clinical manifestations of hyponatremia are related primarily to cerebral edema. When serum sodium concentration falls slowly, over a period of several days or weeks, the brain is capable of compensating by extrusion of solutes and fluid to the extracellular space. Compensatory extrusion of solutes reduces the flow of free water into the intracellular space, and symptoms are much milder for a given degree of hyponatremia. When serum sodium concentration falls rapidly, over a period of 24-48 hours, this compensatory mechanism is overwhelmed and severe cerebral edema may ensue, resulting in brainstem herniation and death. The number and severity of symptoms increase with the degree of hyponatremia and the rapidity with which it develops. When the serum sodium level falls gradually, over a period of several days or weeks, sodium levels as low as 110 mEq/L may be reached with minimal symptomatology. In contrast, an equivalent fall in serum sodium level over 24-48 hours may overwhelm compensatory mechanisms, leading to severe cerebral edema, coma, or brainstem herniation. The symptoms range from mild anorexia, headache, and muscle cramps, to significant alteration in mental status including confusion, obtundation, coma, or status epilepticus.

**Variceal hemorrhage.** The hypertensive portal vein is decompressed by diverting up to 90% of the portal flow through portosystemic collaterals back to the heart, resulting in enlargement of these vessels. These vessels are commonly located at the gastroesophageal junction, where they lie adjacent to the mucosa and present as gastric and esophageal varices. Varices are formed when the HVPG exceeds 10 mm Hg. They usually do not bleed unless the HVPG exceeds 12 mm Hg. Patients with variceal hemorrhage typically present with hematemesis and/or melena. It is typically treated with endoscopic variceal band ligation. Other treatments include endoscopic sclerotherapy and placement of a transjugular intrahepatic portosystemic shunt (TIPS). Variceal hemorrhage is associated with high mortality rates. In the past, the mortality rate of a single variceal hemorrhage was 30 percent, and only one-third of patients survived for one year. Although the survival has improved with modern techniques for controlling variceal hemorrhage, mortality rates remain high.

*Differential diagnosis with lung hemorrhage* may occur with renal disease

or in isolation. Presenting symptoms may include cough and hemoptysis, but hemorrhage into alveolar spaces may result in marked iron deficiency anemia and exertional dyspnea, even in the absence of hemoptysis. Depending on the degree and chronicity of lung hemorrhage, examination findings may include pallor, dry inspiratory crackles, signs of consolidation, or respiratory distress. Recent lung hemorrhage typically is shown on the radiograph as central shadowing that may traverse fissures and give rise to the appearance of an air bronchogram. However, even lung hemorrhage sufficient to reduce the hemoglobin concentration may cause only minor or transient radiographic changes, and these cannot be confidently distinguished radiologically from other causes of alveolar shadowing (notably edema, infection). The most sensitive indicator of recent lung hemorrhage is an increased uptake of inhaled carbon monoxide (DlCo).

*Differential diagnosis with nasal hemorrhage (epistaxis)* is hemorrhage from the nostril, nasal cavity, or nasopharynx. Controlling significant bleeding or hemodynamic instability should take precedence over obtaining a lengthy history. Note the duration, severity of the hemorrhage, and the side of initial bleeding. Inquire about previous epistaxis, hypertension, hepatic or other systemic disease, family history, easy bruising, or prolonged bleeding after minor surgical procedures. Recurrent episodes of epistaxis, even if self-limited, should raise suspicion for significant nasal pathology. Use of medications, especially aspirin, nonsteroidal anti-inflammatory drugs (NSAIDs), warfarin, heparin, ticlopidine, and dipyridamole should be documented, as these not only predispose to epistaxis but make treatment more difficult. Perform methodical examination of the nasal cavity. Gently insert a nasal speculum and spread the naris vertically. This permits visualization of most anterior bleeding sources. Approximately 90% of nosebleeds can be visualized in the anterior portion of the nasal cavity. Massive epistaxis may be confused with hemoptysis or hematemesis. Blood dripping from the posterior nasopharynx confirms a nasal source. A posterior bleeding source is suggested by failure to visualize an anterior source, hemorrhage from both nares, and by visualization of blood draining in the posterior pharynx.

**Portal hypertensive gastropathy** (congestive gastropathy), while extremely common in patients with portal hypertension, is an uncommon cause of significant bleeding in these patients. When portal hypertensive gastropathy is the sole cause of bleeding, there is diffuse mucosal oozing with no other lesions, such as varices, to account for the GI bleeding and

anemia. The mucosa is friable, and bleeding presumably occurs when the ectatic vessels rupture. The severity of gastropathy is related to the level of portal pressure, the level of hepatic vascular resistance, and the degree of reduction in hepatic blood flow.

**Hepatic hydrothorax** is defined as the presence of a pleural effusion in a patient with cirrhosis and no evidence of underlying cardiopulmonary disease. It results from the movement of ascitic fluid into the pleural space through defects in the diaphragm, and it is usually right-sided. The treatment for hepatic hydrothorax includes diuretics and sodium restriction. Patients who do not respond to conservative therapy may require repeated therapeutic thoracenteses or TIPS. The most important aspect of management is evaluation for liver transplantation. Chest tubes should **not** be placed in patients with hepatic hydrothorax. The placement of chest tubes in this setting can result in massive protein and electrolyte depletion, infection, renal failure, and bleeding.

**Hepatopulmonary syndrome (HPS)** is defined by the presence of the following:

- Liver disease
- Presence of platypnea and ortodeoxia (dyspnea that is accentuated by standing or sitting positions due to a marked fall in blood oxygen saturation, and is improved by assuming the lying position)
- Increased alveolar-arterial gradient while breathing room air suggesting a right-to-left shunt
- Evidence for intrapulmonary vascular dilatations (confirmed by contrast-enhanced Ecocardiography).

The blood flows rapidly through such dilated vessels, giving inadequate time for oxygen diffusion and leading to ventilation-perfusion mismatch and right-to-left shunting, manifesting as hypoxia. Hypoxia and resultant dyspnea occur preferentially in an upright position rather than in the recumbent position, as gravity exacerbates the ventilation-perfusion mismatch. The pathogenesis of hepatopulmonary syndrome is unclear, although it has been postulated that the diseased liver may not clear vasoconstrictors such as endothelin-1 or may produce some vasodilators such as NO. Patients with this syndrome have a poorer prognosis than patients without hepatopulmonary syndrome.

**Portopulmonary hypertension.** Portal hypertension-associated pulmonary hypertension (portopulmonary hypertension) refers to the presence of pulmonary hypertension in patients with portal hypertension. Neither

the prevalence nor the severity of portopulmonary hypertension appears to correlate with the degree of portal hypertension. Patients with portopulmonary hypertension may present with fatigue, dyspnea, peripheral edema, chest pain, and syncope. The most common clinical manifestations are dyspnea on exertion and clubbing of the fingers. It seems to depend on concomitant portal hypertension and excessive pulmonary vasoconstriction and vascular remodeling. The diagnosis may be suggested by echocardiography and confirmed by right heart catheterization. Patients with moderate to severe portopulmonary hypertension are difficult to treat with medical therapy, and the perioperative mortality with liver transplantation is high.

**Hepatorenal syndrome (HRS)** refers to a functional renal failure sometimes seen during the terminal stages of liver failure with ascites. It is characterized by progressive azotemia, increased serum creatinine levels, and oliguria. In liver cirrhosis, congestion in the portal venous system due to narrowing of the vascular bed within the liver occurs initially. The hydrostatic pressure in the capillaries rises and excessive amounts of fluid are filtered into the abdominal cavity (ascites). Because of the high protein permeability of the liver sinusoid, plasma proteins are also lost into the extracellular space. In liver cirrhosis the loss of liver parenchyma and the increased amount of blood passing from the portal circulation directly into the systemic circulation, short-circuiting the liver, brings those substances into the systemic circulation unhindered. The mediators have a direct vasodilator effect, while the endotoxins exert a vasodilator effect by stimulating the expression of nitric oxide synthase (iNOS). This may lead to a fall in blood pressure, causing massive sympathetic stimulation. This, together with the hypovolemia, results in diminished renal perfusion and thus a fall in GFR. The reduced renal blood flow promotes the release of renin and thus the formation of angiotensin II, aldosterone and ADH. ADH and aldosterone increase the tubular reabsorption of water and sodium chloride (loss of potassium), and the kidney excretes small volumes of highly concentrated urine (oliguria).

### **Cirrhotic cardiomyopathy**

Cirrhotic cardiomyopathy is a cardiac condition developing in patients with liver cirrhosis. It is characterized by the impaired systolic response to physical stress, diastolic dysfunction, and electrophysiological abnormalities. The impairment of  $\beta$ -adrenergic receptor, the increase in endogenous cannabinoids, the presence of cardiosuppressants such as nitric oxide and inflammatory cytokines are the proposed mechanisms of systolic dysfunc-

tion. The activation of cardiac renin-angiotensin system and salt retention have a major role in the development of cardiac hypertrophy and impaired diastolic function. QT interval prolongation occurs as a result of the derangement in membrane fluidity and ion channel defect. The correct diagnosis of this condition prevents the complications of overt heart failure after procedures such as transjugular intrahepatic portosystemic shunt and liver transplantation.

Several ways to diagnose cirrhotic cardiomyopathy with normal ejection fraction at rest have been proposed:

- 1) examination of systolic function. Patients have documented blunted responsiveness to volume and postural challenge, exercise, or pharmacological infusion;
- 2) examination of diastolic function. The diagnosis of left ventricle diastolic dysfunction can be obtained by Tissue Doppler imaging – TDI, which reveals Peak E-wave transmitral/early diastolic mitral annular velocity ratio ( $E/e'$ )  $> 15$ .
- 3) examination of electrophysiological abnormalities:
  - a) the prolongation of the electrocardiographic corrected QT interval;
  - b) electromechanical uncoupling, which is a dyssynchrony between electrical and mechanical systole (the electrical systole is longer in patients with cirrhosis);
  - c) chronotropic incompetence is the inability of the heart to proportionally increase heart rate in response to stimuli (exercise, tilting, paracentesis, infections and pharmacological agents).

The diagnosis of cirrhotic cardiomyopathy is established in the absence of cardiomyopathies of other origin (see Differential diagnosis of non-ischaemic cardiomyopathies).

## BIBLIOGRAPHY

1. Fallon M.B., Abrams G.A. Pulmonary dysfunction in chronic liver disease. *Hepatology*, 2000, vol. 32(4), p. 859-865.
2. Hourani J.M., Bellamy P.E., Tashkin D.P., et al. Pulmonary dysfunction in advanced liver disease: Frequent occurrence of an abnormal diffusing capacity. *American Journal of Medicine*, 2002, vol. 90(6), p. 693-700.
3. Martínez G.P., Barberà J.A., Visa J., et al. Hepatopulmonary syndrome in candidates for liver transplantation. *Journal of Hepatology*, 2007, vol. 34(5), p. 651-657.

4. Herve P., Le Pavec J., Sztrymf B., et al. Pulmonary vascular abnormalities in cirrhosis. *Best Practice & Research Clinical Gastroenterology*, 2006, vol. 21(1), p. 141-159.
5. Rodríguez-Roisin R., Krowka M.J. Hepatopulmonary Syndrome — A Liver-Induced Lung Vascular Disorder. *New England Journal of Medicine*, 2008, vol. 358(22), p. 2378-2387.
6. Rodríguez-Roisin R., Krowka M.J., Hervé P., et al. Pulmonary-Hepatic Vascular Disorders (PHD). *European Respiratory Journal*, 2004, vol. 24(5), p. 861-880.
7. Gaines D.I., Fallon M.B. Hepatopulmonary syndrome. *Liver International*, 2004, vol. 24(5), p. 397-401.
8. Alessandria C., Ozdogan O., Guevara M. et al. MELD score and clinical type predict prognosis in hepatorenal syndrome: relevance to liver transplantation. *Hepatology* 2005; 41: 1282–9.
9. Wiesner R., Edwards E., Freeman R. et al. Model for end-stage liver disease (MELD) and allocation of donor livers. *Gastroenterology* 2003; 124: 91–6.
10. Wong F., Recent advances in our understanding of hepatorenal syndrome. *Nat Rev Gastroenterol Hepatol* 2012; 9: 382–91.
11. Gerbes A.L., Liver cirrhosis and kidney. *Dig. Dis* 2016; 34: 387–90.
12. Piano S., Rosi S., Maresio G. et al. Evaluation of the Acute Kidney Injury Network criteria in hospitalized patients with cirrhosis and ascites. *J Hepatol* 2013; 59: 482–9.
13. Tsien C.D., Rabie R., Wong F. Acute kidney injury in decompensated cirrhosis. *Gut* 2013; 62:131–7.
14. <https://orcid.org/my-orcid> (accessed 08.11.2018).
15. <https://www.researchgate.net> (accessed 08.11.2018).

# DIFFERENTIAL DIAGNOSIS OF ARTHRITIS

**Introduction.** Arthritis signals the onset of a rheumatic disease in most cases, although many non-rheumatic conditions may develop with this syndrome. Arthritis represents 20-30% of the workload of the primary care physician.

**Definition.** Arthritis is the presence of symptoms and signs of inflammation localized in the joint: pain, hyperthermia, hyperemia, swelling, loss of function. The symptoms may occur simultaneously or can succeed.

## Classification of arthritis

**1. According to etiology** (hereditary, congenital, traumatic, physical, chemical, infectious (bacterial, viral, mycoplasmas, fungal), inflammatory (autoimmune/ autoinflammatory, tumoral), vascular, metabolic, nutritional, psychogenic, iatrogenic, mixt, idiopathic)

**2. According to onset/duration of arthritis**

2.1. Acute arthritis – hours

2.2. Subacute arthritis days –  $\leq 6$  weeks

2.3. Chronic arthritis  $\geq 6$  weeks

**3. According to the course of arthritis**

3.1. Intermittent arthritis with return to baseline

3.2. Arthritis with gradual progression over the time with acute exacerbations

3.3. Arthritis with slow progression over time

**4. According to the pattern of joint involvement**

4.1. Monoarticular arthritis – involvement of one joint:

4.1.1. Acute monoarticular arthritis (crystal arthritis [gout, pseudogout, calcifica periarthritis], septic arthritis, haemarthrosis, traumatic synovitis, foreign-body synovitis-plant thorn, infections (bacterial, mycobacterial, viral, Lyme disease)

4.1.2. Chronic monoarticular arthritis (degenerative, mycobacterial).

4.2. Oligoarthicular/pauciarticular arthritis – 2-4 joints involved (seronegative, crystal-induced, infectious arthritis)

4.3. Asymmetrical oligoarthritis (psoriatic arthritis)

4.4. Polyarthicular arthritis – when more than 4 joints are involved (rheumatoid arthritis, adult, childhood Still's disease, palindromic arthritis, reactive arthritis, Reiter's disease, rheumatic fever, gonococcal arthritis, postviral arthropathy-rubella, HIV, parvovirus, hepatitis B, C, psoriatic arthritis, systemic lupus erythematosus, paraneoplastic syndromes, rheumatic polymyalgia).

## PATHOPHYSIOLOGY

**Immune mechanisms of arthritis** include the following: abnormal types or amounts of serum immunoglobulins/antibodies, antibodies function by binding their ligand (antigen) and destroying it, antibody production is normally under control of T suppressor lymphocytes, failure of T-cell suppressor function leading to production of abnormal antibodies. Antibodies can cause the disease by two main mechanisms: cytotoxic mechanism (a type II immune reaction) and -antibodies production against inappropriate targets (e.g., normal tissues). Immune complex mechanism (a type III immune reaction) consists of antibodies-antigen complexes production and their deposition in tissues.

**Inflammatory response** in arthritis is initiated by complement activation, recruitment of leukocytes, destruction of cells coated with antibodies and alteration of cell functions.

**The role of immunogenetics in arthritis.** Cell surface molecules called human leukocyte antigen (HLA) or major histocompatibility complexes (MHC) play a role in mediating immune reactions and the genes that encode HLAs are localized on chromosome 6. Individuals with certain HLA types may have increased risk of certain immune mediated disease (Table 14) due to: molecular mimicry, effect on T-cell development, inheritance with other pathogenic alleles and spurious correlations.

Table 14

**Human leukocyte antigen type and associated disease**

HLA type	Associated conditions
B27	Ankylosing spondylitis– 70 – 90%, Reiter’s syndrome > 40% Psoriatic arthritis, is also associated with B38 Inflammatory bowel disease, arthropathy of the spine
DR4,DR1	Rheumatoid arthritis – 93%
DR3	Systemic lupus erythematosus, Sjogren’s syndrome Grave’s disease, insulin-dependent diabetes mellitus

**Risk factors.** *Gender:* gout, reactive arthritis, ankylosing spondylitis are common in men and rheumatoid arthritis, and other autoimmune connective tissue diseases are more common in women. *Age:* injury, autoimmune, inflammatory diseases are common in young, middle-aged people and in older persons degenerative diseases, rheumatic polymyalgia, paraneoplastic joint syndrome usually develop. The presence of other associated medical conditions like metabolic and endocrine diseases, hepatopathy, tumors,



etc. are also important (e.g., diabetic arthropathy in diabetes mellitus). The use of medications can induce the onset of arthritis: cyclosporine, alcohol, nicotinic acid, thiazide diuretics, loop diuretics, ethambutol, acetylsalicylic acid (precipitate gout), hormone replacement therapy, oral contraceptives, hydralazine, isoniazid, minocycline, procainamide, quinidine, methyl dopa, chlorpromazine, D-penicillamine, fenitoin, sulphasalazine, hydralazine, atenolol, antiTNF $\alpha$  drugs, captopril, carbamazepine, enalapril, ethosuximide, hydrochlorothiazide, lithium, minoxidil, phenytoin, primidone, statins, trimethadione (precipitate systemic lupus erythematosus), steroids (precipitate avascular necrosis of hip), bleomycine, pentazocin, vitamin K, vitamin B12 (precipitate scleroderma).

**Clinical manifestations of arthritis.** Several types of pain are possible in arthritis. *Mechanical pain* is worse with use, develops at the end of the day and after activity, is relieved by rest and is accompanied by no or minimal morning stiffness (< 30 minutes) and by swelling with no heat. *Inflammatory pain* worsens after rest, increases at the middle of the night or particularly in the morning, may improve with exercise and is accompanied by morning stiffness lasting more than 30 minutes and signs of acute inflammation (*rubor, tumor, calor, dolor et functia laesa*). *Migratory pain* (one joint becoming inflamed as another subsides) usually happens in rheumatic fever, gonococcal arthritis, meningococcal arthritis, viral arthritis, SLE, acute leukemia and Whipple's disease. *Episodic recurrent pain* is characteristic of palindromic rheumatism, Lyme disease, crystal induced arthritis, inflammatory bowel disease (IBD), Whipple's disease, familial Mediterranean fever, Still's disease and SLE. *Pain is disproportionately greater than effusion* in rheumatic fever, Familial Mediterranean fever, acute leukemia and AIDS. *Sinovial effusion is disproportionately greater than pain* in tuberculosis arthritis, bacterial endocarditis, IBD, giant cell arteritis and Lyme disease. *Referred pain* happens in the following conditions: disease of the cervical spine can present with shoulder pain, shoulder disease – with upper arm pain, lumbar spine lesions – with hip or thigh pain and hip disease – with knee pain.

*Swelling* may be due to bony hypertrophy, synovitis, intra-articular fluid, or a swollen periarticular structure. Unlike tenderness, objective evidence of swelling indicates organic disease. In chronic rheumatic diseases *impaired function* is often due to a combination of pain, stiffness, tendon and joint damage, neurological impairment and muscle weakness.

A number of extrajoint manifestations can help to reveal the cause of arthritis: Raynaud's phenomenon (in scleroderma and collagen vascu-

lar disease), skin rash (SLE, vasculitis), conjunctivitis, uveitis, episcleritis (seronegative arthropathy), pleural effusion (SLE, rheumatoid arthritis), pulmonary fibrosis (scleroderma, rheumatoid arthritis), pericarditis (SLE, scleroderma, paraneoplastic syndromes, tuberculosis, hypothyroidism), myocarditis (reactive arthritis, SLE), endocarditis (septic arthritis, SLE, rheumatic fever), inflammatory diarrhea (reactive arthritis), cervicitis, balanitis, prostatitis (reactive arthritis), seizures and psychosis (in SLE) and pancytopenia (SLE).

**Investigations.** Laboratory and instrumental investigations should be considered to support the working diagnosis or to distinguish between different possible diagnoses. Tests in support of inflammatory disease include full blood count (FBC), a marker of the acute-phase response C-reactive protein (CRP), fibrinogen, serum protein, alpha-2 and gamma-globulin. Elevated creatinekinase levels occur in most patients with inflammatory myopathies. Low levels of serum complement reflect activation due to immune complex deposition; this may be a marker of disease activity in autoimmune diseases such as SLE. The presence of rheumatoid factor allows dividing arthritis into seropositive and seronegative arthropathy (Table 15).

Table 15

### Seropositive and seronegative rheumatic diseases spectrum

<i>Seropositive rheumatic diseases</i>	1.Connective tissue diseases: rheumatoid arthritis (RA), systemic lupus erythematosus (SLE), antiphospholipid syndrome (APS), sclerodermia/progressive systemic sclerosis (PSS), polymyositis/dermatomyositis (PMY/DMY), mixed connective tissue disease (MCTD). 2.Vasculitides: polyarteriitis nodosa (PAN), microscopic polyangiitis, Wegener's granulomatosis, hypersensitivity vasculitis, giant cell arteriitis.
<i>Seronegative rheumatic diseases</i>	Seronegative spondyloarthropathies: ankylosing spondylitis, reactive arthritis, Reiter's syndrome, psoriatic arthritis, inflammatory bowel disease (IBD)
	Cristal induced arthritis: Gout (monosodium urate), Pseudogout (CPPD)
	Infectious arthritis
	Osteoarthritis

Autoantibodies (ANA and Patterns, dsDNA, Sm, Ro, La, Scl-70, Cent, Jo, RNP) help to diagnose connective tissue disease. Examination of the synovial fluid is an important diagnostic step (see Table 16).

Table 16

**Synovial fluid analysis in different types of arthritis**

Test	Normal synovial fluid	Non inflammatory	Inflammatory	Septic
Appearance	Clear	Clear, yellow	Clear to opaque Yellow– white	Opaque
WBC/mm <sup>3</sup>	<200	<2000	>2000	>2000
Polymorphonuclear neutrophils	<25%	<25%	≥ 50%	≥75%
Synovial liquid culture	Negative	Negative	Negative	Positive
The most probable diagnosis		Osteoarthritis	Rheumatoid arthritis, crystal arthropathy, seronegative arthropathy	Systemic infection

The diagnosis of crystal-induced arthropathy, vasculitis should be confirmed by biopsies of the tophi, vessels, nodules, etc. Imaging investigations of a patient with arthritis include plain radiograph of the joints, CT, arthroscopy, ultrasound of the joint, magnetic resonance imaging, bone and joint scintigraphy, thermography, electromyography and conduction tests.

**The list of diseases for the differential diagnosis of arthritis includes:**

**Common diseases**

1. Rheumatoid arthritis
2. Seronegative spondylarthropathies
3. Connective tissue diseases
4. Crystal deposition arthritis
5. Infectious arthritis
6. Degenerative arthropathy
7. Paraneoplastic rheumatologic syndromes
8. Arthropathies in endocrine disorders
9. Arthropathies in neurologic disorders
10. Cartilage disorders

**1. Rheumatoid arthritis (RA)** is a chronic inflammatory disease of unknown etiology marked by a symmetric, peripheral polyarthritis and often results in joint damage with progressive destruction of articular and periarticular structures, and physical disability. The age of onset is 20-50 years. There is symmetrical polyarthritis with a predominant involvement of metacarpophalangeal, proximal interphalangeal joints, wrist, metatarsophalangeal joints, knees, ankles, shoulders, elbows, hips, acromioclavicular joints, atlantoaxial joint, and temporomandibular joints. Pain is of the

inflammatory type aggravated by use and can be present at rest. Prolonged morning joint stiffness  $\geq 1$  hour and „gelling” throughout the body and recurrence of this stiffness after resting are some of the many constitutional features that complicate rheumatoid arthritis. Constitutional features of RA are fatigue, weight loss, muscle pain, excessive sweating, or low-grade fever.

*Characteristic deformities* include: boutonnière deformity of the finger (hyperextension of the distal interphalangeal joint and flexion of the proximal interphalangeal joint), swan-neck deformity of the finger (hyperextension at the proximal interphalangeal joint and flexion of the distal interphalangeal joint, ulnar deviation of the metacarpophalangeal joints which can progress to complete volar subluxation of the proximal phalanx from the metacarpophalangeal head, compression of the carpal bones and radial deviation of the carpus, subluxation of the wrist, valgus of the ankle and hind foot, pes planus, forefoot varus and hallux valgus and cock-up toes caused by subluxation at the metatarsophalangeal joints.

*Laboratory findings* are consistent with normochromic/normocytic anemia, polyclonal hypergammaglobulinemia, thrombocytosis, elevated ESR, elevated rheumatoid factor (IgM), elevated ACPA (more specific). The synovial fluid is cloudy but sterile, with reduced viscosity and polymorphonuclear neutrophils, lymphocytes and other mononuclear cells. On X-ray-soft tissue swelling is seen in the first months of disease. Subsequently, periarticular osteoporosis, joint space narrowing and marginal erosion may be present.

## 2. Seronegative spondylarthropathies

There are 5 subtypes of seronegative spondyloarthropathies: **ankylosing spondylitis, psoriatic arthritis, reactive arthritis, the arthritis associated with inflammatory bowel disease, and undifferentiated spondyloarthropathy**. The common features of seronegative spondylarthropathies include: negative rheumatoid factor, involvement of spine and sacroiliac joints, asymmetrical large joint oligo-/monoarthritis, enthesopathy (plantar fasciitis, Achilles tendinitis, costocondritis), extra-articular manifestations (uveitis, aortic regurgitation, upper zone pulmonary fibrosis, amyloidosis) and HLA B27 presence in 88-96%.

**Ankylosing spondylitis** is a systemic inflammatory disease involving the spine, sacroiliac, peripheral joints and entheses. The onset is in teens or mid-20s; the onset after the age of 40 is very unusual. Arthritis in ankylosing spondylitis has the following features: gradual onset of chronic, intermittent pain of large joints and spine, bilateral, symmetric arthritis

of the sacroiliac joints clinically manifested by chronic persistent lower back pain and stiffness for more than 3 months, peripheral arthritis (hip, shoulders), oligoarthritis of the knees, ankle's in the absence of microbial infection; spondylitis with progressive loss of mobility and ankyloses in lumbar, thoracic, cervical, over time, rigidity of spine (bamboo spine by x-ray). The joint involvement is accompanied by enthesitis, morning stiffness that improves with hot shower and exercise, acute anterior uveitis, cardiovascular disease (ascending aortitis, aortic insufficiency, conduction system abnormalities) and neurological complications (spinal fractures, C1/2 subluxation, or cauda equina syndrome).

*The New York diagnostic criteria* for ankylosing spondylitis include: a history of inflammatory back pain, limitation of motion of the lumbar spine in both the sagittal and frontal planes, limited chest expansion, relative to standard value for age and sex, definite radiographic bilateral sacroiliitis.

**Enteropathic arthritis** is a clinical syndrome characterized by spondylitis, sacroiliitis, morning stiffness, and the involvement of large joint arthritis correlates with the activity of colitis (more common Crohn's disease than ulcerative colitis).

Other extraintestinal manifestations of enteropathic arthritis include: fever, clubbing, uveitis, iritis, anemia, jaundice (primary sclerosing cholangitis), aphthous ulcers (Crohn's mainly), arthritis, erythema nodosum, pyoderma gangrenosum, DVT, and amyloidosis.

### **Psoriatic arthritis**

Correlations between arthritis and psoriasis: 20%-30% of cases with psoriasis develop arthritis and spondyloarthritis. In 60%-70% of cases psoriasis precedes arthritis. The articular syndrome may precede the onset of skin disease and may be the first syndrome. There are five clinical types of psoriatic arthritis manifestations:

*Symmetric polyarthritis* affects predominantly distal interphalangeal joint (small joints of the hands and feet, wrists, ankles, knees, elbows): indistinguishable from RA, but often asymmetric involvement, that resembles rheumatoid arthritis. Usually, fewer joints are involved than in rheumatoid arthritis

*An asymmetric oligoarticular form* that may lead to considerable destruction of the affected joints.

A pattern of disease in which *the distal interphalangeal joints are affected primarily*. This may be monoarticular, and often the joint involvement is asymmetric. Pitting of the nails and onycholysis, subungual hyperkerato-

sis frequently accompany joint involvement, symmetric polyarthritis-like rheumatoid arthritis but negative for rheumatoid factor.

*Severe deforming arthritis (arthritis mutilans)* with destructive bone resorption, especially hands and marked osteolysis.

*A spondylitic form of psoriatic arthritis* (20–40%) with sacroiliitis and spinal involvement, similar to ankylosing spondylitis, is characterized by the presence of HLA-B27-positive in 50% of patients.

**Reactive arthritis** represents an acute synovitis < 6 weeks after urogenital infection with *Chlamydia* and/or *Ureaplasma urealyticum*, which cause nonspecific urethritis or diarrhea after *Salmonella spp.*, *Shigella flexneri*, *Yersinia enterocolitica* and *Campylobacter jejuni* infection. This is an aseptic arthritis induced by a host response to an infectious agent rather than direct infection. In contrast to septic arthritis, these microorganisms cannot be cultivated from joint tissue or fluid. HLA-B27 is associated in 80% of cases. Clinical manifestations appear after 15–30 days of infection. The first symptoms of reactive arthritis may evolve only a few weeks after intestinal or urogenital infection. Several manifestations may occur along with fatigue and occasional fever.

Joint predilection is for the toes and asymmetric oligoarthritis of large joints in the lower extremities—such as one or both ankles, wrists, or knees. It can cause a single finger or toe with livid skin coloration (so-called dactylitis or „sausage” finger), as psoriatic arthritis can. The distal interphalangeal joints in the hands can also be affected. Spondylarthropathy with lower back pain in the early morning and stiffness of the spine, frequently along with asymmetric involvement of the sacroiliac joints can also occur.

*Diagnosis.* The culture of the feces and PCR examination of the serum may detect the enteral infectious agents, as well as *Chlamydia* in the urine in the early stages of the disease. HLA-B27 does not really contribute to confirming the diagnosis, although 70% of the cases are positive. In the differential diagnosis gonococcal urethritis with septic arthritis should be considered.

Reiter's syndrome and reactive arthritis may occur as a single episode, as infrequently recurring episodes, or as a chronic arthritis. Reactive arthritis in its full form is called Reiter syndrome.

**Reiter's syndrome** classically includes the triad of arthritis, urethritis, prostatitis/cervicitis, and conjunctivitis. Men between 20 and 40 years of age are most often affected. Joint predilection is for the toes and asymmetric large joints in the lower extremities. It can cause „sausage” toe, as can

psoriatic arthritis. The distal interphalangeal joints in the hands can also be affected and sacroiliitis (sometimes unilateral) can occur. Other features include: cardiac conduction disturbances and aortitis, conjunctivitis or iritis, balanitis, oral ulcerations, or keratoderma) can also occur. Criteria for the diagnosis: oligoarthritis, predominantly lower limb, symmetrical, dactylitis, enthesitis (especially heels), low back / buttock pain (inflammatory sacroiliitis).

**Undifferentiated spondyloarthropathy** is characterized by inflammatory back pain, alternating and unilateral buttock pain, enthesitis, peripheral arthritis, dactylitis („sausage” digit), acute anterior uveitis, the presence of HLA-B27 or family history of spondyloarthropathy. Many manifestations of spondylarthropathies may occur without isolated peritendinitis of the Achilles tendon. The male-to-female ratio is 1:3. Late age of the onset, female predominance, and low HLA-B27 positivity suggest that undifferentiated spondyloarthropathy is distinct from ankylosing spondylitis and other classic spondyloarthropathies. *Extra articular manifestations* are less than 10% of patients, and include acute anterior uveitis (1-2%), oral ulcers, rash, nonspecific IBD, pleuritis, and pericarditis. More than half of the patients also complain of fatigue. *Diagnosis.* The examination of the patient can reveal: limited chest expansion, spine stiffness, tenderness at the entheses and joint stiffness. Not much radiological changes are seen with the passage of time. Sacroiliitis and spondylitis are either absent or appear very mild on routine radiography. HLA-B27 antigen is positive only in approximately 20-25% of patients.

### 3. Connective tissue diseases

**Systemic lupus erythematosus (SLE)** is a chronic inflammatory disease of unknown cause with a wide spectrum of clinical manifestations and variable course characterized by exacerbations and remissions. The arthritis is usually a symmetric inflammatory non-deforming and non-erosive polyarthritis of hands, with joint pain, swelling, redness, morning stiffness (>1 hour), and sometimes, dysfunction with joint deformities (Jaccoud's arthritis). Avascular necrosis of bone occurs (hip- the femoral head, clavicular bone, shoulder, knee and tibia may be affected), and not only in patients taking steroids.

**Mixed connective tissue disease (MCTD)/Overlap syndrome** is an uncommon systemic inflammatory rheumatic disease. MCTD is a specific subset of the broader category of rheumatic „overlap syndromes”, a term used to describe when a patient has features of more than one classic inflammatory rheumatic disease.



Pain in multiple joints (polyarthralgia) or inflammation of joints (arthritis) also occurs in the majority of affected individuals. Raynaud's phenomenon may precede the development of additional symptoms of MCTD. Lupus-like skin inflammation in sun-exposed areas and hair loss are common, as are skin scarring changes on the fingers and face like those seen in scleroderma. Muscle weakness due to inflammation (myositis) of proximal muscle groups can also occur. Additional frequent symptoms include hand swelling and fatigue. Heartburn and dysphagia occur in at least half of individuals with MCTD. MCTD lung disease may lead to pulmonary hypertension or interstitial lung disease. Mixed connective tissue disease may be diagnosed and differentiated based upon: a thorough clinical evaluation, detection of complete diagnostic criteria for one (or more than one) classic rheumatic disease, detailed patient history, identification of characteristic findings, high levels of antibodies to the U1 small nuclear ribonucleoprotein (anti-RNP).

**Systemic sclerosis.** Scleroderma is an uncommon autoimmune disease characterized by abnormally increased production and accumulation of collagen, the body's major structural protein, in skin and other organs of the body. The involvement of joints has different forms: arthralgia, true inflammatory arthritis, reabsorption of tufts of distal phalanges, osteolysis of distal zone of radius and cubital bone, secondary joint contractures with loss of joint function because of skin fibrosis.

Patients can have both articular erosions and nonarticular bony resorptive changes of ribs, mandible, radius, ulna, and distal phalangeal tufts which are unique to systemic sclerosis. Up to 60% of patients have „leathery” crepitation of the tendons of the wrist.

**Polymyositis/dermatomyositis.** Polymyositis is a rare autoimmune disease characterized by inflammatory degenerative changes in the muscle fibers and the supportive collagen of connective tissue. The major early symptom of this disorder is muscle weakness, usually in the neck, trunk, shoulders, and thighs. The involvement of joints is characterized by arthralgia, joint contractures, subcutaneous calcifications and symmetric arthritis of the hands. Muscle weakness provokes difficulty to rise from a sitting position, climb stairs, lift objects and/or reach overhead. Additional symptoms may also include interstitial pneumonitis and arrhythmias. There is a possible association with other autoimmune rheumatic diseases (SLE, RA, SS) or with malignancy (lung, ovary, breast, stomach). Investigations to confirm the diagnosis show elevation of ESR, muscle enzyme and aldolase, positive Anti-Jo1 antibody, electromyography, fine-needle muscle biopsy.



#### 4. Crystal deposition arthritis

**Gout** is an inflammatory arthritis associated with hyperuricaemia caused by the imbalance of decreased urate excretion and/or increased urate production with uric acid crystals deposited in joints, skin, and kidneys. The *causes of impaired excretion of uric acid* include chronic renal disease (clinical gout unusual), drug therapy (thiazide diuretics, low dose aspirin), arterial hypertension, lead toxicity, primary hyperparathyroidism, hypothyroidism, increased lactic acid production from alcohol, exercise, starvation, glucose-6-phosphatase deficiency (interferes with renal excretion). *The causes of increased production of uric acid* include increased purine synthesis de novo (hypoxanthine-guanine-phosphoribosyl transferase reduction (Lesch-Nyhan syndrome), phosphoribosyl-pyrophosphate synthetase overactivity, glucose-6-phosphatase deficiency with glycogen storage disease type I and increased turnover of purine (polycythaemia vera, leukaemia, carcinoma, severe psoriasis). The main precipitants are surgery, dehydration, fasting, binge eating, binge drinking, exercise and trauma. In gout arthritis has a sudden onset (frequently nocturnal) with extremely painful methatharso-phalangeal joint of great toe („podagra”), ankle, tarsus or knee. The overlying skin is warm, tense, dusky red. Occasionally polyarticular appearance with the involvement of hip, knee, ankle, foot, shoulder, elbow, wrist, hand, or other joints may develop. Tophi (deposits of urate crystals in subcutaneous tissue and joints) are commonly observed above the joints of fingers, wrists, knees, on the pinna, Achilles tendon and ulnar aspect of the forearm. The development of bursitis of olecranon and patella is also possible. Chronic tophaceous gout results in deforming arthritis from tophus formation and joint erosion. Renal manifestations (urate nephrolithiasis, urate nephropathy with interstitial deposits of urate), presence of metabolic syndrome (obesity, arterial hypertension, dyslipidemia, decreased tolerance to glucose) are complementary to the diagnosis of gout.

The diagnosis and differentiation are mainly based on clinical data and presence of urate crystals in tissues and synovial fluid (needle shaped, negative birefringence, i.e. yellow when parallel to the plane of polarized light). Joint X-rays may be normal or consistent with soft tissue swelling, normal joint space, early S show soft tissue swelling; late S bony erosions („punched out”) with overhanging edge, and soft tissue calcifications within tophi, useful to exclude chondrocalcinosis or septic changes.

**Calcium pyrophosphate dehydrate (CPPD) deposition disease (pseudogout)** represents a deposition of CPPD crystals within tendons,

ligaments, articular capsules, synovium and cartilage. It is more common in elderly. The study of the anamnesis for differentiation is useful to know if the patient has metabolic disorders (hemochromatosis, hypothyroidism, hyperparathyroidism, diabetes mellitus, hypomagnesemia, alkaline phosphatase deficiency, familial hypocalciuric hypercalcemia, gout, Gitelman's syndrome, X-linked hypophosphatemic rickets), trauma and genetic predisposition (familial chondrocalcinosis). The involvement of joints occurs in two forms (pseudogout and pseudorheumatoid arthritis). Pseudogout is characterized by acute mono- or asymmetric oligoarticular arthritis, indistinguishable from gout except through synovial fluid exam for crystals from the knees, wrists, and metacarpophalangeal joints. Pseudorheumatoid arthritis means chronic polyarticular arthritis with morning stiffness. The diagnosis is based on clinical data, synovial fluid examination under space polarized microscopy (S-rhomboid-shaped, weakly positively birefringent crystals, WBC 2000–100,000/mm<sup>3</sup>), Gram stain and culture of synovial fluid (infection may coexist with acute attacks). Joint radiographs show destruction of articular cartilage and bony overgrowths, S-rhomboid-shaped degeneration of joints and chondrocalcinosis (punctate and linear densities in joint cartilage, menisci, triangular fibrocartilage of the wrist, small joints of fingers, and symphysis pubis).

**Infectious arthritis** includes: acute and chronic bacterial arthritis, viral arthritis (HBV, HCV, HIV, EBV, CMV, parvovirus), fungal arthritis (aspergilosis, candidosis, sporothrycosis, cryptococcosis, coccidiomycosis). The etiology and predisposing conditions of bacterial arthritis are shown in Table 17.

Table 17

### Etiology and predisposing conditions of bacterial arthritis

Causative microorganism	Predisposing conditions and age
Methicillin-resistant <i>Staphylococcus aureus</i> (MRSA) Group B Streptococcus	Previous joint damage– rheumatoid arthritis, prosthetic joints, Compromised immunity (diabetes mellitus, endocarditis, infection at other sites advanced chronic kidney disease, alcoholism, cirrhosis, and immunosuppressive therapy), Intravenous drug abusers
<i>Streptococcus spp.</i> , <i>Gonococcus</i>	Young adults
<i>Escherichia coli</i> , <i>Pseudomonas aeruginosa</i>	Adults
<i>Haemophilus influenzae</i>	Children

**Gonococcal arthritis** usually occurs in otherwise healthy individuals. Migratory polyarthralgia involves the wrist, knee, ankle, or elbow at the onset within 1-4 days. tenosynovitis is also the most common sign. There are two patterns of joint involvement. The first pattern is characterized by tenosynovitis that most often affects the wrists, fingers, ankles, or toes and is seen in 60% of patients. The second pattern is purulent monoarthritis that most frequently involves the knee, wrist, ankle, or elbow and occurs in 40% of patients. Most patients are asymptomatic, less than half of patients have fever, and less than one-fourth have any genitourinary symptoms. The diagnosis is based on the above mentioned clinical data and peripheral blood leukocytosis, synovial fluid analysis (white blood cell count ranges from 30,000 to 60,000 cells/mcL), synovial fluid Gram stain, synovial culture, urethral, throat, cervical, and rectal cultures and urinary nucleic acid amplification tests (for the detection of *Neisseria gonorrhoeae* in genitourinary sites). Imaging radiographs are usually normal or show only soft tissue swelling.

**Non-gonococcal (septic) arthritis.** It is characterized by acute onset of inflammatory monoarticular arthritis of the knee, hip, shoulder, with pain, swelling, and heat of the affected joint, worsening over hours. The knee is most frequently involved, other commonly affected sites are the hip, wrist, shoulder, and ankle. The sternoclavicular or sacroiliac joint, can be involved in injection drug users. Infection of the hip usually results in groin pain greatly aggravated by walking. The diagnosis is based on infection with causative organisms commonly found elsewhere in body. Synovial fluid analysis is critical for the diagnosis. The leukocyte count of the synovial fluid usually exceeds 50,000/mcL and often is more than 100,000/mcL, with 90% or more of polymorphonuclear cells. Gram stain of the synovial fluid is positive in 75% of staphylococcal infections and in 50% of gram-negative infections. Synovial fluid cultures are positive in 70-90% of cases; administration of antibiotics prior to arthrocentesis reduces the likelihood of a positive culture result. X-rays are usually normal early in the disease and MRI and CT are more sensitive in detecting fluid in joints that are not accessible to physical examination (hip, column). Bony erosions and narrowing of the joint space followed by osteomyelitis and periostitis may be seen within 2 weeks.

**Lyme disease** is a tick-borne spirochetal illness with acute and chronic evolution. Signs and symptoms occur in stages that may overlap. Later stages may occur without evidence of previous disease. The arthritis usually

appears in stage II and III of disease. More than 50% of untreated patients develop arthritis. This usually affects large joints, primarily the knees, and joint fluid analysis shows leukocytosis similar to that in rheumatoid arthritis. Baker cysts may form early and are prone to rupture in patients who have arthritis of the knees. The differential diagnosis is based on antibody to spirochete measured by ELISA assay. It is important that test results remain negative for up to 4 to 6 weeks after infection. Patients treated early with tetracycline or other antibiotics may never have positive results.

**Tuberculous arthritis.** The usual risk factors of tuberculosis are important co-morbidities (e.g., diabetes mellitus), alcohol abuse and immunosuppression, HIV infection inclusively. The bacillus invades the synovium and/or intervertebral disc which lead to caseating granulomas and rapid destruction of cartilage and adjacent bone. A hip or knee joints are most commonly affected but around 50% of patients develop spine disease. It occurs in primary tuberculosis in children. The patient usually presents with constitutional syndrome (fever, night sweats, anorexia and weight loss). The diagnosis should be confirmed by culture and fluid of the synovium, as well as by X-ray signs of bone destruction.

In **viral arthritis** arthralgia occurs frequently in the course of acute infections with many viruses, but frank arthritis is uncommon.

**Acute parvovirus B19 infection** leads to acute polyarthritis in > 60% of adult cases (infected children develop the febrile exanthema known as „slapped cheek fever“). This arthritis can mimic rheumatoid arthritis but is almost always self-limited and resolves within several weeks. The diagnosis is made by the presence of IgM antibodies.

In **acute viral hepatitis B infection**, self-limited polyarthritis typically occurs before the onset of jaundice. Urticaria or other types of skin rash may be present. The clinical picture resembles that of serum sickness. Serum transaminase levels are elevated, and tests for hepatitis B surface antigen are positive. Serum complement levels are often low during active arthritis and become normal after remission of arthritis.

**Chronic infection with viral hepatitis C** is associated with chronic polyarthralgia in up to 20% of cases and with chronic polyarthritis in > 5%. Both can mimic rheumatoid arthritis, and the presence of rheumatoid factor in most hepatitis C infected individuals leads to further diagnostic confusion. *Distinguishing hepatitis C-associated arthritis/arthralgias from the co-occurrence of hepatitis C and rheumatoid arthritis can be difficult.* The important moments in differential diagnosis are: rheumatoid arthritis

always causes objective arthritis (not just arthralgias) and can be erosive (hepatitis C-associated arthritis is nonerosive). The presence of anti-CCP antibodies points to the diagnosis of rheumatoid arthritis.

**Chikungunya** is an arthropod-borne viral infection that, while endemic to West Africa, has occurred in many locations including the Indian Ocean islands, the Caribbean and the southeastern United States. Distinguishing chikungunya from dengue fever can be challenging since both can cause high fever, rash, and incapacitating bone pain. However, polyarthralgia and polyarthritis develop much more commonly with chikungunya infection. These polyarthralgia and polyarthritis can persist for months or years.

**Arthritis of HIV infection.** Infection with HIV has been associated with various rheumatic disorders, most commonly arthralgia and arthritis. HIV causes severe arthralgia in an oligoarticular, asymmetric pattern that sometimes resolves within 24 hours and the joint examination is normal. HIV-associated arthritis is seronegative, predominantly lower-limb with objective findings of arthritis and a self-limited course that ranges from weeks to months. Spondylitis can also occur. Avascular necrosis possibly associated with corticosteroids or alcohol can also occur. Psoriatic arthritis and reactive arthritis occur in HIV-infected individuals and can be severe.

**Fungal arthritis** (mycotic arthritis). It can be caused by any of the invasive types of fungi. The infection can result from an infection in another organ, such as the lungs. Immunocompromised patients who travel or live in areas where the fungi are common, are more susceptible to most causes of fungal arthritis like Blastomycosis, Candidiasis, Coccidioidomycosis, Cryptococcosis, Histoplasmosis, Sporotrichosis and *Exserohilum rostratum* (from injection with contaminated steroid vials). Fungal arthritis is a rare condition. The fungus can affect bone or joint tissue. One or more joints can be affected, most often the large, weight-bearing joints, such as the knees, ankles, feet, and legs with pain, stiffness, swelling. The symptoms may include constitutional syndrome.

**Acute rheumatic fever (ARF) and post-streptococcal reactive arthritis.** The typical reactive arthritis develops after infection with group A *beta-hemolytic streptococcus*, with fever and polyarthritis, predominantly of the larger joints, carditis, and later chorea minor, subcutaneous nodules and transient erythema anulare marginatum. Arthritis affects two-thirds of all patients with rheumatic fever. In adults, arthritis may be the only clinical feature of acute rheumatic fever and often occurs early. This arthritis usually involves the large joints, particularly the knees, ankles, elbows, and wrists.

It may be migratory, with each joint remaining inflamed for approximately 1 week. This arthritis of rheumatic fever is nonerosive; however, repeated attacks may result in a Jaccoud deformity, in which the metacarpophalangeal joints are in ulnar deviation as a result of tendon laxity, rather than bony damage.

### 5. Degenerative arthropathy

**Osteoarthritis** is a failure of articular cartilage and subsequent degenerative changes in subchondral bone, bony joint margin synovium, and para-articular fibrous and muscular structures.

Osteoarthritis is the most common rheumatic disease; 80% of patients have some limitation of their activities, and 25% of patients are unable to perform major activities of daily living. More than 10% of the population older than 60 has osteoarthritis. Annually, symptomatic hip or knee osteoarthritis develops in half a million new patients.

*Primary idiopathic* affection of three or more joints may be with localization or generalized. The hands (distal interphalangeal), foot, knee, hip and column are affected more frequently

The characteristic pain of osteoarthritis is *of mechanical type*, increasing with movement and joint loading and decreasing and ceasing at rest. The pain is the worst when starting movement after rest (in the morning and after prolonged sitting or resting); however, it then eases, but later increases after extended periods of walking or movement, because of overload. In the inflammatory stage of osteoarthritis, pain at rest also occurs. Nocturnal pain is most characteristic of inflammatory pain, e.g. in hip osteoarthritis, and is usually associated with hip joint effusion detectable by ultrasound. Subchondral bone edema may contribute to the pain.

Nodal osteoarthritis most commonly involves the distal interphalangeal joints and is familial. The joint swells and becomes inflamed and painful, but the pain subsides over a few weeks or months and leaves bony swellings (Heberden's nodes). Occasionally, the joint becomes unstable and limits pinch gripping. The involvement of the proximal interphalangeal joints (Bouchard's nodes) is less common and may be mistaken for early rheumatoid arthritis. Stiffness of the proximal joints impairs hand function significantly.

**Writer's cramp.** Writer's cramp is the most common type of focal dystonia and occurs during complex hand activities – writing or playing a musical instrument. Clumsiness and painful tightness in the hand and forearm occur during writing or playing, and abnormal tension and strange

posturing develop. Focal dystonia is often inappropriately described as „psychological.” Local botulinum toxin injection produces temporary relief. Retraining and learning new techniques help some patients, but the outlook is poor and may lead to the end of musical careers.

**Bypass arthritis** occurs in patients who have undergone intestinal bypass operations, including jejunocolic or jejunoileal ones. This arthritis may be acute or subacute, is usually intermittent, and can last occasionally for short periods, only to recur. The most commonly affected joints are the metacarpophalangeal, proximal interphalangeal, wrists, knees, and ankles. It is commonly associated with dermatitis, which can be pustular. Circulating immune complexes composed of bacterial antigens have been found in both the circulation and the synovial fluid and are thought to be the cause of this disorder.

**6. Paraneoplastic rheumatologic syndromes** (arthritis associated with neoplasms) have the following features: direct invasion of bones, joint, muscle; synovial reaction to bony or soft-tissue tumors; hemarthrosis caused by hemorrhage into joint or periarticular structures; secondary gout; treatment-related arthropathy secondary to immunosuppressive drugs.

**Hypertrophic osteoarthropathy (HOA)** embraces the triad of polyarthritis, clubbing, and symmetric bilateral periostitis of distal long bones (especially distal tibia). Arthritis is symmetric and affects the knees, ankles, elbows, wrists, metacarpophalangeal joints, proximal interphalangeal joints. Synovial fluid is „non-inflammatory”, WBC < 2000. Periostitis of the long bones can cause deep bone pain that mimics bony metastases. Pain in HOA is usually dependent in nature (alleviates by elevation) and is frequently associated with lung mesothelioma, pulmonary metastasis, and lymphoma.

**Carcinoma polyarthritis** is a seronegative inflammatory arthritis that mimics RA. It is differentiated from RA by late age of onset, explosive onset, asymmetric distribution, and predominance of lower extremity involvement, absence of erosions on radiography, negative RF, no family history of rheumatic disease, no deformation of joints and no rheumatic nodules. The differential diagnosis includes direct tumor invasion into joints and hypertrophic osteoarthropathy. It is mostly associated with breast cancer in women and lung cancer in men.

**Amyloid arthritis.** Most commonly occurs in patients with multiple myeloma. Synovial fluid is non-inflammatory, WBC < 2000, and deposits of AL amyloid (apple-green birefringence) can be seen. „Shoulder pad signs” are symmetric and painless. Other clinical manifestations include



peripheral neuropathy, carpal tunnel, peri-articular deposits, macroglossia, nephropathy, cardiomyopathy. The diagnosis and differential diagnosis include analysis of synovial fluid, bone marrow biopsy, serum protein electrophoresis/urine protein electrophoresis.

**Remitting seronegative symmetrical synovitis with pitting edema (RS3PE)** is a rare syndrome that is a subset of the seronegative symmetrical polyarthritis of older people. Paraneoplastic RS3PE is usually characterized by systemic symptoms of fever, anorexia and weight loss and has a poor response to the treatment with corticosteroids. It only seems to resolve with successful treatment of underlying malignancy. Ultrasound reveals tenosynovitis of both flexor and extensor tendons of the wrist and the extensor tendons of the feet is a hallmark of RS3PE. MRI can be used for assessing disease activity as it provides information about soft tissue, cartilage and bony erosions. Whole body Ga-67 scan shows increased uptake in hands and feet and is rarely used for assessing disease activity.

**Secondary gout** can occur in leukemia, lymphoma, myeloma, and tumor lysis syndrome associated with high levels of uric acid.

**Arthropathies in endocrine disorders.** Endocrine disorders such as diabetes mellitus, acromegaly, hyperparathyroidism, and hyperthyroidism/hypothyroidism may be associated with arthropathies. Long-standing cortisone intake may be followed by osteonecrosis of the femur head.

**Diabetic stiff hand** (cheiroarthropathy-limited joint mobility syndrome). Stiff hands are seen in 5 – 10% of patients with type I diabetes. This is more common in those with poor diabetic control and is associated with limited shoulder mobility, diabetic nephropathy and retinopathy. Patients develop waxy, tight skin and a so-called positive prayer sign – inability to hold the fingers and palms together. Limited joint mobility in diabetes is multifactorial, and may also be due to flexor tenosynovitis, Dupuytren's contracture or nodal osteoarthritis.

**Arthropathies in neurologic disorders.** The so-called neuropathic joint disorders result in an impressive diffuse destruction of the joints, which usually is pain-free. Such changes may occur with disturbances of deep and superficial sensitivity, whereas repeated microtraumas and overuse of joint tissue may lead to extensive destruction of the joints. Similar joint disorders may be observed in tabes dorsalis and in syringomyelia. About 10% of patients who have diabetic polyneuropathy will develop neuropathic arthropathy with special preference for the tarsal and MTP joints, and more rarely of the finger joints.



## Cartilage disorders

**Polychondritis (relapsing polychondritis)** belongs to the connective tissue diseases and is characterized by inflammation and partial destruction of the cartilage, especially of the nose, ears, trachea, and larynx. Asymmetrical arthropathy of large and small joints is characteristic. The eyes may also be affected (episcleritis, uveitis). Further findings may include alterations of the heart valves (aortic insufficiency) or renal involvement. This rare disease may develop as a primary disease or in association with systemic lupus erythematosus, rheumatoid arthritis, or multiple myeloma.

**Osteochondritis dissecans** is a disorder caused by mechanical traumatic damage of the superficial joint cartilage which may lead to arthropathy. The knee and hip are most often involved.

In **sarcoidosis** there is acute symmetric migratory arthritis of ankles and knees in 5-30% of cases. Nodular erythema and hilar enlarged lymphatic nodes are also present.

**Polymyalgia rheumatica** is a clinical syndrome usually characterized by the onset of aching and morning stiffness in the proximal musculature (hip and shoulder girdles). It is more common in females than males and usually occurs in patients older than 60 years. Extremity edema or oligoarticular synovitis, particularly of the knees, wrists, and shoulders can occur. Polyarticular small joint arthritis is not a feature. In patients with active polymyalgia rheumatica the diagnosis is based on radionuclide joint scanning and it confirms hip and shoulder synovitis.

## BIBLIOGRAPHY

1. Abu-Shakra M., Buskila D., Ehrenfeld M., et al. Cancer and autoimmunity: autoimmune and rheumatic features in patients with malignancies. *Ann Rheum Dis.* 2001; 60: 433-41.
2. Altman R., Lozada C. Osteoarthritis and related disorders: clinical features. In: Hochberg M., Silman A., Smolen J., et al. eds. *Rheumatology*, Edinburg: Mosby, 2003; 2 (10): 1793-1800.
3. Elyan M., Khan M.A. Diagnosing ankylosing spondylitis. *J Rheumatol Suppl.* 2006; 78: 12-23.
4. Fam A.G. Paraneoplastic rheumatic syndromes. *Baillieres Best Pract Res Clin Rheumatol.* 2000; 14: 515-33.
5. Gaston H. HLA-B27 – new pathogenetic mechanism. *Ann Rheum Dis* 2004 July 2004. Conference: Annual European Congress of Rheumatology (EULAR 2004), Vol. 63.
6. Gran J.T., Husby G. The epidemiology of ankylosing spondylitis. In: Hochberg

- M., Silman A., Smolen J., et al., eds. Rheumatology. 3rd ed. London: Elsevier Limited; 2003; Vol. 2:1153-1159.
7. Groppa I. Compendiu de reumatologie. Chisinau: Sirius; 2009. 315 p.
  8. <https://www.researchgate.net/publication/296289611> (accessed 14.07.2017).
  9. Kelley's text book of internal medicine / H. David Humes, et al.– 4th ed.; Philadelphia: LWW; 2000.– 3254p.
  10. Kumar P, Clark M. Clinical medicine: a textbook for medical students and doctors – 4th ed. Edinburg: W. B. Saunders Company; 1998. 1326p.
  11. Lawson E., Walker-Bone K. The changing spectrum of rheumatic disease in HIV infection. *Br Med Bull.* 2012; 103: 203-21. doi: 10.1093/bmb/lds022.
  12. Longmore M., Wilkinson I., Torok E. Oxford handbook of clinical medicine. – Fifth ed.-Oxford; New York: Oxford univ. press; 2002. 882p.
  13. M. Hochberg, A. Silman, J. Smolen, M. Weinblatt, M. Weismann, eds. Rheumatology. 3rd ed. London: Mosby; 2003.– 2282p.
  14. Rudwaleit M., van der Heijde D., Khan M. A., et al. How to diagnose axial spondyloarthritis early. *Ann Rheum Dis.* 2004; 63:535-543.
  15. Sibia J., Limbach F. X. Reactive arthritis or chronic infections arthritis? *Ann Rheum Dis.* 2002; 61: 580-587.
  16. Siegenthaler W. Differential diagnosis in internal medicine. From symptom to diagnosis. Stuttgart, Germany: Thieme Publishing Group; 2007. 1104p.
  17. Taylor W., Gladman D., Helliwell P., et al. Classification criteria for psoriatic arthritis: development of new criteria from a large international study. *Arthritis Rheum.* 2006; 54: 2665–2673.
  18. Wollenhaupt J., Zeidler H. Undifferentiated arthritis and reactive arthritis. *Curr Opin Rheumatol.* 1998; 10: 306-313.

## DIFFERENTIAL DIAGNOSIS OF BACK PAIN

**INTRODUCTION.** Back pain is the most common cause of disability among young adults. Low back pain, affects over 80% of persons at some point in their life, and 4-33% of population at any one time. Many physical, psychological and occupational factors contribute to the occurrence of back pain.

**DEFINITION.** Pain syndrome is localized in different regions of the column. This is very common, and often self-limiting, but be alert to sinister causes. Etiology of back pain and clinical entity are shown in Table 18.

*Table 18*

**Etiology of back pain and clinical entity**

<b>Etiology of back pain</b>	<b>Clinical entity</b>
Mechanical	Muscular pain Postural back pain Prolapsed disc Lumbar spondylosis+/-spinal stenosis Disseminated idiopathic skeletal hyperostosis (Forrestier's disease) Spondylolisthesis Fibromyalgia
Inflammatory	Infective lesions of spine Seronegative spondylarthritis-ankylosing spondylitis/sacroiliitis
Metabolic	Osteoporosis+ fractures Osteomalacia Paget's disease
Neoplastic	Metastasis Multiple myeloma Primary bone tumor
Referred pain	Disease of internal organ (respiratory, cardiovascular, hepatobiliary, genitourinary system)

### **Causes of back pain in correlation with patients' age:**

- Patients aged 15-30-year-old – prolapsed disc, trauma, fractures, ankylosing spondylitis, spondylolisthesis (e.g., L5 shifts forward on S1), pregnancy;
- Patients aged 30-50-year-old – degenerative joint diseases, prolapsed disc, malignancy (lung, breast, prostate, thyroid, kidney);

- Patients aged older than 50 years – degenerative, osteoporosis, Paget's, malignancy, myeloma, lumbar artery atheroma (which itself may cause disc degeneration).

## CLASSIFICATION OF BACK PAIN

*According to the duration of pain:*

- Acute (up to 6 weeks);
- Subacute (6 weeks – 3 months);
- Chronic (more than 3 months).

*According to the type of pain:*

- Mechanical back pain;
- Inflammatory back pain;
- Back pain due to nerve compression;
- Axial pain with radiculopathy (cervical, dorsal, lumbar);
- Axial pain without radiculopathy (cervical, dorsal, lumbar);
- Referred back pain.

**Clinical features.** Back pain can incorporate a wide variety of symptoms. It can be mild and merely annoying or it can be severe and debilitating depending on the underlying cause of the pain.

**Mechanical pain.** The most common cause of back pain, mechanical pain (axial pain), is the pain primarily from the muscles, ligaments, joints (facet joints, sacroiliac joints), or bones in and around the spine. Muscular pain results from muscle spasm and can be caused by a partially torn muscle, bone or joint pathologic lesion, or neurapraxia of the spinal roots. Mechanical back pain is relieved by rest. Mechanical problems such as vertebral fracture can occur, particularly in postmenopausal women. The pain associated with this is acute, well localized, and associated with characteristic radiographic findings. In the case of a pathologic fracture (e.g., a vertebral body fracture with a metastasis from a lung tumor or a fracture in a thin malnourished woman with a long-standing malabsorption syndrome), the trauma may have been as mild as putting on underwear. In contrast, damage to intervertebral ligaments or dislocation of the spine requires high-velocity trauma. Mechanically caused low back pain, due to spondylosis or arthrosis of the intervertebral facet joints, is common in middle-aged and older persons.

Low back pain may start suddenly, or can start slowly, can be recurrent and gradually gets worse over time. It is often unilateral. It is usually influenced by loading the spine and may feel different based on motion (for-

ward/backward/twisting), activity, standing, sitting, or resting. Low back pain that gets worse with certain positions (e.g., sitting for long periods). They are often associated with spondylosis. It is the most common cause of chronic low back pain with radiation to the lower extremities in males in these age groups.

Sometimes there is no low back component to the pain. Spinal instability can result from congenital and developmental problems. Symptoms of claudication (pain and cramping in the buttocks or below that occurs during walking and is relieved by rest) imply stenosis of the spinal canal and are frequently arthritic in origin. In such cases, arterial claudication of the lower extremities must be ruled out.

**Inflammatory back** pain is characterized by nocturnal intensification, persistence with axial rigidity in the morning. It decreases after axial movements and exercises. This type of pain is specific for inflammatory arthropathy (rheumatoid arthritis, seronegative spondylarthritis, collagenosis), neoplasm. Differential signs between inflammatory and mechanical back pain are shown in Table 19.

Table 19

**Diagnostic distinguishing features between inflammatory and mechanical back pain**

	<b>Inflammatory</b>	<b>Mechanical</b>
Age	Younger	Older
Onset	Insidious	Abrupt
Duration	>3 months	Shorter
Morning stiffness	++	+/-
Resting	Worsens	Improves
Activity	improves	Worsens
Sacroiliac joints	++	-

**Postural back pain** develops in individuals who sit in poorly designed, unresponsive chairs/ position.

**Radicular pain.** This type of pain can occur if a spinal nerve root becomes impinged or inflamed. Radicular pain may follow a nerve root pattern or dermatome down into the buttock and/or leg. Its specific sensation is a sharp, electric, burning-type pain and can be associated with numbness or weakness (sciatica). It is typically felt on only one side of the body. Axial low back pain can vary widely. It can be a sharp or dull pain; it can be felt constantly or intermittently. Muscle spasms and tightness in the low back, pelvis, and hips may develop. It is characterized by the pain that worsens

after prolonged sitting or standing, difficulty standing up straight, walking, or going from standing to sitting. In addition, symptoms of lower back pain are usually described by type of onset and duration.

**Neurogenic pain** is associated with the clinical signs of neurapraxia. It is a disorder of the peripheral nervous system in which there is a temporary loss of motor and sensory function due to blockage of nerve conduction, usually lasting an average of six to eight weeks before full recovery. The term „neurapraxia” is derived from the word „apraxia” meaning „loss or impairment of the ability to execute complex coordinated movements without muscular or sensory impairment”. Neurapraxia is very common in professional athletes. The clinical features are motor weakness, sensory loss, and reflex diminution. It is not appropriate to make a diagnosis of neurogenic pain on the basis of pain alone without these physical findings. Neither the nature of the pain (e.g., sharp, dull) nor its pattern of radiation differentiates reliably between mechanical and neurogenic causes. Acute ruptured disks are rare, but chronic ruptured disks are common and frequently asymptomatic. Bulging intervertebral disks are normal with aging. Magnetic resonance imaging evidence of an old ruptured disk in a patient with low back pain radiating to the lower extremities may be a false-positive finding.

**Acute pain.** Ninety-five percent of all cases of acute low back pain are the result of pulled muscles. This type of pain typically comes on suddenly and lasts for *a few days or weeks*, and is considered a normal response of the body to injury or tissue damage. The muscles of the back are torn when they are contracted and the patient moves suddenly, stretching them. The symptoms of a spinal muscle tear can be acute and incapacitating. This type of pain tends to be localized to the lower back, buttocks, and sometimes the top of the legs. The most acute low back pain results from injury to the muscles, ligaments, joints, or discs. The body also reacts to injury by mobilizing an inflammatory healing response. While inflammation sounds minor, it can cause severe pain. Features which may indicate sinister back pain are listed in Table 20. There is a significant overlap of nerve supply to many of the discs, muscles, ligaments, and other spinal structures, and it can be difficult for the brain to accurately sense which is the cause of the pain. For example, a degenerated or torn lumbar disc can feel the same as a pulled muscle – both creating inflammation and painful muscle spasm in the same area. Muscles and ligaments heal rapidly, while a torn disc may or may not. The pain gradually subsides as the body heals.

Table 20

**Features which may indicate sinister back pain**

- Patient's age < 50 years or > 55years	- Progressive, continuous, non-mechanical pain
- Violent trauma	- Systemically unwell, drug abuse, HIV +ve,
- Alternating sciatica	- Spine movement in all directions painful,
- Bilateral sciatica	- Localized bony tenderness
- Weak legs	- CNS deficit at more than one root level
- Weight loss	- Pain or tenderness of thoracic spine
- Fever	- Bilateral signs of nerve root tension
- Elevated ESR	- Past history of neoplasia
- Administration of systemic steroids	

**Subacute back pain.** Lasting between *6 weeks and 3 months*, this type of pain is usually mechanical in nature (such as a muscle strain or joint pain) but is prolonged. At this point, a medical workup may be considered, and is advisable if the pain is severe and limits one's ability to participate in activities of daily living, sleeping, and working.

**Chronic back pain.** It is usually defined as lower back pain that *lasts over 3 months*. This type of pain is usually severe and does not respond to initial treatments. It requires a thorough medical workup to determine the exact origin of the pain and it can range from mild to severe.

**Diagnostic.** In evaluating patients with back pain, important determinations should be made:

- the pain is primarily muscular in origin,
- is mechanical in origin
- or neurogenic in origin

*Key points in the history:*

- pain duration >1month,
- "history" of cancer,
- unexplained weight loss,
- failure to improve with conservative therapy are all relatively specific for cancer pain.
- intravenous drugs users— may be infection,
- urinary infection suggests spinal infection.
- back pain in young men increases the possibility of ankylosing spondylitis.

- sciatica or pseudo-claudication suggests neurological involvement.
- bladder dysfunction and saddle anesthesia suggest „cauda equine” syndrome
- physical vertebral tenderness (sensitive but not specific) and fever suggest spinal infection.
- straight leg raising should be assessed bilaterally in sciatica or neurogenic claudication.
- In addition to back examination, tone, strength, reflexes and sensory examination of lower limbs should be done”.
- When considering the diagnosis, it is important to look for „red flags” (Table 21) or clinical features that indicate that there might be a serious underlying cause of the complaint.

Table 21

**„Red flags” that indicate the need for early diagnostic testing**

<b>Spinal fracture</b>	Significant trauma Prolonged glucocorticoid use Age > 50 years
<b>Infection or cancer</b>	History of cancer Unexplained weight loss Immunosuppression Injection drug use Nocturnal pain Age > 50 years
<b>Cauda equina syndrome</b>	Urinary retention Overflow incontinence Fecal incontinence Bilateral or progressive motor deficit Saddle anesthesia
<b>Spondyloarthropathy</b>	Night – time waking with pain and stiffness Morning stiffness in the back Low back pain that improves with activity Age < 40 years

- Laboratory (depending on suspicion): CBCD (Complete Blood Count with Differential), ESR, Ca, PO<sub>4</sub>, cerebrospinal fluid, serum protein electrophoresis, urinary protein electrophoresis
- basic imaging spine X-rays
- special imaging CT spine,
- MRI spine (if surgery),
- myelogram (gold standard but seldom used)



- bone scan
- Electromyography and Nerve Conduction Studies may be useful to distinguish root/plexopathies from peripheral neuropathies

**The list of special entities for the differential diagnosis of back pain includes:**

*Common special entities*

1. Cervical pain
2. Dorsal (thoracic) pain
3. Low back pain

**1. Cervical pain**

Pain in the neck usually arises because of poorly defined mechanical influences, although it can occur because of pathology within the spine or be referred from elsewhere. Risk factors include manual jobs, heavy workloads, increasing age and depression, while chronicity is weakly predicted by the presence of concomitant low back pain, older age and previous episodes of neck pain.

Causes of cervical pain and clinical orientation are shown in Table 22. Restricted cervical movements and local tenderness help to confirm the local origin of neck pain. Simple mechanical neck pain describes a common, usually self-limiting, clinical presentation of pain with or without restricted movement, but without neurological or „red flag” features. The onset may be acute (acute torticollis, or „wry neck”) or gradual, and, like low back pain, tends to be recurrent. It usually responds to conservative treatment, although patients should be instructed to return for further assessment if symptoms persist or change in quality. Neck pain may be accompanied by myofascial or diffuse regional pain often involving the shoulder girdle, on palpation of trigger points („knots” within muscle).

*Table 22*

**Causes of cervical pain**

Malformations	Arnold-Chiari malformation Atlantoaxoid malformation
Developmental anomalies	Klippel-Feil syndrome, Vertebra in block, Cervical rib
Congenital diseases	Hunter syndrome Hurler syndrome Morquio syndrome Down syndrome Other congenital diseases

Table 22 (cont.)

Changes in cervical curvature	Congenital or acquired torticollis
Inflammatory diseases	Ankylosing spondylitis, rheumatoid arthritis, juvenile chronic arthritis, adult Still disease, psoriatic arthritis
Infections	Spondylodiscitis (brucella, tuberculosis, other bacteria's)
Degenerative diseases	Cervical osteoarthritis, Forestier and Rotes-Querol disease
Discopathies	Herniated disc
Trauma	Vertebral fractures, Vertebral whiplash syndrome
Tumors	Primary, metastatic
Metabolic diseases	Osteoporosis, Paget disease, alcaptonuria (ochronosis), Acromegaly
Nonvertebral cervicalgia's (referred pain)	Cardiovascular diseases, rheumatic diseases, neurological diseases, others
Soft tissue disease	Fibromyalgia, postural cervicalgia, myofascial syndrome, tension headache
Others	Spinal canal stenosis
Psychogenic origin	

**Radicular cervical pain** due to compression of a nerve root from herniation of a cervical disc, or due to non-compressive causes such as local infection or tumour, refers to neck pain that radiates into the shoulder girdle and/or arm with paraesthesia or numbness in a root distribution (Table 23). Subjective weakness is less common. Examination may not reveal the nerve root level because of the extensive overlap of dermatomes. Motor involvement and/or objective sensory loss warrant urgent referral for specialist assessment. About 40 – 80% of people with compressive cervical radiculopathy have complete resolution of their symptoms over time with conservative treatment.

An important clue is that lumbar disc protrusion tends to compress the nerve root that exits one vertebral level below the protrusion.

**Cervical myelopathy** (compression of the spinal cord), which may arise due to midline disc herniation, is suggested by a history of difficulty walking, lower limb symptoms or bladder and bowel dysfunction. Motor signs of myelopathy below the level of spinal cord involvement may include weakness with increased reflexes and tone (upper motor neurone signs), decreased pinprick sensation and loss of position and/or vibration sense.

**Disc herniation: cervical and lumbar radiculopathy**

Disc	Root	Pain/ Paresthesia	Sensory loss	Motor loss	Reflex Loss
C4–C5	C5	Neck, shoulder, upper arm	Shoulder	Deltoid, biceps infra-spinatus	Biceps
C5–C6	C6	Neck, shoulder, lateral, arms, radial forearm, thumb and index finger	Lateral arms, radial forearm, thumb and index finger	Biceps brachio-radialis	Biceps, brachioradialis supinator
C6–C7	C7	Neck, lateral arm, ring and index fingers	Radial forearm index and middle fingers	Triceps, extensor carpi ulnaris	Triceps supinator
C7–T1	C8	Ulnar forearm and hand	Ulnar half of ring finger, little finger	Intrinsic hand muscles, wrist extensors, flexor dig profundus	Finger flexion
L3–L4	L4	Anterior thigh, inner shin	Anteromedial thigh and shin, inner foot	Quadriceps	Patella
L4–L5	L5	Lateral thigh and calf dorsum of foot, great toe	Lateral calf and, great toe	Extensor hallucis longus +/-foot dorsiflexion inverts and everts	None
L5–S1	S1	Back of thigh lateral posterior calf, lateral foot	Posterolateral and lateral calf, and sole of foot, smaller toes	Gastrocnemius +/- foot eversion	Achilles

**Whiplash injury**, an abrupt flexion/extension movement of the cervical spine as a result of sudden acceleration– deceleration, may occur in road traffic or sporting injuries, and is characterized by localized or diffuse neck and arm pain with muscle spasm, and limited neck movements. The symptoms may be persistent, although 50% of patients recover within 3 months and 80% within 12 months. The risk factors for chronicity after whiplash include the severity of the initial symptoms and psychological disturbance.

In **inflammatory arthropathy** neck pain is common. Inflammatory type of pain in atlanto-axial and subaxial subluxation may develop in rheumatoid arthritis. Immobility due to osteophytic linking of vertebrae may be seen in ankylosing spondylitis.

**Diffuse idiopathic skeletal hyperostosis (DISH)**, also known as For-estier-Rotes-Querol disease, is characterized by the ossification of the

entheses (i.e., enthesopathy). Although the prevalence estimates vary with the number of bridges used to define the disease, the prevalence of DISH is consistently high and increases with age and obesity.

*Clinical features.* Cervical spine ossification is the most extensively studied manifestation, as dysphagia due to esophageal compression may require surgery. As with spondylarthritis, vertebral fractures on a hyperostotic fused spine may escape recognition, placing the patient at risk for complications in the event of subsequent displacement. These fractures are particularly severe, as they often involve the cervical spine and can therefore, cause major neurological impairments. DISH is associated with an increased risk of metabolic syndrome. Various signs and symptoms have been described in patients suffering from DISH, such as polyarticular pain, neck/thoracic/lumbar/extremity pain, acute monoarticular synovitis, limited range of spinal motion, dysphagia, increased susceptibility to unstable spinal fractures, and different degrees of airway obstruction.

The frequency and quality of complaints among these subjects vary by the site of the pathologic ossification. In contrast, many individuals who are diagnosed with DISH (visible ossifications on imaging studies acquired for other medical reasons) may be completely asymptomatic. Although DISH affects selectively the spine (with predilection to its thoracic portion – the hallmark of the disease is considered to be the ossification of the anterolateral aspect of the thoracic spine), it is important to emphasize that this condition is not limited to the spine and has often been reported to involve multiple peripheral locations as well (extraspinal enthesal ossifications). These include periarticular hyperostosis of the hands, pelvis, knees, elbows, etc. The enthesophytes seen in DISH must be differentiated from osteophytes due to osteoarthritis and from syndesmophytes due to spondyloarthritis. Some of the features that help differentiate DISH from other pathologic structures are: developing from joints that are rarely affected by osteoarthritis, such as shoulder, elbow, and metacarpophalangeal joints; developing from bone that is distant from the bone–cartilage junction; affecting distinctive entheses such as the calcaneal spur, quadriceps tendon, among others.

The diagnosis of DISH requires at least two (according to Forestier) or three (according to Resnick) contiguous intervertebral bridges, without severe disk alterations (in contrast to degenerative spinal disease) or ankylosis of the sacroiliac or facet joints (in contrast to spondylarthritis).

*Criteria to diagnose diffuse idiopathic skeletal hyperostosis* (according to Resnic and Niwayama) are as follows:

- The presence of calcification and ossification along the ventrolateral aspects of at least four contiguous vertebral bodies with or without localized pointed excrescences at intervening vertebral body-disc junctions;
- The relative preservation of disc height to the evolved areas and the absence of extensive radiographic changes of degenerative disc disease (intervertebral osteochondrosis) including vacuum phenomena and vertebral body marginal sclerosis;
- The absence of apophyseal joint bony ankyloses and sacroiliac joint erosion, sclerosis or intraarticular bony fusion.

**Differential diagnosis of diffuse idiopathic skeletal hyperostosis and other spondylopathy.** The most common conditions that may also present with bony excrescences, similar to those related to DISH, are spondylosis deformans and ankylosing spondylitis (see Differential diagnosis of arthritis). The former disease is by far the most common of the disorders to be considered in the differential diagnosis of DISH. Spondylosis deformans, however, does not affect the anterior longitudinal ligament in the thoracic spine, and that is how one can differentiate these two conditions. The latter disease shares some features occurring in DISH, such as preponderance in males and an association with ligamentous ossification and syndesmo-phytes. One may distinct these two conditions by noting that in ankylosing spondylitis, the bony bridges are slender and vertical, and involve the outer margin of the annulus fibrosus and do not involve the anterior longitudinal ligament. In addition, erosions and bony ankylosis of the sacroiliac and apophyseal joints do not occur in DISH.

**2. Dorsal (thoracic) pain.** Dorsalgia is a less frequent symptom than other rachialgias, which is probably related to the anatomical configuration of the thoracic and spinal column. The dorsal region of the spine represents a static segment, relatively immobile. It is practically rigid due to its articulation with the rib cage, which is why it is exposed to lower mechanical demands. This explains why degenerative and other lesions are well tolerated at this level. Painful functional syndromes are very common, especially in females. Dorsalgias are accompanied by functional muscular insufficiency, aggravated by inappropriate professional attitudes, depression and other pathological states. Frequently it is a seat of pains irradiated from the territory of the cervicodorsal carcase, and it is also the origin of back pains of the dorsolumbar carcase, referred pain from internal organs – situations that in many cases lead to diagnostic errors and of treatment.

Causes of dorsal (thoracic) pain:

- Deformities -Scheuermann disease
- Inflammatory disease – ankylosing spondylitis, rheumatoid arthritis, psoriatic arthritis, juvenile chronic arthritis;
- Infections – spondylitis, spondylodiscitis, Pott’s morbus;
- Degenerative disease – osteoarthritis of the thoracic spine, spondylolisthesis, spondylolysis, Forestier and Rotes-Querol disease;
- Discopathies – herniated disc;
- Trauma– vertebral fractures;
- Tumors – primary and metastatic;
- Metabolic diseases– osteoporosis, osteomalacia, Paget disease, arthropathy by calcium pyrophosphate crystals;
- Dorsalgia nonvertebrales (referred pain) – Herpes zoster, cardiovascular diseases, abdominal disease (pancreatobiliary system, peptic ulcer), retroperitoneal disease;
- Soft tissue disease and psychogenic origin – mechanical and postural dorsalgia, fibromyalgia, psychogenic rheumatism;
- Dorsalgia of young age.

**Scheuermann disease (vertebral epiphysistis)** is a juvenile kyphosis with sinking of the vertebral plates by the intraspinal hernias of Schmorl. In 20% of cases pain may occur progressively, in the form of a fatigue of the dorsal region, which is manifested by ortostatism or physical work (carrying the weights) and calms down at rest.

**Static dorsalgia.** Scoliosis is generally well tolerated, but it becomes painful in the stages of development with severe deformities. Dorsolumbar scoliosis is characterized by more frequent pain in the lumbar region than thoracic back.

**Thoracic outlet syndromes (TOS).** The thoracic outlet contains the first rib, subclavian artery and vein, brachial plexus, clavicle, and lung apex. Injury to these structures may result in postural or movement-induced pain around the shoulder and supraclavicular region.

**True neurogenic thoracic outlet syndrome (TOS)** is an uncommon disorder resulting from compression of the lower trunk of the brachial plexus or ventral rami of the C8 or T1 nerve roots, caused most often by an anomalous band of tissue connecting an elongated transverse process at C7 with the first rib. The pain is mild or may be absent. The signs include weakness and wasting of intrinsic muscles of the hand and diminished sensation on the palmar aspect of the fifth digit. An anteroposterior cervi-

cal spine x-ray will show an elongated C7 transverse process (an anatomic marker for the anomalous cartilaginous band), and EMG and nerve conduction studies confirm the diagnosis.

**3. Low back pain (LBP)** is the most common musculoskeletal symptom and poses a major socio-economic burden. An estimated 80% of the population will experience back pain during their lifetime; 90% of these patients will have resolution of their symptoms within 4 weeks. Sciatica is the result of nerve root impingement and occurs in < 1% of patients. The pain is radicular (and almost invariably radiates below the level of the knee) in the distribution of a lumbosacral nerve root, sometimes accompanied by sensory and motor deficits. Sciatica should be differentiated from non-neurogenic sclerotomal pain, which arises from pathology within the disc, facet joint or paraspinal muscles and ligaments. Sclerotomal pain is non-dermatomal in distribution and often radiates into the lower extremities but not below the knee or with associated paraesthesiae as with sciatica.

**There are the following causes of lumbar pain:**

- Congenital anomalies of the lumbar spine – Spondylolysis, spondylolisthesis, sacralization of L5, lumbarization of S1, Spina bifida, congenital canal stenosis, Scheuermann disease;
- Trauma and functional or postural overload – muscular contractures and strains, vertebral fractures;
- Diseases causing narrowing of the channel and junction holes – discal hernia, hypertrophy of the articular veneers (canal stenosis), limb claudication of neurogenic features;
- Benign tumors – extradural (osteoma, condroma, osteochondroma, hemangioblastoma, aneurysmal bone cyst), intradural (meningioma, neuroma, lipoma, cysts);
- Neoplasia – extradural (metastasis, plasmocytoma/myeloma, sarcoma, chordoma) and intradural (glioblastoma);
- Degenerative disease – osteoarthritis, Forestier and Rotes-Querol disease;
- Inflammatory arthritis – ankylosing spondylitis, sacroiliitis not associated with ankylosing spondylitis, Reiter syndrome, psoriatic arthritis, inflammatory bowel disease, non-differentiated spondylarthropathy;
- Diseases of bone metabolism – osteoporosis, Paget disease, osteomalacia, acromegaly, hyperparathyroidism, alcaptonuria;
- Infectious diseases – pyogenic spondylodiscitis, tuberculous spon-

dylodiscitis, brucellosis spondylodiscitis, other agents (fungi, parasites);

- Pain of visceral origin – dissection of abdominal aortic aneurysm, disease of digestive organs, renourinary, gynecological systems, retroperitoneal pathology;
- Miscellaneous – Hematological disease (leukemia, multiple myeloma, haemoglobinopathy, mielophybroysis, mastocytosis), psychiatric diseases.

### **Lumbar spondylosis**

In spondylosis the fundamental lesion is in an intervertebral disc or/and a fibrous joint whose tough capsule inserts into the rim of the adjacent vertebrae. This capsule encloses a fibrous outer zone and a gel-like inner zone. The disc allows for rotation and bending. Changes in the disc may start in adolescence or early 20s and increase with age. The gel changes chemically, breaks up, shrinks and loses its compliance. The surrounding fibrous zone develops circumferential or radial fissures. In the majority this is initially asymptomatic but visible on MRI as decreased hydration. Later the discs become thinner and less compliant. These changes cause circumferential bulging of disc capsules. Reactive changes develop in adjacent vertebrae; the bone becomes sclerotic and osteophytes form around the rim of the vertebra. The most common sites of spondylosis are L5/S1 and L4/L5 disc prolapse through an adjacent vertebral endplate to produce a Schmorl's node on X-ray is painless but may accelerate disc degeneration.

As there is no spinal cord in the lumbar spine and because the spinal canal is usually fairly spacious in the low back, problems in the lumbosacral region (the lumbar spine and sacral region of the spine) usually cause nerve root problems, not spinal cord injury.

Spondylosis may be symptomless, but it can cause episodic mechanical spinal pain, progressive spinal stiffening, acute disc prolapses with or without nerve root irritation, spinal stenosis and spondylolystesis.

**Facet joint syndrome.** Lumbar spondylosis also causes secondary osteoarthritis of the facet joint. The pain is typically worse on bending backwards and when straightening from flexion. It is lumbar in site, unilateral or bilateral and radiate to the buttock. For example, nerves that exit the cervical spine travel down through the arms, hands, and fingers. This is why neck problems that affect a cervical nerve root can cause pain and other symptoms through the arms and hands (radiculopathy), and low back problems that affect a lumbar nerve root can radiate through the leg and



into the foot (radiculopathy, or sciatica), thus prompting leg pain and/or foot pain.

**Acute spinal cord compression** is characterized by bilateral pain, lower motor neuron signs at the level of compression, upper motor neuron and sensory signs below and sphincter disturbance. Symptoms include lower limb weakness, increased tendon reflexes in legs, sensory loss usually 1–5 levels below cord lesion with sacral lesion. There are the same types of compression: bonemetastasis (look for missing pedicle on X-ray), myeloma, cord or paraspinal tumor, TBC and abscess.

MRI is the best way to illustrate cord compression, myelopathy, intraspinal neoplasms, cists, hemorrhages and abscesses (myelography, plain X-ray and CT are problematic). FBC and ESR are elevated in myeloma, infections, tumors. Urea, creatinin, electrolits, Prostate Specific Antigen, and technetium scan „hot spot” may support the diagnosis and differentiation if there is neoplastic or inflammatory lesion.

**Cauda equina syndrome** compression of lumbosacral nerve roots (lower motor neurons, mostly below L1 level) is a neurosurgical emergency. The symptoms include lower limb weakness or alternating or bilateral root pain in legs, depressed tendon reflexes in legs, and sacral paresthesia, saddle anaesthesia, and disturbance of bladder or bowel function.

**Sciatica (lumbosacral radiculopathy)** is defined as pain radiating in the dermatomal distribution. The classic features are aching pain in the buttock and paresthesias radiating into the posterior thigh and calf or into the posterior lateral thigh and lateral fore leg. Radiating pain below the knee is more likely to indicate a true radiculopathy than radiation only to the posterior thigh.

**Spondylolisthesis** forwards lipping of one vertebra on another. This occurs in adolescents and young adults when bilateral congenital pars interarticularis defects cause instability and permit the vertebra to slip, with or without preceding of repeated stress/injury on pars interarticularis. The symptoms include sciatica and low back pain, although it can also be asymptomatic. Rarely a cauda equine syndrome with loss of bladder and anal sphincter control and saddle distribution anaesthesia develops. Low back pain in adolescents' warrant investigation, and spondylolisthesis requires orthopedic assessment. A degenerative spondylolisthesis may also develop in older people with lumbar spondylosis

**Disc herniation prolapse** of nucleus pulposus through the annulus, due to intervertebral pressure and degeneration of the ligamentous fib-

ers, occurs more commonly in younger patients. If the prolapsed material presses on a nerve root, may cause inflammation and sciatic symptoms. Over 95% of herniated discs affect the L4 -L5 or L5 -S1 interspace. Most herniated discs resolve in 1– 2 weeks with conservative treatment.

**Back pain in osteoporosis.** Osteosclerosis, immobilization, osteomalacia, the postmenopausal state, renal disease, multiple myeloma, hyperparathyroidism, hyperthyroidism, metastatic carcinoma, or glucocorticoid use may accelerate osteoporosis and weaken the vertebral body, leading to compression fractures and pain. Up to two-thirds of compression fractures seen on radiologic imaging are asymptomatic. The most common nontraumatic vertebral body fractures are due to postmenopausal or senile osteoporosis. The risk of an additional vertebral fracture in 1 year following a first vertebral fracture is 20%. The presence of fever, weight loss, fracture at a level above T4, or the conditions described above should increase suspicion for a cause other than senile osteoporosis. The sole manifestation of a compression fracture may be localized back or radicular pain exacerbated by movement and often reproduced by palpation over the spinous process of the affected vertebra. The relief of acute pain can often be achieved with acetaminophen or a combination of opioids and acetaminophen. The role of NSAIDs is controversial. Both pain and disability are improved with bracing.

**Fibrositic nodulosis** causes unilateral or bilateral low back pain, radiating to the buttock and upper posterior thigh. There are tender nodules in the upper buttock and along the iliac crest. Such nodules are relevant only if they are tender and associated with pain. They are probably traumatic. Local intralesional corticosteroids injections help.

**Sway back (back pain of pregnancy).** Low back pain in pregnancy reflects altered spinal posture and increased ligamentous laxity. Weight control and pre- and post-natal exercises are helpful, and pain usually settles after delivery.

**Infection /inflammation as a cause of back pain.** Fever or an elevated white blood cell count is found in a minority of patients. MRI and CT are sensitive and specific for early detection of osteomyelitis. CT may be more readily available in emergency settings and better tolerated by some patients with severe back pain.

**Spinal Septic Arthritis.** Vertebral osteomyelitis is often caused by staphylococci, but other bacteria or tuberculosis (Pott's disease) may be responsible. The primary source of infection is usually the urinary tract, skin, or lungs. Intravenous drug use is a well-recognized risk factor. Whenever pyo-

genic osteomyelitis is found, the possibility of bacterial endocarditis should be considered. This condition should be suspected in patients with acute or chronic, unrelenting back pain associated with fever and marked local tenderness. Back pain unrelieved by rest, spine tenderness over the involved spine segment, and an elevated ESR are the most common findings in vertebral osteomyelitis. The thoracolumbar region is most commonly affected. The intervertebral disk can also be affected by infection (diskitis) and, very rarely, by tumor.

**Spinal epidural abscess** presents with back pain (aggravated by movement or palpation), fever, radiculopathy, or signs of spinal cord compression. The subacute development of two or more of these findings should increase the index of suspicion for spinal epidural abscess. The abscess may track over multiple spinal levels and is best delineated by spine MRI. An antecedent infection or procedure predisposing to bacteremia may help suggest this diagnosis. Imaging studies usually have evidence for infection crossing the disk space. In tuberculous spinal septic arthritis (Pott disease), the site of involvement is most commonly T10-L2, and there is usually an associated paraspinal abscess. Intravertebral disk infection is often difficult to diagnose because pain patterns may be unusual and localizing signs may be absent. Bone scanning may be helpful, but magnetic resonance imaging may be very helpful, particularly because of the ability to show an spread of infection into surrounding tissues.

**Inflammatory rheumatologic back pain.** The onset of back pain prior to the age 30 and an „inflammatory” quality of the back pain (morning stiffness and pain that improve with activity) should raise the possibility of ankylosing spondylitis. In this case it is important to do a test for ankylosing spondylitis (Table 24). In contrast to ankylosing spondylitis, rheumatoid arthritis predominantly affects multiple, small, peripheral joints of the hands and feet. Rheumatoid arthritis spares the sacroiliac joints and only affects the cervical component of the spine. Bilateral sacroiliitis indistinguishable from ankylosing spondylitis is seen with the spondylitis associated with inflammatory bowel disease. Sacroiliitis associated with reactive arthritis and psoriasis, on the other hand, is often asymmetric or even unilateral. Diffuse idiopathic skeletal hyperostosis (DISH) causes exuberant osteophytes („enthesophytes”) of the spine that occasionally are difficult to distinguish from the syndesmophytes of ankylosing spondylitis. The enthesophytes of DISH are thicker and more anterior than the syndesmophytes of ankylosing spondylitis, and the sacroiliac joints are normal in DISH.

Table 24

**Results of testing in ankylosing spondylitis**

Test	Method	Results
Schober	Make a mark on the spine at level of L5 and one at 10 cm directly above with the patient. Patient then bends forward maximally and the distance between the two marks is measured.	An increase of < 5 cm indicates early lumbar involvement standing erect.
Chest expansion	Measure maximal chest expansion at nipple line.	Chest expansion of < 5 cm is a clue to early costovertebral involvement.
Sacroiliac compression	Exert direct compression over sacroiliac joints.	Tenderness or pain suggests sacroiliac involvement.

**Neoplastic back pain** is the most common neurologic symptom in patients with systemic cancer and is the presenting symptom in 20% of patients. The cause is usually vertebral body metastasis but it can also result from spread of cancer through the intervertebral foramen (especially with lymphoma), from carcinomatous meningitis, or from metastasis to the spinal cord. Cancer-related back pain tends to be constant, dull, unrelieved by rest, and worse at night. By contrast, mechanical low back pain usually improves with rest. MRI, CT, and CT myelography are the studies of choice when spinal metastasis is suspected. Once a metastasis is found, imaging of the entire spine reveals additional tumor deposits in one third of patients. MRI is preferred for soft tissue definition, but the most rapidly available imaging modality is best because the patient's condition may worsen quickly without intervention. Fewer than 5% of patients who are non-ambulatory at the time of diagnosis ever regain the ability to walk; thus, the early diagnosis is crucial.

**Referred pain from visceral disease.** Diseases of the thorax, abdomen, or pelvis may refer pain to the posterior portion of the spinal segment that innervates the diseased organ. Occasionally, back pain may be the first and only manifestation. Upper abdominal diseases generally refer pain to the lower thoracic or upper lumbar region (eighth thoracic to the first and second lumbar vertebrae), lower abdominal diseases to the midlumbar region (second to fourth lumbar vertebrae), and pelvic diseases to the sacral region. Local signs (pain with spine palpation, paraspinal muscle spasm) are absent and little or no pain accompanies routine movements of the spine.

Low thoracic or lumbar pain with abdominal disease tumors of the posterior wall of the stomach or duodenum typically produce epigastric pain, but midline back or paraspinal pain may occur if retroperitoneal extension is present. Fatty foods occasionally induce back pain associated with biliary disease. Diseases of the pancreas can produce right or left paraspinal back pain. Pathology in retroperitoneal structures (hemorrhage, tumors, pyelonephritis) can produce paraspinal pain that radiates to the lower abdomen, groin or anterior thighs. A mass in the iliopsoas region can produce unilateral lumbar pain with radiation toward the groin, labia, or testicle. The sudden appearance of lumbar pain in a patient receiving anticoagulant therapy suggests retroperitoneal hemorrhage.

**Back pain in psychiatric disease.** Chronic low back pain may be encountered in patients who seek financial compensation, in malingerers or in those with concurrent substance abuse. Many patients with chronic low back pain have a history of psychiatric illness (depression, anxiety states) or childhood trauma (physical or other type of abuse) that antedates the onset of back pain.

**Idiopathic back pain.** The cause of low back pain occasionally remains unclear. Some patients have had multiple operations for disk disease but have persistent pain and disability. The original indications for surgery may have been questionable, with back pain only, no definite neurologic signs, or a minor disk bulge noted on CT or MRI. Scoring systems based on neurologic signs, psychological factors, physiologic studies, and imaging studies should be used to minimize the likelihood of unsuccessful surgery.

## BIBLIOGRAPHY

1. Bradford D.S., Lonstein J.E., Moe J.H., et al. Juvenile kyphosis. In: Moe's textbook of scoliosis and other spinal deformities. 2nd ed. Philadelphia: WB Saunders Co.; 1987:347-368.
2. Carrage E. J. Clinical practice. Persistent low back pain. *N Engl J Med* 2005; 352:1891-1898.
3. Harrison's principles of internal medicine /ed. D. L. Kasper, A. S. Fauci, S. Hauser, – 19th ed. – New York: McGraw-Hill; 2015.– 2578 p.
4. Inman R. D. Mechanisms of disease: infection and spondyloarthritis. *Nat Clin Pract Rheumatol.* 2006; 2:163-169.
5. Kelley's text book of internal medicine / H. David Humes, et al. 4th ed.; Philadelphia: LWW; 2000. 3254 p.
6. Kumar P, Clark M. Clinical medicine: a textbook for medical students and doctors – 4th ed.– Edinburg: W. B. Saunders Company; 1998. 1326 p.

7. Mannion A.F. Pain measurement in patients with low back pain. *Nat Clin Pract Rheumatol.* 2007; 3: 610-619.
8. Nascimento F. A., Gatto L. A., Lages R.O., et al. Diffuse idiopathic skeletal hyperostosis: A review. *Surg Neurol Int.* 2014; 16; 5 (Suppl 3): S122-5. doi: 10.4103/2152-7806.130675.
9. Resnick D., Niwayama G. *Diagnosis of bone and joint disorders.* 2nd ed. Philadelphia: W. B. Saunders Co.; 1988. pp. 1563-615.
10. Rodriguez Garcia J. L. *Diagnostico, tratamiento medico.* Madrid: Marban; 2010. 1997p.
11. Sabatine M. S. *Pocket medicine: The Massachusetts General Hospital Handbook of Internal Medicine, (Pocket Notebook) 4ed.* Philadelphia:Lippincott Williams & Wilkins; 2010. 280 p. [https://www.gettextbooks.com/author/Marc\\_Sabatine](https://www.gettextbooks.com/author/Marc_Sabatine) (accessed 10.07.2017).

# DIFFERENTIAL DIAGNOSIS OF CONNECTIVE TISSUE DISEASES

**INTRODUCTION.** When differentiating a clinical picture, frequently it is initially impossible to identify the real diagnosis. Until relevant findings are present, one has to be content with the classification into one of the groups of diseases. In all unclear cases, consideration is almost always given to this at the beginning of the differential diagnostic process. This approach is frequently chosen because a diagnosis in the conventional sense is not always easy to make, as more than one diagnosis can often be possible at the same time.

## **Immune mediated diseases**

1. Systemic lupus erythematosus,
2. Polyarteriitis nodosa
3. Sclerodermia,
4. Dermatomyositis /polymyositis,
5. Periarthritis nodosa,
6. Wegener granulomatosis,
7. Allergic vasculitis.

## ***Common clinical manifestations***

- can be recognized clinically by the simultaneous involvement of multiple organs and
- are associated with arthritis,
- myopathy
- skin manifestations (purpura, exanthema, livedo reticularis),
- glomerulonephritis,
- pericarditis,
- pleuritis,
- alveolitis,
- mononeuritis.

## ***Laboratory test results can reveal:***

- median elevated erythrocyte sedimentation rate,
- anemia,
- immune complexes, the result of different antigens (e.g., bacteria, viruses, body's substances such as DNA, ribonucleoproteins, and medication),
- antinuclear antibodies in patients with collagen disease (Table 25).

**Antinuclear antibody patterns**

<b>Fluorescent pattern</b>	<b>Antigen</b>	<b>Disease association</b>
Rim peripheral shaggy	NDNA	SLE
Homogeneous	DNP	SLE, others
Speckled	ENA	MCTD, SLE, others
Nucleolar	RNA	Scleroderma

Notes: DNP– deoxyribonucleoprotein, ENA– extractable nuclear antigen, MCTD– mixed connective tissue disease; SLE– systemic lupus erythematosus.

**1. Systemic lupus erythematosus****Clinical forms of systemic lupus erythematosus**

- *Subacute cutaneous SLE*
- *Discoid SLE*
- *Latent SLE*
- *Drug-induced SLE*

**Subacute cutaneous SLE** – is characterized by the presence of distinct skin lesions (erythematous macules, papules, cancellous plaques, polycyclic contour, sometimes squamous) with recurrent development. The prevalence of musculoskeletal damage with high frequency of arthritis predominates is noted. The central nervous system and renal system deprivation, giving a favorable prognosis and serologically frequent detection of antibodies anti-SS-A/Ro or anti-DNAmc, sometimes in the absence of antinuclear antibodies occur.

**Discoid SLE** – Chronic skin lesions are present in the absence of systemic damage. Skin lesions are on the face, scalp, ears are erythematous and evolve with central atrophy and scarring, with definitive loss of appendages through follicular obstruction, telangiectasia, definitive alopecia. In 5% of cases it can turn to the systemic form.

**Latent SLE** – defines the situation where only one or two ACR criteria for SLE are present and a series of clinico-biological manifestations suggestive of autoimmune disease. There may be fever, physical asthenia, arthralgia, adenopathy, headache, neuropathies, against background of modified biological tests: increased ESR, hypocomplementemia, hypergammaglobulinemia, present rheumatoid factor. Some authors recommend the classification as undifferentiated connective tissue disease, the prognosis being good due to the evolution either to SLE without affecting the central nervous system and kidney, or stationary. Complement activity (increased/decreased) may be seen not only in SLE.



*Increased complement activity may be seen in:*

- Cancer
- Certain infections
- Ulcerative colitis

*Decreased complement activity may occur:*

- Systemic lupus erythematosus
- Lupus nephritis
- Cirrhosis
- Glomerulonephritis
- Hereditary angioedema
- Hepatitis
- Kidney transplant rejection
- Malnutrition.

**Drug-Induced Lupus.** Drug-induced SLE shows a direct relation of the disease with the consumption of drugs, and disappearance of the disease after discontinuation of the drugs. The drugs most commonly associated with drug-induced lupus are shown in Table 26. The clinical symptoms of drug-induced SLE mainly include fever, arthralgia, myalgia, and pleuropericarditis. Kidney and central nervous system manifestations are occur rarely, and the laboratory complement factors C3 and C4 therefore remain normal. Anti-DNA antibodies are mostly negative. Antinuclear antibodies and antibodies to histones and chromatin are positive.

Clinical features compared to systemic lupus, drug -induced lupus has the following features: middle age presentation, no gender difference, no “blacks,” acute onset, less cutaneous, renal, neurologic, and hematologic involvement, but equal joint, hepatic, and constitutional symptoms. Usually anti-histone antibody positive, anti-Smith negative, anti-dsDNA negative and normal complement levels.

Table 26

**Agents implicated in drug-induced SLE**

Definite	Probable
<p><b>Common</b>                      Beta-blockers, Carbamazepine, Chlorpromazine, D-Penicillamine, Ethosuximide, Hydralazine, Isoniazid, Hydantoins, Methyldopa, Phenytoin, Procainamide, Sulfasalazine</p>	<p>Amiodarone, Atenolol, Acebutolol, Captopril, Diclofenac, Estrogens, Ethanercept, Gold salts, Interferone, Infliximab, Lithium carbonate, Minocycline, Nalodixid acid, Oral contraceptive, Penicillin, Proctolol, Psoralen, Propylthiouracil, Quinidine, Spironolactone, Statins, Tetracycline</p>

**Differential diagnosis of SLE** is difficult in the onset of disease when symptoms and signs are diverse and variable. The differentiation should be with:

- Felty's syndrome,
- rheumatoid arthritis
- mixed connective tissue disease

**Felty's syndrome** is characterized by symmetric arthritis of the small joints, with bycitopeny-leukopenia and thrombocytopenia, splenomegaly; radiologic investigation show erosive arthritis with destruction of the joint tissue (rheumatoid arthritis pictures); biological tests are without SLE immunological markers.

**Rheumatoid arthritis** can be confused with SLE with inherent articular expression, especially at the onset of both conditions, when other additional criteria for diagnosis are absent. Raynaud's phenomenon, rheumatoid factor, acute phase reactants at elevated levels, and sometimes antinuclear antibodies may coexist. Instead, identifying an anti-CCP antibodies can distinguish in favor of RA. Important difficulties arise with the overlap syndrome-AR and LES, when the immunological picture can translate the diagnosis.

**Mixed Connective Tissue Disease (MCTD) or Overlap Syndrome (Sharp Syndrome).** MCTD is characterized by combination of clinical features of more than one connective tissue disease (systemic lupus erythematosus, progressive scleroderma, and polymyositis).

**Symptoms.** The primary features of MCTD are variable and include features of SLE, polymyositis, systemic sclerosis, and rheumatoid arthritis: the association of arthralgia and arthritis (96%), swelling of hands and fingers (88%), Raynaud syndrome (84%), myositis, acrosclerosis and myositis which mainly affect proximal muscles in the extremities (72%).

The involvement of the kidney is rare, and the response to corticosteroids is positive. After many years, however, MCTD progresses into progressive systemic sclerosis (PSS), and myositis lupus-like symptoms are no longer the leading symptoms.

**Diagnosis.** High titers of antinuclear antibodies directed to ribonuclease-sensitive ribonucleoprotein (RNP) are characteristic, but they have also been reported to occur in other connective tissue diseases. It is serologically characterized by a positive antinuclear antibody and by a high titer of the autoantibody anti-U1-70 RNP antibodies at the titer  $\geq 1:1600$ ; constantly missing anti-antibody anti nDNA and antiSm.

**The antiphospholipid syndrome.** The primary antiphospholipid antibody syndrome represents 50% of cases.

**Clinical features.** There is an association between the presence of the lupus anticoagulant and antiphospholipid antibodies and recurrent venous or arterial thrombosis. Thrombotic events described have included stroke, transient ischemic attacks, myocardial infarctions, brachial artery thrombosis, deep venous thrombophlebitis, retinal vein thrombosis, hepatic vein thrombosis resulting in Budd-Chiari syndrome, and pulmonary hypertension. Other manifestations include recurrent fetal loss, thrombocytopenia, positive results of Coombs test, migraines, chorea, epilepsy, chronic leg ulcers, livedo reticularis, and progressive dementia resulting from cerebrovascular accidents. Acquired valvar heart disease, especially aortic insufficiency, has been described. Although many patients with lupus and other diseases can have lupus anticoagulant or antiphospholipid antibodies, of either IgG or IgM class, thrombosis will not necessarily develop. Patients with the highest levels of antiphospholipid antibodies are more prone to thrombosis than those with lower levels. Also, IgG antiphospholipid antibody is more strongly associated with recurrent thrombosis than IgM antiphospholipid antibody.

Sensitive tests for detection of lupus anticoagulants:

- plasma clotting time,
- kaolin clotting time,
- platelet neutralization procedure,
- modified Russell viper venom time.

Many, but not all, patients with the lupus anticoagulant have also increased IgG or IgM antiphospholipid antibody levels. The hallmark of the antiphospholipid antibody syndrome is prolongation on all phospholipid-dependent coagulation tests.

The antibodies prolong the partial thromboplastin time at the level of the prothrombin activator complex of the clotting cascade.

***Lupus anticoagulant and antiphospholipid antibodies are associated with:***

- SLE,
- malignancy,
- infectious,
- drug-induced diseases.

Other associated diseases are

- Sjögren syndrome,
- rheumatoid arthritis,

- idiopathic thrombocytopenic purpura,
- Behçet syndrome,
- myasthenia gravis, and mixed connective tissue disease.

The antibodies (lupus anticoagulant and antiphospholipid antibodies) are also found in persons with no apparent disease but in whom recurrent thrombosis develops.

*The differential diagnosis* can be done to analyzed for multiple neurological, renal, pleuro-pulmonary, cardiovascular, muscular, articular disorders – but with no particular and specific SLE and immunological context.

## 2. Progressive systemic sclerosis (PSS)

**Definition.** Progressive systemic sclerosis is an autoimmune disease which affects connective tissue and leads to fibrosis. The fibrosis is mainly seen in the skin (scleroderma), lung, gastrointestinal tract, heart, and kidney. The major criteria are symmetric induration of the skin of the fingers and the skin proximal to the metacarpophalangeal or metatarsophalangeal joints. The minor criteria are sclerodactyly, digital pitting scars or loss of substance from the finger pad, and bibazial pulmonary fibrosis. One major criterion or two or more minor criteria need to be present for the diagnosis of systemic sclerosis.

Table 27

**Clinical manifestations of limited and systemic scleroderma**

Systemic Sclerosis	Limited	Diffuse
General		Fatigue, weight loss
Skin	Thickening on distal extremities and face only	Thickening on extremities (incl. digits), face, and trunk
Nails	Capillary dropout +/- dilatation	Capillary dropout & dilatation
Pulmonary	PAH > fibrosis	Fibrosis > PAH
Gastrointestinal	GERD, hypomotility, PBC	GERD, hypomotility
Renal		Renovascular HTN
Cardiac		Restrictive cardiomyopathy
Other	CREST syndrome = Calcinosis, Raynaud's Esophageal dysmotility Sclerodactyly, Telangiectasias	Raynaud's phenomenon
Antibodies	Anticentromere (70%)	Anti-Scl 70 (40%)
Prognosis	Survival >70% at 10 years	Survival 40–60% at 10 years

*Differential diagnosis of scleroderma early in its course* can cause diagnostic confusion with other causes of Raynaud phenomenon, particularly SLE, mixed connective tissue disease, and inflammatory myopathies. Scleroderma can be mistaken for other disorders characterized by skin hardening.

**Raynaud phenomenon** (RP) is a syndrome of paroxysmal biphasic or triphasic color changes (pallor, cyanosis, erythema) accompanied by pain and numbness in the hands or feet digital ischemia, most commonly caused by an exaggerated response of digital arterioles to cold or emotional stress. The initial phase of RP, mediated by excessive vasoconstriction, consists of well-demarcated digital pallor or cyanosis; the subsequent (recovery) phase of RP, caused by vasodilation, leads to intense hyperemia and rubor. Although the fingers are chiefly affected, RP can also affect toes and other acral areas such as the nose and ears. RP is classified as primary (idiopathic or Raynaud disease) or secondary. It usually persists for more than 2 years before the skin changes develop.

*Primary form of Raynaud phenomenon/disease* (50%) is benign, except for all secondary causes. In primary Raynaud disease, are usually affected females. The ratio women: males =5:1. The onset is at menarche, usually all digits are involved, and attacks are very frequent. The severity of symptoms is mild to moderate, and they can be precipitated by emotional stress. In male patients with Raynaud phenomenon, a rare occurrence, a connective tissue disease may develop. Although Raynaud phenomenon is common in females, it is usually not associated with a connective tissue disease unless the patient has positive results for antinuclear antibody, which suggest that a connective tissue disease may develop in the future. Digital ulceration and finger edema are rare, as is periungual erythema. Livedo reticularis is frequent.

**Clinical features:** mild symmetric episodic attacks with no evidence of peripheral vascular disease, no tissue injury, normal nail fold capillary examination. Biological tests: negative ANA, normal ESR.

**Secondary form of RP** can cause digital ulceration or gangrene. Typically, patients are over 35 years of age and there is presence of different diseases (Table 28).

Males and females are affected with Raynaud phenomenon due to a connective tissue disease. It often begins in a single digit, and attacks are usually infrequent (zero to five a day). It is moderate to severe, and the disorder is not precipitated by emotional stress. Skin capillary microscopy reveals tortuous, dilated capillary loops in systemic sclerosis, mixed connective tissue disease, and polymyositis. They may also be present in patients with Raynaud phenomenon who will develop further systemic sclerosis, polymyositis, or mixed connective tissue disease. Digital ulceration, finger edema, and periungual erythema are frequent. Livedo reticularis is uncommon.

**Causes of secondary Raynaud phenomenon**

Chemotherapeutic agents	Bleomycin, Vinblastine, polyvinyl clorid, beta-blockers, estrogen, progesterone, nicotine
Toxins	Vinyl chloride
Vibration-induced injuries	Jack hammer use
Vascular occlusive disorders (Obstructive artheriopathy)	Thoracic outlet obstruction Atherosclerosis Vasculitis Brachiocephalic atherosclerosis, thrombosis, embolism, external compression
Rheumatic and auto-immune diseases Connective tissue diseases	Scleroderma, 90%-100% Mixed connective tissue disease, 90%-100% Systemic lupus erythematosus, 15% Rheumatoid arthritis, <10% Polymyositis Takayasu vasculitis, giant cells arteriitis, primary biliary cirrhosis carpian tunnel chanal syndrome, chest defile thoracic syndrome
Physical aggression	Vibrations, frost-bite, trauma of large vessels
Vasospastic diseases	Migraine or vascular headache, Prinzmetal angina pectoris,
Endocrine diseases	Feochromocytoma, Carcinoid syndrome
Neurological diseases	Poliomyelitis, siringomieli, hemiplegy
Neoplasia	Ovarian tumor, angiocentric lymphoma
Miscellaneous Blood abnormalities	Cryoglobulinemia Cold agglutinins Increased blood viscosity cryofibrinogenemia, paraproteinemia, polycythemia,
Infections	Parvovirus B19, <i>Helicobacter pylori</i>
Others	Nervous anorexia, algoneurodystrophy

**CREST syndrome.** This is characterized by calcinosis cutis, Raynaud phenomenon, esophageal dysmotility, sclerodactyly, and telangiectasias. Skin involvement progresses slowly and is limited to the extremities. The development of internal organ involvement occurs but is delayed. Lung involvement occurs in 70% of patients. Diffusing capacity may be low, and pulmonary hypertension can develop. The latter is more common in CREST than in diffuse scleroderma. Bosentan was recently approved for severe pulmonary hypertension, scleroderma, and CREST syndrome. The onset of Raynaud phenomenon occurs less than 2 years before the skin

changes. Anticentromere antibody is found in 70% to 90% of patients and antiscleroderma-70 antibody – in 10%. The incidence of primary biliary cirrhosis is increased.

### ***Circumscribed scleroderma***

Circumscribed scleroderma (morphea) must be differentiated from progressive systemic sclerosis (PSS), as it is limited to the skin, and presents neither with acral lesions nor with Raynaud syndrome. Various dermal manifestations have been described: focal forms (morphean plaques), linear (scleroderma en coup de sabre, sword stroke) and patchy (morphea guttata) ones. The prognosis of circumscribed scleroderma is favorable. Spontaneous remissions are frequent (50%), and transition to PSS is rare.

### ***Scleroederma adultorum (Buschke Syndrome)***

In both adolescents and women, a scleroderma-like disease, named scleroderma adultorum, develops within one to six weeks after an infection, usually streptococcal one, and initially affects the throat. However, the whole body can become involved. The prognosis is favorable, and the disease resolves after six to 12 months.

***One form of PSS is Thibierge–Weissenbach syndrome*** (calcinosis of the skin, tendons, bursas). Systemic diseases of the connective tissues occur either separately or combined with other collagenoses. Sometimes it is hard to define the clinical unit exactly and therefore these states are called *overlap syndromes or close syndromes*. One of such collagenoses coinciding with these diseases is calcinosis. It is most often found in children but rarely in adults.

***Scleroderma-Like Syndromes Disorders*** associated with occupation or environment. This group includes polyvinyl chloride disease, organic solvents, jackhammer disease, silicosis, and toxic oil syndrome.

***Scleroderma-like diseases*** also occur in graft-versus-host disease (GVH) after bone marrow transplantation, in primary biliary cirrhosis (PBC), and in intestinal carcinoid syndrome.

An association with silicone breast implants has been suggested but remains unverified.

***Metabolic Causes of Scleroderma-Like Syndrome*** This group includes porphyria, amyloidosis, carcinoid, and diabetes mellitus (flexion contractures of the tendons in the hands, cheiropathy, can develop).

In ***graft-versus-host*** disease skin induration develops in up to 30% of patients after bone marrow transplantation.

***Drug-induced disorders*** are caused by carbidopa, bleomycin, and bromocriptine.

**Pulmonary fibrosis** is observed from exposure to busulfan, bleomycin, and trichloroethylene.

**Eosinophilic myalgia syndrome** is associated with ingestion of contaminated L-tryptophan. Eosinophilia, myositis, skin induration, fasciitis, and peripheral neuropathy develop. Skin changes are similar to those of eosinophilic fasciitis. There is a poor response to steroids.

**Scleroderma frequently occurs after streptococcal upper respiratory tract infection in children.** It is usually self-limiting. Swelling of the head and neck is common. In adults, diabetes mellitus often is associated. Cocaine use and appetite suppressants also cause scleroderma-like illness.

**Eosinophilic fasciitis (Shulman syndrome)** is a rare scleroderma-like disease presenting with skin changes that resemble diffuse scleroderma. The inflammatory abnormalities are limited to the fascia rather than the dermis and epidermis and are characterized by subepidermal, eosinophilic skin indurations of the extremities with heavily reduced agility of the joints. Patients with eosinophilic fasciitis are distinguished from those with scleroderma by the presence of peripheral blood eosinophilia, absence of Raynaud phenomenon, good response to prednisone, and association (in some cases) with paraproteinemia. The hallmark of this disease is a distinct eosinophilia, hypergammaglobulinemia, and an elevated erythrocyte sedimentation rate. Antinuclear antibodies are absent. A good response to systemic treatment with corticosteroid has been observed, and the disease resolves within two to 19 months. There is no involvement of the internal organs.

**Scleromyxedema.** Diffuse skin thickening and visceral involvement are the features of scleromyxedema. The presence of paraprotein, the absence of Raynaud phenomenon, and distinct skin histology point to scleromyxedema. That is associated with IgG monoclonal protein.

**Diabetic cheiropathy** typically develops in long-standing, poorly controlled diabetes and can mimic sclerodactyly.

**Nephrogenic fibrosing dermopathy** produces thickening and hardening of the skin of the trunk and extremities in patients with chronic kidney disease; exposure to gadolinium may play a pathogenic role.

**Morphea and linear sclerodermas** cause sclerodermatous changes limited to circumscribed areas of the skin and usually have excellent outcomes.

**Differential diagnosis of Progressive systemic sclerosis** must be distinguished from

- rheumatoid arthritis,
- SLE,



- Raynaud syndrome,
- dermatomyositis,
- Sjögren syndrome,
- mixed connective tissue disease (MCTD) or Sharp syndrome. Many of the patients described by Sharp in 1972 later developed PSS in the course of their disease.

### 3. Polymyositis and dermatomyositis

The clinical picture is dominated by nonsuppurative inflammation of the striated muscle, causing proximal muscle weakness. When the skin is involved it is called dermatomyositis.

In clinical pictures of polymyositis the major feature is proximal muscle weakness which is progressive. There is wasting of the shoulder and pelvic girdle muscles with pain, weakness and tenderness. Patients have difficulty squatting, going up stairs, rising from a chair and rising their hands above the head. Respiratory muscles are affected in severe disease (in Jo1 antibodies positive patients) and may require ventilation. Dysphagia is seen in 50% of patients owing to esophageal muscle involvement. Arthralgia occurs in 25–30% of cases and as a rule is mild. Cutaneous feature includes a heliotrope (purple) discoloration of the eyelids and periorbital oedema. Scaly, purple-red raised vasculitic patches occur over the extensor surface of joints and fingers (collodion patches). Ulcerative vasculitis and calcinosis of the subcutaneous tissue are common in the childhood form and occur in 25% of adults. In the long term, muscle fibrosis and contractures of joints occur. There is an association with other autoimmune disease (SLE, RA, SS) with Raynaud's phenomenon.

There is also an association with malignancy (lung, ovary, breast, stomach) which can predate the onset of myositis. This occurs in males with dermatomyositis.

*Inflammatory myopathies* are classified as polymyositis, dermatomyositis, and inclusion body myositis associated with malignancy (gastrointestinal, lung, ovarian, breast, lymphoma) in >45% of patients. The clinical features of proximal, symmetric, progressive muscle weakness developing over weeks to months, may be associated with morning stiffness. Muscle pain is not common. Extramuscular manifestations include arthralgias, cardiac signs (conduction abnormalities, cardiomyopathy), respiratory signs (muscle weakness, aspiration, interstitial lung disease), skin manifestations (Gottron's papules (dorsal aspect of MCP and IP joints/elbows/knees), heliotrope rash (over the upper eyelids with periorbital edema), V rash/

shawl sign (erythematous rash over upper chest/back/shoulders), periungual telangiectasia, mechanic's hand (with darkened horizontal lines across the lateral and palmar aspects of fingers/ hands), and constitutional symptoms. Reflexes are usually normal. Differentiation between steroid myopathy and inflammatory are shown in Table 29.

Table 29

### Distinguishing features between steroid myopathy and inflammatory myopathy

	<b>Steroid myopathy</b>	<b>Inflammatory myopathy</b>
History	Steroid use Other steroid related symptoms	Other inflammatory myopathy symptoms
Physical	Neck flexor normal	Weaker neck flexor
Tests	CK less often ↑	CK often ↑, anti Jo1/anti Mi2 Ab
EMG	Normal	Abnormal activity
Discontinuation of steroid treatment	Improves	Worsens

**Diagnosis.** The laboratory results can show elevation of muscle enzymes, EMG findings consistent with inflammatory myositis, muscle biopsy consistent with inflammatory myositis. All four criteria for definite polymyositis, and three criteria plus skin findings are needed for definite dermatomyositis. It is important to exclude other causes of myopathy. Myositis – specific antibodies for the differentiation are shown in Table 30.

Table 30

### Myositis-specific antibodies

<b>Antibody</b>	<b>Clinical Association</b>
Anti-Jo-1 and other antisynthetase antibodies	Polymyositis or dermatomyositis with interstitial lung disease, arthritis, mechanic's hands
Anti-Mi-2	Dermatomyositis with rash more than myositis
Anti-MDA5 (anti-CADM 140)	Dermatomyositis with rapidly progressive lung disease, cutaneous ulcers
Anti-155/140	Cancer-associated myositis
Anti-140	Juvenile dermatomyositis
Anti-SAE	Cancer-associated dermatomyositis, dermatomyositis with rapidly progressive lung disease
Anti-signal recognition particle	Severe, acute necrotizing myopathy
Anti-HMG CoA reductase	Necrotizing myopathy related to statin use

**4. Polyarteriitis nodosa (PAN)** is a systemic necrotizing vasculitis. It brings together polymorphic manifestations with multisystem, cutaneous, cardiovascular, neurological, renal, digestive, articular, similar LES, with the presence of rheumatoid factor and decrease complement. PAN affects predominantly males aged 50–60. Vasculitis is dominant, angiographically and histopathologically objectivized. Serological level of p ANCA may be elevated and HBV and HCV markers were positive in 10–50% of patients. But there are no photosensitivity phenomena; antibodies anti DNA<sub>n</sub>, antiSm, anticardiolipin are negative.

The criteria of PAN (American College of Rheumatology 1990), when a radiographic or pathological diagnosis of vasculitis is made are the following:

- Weight loss greater than/equal to 4.5 kg
- Livedo reticularis (a mottled purplish skin discoloration over the extremities or torso)
- Testicular pain or tenderness (occasionally, a site biopsied for diagnosis)
- Muscle pain, weakness, or leg tenderness
- Nerve disease (either single or multiple)
- Diastolic blood pressure greater than 90 mmHg (high blood pressure)
- Elevated kidney blood tests (BUN greater than 40 mg/dl or creatinine greater than 1.5 mg/dl)
- Hepatitis B (not C) virus tests positive (for surface antigen or antibody)
- Arteriogram (angiogram) showing the arteries that are dilated (aneurysms) or constricted by the blood vessel inflammation
- Biopsy of tissue showing arteritis (typically inflamed arteries):  
The sural nerve is a frequent location for the biopsy.

A patient is said to have polyarteritis nodosa if he/she has three of the 10 signs known.

**5. Wegener's granulomatosis.** The presence of cutaneous, neurological and articular lesions may clinically suggest SLE.

Diagnostic criteria:

- Necrotizing granulomas in respiratory tract,
- Generalized necrotizing arteritis,
- Glomerulonephritis,

Any organ may be involved, eg nasal ulcers, epistaxis, rhinitis, sinus

involvement, otitis media (+/- sensorineural deafness/ vertigo), multiple cranial nerve lesions, oral ulcers, gum hypertrophy +/- bleeding and microabscesses, lung symptoms and variable shadows on chest X ray. Eye signs are proptosis +/- ptosis (orbital granuloma), conjunctivitis, corneal ulcers, episcleritis, scleritis, uveitis, retinitis.

The clinical distinction is achieved by signs of the upper respiratory tract, lung and ocular damage, as well as by the high specific identification of antibodies c- ANCA anti PR3.

## 6. Allergic vasculitis

*Churg – Strauss syndrome* has similarities with SLE – purpura phenomena, Reynaud phenomenon, glomerular, pleural, cardiac and neurological impairment. But the distinction is made by the presence of characteristic respiratory manifestations – severe asthmatic attacks with aggravations that precede the manifestations of vasculitis, maxillary sinusitis, allergic rhinitis, nasal polyposis, respiratory failure. Biological tests are specific – constant eosinophilia and characteristic  $>1000/\text{mm}^3$ , serological IgE elevated, antibody ANCA – positive, especially in antimyeloperoxidase type.

*Microscopic polyangiitis* has cutaneous, renal, neurological signs that may suggest SLE, but there is respiratory impairment, cANCA antibodies and p ANCA (absent in LES), lacking antibodies anti DNAn.dc and anti Sm.

*Haemoblastosis* – such as acute and chronic leukemia, lymphomas, may suggest SLE by fever, adenoma gals, splenomegaly, joint, pleural, and neurological affections – but there is a characteristic feature and medullary hematology and missing antibodies anti DNAn.dc and anti Sm.

*Sjögren's syndrome* is a chronic inflammatory autoimmune disease with clinical symptoms characterized by keratoconjunctivitis sicca, xerostomia, and intermittent swelling of salivary glands. The histopathology of the salivary glands has been well documented and consists of infiltration of the glands with lymphoid cells associated with atrophy of acinar glands. At times, lymphocyte infiltration is so extensive that lymphoid follicles are present in these tissues. Sjögren's syndrome however can be found in association with other connective tissue diseases, such as rheumatoid arthritis (RA), progressive systemic sclerosis (PSS), and systemic lupus erythematosus (SLE). In addition, complications of the disease such as renal tubular acidosis, myopathy, and plasma cell dyscrasias are frequently encountered.

*Secondary Sjögren syndrome* accompanying another connective tissue disease is not classified as an overlap syndrome.

***Connective tissue disease – associated vasculitis***

It is vasculitis associated with RA, SLE, or Sjögren's syndrome.

Its clinical manifestations are distal arteritis—digital ischemia, livedo reticularis, palpable purpura, cutaneous ulceration; visceral arteritis – pericarditis and mesenteric ischemia; peripheral neuropathy. *Diagnosis.* Skin and sural nerve biopsy, angiography, electromyography; decreased complement in SLE, positive in RA.

***Undifferentiated connective tissue disease***—overlap syndrome with clinical features of two or more rheumatologic disorders (RA, SLE, Sjogren's syndrome, scleroderma, inflammatory myopathies). This category includes patients with symptoms that do not fulfill the diagnostic criteria for a definite or specific connective tissue disease. The common symptoms include Raynaud phenomenon, arthralgias, fatigue, and variable joint or soft tissue swelling. The antinuclear antibody may be positive, but other autoantibodies are not present.

***Rheumatic (vasculitic) manifestations of HIV*** include diffuse infiltrative lymphocytosis syndrome (with parotid gland enlargement, the glands are infiltrated with CD8 lymphocytes) that is manifested by xerostomia, xerophthalmia, and salivary gland swelling mimicking Sjögren syndrome, lupus-like syndrome, systemic vasculitis of the necrotizing a hypersensitivity type and myositis. In contrast to Sjögren syndrome, HIV-positive patients usually do not have antibodies to SS-A or SS-B and are usually rheumatoid factor-negative. There is an acquired immunodeficiency syndrome-associated myopathy that may be viral. There is also myopathy due to zidovudine therapy. Fibromyalgia has also been reported in up to 25% of HIV-infected patients. The introduction of HAART (Highly Active Anti-Retroviral Therapy) has been associated with a marked decreased frequency of painful articular syndromes, psoriatic arthritis, spondyloarthropathy, increased frequency of the immune reconstitution inflammatory syndrome (IRIS) and osteoporosis.

**BIBLIOGRAPHY**

1. Bennett R. M., Axford J. S. Romain P. L. Clinical manifestations of mixed connective tissue disease. Literature review current through: Apr 2012 (This topic last updated: May 12, 2011). <https://www.uptodate.com/contents/clinical-manifestations-of-mixed-connective-tissue-disease> (accessed 20.07.2017).
2. Brey R. L. Differential diagnosis of central nervous system manifestations of the antiphospholipid antibody syndrome. *J Autoimmun.* 2000; 15:133-138.

3. Ciurea P., Rosu A., Musetescu A., et al. *Reumatologie*. Craiova : Editura Medicala Universitara Craiova; 2007. 466 p.
4. Denton C. P., Black C. M. Management of systemic sclerosis. In: Hochberg M., Silman A., Smolen J., Weinblatt M., et al eds. *Rheumatology*, 3rd ed. Edinburg London: Mosby; 2003;2 (10):1493-1506.
5. Firestein G.S. Etiology and pathogenesis of rheumatoid arthritis. In: Ruddy S., Harris E., Sledge C., eds. *Kelly's Textbook of Rheumatology*, 6th ed. Philadelphia: WB Saunders; 2001, p. 921-966. <http://www.sciepub.com/reference/107603> (accessed 22.08.2017)
6. Gladman D. D., Urowitz M. B. Systemic lupus erythematosus. Clinical features. In: *Rheumatology*. Eds: Hochberg M., Silman A., Smolen J., et al. Philadelphia: Elsevier Limited; 2003, V. 2: 1359–1380. [https://internadomedicina.files.wordpress.com/2014/10/pocket-medicine\\_-the-massachusetts-general-hospital-handbook-of-internal-medicine.pdf](https://internadomedicina.files.wordpress.com/2014/10/pocket-medicine_-the-massachusetts-general-hospital-handbook-of-internal-medicine.pdf) (accessed 10.07.2017).
7. Le Roy E.C., Medsger T. A. Jr. Criteria for the classification of early systemic sclerosis. *J Rheumatol*. 2001; 28:1573-1576.
8. Ramos-Casals M., Tzioufas A.G., Font J. Primary Sjogren's syndrome: new clinical and therapeutic concept *Ann Rheum Dis*. 2005; 64:347-354.
9. Rodriguez Garcia J. L. *Diagnostico, tratamiento medico*. Madrid: Marban; 2010.1997 p.
10. Sabatine M. S. *Pocket medicine: The Massachusetts General Hospital Handbook of Internal Medicine, (Pocket Notebook)*. 4ed. Philadelphia: Lippincott Williams & Wilkins; 2010. 280p. [https://www.gettextbooks.com/author/Marc\\_Sabatine](https://www.gettextbooks.com/author/Marc_Sabatine) (accessed 10.07.2017).
11. Smith E. A. Systemic sclerosis-etiology and pathogenesis. In: Hochberg M., Silman A., Smolen J.S., et al.), Mosby, New York, pp.1481-1492.
12. Vitali C., Bombardieri S., Jonsson R., et al. European Study Group on Classification Criteria for Sjögren's Syndrome. Classification criteria for Sjogren's syndrome: a revised version of the European criteria proposed by the American-European Consensus Group. *Ann Rheum Dis*. 2002; 61: 554-8.

## DIFFERENTIAL DIAGNOSIS OF FEVER OF UNKNOWN ORIGIN

**INTRODUCTION.** Initially, all febrile illnesses are Fevers of Unknown Origin (FUOs). However, FUOs are an unusual and heterogeneous group of prolonged febrile disorders that elude diagnosis even after intensive investigation for an internist.

### DEFINITION.

Classic definition: Petersdorf (1961) and Beeson suggested the following criteria for the definition of FUO:

- Fever  $\geq 38.3^{\circ}\text{C}$  [ $\geq 101^{\circ}\text{F}$ ], on several occasions
- Fever persisting without diagnosis for at least  $\geq 3$  weeks,
- At least one week investigation in hospital

*A new definition* which includes the outpatient setting (which reflects current medical practice) is broader, stipulating:

- 3 outpatient visits or
- 3 days in the hospital without elucidation of a cause or
- One week of "intelligent and invasive" ambulatory investigation.

**ETIOLOGY AND EPIDEMIOLOGY.** The range of FUO etiologies has evolved over time as a result of changes in the spectrum of diseases causing FUO, the widespread use of antibiotics, and the availability of new diagnostic techniques. The proportion of cases caused by intraabdominal abscesses and tumors, for example, has decreased because of earlier detection by CT and ultrasound; infective endocarditis is a less frequent cause because blood culture and echocardiographic techniques have improved. Acute HIV infection were unknown four decades ago. Neoplasms and noninfectious inflammatory diseases (NIIDs), the latter including collagen or rheumatic diseases, "vasculitis syndromes", and granulomatous disorders are next in frequency. Many NIIDs can be diagnosed only after prolonged observation and exclusion of other diseases. The percentage of undiagnosed cases of FUO has increased in more recent studies.

### Common causes of FUO:

- Infections (23%–36%): Tuberculosis, endocarditis, local suppurative process (e.g., biliary tract, kidney), septic thrombophlebitis, cytomegalovirus, Epstein-Barr virus, parvovirus, etc.
- Neoplastic disease (7%–31%): Lymphoma, leukemia, renal cell car-

- cinoma, and gastrointestinal tumors
- Collagen vascular diseases (9%–20%): systemic lupus erythematosus, rheumatoid arthritis, mixed connective tissue disease, temporal arteritis, etc.
  - Miscellaneous(17%–24%): Drug fever, deep vein thrombosis, pulmonary emboli, sarcoidosis, factitious or fraudulent fever,
  - Nosocomial FUO – temperature  $>38.3^{\circ}\text{C}$ , patient hospitalized  $> 24$  hours, but no fever or incubating on admission. Lasting for at least 3 days. Common causes: *Clostridium difficile* enterocolitis, drug-induced, pulmonary embolism, septic thrombophlebitis, sinusitis.
  - Immune deficient (neutropenic) FUO – Temperature  $>38.3^{\circ}\text{C}$ , neutrophil count  $\leq 500$  per  $\text{mm}^3$ , lasting for at least 3 days. Common causes: Opportunistic bacterial infections, aspergilosis, candidiasis, herpes virus
  - HIV – associated – temperature  $>38.3^{\circ}\text{C}$ , duration of  $>4$  weeks for outpatients,  $>3$  days for inpatients, HIV infection confirmed. Common causes: Cytomegalovirus, *Mycobacterium avium intracellulare* complex, *Pneumocystis jirovecii* pneumonia, drug – induced, Kaposi's sarcoma, lymphoma.

#### **Uncommon causes of FUO:**

- central fever,
- endocrine (hypothalamic dysfunction, hyperthyroidism, pheochromocytoma, adrenal insufficiency), infections (dental abscess, Q fever, leptospirosis, psittacosis, tularemia, melioidosis, syphilis, gonococemia, chronic meningococemia, Whipple's disease, yersiniosis, brucellosis),
- hereditary periodic fever syndromes (familial Mediterranean fever, PFAPA syndrome (Periodic Fever with Aphthous Stomatitis and Adenitis),
- TNFR 1 – associated periodic syndrome, hyper-IgD syndrome, Muckle Wells syndrome, familial cold autoinflammatory syndrome), alcoholic hepatitis, hematoma.

**Clinical manifestation** include dorsolumbar pain, generalized myalgia, arthralgia, anorexia and sleepiness.

Chills– feeling cold (occurs in most febrile states and is a response of the nervous system to the „thermoregulation threshold”);

Frequently, true chills are observed in the following conditions:

- bacteremia of various origins



- sepsis, subacute bacterial endocarditis
- bacterial pneumonia
- meningococcal meningitis
- erysipelas
- malaria
- acute pyelonephritis
- Weil disease
- allergic reactions (intravenous drugs, radiograph contrast media, or blood products).

Chills occur rarely in tuberculosis, paratyphus, typhus, rickettsiosis and viral diseases and never in rheumatic fever. Rigor, piloerection („chicken skin”) associated with teeth chattering, not rarely accompanied by tremor. Skin lesion— a rash or other features: fungal infections, HIV, measles, rubella, Epstein-Barr virus, hepatitis B virus, usually present with a maculopapular rash. Herpes simplex virus and varicella-zoster virus present with a vesicular rash, whereas patients with Rickettsiae, yellow fever, viral hemorrhagic fever, and coxsackie virus may develop a petechial rash. Constitutional syndrome is frequently present.

**Diagnosis.** The evaluation of the patient with FUO must be systematic.

*Medical History.* A detailed history and careful physical examination are its cornerstones. The epidemiologic history is especially important. Details about a patient’s background, family medical history, occupations, hobbies, participation in sports, recent travel, international travel (tropical), contacts with animals, insect bites and other injuries, food consumption, previous illnesses, as well as diagnostic and therapeutic interventions, vaccinations, skin rashes, medications, or illicit (intravenous) drug use can provide important information. A systematic interview concerning the functioning of organ systems and comprehensive information about the present condition are likewise important. The social environment of the patient and his or her sexual preferences should also be discussed. Family history of fevers (familial Mediterranean fever), and a complete list of medication used by the patient should be studied.

The following parts of the body are occasionally neglected during physical examination: ocular fundus, temporal arteries, nasal sinuses, thyroid gland, renal beds, spinal column, uterine appendages, and prostate gland. Afflictions of these organs are occasionally clinically asymptomatic, which incorrectly leads to the search for a systemic cause of the fever.

**Laboratory evaluation.** Initial studies should include:

- Complete blood count with manual differential, blood smear, erythrocyte sedimentation rate;
- urinalysis;
- biochemical tests;
- serologic studies for fungal infections and for connective tissue disorders;
- examination of the stool for the presence of occult blood;
- bacterial cultures of urine, sputum, and blood;
- testing of thyroid function;
- chest radiography;
- electrocardiography,
- lumbar puncture.
- a tuberculin skin test should also be carried out.
- A careful funduscopic examination: which may show choroid tubercles suggestive of miliary tuberculosis,
- otoscopic test,
- genital, and rectal examination should also be performed.

The source of abnormalities detected in one or more of the initial studies should be pursued with more specific investigations. If these tests do not give conclusive results, repeated physical examination and empirical investigations are administered.

### **Imaging studies**

- bronchoscopy
- gastrointestinal endoscopy,
- oral cholecystography
- Computed tomography scans, magnetic resonance imaging of the brain, chest, and abdomen also may be helpful,
- ultrasound
- lymphangiography or gallium scintigraphy identifies important abnormalities not apparent in other examinations.
- Biopsy of the liver, bone marrow, affected lymph nodes or skin may be indicated for some patients

If these studies fail to yield a diagnosis, the physician has three options:

1. The entire evaluation may be repeated in anticipation of the development of abnormalities on tests that previously showed normal results;
2. a therapeutic trial directed against a probable but unproved diagnosis (e.g., a therapeutic trial of isoniazid and rifampin for suspected occult tuberculosis) may be initiated;

3. or the patient may be monitored for new signs or symptoms requiring further assessment.

### *Special entities*

**Tuberculosis** (see Differential diagnosis of pulmonary consolidation)

**Infective endocarditis.** The clinical finding of a heart defect (congenital heart defect 7–16%, post-rheumatic valvulopathy – 20–40%) must raise the suspicion of infectious endocarditis in each incidence of fever. However, pathological and anatomical studies indicate that in up to 50% of cases endocarditis is present in normal or degeneratively altered valves. The mitral valve is most often affected, followed by the aortic valve. Incidents of endocarditis affecting the right heart are found in less than 10% of the cases (especially in intravenous drug abuse). Cases of postoperative endocarditis after heart operations, especially after using a heart–lung machine, endocarditis on artificial valves, and endocarditis in intravenous drug users have increased significantly during recent years.

There are the following categories of endocarditis:

- Native valve endocarditis (NVE), acute and subacute
- Prosthetic valve endocarditis (PVE), early and late
- Intravenous drug abuse (IVDA) endocarditis
- Other terms commonly used to classify types of IE include pacemaker IE and nosocomial IE (NIE).

**Clinical features and course.** Acute endocarditis is rare. Insidious courses are more frequent. A general feeling of malaise, ill-defined limb pain, subfebrile temperatures, and night sweats are the earliest symptoms. Initially chills are unusual. They occur more frequently later in the course of the disease. Noninfectious endocarditis (Libman–Sacks syndrome in systemic lupus erythematosus, rheumatic fever, carcinoid syndrome) occurs without chills.

The alteration in the character of the heart murmur is of decisive, diagnostic significance in auscultation. Splenomegaly is commonly found in about 30% of advanced cases. Septic microembolisms are of pathognomonic significance (approximately 30% of the cases), which are predominantly located on the fingers and toes (Osler nodes), palms and soles of the feet (Janeway lesions), but also in the conjunctivae or subungually. Microembolisms can still develop during an adequate antibiotic therapy. Larger embolisms can also cause cerebral deficits. Therefore, it is always necessary to consider infectious endocarditis in younger patients experiencing a febrile apoplectic stroke.

**Acute native valve endocarditis**

- Frequently involves normal valves and usually has an aggressive course.
- It is a rapidly progressive illness in persons who are healthy or debilitated.
- Virulent organisms, such as *S aureus* and group *B streptococci*, are typically the causative agents of this type of endocarditis. Underlying structural valve disease may not be present.

**Subacute native valve endocarditis**

- Typically affects only abnormal valves.
- Its course, even in untreated patients,
- Is usually more indolent than that of the acute form and may extend over many months.
- *Alpha-hemolytic streptococci* or *enterococci*, usually in the setting of underlying structural valve disease, typically are the causative agents of this type of endocarditis.

**Prosthetic valve endocarditis accounts for 10-20% of cases of IE**

- Eventually, 5% of mechanical and bioprosthetic valves become infected.
- Mechanical valves are more likely to be infected within the first 3 months of implantation, and, after 1 year, bioprosthetic valves are more likely to be infected.
- The valves in the mitral valve position are more susceptible than those in the aortic areas
- Early PVE occurs within 60 days of valve implantation.
- Traditionally, *coagulase-negative staphylococci*, *gram-negative bacilli*, and *Candida species* have been the common infecting organisms.
- Late PVE occurs 60 days or more after valve implantation. *Staphylococci*, *alpha-hemolytic streptococci*, and *enterococci* are the common causative organisms.
- Recent data suggest that *S. aureus* may now be the most common infecting organism in both early and late PVE

**IE in drug abusers.** In 75% of cases of IVDA IE, no underlying valvular abnormalities are noted, and 50% of these infections involve the tricuspid valve. *S. aureus* is the most common causative organism.

Colon carcinomas have frequently been found in patients with *Streptococcus bovis* sepsis. In sterile endocarditis and joint pain, Whipple disease must be considered in the differential diagnosis. The pathogen, *Tropheryma*

*whippleii*, has been detected in valve material by molecular genetic methods. In fungal endocarditis (drug addicts and after valve replacement), blood cultures usually remain sterile. If an appropriate clinical suspicion exists, the microbiological laboratory must be informed of the tentative diagnosis.

Table 31

### Duke criteria for infective endocarditis

Major criteria	Minor criteria
<ul style="list-style-type: none"> <li>• Positive blood culture:</li> <li>• Typical organism in 2 separate cultures or</li> <li>• Persistently positive blood cultures (eg. 3&gt;12h (or majority if ≥4)</li> <li>• Endocardium involved;</li> <li>• Positive echocardiogram (vegetation, abscess, dehiscence of prosthetic valve) or</li> </ul> New valvular regurgitation (change in murmur not sufficient)	<ul style="list-style-type: none"> <li>• Predisposition (cardiac lesion, IV drug abuse)</li> <li>• Fever&gt;38°C</li> <li>• vascular/immunological signs</li> <li>• Positive blood culture that do not meet major criteria</li> <li>• Positive echocardiogram that does not meet the major criteria</li> </ul>

#### ***Definitive diagnosis is based on:***

2 major criteria or

1 major and 3 minor criteria or

All 5 minor criteria (if no major criteria are met)

Laboratory tests and imagistic investigation:

- As in sepsis, blood cultures are of decisive importance in making the diagnosis.
- transesophageal (endoscopic) echocardiography is significantly better than that of the transthoracic examination echocardiography because it cannot exclude endocarditis with certainty. The detection of persistent outgrowths on the aortic or mitral valve or a subvalvular abscess in echocardiography is diagnostically and prognostically significant and supports the indication for surgical valve replacement.
- The blood cell count, with a moderate leukocytosis and a distinct left shift, is usually toxically altered.
- Urinalysis– Focal glomerulonephritis occurs in approximately 50% of endocarditis cases and is characterized by erythrocyturia, cilindru-ria, and proteinuria.

#### ***Hereditary Febrile Syndromes***

***Hyper-IgD Syndrome*** The hyper-IgD syndrome has a clinical picture that is similar to that of familial Mediterranean fever. Starting in newborns

or infants, fever attacks develop, lasting three to seven (maximally 14) days and recur at intervals of four to eight weeks. The fever is accompanied by lymph node enlargement, splenomegaly (50%), arthralgia or arthritis, abdominal pain, peritonitis with secondary adhesions, and erythematous skin alterations. In addition to leukocytosis and elevated ESR, repeated, elevated IgD values are crucial to the diagnosis (possibly combined with elevated IgA). A mutation of mevalonate kinase has been confirmed. This leads to a slight reduction of serum cholesterol and elevated mevalonic acid concentration in the urine. The relationship of the mevalonate kinase mutation to the elevated IgD value and inflammation is unclear. Differential diagnosis of hereditary febrile syndrome are shown in Table 32. Elevated IgD values can also be found in chronic infections (HIV, tuberculosis), aspergillosis, sarcoidosis, lymphomas, and in smokers.

**Familial Mediterranean fever.** This is an autosomal recessive disease which is caused by a mutation in the pyrin gene. The disease has primarily been described in Jewish, Armenian, Turkish, and Arab populations and occurs throughout the Mediterranean region

Table 33

#### Diagnostic criteria for familial Mediterranean fever

Major criteria	Minor criteria
Typical attacks:	1-3 incomplete attacks involving 1 or more of the following sites:
Peritonitis (generalised)	- Abdomen - Chest - Joint
Pleuritis (unilateral) or pericarditis	- Exertional leg pain - Favourable response to colchicine. - Supportive criteria
Monoarthritis (hip, knee, ankle).	- Family history of familial Mediterranean fever - Appropriate ethnic origin - Age <20 years at disease onset

The requirements for the diagnosis of familial Mediterranean fever are  $\geq 1$  major criterion, or  $\geq 2$  minor criteria, or 1 minor criterion plus  $\geq 5$  supportive criteria, or 1 minor criterion plus  $\geq 4$  of the first 5 supportive criteria.

Features of attacks: typical attacks are defined as recurrent ( $\geq 3$  of the same type), febrile (rectal temperature of  $38^{\circ}\text{C}$  ( $100^{\circ}\text{F}$ ) or higher), and short (lasting between 12 hours and 3 days). Incomplete attacks are defined as painful and recurrent, differing from typical attacks in 1 or 2 features, as follows:

- The temperature is normal or lower than 38°C (100°F)
- The attacks are longer or shorter than specified (but not shorter than 6 hours or longer than a week); may be severe, requiring bed rest or spontaneous remission/ symptom-free interval.
- No signs of peritonitis are recorded during the abdominal attacks. The abdominal attacks are localized.
- Arthritis is in joints other than those specified above. Attacks are not counted if they do not fit the definition of either typical or incomplete attacks.

*Diagnosis.*

- Transient inflammatory response, with 1 or more abnormal test result(s) for WBC count,
- C-reactive protein,
- Erythrocyte sedimentation rate,
- Serum amyloid A,
- Fibrinogen,
- Episodic proteinuria/haematuria,
- Unproductive laparotomy or removal of „white” appendix.
- Consanguinity of parents.

***Tumor Necrosis Factor Receptor-associated Periodic Fever Syndrome (TRAPS)*** The autosomally dominant inherited mutations in the tumor necrosis factor receptor 1 gene (especially observed in Ireland and Scotland) exhibit acute fever that lasts for one to two (maximally 10) days, notably severe myalgia, abdominal pain with possible diarrhea periorbital facial edemas with conjunctivitis, exanthema, pleuritis, and arthralgia. The CRP and leukocyte values in the serum are elevated and the soluble TNF receptor 1 is reduced.

*Table 32*

**Differential diagnosis of familial Mediterranean fever (FMF), hyper-immunoglobulinemia D syndrome (HIDS), and tumor necrosis factor (TNF) receptor-associated periodic fever (TRAPS)**

	<b>FMF</b>	<b>HIDS</b>	<b>TRAPS</b>
Mutation	pyrin gene	mevalonate kinase gene	TNF receptor 1 gene
Mode of inheritance	autosomal recessive	autosomal dominant	autosomal dominant
Age at time of first clinical manifestations(years)	<20	<1	<20

Attack duration of fever	0.5–3 days	3–7 (maximally 14) days	1–2 (maximally 10) days
Clinical manifestations	sterile pleuritis, peritonitis, arthritis	Lymphadenopathy, arthritis, peritonitis, maculo-papular rash	Myalgia, periorbital edema, pleuritis, arthralgia
Laboratory findings	leukocytosis, CRP ↑	leukocytosis, CRP ↑ IgD ↑ (possibly IgA ↑)	leukocytosis CRP ↑ soluble TNF receptor 1 ↓

**Periodic Fever.** This term refers to fever attacks of one to four days duration, which occur over a period of years at more or less regular intervals.

**Clinical Features.** While the rise in temperature is the obligatory symptom, the secondary symptoms (arthralgia, myalgia, impairment of general health) can vary.

**Diagnosis.** In addition to fever the objective parameters that can be determined are elevated ESR, CRP, moderate leukocytosis with left shift, rarely joint swelling, skin manifestations, as well as acute abdomen. After excluding infectious and neoplastic diseases as well as collagenosis, recurrent fever attacks over a period of years lead to the consideration of several clinical pictures.

**Muckle-Wells syndrome.** Muckle–Wells syndrome (MWS), also known as urticaria-deafness-amyloidosis syndrome (UDA), is a rare autosomal dominant disease which causes sensorineural deafness and recurrent hives, and can lead to amyloidosis. Individuals with MWS often have episodic fever, chills, and joint pain. As a result, MWS is considered a type of periodic fever syndrome. MWS is caused by a defect in the CIAS1 gene which creates the protein cryopyrin. MWS is closely related to two other syndromes, familial cold urticaria and neonatal onset multisystem inflammatory disease. In fact, all three are related to mutations in the same gene and subsumed under the term cryopyrin-associated periodic syndromes (CAPS). *Signs and symptoms:* sensorineural deafness, recurrent urticaria, fevers, chills, arthralgia.

**Periodic Fever, Adenitis, Pharyngitis, and Aphthous stomatitis („PFAPA”) Syndrome.** The etiologically unexplained „PFAPA” syndrome (periodic fever, adenitis, pharyngitis, and aphthous stomatitis) can cause long-lasting, periodic fever in infants. The attacks, which last for three to five days, are partially to occur in hyperthyroidism, namely when an underlying case of subacute thyroiditis is present. In thyrotoxic crises the fever



increases to over 40°C. Fever is also a frequent symptom in an Addisonian crisis. This must especially be considered when discontinuing long-term steroid therapy. In contrast other steroids (e.g., progesterone) are themselves pyrogenic. Individual patients with pheochromocytoma also exhibit elevated temperatures. The rare combination of hyperglycemia and fever is also attributed to elevated catecholamines. It is also worth mentioning cases of hyperthermia in acute hyperparathyroidism with extremely high calcium values. These are due to lesions near the thermoregulation center of the hypothalamus.

***Fever in Vegetative Dystonia.*** The differentiation between hyperthyroid rises in temperature and vegetatively caused febrile conditions is often very difficult, because the symptoms frequently overlap. However, the specific hyperthyroid symptoms such as fine tremor, constant resting tachycardia, warm moist skin, ocular symptoms, and struma do not belong to vegetative dystonia. In doubtful cases, determination of thyroid gland hormone values can facilitate a differentiation.

***Fever in tumors.*** In some tumors, unexplained febrile states remain in the foreground of the clinical presentation for a long period of time. These rises in temperature are already present at an early stage, and therefore, can hardly be explained by tumor lysis. Mainly hypernephroma and carcinomas of the pancreas, liver, and stomach that are associated with fever prevail among solid tumors. In bronchial carcinoma the tumor itself, as well as secondary pneumonic processes can cause fever. An additional cause is atrial myxoma (changing findings on auscultation, recurrent embolisms, joint pain). Tumors of the lymphoreticular system, such as malignant lymphomas or leukemias, frequently cause recurrent febrile states. In 5–10% of patients with lymphogranuloma a characteristic periodic type of fever (Pel-Ebstein) is observed. In Hodgkin disease and non-Hodgkin lymphoma A-symptoms are present if general symptoms are absent. B-symptoms are present if a weight loss of more than 10% within a six-month period and/or an inexplicable fever of more than 38°C and/or night sweats are observed. Pruritus and alcoholic pain do not count as B-symptoms.

***Fever in the elderly.*** There may be different causes of fever, but we should exclude first of all malignancies – such as chronic leukemias, lymphomas, renal cell carcinomas, and metastatic cancers. Collagenvascular disease (polymyalgia rheumatica, vasculitis) and infections should also be excluded.

***Fever in Tissue Degradation.*** Frequent causes of fever include: myocardial infarction, pulmonary infarction, renal infarction, gangrene of the

extremities, pancreatitis, cirrhosis of the liver, hematoma in the resorption stage in body cavities or in the gastrointestinal tract, or intracranial hemorrhages. However, in these cases it is virtually always the primary clinical event and not the fever which is in the foreground.

**Sweet syndrome** includes acute febrile neutrophilic dermatosis, thrombosis, tubulo-interstitial nephritis and uveitis syndrome (TINU).

**Thermoregulatory disorders.** It is necessary to differentiate the following conditions:

- Central brain tumor,
- cerebrovascular accident,
- encephalitis
- hypothalamic dysfunction,
- anhidrotic ectodermal dysplasia,
- exercise-induced hyperthermia,
- hyperthyroidism,
- pheochromocytoma

**Urticaria.** Urticarial skin lesions occur frequently and can be associated with infections caused by mycoplasma, enteroviruses, adenoviruses, Epstein-Barr virus, HIV, and hepatitis viruses, as well as febrile, noninfectious systemic diseases (allergy, vasculitis, malignancy).

**Fever in allergic reactions.** In this group drug fever is of greatest significance. Nearly all medications can cause fever if the patient is hypersensitive. Sometimes (but not obligatorily) this fever reaction is accompanied by skin manifestations, which make the diagnosis easier. The drug eruptions exhibit an extremely varied morphology. The most frequently occurring are maculopapular exanthemas and urticaria. Scarletiform (e.g., quinine), morbilliform (e.g., barbiturates), bullous, eczematous, and purpurallike exanthemas also occur. A febrile erythema nodosum or a Stevens-Johnson syndrome is observed after taking diphenylhydantoin or sulfonamides. In drug fever, eosinophils are usually present in the peripheral blood, but eosinophilia exists only in approximately 20% of the cases. The ESR or CRP values can be significantly elevated and often leukocytosis and slightly elevated transaminase levels are also present. One to two days after discontinuing the responsible medication, the fever generally can be expected to remit. A renewed exposure to the responsible medication can possibly cause an anaphylactic reaction.

**Drug fever.** Many drugs have the capacity to induce fever as an adverse reaction. Such fever may be the result of a pharmacologic effect of the drug,

an idiosyncratic reaction, or a complication related to drug administration (phlebitis, chemical meningitis, sterile abscess). If fevers due to complications of drug administration are excluded, it is apparent that certain drugs, such as  $\alpha$ -methyl dopa, quinidine, and the penicillins, are more likely causes of the disorder than others, such as the aminoglycoside antibiotics and cardiac glycosides. Although the list of drugs capable of inducing fever is long, the list of agents that actually cause the disorder is considerably shorter. Important former causes of drug fever, such as laxatives, bromides, arsenical agents, and vancomycin, are now rarely incriminated in the disorder, either because they are no longer used or because new drug preparations are less pyrogenic (e.g., vancomycin).

**Immunodeficiency- and human immunodeficiency virus-associated fever of unknown origin.** HIV-associated FUO is defined as recurrent fevers over a four-week period in an outpatient or for three days in a hospitalized patient with HIV infection. Although acute HIV infection remains an important cause of classic FUO, the virus also makes patients susceptible to opportunistic infections. The differential diagnosis of FUO in patients who are HIV positive includes infectious etiologies such as *Mycobacterium avium*-intracellulare complex, *Pneumocystis jirovecii*, pneumonia, Cytomegalovirus and fungi (*Histoplasma capsulatum*, *Cryptococcus neoformans*, and *Coccidioides immitis*). Malignancies such as Kaposi sarcoma and primary brain lymphoma should also be entertained. Geographic considerations are also important.

**Hemophagocytosis syndrome.** Hemophagocytosis syndrome (also called hemophagocytic lymphohistiocytosis) is a rare, but often very severe, multiorgan disease with a high mortality rate. It is associated with malignant or autoimmune diseases or can develop after activation of macrophages (probably infection related). The clinical picture is associated with a great variety of microorganisms, but most frequently with Epstein-Barr, cytomegalovirus infection, hepatitis, or HIV infections. In the bone marrow and other lymphoepithelial tissues an increased number of histiocytes phagocytose erythrocytes, leukocytes, and thrombocytes are detected. Histiocytes and other blood cells are morphologically mature. The clinical presentation is characterized by fever, splenomegaly, lymphadenopathy, hepatomegaly, jaundice, and sometimes exanthema or neuropsychological deficits. The cardinal symptom is pancytopenia and there is often a massive elevation of the ferritin value, an intravascular coagulation disorder, and hepatic dysfunction.

**Nosocomial FUO.** Nosocomial fever is a fever occurring on several occasions in a patient hospitalized for at least 24 hours and without any manifestation of an obvious source of infection that could have been present before the admission. A minimum of three days of evaluation without establishing the cause of fever is required to make this diagnosis. It requires special attention to all intravascular devices, previous surgical procedure sites, evidence of pneumonia, and medications.

Conditions causing nosocomial FUO include:

- septic thrombophlebitis,
- pulmonary embolism,
- *Clostridium difficile* enterocolitis,
- drug-induced fever.

In patients with nasogastric or nasotracheal tubes, sinusitis may also be a cause. The most common causes of nosocomial FUO include pneumonia, urinary tract infection, surgical site infection, catheter-related infections, *Clostridium difficile* colitis, and drugs.

The differential diagnostic spectrum of the causes of fever is changed in the presence of an underlying disease (neutropenia, HIV infection, endoprostheses) or a specific epidemiological situation (nosocomial infection, following a stay in, or return from endemic regions, with specific infectious diseases).

**Immune-deficient FUO (neutropenic FUO).** It is a recurrent fever in a patient whose neutrophil count is 500 per mm<sup>3</sup> or less and who has been assessed for three days without detection an etiology for the fever. In most of these cases, the fever is caused by opportunistic bacterial infections. These patients are usually treated with broad-spectrum antibiotics to cover the most likely pathogens. Occult infections caused by fungi, such as hepatosplenic candidiasis and aspergillosis, must be considered. Less commonly, herpes simplex virus may be the inciting organism, but this infection tends to present with characteristic skin findings

**Chronic mercury intoxication.** The differential diagnosis should also consider chronic mercury poisoning. Persons with a long-term and concentrated exposure to mercury vapors in industry and certain laboratories can present with the following symptoms: loss of appetite, weight loss, gastric symptoms, sleeplessness, increased salivation, stomatitis, diarrhea, fine tremor of the hands, eyelids, lips, and tongue, ataxia, dysarthria, mental disorders (depression, irritability, anxiety, exaggerated emotional reactions), and vegetative disorders (dermographism, blushing and turning pale, sweating). A detailed work history and multiple determinations of mercury excretion values in the urine can confirm the diagnosis.

**Fever in thrombosis and thrombophlebitis.** Thrombosis, phlebitis, and thromboembolisms can be accompanied by fever even in the absence of any significant clinical findings. Of these, especially recurrent pulmonary embolisms are of great practical significance. After long-term infusion therapy, thrombophlebitis frequently occurs in the arms. In these cases the differential diagnosis must also exclude endoplasmitis with bacteremia or septicemia.

**Factitious fever or simulated fever** is usually recognized in persons with psychosocial or psychiatric problems by the atypical course and the disproportion between the magnitude of the temperature and the pulse rate. The evidence of psychiatric problems or a history of multiple hospitalizations at different institutions is common in patients with factitious fever.

Rapid changes of body temperature without associated shivering or sweating, large differences between rectal and oral temperature, and discrepancies between fever, pulse rate, or general appearance are typically observed in patients who manipulate or exchange their thermometers, that is the most common cause of factitious fever. Alternatively, fever may be caused by injection of nonsterile material (e.g., feces, milk), resulting in atypically localized abscesses or polymicrobial infections.

## BIBLIOGRAPHY

1. Atkins E. Fever: its history, cause and function. *Yale J Biol Med* 1982; 55:283–289.
2. Hashmey R. H., Roberts N. J. Jr. Fever and fever of unknown etiology. In: Betts R. F., Chapman S. W., Penn R. L. Rees and Betts' a practical approach to infectious disease. 5th ed. Philadelphia, PA: Lippincott Williams & Wilkins; 2003, p.1-18.
3. Kumar P., Clark M. *Clinical medicine: a textbook for medical students and doctors* – 4th ed. Edinburg: W. B. Saunders Company; 1998. – 1326 p.
4. Mackowiak P. A. *Fever: basic mechanisms and management*. 2nd ed. Philadelphia: Lippincott-Raven Publishers; 1997. 506p.
5. Mackowiak P. A., Durack D. T. Fever of unknown origin. In: Mandell G. L., Bennett J. E., Dolin R, eds. *Principles and practice of infectious diseases*. 6th ed. Philadelphia: Elsevier Churchill Livingstone; 2005:718-29.
6. Moya E., Canora J., Serrano M., et al. Fiebre de origen desconocido. In: Rodriguez Garcia J. L. *Diagnostico, tratamiento medico*. Madrid: Marban; 2010. p. 871-894.
7. Norman D. C. Fever in the elderly. *Clin Infect Dis*. 2000; 31:148–151.
8. Petersdorf R. G., Beeson P. B. Fever of unexplained origin: report on 100 cases. *Medicine (Baltimore)*. 1961; 40:1–30.

9. Rodriguez Garcia J.L. Diagnostico, tratamiento medico. Madrid: Marban; 2010.1997 p.
10. Siegenthaler W. Differential diagnosis in internal medicine. New York; Stuttgart: Thieme; 2007. 1140p.
11. Sivakumar R., Pavularu S., Ellis E. Fever of unknown origin; case outcome. BMJ. 2006; 30:333;691; discussion 692-4.
12. Sabatine M. S. Pocket medicine: The Massachusetts General Hospital Handbook of Internal Medicine, (Pocket Notebook). 4ed. Philadelphia: Lippincott Williams & Wilkins; 2010. 280p. [https://www.gettextbooks.com/author/Marc\\_Sabatine](https://www.gettextbooks.com/author/Marc_Sabatine) (accessed 20.08.2017)
13. [https://internadomedicina.files.wordpress.com/2014/10/pocket-medicine\\_-the-massachusetts-general-hospital-handbook-of-internal-medicine.pdf](https://internadomedicina.files.wordpress.com/2014/10/pocket-medicine_-the-massachusetts-general-hospital-handbook-of-internal-medicine.pdf)(accessed 20.08.2017)

## DIFFERENTIAL DIAGNOSIS OF FIBROMYALGIA SYNDROME

**INTRODUCTION.** Fibromyalgia syndrome (FMS) affects 2-10% of all populations studied; 75-95% of patients are women with a prevalence between the ages of 30 and 50. Doctors will meet patients with fibromyalgia in a variety of settings. There are similarities between patients with fibromyalgia, chronic fatigue syndrome/myalgic encephalopathy (ME), multiple chemical sensitivities and depression (or their parents), 60% of recall childhood growing pains (leg pains). Fibromyalgia is associated with psychosocial stress.

**DEFINITION.** The generalized form of soft tissue rheumatism is called fibromyalgia. Older synonyms include fibrositis, tension myalgia, generalized nonarticular rheumatism, and psychogenic rheumatism.

**CLASSIFICATION.** The problem of classifying chronic bodily complaints without any clearly demonstrable physical lesion (functional somatic syndromes) is common to all medical specialties. Chapter XIII the International Classification of Diseases (ICD-10), which is entitled „Diseases of the musculoskeletal system and connective tissue” contains the heading M79, „other soft tissue disorders, not elsewhere classified” under which „fibromyalgia” is found as item M79.7. The guideline recommends classifying FMS as a functional somatic syndrome rather than a mental disorder.

*Primary*– genetic FMS. Individuals with the 5-HT<sub>2A</sub> receptor 102T/C polymorphism have been found to be at increased risk of developing fibromyalgia.

*Secondary FMS* – may be associated with irritable bowel syndrome, irritable bladder syndrome, chronic headaches, mood disorders (depression, anxiety), sleep disorders, paraneoplastic syndrome.

**PATHOPHYSIOLOGY.** Fibromyalgia is a multifactorial syndrome characterized by abnormal processing of pain, known as „central sensitization”. It is potentially associated with polymorphisms of genes in the serotonergic, dopaminergic and catecholaminergic systems. Patients have a lower pain threshold due to increased reactivity of pain-sensitive nerve cells in the spinal cord or brain. In this process neuronal pain pathways originally activated from an identifiable noxious source become activated later in the absence of clear stimuli.

There are several hypotheses about the way fibromyalgia develops:

- Genetic predisposition to pain sensitivity
- Neuroendocrine disturbance
- Neurotransmitter regulation
- Abnormal pain processing
- Autonomic nervous system dysfunction
- Sleep physiology– Lack of stage 4 sleep
- Muscle pathology -Changes in regulation of intramuscular micro-circulation; decrease in energy – rich phosphates
- Allergy, infection, toxicity and nutritional deficiency
- Psychosomatic
- Trauma – whiplash

**Clinical Findings.** Fibromyalgia syndrome is characterized by:

- widespread, symmetrical, diffuse pains of characteristic tender points of muscles and muscle insertions and hyperalgesic tender spots along. Patients localize the pain poorly, referring it to muscle attachment sites or muscles, temporomandibular joint symptoms, pelvic pain
- subjective joint swelling (without objective synovitis on examination), arthralgia.
- pain and tenderness tend to come and go, and move about the body
- morning stiffness, but it is usually not as long or as severe as in patients with inflammatory arthritis
- multiple somatic visceral symptoms: urinary irritability, an irritable colon
- fatigue, anxiety,
- paresthesia
- headache,
- depression.
- sleep disturbance (nonrestorative, non-restful sleep)
- other physical and psychological symptoms,
- The discomfort may be worse late in the day after activity or is associated with psychosocial stress.
- Physical activity or changes in the weather typically aggravate the symptoms
- There is no progressive physical disability; however, patients may feel that they are unable to function normally.

*The typical patient* will tend to be female, aged 30 – 50 years, with long-standing diffuse pain. She will often have a history of physical or psycho-



logical trauma, and this may have been related to previous abuse. She will describe a fatigue on waking. The symptoms are always present but are exacerbated by other stressors in her life. She may have experienced rejection by other doctors who investigated but did not find any organic cause of the symptoms. This rejection can lead to more anxiety and hence intensification of the symptoms. The patient may also have become depressed if her symptoms have not been helped by previous interventions. The examination of such a patient reveal tender hyperalgesic sites and the patient visibly winces when they are pressed.

**Diagnosis.** A detailed history and careful physical examination exclude most rheumatologic and neurologic diseases. The finding of painful points at muscle attachment sites supports the diagnosis of fibromyalgia, *the pain should be present for at least 3 months and should involve areas on both sides of the body above.* The tender points usually are clearly delineated in a symmetrical manner. Other points examined for comparison are less, or not, tender (for example other muscles, clavícula). These control points are important in the delineation of general pain syndromes and other expressions of pain

The diagnostic criteria of the American College of Rheumatology (ACR) have gained worldwide acceptance as the prevailing definition of FMS. These criteria define FMS as chronic pain (i.e., pain for more than 3 months) in multiple parts of the body.

**American College of Rheumatology diagnosis criteria of fibromyalgia (1990)**

- Widespread musculoskeletal pain in all four quadrants of the body and some axial pain (cervical spine, anterior chest, thoracic spine or low back) present for at least 3 months
- Hyperalgesic points positive on digital pressure of 4 kg in 11 out of 18 points on the figure (hyperalgesia is absent in other control areas of the body, e.g. forehead)
- The points are all bilateral and situated in:
  - The suboccipital muscle insertions at the base of the skull
  - The low cervical spine C5 – 7 interspinous ligaments
  - The trapezius muscles at the midpoint of the upper border
  - The supraspinatus muscle originating above the scapulae spines
  - The second costochondral junctions on the upper surface lateral to the junction in 2cm distally to the lateral epicondyles
  - The upper outer quadrants of the buttocks in the anterior fold of the gluteus medius

- The greater trochanters posterior to the trochanteric prominence
- medial fat pads of the knee proximal to the joint line ABC

The revised criteria use the widespread pain index (WPI) and the symptom severity scale (SS) in place of tender point testing under the 1990 criteria. The WPI counts up to 19 general body areas in which the person has experienced pain in the preceding two weeks. The SS rates the severity of the person's fatigue, unrefreshed waking, cognitive symptoms, and general somatic symptoms, each on a scale from 0 to 3, for a composite score ranging from 0 to 12.  $WPI \geq 7$  and  $SS \geq 5$  OR  $WPI 3-6$  and  $SS \geq 9$ . The symptoms have been present at a similar level for at least three months, and no other diagnosable disorder otherwise explains the pain.

**Laboratory evaluation** There is no diagnostic test for fibromyalgia. Laboratory and radiologic findings are normal, but the following tests are recommended for the differential diagnosis and exclusion of other serious conditions:

- a complete blood count,
- erythrocyte sedimentation rate, ESR,
- thyroid function studies TSH
- electrolytes- Ca, Mg, Potassium,
- Cr, Phosphorus(PO<sub>4</sub>)
- urea, creatinine,
- liver function.
- alkaline phosphatase
- In selected cases, if liver transaminase values are increased, then creatinekinase and hepatitis serologic tests may be indicated.
- Radiographs- for excluding other diseases.
- Sleep studies -if sleep disturbance is prominent (patients with sleep apnea have fibromyalgia symptoms):
- the presence of anomalous alpha wave activity (typically associated with arousal states) measured by electroencephalogram (EEG) during non-rapid eye movement sleep of "fibrositis syndrome".

**Neuroimaging:**

- decreased levels of N-acetyl-aspartate (NAA) in the hippocampus of people with fibromyalgia, indicating decreased neuron functionality in this region.
- Altered connectivity and decreased grey matter of the default mode network, the insula, and executive attention network have been found in fibromyalgia.

- Increased levels of glutamate and glutamine have been observed in the amygdala, the parts of the prefrontal cortex, the posterior cingulate cortex, and the insula, correlating with pain levels in FM.
- Decreased GABA has been observed in the anterior insular in fibromyalgia. resting functional connectivity magnetic resonance imaging (fcMRI)

**fMRI study** – Resting functional connectivity magnetic resonance imaging (fcMRI) is a recent adaptation of fMRI that examines intrinsic connectivity defined as synchronous oscillations of the fMRI signal that occurs in the resting basal state.

- Increased cerebral blood flow in response to pain was found
- Findings of decreased blood flow in the thalamus and other regions of the basal ganglia correlating with treatment have been relatively consistent over three studies.
- Decreased binding of  $\mu$ -opioid receptor have been observed, however it is unknown if this is a result of increased endogenous binding in response to pain, or down regulation.

### **Differential diagnosis of diffuse body pain fibromyalgia**

#### **Common causes of body pain fibromyalgia:**

- systemic lupus erythematosus
- Sjögren syndrome,
- non-celiac gluten sensitivity,
- hypothyroidism,
- ankylosing spondylitis,
- polymyalgia rheumatica,
- rheumatoid arthritis,
- psoriatic-related polyarthralgia,
- hepatitis C,
- peripheral neuropathies,
- multiple sclerosis,
- disorders of the spine,
- myopathies,
- drug –induced causes,
- myofascial pain syndrome (more localized)
- disorders of subcutaneous connective tissue: panniculitis or panniculitis
- pancreatic diseases
- sarcoidosis.
- psychiatric: depression.

Table 34

**Physical and psychological associations with fibromyalgia**

Physical	Psychological
Irritable bladder	Panic attacks
Irritable bowel	Anxiety
Migraine	Depression
Muscle spasm	Irritability
Dizziness	Memory lapses
Perception of swelling	Word mix – ups
Paraesthesiae	Reduced concentration
Temperature changes	
Fatigue	

**Persistent somatoform pain disorder.** 40% to 70% of patients can be found to have relevant emotional or psychosocial conflicts that are temporally related to the appearance or intensification of the painful symptoms. About 60% of the patients spontaneously report having such conflicts.

**Affective disorders and anxiety disorders.** Depending on the level of care and the criteria and diagnostic instruments that are applied, the prevalence of affective disorders in patients with FMS is 20% to 80%, while that of anxiety disorders is 15% to 65%.

**Polysymptomatic functional somatic syndrome.** Depending on the level of care and the criteria and diagnostic instruments that are applied, the prevalence of other functional somatic syndromes (FSS), such as irritable bowel syndrome or chronic fatigue syndrome, in patients with FMS ranges from 20% to 80%.

Other symptoms often attributed to fibromyalgia that may be due to a comorbid disorder include **myofascial pain syndrome**, also referred to as chronic myofascial pain, diffuse non-dermatomal paresthesias, functional bowel disturbances and irritable bowel syndrome, genitourinary symptoms and interstitial cystitis, dermatological disorders, headaches, myoclonic twitches, and symptomatic hypoglycemia. Although fibromyalgia is classified based on the presence of chronic widespread pain, pain may also be localized in areas such as the shoulders, neck, low back, hips, or other areas. Many sufferers also experience varying degrees of myofascial pain and have high rates of comorbid temporomandibular joint dysfunction. 20–30% of people with rheumatoid arthritis and systemic lupus erythematosus may also have fibromyalgia.

**Multiple sclerosis.** Patients with multiple sclerosis have neurological

symptom or sign, with autonomic, visual, motor, and sensory problems. The specific symptoms are determined by the locations of the lesions within the nervous system, and may include loss of sensitivity or changes in sensation such as tingling, pins and needles or numbness, muscle weakness, blurred vision, very pronounced reflexes, muscle spasms, or difficulty in moving; difficulties with coordination and balance (ataxia); problems with speech or swallowing, visual problems (nystagmus, optic neuritis or double vision), feeling tired, acute or chronic pain, and bladder and bowel difficulties, among others. Difficulties thinking and emotional problems such as depression or unstable mood are also common. Uhthoff's phenomenon, worsening of symptoms due to exposure to higher than usual temperatures, and Lhermitte's sign, an electrical sensation that runs down the back when bending the neck, are characteristic. Some relapses are preceded by common triggers and they occur more frequently during spring and summer; viral infections such as cold, influenza, or gastroenteritis increase their risk. Stress may also trigger an attack.

**Non-celiac gluten sensitivity (NCGS)** is the most common syndrome of gluten-related disorders with prevalence rates between 0.5–13% in the general population. It is defined as „a clinical entity induced by the ingestion of gluten leading to intestinal and/or extraintestinal symptoms that improve once the gluten-containing foodstuff is removed from the diet, and celiac disease and wheat allergy have been excluded”. The diagnostic criteria of non-celiac gluten sensitivity were debated. In the „classical” presentation of NCGS, gastrointestinal symptoms are similar to those of irritable bowel syndrome, and are also not distinguishable from those of wheat allergy, but there is a different interval between exposure to wheat and onset of symptoms. Wheat allergy has a fast onset (from minutes to hours) after the consumption of food containing wheat and can be anaphylactic. Gastrointestinal symptoms include any of the following: abdominal pain, bloating, bowel habit abnormalities (either diarrhea or constipation), nausea, aerophagia, gastroesophageal reflux disease, and aphthous stomatitis. Extraintestinal symptoms, which can be the only manifestation of NCGS in the absence of gastrointestinal symptoms include any of the following: headache, migraine, „foggy mind”, fatigue, fibromyalgia, joint and muscle pain, leg or arm numbness, tingling of the extremities, dermatitis (eczema or skin rash), atopic disorders such as asthma, rhinitis, other allergies, depression, anxiety, iron-deficiency anemia, folate deficiency, or autoimmune diseases. NCGS has also been controversially implicated

in some neurological and psychiatric disorders, including schizophrenia, autism, peripheral neuropathy, ataxia, attention deficit hyperactivity disorder (ADHD), and hallucinations (so-called „gluten psychosis”). Fibromyalgia has also been linked with bipolar disorder, particularly the hypomania component.

## BIBLIOGRAPHY

1. Aziz I., Hadjivassiliou M., Sanders D.S. The spectrum of noncoeliac gluten sensitivity. *Nat Rev Gastroenterol Hepatol* (Review) 2015; 12 (9): 516–526. doi:10.1038/nrgastro.2015.107. PMID 26122473 (accessed 21.06.2018)
2. Bennett R. Contemporary overview of fibromyalgia. National Fibromyalgia Research Association's Subgroups in Fibromyalgia Symposium, Portland, Oregon 1999. National Fibromyalgia Research Association's Subgroups in Fibromyalgia Symposium; September 26– 27, 1999; Portland, Oregon.
3. Ciurea P., Rosu A., Musetescu A., et al. *Reumatologie*. Craiova: Editura Medicala Universitara Craiova, 2007. 466 p.
4. Elli L., Branchi F., Tomba C., Villalta D., Norsa L., Ferretti F., Roncoroni L., Bardella M.T.. Diagnosis of gluten related disorders: Celiac disease, wheat allergy and non-celiac gluten sensitivity". *World J Gastroenterol*. 2015; 21 (23): 7110. doi:10.3748/wjg.v21.i23.7110. PMC 4476872 . PMID 26109797. (accessed 21.06.2018)
5. Goldenberg D. L. Fibromyalgia and related syndrome. In: Hochberg M., Silman A., Smolen J., Weimblatt M., Weisman M. *Rheumatology*, 3rd ed. London: Mosby; 2003:701-12.
6. Goldenberg D.L. Diagnosis and differential diagnosis of fibromyalgia. *Am J Med* (Review) 2009; 122 (12 Suppl): S 14-21. doi:10.1016/j.amjmed.2009.09.007. PMID 19962492. (accessed 21.06.2018)
7. Groppa L. *Compendiu de reumatologie*. Chisinau: Sirius; 2009. 315 p.
8. Jensen B., Wittrup I. H., Rogind H., et.al. Correlation between tender points and the fibromyalgia impact questionnaire. *J Musculoskeletal Pain* 2000; 8:19-29. Published online: 16 Jan 2010. [https://doi.org/10.1300/J094v08n04\\_04](https://doi.org/10.1300/J094v08n04_04) (accessed 20.07.2017)
9. Marchesoni A., De Marco G., Merashli M., McKenna F., Tinazzi I., Marzo-Ortega H., et al. The problem in differentiation between psoriatic-related polyarthralgia and fibromyalgia. *Rheumatology* (Oxford) (Review) 2018; 57 (1): 32–40. doi:10.1093/rheumatology/kex079. PMID 28387854. (accessed 20.06.2018)
10. Palazzi C., D'Amico E., D'Angelo S., Gilio M., Olivieri I. Rheumatic manifestations of hepatitis C virus chronic infection: Indications for a correct diagnosis. *World J Gastroenterol* (Review) 2016; 22 (4): 1405–10. doi:10.3748/wjg.v22.i4.1405. PMC 4721975 . PMID 26819509.(accessed 20.06.2018)

11. Rodriguez Garcia J.L. *Diagnostico, tratamiento medico*. Madrid: Marban; 2010.1997p.
12. Sabatine M. S. *Pocket Medicine: The Massachusetts General Hospital Handbook of Internal Medicine*. Fourth ed., International ed. Philadelphia: Lippincott Williams & Wilkins; 2010. 304p. Online, 2017. (accessed 28.07.2017)
13. Siegenthaler W. *Differential diagnosis in internal medicine: from symptom to diagnosis*. New York; Stuttgart: Thieme; 2007. 1140p.
14. Smythe H. The Symptom Intensity Scale, fibromyalgia and the meaning of fibromyalgia – like symptoms. A review. *J Rheumatol*. 2006; 33:2113-4.
15. Wolfe F., Smythe H.A., Yunus M.B., et al. The American College of Rheumatology 1990 criteria for the classification of fibromyalgia: Report of the multi-center criteria committee. *Arthr Rheum*.1990; 33: 160–172.
16. [http://everything.explained.today/Gluten\\_sensitivity/](http://everything.explained.today/Gluten_sensitivity/)
17. [https://en.wikipedia.org/wiki/Gluten\\_sensitivity](https://en.wikipedia.org/wiki/Gluten_sensitivity)
18. [https://en.wikipedia.org/wiki/Non-celiac\\_gluten\\_sensitivity](https://en.wikipedia.org/wiki/Non-celiac_gluten_sensitivity)
19. [https://en.wikipedia.org/wiki/Gluten\\_allergy](https://en.wikipedia.org/wiki/Gluten_allergy)

## DIFFERENTIAL DIAGNOSIS OF MULTIVISCERAL SYNDROME IN CONNECTIVE TISSUE DISEASES

**DEFINITION.** Connective tissue diseases are autoimmune (autoinflammatory) rheumatic disorders and include the following entities such as systemic lupus erythematosus (SLE), Sjögren's syndrome, systemic sclerosis, vasculitis and inflammatory myopathies. They are multisystem disorders with multi-organ implication and frequent clinical manifestations are complex and varied. In general, the number and severity of the extra-articular features vary with the duration and severity of disease.

### Connective tissue diseases:

- Systemic lupus erythematosus,
- Systemic sclerosis
- Sjögren's syndrome
- Dermatomyositis / polymyositis,
- Vasculitis

*Table 35*

### Visceral implication in autoinflammatory disease

	SLE	Systemic sclerosis	Sjögren's syndrome	Inflammatory myopathies	Vasculitis
Skin	81%	95%	13-20%	30%	50-70%
Lungs	50%	>70%	25%	70%	
Heart	33%	70%	25%	20%	25-70%
Digestive tract	30%	Esophagus – 90%, Small Intestine – 20-50%, colon – 10-50%	25-50%	25%	30-60%
Renal	70%	10-15%	5-10%	20-40%	35-60%
Nervous system	54%	10%	70%	50%	75%

### Visceral manifestations in systemic lupus erythematosus

**Pulmonary manifestations.** In SLE pulmonary involvement is manifested by any of the following: pleuritis – 50%, pleural effusions, bronchopneumonia and pneumonitis are frequent, pulmonary hypertension, hemorrhage, and diaphragmatic dysfunction, pulmonary embolism also may occur. Restrictive lung disease can develop. Alveolar hemorrhage is uncommon but life-threatening. Interstitial lung disease is rare. Shrinking



lung syndrome (dyspnea, pleuritic chest pain, progressive reduction in lung volume, elevated diaphragms) is possible.

**Cardiac manifestations.** In SLE cardiac involvement is frequent. The pericardium is affected in the majority of patients and is manifested by pericarditis; it may be episodic, isolated or recurrent, more frequently in the onset of the disease. The amount of fluid is reduced without haemodynamic disturbances. It is exudate and anti DNAdc also may be present. Myocarditis is also relatively frequent with arrhythmias, valvular involvement, cardiac failure and accelerated coronary atherosclerosis, coronary vasculitis. Libman-Sacks endocarditis is described with mitral and aortic valves implication. It is usually clinically silent but occasionally can produce acute or chronic valvular regurgitation – most commonly mitral regurgitation. Coronary arteritis with clinical picture of angina or myocardial infarction may also occur. Heart failure may result from myocarditis and hypertension.

**Renal manifestations** may be present at the onset of the disease. Sometimes asymptomatic manifestations occur through edema after the installation of nephrotic syndrome or renal insufficiency. The type of lupus nephritis is shown in Table 36.

Table 36

### WHO classification of lupus nephritis

normal (class I)	asymptomatic
mesangial proliferative (class II)	mild hematuria or proteinuria
focal proliferative (class III)	nephritic syndrome, proteinuria
diffuse proliferative (class IV)	nephritic syndrome, nephrotic syndrome
membranous glomerulonephritis (class V)	nephrotic syndrome
glomerulosclerosis (class VI)	uremia
Severity VI >IV >III >V >II >I	consider aggressive treatment for class III, IV

**Gastrointestinal manifestations:** Mesenteric thrombosis and vasculitis, occasionally occur in SLE including the presence of aneurysms in medium-sized blood vessels and may closely resemble polyarteritis nodosa. Hepatitis/ hepatopathy with high level of transaminases may also develop. Abdominal pain (particularly postprandial), ileus, peritonitis/ peritoneal serositis, and perforation may result. Corticosteroids could increase the risk of peptic ulcer disease. The presence of persistent peritoneal effusion is the consequence of imbalances in colloid osmotic pressure from congestive

heart failure, nephrotic syndrome or cirrhosis. The acute surgical abdomen of lupus disease is due to intestinal vasculitis. Intestinal vasculitis can also induce digestive haemorrhages, intraperitoneal haemorrhage and intestinal perforation. Lupus pancreatitis is due to arteriitis and/or other vascular lesions, pancreatic infarction and corticosteroid therapy. Hepatitis is also present and may be viral or secondary to treatment.

**Antiphospholipid syndrome** is responsible for thrombosis in different topographic areas with hepatic, splenic or intestinal infarctions.

**Hematologic manifestations** include moderate anemia, inflammatory type, reticulocytosis, leucopenia, sometimes thrombocytopenia, pancytopenia. Anemia is usually haemolytic, with a positive Coombs test. Iron deficiency may be secondary to bleeding or nephrotic syndrome.

**Neurologic** complications of SLE: central nervous system lupus is a most variable and unpredictable phenomenon.

Manifestations such as:

- depression
- psychosis,
- impaired cognitive function, seizures
- migraine like attacks
- long tract signs,
- stroke
- aseptic meningitis,
- transverse myelitis
- organic brain syndrome
- peripheral and cranial neuropathy

occur with little apparent relationship to each other or to other systemic manifestations. Severe depression and psychosis are sometimes exacerbated by the administration of large doses of corticosteroids. When there is doubt about the cause of psychosis in patients with SLE, the steroid dose can be increased and the patient observed. Patients rarely can have isolated central nervous system involvement and normal results of cerebrospinal fluid examination and no other organ involvement. Secondary cause particularly with neuropsychiatric symptoms or respiratory symptoms must be considered, especially infection, hypertension, anemia, hypoxia, and fever. Fever should be considered due to infection until proved otherwise.

Diagnosis of nervous system implications:

- increased cerebrospinal fluid protein (IgG),
- pleocytosis, and

- antineuronal antibodies.
- Immune complexes in the choroid plexus are not specific for central nervous system disease because they also occur in patients without central nervous system disease.
- electroencephalography can be abnormal.
- MRI shows areas of increased signal in the periventricular white matter, similar to those found in multiple sclerosis. Magnetic resonance imaging findings are often nonspecific and sometimes can be seen in patients who have SLE without central nervous system manifestations

**Ocular manifestations** include conjunctivitis, photophobia, transient or permanent monocular blindness, and blurring of vision. Cotton-wool spots on the retina (cytoid bodies) represent the degeneration of nerve fibers due to occlusion of retinal blood vessels.

**Dermatologic manifestations.** Discoid SLE involves the face, scalp, and extremities, photosensitivity, malar rash (nasolabial folds spared), discoid lupus (erythematous papules/plaques with central hypopigmentation, atrophic scarring involving scalp and exposed skin, mucosal ulcers (oral, vaginal, nasal septal), alopecia, livedo reticularis, palpable purpura, Raynaud's phenomenon. There is follicular plugging with atrophy leading to scarring. Subacute cutaneous SLE is a subset of SLE that primarily has skin involvement with psoriasiform or annular erythematous lesions. Patients may be negative for antinuclear antibodies but frequently are positive for antibodies to the extractable nuclear antigen SS-A (Ro).

**Serologic changes.** Correlation between visceral implication and frequency of autoantibody is shown in Table 37.

Table 37

**Autoantibody in SLE and visceral implication**

Antigen	%	Clinical features of visceropathy
Native DNA	80	Nephropathy, high activity
Histone	30	Nephropathy, Drug induce lupus (80%)
Nucleosome/chromatin	85	Nephropathy
Anti-C1q	40	Nephropathy
Ro/SS-A, La/SS-B	20-40	Sjogren's syndrome, neonatal skin lupus, sub-acute SLE
Sm	20-30	Hepatopathy
U1 RNP	30-40	Polymyositis

Table 37 (contin.)

AL, cardiopyne	30-50	Thrombosis , fetal loss, valvulopathy, thrombocytopenia
Red blood cells	10-50	Hemolytic anemia
Thrombocytes	10-20	Thrombocytopenia
P ribosomes protein	15	Psychosis
Rheumatoid factor	40	Polyarthritis

**Constitutional symptoms:** fatigue, fever (high grade), lymphadenopathy, weight loss, myalgia.

**Criteria for the diagnosis of SLE:**

1. Malar rash
2. Discoid rash
3. Photosensitivity
4. Oral ulcers
5. Arthritis
6. Serositis
7. Kidney disease: > 0.5 g/day proteinuria,  $\geq$  3+ dipstick proteinuria, cellular casts
8. Neurologic disease: seizures, psychosis (without other cause)
9. Hematologic disorders: hemolytic anemia, leukopenia (< 4000/mcL), lymphopenia (< 1500/mcL), thrombocytopenia (< 100,000/mcL)
10. Immunologic abnormalities: antibody to native DNA, antibody to Sm, antibodies to antiphospholipid antibodies based on IgG or IgM anticardiolipin antibodies, lupus anticoagulant, or false-positive serologic test for syphilis
11. Positive ANA

A patient is classified as having SLE if any 4 or more of 11 criteria are met.

**Systemic scleroderma** is an extensive fibrosis and inflammation of skin, blood vessels, and internal organs (see Tab. 38).

There are several subtypes of scleroderma:

**Localized scleroderma**— no involvement of internal organs, mostly in children and young adult

- Morphea with hard oval patches on the skin
- Linear –line of thickened skin.

**Generalized systemic sclerosis**

- Limited systemic sclerosis—develops at the age of 30-40, pulmonary hypertension is common, CREST (calcinosis, raynaud's phenomenon, esophageal dysmotility, sclerodactyly, telangiectasias) is present.
- Diffuse-widespread skin disease (involves trunk), early visceral involvement.

Table 38

**Clinical manifestations of visceral involvement in systemic sclerosis**

Skin	Tightening and thickening of extremities, face, trunk (biopsy not require for diagnosis), „puffy” hands, carpal tunnel syndrome, sclerodactyly nailfold capillary dilatation and dropout; immobile, pinched, „mouselike” faces and „purse-string” mouth; calcinosis cutis (subcutaneous calcification); telangiectasias
Arteries	Raynaud’s phenomenon (80%); digital or visceral ischemia
Renal	Scleroderma renal crisis – sudden onset severe HTN, rapidly progressive glomerulonephritis, microangiopathic hemolytic anaemia, Crescentic glomerulonephritis (rare) with p-ANCA
Gastrointestinal	GERD and erosive esophagitis Esophageal dysmotility → dysphagia, odynophagia, aspiration Gastric dysmotility → early satiety and gastric outlet obstruction Small intestinal dysmotility → bloating, diarrhea, malabsorption
Musculoskeletal	Polyarthralgias and joint stiffness; muscle weakness, tendon friction rubs
Cardiac	Myocardial fibrosis, pericarditis; conduction abnormalities
Pulmonary	Pulmonary fibrosis (typically develops within 4 years); pulmonary arterial hypertension (typically develops after many yrs). 1st cause of mortality
Endocrine	Amenorrhea and infertility common; thyroid fibrosis +/- hypothyroidism

**Pulmonary manifestations.** A considerable decrease in diffusing capacity can be present with a normal chest radiograph. Diffuse interstitial fibrosis occurs in approximately 70% of patients and is the most common pulmonary abnormality. It also occurs in patients who have active alveolitis demonstrated by:

- 1) bronchopulmonary lavage,
- 2) high-resolution computed tomography showing ground-glass appearance without honeycombing, or
- 3) lung biopsy.

Pneumopathy in scleroderma are most likely to respond to prednisone and cyclophosphamide therapy with improvement of pulmonary function.

Pulmonary hypertension is more common in patients with CREST variant. Pleuritis (with effusion) is rare.

**Cardiac** abnormalities occur in up to 70% of patients. Conduction defects and supraventricular arrhythmias are most common. Myocardial fibrosis and pericarditis may also be present. Pulmonary hypertension with *cor pulmonale* is the most serious problem.

**Gastrointestinal manifestations.** Esophageal dysfunction is the most frequent gastrointestinal abnormality. It occurs in 90% of patients and often is asymptomatic. Lower esophageal sphincter incompetence with acid reflux may produce esophageal strictures or ulcers. Small bowel hypomotility may be associated with pseudo-obstruction, bowel dilatation, bacterial overgrowth, and malabsorption. Colonic dysmotility also occurs, and wide-mouthed diverticuli may be found. Medications to reduce acid production are important. Reduced esophageal motility may respond to therapy with metoclopramide, cisapride, or erythromycin. Treatment with tetracycline may be helpful, but promotility agents are less effective.

**Renal involvement** may result in fulminant hypertension, renal failure, and death if not treated aggressively. Proteinuria, newly diagnosed mild hypertension, microangiopathic hemolytic anemia, vascular changes on renal biopsy, and rapid progression of skin thickening may precede overt clinical findings of renal crisis. Renal involvement with hyperreninemia necessitates the use of angiotensin-converting enzyme inhibitors. Aggressive early antihypertensive therapy can extend life expectancy.

**Serologic tests** include antibodies to topoisomerase I (anti Scl-70) seen more in diffuse systemic sclerosis and antibody to centromere seen more in CREST syndrome.

**Sjögren's syndrome** – is autoimmune disorder characterized by exocrine gland dysfunction. Its common features include dry eyes, mouth, and skin; arthralgias, neuropathies, and fatigue.

Sjögren's syndrome strict criteria include:

- Gritty or dry eyes,
- dry mouth for over 3 months.

Patient requires liquids to swallow dry food, frequent sips of water, because obvious swelling of the salivary glands develops. Many patients develop arthralgias and fatigue along with severe sicca symptoms but do not strictly meet the criteria for the diagnosis. The terms „partial” or ”incomplete” Sjögren's syndrome is applied in these settings. These patients should be seen periodically to monitor for further evidence of classic Sjögren's syndrome.

Affecting other glands is clinically expressed by reducing secretions.

**Respiratory system involvement.** At the tracheobronchial level and lungs: tracheobronchitis and pneumonia may occur. Secondary pleurisy is rare.

**Cardiac** abnormalities occur in up to 10%-20% of patients. Conduction defects and supraventricular arrhythmias are most common.

*At the digestive tract level* – xerostomy, gastritis (hypoacidity, glandular atrophy) and pancreatitis (exocrine disorder) are reported.

*Renal implications* – tubulointerstitial nephropathy, distal tubular acidosis, nephrocalcinosis; different types of glomerulopathy appear in the evolution of the disease.

Table 39

### Extraglandular involvement

Arthritis	arthralgias, intermittent joint swelling, or synovitis, usually not associated with deformities
Respiratory tract	Chronic bronchitis
Neurologic	Sensory or motor peripheral neuropathy, Cranial neuropathy Central nervous system involvement has been characterized by paralysis, seizures, transverse myelopathy, encephalopathy, meningitis or dementia
Endocrine	Antithyroid antibodies, altered thyroid function
Gastrointestinal	Dysphagia, atrophic gastritis, acute or chronic pancreatitis, elevated liver enzymes
Dermatologic	Dryness, palpable purpura, nonpalpable purpura
Renal	Glomerulonephritis Interstitial nephritis Distal or proximal renal tubular acidosis Nephrogenic diabetes insipidus
Haematological	Lymphomas may develop in patients with Sjögren (7% of patients).

### Diagnosis:

- positive Schirmer test
- rose bengal staining, or lissamine green staining
- lip biopsy may show inflammation of the salivary glands
- hypergammaglobulinemia
- positive for antinuclear antibodies, especially antibodies to SS-A (Ro) or SS-B (La), or rheumatoid factor.
- positive salivary scintigraphy, parotid sialography, or an unstimulated salivary flow assessment.

Secondary Sjogren's syndrome can be found in association with other connective tissue diseases, such as rheumatoid arthritis, progressive systemic sclerosis, and systemic lupus erythematosus. In addition, characteristic complications of the disease such as renal tubular acidosis, myopathy,

plasma cell dyscrasias and other organ implication are frequently encountered.

### **Inflammatory myopathies**

**Inflammatory myopathies** include polymyositis, dermatomyositis, inclusion body myositis. These three illnesses are characterized by inflammatory lesions in the muscles. They are all associated with weakness.

#### *Polymyositis/Dermatomyositis*

The classic criteria by Bohan and Peter published in 1975 include:

- proximal muscle weakness in the arms, legs, and neck,
- inflammation,
- necrotic muscle biopsy,
- muscle enzyme elevations in the serum, and
- EMG abnormalities.

**Inclusion body myositis.** No established criteria for diagnosing this condition. It generally requires a muscle biopsy which reveals classic inclusion bodies. Presumed diagnosis can be made based on male gender, advanced age, distal (hand and finger) involvement, and poor response to therapy. Laboratory testing should reveal an elevation of creatine kinase and aldolase levels, as in polymyositis and dermatomyositis.

### **Vasculitis**

**Vasculitis** is a clinicopathologic process characterized by inflammation and damage of blood vessels. The vessel lumen is usually compromised, and this is associated with ischemia of the tissues supplied by the involved vessel. A broad and heterogeneous group of syndromes may result from this process (see Tab. 40).

#### **Vasculitis syndromes (adapted from Jennette J.C. et al: *Arthritis Rheum* 2013; 65:1)**

<b>Primary Vasculitis Syndromes</b>	<b>Secondary Vasculitis Syndromes</b>
Granulomatosis with polyangiitis (Wegener's)	Vasculitis associated with probable etiology
Microscopic polyangiitis	Drug-induced vasculitis
Eosinophilic granulomatosis with polyangiitis (Churg-Strauss)	Hepatitis C virus-associated cryoglobulinemic vasculitis
IgA vasculitis (Henoch-Schönlein)	Hepatitis B virus-associated vasculitis
Cryoglobulinemic vasculitis	Cancer-associated vasculitis
Polyarteritis nodosa	Vasculitis associated with systemic diseases
Kawasaki disease	Lupus vasculitis
Giant cell arteritis	Rheumatoid vasculitis
Takayasu arteritis	
Behçet's disease	



Table 40 (cont.)

Cogan's syndrome Single organ vasculitis Cutaneous leukocytoclastic angiitis Cutaneous arteritis Primary central nervous system vasculitis Isolated aortitis	Sarcoid vasculitis
---	--------------------

**Classification.** A major feature of vasculitic syndromes as a group is the fact that there is a great deal of heterogeneity at the same time as there is a considerable overlap among them. This heterogeneity and overlap in addition to a lack of understanding of the pathogenesis of these syndromes have been major impediments to the development of the coherent classification system for these diseases.

**General principles of diagnosis.** The diagnosis of vasculitis is when considered in any patient with an unexplained systemic illness. However, there are certain clinical abnormalities that when present alone or in combination should suggest a diagnosis of vasculitis:

- palpable purpura
- pulmonary infiltrates
- microscopic hematuria
- chronic inflammatory sinusitis
- mononeuritis multiplex
- unexplained ischemic events
- glomerulonephritis with evidence of multisystem disease.

A number of nonvasculitic diseases may also produce some or all of these abnormalities. Thus, the first step in the workup of a patient with suspected vasculitis is to exclude other diseases that produce clinical manifestations that can mimic vasculitis. It is particularly important to exclude infectious diseases with features that overlap those of vasculitis, especially if the patient's clinical condition is deteriorating rapidly and empirical immunosuppressive treatment is being contemplated. Once diseases that mimic vasculitis have been excluded, the workup should follow a series of progressive steps that result in the diagnosis of vasculitis and determine the possible site of lesion.

The determination of the site of biopsy should be performed based on the presence of clinical disease in the affected organ. Common sites where biopsies may be performed include the lung, kidney and skin. Other sites

such as the sural nerv, brain, testicle, and gastrointestinal tissues may also demonstrate features of vasculitis and be appropriate locations for biopsy when clinically affected.

## BIBLIOGRAPHY

1. Ciurea P., Rosu A., Musetescu A., et al. Reumatologie. Craiova: Editura Medicala Universitara Craiova; 200. 466p.
2. Gannot G., Lancaster H. E., Fox P. C., et al. Clinical course of primary Sjogren's syndrome: salivary, oral and serological aspects. *J Rheumatol.* 2000; 27:1905-1909.
3. Groppa L. Compendiu de reumatologie. Chişinău. Sirius, 2009. 315 p.
4. Haberman T., Ghosh A. Mayo Clinic internal medicine concise textbook. Boca Raton: CRC Press LLC; 2007. 928p.
5. Harrison's principles of internal medicine /ed. D. L. Kasper, A.S. Fauci, S. 19th ed. New York : McGraw-Hill; 2015. – 2578 pp.
6. Longmore M., Wilkinson I., Torok E. Oxford handbook of clinical medicine; fifth ed. 2004, 857 p. Longmore M., Wilkinson I., Torok E. Oxford handbook of clinical medicine; 5th ed. Oxford : Oxford University Press; 2001. 857p.
7. Miksad R. A., Patricia De La Mora, George Meyer. Last Minute Internal Medicine: A concise review for the specialty boards. New York: McGraw-Hill Professional; 2008. 556pp.
8. Ramos-Casals M., Tzioufas A.G., Font J. Primary Sjogren's syndrome: new clinical and therapeutic concept. *Ann Rheum Dis.* 2005; 64:347-354.
9. Sabatine M. S. Pocket medicine: The Massachusetts General Hospital Handbook of Internal Medicine. (Pocket Notebook). 4ed. Philadelphia: Lippincott Williams & Wilkins; 2010. 280p. [https://www.gettextbooks.com/author/Marc\\_Sabatine](https://www.gettextbooks.com/author/Marc_Sabatine) . (accessed 12.07.2017)
10. Venables P. J. Mixed connective tissue disease. *Lupus.* 2006; 15: 132-7. DOI:10.1191/0961203306lu2283rr,<http://journals.sagepub.com/doi/abs/10.1191/0961203306lu2283rr> (16.06.2017).
11. Vitali C., Bombardieri S., Jonsson R. et al. European Study Group on Classification Criteria for Sjögren's Syndrome. Classification criteria for Sjogren's syndrome: a revised version of the European criteria proposed by the American-European Consensus Group. *Ann. Rheum. Dis.* 2002; 61: 554-558.

## DIFFERENTIAL DIAGNOSIS OF ACUTE RENAL FAILURE

**DEFINITION.** Acute renal failure (ARF) or acute kidney injury (AKI) is defined as a rapid decline in renal filtration function and is based on a rise in serum creatinine, retention of urea and other nitrogenous products, the disturbance of extracellular volume and electrolytes, fall in urine output. This can occur in the setting of previously normal renal function or in patients with pre-existing renal disease. More recently it has been recognized that even very small increase in serum creatinine is associated with adverse patient disease evolution.

**PATHOPHYSIOLOGY.** There are three main mechanisms of ARF: prerenal, intrinsic and postrenal (obstructive). In prerenal failure, glomerular filtration rate (GFR) is depressed by compromised renal perfusion. Tubular and glomerular functions remain normal.

Severe renal injury is the most common cause of intrinsic renal failure. Impaired renal blood flow (RBF) due to different causes leads to ischemia and cell death. The initial ischemic episode provokes a cascade of events, including production of oxygen free radicals, cytokines and enzymes, endothelial activation and leukocyte adhesion and activation of coagulation agents. The damage of renal tubes results in disruption of tight junctions between cells, allowing leak of glomerular basal membrane, and produces the depressing effect on glomerular filtration rate (GFR). In addition, dying cells form obstructing casts in the tubules, which further decrease GFR and lead to oliguria. During this period of compromised renal blood flow, the kidneys are particularly vulnerable, especially, when iatrogenic renal injury is present.

Although these changes are observed predominantly in proximal tubules, injury to the distal nephron can also be observed and may become obstructed by desquamated cells and casts. Intrarenal vasoconstriction, followed by renal ischemia is the dominant mechanism for reduced GFR in patients with AKI. These pathophysiologic mechanisms provoke a severe imbalance between the mediators of vasoconstriction and dilatation that result in intrarenal vasoconstriction. The vasoconstrictors include angiotensin II, endothelin, thromboxane and adenosine. The vasodilators include prostaglandin I<sub>2</sub> and endothelial-derived nitric oxide. High levels of vasoconstrictors and low levels of vasodilators cause continued hypoxia and

cell damage. Therefore, during recent years it has become evident that pronounced medullary ischaemia makes an important contribution.

**CLASSIFICATION.** The classification of AKI was based on the Risk, Injury, Failure, Loss of kidney function, End-stage (RIFLE 2004) criteria (Table 41).

Table 41

**The RIFLE classification of AKI**

Class	Glomerular filtration rate (GFR)	Urine output
Risk	↑ Serum creatinine (SCr) × 1.5 or ↓ GFR >25%	<0.5 mL/kg/h × 6 h
Injury	↑ SCr × 2 or ↓ GFR >50%	<0.5 mL/kg/h × 12 h
Failure	↑ SCr × 3 or ↓ GFR >75% or if baseline SCr ≥353.6 μmol/L (≥4 mg/dL) ↑ SCr >44.2 μmol/L (>0.5 mg/dL)	<0.3 mL/kg/h × 24 h or anuria × 12 h
Loss of kidney function	Complete loss of kidney function >4 weeks	
End-stage kidney disease	Complete loss of kidney function >3 months	

A new classification of AKI by the Acute Kidney Injury Network (AKIN) working group was proposed in 2007 (Table 42).

Table 42

**The AKIN classification/staging system of acute kidney injury**

Stage	Serum creatinine (SCr)	Urine output
1	↑ SCr ≥26.5 μmol/L (≥0.3 mg/dL) or ↑ SCr ≥150 a 200% (1.5 a 2×)	<0.5 mL/kg/h (>6 h)
2	↑ SCr >200 or 300% (>2 a 3×)	<0.5 mL/kg/h (>12 h)
3	↑ SCr >300% (>3×) or if baseline SCr ≥353.6 μmol/L (≥4 mg/dL) ↑ SCr ≥44.2 μmol/L (≥0.5 mg/dL)	<0.3 mL/kg/h (24 h) or anuria (12 h)

The RIFLE criteria and AKIN classification resulted in the Kidney Disease Improving Global Outcomes (KDIGO) classification proposed in 2012 (Table 43).

Acute renal failure is also identified as prerenal AKI, renal intrinsic AKI and postrenal AKI.

**Classification of AKI (KDIGO)**

AKI is defined as any of the following:		
<ul style="list-style-type: none"> <li>• Increase in serum creatinine by <math>\geq 0.3</math> mg/dl (<math>\geq 26.5</math> <math>\mu\text{mol/l}</math>) within 48 h; or</li> <li>• Increase in serum creatinine to <math>\geq 1.5</math> times baseline, which is known or presumed to have occurred within the prior 7 days; or</li> <li>• Urine volume <math>&lt; 0.5</math> ml/kg/h for 6 h.</li> </ul>		
<i>AKI staging system:</i>		
AKI stage	Serum creatinine criteria	Urine output criteria
AKI stage I	Increase of serum creatinine by $\geq 0.3$ mg/dl ( $\geq 26.4$ $\mu\text{mol/L}$ )	Urine output $< 0.5$ ml/kg/h For 6–12 h
	Or increase to 1.5–1.9 times from baseline	
AKI stage II	Increase of serum creatinine to 2.0–2.9 times from baseline	Urine output $< 0.5$ ml/kg/h For $\geq 12$ h
AKI stage III	Increase of serum creatinine $\geq 3.0$ times from baseline	Urine output $< 0.3$ ml/kg/h For $\geq 24$ h
	Or	
	serum creatinine $\geq 4.0$ mg/dl ( $\geq 354$ $\mu\text{mol/L}$ )	
	Or	
	treatment with RRT	
Or	anuria for $\geq 12$ h	
in patients $< 18$ years, decrease in estimated GFR to $< 35$ ml/min per $1.73$ m <sup>2</sup>		

Prerenal kidney injury is the most common form of renal failure ( $> 50\%$ ).

***Causes of prerenal AKI:***

Hypovolemia (haemorrhage, vomiting, diarrhea, burns), renal losses (excess of diuretics, polyuria)

- 1) Hypotension (cardiogenic shock, sepsis, anaphylaxis)
- 2) Edema (cardiac failure, nephrotic syndrome, liver cirrhosis)
- 3) Hepatorenal syndrome
- 4) Severe cardiac failure, arrhythmias, pulmonary embolus, acute myocardial infarction
- 5) Abdominal aortic aneurysm, renal artery stenosis or occlusion
- 6) Renal hypoperfusion due to administration of some medications (NSAIDs, selective cyclo-oxygenase inhibitors, ACE inhibitors, angiotensin-II receptor antagonists).

*Causes of intrinsic AKI:*

- 1) Tubular injury: acute tubular necrosis, nephrotoxins (aminoglycosides, radiocontrast media, myoglobin, heavy metals, myeloma kidney etc)
- 2) Pyelonephritis
- 3) Glomerular disease: glomerulonephritis, thrombosis, haemolytic uraemic syndrome, eclampsia
- 4) Acute interstitial nephritis due to drugs, toxins, infections
- 5) Systemic diseases: vasculitis, polyarteritis nodosa, cryoglobulinaemia, thrombotic microangiopathy

*Causes of postrenal AKI:*

- 1) Retroperitoneal fibrosis
- 2) Radiation fibrosis
- 3) Tumours
- 4) Calculus
- 5) Urethral strictures
- 6) Prostatic hypertrophy
- 7) Papillary necrosis

**CLINICAL FEATURES OF AKI**

*Clinical examination of eyes in patients with AKI may reveal the following:*

1. Jaundice – in liver cirrhosis
2. Iritis, keratitis, uveitis, dry conjunctivae – in autoimmune vasculitis
3. Keratopathy due to hypercalcemia – in multiple myeloma
4. Atheroemboli: retinopathy (cholesterol microembolism) in diabetes mellitus and hypertension

The presense of uveitis may indicate interstitial nephritis and necrotizing vasculitis

Ocular palsy may indicate ethylene glycol poisoning or necrotizing vasculitis

Findings suggestive of severe hypertension, atheroembolic disease and endocarditis may be observed on careful examination of the eyes.

*Skin examination may reveal the following in patients with AKI:*

1. Livedo reticularis, digital ischemia, butterfly rash – in SLE
2. Palpable purpura – in systemic vasculitis
3. Maculopapular rash – in allergic interstitial nephritis
4. Skin signs of intravenous drug abuse – in endocarditis
5. Petechiae, purpura, ecchymosis and livedo reticularis provide clues to

inflammatory and vascular causes of AKI. Disseminated intravascular coagulation, thrombotic thrombocytopenic purpura and embolism can produce typical cutaneous changes.

*Ear examination of the patients may reveal:*

1. Loss of hearing – in Alport disease and aminoglycoside toxicity
2. Mucosal or cartilaginous ulcerations, granulomas – Wegener granulomatosis

*Pulmonary examination may reveal:*

1. Hemoptysis – in ANCA vasculitis, Goodpasture syndrome, Wegener granulomatosis
2. Rales – in pulmonary edema, infectious pulmonary process, Goodpasture syndrome, Wegener granulomatosis

*Cardiovascular examination must include the following:*

1. Pulse rate and blood pressure recordings measured in the supine and the standing position
2. Close inspection of the jugulo-venous pulse
3. Careful examination of the heart and lungs, skin turgor, and mucous membrane
4. Assessment for peripheral edema
5. Arrhythmias (e.g., atrial fibrillation) – in thromboembolism
6. Cardiac murmurs – in endocarditis
7. Pericardial friction rub – in uremic pericarditis
8. Increased jugulo-venous distention and rales– in heart failure

*Abdominal examination may reveal:*

1. Abdominal tenderness – in nephrolithiasis, renal artery thrombosis, renal vein thrombosis, papillary necrosis
2. Urinary obstruction in pelvic masses, prostatic hypertrophy, distended bladder

Abdominal examination findings can be useful in helping to detect obstruction at the bladder outlet as the cause of renal failure, such obstruction may be due to cancer or to an enlarged prostate.

The presence of tense ascites can indicate elevated intraabdominal pressure that can retard renal venous return and result in AKI. The presence of an epigastric bruit suggests renal vascular hypertension, which may predispose to acute renal failure.

### **Diagnosis and diagnostic accomplishment of AKI**

The diagnosis of AKI is traditionally based on a rise in serum creatinine and fall in urine output. These abnormalities have to persist for longer than

3 days. However, immediately after a kidney injury, urea and creatinine levels may be normal and the only sign of a kidney injury may be decreased urine production.

A number of new biomarkers were identified as risk factors predicting AKI in patients at risk for the disease. It is allowable that profound reno-vascular constriction may cause subclinical tubular damage in at least a subset of nephrons, not detectable by urinary sodium, which is not sensitive enough to identify mild tubular epithelial damage.

Although in human urine around 50 enzymes were detected, several of them are used for diagnostic purposes. Urinary lysosomal hydrolytic enzyme— N-acetyl- $\beta$ -glucosaminidase (NAG) is released by lysosomes from the cytoplasm of epithelial cells in the renal proximal convoluted tubules. Gamma-glutamyltransferase and alkaline phosphatase are released by lysosomes from the cytoplasm of epithelial cells in the renal proximal tubule, too, and demonstrate a high activity in certain clinical states, being eliminated in tubular fluid.

Alpha-glucosidase is another enzyme localized in the cytoplasm of epithelial cells of the brush border membrane of renal proximal tubule cells and its excessive secretion in urine was reported. Similarly, increased number of cytoplasmic enzymes – lactate dehydrogenase and glutamate dehydrogenase, synthesized in mitochondria determine renal tubular epithelial cell cytolysis.

## DIFFERENTIAL DIAGNOSIS OF AKI

A detailed and well-aimed history is crucial for the diagnosis of acute kidney injury. Distinguishing AKI from chronic kidney disease is important.

Factors that suggest chronic kidney disease (CKD) include:

1. Long duration of symptoms. A history of chronic symptoms— years of fatigue, weight loss, nocturia, sleep disturbance and pruritus;
2. Nocturia;
3. Absence of acute illness;
4. Anaemia, hyperphosphataemia, hypocalcaemia;
5. Reduced renal size and cortex/ parenchyma ratio on renal ultrasound (except in patients with diabetes and amyloidosis – renal size is preserved).

The classification of AKI as prerenal, intrinsic renal or postrenal failure— can help in differential diagnosis.

In prerenal failure patients present with decreased urine output, dizzi-



ness, orthostatic hypotension, low fluid intake, gastroenteritis, volume loss from vomiting, diarrhea or hemorrhage. Patients with advanced cardiac failure and compromised renal perfusion may present with orthopnea and paroxysmal nocturnal dyspnea.

In intrinsic renal failure patients can present nephrotic syndrome, edema, and hypertension that indicate a glomerular etiology for AKI. Acute tubular necrosis should be suspected in any patient with hemorrhage, sepsis, drug overdose, surgery, diabetes mellitus associated with bacterial infections (Table 44).

Table 44

**Criteria for diagnosis of acute renal failure – prerenal azotemia and acute tubular necrosis**

<b>A. Acute renal failure</b>
1. Azotemia—rapidly increasing blood urea nitrogen (BUN) and creatinine (BUN>30 mg/dL and creatinine>1.5 mg/dL) with or without oliguria.
2. Serum creatinine increase in excess of 0.5 mg/dL in the preceding 2 days.
<b>B. Criteria to differentiate acute tubular necrosis from prerenal azotemia</b>
1. History (volume depletion, decreased cardiac output or vasodilation related to sepsis, liver failure and anaphylaxis favor prerenal azotemia, while exogenous toxins such as medications, or endogenous toxins as in the case of myoglobin, or even prolonged renal hypoperfusion that became unresponsive to appropriate corrective measures or to high dose of loop diuretics).
2. Physical examination (blood pressure, heart rate, orthostatic changes, cardiac sounds, pulmonary findings, presence of ascites or leg edema).
3. Findings of the urine analysis (urinary sediment undetected in prerenal failure, presence of muddy brown granular casts in patients with ATN). Response to therapy should also be recorded.
4. Urinary indices evaluated at the time of consultation are: <ul style="list-style-type: none"> <li>– Urinary sodium (<math>U_{Na}</math>): <math>U_{Na} &lt; 15</math> mEq/L favors prerenal failure, while a value higher than 20 is consistent with ATN.</li> <li>– Urinary to plasma creatinine ratio (<math>U/P_{Cr}</math>). <math>U/P_{Cr} &gt; 20</math> is consistent with prerenal failure, while levels <math>&lt; 15</math> suggest ATN.</li> <li>– Fractional excretion of sodium (<math>FE_{Na}</math>). <math>FE_{Na} &lt; 1\%</math> is suggestive of prerenal azotemia, while levels <math>&gt; 1\%</math> indicate the presence of ATN.</li> <li>– Urinary sodium/potassium ratio (<math>U_{Na}/K</math>; a reflection of prerenal conditions with associated hyperaldosteronism). If <math>U_{Na}/K</math> is less than <math>1/4</math>, this favors prerenal azotemia.</li> </ul>

A careful search for nephrotoxic agents should include a detailed list of all current medications and recent exposure to radiologic contrast agents.

Pigment-induced AKI should be suspected in patients with possible rhabdomyolysis (muscular pain, recent coma, seizure, intoxication, excessive exercise) or hemolysis (recent blood transfusion).

Exposure to toxic substances, such as ethyl alcohol or ethylene glycol, mercury vapors, cadmium or other heavy metals have to be excluded.

Patients with fevers, rash, arthralgias and exposure to medications, including NSAIDs and antibiotics are susceptible to allergic interstitial nephritis.

Postrenal kidney failure needs imagistic confirmation. It occurs in older men with prostatic obstruction, sometimes asymptomatic, because of the chronicity of their symptoms. A history of prior gynecologic surgery or abdominopelvic malignancy often can be helpful in elucidating the cause and level of postrenal obstruction in women. Flank pain and hematuria should raise a concern about renal calculi or papillary necrosis. The use of methotrexate, triamterene or sulfonamides implies the possibility that crystals of these medications have caused tubular obstruction.

### **Urine output role in differential diagnosis**

Abrupt anuria suggests acute and severe glomerulonephritis, embolic renal artery occlusion or acute urinary obstruction. The diminishing of urine output can be the cause of prostate enlargement, urethral stricture or bladder chronic obstruction.

Approximately 50-60% of all causes of AKI are nonoliguric. The changes in urine output correlate poorly with changes in the glomerular filtration rate. Nevertheless, in the differential diagnosis of AKI the identification of anuria, oliguria, and nonoliguria may be useful:

- Anuria (< 100 mL/day) indicates total urinary tract obstruction, bilateral renal artery obstruction, renal cortical necrosis and severe rapidly progressive glomerulonephritis;
- Oliguria (100-400 mL/day) may indicate hepatorenal syndrome, myocardial infarction, prerenal kidney failure;
- Nonoliguria (>400 mL/day) is possible in case of acute interstitial nephritis, acute glomerulonephritis, partial obstructive nephropathy, acute toxic nephritis (radiocontrast-induced, nephrotoxic agents, ischemia), rhabdomyolysis.

### **Serologic tests in differential diagnosis**

Increased rouleaux formation suggests multiple myeloma, the presence of schistocytes – hemolytic uremic syndrome or thrombotic thrombocytopenic purpura.

The presence of the following with related findings may help to define the etiology of AKI:

- Increased serum uric acid level – tumor lysis syndrome
- Serum lactate dehydrogenase (LDH) – renal infarction
- Myoglobin or free hemoglobin – pigment nephropathy
- Antineutrophil cytoplasmic antibody (ANCA) – vasculitis
- Anti-glomerular basement membrane (anti-GBM) antibody – Goodpasture syndrome
- Complement levels – nephritis in autoimmune disease (e.g., SLE)
- Antinuclear antibody (ANA) – SLE or other connective tissue disorders
- Hepatitis B and C virus markers – nephritis secondary to viral hepatitis
- Antistreptolysin (ASLO) antibodies – streptococcal glomerulonephritis.

### Urinalysis in differential diagnoses

In the differential diagnosis of AKI the clinical utility of urine microscopy may be increased by using a simple urinary evaluation based on the number of renal tubular epithelial cells and renal tubular granular casts. The presence of tubular cells and tubular cell casts, granular, brown casts in urine sediment are highly suggestive of tubular necrosis.

The presence of white blood cells (WBCs) and WBC casts suggests pyelonephritis or acute interstitial nephritis. Eumorphic RBCs suggest bleeding along the collecting system. Dysmorphic RBCs or RBC casts indicate glomerular inflammation, suggesting glomerulonephritis.

The dipstick assay may reveal significant proteinuria as a result of glomerular injury. The presence of eosinophils, as visualized with Wright stain or Hansel stain, suggests interstitial nephritis and uric acid crystals may represent ATN associated with uric acid nephropathy.

Urine electrolyte findings can also serve the indicators of functioning renal tubules. The fractional excretion of sodium is the commonly used indicator. However, the interpretation of results from patients in nonoliguric states, those with glomerulonephritis and those receiving or ingesting diuretics can be uncertain.

The formula for calculating the FENa is:

$$FENa = (U_{Na}/P_{Na}) / (U_{Cr}/P_{Cr}) \times 100,$$

where  $U_{Na}$  is sodium in urine;  $P_{Na}$  is sodium in plasma;  $U_{Cr}$  is creatinine in urine and  $P_{Cr}$  is creatinine in plasma.

FENa is identified as the most effective non-invasive test for the differential diagnosis of acute renal failure. A FENa of 1 classifies all entities into two groups: FENa more than 1 (acute tubular necrosis, non-oliguric acute tubular necrosis and urinary tract obstruction) and less than 1 (prerenal azotemia and acute glomerulonephritis).

Finally, the most common differentials to consider in AKI contain the following:

### **Prerenal differentials**

**Cardiorenal syndrome (CRS)** is defined as a condition characterized by the initiation and progression of renal insufficiency secondary to heart failure with negative effects of reduced renal function on the heart and circulation. The classification of CRS is a start point in its differential diagnosis in AKI.

Type 1 CRS reflects an abrupt worsening of cardiac function (e.g., acute cardiogenic shock or decompensated congestive heart failure) leading to acute kidney injury.

Type 2 CRS comprises chronic abnormalities in cardiac function (e.g., chronic congestive heart failure) causing progressive chronic kidney disease.

Type 3 CRS consists of an abrupt worsening of renal function, causing acute cardiac dysfunction (heart failure, arrhythmia, ischemia).

Type 4 CRS describes a state of chronic kidney disease (e.g., chronic glomerular disease) contributing to decreased cardiac function, cardiac hypertrophy, and/or increased risk of adverse cardiovascular events.

Type 5 CRS reflects a systemic condition (sepsis) causing both cardiac and renal dysfunction.

**Hepatorenal syndrome (HRS)** HRS is the development of renal failure in patients with advanced chronic liver disease who have portal hypertension and ascites. The condition is almost always caused by cirrhosis of the liver. Actually, at least 40% of patients with cirrhosis and ascites will develop HRS during the natural history of their disease.

**Volume depletion** as a cause of AKI is probable in any of the following conditions: history of vomiting, diarrhea, diuretic overuse, osmotic diuresis, hemorrhage, burns and reduced fluid intake.

**Septic systemic vasodilatation.** Septic AKI is responsible for about 50% of ARF in ICU. The incidence of severe sepsis depends on how acute organ dysfunction is defined and on whether that dysfunction is attributed to an underlying infection. The clinical manifestations of sepsis are highly variable, depending on the initial site of infection, causative organism and the

pattern of acute organ dysfunction. The signs of both infection and organ dysfunction may be subtle, and thus the most recent international consensus guidelines provide a long list of warning signs of incipient sepsis. Acute kidney injury frequently requires treatment with renal-replacement therapy.

**Alcoholic ketoacidosis** is a metabolic complication of alcohol use and starvation characterized by hyperketonemia and metabolic acidosis without significant hyperglycemia. Alcoholic ketoacidosis causes nausea, vomiting, and abdominal pain. The diagnosis is based on the history of alcohol use and findings of ketoacidosis without hyperglycemia. Patients report nausea, vomiting, pain in abdomen, tachypnoea, tachycardia and hypotension. This syndrome is rapidly reversible and, if taken care of it has a low mortality. The main differences between patients with diabetic ketoacidosis is that patients with alcoholic ketoacidosis are usually alert and lucid despite the severity of the acidosis and marked ketonaemia. The greatest threats to patients with alcoholic ketoacidosis are marked reduction in extracellular fluid volume (resulting in shock and AKI), hypokalaemia, hypoglycaemia and acidosis.

**Diabetic ketoacidosis.** Acute kidney injury in diabetic ketoacidosis is associated with markers of volume depletion and severe acidosis. Acute kidney injury is of concern because it is associated with increased morbidity and mortality as well as increased risk of chronic renal disease. Predominant symptoms are nausea and vomiting, pronounced thirst, abdominal pain that may be severe. In AKI and diabetic ketoacidosis there is usually a clinical evidence of dehydration. If the dehydration is profound enough to cause a decrease in the circulating blood volume, a rapid heart rate and low blood pressure may be observed. In severe diabetic ketoacidosis breathing becomes rapid and of a deep, gasping character, called Kussmaul breathing, complicated with coma, features that are not typical for alcoholic ketoacidosis.

### **Intrinsic renal differentials**

**Acute tubular necrosis (ATN)** is the most common cause of renal acute kidney failure, caused either by ischemic events (hemorrhage, volume loss from gastrointestinal tract and kidney, burns, liquid sequestration, cardiogenic, anaphylactic, obstructive or septic shocks, disseminated intravascular coagulation) or nephrotoxic events (aminoglycosides, amphotericin B, radiocontrast media, cisplatin, tacrolimus, ifosfamide, foscarnet, pentamidine, acyclovir, sulfa drugs, concomitant use of diuretics, ACE inhibitors or angiotensin receptor blockers, myoglobinuria in rhabdomyolysis, hemoglobinuria in hemolysis, acute crystal-induced nephropathy, multiple

myeloma). Clinical findings may include: oliguria, low jugular venous pressure, loss of skin turgor, orthostatic hypotension, dry mucous membranes, tachycardia, abdominal distension (in intra-abdominal compartment syndrome) and muscle tenderness (in rhabdomyolysis). In case of aminoglycoside-induced ATN specific features are as follows: nonoliguric renal failure with elevation in serum creatinine occurring 7-10 days after therapy, elevated FENa, wasting of potassium, calcium and magnesium. In case of tacrolimus and cyclosporine toxicity patients present with hypertension, hyperkalemia, urinary wasting of phosphate and magnesium. Foscarnet toxicity is associated with hypocalcemia, isofosfamide toxicity – with significant hypokalemia and pentamidine nephrotoxicity – with hypomagnesemia and hyperkalemia. Acyclovir leads to the formation of needle-shaped intratubular crystals viewed on microscopy.

**Chronic renal failure (CRF)** is defined as either kidney damage or a decreased glomerular filtration rate of  $<60 \text{ ml/min/1.73m}^2$  for 3 or more months comparing to ARF, which occurs suddenly or over a short period of time. ARF is usually reversible, but CRF is irreversible. Most common cause of ARF is hypovolaemia, but in CRF, common causes are chronic glomerulopathy and diabetic nephropathy. Other causes include chronic pyelonephritis, polycystic kidney disease, connective tissue disorders, and amyloidosis. Clinically the patients present with malaise, anorexia, itching, vomiting, convulsions. The patient is investigated to make the diagnosis, identify the stage of the disease and assess the complications. In ARF, patient usually presents with reduced urine output, but CFR can presents with constitutional symptoms or its long term complication.

Ultrasound examination of the kidney shows small kidneys, reduced cortical thickness, increased echogenicity. In CRF renal size may remain normal in patients with diabetic nephropathy, myeloma, adult polycystic kidney disease and in amyloidosis. In acute renal failure the impairment of renal function occurs suddenly or within a short period of time (days to weeks) in contrast to chronic renal failure, which is diagnosed it lasts than 3 months.

#### **Acute versus chronic renal failure includes:**

##### **In AKI**

- 1) Acute onset
- 2) Rapid reduction in urine output
- 3) Usually reversible
- 4) Tubular cell death and regeneration

### In CRF

- 1) Progressive evolution
- 2) Not reversible
- 3) Nephron loss
- 4) 75% renal function can be lost before noticeable

**Acute glomerulonephritis** (AGN) comprises a specific set of renal diseases in which an immunologic mechanism triggers inflammation and proliferation of glomerular tissue results in damage to the basement membrane, mesangium or capillary endothelium. Patients with AGN and AKI may present with generalized edema, hypertension, severe proteinuria. In the differential diagnoses of glomerulonephritis and AKI we will discuss those glomerular diseases that are manifested with a nephritic syndrome with haematuria, proteinuria and impaired renal function together with hypertension, fluid overload, and oedema.

In primary acute glomerulonephritis, disease is almost entirely restricted to the kidneys (as in IgA nephropathy or post-streptococcal glomerulonephritis), while in secondary acute glomerulonephritis it occurs in association with more diffuse inflammation (as in systemic lupus erythematosus or systemic vasculitis). Prompt diagnosis of glomerulonephritis and AKI is vital as patients with impaired renal function, hypertension, and urinary abnormalities may rapidly lose kidney function.

**Hemolytic uremic syndrome** is the most common cause of acute kidney injury in children which develops after prodromal diarrhea caused by bacteria (*S.dysenteriae*, *E.coli*, *S.typhi*, *C.jejuni*, *L.pneumophila*), rickettsial (Rocky Mountain spotted fever, microtubiotics) and viral infections (*HIV*, *Coxsackievirus*, *Echovirus*, *Influenza virus*, *Ebstein-Barr virus*, *Herpes simplex virus*). It is characterized by progressive renal failure, microangiopathic nonimmune hemolytic anemia, thrombocytopenia and neurological abnormalities (irritability, lethargy, seizures).

### Postrenal differentials

Obstructive nephropathy and AKI are caused by obstruction of urinary outflow and slowing of the tubular function and glomerular filtration rate. A close examination of patient is necessary. It can be identified by kidney, bladder scanning which will reveal a large amount of retained urine or by ultrasonography of the kidneys, which will show hydronephrosis.

Extrarenal obstruction includes prostate hypertrophy, neurogenic bladder, retroperitoneal fibrosis, prostate, bladder or cervical cancer, ureter stones. Intrarenal obstruction is caused by stones, clots and tumors of the kidney.



**BIBLIOGRAPHY**

1. Palevsky P, Murray P.T., eds. Acute Kidney Injury and Critical Care Nephrology. Nephrology Self-Assessment Program (NephSAP) 2006; 5: 1-76.
2. Mehta R.L., Kellum J.A., Shah S.V., Molitoris B.A., Ronco C., Warnock D.G., et al. Acute Kidney Injury Network: report of an initiative to improve outcomes in acute kidney injury. *Crit Care* 2007; 11: R 31.
3. Bellomo R., Ronco C., Kellum J.A., Mehta R.L., Palevsky P., and the Acute Dialysis Quality Initiative Workgroup. Acute renal failure – definition, outcome measures, animal models, fluid therapy and information technology needs: the Second International Consensus Conference of the Acute Dialysis Quality Initiative (ADQI) Group. *Crit Care* 2004; 8: R 204-R 212.
4. Bellomo R., Kellum J.A., Ronco C. Defining acute renal failure: physiological principles [review] *Intensive Care Med* 2004; 30: 33-37.
5. Abosaif N.Y., Tolba Y.A., Heap M., Russell J., El Nahas A.M. The outcome of acute renal failure in the intensive care unit according to RIFLE: model application, sensitivity, and predictability. *Am J Kidney Dis* 2005; 46: 1038-1048.
6. Hoste E.A., Clermont G., Kersten A., Venkataraman R., Angus D.C., De Bacquer D., et al. RIFLE criteria for acute kidney injury are associated with hospital mortality in critically ill patients: a cohort analysis: *Crit Care* 2006;10: R73.
7. Zhou H., Hewitt S.M., Yuen P.S.T., Star R.A. Acute kidney injury biomarkers—needs, present status, and future promise. In: Palevsky P, Murray P.T., eds. Acute Kidney Injury and Critical Care Nephrology. Nephrology Self-Assessment Program (NephSAP). 2006; 5: 63-70.
8. Schrier R.W., Wang W., Poole B., Mitra A. Acute renal failure: definitions, diagnosis, pathogenesis, and therapy. *J Clin Invest* 2004; 114: 598.
9. Davidson's Principles and practice of medicine (21<sup>st</sup> revised ed.) / by Colledge N.R., Walker B.R., and Ralston S.H., eds. – Churchill Livingstone, 2010. – 1376 p.
10. Harrison's principles of internal medicine (18<sup>th</sup> edition) / by Longo D.L., Kasper D.L., Jameson J.L. et al. (eds.). – McGraw-Hill Professional, 2012. – 4012 p.
11. <http://www.medscape.com/viewarticle/822384> (accessed 11.04.2018)
12. <http://www.renalguard.com/> (accessed 11.04.2018)
13. <https://www.ncbi.nlm.nih.gov/pubmed/11230333> (accessed 12.04.2018)
14. [emedicine.medscape.com/article/243492-overview](http://emedicine.medscape.com/article/243492-overview) (accessed 12.04.2018)



## DIFFERENTIAL DIAGNOSIS OF EDEMA

**DEFINITION.** Edema is an accumulation of fluid in the intercellular tissue, that results from an abnormal expansion in interstitial fluid volume and it is generally not clinically apparent until the interstitial volume has increased by at least 2.5–3 liters.

There are different medical terms for edema in specific areas or organs of the body:

- 1) *Hepatic edema* is the excessive fluid accumulation in tissues due to a liver dysfunction
- 2) *Cardiac edema* is the excessive fluid accumulation in tissues due to heart failure
- 3) *Renal edema* is the excessive fluid accumulation in the body's tissues due to kidney disease
- 4) *Anasarca* is the term for severe generalized edema
- 5) *Ascites* is the term for excessive fluid accumulation within the peritoneal cavity
- 6) *Pleural effusion* is the term for edema in the pleural space
- 7) *Pericardial effusion* is edema in the pericardial space
- 8) *Pulmonary edema* is the term for edema within the lungs
- 9) *Cerebral edema* is the edema within the brain
- 10) *Lymphedema* is the excessive fluid that cannot be drained by the lymphatic vessels

**PATHOPHYSIOLOGY.** The fluid between the interstitial and intravascular spaces is regulated by the capillary hydrostatic pressure gradient and the oncotic pressure gradient across the capillary. The accumulation of fluid occurs when local or systemic conditions disrupt this equilibrium. It is useful to review some background pathophysiology of total body water: 67% is intracellular and 33% – extracellular. In extracellular water 25% is intravascular and 75% is interstitial.

The regulation of fluid distribution between the intravascular and interstitial spaces consists of a constant exchange of water and solutes at the arteriolar end of the capillaries. The water exchange includes the following:

- a) Fluid is returned from the interstitial space to the intravascular space at the venous end of the capillaries and via the lymphatics
- b) The movement of fluid from the intravascular space to the interstitium occurs through capillary hydrostatic pressure that pushes the fluid out of the vessels. The interstitial oncotic pressure pulls the fluid

into the interstitium and capillary permeability allows the fluid to escape into the interstitium

- c) The movement of fluid from the interstitium to the intravascular space occurs when the plasma oncotic pressure from plasma proteins pulls the fluid into the vascular space and the interstitial hydrostatic pressure pushes the fluid out of the interstitium

The capillary hydrostatic pressure and the intravascular oncotic pressure are the most important factors. A small gradient favors filtration. The disturbance of the pressure gradient includes:

- 1) An increase in the capillary hydrostatic pressure (increased renal sodium vascular space into the interstitium; the excess fluid is removed by the lymphatic system)
- 2) A decrease in the plasma oncotic pressure (hypoalbuminemia)
- 3) An increase in the capillary permeability (burns, angioedema)
- 4) Lymphatic obstruction
- 5) An increase in the interstitial oncotic pressure (myxedema)

In this context the causes of edema can be different (systemic and local) and they are systematized in Table 45.

*Table 45*

#### Local and systemic causes of edema

Cause of edema	Regulation of fluid distribution
<b>Local causes</b>	
Cellulitis	Increased capillary permeability
Chronic venous insufficiency	Increased capillary permeability caused by local venous hypertension
Deep venous thrombosis	Increased capillary permeability caused by local venous hypertension
Lymphedema	Primary and secondary lymphatic obstruction
Lipedema	Accumulation of fluid in adipose tissue
May-Thurner syndrome (compression of the left iliac vein by right iliac artery)	Increased capillary permeability caused by local venous hypertension from compression
<b>Systemic causes</b>	
Cardiac disease	Increased capillary permeability from systemic venous hypertension; increased plasma volume
Hepatic disease	Increased capillary permeability from systemic venous hypertension; decreased plasma oncotic pressure, reduced protein synthesis

Malabsorption/protein-calorie malnutrition	Reduced protein synthesis leading to decreased plasma oncotic pressure
Renal disease	Increased plasma volume; decreased plasma oncotic pressure from protein loss
Allergic reaction, urticaria and angioedema	Increased capillary permeability
Obstructive sleep apnea	Pulmonary hypertension resulting in increased capillary hydrostatic pressure
Pregnancy and premenstrual edema	Increased plasma volume

The main derangement that leads to edema is a reduction of effective arterial volume. This reduction is caused by diminished cardiac output or systemic vascular resistance.

Reduced effective arterial volume leads to physiologic activation that tries to restore the volume. This response leads to the retention of salt and water. Hypovolemia causes the diminished blood flow to the juxtaglomerular cells in the kidney. This causes a cascade of renin release, angiotensinogen and then angiotensin I, which is then converted to angiotensin II hypersecretion. This activation eventually leads to vasoconstriction on the renal efferent arterioles with resultant enhanced salt and water reabsorption in the kidneys. Angiotensin II enters the systemic circulation, stimulating aldosterone release in the adrenal cortex. Aldosterone will further enhance sodium reabsorption and potassium excretion and its release is increased in many edematous states such as heart failure, liver ascites, nephrotic syndrome, renal failure (Figure 4).

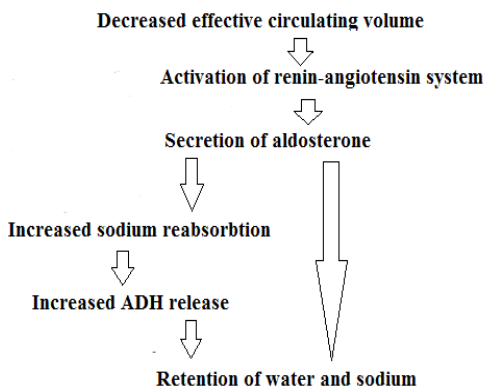


Figure 4. Pathophysiology of edema

In non-pitting edemas (e.g., myxedema) the tissues are gradually filled with water-loving molecules such as hyaluronan, a carbohydrate-like molecule. These molecules are responsible for attracting fluid to the tissues. They absorb water and swell up to cause the edema.

Non-pitting edema may be also caused by certain disorders of the lymphatic system such as lymphedema, a condition of the lymphatic circulation which may occur congenitally, after a mastectomy or lymph node surgery. It occurs in lymphedema, where the lymphatic system breaks down and the lymph nodes swell up. The osmotic pressure generated by the swollen lymph nodes may be responsible for the pushing of the fluids against the skin even when pressure is applied on the affected area.

### CLASSIFICATION OF EDEMA

**Pitting edema** is detected by the presence of pitting after pressure is applied to the edematous area.

- Grade 1 pitting edema: A pit of 2 mm or less, presents as slight pitting with no distortion. Pitting disappears immediately
- Grade 2 pitting edema – A deeper pit measuring between 2 mm and 4 mm. and the pitting will disappear in 10 – 15 seconds
- Grade 3 pitting edema – A noticeably deep pit measuring between 4 mm and 6 mm. The area affected will look swollen. The indentation will take as long as 1 minute before it disappears
- Grade 4 pitting edema – A very deep pit is seen which will last between 2 to 5 minutes before it disappears. It will measure 6 – 8 mm in depth and the edema will look gross and distorted

**Non-pitting edema** – Non-pitting edema usually affects the legs or arms. If the pressure applied to the skin does not result in a persistent indentation, this type of edema is referred to as non-pitting edema, when lymphedema or pretibial myxedema should be considered.

**According to the distribution of edematous fluid edema is classified into:**

- a) Local edema
- b) Generalized edema.

Local edema occurs in one organ or a part of the body (brain edema, pulmonary edema, etc.). In regional edema, the clinician should localize the area of swelling to help deduce where a region of venous or lymphatic obstruction is likely to be present or localized allergen exposure has occurred. As cellulitis also can manifest with regional edema, the assessment of the

patient for fever and local signs of inflammation is important. If the edema is localized to the face, the patient should be carefully evaluated for concurrent airway involvement, which can be life threatening. Generalized edema occurs in the whole body (cardiac edema, renal edema, ascites).

### Clinical considerations and differential diagnosis of edema

The goals of the evaluation of a patient with edema include the determination of the underlying character of the edema (localized or generalized), and causes of edema, as it will guide both the evaluation and treatment. It is important to identify those conditions that are potentially life-threatening or have serious medical complications, although most causes of edema are limiting local disorders (Table 46).

Table 46

Pathological status of edema

Pathological status	Pulmonary edema	Central venous pressure	Ascites	Peripheral edema	Anasarca	Pitting edema	Non-pitting edema
Right heart failure		>	+	+	+	+	
Left heart failure	+	>					
Liver cirrhosis		<	+	+		+	
Nephrotic syndrome		>	+	+	+	+	
Idiopathic edema				+			
Hypoalbuminemia			+			+	
Venous insufficiency				+		+	
Deep venous thrombosis				+		+	
Myxedema							+
Allergic reactions							+

Potentially serious medical disorders also include anaphylaxis, angioedema with laryngeal involvement, decreased cardiac output (espe-

cially as a result of myocarditis or restrictive pericarditis) and anuria in hepatic and renal disease.

The physical examination is focused on measuring growth parameters, full evaluation of the cardiovascular system, including vital signs. Findings of tachycardia, tachypnea, gallop, pulmonary rales or hepatomegaly are seen in patients with heart failure, tachypnea and rales alone may be indicative of pulmonary edema. Increased blood pressure levels may reflect hypervolemia resulting from acute or chronic renal failure, chronic glomerulonephritis.

The following signs and symptoms are found in a variety of diseases that cause edema:

1. A patient with diaphoresis, dyspnea on exertion and a history of heart disease may have edema secondary to cardiac failure. Findings of clinical examination include tachycardia, tachypnea, rales, hepatomegaly
2. A history of food allergies may present acutely with urticaria and angioedema after allergen exposure. If there is airway involvement, this is a medical emergency
3. A history of jaundice, steatorrhea or abdominal pain should point the clinician toward a diagnosis of chronic liver disease or a protein losing-enteropathy
4. A progressive anasarca with significant periorbital edema and edema of the face, but minimal systemic complaints, may suggest a possible nephrotic syndrome
5. Cola-colored urine with either generalized or facial edema strongly suggests acute glomerulonephritis. These patients may also have hypertension
6. Lymphangiosarcoma is a late complication of lymphedema. This was originally described in the lymphedematous arms of patients following radical mastectomy

**Acute swelling** of a limb over a period of less than 72 hours is more characteristic of deep venous thromboses, cellulitis, trauma, or recent initiation of treatment with calcium channel blockers

**Unilateral swelling** from compression or compromise of venous or lymphatic drainage can result from venous thrombosis, venous insufficiency, venous obstruction by tumor, lymphatic obstruction or lymphatic destruction.

**Bilateral or generalized swelling** suggests a systemic cause and is due

to the onset or exacerbation of chronic systemic conditions, such as congestive heart failure, renal disease or hepatic failure, pulmonary hypertension, chronic renal or hepatic disease, protein-losing enteropathies, or severe malnutrition.

Edema can be an adverse effect of certain medications. The mechanism often includes the retention of salt and water with increased capillary hydrostatic pressure (Table 47).

Table 47

#### Edema as an adverse effect of medication

Classes of drugs	Medications
Antihypertensives	Calcium channel blockers, clonidine, hydralazine, methyldopa, beta-adrenergic blockers
Antivirals	Acyclovir
Chemotherapeutics	Cyclophosphamide, cyclosporine, mithramycin
Hormones	Androgen, corticosteroids, estrogen, progesterone, testosterone
Nonsteroidal antiinflammatory drugs	Diclofenac, nimesulid, celecoxib, ibuprofen

**Laboratory evaluation** includes urinalysis with dipstick for proteinuria, testing principally detects albumin. The finding of a markedly positive dipstick for protein in combination with hypoalbuminemia and clinical edema is virtually diagnostic of the nephrotic syndrome. False-positive results may be obtained with very alkaline or concentrated urines. Highly positive results (>300 mg/dL) cannot be explained by a concentrated and a very alkaline urine.

Examination of the urine sediment may also reveal hematuria, pyuria and cellular casts. In the edematous patient with renal disease, different patterns of urinary findings favor different renal diseases. Hematuria with red cell casts with or without heavy proteinuria is a suspicion of poststreptococcal glomerulonephritis. The absence of red cell casts does not exclude the diagnosis.

Heavy proteinuria is most consistent with a noninflammatory cause of nephrotic syndrome such as minimal change disease or focal segmental glomerulosclerosis. Based upon the results of clinical history, physical examination and urinalysis, additional serum laboratory tests will be indicated (e.g. brain natriuretic peptide measurement in chronic heart failure).

In nephrotic syndrome these will include complement C3, C4, ANA, and anti-double stranded DNA to screen for diseases such as membranous

proliferative glomerulonephritis or lupus. If acute glomerulonephritis is suspected, the serum complement component 3 (C3) level is a useful test, as causes of glomerulonephritis can be classified as either hypocomplementemic or normocomplementemic.

The presence of antistreptococcal antibodies is characteristic of post-streptococcal glomerulonephritis and antinuclear antibodies (ANA), antiglomerular basement membrane (GBM) antibodies, and antineutrophil cytoplasmic autoantibodies (ANCA) favors the diagnosis of nephrotic syndrome and vasculites.

In chronic liver disease serologic screening for markers of viral infection will be performed. These include tests for hepatitis B (hepatitis B surface antigen and core antibody), hepatitis C (antibody), and HIV (antibody) infection. A diagnosis of chronic liver disease is suspected in a patient with hypoalbuminemia, but no proteinuria. In this setting, liver functions tests, total serum protein levels and prothrombin times should be performed.

Stool level of alpha-1 antitrypsin is the best screening test for protein-losing enteropathy.

Angioedema assessment includes the evaluation of plasma levels of the complement components, C1, C4, C2, and C1 inhibitor may help diagnose inherited or acquired C1 inhibitor deficiency. C4 and C2 levels are constantly low in this category of patients. If we are suspecting venous thrombosis, coagulation studies should be obtained. If thrombosis is diagnosed, additional studies may include the measurement of antithrombin III and Factor V Leiden levels.

Based upon on the results of the clinical evaluation and laboratory findings the imaging studies will be indicated in differential diagnosis of edema (Table 48):

1. Chest radiography is helpful in detecting pulmonary edema
2. Doppler ultrasonography (or other studies assessing vascular flow) is indicated in patient with suspected venous thrombosis. A D-dimer enzyme-linked immunosorbent assay can rule to deep venous thrombosis in low-risk patients. Duplex ultrasonography can also be used to confirm the diagnosis of chronic venous insufficiency
3. Magnetic resonance venography of the lower extremity and pelvis should be obtained in patients with unilateral left leg swelling and negative results on duplex ultrasonography if the suspicion for deep venous thrombosis persists. Compression of the left iliac vein by the right iliac artery (May-Thurner syndrome) should be suspected in



**Differential diagnosis of edema**

<b>Pathological status</b>	<b>Characteristic features of edema</b>	<b>Aspects of edema</b>	<b>Confirmation of diagnosis</b>
<b>Unilateral edema</b>			
Lipedema	Chronic course, begins around or after puberty. Location: predominantly lower extremities	Non-pitting edema; increased distribution of soft, adipose tissue, tibial tenderness	Clinical evaluation
Medication - induced edema	Location: lower, weeks after initiation of medication, resolves within days of stopping the medication	Soft, pitting edema	Clinical history of medication
Obstructive sleep apnea	Chronic evolution, located on lower extremities	Mild, pitting edema associated with: daytime fatigue, snoring, obesity	Clinical evaluation, History Polysomnography Echocardiography
<b>Bilateral edema</b>			
Chronic venous insufficiency	Chronic; begins in middle to older age with location on lower extremities, bilateral distribution in later stages	Soft, pitting edema Associated findings: venous ulcerations over medial malleolus. The possibility of a ruptured Baker's cyst should also be borne in mind.	Duplex sonography Ankle-brachial index to evaluate for arterial insufficiency
Deep venous thrombosis	Acute evolution Location: upper or lower extremities	Pitting edema with tenderness, with or without erythema Positive Homans sign	D-dimer assay Duplex ultrasonography, Magnetic resonance
Lymphedema	Chronic evolution, often following lymphatic obstruction from trauma, surgery	Early: dough-like skin; pitting Late: thickened, fibrotic, skin painless, heavy extremities	Lymphoscintigraphy T1-weighted magnetic resonance Lymphangiography

women between 18 and 30 years of age who present with edema of the left lower extremity. Magnetic resonance imaging may aid in the diagnosis of musculoskeletal etiologies, such as a gastrocnemius tear or popliteal cyst. T1-weighted magnetic resonance lymphangiography can be used to visualize directly the lymphatic channels when lymphedema is suspected.

4. Renal ultrasonography allows the clinician to characterize kidney size and assess for cystic renal disease and hydronephrosis.
5. Echocardiography can evaluate ventricular function, assess for the presence of a pericardial effusion, and aid in the diagnosis of cardiac disease. Echocardiography should be performed in patients with obesity, obstructive sleep apnea and edema.
6. Ankle-brachial index should be measured in patients with chronic venous insufficiency.
7. Indirect radionuclide lymphoscintigraphy, which shows absent or delayed filling of lymphatic channels, is the method of choice for evaluating lymphedema when the diagnosis cannot be made clinically.
8. Renal biopsy is a direct indication in the suspicion of glomerulonephritis, particularly with heavy proteinuria with significant renal dysfunction.

## BIBLIOGRAPHY

1. Davidson's Principles and practice of medicine (21<sup>st</sup> revised ed.) / by Colledge N.R., Walker B.R., and Ralston S.H., eds. – Churchill Livingstone, 2010. – 1376 p.
2. Harrison's principles of internal medicine (18<sup>th</sup> edition) / by Longo D.L., Kasper D.L., Jameson J.L., et al. (eds.). – McGraw-Hill Professional, 2012. – 4012 p.
3. The Merck Manual of Diagnosis and Therapy (nineteenth Edition)/ Berkow R., . Fletcher A.J. and others. – published by Merck Research Laboratories, 2011.
4. Alraies O., Kabach M., Shaheen K., Alraies A.H. Unilateral leg swelling and hydronephrosis. *QJM* 2013; 106: 681–683.
5. JCS Joint Working Group: Guidelines for the diagnosis, treatment and prevention of pulmonary thromboembolism and deep vein thrombosis (JCS 2009). *Circ J* 2011; 75: 1258–1281.
6. The management of secondary lymphoedema – a guide for health professionals. Available at <http://www.nbooc.org.au/> (accessed 02.10.2017)

7. Hilton R. Acute renal failure. *BMJ* 2006; 333:786-790.
8. Koo L.W., Reedy S., Smith J.K. Patient history key to diagnosing peripheral edema. *Nurse Pract* 2010; 35:44-52.
9. Maegawa J., Mikami T., Yamamoto Y., et al. Types of lymphoscintigraphy and indications for lymphaticovenous anastomosis. *Microsurgery* 2010; 30: 437-442.
10. Villeco J.P. Edema: a silent but important factor. *J Hand Ther* 2012; 25(2): 153-162.
11. [www.tdmu.edu.ua](http://www.tdmu.edu.ua): Management of patients with urinary syndrome (accessed on 20.02.2018)
12. <http://meded.ucsd.edu/clinicalmed/introduction.htm> (accessed 20.02.2018)
13. [www.tdmu.edu.ua](http://www.tdmu.edu.ua). Management of patients with urinary syndrome (accessed 20.02.2018)
14. [emedicine.medscape.com/article/243492-overview](http://emedicine.medscape.com/article/243492-overview) (accessed 14.04.18)
15. [www.reliasmedia.com/articles/65034-i-m-swollen-eva...emergency-department](http://www.reliasmedia.com/articles/65034-i-m-swollen-eva...emergency-department) (accessed 14.04.18).
16. [www.brainkart.com/article/Edematous-Stat](http://www.brainkart.com/article/Edematous-Stat) (accessed 18.04.18).
17. [iliveok.com/health/focal-segmental-glomerul](http://iliveok.com/health/focal-segmental-glomerul) (accessed 20.04.18).

## DIFFERENTIAL DIAGNOSIS OF NEPHROTIC SYNDROME

**DEFINITION.** Nephrotic syndrome is a glomerular disorder with clinical complex characterized by a number of renal and extrarenal features. In nephrotic syndrome (NS) is a classical triad defined as proteinuria ( $>3.5$  g/24 hours), hypoalbuminaemia ( $<30$  g/L), edema, hyperlipidemia, lipiduria and hypercoagulability

The key component is proteinuria, which results from altered permeability of the glomerular filtration barrier for proteins. The other components of the nephrotic syndrome and the ensuing metabolic complications are all secondary to urine protein loss and can occur with lesser degrees of proteinuria or may be absent even in patients with massive proteinuria.

**PATHOPHYSIOLOGY.** The glomerular capillaries are lined with fenestrated endothelium that sits on the glomerular basement membrane, which is covered by glomerular epithelium or podocytes, which envelops the capillaries with cellular extensions called foot processes. Between the foot processes are the filtration slits. These three structures – the fenestrated endothelium, glomerular basement membrane and glomerular epithelium – are the glomerular filtration barrier.

In nephrotic syndrome podocytes, which normally prevent proteins from being filtered loses their selectivity. An increase in glomerular permeability leads to albuminuria and to hypoalbuminemia, that lowers the plasma colloid osmotic pressure, causing greater transcapillary filtration of water throughout the body. One or more of these mechanisms may be seen in any one type of nephrotic syndrome. Albuminuria alone may occur or, with greater injury, leakage of all plasma proteins may take place.

Proteinuria with more than 85% of albumin is selective proteinuria. Albumin has a net negative charge and it is proposed that loss of glomerular membrane negative charges could be important in causing albuminuria. Nonselective proteinuria, being a glomerular leakage of all plasma proteins, would not involve changes in glomerular net charge but rather a generalized defect in permeability. This construct does not permit clear-cut separation of causes of proteinuria, except in minimal-change nephropathy, in which proteinuria is selective.

Capillary hydrostatic pressure and the gradient of plasma to interstitial fluid oncotic pressure determine the movement of fluid from the vessels to

the interstitium. With a high capillary hydrostatic pressure or a low intravascular oncotic pressure, the amount of fluid filtered exceeds the maximal lymphatic flow. The produced hypovolemia will increase additionally sodium and water retention by the kidneys and edema appears.

Hypovolemia produces the following neurohormonal disturbances:

- increased activation of the renin-angiotensin-aldosterone system
- hypersecretion of vasopressin, aldosterone
- increased activity of the sympathetic nervous system

This hypothesis does not, however, explain the occurrence of edema in many patients in whom plasma volume is expanded and the renin-angiotensin-aldosterone axis is suppressed. The latter finding suggests that primary renal salt and water retention may also contribute to edema formation in some cases.

An alternative hypothesis relates the presence of nephritic syndrome and an intrinsic defect in the renal tubules causing a decrease in sodium excretion. The filtered intraluminal protein directly stimulated renal sodium reabsorption. This hypothesis is supported by the following data: sodium retention is observed even before the serum albumin level starts falling and intravascular volume is normal or it can be increased in some patients with nephrotic syndrome.

Additionally, an enhanced peripheral capillary permeability is related to albumin, as shown by radioisotopic technique in human studies. This then would lead to increased tissue oncotic pressure, fluid retention and edema.

Supplementary, a reduction in glomerular plasma flow play a role in the urinary loss of proteins. The increase in the clearance of proteins along the glomerular capillary will remove the water and will create an increased diffusion gradient along the Bowman's space.

It is important to emphasize that, edema formation is not simply due to a sodium retention following a decrease in systemic volume and fall in plasma colloid pressure. Recent evidence has shown that edema formation and sodium retention may thus be less related to hypovolemia itself, but to a primary intrinsic dysfunction of the renal handling of sodium tubular absorption and it is increased in patients with nephrotic syndrome, even in segments of distal convoluted tubule, due to mechanisms that remain obscured.

The greater proteinuria, the lower the serum albumin level is. Hypoalbuminemia is compounded further by increased renal catabolism and usually increased hepatic synthesis of albumin. Nonselective proteinuria would

not involve changes in glomerular basement membrane but rather a generalized defect in permeability.

In nephrotic syndrome, enzymes like hepatic 3-hydroxy-3-methylglutaryl-coenzyme A reductase and acyl-coenzyme-A-cholesterol acyltransferase are both increased. Simultaneously, cholesterol-7-alpha-hydroxylase and lipase are decreased. Both processes confirm that lipid synthesis is increased in nephrotic syndrome.

The severity of lipid abnormalities directly correlates with the severity of proteinuria, but not with the identity of glomerular lesions or primary etiology of nephrotic syndrome. Increased triglycerides also contribute to the glomerular damage in mechanisms that remain unclear. It is believed that lipoprotein-mediated conversion of VLDL to LDL may be slowed down in nephrotic syndrome.

Hypercoagulability is probably multifactorial in origin and is caused, at least in part, by increased urinary loss of antithrombin III, hyperfibrinogenemia due to increased hepatic synthesis, impaired fibrinolysis, and increased platelet aggregability.

## CLASSIFICATION

Nephrotic syndrome can be classified into primary or secondary depending on the underlying etiology. Nephrotic syndrome can be primary (a disease specific to the kidneys), or it can be secondary (renal manifestation of a systemic illness).

**Primary (idiopathic) nephrotic syndrome** is defined as nephrotic syndrome due to a primary glomerular disease. This is a diagnosis of exclusion that is made only if secondary causes cannot be found and include the following:

Minimal change disease

- Focal segmental glomerulosclerosis
- Membranous nephropathy
- Membranoproliferative glomerulonephritis
- IgM nephropathy
- Hereditary nephropathies: Alport's syndrome, IgA nephropathy, C1q nephropathy, etc.

**Secondary nephrotic syndrome** falls into the same three categories:

- Membranous nephropathy – viral hepatitis, diabetes mellitus, SLE, preeclampsia, sarcoidosis, syphilis, malignancy, amyloidosis and paraproteins

- Focal segmental glomerulosclerosis –viral infections (e.g., hepatitis B, hepatitis C, human immunodeficiency virus), obesity, diabetes mellitus, hypertensive nephrosclerosis
- Minimal change disease –drugs, malignancy, particularly Hodgkin’s lymphoma

Nephrotic syndrome may be classified from the therapeutic perspective, as steroid sensitive, steroid resistant, steroid dependent, or frequently relapsing.

**Clinical considerations and diagnostic items.** Clinical evaluation of nephrotic syndrome will take in considerations the presence of the following symptoms:

1. Swelling of face, periorbital edema, pitting bilateral edema in the lower extremities and genitals or anasarca
2. Features of systemic disease
3. Drug administration history
4. Symptoms of high blood pressure, such as visual disturbance and headache
5. Dyspnea suggestive of pleural and pericardium effusions
6. Abdominal fullness, distension suggestive for ascites
7. Emission of foamy urine
8. Weight gain, anorexia

Symptoms of deep vein thrombosis or pulmonary edema as complication of nephrotic syndrome

**Diagnostic studies for nephrotic syndrome will include the following:**

A full laboratory examination should be performed in patients. When nephrotic syndrome is diagnosed (24-hour urine collection shows proteinuria  $> 3.5\text{g}/24\text{hrs}$ ), the following laboratory data will be present:

1. Low serum albumin concentration
2. Abnormal lipid panel
3. Normal or elevated plasma creatinine concentration
4. Abnormal urine culture and antibiogram
5. Electrolyte serum concentration disturbances
6. Anemia by hemodilution

To elucidate the secondary etiologies of nephrotic syndrome it is necessary to perform:

1. Plasma glucose level
2. Antinuclear antibody panel
3. C reactive protein

4. Value of hepatic enzymes
5. Anti- ds DNA antibodies
6. Serologic tests for Hepatitis BV and Hepatitis CV
7. Rheumatoid factor
8. HIV test
9. Complement C3 and C4 levels
10. Serum and urine protein electrophoresis
11. ANCA

Urinalysis is the first test used in the diagnosis of nephrotic syndrome. The chemistry of the dipsticks is such that albumin is the major protein that is tested. Glucosuria suggest the diabetes.

The urine sediment exam may show cells and/or casts. Waxy casts mark proteinuria suggests renal disease. One can see oval fat bodies and also fatty casts by use of a polarizing microscope. They occur because of glomerular filtration of lipoproteins. Viewed by polarizer, the oval fat bodies and fatty casts cause a "Maltese cross" appearance. Proteinuria can be classified according to its selectivity in high selective and low selective proteinuria (Table 49).

Table 49

#### Types of proteinuria

High selective proteinuria	Low selective proteinuria
Low molecular weight proteins	High molecular weight proteins
Albumin	Globulins
Transferrin	Albumins

The presence of more than 10 red blood cells (RBCs) is indicative of microhematuria. Microhematuria may occur in membranous nephropathy but not in minimal-change nephropathy.

Glomerular disease may allow RBCs to traverse the damaged glomerular basement membrane and the RBCs in the sediment may then be deformed, or dysmorphic. More than 2 granular casts in the entire sediment is a biomarker for renal parenchymal disease. Granular casts are present in marked proteinuria and point to reduced renal function. Urinary protein is of potential interest. This can be tested by urine protein electrophoresis. Proteinuria is measured by a timed collection or a single spot collection. The overflow proteinuria occurs in paraproteinemia, such as multiple myeloma.

In the case of selective proteinuria, a charge-selective leak of albumin across the glomerular barrier may occur, perhaps due to reduced negative



charges on that barrier, whereas nonselective proteinuria points to more substantial glomerular injury and can evaluate the response to prednisone treatment. Ultrasound guided renal biopsy for visualization under light microscopy, immunofluorescence and electron microscopy are usually recommended for patients with nephrotic syndrome. Renal biopsy provides diagnostic and prognostic benefits.

This technique has increased greatly our understanding of renal disease and, in particular, knowledge of glomerulonephritis. To obtain the maximum information from this invasive investigation, it is important to examine the tissue obtained by light and electron microscopy and by immunohistological techniques.

### **I. Direct indications to renal biopsy:**

- nephritic syndrome
- persistent proteinuria  $> 1$  g/24 hours
- persistent microscopic or macroscopic hematuria (disordered hemostasis excluded)
- systemic diseases with renal involvement
- chronic renal failure with normal or near normal sized kidneys
- unexplained acute renal failure
- acute nephritic syndrome, if significant haematuria is present or if it is unresponsive to corticosteroid treatment
- acute nephritic syndrome, if significant urinary abnormalities persist for longer than 12 months or renal functional impairment present

### **II. Contraindications to renal biopsy:**

- disorders of coagulation
- thrombocytopenia

Renal biopsy is not strongly recommended in minimal change disease – the most common primary cause of nephrotic syndrome in children and in patients with diabetic nephropathy. In the most common secondary causes of nephrotic syndrome in adults, renal biopsy is not generally recommended. But patients with unknown or unsure etiology of nephrotic syndrome, with relapses and low response to steroids are recommended to undergo renal biopsy for definitive diagnosis and treatment.

Identification of a pathological diagnosis is important because minimal change glomerular disease, focal glomerulosclerosis and membranous nephropathy have different treatment options and prognoses. It is important to differentiate minimal-change disease presenting in adults from

focal glomerulosclerosis, as the former has an excellent response to steroids. Immunoglobulin M nephropathy falls in between the two and has an intermediate response to steroids. Serum tests for kidney function are essential. Serum creatinine will be in the normal range in uncomplicated nephrotic syndrome, such as it occurs in minimal change nephropathy.

The serum albumin level is classically low in nephrotic syndrome, being below its normal range of 3.5-4.5 g/dL, but in some cases it can be under normal values.

Tests for previous streptococcal infection, such as antistreptolysin O, are not usually indicated for nephrotic syndrome, since postinfectious glomerulonephritis usually causes a nephritic rather than a nephrotic syndrome.

Phospholipase A<sub>2</sub> receptor (PLA<sub>2</sub>R) is a cell surface transmembrane receptor expressed on the surface of podocytes. About 70% of patients with idiopathic membranous nephropathy have autoantibodies directed against PLA<sub>2</sub>R. The levels of this antibody have a strong correlation with clinical disease activity and really help in monitoring treatment efficacy. The absence of these antibodies may suggest secondary membranous nephropathy such as they are associated with cancers or diabetic nephropathy. During the treatment, the levels of the antibodies generally decline before remission of proteinuria. After treatment, about half of the patients who are PLA<sub>2</sub>R negative remain in remission for 5 years, but those who remain PLA<sub>2</sub>R positive relapse in just 2 years. The use of the PLA<sub>2</sub>R antibody test has changed the diagnosis and treatment of idiopathic membranous nephropathy.

Metabolic consequences of the nephrotic syndrome include infections, hyperlipidemia and accelerated atherosclerosis, hypocalcaemia, hyperkalemia and hypercoagulability. Impaired fibrinolysis, and increased platelet agreeability are severe. As a consequence of these perturbations, patients can develop spontaneous peripheral arterial or venous thrombosis, renal vein thrombosis and pulmonary embolism. Renal vein thrombosis is particularly common (up to 40%) in patients with nephrotic syndrome due to membranous glomerulopathy, membranoproliferative glomerulonephritis and amyloidosis.

Other complications of nephrotic syndrome include protein malnutrition and iron-resistant microcytic hypochromic anemia due to transferrin loss. Hypocalcemia and secondary hyperparathyroidism can occur as a consequence of vitamin D deficiency due to enhanced urinary excretion of cholecalciferol-binding protein, whereas loss of thyroxine-binding globulin can result in depressed thyroxine levels. An increased susceptibility to

infection may reflect low levels of IgG that result from urinary loss and increased catabolism. In addition, the patients can expect unpredictable changes in the pharmacokinetics of therapeutic agents that are normally bound to plasma proteins.

Acute kidney injury may indicate an underlying glomerulonephritis but is more often precipitated by hypovolemia or sepsis. Hypertension with fluid retention may occur. Persistent edema may cause defective absorption and malnutrition. Ascites and pleural effusions can develop.

### **Differential diagnosis of nephrotic syndrome.**

The main pathological situations in differential diagnosis of primary nephrotic syndrome are primary kidney diseases such as minimal-change nephropathy, focal glomerulosclerosis and membranous nephropathy.

**Minimal change nephropathy** specific characteristics are:

- Common in children, particularly in male, but may occur in all age groups
- On light microscopy, there is no abnormality
- No immune deposits on immunofluorescence
- On electron microscopy, there is a fusion of podocyte foot process
- Preserved renal function, rarely renal failure can develop
- Good response to steroid and cytotoxic drugs with complete resolution and treatment in childhood

**Membranous glomerulopathy** specific characteristics are:

- It is usually idiopathic
- It is the most common cause of NS in adults, predominantly in males
- Renal vein thrombosis is a common complication
- Renal biopsy shows granular subepithelial IgG deposits, thickening of glomerular basement membrane, increased matrix deposition and glomerulosclerosis
- It is a chronic progression of the disease to renal failure
- Response to treatment with steroid and cytotoxic drugs is insufficient

**Focal segmental glomerulosclerosis** specific characteristics are:

- The origin is unknown
- On electron microscopy segmental scar in glomeruli, podocyte foot process fusion may be found
- There is C3 and IgM deposition on basement membrane of glomerulus

- It may progress to renal failure
- It is frequently resistant to steroid therapy and recurs after renal transplantation
- Massive non selective proteinuria, hematuria, hypertension and renal impairment are present.

### **Nephrotic syndrome versus nephritic syndrome**

The acute nephritic syndrome is the clinical correlate of acute glomerular inflammation. In its most dramatic form, the acute nephritic syndrome it is characterized by a sudden onset of acute renal failure and oliguria (<400 mL of urine per day). Renal blood flow and GFR fall as a result of obstruction of the glomerular capillary lumen by infiltrating inflammatory cells and proliferating resident glomerular cells. Renal blood flow and GFR are further compromised by intrarenal vasoconstriction and mesangial cell contraction that result from local imbalances of vasoconstrictors (leukotrienes, platelet-activating factor, thromboxanes, endothelins) and vasodilator substances (nitric oxide, prostacyclin) within the renal microcirculation. Extracellular fluid volume expansion, edema and hypertension develop because of impaired GFR and enhanced tubular reabsorption of salt and water not due to excessive loss of proteins by urine.

Apparently, nephritic syndrome is characterized by a loss of blood in the urine from the damaged renal epithelia, but in nephrotic syndrome, a huge loss of proteins in urine is present. The severity of proteinuria and edema is far less in the nephritic syndrome, compared to the nephrotic syndrome.

The main difference between nephritic and nephrotic syndrome is that haematuria is present in nephritic syndrome. There is also proteinuria, hypertension, encephalopathy, possibly oliguria. The two standout features are hypertension and red blood casts.

Urinary casts are cylindrical structures produced by the kidney and present in the urine in certain renal diseases. The presence of RBCs is always pathologic and strongly indicative of glomerular damage. The proteinuria is often smaller than in nephrotic syndrome, thus a coexistent condition of nephrotic syndrome is not usually present.

As mentioned above, nephritic syndrome is only a set of symptoms rather than a disease itself. The classical pathologic correlate of the nephritic syndrome is proliferative glomerulonephritis. The proliferation of glomerular cells is initially due to infiltration of the glomerular tuft by neutrophils and monocytes and subsequently to proliferation of resident glomerular endothelial and mesangial cells (endocapillary proliferation). In its most

severe form, the nephritic syndrome is associated with acute inflammation of most glomeruli, as it happens in acute diffuse proliferative glomerulonephritis. In milder forms of nephritic injury, cellular proliferation may be confined to the mesangium and provoke mesangiocapillary glomerulonephritis.

Finally, the diseases usually associated with nephritic syndrome are:

1. **Poststreptococcal glomerulonephritis:** usually occurs two weeks after upper respiratory tract infection. Postinfectious GN is the classic illustration of nephritic syndrome
2. **IgA nephropathy:** usually occurs 1-2 days after upper respiratory tract infection
3. **Rapidly progressive glomerulonephritis** also known as crescentic glomerulonephritis, characterized by rapid loss of kidney function and uremia
4. **Henoch-Schoenlein purpura**, characterized by the deposition of IgA in kidneys and a benign evolution
5. **Membranoproliferative glomerulonephritis** is also known as mesangiocapillary glomerulonephritis, and nephropathy frequently associated with Hepatitis C

These syndromes may overlap, in which case, mostly the nephrotic syndrome precedes the nephritic syndrome. It is important to mention that some pathological conditions might have symptoms that most often appear in nephritic syndrome. For example, in rapidly progressive glomerulonephritis proteinuria exceeds 3 g/day, which is usually associated with proteinuria in the nephrotic syndrome.

Different types of urinary sediment are characteristic of focal nephritic, diffuse nephritic and nephrotic syndromes:

- A mild nephritic sediment is generally associated with inflammatory lesions in less than one-half of glomeruli on light microscopy (focal glomerulonephritis). The urinalysis reveals red cells (which often have a dysmorphic appearance), red cell casts and mild proteinuria (usually less than 1.5 g/day). The findings of more advanced disease such as heavy proteinuria, edema, hypertension, and renal failure are usually absent. These patients often present with asymptomatic hematuria and proteinuria discovered on routine examination or sometimes with episodes of gross hematuria. Focal glomerulonephritis affects less than 50% of glomeruli.
- Diffuse nephritic type urinalysis (diffuse glomerulonephritis) is

Table 50

**Differential diagnosis of secondary nephrotic syndrome in some systemic diseases**

<b>Disease presentation</b>	<b>Characteristic Features</b>
<b>Liver cirrhosis</b>	<p>Pitting edema and ascites, Commonly there is no generalized edema and no gross proteinuria Gynecomastia, spider angiomas, testicular atrophy, Encephalopathy, jaundice</p>
	<p>Normal or elevated liver transaminases Thrombocytopenia Hypoalbuminemia Micro- or macronodular structure of liver, enlarged vena portae and vena lienalis on ultrasound imaging</p>
<b>Congestive heart failure</b>	<p>History of cardiovascular disease Dyspnea, orthopnea, there is no gross proteinuria Paroxysmal nocturnal dyspnea, pitting edema, pulmonary edema Enlarged tender liver and dependent edema Low ejection fraction on echocardiography Elevated brain natriuretic peptide levels in serum Elevated jugular venous pressure Engorged pulsatile neck vein, Cardiomegaly on chest X-ray</p>
<b>Malnutrition</b>	<p>Weight loss, fatigue, irritability and depression Menstrual irregularities, anemia Poor wound healing and easy bruisability Muscle atrophy and fat wasting, hypoproteinemic pitting edema Dry skin and hair loss</p>
<b>Malignancy</b>	<p>Weight loss, subfebrile fever, fatigue Pitting or non-pitting edema with serous exudation, Ascites, pleural effusion, pulmonary edema</p>
<b>Protein losing enteropathy</b>	<p>Hypoalbuminemia Watery diarrhea Abdominal pain Weight loss Hypoalbuminemia and hypoglobulinemia Stool alpha-1-antitrypsin Imaging and endoscopy findings confirming the type of enteropathy</p>

similar to focal disease, but heavy proteinuria (which may be in the nephrotic range), edema, hypertension, and renal insufficiency may be observed. Diffuse glomerulonephritis affects most or all of the glomeruli.

- Nephrotic sediment is associated with heavy proteinuria and lipiduria, but few cells or casts. It is specifically defined by the presence of heavy proteinuria (protein excretion greater than 3.5 g/24 hours), hypoalbuminemia and peripheral edema. Hyperlipidemia and thrombotic disease are also frequently observed.
- Isolated heavy proteinuria without edema or other features of the nephrotic syndrome is suggestive of a glomerulopathy (with the same etiologies as the nephrotic syndrome), but is not necessarily associated with the multiple clinical and management problems characteristic of the nephrotic syndrome. This is an important clinical distinction because heavy proteinuria in patients without edema or hypoalbuminemia is more likely to be due to secondary focal segmental glomerulosclerosis.
- Some extrarenal diseases should also be taken into consideration in the differential diagnosis of nephrotic syndrome, among them liver cirrhosis, congestive heart failure, malnutrition, malignancies and protein losing enteropathy (see Table 46).

## BIBLIOGRAPHY

1. Zacchia M., Trepiccione F., Morelli F., et al. Nephrotic syndrome: new concepts in the pathophysiology of sodium retention. *J Nephrol* 2008; 21(6): 836-842.
2. Chen T., Lv Y., Lin F., Zhu J. Acute kidney injury in adult idiopathic nephrotic syndrome. *Ren Fail* 2011; 33 (2): 144-149.
3. Schönenberger E., Ehrlich J.H., Haller H., Schiffer M. The podocyte as a direct target of immunosuppressive agents. *Nephrol Dial Transplant* 2011; 26 (1): 18-24.
4. Crew R.J., Radhakrishnan J., Appel G. Complications of the nephrotic syndrome and their treatment. *Clin Nephrol* 2004; 62 (4): 245-259.
5. Clement L.C., Macé C., Avila-Casado C., et al. Circulating angiopoietin-like 4 links proteinuria with hypertriglyceridemia in nephrotic syndrome. *Nat Med* 2014; 20 (1): 37-46.
6. Bianchi S., Bigazzi R., Caiazza A., Campese V.M. A controlled, prospective study of the effects of atorvastatin on proteinuria and progression of kidney disease. *Am J Kidney Dis* 2003; 41 (3): 565-570.

7. Davidson's Principles and practice of medicine (21<sup>st</sup>revised ed.) / by Colledge N.R., Walker B.R., and Ralston S.H., eds. – Churchill Livingstone, 2010. – 1376 p.
8. Harrison's principles of internal medicine (18<sup>th</sup>edition) / by Longo D.L., Kasper D.L., Jameson J.L. et al. (eds.). – McGraw-Hill Professional, 2012. – 4012 p.
9. [img.medscape.com/pi/iphone/medscapeapp/html/A244631-business.html](http://img.medscape.com/pi/iphone/medscapeapp/html/A244631-business.html) (accessed 10.05.18)
10. [emedicine.medscape.com/article/244631-ov](http://emedicine.medscape.com/article/244631-ov) (accessed 20.05.18).