

MANUAL
FOR HEALTH OFFICER STUDENTS

Essential Surgical Skills



**Ethiopia Public Health
Training Initiative**

**Dr. Amezene Tadesse, Dr. Mohammed Kedir, Dr. Sahilu
Wondimu, Dr. Bernard Anderson, Dr. Solomon Yerdaw, Dr. Zeki
Abdurahman, Dr. Yonas Getachew, Dr. Workeneh Agegnhu**

University of Gondar

In collaboration with the Ethiopia Public Health Training Initiative, The Carter Center,
the Ethiopia Ministry of Health, and the Ethiopia Ministry of Education

2007



Funded under USAID Cooperative Agreement No. 663-A-00-00-0358-00.

Produced in collaboration with the Ethiopia Public Health Training Initiative, The Carter Center, the Ethiopia Ministry of Health, and the Ethiopia Ministry of Education.

Important Guidelines for Printing and Photocopying

Limited permission is granted free of charge to print or photocopy all pages of this publication for educational, not-for-profit use by health care workers, students or faculty. All copies must retain all author credits and copyright notices included in the original document. Under no circumstances is it permissible to sell or distribute on a commercial basis, or to claim authorship of, copies of material reproduced from this publication.

©2007 by Awala Equar, R.N., B.Sc., M.P.H.; Azarias Assefa, M.D.; Dawit Shawel, B.Sc., M.Sc.; and Seifu Hagos, B.Sc., M.P.H.

All rights reserved. Except as expressly provided above, no part of this publication may be reproduced or transmitted in any form or by any means, electronic or mechanical, including photocopying, recording, or by any information storage and retrieval system, without written permission of the author or authors.

This material is intended for educational use only by practicing health care workers or students and faculty in a health care field.

PREFACE

Essential surgical skills are vital for the training of trainees in surgical practice. In North America it has been a corner stone of surgical training for more than a century. In Ethiopia this course started to be given as integral part of the surgical curricula of medical students not for more than 10 years. The ethical issue and effectiveness of surgical training by using real patient has raised the concept of essential surgical course. These basic surgical skills are learned and practiced on models and simulators.

It was found that trainees who didn't take this course have a problem in handling basic surgical problems. The department of surgery, University of Gondar, was involved in in-service training of health officers who have started practicing in the health centers. The trainees found this important and useful. The inclusion of this course in the health officer curriculum was the main reason which initiates the preparation of this practical manual.

In this manual we intended to highlight the practical and management skill for health officer students. The management skill was attempted to be addressed through a short theoretical introduction and case scenarios. The case scenarios are meant to elicit discussion and to revise the subject matter in that specific chapter. The practical sessions are designed for development of surgical skills. These should be conducted using models and simulators. These sessions should be student centered. The role of the instructor should be very brief and limited only to demonstration of a specific procedure.

Finally the authors would like to express their willingness to accept any comment or suggestion both from students and instructors.

ACKNOWLEDGEMENT

The authors would like to express their deepest gratitude to the Carter center/ EPHTI for its initiation, funding and coordination in the production of this manual.

We would like to thank Dr. Tizazu Tefera from Hawwasa University, Dr Maru Mesfin from Jimma University, Dr. Amir Zeidan from Hiwot Fana hospital, Harar and Dr Birhanu Kottiso from AAU-MF for the interest and devotion in revising the manual and their valuable comment.

We would like to acknowledge the Dean's office, College of Medicine and Health Science, University of Gondar. Our special thank will go to W/t Senait Fentahun for her secretarial work.




TABLE OF CONTENTS

Preface	i
Acknowledgement ii	ii
Table of Contents	iii
Chapter 1: Fundamentals of surgical practice	1
• Wounds –classification, management & complications	2
• Different types of suturing materials, needles & instruments	6
• 1.3 Technique in skin closure	12
• 1.4 knots & tying techniques	15
Chapter 2: Anesthesia & basic life support	20
• Local anesthesia	20
• Spinal anesthesia	23
• General anesthesia	27
• Tracheal intubation	29
• Cardiopulmonary resuscitation (CPR).....	36
• Venous cut down	39
Chapter3: Thoracic trauma & other chest emergencies	45
○ Chest injuries	45
○ chest tube (tube thoracostomy)	48
○ Tracheostomy	52
Chapter 4: Acute abdomen (abdominal emergencies)	60
○ acute abdomen	60
○ Laparatomy	63
○ Repair of small bowel perforation	68
○ Resection & anastomosis of small bowel	70

○ Colostomy	75
○ Drainage of perianal abscess	78
Chapter 5: Urologic emergencies	79
○ Urinary retentions	80
○ Urethral catheterizations	81
○ Open cystostomy	86
○ Circumcision	91
○ Paraphimosis	95
Chapter 6: Obstetric emergencies	98
○ Obstructed labour.....	98
○ Forceps	101
○ Vacuum extractor (Ventous)	106
○ Cesarean section	110
Chapter 7: Orthopedic emergencies	114
Part I Fractures	114
○ Classification, clinical feature & management	114
○ Common specific fractures and dislocations	115
○ X-ray readings	122
○ Bandage immobilization of the upper arm	123
○ Plaster of Paris application	123
○ Skeletal and skin traction	125
Part II Amputations	126
○ Causes, types & indications of amputations	126
○ Techniques & post operative care	133
○ Compartment syndrome	134

○ Fasciotomy - Techniques & indications135



CHAPTER ONE

FUNDAMENTALS OF SURGICAL PRACTICE

Learning objectives

At the end of the practical session each student should be able to do:

- ▶ Instrumental tie
- ▶ One handed knot
- ▶ Two handed knot
- ▶ Different types of sutures (simple sutures, intradermal, horizontal mattress, vertical mattress) on sheep's or goat's leg

Patient First

The first fundamental of surgical practice is the understanding that the best interest of the patient comes first. The Health Officer as care giver and often team leader should aim to give, or arrange for the delivery of care that he or she would want for himself or her family. This includes:

- Being available when the patient needs care
- Delivery of services in a safe, clean, calm and private place
- Full disclosure to the patient and family of the aims of treatment and the risks of both treatment and diseases.
- The willingness to seek help or refer when time and conditions permit and when the best interest of the patient would be better served.
- The willingness to be flexible and creative within the available resources while being a determined advocate for the materials and personnel needed to optimize the delivery of care.

The team

Respect for the team is the second fundamental. As team leader this includes:

- Leading by example. Do your own job well and conduct yourself in a good and exemplary manner.

Essential Surgical Skills

- The fostering of a courteous, respectful, harmonious work environment that recognize the contribution of each member.
- The willingness to “pitch in” and “help out” when the situation demands.

1.1 wounds

Classification

According to risk for bacterial contamination and potential for infection:

- a. Clean wounds: traumatic, non-infected wound no break in sterility technique, as occurring during elective hernia repair.
 - Risk of bacterial contamination is low
 - Antibiotics not needed usually
 - Incidence of infection should be less than 1.5%
- b. Clean-contaminated wounds: minor break in sterility technique, the oropharynx, respiratory, gastrointestinal and genitourinary tract entered as occurring during elective cholecystectomy, colon resection and appendectomy for early appendicitis.
 - Risk of contamination by bacteria, but in so small a number that risk of infection remains low (<3%)
 - Prophylactic antibiotic usage is useful in these cases.
- c. Contaminated wounds: Wounds in which there is a break in technique or gross spillage of bile or enteric contents during elective surgery and nearly all traumatic wounds as these occur in uncontrolled environments
 - Risk of infection increased to 5% or more
 - Empiric antibiotic therapy indicated
 - Consider leaving these wounds open initially for about 5 days during which time the resistance to infection increases
- d. Dirty wounds: wounds which are known to be heavily contaminated with bacteria such as abscess drainage wounds, gun shot wounds, accidental wounds in septic environments.

Essential Surgical Skills

- Risk of infection is high if closed initially
- Leave these wounds open initially
- Antibiotic usage expected adjunctively to debridement and open wound care

Evaluation of Traumatic wounds

History:

When did the wound occur? The longer the interval, the higher the likelihood that bacteria contaminating the wound.

- For this reason consider leaving wounds older than 6 hours old initially open and consider adjunctive antibiotics

Where did the wound occur? In a heavily contaminated or dirty environment or not?

- Initial inoculum or bacterial virulence may be high. In these instances open initial wound care and antibiotics may be considered.

Physical examination:

Certain wound types have unique implications.

Lacerations (wounds whose depths can be easily examined, cleaned and debrided)

- Favors primary closure

Puncture wounds: - (depths can not easily be examined, cleaned and debrided)

- Do not close these wounds immediately
- Consider extending the wound to facilitate cleaning and checking for extension to a body cavity

Crushing wounds: - (imply impaired blood supply and venous and lymphatic drainage)

- Often seen in context of blunt force trauma
- Impaired circulation and normal inflammatory response predispose these wounds to infection
- Dress these wounds without initial closure until the reexamined wound becomes fit.

Gunshot wounds and blast injuries: - have characteristics of both puncture and crushing wounds with the same treatment implications.

Management:

- Patients should be supine while being attended to protect them from injury from fainting.
- Scrub, glove and gown yourself appropriately
- Wash the skin around the wound with soap and water copiously when necessarily.
- Apply an antiseptic solution (iodine, alcohol, chlorhexidine) over a wide area around the wound
- Apply sterile drapes to cover the operative field.
- Anesthetize the wound (and sometimes the patient)
- Debride dead tissue and foreign body and clean the wound further with normal saline (sterile)
- Obtain hemostasis and close the wound according to the prior discussed principles by- **Primary intention** (immediate closure of wound by suturing).
 - **Second intention** (leaving the wound open to heal by epithelialization and contraction).
 - **Or Delayed Primary** intention (dress the wound without closure for about 5 days then close it by sutures after it has become clean)
- Dress the wound with sterile bulky absorptive gauze with attention to need for immobilization, elevation, antibiotics, immunization and tetanus prophylaxis.
- Close follow of patient (within days to a week) to check for complications.
- Don't close human or animal bite primarily

Complications

1. Infection- suspect if wound becomes swollen, painful, tender, drains pus or if there are systemic signs of sepsis (tachycardia, tachypnea, elevated temperature and mental disorientation). If present:

Essential Surgical Skills

- Remove sutures.
 - open the wound
 - clean and pack the wound
 - adjunctive antibiotics and
 - Systemic support as needed.
2. Hematoma- often after an early post operative complication. Marked by swelling and pain in of the wound.
- Minimize by exacting hemostasis.
 - Treat if significant by reopening the wound under sterile conditions to evacuate the collection and to obtain hemostasis
 - The wound can usually be closed again
3. Seroma-caused by “dead space” in a wound
- Minimize by approximating subcutaneous tissues during wound closure. If they do not come together naturally, with absorbable sutures. If not feasible, consider using a drain (preferably an active closed drain).
 - Treat by aspiration with a sterile needle and syringe (may have to be repeated).
4. Dehiscence- separation of wound after removal of sutures or after suture failure.
- Minimize by leaving sutures in longer at sites of known increased risk for wound separation. These sutures may need to stay in for 2 weeks; use of long acting or permanent sutures in the dermis and in collagenous tissues like deep fascia and tendons.

1.2. Different types of suturing material, needles and instruments

Sutures

Can be classified as

- a. Absorbable (degraded and absorbed in the body over time)
 - Does not stay in the body decreasing the risk for infection
 - May lose strength before the wound has healed
 - Causes a greater local tissue reaction than permanent suture material
- b. Non absorbable (not degraded by the body over time).
 - Useful for epithelial skin closure.
 - Useful for repair of hernias and tendons

Either may be braided (easy to tie and greater knot security but with more interstices for bacteria to hide causing increased risk for wound infection) or monofilament.

In general:

- Also either absorbable or non absorbable sutures may be of natural or synthetic derivation.
- Select the “right” suture for the job at hand
- Use the finest size to achieve security of the wound
- Use the minimal amount of sutures to do the job

Essential Surgical Skills

Some common sutures, their characteristics and uses are summarized below.

Suture	Time for absorption	Clinical uses
Absorbable		
Plain cat gut	1-2 weeks	Subcutaneous fat closure, small vessel ligation
Chromic cat gut	2-3 weeks	Subcutaneous intradermal suturing and ligation
Vicryl (braided)	2-3 months	Intradermal suturing gut anastomosis
PDS (monofilament)	6 months	Same as vicryl used in potentially infected field
Non absorbable		
Silk (braided)	Permanent	Skin closure, gut anastomosis + hernia repair + tendon repair
Prolene (monofilament)	Permanent	Vascular anastomosis + hernia repair

Needles:

- Straight or curved.
- Eyed-opening for playing suture at one end.
- Swaged- suture fixed to needle at one end.
- Cutting-sharp point for going through tough tissues like skin easily.
- Tapered-smooth point causing minimal tissue injury. Useful for delicate tissue like blood vessels and gut anastomosis.
- Different sizes for different applications.

Instruments:

Essential Surgical Skills

1. Needle holder (driver) (Fig. 1:5)

- Use the shortest holder to reach the work
- Hold needle 2/3 in front 1/3 behind in body *b)
- Hold needle with tip of needle holder (c)
- Just enough of the thumb and 4th finger in the rings of the handle (fig 1:1)
- Index finger on front of holder to stabilize the drive (e)
- Strike perpendicularly and follow the curve of the needle through the tissue (supination) for best control.

2. Hemostat (artery forceps) (Fig. 1:1 &1:5)

- Thumb and 4th finger is rings of handle.
- Index finger in front of instrument.
- Grasp the smallest amount of tissue to stop bleeding.

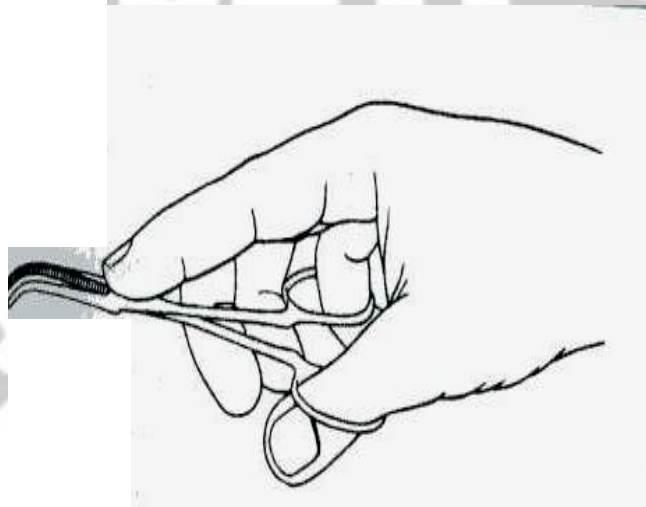


Figure 1:1

3. Tissue Forceps (pick ups) (Fig. 1:2 &1:5)

Essential Surgical Skills

- Toothed-for secure grasping of tissue. When used on the skin, hold the dermis if possible to avoid injury to the epidermis
- Non toothed –useful for grasping needles
- “Pick up on what you want, where you want it and you will get it right.

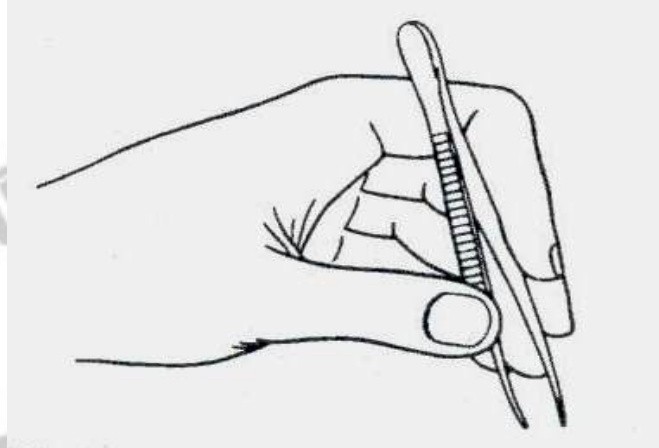

Figure 1:2

4. Scissors (Fig. 1:3&1:5)

- Tissue (dissecting scissors)- used to separate and cut tissue
- Suture scissors- used to cut suture
- Cut with the tip of the scissors to avoid inadvertent cutting of “some thing else with the tip”.
- Dissect with tip up so as to see well the tissue being dissected.



Figure 1:3

5. Scalpel (Fig. 1:4&1:5)

- Hold like a pen with thumb and 3rd finger and steady and apply pressure with second finger.
- Sharpest point is the bevel or “belly” of the blade. Cut with it!
- 15 blade for delicate work (smaller)
- 10 blade-larger blade

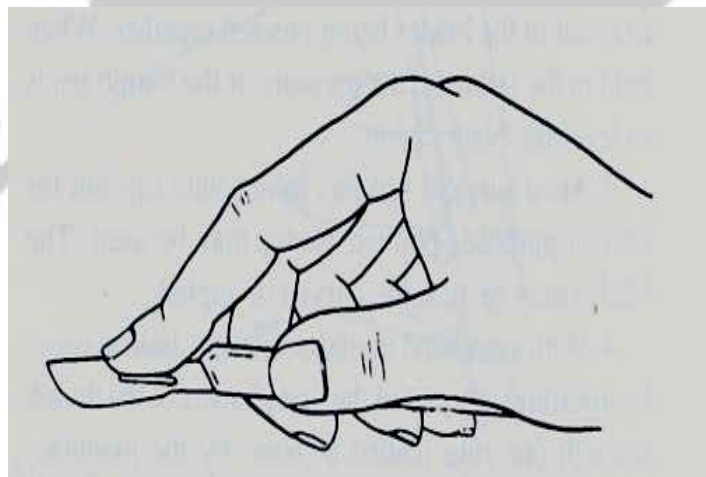


Figure 1:4

6. Retractor

Essential Surgical Skills

- Facilitates exposure by traction and counter traction
- Apply just enough pressure to give clear exposure. More than needed pressure causes injury.

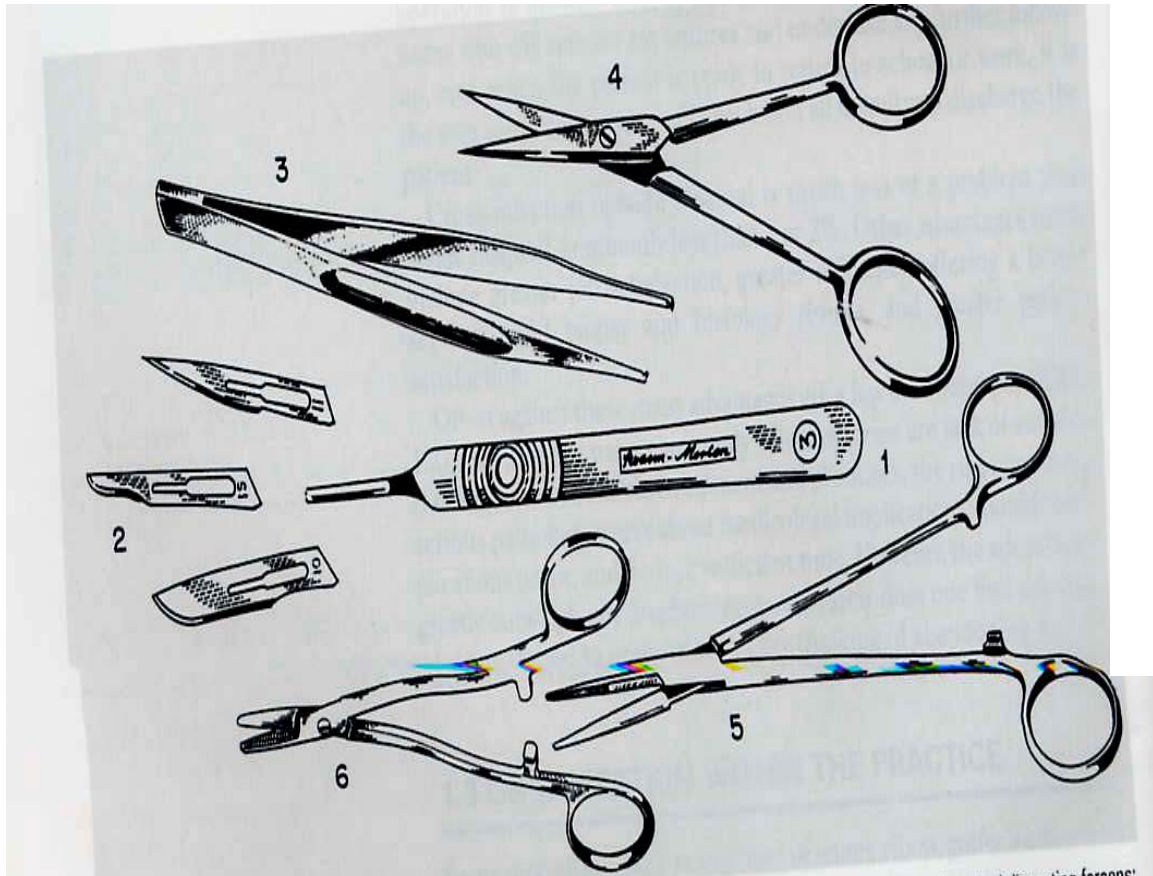

Figure 1:5(1- blade holder, 2-different sized blades, 3-tissue forceps, 4-scissors, 5-straight artery forceps, 6-needle holder)

1.3 Techniques in skin closure

Simple interrupted:

- Most commonly used technique
- Volume of tissue included in the stitch on either side of the wound should be the same to prevent over riding of skin edges
- Distance across base of dermis should be longer than distance in loop across epidermis
- Tighten with just enough tension to appose the wound.

Simple continuous (baseball stitch)

- Rapid wound closure technique
- Less cosmetic result than with simple suturing

Vertical mattress (1:6)

- Provides for exacting apposition of wound edges and the different layers of the skin

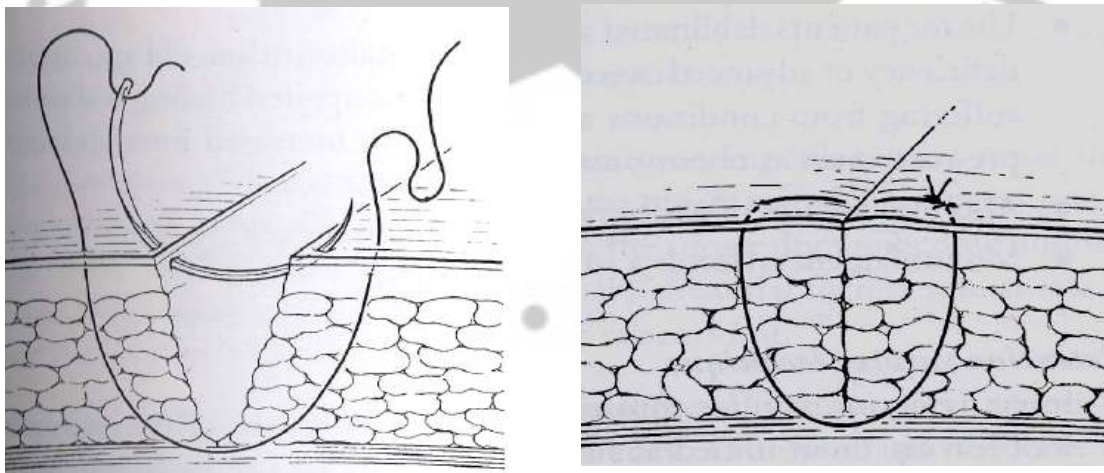


Figure 1;6

Horizontal mattress (fig1:7)

- Convenient to level the epithelium when closure results in parts of the wound in which the skin on one side rides over the skin on the other side
- Don't tie too tightly as technique tends to be ischemic

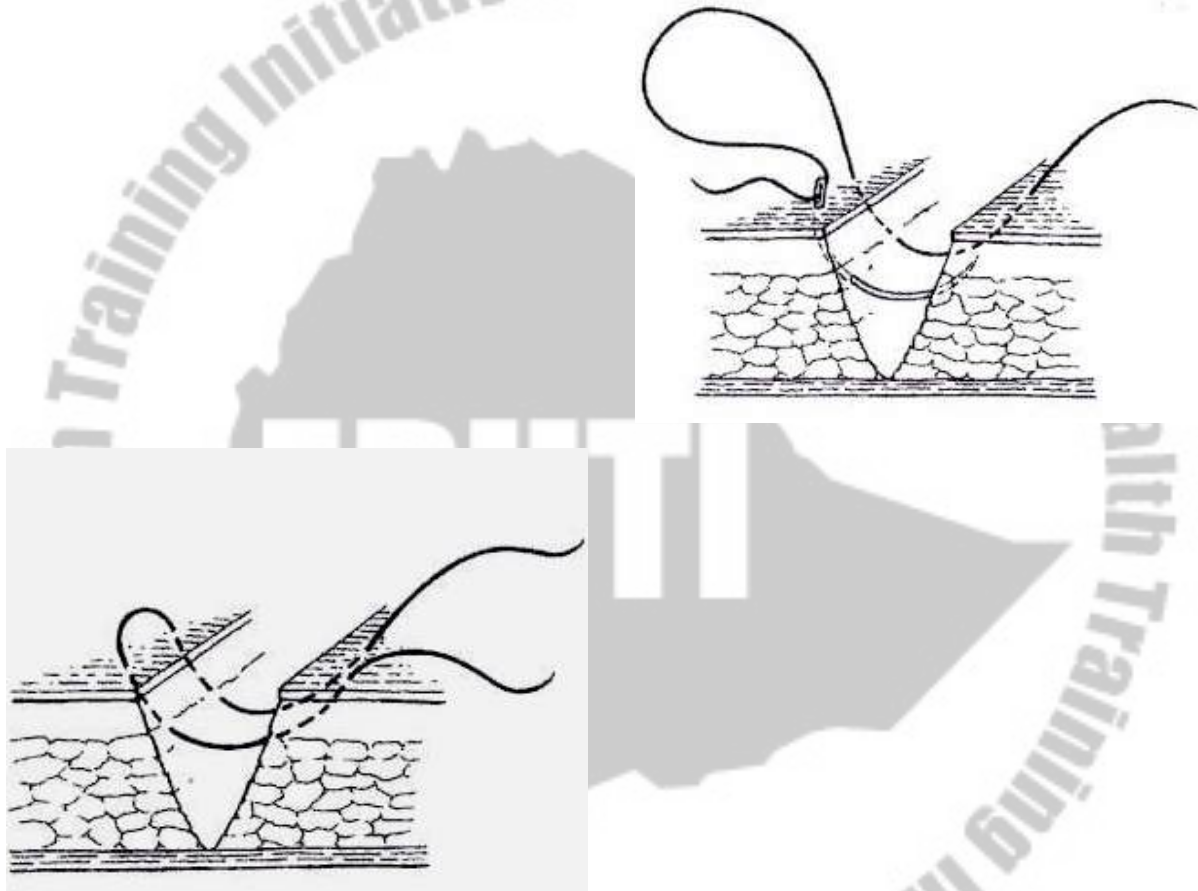


Figure 1:7

Intradermal suturing (subcuticular) (1:8)

- Excellent apposition of dermis and epidermis
- Interrupted or continuous in the dermis
- Highly cosmetic
- Use long lasting absorbable suture (vicryl/or PDS) if suture is to be left in.

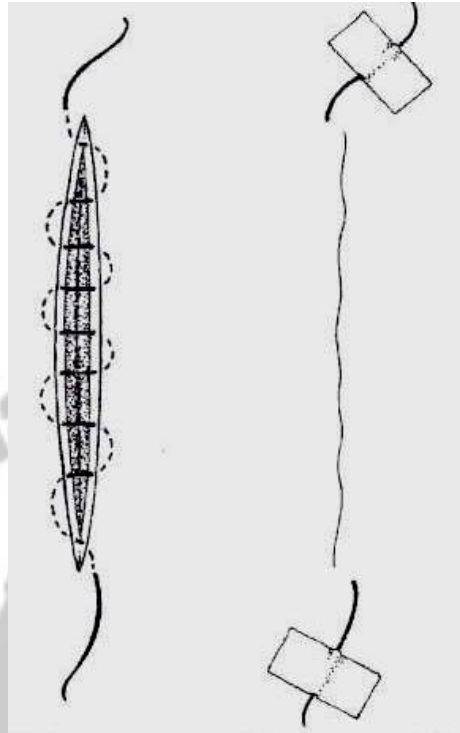


Figure 1:8

Case scenario

A 25 year old farmer accidentally stuck himself with a fork while cleaning the pen of his cattle. He washed his foot right away with soap and water and came to the hospital within 2 hours.

- (1) What kind of wound is this according to risk category for infection?
- (2) Select the best answer from the choices below for treatment.
 - A) Clean the foot and leg with soap+ water, apply an antiseptic- like iodine to the skin, wash the wound with saline and debride any foreign body and close the wound with monofilament nylon
 - B) Leave the wound open after cleaning the skin with soap and water, applying an antiseptic, irrigate and debride, sterile dressing, tetanus immunization P.O. antibiotics and follow up in OPD within one week.
 - C) Admit him to the hospital for IV antibiotics and wound care.

1.4 Knots & tying techniques

A) Instrument tie (fig 1:9)

Step 1. Place needle holder on top of suture

Step 2. Wrap suture around the end of the needle holder once for Square knot and twice for a surgeons knot

Step 3. Grasp end of suture with needle holder and pull this end flat through the loop with hands crossed. Congratulations! You have completed the first throw. Now release the end of the Suture.

Step 4. Now again place the needle holder on top of the suture on the other side.

Step 5. Wrap the suture once completely around the end of the needle holder.

Step 6. Now grasp the end of the suture and pull it through the loop. You have now completed either a square knot or a surgeon's knot. repeat 3 or 4 throws for added security then cut the suture above the knot.

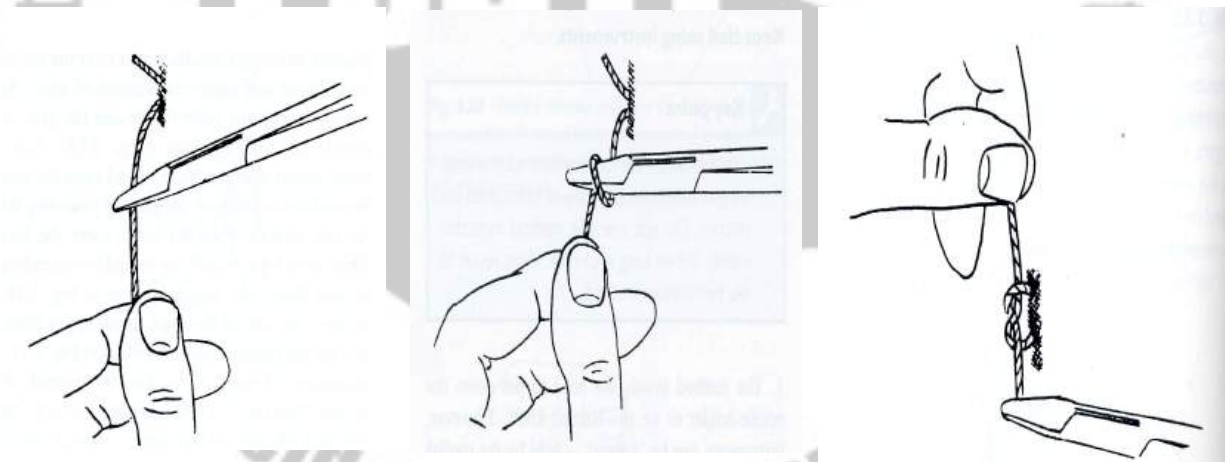


Figure 1:9

B) One hand tie (fig 1:10)

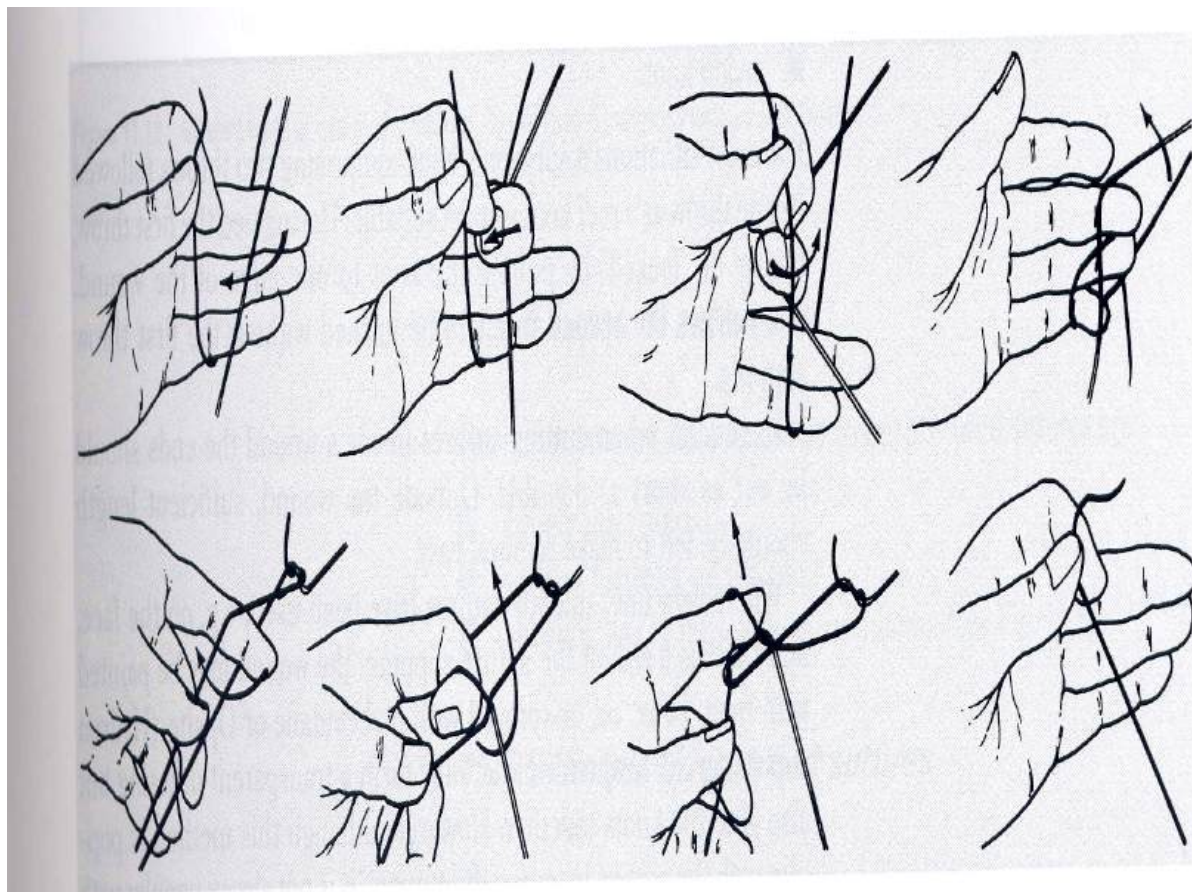


Figure 1:10

C) Two hand tie: (fig1:11) the line drawings of this technique tend to be confusing

- A narrative and line drawings of the steps are detailed below
- The technique will be further demonstrated by your instructor
- With practice it will become effortless and second nature

Step 1. Hold the needle end of the suture in the palm of the left hand draped over the left index finger. At the same time hold the end of the suture with the right hand and place it on top of the left thumb.

Essential Surgical Skills

Step 2. Appose the thumb and index fingers of the left hand and pass the thumb of the left hand through the loop of suture.

Step 3. Now pass the suture held in the right hand between the thumb and index finger of the left hand and pass it through the loop

Step 4. Now grasp the suture with the right hand, cross your hands and pull the knot down flat to complete the first throw.

Step 5. With the hands crossed wrap the suture held in the left hand around the left thumb and bring the suture held in the right hand on top of it.

Step 6. Now appose the left index finger and thumb and bring the left index finger through the loop to grasp the end of the suture.

Step 7. With the end of the suture now between the thumb and index finger of the left hand, pass it back through the loop.

Step 8. Now grasp the end of the suture with the right hand and complete the second throw of the two hand tie by pulling both sides of the suture.

Repeat 3 or 4 times for added security. Cut the suture above the Knot

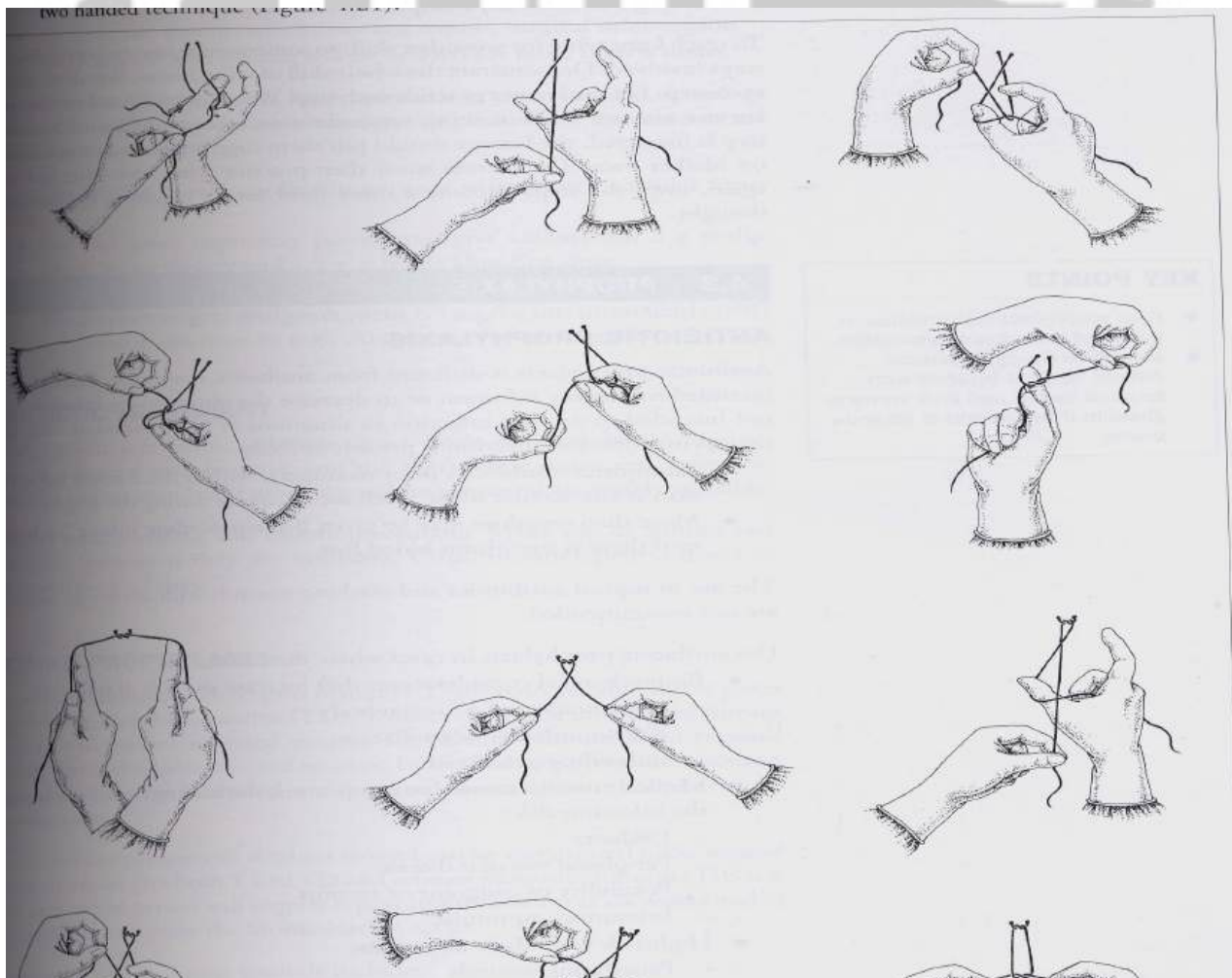
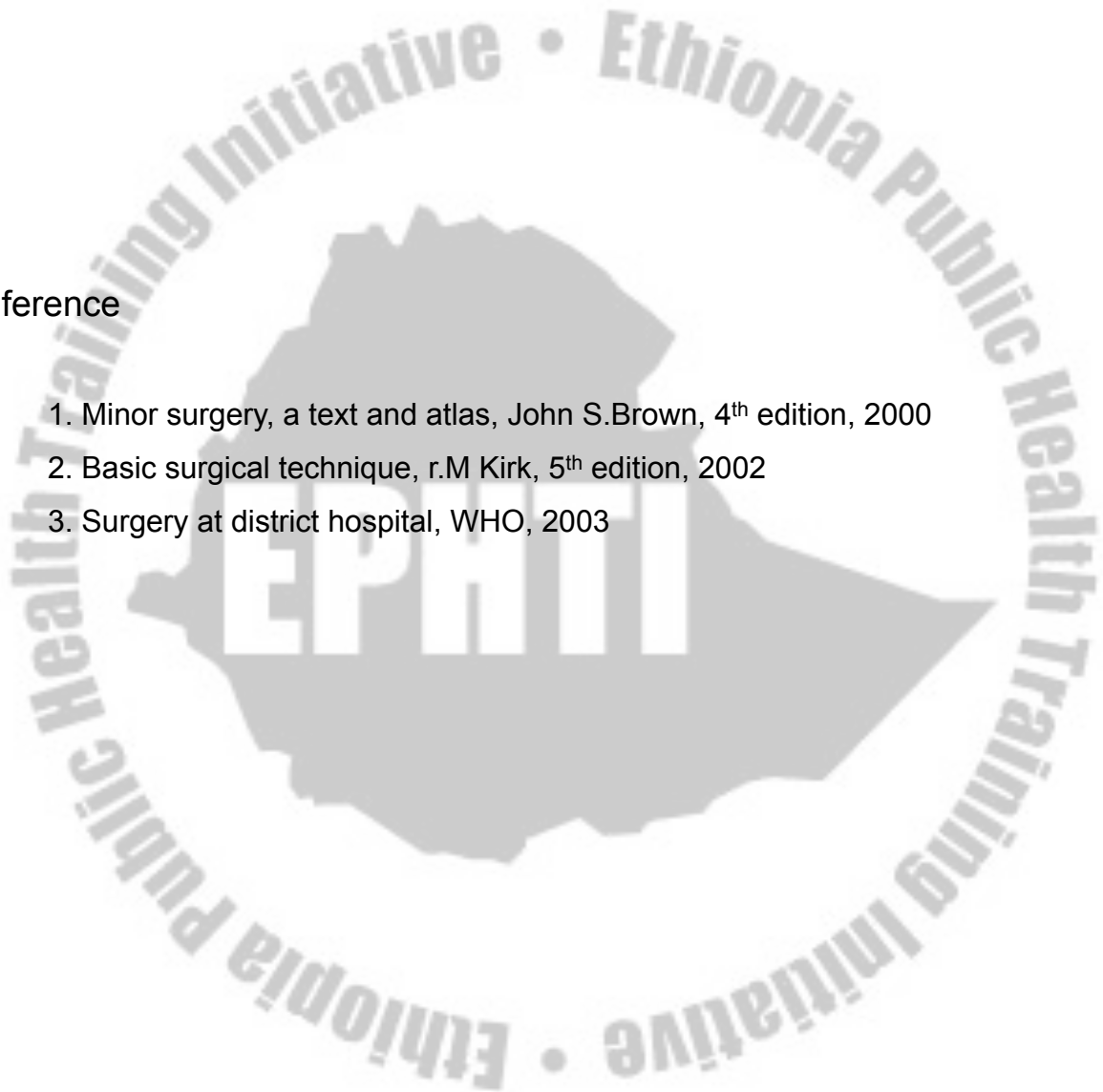

Figure 1:11

Reference

1. Minor surgery, a text and atlas, John S.Brown, 4th edition, 2000
2. Basic surgical technique, r.M Kirk, 5th edition, 2002
3. Surgery at district hospital, WHO, 2003





CHAPTER TWO

ANESTHESIA AND BASIC LIFE SUPPORT

Learning objectives

At the end of the practical session the student should be able to:

- ▶ Know the different types of anesthesia
- ▶ To intubate the trachea (using a manikin model)
- ▶ One person and two persons CPR on a manikin
- ▶ Locate greater saphenous vein cut down site and do cut down on lower leg simulator (made from sugarcane or bamboo as leg and IV line as a vein)

Local Anesthesia

There is localized loss of pain feeling and consciousness remains intact.

Local anesthetics

Drugs which produce reversible block to the transmission of peripheral nerve impulse.

Classification

Categories of local anesthesia:-

1. **Topical anesthesia** – Local anesthetic agents are applied topically to such diverse sites as skin, eye, gingival mucosa, tympanic membrane, tracheobronchial tree, and rectum.

Forms of topical anesthetic preparation include

- ointment
- spray
- solution
- suppository

Example of topical preparations of lidocaine

- 4% aqueous solutions for endotracheal installations
- 2% Jelly for intra urethral use
- 10% aerosol for anesthesia of gingival mucosa

2. Infiltration anesthesia

- produced by intra dermal and subcutaneous injection of local anesthetics in the area of the intended surgery.
- Primarily useful for minor superficial procedures
- Dosage of local anesthetic required for adequate infiltration depends on the extent of the area to be anesthetized and the expected duration of the surgical procedures .

Upper dose limits for commonly used local anesthetics agents

	Plain solution	with adrenaline
	<u>mg /kg</u>	<u>mg/ kg</u>
- prilocaine	6	9
- lidocaine	3	7
- bupivacaine	2	2

N: B 1 % local anesthesia is 1 gm /100ml

- Addition of adrenaline reduces the peak concentration in blood.

- Any local anesthetic can be employed for infiltrative anesthesia.

3. Peripheral nerve block

Local anesthetic agent is injected through a needle which is passed percutaneously in the area of the nerve to be blocked.

It can be divided arbitrarily into

a) Minor nerve block

- involves the blockade of single nerve example digital nerve block

PRACTICAL SESSION I

Digital nerve block

What to do:

- Cleanse the finger and paint the area with povidone- iodine (Betadine) solution.
- Using a 27 gauge needle, slowly inject 1% lidocaine midway between the dorsal and palmar surfaces of the finger at the midpoint of the middle phalanx.
- Inject straight in along the side of the periosteum. Then pull back without removing the needle from the skin and fan the needle dorsally.
- Advance the needle dorsally and inject again. Pull the needle back a second time and, without removing it from the skin, fan the needle in a palmar direction.
- Advance the needle and inject the lidocaine in the vicinity of the digital neurovascular bundle.
- With each injection, instill enough lidocaine to produce visible soft tissue swelling.
- Repeat this procedure on the opposite side of the finger.
- For anesthesia of the proximal phalanx as well, a similar block may be performed as far proximally as the middle of the metacarpal. There, the connective tissue is looser, and the needle need not be fanned into digital septae as described above. Be prepared to wait three to ten minutes for adequate anesthesia.

Essential Surgical Skills

- With painful crush injuries or when the pain will be prolonged, substitute bupivacaine for lidocaine.

What not to do:

- Do not use lidocaine with epinephrine. The digital arteries are end arteries that can spasm and provide prolonged anesthesia, ischemia of the fingertip, and potentially, necrosis.

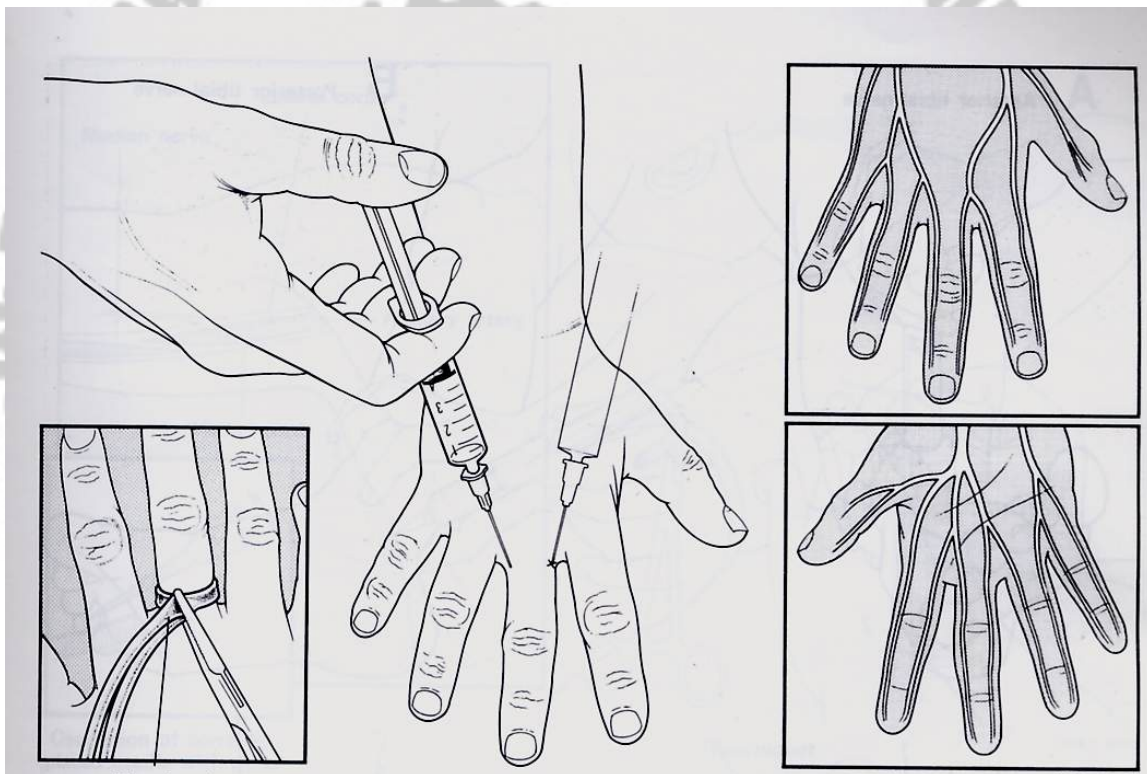


Figure 2:1 digital nerve block

b) Major nerve block

-involve blockade of major trunks or plexus such as brachial plexus blockade.

4. Central neural blockade

Essential Surgical Skills

The local anesthetic agents interrupt the conduction of nerve impulse near the site where the nerve roots enter and leave the spinal cord.

It includes spinal and epidural anesthesia

Spinal Anesthesia

Indications

- For operations below the umbilicus
- For operations on the perineum or genitalia
- For operations on the legs

Contraindications

- Hypovolemia
- Increased intracranial pressure
- Coagulopathy
- Infection at the puncture site
- Sepsis (increased risk of meningitis)
- Patient refusal (absolute contra indication)
- Pre-existing neurologic disease

Technique- the important points when spinal block is performed are:

1. IV administration of 500 ml to 1000 ml crystalloid solutions before performing the block
2. Position of patient-can be lateral decubitus, sitting or prone
3. It should be done under absolute sterile condition
 - Clean patients back with the swabs and antiseptics
4. Locate sites of needle insertion
 - Safe sites of needle insertion are L₂-L₃, L₃-L₄, L₄-L₅, lumbar interspaces
 - Iliac crests are used as a land mark to identify these interspaces
 - The line drawn between the iliac crests crosses L₃-L₄ interspaces
5. Direction of needle insertion

Essential Surgical Skills

Spinal needle can be inserted at a direction perpendicular to the saggital plane in the midline.

6. The needle is advanced until CSF is obtained
 - Spinal meninges are typically at the depth of 4-6 cm,.



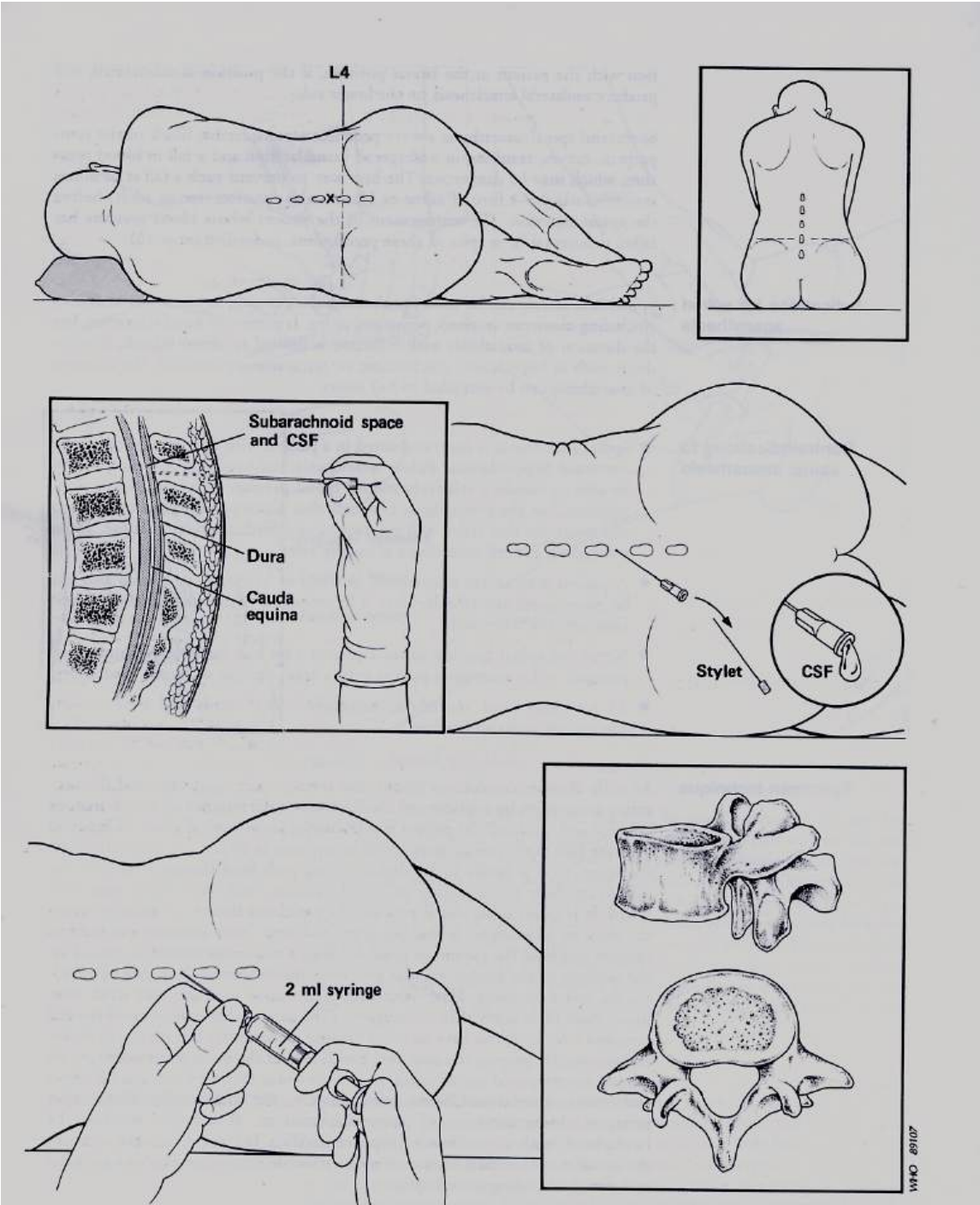


Figure 2:2 spinal anesthesia

Epinephrine

Epinephrine is added to local anesthetic solutions because it markedly prolongs the duration of anesthesia. Epinephrine is added to local anesthetic solutions in a dose of 5ug /ml (1:200,000)

Contraindication to the inclusion of epinephrine in local anesthetic solutions.

- Cardiac disease such as IHD, cardiac dysrhythmias.
- hypertension
- Peripheral nerve blocks in the areas that may lack collateral blood flow for example, ear lobe, penis, fingers and toes.

Toxicity of local anesthetic agents

- Systemic toxicity usually results from an accidental intravascular injection or administration of excessive dose of local anesthetic agents.
- Systemic reactions to local anesthetics involve CNS and CVS.
- Initial symptoms of CNS toxicity involve feeling of light-headedness, dizziness, and circumoral paraesthesia, difficulty of focusing and tinnitus. Objective signs include shivering, muscular twitching, tremors and generalized convulsions.
- If sufficiently large dose is given the initial signs of excitation may progress to generalized CNS depression and coma; respiratory depression may occur resulting in respiratory arrest.
- CVS toxicity usually occurs at dose and blood concentration higher than those required to produce CNS toxicity. Local anesthetic agents can exert direct effect on the heart and peripheral blood vessels resulting in cardiac dysrhythmias and hypotension.

Management of toxicity

1. Air way maintenance, administration of O₂ by face mask, prevention of aspiration by turning the patient to the side and lower the head.
2. Artificial breathing if apnea occurs.
3. Circulation
 - Check pulse, CPR if cardiac arrest occurs.

Essential Surgical Skills

- Start monitors - ECG
 - BP
 - Pulseoximetry
- 4. Control convulsion
 - Diazepam (10-20mg IV)
 - Thiopental (150-250mg IV)
- 5. Profound hypotension and bradycardia should be treated with
 - Atropine (0.5 -1mg IV)
 - Colloid or crystalloid infusion
 - IV ephedrine or adrenaline may be required for sever hypotension or bradycardia

General Anesthesia

There is depression of CNS resulting into generalized loss of responses to and perception of all external stimuli.

Four basic elements of general anesthesia are

- Analgesia
- Loss of consciousness
- Immobility
- Inhibition of noxious reflexes

Routes of administration of general anesthetic drugs

- A. Inhalation - Access to the circulation through the lungs
 - For example - Nitrous oxide
 - Halothane
 - Enflurane
 - Isoflurane

Methods of administration

- Face mask
- Endotracheal tube
- Insufflations- anesthetic agent and oxygen delivered into the mouth or trachea

Essential Surgical Skills

B. Parenteral

	<u>Dosage</u>
I. Intravenously - Thiopental	3-6 mg/kg
- Propofol	1.5-2.5 mg/kg
- Etomidate	0.2-0.3 mg/kg
- Ketamine	1-2 mg/kg
	<u>Dosage</u>
II. Intra muscular - Ketamine	5-10 mg/kg

Ketamine anesthesia

Ketamine produces a state of “Dissociative anesthesia” which implies that the patients are detached from their surroundings.

It produces systemic effects that are characteristics of sympathetic nervous system stimulation.

The more commonly observed hemodynamic effects include increased heart rate, blood pressure & cardiac output.

Ketamine also increases intracranial pressure. The effects of sympathetic stimulation from ketamine anesthesia may be useful in patients with bronchospastic disease or hypovolemia.

Ketamine can also be given IM, producing effects in two or four minutes. Administration via IM route may be useful in children who are unlikely to tolerate separation from parents or alternative method of inducing anesthesia.

Ketamine may be used as a sole anesthetic agent for a large number of superficial operations & procedures in both adults & children.

As ketamine increases salivation it is best to give atropine at a dose of 10 to 20 mg/kg IM before ketamine (can be given IV at the time of ketamine administration)

Essential Surgical Skills

Guide to ketamine anesthesia

i. IM administration

Induction	5-10 mg/kg
Maintenance	3-5 mg/kg IM

ii. IV administration

Induction	1-2 mg/kg
Maintenance Iv boluses	0.5 mg/kg

Tracheal Intubation

Indications for tracheal intubation are principally

- 1) To administer inhalation general anesthesia
- 2) To provide a patent airway
- 3) Protect the lungs from aspiration

There are preliminary preparations that must be completed prior to tracheal Intubation

1. The following air way equipments must be available

a) Endotracheal tubes

Endotracheal tubes are calibrated by internal diameter. The size range for adult men is between 7.5mm and 9mm internal diameter. The size range for adult women is between 6.5mm and 8mm internal diameter.

The following sizes are used for children

<u>Age</u>	<u>size(mm internal diameter)</u>
Premature	2.5-3.0
Neonate to 6 month	3.0-3.5
6 months-1year	3.5-4.0
1-2 years	4.0-4.5
> 2 years	4.5-5.0

Use the formula $4 + \text{age}/4$

b) Laryngoscope

Laryngoscope has two components;

The handle, which houses the batteries and the blade, is designed to displace the tongue and epiglottis during intubation. The light source is usually on the blade.

Blade sizes

Adult men	4
Adult women	3
Children	2
Infant	1
Neonate	0

c) Various aids to tracheal intubation

- Stylet
- Syringe
- Securing tape or bandage
- Tracheal tube lubricant
- Face mask
- Oral airway
- Suction catheter

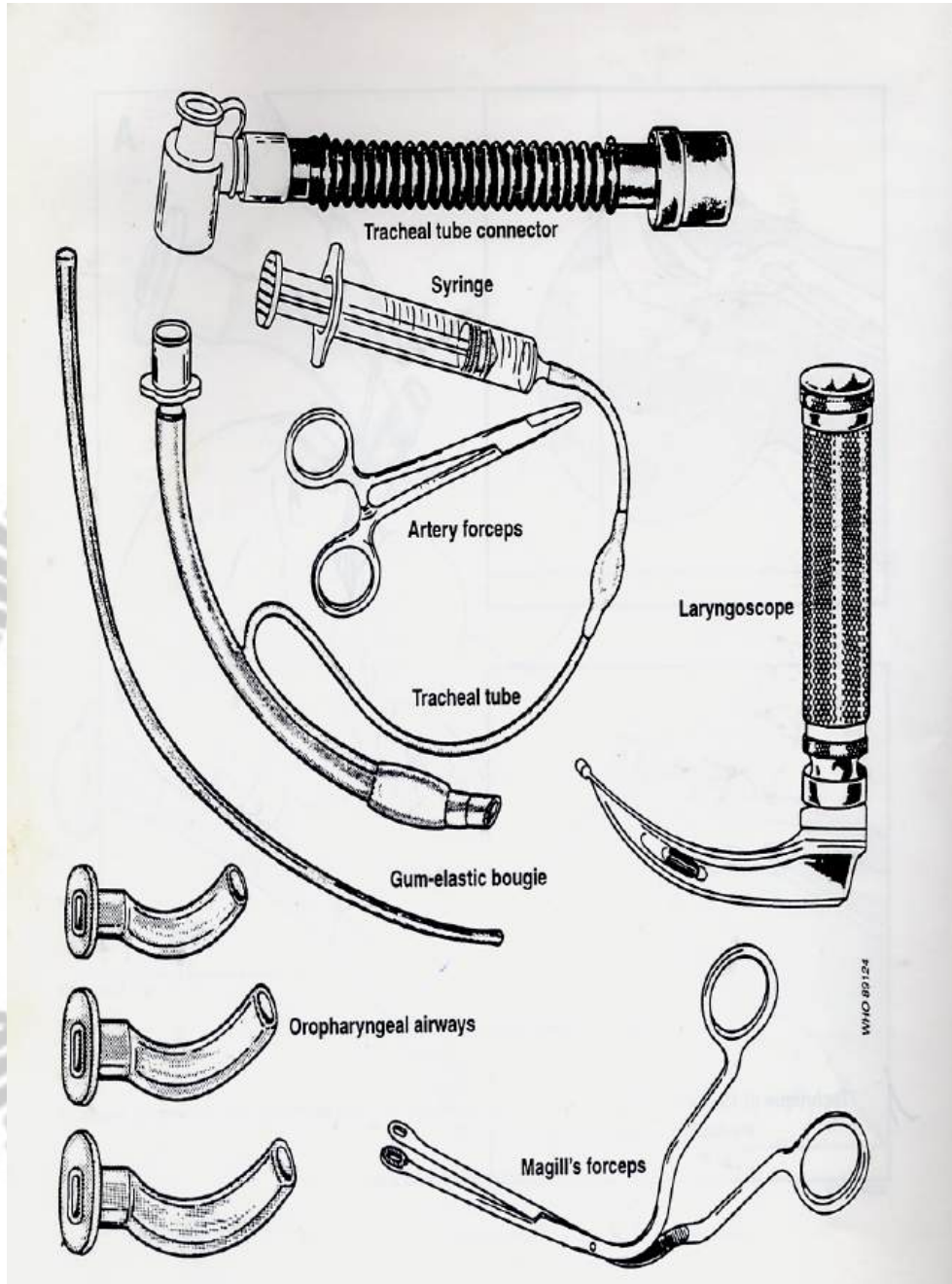


Figure 2:3 airway equipments

2) pre oxygenation

Hundred percent oxygen for 3 to 5 minutes should be administered by mask ventilation immediately prior to laryngoscopy. The inspired atmospheric air within the lung mainly contains nitrogen which should be washed out and substituted by O_2 . (figure 2:4)

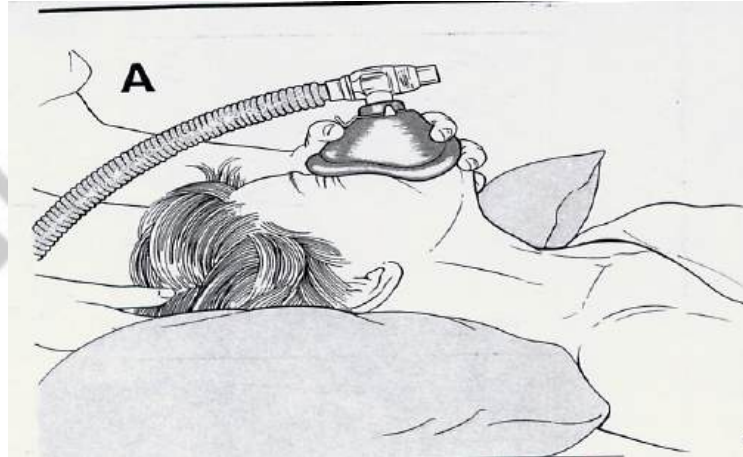


Figure 2:4 preoxygenation

3) Sedatives and muscle relaxants

Intubation in conscious patient is usually performed after sedation has been done. This is to make intubation less noxious and more tolerable.

Muscle relaxants should also be given in order to paralyze the patient

Practical session II (Endotracheal intubation)

Technique

Oro tracheal intubation is the most commonly practiced method. Exposure of the laryngeal inlet by means of direct laryngoscope is performed to facilitate translaryngeal placement of endotracheal tube.

Take the laryngoscope with your left hand (see figure 2:5)

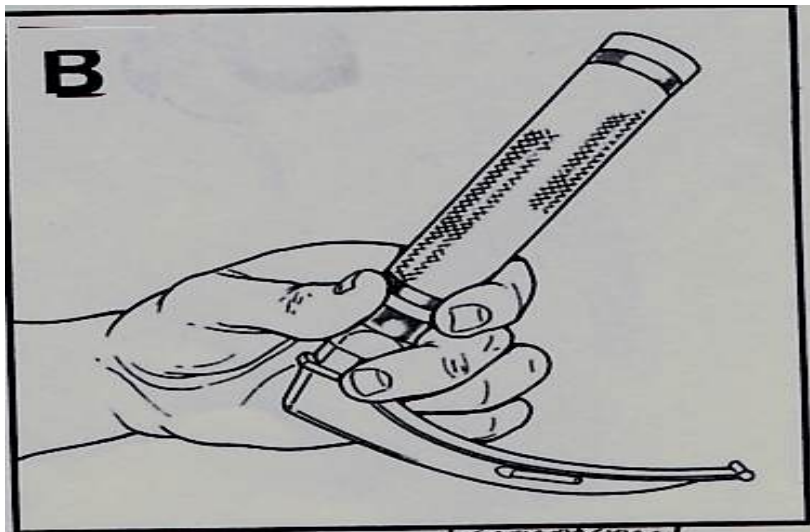


Figure 2:5 laryngoscope with left hand

An optimal alignment of the operator's visual axis and patient's laryngeal axis is desirable for optimal visualization of the glottis opening by direct laryngoscope.

An optimal position of the head and the neck for an alignment of these axes can be achieved by flexion of the neck and extension of the head at the atlanto occipital joint (Sniff position). (See figure 2:6)

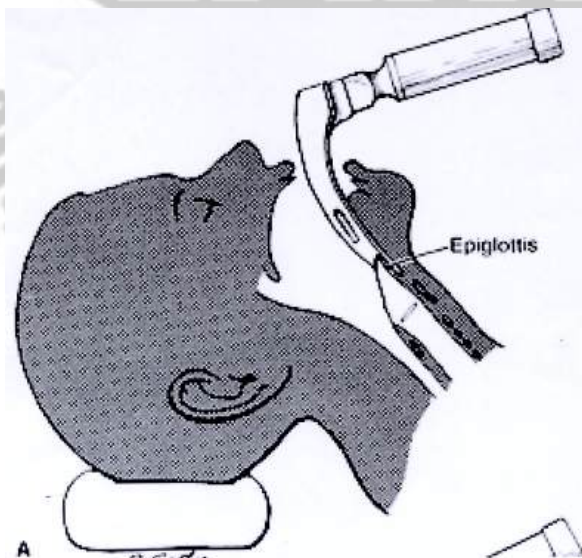


Figure 2:6 Sniff position

Essential Surgical Skills

The neck is flexed by hand or by elevation of patient's head with a pad (intubation pillow) under the occiput with the shoulders remaining on the table. Then, with the sustained axes alignment and the patient's mouth opened maximally and the lower lip rolled forward, the laryngoscope blade is inserted in the right side of the mouth, displacing the tongue to the left as the blade is advanced into the vallecula. (figure 2:7)

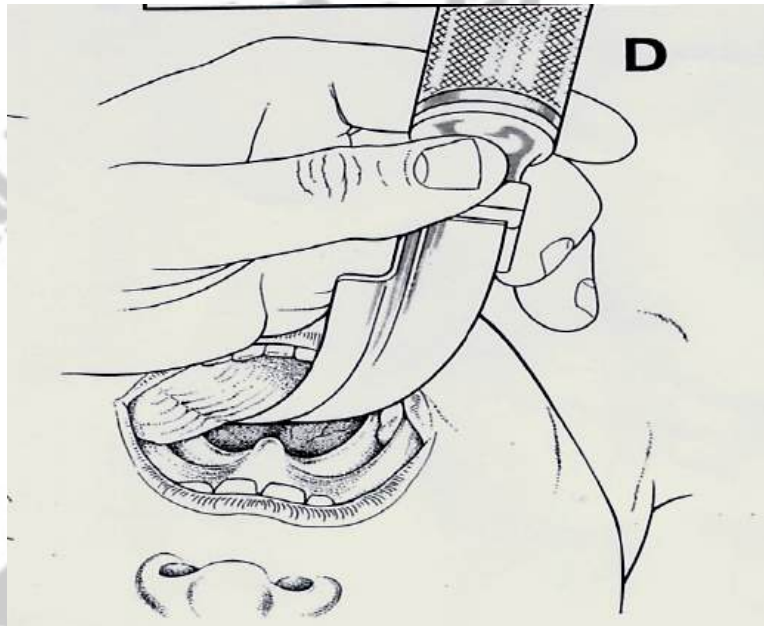


Figure 2:7 Blade advanced into the vallecal

The wrist is held steady to avoid using the teeth as a fulcrum. (Figure 2:8)

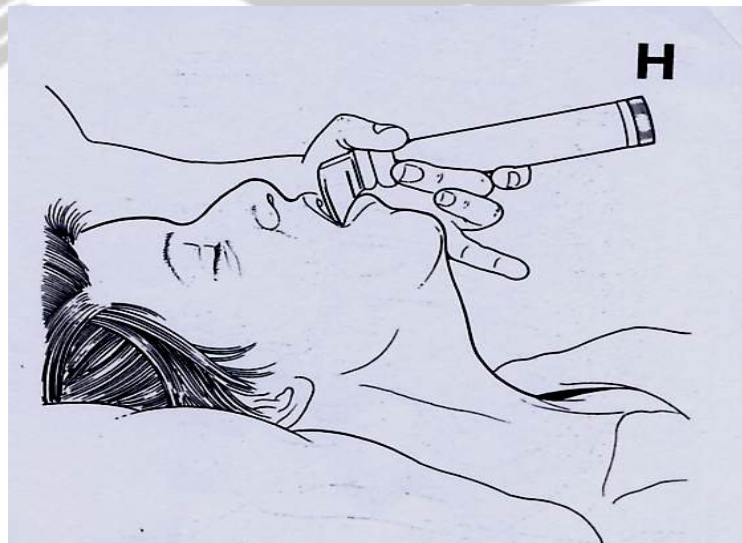


Figure 2:8 Wrist held steady

The endotracheal tube is passed through the glottis. (Figure 2:9 and 2:10)

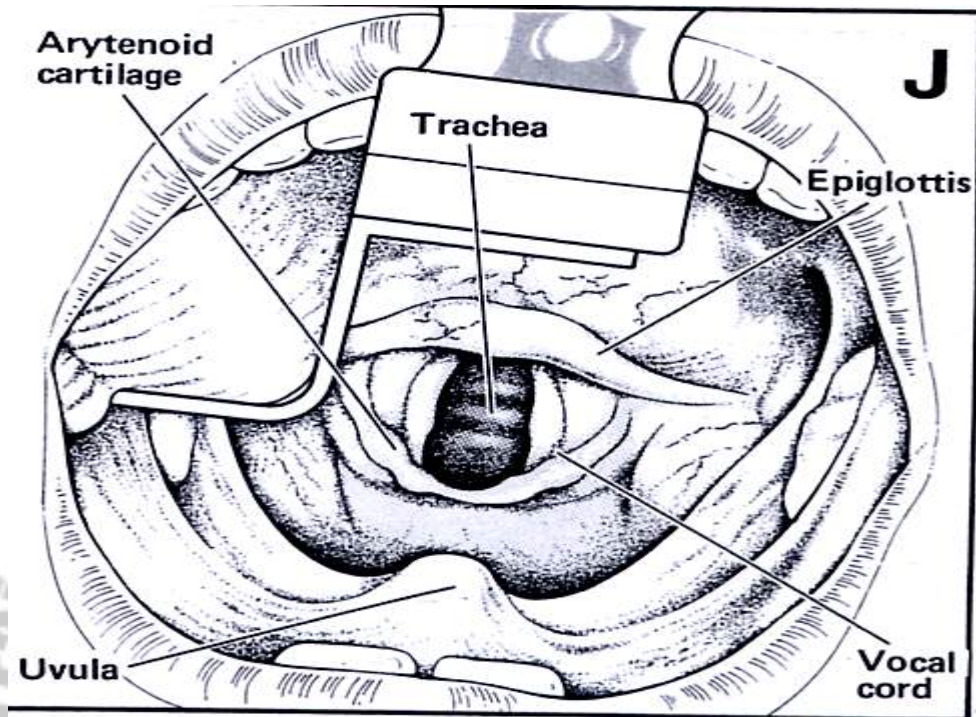


Figure 2:9 Visible structures

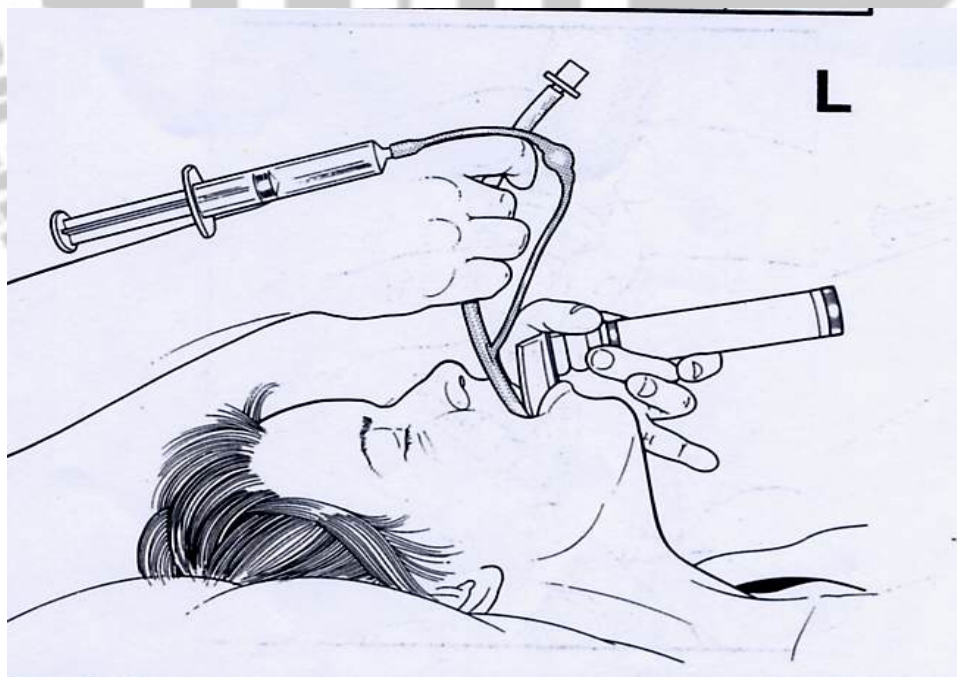


Figure 2:10 insertion of Endotracheal tube

Essential Surgical Skills

The placement of the tube in the trachea is confirmed by clinical signs.

Evidences of successful tracheal intubation are

- 1) Bilateral breathing sounds.
- 2) Absence of air movement during epigastric auscultation.
- 3) Condensation (fogging) of water vapor in tube during exhalation
- 4) Symmetrical movement of the chest
- 5) To see when the tip of the tube passes through the glottis is an absolute proof

Inflate the balloon

Secure the tube by adhesive tape or cotton bandage

Insert oro pharyngeal airway

Case scenario

A 25 year old male patient was involved in car accident & sustained head injury. He is unconscious and has labored breathing.

- a. Discuss how to keep the airway patent
- b. List the steps and equipment for Endotracheal intubation
- c. Discuss the possibilities of mechanical ventilation.

Cardiopulmonary resuscitation (CPR)

CPR is symptomatic therapy aimed at sustaining vital organ function until natural cardiac function can be restored.

Causes of cardiac arrest

- Underlying cardiac or pulmonary diseases
- Metabolic and physical abnormalities such as
 - Hypoxia
 - Hypovolemia
 - Acid-base abnormalities
 - Electrolytes derangement
 - Adverse drug effects
 - Pericardial tamponade
 - Tension pneumothorax

Diagnosis of cardiac arrest

- Pulselessness in large arteries (carotid, femoral, brachial) is the most important point in the diagnosis.
- Intraoperatively the disappearance of the circulation may be noted by a sudden cessation of bleeding
- Unconsciousness and cessation of respiration occurs and, usually within one minute, the pupils dilated.

Two levels of CPR

a. Basic life support

GOAL: To provide an artificial circulation of oxygenated blood to the vital Organs

1. Airway maintenance

Upper airway is obstructed by the tongue in unconscious patients. Ensure that clear and unobstructed airway is present. Vomit, blood or foreign material in the mouth should be removed manually or with rigid sucker.

Techniques of airway maintenance

- Head tilt-chin lift
 - Lifting the tongue away from the posterior pharynx, prevent airway obstruction in an unconscious patient
- Jaw – thrust
- An oro pharyngeal or nasopharyngeal airway insertion
- Tracheal intubation

In all cases, the first step is to clear the airway and then maintain clarity while ventilation is carried out.

2. Technique of rescue breathing

- Mouth-to-mouth ventilation
- Mouth-to-nose ventilation
- Mouth to mask ventilation
- Self-inflating resuscitation BAG

Essential Surgical Skills

Tracheal intubation is an eventual aim so that the lungs can be easily inflated with less likelihood of gastric distension regurgitation of gastric contents & potential lung soiling and obstructing from inhalation.

3. Circulation:

An artificial blood flow is provided by external cardiac compression.

PRACTICAL SESSION IV

Techniques of external cardiac compression (Figure2:11)

- Position victim supine on a firm surface
- Rescuer should stand or kneel next to the victim's side
- Heel of one hand is placed on the lower sternum and the other hand on top (in adult)
- Apply pressure only with heel of one hand straight down on sternum
- Compression rate 80-100 /minutes
- Compression ventilation ratio; 15:2 (one rescuer)
5:1 (two rescuer)

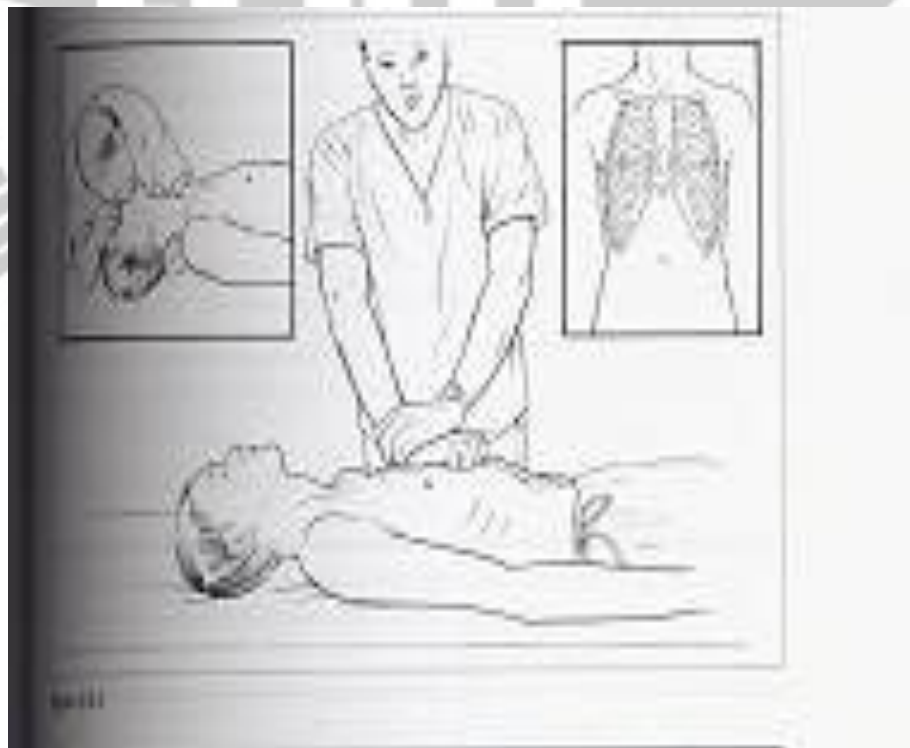

Figure 2:11 CPR

b. Advanced cardiac life support

- Using all modalities available for resuscitation

GOAL: Restoration of cardiac function and adequate cardiac output

Drug therapy

	Dose (IV)	Dose Interval (Minute)	Maximum dose (mg/kg)
Epinephrine	1mg	3-5	none
Lidocaine	1mg/kg	3-5	3
Atropine	1mg	3-5	0.04
Sodium Bicarbonate	1meq/kg	as needed	check PH

- Of the drugs given during CPR, only epinephrine is acknowledged as being useful in helping restore spontaneous circulation.

Venous cut down

- It is an emergency surgical procedure, which enables access to veins.
- It is indicated to establish an IV line in a patient who is in shock when the Usual percutaneous way of cannulating peripheral veins fails.
- The most commonly used vein is the great saphenous vein which is constantly located 1-2 cms above & medial to the medial malleolus. (Figure 2:10).

Practical Session V

The incision should follow the broken lines shown on the picture below

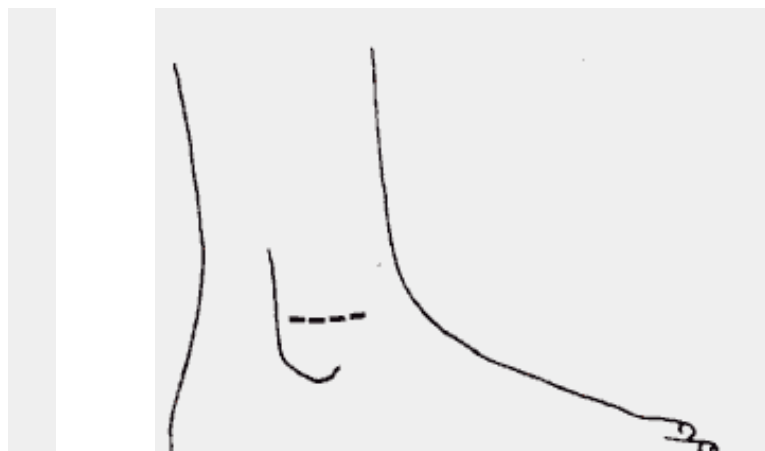


Figure 2:11 The great saphenous vein

The great saphenous vein at the ankle is commonly used for the procedure; although other sites are also available. After isolation of the vein in the usual manner, a loop of thread is passed under the vein as shown in figure 2:12. The apex of the loop is then divided.

Figure 2:12 Loop of thread passed



The distal ligature is knotted and the ends of the proximal ligature are held without knotting. A needle (21G needle or the needle of the intravenous cannula which is to be used for the cannulation) is used to transfix the vein at the proposed site of cannulation, as shown in figure 2:13




Figure 2:13 Transfixation

Essential Surgical Skills

The circumference of the vein anterior to the needle is almost completely incised with a scalpel as shown in figure 2:14. The needle prevents injury to the posterior wall of the vein and also facilitates a clean-cut incision.




Figure 2:14 Vein

opening

The intravenous cannula without the inner needle is then introduced into the venotomy opening, with the needle steadying the vein (Figure 2:15). The needle is then removed, the proximal ligature tied over the cannula and the wound closed.

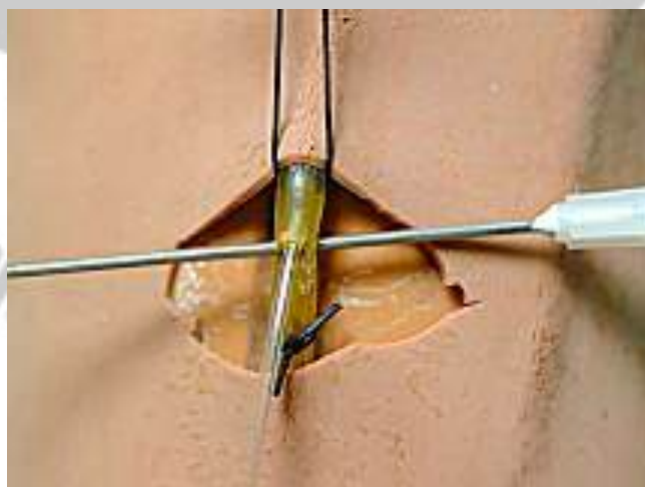


Figure 2:15 Cannula insertion

Complications:

- Cellulitis

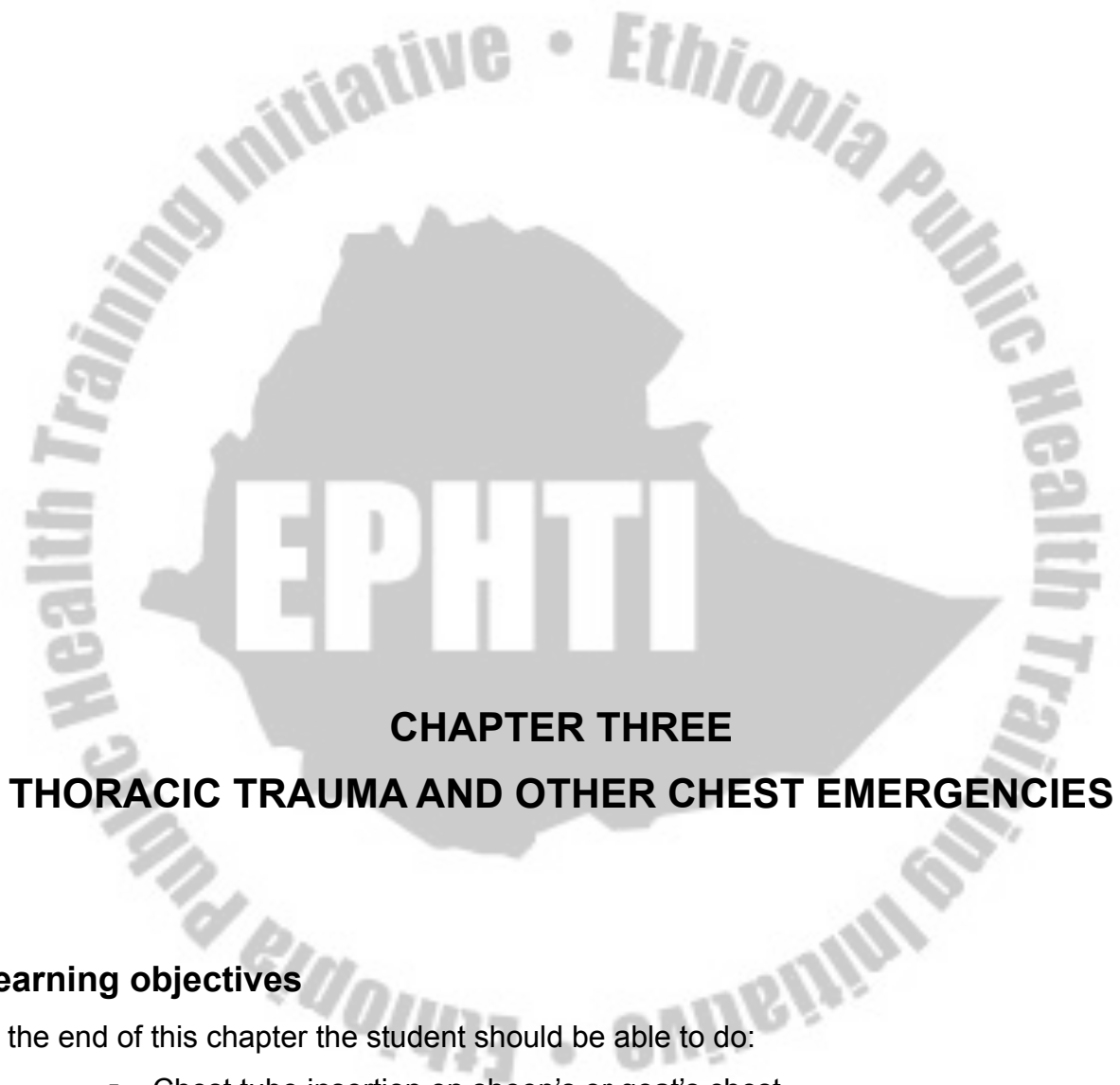
Essential Surgical Skills

- Hematoma
- Thrombophlebitis



Reference:

1. Clinical anesthesia, Paul G. Barash, Bruce F. Cullen, Robert K. Stoelting; Third edition, 1997
2. Principle and procedures in anesthesiology, Philip L.Li, 1992
3. Clinical anesthesia, procedures of Massachusetts General hospital, William E. Hurford, Fifth edition, 1998
4. Anesthesia at district hospitals, Geneva, WHO, 1988
5. Update in anesthesia, No4, 1994
6. McIntosh BB, dulchavsky SA. Peripheral venous cut down, Cr care clin 1992,8:807-18



CHAPTER THREE

THORACIC TRAUMA AND OTHER CHEST EMERGENCIES

Learning objectives

At the end of this chapter the student should be able to do:

- Chest tube insertion on sheep's or goat's chest
- Tracheostomy on sheep's or goat's throat

Chest injuries:

- Account for about 25% of all deaths due to trauma.
- About 75% of them have associated non thoracic trauma.

Essential Surgical Skills

- About 85% of them can be managed without thoracotomy (open chest surgery)
- The initial assessment of a patient with thoracic injury should follow the ABC rule of trauma management.

Can be:

- (a) Penetrating : stab, bullets etc...
- (b) Blunt: fall downs, RTA, etc
- Penetrating injuries of the chest occurring below the level of the nipple can traverse the diaphragm & involve the abdominal viscera.

Commonly encountered specific Chest Injuries requiring urgent intervention:

1. Pneumothorax:

- Defined as collection of air in the pleural space

Can be

(a) Tension pneumothorax

- Air is allowed to enter to the pleural space during expiration but doesn't leave during inspiration as the site of injury acts like a one-way valve.
- This leads to continuous accumulation of air in the pleural space with progressive build up of pressure & tension.
- The outcomes of this are:
 - Complete collapse of the ipsilateral lung.
 - Shift of the mediastinum & the great vessels to the opposite side obliterating the cardiocaval angle & impairing the venous return which in turn reduces the cardiac output.
- Diagnosis
 - Clinical
 - Chest x ray

Treatment

Essential Surgical Skills

- Insert a wide bore needle to the 2nd intercostal space at mid clavicular line right after diagnosis.
- Tube thoracostomy.

(b) Open Pneumothorax

- Also called a sucking chest wound
- Occurs when there is a loss of a full thickness segment of the chestwall allowing direct entry of air from the atmosphere to the alveoli through the wound rather than through the tracheobroncheal tree.
- Caused by a penetrating injury e.g. blast fragments, gunshots.

Diagnosis:

Inspection of the sucking wound

Treatment:

Immediate closure of the sucking wound followed by chest tube insertion.

(c) Simple pneumothorax

- Defined as the presence of air in the pleura with variable degree of collapse of the ipsilateral lung but with no tension & mediastinal shift.

Diagnosis: clinical

Chest x ray

Treatment

Chest tube insertion

3. Hemothorax

- Defined as accumulation of blood in the pleural space
- Results from bleeding to the pleural space from any of the following sources:
 - Lung parenchyma
 - Intercostal or internal mammary arteries.
 - The heart & the great vessels.
- Mainly occurs at the time of injury but can be delayed.
- Diagnosis

Essential Surgical Skills

- Clinical
- Chest x ray
- Chest tap

Treatment:

- Thoracentesis: hemothorax of minimal amount.
- Chest tube
- Thoracotomy:if(Indication for referral to higher center)
 - Massive hemothorax>1.5 L of blood at the time of chest tube insertion.
 - Continued bleeding>200cc/hr for more than 4 hrs continuously.
 - Associated with widened mediastinum
 - Clot which can't be removed by the chest tube completely.

4. Hemopneumothorax

- Defined as the presence of both air & blood in the pleural space.
- Caused by either blunt or penetrating trauma of the chest.
- Diagnosis
 - Clinical
 - Chest x ray
- Treatment Always requires chest tube insertion.

5. Flail chest

- Results exclusively from a blunt trauma that has caused fracture of>4 ribs at two different sites on each rib involved.
- This creates an isolated flail segment which moves in the opposite direction to the rest of the chest wall (Paradoxical movement).
- This impairs ventilation & hypoxia develops soon.
- There is usually an associated pulmonary contusion that worsens the hypoxia.

Diagnosis:

- Close inspection to witness the paradoxical movement of the flail segment.

Essential Surgical Skills

- Feel the paradoxical movement by putting one hand on the flail segment & the other on the normal chest wall.
- Chest x ray
 - Confirms the fracture.
 - Shows pulmonary contusion

Treatment

- Lie the patient with the affected side down.
- Potent analgesics
- Nasal oxygen
- Stabilization of the flail segment is done at higher centers & so the patient must be referred.

General indications of Referral to higher centers in a patient with chest injury:

- Massive hemothorax or continued bleeding
- Massive air leak
- Perforation of the intrathoracic esophagus
- Mediastinal widening associated with hemothorax.
- Flail chest

Chest tube (tube thoracostomy), underwater seal chest drains)

The indications for the underwater seal chest drainage are:

- Pneumothorax
- Hemothorax
- Hemopneumothorax
- Acute empyema
- In elective open chest surgeries &
- For medical management of malignant pleural effusion (pleurodesis)

Case scenario

A 25yrs old male patient sustained a car accident & was brought to the emergency OPD complaining severe chest pain & shortness of breath. On examination, the patient was

Essential Surgical Skills

in severe respiratory distress with a respiratory rate of 48/min, p=120/min & BP=80/50. There was mild cyanosis & the trachea was shifted to the left side. There was a big bruise on the Rt posterior chest & this hemithorax was prominent & hardly moves with respiration compared to the left side. It was hyperresonant to percussion & there was no breath sounds. No significant finding was detected in the other systems except simple bruises on the left lower limb.

- (a) What is the most likely clinical diagnosis of this patient.
- (b) What life saving intervention must be done right after the clinical diagnosis?
- (c) What is the ultimate treatment?

PRACTICAL SESSION 3:1

Chest tube insertion

- Position of the patient - sitting erect, or supine with the head of the bed elevated 45°
- The arm on that side should be abducted or raised above the head.

Site of insertion is 5th or 6th intercostal space along the mid axillary line if only pneumothorax 2nd intercostal space at midclavicular line

1. Clean the selected site with antiseptics & apply a sterile drape (preferably a fenestrated drape)
 - Infiltrate the skin, muscle & pleura at the chosen intercostal space with local anesthetics (1% lidocaine)

See the figures below (Fig 3:1-3:2).

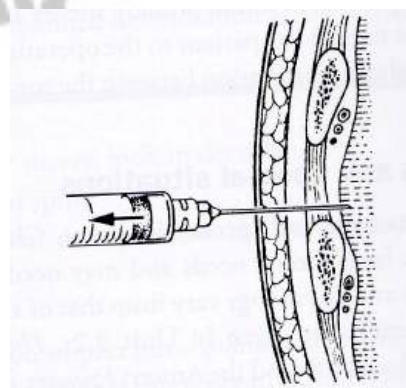
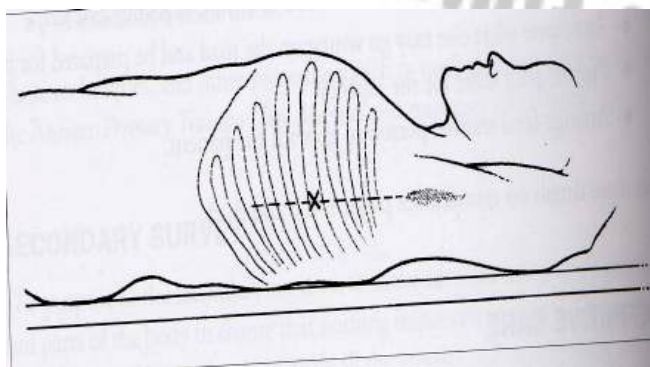


Figure 3:1

Figure 3:2

2. Make a small transverse incision just above the lower rib to avoid damage to neurovascular structures running along the lower border of the ribs. In children, it is better to make the incision in the middle of the intercostal space. (Fig 3:3 and 3:4)

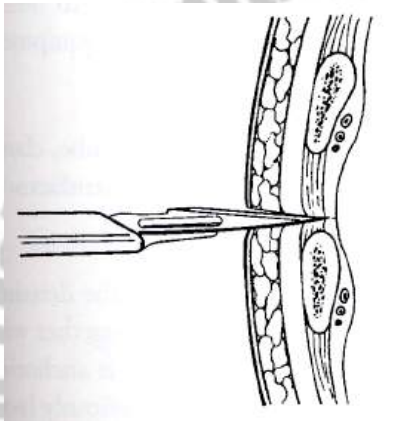


Figure 3:3

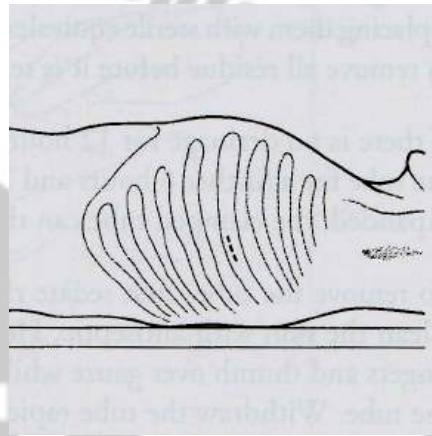


Figure 3:4

3. Using a pair of large curved artery forceps, split the intercostal muscles, penetrate the pleura & enlarge the opening. A gush of air will be noted at this stage. Put an index finger into this opening & make sure that the pleural space is free. To minimize subcutaneous emphysema, seal this opening with the index finger of the left hand while holding the tip of the chest tube with the same artery forceps & introduce it to the opening. Push the tube until all the fenestrae are well in the pleural space. (Fig 3:5-3:7)

NB: No fenestra should be left outside or in the chest wall!!!

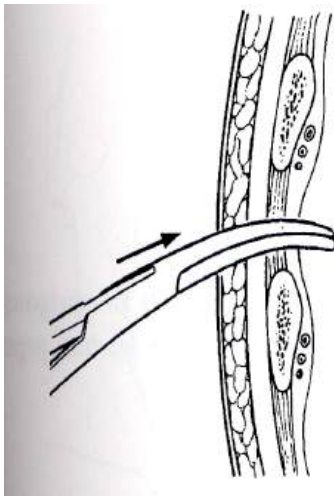


Figure 3:5

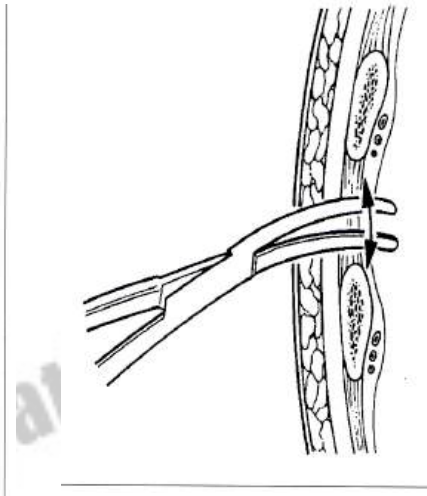


Figure3:6

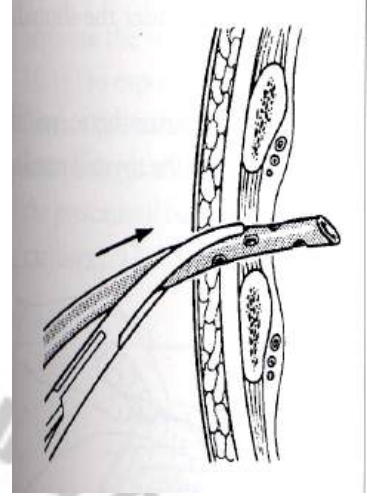


Figure3:7

3. Clamp the tube with an artery forceps & while the assistant keeps the tube in place, close the incision with interrupted sutures. Take deep bites as much as possible. This prevents the development of subcutaneous emphysema in the chest wall. With one of these stitches, anchor the tube & leave another untied suture adjacent to the tube for closing the wound when the tube is removed. Apply a gauze dressing & plaster it. (Fig 3:8)

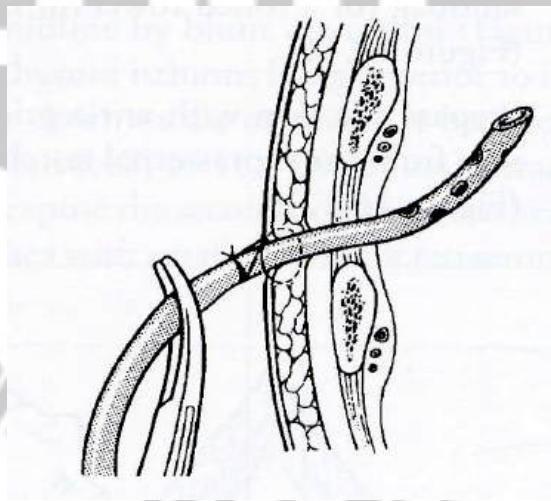


Figure 3:8

5. Remove the clamp & connect the tube to the underwater-seal drainage system & mark the initial level of the fluid in the drainage bottle.(Fig3:9)

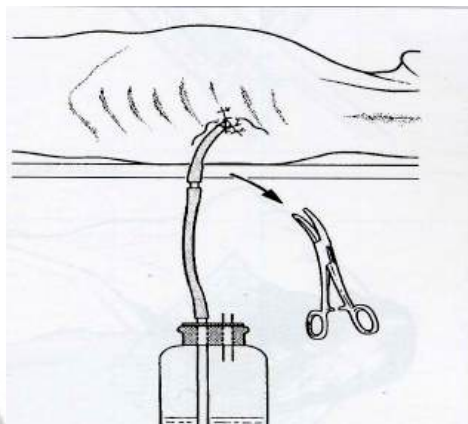


Figure 3:9

Postoperative care:

- Make sure that the chest tube is functional by checking if there is oscillation in the tube with changes in the intra pleural pressure as the patient breathes in & out. Regular massage of the tube helps to dislodge any clots or dried secretions blocking the tube.
- Record the out put of the chest tube over every 24hrs.
- Change the fluid in the bottle at least once in 48hrs.
- Patient should be given adequate analgesia & should be encouraged to take deep breaths & cough.
- Perform regular examination of the chest & take control X-ray to see if the lung has expanded or not.
- Decide to remove the chest tube if:
 - Drainage over 24hrs is nil or <50c
 - Physical examination or chest X-ray reveals full expansion of the lungs.
- Referral to higher centers should be considered if :
 - There is continuous bubbling both during inspiration & expiration for several days (Bronchopleural fistula)
 - Continued massive bleeding (>200cc/hr for more than 4 consecutive hrs)

Tracheostomy

- It is defined as an operative procedure, which creates a surgical airway in the cervical trachea.

Essential Surgical Skills

- It gives a direct access to the tracheobronchial tree & provides a path of low resistance for air exchange in a patient with upper airway obstruction.

- Indications:

1) Upper airway obstruction which can be caused by:

- Laryngeal pathology

- a. Infections (Croup, TB)
- b. Spasm (Tetanus, Vasovagal reflexes)
- c. Edema (inhalational injury,, allergy,trauma etc..)
- d. Tumors (papilloma, ca)

- Trauma

Neck trauma with severe injury to the thyroid or cricoid cartilages, hyoid bone or great vessels

Severe facial fractures (midface, mandibular fractures)

2) To provide a long-term route for mechanical ventilation

- In cases of respiratory failure
- Severe head injury

3) To provide pulmonary toilet

- Impaired cough reflex due to chronic pain or weakness

4) Prophylaxis

- Elective maxillofacial surgeries

Tracheostomy tubes

- Present in different sizes expressed in numbers .The tracheostomy tube to be used should be $\frac{3}{4}$ th of the diameter of the trachea. For an average adult male of average body habitus, no.8 & for females no.6 is appropriate. In obese patients extra long tubes should be used as the distance b/n the trachea & the skin is large.

- Has three parts namely (see the figure 3;10)

(a) The outer tube (fig. a)

(b) The inner cannula or inner tube (fig. b & d)

(c) The stellate(fig. c)



Figure 3:10

Case scenario:

A 2 yrs old male child presented with severe difficulty of breathing of 8hrs duration after a prior mild upper respiratory tract infection. The mother noticed that his breathing has become labourous & noisy.

Examination revealed:

- Severe respiratory distress with audible stridor
- Tachypnea & low grade fever
- Uninflamed tonsils & adenoids
- Severe inter- & subcostal retraction with clear lung fields.

(a) What do you think is wrong with this child?

(b) Do you need any investigative modality to confirm your diagnosis?

(c) What is the immediate management of this child?

PRACTICAL SESSION 3:2

Tracheostomy

1. Position-The patient must be in supine position with the neck extended using a pillow or a sand bag under his/her shoulders.(fig 3:11)

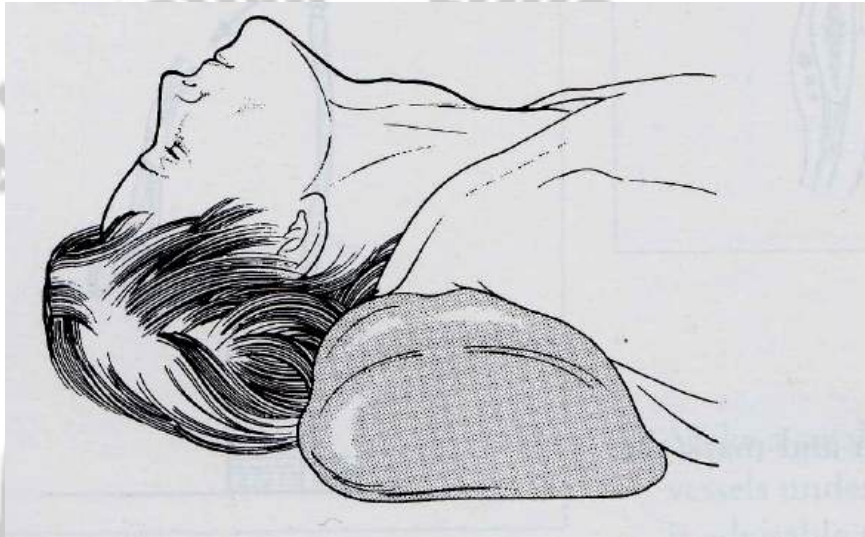


Figure 3; 11

2. Prepare the skin with antiseptic & drape it.Infiltrate the area b/n the supra sternal notch & the thyroid cartilage along the midline with local anesthetics.(fig.3:.12)

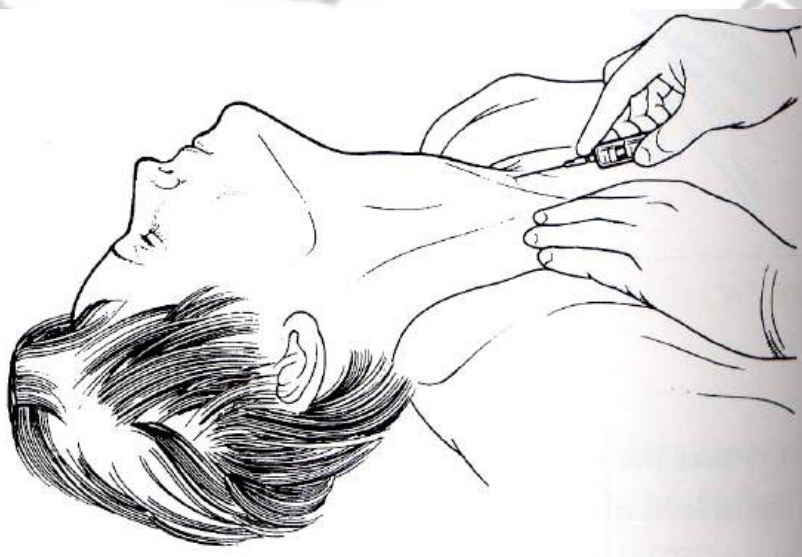

Figure 3:12

2. Make a midline vertical incision b/n the lower end of cricoid cartilage & the superior margin of the suprasternal notch. A transverse incision few centimeters above the suprasternal notch can also be used .The incision should be deepened through the skin, platysma & the cervical fascia until the strap muscles are well exposed.(fig 3:13-14)

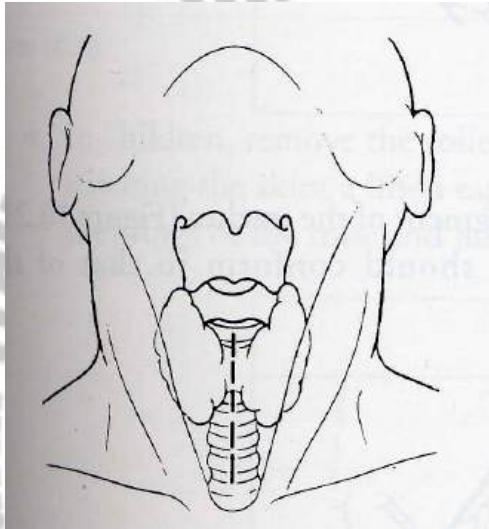


Figure 3; 13

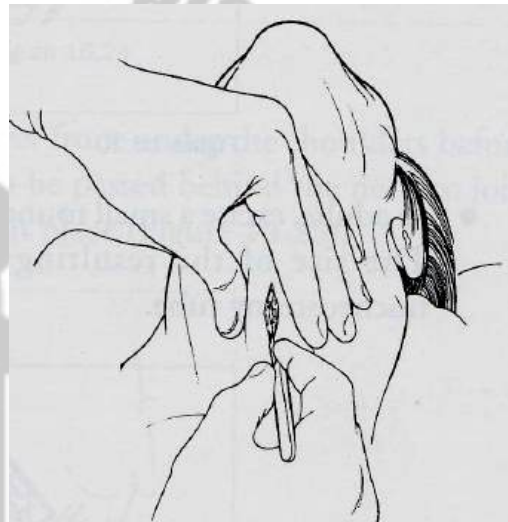


Figure 3; 14.

4. Split the strap muscles to expose the isthmus of the thyroid gland which can be either retracted up or down or divided to expose the 2nd & 3rd tracheal rings. The trachea can then be lifted & steadied by skin hooks or stay stiches. (fig 3:15- 3:3:17).

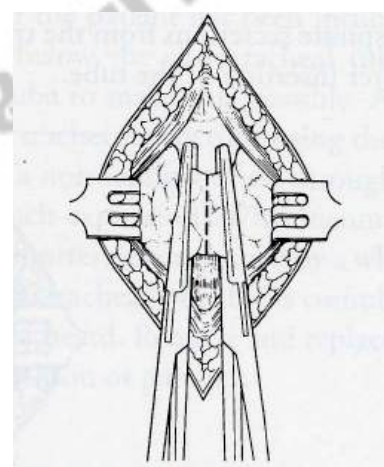
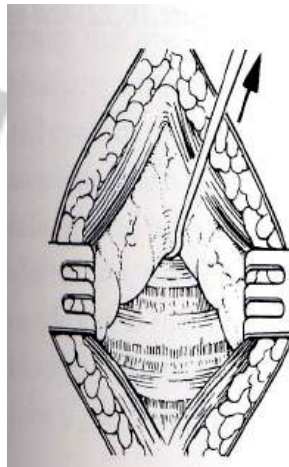
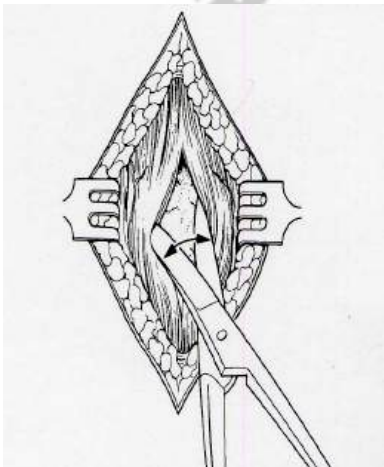


Figure 3:15

Figure 3:16

Figure 3:17

5. In infants & children, make a transverse intercartilagenous incision b/n the 2nd & 3rd tracheal rings. Avoid excising a piece of trachea.(fig 3:18).In adults excise a small rounded segment of trachea whose size is equivalent to the size of the tracheostomy tube selected.(Fig 3:19) A simple vertical incision in the mid line just over the 2nd & 3rd tracheal rings can also be used to open the trachea in very urgent conditions.

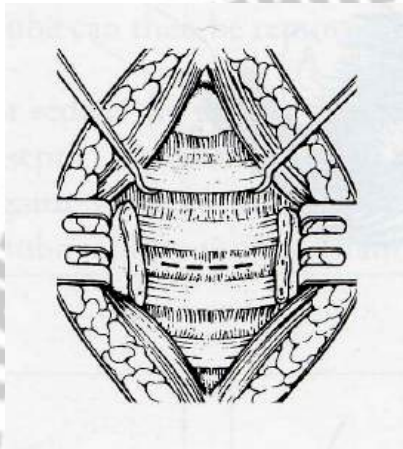


Figure 3:18

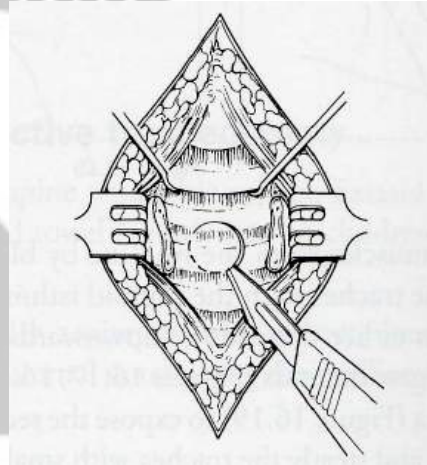


Figure 3:19

6. Suck all the secretions from the trachea (fig.3:20) & carefully insert the tracheostomy tube. In infants & children a tracheal spreader can be used to widen the tracheal opening & facilitate the insertion of the tube.

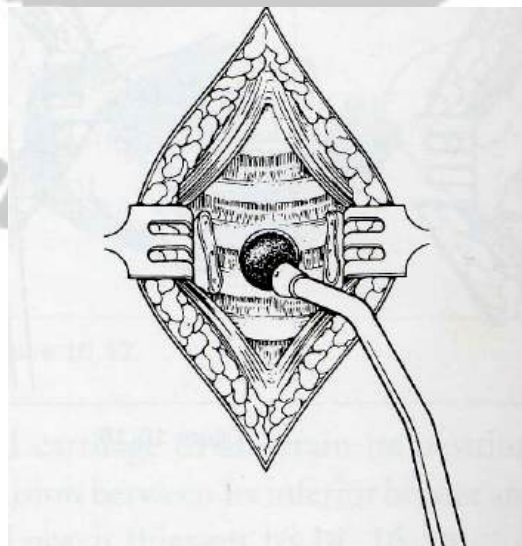


Figure 3:20

7. Remove the stellate & suck all the secretions. While the assistant keeps the tube in place loosely stitch the skin with interrupted 2-0 suture material. Pass a linen tape behind the neck & join the wings of the tube to hold it in place. (Fig 3:21-3:23) Put a small dressing around the tube for the first few post operative days.

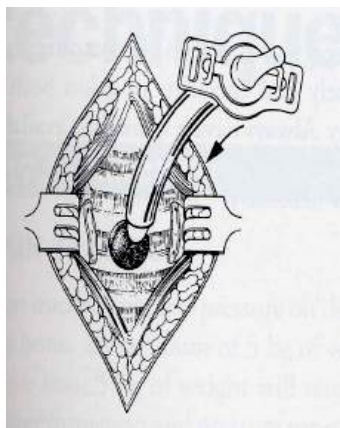


Figure 3; 21

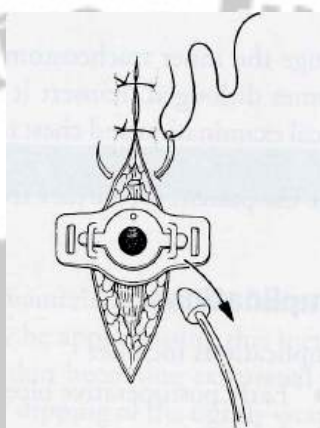


Figure3:22

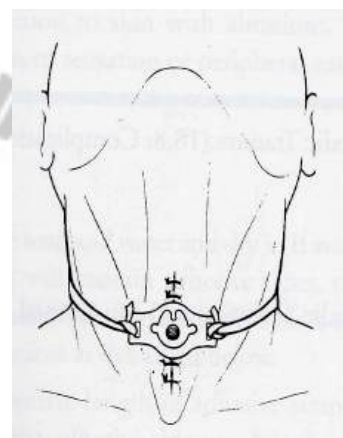


Figure3:23

Postoperative care:

Suctioning

- Is the cornerstone of the postoperative care
- Has to be done very frequently (e.g. Q15mnts) so as to keep the tube patent.
- Irritation of the trachea & stimulating cough reflex by inserting the suction tube deeper than the length of the tracheostomy tube should be avoided.
- The inner tube should be removed during suctioning.

Warming & humidification of the air

- Sometimes small amounts of sterile saline can be instilled into the bronchi to soften the secretions.

NB:

- A spare tracheostomy set should be kept by the bedside incase it is needed e.g as in accidental decannulation. The tracheostomy tube should not be changed earlier than the first postoperative week.

Complications:

Early

- Blockage of the tube by thick secretions
- Bleeding
- pneumothorax or pneumomediastinum
- Injury to adjacent structures
- Subcutaneous emphysema
- Accidental decannulation
- Tracheal inflammation
- Wound infection

Late

- Tracheal stenosis
- Tracheoesophageal fistula
- Tracheocutaneous fistula
- Keloid

References:

1. Surgical care at the district hospital, WHO, 2003
2. PHTLS, basic & advanced Prehospital Trauma Life Support, 4th edition, 1999
3. McIntosh BB, Dulchavsky SA. Peripheral venous cut down. Cr care clin 1992;8:807-18
4. Shock, Chapter 3, advanced trauma life support student course manual, 6th edition, American college of surgeons Chicago 1997;87-125.

CHAPTER FOUR

ACUTE ABDOMEN (ABDOMINAL EMERGENCIES)

Learning objectives

At the end of this chapter each student should be able to do:

- How to open and close laparotomy using a simulator as an abdominal wall
- Repair bowel perforation using goat's or sheep's gut
- Resection and anastomosis of goat's or sheep's gut
- Loop and end colostomy using goat's or sheep's gut

Definition: - acutely presenting signs & symptoms of intra-abdominal disease usually treated surgically.

- Pain that persists for 6 hrs or more and is of severe intensity usually requires operative intervention
- Pain of sudden onset which may experience complete resolution in 4-6hrs does not require surgical intervention.
- Abdominal emergencies are common reason for hospital visit
- Proper management of patients with acute abdomen needs timely decision about the need for surgical operation if you are in hospital or timely referral if you are in health center or health station.
- Abdominal emergencies affect all age groups.

Essential Surgical Skills

The following are possible differential diagnosis

- A) Gastro intestinal
 - Intestinal obstruction
 - Appendicitis
 - Cholecystitis
 - Perforated PUD
 - Pancreatitis
 - Peritonitis
- B) Gynecological cause
 - Ectopic pregnancy
 - Torsion or rupture of ovarian cyst
 - PID
- C) Genitourinary system
 - UTI
 - Urinary tract calculus

Diagnosis of acute abdomen

Depends on thorough evaluation by:-

- 1) History
 - Duration, on set and characteristics of pain
 - Associated symptoms
- 2) Physical examination
 - Tenderness, guarding and derangement of vital signs
- 3) If available
 - Laboratory investigation
 - Imaging studies

Treatment

- Treatment of patients with acute abdomen depends on the type of disease and is usually surgery
- If you are in a health institution where surgery can not be done, you have to refer the patient to a center where surgery can be done.
- Before referring the patient you may need to
 - Insert NG-tube
 - Open IV-line and give IV fluid
 - Catheterize the patient

Give IV anti-biotic

Perianal abscess

Definition → collection of pus in the perianal region due to infection commonly by bacteria

It results from

- 1) infection of anal glands → 90% of cases
- 2) penetration of anal mucosa by (bone, hard stool etc)
- 3) blood born infection
- 4) extension of cutaneous boils
- 5) underlying anal disease

-Ca, Tuberculosis, Crohn's disease

- *Mixed organisms involved, such as E-coli, staph aureus, Bacteroids fragilis.*
- Patients with diabetes mellitus, AIDS are more likely to develop perianal abscess.

History

Severe perianal pain, aggravated by walking, coughing straining

- some times, fever, chills → in patients with sepsis

P/E

Tender, rounded and induration at anal verge

Treatment

- incision and drainage of pus (cruciate incision, excising skin edge)
- irrigate with saline or H₂O₂
- anti-biotic (IV or PO)
- sitz bath

Case scenario

1. 20 years old female patient presented with peri-umbilical abdominal pain which later shifted to RLQ; two episode of vomiting and nausea of 10 hours duration, passed faces and flatus. On examination, vital signs are normal and has tenderness with rebound tenderness over the RLQ.
 - A. What are your DDX?
 - B. What would be your plan of management
 - C. What will happen to the patient if not operated?

Essential Surgical Skills

2. 36 years old male patient with previous history of dyspepsia presented with sudden onset of severe agonizing epigastric pain, after alcohol intake followed by pain all over the abdomen and fever. On examination he has generalized abdominal tenderness and rigidity, bowel sounds are absent
 - A. What is your impression?
 - B. What are the possible differential diagnoses?
 - C. What investigation would you order to confirm the diagnosis?
 - D. What is your plan of management?
3. 30 years old farmer presented with vomiting of bilious material, colicky central intermittent abdominal pain of 4 hours duration. On examination patient was acutely sick looking; with dry tongue and buccal mucosa, sunken eye balls, hypotensive, and tachycardic. There was central abdominal distention, but no area of tenderness and bowel sounds were hypereactive.
 - A. What is your impression?
 - B. What are common causes for the above problem?
 - C. What investigation would you order to diagnose the above condition?
 - D. How would you manage the above patient?
 - E. What are possible complications if you don't timely treat the above patient
4. 50 years old man presented with Lower abdominal pain, gross abdominal distension, and failure to pass feces and flatus of 1 day duration. On examination, vital signs are within the normal limit, abdomen is grossly distended, no area of tenderness and bowel sounds are hyperactive.
 - A. What is your impression?
 - B. What are the possible causes of the above problem?
 - C. How would you treat the above patient?
 - D. If the above patient is not treated, what complication could occur?
5. 20 years old male patient involved in road traffic accident came with severe abdominal pain, on examination he was pale; and hypotensive. Abdomen is tender all over, bowel sound are absents.
 - A. What is your impression?
 - B. How would you proceed to diagnose?

C. What are the treatment options?

Practical session 4:1

1. Laparotomy

Make midline incision. Open skin and subcutaneous tissue (see figure 4:1)

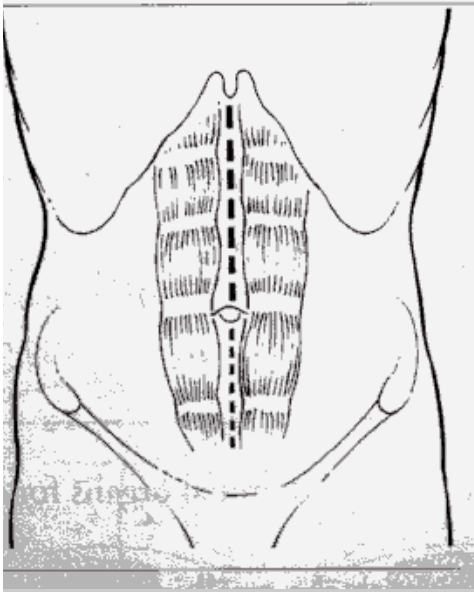


Figure 4:1

Open fascia(linea alba)(see figure 4:2)

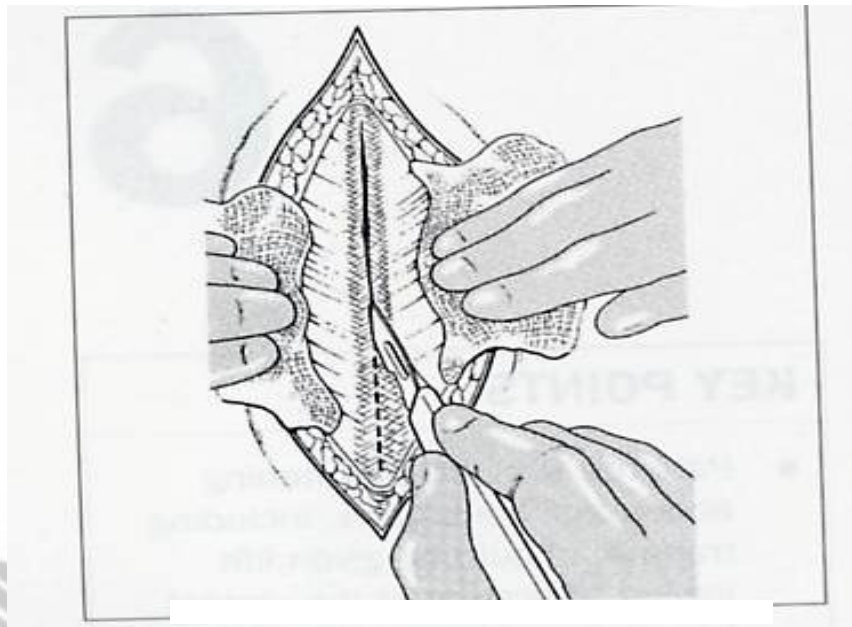


Figure 4:2

Hold peritoneum with two artery forceps and check for absence of bowel (see figure 4; 3)

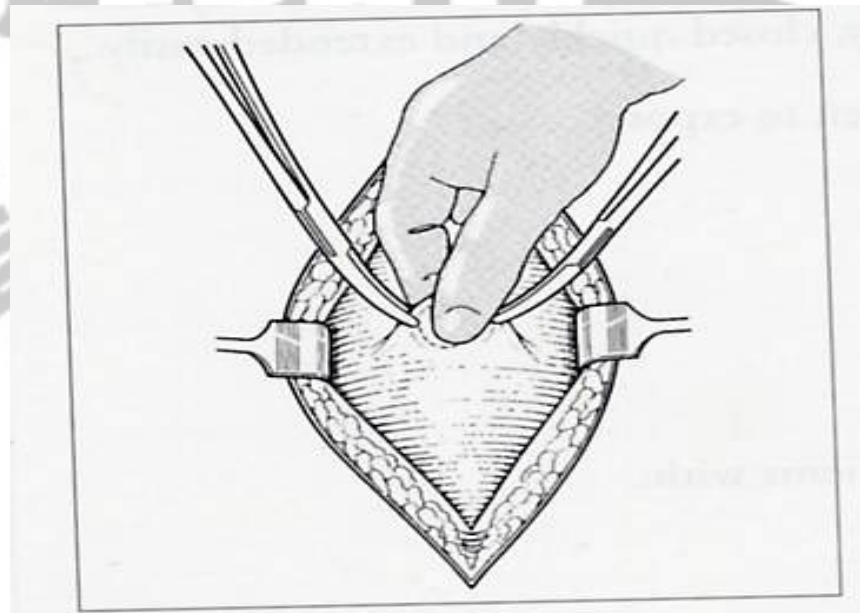


Figure4:3

Incise peritoneum carefully with a knife (see 4; 4)

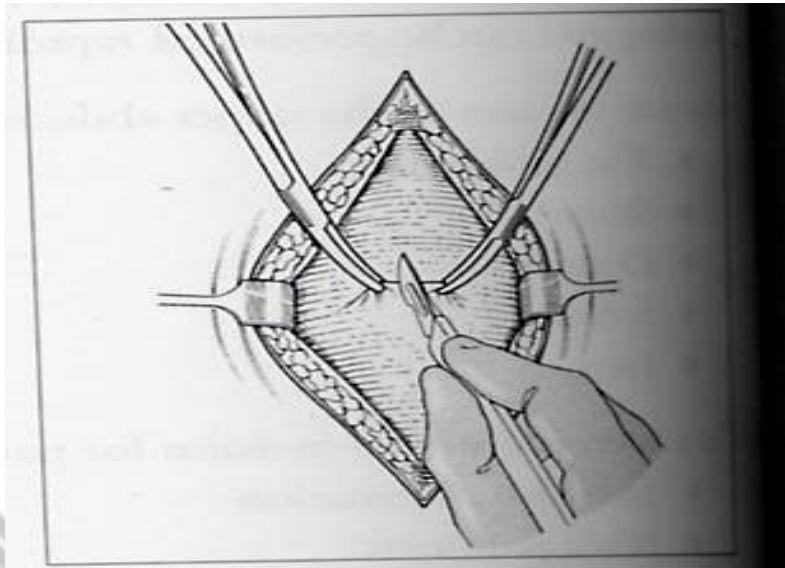


Figure 4:4

Extend peritoneal opening using scissors (see figure 4:5)

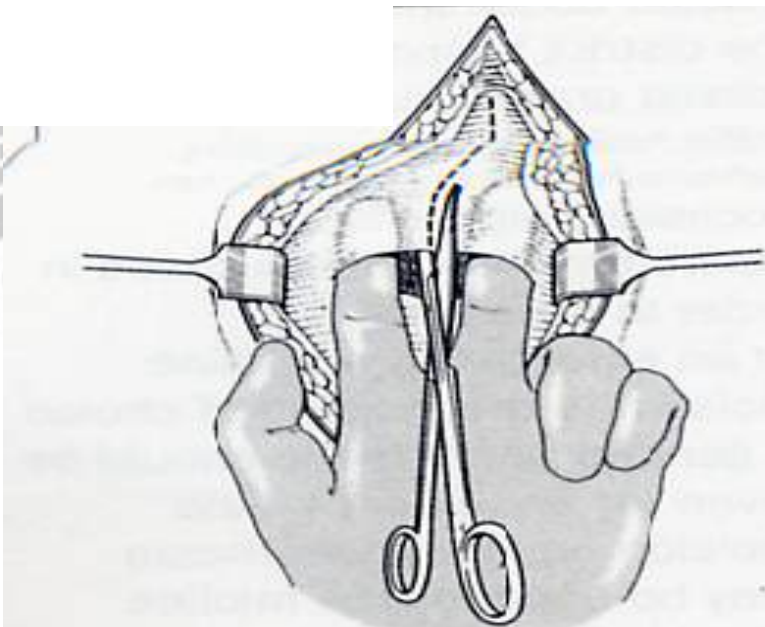


Figure 4:5

Explore peritoneal cavity

Closure of laparotomy

Essential Surgical Skills

Close the peritoneum (see figure 4:6)

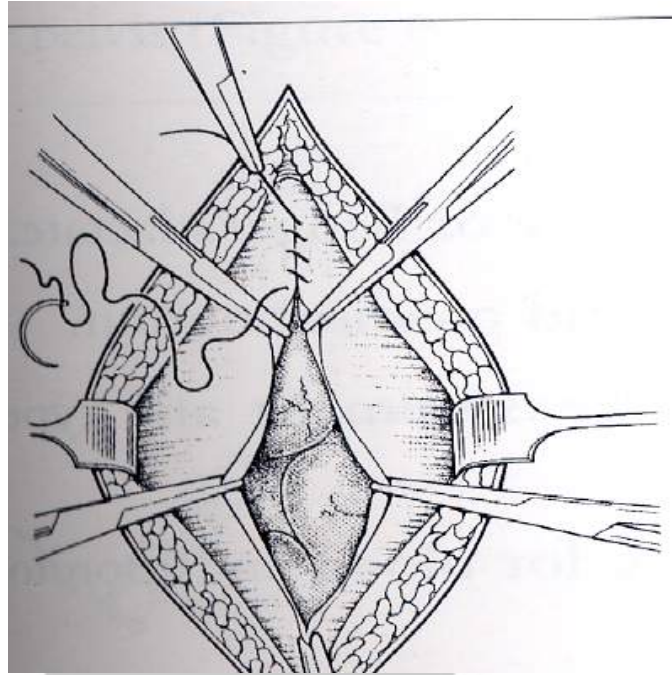


Figure 4:6

Protect the bowel (see figure 4:7)

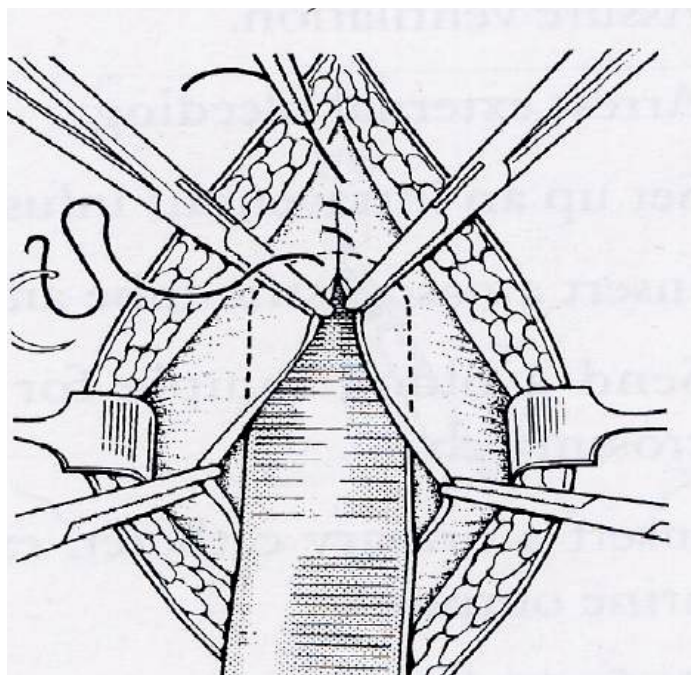


Figure 4:7

Close the fascia (see figure 4:8)

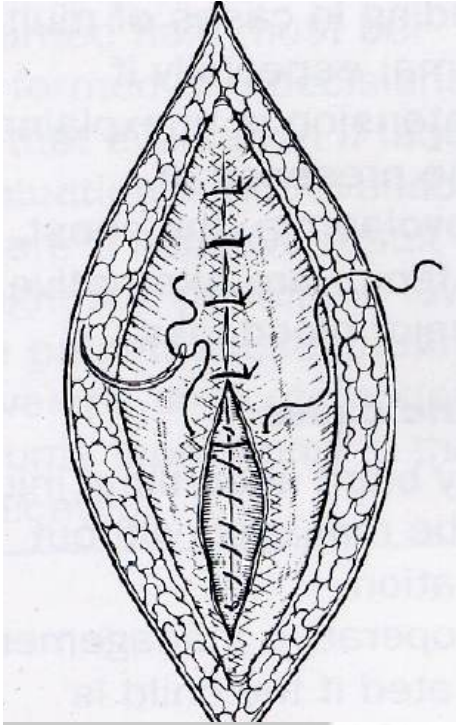


Figure 4:8

Close the skin (see figure 4:9)

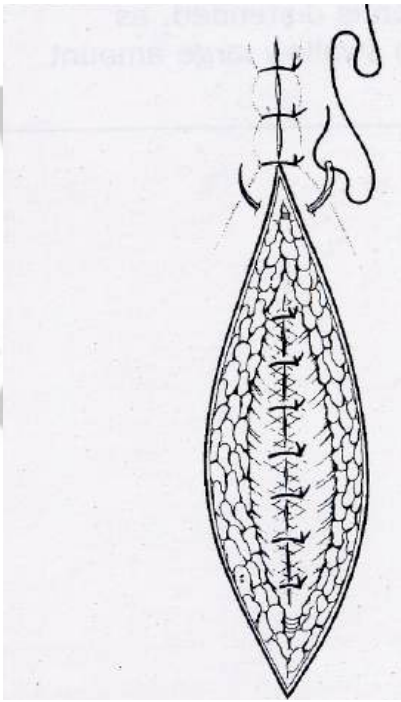


Figure 4:9

PRACTICAL SESSION 4:2

Repair of small bowel perforation (in two layers)

Expose the wounded portion of the small intestine (see figure 4:10)

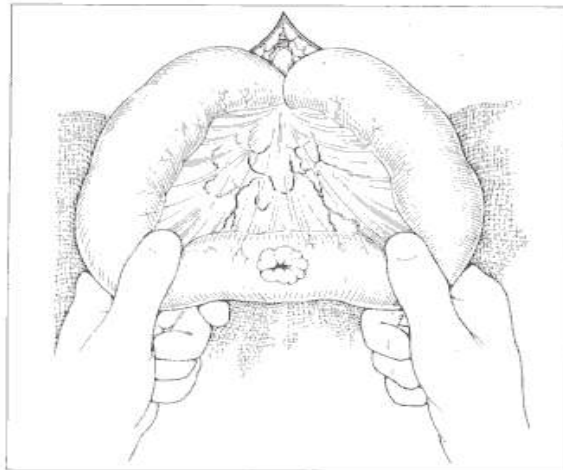


Figure 4:10

Pull the gut transversely with stay sutures (see figure 4:11)

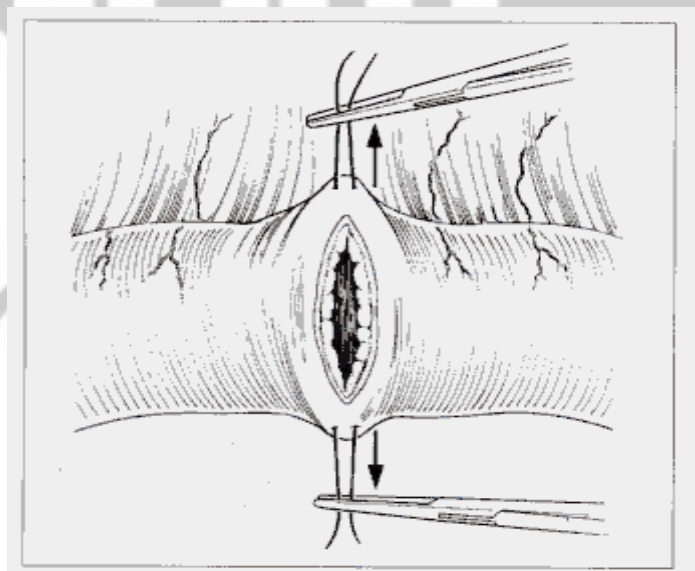


Figure 4:11

Insert the first layer of invaginating sutures to include all layers of the gut wall (see figure 4:12)

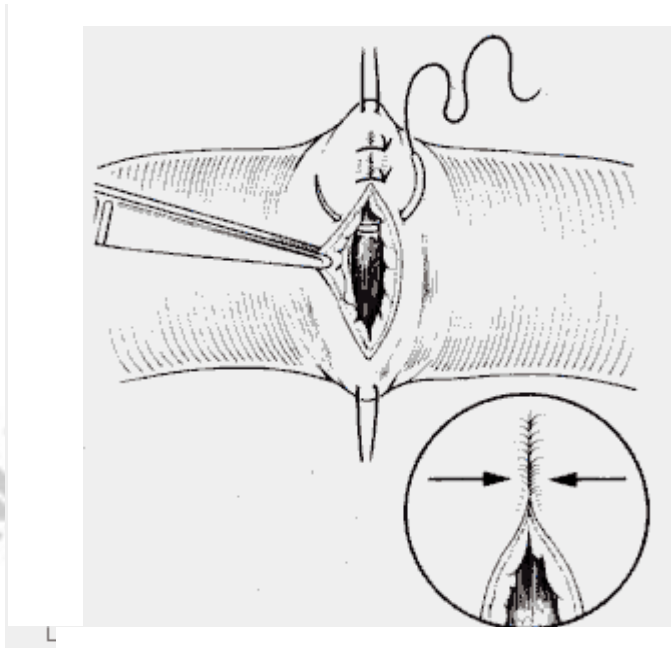


Figure 4:12

The second layer of serosa to serosa complete the repair (see figure 4:13)

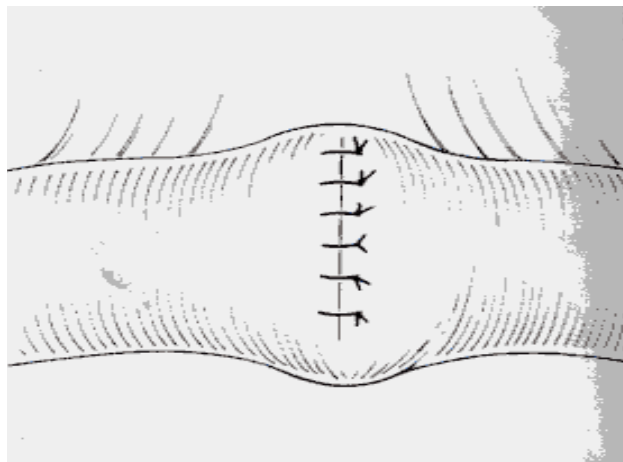


Figure 4:13

PRACTICAL SESSION 4:3

Resection and anastomosis of small bowel

Essential Surgical Skills

Indication

- Gangrenous small bowel
- Small bowel tumor
- Trauma to small bowel with devitalized segment

Isolate the bowel to be resected and mesenteric vessels to be ligated. (See figure 4:14)

Ligated mesenteric vessels and divided the mesentery of bowel to be resected. (See figure 4:15)

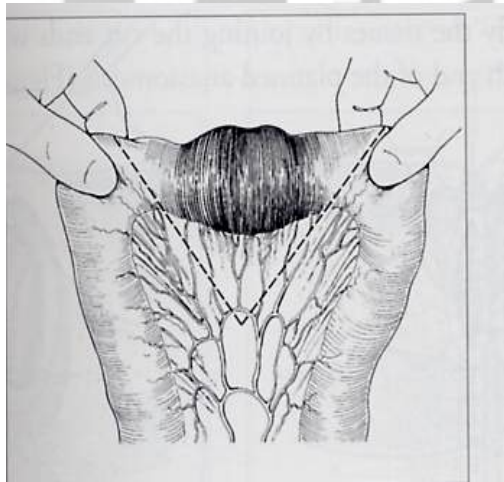


Figure 4:14

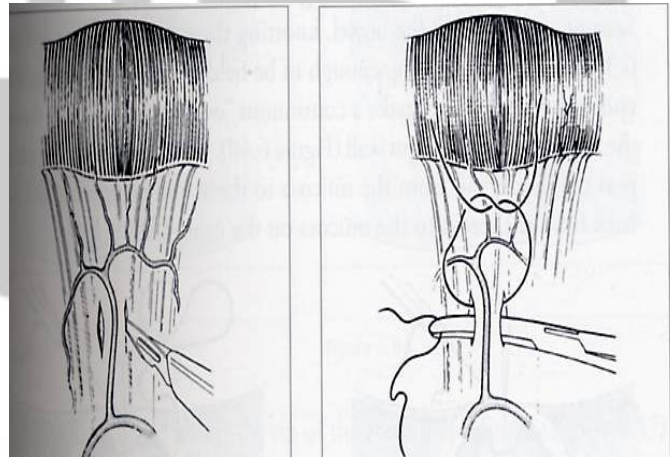


Figure 4:15

Clamp the bowel on both sides(See figure 4:16)

Non-crushing clamp to normal bowel

Crushing clamps to bowel to be resected

Essential Surgical Skills

Divide and remove the bowel (see figure 4:16 and 4:17)

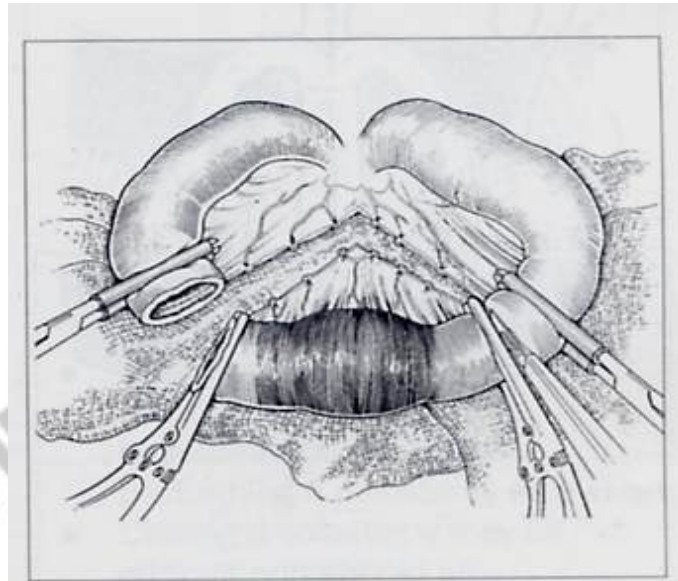


Figure 4:16

Anastomosis

- Use two layered technique
- Use 2/0 absorbable suture on half-circle atraumatic needle
- Bring together the occlusion clamps and hold them in opposition to hold opposed the cut ends of the bowels; check the proper orientation of the bowel (see figure 4:17)

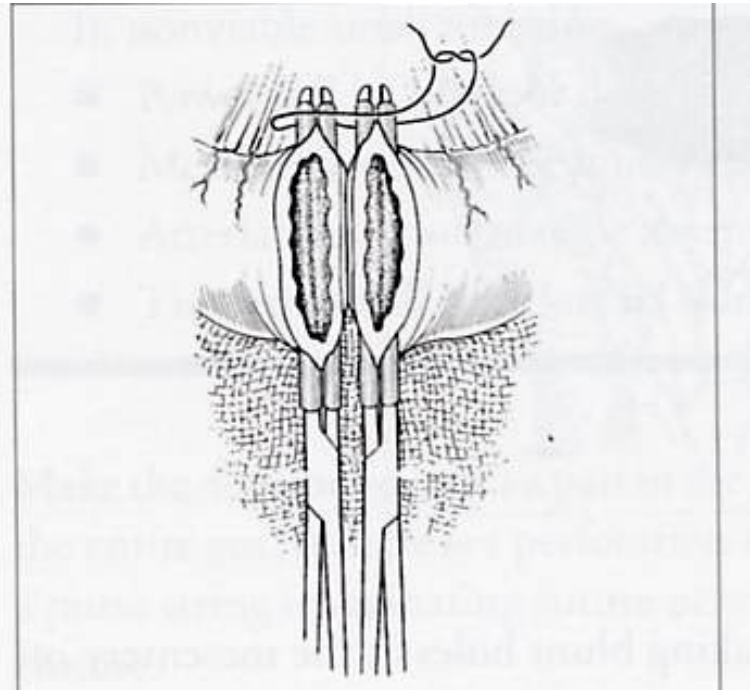


Figure 4:17

Steady the tissues by joining the cut ends with seromuscular stay sutures at each end of planned anastomosis (see figure 4:18)

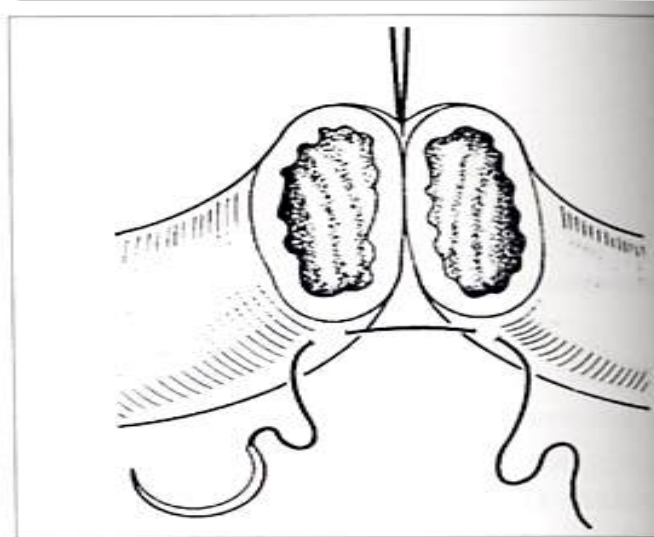


Figure 4:18

Essential Surgical Skills

Suture inner layer continuous suture by starting from one corner full thickness gut wall (see figure 4:19)

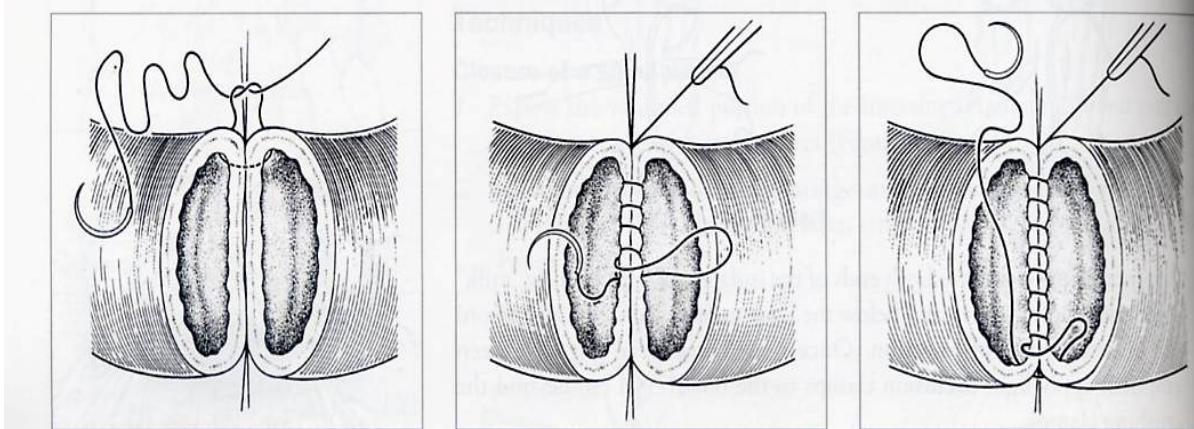


Figure 4:19

Place continuous suture seromuscular; circumferentially; covering the previous suture line. (See 4:20)

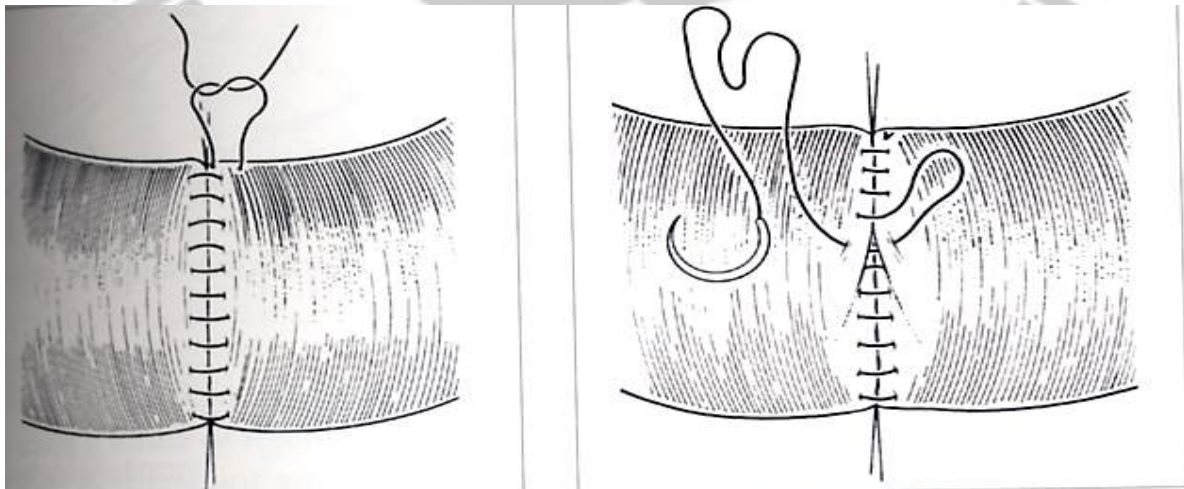


Figure 4:20

Essential Surgical Skills

Close the mesentery with interrupted 2/0 absorbable suture; do not puncture mesenteric vessels, check adequacy of the stoma by palpation, it should admit the tip of the thumb and finger (see figure 4:21)

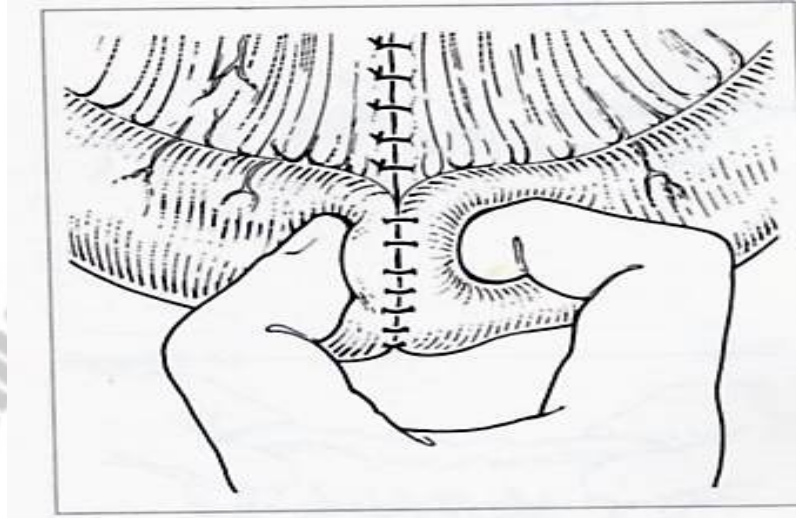


Figure 4:21

PRACTICAL SEESION 4:4

Colostomy

Indication

- Gangrenous sigmoid volvulus
- Colorectal cancer presenting with large bowel obstruction
- Traumatic perforation of left colon.

Selected colostomy: two types

- a) loop colostomy
- b) end colostomy

Essential Surgical Skills

Steps

- Do laparotomy
- Bring out the colon

Loop colostomy

Bring out the loop of colon with out kinking or twisting.(see figure 4:22)

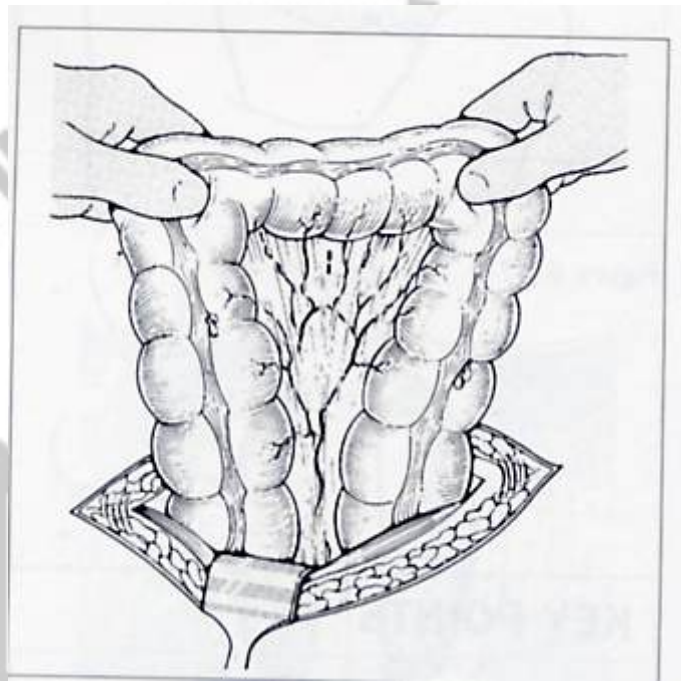


Figure 4:22

Make an opening in the mesocolon just large enough to admit pieces of glass rod; insert glass rod in the opening. Attach the ends to pieces of suction tube (see figure 4:23)

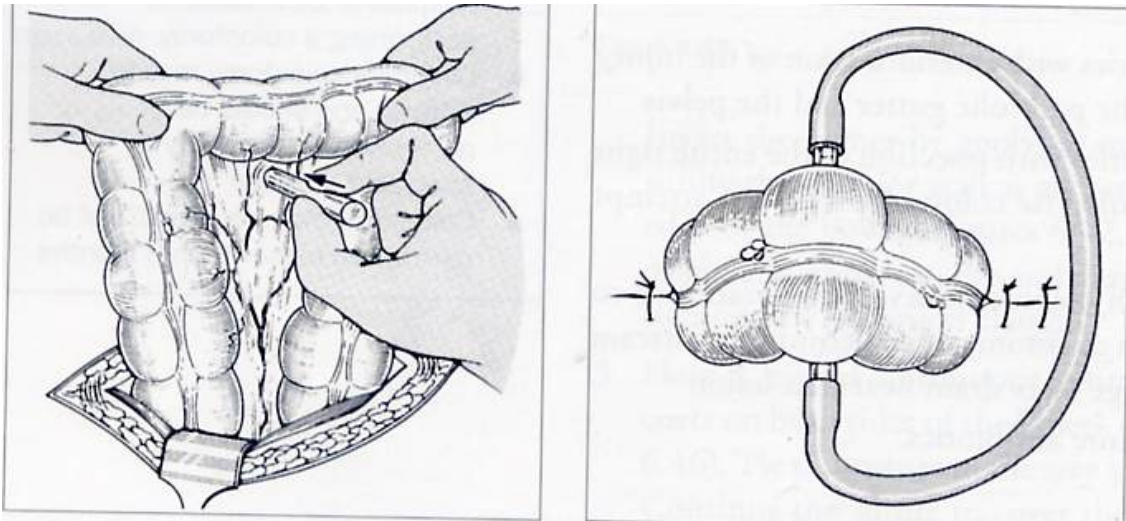


Figure 4:23

The colon is opened anteriorly and the margins are sutured to the abdominal wall (figure 4:24)

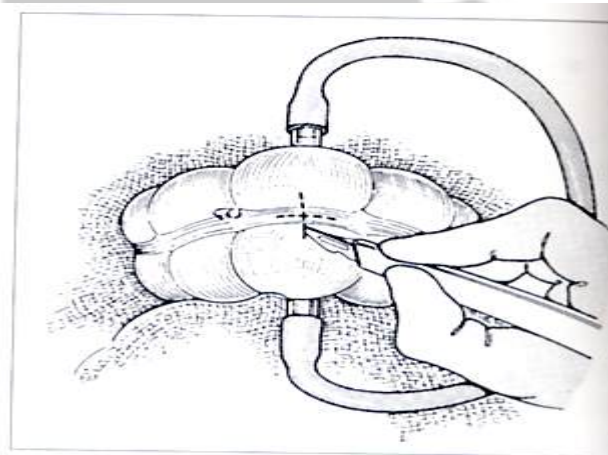


Figure 4:24

End colostomy

- Bring out the colon
- Resect gangrenous or injured part as described for resection of small intestine (see figure 4:25)

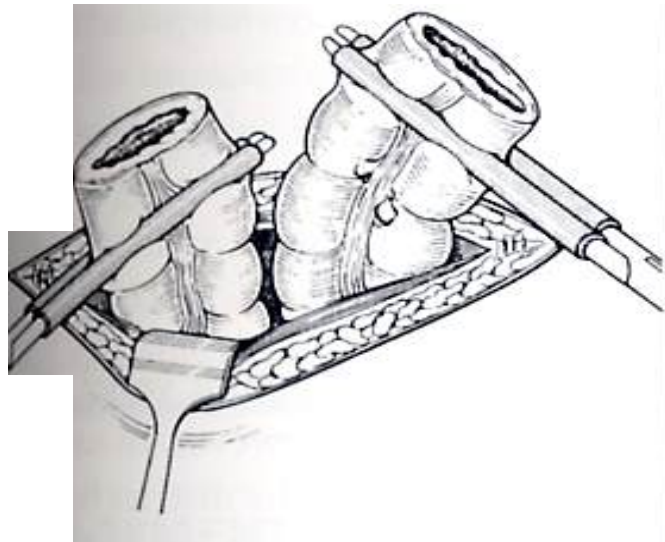


Figure 4:25

Close the distal stump of the colon in two layers (see figure 4:26)

- Inner continuous 2/0 absorbable suture
- Outer- interrupted 2/0 vicryl or non absorbable suture

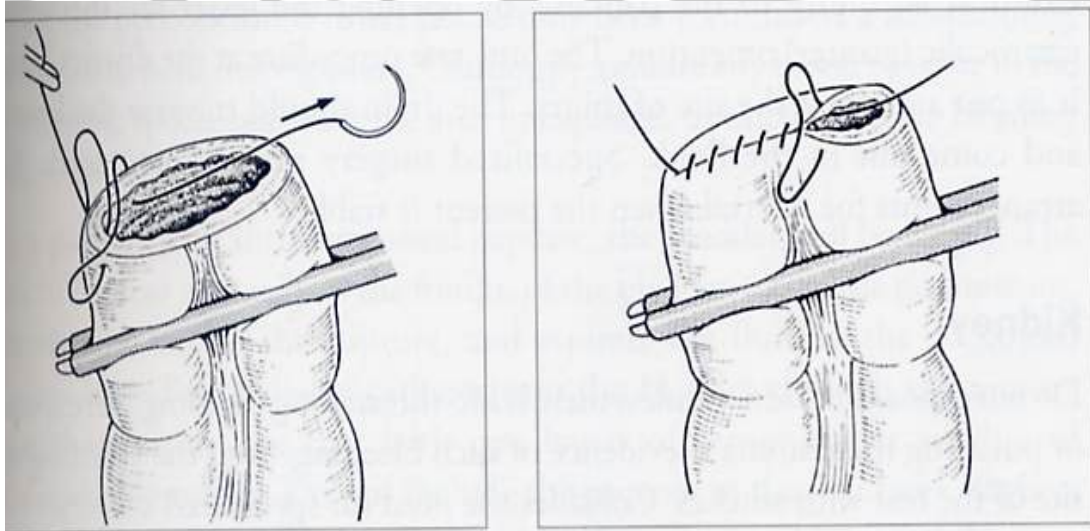


Figure 4:26

Essential Surgical Skills

Bring the proximal end as end colostomy and suture it to the skin(see figure 4:27)

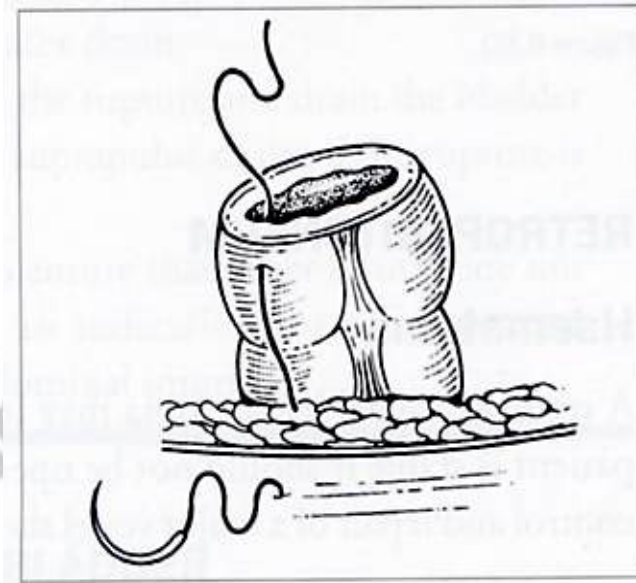


Figure 4:27

PRACTICAL SESSION 4:5

Drainage of perianal abscess

- Anesthesia – ketamine or pethidine + valium
- Local anesthesia

Make cruciate incision(see figure 4:28)

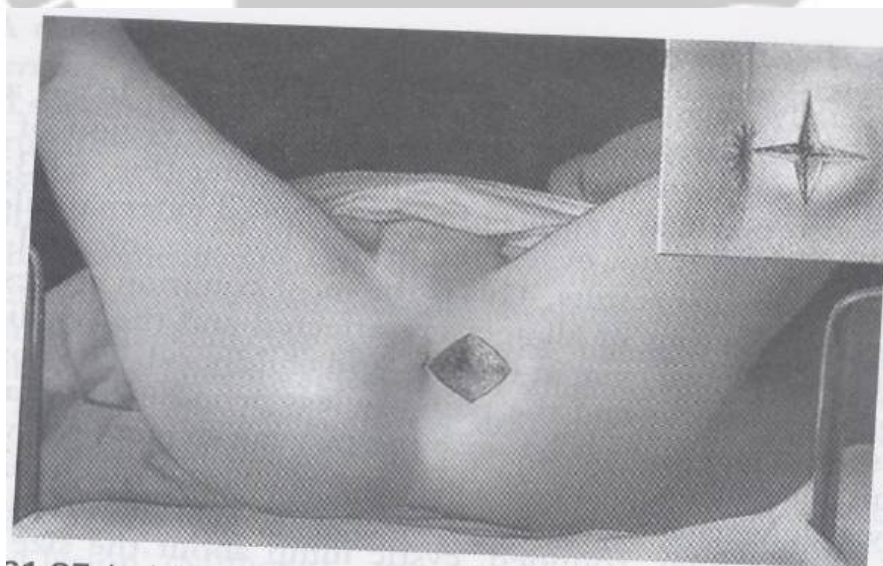


Figure 4:28

CHAPTER FIVE

UROLOGIC EMERGENCIES

Learning objectives

At the end of this practical session each student must be able to;

- Catheterise using bladder and urethral simulator
- Do percutaneous and open cystostomy
- Know principles of circumcision and dorsal slit

Retention of urine: causes, clinical feature and management

- Retention of urine can be acute or chronic

Acute retention

- Presents with inability to pass urine for several hours
- Usually associated with lower abdominal pain
- Bladder is visible and palpable
- Bladder is tender on palpation
- It is dull to percussion

Etiology

The common causes of acute urinary retention of urine in males are **urethral stricture** and **benign prostatic hypertrophy**.

Other causes include

- Rupture of the urethra
- Following spinal anesthesia
- Acute urethritis and prostatitis
- Blood clot in the bladder
- Calculus in the bladder
- Phimosis
- Neurogenic (injury or disease of the spinal cord)
- Fecal impaction in the rectum

Essential Surgical Skills

- Anal pain (haemorrhoidectomy)
- Prostatic carcinoma

Chronic retention

- Chronic retention is usually relatively painless
- High intra vesical pressure can cause hydronephrosis and renal impairment
- Can present as overflow incontinence
- Low pressure chronic retention presents with symptoms of bladder outflow obstruction
- Patients with chronic retention and renal impairment need urgent urological assessment and should be referred

Treatment

The correct treatment is to pass urethral catheter and to arrange further urological management.

Emergency drainage of the bladder in acute retention include

- Urethral catheterization
- Suprapubic cystostomy
 - Percutaneous cystostomy
 - Open cystostomy

Urethral catheterization is usually adequate, but cystostomy may become necessary for more prolonged drainage, for example after rupture of urethra and or if there is a urethral stricture with complications.

Case Scenario

1. A 65 years old man presented to a health center with a chief complaint of urinary retention of a day duration. He has history of poor urinary



PRACTICAL SESSION 5:1

Technique of Urethral catheterization in the male patient

1. Reassure the patient that catheterization is atraumatic and usually uncomfortable rather than painful. Explain the procedure.
2. Put on sterile gloves and, with sterile swabs, apply a bland antiseptic to the skin of the genitalia. Isolate the penis with a perforated sterile towel. Lubricate the catheter with generous amounts of lubricant

3. Check the integrity of the Foley catheter balloon. If you are right-handed, stand to the patient's right, hold the penis vertically and slightly stretched with the left hand, and introduce the Foley catheter gently with the other hand. (Figure 5:1.)

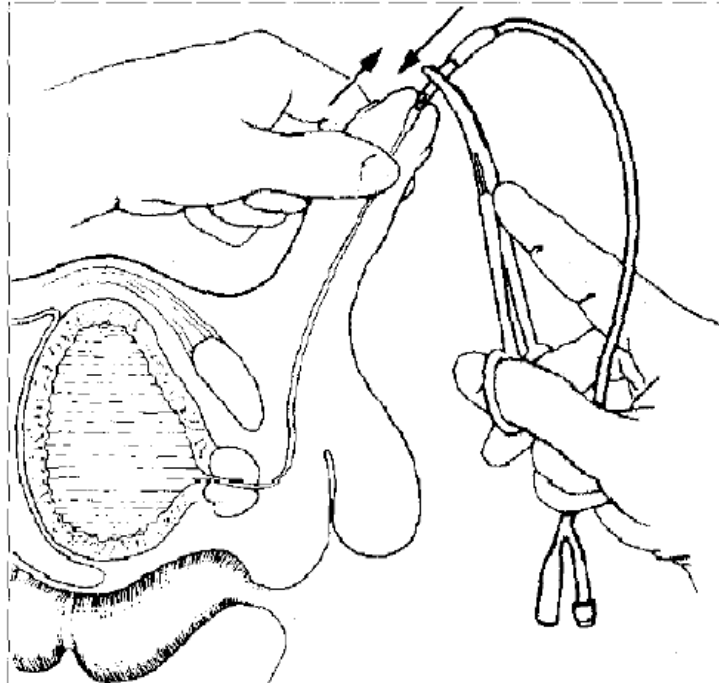


Figure 5:1.

At 12-15 cm, the catheter may stick at the junction of the penile and bulbous urethra, in which case angle it down to allow it to enter the posterior urethra. A few centimeters further, there may be resistance caused by the external bladder sphincter, which can be overcome by a gentle pressure applied to the catheter for 20-30 seconds. Urine escaping through the catheter confirms entry into the bladder.

Advance the catheter in full length before inflating the balloon. This prevents the balloon inflating in the prostatic urethra.

4. If the catheter fails to pass the bulbous urethra and the membranous urethra, try a semi-rigid Coude catheter.

Fixation of the catheter

1. If you are using a Foley catheter, inflate the balloon with 10-15ml of sterile water or clean urine (Figure 5:2.). Partially withdraw the catheter until its balloon abuts on the bladder neck.

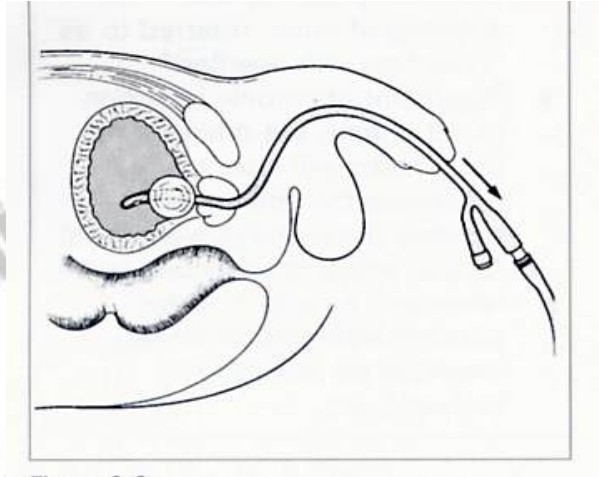


Figure 5:2

2. If the catheter has no balloon, knot a ligature around the catheter just beyond the external meatus and carry the ends along the body of the penis, securing them with a spiral of strapping brought forward over the glans and the knot (Figure 5:3, 5:4,5: 5.).

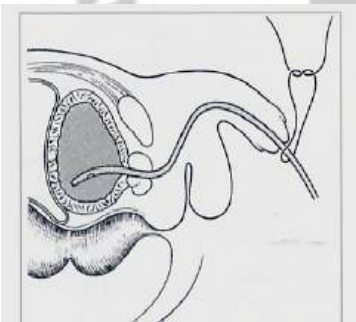


Figure 5: 3.

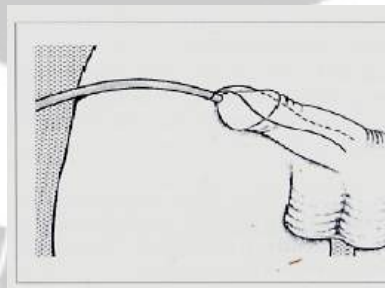


Figure 5: 4.

Figure.5:5.

Aftercare

- If the catheterization was traumatic, administer an antibiotic with a gram negative spectrum for 3 days
- Always decompress a chronically distended bladder slowly

Essential Surgical Skills

- Connect the catheter through a closed system to a sterile container (Figure 5:6)
- Change the catheter if it becomes blocked or infected, or as otherwise indicated every 2 to 3 weeks. Ensure a generous fluid intake to prevent calculus formation in recumbent patient, who frequently have urinary infections, especially in tropical countries.

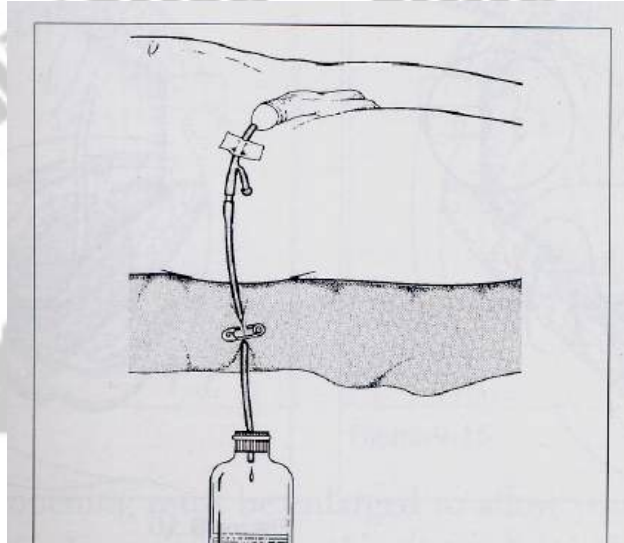


Figure 5:6

PRACTICAL SESSION 5:2

Percutaneous cystostomy

- Percutaneous cystostomy may become necessary if urethral catheterization fails or in cases of traumatic urethral injury.
- It is essential that the bladder is palpable if Percutaneous cystostomy is to be performed.

Technique

1. Assess the extent of bladder distension by inspection and palpation.
2. If you are proceeding to percutaneous cystostomy immediately after catheterization has failed, remove the perforated sheet that was used to isolate the penis and center the opening of a new sheet over the midline above the pubis.

Essential Surgical Skills

3. Infiltrate local anesthetic in the midline, 2 cm above the symphysis pubis, and then continue with deeper infiltration (Figure 5: 7).
4. Make a simple puncture 2 cm above the symphysis pubis in the midline
5. Introduce the trochar and cannula and advance them vertically with care (Figure 5:8). After meeting some resistance, they will pass easily into the cavity of the bladder, as confirmed by the flow of urine when the trochar is withdrawn from the cannula.

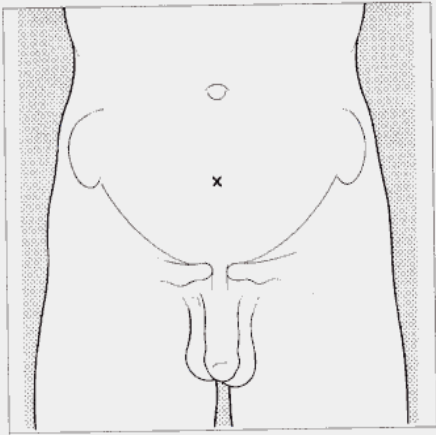


Figure 5:7.

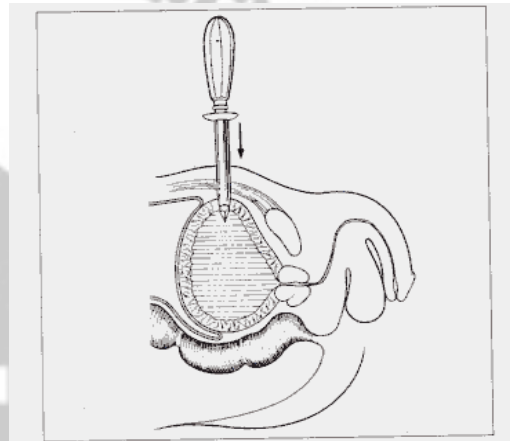


Figure 5:8.

6. Introduce the catheter well into the bladder (Figure 5:9). Once urine flows freely from the catheter, withdraw the cannula (Figure 5:10).

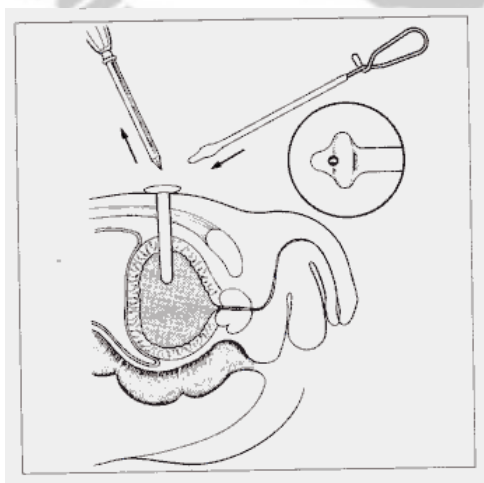


Figure 5:9.

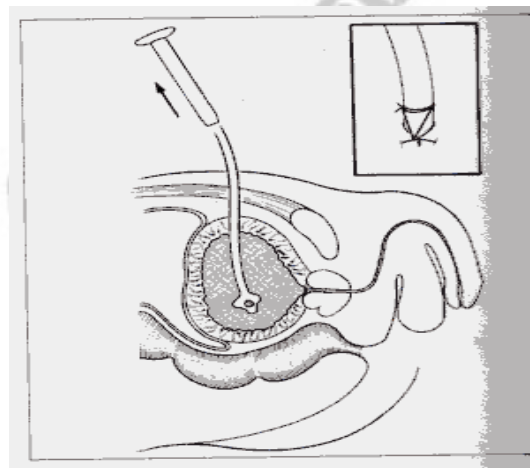


Figure 5:10.

7. Fix the catheter to the skin with the stitch used to close the wound and connect it to a bag or bottle. Take care that the catheter does not become blocked, especially if the bladder is grossly distended. If necessary, clear the catheter by syringing with saline.

PRACTICAL SESSION 5:3

Open cystostomy

The purpose of supra pubic cystostomy is:

- To permit insertion of a large drainage tube, usually a self-retaining catheter
- To allow supra pubic drainage of a non-palpable bladder

Technique

1. Use ketamine or spinal anesthesia,
2. Place the patient supine. Centre a midline suprapubic incision 2 cm above the symphysis pubis (Figure 5:11) and divide the subcutaneous tissues. Achieve hemostasis by pressure and ligation

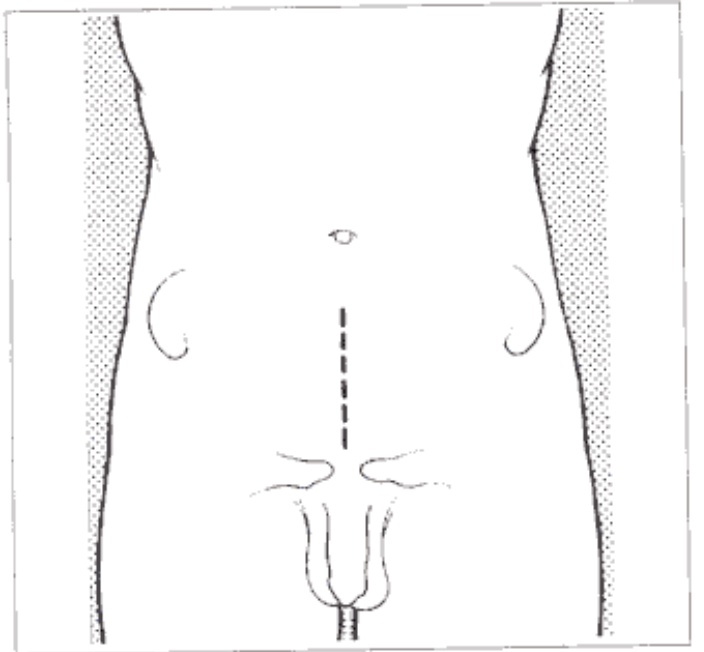


Figure 5.11

3. Open the rectus sheath, starting in the upper part of the wound. Continue dissection with scissors to expose the gap between the muscles (Figure 5:12). In the lower part of the incision, the pyramidalis muscles will obscure this gap. Finally, expose the extra peritoneal fat.

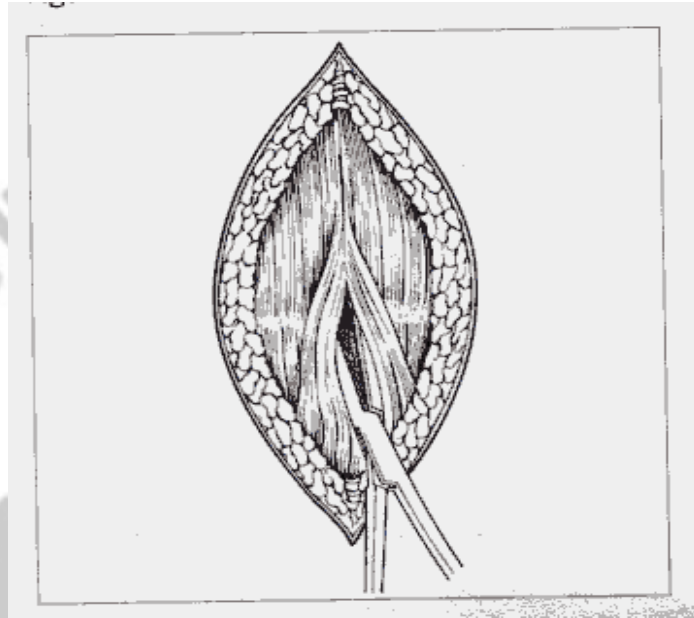


Figure 5.12

4. Carry the incision in the linea alba down to the pubis, splitting the pyramidalis muscles. With a finger, break through the pre vesical fascia behind the pubis; then sweep the fascia and peritoneum upwards from the bladder surface (Figure 5:13). Take care not to open the peritoneum.
5. The bladder is identified by the prominent blood vessel. On palpation, it has the resistance of a distended sac.
6. Insert a self-retaining retractor to hold this exposure (Figure 13). Aspirate with needle and syringe to confirm that it is a bladder.

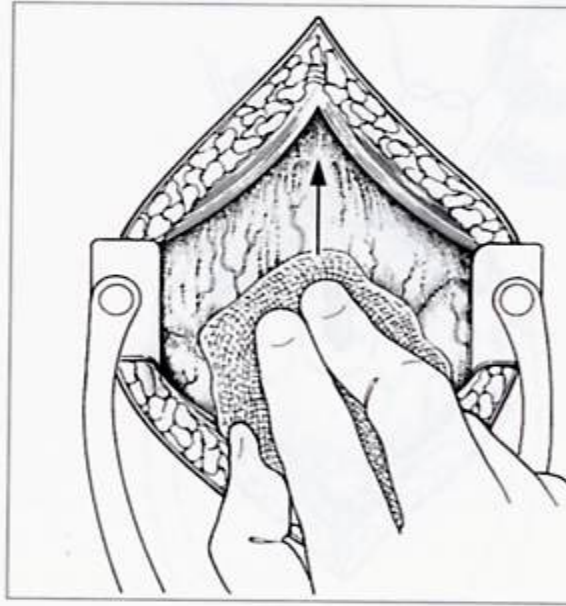


Figure 5:13

7. Insert stay sutures of No. 1 absorbable suture into the upper part of the bladder on either side of the midline (Figure 5:14).

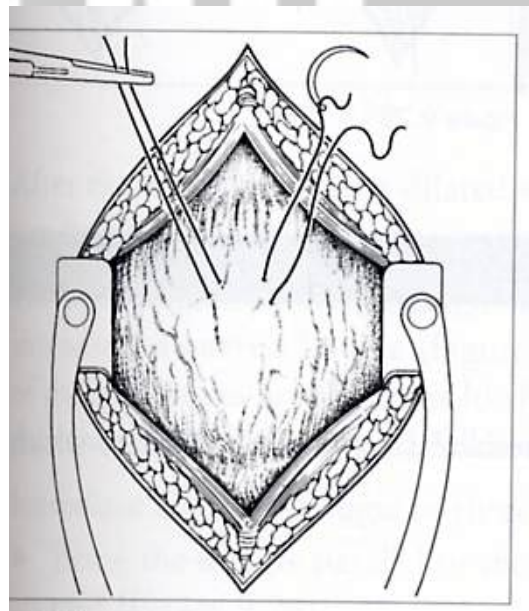


Figure 5:14

8. Puncture the bladder between the sutures and empty it by suction (Figure 5:15).

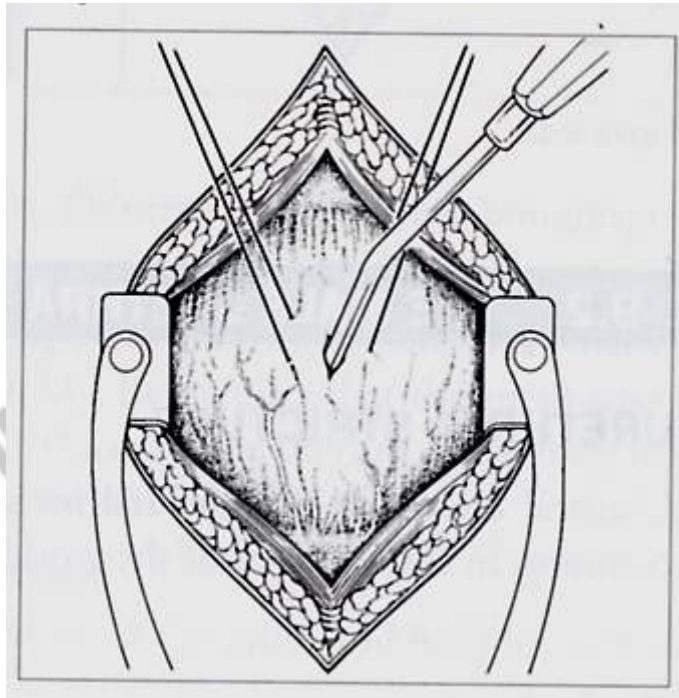


Figure 5:15

9. For insertion of the catheter, hold the edges of the incision with two pairs of tissue forceps, making sure that the mucosa is included so that the catheter does not slip beneath the mucosa (Figure 5:16)
10. Introduce the Foley catheter in the bladder and inflate the balloon.

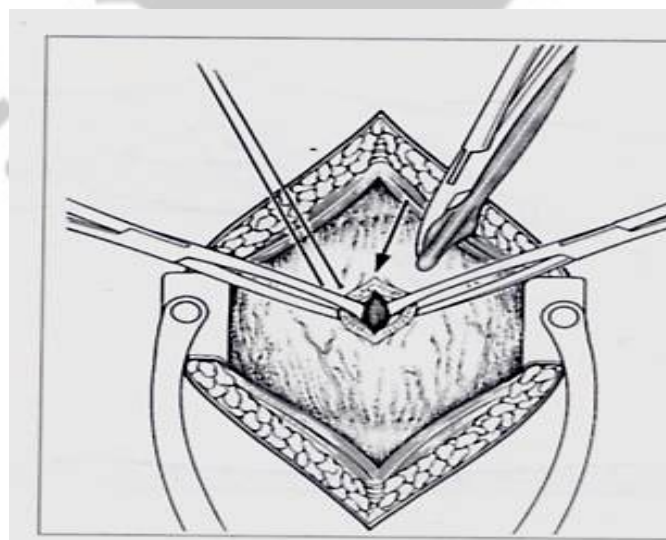


Figure 5:16

11. Insert a purse-string 2/0 absorbable suture in the bladder muscle to ensure a watertight closure around the tube or, if you have made an extended incision in the bladder, secure the catheter with the final stitch needed to close the incision (Figure 5:17).

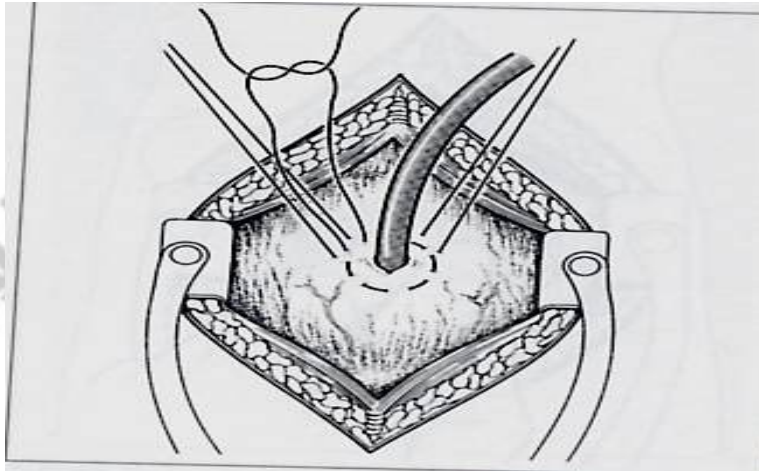


Figure 5:17

12. Close the linea alba with 0 absorbable suture and the skin with 2/0 non-absorbable suture (Figure 5:18). Connect the tube to a sterile, closed drainage system. Dress the wound every second day until it is healed.

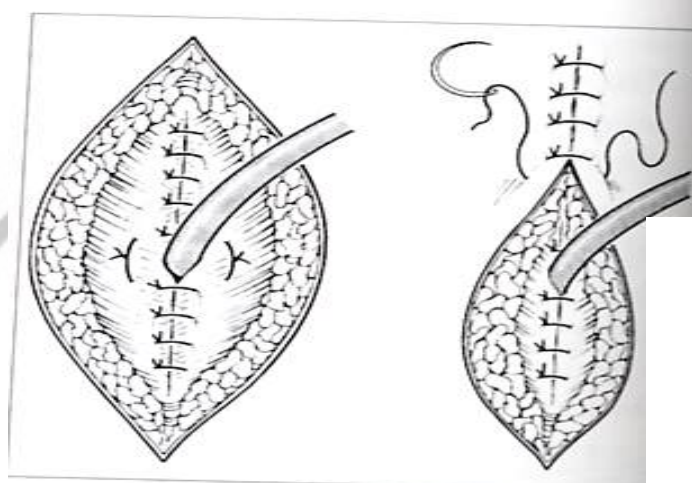


Figure 5:18

Circumcision, Phimosis and paraphimosis

Diseases of the penile foreskin include:

- Phimosis
- Paraphimosis

Phimosis

Phimosis is a condition in which the foreskin cannot be retracted behind the glans penis.

In males younger than 4 years, it is normal for the foreskin to be unretractable.

Phimosis usually not painful, but it may produce urinary obstruction with ballooning of the foreskin

It may also follow improper circumcision

Definitive treatment is circumcision

Treatment: circumcision

- The resection of the prepuce is the definitive surgical treatment.
- The purpose of the operation is to resect the prepuce obliquely at the level of the corona of the glans, allowing the glans to be fully exposed while preserving enough of the frenulum to permit erection.

Case Scenario

A 4 years old child presented with difficulty of urination of a month duration He has history of circumcisions by local healer 4 months back. The mother didn't see the gland penis since he was circumcised. She also noticed ballooning at the tip of the shaft of penis whenever he tries to urinate

- a. What is the possible diagnosis?
- b. How do you treat him?
- c. Can he have the same problem even if he is not circumcised?

PRACTICAL SESSION 5:4

Circumcision

1. Prepare all the external genitalia with an antiseptic. If the prepuce can be retracted, carefully clean the glans and the preputal furrow with soap and water.

Essential Surgical Skills

2. If the prepuce cannot be retracted, gently stretch the preputial opening by inserting the blades of a pair of artery forceps and slowly opening them until the area can be properly cleaned (Figure 5:19)

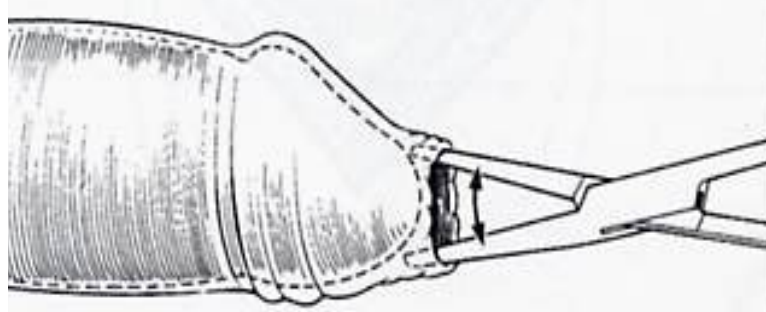


Figure 5:19

3. Break down any fine adhesions between the glans and replace the prepuce. Isolate the penis with a perforated towel.
4. Dorsal nerve block is undertaken using local anesthetic without adrenaline. Never use local anesthetic with adrenaline
5. Take hold of the prepuce dorsally in the midline with pairs of forceps and cut down between the forceps with scissors until the blades nearly reach the corona (Figures 5:20, 5:21)

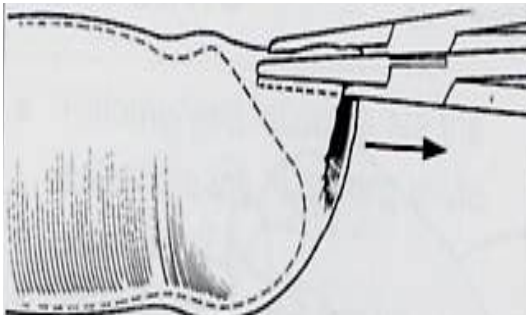


Figure 5:20

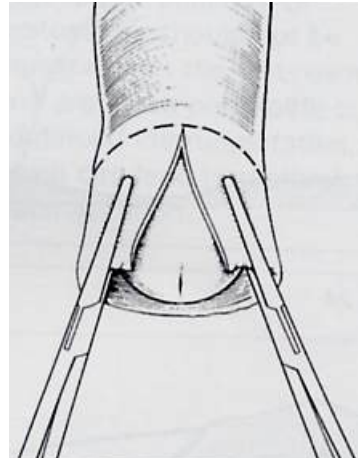


Figure 5:21

6. Check that the lower blade really is lying between the glans and prepuce and has not been inadvertently passed up the external meatus. Then excise the prepuce by extending the dorsal slit obliquely around on either side to the frenulum, and trim the inner preputial layer, leaving at least 3 mm of mucosa (Figure 5:22).

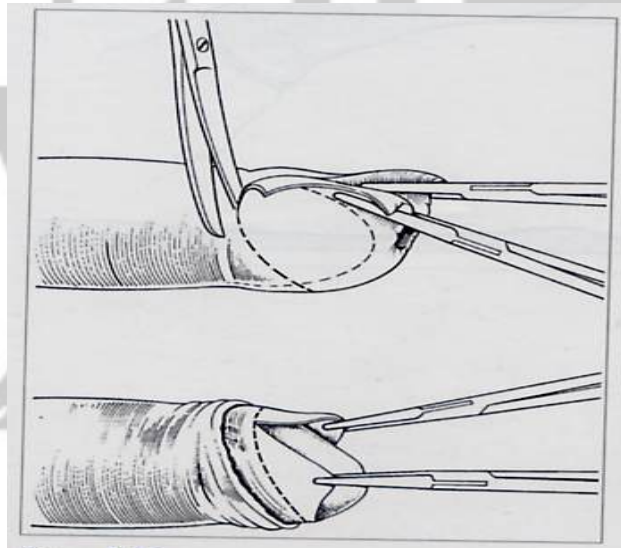


Figure 5:22

Essential Surgical Skills

7. Catch the cut edges of the frenulum and the bleeding artery of the frenulum with absorbable suture, leaving the suture long as a traction stitch to steady the penis (Figure 5:23).

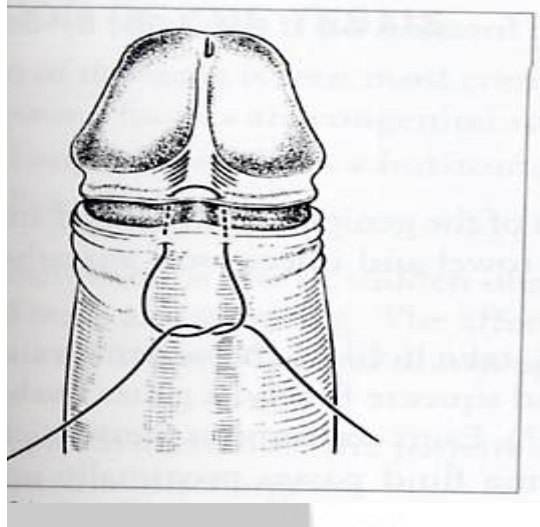


Figure 5:23

8. Insert a similar traction stitch to unite the edges of the prepuce dorsally (Figure 5:24).

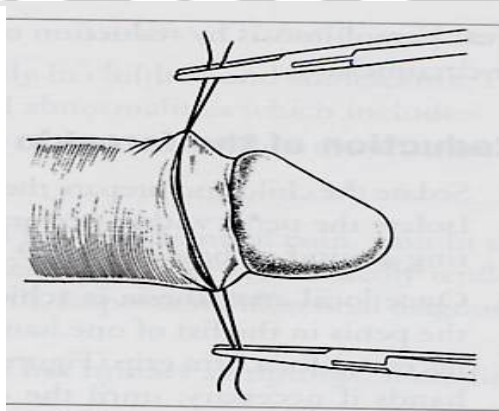


Figure 5:24

9. Catch and tie any bleeding vessels on either side of the raw area. Unite the edges of the prepuce with interrupted stitches and cut the stitches short (Figure 5:25 & 5: 26).

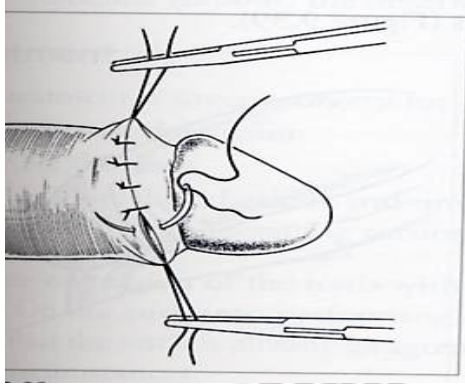


Figure 5:25

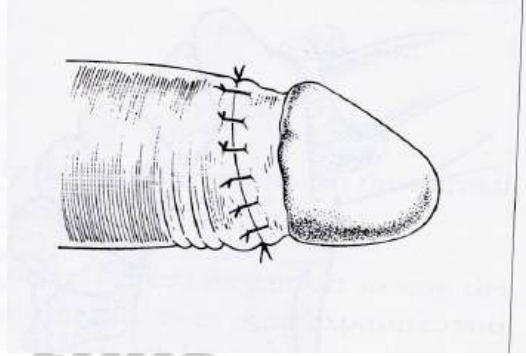


Figure 5:26

Aftercare

Dressing the penis with loose layers of petroleum gauze covered with dry gauze is optional.

Complications

- Bleeding
- Hematoma

Paraphimosis

- Paraphimosis is a condition in which the foreskin has been retracted and left behind the glans penis, constricting the glans and causing painful vascular engorgement and edema.
- Paraphimosis can result in marked swelling of the glans penis such that the foreskin can no longer be drawn forward, necessitating an emergency dorsal slit or circumcision
- Diagnose it by recognizing a retracted, swollen and painful foreskin. The glans penis is visible, and is surrounded by an oedematous ring with a proximal constricting ring (Figure 5:27).

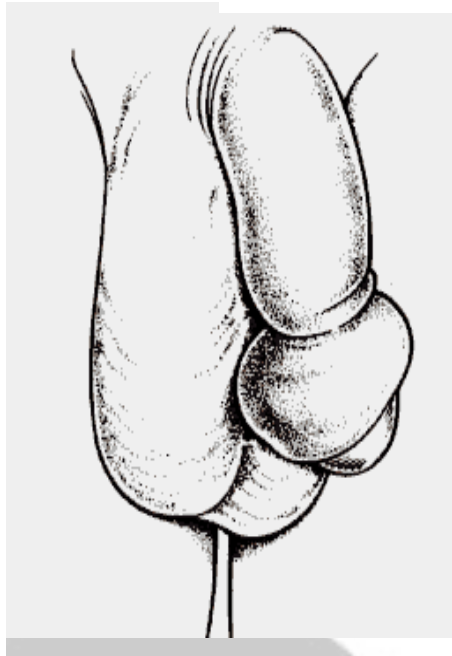


Figure 5:27

- Phimosis and paraphimosis are definitively treated with circumcision
- Dorsal slit can be performed with direct infiltration of the foreskin with xylocaine 1% without epinephrine (adrenaline)
- Clamp the foreskin with two artery forceps and make an incision between them (Figure 5:28)

PRACTICAL SESSION 5:5

Dorsal slit

Use local anesthesia

Incise the constricting ring as seen in figure 5:28

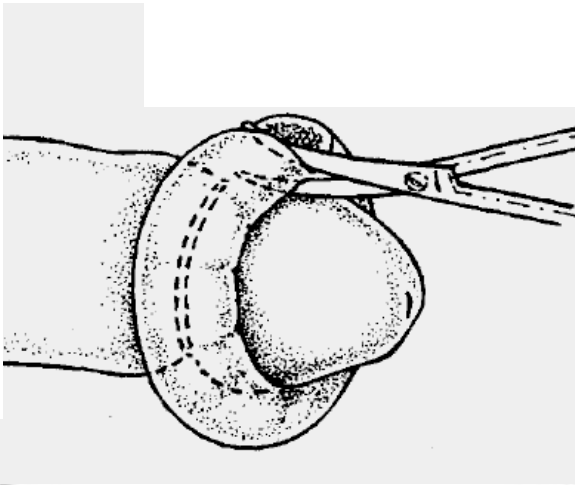


Figure 5:28



CHAPTER SIX

OBSTETRIC EMERGENCIES

Learning objective

At the end of this chapter the student should be able to do;

- To conduct normal delivery on a manikin
- Vacuum extraction
- Forceps delivery
- Cesarean section on beef's heart

Obstructed Labor

Definition: Failure of descent of the fetus in spite of good uterine contraction for a mechanical reason. It is preventable complication.

Causes

1. CPD
2. Malpresentation & Malpositions
 - Breech
 - Transverse Lie
 - Brow presentation
 - Mentoposterior
 - Occiputoposterior
3. Impacted shoulder
4. tumor previa
5. Abnormalities of vagina and uterus

Clinical diagnosis

- History of prolonged and difficult labor
- Sign of dehydration, acidosis
- tachycardia, hypotension, fever
- distended abdomen, three tumor

Essential Surgical Skills

- Edematous vulva, and cervix
- Excessive caput, molding over fetal head
- Offensive discharge and bleeding
- Difficult to catheterize bladder
- Fetal distress or death

Complications

Acute complication

- **Protracted and arrested active 1st stage of labor**
- Fetal Asphyxia
- Cerebral birth trauma
- Septicemia and shock
- Peritonitis with abscess formation
- Atonic PPH
- Rupture of genital tract

Chronic complication

- Pressure necrosis
- Vesico vaginal fistula
- Recto vaginal fistula
- Contracture and stenosis of vagina
- Foot drop
- Psychological trauma
- Ostitis pubis
- Amenorrhea, Sheehan's syndrome
- Infertility
- Dysparunia

Essential Surgical Skills

- Fistula is common in primigravid while uterine rupture is common in multigravid

Management

1. Prevention
2. Resuscitation
3. Operative delivery
4. Destructive operations

Case Scenario

A 23 years old primigravid who is living in a village 50 kms away from a hospital came with a complaint of pushing down sensation of 5 days duration. She was ammenorhic for the last 9 months.

Physical examination: Blood pressure 100/70

PR: 112

38 week gravid uterus

FHB is 112 beats per minute

Cervix fully dilated, station + 2

Excessive capute and molding

1. What is the possible diagnosis?
2. What recitatives measure should be taken?
3. What should be the mode of delivery?

FORCEPS

A forceps is an instrument designed to aid in the delivery of the fetus by applying traction to the fetal head. (Fig 6:1)

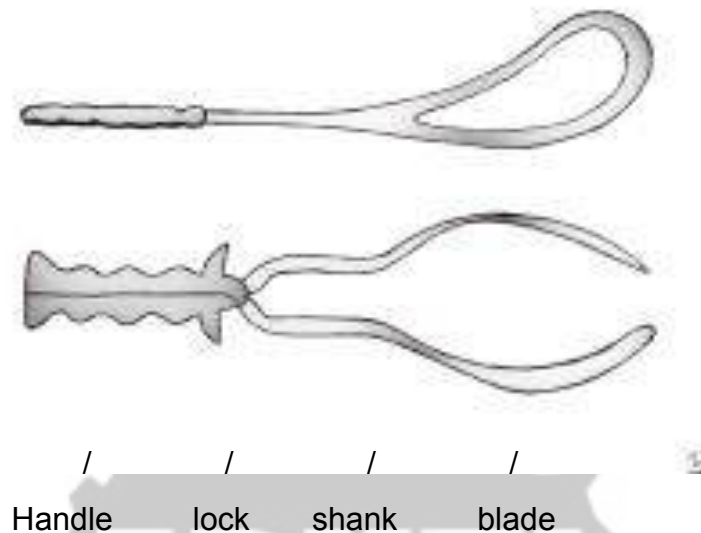


Figure 6.1

Indications

- Prolonged second stage
- Suspicion of immediate or potential fetal compromise
- Shortening of the second stage for maternal benefits
- Exhaustion, bleeding, cardiac or pulmonary disease
- Fetal malpositions, including the after-coming head in breech vaginal delivery

Prerequisites for forceps delivery

- The head must be engaged.
- The cervix must be fully dilated
- The position of the head must be known.
- The membranes must be ruptured.
- Bladder should be emptied

Application of the forceps

- *Two types*
- **Cephalic**

The most crucial point of forceps delivery is the precise knowledge of the presentation and the fetal head position.

- **Pelvic**

Pelvic application

- The term pelvic application is used when the left blade is applied to the left side of the pelvis and the right blade is applied to the right side of the pelvis irrespective of the position of the presenting part
- It may be injurious to the fetus and mother.

The three checks

- The median angle of the posterior fontanel should be located halfway between the blades and approximately 1-1.5 cm above the plane of the shanks
- The sagittal suture is perpendicular to the plane of the shanks
- Only 1-1.5 cm of the blade should be palpable beyond the fetal skull (the space between the fenester and the skull should not admit more than one finger)

Maternal complications

- **Early (acute) complications include**
 - Lacerations to the cervix, vagina, perineum, or bladder
 - Extension of episiotomies
 - Increase in blood loss
 - Hematomas; and
 - Intrapartum rupture of the unscarred uterus.

Essential Surgical Skills

- **Late complications mainly are related to injury to the pelvic support tissues and organs and include**
 - Urinary stress incontinence
 - Fecal incontinence
 - Anal sphincter injuries, and
 - Pelvic organ prolapse

Fetal complications

Transient facial forceps marks,

- Bruising, lacerations, and cephalohematomas.
- Skull fractures, intracranial hemorrhage with falx, or tentorial lacerations
- Cerebral palsy,
- Mental retardation, and
- Behavioral problems tend to be more related to hypoxic episodes or other intrapartum, environmental, or congenital factors.

PRACTICAL SESSION 6:1

Forceps delivery

The left
handle held in the
left hand
Left blade in place;
introduction of

(fig 6:2)

the right blade by the right hand

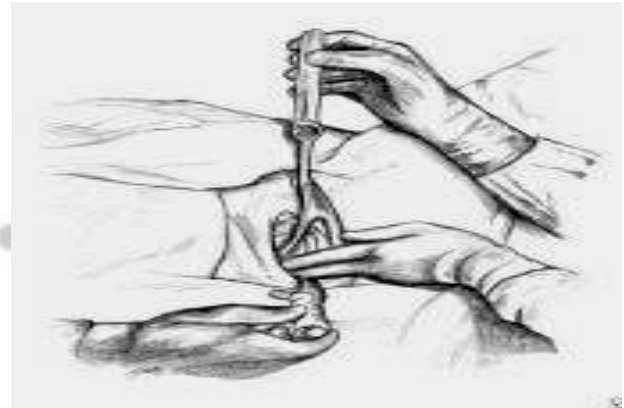
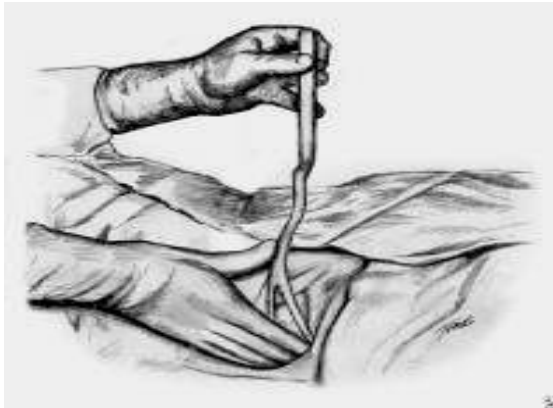
Figure 6.2

Figure 6.3

A median or mediolateral episiotomy may be performed at this point. A left mediolateral episiotomy is shown here (fig 6.4)

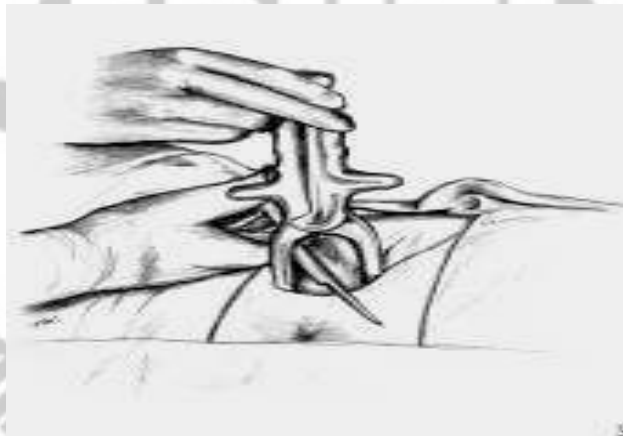

Figure 6.4

The forceps have been locked. The inset shows a left occipitoanterior fetal position (fig 6:5)



Figure 6.5

Horizontal traction with f

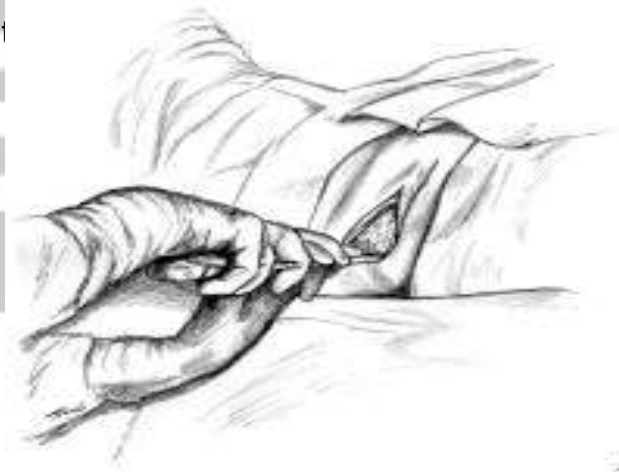

Figure 6.6

Upward traction (fig 6:7)

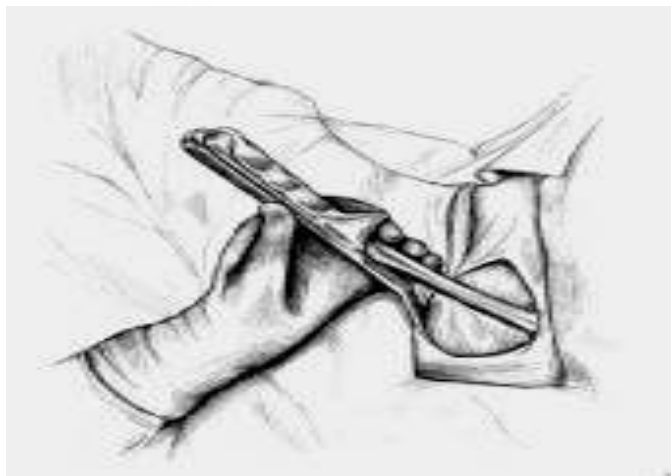

Figure 6.7

Disarticulation of the branches of the forceps; beginning modified Ritgen maneuver (fig 6:8)

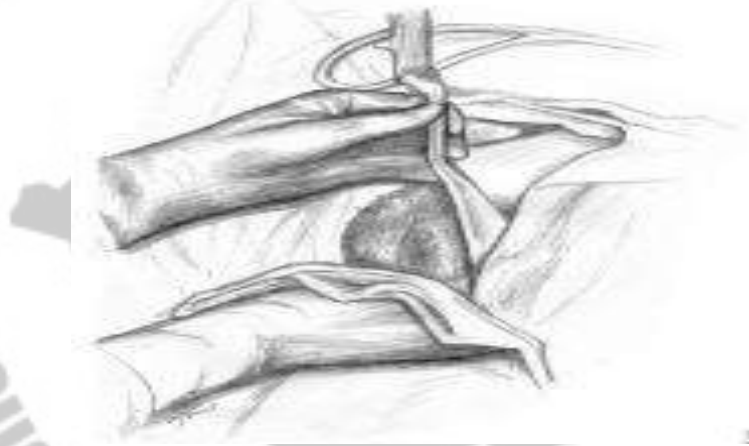

Figure 6.8

PRACTICAL SESSION 6: 2

Vacuum Extractor (Ventous)

- The classic instrument consists of a disc shaped cup through which a vacuum of up to 0.8 kg/CC² is applied to the fetal scalp(fig 6:9)



Figure 6.9

- Creates an artificial caput (chignon) through suction and application of metallic or plastic cup that holds firmly and allows adequate traction
- In general, VE operations have similar indications as operations with forceps.
- An advantage of VE may be that it could be done with minimal maternal analgesia

Currently available instruments

- Metal cups in 3 sizes (40,50,60 mm)
- Silastic cups which are cone shaped
- Manually or electrically operated vacuum sources are available

Indications

- Essentially the same with that of forceps

Contraindications to vacuum extraction

- Operator inexperience
- Inability to achieve a proper application
- Inadequate trial of labor
- Uncertainty concerning fetal position/station
- Suspicion of feto-pelvic disproportion
- High fetal head
- Malpositioning (eg, breech, face, brow)
- Known or suspected fetal coagulation defect
- Prior failed forceps

Relative contraindications

- Prematurity (fetuses <36 wk gestation)
- Prior scalp sampling

Mandatory prerequisites

- Cervix dilated more than 8 cm (preferably fully)
- The head must be engaged.
- The position of the head must be known
- The membranes must be ruptured
 - No disproportion should be suspected between the size of the head and the size of the pelvic inlet and mid pelvis.
 - The patient must have adequate anesthesia/analgesia.
 - Adequate facilities and supportive elements
 - The operator should be fully competent in the use of the instruments and the recognition and management of potential complications.
 - Bladder should be emptied

Complications

- **Neonatal injury**
 - Subgaleal/subaponeurotic hemorrhage
 - Scalp bruising/lacerations
 - Long-term neonatal outcomes
- **Maternal injury**
 - Lacerations

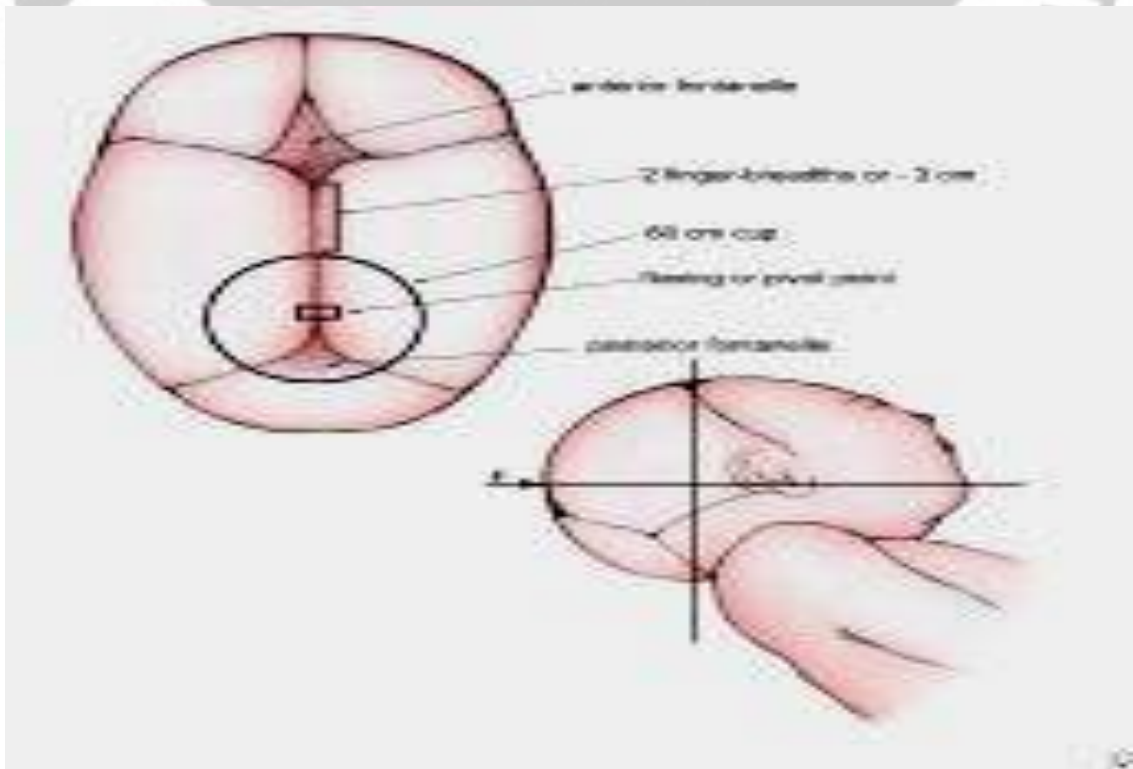


Figure 6.10

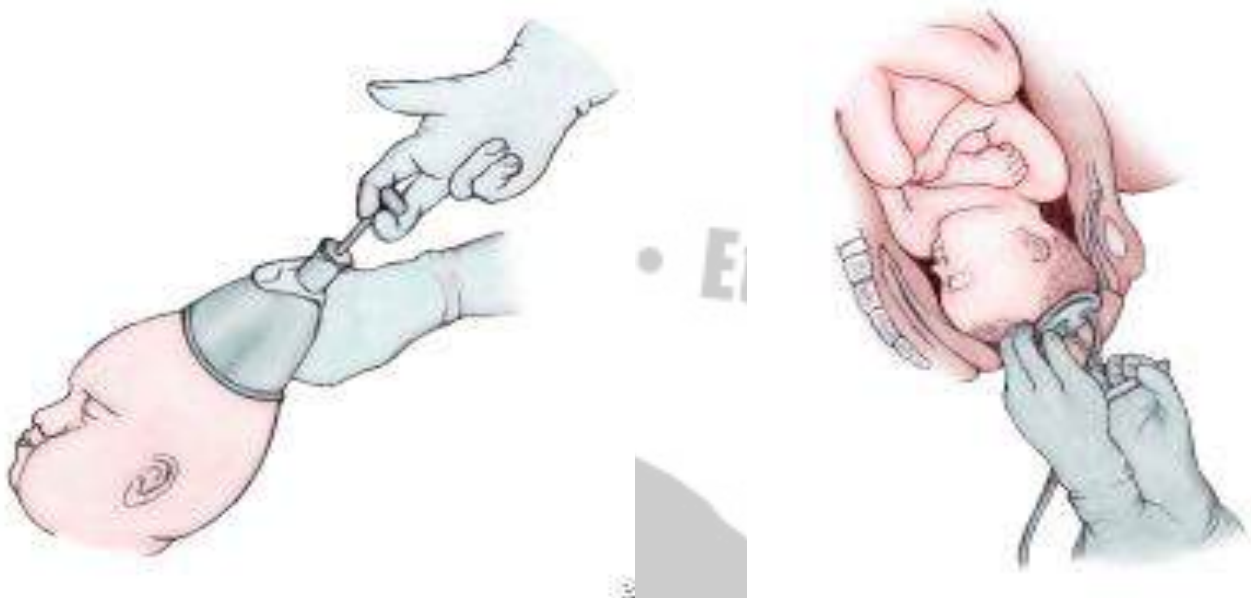

Figure 6.11 axis of traction

Figure 6.12 support the cup throughout the pull

PRACTICAL SESSION 6:3

Cesarean section

Cesarean section is making an abdominal incision and uterine incision to deliver a fetus

Type

- Elective
- Emergency

Indication: There are maternal and fetal indication to do cesarean section

Fetal Indication

- Prolapsed cord
- Macrosomic
- Malpresentation /malposition
- Fetal distress
- Breech
- Other

Maternal Indication

- Cephalopelvic disproportion
- Two or more prior C/S
- Major degree of placenta previa
- Dystocia
- Previously repaired VVF
- Obstructing tumors, like myoma, ovarian tumor

Pre operative care

- Should be done in the morning in case of elective cesarean section
- Lab investigations (Hemoglobin and BG/RH)
- Get written informed consent
- Mild sedation unless contraindicated
- Keep the mother NPO after mid night
- Start IV fluid in the morning
- Administer prophylactic antibiotics
- Transfer the mother to operation theater with stretcher in lateral position
- Instruct the mother to void just before the procedure or catheterize

Abdominal incision

■ **Types**

- Pfannensteil incision, cosmetic, less dehiscence
- Midline incision fast, easy, less bleeding, exposure is good

Uterine incision

Lower transverse

Opening the uterus

1. Use a scalpel to make a 3 cm transverse incision in the lower segment of the uterus, about 1 cm below the level where the vesico-uterine serosa was incised to bring the bladder down.
2. Widen the incision by placing a finger at each edge, and by pulling up and laterally at the same time. If the lower uterine segment is thick and narrow, extend the incision using scissors instead of fingers in a crescent shape to avoid extension to the uterine vessels.

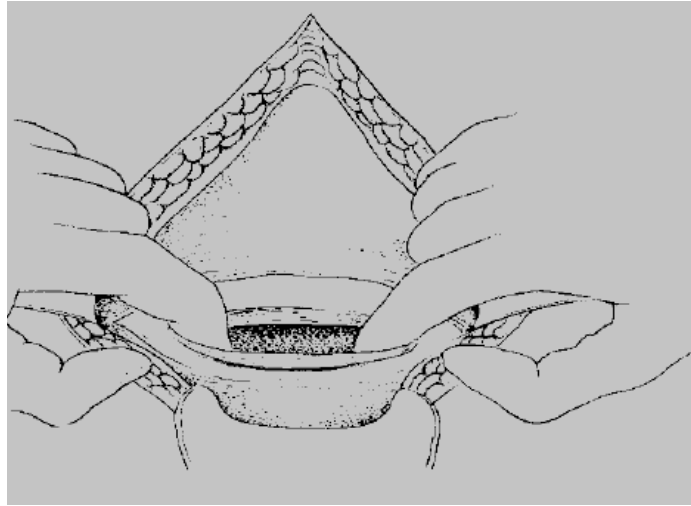


Figure 6.13

Closing the uterine incision

1. Grasp the corners of the uterine incision with clamps.
2. Grasp the bottom edge of the incision with clamps. Make sure it is separate from the bladder.
3. Look carefully for any extensions of the uterine incision.
4. Repair the incision and any extensions with a continuous locking stitch of 0 chromic non absorbable (or polyglycolic) suture.
5. If there is any further bleeding from the incision site, close with figure- of eight sutures. There is no need for a routine second layer of sutures in the uterine incision.



Figure 6.14

Complications

- Anesthesia related complications
- Hemorrhage
- Puerperal sepsis
- Thromboembolisms
- Trauma to genital tract
- Low APGAR

CHAPTER SEVEN

ORTHOPEDIC EMERGENCIES

Learning objectives

At the end of the chapter the student should be able to:

Apply bandage

Apply and remove POP on upper and lower limb of his colleague

Do skin and skeletal traction on simulator (bamboo or sugarcane)

Do amputation on simulator (bamboo or sugarcane)

Part I Fractures:

Limb (extremity) Fractures

Causes

- Fall
- Motor vehicle accident
- Homicidal (Quarrels)

Classification

- Open (Compound) or closed
- Transverse, Oblique or spiral
- Displaced or undisplaced
- Pathological (Underlying bone disease)

Diagnosis

- History- mechanism of injury
- Physical examination- deformity, abnormal movement, visible bone
- X-rays in two views

Principles of management

- ABC rule
- Reduction
 - if indicated and usually under general anesthesia

Types

Essential Surgical Skills

- Closed manual manipulation
- Open (Operative)
- Traction
- Immobilization
 - Splints, Bandages and Plaster Of Paris (POP)- for many common fractures and also whenever patient is referred
 - Traction
 - Operative- Internal and External Fixation
- Rehabilitation
 - Physiotherapy

Complications of Fracture

- Malunion
- Delayed union
- Non-union
- Osteomyelitis
- Compartment syndrome

Common Specific fractures and dislocations

1. Fracture of the clavicle

- Common in children
- Require no X-ray for diagnosis
- Chest x-ray may be needed to rule out pneumothorax
- can be treated by arm neck triangular splint (fig 7:1)



Figure 7.1

2. Shoulder dislocation

- Commonest dislocation
- Reduction is best done by Hippocrates's maneuver under GA or pethidine (fig 7:2) or Kocher's maneuver
- Has been successfully reduced when the hand can rest on the opposite shoulder
- immobilize with elastic bandage afterwards

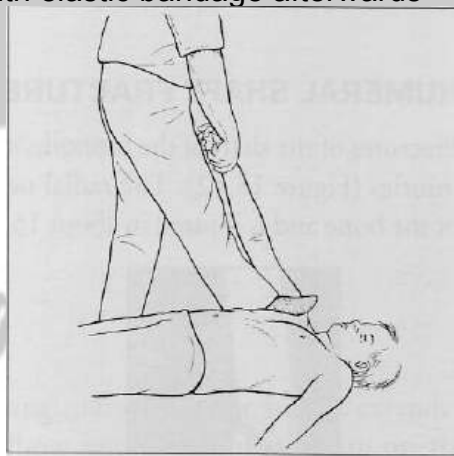


Figure 7.2

3. Subcapital humerus fracture

Essential Surgical Skills

- Is commonly at the surgical neck
- Commoner in the elderly
- Displacement is minimal
- Can be treated by immobilizing the affected arm with the chest wall using sling and elastic bandage (Desault) for three weeks

Chest- Arm Bandage (Desault) (fig 7.3)

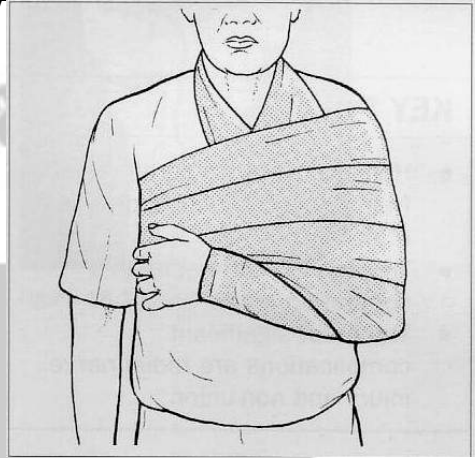

Figure 7.3

4. Humeral shaft (diaphysis) fracture

- Occurs after fall on out stretched arm
- Can be complicated by injury to the radial nerve
- In open fractures (bullet) the brachial artery can be injured
- Treatment is best done by immobilizing the affected arm with the chest wall (Desault)
- U- slab can be applied for distal shaft fracture
- Heavy hanging cast can lead to destruction and pseudoarthrosis

5. Supracondylar fracture of the humerus

- Common in children (7 up to 12 years)
- Condyle is displaced posteriorly and cranially
- Reduction by closed manual reduction could be very difficult
- Best treated by internal fixation if closed reduction fails

6. Elbow dislocation

Essential Surgical Skills

- May be associated with fracture
- Can be diagnosed due to the loss of triangular relationship of the epicondyles and the olecranon
- Elbow remains extended
- Can be easily reduced under anesthesia if the patient comes to the health center early
- If the patient comes after weeks or months the only option is operative treatment

7. Radio-ulnar fractures

- Displacement is common
- Internal fixation (plating) is the only option in the majority of adult fractures
- In children, reduction under GA and long arm POP could be applied

8. Distal radial fracture

- Very common fracture in the elderly women
- Can be classified as Colle's (commonest), Barton's or Smith's fracture
- Displacement is common and needs closed manual reduction under GA
- Immobilization is done by forearm POP

Reduction under GA

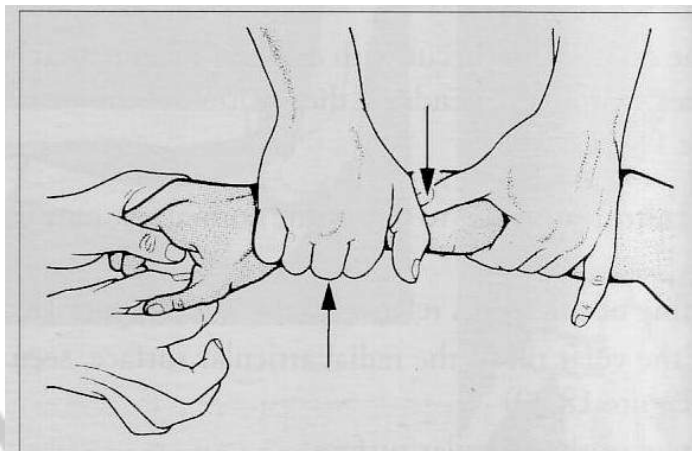


Figure 7.4

9. Fracture of the femur bone

- Very common both in adults and children
- Conservative treatment by traction has poor outcome except in children
- Internal fixation by nailing or plating is usually indicated
- In open fractures external fixation may become the only option

10. Femur neck fracture

- Commonly affects elderly women (osteoporosis)
- Can lead to avascular necrosis or pseudoarthrosis
- Might be treated by skeletal traction for more than 10 weeks
- In the developed world semi-emergency internal fixation is done to avoid complications of long time immobilization
- If the fracture is between the trochanters (intertrochanteric) prognosis is better

11. Subtrochanteric and proximal shaft fracture of the femur

- Liable to significant displacement
- If treated with out operative means (traction), the outcome will be angulated femur leading to disability or even refracture)
- Best treated by intramedullary nailing or plating

12. Transverse midshaft fracture of the femur

- Common in children and can be treated well with skin traction

Essential Surgical Skills

followed by hip spica POP

- Distal femoral skeletal traction can be applied in adults
- Follow-up for alignment and proper healing is very essential
- Healing with out angulation is very vital for future function

13. Supra-condylar fracture of the femur

- Displacement is the usual feature
- Injury to the popliteal artery is one important complication
- The best treatment is internal fixation

14. Patellar fracture

- Is transverse if it results from muscle pull
- Comminuted fracture results from direct trauma
- Undisplaced fracture can be treated by cylindrical POP
- However, mostly internal fixation is indicated

Cylindrical cast

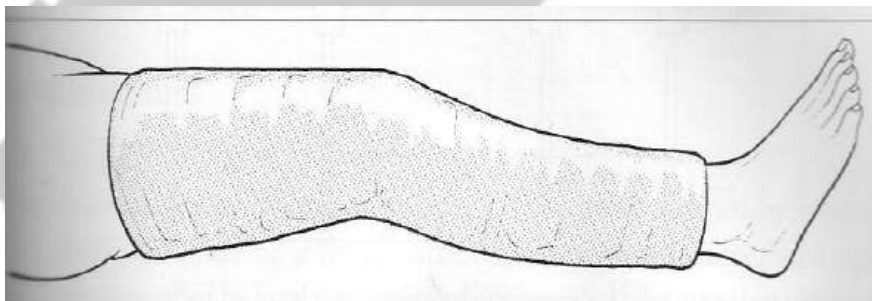


Figure 7.6

15. Tibio-fibular (lower leg) fractures

- Very common fractures which can be treated by serial long leg
And lower leg POP
- Displacement can be tolerated
- Compartment syndrome is to be expected in closed fractures
- If open with wide soft tissue injury external fixation and other
surgical procedures become necessary
- Sometimes calcaneal pin traction could be applied for displaced or
open fractures

Essential Surgical Skills

16. Malleolar fractures

- Simple fractures involving the tip of the malleoli can be treated by lower leg POP after the edema has subsided
- Bimalleolar fractures with additional dislocation of the joint are indications for internal fixation

Case scenario 7:1

Patient: Sixty years old female patient after a fall injury with dinner fork deformity at the right wrist joint.

Scenario: Instructor is patient; learner is Health officer on duty

Objectives: Diagnosis and management of Colles fracture

Case Scenario7:2

Patient: Thirty-three years old male patient; fall accident; shoulder pain and limitation of movement; empty glenoid fossa

Scenario: Students improvise on each other Hipocrates shoulder dislocation maneuver

Objectives: Demonstration of reduction of shoulder dislocation and subsequent management

Case scenario 7:3

Patient: Thirty-five years old male victim; gunshot wound to femur; 2 days old contaminated wound.

Scenario: Instructor is clinical informant; learner is Health officer on duty

Objectives: Patient evaluation and resuscitation; trauma priorities, wound debridement, tetanus prophylaxis, open fracture management, skeletal traction and external fixation.

PRACTICAL SESSION 7:1

1. X-Ray Readings

a) Upper Extremity

Activity: The learner reads upper extremity trauma x-rays

Objectives: Demonstration of approach how to read upper extremity x-rays

Equipment:

- Upper extremity trauma x-rays
- X-ray viewer

Teaching hints: Diagnosis and management of upper extremity fractures and dislocations

b) Lower extremity

Objectives: Reading lower extremity trauma x-rays

Equipment:

- Lower extremity trauma x-rays
- X-ray viewer

Teaching Hints: Diagnosis and management of lower extremity fractures and dislocations

PRACTICAL SESSION 7:2

Bandage immobilization of the upper arm

Objectives: Enable learner immobilize the upper arm for upper arm fractures

Scenario: Students apply elastic bandages on one another and immobilize the upper arm to the chest wall

Equipment:

Elastic bandage

Adhesive plaster

Sling (triangular)

PRACTICAL SESSION 7:3

Plaster of Paris Application

Objectives: Enable learner to immobilize the upper or lower extremity, bivalve and window cast; remove cast

Scenario: The students take turns applying casts to each other (grouped in to two)

Equipment:

- POP rolls
- Cotton
- Cotton bandage
- Bucket and warm water
- POP scissors and spreader

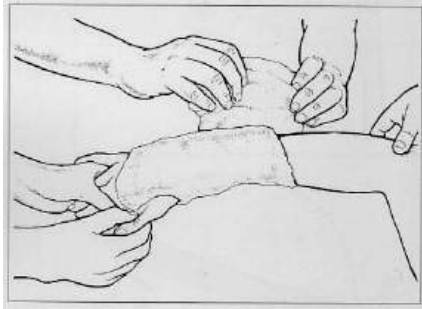

Figure 7.7 cotton application

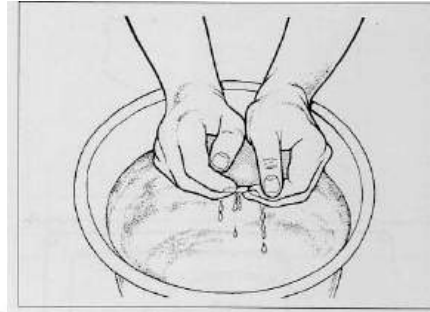

Figure 7.8 immersion of POP in water

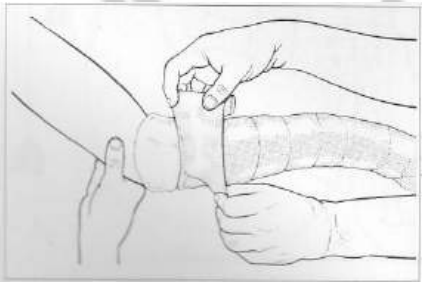


Figure 7.9 application of POP
Cylindrical POP

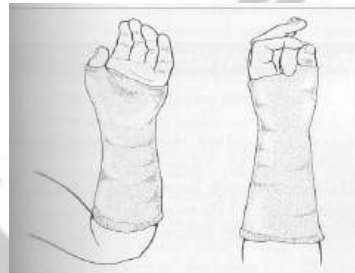

Figure 7.10 short arm POP completed

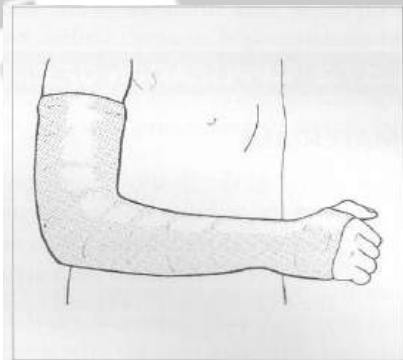


Figure 7.11 long arm cast completed

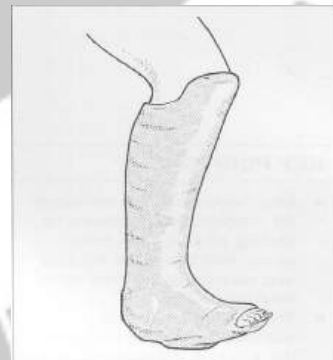


Figure 7.12 patellar bearing cast
Completed

POP removal

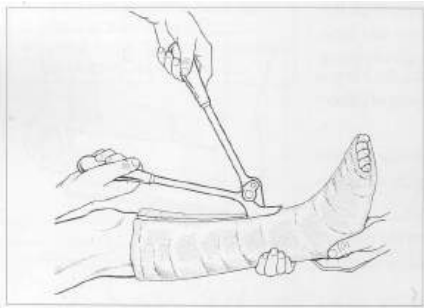


Figure 7.13 POP cutting

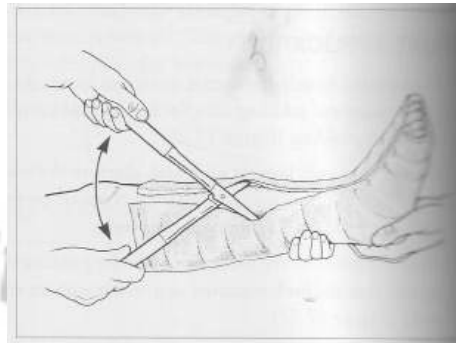


Figure 7.14 POP spreading

PRACTICAL SESSION 7:4

Skeletal and Skin traction

Objective: To make learner able to apply skeletal and skin traction

Scenario: Students apply skeletal and skin tractions

Equipment:

- Bamboo/sugarcane
- Steinman pin
- Hammer
- Bandage
- Adhesive plaster
- Knife
- Piece of carton
- Thread

Skin traction

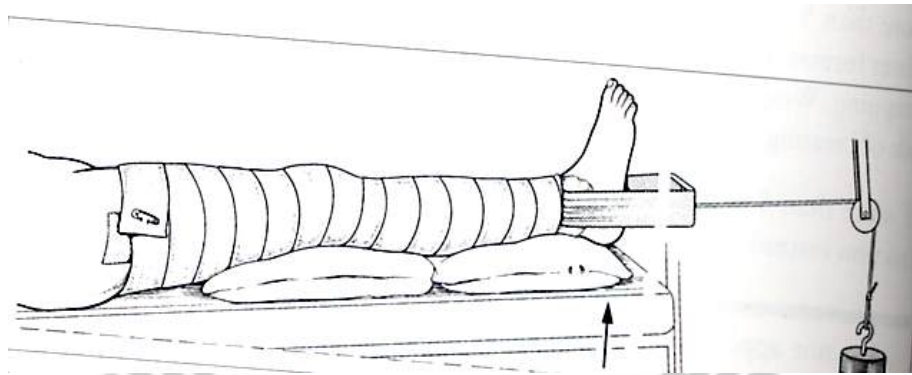


Figure 7.15 skin traction

Skeletal traction

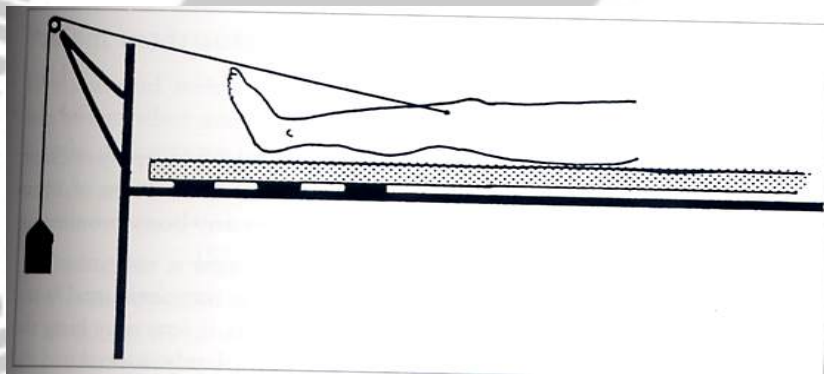


Figure 7:16

Part II: Amputations Dr Zeki Abdurahman

Definition: Amputation is removal or excision of part a whole of a limb.

Indications:

1. Dead limb (Gangrene)
 - Due to
 - Atherosclerosis
 - Embolism

Essential Surgical Skills

- Major arterial injury
- Diabetic gangrene
- E.t.c.

2. Deadly limb

- Life threatening infections (Eg. Gas gangrene) or malignancies, which can't be controlled by other local measures.

3. Dead loss

- Severe soft tissue injury especially associated with major heavy injury, which may occur in compound fractures.

NB. In developing countries, majority of amputations are done for trauma or infection.

Level of Amputation

The choice for the level of amputation depends on:

- Age of the patient
- The nature & extent of the pathology Eg. Trauma, neoplasm
- The vascularity of tissues
- Status of the joints
- Access to the various types of prostheses

In general, the most distal level will be and still provide a functional stump is selected

- In the upper limb, attempt should be made to conserve every possible inch.
- In the lower limb, the most important factor is to conserve the knee joint whenever possible.
- Lower limb amputations should have a standardized stump length for easy prosthetic fitment.
- Above knee amputations should be planned so as to leave about 25 cm of the femur below the greater trochanter.
- In below knee amputations, the tibia is cut at 8-14 cm below the tibial tuberosity.

- In children disarticulations (amputations through the joint) are better because they retain the epiphyseal plates, which are necessary for the bone growth.

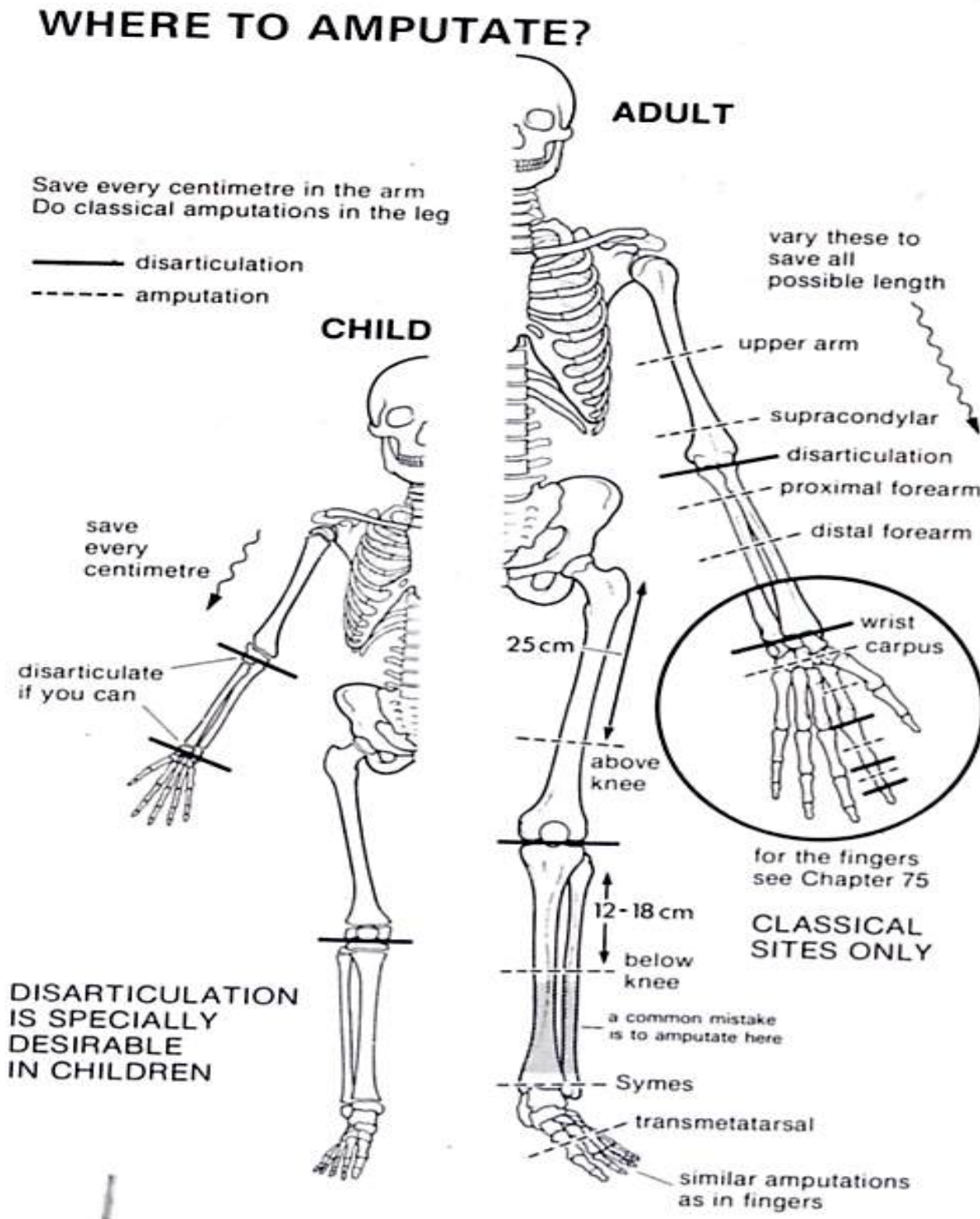


Figure 7:17

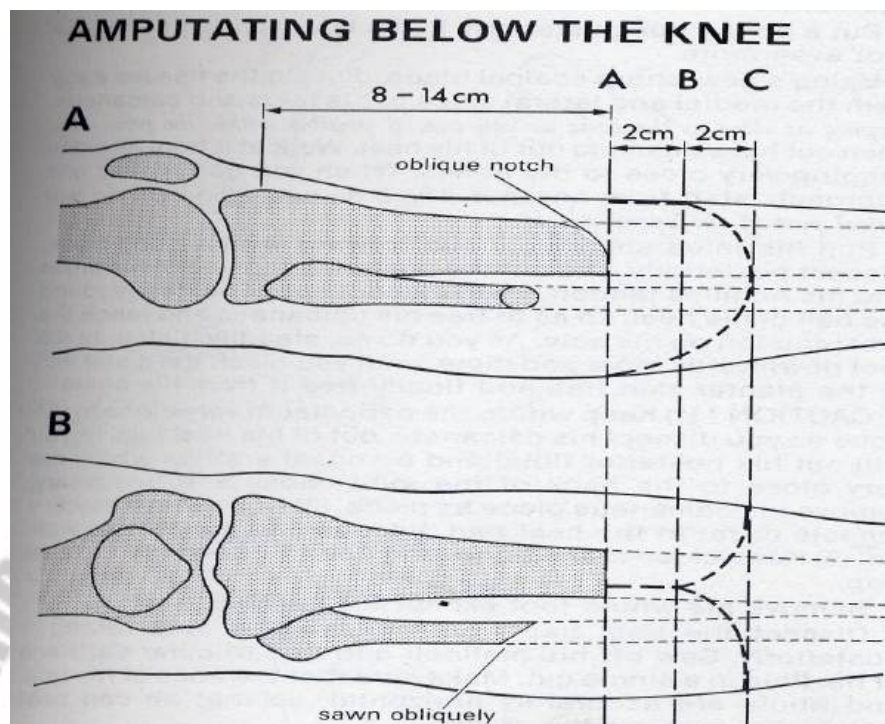


Figure 7:18

Pre operative care

- Correct hypovolemia and replace blood loss before taking the patient to the operating room unless active bleeding couldn't be controlled by other local measures like pressure dressing or tourniquet.
- Start IV antibiotics for patients with trauma, infection or ischemia
- Counsel patient and family and obtain an informed consent.

Case Scenario

A 30 years old man presented two days after he was over run by a car. On examination, he was tachycardic and febrile; he has compound comminuted fracture of his left leg bones with extensive soft tissue injury and foul smelling wound. His left foot is cold and has no palpable pulse.

- a. What is your diagnosis?
- b. What pre operative preparation is needed for this patient?
- c. What is the definitive surgical treatment
- d. Do you close his wound at the end of the surgery?

PRACTICAL SESSION

Anesthesia

- Ketamine anesthesia usually suffices for most amputations, especially in children.
- Lower limb amputations in adults can be done using spinal anesthesia.
- Digital amputations can safely be done by a digital nerve block using local anesthetics without adrenalin.

Tourniquet

Except in amputations done for ischemic gangrene, a tourniquet should be applied proximal to the site of amputation to minimize blood loss during the operations.

Cutting fish mouth flaps (skin & muscle flap)

- Decide the level of bone section and place the angle of the fish mouth at the site of the section. Mark it carefully with scratch marks before you cut.
- Unequal flaps may be used sometimes
 - Eg. A posterior flap is mostly used to cover the stump after a below knee amputation
- Cut through the skin & muscle at the same level.

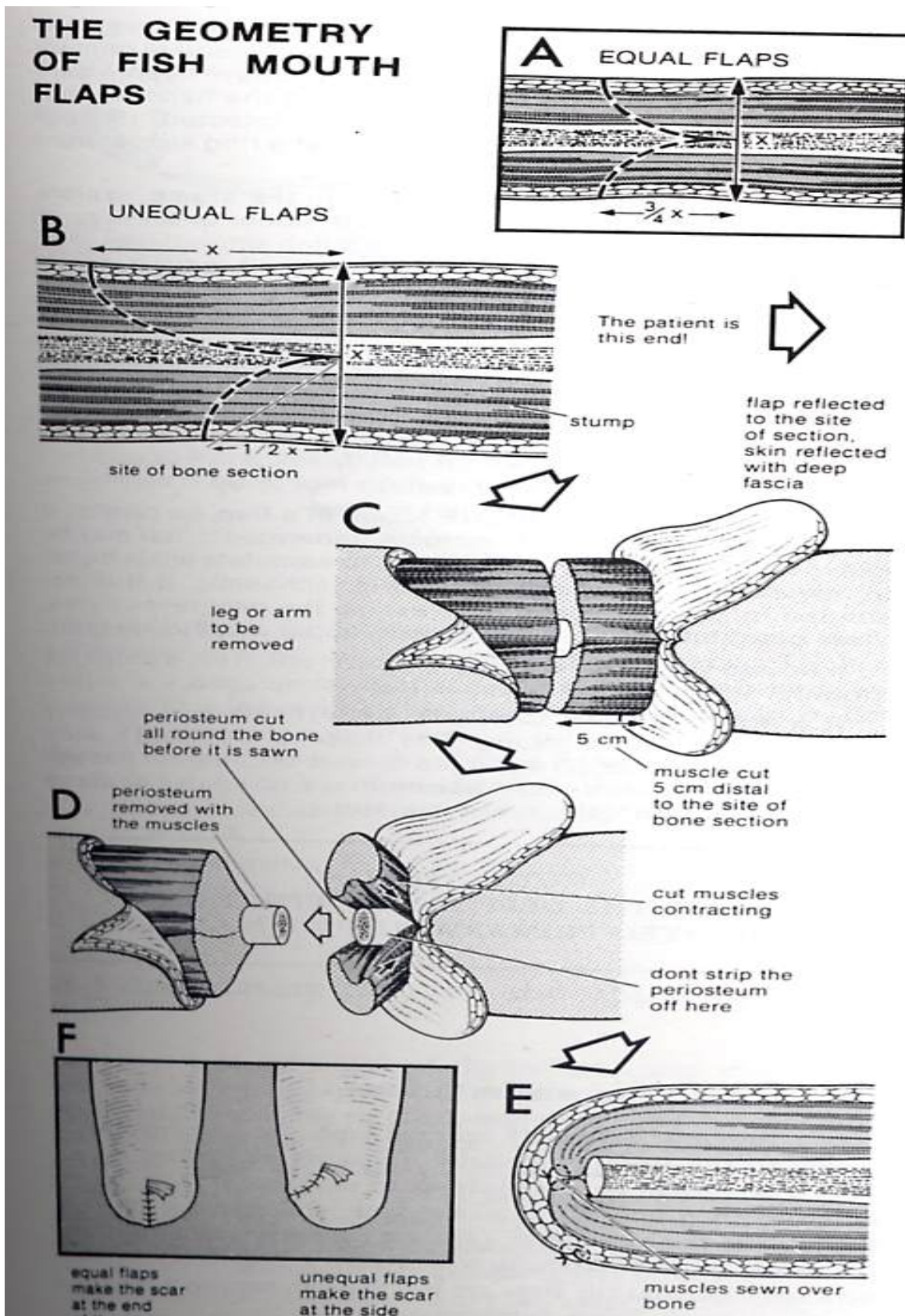


Figure 7:19

Controlling bleeding

- Early in the operation, find the major arteries and veins & ligate them separately with transfixion ligature using non absorbable sutures.
- Later after the muscles and bone are cut, the tourniquet should be released slowly and smaller bleeding vessels identified, clamped and ligated failure to do this may result in a hematoma which may be infected.

Cutting nerves

- Gently pull each nerve in to the wound, cut it cleanly with a knife and let it retract above the amputation site

Sawing the bones

- Clear the muscle from the site of bone sectioning and incise the periosteum all round it and reflect it distally for one or two centimeters with the muscles so as to leave bare bone for the saw.
- Don't reflect the periosteum proximally because the bone under it will die!
- Cut the bone with the saw while the assistant protects the muscle and steadies the limb.
- Use a file to bevel this sharp protruding bone edges.

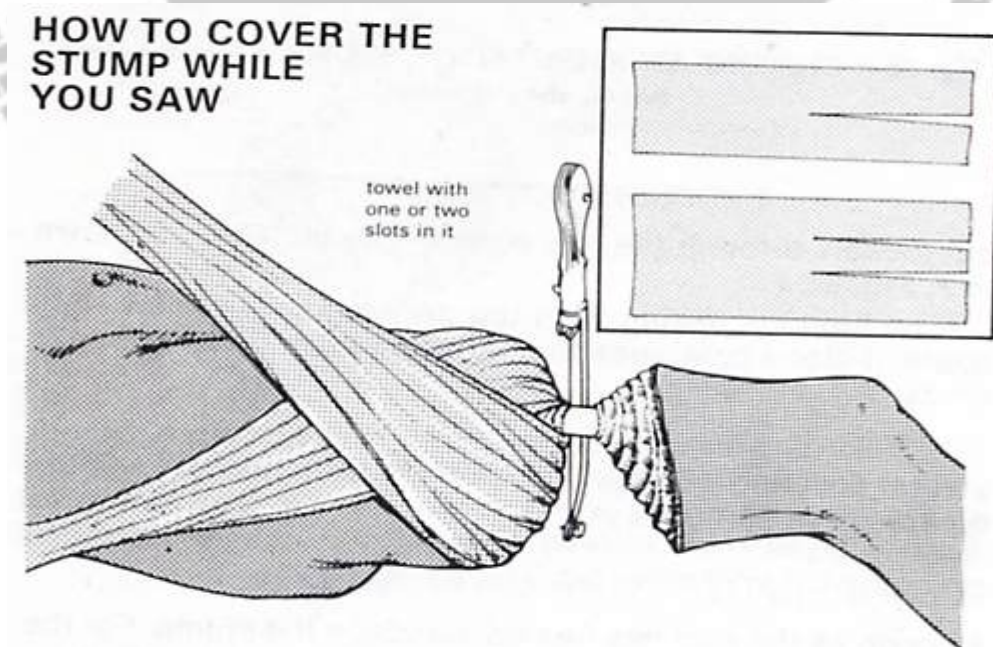


Figure 7.20

Closure of the stump

- An amputation stump may be closed primarily or left unsutured for closure at a later date.
- It is safer to leave the stump unsutured if:
 - The patient's limb is already infected.
 - In all battle casualties
 - There is much soft tissue injury & contamination at the site of amputation
 - Blood supply to the stump is uncertain
- If the stump is to be closed primarily, suture the deep fascia of the muscles over the bone end with absorbable sutures so as to provide an adequate cushion for the stump.
- Drains should always be used if a stump is closed primarily. It should be the ends brought out at the wound edges on both sides. Drains should be removed after 48 hours.
- The skin is sutured interrupted with out tension.

Dressing

- Dress the stump firmly but not too tightly to prevent excessive swelling.

Post operative care

- Provide adequate analgesia
- Elevate the stump to decrease edema & hematoma formation.
- Exercise the joints of the limb to prevent contracture, specially the knee point after a below knee amputation.
- Once the wound heals apply firm bandage to the stump to prepare if for prosthetic fitment.

Complications of amputation

- Edema
- Hematoma
- Secondary & reactionary hemorrhage

Essential Surgical Skills

- Infection
- Ischemic necrosis
- Flexion contracture of adjacent joint
- Chronic pain

Compartment Syndrome

Definition: Is an acute rise of pressure in the closed fascial compartments of extremities.

Causes

- It usually occurs in the fore arm and leg following closed fractures but may occur in traumas without fracture.
- Applying circular POP casts and tight bandages on a fresh of injured limb may precipitate the condition.
- The acute rise in the fascial compartments is due to the swelling and bleeding occurring in a closed non yielding space which causes obstruction of the veins and the small arteries in the compartment and ending up in necrosis of the muscles in the compartment if left untreated.

Clinical manifestation

- Persistent severe pain occurring after a circular POP a tight bandage of an injured limb is the most important alerting symptom.
- Pain on passive extension of the digits is a reliable early finding.
- Paralysis, pallor and absence of distal pulse are found in advanced cases.

Treatment

- Early diagnosis of the condition is very important to save the patient's limb.
- Any externally applied bandage should be removed and a circular POP cast should be split opened along its length and down to the skin on both sides.
- If the condition is not relieved by these measures urgent fasciotomy should be performed

Fasciotomy

Indications

1. Closed injury of a limb usually with fractures developing compartment syndrome
2. Circumferential full thickness burn of an extremity
3. An ischemic limb due to vascular trauma or occlusion for which revascularization is done.

PRACTICAL SESSION

Fasciotomy for the leg

1. Make a longitudinal 15 cm incision on the medial side of the patient's leg.
 - Cut through the deep fascia from his knee to his ankle
2. Make a similar 15 cm longitudinal incision on the outer side of his leg.
 - Incise the fascia directly underneath it and decompress his peroneal compartment
 - Slide the skin incision anteriorly over the subcutaneous tissue as shown in figure 1 by the arrow and incise the fascia over the anterior tibial compartment. This enables you to decompress both compartments through the same incision.

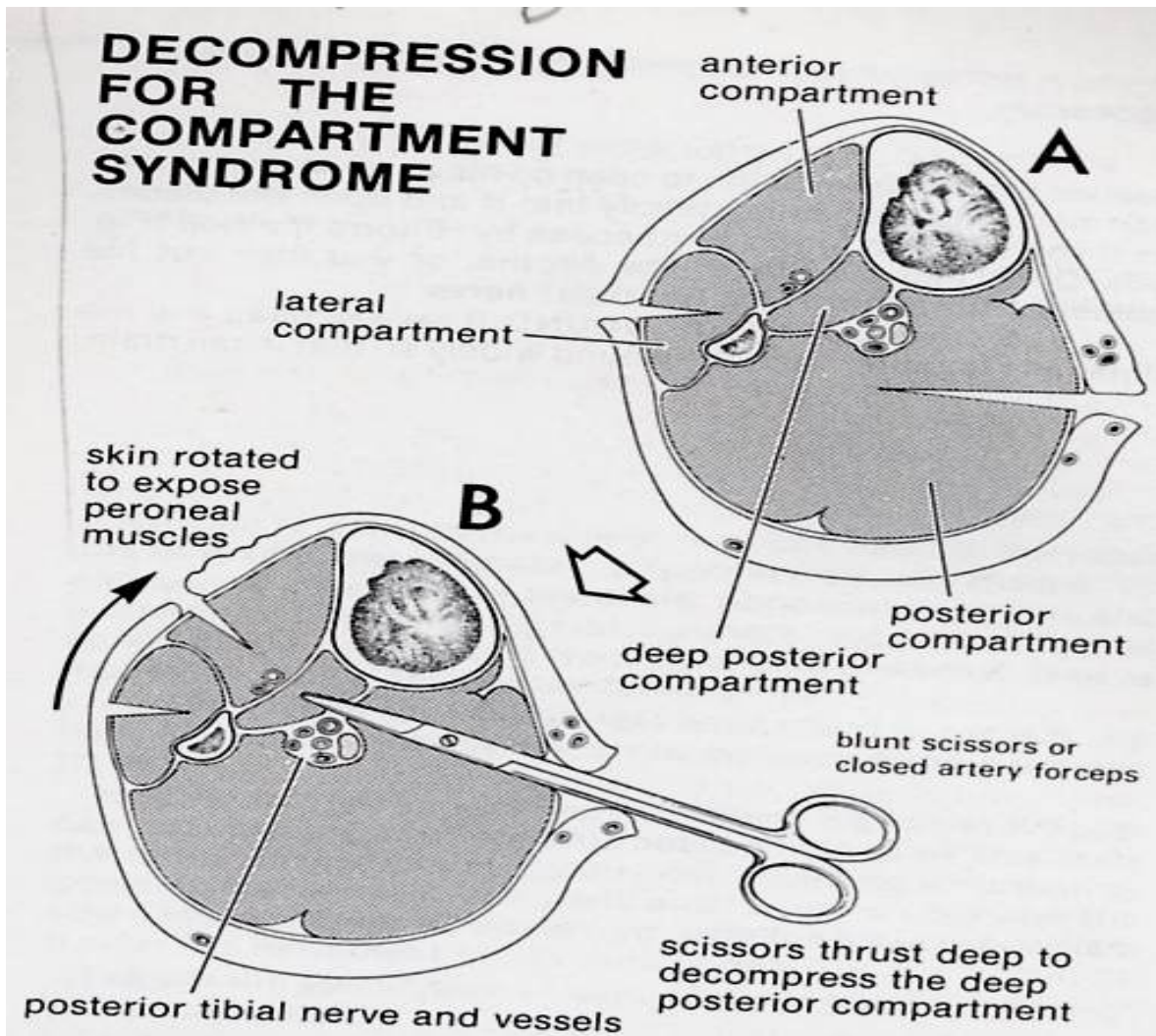


Figure 7.21

3. Do not close the skin wound. Apply a moist dressing and leave the wound open for a later closure.