

CARDIOTHORACIC TRAUMA

A SCANDINAVIAN PERSPECTIVE

Moheb A. Rashid, M.D.



The Sahlgrenska Academy
AT GÖTEBORG UNIVERSITY

Göteborg, 2007

CARDIOTHORACIC TRAUMA

A Scandinavian Perspective

Moheb A. Rashid, MD

Division of Surgery, Institute of Clinical Sciences
Sahlgrenska Academy, Gothenburg University,
Gothenburg, Sweden



The Sahlgrenska Academy
AT GÖTEBORG UNIVERSITY

Göteborg 2007

“..And if any one saved a life it would be as if he/she saved the life of the whole people..”

(Quran S. The Table 005:032)

“The wards are the greatest of all research laboratories”

(Sir Henry Wade, 1877-1955, Surgeon, Royal Infirmary, Edinburgh)

The cover depicts the Papyrus of Hunefer from the 19th Dynasty (1307-1196 BC) showing the deceased (Hunefer) led in by Anubis, and his heart weighed against a feather. Anubis checks the balance while the crocodile (eater) stands ready and Toth records the results. It is believed to be the first picture of the heart.

Dedicated to:

My Parents Om-Hashem & Abdelhay

My Sisters & Brothers in Egypt

Christina, Magda, Joseph

& Jacob

CARDIOTHORACIC TRAUMA

A Scandinavian Perspective

Moheb A. Rashid, MD, Division of Surgery, Institute of Clinical Sciences, Sahlgrenska Academy, Gothenburg University, Gothenburg, Sweden.

Abstract

Background: Trauma in general is a major cause of morbidity and mortality worldwide, and causes more loss of productive years than ischemic heart disease and malignancy together. Cardiothoracic trauma occurs in 60% of multitrauma patients and is 2-3 times more common than intra-abdominal visceral injuries. It constitutes 25% of traumatic deaths and contributes significantly to at least another 25% of these fatalities. Though only about 15% of chest trauma requires operative intervention, a considerable number of preventable deaths occur due to inadequate or delayed treatment of otherwise an easily remediable injury. **Aims of the study:** The aim of this study was to describe rare but serious and sometimes fatal entities in patients with cardiothoracic trauma sustained in two Scandinavian countries, and to determine the outcome. **Patients and Methods:** This study is a retrospective review of 496 patients of which 477 patients with significant cardiothoracic trauma managed during a ten-year period, between January 1988 and December 1997 (Sahlgrenska University Hospital/Östra, Gothenburg, Sweden) and 19 patients treated between January 1995 and December 2001 (Copenhagen University Hospital/Rigshospitalet, Copenhagen, Denmark). Age, gender, mechanism of injury, co-morbidity, risk factors, clinical diagnosis, associated injuries, complications, treatment, length of hospital stay and follow-up were recorded. Injury severity score (ISS) was calculated using the 1990 Abbreviated Injury Scale **Results:** The mechanisms of injury in penetrating trauma were knife stabs and in blunt trauma were mainly motor vehicular crashes and falls. Associated rib fractures in patients with traumatic extrapleural hematoma (TEH) were found in 31/34 (88.2%), and more than 50% had an associated hemothorax. No cardiovascular injuries have been found in patients with sternal fractures. All patients with penetrating lung injuries survived without major sequelae. ISS averaged 14.9 ± 9.5 SD in all survivors versus 49.9 ± 13.6 SD in those who died ($p < 0.0001$). All patients with penetrating ventricular wounds presented with pericardial tamponade. The incidence of blunt cardiac injury was very low in both the Swedish and Danish centers. Eight patients with aortic ruptures were operated on using left heart bypass and one with cardiopulmonary bypass. One patient had postoperative renal failure, but no incidence of paraplegia. **Conclusions:** This study suggests a nomenclature, and classification of TEH, and depicts its clinical significance. Sternal fractures are not reliable indicator of heart or aortic injuries. Good outcome in penetrating injuries to the lungs can be obtained by an aggressive approach including emergency room thoracotomy when needed. The study reflects the Swedish and Danish experiences of heart trauma: there were few cases, alcohol and drug misuse is the principal risk factor, and there were no gunshot wounds. Left heart bypass is recommended if paraplegia is to be prevented in managing patients with traumatic rupture of the thoracic aorta.

Key words: Cardiothoracic trauma, Trauma, Extrapleural hematoma, Sternal fractures, Heart and lung contusions, Cardiac, pulmonary, and thoracic aortic injuries, Urgent or emergency room/department thoracotomy, Sternotomy, Paraplegia, Outcome.

ISBN 978-91-628-7171-0

Original papers

This thesis is based on the following papers, which will be referred to in the text by their Roman numerals.

- I. Rashid MA, Wikström T, Örténwall P.
Nomenclature, classification, and significance of traumatic extrapleural hematoma.
J Trauma 2000; 49:286-290.
- II. Rashid MA, Örténwall P, Wikström T.
Cardiovascular injuries associated with sternal fractures.
Eur J Surg 2001; 167:243-248.
- III. Rashid MA, Wikström T, Örténwall P.
Outcome of lung trauma.
Eur J Surg 2000; 166:22-28.
- IV. Rashid MA, Wikström T, Örténwall P.
Cardiac injuries: a ten-year experience.
Eu J Surg 2000; 166:18-21.
- V. Rashid MA, Lund JT.
Trauma to the heart and thoracic aorta: the Copenhagen experience.
Interactive Cardiovasc Thorac Surg 2003; 2:53-57.

CONTENTS

• Glossary	8
- Abbreviations	8
- Definitions	9
• Introduction	10
- History	10
. Egypt, Greece and the Ancient World	10
- Background	12
. Pathophysiology	12
. Management	12
. Prevention	13
- Study Topics	14
. Chest Wall Trauma.....	14
. Pulmonary Injuries	15
. Cardiac Injuries	15
. Thoracic Aortic Injuries	16
• Aims of the Study	17
• Patients and Methods	18
- Chest Wall Trauma	18
- Pulmonary Injuries.....	18
- Cardiac Injuries.....	19
- Thoracic Aortic Injuries.....	19
- Statistical Analysis.....	20
• Results	21
- Chest Wall Trauma	21
- Pulmonary Injuries.....	24
- Cardiac Injuries.....	28
- Thoracic Aortic Injuries.....	30
• Discussion	34
- Chest Wall Trauma	34
- Pulmonary Injuries.....	36
- Cardiac Injuries.....	36
- Thoracic Aortic Injuries.....	37
- Other Chest Injuries.....	38
• Conclusions	39
- Chest Wall Trauma.....	39
- Pulmonary Injuries.....	39
- Cardiac Injuries.....	39
- Thoracic Aortic Injuries.....	39
• The Future	40
• Acknowledgement	41
• References	43
• Papers	51

GLOSSARY

ABBREVIATIONS

- AAST	American Association for the Surgery of Trauma
- AIS	Abbreviated Injury Scale
- ARDS	Acute Respiratory Distress Syndrome
- ATLS	Advanced Trauma Life Support System
- CK-MB	Creatine Kinase Isoenzyme
- CNS	Central Nervous System
- CO	Cardiac Output
- COPD	Chronic Obstructive Pulmonary Disease
- CT	Computed Tomography
- cTn-I	Cardiac Troponin I
- cTn-T	Cardiac Troponin T
- CTT	Chest Tube Thoracostomy
- CXR	Chest X-Ray
- 2-D echo	Two-Dimensional echocardiography
- ECG	Electrocardiogram
- ED/ER	Emergency Department/ Room
- EDT/ERT	Emergency Department/Room Thoracotomy
- EH	Extrapleural Hematoma
- ESG	Endovascular Stent Grafting
- ETT	Emergency Tube Thoracostomy
- FAST	Focused Abdominal Sonography for Trauma
- ICU	Intensive Care Unit
- IEH	Iatrogenic Extrapleural Hematoma
- ISS	Injury Severity Score
- LOS	Length of Hospital Stay
- MOF	Multiple Organ Failure
- MRI	Magnetic Resonance Imaging
- MVC	Motor Vehicle Crashes
- OIS	Organ Injury Scale
- OPCAB	Off-Pump Coronary Artery Bypass
- OR	Operation Room
- SEH	Spontaneous Extrapleural Hematoma
- TAR	Traumatic Aortic Rupture
- TEE	Transesophageal Echocardiography
- TEH	Traumatic Extrapleural Hematoma
- TTE	Transthoracic Echocardiography
- VATS	Video-Assisted Thoracoscopic Surgery

DEFINITIONS

- *Abbreviated Injury Scale*: An anatomical scoring system, in which the injuries are rated on a scale of 1-6, with 1 being minor, 5 severe and 6 no survivable injuries.
- *Beck's triad*: A triad composed of distended neck veins, hypotension, and muffled heart sounds. Claud Beck described it in 1935 as an aid in the clinical diagnosis of cardiac injuries.
- *Capricious syndrome*: Myocardial contusion (blunt cardiac injury).
- *Emergency Department Thoracotomy*: A thoracotomy performed in the emergency department. It is also termed as Emergency Room Thoracotomy.
- *Emergency Tube Thoracostomy*: Urgent insertion of chest tube in the emergency room.
- *Flail chest*: The result of two or more ribs being fractured in two places or are fractured posteriorly with sternochondral dislocation anteriorly. The flail segment renders the chest wall unstable interfering with the mechanics of ventilation.
- *Injury Severity Score*: An anatomical scoring system providing an overall score for patients with multiple injuries. Each injury is assigned an AIS score and is allocated to 1 of 6 body regions (head, face, chest, abdomen, extremities & pelvis and skin). Only the highest AIS score in each body region is used. The 3 most severely injured body regions have their score squared and added together to produce the ISS score.
- *Myocardial contusion*: An anatomical injury to the myocardium, which can be diagnosed either by raised CK-MB, cardiac troponins or on direct vision during surgery or autopsy.
- *Myocardial concussion (commotio cordis)*: A term used to describe where there is no anatomical cellular injury, but some dysfunction can be seen on two-dimensional echocardiography or other wall-motion studies. Simply defined as sudden cardiac death caused by blunt chest trauma.
- *Pericardial tamponade*: The presence of blood into the pericardial sac, to such an extent that heart function is impaired. The same effect can be caused by pneumopericardium when tension occurs.
- *Postpericardiectomy syndrome*: Syndrome consisting of fever, malaise, arthralgia, dyspnea and pleural as well as pericardial pain.
- *Post-traumatic ARDS*: Acute respiratory distress syndrome, which is a clinical condition of rapid onset, associated with a mortality of over 50%. ARDS is a common complication in multitrauma patients and is often a component of MOF with variable prognosis according to the underlying lesion. Aspiration, head trauma, pulmonary contusion, massive blood transfusion, shock, disseminated intravascular coagulation, fat embolism, or a septic focus (pneumonia, occult intraabdominal abscess) singly or in combination may be responsible.
- *Pulmonary contusion*: Injury to lung parenchyma resulting in edema and hemorrhage.

INTRODUCTION

HISTORY

EGYPT, GREECE, AND ANCIENT WORLD

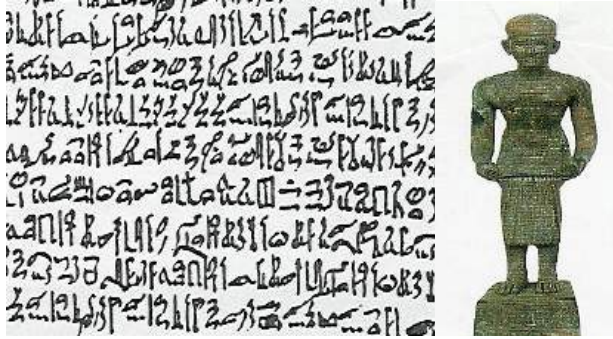


Fig. 1: The Edwin Smith Surgical Papyrus and Imhotep.

The earliest known record of thoracic injuries is found in the Edwin Smith Surgical Papyrus (Fig. 1), written 5000 years ago. This Papyrus details the care of 21 cases with chest and neck injuries by the Egyptian *Imhotep* (Fig. 1) (18), the first *trauma surgeon* described in the human history.

Hippocrates was the first to drain the pleural space, with incision, cautery and metal tubes (53). Although chest tubes were used regularly post-thoracotomy in World War II, emergency chest tube insertion for trauma did not become common until the Korean War (63). As early as 950 BC, a penetrating cardiac wound was described by *Homer* in *The Iliad* (54). The Greek physician *Galen* observed that left ventricular wounds were the most rapidly fatal of all heart injuries (42) in the second century. Until the nineteenth century, cardiac injuries were considered technically impossible and ethically incorrect "*The surgeon who should attempt to suture a wound of the heart would soon loose the respect of his colleagues*" (1, 84). This attitude changed at the end of that century, and repair of cardiac wounds was attempted in Oslo by Cappelen in 1894 (23). However, the first successful heart operation was done in Germany in 1896 (105).

Wilhelm Justus, was a young gardener, had been stabbed in the chest on September 7, 1896 while walking in a park near the Main river in Frankfurt. *Dr. Rehn* was out of town, and when he returned to the hospital on September 9, he was informed of the stabbing case. *Rehn* decided to operate in an attempt to save *Justus*' life. At 7:30 PM the operation started. The chest was entered through the left 4th intercostal space, the pericardium was opened. *Rehn* failed to properly expose the heart, and the incision proved to be inadequate, since the right ventricle kept disappearing under the sternum during systole. However, *Rhen* found a 1.5 cm wound in the right ventricle, and was able to close it with 3 silk stitches carefully placed during diastole. During convalescence, the heart worked "better than before the injury".

This case report is the origin of modern heart surgery. It denotes the importance of rare, significant case reports, which may change the clinical practice of such a speciality. In 1907 *Rehn* reported a large series of cardiac injuries managed surgically with a remarkably high survival rate (106).

Despite this, treatment of chest trauma was restricted to closed drainage of empyema during World War I (49) and removal of foreign bodies (121), until World War II, when thoracotomy was mandated by the Office of the Surgeon General for any penetrating wound of the chest with significant blood loss.

BACKGROUND

Trauma is a major cause of morbidity and mortality worldwide. In spite of a 20% decrease in mortality during the last 25 years, motor vehicle crash (MVC) injuries remain the most common cause of death in under 40-year-old patients not only in Sweden (120), but worldwide (14) as well. About 3,000 die due to injuries. The total cost is calculated to amount to about 4% of the total Swedish national income annually. In the United States, trauma is the leading cause of death from age 1-44 years. It maims or kills about 1/2 million people every year in the USA mainly from multitrauma (128). The cost is estimated to exceed more than 150 billion dollars a year. Due to the age of the stricken population trauma causes a greater loss of productive years of life than ischemic heart disease and malignancy together. Civilian violence is increasing, and ongoing military conflicts in combination with terrorist actions create a tremendous number of trauma patients annually.

About 1/3 of all trauma related deaths occur in the hospital. In a Swedish report, 20 out of 74 (27%) in-hospital fatalities were considered to be potentially preventable (82). Thirty percent of trauma deaths in the UK and a similar percentage in the USA are considered to be preventable (6, 44). In 1980, it has been stated that the number of survivors of trauma has increased by 50% in recent years probably due to prompt treatment, and rapid transfer to dedicated trauma centers (129). Epidemiological studies showed a wide variation of competence in managing multitrauma patients, and have highlighted advantages of properly equipped trauma centers with trained personnel (78, 139). Thus, organized systems (such as level I or II trauma centers) are critical to the success of patient management (45, 140). A reduction of trauma deaths from 73% to 9% with greater survival and less morbidity has been shown using this organized system (14, 140).

PATHOPHYSIOLOGY

When the chest wall is impacted from the sides, an increase in intrathoracic pressure will be created. This results in increased pleural pressure against a closed glottis producing a blow-out parenchymal laceration, causing pneumothorax. A direct or indirect pressure to the lung tissue produces a contusion on the same side or contralateral side "a contre-coup lung contusion" as recently described (93). In case of MVC, the sternum stops its forward motion against the interior of the car. The continued motion of the vertebral column traps the heart in between, resulting in cardiac contusion or rupture. Increased intra-abdominal pressure can force the column of blood retrograde up the aorta and against the aortic valve, and up the inferior vena cava (IVC) and against the right atrium, which will rupture if the force is great enough. Cardiac trauma is virtually always overlooked in case of multitrauma unless accompanied by an obvious tamponade, arrhythmias, or ventricular failure. Cardiovascular injuries occur in up to 30% of trauma patients and the blunt type of cardiac injuries is almost exclusively related to the rapid deceleration in MVCs (64). Falls from a height may avulse the heart from the aortic root. The production of shearing forces and direct compression against the points of fixation particularly at the isthmus are possible mechanisms of injury of the traumatic aortic rupture (TAR).

MANAGEMENT

It is mandatory to determine within the first few minutes whether an immediately life threatening problem exists, and the primary survey must take into account the mechanism of injury (142). The basis for successful management of patients with cardiothoracic trauma is effective resuscitation (141) followed by immediate detection of life threatening conditions such as hypoxia, acidosis, low cardiac output (COP), cardiac or vascular injury (142, 143). The diagnosis of chest trauma may be difficult and should therefore, depend on prediction and exclusion policy rather than direct

manifestation of injury. More than 50% of these patients have an altered level of consciousness, which makes the clinical diagnosis difficult, and up to 35% are intoxicated (15). Even the most serious intrathoracic injuries can occur without obvious damage to the chest wall. Thoracic injuries occur in 60% of multitrauma patients and are 2-3 times more common than intra-abdominal visceral injuries. Serious injuries due to blunt trauma particularly TAR, and myocardial contusion is often initially overlooked (24, 41). Most patients with catastrophic intrathoracic conditions like severe injuries to the heart, aorta or major airways die at the scene of accident. Those who reach the hospital with signs of life could be considered as a selected group who have a chance of survival. Survival rate in this group depends on skilled personnel and a well equipped emergency unit (78, 139). Most patients, who die after arrival to hospital with chest trauma, do so due to lack of an optimal management (6, 44, 82). The majority (85%) of patients with cardiothoracic trauma can initially be saved using chest tube thoracostomy (CTT) and only 15% needs thoracotomy or sternotomy (71, 91, 146). Although CTT is a life-saving procedure, it is not without risk, especially when aggressively used in trauma patients (74, 75, 92, 94, 95, 98, 99, 130, 131). A clinical examination is sometimes unreliable in patients with chest trauma particularly with regards to cardiac, vascular or diaphragmatic lesions (24, 43, 97). Injuries may be overlooked (113) especially, in patients with head injuries and depressed level of consciousness (12). When injuries such as multiple rib fractures, or pneumothorax are ignored, underestimated or inadequately managed, they may be fatal during a surgical procedure for seemingly more important intracranial or abdominal bleeding.

PREVENTION

Prevention of trauma is usually the most effective way to reduce the number of years lost with respect to life and productivity. This policy, which for MVC includes legislation of seat-belts, air bags, lower speed limits, better roads, and introduction of helmets to motor cyclists (thirteen times more likely to die than motor vehicle drivers) has led to a considerable reduction in morbidity and mortality (19, 39, 73, 83). Fifty percent of fatal crashes are related to alcohol consumption (51), which was considered as a major risk factor in stab wounds of the heart (100, 104) and penetrating injuries of the lung (101).

STUDY TOPICS

CHEST WALL TRAUMA

The majority of chest injuries involve soft tissue, thoracic cage, and the underlying pleura and lung. Chest wall injuries compose one half to two thirds of all thoracic injuries encountered in trauma care (11).

- *Extrapleural hematoma (paper I)*

Traumatic extrapleural hematoma (TEH) is defined as hemorrhage confined entirely to the extrapleural space due to chest trauma (96). It is rare and has been found mostly as single case reports with different names (Table 1). TEH could be a sign of ruptured aortic aneurysm (65). Although large extrapleural hematoma (EH) may cause ventilatory and circulatory disturbances and even death has been reported (107), it has so far received sporadic attention in the world literature. Therefore, certain facts regarding the definition, classification, mechanisms of injury, and significance of extrapleural hematoma in the practice of chest trauma is warranted. Paper I including 34 patients deals with this entity, and to the best of our knowledge, this is the largest study in the literature.

- *Sternal trauma (paper II)*

Sternal fractures result from direct impact to the anterior wall of the chest, especially in MVC. The sternum usually fractures transversely, at the body or manubrium. The severity of sternal fractures differs greatly from a simple fracture to comminuted fractures with or without overlapping fragments (110). Most textbooks on trauma states that, the surgeon should suspect and carefully assess for any underlying injuries to the retrosternal vital structures such as the heart, and the great vessels in case a sternal fracture is found. This study (paper II) was carried out to assess the nature of sternal fractures, and especially to evaluate whether sternal fractures increase the risk of cardiovascular injuries. Another aim in this study was to differentiate between retrosternal hematoma and widened mediastinum.

Table 1: Reports of extrapleural hematomas

Author	Reference	Year	No			Total
			SEH	IEH	TEH	
Pendergrass & Allbritten, Jr	90	1947	-	4	-	4
Smedal & Lippincott	118	1950	-	19	-	19
Scheff et al	116	1957	-	40	-	40
Lipchik & Robinson	65	1968	-	-	1	1
Schechter & Held	115	1974	1	-	-	1
Butchart et al	21	1975	1	-	-	1
McEnany & Austen	72	1977	-	1	-	1
Bluhm & Gross	13	1980	-	-	1	1
Toombs et al	127	1981	-	-	1	1
Wasylenko & Busse	137	1981	-	-	1	1
Brandi et al	17	1984	-	1	-	1
Direnhofer et al	32	1984	-	-	1	1
Reiter & Denk	107	1985	-	-	1	1
Nishiuchi et al	81	1985	1	-	-	1
Kucich et al	61	1986	2	-	-	2
Kay et al	57	1987	-	1	-	1
Parithivel et al	85	1988	-	1	-	1
Manenti et al	68	1989	-	-	1	1
Mohlala et al	76	1989	-	-	10	10
Rosenberg et al	114	1989	-	-	x	x
Williams et al	145	1991	1	-	-	1
Aron et al	7	1992	-	-	1	1
Massard et al	69	1992	1	-	-	1
Moulin et al	79	1992	-	-	1	1
Komoda et al	60	1994	1	-	-	1
Herridge et al	52	1995	-	1	-	1
Machin & Lau	66	1995	-	-	1	1
Aquino et al	4	1997	-	1	-	1
Rashid	92	1999	-	-	1	1
Rashid et al (Paper I)	96	2000	-	-	34	34
<i>Total</i>			8	69	55	132

SEH; spontaneous extrapleural hematoma, IEH; iatrogenic extrapleural hematoma, TEH; traumatic extrapleural hematoma. x; unknown.

PULMONARY INJURIES (*paper III*)

The initial treatment in penetrating chest injuries is the placement of thoracostomy tubes. However, pneumonorrhaphy, anatomical resection including lobectomy (34) or tractotomy with selective vascular ligation (138) may be required according to the nature of the lesion. Pneumonectomy while it carries a high mortality, may be necessary for hilar injuries (16, 108, 126). Pulmonary contusion is defined as injury to lung parenchyma resulting in edema and hemorrhage. It is the second most common injury in blunt thoracic trauma and has been shown to be associated with a mortality rate ranging from 14-40% (108). This study (*paper III*) deals with penetrating and blunt trauma of the lung with morbidity and mortality as the main outcome of management.

CARDIAC INJURIES (*papers II, IV & V*)

Although several studies have been published on the subject of cardiac injuries (8, 40, 88, 122, 124), only 20% of patients with penetrating wounds to the heart reach the hospital alive (122). Therefore, all clinical series of heart wounds are highly selective. The severity of blunt cardiac injury and mortality vary (122) from subepicardial, subendocardial, or transmural myocardial contusion (47) to complete rupture of a chamber with acute pericardial tamponade (88). Myocardial contusion includes anatomical injury, which can be diagnosed either by raised creatine kinase isoenzyme

(CK-MB) or troponins or on direct vision during surgery or autopsy. With myocardial concussion there is no anatomical cellular injury, but some functional damage can be seen on two-dimensional echocardiography or other wall-motion studies (41). Some patients may have right heart failure and this can complicate their resuscitation. Echocardiography is very useful in these patients. The risk of blunt cardiac injuries in patients with sternal fractures is presented (paper II). The experience from one Swedish urban hospital is reported (paper IV), and the Danish experience of cardiac injuries is shown as well (paper V).

THORACIC AORTIC INJURIES (*papers II & V*)

*"Clinical diagnosis is an art, and the mastery of an art has no end;
you can always be a better diagnostician"
(Professor Logan Clendenen, University of Kansas, 1884-1945)*

The widely quoted study of Parmely (87) has shown that only 20% of patients with TAR survive for more than 1 hour after injury; 80% of patients die at the scene. In initial survivors, if the injury is not surgically addressed, 40% die within 24 hours and 90% are dead by 10 weeks. However, the nature of thoracic aortic injuries in the Scandinavian countries is not well characterized. This study (paper II) was done to see whether sternal fractures increase the risk of TAR in multitrauma patients in a large Swedish hospital. Furthermore, another study (paper V) was undertaken to review the management of thoracic aortic injuries in Denmark's busiest medical center, Rigshospitalet in Copenhagen.

AIMS OF THE STUDY

- To describe rare but dangerous, life-threatening, and sometimes fatal entities in Scandinavian cardiothoracic trauma patients.

(Papers I-V)

- To suggest a definition, and classification of extrapleural hematoma in trauma patients, and to depict its clinical significance.

(Paper I)

- To determine the nature of sternal fractures, and to evaluate its relation to the risk of cardiac, and aortic injuries. To clarify the difference, and significance between retrosternal hematoma, and widened mediastinum in thoracic trauma patients.

(Paper II)

- To determine the outcome of patients with lung trauma.

(Paper III)

- To define the characteristics, and management of heart injuries in a Scandinavian series.

(Papers II, IV, V)

- To describe thoracic aortic ruptures in a Scandinavian material.

(Papers II, V)

PATIENTS AND METHODS

The study was a retrospective review of 496 patients with significant thoracic trauma. Four hundred and seventy seven patients consecutively admitted to the emergency ward at Sahlgrenska University Hospital/Östra, between January 1988 and December 1997 (papers I-IV) constitute the Swedish material in this study. Nineteen patients with heart or thoracic aortic injuries compose the Danish material (paper V). Patients with cardiac injuries were admitted between May 1995 through June 2001, while those with TAR were admitted between March 1996 and August 2000 to the department of cardiothoracic surgery at Copenhagen University Hospital/Rigshospitalet in Copenhagen. The patients were analyzed regarding age, gender, mechanism of injury, co-morbidity, risk factors, clinical diagnosis, associated injuries, complications, treatment, length of hospital stay [intensive care unit (ICU) and ward] and follow-up. Injury severity score (ISS) was calculated using the 1990 Abbreviated Injury Scale (AIS) (27) and the method of Baker et al. (9).

CHEST WALL TRAUMA

Extrapleural hematoma

- Paper I included 34 patients (22 males and 12 females) with an average age of 59 years (range 29-87). The diagnosis was achieved using the simple cheap and reliable chest x-ray (CXR) with its characteristic pattern; the D-shaped outline with its base located against the corresponding part of the chest wall was characteristic in all cases. All our cases were diagnosed using only CXR. When the diagnosis is still difficult then a CT scan of the chest may be helpful, and may show the recently described sign (92). This examination was never done just to make such a diagnosis, since at the time of care of these patients, there was no special attention regarding this diagnosis. We performed a scrutiny of the CT scans of the 2 patients who underwent this examination which was done to detect other major injuries particularly TAR and not the extrapleural hematoma. Therefore, the described sign was not seen in these CT scans.

Sternal trauma

- Paper II included 418 patients as illustrated in Fig. 2.

PULMONARY INJURIES

- Paper III was based on 81 patients (6 penetrating and 75 blunt). There was only one patient with blunt trauma and isolated lung contusion. For the purpose of analysis, the remaining 74 patients with blunt trauma were separated into two groups: patients with pulmonary contusion and thoracic lesions (n=32), and patients with pulmonary contusion and extrathoracic lesions (n=42).

CARDIAC INJURIES

- Paper IV was based on 11 patients with heart injuries (7 penetrating and 4 blunt, average 33 years, and range 19-54) treated at a Swedish hospital during a 10-year period.

- Paper V was based on 11 patients with cardiac injuries (4 penetrating, 4 blunt, and 3 iatrogenic) treated at a Danish cardiothoracic center during a 6-year period.

Patients with myocardial contusion were diagnosed on the basis of raised CK-MB activity, ST/T wave changes or arrhythmias (papers IV, V).

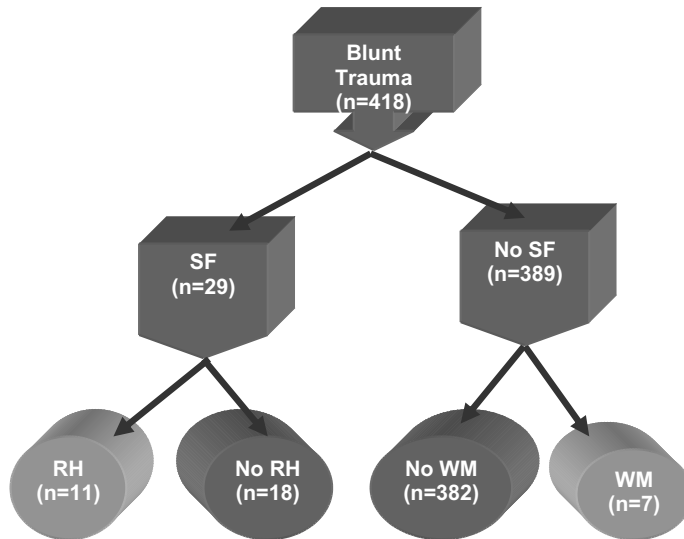


Fig. 2: This diagram shows the distribution of patients with blunt chest trauma with and without sternal fractures. SF; sternal fracture, RH; retrosternal hematoma, WM; widened mediastinum.

THORACIC AORTIC INJURIES

- Papers II and V contained 10 patients with TAR.

STATISTICAL ANALYSIS

Statistical analysis was performed using the rank sum two-sample (Mann-Whitney test) and Chi square tests. A stepwise logistic regression analysis was done in Paper III. A p-value of less than 0.05 was considered significant.

RESULTS

CHEST WALL TRAUMA

Extrapleural hematoma

• Paper I suggests a nomenclature, classification, mechanism, and the clinical significance of TEH. The incidence herein is 7.1% (34/477) among consecutive patients admitted with chest trauma during a ten-year period (1988-1997). We found that the incidence of thoracic lesions was 86/34=2.5 lesions/patient, while the incidence of extrathoracic lesions was 30/34=0.9 lesions/patient. The most common associated extrathoracic injuries were cerebral concussion, and skeletal fractures. The most common chest injuries in association with TEH were rib fractures (88.2%), hemothorax, lung contusions, pneumothorax, and chest wall contusions. More than half of the patients had hemothorax. The etiological classification of EH is presented in Table 2.

The typical radiological findings of TEH are presented in Fig. 3-5.

Table 2: The etiological classification of extrapleural hematoma.

<i>Etiology</i>	<i>References</i>
<i>Spontaneous</i>	
- Ruptured aneurysm of the descending thoracic aorta	61, 81, 115
- Avulsion of the 10th intercostal artery from the aorta	21
- Right apical tuberculosis with pleural thickening	69
- Penetrating atherosclerotic aortic ulcer	145
- Ruptured thymic branch aneurysm	60
<i>Iatrogenic</i>	
- Following sympathectomy	90, 116, 118
- Inadvertent cervical arteriotomy and heparinization	72
- Cannulation of the right internal jugular vein	17, 57
- Subclavian vein catheterization	85
- Extrapleural malposition of chest tube	4
- Following double lung transplantation	52
<i>Traumatic</i>	
- Motor vehicle crash	7, 13, 65, 68 79, 114, 137
- Fall trauma	32, 107
- Industrial crash injuries	114
- Unidentified trauma	76, 127

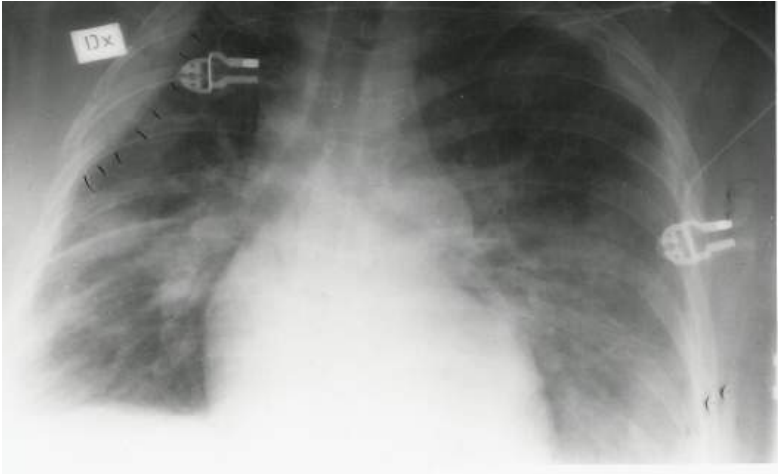


Fig. 3: CXR showing upper right extrapleural hematoma with clarity of a D-shaped outline with its base against the corresponding part of chest wall. The pleural reflection at the lower margin of the lesion is seen.

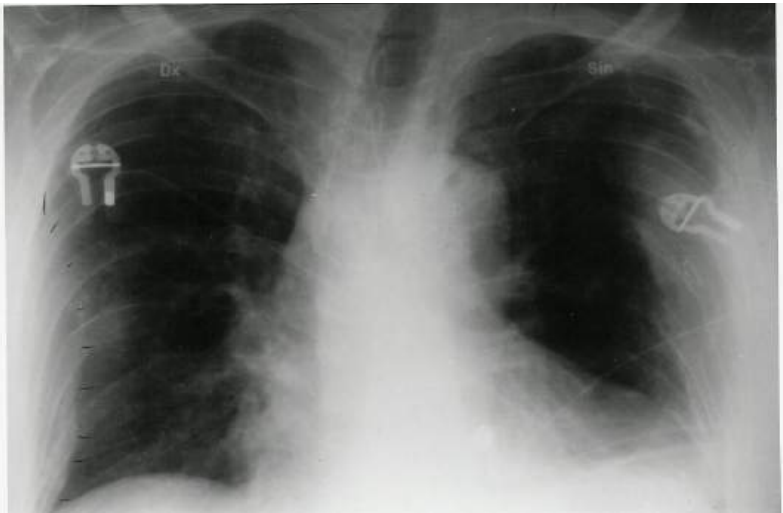


Fig. 4: CXR showing lower right extrapleural hematoma. The pleural reflection at the lower margin of the lesion is seen and the costophrenic angle is not obliterated.

All these patients were subjected to follow-up at least once following injury and a chest radiograph (CXR) was taken as a part of the routine follow-up. The EH decreased or disappeared within 3-6 weeks when small with a resulting pleural thickening. The most common complication was pain in six patients, chest tube complications and sternal hematoma in two patients each.

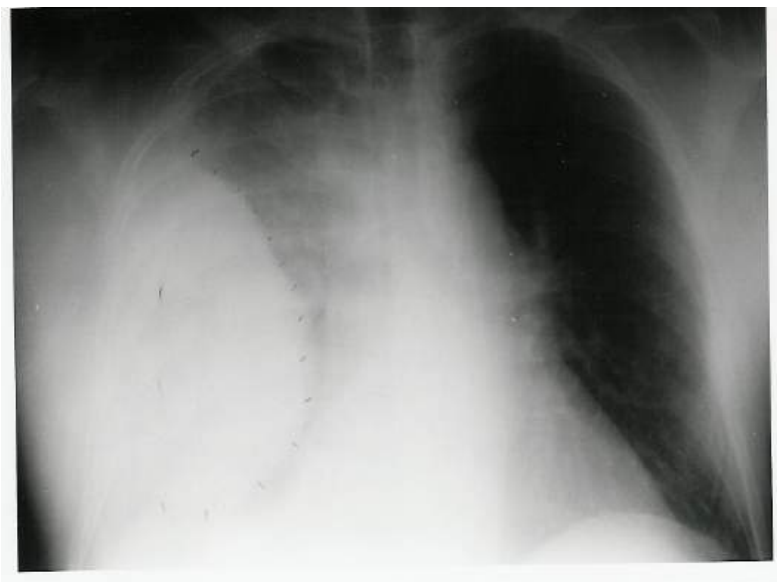


Fig. 5: CXR showing huge right extrapleural hematoma. Needle aspiration was unsuccessful and a thoracotomy was mandatory.

Sternal fractures

All sternal fractures were caused by blunt injury (paper II). No patients were found to have a myocardial contusion or aortic injury in the group with sternal fracture. A retrosternal hematoma was found adjacent to many of the fractures and ranged from a few millimeters to 2 centimeters and was more common in fractures to the body of the sternum (Fig. 6&7). Aortic injury was suspected after CXR in 7/29 cases. The further diagnostic work-up was done by aortography in 3 cases and computed tomography (CT) in 4 cases. An atherosclerotic (not traumatic) aneurysm was discovered by aortography in one patient who was successfully operated on with a prosthetic graft. One patient had a posttraumatic throacoabdominal aortic aneurysm in the group with widened mediastinum without sternal fractures. This patient was operated on, but died on the third postoperative day. A summary of the findings from this study are presented in Tables 3 and 4.

Table 3: Differences between retrosternal hematoma and widened mediastinum.

	<i>Retrosternal Hematoma</i>	<i>Widened mediastinum</i>
Site	Adjacent to sternal fractures	Diffuse
Size	Few millimeters to 2 cm	Larger in size
Mechanism	May be trivial trauma	Serious trauma
Sternal fracture	Usually present	Not usually present
Part of sternum	Body or manubrium	Not specific
Further work-up	Observation and CT if in doubt	CT and/or angiography

Table 4: Differences in the clinical data between retrosternal hematoma and widened mediastinum.

	<i>SF and RH Mean (SD)</i>	<i>No SF but with WM Mean (SD)</i>	<i>(P value)</i>
Associated thoracic lesions	1.3 (1.2)	2.4 (1.4)	<i>(p<0.05)</i>
Associated extrathoracic lesions	0.7 (1.8)	2.1 (2.5)	<i>(p<0.005)</i>
ISS	10.5 (3.2)	17.3 (10.4)	<i>(p<0.0001)</i>
LOS	7.5 (6.1)	16 (9.6)	<i>(p<0.0001)</i>
Cardiac injury	0	0	
Aortic injury	0	1	

SF; sternal fractures, RH; retrosternal hematoma, WM; widened mediastinum, ISS; injury severity score, LOS; length of hospital stay.

PULMONARY INJURIES

There were 32 patients with pulmonary contusions and thoracic lesions (average age 47.4 ± 17.5 , 25 males and 7 females) and 42 patients with pulmonary contusions and extrathoracic lesions (average age 40.6 ± 17 , 32 males and 10 females). The mechanism of injury was stabbing by knives in all patients in the penetrating group. The mechanism of injury in the blunt group is described in Table 5. Four patients (4/6) in the penetrating group presented with shock and all underwent urgent surgery (emergency room thoracotomy 1, urgent thoracotomy 2, and urgent thoracoabdominal exploration 1) successfully. All these patients survived without major sequelae.

ISS averaged 9.3 ± 4.8 in patients with thoracic lesions versus 24.1 ± 14.7 in patients with associated extrathoracic lesions ($p < 0.0001$), while ISS averaged 14.9 ± 9.5 in all survivors versus 49.9 ± 13.6 in those who died ($p < 0.0001$). No one died with $ISS < 29$, while all patients with $ISS \geq 40$ died (Table 6). All pulmonary injuries in this series were graded using AAST-OIS for lung injuries (Table 7) (77). The majority of pulmonary injuries were found in grade I without mortality, while 40% of mortalities were in grade IV. No injuries were clustered around grades V-VI (Table 7). The treatment and complications in patients with penetrating lung injuries as well as mortality are presented in Tables 8 and 9 respectively.

Table 5: The mechanism of injury in patients with nonpenetrating lung trauma.

<i>Mechanism of injury</i>	<i>(N)</i>	<i>(%)</i>
- Motor vehicle crash	30	(40)
- Fall	24	(32)
- Pedestrian-car/tram accident	9	(12)
- Crushing	3	(4)
- Miscellaneous (abuse 6, football trauma 1)	7	(9.3)
- Bicycle-motorcycle accident	1	(1.3)
- Barotrauma	1	(1.3)
<i>Total</i>	<i>75</i>	<i>(100)</i>

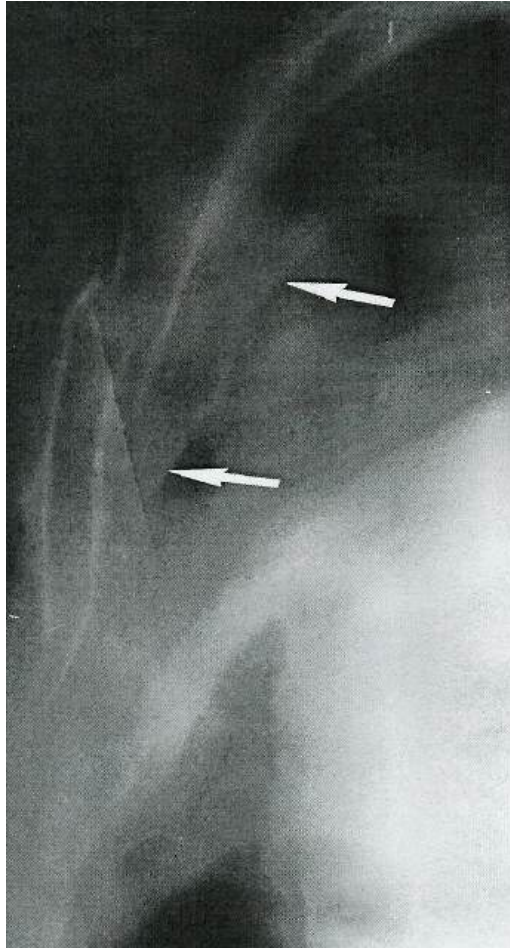


Fig. 6: A lateral sternal radiogram showing a transverse overlapping fracture in the body of the sternum in which the upper segment lies behind the lower fragment. The retrosternal hematoma is shown (arrowheads). Angiography of the aortic arch in this patient was normal.

Table 6: Mortality versus ISS in blunt trauma patients (N=75).

<i>ISS</i>	<i>Patients (N)</i>	<i>Deaths (N)</i>	<i>Mortality (%)</i>
- 0-10	32	0	0
- 11-20	23	0	0
- 21-30	8	1	12.5
- 31-40	8	1	12.5
> 40	4	4	100

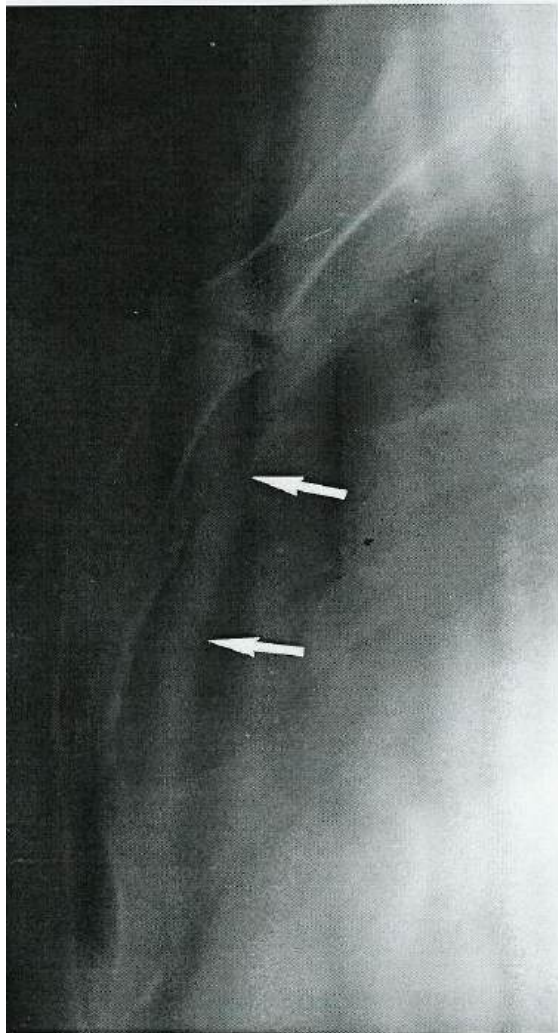


Fig. 7: A lateral sternal radiogram depicting a wide separation at the synchondrosis. The retrosternal bleeding is shown (arrowheads). The angiogram of the aortic arch in this patient was normal.

Table 7: American Association for the Surgery of Trauma–Organ Abbreviated Injury Scale (AAST-OIS); Lung Injury Scale.

<i>AAST-OIS Grade</i>	<i>No. of injuries</i>	<i>Total (%)</i>	<i>Mortality (%)</i>
- I	45	55.6	0
- II	13	16	15.4
- III	18	22.2	11.1
- IV	5	6.2	40
- V	0	0	0
- VI	0	0	0

Table 8: The treatment and complications in patients with penetrating lung injuries (N=6).

<i>Treatment</i>	<i>Complications</i>
- <i>Emergency room thoracotomy (right)</i>	- None
◦ Pulmonary hilar cross-clamping	
◦ Ligation of middle lobe pulmonary vessels	
◦ Pneumonorrhaphy of 2 big parenchymal lacerations	
- <i>Urgent thoracotomy (right)</i>	- None
◦ Ligation of pericardial artery	
◦ Evacuation of pericardial tamponade	
◦ Pneumonorrhaphy of 2 parenchymal wounds;	
◦◦ One in the right upper lobe	
◦◦ One in the middle lobe	
- <i>Urgent thoracotomy (left)</i>	- Pain
◦ Ligation of left internal mammary artery	
◦ Pneumonorrhaphy of 2.5 cm wound in cranial pole of left upper lobe	
- <i>Urgent thoracotomy (left)</i>	- Abscess in chest incision
◦ Pneumonorrhaphy of wound in left lower lobe	
◦ Two chest tubes	
◦ Gastrorrhaphy and diaphragmorrhaphy	
- <i>Chest tubes</i>	
◦ In 2 patients without shock	- None

Table 9: Mortality among patients with lung injuries.

<i>Age</i>	<i>Sex</i>	<i>ISS</i>	<i>Lung lesion</i>	<i>Cause of death</i>
- 75	- M	- 57	- Lung hematoma	- CNS lesion
- 20	- M	- 68	- Bilateral contusions	- CNS lesion
- 34	- M	- 40	- Unilateral contusion	- CNS lesion
- 84	- M	- 50	- Lung hematoma	- CNS lesion
- 46	- M	- 54	- Ruptured lung	- Hemorrhage
- 47	- F	- 29	- Bilateral contusions	- Posttraumatic MOF

M; male, F; female, MOF; multiple organ failure, CNS; central nervous system.

CARDIAC INJURIES

All patients with penetrating cardiac injuries abused drugs or alcohol or both (papers IV&V). Six patients presented in shock, while one patient with a penetrated pericardium was stable. Beck's triad (distended neck veins, hypotension, and muffled heart sounds) was found to be a good clinical indicator of cardiac tamponade (papers IV and V). Details of the operations done for the patients with penetrating injuries are shown in Table 10 (paper IV). In this paper, cardiac wounds involved the left ventricle in three, right ventricle in two, and the pericardium in two patients. All five patients with penetrating ventricular wounds presented with pericardial tamponade. The details of surgery in the Copenhagen experience is shown in Table 11, and its mortality in Table 12.

Patients with blunt trauma (myocardial contusion) were diagnosed on the basis of raised CK-MB activity, ST/T wave changes or arrhythmias (Table 13).

Table 10. Details of operations in seven patients with penetrating injuries (Swedish series, paper IV).

<i>Case</i>	<i>Operations</i>	<i>Lesions</i>
1	<i>Urgent left thoracotomy</i> - defibrillation (ventricular fibrillation) - cardiorrhaphy	- 5 mm Apical, and pericardial wound
2	<i>Urgent right thoracotomy</i> - ligation of pericardial artery	- Pericardial lesion
3	<i>Urgent left thoracotomy</i> - massive left hemothorax	- 1.5 cm Left ventricle pericardial wound and tamponade (at necropsy)
4	<i>Urgent laparotomy and sternotomy</i> - negative laparotomy - cardiorrhaphy	- 2 cm Pericardium, and 1 cm right ventricle
5	<i>Urgent left thoracotomy</i> - cardiorrhaphy	- 1 cm Left ventricle, and pericardial wound
6	<i>Delayed laparotomy and sternotomy</i> - cardiorrhaphy	- 1.5 cm Left ventricle, and pericardial wound
7	<i>Urgent laparotomy</i> - suturing of diaphragmatic lesion - insertion of right-sided chest tube	- Pericardial lesion

Table 11. Surgical procedures for patients with cardiac penetration or rupture (Danish series, paper V).

<i>Case</i>	<i>Surgical Procedures</i>	<i>Outcome</i>
1	<i>Emergency room thoracotomy</i> - cardiorrhaphy - Rt. pulmonary hilar cross clamping - pneumonorrhaphy	- Died during surgery from exanguination
2	<i>Urgent posterolateral thoracotomy</i> - cardiorrhaphy - reconstruction of TAR with CPB and circulatory arrest	- Died 4 days postop. from CNS lesions
3	<i>Urgent sternotomy</i> - cardiorrhaphy	- Survived (steel wire irritation)
4	<i>Urgent sternotomy</i> - cardiorrhaphy	- Survived (psychological disturbances)
5	<i>Urgent sternotomy</i> - cardiorrhaphy	- Survived (cardiac ischemic changes)

CNS: central nervous system, CPB: cardiopulmonary bypass, postop: postoperative, Rt: right-sided, TAR: traumatic aortic rupture.

Table 12. Mortality among patients with cardiac injuries (the second patient had a combined cardiac and aortic lesions).

<i>Age</i>	<i>Sex</i>	<i>ISS</i>	<i>Time of Death</i>	<i>Cause</i>
30	M	25	During surgery	Exanguination
39	M	42	4 days after surgery	CNS damage

Table 13. Reasons for diagnosis of blunt myocardial injury in 7 patients [paper IV (4 patients) and paper V (3 patients)].

<i>Variable</i>	<i>(Paper IV)</i>	<i>(Paper V)</i>
ST/T wave changes	3	3
Increased CK-MB	2	3
Right bundle branch block	1	1
Bradycardia	1	0
Tachycardia	1	0

THORACIC AORTIC INJURIES

In the Swedish material, there was only one patient with traumatic thoracoabdominal aortic injury, which presented as a thoracoabdominal pseudoaneurysm. This patient died due to exsanguination on the third postoperative day (paper II). The Danish series showed that the diagnosis of TAR is a difficult process. CXR was used in the primary survey and angiography was the gold standard in diagnosing TAR (Table 14). The type of bypass used during the repair of TAR is shown in Table 15.

Table 14. The diagnostic tools used in the detection of aortic lesions (Danish series, paper V).

	<i>Normal</i>	<i>Suspicious</i>	<i>Diagnostic</i>	<i>Figure</i>
<i>CXR</i>	2/8 (25%)	6/8 (75%)	0	8
<i>CT</i>	0	3/6 (50%)	3/6 (50%)	9
<i>TEE</i>	1/7 (14%)	0	6/7 (86%)	10
<i>Angiography</i>	0	0	4/4 (100%)	11

CT; computed tomography, CXR; chest radiographs, TEE; transesophageal echocardiography.

Table 15. The use of cardiac bypass during the repair of aortic lesions (Danish series, paper V).

<i>Lesion</i>	<i>Number</i>
Total cardiopulmonary bypass	1
Partial left cardiac bypass	
* Atrio-aortic	6
* Atrio-arterial	1
* Aortic-arterial	1

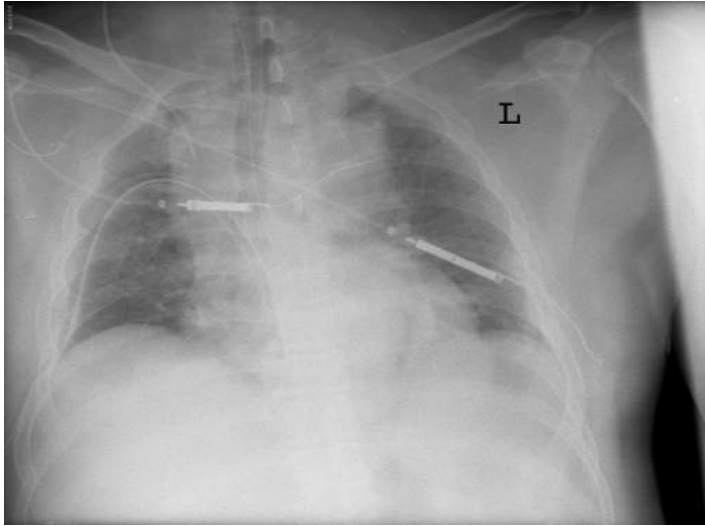


Fig. 8. CXR: Widened mediastinum is shown. This triggered further work-up in a patient who had a TAR diagnosed by angiography and confirmed at surgery.

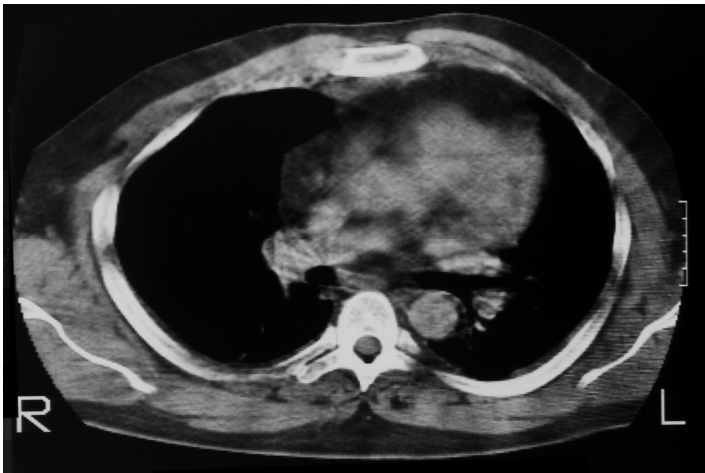


Fig. 9. CT scan of the chest suspecting TAR.

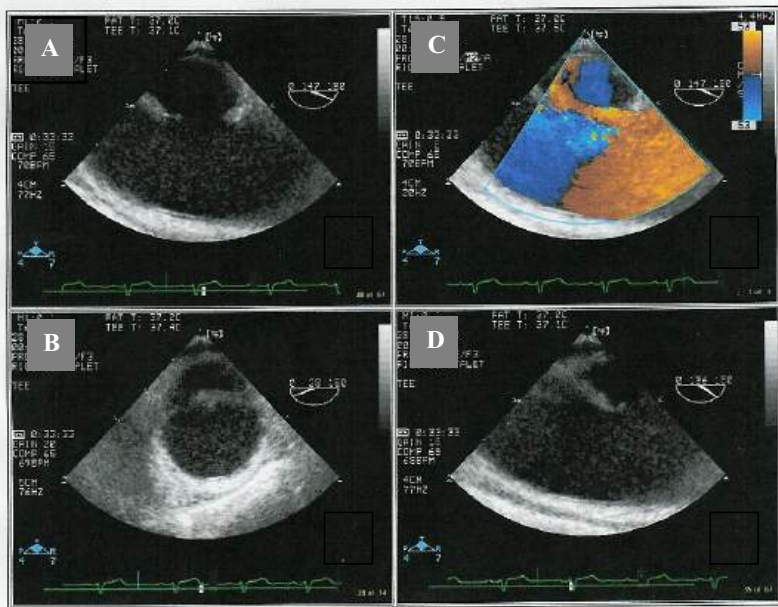


Fig. 10. Transesophageal echocardiography showing TAR at the isthmus. A 12-mm long rupture in the aortic wall (A), and 11x19 mm pseudoaneurysm located against the defect (B) are clearly illustrated. The flow of blood between the aneurysm and the aortic lumen is the same (C). A mobile intimal flap can be seen (D).

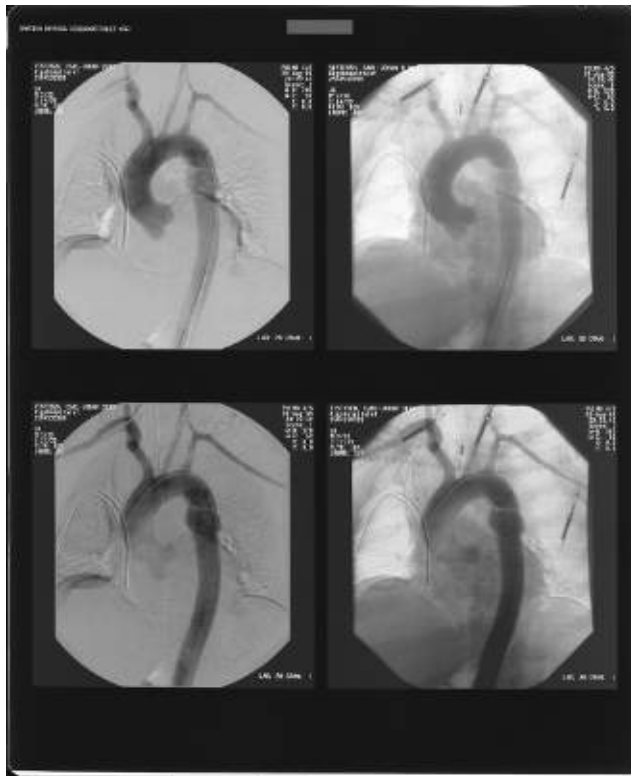


Fig. 11. Angiography showing TAR. The bulging and pseudocoarctation are visualised in all 4 projections.

DISCUSSION

This thesis represents a clinical experience of cardiothoracic trauma gained at two large surgical departments in Scandinavia. It highlights the fact that certain entities with significant clinical implications are rare, and that the personal experience in managing these injuries are low among most Scandinavian surgeons. However, when a seriously injured patient is admitted to the emergency department, it is critical to quickly resuscitate the patient (141) and diagnose the full extent of all severe injuries (142, 143). The selection of priorities for the definite treatment of such injuries may tax the wisdom of even the most experienced surgeon, and may present a serious challenge to the less experienced ones.

CHEST WALL TRAUMA

Injuries to the chest wall compromise the ventilatory function in three ways:

1. *Pain* is produced by the friction of one rib fragment against another at the site of fracture, stretching the periosteum with pain release. Reduction of the movement of a fractured rib reduces motion of the underlying lung parenchyma resulting in atelectasis that can lead to pneumonia and death.
2. *Chest wall defect* which can produce an open pneumothorax, with collapse of the affected lung and impaired ventilation.
3. *Paradoxical motion* described as flail chest is classically defined as two adjacent ribs fractured in two or more places. The external compression produced by the trauma forces the ribs inward enough to compress the lung and cause contusion. This underlying lung contusion plays a more important role in the pathophysiology of flail chest than does paradoxical movement (25).

- *Extrapleural hematoma*

A suggestion was made in paper I to call the hematoma extrapleural which is more appropriate than subpleural, epi-pleural, or retropleural. The pathophysiology of TEH differs slightly between blunt and penetrating injury. In case of blunt thoracic injury, the impact suddenly increases the intrathoracic pressure causing vascular rupture of the chest wall with blood collection, which cannot escape into the pleural space (hemothorax) especially when the parietal pleura remains intact, producing TEH. In case of penetrating injuries, TEH will occur, if the parietal pleura is not breached or the laceration in it is small or the underlying lung is adherent to the chest wall (Paper I).

A simple etiological classification of extrapleural hematoma; spontaneous, iatrogenic and traumatic was presented (Table 2). TEH impose diagnostic difficulties, however, the displaced "*extrapleural fat layer and parietal pleura sign*" (Fig. 12) is an aid in the detection of TEH using CT scan in trauma patients (92). Video-assisted thoracoscopic surgery (VATS) has been proposed as the preferred approach for the management of pleural disease (67). This has been questioned in patients with TEH (92). TEH is important as it may be confused with more serious intrathoracic lesions such as neurofibroma, pleural effusion or tumor, mediastinal tumor or pulmonary lesions. Diagnostic abnormalities can be encountered several months after the onset of TEH, due to its reticular pattern, particularly when it is incompletely resolved. It is important to recognize TEH because it is usually managed conservatively, with resolution in the majority of patients. Insertion of chest tubes is often ineffective and may be dangerous, especially if the pleural space is obliterated.

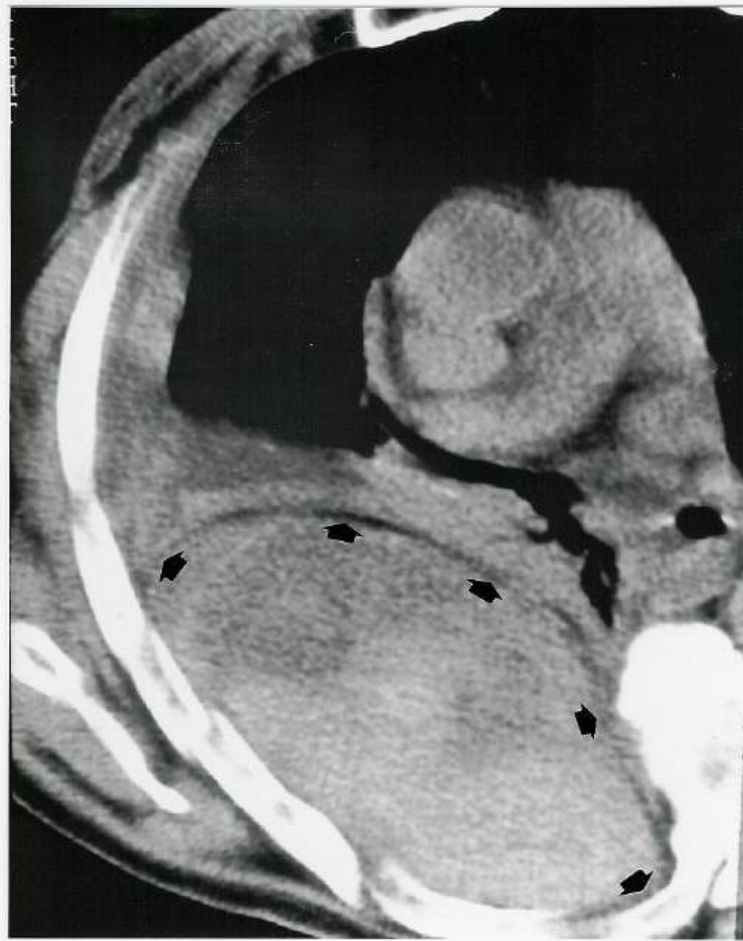


Fig. 12: CT scan of the chest showing two fluid collections separated by a low-attenuated stripe representing medially displaced *extrapleural fat and parietal pleura* (arrowheads). The outer huge fluid collection has heterogenous attenuation consistent with blood.

- *Sternal fractures*

Paper II suggests that sternal fractures per se are usually benign. The most common associated injuries were rib fractures. Sternal fracture has been reported to be associated with cardiac injuries (125). This was not seen in our study, which is consistent with others (48). This could be explained by the fact that clinical and laboratory findings of cardiac contusion are sometimes indistinguishable from those found in multiple injuries which were found in the majority of patients in this report (89.7%). Cardiac contusion in this study probably was overshadowed by the overt manifestation of associated skeletal, abdominal, thoracic or cerebral injuries. The ECG changes and the pathological CK-MB are considered the standard in the diagnosis of myocardial contusion in large series of blunt trauma patients (58). The incidence of associated aortic rupture was nil in the cases with sternal fractures compared to one in the group of patients with chest trauma without sternal fractures. Postoperative pain was the salient complaint during follow-up visits, causing significant absence from work and even long-term disability (2/29). The retrosternal hematoma in patients with sternal fractures can be differentiated from real mediastinal widening using the features in Tables 3 and

4, which may aid in the management of sternal fractures and associated injuries. This may reduce unnecessary angiograms in the stable patient with traumatic retrosternal hematoma. Sternal fractures with or without retrosternal hematomas in this study were not associated with cardiac or aortic injuries, while mediastinal widening is still a fairly reliable clue which should initiate further work-up.

PULMONARY INJURIES

All penetrating wounds of the lung in this study (paper III) were caused by knife stabs, which produce injury only along the wound tract, with minimal contusion. The majority of patients with penetrating lung trauma may be treated with chest tubes only (50, 112), while thoracotomy, if indicated, should be performed very soon after admission if it is to be an effective procedure (2, 50). EDT/ERT in patients with penetrating thoracic injury is often more successful after cardiac than extracardiac (great vessel, hilum or lung) trauma (37). Good outcome with this maneuver and with all urgent thoracotomies for pulmonary injuries have been achieved (paper III). Furthermore, acute thoracotomy is recommended for patients with penetrating chest trauma and in hemorrhagic shock, without evidence of cardiac, aortic, or major vessel injury (103). In this study (paper III), pulmonary contusions obviously seem to be lesions almost always associated with other thoracic lesions; most commonly rib fractures, hemothorax and pneumothorax. Chest physiotherapy and pain relief using intravenous analgesia, intercostal nerve blocks, intrapleural and epidural analgesia should be used as needed. Adequate and selective ventilatory support and frequent airway suction procedures to prevent pneumonia are important. This series differs from others (123) in that, the incidence of associated injuries in the chest was more severe and doubles the incidence of extrathoracic lesions. A similar observation has been reported from San Francisco (25) and showed that a higher morbidity and mortality included severe associated thoracic injuries. Patients who suffer pulmonary contusions are often victims of blunt trauma with multiple injuries (25, 56). This has been noticed in our series (paper III). The hospital mortality in patients with pulmonary contusion and extrathoracic lesions was 6/42 (19%) due to associated injuries, mostly central nervous system lesions (4/6).

Another aim of this study (paper III) was to present the incidence of concomitant pulmonary contusion in multitraumatized patients in general and in patients with other chest injuries, and to find out whether lung contusion in itself adds to morbidity and mortality. We found that lung contusion per se added nothing to morbidity or mortality. The nature of lung lesions (contusion with or without flail chest, lacerations, and lung hematomas) showed a tendency towards the group with extrathoracic lesions but this was not significant. Therefore, we consider the concomitant lung contusion in patients with chest trauma as a benign lesion.

CARDIAC INJURIES

Penetrating cardiac injuries are associated with high mortality, which has improved only minimally in the last three decades despite the institution of elaborate prehospital systems and modern technological advances (109). The diagnosis of penetrating cardiac injury should be considered in all patients with penetrating wound to the chest, neck or upper abdomen, with cardiovascular instability.

Pericardial tamponade means the presence of bleeding into the pericardial sac, impairing heart function. The same effect can be caused by pneumopericardium when

tension occurs (29). Tamponade may occur even if the blood escapes to the pleural cavity causing hemothorax. The decrease in stroke volume and CO will cause tachycardia to compensate the fall in CO. If bleeding continues right ventricular obstruction will occur. On the other hand, pericardial tamponade may prevent a massive hemorrhage and death giving a chance to surgery and survival (30) (papers IV and V). Beck's triad (10) is a clinical aid for the diagnosis of pericardial tamponade whatever the cause. Hypotension, congested neck veins, and muffled heart sounds constitute this triad. These vital signs are cardinal in all patients with chest trauma and are usually documented, whether positive or negative. However, congested neck veins could be caused by tension pneumothorax and even in the presence of a cardiac tamponade this sign might be absent due to hypotension caused by bleeding from other injuries. Muffled heart sounds are the least reliable in this triad since assessment of heart sounds may be difficult in a noisy ED/ER. Therefore, we have not relied just on muffled heart sound as a diagnostic criteria when it was the only sign found.

EDT/ERT is indicated in moribund patients, presenting with at least one vital sign of life (respiratory efforts, cardiac activity or reactive pupils) or in those who abruptly decompensate hemodynamically during resuscitation (31, 55, 70). This procedure was done in two patients, with one survivor (papers III & V). Urgent thoracotomies/sternotomies with or without laparotomy were performed in 13 cases with 11 survivors without major sequelae (papers III, IV & V). When the patient presents with a weapon like a knife or any object penetrating the chest, this must not be disturbed since the object serves as a tamponade by sealing the cardiac wound (95, 144). This should be done only after making the appropriate incision, enabling the surgeon to perform the extraction under direct visual control. This policy is important not only for heart injuries but also for any impalement injury of the torso.

In our series, clinically significant blunt injuries to the heart were rare.

THORACIC AORTIC INJURIES

The descending thoracic aorta is firmly attached to the thoracic spine, whereas the heart and aortic arch are more loosely suspended in the mediastinum. Aortic rupture is thought to occur either from traction or shear forces generated between relatively mobile portions of the vessel and points of fixation or, secondly, due to direct compression over the vertebral column or, thirdly, caused by an excessive increase of intraluminal pressure. The greatest shear force occurs just distal to the left subclavian artery (87). Such an injury occurred in 8 patients (paper V).

The diagnosis of TAR continues to be a challenge. In the Danish material (paper V), we found that the CXR gave an early clue to the suspicion of TAR in the majority of cases. The widened mediastinum was the most frequently cited CXR finding that triggered further work-up. CXR in patients with blunt chest trauma may show signs of mediastinal widening leading to aortography according to the ATLS protocols of the American College of Surgeons (5). However, our observations in patients with sternal fractures may make selection easier and avoid unnecessary angiograms (102). CT scan for the diagnosis of TAR is considered to be less invasive, safer, faster, simpler, cheaper, with less resource intensive than aortography. CT scanning of the chest particularly the helical one has been shown in some series to have a sensitivity and negative predictive value equivalent to that of aortography (86). Some centers have relied on CT as the screening and diagnostic method of choice while aortography has been reserved for equivocal cases (22, 33). Other centers still recommend aortography as the method of choice (38). The associated aortic arch injuries can be missed using either CT scan or TEE and angiography can be helpful (3). In our series, CT scans were

performed in 6 patients and was suspicious but not conclusive (Table 14). Thus CT scan did not alter decision making in our hands. TEE is a highly sensitive and specific tool in detecting TAR in the critically injured patients and compares favourably with aortography (119). TEE is a very sensitive screening test, but its availability is limited due to the need of specifically trained investigators (46). TEE yielded a false negative result in 1 case in our experience. Although aortography, which has been the reference-standard procedure for the detection of TAR, is relatively safe, it is expensive, time-consuming, resource intensive, and invasive. Angiography is still the gold standard in diagnosing TAR according to the latest guidelines recommended by the EAST practice management guidelines work group (80). In a twenty-year meta-analysis study (136), the authors found only 1742 patients who reached the hospital alive. Furthermore, a prospective multicenter trial of TAR involving 50 busy trauma centers in North America (36) has shown a mortality rate of 34% and a paraplegia rate of 10%. These major trials reported that angiography is still the “gold standard” to diagnose TAR. This is in accordance with ATLS protocols (5). We performed angiography in 4 patients and showed TAR in all of them (Table 14). Magnetic resonance imaging (MRI) has been tried just in very few case-reports (26) where it shows the lesion perfectly, whether partial or circumferential, a diverticular or a fusiform pseudoaneurysm, its size and distance from the other structures, particularly left subclavian artery, the presence of periaortic hematoma, pericardial, mediastinal or pleural effusion, and other associated injuries. So it is useful in selected subacute patients particularly those patients subjected to delayed treatment.

When the patient is a poor operative candidate because of age or comorbidities, the repair of TAR may be delayed. Other causes of hemodynamic instability such as pelvic or femur fractures should be assessed first before going to aortography and repair of TAR (111). When the diagnosis is confirmed, the timing and optimal method of treatment must be decided. If treatment has to be delayed, patients are recommended to be kept on the lowest blood pressure that they can tolerate. Beta-blockers or Nitroprusside can be used to lower the blood pressure (35). Minimal invasive therapy is an evolving technology in the management of patients with TAR. Since the publication of the first use of endovascular stent-grafting (ESG) for abdominal aortic aneurysms in 1991 (89) several patients with TAR have been successfully managed (62).

OTHER CHEST INJURIES

Iatrogenic penetration of the right atrium during pacemaker insertion was obvious in our series from Copenhagen (104). Iatrogenic penetration of the descending thoracic aorta with a nail during a neurosurgical procedure was also reported in our material (104). Iatrogenic lesions occurring with CTT which is the most common procedure in chest trauma are numerous and we have described a considerable number of such injuries (92, 94, 95, 98, 99). In fact, iatrogenic injuries is becoming one of the most common causes of injury to the chest. However, no tracheobronchial injuries, air embolism or thoracic duct injuries have been detected in our series.

CONCLUSIONS

CHEST WALL TRAUMA

Extrapleural hematoma (paper I)

- A nomenclature, classification, and treatment for TEH are described.
- TEH should be differentiated from the classic hemothorax since the treatment of each entity is different.
- TEH is important as it may be confused with more serious intrathoracic lesions

Sternal fracture (paper II)

- Sternal fractures are not reliable indicators of cardiac or aortic injuries in the multitrauma patient.
- Our suggestions given to differentiate between retrosternal hematoma, and widened mediastinum could be helpful in managing patients with sternal fractures and suspected cardiovascular injuries, thus reducing the number of CT scans, and angiograms.

PULMONARY INJURIES (*paper III*)

- Good results can be achieved by an aggressive approach in managing patients with penetrating lung injury presenting with shock.
- Pulmonary contusion is considered as a relatively benign lesion.
- Associated CNS lesions play a major role in the mortality of patients with lung injuries.

CARDIAC INJURIES (*papers II, IV and V*)

- Although Beck's triad can be deceptive, it is found to be a reliable clinical aid in the detection of penetrating cardiac injuries.
- Our results reflect a Scandinavian experience of cardiac trauma, where good results can be achieved by immediate diagnosis, and aggressive treatment, despite small numbers.

THORACIC AORTIC INJURIES (*papers II and V*)

- Chest radiogram is a good screening method for patients with TAR.
- CT scan is a useful screening examination in the stable patient with TAR, but does not alter decision making.
- Angiography remains the gold standard to diagnose TAR.
- Bypass seems to prevent paraplegia in the treatment of TAR.

THE FUTURE

Since the majority of patients with blunt cardiothoracic trauma were caused by MVC (Papers I-V), the future should concentrate on the prevention of these injuries. Such a policy includes improvements in motor vehicle design, air bags and passive restraint devices which altogether have the greatest impact in reducing mortality (117). All penetrating injuries in this thesis were caused by different types of knives, and one would suggest and encourage the Swedish and Danish laws to mandate knife control legislation besides gun control legislation. The majority of trauma deaths take place in the prehospital phase, prior to initiation of resuscitation, and the only cure is to prevent them from occurring. Furthermore, the majority of surgeons - even those working with trauma - are not involved in injury prevention programs which are important for both the medical staff as well as the public (59). A thorough knowledge of trauma care (128, 129, 143), especially early recognition, rapid transport to hospital (20), aggressive resuscitation and expeditious surgical intervention are essential for successful management.

Technology is also needed to improve the performance of chest protectors used in sports so as to decrease or prevent the incidence of cases with commotio cordis usually seen in young healthy athletes who die immediately on the scene (135). In Scandinavian countries, such patients usually get another diagnosis or not at all, due to the lack of knowledge of cardiac injuries (papers II, IV, V). Consistent with rib cage geometry, the ribs are flatter and less supported in the lateral position. The point of maximal weakness of the thoracic cage is located at 60 degrees rotation from the sternum (134). This has significant implications for automotive design as 32% of passenger car fatalities take place in lateral impact crashes, which frequently involve the elderly and the risk for injury increases steadily with age (133). This may help in the development of chest stress wave decouplers to protect the lungs from overpressure (28).

The minimally invasive nature of endovascular stents make them very attractive in accordance with the new trend in surgery to develop less invasive procedures aiming at reduction of operative risks and complications. ESG is still in its early stages of development and one should follow reasonable guidelines, which direct the development of such a feasible technique and to prevent unjustified overuse (132). Currently, these devices are not available for urgent cases, but in the near future, we can expect to have sufficient inventory of devices available for emergency use.

Prevention of secondary injuries caused by trauma as a result of physiologic decompensation, delay in treatment, or suboptimal management is essential. Research in the future should be directed towards this target. Secondary injuries in case of brain and abdominal trauma are better recognized than in case of chest trauma. Secondary injury in cardiothoracic trauma could be similar resulting in MOF caused by general inflammatory response with subsequent release of oxygen-derived free radicals with its damaging effects. This may potentiate a modification in clinical protocols used in the management of patients with cardiothoracic trauma in the future.

ACKNOWLEDGEMENT

- My deepest gratitude belongs to my **parents** who taught me how to live the life and who instilled in me a keen interest in surgery and a strong power to succeed. Mother and Father; I never ever forget you or disappoint you in spite of thousands of miles from you in the motherland Egypt. Your belief in me kept me going on when I was, sometimes “just about to give up”. I feel to express my heartfelt appreciation to my **grandparents** who envisioned and upheld an uncompromising goal in life, which was “to be what you want to be at any place in this world”. Sadly, they recently died without sharing me this honour. Special heartfelt thanks go to my **sisters and brothers** in Egypt and the **big family** over there.
- I wish to thank with deep appreciation my advisor associate professor **Per Örténwall**, for his continuing support, constructing criticism, and friendship. Thank you very much **Per** for never giving-up during this time-consuming and effort-demanding project.
- I also wish to thank acting professor **Tore Vikström**, my co-author for his encouraging criticisms, “traumatic” discussions, and friendship. Many thanks **Tore** for your fruitful ideas when **you, Per** and **me** had a meeting.
- I owe many thanks to my friend, colleague, and co-author associate professor **Jens Lund** at the Department of Cardiothoracic Surgery, Copenhagen University Hospital “Rigshospitalet” for his skilful cooperation during surgery, and I never forget the several hours operating together while listening to **Tracy Chapman** “...*Knives and guns are drawn, two black boys get killed. Why are the missiles called peace keepers, while they ´re aimed to kill... etc*”
- A lot of thanks go to the whole staff at the Department of Cardiothoracic Surgery, Copenhagen University Hospital “Rigshospitalet” for a pleasant time there, fantastic cooperation, and for allowing me to enjoy working with them.
- Many heartfelt thanks with deep appreciation go to professor **Kent Lundholm**, the chief of the Division of Surgery, Sahlgrenska Academy, Gothenburg University, who recently decided that this work should come into its reality. **Kent**, without your help, this thesis would not existed!
- A lot of thanks go to professor **Håkan Ahlman**, at the Division of Surgery, and professor **Rolf Ekrot** at the Department of Cardiothoracic Surgery, Sahlgrenska University Hospital, Gothenburg University for their positive impressions to go on with this dissertation 1999.
- Many thanks go to professor **Bo Risberg** at the Division of Vascular Surgery, to professor **Michael Olausson** chief the Division of Transplantation Surgery, and associate professor **Stefan Lundin** at the Department of Anesthesia, Sahlgrenska University Hospital for their valuable advice at the predisputation held on March 3, 2003.
- Special thanks to Dr. **Bo Palmertz**, at the Department of Radiology Sahlgrenska University Hospital/Östra for his great help.
- Many thanks go to associate professor **Ingvar Holmberg**, at the Department of Economics and Statistics, Gothenburg University, for his great help with the statistics.

- I heartedly thank associate professor **James O'Connor**, the Director of Department of Thoracic and Vascular surgery at the R Adams Cowley Shock Trauma Center in Baltimore, Maryland's University Medical Center, USA. Thank you **Jim** for your revision of the thesis and your much appreciated comments which were taken into consideration throughout the dissertation.
- I owe many thanks to professor **John A. Odell**, the Director of Department of Thoracic and Cardiovascular Surgery at Mayo Clinic in Jacksonville, Florida, USA. **John**, many thanks for your comprehensive revision of the thesis and for your much appreciated comments which definitely were taken into consideration throughout the thesis.
- I cordially thank with deep appreciation professor **Kenneth L. Mattox**, Vice Chairman of Surgery in the General Surgery Division of the Michael E. DeBakey Department of Surgery at Baylor College of Medicine and Chief of the Surgery Service and Chief of Staff at Ben Taub General Hospital, Houston, Texas, USA. Thank you very much **Ken** for taking your precious time to revise the material of the thesis. Your revision was much appreciated and your invaluable comments were considered in the manuscript.
- Finally, I would like to express my deep gratitude to my wife **Christina**, to my lovely daughter **Magda** (10 y) who usually makes wonderful drawings to me, and to my dear son **Joseph** (6 y) with his unforgettable and encouraging smiles and his patience when I occupied the computer for this work, and to my dear son **Jacob** (1 y) who almost always wants to play with me, simply by turning the computer off, detaching its connection, looking at me... and laughs loudly - just teasing me. I thank you all for your endless love, patience, and support.

REFERENCES

A

1. Absolom KB. Theodor Billroth and cardiac surgery. *J Thorac Cardiovasc Surg* 1983;86:451-452.
2. Adkins RB, Jr., Whiteneck JM, Woltering EA. Penetrating chest wall and thoracic injuries. *Am Surg* 1985;51:140-148.
3. Ahrar K, Smith DC, Bansal RC, Razzouk A, Catalano RD. Angiography in blunt thoracic aortic injury. *J Trauma* 1997;42:665-669.
4. Aquino SL, Chiles C, Oaks T. Displaced extrapleural fat as revealed by CT scanning: evidence of extrapleural hematoma. *Am J Roentgenol.* 1997;169: 687-689.
5. American College of Surgeons, Committee on Trauma. *Advanced Trauma Life Support Manual.* Washington DC: ACS, 1997.
6. Anderson ID, Woodford M, de Dombal FT, Irving M. Retrospective study of 1000 deaths from injury in England and Wales. *BMJ* 1988;296:1305-1308.
7. Aron C, Jounieaux V, Nikels JC, Toris T. Extrapleural hematoma: emergency diagnostic pitfall. Value of computerized x-ray tomography [in French]. *Rev Pneumol Clin* 1992;48:169-171.
8. Asensio JA, Murray J, Demetriades D, et al. Penetrating cardiac injuries: a prospective study of variables predicting outcomes. *J Am Coll Surg* 1998;186:24-34.

B

9. Baker SP, O'Neill B, Haddon W, Jr., Long WB. The injury severity score: a method for describing patients with multiple injuries and evaluating emergency care. *J Trauma* 1974;14:187-96.
10. Beck CS. Two cardiac compression triads. *JAMA* 1935;104:714-716.
11. Besson A, Saegessen F. Color atlas of chest trauma and associated injuries, Vol 1. Oradell, NJ, Medical Economic Books, 1982.
12. Blair E, Topuzlu C, Davis JH. Delayed or missed diagnosis in blunt chest trauma. *J Trauma* 1971;11:129-140.
13. Bluhm R, Gross N. Extrapleural hemorrhage. *Clin Notes Resp Dis* 1980;19:11-12.
14. Bone L, Bucholz R. The management of fractures in the patient with multiple trauma. *J Bone Joint Surg Am* 1986;68:945-949.
15. Born CT, Ross SE, Iannacone WM, et al. Delayed identification of skeletal injury in multisystem trauma: the "missed" fracture. *J Trauma* 1989;29:1643-1646.
16. Bowling R, Mavroudis C, Richardson JD, Flint LM, Howe WR, Gray LA, Jr. Emergency pneumonectomy for penetrating and blunt trauma. *Am Surg* 1985;51:136-139.
17. Brandi LS, Mosca F, Carmellini, et al. An unusual complication of percutaneous catheterization of the internal jugular vein. *Acta Anæsthesiologica Belgica* 1984;35:231-236.
18. Breasted JH, ed. *The Edwin Smith Surgical Papyrus.* Vol 1, Chicago: The University of Chicago Press, 1930: 369-373.
19. Bried JM, Cordasco FA, Volz RG. Medical and economic parameters of motorcycle-induced trauma. *Clin Orthop* 1987;223:252-256.
20. Buckman RF, Jr, Badellino MM, Mauro LH, et al. Penetrating cardiac wounds: prospective study of factors influencing initial resuscitation. *J Trauma* 1993;34:717-725.
21. Butchart EG, Grötte GJ, Barnsley WC. Spontaneous rupture of an intercostal artery in a patient with neurofibromatosis and scoliosis. *J Thorac Cardiovasc Surg* 1975;69:919-921.

C

22. Cardarelli MG, McLaughlin JS, Downing SW, Brown JM, Attar S, Griffith BP. Management of traumatic aortic rupture: a 30-year experience. *Ann Surg* 2002;236:465-469.
23. Cappelen A. *Vulnus cordis*: Suture af hjertet. *Norsk Magazin Lægevidenskaben* 1896;6:285-288.
24. Chan RN, Ainscow D, Silkorski JM. Diagnostic failures in the multiple injured. *J Trauma* 1980;20:684-687.
25. Clark GC, Schechter WP, Trunkey DD. Variables affecting outcome in blunt chest trauma: flail chest vs. pulmonary contusion. *J Trauma* 1988;28:298-304.
26. Cohn SM, Pollak JS, McCarthy S, Degutis LC. Detection of aortic tear in the acute trauma patient using MRI. *Magn Reson Imaging* 1994;12:963-967.
27. Committee on Injury Scaling: The Abbreviated Injury Scale, 1990 revision. Des Plaines, Illinois, American Association for Automotive Medicine, 1990.
28. Cooper GJ. Protection of the lung from blast overpressure by thoracic stress wave decouplers. *J Trauma* 1996;40:S105-S110.
29. Cummings RG, Wesly RL, Adams DH, Lowe JE. Pneumopericardium resulting in cardiac tamponade. *Ann Thorac Surg* 1984;37:511-518.

D

30. Demetriades D. Cardiac wounds: experience with 70 patients. *Ann Surg* 1986;203:315-317.
31. Demetriades D, Rabinowitz B, Sofianos C. Emergency room thoracotomy for stab wounds to the chest and neck. *J Trauma* 1987;27:483-485.
32. Dirnhofer R, Sigrist Th, Ranner G. The "epipleural" haematoma: origin, morphology and progress [in German]. *Unfallheilkunde* 1984;87:180-183.
33. Downing SW, Sperling JS, Mirvis SE, et al. Experience with spiral computed tomography as the sole diagnostic method for traumatic aortic rupture. *Ann Thorac Surg* 2001;72:495-501.

E

34. Eddy AC, Carrico CJ, Rusch VW. Injury to the lung and pleura. In: Moore EE, Mattox KL, Feliciano DV, eds. *Trauma*. 2nd ed. Norwalk, Connecticut: Appleton&Lange: 1991:357-371.

F

35. Fabian TC, Davis KA, Gavant ML, Croce MA, Melton SM, Patton JH Jr, Haan CK, Weiman DS, Pate JW. Prospective study of blunt aortic injury: helical CT is diagnostic and antihypertensive therapy reduces rupture. *Ann Surg* 1998;227:666-677.
36. Fabian TC, Richardson JD, Croce MA et al. Prospective study of blunt aortic injury: multicenter trial of the American Association for the Surgery of Trauma. *J Trauma* 1997;42:374-380.
37. Feliciano DV, Bitondo CG, Cruse PA, et al. Liberal use of emergency center thoracotomy. *Am J Surg* 1986;152:654-659.
38. Fisher RG, Chasen MH, Lamki N. Diagnosis of injuries of the aorta and brachiocephalic arteries caused by blunt chest trauma: CT vs aortography. *Am J Roentgenol* 1994;162:1047-1052.
39. Foege W. Highway violence and public policy. *N Engl J Med* 1987;316:1407-1408.
40. Fulda G, Brathwaite CE, Rodriguez A, Turney SZ, Dunham CM, Cowley RA. Blunt traumatic rupture of the heart and pericardium: a ten-year experience (1979-1989). *J Trauma* 1991;31:167-172.

41. Frazee RC, Mucha P, Farnell MB, Miller FA, Jr. Objective evaluation of blunt cardiac trauma. *J Trauma* 1986;26:510-520.

G

42. Galen C. *De locis affectis* (translation RE Seigel). Basel: S Karger, 1976; 139.
43. Garland DE, Bailey S. Undetected injuries in head-injured adults. *Clin Orthop* 1981;155:162-165.
44. Gertner HR, Jr., Baker SP, Rutherford RB, Spitz WU. Evaluation of the management of vehicular fatalities secondary to abdominal injury. *J Trauma* 1972;12:425-431.
45. Gill W, Champion HR, Long WB, et al. A clinical experience of major multiple trauma in Maryland. *Md State Med J* 1976;25:55-58.
46. Goarin JP, Catoire P, Jacquens Y, et al. Use of transesophageal echocardiography for diagnosis of traumatic aortic injury. *Chest* 1997;112:71-80.
47. Godwin JD, Tolentino CS. Thoracic cardiovascular trauma. *J Thorac Imaging* 1987;2:32-44.
48. Gouldman JW, Miller RS. Sternal fractures: a benign entity? *Am Surg* 1997;63:17-19.
49. Graham EA, Bell RD. Open pneumothorax: its relation to the treatment of empyema. *Am J Med Sci* 1918;156:839.
50. Graham JM, Mattox KL, Beall AC, Jr. Penetrating trauma of the lung. *J Trauma* 1979;19:665-669.

H

51. Heise HA. Alcohol and automobile accidents. *JAMA* 1934;103:739.
52. Herridge MS, de Hoyos AL, Chaparro C, et al. Pleural complications in lung transplant recipients. *J Thorac Cardiovasc Surg* 1995;110:22-26.
53. Hippocrates, Writings. In: Great books of the western world. Hutchins RA, ed. Chicago: Encyclopedia Britannica Inc, 1952;29, 142.
54. Homer. *The Iliad*. Book XIII; Vol II. Cambridge, MA: Harvard University Press, 1924.

I

55. Ivatury RR, Shah PM, Ito K, Ramirez-Schon G, Suarez F, Rahman M. Emergency room thoracotomy for the resuscitation of patients with 'fatal' penetrating injuries of the heart. *Ann Thorac Surg* 1981;32:377-385.

J

56. Johnson JJ, Cogbill TH, Wingo ER. Determinants of outcome after pulmonary contusion. *J Trauma* 1986;26:695-697.

K

57. Kay J, Goodman LR, Gurney J. Extrapleural hematoma: a recognizable complication of central venous pressure monitoring. *J Clin Monit* 1987;3:64-66.
58. Kettunen P. Cardiac damage after blunt chest trauma, diagnosed using CKMB enzyme and electrocardiogram. *Int J Cardiol* 1984;6:355-371.
59. Knudson MM, Vassar MJ, Straus EM, Hammond JS, Campbell SD. Surgeons and injury prevention: what you don't know can hurt you! *J Am Coll Surg* 2001;193:119-124.
60. Komoda K, Hujii Y, Nakajima T, et al. A ruptured thymic branch aneurysm mimicking a ruptured aortic aneurysm, with associated bronchial artery aneurysms: Report of a case. *Surgery Today-Jpn J Surg* 1994;24:258-262.

61. Kucich VA, Vogelzang RL, Hartz RS, et al. Ruptured thoracic aneurysm: unusual manifestation and early diagnosis using CT. *Radiology* 1986;160:87-89.

L

62. Lachat M, Pfammatter T, Witzke H, Bernard E, Wolfensberger U, Kunzli A, Turina M. Acute traumatic aortic rupture: early stent-graft repair. *Eur J Cardiothorac Surg* 2002;21:959-963.
63. Lawrence GH. Closed chest tube drainage for pleural space problems. In: *Major problems in clinical surgery*, vol 28. Problems of the pleural space, 1983:14-24.
64. Le Cicero J, Mattox KL. Epidemiology of chest trauma. *Surg Clin North Am* 1989;69:15-19.
65. Lipchik EO, Robinson KE. Acute traumatic rupture of the thoracic aorta. *Am J Roentgenol Radium Ther Nucl Med* 1968;104:408-412.

M

66. Machin VG, Lau OJ. Extra-pleural haematoma secondary to blunt chest trauma: an unusual presentation. *Eur J Cardiothorac Surg* 1995;9:109-110.
67. Mack MJ, Scruggs GR, Kelly KM, Shennib H, Landreneau RJ. Video-assisted thoracic surgery: has technology found its place? *Ann Thorac Surg* 1997; 64:211-215.
68. Manenti A, Buttazzi A, Speranza M, Barbieri A. Left extrapleural hemothorax from rupture of the subclavian artery. *Resuscitation* 1989;18:163-164.
69. Massard G, Roeslin N, Wihlm JM, Morand G. Extrapleural hematoma as a late complication of collapse therapy for tuberculosis [letter]. *Chest* 1992;101:1476-1477.
70. Mattox KL, Beall AC, Jr, Jordan GL, Jr, DeBaakey ME. Cardiorrhaphy in the emergency center. *J Thorac Cardiovasc Surg* 1974;68:886-895.
71. Mattox KL, Pickard LR, Allen MK. Emergency thoracotomy for injury. *Injury* 1986;17:327-331.
72. McEnany MT, Austen WG. Life-threatening hemorrhage from inadvertent cervical arteriotomy. *Ann Thorac Surg.* 1977;24:233-236.
73. McSwain NE, Jr., Petrucelli E. Medical consequences of motorcycle helmet nonusage. *J Trauma* 1984;24:233-236.
74. Meisel S, Ram Z, Priel I, Nasse D, Lieberman P. Another complication of thoracostomy - perforation of the right atrium. *Chest* 1990; 98:772-773.
75. Millikan JS, Moore EE, Steiner E, Aragon GE, Van Way CW 3rd. Complications of tube thoracostomy for acute trauma. *Am J Surg* 1980;140:738-741.
76. Mohlala ML, Vankejr EA, Ballaram RS. Internal mammary artery hematoma. *S Afr J Surg.* 1989;27:136-138.
77. Moore EE, Malangoni MA, Cogbill TH, et al. Organ injury scaling IV: thoracic vascular, lung, cardiac, and diaphragm. *J Trauma* 1994;36:299-300.
78. Moylan JA, Detmer DE, Rose J, Schulz R. Evaluation of the quality of hospital care for major trauma. *J Trauma* 1976;16:517-523.
79. Moulin G, Bartoli JM, Fighiera M, et al. Extra-pleural hematoma [in French]. *J Radiol* 1992;73:327-330.

N

80. Nagy K, Fabian TC, Rodman G, et al. Guidelines for the diagnosis and management of blunt aortic injury: an EAST practice management guidelines work group. *J Trauma* 2000;48:1128-1143.
81. Nishiuchi S, Ogino H, Hashihira M, et al. Surgical management of ruptured descending thoracic aneurysm with massive extrapleural hematoma [in Japanese]. *Kyobu Geka - Jpn J Thorac Surg* 1985;38:812-814.

82. Norberg K-A, Andersson L, Björnstig U, et al. Trauma och asthma. Aktiv uppföljning. Socialstyrelsen, 1992.

O

83. Orsay EM, Turnbull TL, Dunne M, Barrett JA, Langenberg P, Orsay CP. Prospective study of the effect of safety belts on morbidity and health care costs in motor-vehicle accidents. *JAMA* 1988;260:3598-3603.

P

84. Paget S. *The surgery of the chest*. London: John Wright, 1896;121.
85. Parithivel VS, Shah S, Gerst PH. Extrapleural hematoma following infraclavicular subclavian vein catheterization [letter]. *NY State J Med* 1988;88:332-333.
86. Parker MS, Mathesen TL, Rao AV, et al. Making the transition: the role of helical CT in the evaluation of potentially acute thoracic aortic injuries. *AJR* 2001;176:1267-1272.
87. Parmely LF. Nonpenetrating traumatic injury of the aorta. *Circulation* 1958;17:1086-1101.
88. Parmley LF, Manion WC, Mattingly TW. Nonpenetrating traumatic injury of the heart. *Circulation* 1958;18:371-396.
89. Parodi JC, Palmaz JC, Barone HD. Transfemoral intraluminal graft implantation for abdominal aortic aneurysms. *Ann Vasc Surg* 1991;5:491-499.
90. Pendergrass RC, Allbritten FF. Pulmonary complications of dorsal sympathectomy. *Am J Roentgenol* 1947;57:205-212.
91. Pickard LR, Mattox KL. Thoracic trauma, general consideration and indications for thoracotomy. In: Moore EE, Mattox KL, Feliciano DV, eds. *Trauma*. 2nd ed. Norwalk, Connecticut: Appleton&Lange: 1991, pp 319-326.

R

92. Rashid MA. Value of video-assisted thoracic surgery in traumatic extrapleural hematoma. *Thorac Cardiovasc Surg* 1999;47:255-257.
93. Rashid MA. Contre-coup lung injury: evidence of existence. *J Trauma* 2000;48:530-532.
94. Rashid MA. Intracardiac chest tube placement: The author's reply. *J Trauma* 1999;46:529-530.
95. Rashid MA, Ackèr A. Cardiac herniation with catheterization of the heart, inferior vena cava, and hepatic vein by a chest tube. *J Trauma* 1998;45:407-409.
96. Rashid MA, Wikström T, Örténwall P. Nomenclature, classification, and significance of traumatic extrapleural hematoma. *J Trauma* 2000;49:286-290.
97. Rashid MA, Wikström T, Örténwall P. Pneumopericardium and pneumoperitoneum after penetrating chest injury. *Eur J Surg* 1999;165:278-279.
98. Rashid MA, Wikström T, Örténwall P. Mediastinal perforation and contralateral hemothorax by a chest tube. *Thorac Cardiovasc Surg* 1998;46:375-376.
99. Rashid MA, Wikström T, Örténwall P. A simple technique for anchoring chest tubes. *Eur Respir J* 1998;12:958-959.
100. Rashid MA, Wikström T, Örténwall P. Cardiac injuries: a ten-year experience. *Eur J Surg* 2000;166:18-21.
101. Rashid MA, Wikström T, Örténwall P. Outcome of lung trauma. *Eur J Surg* 2000;166:22-28.
102. Rashid MA, Örténwall P, Wikström T. Cardiovascular injuries associated with sternal fractures. *Eur J Surg* 2000;167:243-248.
103. Rashid MA, Wikström T, Örténwall P. Thoracic vascular injuries: a major problem in trauma. *Scand Cardiovasc J* 2001;35:285-287.
104. Rashid MA, Lund TL. Trauma to the heart and thoracic aorta: the Copenhagen experience. *Interact Cardiovasc Thorac Surg* 2003;2:53-57.

105. Rehn L. über penetriren der herzwunden und herznaht. Arch Klin Chir 1897;55:315-329.
106. Rehn L. Zur chirurgie des herzens und des herzbeutels. Arch Klin Chir 1907;83:723-778.
107. Reiter C, Denk W. Delayed epipleural hematoma as a fatal complication after blunt thoracic trauma [in German]. Wiener Klinische Wochenschrift 1985;97:535-537.
108. Reul GJ Jr, Mattox KL, Beall AC Jr, Jordan GL Jr. Recent advances in the operative management of massive chest trauma. Ann Thorac Surg 1973;16:52-66.
109. Rhee PM, Foy H, Kaufmann C, et al. Penetrating cardiac injuries: a population-based study. J Trauma 1998;45:366-370.
110. Richardson JD, Grover FL, Trinkle JK. Early operative management of isolated sternal fractures. J Trauma 1975;15:156-158.
111. Richardson JD, Wilson ME, Miller FB. The widened mediastinum: diagnostic and therapeutic priorities. Ann Thorac Surg 1990;211:731-737.
112. Robison PD, Harman PK, Trinkle JK, Grover FL. Management of penetrating lung injuries in civilian practice. J Thorac Cardiovasc Surg 1988;95:184-190.
113. Rogers LF, Hendrix RW. Evaluating the multiple injured patient radiographically. Orthop Clin North Am 1990;21:437-447.
114. Rosenberg JM, Bredenberg CE, Marvasti MA, et al. Blunt injuries to the aortic arch vessels. Ann Thorac Surg 1989;48:508-513.

S

115. Schechter LS, Held BT. Right-sided extrapleural hematoma: an unusual presentation of ruptured aortic aneurysm. Chest 1974;65:355-357.
116. Scheff S, Bendarz WW, Levene G. Roentgenologic aspects of retropleural hematomas following sympathectomy. Am J Roentgenol 1957;68:224-230.
117. Shackford SR, Mackersie RC, Holbrook TL, et al. The epidemiology of traumatic death: a population-based analysis. Arch Surg 1993;128:571-575.
118. Smedal MI, Lippincott SW. Extrapleural fluid complicating thoracic and thoracolumbar sympathectomy. Surg Clin North Am 1950;30:829-836.
119. Smith MD, Cassidy JM, Souther S, Morris EJ, Sapin PM, Johnson SB, Kearney PA. Transesophageal echocardiography in the diagnosis of traumatic rupture of the aorta. N Engl J Med 1995;332:346-362.
120. Socialstyrelsen. Strategier för ett olycksfritt Sverige. SoS-rapport 1991;18.
121. Sparkman RS, Nixon PI, eds. The Texas Surgical Society: The first fifty years. Dallas, TX, 1965:4-5.
122. Sugg WL, Rea WJ, Ecker RR, Webb WR, Rose EF, Shaw RR. Penetrating wounds of the heart: an analysis of 459 cases. J Thorac Cardiovasc Surg 1968;56:531-545.
123. Svennevig JL, Pillgram-Larsen J, Fjeld NB, Birkeland S, Semb G. Early use of corticosteroids in severe closed chest injuries: a 10-year experience. Injury 1987;18:309-312.

T

124. Tenzer ML. The spectrum of myocardial contusion: a review. J Trauma 1985;25:620-627.
125. Terry TR, Cook A. Blunt injury of the heart. Br Med J 1983;286:805.
126. Thompson DA, Rowlands BJ, Walker WE, Kuykendall RC, Miller PW, Fischer RP. Urgent thoracotomy for pulmonary or tracheobronchial injury. J Trauma 1988;28:276-280.
127. Toombs BD, Sandler CM, Lester RG. Computed tomography of chest trauma. Radiology 1981;140:733-738.
128. Trunkey DD. Trauma care systems. Emerg Med Clin North Am 1984;2:913-922.

129. Trunkey DD, Lewis FR. Chest trauma. *Surg Clin North Am* 1980;60:1541-1549.

U

130. Urschel JD. Intracardiac chest tube placement: Letters to the Editor. *J Trauma* 1999;46:529.
131. Urschel JD, Takita H, Antkowiak JG. Necrotizing soft tissue infections of the chest wall. *Ann Thorac Surg* 1997;64:276-279.

V

132. Veith FJ, Abbot WM, Yao JS. Endovascular Graft Committee: guidelines for development and use of transluminally placed endovascular prosthetic grafts in the arterial system. *J Vasc Surg* 1995;21:670-685.
133. Viano DC, Culver CC, Evans L, Frick M, Scott R. Involvement of older drivers in multivehicle side-impact crashes. *Accid Anal Prev* 1990;22:177-188.
134. Viano DC, Lau IV, Asbury C, King AI, Begeman P. Biomechanics of the human chest, abdomen, and pelvis in lateral impact. *Accid Anal Prev* 1998;21:553-574.
135. Viano DC, Bir CA, Cheney AK, Janda DH. Prevention of commotion cordis: an evaluation of chest protectors. *J Trauma* 2000;49:1023-1028.
136. Von Oppell UO, Dunne TT, De Groot MK, Zilla P. Traumatic aortic rupture: twenty-year metaanalysis of mortality and risk of paraplegia. *Ann Thorac Surg* 1994;58:585-593.

W

137. Wasylenko MJ, Busse EF. Posterior dislocation of the clavicle causing fatal tracheoesophageal fistula. *Can J Surg* 1981;24:626-627.
138. Wall MJ Jr, Hirshberg A, Mattox KL. Pulmonary tractotomy with selective vascular ligation for penetrating injuries to the lung. *Am J Surg* 1994;168:665-669.
139. Waters JM Jr, Wells CH. The effects of a modern emergency medical care system in reducing automobile crash deaths. *J Trauma* 1973;13:645-647.
140. West JG, Trunkey DD, Lim RC. Systems of trauma care. A study of two counties. *Arch Surg* 1979;114:455-460.
141. Westaby S. Resuscitation in thoracic trauma. *Br J Surg* 1994;81:929-931.
142. Westaby S, Brayley N. ABC of major trauma: thoracic trauma-I. *BMJ* 1990;300:1639-1643.
143. Westaby S, Brayley N. ABC of major trauma: thoracic trauma-II. *BMJ* 1990;300:1710-1712.
144. Westaby S. Transfixion injuries. In: Westaby S, Odell JA, eds. *Cardiothoracic trauma*. 1st ed. London, UK, Arnold: 1999, pp 196-201.
145. Williams DM, Kirsh MM, Abrams GD. Penetrating atherosclerotic aortic ulcer with dissecting hematoma: control of bleeding with percutaneous embolization. *Radiology* 1991;181:85-88.
146. Wilson RF, Murray C, Antonenko DR. Nonpenetrating thoracic injuries. *Surg Clin North Am* 1977;57:17-36.

ORIGINAL PAPERS

I-V

I

Nomenclature, Classification, and Significance of Traumatic Extrapleural Hematoma

Moheb A. Rashid, MD, FACA, Thore Wikström, MD, PhD, and Per Örténwall, MD, PhD

Background: Extrapleural hematoma has been found mostly in single case reports as diagnoses with different names. Although huge extrapleural hematoma can cause ventilatory and circulatory disturbances and even death, it has received almost no attention in the literature. Certain basic and modern facts need to be clarified regarding the definition, classification, and significance of extrapleural hematoma in the practice of chest trauma.

Methods: A 10-year retrospective study was undertaken to analyze the incidence, diagnosis, management, morbidity, and mortality of patients with chest

trauma and a documented extrapleural hematoma.

Results: The incidence of traumatic extrapleural hematoma was 34 of 477, 7.1%. The incidence of thoracic lesions was 86 of 34 = 2.5 lesions per patient, whereas the incidence of extrathoracic lesions was 30 of 34 = 0.9 lesions per patient. Associated rib fractures were found in 30 of 34, 88.2%. More than half of the patients had an associated hemothorax. A thoracotomy was used successfully to remove a huge hematoma in one patient.

Conclusion: Extrapleural hematoma

has been found to be more common than previously reported. Nomenclature and classification are suggested. One of the common injuries to the chest, particularly rib fracture, hemothorax, lung contusion, or pneumothorax might provide the surgeon with a reliable clinical clue that the patient is at inordinate risk to have associated extrapleural hematoma. A formal or mini-thoracotomy is the recommended procedure in cases of huge hematomas.

Key Words: Extrapleural hematoma, Subpleural/retropleural/epipleural bleeding, Chest trauma, Nomenclature, Management, Morbidity, Mortality

J Trauma. 2000;49:286–290.

As our experience with chest injuries increases, we have become aware of other complications that can lead to significant morbidity and mortality. One such complication is pleural disorder. Pleural abnormalities after chest trauma are the most frequent complications. When there is blood in the intrapleural space, the term hemothorax is used, whereas there is no appropriate scientific term nor nomenclature for bleeding in other abnormal spaces in the chest wall. Extrapleural hematoma (EH) can be defined as blood collection in the extrapleural space. A search of the world literature^{1–29} has failed to identify a common definition, classification, or significance of traumatic EH. Therefore, we conducted this retrospective study of 34 patients who had sustained chest trauma and experienced radiologic signs of EH during the last 10-year period. We have thoroughly studied the world literature as well as our own cases and derived a nomenclature. We suggest a simple classification and present the pathophysiology, diagnosis, differential diagnosis, management, and significance of EH in the clinical treatment of thoracic trauma.

PATIENTS AND METHODS

We analyzed 34 patients, including 22 men and 12 women, ranging from 29 to 87 years with an average age of 58.9 years, between January 1988 to December 1997. We examined patient age, gender, mechanism of injury, comorbidity, clinical diagnosis, radiologic diagnosis, associated injuries, complications, treatment, length of hospital stay in the intensive care unit and the ward, and follow-up. All patients sustained thoracic trauma and had radiologic signs of EH. We report only cases of traumatic EH that were extracted from the files as incidental findings and never mentioned as main or associated diagnoses.

Chest radiograph was the standard method for the diagnosis in all cases. The presumptive diagnosis of EH was made on the basis of the pleural reflection at the lower margin of the lesion (Fig. 1). The EH has a D-shaped outline with its base located against the corresponding part of the chest wall (Fig. 1). A lateral projection is the best to detect EH on the anterior or posterior wall, whereas a frontal projection can demonstrate a lateral EH, which can be shown simply as focal thickening that does not shift with gravity.

RESULTS

The cause of injury was motor vehicle crash (15 of 34, 44.1%), falls (13 of 34, 38.2%), assault (2 of 34, 5.9%), miscellaneous (3 of 34, 8.8%), and knife stab (1 of 34, 2.9%). The trauma was blunt in 33 cases and penetrating in 1 case. The incidence of EH was 34 of 477, 7.1% among consecutive patients admitted with chest trauma during the last 10-year period. We found that the incidence of thoracic lesions was 86 of 34 = 2.5 lesions per patient, whereas the incidence of

Submitted for publication June 21, 1999.

Accepted for publication April 18, 2000.

Copyright © 2000 by Lippincott Williams & Wilkins, Inc.

From the Division of Vascular and Trauma Surgery, Department of Surgery, Sahlgrenska University Hospital/Östra, Gothenburg University, Gothenburg, Sweden.

Address for reprints: Moheb A. Rashid, MD, Trebackegatan 11, 416 74 Gothenburg, Sweden; Fax: +46(46)173765.

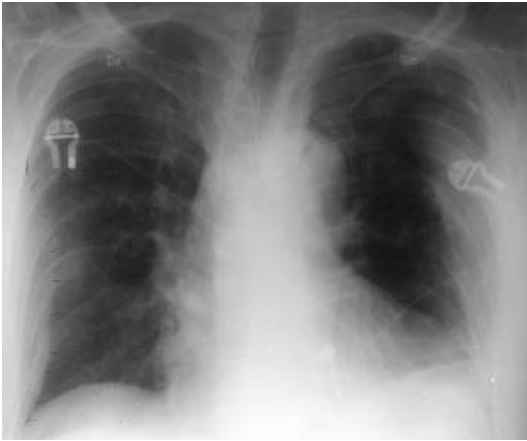


Fig. 1. Chest radiograph showing lower right extrapleural hematoma that has a D-shaped outline with its base located against the corresponding part of the chest wall. The pleural reflection at the lower margin of the lesion is seen, and the costophrenic angle is not obliterated.

extrathoracic lesions was 30 of 34 = 0.9 lesions per patient. The most common associated injuries were rib fractures, hemothorax, lung contusions, pneumothorax, and chest wall contusions. Associated rib fractures were found in 30 of 34 (88.2%). More than half of the patients had an associated hemothorax. The most common associated extrathoracic injuries were cerebral concussion, clavicular and other skeletal fractures.

The initial diagnosis was chest trauma in all patients, and the radiologic diagnosis of EH was established in the first 24 to 48 hours after admission in 30 patients, but delayed 5 days in 1 patient and 10 days in 3 patients. Of these four patients, there were only two patients with associated hemothorax; this frequency seems similar to that for the total number of patients with EH and associated hemothorax (more than 50%). Furthermore, most cases were observed only (no other treatment was given), and we found that no patient developed a delayed hemothorax. Therefore, we do not suspect that a delayed diagnosis of EH might reflect intrapleural collection. There was no side dominance; 15 patients were diagnosed with EH in the right side, 17 with EH in the left side, 1 with bilateral EH, and 1 with retrosternal EH. EH decreased or disappeared within 3 to 6 weeks when small in size with a resulting pleural thickening.

Conservative treatment with observation and chest radiograph control was provided in 33 patients, and 1 patient needed a thoracotomy to evacuate the hematoma after unsuccessful needle aspiration. No thoracoscopy had been tried in this series. The associated lesions required an urgent thoracotomy for severe hemothorax in one patient chest tubes in seven, laparotomy in three, tracheostomy in two, surgical fixation of fractures in two, and a fasciotomy of the carpal

tunnel in one. The average length of hospital stay in the ward was 6.2 days per patient and in the intensive care unit was 2.1 days per patient. Follow-up of these patients showed that the most common complication was pain in six patients, chest-tube complications in three, and sternal hematomas in two. One patient died a few hours after admission because of cerebral bleeding and lung injury. However, no one died in this series as a direct result of EH.

DISCUSSION

Nomenclature

We found only two cases in the world literature published with the term "subpleural."^{22,27} Thirty-one cases in the present study were diagnosed as "subpleural" in the files. Two cases were called "extrapleural," and one case was named both "extrapleural" and "subpleural" by two different radiologists. According to a standard medical dictionary,³⁰ the word "subpleural" is defined as located beneath the pleura, "extrapleural" is described as outside the pleural cavity, and "epipleural" is described as located on a pleural element, or pleurapophysis. EH has been called "extrapleural fluid collection, hemothorax and bleeding" in the same report of three patients followed up after sympathectomy.¹ Pendergrass and Allbritten,¹ considered EH the most serious complication of dorsal sympathectomy. EH after sympathectomy was called "extrapleural fluid" by Smedal and Lippincott in 1950² and "retropleural hematoma" by Scheff et al.³ in 1957. EH was called "epipleural" in the German literature.^{12,13,16} The neurosurgical terms "epidural" and "subdural" are well established in the neurosurgical practice because of the significance and difference in treatment of both entities. These terms are almost unknown in our practice of cardiothoracic and trauma surgery, probably because of the unrecognized significance of epipleural or subpleural bleeding. When we analyzed our cases as well as those published by others, we found that the word "subpleural" is probably a misnomer for the extrapleural term. Retropleural is not informative enough because the pleura turns itself, and what is called retropleural posteriorly could be intrapleural anteriorly. The visceral pleura is firmly adherent and the incidence of bleeding that could separate the visceral pleura from lung parenchyma is unlikely. Therefore, the term subpleural is invalid and the word extrapleural is suggested to be much more appropriate than the above mentioned names.

Classification

We suggest the following simple etiologic classification of EH; namely, spontaneous, iatrogenic, and traumatic. Iatrogenic EH (IEH) was first described in earlier reports by Pendergrass and Allbritten,¹ spontaneous EH (SEH) was first reported by Schechter and Held in 1974,⁵ and traumatic EH (TEH) was first reported by Lipchik and Robinson in 1968.⁴

Pathophysiology

The pathophysiology of TEH can be explained as follows. Blunt thoracic injury begins with fractures of the sternum and/or ribs, causing tears or ruptures of blood vessels of the chest wall with blood collection, or traumatic transection of these vessels by intercostal sharp objects such as knife or missiles. This blood cannot escape into the pleural space as in the case of hemothorax, particularly if the parietal pleura remains intact. Probably, patients with thickening of the parietal pleura might be at greater risk for EH. The thickness of parietal pleura might prevent its rupture, which occurs in the majority of cases, producing EH instead of hemothorax. The origin of blood is usually intercostal or internal mammary vessels. Minor injuries to mediastinal vessels, traumatic aortic rupture or any arch vessels, and fracture of vertebrae or ribs are other causes of EH. Penetrating injuries also produce typical EH, when the parietal pleura is not breached, the laceration in the parietal pleura is small, or the underlying lung is adherent to the chest wall. This mechanism probably explains the formation of EH in the case of knife stab in this series.

Diagnosis

The diagnosis of EH is interesting. A history of surgery, particularly that of open sympathectomy¹⁻³ and lung transplantation,²⁷ is frequently the cause of IEH. Slight chest pain and fever were common in the literature.² Many of the patients with clinical evidence of EH were asymptomatic,³ and this is consistent with our study. The presence of multiple risk factors such as old age with tortuous vessels, skeletal deformity such as scoliosis, other comorbidity such as neurofibromatosis, or coagulopathy can lead to SEH. Understanding the pleural anatomy is important in interpreting EH using plain chest radiograph or computed tomography of the chest. Chest radiograph is not entirely pathognomonic of EH, but it demonstrates a parietal shadow, which may be linear or rounded. In cases of frank or clotted hemothorax, the costophrenic angle is usually obliterated (unless there is pleural symphysis), but this is not the case in EH (Fig. 1). A pleural thickening that does not shift with gravity could be a clotted hemothorax, but one should look at the costophrenic angle when an EH is suspected. When the diagnosis is still difficult, a computed tomographic (CT) scan of the chest is recommended, and one may observe the recently described "displaced extrapleural fat layer and parietal pleura" sign²⁹ that is pathognomonic of EH. We recognized all our cases of EH using just chest radiographs, which is a rapid, noninvasive, and inexpensive diagnostic method for detecting EH and can be used by thoracic and trauma surgeons in the emergency room. This is consistent with earlier reports.⁸ EH disappeared in 2 weeks, and the chest appeared clear after 1 month.² This is consistent with the findings in our patients. CT scan of the chest is quite sensitive in detecting pleural abnormalities.⁹ CT scan has been shown to be the procedure of choice in the

initial evaluation of aortic aneurysms and dissections because of its superior depiction of processes occurring in or around the aortic wall, including the pleural spaces and mediastinum.³¹ A Swedish report²⁹ has shown that medially displaced extrapleural fat as revealed by CT scans is useful in detecting the traumatic EH and distinguishing it from pleural fluid. We completed a CT scan of the chest in two cases, but the scan gave no additional significant information compared with that obtained by chest radiograph. Angiography can be used in diagnosis of obscure cases with widened mediastinum after trauma and with a suspected rupture of the heart/great vessels. We completed an angiogram of the aortic arch in three cases with suspected widened mediastinum, but this examination showed no abnormalities.

Differential Diagnosis

EH might be confused with encysted intrapleural effusion, a large pleural tumor (mesothelioma, secondaries, benign tumor, or pleural sarcoma), or peripheral lung tumor, particularly when the chest radiograph shows rounded shadows. EH may simulate a diaphragmatic hernia if located posteriorly. However, most of EH will leave no roentgenologic evidence after 4 months, but the hematoma can assume a reticulated appearance, probably because of fibrosis or thickening of the overlying pleura that persists for 2 years or more.³ Therefore, EH can be mistaken as pneumonia or a tumor. Oleothorax, which is an extrapleural-based mass, was treated by surgical insertion of plomb composed of paraffin.³² This extrapleural plumbage, used in the treatment of tuberculosis, should be differentiated from EH. Extrapleural tumor could be even more confusing to diagnose if it is discovered after trauma.³³

Treatment

Treatment of TEH consists of merely evacuating the hematoma if it is large, securing the source of bleeding if found, and only observing the hematoma if it is small. Of 40 iatrogenic cases, only 4 (10%) were drained.³ Needle aspiration should be performed early.¹ Aspiration and closed-tube thoracostomy drainage might prove unsatisfactory when the hematoma is clotted. In such cases with a large hematoma, an open thoracotomy should be undertaken, because huge EH can cause ventilatory and circulatory disturbances. This was found in one case in this series. Therefore, the recognition and the proper treatment of such a rare entity is important. The EH might expand, as in case of old age with tissue laxity, even without coagulopathy, and may necessitate blood transfusion²⁹ where an active intercostal or muscular arterial bleeder is usually found. Because treatment of EH in the stable patient should be a limited or formal thoracotomy, the management of expanding EH in older patients with anticoagulants should be the same, but probably on an acute basis. Despite thoracotomy, a huge EH might present certain difficulties for the surgeon, who might perform surgery in a wrong space or fail to identify the bleeder. Such a bleeder,

however, could be identified using thoracic artery angiogram with embolization as an option of treatment, but it carries a risk of embolization to the anterior spinal artery with possible resultant paraplegia. Several recent reports have shown that video-assisted thoracic surgery (VATS) is an accurate, safe, and minimally invasive method for the control of traumatic chest wall bleeding and early evacuation of clotted hemothorax.³⁴⁻³⁷ In our current report, VATS was not used in any patient with TEH. Although VATS has been considered the preferred approach for the management of pleural disease,³⁸ it has been shown to be a relatively major contraindication for patients with TEH.²⁹ It is important to save time and money and to treat patients with TEH in the most cost-effective manner, specifically by performing thoracotomy if a chest tube fails to drain it.

Morbidity and Mortality

The most common associated thoracic injuries were rib fractures, hemothorax, lung contusions, pneumothorax, and chest wall contusions, whereas the most common associated extrathoracic injuries were cerebral concussion and clavicular and other skeletal fractures. The associated early mortality was 2.9%, but no one died in this series as a direct result of EH. Although huge extrapleural hematoma might cause ventilatory and circulatory disturbances and even death,¹³ it has received almost no attention in the literature.

Significance

EH is fairly common but usually goes unrecognized. Common injuries to the chest, particularly rib fractures, hemothorax, lung contusion, and pneumothorax might provide the surgeon with a reliable clinical clue that the patient is at inordinate risk for associated EH. It may produce some local discomfort and a transient rise in temperature but has less dramatic appearance if it is small in size. A larger EH, implying greater blood loss, can produce dyspnea or become infected. Death has been reported.¹³ EH is important chiefly because it might be confused with the more serious diagnosis of intrathoracic lesions such as neurofibroma if it is found in the cervicodorsal area or confused with pleural, mediastinal, or pulmonary lesion when situated in other zones. The reticular pattern of an incompletely absorbed EH might offer diagnostic abnormalities months after its occurrence.

ACKNOWLEDGMENT

We thank Dr. Bo Palmertz, consultant radiologist at the Department of Radiology, Sahlgrenska University Hospital/Östra, for his second opinion on the chest x-ray films.

REFERENCES

1. Pendergrass RC, Allbritten FF. Pulmonary complications of dorsal sympathectomy. *AJR Am J Roentgenol.* 1947;57:205-212.
2. Smedal MI, Lippincott SW. Extrapleural fluid complicating thoracic and thoracolumbar sympathectomy. *Surg Clin North Am.* 1950; 30:829-836.
3. Scheff S, Bendarz WW, Levene G. Roentgenologic aspects of retropleural hematomas following sympathectomy. *AJR Am J Roentgenol.* 1957;68:224-230.
4. Lipchik EO, Robinson KE. Acute traumatic rupture of the thoracic aorta. *Am J Roentgenol Radium Ther Nucl Med.* 1968;107:408-412.
5. Schechter LS, Held BT. Right-sided extrapleural hematoma: An unusual presentation of ruptured aortic aneurysm. *Chest.* 1974; 65:355-357.
6. Butchart EG, Gršte GJ, Barnsley WC. Spontaneous rupture of an intercostal artery in a patient with neurofibromatosis and scoliosis. *J Thorac Cardiovasc Surg.* 1975;69:919-921.
7. McEnany MT, Austen WG. Life-threatening hemorrhage from inadvertent cervical arteriotomy. *Ann Thorac Surg.* 1977;24:233-236.
8. Bluhm R, Gross N. Extrapleural hemorrhage. *Clin Notes Respir Dis.* 1980;19:11-12.
9. Toombs BD, Sandler CM, Lester RG. Computed tomography of chest trauma. *Radiology.* 1981;140:733-738.
10. Wasylenko MJ, Busse EF. Posterior dislocation of the clavicle causing fatal tracheoesophageal fistula. *Can J Surg.* 1981;24:626-627.
11. Brandi LS, Mosca F, Carmellini, et al. An unusual complication of percutaneous catheterization of the internal jugular vein. *Acta Anaesthesiol Belg.* 1984;35:231-236.
12. Dirnhöfer R, Sigrist Th, Ranner G. Epipleural hematoma: etiology, morphology and clinical course [in German]. *Unfallheilkunde.* 1984; 87:180-183.
13. Reiter Ch, Denk W. Delayed epipleural haematoma as a fatal complication after blunt thoracic trauma [in German]. *Wien Klin Wochenschr.* 1985;97:535-537.
14. Nishiuchi S, Ogino H, Hashihira M, et al. Surgical management of ruptured descending thoracic aneurysm with massive extrapleural hematoma [in Japanese]. *Kyobu Geka.* 1985;38:812-814.
15. Kucich VA, Vogelzang RL, Hartz RS, et al. Ruptured thoracic aneurysm: unusual manifestation and early diagnosis using CT. *Radiology.* 1986;160:87-89.
16. Ranner G, Dirnhöfer R, Sigrist Th, Kullnig P. Unusual clinical forms of extrapleural (epipleural) hematoma on the chest x-ray [in German]. *Radiologe.* 1986;26:467-470.
17. Kay J, Goodman LR, Gurney J. Extrapleural hematoma: a recognizable complication of central venous pressure monitoring. *J Clin Monit.* 1987;3:64-66.
18. Parithivel VS, Shah S, Gerst PH. Extrapleural hematoma following infraclavicular subclavian vein catheterization [letter]. *NY State J Med.* 1988;88:332-333.
19. Manenti A, Buttazzi A, Speranza M, Barbieri A. Left extrapleural hemothorax from rupture of the subclavian artery. *Resuscitation.* 1989;18:163-164.
20. Mohlala ML, Vankejr EA, Ballaram RS. Internal mammary artery hematoma. *S Afr J Surg.* 1989;27:136-138.
21. Rosenberg JM, Bredenberg CE, Marvasti MA, et al. Blunt injuries to the aortic arch vessels. *Ann Thorac Surg.* 1989;48:508-513.
22. Williams DM, Kirsh MM, Abrams GD. Penetrating atherosclerotic aortic ulcer with dissecting hematoma: control of bleeding with percutaneous embolization. *Radiology.* 1991;181:85-88.
23. Aron C, Jounieux V, Nikels JC, Toris T. Extrapleural hematoma: emergency diagnostic pitfall. Value of computerized x-ray tomography [in French]. *Rev Pneumol Clin.* 1992;48:169-171.
24. Massard G, Roeslin N, Wihlm JM, Morand G. Extrapleural hematoma as a late complication of collapse therapy for tuberculosis [letter]. *Chest.* 1992;101:1476-1477.
25. Moulin G, Bartoli JM, Fighiera M, et al. Extra-pleural hematoma [in French]. *J Radiol.* 1992;73:327-330.
26. Komoda K, Hujii Y, Nakajima T, et al. A ruptured thymic branch aneurysm mimicking a ruptured aortic aneurysm, with associated bronchial artery aneurysms: report of a case. *Surg Today.* 1994;

- 24:258–262.
27. Herridge MS, de Hoyos AL, Chaparro C, et al. Pleural complications in lung transplant recipients. *J Thorac Cardiovasc Surg.* 1995; 110:22–26.
28. Aquino SL, Chiles C, Oaks T. Displaced extrapleural fat as revealed by CT scanning: evidence of extrapleural hematoma. *AJR Am J Roentgenol.* 1997;169:687–689.
29. Rashid MA. Value of video-assisted thoracic surgery in traumatic extrapleural hematoma. *Thorac Cardiovasc Surg.* 1999;47:255–257.
30. Dorland WAN. *Dorland's Illustrated, Medical Dictionary*, 27th ed. Philadelphia: W.B. Saunders; 1988;569, 599, 1309.
31. Gowdin JD. Examination of the thoracic aorta by computed tomography. *Chest.* 1984;85:564–567.
32. Irwin RS, Weg JG: ACCP-seek board review question of the month: a woman with productive cough, dyspnea, and a past history of surgery for tuberculosis. *Chest.* 1997;112:1115–1116.
33. Iichashi T, Ietsugu K, Seki M, Kobayashi H, Kouno N, Terada T. Primary hemangiopericytoma of the chest wall: a case report [in Japanese]. *Kyobu Geka.* 1995;48:422–425.
34. Graeber GM, Jones D. The role of thoracoscopy in thoracic trauma. *Ann Thorac Surg.* 1993;56:646–648.
35. Heniford BT, Carrillo EH, Spain DA, Sosa JL, Fulton RL, Richardson JD. The role of thoracoscopy in the management of retained thoracic collections after trauma. *Ann Thorac Surg.* 1997; 63:940–943.
36. Sosa JL, Pombo H, Puente I, et al. Thoracoscopy in the evaluation and management of thoracic trauma. *Int Surg.* 1998;83:187–189.
37. Villavicencio RT, Aucar JA, Wall MJ Jr. Analysis of thoracoscopy in trauma. *Surg Endosc.* 1999;13:3–9.
38. Mack MJ, Scruggs GR, Kelly KM, Shennib H, Landreneau RJ. Video-assisted thoracic surgery: has technology found its place? *Ann Thorac Surg.* 1997; 64:211–215.

III

Cardiovascular Injuries associated with Sternal Fractures

Moheb A. Rashid, Per Örténwall and Thore Wikström

From the Division of Vascular and Trauma Surgery, Department of Surgery, Sahlgrenska University Hospital/Östra, Gothenburg University, Gothenburg, Sweden

Eur J Surg 2001; 167: 243–248

ABSTRACT

Objective: To find out if the presence of a sternal fracture indicates cardiac and aortic injuries and to clarify the difference between a retrosternal haematoma and widened mediastinum.

Design: Retrospective study.

Setting: Teaching hospital, Sweden.

Subjects: 418 patients with blunt chest trauma of whom 29 had a fractured sternum (11 with retrosternal haematoma and 18 without) and 389 did not (7 with widened mediastinum and 382 without).

Main outcome measures: Definitions, risk factors, morbidity, and mortality.

Results: Retrosternal haematomas were found adjacent to many fractures and ranged in size from a few mm to 2 cm. They were more common in fractures of the body of sternum. There was no significant difference in the number of associated lesions between patients with sternal fractures with or without a retrosternal haematoma. Conversely, patients with a widened mediastinum had a higher injury severity score, longer hospital stay ($p < 0.0001$), and more associated lesions ($p < 0.05$) than those with retrosternal haematomas. Six patients still had pain 1 month after injury of whom two had injury-related long-term disability because of pain. No serious cardiac or aortic injuries were detected in this series. The early mortality in our study was 2/29 in patients with sternal fractures and 1/7 in patients with widened mediastinum.

Conclusions: Sternal fractures are more common than previously reported. An aggressive approach including early operative reduction is recommended even for a stable fracture to reduce the overwhelming pain. Sternal fracture with or without retrosternal haematoma is not a reliable indicator of cardiac and aortic injuries, while mediastinal widening is still a fairly reliable clue that should indicate further investigation.

Key words: sternal fractures, retrosternal hematoma, mediastinal widening, diagnosis, management, morbidity and mortality, cardiac and aortic injuries.

INTRODUCTION

Most chest injuries involve soft tissue, the bone cage, and the underlying pleura and lung, and chest wall injuries make up a half to two thirds of all thoracic injuries that require admission to hospital. Sternal fractures result from direct impact to the anterior wall of the chest, particularly in motor vehicle accidents. The sternum usually fractures transversely, at the body or manubrium, and such fractures may vary in severity from a simple undisplaced fracture to comminuted fractures with overlapping fragments (11). The surgeon should suspect and assess any underlying injuries to the heart, bronchus, and great vessels. Reports about sternal fractures are almost always contradictory (3, 5, 7, 9, 12, 15). However, sternal fractures are usually benign injuries (4). Because most of them are associated with the steering wheel type of injury the mortality rate may be high because of the severity of associated cardiovascular injuries. We therefore conducted this retrospective study to look at the incidence, approach, management, morbidity, and mortality associated with sternal fractures in all patients admitted to

our emergency department with a fractured sternum during the past 10 year period. One of our main aims was to find out if the presence of a sternal fracture indicates cardiac and aortic injuries and to clarify the difference between a retrosternal haematoma and widened mediastinum.

PATIENTS AND METHODS

The records of all patients who sustained blunt chest injuries with sternal fractures between January 1988 and December 1997 were analysed. The age, sex, mechanism of injury, comorbidity, clinical diagnosis, radiological diagnosis, associated injuries, complications, treatment, length of hospital stay, and follow-up were recorded. There were 418 patients with blunt chest trauma of whom 29 patients (range 30–92 years, mean age 64, 17 women and 12 men) had a fractured sternum (11 with retrosternal haematoma and 18 without) and 389 did not (7 with widened mediastinum and 382 without).

Statistical analysis: The Wilcoxon signed rank test was used to identify the differences between groups.

Table I. Sites of sternal fractures

Site	Sternal fracture (n = 29)	Associated retro- sternal haematoma (n = 11)
Mid-body	9	3
Upper body	7	2
Manubrium	6	3
Lower body	3	1
Multiple parts	2	1
Manubriosternal	1	1
Adjacent to xiphoid	1	0

Probabilities of less than 0.05 were considered significant.

RESULTS

The main causes of injury in patients with sternal fractures were motor vehicle crash (19/29, 66%), falls (9/29, 31%), and assault (1/29, 3%). Two patients had coexisting cardiac diseases, but neither of them had cardiac problems from the sternal fractures. Electrocardiographic monitoring with estimation of cardiac enzyme activities were done in nine cases. No serious cardiac lesion was detected. No patients were recorded as having aortic injuries. The incidence of suspected aortic injury and aortography was 7/29, (3 angiograms and 4 computed tomograms (CT)). One aneurysm of the descending thoracic aorta was discovered on aortogram in one patient who had a prosthetic graft

inserted successfully. This aneurysm was arteriosclerotic and not traumatic. The incidence of suspected aortic injury in patients with widened mediastinum was 7/7 (6 angiogram and 1 CT) of whom one had a thoracoabdominal aortic aneurysm. This patient bled to death of his aneurysm on the third postoperative day.

Three patients initially had echocardiograms and one a transoesophageal echocardiogram and all were inconclusive. A grossly displaced sternal fracture was surgically fixed in one patient. Two patients had displacement by one anteroposterior thickness, four cases were displaced by half an anteroposterior thickness, and 22 cases had stable fractures. Three patients were operated on for associated lesions: two had laparotomies, one for intestinal perforation and other for a ruptured urinary bladder, and the third was operated on for multiple skeletal fractures. However, it is impossible to report with certainty that no other patients in the group without sternal fractures did not later have evidence of a traumatic aortic aneurysm, even if the follow-up was unremarkable. The retrosternal haematomas were found adjacent to many of fractures and ranged from a few mm to 2 cm in size; they were more common in fractures of the body of sternum (Table I & II and Fig. 1 & 2).

There was no significant difference in the incidence of associated lesions between patients with sternal fractures with or without a retrosternal haematoma. Conversely, patients with widened mediastinum had higher injury severity scores, longer stay in hospital and more associated thoracic lesions and extrathoracic

Table II. Differences between retrosternal haematoma and widened mediastinum

	Retrosternal haematoma	Widened mediastinum
Site	Adjacent to sternal fractures	Diffuse
Size	Few mm to 2 cm	Larger
Mechanism	May be trivial trauma	Serious trauma
Sternal fracture	Usually present	Not usually present
Part of sternum	Body or manubrium	No-specific
Further investigation	Observation and CT if in doubt	CT or angiography, or both

Table III. Differences between patients with sternal fractures and retrosternal haematomas and those with a widened mediastinum alone

	Sternal fracture and retrosternal haematoma (n = 11)	Widened mediastinum alone (n = 18)	p Value
Associated thoracic lesions	1.3	2.4	<0.05
Associated extrathoracic lesions	0.7	2.1	<0.005
Injury severity score	10.5	17.3	<0.0001
Duration of hospital stay (days)	7.5	16	<0.0001
Cardiac injury	0	0	
Aortic injury	0	1	

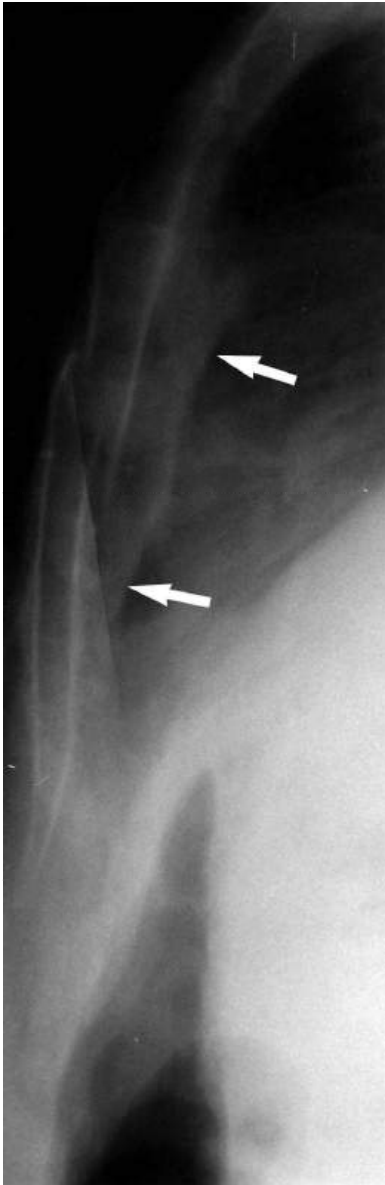

Fig. 1. Lateral sternal radiograph showing a transverse overlapping fracture in the body in which the upper segment lies behind the lower fragment. The retrosternal haematoma is shown (arrowheads). Angiogram of the aortic arch in this patient was normal.

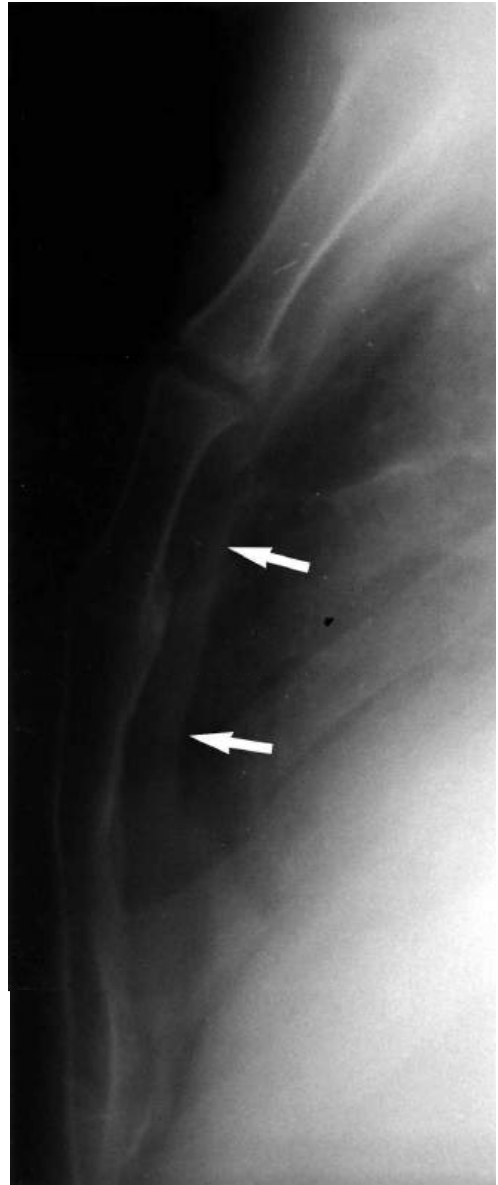

Fig. 2. A lateral sternal radiograph showing a wide separation at the synchondrosis. The retrosternal bleeding is shown (arrowheads). Angiogram of the aortic arch in this patient was within normal limits.

lesions than those with retrosternal haematomas (Table III). No serious cardiac or aortic injuries were detected. Only four patients had isolated sternal fractures, and

they were admitted because of pain and old age. Six patients still had pain 1 month after injury of whom two had injury-related long-term disability because of pain.

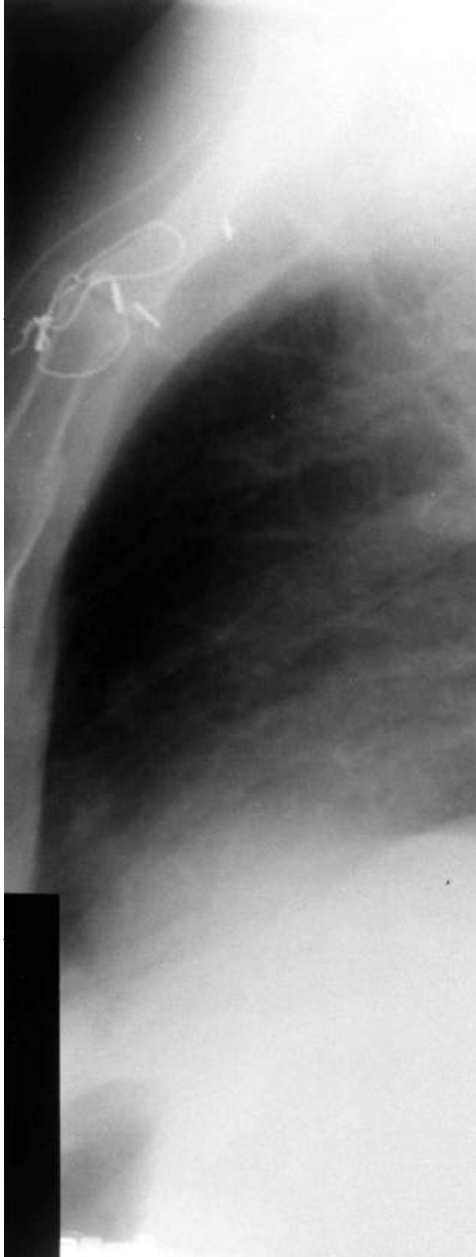

Fig. 3. A lateral sternal radiograph of the same patient as shown in in Fig. 2 after fixation by wiring.

The early mortality in our study was 2/29 in patients with sternal fractures (one patient died on the 13th day after injury of multiple organ failure, and one patient

died on the tenth day after injury of an unknown cause); and 1/7 in patients with a widened mediastinum who died of aneurysmal bleeding on the third postoperative day.

DISCUSSION

Incidence and definitions: The incidence of sternal fracture in a previous study was 3.7% (10). It is 29/418 (7%) in this updated series. Most fractures of the sternum involved the body, a fact noted in previous studies (3, 15). It is worth emphasising that retrosternal haematomas were more common in fractures of the mid-body and manubrium of the sternum (Table I). These haematomas caused by the fracture itself should be differentiated from retrosternal bleeding with appreciable mediastinal widening as a result of injury to major vessels or the heart (Table II). The presence of such widening is an indication for urgent aortography to rule out the possibility of concurrent major vascular injury (2).

The diagnosis in all cases was based on a history of trauma to the sternum in patients wearing seat belts, with pain and local tenderness. Lateral sternal radiograph confirmed the diagnosis. Clinically, most sternal fractures occur in the body (Fig. 1) or manubrium and the synchondrosis between these may be separated (Fig. 2). These structures are usually transverse and if displaced the upper segment lies behind the lower fragment (Fig. 1). Impacted fractures may pass unnoticed if there are other grave injuries. Such fractures can even be missed radiologically if a lateral film is not taken. This happened in two patients in this study. One patient was diagnosed 6 days after admission and the fracture was not seen in the initial radiograph and was even missed on the CT of the chest. Sonography has been used in other series (8).

Treatment of undisplaced fractures consists of pain relief. In the past, immersion in cold water was recommended to reduce the fracture by sudden inspiratory movements, but this is of historical interest only (12). If in patients with isolated sternal fractures, no abnormality was found on ECG examination or anteroposterior chest radiograph, together with lateral sternal radiograph and in the absence of other injuries, hospital admission is not indicated. Surgical reduction and fixation is reserved for severe deformity, as in one case in this study. Because the posterior periosteum is usually intact, this type of injury is stable with good union. Impacted and mildly displaced sternal fractures will usually heal satisfactorily without any deformity. In this series one patient developed a big organised haematoma over the fracture. The residual symptom during early follow-up of these patients was usually pain, which was exaggerated by chest movement.

However, there are some treatments for sternal fractures: analgesics were taken by all patients and should be tried first. Local injection of anaesthetics may be convenient and rewarding but we did not do this.

Operative reduction and fixation can be done by wiring the proximal and distal fragments together with 2 or 3 heavy wire sutures (Fig. 3). This can be done as soon as the patient is stable and other injuries have been ruled out. We treated only one patient by operative reduction, who had an uneventful course. Like others (11), we advocate early surgical repair when indicated, even when the fracture is isolated, so as to prevent painful pseudoarthrosis.

Morbidity and mortality: Although sternal fractures themselves are usually benign if not excessively displaced, they are associated with appreciable morbidity and mortality, particularly in old age. The incidence of sternal fractures and the associated mortality seems to increase with age. The most common associated injuries were rib fractures, as in a previous report (11). However, we found no cardiac or vascular complications. Twenty-five patients had associated injuries and four had isolated sternal fractures. Sternal fracture has been reported to be associated with cardiac injury (13), but this was not seen in our study or others (6). This could be explained by the fact that clinical and laboratory findings of cardiac contusion are sometimes indistinguishable from those found in multiple injuries (which were found in most patients in this report). The absence of cardiac contusion was probably overshadowed by the obvious associated skeletal, abdominal, thoracic, or cerebral injuries. The associated head injuries decreased with time from 49% in 1984 (9) to 19% in 1987 (3), to 18% in 1988 (15) and 10% in our up-to-date series.

An interesting observation in this study was that associated chest injuries were dominant; we can attribute this distribution of injuries to the fact that reduced speed limits, legislation about seat belts, safer cars and roads, and the use of airbags has led to an appreciable reduction in the number of major head and fatal chest injuries with more multiple but less dangerous chest injuries. As previously reported (14), the use of seat belts increased the incidence of minor thoracic injuries and prevented more life-threatening injuries. The use of seat belts in the series was not clear, and seldom reported by the patient or ambulance personnel. Postoperative pain was the main complaint during follow-up visits. This led to several days, weeks, or even months absence from work or even invalidity for the current job (2/29). We therefore recommend an aggressive approach including early operative reduction even for stable fractures to reduce the overwhelming pain. However, a similar paper (4)

showed that pain was the major complication but those authors did not suggest radical solution such as surgical correction.

We conclude that sternal fractures are more common than previously reported. A retrosternal haematoma can be differentiated from real mediastinal widening but our observations are clinical and based on only a small series, so should be interpreted cautiously (Table II and III). They may aid the management of sternal fractures and associated injuries (Table II), which may lessen the unnecessary use of angiograms in a stable patient with a traumatic retrosternal haematoma. However, the advanced trauma life support system (ATLS) recommends that any mediastinal widening is an indication for angiography (1). Our observations may make selection easier and avoid unnecessary angiograms. Sternal fracture with or without retrosternal haematoma was not associated with cardiac and aortic injuries, while mediastinal widening is still a fairly reliable indicator of the need for angiography.

REFERENCES

1. American College of Surgeons, Committee on Trauma *Advanced trauma life support manual*. Washington DC: ACS, 1993.
2. Attar S, Ayella RJ, McLaughlin JS. The widened mediastinum in trauma. *Ann Thorac Surg* 1987; 13: 435-449.
3. Buckman R, Trooskin SZ, Flancabaum L, Chandler J. The significance of stable patients with sternal fractures. *Surg Gynecol Obstet* 1987; 164: 261-265.
4. De Oliveira M, Hassan TB, Sebewufu R, Finlay D, Quinton DN. Long-term morbidity in patients suffering a sternal fracture following discharge from the A and E department. *Injury* 1998; 29: 609-612.
5. Gibson LD, Carter R, Hinshaw DB. Surgical significance of sternal fracture. *Surg Gynecol Obstet* 1962; 114: 443-448.
6. Gouldman JW, Miller RS. Sternal fractures: a benign entity? *Am Surg* 1997; 63: 17-19.
7. Harley DP, Mena I. Cardiac and vascular sequelae of sternal fractures. *J Trauma* 1986; 26: 553-555.
8. Hendrich C, Finkewitz U, Berner W. Diagnostic value of ultrasonography and conventional radiography for the assessment of sternal fractures. *Injury* 1995; 26: 601-604.
9. Newman RJ, Jones S. A prospective study of 413 consecutive car occupants with chest injuries. *J Trauma* 1984; 24: 129-135.
10. Otremski I, Wilde BR, Marsh JL, McLardy Smith PD, Newman RJ. Fracture of the sternum in motor vehicle accidents and its association with mediastinal injury. *Injury* 1990; 21: 81-83.
11. Richardson JD, Grover FL, Trinkle JK. Early operative management of isolated sternal fractures. *J Trauma* 1975; 15: 156-158.
12. Stuck WG. Fractures of the sternum. *Am J Surg* 1933; 22: 266-270.
13. Terry TR. Blunt injury of the heart. *BMJ* 1983; 286: 805.

14. Trinca GW, Dooley BJ. The effects of mandatory seat belt wearing on the mortality and pattern of injury of car occupants involved in motor vehicle crashes in Victoria. *Med J Aust* 1975; 1: 675–678.
15. Wojcik JB, Morgan AS. Sternal fractures—the natural history. *Ann Emerg Med* 1988; 17: 912–914.

Submitted December 15, 1999; submitted after revision May 16, 2000; accepted September 20, 2000

Address for correspondence:

Moheb A. Rashid, M.D.
Hagforsgatan 71
SE-416 75 Gothenburg
Sweden

III

Outcome of Lung Trauma

Moheb A. Rashid, Thore Wikström and Per Örtengren

From the Division of Vascular and Trauma Surgery, Department of Surgery, Sahlgrenska University, Hospital/Östra, Gothenburg University, Gothenburg, Sweden

Eur J Surg 2000; 166: 22–28

ABSTRACT

Objective: To find out whether we could manage critical pulmonary haemorrhages in penetrating injuries, and to report our experience with blunt trauma of the lung.

Design: Retrospective study

Setting: Teaching hospital, Sweden.

Subjects: 81 patients who presented with pulmonary injuries during the period January 1988–December 1997; 6 were penetrating and 75 blunt.

Results: There was only one patient with an isolated lung contusion. The remaining was divided into 2 groups: those with pulmonary contusion and thoracic lesions ($n = 32$), and those with pulmonary contusion and extrathoracic lesions ($n = 42$). Four patients in the penetrating group were shocked and required urgent operations; emergency room thoracotomy ($n = 1$), urgent thoracotomy ($n = 2$), and urgent thoracoabdominal exploration ($n = 1$) were done successfully. We correlated grade of lung injury [American Association for the Surgery of Trauma-Abbreviated Injury Scale (AIS)] with mortality. All patients with penetrating injuries survived without serious consequences. There were a mean (SD), of 6 (2) injuries/patient in those with extrathoracic injuries compared with 3 (1) injuries/patient in the group with thoracic lesions ($p < 0.001$). The corresponding hospital mortality was 6/42 (19%) mainly as a result of the central nervous system lesions (4/6) compared with 0/32. The mean (SD) Injury Severity Score (ISS) was 9.3 (4.8) in patients with thoracic lesions compared with 24.1 (14.7) in patients with extrathoracic lesions ($p < 0.0001$), and 14.9 (9.5) in all survivors compared with 49.9 (13.6) among those who died ($p < 0.0001$).

Conclusions: An excellent outcome can be achieved managing penetrating injuries of the lung by an aggressive approach and urgent surgical intervention even when emergency room thoracotomy is essential. Pulmonary contusion is considered to be a relatively benign lesion that does not add to the morbidity or mortality in patients with blunt chest trauma. These data may help to decrease the obsession with pulmonary contusion in patients with chest trauma, with or without extrathoracic lesions, and avoid many unnecessary computed tomograms of the chest.

Key words: lung injuries, pulmonary contusion, thoracotomy, morbidity, mortality.

INTRODUCTION

The earliest known record of thoracic injuries is found in the *Edwin Smith Surgical Papyrus*, written 5000 years ago. This details the care given to 21 patients with chest and neck injuries by the Egyptian Imhotep (4). Since that time, the treatment of chest trauma had been restricted to closed drainage of empyema during World War I (11) and removal of foreign bodies that entered the chest (26). During World War II, the Office of the Surgeon General decided that a thoracotomy should be done for any penetrating wound of the chest with appreciable blood loss. However, nowadays thoracostomy tubes are used in 85% of penetrating injuries, and only 15% need thoracotomy (20). Repair of wounds, anatomical resection including lobectomy (7), or tractotomy with selective vascular ligation (34) may be required, depending on the nature of the lesion. Pneumonectomy could be fatal and should be the last resort in the treatment of pulmonary injury.

Pulmonary contusion is defined as injury to lung

parenchyma that results in oedema and haemorrhage. It is often considered to be inconsequential in patients with chest trauma, but it is the second most common injury in blunt thoracic trauma and is associated with a mortality ranging from 14%–40% (22).

The present study was undertaken to review the management and outcome of 81 patients with chest trauma and documented penetrating or blunt injury to the lung.

PATIENTS AND METHODS

We retrospectively reviewed the medical records of 81 patients with penetrating or blunt trauma to the lung who were admitted to one emergency department in Sweden during the period January 1988 to December 1997. We recorded the age, sex, mechanism of injury, risk factors, associated injuries, complications, morbidity, and mortality. Six patients had penetrating injuries and 75 blunt trauma. There was only one

Table I. Mechanisms of injury in patients with blunt lung trauma

Mechanism of injury	Number (%)
Motor vehicle crash	30 (40)
Fall	24 (32)
Pedestrian car or tram accident	9 (12)
Crushing	3 (4)
Miscellaneous (abuse 6, football trauma 1)	7 (9)
Bicycle or motorcycle accident	1 (1)
Barotrauma	1 (1)
Total	75 (100)

patient with blunt trauma and an isolated lung contusion. For the purpose of analysis, we divided the remaining 74 patients with blunt trauma into two groups, those with pulmonary contusion and thoracic lesions and those with pulmonary contusion and extrathoracic lesions.

The diagnosis of pulmonary contusion was made or suspected by the radiologist in charge and confirmed by looking at the timing of the radiological changes, the site of the abnormality relative to the site of the penetrating injuries or blow, and whether the opacification was segmental or not. Atelectasis, aspiration, or contusion could be indicated by segmental opacification. Although the diagnosis of pulmonary contusion was not completely accurate, the main criteria "timing and anatomical distribution" were helpful in differentiating it from atelectasis and aspiration.

The Injury Severity Score (ISS) was calculated using the 1990 Abbreviated Injury Scale (AIS) (6) and the method of Baker et al. (2). All patients were treated in the emergency department by primary survey including airway management, and volume resuscitation as

Table II. The risk factors for injury in patients with lung trauma

Risk factors	Blunt (n = 74)	Penetrating (n = 6)
Alcohol/drug abuse or affected	17	2
Depression, sadness or neurosis	6	0
Attempted suicide	3	0
Co-existing conditions		
Epilepsy	1	0
Cerebrovascular lesion	1	0
Parkinson's disease	1	0
Syncope	1	0
Previous attempted suicide	1	0
Malignant lymphoma	1	0
Patent ductus arteriosus and total anomalous pulmonary venous drainage	1	0

Table III. Treatment of patients with penetrating lung injuries and its complications (n = 6)

Treatment	Complications
<i>Emergency room thoracotomy (right)</i>	None
Pulmonary hilar cross-clamping	
Ligation of middle lobe pulmonary vessels	
Repair of two big parenchymal lacerations	
<i>Urgent thoracotomy (right)</i>	None
Ligation of pericardial artery	
Evacuation of pericardial tamponade	
Repair of two parenchymal wounds;	
One in the right upper lobe	
One in the middle lobe	
<i>Urgent thoracotomy (left)</i>	Pain
Ligation of left internal mammary artery	
Repair of 2.5 cm wound in upper pole of left upper lobe	
<i>Urgent thoracotomy (left)</i>	Abscess of chest incision
Repair of wound in left lower lobe	
Two chest tubes	
Repair of perforated stomach and diaphragm	
<i>Chest tubes</i>	
In two patients who were not shocked	None

required. A physical examination was made followed by appropriate investigations. The management of lung injuries was individualised according to the clinical judgement of the surgeon in charge of the patient.

The significance of differences was assessed using the rank sum two-sample (Mann-Whitney test) and chi square tests where applicable. A probability of less than 0.05 was considered significant.

RESULTS

Over a 10-year period, 81 patients with lung trauma were managed at Sahlgrenska University hospital/Östra, Gothenburg, Sweden. There were 32 patients with contusions and thoracic injuries [mean (SD) age 47.4 (17.5), 26 men and 7 women] and 42 patients with contusions and extrathoracic lesions [mean (SD) age 40.6 (17), 32 men and 10 women]. The mechanism of injury was stabbing with a knife in all those in the penetrating group and the mechanisms of injury in the blunt group are shown in Table I. The risk factors are presented in Table II. Four patients (4/6) in the penetrating group presented with shock and all required urgent operations, emergency room thoracotomy ($n = 1$), urgent thoracotomy ($n = 2$), and urgent thoracoabdominal exploration ($n = 1$), all of which were successful. All these patients survived without serious consequences. Details of the operations are shown in Table III. The associated injuries in the different groups are shown in Tables IV–VI.

There were 6 (2) injuries/patient in the extrathoracic

Table IV. Associated injuries in patients with penetrating lung trauma (n = 6)

Type of injury	Number
Pneumothorax	4
Haemothorax	5
Subcutaneous emphysema	1
Cerebral concussion	1
Limb lacerations	1
Facial wounds	1
Lacerations of the neck	1
Pericardial injury	1
Cardiac tamponade	1
Gastric perforation	1
Diaphragmatic injury	1
Internal mammary artery injury	1
Total	19
Mean (SD)	3 (1) lesions/patient

injury group compared with 3 (1) injuries/patient in the thoracic group ($p < 0.001$). The hospital mortality in extrathoracic group was 6/42 (19%) mainly as a result of lesions of the central nervous system ($n = 4$). One patient died of haemorrhage and another one of multiple organ failure (Table VII). The mean (SD) Injury Severity Score (ISS) was 9.3 (4.8) in patients with thoracic lesions compared with 24.1 (14.7) in patients with extrathoracic lesions ($p < 0.0001$), and 14.9 (9.5) in all survivors compared with 49.9 (13.6) among those who died ($p < 0.0001$). All patients less than 30 years old (17/81, 21%) were male.

There was no significant difference between the two groups regarding age, sex, and duration of stay in intensive care and the ward. However, there was significant difference in length of hospital stay which was 8 (7) in the thoracic group compared with 13 (10) ($P < 0.04$) in the extrathoracic group. We had no cases of systemic air embolism, intrabronchial bleeding,

Table V. Associated injuries in patients with thoracic lesions—blunt lung trauma (n = 32)

Type of injury	Number
Rib fractures	26
Pneumothorax	23
Haemothorax	19
Subcutaneous emphysema	9
Chest wall contusion	7
Extrapleural haematoma	5
Flail chest	3
Scapular fracture	3
Sternal fracture	1
Pneumomediastinum	1
Total	97
Mean (SD)	3 (1) lesions/patient

Table VI. Associated injuries in patients with extrathoracic lesions—blunt lung trauma (n = 42)

Type of injury	Number
Rib fractures	36
Haemothorax	34
Pneumothorax	27
Fractured limb	15
Hepatic rupture or injury	13
Subcutaneous emphysema	12
Pelvic fracture	10
Splenic rupture or injury	9
Chest wall contusion	8
Clavicular fracture	8
Lacerations of limbs	8
Vertebral fractures	7
Renal injury	6
Cerebral concussion	6
Intra-abdominal bleeding	5
Extrapleural haematoma	4
Flail chest	4
Scapular fracture	3
Sternal fracture	3
Cerebral bleeding	3
Fractured skull	3
Facial wounds	3
Haematoma of scalp	3
Pancreatic injury	3
Pneumomediastinum	2
Epidural haematoma	2
Subdural haematoma	2
Colonic lacerations	2
Small intestinal lacerations	2
Cardiac contusion	2
Facial fracture	1
Subarachnoid bleeding	1
Fracture hip	1
Lacerations of the neck	1
Urethral injury	1
Injury of small intestinal mesentery	1
Ruptured urinary bladder	1
Ruptured inferior vena cava	1
Traumatic asphyxia	1
Total	254
Mean (SD)	6 (2) lesions/patient

arteriovenous fistula, or aspiration. There was only one case of isolated lung contusion and this patient survived without complication. No patient died in the thoracic group. Twenty patients (27%) with blunt injuries and four with penetrating injuries presented with shock. No one died when the ISS was less than 29, while all patients with an ISS of 40 or more died (Table VIII).

All pulmonary injuries in this series were graded using AIS for lung injuries (19). Most pulmonary injuries were grade I without mortality, two deaths in each of grades II–IV. No injuries were clustered around grades V or VI (Table IX). The difference in the number of complications after treatment of blunt

Table VII. Mortality

Age	Sex	ISS	Lung lesion	Cause of death
75	Male	57	Lung haematoma	Lesion of CNS
20	Male	68	Bilateral contusions	Lesion of CNS
34	Male	40	Unilateral contusion	Lesion of CNS
84	Male	50	Lung haematoma	Lesion of CNS
46	Male	54	Ruptured lung	Haemorrhage
47	Female	29	Bilateral contusions	Post-traumatic multiple organ failure

CNS = central nervous system.

Table VIII. Mortality and ISS in patients with blunt trauma (n = 75)

ISS	No. of patients	No. who died
0-10	32	0
11-20	23	0
21-30	8	1
31-40	8	1
>40	4	4

Table IX. American Association for the Surgery of Trauma—Abbreviated Injury Scale

Scale	No. (%) of Injuries	No. who died
I	45 (56)	0
II	13 (16)	2
III	18 (22)	2
IV	5 (6)	2
V	0	0
VI	0	0
Total	81 (100)	6

trauma to the lung in the two groups was not significant (Table X), while the number of patients who required treatment for associated injuries was 6/32 in the

Table X. Complications after the treatment of blunt trauma to the lung

Complications	With thoracic lesions (n = 32)	With extrathoracic lesions (n = 42)
Pain	8	5
Adult respiratory distress syndrome	1	1
Failed thoracentesis	1	0
Encysted haemothorax	0	2
Extrapleural drain insertion	1	0
Encysted extrapleural haematoma	0	2
Persistent haematomas for longer than two weeks	1	0
Total	12	10

thoracic group compared with 21/42 in the extrathoracic group ($P < 0.02$) (Table XI).

DISCUSSION

Penetrating injuries

The incidence of penetrating lung injuries in our series was 1.3%. This is an accurate incidence as it was measured according to the total number of consecutive

Table XI. Treatment of associated injuries and its complications

Treatment	No.	Complications
With thoracic lesions (n = 32)		
Thoracentesis (with sonography in 2)	3	Incomplete resolution in one
Delayed thoracotomy	1	None
Hyperbaric oxygen	1	Pain and tiredness Hypoesthesia of the left infraorbital nerve
Video-assisted thoracic surgery for; Excision of an emphysematous bulla Pulmonary wedge resection Partial pleurectomy	1	None
With extrathoracic lesions (n = 42)		
Urgent laparotomy without chest tubes	7	Pancreatic cysts No abnormality found
Operation for skeletal fracture	7	None
Urgent laparotomy and chest tubes	3	Psychological reaction
Urgent thoracolaparotomy	2	One died
Emergency bilateral craniotomy	1	Died
Embolisation of hepatic artery	1	None
Cystostomy	1	None

patients (6/477) who sustained chest trauma that necessitated admission during the last 10-year period. We found that a third of the patients with penetrating injuries were affected by alcohol or drugs. All penetrating wounds of the lung in this study were caused by knives. These typically injured only the wound track, with minimal contusion or haematoma that resolved spontaneously. However, bleeding from moderate-sized central pulmonary vessels, in case of deep central injury, may not be controlled and can flood the alveoli in the segment, lobe, or entire lung. This may lead to internal blood aspiration in the damaged parenchyma resulting in decreased alveolar membrane diffusion and compliance (10). This results in worsening atelectasis, intrapulmonary shunting, and hypoxaemia (24), which roughly parallels the extent of parenchymal involvement in pulmonary contusion (8). Deep central injuries to the lung predispose to communication between the airways and the pulmonary venous plexus. When ventilation pressure exceeds 60 mm Hg, it may result in pulmonary venous air embolism taking air into the coronary arteries and cerebral vessels (12).

We had no experience with air embolism in injured patients during the past 10 years. However, we had a patient with massive bleeding who underwent emergency room thoracotomy with hilar cross-clamping that saved his life, and the postoperative course was uneventful.

The diagnosis of penetrating lung injury is made immediately from the history of stabbing or gunshot. Inspection of the wound (entrance or exit or both) before or during thoracotomy may confirm the diagnosis.

In our study, we did not do tractotomy, lobectomy, or pneumonectomy, but we repaired all lacerations in all those who were operated on, with or without ligation of vessels. Pulmonary tractotomy with selective vascular ligation is a less technically demanding procedure being short and simple and preserving lung tissue. It is indicated for lung injuries that are located towards the hilum in relatively stable patients, who do not require lobectomy or pneumonectomy (34). It also allows direct control of bleeding and air leak, and avoids the need for resection (35). Most recently, stapled tractotomy was shown to be rapid and effective in the control of bleeding and air leaks (31). The surgeon should strive to preserve as much viable tissue as possible, because the pulmonary parenchyma seals itself and heals well. In addition, there is appreciable mortality associated with pneumonectomy in injured patients (3, 22), which may reach 100% as shown in a report from Houston, Texas (28). Although most patients with penetrating lung trauma may be treated conservatively with chest tube (13, 23), urgent thor-

acotomy should be done soon after admission if it is to be effective, as shown by our study and others (1, 13).

All four patients who required urgent thoracic surgery survived without serious consequences. Emergency room thoracotomy in patients with penetrating thoracic injuries is often more successful after cardiac than extracardiac (great vessel, hilum, or lung) trauma (9). However, the outcome was excellent for all our urgent thoracotomies for pulmonary injuries.

We therefore recommend an aggressive approach in managing patients with penetrating lung injury who present with shock even when emergency room thoracotomy is essential. We also recommend pulmonary hilar cross-clamping in patients with massive and intractable pulmonary bleeding as it controls the bleeding, and reduces the risk of systemic air embolism (36) and aspiration in the uninjured lung parenchyma.

Blunt injuries

The incidence of blunt lung injuries in our series was 16%. Seventeen (23%) patients with blunt injuries were under the influence of alcohol or drugs. Depression, attempted suicide, and associated diseases such as epilepsy, syncope, Parkinson's disease, and so on (Table II) were among the risk factors in this group. Obviously, pulmonary contusion is a lesion caused by trauma and is almost always associated with thoracic lesions, most commonly rib fractures, haemothorax, and pneumothorax (Tables V and VI). However, the precise mechanism for the development of pulmonary contusion in blunt trauma of the lung is not clear.

The radiographic changes of lung contusion appear during the first 4–6 hours after injury and in other patients within the next 24 hours. Generally, pulmonary contusions are much larger than one would suspect from initial chest radiographs (15), which tend to lag at least 24 hours behind changes in blood gases. The changes of pulmonary contusion often progress during the first 24 hours after the injury, so repeated chest radiographs and blood gas measurements are recommended at 6–12 hour intervals, to guide management. Chest radiographs remain the best way of evaluating the chest after blunt trauma. Although they are less sensitive in detecting parenchymal and pleural injuries than computed tomograms (CT), most injuries identified by CT alone are minor and require no treatment (18).

However, CT of the chest can quantify the extent of injury with confidence, with the caveat that the injury is an evolving lesion. The consolidation seen on CT has been interpreted as blood-filled alveoli without interstitial injury and the fissures almost always restrict the consolidation (33).

The treatment of pulmonary contusion includes volume replacement; blood loss should be replaced

with blood or blood components and the amount of crystalloid given should probably be kept to a minimum, because excessive amounts of crystalloid aggravate contusion (15). However, there is no consensus about the type and amount of fluids to be given to patients with pulmonary contusions, but one should try to keep the hourly urine output at about 0.5 ml/kg body weight with crystalloids. There is no evidence claiming that colloids should be preferred to crystalloids to reduce pulmonary oedema (30).

Adequate and selective ventilatory support and aggressive pulmonary toilet to prevent pneumonia are important. Chest physiotherapy, nasotracheal suction; and pain relief with intravenous analgesia, intercostal nerve blocks, intrapleural, and epidural analgesia; should be used as needed. Methylprednisolone (30 mg/kg body weight) has been reported to reduce the mortality and some serious haemodynamic effects in patients with blunt chest trauma and lung contusion (27). We had limited experience with this, and as the treatment was individualised, we found only 8 patients (10%) given both corticosteroids and antibiotics and only five (6%) treated with antibiotics. The optimal treatment of lung contusion may be difficult to evaluate, because most patients have appreciable associated cardiothoracic and extrathoracic lesions (5, 27). So, we could not work out which patients were mechanically ventilated just because of lung contusion.

Our series differs from the Oslo study (27) in that the incidence of associated injuries in the chest was higher and double the incidence of extrathoracic lesions (Tables IV–VI). A similar observation has been reported previously from San Francisco (5) and showed that a higher morbidity and mortality included severe associated thoracic injuries.

Patients with pulmonary contusions are often victims of blunt trauma with multiple injuries (5, 16), as in our series. All patients less than 30 years old (17/81, 21%) were male. We suggest that this age and sex could be a risk factor for lung trauma.

Video-assisted thoracic surgery is an effective and safe method for the initial diagnostic evaluation and surgical treatment of stable patients with thoracic trauma (14, 25, 32). Although the incidence of complications is similar to that after formal thoracotomy, it has many advantages including shorter hospital stay, less pain, and faster return to normal activity (17). In our study, we used it in one patient for resection of an emphysematous bulla, wedge pulmonary resection, and partial pleurectomy. The postoperative course was uneventful. However, it is contraindicated in patients with traumatic extrapleural haematoma (21).

Hyperbaric oxygen was given to one patient with barotrauma of the lung after a diving accident. The

postoperative course was complicated by pain, tiredness, and hypoaesthesia of the left infraorbital nerve. There were a mean (SD) of 6 (2) injuries/patient in the extrathoracic group compared with 3 (1) injuries/patient in the thoracic group ($p < 0.001$). The hospital mortality in the former group was 6/42 (19%) as a result of associated injuries, mostly lesions of the central nervous system (4/6). This is consistent with previous studies (5, 16), which have shown that the severity of associated injuries and injuries of the central nervous system were the primary predictors of outcome in patients with pulmonary contusion.

As pulmonary contusion itself does not add to morbidity and mortality, our results may help to lessen the obsession with pulmonary contusion in patients with chest trauma with or without extrathoracic lesions, and avoid the many unnecessary CT of the chest.

ACKNOWLEDGEMENT

We thank Dr. Roland Andersson, M.D., Ph.D., for his help during calculation of the results.

REFERENCES

- Adkins Jr RB, Whiteneck JM, Woltering EA. Penetrating chest wall and thoracic injuries. *Am Surg* 1985; 51: 140–148.
- Baker SP, O'Neill B, Haddon Jr W, Long WB. The Injury Severity Score: a method for describing patients with multiple injuries and evaluation of emergency care. *J Trauma* 1974; 14: 187–196.
- Bowling R, Mavroudis C, Richardson JD, Flint LM, Howe WR, Gray Jr LA. Emergency pneumonectomy for penetrating and blunt trauma. *Am Surg* 1985; 51: 136–139.
- Breasted JH, ed. *The Edwin Smith Surgical Papyrus*. Vol 1. Chicago: University of Chicago Press, 1930: 369–373.
- Clark GC, Schechter WP, Trunkey DD. Variables affecting outcome in blunt chest trauma: flail chest vs pulmonary contusion. *J Trauma* 1988; 28: 298–304.
- Committee on Injury Scaling The Abbreviated Injury Scale, 1990 revision. Des Plaines, Ill: American Association for Automotive Medicine, 1990.
- Eddy AC, Carrico CJ, Rusch VW. Injury to the lung and pleura. In: Moore EE, Mattox KL, Feliciano DV, eds. *Trauma*. 2nd ed. Norwalk, Conn: Appleton & Lange, 1991: 357–371.
- Erickson DR, Shinozaki T, Beekman E, Davis JH. Relationship of arterial blood gases and pulmonary radiographs to the degree of pulmonary damage in experimental pulmonary contusion. *J Trauma* 1971; 11: 689–694.
- Feliciano DV, Bitondo CG, Cruse PA, et al. Liberal use of emergency center thoracotomy. *Am J Surg* 1986; 152: 654–659.
- Fulton RL, Peter ET. The progressive nature of pulmonary contusion. *Surgery* 1970; 76: 499–506.

11. Graham EA, Bell RD. Open pneumothorax: its relation to the treatment of emphyema. *Am J Med Sci* 1918; 156: 839.
12. Graham JM, Beall Jr AC, Mattox KL, et al. Systemic air embolism following penetrating trauma to the lung. *Chest* 1977; 72: 449–454.
13. Graham JM, Mattox KL, Beall Jr AC. Penetrating trauma of the lung. *J Trauma* 1979; 19: 665–669.
14. Heniford BT, Carrillo EH, Spain DA, Sosa JL, Fulton RL, Richardson JD. The role of thoracoscopy in the management of retained thoracic collections after trauma. *Ann Thorac Surg* 1997; 63: 940–943.
15. Hoff ST, Shotts SD, Eddy VA, et al. Outcome of isolated pulmonary contusion in blunt trauma patients. *Am Surg* 1994; 60: 138–142.
16. Johnson JJ, Cogbill TH, Winga ER. Determinants of outcome after pulmonary contusion. *J Trauma* 1986; 26: 695–697.
17. Kaiser LR, Bavaria JE. Complications of thoracoscopy. *Ann Thorac Surg* 1993; 56: 796–798.
18. Marts B, Durham R, Shapiro M, et al. Computed tomography in the diagnosis of blunt thoracic injury. *Am J Surg* 1994; 168: 688–692.
19. Moore EE, Malangoni MA, Cogbill TH, et al. Organ injury scaling IV: Thoracic vascular, lung, cardiac, and diaphragm. *J Trauma* 1994; 36: 299–300.
20. Pickard LR, Mattox KL. Thoracic trauma, general consideration and indications for thoracotomy. In: Moore EE, Mattox KL, Feliciano DV, eds. *Trauma*. 2nd ed. Norwalk, Conn: Appleton & Lange, 1991: 319–326.
21. Rashid MA. Value of video-assisted thoracic surgery in traumatic extrapleural hematoma. *Thorac Cardiovasc Surg* 1999; 47: 255–257.
22. Reul GJ, Mattox KL, Beall Jr AC, et al. Recent advances in the operative management of massive chest trauma. *Ann Thorac Surg* 1973; 16: 52–66.
23. Robison PD, Harman PK, Trinkle JK, Grover FL. Management of penetrating lung injuries in civilian practice. *J Thorac Cardiovasc Surg* 1988; 95: 184–190.
24. Shackford SR. Blunt chest trauma: the intensivist's perspective. *J Int Care Med* 1986; 1: 125–136.
25. Sosa JL, Pombo H, Puente I, et al. Thoracoscopy in the evaluation and management of thoracic trauma. *Int Surg* 1998; 83: 187–189.
26. Sparkman RS, Nixon PI, eds. *The Texas Surgical Society: the first fifty years*. Dallas, Texas, 1965: 4–5.
27. Svennevig JL, Pillgram-Larsen J, Fjeld NB, et al. Early use of corticosteroids in severe closed chest injuries: a 10-year experience. *Injury* 1987; 18: 309–312.
28. Thompson DA, Rowlands BJ, Walker WE, Kuykendall RC, Miller PW, Fischer RP. Urgent thoracotomy for pulmonary or tracheobronchial injury. *J Trauma* 1988; 28: 276–279.
29. Turney SZ, Rodriguez A, Cowley RA. Preface. In: Turney SZ, Rodriguez A, Cowley RA, eds. *Management of cardiothoracic trauma*. Baltimore: Williams and Wilkins, 1990; IX.
30. Velanovich V. Crystalloid vs colloid fluid resuscitation: a meta-analysis of mortality. *Surgery* 1989; 105: 65–71.
31. Velmahos GC, Baker C, Demetriades D, Goodman J, Murray JA, Asensio JA. Lung-sparing surgery after penetrating trauma using tractotomy, partial lobectomy, and pneumonorrhaphy. *Arch Surg* 1999; 134: 186–189.
32. Villavicencio RT, Aucar JA, Wall Jr MJ. Analysis of thoracoscopy in trauma. *Surg Endosc* 1999; 13: 3–9.
33. Wagner RB, Jamieson PM. Pulmonary contusion: evaluation and classification by computed tomography. *Surg Clin North Am* 1989; 69: 31–40.
34. Wall Jr MJ, Hirshberg A, Mattox KL. Pulmonary tractotomy with selective vascular ligation for penetrating injuries to the lung. *Am J Surg* 1994; 168: 665–669.
35. Wall Jr MJ, Villavicencio RT, Miller III CC, et al. Pulmonary tractotomy as an abbreviated thoracotomy technique. *J Trauma* 1998; 45: 1015–1023.
36. Wiencek Jr RG, Wilson RF. Central lung injuries: a need for early vascular control. *J Trauma* 1988; 28: 1418–1424.

Submitted September 1, 1998; submitted after revision May 11, 1999; accepted May 20, 1999

Address for correspondence:

Moheb A. Rashid, M.D.
 Trebackegatan 11
 SE-416 74 Gothenburg
 Sweden

IV

Cardiac Injuries: a Ten-Year Experience

Moheb A. Rashid, Thore Wikström and Per Örtengren

From the Division of Vascular and Trauma Surgery, Department of Surgery, Sahlgrenska University Hospital, Östra, Gothenburg University, Gothenburg, Sweden

Eur J Surg 2000; 166: 18–21

ABSTRACT

Objective: To present our experience of cardiac injuries treated at one Swedish emergency department in the 10 years 1988–97.

Design: Retrospective study.

Setting: Teaching hospital.

Subjects: 11 patients (9 men and 2 women, mean age 33 years, range 19–54); in 7 they were penetrating injuries and in 4 blunt.

Main outcome measures: Morbidity and mortality.

Results: The mechanisms of injury were stab wound ($n = 7$), and car crash, fall, boat crash, and abuse ($n = 1$ each); drug or alcohol misuse played a part in all those with penetrating injuries. The penetrating wounds involved the left ventricle ($n = 3$), the right ventricle ($n = 2$), and the pericardium ($n = 2$). All 5 patients with ventricular wounds presented with cardiac tamponade, in 1 of whom it was fatal (he bled to death during emergency thoracotomy). The main complications were anoxic brain damage and postpericardiotomy syndrome (1 each). There was no case of myocardial concussion.

Conclusion: Our data reflect the Swedish experience of heart trauma: there are few cases, alcohol and drug misuse is the principal risk factor, and there were no gunshot wounds.

Key words: heart injuries, pericardial tamponade, myocardial contusion, commotio cordis.

INTRODUCTION

There have been numerous publications on the subject of injuries of the heart (3, 9, 19, 22, 23), and only 20% of patients with penetrating wounds reach the hospital alive (22); all clinical series of heart wounds are therefore, highly selective. The severity and mortality of blunt cardiac injury vary (23), and there is a wide range of injuries, from subepicardial, subendocardial, or transmural myocardial contusion (10) to rupture of a chamber with acute pericardial tamponade (19). Myocardial contusion includes anatomical injury, which can be diagnosed either by raised creatine kinase isoenzyme (CK-MB) or on direct vision during operation or necropsy. With myocardial concussion there is no anatomical cellular injury, but some functional damage can be seen on two-dimensional echocardiography or other wall-motion studies (8, 19).

Our university hospital is one of Sweden's most active trauma centres and our results therefore reflect the Swedish experience of cardiac trauma. The incidence and causes of heart trauma in Scandinavian countries including Sweden are poorly defined, so we analysed retrospectively all patients with a documented penetrating or blunt heart injury during the 10-year period, January 1988–December 1997.

PATIENTS AND METHODS

All patients who sustained chest injuries with cardiac

trauma between January 1988 and December 1997 were analysed. The age, sex, mechanism of injury, comorbidity, risk factors, clinical diagnosis, associated injuries, complications, treatment, length of hospital stay [intensive care unit (ICU) and ward] and follow-up were recorded. There were 11 patients (9 men and 2 women, average age 33 years, range 19–54) of whom 7 had penetrating injuries and 4 blunt. The mechanism of injury was knife stab ($n = 7$), and car crash, fall, boat crash, and abuse ($n = 1$ each).

RESULTS

All patients with penetrating injuries misused drugs or alcohol or both. Six patients presented with shock, while one patient with a penetrated pericardium was stable. Beck's triad (distended neck veins, hypotension, and muffled heart sounds) was found in two patients of whom one had a normal echocardiogram. This was disproved because tamponade was found at operation. Two components of Beck's triad were seen in three patients and one component of the triad was seen in one patient who underwent an echocardiogram which indicated tamponade and was confirmed at operation.

Details of the operations done for the patients with penetrating injuries are shown in Table I. Cardiac wounds involved the left ventricle in three, right ventricle in two and the pericardium alone in two. All five patients with penetrating ventricular wounds

Table I. Details of operations in seven patients with penetrating injuries

Case (no.)	Operations	Lesion
1	<i>Urgent left thoracotomy</i> Defibrillation (ventricular fibrillation) Cardiorrhaphy	5 mm apical, and pericardial wound
2	<i>Urgent right thoracotomy</i> Ligation of pericardial artery	Pericardial lesion
3	<i>Urgent left thoracotomy</i> Massive left haemothorax	1.5 cm left ventricle pericardial wound and tamponade (at necropsy)
4	<i>Urgent laparotomy and sternotomy</i> Negative laparotomy Cardiorrhaphy	2 cm pericardium, and 1 cm right ventricle
5	<i>Urgent left thoracotomy</i> Cardiorrhaphy	1 cm left ventricle, and pericardial wound
6	<i>Delayed laparotomy and sternotomy</i> Cardiorrhaphy	1.5 cm left ventricle, and pericardial wound
7	<i>Urgent laparotomy</i> Suturing of the diaphragmatic lesion Insertion of right-sided chest tube	Pericardial lesion

presented with cardiac tamponade which was fatal in one. Urgent laparotomy was done for associated splenic rupture that required splenectomy, and for a mesenteric lesion that needed suturing in a patient with blunt trauma. The major complications were reversible cortical blindness, ataxia, and dysphasia as a result of anoxic brain injury in one patient, and postpericardiotomy syndrome (fever, malaise, arthralgia, dyspnoea and pleural pericardial pain) in another. Pancreatic cysts, pain in the chest, and psychological stress reaction were found in one patient each. One patient died during urgent thoracotomy because of pump failure and blood loss.

Patients with blunt trauma (myocardial contusion) were diagnosed on the basis of raised CK-MB activity, ST/T wave changes or arrhythmias (Table II). We had no case diagnosed with myocardial concussion "commotio cordis" and the incidence of blunt trauma was small (4/11). Two patients had echocardiograms, one had an angiogram of the thoracic aorta, and one a sonogram of the carotid arteries. These investigations were within normal limits. The incidence of associated injuries is shown in Table III. The median duration of hospital stay was 9.1 and 6.8 days in the ward and 4.9

and 4.3 days in the ICU for patients with penetrating and blunt injuries, respectively.

DISCUSSION

Clinically, the patient with penetrating cardiac injuries may present with haemorrhagic shock, or pericardial tamponade, or may be stable. In stable patients, the diagnosis may be overlooked (16) and delayed haemorrhage may occur from 2 days to 3 weeks after the injury (14); rapid bleeds may be fatal. Beck's triad (5) (including distended neck veins, hypotension, and muffled heart sounds) may be found. We found this triad or one of its components in all patients with tamponade, which is consistent with the findings of

Table II. Reasons for diagnosis of blunt myocardial injury in 4 patients

Variable	No. of patients
Increased CK-MB	2
ST/T changes	3
Right bundle branch block	1
Bradycardia	1
Tachycardia	1

Table III. Associated injuries in 11 patients with cardiac trauma

Associated injuries	Penetrating (n = 14)	Blunt (n = 13)
Haemothorax	3	2
Pulmonary contusion	3	2
Rib fractures	2	1
Subcutaneous emphysema	1	2
Penetration of lung	1	0
Pneumothorax	1	0
Diaphragmatic injury	1	0
Pneumoperitoneum	1	0
Hepatic wound	1	0
Flail chest	0	1
Splenic rupture	0	1
Pancreatic lesion	0	1
Lesion of intestinal mesentery	0	1
Cerebral concussion and contusion	0	1
Fractures of clavicle and humerus	0	1

others (7). However, it can be deceptive (24), as the neck veins in patients with shock from pericardial tamponade will not usually become distended until coexistent hypovolaemia is at least partly corrected. Distended neck veins after chest trauma may be caused by shivering, pain, and splinting in the chest or abdomen because of pleural or peritoneal irritation. Tension pneumothorax is a common cause of such distension in both penetrating and blunt chest trauma. Muffled heart sounds are an insensitive, non-specific sign and are the least reliable sign in Beck's triad. Pericardiocentesis is generally misleading and not safe. A subxiphoid pericardial window made with a subxiphoid or subcostal technique is a well-accepted method for the diagnosis and relief of tamponade (2). In this series, we did neither pericardiocentesis nor a pericardial window. We relied on the clinical picture with some help from two-dimensional echocardiography to diagnose cardiac injuries. FAST (Focused Abdominal Sonography for Trauma) was done for one patient and it showed pericardial fluid during abdominal investigation. Two-dimensional echocardiography is a fairly reliable method of diagnosing tamponade (1), but there are occasional false positive and false negative results. We did encounter a false-negative result in our series, probably because intrapericardial blood moves to the most dependent portions of the pericardial cavity and there may be a haemothorax at the interface. We did not find a haemothorax, but there was a huge haematoma in the anterior mediastinum that probably interfered with the accuracy and gave the false-negative result on two-dimensional echocardiography. The patient had a tamponade caused by a 1.5 cm left ventricular wound two days before operation. There was no pleural breach, which may explain that the patient lived with the tamponade for two days before it was relieved. In the penetrating group, the pleura was breached in three cases including the patient who bled to death, with a left pleural breach and massive haemothorax shifting the mediastinum to the right. Like others (6), we consider pleural breach as a risk factor for death in patients with penetrating cardiac injuries.

All patients with penetrating ventricular wounds presented with cardiac tamponade, which was fatal in one patient. Pericardial tamponade may prolong life by reducing the severity of the initial blood loss, which allows enough time for resuscitation (17), (as in four patients in this study). However, it may be fatal because it interferes with venous return and diastolic filling of the heart, impairs cardiac contractility and reduces cardiac output. The time during which its protective effect becomes deleterious has yet to be defined. So, its effects on survival are not clear cut (3). In our limited experience pericardial tamponade can be

both good and bad in penetrating cardiac wounds. The treatment of ventricular wounds in this study was by tamponading the defect with the surgeon's finger while pledged horizontal mattress sutures of 2/0 polypropylene (Prolene) were passed under the finger (avoiding the coronary arteries—the suture is placed below it) and tied by an assistant. Cardiopulmonary bypass was not used in these cases, but is of great help when the injury involves the posterior aspect of the heart or when it is large. However, it is ineffective in saving patients with cardiogenic shock, but it was essential in some patients with complex multiple-chamber cardiac injuries that could not be exposed and repaired by other means (4). We saw no coronary artery injuries, septal defects, valvular injuries, aneurysms or air embolisms in this study.

Blunt cardiac injury (previously termed *myocardial contusion*) is a nebulous term used to describe an injury that may consume considerable resources, but is often of little clinical relevance (15). It is difficult to diagnose with certainty and has been referred to as "capricious syndrome" (12). Isolated raised CK-MB activity or admission electrocardiogram (ECG) have varying sensitivity and specificity for both diagnosis and risk stratification (23). It should be suspected in any case with severe trauma to the anterior chest. When a myocardial contusion is suspected or must be ruled out, then a chest radiograph, ECG (serially), echocardiogram, and cardiac troponin analysis should be done. However, screening of heart contusion by measuring CK-MB activity, and taking an ECG seems to be sufficient when the trauma is less than 12 hours old. Cardiac troponin immunoassays (cTnI and cTnT) are now considered to be the "gold" standard (when positive) as confirmatory adjuncts in the diagnosis of myocardial contusion, and in separating it from skeletal muscle trauma (11). The sensitivity of the assay is as good as or better than that of CK-MB activity and their specificity may reach 100% (21). If there is evidence of cardiac dysfunction, aggressive investigation using transoesophageal echocardiography, which is accurate and allows evaluation of the thoracic aorta, is helpful (18). Arrhythmias were found in 3/4 cases in this series. In this study cardiac contusion was probably overshadowed by the overt signs of associated skeletal, abdominal, thoracic or cerebral injuries.

Myocardial concussion may result from a sudden, forceful, or high-velocity blow to the chest (hockey puck, kick, or baseball), and can result in sudden death as a consequence of cardiac arrhythmia. These deaths are probably caused by ventricular dysrhythmia induced by an abrupt, blunt, myocardial blow delivered at an electrically vulnerable phase of ventricular excitability (13). We had no patients with this diagnosis. A point worthy of mention is that the

incidence and severity of associated injuries in blunt trauma were more common and severe, than with penetrating injuries (Table 3).

Penetrating cardiac injuries are associated with high mortality, which has improved only minimally in the past three decades despite the institution of elaborate prehospital systems and modern technological advances (20). Our mortality for penetrating cardiac injuries was 20% compared with 32% in a major trauma centre (3) in which 60 cases were studied prospectively during a one year period. Although our series is too small to analyse statistically, it does reflect the Swedish experience of heart trauma, which is limited and in which alcohol or drug misuse were a risk factor, and there were no gunshot wounds.

REFERENCES

1. Aaland MO, Bryan III FC, Sherman R. Two-dimensional echocardiogram in hemodynamically stable victims of penetrating precordial trauma. *Am Surg* 1994; 60: 412–415.
2. Arom KV, Richardson JD, Webb G, et al. Subxiphoid pericardial window in patients with suspected traumatic pericardial tamponade. *Ann Thorac Surg* 1977; 23: 545–549.
3. Asensio JA, Murray J, Demetriades D, et al. Penetrating cardiac injuries: a prospective study of variables predicting outcomes. *J Am Coll Surg* 1998; 186: 24–34.
4. Baker JM, Battistella FD, Kraut E, Owings JT, Follette DM. Use of cardiopulmonary bypass to salvage patients with multiple-chamber heart wounds. *Arch Surg* 1998; 133: 855–860.
5. Beck CS. Two cardiac compression triads. *JAMA* 1935; 104: 714–716.
6. Campbell NC, Thomson SR, Muckart DJJ, Meumann CM, Van Middelkoop I, Botha JBC. Review of 1198 cases of penetrating cardiac trauma. *Br J Surg* 1997; 84: 1737–1740.
7. Demetriades D. Cardiac wounds. *Ann Surg* 1985; 203: 315–317.
8. Frazee RC, Mucha P, Farnell MB, Miller FA. Objective evaluation of blunt cardiac trauma. *J Trauma* 1986; 26: 510–520.
9. Fulda G, Brathwaite CEM, Rodriguez A, et al. Blunt traumatic rupture of the heart and pericardium: a ten year experience (1979–1989). *J Trauma* 1991; 31: 167–173.
10. Godwin JD, Tolentino CS. Thoracic cardiovascular trauma. *J Thorac Imaging* 1987; 2: 32–44.
11. Guest TM, Ramanathan AV, Tuteur PG, et al. Myocardial injury in critically ill patients: a frequently unrecognized complication. *JAMA* 1995; 273: 1945–1949.
12. Jones JW, Hewitt RL, Drapanas T. Cardiac contusion: a capricious syndrome. *Ann Surg* 1975; 181: 567–574.
13. Maron BJ, Pollac LC, Kaplan JA, et al. Blunt impact to the chest leading to sudden death from cardiac arrest during sports activities. *N Engl J Med* 1995; 333: 337–342.
14. Mason LB, Warshauer SE, Williams RW. Stab wounds of the heart with delayed hemopericardium. *J Thorac Surg* 1958; 29: 524–527.
15. Mattox KL, Flint LM, Carrico CJ, et al. Blunt cardiac injury (formerly termed “myocardial contusion”). *J Trauma* 1992; 33: 649–650.
16. Mayor-Davies JA, D’Egidio A, Schein M. ‘Missed stabbed hearts’—pitfalls in the diagnosis of penetrating cardiac injuries. Report of 4 cases. *S Afr J Surg* 1992; 30: 18–19.
17. Moreno C, Moore EE, Majure JA, Hopeman AR. Pericardial tamponade. A critical determinant for survival following penetrating cardiac wounds. *J Trauma* 1986; 26: 821–825.
18. Oraliague G, Jacquens Y, Riou B, et al. Combined severe myocardial and pulmonary contusion: early diagnosis with transesophageal echocardiography and management with high frequency jet ventilation: Case report. *J Trauma* 1993; 34: 455–457.
19. Parmley LF, Manion WC, Mattingly TW. Nonpenetrating traumatic injury of the heart. *Circulation* 1958; 18: 371–396.
20. Rhee PM, Foy H, Kaufmann C, et al. Penetrating cardiac injuries: A population-based study. *J Trauma* 1998; 45: 366–370.
21. RuDusky BM. Cardiac troponins in the diagnosis of myocardial contusion. *Chest* 1996; 109: 1413–1414.
22. Sugg WL, Rea WJ, Ecker RR, et al. Penetrating wounds of the heart: an analysis of 459 cases. *J Thorac Cardiovasc Surg* 1968; 56: 531–545.
23. Tenzer ML. The spectrum of myocardial contusion: a review. *J Trauma* 1985; 25: 620–627.
24. Wilson RF, Basset JS. Penetrating wounds of the pericardium or its contents. *JAMA* 1966; 195: 513–518.

Submitted September 1, 1998; submitted after revision February 2, 1999; accepted March 11, 1999

Address for correspondence:

Moheb A. Rashid, M.D.
Trebackegatan 11
SE-416 74 Gothenburg
Sweden

V



ELSEVIER

Interactive Cardiovascular and Thoracic Surgery 2 (2003) 53–57

INTERACTIVE
CARDIOVASCULAR AND
THORACIC SURGERY

www.icvts.org

Institutional review – Cardiac general

Trauma to the heart and thoracic aorta: the Copenhagen experience

Moheb A. Rashid*, Jens T. Lund

Department of Cardiothoracic Surgery, Copenhagen University Hospital (Rigshospitalet), Copenhagen, Denmark

Received 9 August 2002; received in revised form 4 November 2002; accepted 7 November 2002

Abstract

Injuries of the heart and thoracic aorta (traumatic aortic rupture, TAR) remain amongst the most challenging of all injuries seen in the field of trauma and cardiothoracic surgery. The aim herein was to present our experience of such lethal injuries treated at Denmark's busiest hospital. We found 11 patients with cardiac injuries and nine patients with TAR. Five patients with cardiac injuries presented in shock of which two died. Eight patients with TAR were operated on using bypass without paraplegia. The Danish experience of heart trauma is limited but with satisfactory results. We recommend left heart bypass to prevent paraplegia in TAR.

© 2002 Elsevier Science B.V. All rights reserved.

Keywords: Cardiac and aortic injuries; Urgent thoracotomy and sternotomy; Left heart bypass; Paraplegia; Mortality

1. Introduction

The Egyptians were the first to describe medicine in general and trauma to the heart and aorta in particular as shown in the *Edwin Smith* surgical Papyrus written by the Egyptian *Imhotep* more than 5000 years ago [1]. The heart since that time has inspired many talented poets, writers and musicians not only in Egypt but all over the world. Patients with trauma to the heart often require immediate surgical intervention, excellent surgical technique and well performed postoperative care. Traumatic transection of the thoracic aorta also requires a meticulous way of assessment and management, because its diagnosis is difficult, its mortality is high, and its morbidity is tragic particularly when trauma victims are mostly below the age of 40. Paraplegia is a dreaded complication, which is related to the bad protection of the spinal cord during management, and the situation can be a medicolegal problem to the surgeon and a tragedy to the young patient. Currently, most knowledge involving injuries of the heart and thoracic aorta comes from American studies [2,3] or South African series [4,5] due to the increased violence in these societies compared with Europe. This issue is yet to be defined in Scandinavian countries, therefore we performed this study to find out if we could characterize such injuries in Denmark's busiest medical center (Rigshospitalet) in Copenhagen and to present our experience with such lethal injuries.

2. Patients and methods

We found 19 patients with heart or thoracic aortic injuries; one had both cardiac and aortic lesions. Cardiac injuries were found between May 1995 and June 2001, while aortic injuries were found between March 1996 and August 2000. There were 11 patients with cardiac injuries, of whom three were iatrogenic. Of the remaining eight patients (mean age 37 years, range 16–63 years) four had penetrating injuries, and four had blunt injuries. Of nine patients with thoracic aortic injuries, one was iatrogenic. The remaining eight patients (mean age 50 years, range 31–69 years) were meticulously analyzed. We collected the following data: mechanism of injury, age, sex, clinical presentation, risk factors, methods of investigations, surgical techniques, associated lesions, morbidity, mortality and follow-up. The injury severity score (ISS) was calculated for all patients.

3. Results

3.1. Cardiac injuries

The mechanism of injury was a knife stabbing wound in penetrating injuries of the heart ($n = 4$), motor vehicular crash (MVC) in three, and door edge in one. Fifty percent of patients had alcohol and/or drug misuse and suicide as risk factors. The time between wounding and arrival at the hospital was minimal and recorded as immediately in six patients while it took 43 and 45 min in two other patients. All five patients with penetrating or ruptured cardiac injuries

* Corresponding author. Hagforsgatan 71, 416 75 Gothenburg, Sweden. Tel.: +46-31-256985; fax: +46-707-691067.

E-mail address: moheb_rashid@hotmail.com (M.A. Rashid).

Table 1
Surgical procedures for patients with cardiac penetration or rupture^a

Case	Surgical procedures	Outcome
1	Emergency room thoracotomy – cardiorrhaphy – right-sided pulmonary hilar cross-clamping – pneumorrhaphy	Died during surgery from exsanguination
2	Urgent posterolateral thoracotomy – cardiorrhaphy – reconstruction of TAR with CPB and circulatory arrest	Died 4 days postoperatively from CNS lesions
3	Urgent sternotomy – cardiorrhaphy	Survived (steel wire irritation)
4	Urgent sternotomy – cardiorrhaphy	Survived (psychological disturbances)
5	Urgent sternotomy – cardiorrhaphy	Survived (cardiac ischemic changes)

^a CNS, central nervous system; CPB, cardiopulmonary bypass; TAR, traumatic aortic rupture.

presented with one or more components of Beck's triad [6]. The ISS average was 19 (range 9–42). The penetrating wounds involved the right ventricle and left ventricle ($n = 2$ each). A blunt rupture of the right atrium was found in one case and myocardial contusion in three. Patients with cardiac penetration or rupture ($n = 5$) presented in shock and underwent urgent surgery (Table 1). The three patients with blunt cardiac injury had ST/T wave changes, arrhythmias and raised creatine kinase isoenzyme. The average length of hospital stay in the intensive care unit (ICU) was 2 days (range 1–5 days), and in the ward 3 days (range 2–16 days). In all patients with penetrating or ruptured cardiac injuries ($n = 5$) there was hemothorax (two right, two left, and one bilateral), and all had pericardial tamponade. The mortality among patients with cardiac and aortic injuries is shown in Table 2.

3.2. Aortic injuries

The mechanism of injury was MVC in all patients ($n = 8$) with traumatic aortic rupture (TAR). The time between wounding and arrival at the hospital was minimal and recorded as immediately in six cases while it took 37 and 45 min in two other cases. All patients with aortic lesions were operated on between 2 and 24 h following trauma, and the tear was found in the classic position 'isthmus' of the descending thoracic aorta. Seven patients were operated on using left heart bypass with the BioMedicus pump (Medtronic Inc., Minneapolis, MN) (left atrial to descending aorta in six and left atrial to left femoral in one) and one patient was put on cardiopulmonary bypass because of respiratory insufficiency due to bilateral severe pulmonary contusions. The average ischemic time was 21 min (range 13–52 min). A Hemashield graft (Meadox; Boston Scientific Corp., Oakland, NJ) was inserted in seven patients and one was sutured directly. One patient had postoperative renal failure, but no incidence of paraplegia or cardiac failure. The average length of hospital stay in the ICU was 2 days (range 2–4 days), and in the ward 6 days (range 8–15 days). Only one patient died due to cerebral damage 4 days after successful aortic repair, and his death was not directly related to the repair. The diagnostic methods used in the detection of TAR are shown in Table 3. The iatrogenic cardiovascular injuries are presented in Table 4.

4. Discussion

4. Discussion

4.1. Cardiac injuries

In this study, alcohol or drug abuse and suicide were significant risk factors and there were no gunshot wounds in this discrete number of patients who reached the hospital alive with such injuries. This is consistent with the Swedish experience of heart trauma [7,8]. All patients with penetrating or ruptured cardiac injuries presented with one or more components of Beck's triad [6] consisting of distended neck veins, muffled heart sounds and hypotension. This was the classic clinical presentation of pericardial tamponade that was confirmed at surgery. Pericardial tamponade in this

Table 2
Mortality among patients with cardiac injuries (the second patient had combined cardiac and aortic lesions)

Age (years)	Sex	ISS	Time of death	Cause
30	M	25	During surgery	Exsanguination
39	M	42	4 days after surgery	CNS damage

Table 3
The diagnostic tools used in the detection of aortic lesions^a

	CXR (%)	CT (%)	TEE (%)	Angiography (%)
Normal	2/8 (25)	0	1/7 (14)	0
Suspicious	6/8 (75)	3/6 (50)	0	0
Diagnostic	0	3/6 (50)	6/7 (86)	4/4 (100)

^a CT, computed tomography; CXR, chest radiographs; TEE, transesophageal echocardiography.

Table 4
Patients with iatrogenic cardiovascular injuries (three cardiac and one aortic)^a

Case	Mechanism	Diagnosis	Treatment	Outcome
1	Pacemaker insertion, perforation RA	During surgery for CABG with OPCAB	Direct suture	Survived
2	Pacemaker insertion, perforation RA	During surgery for CABG	Direct suture	Survived
3	Pacemaker insertion, perforation RA	During surgery for CABG	Direct suture	Survived
4	Nailing of the DTA during spinal surgery	Manifest bleeding day 5 after surgery	Bypass (aortic-femoral)	Survived, reconstruction of FAL

^a CABG, coronary artery bypass grafting; DTA, distal thoracic aorta; FAL, femoral artery lesion; OPCAB, off-pump coronary artery bypass; RA, right atrium.

series showed both good and bad effects and acted as a double-sword. In patients with blunt cardiac injuries, echocardiography has also shown several limitations being difficult to perform in a badly-positioned patient with chest wall tenderness, the presence of hemothorax and/or pneumothorax adds more difficulties with poor quality, and this probably adds nothing as a screening test in such patients [9]. Similarly, our results showed no advantage of echocardiography and the clinical picture was consistent with tamponade, which was confirmed during surgery. We have recently observed that echocardiography was not helpful in patients with cardiac injuries and it gave false negative results in one patient who had tamponade clinically and proven at surgery [7]. In the present study, this may be explained by the fact that all patients with penetrating or ruptured cardiac injuries had pleural breach with hemothorax. One patient had bilateral pleural breach and died from exsanguination. Consistent with other reports [4,7], we consider that pleural breach with hemothorax is a risk factor for death in patients with penetrating or ruptured cardiac injuries. The incidence of myocardial contusion was small (3/8) due to the difficulty in the diagnosis of such an entity that is sometimes indistinguishable from associated injuries in patients with multitrauma as shown in this study and previous series [7,8]. We had two patients who died and the cause of death was not directly related to the cardiac or aortic repair (Table 2). Of those who died, there was one patient who underwent an emergency room thoracotomy because of abrupt severe hypotension in the emergency room and died from intractable bleeding during surgery, particularly from the injured right pulmonary hilum. Our data reflect the Danish experience of heart trauma: there were few cases, alcohol and drug misuse and suicide are the principal risk factors, and there were no cases with commotio cordis or gunshot wounds.

4.2. Aortic injuries

TAR is the second most common cause of death in blunt trauma patients [3]. A South African report [5] has estimated that the average number of patients with TAR per trauma center per year was 2.6 (range 0.2–10.7) in a twenty-

year metaanalysis study and found only 1742 patients who reached the hospital alive. The diagnosis of TAR is not an easy task. In this study, we found that the chest radiographs (CXR) gave an early clue to the suspicion of TAR in 6/8 (75%) cases, and the widened mediastinum was the most frequently cited CXR finding that triggered further work-up. Most CXR in cases with blunt chest trauma may show evidence of mediastinal abnormalities leading to aortography according to the Advanced Trauma Life Support protocols of the American College of Surgeons. These radiographs are often performed in bad conditions in a typical multitrauma patient with injuries caused by MVC. Although CXR are useful and may lead to the proper method of reaching the diagnosis of TAR as clearly shown in this study, a critical and careful examination of these radiographs is important. Recently, we proposed a schedule for a better selection of patients going to aortography in the multitrauma setting with some mediastinal abnormalities. This schedule definitely spares many unnecessary transports and angiographies, and is thereby cost-effective [8]. Angiography is a very sensitive, specific and accurate test for the diagnosis of TAR, and it is still the 'gold standard' of diagnosis [10]. We performed angiography in four patients and showed TAR in all of them (Table 3). TAR is rarely a single lesion and the surgeon must decide without delay which comes first, thoracotomy, laparotomy or craniotomy. Rare causes of hemodynamic instability such as pelvic or femur fractures should be assessed first before going to aortography and repair of TAR [11]. If the patient has more immediately life-threatening injuries that require urgent intervention, or if the patient is a poor operative candidate because of comorbidities or age, the repair of TAR may be delayed. However, we recently found that urgent thoracotomy is mandatory in salvaging unstable patients with penetrating thoracic trauma, without evidence of injury to cardiac, aortic or other major vascular structures [12]. To determine the optimal time for surgical repair, medical treatment or stenting is dependent on many factors, particularly age, comorbidities, associated injuries and hemodynamic stability. In cases with delayed surgical intervention, it is extremely important to control blood pressure with beta-blockers or nitroprusside [13], but it is not easy at

all to maintain an optimal blood pressure (not too high and not too low) in such patients who mostly are in hypovolemic shock. Furthermore, minimal invasive therapy is an evolving technology in the management of TAR. Since the publication of the first report describing the initial experience with endovascular stent-grafting (ESG) for abdominal aortic aneurysms in 1991, a number of cases with TAR have been treated and showed successful outcome [14]. By sealing the rupture initially with ESG hypotensive therapy is not necessary following insertion of stents which may act as a bridging therapy for patients with TAR waiting for a definitive surgical repair. On the other hand, ESG has serious complications such as endoleakage and migration and is not easily available in appropriate sizes. We have not tried this feasible therapy in the present study. However, prompt surgical repair of the TAR is the best approach [3]. There is considerable controversy surrounding the details of techniques of aortic repair. These techniques include both primary repair and placement of a prosthetic graft. In our study, direct suture was performed only in one patient and the ischemic time was 13 min. Many surgeons support the clamp and sew technique because it is expeditious, does not require bypass, and avoids complications associated with cannulation, bypass, and heparinization. However, a prospective multicenter trial [3] of TAR involving 50 busy trauma centers in North America has shown a mortality rate of 34% and a paraplegia rate of 10%. The mortality rate was not affected by the method of repair. This trial reported that bypass techniques that provide distal aortic perfusion produce significantly lowered paraplegia rates (4.5%) compared with the clamp and sew technique (16.4%). This is supported by a recent study [15]. Such a beneficial effect was clearly seen in our series where paraplegia was avoided. We, like others [3,5,15], recommend that repair of TAR surgically is best accomplished with some method of distal perfusion, and find that left heart bypass is an excellent method to prevent paraplegia in the management of patients with TAR. Despite our limited experience, which is characteristic for Scandinavian and European countries, our results were satisfactory.

References

- [1] Breasted JH. The Edwin Smith surgical Papyrus, 1. Chicago, IL: University of Chicago Press, 1930. p. 369.
- [2] Mandal AK, Sanusi M. Penetrating chest wounds: 24 years experience. *World J Surg* 2001;25:1145–1149.
- [3] Fabian TC, Richardson JD, Croce MA, Smith Jr. JS, Rodman Jr. G, Kearney PA, Flynn W, Ney AL, Cone JB, Luchette FA, Wisner DH, Scholten DJ, Beaver BL, Conn AK, Coscia R, Hoyt DB, Morris Jr. JA, Harviel JD, Peitzman AB, Bynoe RP, Diamond DL, Wall M, Gates JD, Asensio JA, Enderson BL, et al. Prospective study of blunt aortic injury: Multicenter Trial of the American Association for the Surgery of Trauma. *J Trauma* 1997;42:374–380.
- [4] Campbell NC, Thomson SR, Muckart DJ, Meumann CM, Van Middelkoop I, Botha JB. Review of 1198 cases of penetrating cardiac trauma. *Br J Surg* 1997;84:1737–1740.
- [5] Von Oppell UO, Dunne TT, De Groot MK, Zilla P. Traumatic aortic rupture: twenty-year metaanalysis of mortality and risk of paraplegia. *Ann Thorac Surg* 1994;58:585–593.
- [6] Beck CS. Two cardiac compression triads. *J Am Med Assoc* 1935;104:714–716.
- [7] Rashid MA, Wikström T, Örténwall P. Cardiac injuries: a ten-year experience. *Eur J Surg* 2000;166:22–28.
- [8] Rashid MA, Örténwall P, Wikström T. Cardiovascular injuries associated with sternal fractures. *Eur J Surg* 2001;167:243–248.
- [9] Nagy KK, Krosner SM, Roberts RR, Joseph KT, Smith RF, Barret J. Determining which patients require evaluation for blunt cardiac injury following blunt chest trauma. *World J Surg* 2001;25:108–111.
- [10] Sturm JT, Hankins DG, Young G. Thoracic aortography following blunt chest trauma. *Am J Emerg Med* 1990;8:92–96.
- [11] Richardson JD, Wilson ME, Miller FB. The widened mediastinum: diagnostic and therapeutic priorities. *Ann Thorac Surg* 1990;211:731–737.
- [12] Rashid MA, Wikström T, Örténwall P. Thoracic vascular injuries: a major problem in trauma. *Scand Cardiovasc J* 2001;35:285–287.
- [13] Fabian TC, Davis KA, Gavant ML, Croce MA, Melton SM, Patton Jr. JH, Haan CK, Weiman DS, Pate JW. Prospective study of blunt aortic injury: helical CT is diagnostic and antihypertensive therapy reduces rupture. *Ann Surg* 1998;227:666–677.
- [14] Lachat M, Pfammatter T, Witzke H, Bernard E, Wolfensberger U, Kunzli A, Turina M. Acute traumatic aortic rupture: early stent-graft repair. *Eur J Cardiothorac Surg* 2002;21:959–963.
- [15] Jahromi AS, Kazemi K, Safar HA, Doobay B, Cina CS. Traumatic rupture of the thoracic aorta: cohort study and systematic review. *J Vasc Surg* 2001;34:1029–1034.

Appendix A. ICVTS on-line discussion

Author: Dr. Kenneth Mattox, Chief of Surgery, Ben Taub General Hospital, Surgery, One Baylor Plaza, Houston, Texas 77030, USA

Date: 04-Dec-2002 18:41

Message: Injury to the heart and great vessels is not limited to countries with interpersonal violence. As demonstrated by this paper, standardized and comparable results can be achieved through general agreement on standards of practice among the surgeons of the world (would that politics would be as standardizable). Of note in this article is a departure from the use of the thoracic CT scan as an initial screening and even diagnostic tool for thoracic aortic injury in many centers. These authors conform to this commentator's opinion that the CT scan does not alter decision making, but in most cases, merely leads to additional testing, at increased costs and time. In the future, increasing delay in operative therapy will be applied to "stable" patients with thoracic aortic injury and there will be increasing utility for intravascular stented grafts.

Response

Author: Moheb Rashid, Copenhagen University Hospital "Rigshospitalet", Cardiothoracic Surgery, Hagforsgatan 71, Gothenburg, 416 75, Sweden

Date: 12-Jan-2003 14:47

Message: Thank you very much for your interest in our study and we are pleased with your positive and kind comments. As you mentioned, CT scan does not alter decision making in patients with trauma to the thoracic aorta, this is true even in this part of the world, which enjoys less violence when compared with Texas. Recently, we have already started to transfer our 'stable' patients with suspected thoracic aortic injury to the catheterization laboratory equipped with endovascular stented grafts, restricted to some major university hospitals in Scandinavian countries.

Author: *Professor Angelo Pierangeli, University of Bologna, Cardiovascular Surgery, Policlinico S.Orsola, Via Massarenti, 9, Bologna, 40138, Italy*

Date: 16-Jan-2003 12:41

Message: In the present paper the authors describe their experience in traumatic lesions of the heart and the thoracic aorta, the presentation of the

heart lesions is exhaustive. They reported a very limited experience in traumatic aorta treatment. In my opinion, their conclusions about management of these types of lesions are correct. I disagree with their diagnostic approach. The statement that angiography is a very sensitive, specific and accurate test is not supported by recent literature. Spiral CT and also MRI are much more sensitive than angiography (100% HCT and MRI vs 80-90% of angiography) in identifying TAR. In particular, HCT provides a comprehensive evaluation of polytrauma and should be considered the method of choice in TAR. Moreover, the angiography can increase the risks of fatal complications.

