

**Your Dermatology Pocket Guide:
Common skin conditions explained**



Your Dermatology Pocket Guide:
Common skin conditions explained

Authors:

Janice Bianchi

Independent Medical Education Specialist

Barbara Page, MBE

Dermatology Liaison Nurse Specialist,
NHS Fife

Sheila Robertson

Dermatology Liaison Nurse Specialist,
NHS Fife

© **NES 2014**

First Published June 2011

NESD0235



01	The structure and function of the skin	3
02	Taking a history	11
03	Examining the skin and describing lesions	17
04	Common skin conditions in adults	29
	Acne	31
	Cellulitis	35
	Psoriasis	37
	Shingles (herpes zoster)	40
	Skin cancers	42
	Vasculitis	49
05	Common skin conditions in children	51
	Chicken pox (Varicella)	53
	Eczema (atopic)	55
	Henoch-Schönlein purpura	57
	Impetigo	59
	Impetiginised eczema	61
	Miliaria	63
	Measles	65
	Molluscum Contagiosum	67
	Napkin dermatitis (nappy rash)	69
	Rubella (German measles)	71
06	Common skin conditions in both adults & children	73
	Bites (insect)	75
	Common Warts	77
	Eczema herpeticum	79
	Pruritus	81
	Urticaria (acute)	83
	Scabies	85
07	Practical advice on topical treatments	89
08	Glossary	97
09	Resources	105

////////////////////////////////////

This booklet can be used by any clinician who wishes to develop their knowledge of common skin conditions. It has been specifically written for nurse practitioners, specialist nurses, physicians or any other clinicians who undertake structured histories using advanced decision-making skills. It will aid in diagnosis - recognising differential diagnosis, formulating prescriptions and assisting in identifying referral pathways if necessary.

The booklet is divided into three parts.

Part 1

Part 1 (sections 01-03) starts with a review of the structure and functions of the skin, then takes the practitioner through history taking and describing the characteristics of the presenting skin condition.

Part 2


In part 2 (sections 04-06), we provide information on the more common skin conditions, including clinical images, diagnosis and suggested treatment*. There is also advice on practical aspects of coping with the presenting condition for the patient, parent or carer. Finally, there is guidance on when specialist referral is indicated.

Part 3

In part 3 (sections 07-09) you will find practical advice on emollient and steroid therapy, a glossary of terms, useful websites and a list of reference books for further reading.

The aim of this booklet is to assist the clinician in managing most of the common dermatological conditions they are likely to encounter in their clinical practice.

* To prescribe the correct dose of suggested treatments, please refer to British National Formulary (www.BNF.org) or British National Formulary for Children (www.BNFC.org)





Section 01

The structure and function of the skin







It is essential to have some background knowledge on the normal structure and function of any organ before you consider abnormalities.

The skin is often referred to as the largest body organ and serves as the main protective barrier against damage to internal tissues from trauma, ultraviolet light, temperature, toxins and bacteria. The skin is also responsible for sensory perception, temperature regulation, production of vitamin D and excretion of waste products. In addition to preventing harmful substances from entering the body, it also controls the loss of vital substances from the body. It is therefore important that the skin remains intact to allow the body to perform these essential functions.

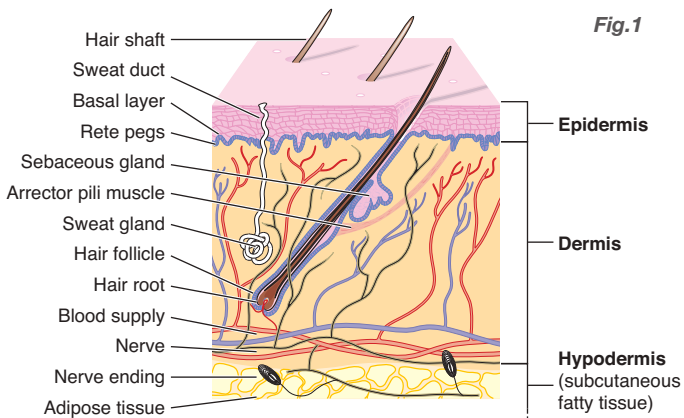
The skin contains a number of accessory organs which assist in its protective role. As we can see in **Fig. 1**, it consists of two main layers: the epidermis, or outer layer, and the dermis, which lies beneath the epidermis.

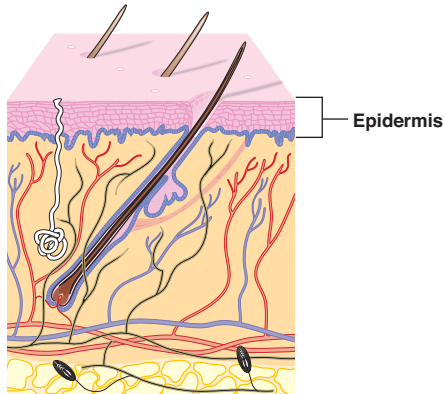
The structure and function of the skin

06

The thickness of the skin varies depending on the site, with thicker skin being present on areas of the body that experience friction or wear and tear, such as the soles of the feet and palms of the hand.

The skin is supported by a layer of fatty tissue, sometimes known as the hypodermis. This fatty area helps to act as a cushion to protect the body and is also important for insulation.





The epidermis

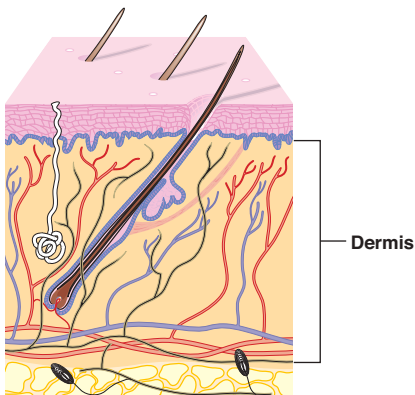
The epidermis (outer layer) contains no blood vessels and is divided into five layers. Cells move from the base of the epidermis up to the surface, changing shape and structure as they go. The epidermis is made up of stratified squamous epithelium or hardened cells which play a role in the skin's protective function. This is referred to as the stratum corneum.

Epidermal cells line the hair follicles, sebaceous glands and sweat glands.

A number of projections which reach down from the epidermis to the dermis can be found at the point at which they join. These are called rete pegs, which help to maintain skin integrity when the skin is under stress.

Melanocytes are cells found in the deepest layer of the epidermis. They produce melanin, which helps protect the body from the sun's harmful rays.

The structure and function of the skin



The dermis

The main function of the dermis is to provide physical support and nutrients to the epidermis. The two layers identified within the dermis are the papillary layer and the reticular layer. Key substances found in the dermis include elastin, fibrillin and collagen (which helps give support and protection), all of which will decrease with age.

The dermis also contains nerve endings, sweat glands, sebaceous glands, hair follicles and blood vessels. The papillary dermis contains smaller blood vessels which supply oxygen, elastic fibres and nutrients to the lower epidermis.

The nerve endings sense pain, touch, temperature and pressure and are a vital part of the body's protective mechanisms. There are more nerve endings in certain parts of the body, such as the fingertips and toes.

The structure and function of the skin

09

Sweat glands produce sweat, which contains some body waste products, water and salt. Evaporating sweat causes cooling of the body. Sweat from the axilla and groin areas (apocrine glands) is more oily in nature and produces a characteristic odour when digested by the skin bacteria.

Sebaceous glands secrete sebum into hair follicles. Sebum is an oily substance that keeps the skin moist and acts as a barrier against foreign substances.

Hair follicles produce the various hair types that can be found around the body, so can affect a person's appearance. Hair is also involved in protecting the body from injury and can improve sensation.

The blood vessels within the dermis are involved in temperature regulation.

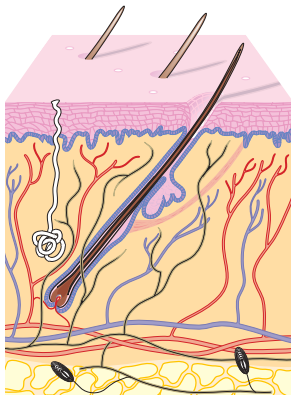
The thicker reticular dermis contains dense connective tissue, larger blood vessels, elastic fibres and bundles of collagen arranged in layers.

Also within the reticular layer are the following key cell types:

- **fibroblasts** – a key cell involved in repairing tissue damage
- **mast cells** – which are involved in fighting infection
- **lymphatic vessels** – the lymphatic system is a key part of the body's defence against infection
- **epidermal appendages or rete pegs** – as explained above, the epidermis and dermis are linked in this way to prevent skin damage
- **ground substance** – a gel-like substance that helps to support the cells within the dermis and provides structure to the area.

The structure and function of the skin

10



Hypodermis
(subcutaneous
fatty tissue)

The hypodermis

The hypodermis provides support for the dermis and is made up largely of fatty and connective tissue. It is essential for protection of internal structures and also provides insulation.



Section 02

Taking a history







The diagnosis of skin disease begins with taking a history. This is followed by careful physical examination. If at this stage a diagnosis has not been made, further examinations should be carried out.

The following information is needed to make a correct diagnosis.

✓ **Past medical history**

Conditions which may be associated with skin disease include diabetes, cancer, renal/liver disease and immunodeficiency.

✓ **History of presenting condition**

How long has the lesion(s) been present? This is the most important question in the history. Acute lesions presenting for less than two weeks need to be distinguished from those that are chronic.

Taking a history

Do the lesions come and go?

Do they occur at the same sites or different sites? This is important if a diagnosis of urticaria or herpes simplex is being considered.

Was the lesion caused by trauma/insect bite?

Is there any associated discharge or odour?

Has the patient travelled abroad recently?

✓ Relationship to physical agents

A past history of living or working in a hot climate may be the clue you need to diagnose skin cancer.

Sun exposure is often indicated by a rash on the face or back of the hands. **The important question here is the time interval after sun exposure until the rash appears.** In solar urticaria, the rash appears within five minutes of sun exposure and is gone within an hour; in polymorphic light eruption, the rash occurs several hours after sun exposure and lasts several days.

Ask about irritants on the skin if the patient has hand eczema.

Common irritants include detergents, oils and some solutions that are found in the workplace (hairdressers, dental workers).

Are the hands in direct contact with irritants?

What makes the skin condition better?

What makes the skin condition worse?

What treatment has been used to date (medical, herbal and over the counter (OTC))?

✓ Pruritus (Itching)

Pruritus (itchy skin) is the single most common symptom of many inflammatory skin conditions (see section 06 for Pruritus). Dry skin itself is itchy and requires management with emollient therapies. While itching is distressing to the patient, it may not help you reach a diagnosis.

Excoriation (scratch marks) on the skin provide evidence of pruritus. Severe itch, especially at night, may be caused by scabies (see section 06 for Scabies). Management of pruritus is an essential component of overall management of the skin condition.

✓ Past, family and social history

Past history: *Has the patient had the rash before and, if so, was it the same as now?*

If eczema is present, a history of infantile eczema, asthma or hayfever may suggest a diagnosis of atopic eczema.

Family history: *Does anyone else in the family have a skin condition? Is it the same as the patient's?*

This will indicate that either the skin disease is genetically determined (e.g., atopic eczema, psoriasis, ichthyosis) or contagious (e.g. scabies or impetigo).

Social history/hobbies/occupation/recent travel to foreign country: *For instance, does hand dermatitis get better at the weekend, or on holiday?*

Hobbies may indicate contact with irritant products or chemicals, etc. Travel to a warm climate may expose the person to tropical infection.

Taking a history

16

////////////////////////////////////



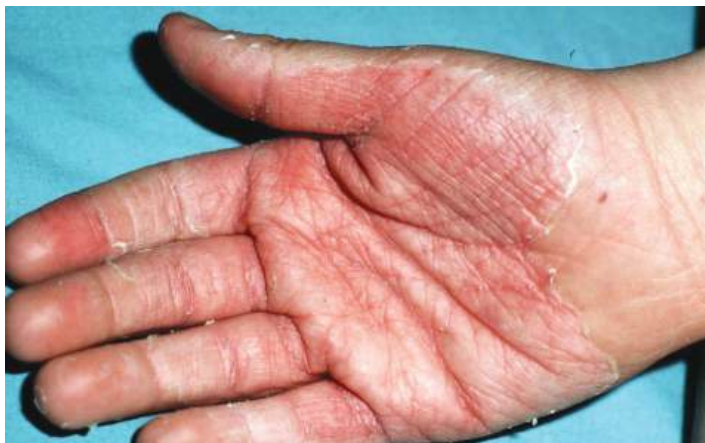A horizontal dashed line consisting of small, evenly spaced rectangular dashes, spanning the width of the page.

Section 03

Examining the skin and describing lesions







This chapter aims to take you through the different stages of examining the skin.

The entire skin surface, as well as hair, nails and mucosal surfaces, should be examined. In order to carry out the examination, you may require the patient to undress down to underwear. If the patient has a widespread rash, it may seem obvious to them that you have to examine their skin in its entirety. They may however question the need for a full skin examination if they present with an isolated lesion. There may be other lesions the patient has not seen, perhaps on the back or buttocks. It is important to explain this to the patient without alarming them.

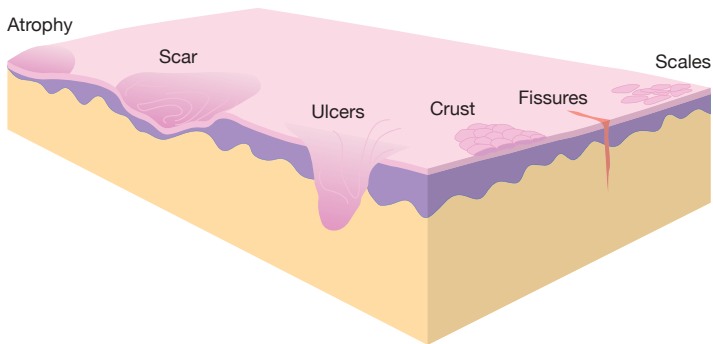
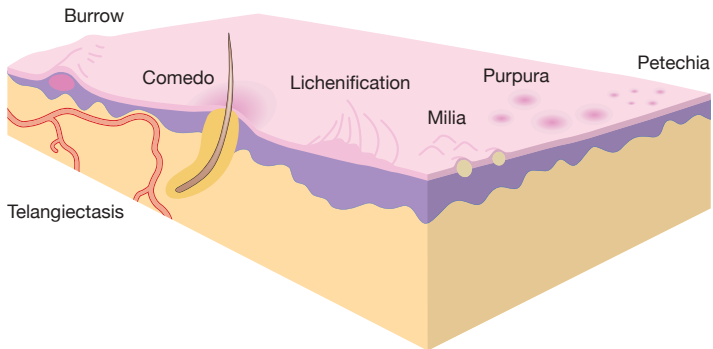
A gown or blanket should be available. The room should be warm with good lighting. An additional light source and magnifying lens are also useful.

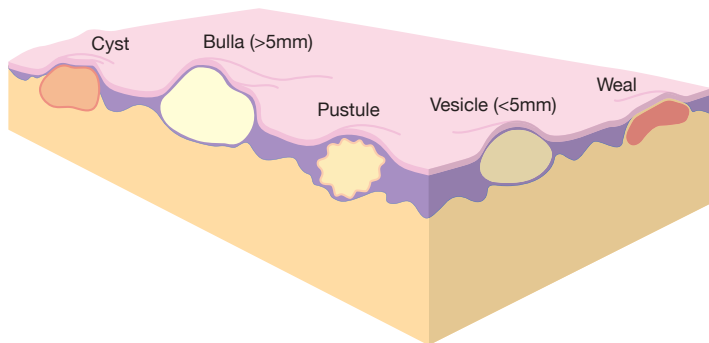
It is important to be aware of, and sensitive to, cultural and religious differences, and a chaperone may be required in some circumstances.

Examining the skin and describing lesions

20

Common presentations of skin lesions





To make an accurate diagnosis, skin examination should follow a pattern. It is important to carry out the following.

🔍 Describing a lesion

Note the distribution and colour of lesions. Are they:

- localised (e.g. a tumour)?
- widespread (e.g. a rash)?
- if widespread, is it symmetrical and, if so, central or peripheral?
- does it involve the flexures (e.g. atopic eczema)?
- does it involve the extensor aspects (e.g. psoriasis)?
- is it limited to sun-exposed sites?
- is it linear?
- is it regional (e.g. groin or axilla)?
- does it follow a dermatomal (corresponding to root nerve distribution) pattern (e.g. shingles)?

Examining the skin and describing lesions

22

🔍 Examine the morphology

Examine the morphology (form and structure) of individual lesions. A magnifying lens is helpful. Consider:

- size
- shape (e.g. linear, grouped, annular, koebner phenomenon (an inflammatory skin response at the site of previous trauma))
- border change (e.g. pearly edge, rolled edge)
- depth – are lesions dermal or epidermal?
- is it macular (flat) or forming papules?
- is it fluid filled – serous fluid or pus?
- is it indurated (hardened) or forming plaques?
- is it forming crusts, scabs, vesicles: if scaly, does surface flake off easily; if crusted, what is underneath?
- spatial relationship (see below).

Spatial relationship

Solitary	single lesion
Satellite	a single lesion in close proximity to a larger group
Grouped	cluster of lesions
Generalised	total body area
Localised	limited area of involvement which is clearly defined

🔍 Palpate

Palpate to check consistency. This should be done by compressing the lesion between the finger and thumb (in widespread rashes, this may not be necessary):

- soft lesions are easily compressed
- firm lesions can only just be compressed
- hard lesions cannot be compressed
- is it raised?
- is it irregular?
- what is the texture?

🔍 Describe colour

If the lesion is non-erythematous, describe changes in colour:

- pink, red, purple, mauve – due to blood
- brown, black, blue – due to pigment
- white – due to lack of blood/pigment
- yellow, orange – lipids or bilirubin.

🔍 Other considerations

These would include:

- is there sensitivity to touch – pain, tingling or itch?
- is there odour, which may be indicative of infection?
- is the affected skin hot or cold to the touch, compared to another area of the skin which is not involved – infection/inflammation should be a consideration.

🔍 Examine nails etc.

Examine and assess nails, hair, scalp, and mucous membranes:

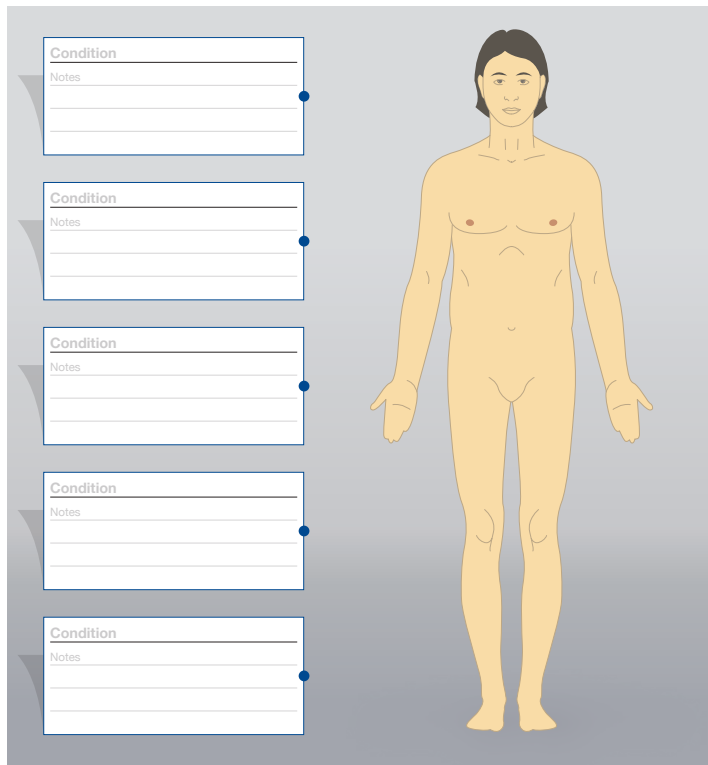
- nails – observe colour and shape, check capillary return, look for pigment changes or longitudinal lines
- hair and scalp – check for scale, erythema, hair loss
- mucous membranes – blistering, erosions, scarring.

Examining the skin and describing lesions

24


🔍 Body map

Everything you see should be recorded on a body map (example below).



The diagram shows a full-body illustration of a female figure. To the left of the figure are five identical data entry boxes, each with a blue dot on its right side. Each box is divided into two sections: 'Condition' and 'Notes'. The 'Condition' section has a horizontal line for text entry. The 'Notes' section has three horizontal lines for text entry.

Condition	Notes
Condition	Notes
Condition	Notes
Condition	Notes
Condition	Notes



Condition _____
Notes _____

Condition _____
Notes _____

Condition _____
Notes _____

Condition _____
Notes _____

Condition _____
Notes _____

You can download copies of the body map at:
www.nhsfife.scot.nhs.uk/bodymaps

Examining the skin and describing lesions

26

🔍 Investigations

The investigations listed below are regularly carried out in dermatology departments. Some, such as skin biopsy, may not be available in your clinical setting. If your assessment indicates that more specialised investigations are required, refer the patient to a dermatology department.

- **Swab for bacterial investigations** – ensure swab tip is moistened, roll swab in a zig-zag motion rotating between fingers.
- **Swab for viral investigations** – pierce vesicle and swab fluid inside.
- **Mycology for fungal or yeast infection investigations** – skin scrapings, nail clippings, hair debris.
- **Common blood tests** performed in dermatology (below).

Test	Pruritus	Atopic eczema	Alopecia	Urticaria	Erythroderma
FBC	🔍	🔍	🔍	🔍	🔍
Albumin					🔍
U&E	🔍			🔍	🔍
ESR	🔍			🔍	🔍
IgE		🔍			
LFT	🔍			🔍	🔍
Thyroxine TSH	🔍		🔍	🔍	
Ferritin	🔍		🔍		🔍
Antinuclear factor			🔍	🔍	

- **Photography.**
- **Woods lamp** – identifies bacterial or yeast infections.
- **Diagnostic biopsy** – to help confirm histological changes.

A general physical examination including height, weight, temperature and cardiovascular/respiratory assessment may also be required if indicated by symptoms or clinical signs.

Key points

- Examine the entire surface area including scalp, axillae, groin and finger/toe webs.
- Good lighting and a hand lens are important.
- Use a systematic approach to assessment: describe the lesion(s) and their distribution, examine morphology, palpate the lesion(s), note any change in colour.
- Note changes or abnormalities in nails, hair and mucous membranes.
- Carry out relevant investigations or refer to dermatology if more specialised investigations are required.

Examining the skin and describing lesions

28

////////////////////////////////////



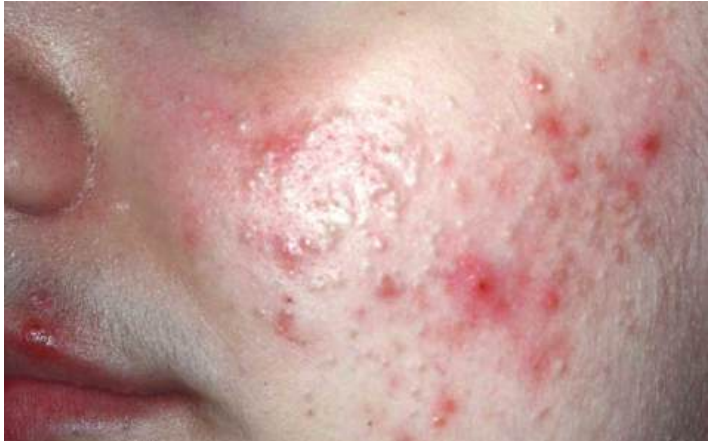A horizontal dashed line consisting of small, evenly spaced rectangular dashes, located near the top of the page.

Section 04

Common skin conditions in adults







© Acne

Acne is a disorder of the pilosebaceous unit which may present with comedones, inflammatory papules or pustules. Nodules and scarring can also occur. The precursor lesion of all acne lesions is the microcomedone which, under the influence of androgens, develops into non-inflammatory lesions (comedones) and inflammatory lesions (papules and pustules). Lesions of acne vary considerably with time, but in acne vulgaris comedones are always present and are a diagnostic sign. Most patients notice a fluctuation in the number and severity of spots. In young women, this is often related to the menstrual cycle.

Common skin conditions in adults

32

🕒 Approximate age group

The first problems are usually encountered in adolescence. In girls, this may be as early as 10 years. In both sexes, incidence peaks at 13–16 years, although it may continue into the 40s. Exceptions to this are:

- infantile/juvenile acne, typically seen in infants and children at 3–12 months: lesions usually subside after 4–5 years, but adolescence often heralds a severe aggravation
- late-onset acne, where first signs develop in the 20s: this is more commonly seen in women and often has a marked premenstrual exacerbation; there will be endocrine involvement, such as polycystic ovary syndrome, in some individuals.

🕒 Presentation

Acne occurs on the face, chest and back depending on the distribution of sebaceous follicles in the individual.

Type of lesion

Non-inflammatory lesions:

- **open comedones** (blackheads)
- **closed comedones** (whiteheads).

Inflammatory lesions:

- **Papules and pustules** – the majority of patients with comedonal acne develop papules and pustules. They are the well known little red spots or pustules on a red base. They may be itchy or quite painful. Papules develop rapidly over a few hours and frequently become pustular as they evolve. They generally resolve over a few days.
- **Nodules and cysts** – as the inflammation within the pilosebaceous unit progresses and extends deeper into the dermis, the size of visible and palpable lesions increases, resulting in deep-seated nodules.

Secondary lesions:

- **Scars** - the inflammatory process of acne can cause scarring. Characteristically, small, deep “ice-pick” scars occur, but more severe disease will leave gross changes with atrophy or keloid formation.
- **Individual lesions** usually last less than two weeks but deeper papules may persist for months. The average “acne life” is 12 years.

Treatment

Treatment depends on severity (consider the possibility of scarring).

Comedonal acne – topical agents such as: Adapalene; Benzoyl Peroxide; Isotretinoin; Tretinoin.

Acne with inflammatory lesions and comedones, topical agents such as: Benzoyl Peroxide; antibiotics (erythromycin, tetracycline, clindamycin); Adapalene; Azelaic acid.

Application of topical agents – the aim is to cleanse, moisturise and treat. Before going to bed, the patient should cleanse the skin with soap and water or medicated wash then apply the weakest strength of topical agent. The strength may be built up gradually. If the skin becomes sore, stop the treatment for a few days then restart on alternate nights. This allows the patient to adapt to the treatment and any irritation quickly resolves. If the skin feels dry in the morning, apply a non-greasy moisturiser.

In moderate to severe acne or unresponsive acne, systemic treatments are usually required in combination with topical treatments. These include antibiotics, anti-androgens and systemic retinoids. Referral to GP or dermatologist is indicated.

Common skin conditions in adults

34

+ Advice to patient

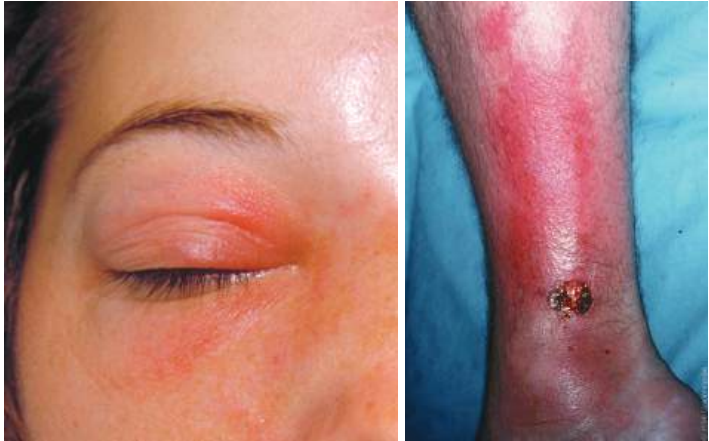Squeezing comedones should be avoided as it can convert comedone to an inflammatory lesion or papule and increases the potential for scarring.

There is no evidence that diet influences acne and it is not caused by over indulgence in chocolate or “junk food”.

⚠ Traffic light

Systemic symptoms (acne fulminans) – this rare condition is almost always seen in young men. Symptoms include severe nodulocystic acne accompanied by fever, malaise and joint pain and swelling.

Psychological impact – the condition generally involves people in their teens and twenties, a time when the psychological impact may be profound (note that the psychological impact is not always related to the degree of severity).



📍 Cellulitis

This is an infection of the subcutaneous tissues most commonly caused by a group A, C or β -haemolytic streptococcus. It usually affects a lower limb but can occur anywhere on the body.

👤 Approximate age group

More common in older people but can be seen in all age groups.

📋 Presentation

There is usually an obvious portal of entry for the organism such as a leg ulcer, tinea pedis between the toes (athlete's foot), eczema on the feet or legs or an insect bite. The area will be erythematous and oedematous with localised pain and restricted mobility. Blisters may be present with areas of skin necrosis. The patient may also have systemic symptoms such as fever, malaise, chills or possibly rigors.

Common skin conditions in adults

36

Treatment

Penicillin-based antibiotics are the treatment of choice (such as benzyl penicillin or flucloxacillin). Oral erythromycin can be used for patients who are allergic to penicillin. If you have local guidelines on the management of common bacterial skin infections, their recommendations should be taken into consideration when prescribing treatment for cellulitis. Most patients can be treated at home but intravenous antibiotics, which may require the patient to be admitted to hospital, may be required if there are signs of systemic illness or extensive cellulitis. The co-existing condition that allowed entry of bacteria into the skin should be treated.

Paracetamol may be prescribed for pain.

Advice to patient

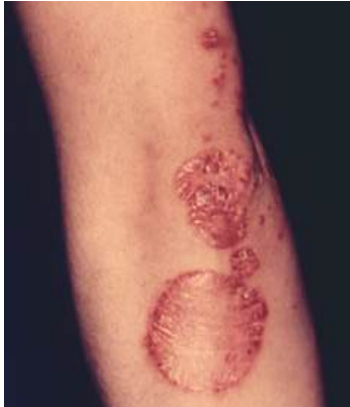After successful treatment, the skin may peel or flake off as it heals (post-inflammatory desquamation).

Traffic light

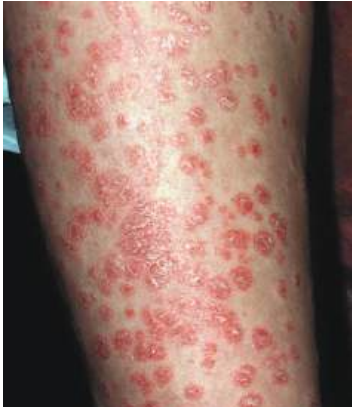If the infection is slow to settle, check that the patient does not have diabetes or is immune-deficient as he or she may require hospital admission.

Cellulitis and allergic irritant contact dermatitis can look similar, particularly on the lower leg. If the patient is wearing compression garments and the condition is bilateral, it is more likely to be an allergic irritant contact dermatitis.

It may be helpful to use a demarcation line to assess whether cellulitis is extending.



Chronic plaque psoriasis



Guttate psoriasis

🕒 Psoriasis

Psoriasis is a common disease which affects about 3% of the population. Psoriasis typically waxes and wanes with periods of relapse and remission. It is probably linked to several genes so occurrence within families varies. It may be precipitated by hormonal changes, infection such as a streptococcal throat infection or trauma. Medications and emotional stress can also be a trigger. There are several different forms of psoriasis. Here we describe two of the more common presentations: **chronic plaque psoriasis** and **guttate or small plaque psoriasis**.

🕒 Approximate age group

It can occur at any age but often begins between the ages of 15 and 25 years.

Common skin conditions in adults

38

Presentation

Chronic plaque psoriasis

The lesions are bright red with clearly defined edges and a silvery scale. The scale will flake off easily. The lesions tend to be symmetrical, commonly affecting the scalp, elbows, knees, sacral area and lower legs. The appearance will be quite different if flexural areas such as axillae, groins, sub-mammary or natal cleft are affected, presenting as smooth and non-keratotic with a shiny glazed appearance. This mainly affects older patients but can also present in children. Note that fungal or bacterial infection may also be present in flexural areas.

The genitals, palms, soles and nails may also be affected in some individuals.

Most patients have a few stable plaques but psoriasis can become unstable and extensive. A small proportion of patients will have joint involvement (psoriatic arthropathy).

Guttate/small plaque psoriasis

This is an acute form of psoriasis which appears suddenly, often after a streptococcal throat infection. The lesions are typical of psoriasis – bright red, well demarcated with silvery scale – but are uniformly small (0.5–1.0cm in diameter). The rash can be very widespread. It often resolves spontaneously in about 2–3 months. It may be the first episode of psoriasis for the patient but it can occur in someone who has had psoriasis for years.

Treatment

The majority of individuals with psoriasis can be treated with topical treatments.

Chronic plaque psoriasis: treatment depends on the type, size and number of lesions. Topical treatments include: emollient, vitamin D analogues or vitamin D analogue in combination with a potent topical steroid; tar preparations; salicylic acid ointments; dithranol.

If the patient has extensive psoriasis, more specialised treatment with phototherapy, systemic treatments and some of the more potent topical treatments is usually administered in dermatology departments.

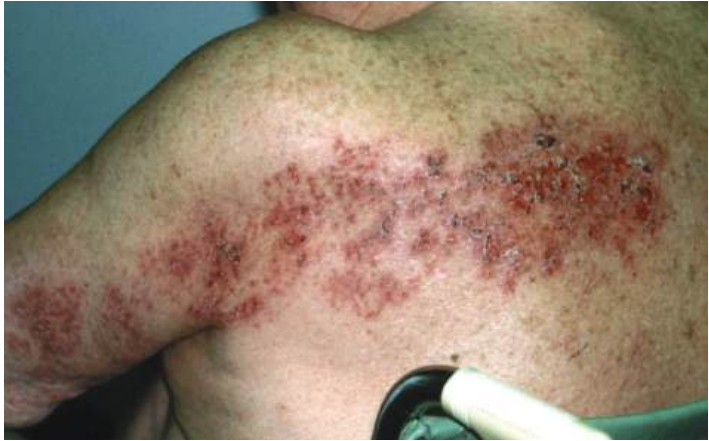Guttate psoriasis: as the condition usually resolves spontaneously, reassurance is all that is needed. Complete emollient therapy (see section 07) is useful if the skin is itchy or a mild topical steroid or weak tar solution may be indicated to give symptomatic relief. In some cases, ultra violet light treatment may be necessary: this would be administered in a dermatology department.

Traffic light

If more than 30% of the body surface area is affected by chronic plaque psoriasis, referral to dermatology should be considered.

Erythrodermic psoriasis, where the entire skin surface is inflamed, must be referred to secondary care.

Generalised pustular psoriasis is an acute form of the disease which develops rapidly and may be associated with withdrawal of systemic or potent topical steroids. Sheets of erythema studded with sterile pustules come in waves, with an associated fever or malaise. This is a dermatological emergency and patients should be admitted to hospital.



📍 Shingles (herpes zoster)

Shingles occurs in people who have previously had chickenpox. The virus lies dormant in the dorsal root ganglion; when reactivated, it travels down the cutaneous nerves to infect the epidermal cells.

👤 Approximate age group

Can occur at any age.

📋 Presentation

There is pain, tenderness or an abnormal sensation in the skin for several days before the rash appears. The rash will form groups of small vesicles on an erythematous background, followed by weeping and crusting. The rash is usually unilateral with dermatomal distribution and a sharp cut off at or near the midline. This feature and associated pain makes any other

diagnosis unlikely. The pain often continues until healing occurs but may go on for months or even years in older people (post-herpetic neuralgia).

👉 Treatment

If the patient is seen in the prodromal phase with pain or abnormal sensation, or within 48 hours of the blisters appearing, treat with a 7-day course of an oral antiviral agents such as Aciclovir, Valaciclovir or Famciclovir.

Antiviral agents are only effective when the virus is replicating and should only be given in the early phase of the disease (within 48 hours of the rash appearing).

Adequate analgesia is important, such as paracetamol 1g every 4 hours or co-proxamol 2 tablets 4 hourly. In older people, prophylactic low dose amitriptyline at night, gradually increasing to 75mg, may help post-herpetic neuralgia if started as soon as the rash appears.

+ Advice to patient

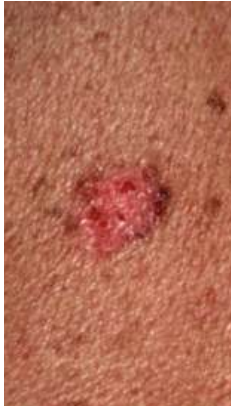Reassure the patient that shingles cannot be caught, but chickenpox can be contracted from a patient with shingles by someone who has never had chickenpox.

🚦 Traffic light

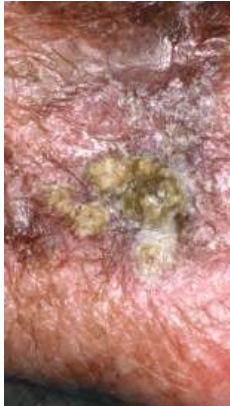If there is ophthalmic involvement, rapid referral to ophthalmology is required to minimise potential complications of shingles involvement of the eye.

Common skin conditions in adults

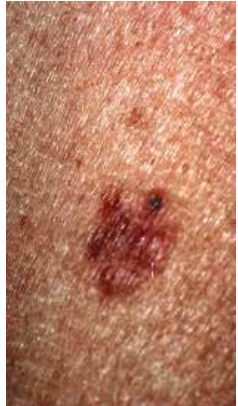42



BCC



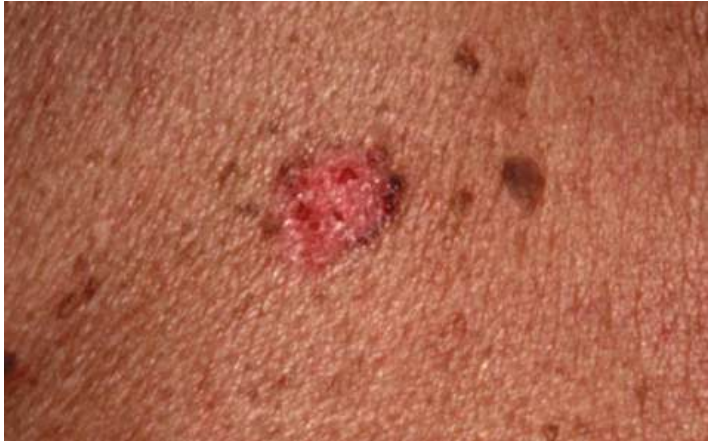SCC



Malignant melanoma

© Skin cancers

Excessive exposure to ultraviolet radiation is linked to non-melanoma type skin cancers and malignant melanoma. Early recognition is most important. A good rule of thumb is to seek medical advice about all lesions which are not healing and may be enlarging. Here we describe the two most common forms of skin cancer and malignant melanoma. Biopsy is usually performed to assess the lesion histologically.



© Basal cell carcinoma (BCC, rodent ulcer)

This is the commonest skin cancer. It usually occurs in fair-skinned people who have worked or had hobbies out of doors. Although due to sun damage, BCC does not occur at the sites of maximum sun exposure (it rarely appears on bald scalps, the lower lip or dorsum of the hand). Most occur on the face, with some on the trunk and limbs. Metastatic spread is rare in BCC.

🕒 Approximate age group

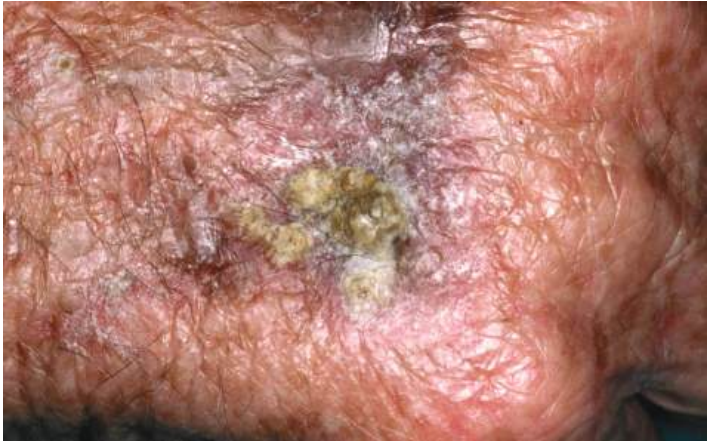
Middle age or older.

Common skin conditions in adults

44

Presentation

BCC commonly starts as a small translucent (pearly) papule with telangiectasia over the surface. It slowly increases in size and, over time, the centre may ulcerate and crust (rodent ulcer). On examination, if you stretch the skin you will see a raised rolled edge like a piece of string sitting around the edge.



© Squamous cell carcinoma (SCC)

Although less common than BCC, SCC is an invasive carcinoma which is faster growing than a BCC and may metastasise if left untreated. It can arise from previously normal skin or from a pre-existing lesion (such as Bowen's disease and actinic keratosis). SCC occur on sun-exposed skin which shows signs of sun damage. Common sites include bald scalp, lower lip, cheeks, nose, top of ear lobes and dorsum of the hand. They can also appear on non sun-exposed sites such as a site of previous radiotherapy or chronic scarring of burns and leg ulcers.

🕒 Approximate age group

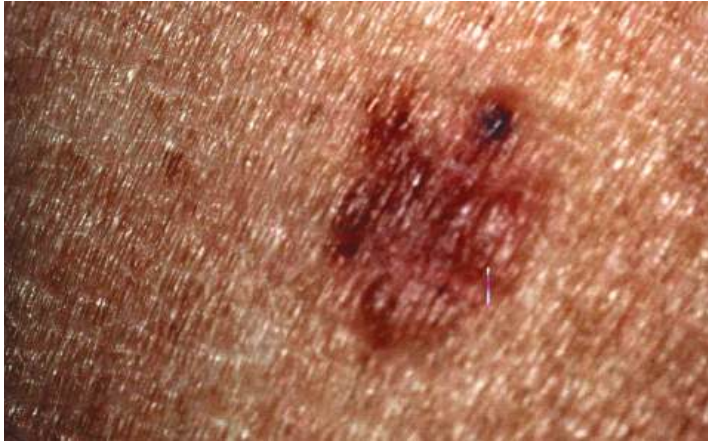Middle age or older.

Common skin conditions in adults

46

Presentation

A hard nodule of indurated skin which may have increased in size quite rapidly and may have ulcerated. Lesions bleed easily. Well-differentiated tumours produce keratin, so the surface will be scaly or even horny and are often painful to touch.



© Malignant melanoma

A malignant melanoma is a malignant tumour of the pigment-producing cells (melanocytes). Two thirds arise from normal skin and one third from a pre-existing mole. Numbers are increasing. It is the most dangerous of the skin cancers as it has the capability to metastasise through the lymphatic and circulatory systems.

🕒 Approximate age group

All age groups, particularly in those with fair or red hair who burn rather than tan in the sun.

Common skin conditions in adults

48

Presentation

New moles developing or change in appearance; bleeding or crusting; increase in size; irregular outline; irregular pigmentation; pain or itch. Early diagnosis is important. If the lesion is superficial (that is, it has not invaded downwards into the dermis), excision is more likely to result in cure. The check lists below have been developed to help with early diagnosis.

The American **ABCDE** list

- A**symmetrical
- B**order irregular
- C**olour irregular
- D**iameter over 1cm
- E**rythema

The **Glasgow** list

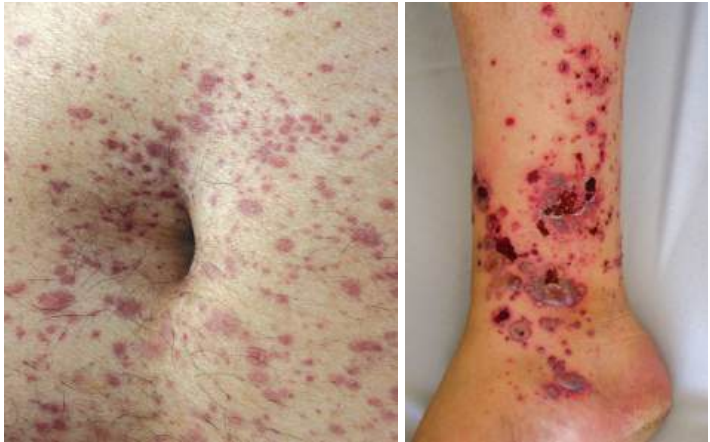Major features (**score 2 points**)

- 2 points.** Change in size (diameter)
- 2 points.** Change or irregular shape
- 2 points.** Change or irregular colour

Minor features (**score 1 point**)

- 1 point.** Diameter more than 6mm
- 1 point.** Inflammation
- 1 point.** Oozing or bleeding
- 1 point.** Mild itch or altered sensation

Suspect melanoma if any major feature is present or there is a total score of 2.



© Vasculitis

Vasculitis is an inflammation of the blood vessels in the skin, usually due to the deposit of immune complexes in the walls of the vessels.

🕒 Approximate age group

Affects all age groups.

📍 Presentation

The presentation will differ depending on the size and site of vessels involved. If the capillaries are involved, there will be a polymorphic rash with palpable purpura, as well as macules, papules, vesicles and pustules. If there is arterial involvement, livedo reticularis, nodules and ulceration of the lower leg may be present. Where there is arterial and venous involvement, there will be red, tender nodules or deep plaques in the subcutaneous fat.

Common skin conditions in adults

50

Vasculitis has numerous causes, including:

- infection (e.g. streptococcal infection)
- collagen vascular disease (e.g. systemic lupus erythematosus (SLE), rheumatoid, systemic sclerosis)
- plasma protein abnormalities
- drugs (e.g. allopurinol, barbiturates, carbimazole, thiazide diuretics)
- idiopathic (no cause found).

👉 Treatment

Identification of the underlying cause and treating this is the aim. Urinalysis will help identify if there is renal involvement. If urinalysis identifies protein or blood in the urine, specialist help should be sought as the patient may require systemic steroids or cyclophosphamide. Treatment is symptomatic (e.g. analgesia for pain).

Where no cause can be found (idiopathic), the patient should be reassured that the condition is self limiting and should resolve within 3–6 weeks.

✚ Advice to patient

Bed rest will stop new lesions forming. Regular analgesia should be taken for pain.

🚦 Traffic light

Henoch-Schönlein purpura is a form of vasculitis and occurs mainly in the young (see section 05).

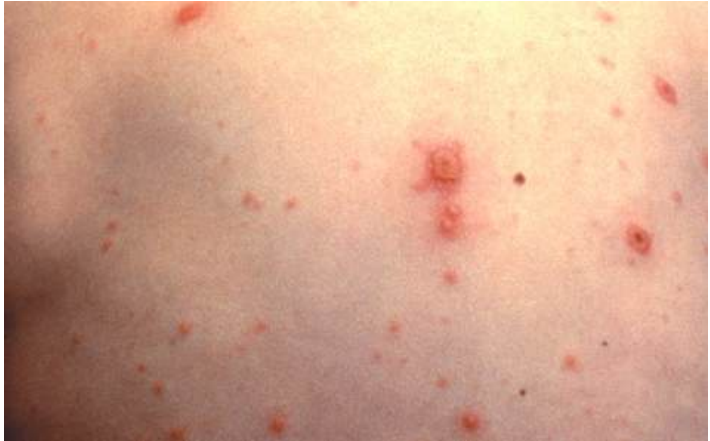

Section 05

Common skin conditions in children







© Chickenpox (Varicella)

Varicella zoster virus causes chickenpox and shingles (see section 04 for shingles).

🕒 Approximate age group

Chickenpox commonly occurs in childhood. By the age of 10 years most children, particularly in urban communities, will have been infected. Primary infection confers long-term immunity but the virus remains dormant in the dorsal root ganglion to be reactivated as shingles.

Common skin conditions in children

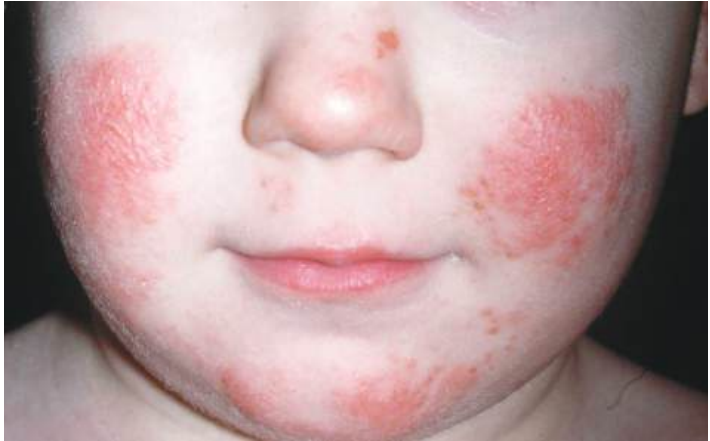54

Presentation

The incubation period is 13–17 days. The patient may be feverish before developing a rash which will start with pink macules. These quickly develop into papules, tense vesicles, pustules then crusts. The condition is communicable from five days before the rash develops until around six days after. The spots can be very itchy and secondary infection may lead to pock-like scarring.

Treatment

In most cases, chickenpox does not require treatment. However, an antiseptic-based emollient may reduce the risk of secondary infection. In adults or immunocompromised patients, aciclovir, valaciclovir or famciclovir will reduce the severity of the attack. An antiviral agent is not usually required for healthy children.



🎯 Eczema (atopic)

Atopy means an inherited predisposition to eczema, asthma or hay fever and atopic individuals may have one or all of these conditions.

🕒 Approximate age group

Eczema usually begins between 3 and 12 months. The condition tends to be long term, but it will clear by puberty in 90% of individuals.

🔥 Presentation

In an acute reaction, the skin displays the signs of inflammation: heat, erythema and swelling. Pain is not usually present but itching is severe. The skin lesions are not sharply demarcated but merge with the surrounding skin. There may be vesicles or bullae which rupture with oozing of clear fluid. The lesions may be localised, particularly to the flexures, or widespread.

Common skin conditions in children

56

In Asian or Afro-Caribbean skin, lesions are more commonly seen on the extensor surfaces.

Treatment

To treat effectively consider the following:

- complete emollient therapy (see section 07)
- for eczematous lesions, treat with topical steroid (see section 07)
- if the itch is disturbing sleep, consider a sedative antihistamine
- if there is infection, refer to impetiginised eczema (see this section).

Advice to parent/carer

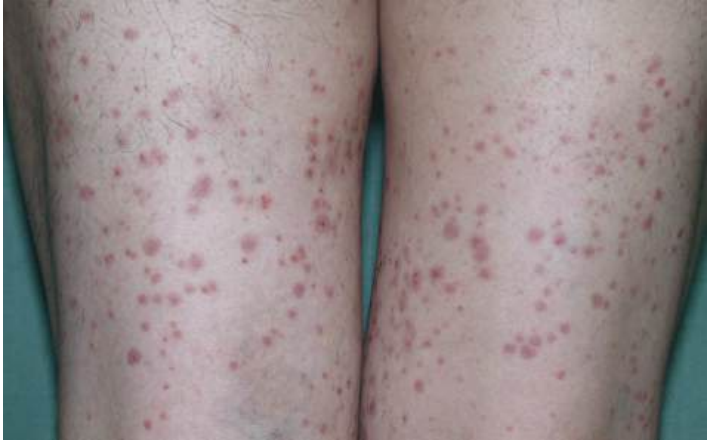Cotton clothing worn next to the skin is comfortable. Cotton gloves may help prevent damage from scratching.

Local dermatology nurses and dermatology departments will help with education, support and long-term management.

The National Eczema Society, British Association of Dermatologists and the Primary Care Dermatology Society can also provide useful written information.

Traffic light

Secondary infection can rapidly worsen. See impetiginised eczema (this section) and eczema herpeticum (section 06).



© Henoch-Schönlein purpura

This is a form of vasculitis (inflammation of the small blood vessels) in the skin and various other tissues in the body. It may also be referred to as anaphylactoid purpura. The precise cause is unknown. Three-quarters of cases are preceded by an upper respiratory tract infection, mostly caused by β haemolytic streptococci. Several other associations have been reported including drugs, food and various infections.

🕒 Approximate age group

Mainly seen in children under the age of 10 years, with a slight male predominance. It may also occur in adults.

Common skin conditions in children

58

Presentation

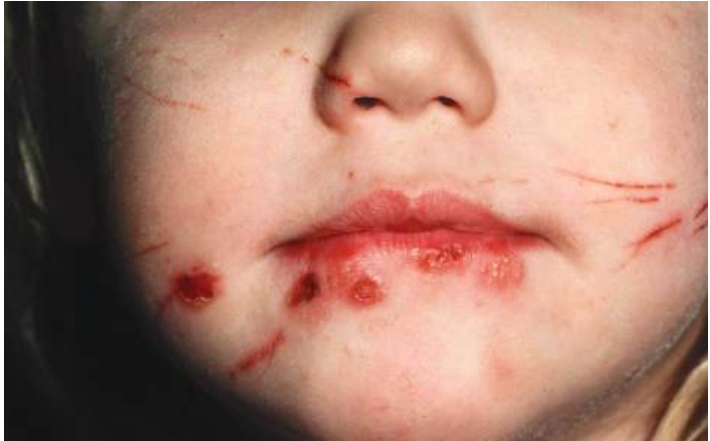The rash consists of erythematous and purpuric macules and papules together with vesicles and pustules. It should be considered in any child with purpura and a normal platelet count. It may follow a streptococcal throat infection. There may be associated arthralgia and abdominal pain. There may also be renal involvement.

Treatment

If it follows a streptococcal infection, treat with phenoxymethyl penicillin. Otherwise, bed rest will stop new lesions occurring and most cases will get better in 3–6 weeks. Paracetamol syrup will help with joint and abdominal pain.

Traffic light

Renal involvement should be considered. Proteinuria and microscopic haematuria without impaired renal function will normally get better spontaneously in less than four weeks. If acute nephritis or progressive renal failure occurs, the patient should be referred to a renal physician.



🕒 Impetigo

A superficial infection of the epidermis caused by *Staphylococcus aureus*, a group A beta-haemolytic streptococcus or a mixture of both. Entrance is gained through broken skin such as cuts and grazes. The condition is highly contagious.

🕒 Approximate age group

Childhood.

🕒 Presentation

Typically starts as vesicles which rapidly break down to form honey-coloured crusts; less commonly, there may be just a glazed erythema. Sites usually involved are the face and neck but it can spread extensively over the body.

Common skin conditions in children

60

👉 Treatment

Impetigo can be a self-limiting condition but antimicrobials are usually prescribed to hasten a clinical cure and to interrupt spread to other areas.

Topical antibiotics (e.g. fusidic acid) are as effective as systemic antibiotics, but where there is concern about fusidic acid resistance, topical 1% hydrogen peroxide cream is an alternative.

If there is a thick crust, this can be removed by applying oil for 20 minutes. This will soften crusting so it can be gently removed. Once the crust has been removed, apply the topical treatment to the affected area, ensuring that the treatment is applied to the nares at the same time.

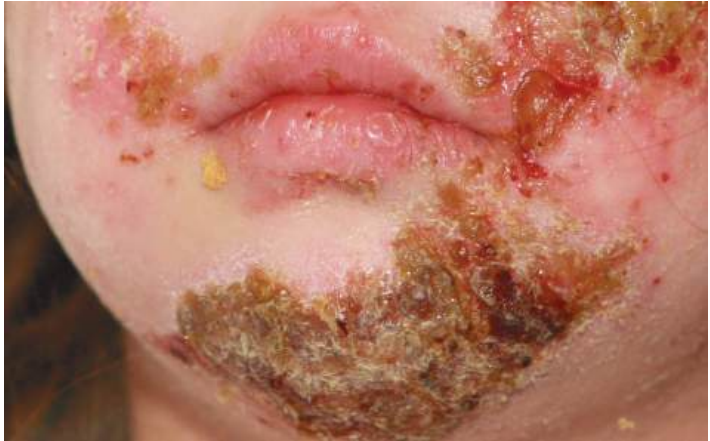If the patient has widespread lesions or impetiginised eczema, systemic antibiotics, such as flucloxacillin or erythromycin if allergic to penicillin, are advised.

+ Advice to parent/carer

Encourage good basic hygiene practices to limit contact and spread of the condition: this includes advice to avoid sharing towels and facecloths and encouraging good handwashing technique after contact. As scratching may spread the lesions, keeping the nails short is advisable.

🚦 Traffic light

Impetigo can occur as a secondary infection in excoriated skin such as in eczema, impetiginised eczema and scabies (see section 06).



🕒 Impetiginised eczema

Secondary infection, most commonly with *Staphylococcus aureus* or streptococcal isolates, can occur in the broken skin caused by scratching in atopic eczema.

🕒 Approximate age group

Childhood.

🕒 Presentation

It is important to establish if the patient has a history of atopic eczema. The diagnosis is made by the history of the preceding erythema and rash. The skin may be weeping with papules and crusts and be rapidly worsening despite using standard treatment for eczema.

Common skin conditions in children

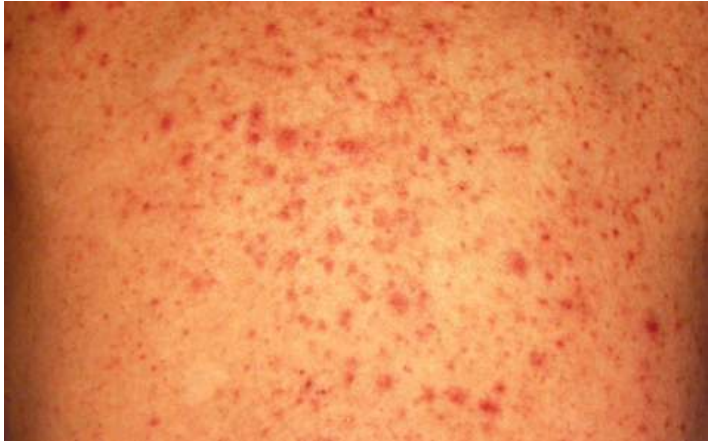62

👉 Treatment

Topical antibiotics should not be prescribed as the patient may be self medicating on an ad hoc basis, promoting antibiotic resistance.

Localised areas may be treated with either a topical antiseptic (e.g. 1% hydrogen peroxide cream or chlorhexidine) or a topical antiseptic combined with a corticosteroid. If the lesions are widespread, treat with oral anti staphylococcal antibiotics such as flucloxacillin or clarithromycin.

Consider skin swab if non responsive.



📍 Miliaria

Miliaria (sweat rash) arises from obstruction of the sweat glands. It is most commonly found in hot, humid conditions.

👶 Approximate age group

Common in infancy, but may occur at any age.

🔥 Presentation

Typically, folliculitis develops in the skin folds and on the body, especially in areas of friction from clothing. In infants, lesions commonly appear on the neck, groins and axillae but can also appear on the face and elsewhere. In contrast to acne and other forms of folliculitis, miliaria spots do not arise around hair follicles.

Common skin conditions in children

64

Miliaria crystalline is caused by obstruction of the sweat ducts and appears as tiny superficial clear blisters.

Miliaria rubra (prickly heat) occurs deeper in the epidermis and results in itchy red plaques.

Miliaria profunda results from sweat leaking into the dermis causing deep, intense, uncomfortable, prickling red lumps.

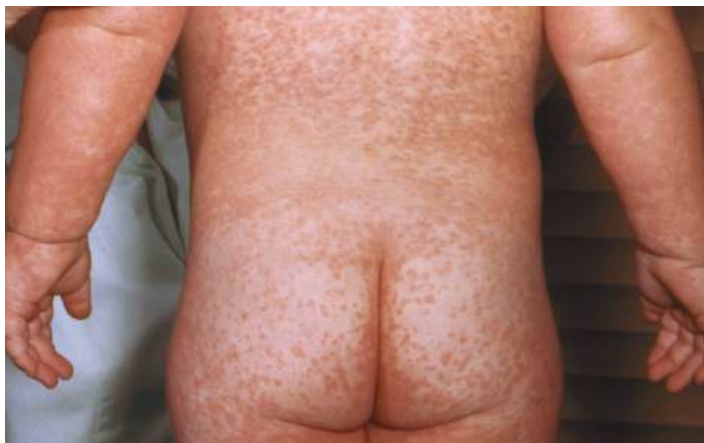Miliaria pustulosa describes pustules due to inflammation and bacterial infection.

👉 Treatment

Antiseptics can reduce bacterial growth. Mild topical steroids (see section 07) can give reasonable symptomatic relief.

+ Advice to parent/carer

- avoid excess heat which predisposes to the condition
- cotton clothing or breathable fabrics should be worn
- cool water compresses will soothe inflamed areas.



© Measles

Measles is a highly contagious disease caused by the RNA morbillivirus. Immunisation can prevent measles but the disease is becoming more common with reduced uptake of vaccination.

🕒 Approximate age group

Childhood.

Common skin conditions in children

66

Presentation

After an incubation period of around 10 days, the child becomes miserable with symptoms similar to a common cold, including: a high fever; runny nose; conjunctivitis; photophobia; brassy cough; and inflamed tonsils. Koplik spots on the buccal mucosa are diagnostic at this stage (these look like grains of salt on a red base). Around day 4, a red macular rash will appear behind the ears and spread to the face, trunk and limbs. The macules may become papules which join together and become confluent. It lasts up to 10 days and leaves brown staining and some scaling.

Treatment

Treatment is symptomatic as affected children get better spontaneously. Bed rest is advisable if the child is sick and pyrexia can be treated with paracetamol elixir.

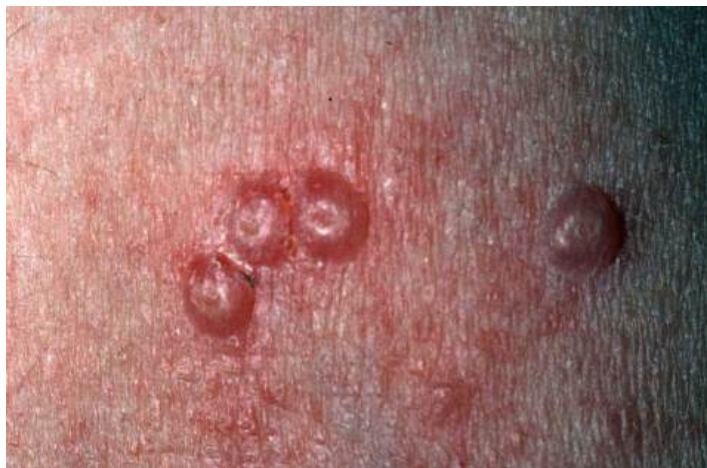Advice to parent/carer

Adequate fluid intake to avoid dehydration.

Traffic light

Individuals at risk of severe measles and its complications include:

- malnourished individuals
- those with underlying immune deficiency
- pregnant women.



© Molluscum Contagiosum

This is a common and harmless pox virus infection of the skin. Molluscum contagiosum can be spread from person to person (especially children) by direct skin contact. This appears to be more likely in wet conditions, such as when children bathe, swim together or share towels.

🕒 Approximate age group

This condition commonly affects infants and young children but adults can also be infected.

Common skin conditions in children

68

Presentation

Small 1-5mm white, pink or brown umbilicated papules. They often have a waxy, pinkish look. The lesions can be found anywhere on the skin but often occur in moist places such as armpit, groin or behind the knees. There may only be a few or multiple lesions. As they resolve they may become inflamed or red in colour and crusted. They last for months or occasionally a couple of years. It frequently induces dermatitis in the infected area with lesions becoming dry, pink and itchy. An itchy rash may also appear on distant sites as the body mounts an immunological reaction to the virus.

Treatment

There is no single treatment for molluscum contagiosum and, as it is self-limiting, in many no specific medical treatment is necessary and the papules will disappear spontaneously.

If a secondary infection occurs, treat with a topical antiseptic (e.g. 1% hydrogen peroxide cream) or antiseptic washes.

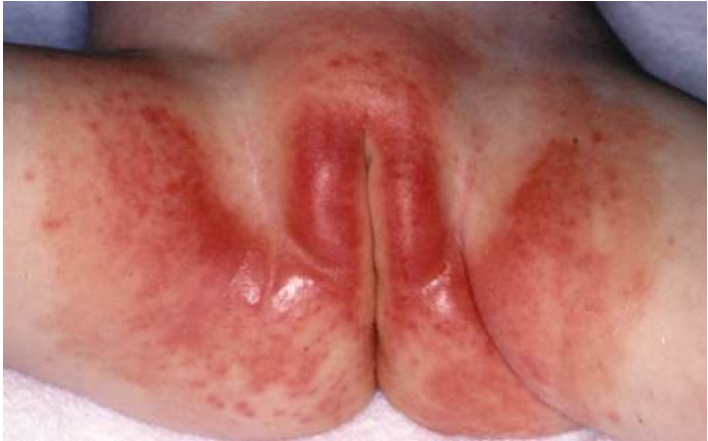Advice to parent/carer

Highlight that as the papules disappear, they may occasionally leave tiny pit-like scars.

Traffic light

The lesions tend to be more numerous and last longer in children who also have atopic eczema. Local dermatology nurses can help with education and support.





📍 Napkin dermatitis (nappy rash)

The common type of nappy rash is an irritant contact dermatitis, caused by urine and faeces being held next to the skin under occlusion. Bacteria in the faeces break down the urea in the urine into ammonia which irritates the skin.

👶 Approximate age group

Nappy-wearing infants or children (rare after 12 months).

🔥 Presentation

The rash will be patchy and tends to involve the skin in contact with the nappy (buttocks, genitalia, thighs); the skin folds may be spared. Only erythema is present in mild cases, but erosion or even ulceration can occur in severe cases. The affected area is sore and cleaning or bathing causes much discomfort.

Common skin conditions in children

70

Treatment

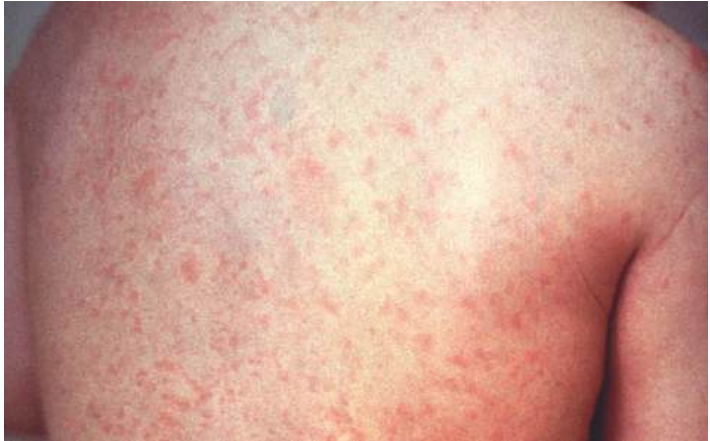Nappies should be changed as soon as they are wet or soiled and the skin gently cleaned and patted dry. A barrier cream or ointment should then be applied to the area covered by the nappy. Disposable nappies are more suitable than towelling ones while skin is affected as they are more effective at drawing liquid away from the skin. Avoid plastic pants.

Advice to parent/carer

In a child over nine months, 60–80mls of cranberry juice daily may help by altering the pH of the urine.

Traffic light

If the rash does not improve after taking these simple measures, a weak topical steroid such as 1% hydrocortisone (see section 07) can be applied once a day for 3–5 days.



📍 Rubella (German measles)

Rubella, caused by a rubivirus, is a common viral illness in children. It is spread by inhalation of infected droplets.

👶 Approximate age group

Childhood.

📌 Presentation

After an incubation period of 14–21 days, a macular rash begins on the face and neck. It spreads down the body in 24–48 hours then clears from the face downwards in 2–3 days. It is associated with enlarged occipital and posterior cervical lymph nodes and, occasionally, an arthritis. The child is infectious from 1 week before symptoms appear and up to 4 days after rash appears

Common skin conditions in children

72

👉 Treatment

If the diagnosis is suspected, rubella antibody titres should be measured immediately and after 10 days so that diagnosis can be confirmed.

Treatment is symptomatic as affected children get better spontaneously. Paracetamol elixir will ease pain.

+ Advice to parent/carer

Adequate fluid intake to avoid dehydration.

🚦 Traffic light

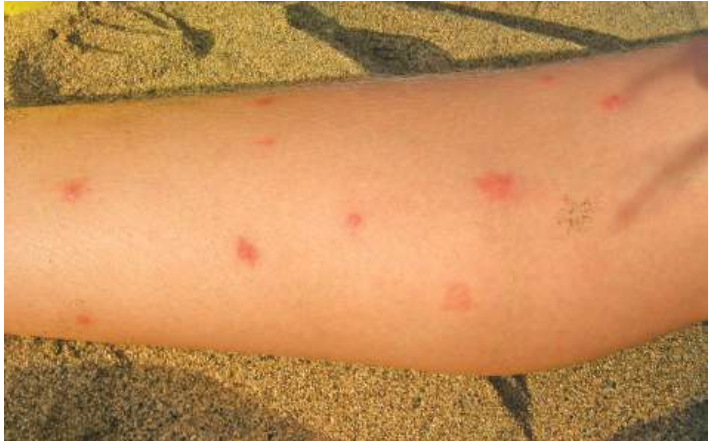Pregnant women are at risk, particularly in the first trimester.

Section 06

Common skin conditions in both adults & children



Common skin conditions in both adults & children 75



🕒 Bites (insect)

The presentation of the bite will help determine the causative insect.

👤 **Approximate age group**

Affects all age groups.

📄 **Presentation**

Insect bites present as itchy papules with a central punctum. If there are groups or rows of 3 or 4, think of flea bites; bed bug bites produce single very large lesions on the hands or face, with new lesions usually being found each morning. Numerous other insects can bite humans, including midges, mosquitoes, flies, wasps, ticks, bees, ants, moths and butterflies, centipedes, ladybirds and spiders. Sometimes large blisters will appear following an insect bite.

Common skin conditions in both adults & children 76

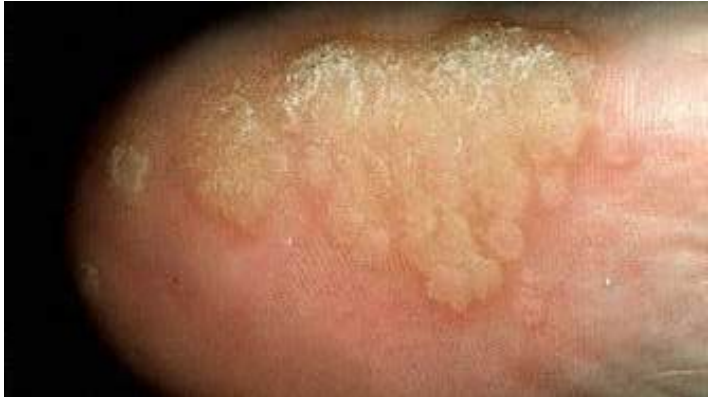👉 Treatment

Itch can be relieved by the application of 10% crotamiton cream, or a topical steroid for short-term use. If itch keeps the patient awake at night, a sedating night-time antihistamine can be prescribed.

+ Advice to patient

If there is a family pet (cat or dog) and flea bites are suspected, the animal, rather than the human, should be treated. Advise to take the animal to the vet for treatment.

Common skin conditions in both adults & children 77



🕒 Common warts

Common warts are an infection of the epidermis with one of numerous papilloma viruses. They are transmitted from one individual to another through broken skin (cuts, grazes etc). Autoinoculation can also occur if the wart is scratched and viral particles spread to another area of skin. Warts disappear spontaneously without scarring after weeks to years (average about 2 years).

👤 Approximate age group

Common warts are particularly prevalent in childhood but can affect all age groups.

📍 Presentation

Common warts arise most often on the backs of fingers or toes and on the knees. They are firm, rough, skin coloured or brown papules with black pin point dots on the surface due to thrombosed capillary blood vessels. There may be a single wart or multiple lesions.

Common skin conditions in both adults & children 78

👉 Treatment

Treatment depends on the age of the patient and how many warts are present. In young children the best treatment is to leave alone. Many people don't bother to treat them because the treatment is more uncomfortable and troublesome than the wart. They hardly ever cause serious problems, however, warts may be painful and often look ugly and cause embarrassment.

Treatment options include:

- **Occlusion** (keeping the wart covered for 24 hours of the day). Duct tape is convenient and inexpensive, where removal of the tape can strip the viral cells.
- **Topical treatment with wart paint** which contains salicylic acid, is usually applied once daily. The skin can be softened in a bath or hot soapy water then the surface of the wart gently rubbed away with a piece of pumice stone or emery board prior to paint application. Around 70% of warts will disappear with wart paint.

If these treatments are not successful, reassure and consider referral to a wart clinic locally if available.

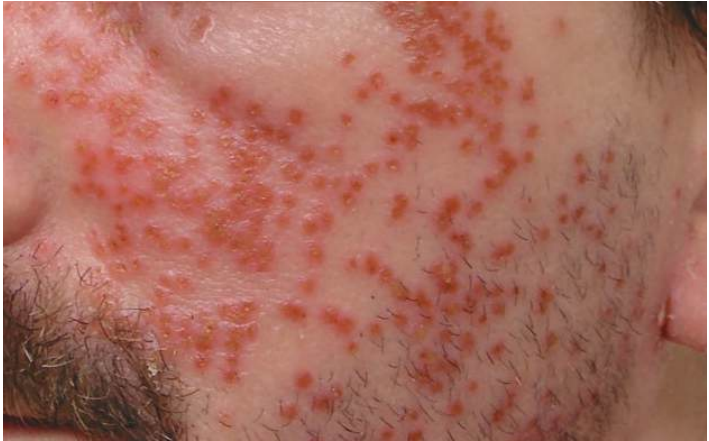✚ Advice to parent/carer

If wart paint makes the skin sore, stop treatment until discomfort has settled. Perseverance is essential and treatment should be applied daily for a minimum of 12 weeks.

🚦 Traffic light

Warts can be particularly numerous and troublesome in patients who are immunosuppressed.

Common skin conditions in both adults & children 79



🎯 Eczema herpeticum

Atopic eczema which has become secondarily infected with herpes simplex virus.

👤 Approximate age group

Affects all age groups.

📌 Presentation

The rash is made up of small umbilicated vesicles or grouped “punched-out” erosions which are painful rather than itchy. The patient will be generally unwell, which you would not normally expect with atopic eczema.

Common skin conditions in both adults & children 80

Treatment

A viral swab should be taken from one of the vesicles to confirm the diagnosis. Treat adults with a 7-day course of an oral antiviral agent such as aciclovir, valaciclovir or famciclovir. In children, topical aciclovir can be prescribed if infection is mild, and oral aciclovir if severe. These drugs are only effective when the virus is replicating so should only be given in the early phase of the disease (within 48 hours of the rash appearing).


Adequate analgesia, such as paracetamol or co-proxamol (adults only), is important.

Advice to patient/parent

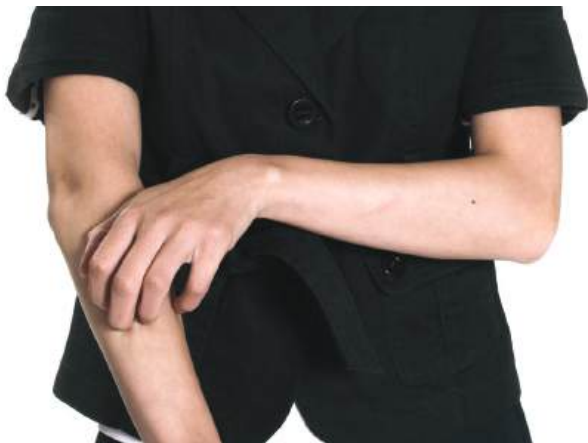Good hygiene: avoiding the sharing of towels and good handwashing techniques are important to minimise the risk of spreading the infection to others.

Traffic light

In children, hospitalisation may be considered in cases of severe infection.

 **DO NOT apply topical steroids if viral infection is suspected.**

Common skin conditions in both adults & children 81



🎯 Pruritus

Pruritus is a medical term for itchy skin.

👤 **Approximate age group**

All ages.

🚰 **Presentation**

In generalised pruritus, the patient presents with itchy skin all over with no visible rash but may have evidence of excoriation due to scratching.

A detailed history is required as there are many possible causes of pruritus, which include the following.

Anaemia

Check serum iron and ferritin levels.

Common skin conditions in both adults & children 82

Polycythemia rubra vera (itching especially after a hot bath) Check full blood count (FBC).

Uraemia (also seen in 80% of patients on maintenance haemodialysis) Check creatinine and urea.

Obstructive jaundice (may occur in patients with primary biliary cirrhosis before jaundice occurs) Check liver function tests and autoimmune profile.

Thyroid disease

Both hypo- and hyperthyroidism: check T4 and thyroid stimulating hormone levels.

Lymphoma

Especially in young adults, check for enlarged lymph nodes clinically and on chest x-ray.

HIV/AIDS

Check HIV ELISA test.

Drying out of skin

Common in older people.

Body lice

Look for lice and nits in the seams of underwear.

Psychological

Look for evidence of depression, anxiety or emotional upset.

Common skin conditions in both adults & children 83

Treatment

If the history fits with any of the above causes, carry out appropriate tests or refer to relevant specialist.

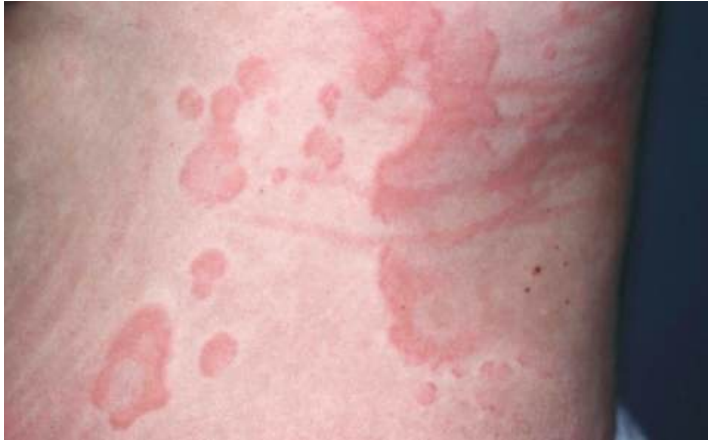If no cause can be found, treatment should be symptomatic. Start with 10% crotamiton cream twice a day. Complete emollient therapy (see section 07) should also be prescribed. If this does not help, a moderately potent topical steroid should be considered. If the itch is not settling and is interfering with sleep, a sedative antihistamine should be prescribed to be taken an hour before going to bed. Advise adults to be careful about driving the next day.

0.5% menthol in aqueous/hydrophilic cream may also be useful to relieve the itch.

Traffic light

The patient often feels dirty and may describe a feeling of something crawling under the skin. Reassure that this is a medical condition which can be treated. Encourage frequent use of emollients and encourage patting (not rubbing) skin dry after bathing.

Common skin conditions in both adults & children 84



🕒 Urticaria (acute)

Urticaria refers to a group of disorders caused by the release of chemicals such as histamine from the mast cells in the skin. This causes small blood vessels to leak, which results in tissue swelling.

👤 Approximate age group

This disorder affects both adults and children.

📋 Presentation

The skin itches or stings, with the development of weals which are first white, then turn red. The weals can vary from a few millimetres to several centimetres in diameter and can become very extensive, developing in many sites at once. They will clear spontaneously in a few hours, even though new lesions may continue to develop.

Common skin conditions in both adults & children 85

👉 Treatment

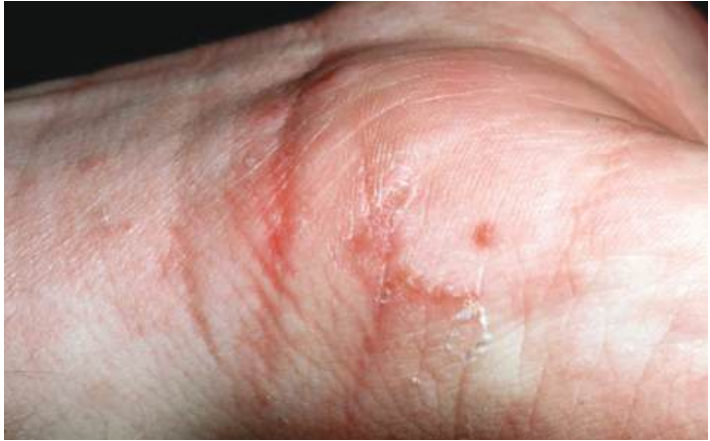Antihistamines until rash settles.

There is no need for specific investigations in most cases of urticaria, but the following tests may be helpful in some cases:

- **FBC** – identify eosinophilia caused by allergen or parasitic infestation; low white blood count for systemic lupus erythematosus
- **thyroid antibodies and function** – in chronic urticaria if autoimmune origin is considered
- **skin-prick test and blood tests** for specific allergens
- **skin biopsy** – if weals are prolonged, to identify vasculitis.

🚦 Traffic light

A frequent accompanying feature of urticaria is angioedema, in which oedema develops in the subcutaneous tissues around the eyes, lips, mouth and in the pharynx. The swelling may cause the airway to be compromised. If life-threatening swelling of the larynx or tongue occurs (anaphylaxis), follow local guidelines.

Common skin conditions in both adults & children 86**🕒 Scabies**

Scabies is an infestation with the *Sarcoptes scabiei* mite. It is transmitted by prolonged skin-to-skin contact with someone who is infected. A fertilised female has to be transferred for infestation to occur. The female mite will then burrow into the skin to lay the eggs: 4–6 weeks later, a hypersensitivity rash will appear.

👤 Approximate age group

Affects all age groups.

Common skin conditions in both adults & children 87

Presentation

The rash is made up of excoriated papules scattered over the trunk and limbs but sparing the face (except in infants). The patient will experience intense itch, especially at night. Identification of one or more burrow will confirm the diagnosis. Burrows are most often found on the hands and feet in the sides of the fingers and toes and web spaces. In infants, burrows are often present on the palms of the hands and soles of the feet.

Treatment

5% permethrin cream or 0.5% malathion lotion can be used. It is important to take the time to explain to the patient exactly how to use the treatment, and explanatory treatment sheets are also useful. All family members and close physical contacts with the affected individual should be treated simultaneously. Advise the patient not to have a bath or shower prior to applying treatment. Topical applications should be applied from the neck to the toes, paying particular attention to behind both ears, axillae, under breasts, navel, groin and genital areas, and between fingers and toes. The patient should be reminded not to wash their hands after applying treatment. If hands need to be washed during the night, further application is required. The treatment is applied at night before the patient goes to bed and is left on for the allotted time. After the allotted time, the treatment should be washed off in the bath or shower. Underwear, nightwear and bed sheets should be changed. Bedding and nightwear should be washed and ironed.

Advice to patient

Itch does not resolve immediately following treatment but will gradually improve over 2–3 weeks in some individuals, although it may take up to 8 weeks to finally resolve. Residual itch can be treated with a mild or moderate topical steroid or crotamiton cream twice a day together with regular emollient therapy.

Common skin conditions in both adults & children 88

Traffic light

Treatment failure in scabies is due to:

- the scabicide not being applied over the whole body
- the contacts not being treated
- the wrong diagnosis.

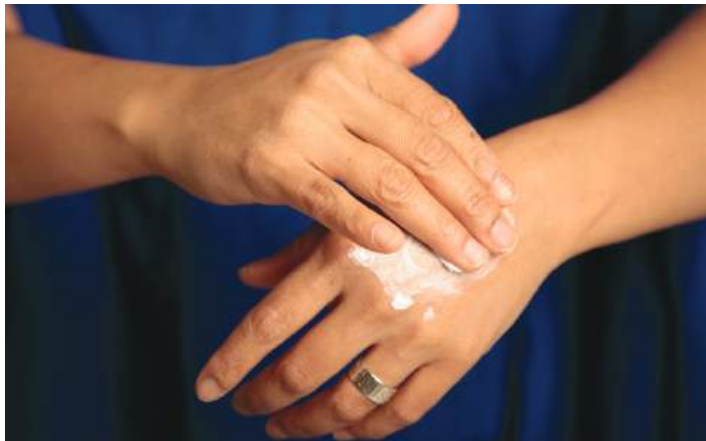A horizontal dashed line consisting of small, evenly spaced rectangular dashes, located near the top of the page.

Section 07

Practical advice on topical treatments







Emollients/moisturisers and complete emollient therapy

Emollients are a key element in controlling and managing dry skin conditions. These products may be prescribed alone or be used as an adjuvant to other topical treatments such as topical steroids.

Causes of dry skin include: environmental factors (dry air, exposure to wind); reduction in production of sebum (usually in old age); underactive thyroid; inherited factors; and skin conditions (eczema, psoriasis).

Complete emollient therapy

This is the term given to a regime which includes soap substitutes, bath oil and moisturiser.

Soap substitutes – soap can have a drying effect on the skin so should be avoided in dry skin conditions. Soap substitutes, when applied prior to contact with water, help prevent stinging and act as a moisturiser.

Practical advice on topical treatments

92

Bath additives – help to moisturise the skin while bathing. Some contain antipruritic and antistaphylococcal agents. These should only be used if indicated and for the prescribed period (usually 4–6 weeks). Patients should be advised not to purchase bath oils containing fragrance as it is a known sensitiser.

Advise the patient that bath additives can make the bath slippery.

Moisturisers

Come as lotion, cream, gels, ointment and spray canisters.

Lotions

Are used for scalps or other hairy areas and for mild dryness on the face, trunk and limbs.

Creams

Cream-based products are the most commonly used moisturisers for dry skin conditions as they can be applied to the entire body, are cosmetically acceptable and have cooling properties.

Gels

Similar to creams.

Ointments

Are prescribed for drier, thicker, more scaly areas, but patients may find them too greasy.

Spray canisters

Quick to use.

Application

Patients should be advised to apply moisturiser directly to the skin in a downward motion in the direction of hair growth. This will reduce the risk of blocking the hair follicles (folliculitis).

Moisturiser should be applied at least twice daily.

It is important to prescribe the right amount of moisturiser. Prescribe 250g per week for a child under 10 years, and 600g for adults and children over 10 years.

For further information you can download the Skin Integrity Emollient Factsheet from www.nhsfife.scot.nhs.uk/skinintegrity

It is important to advise the patient, parent or carer not to stop complete emollient therapy once the condition is controlled as this will help to prevent future exacerbations.

Topical steroid therapy

Topical steroids are extremely useful in inflammatory skin conditions such as eczema. In the UK, they are divided into four groups according to their potency.

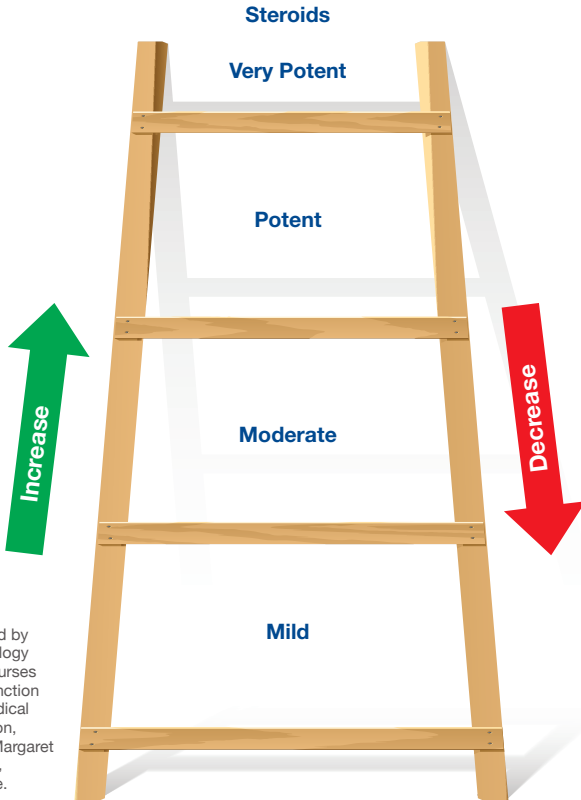
Group	Strength
Weak	= to hydrocortisone
Moderately potent	2.5 times stronger
Potent	10 times stronger
Very potent	50 times stronger

There are large numbers to choose from, but it is best to become familiar with a few, perhaps one or two from each group.

The **steroid ladder** (below) identifies some of the steroids available and their potency. It also demonstrates the importance of titration of topical steroids: if the patient has been treated with a potent steroid and is improving, it is important to gradually reduce the potency, not discontinue treatment, to avoid a flare up of the condition.

Practical advice on topical treatments

94



Designed by dermatology liaison nurses in conjunction with medical illustration, Queen Margaret Hospital, NHS Fife.

Climb up the ladder but don't jump off

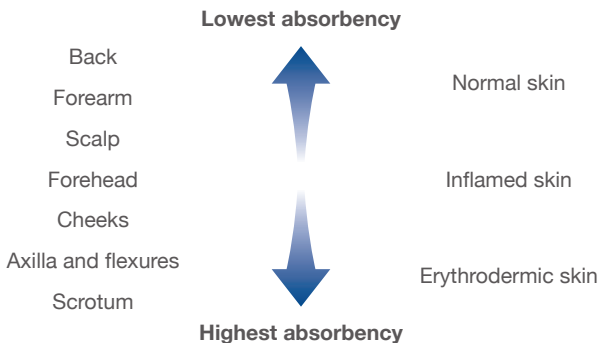
As a general rule, use the weakest possible steroid that is effective. For the face, 1% hydrocortisone or equivalent (weak) should be prescribed. Start with this elsewhere and only prescribe something stronger if this does not work. In general practice, it is rarely necessary to use anything stronger than a moderately potent steroid for extensive eczema. For localised persistent eczema, a potent steroid can be useful. Very potent steroids should rarely be used.

30g of ointment or cream is enough to cover the adult body once. To cover the whole body for a week if applied twice daily will require 200g. If a patient has widespread eczema, adequate amounts of topical steroid should be prescribed to avoid relapse. A useful guide to using the correct amount of topical steroid is the finger-tip unit guide, which is the amount of cream/ointment squeezed onto the index finger from tip to the first joint. This amount will cover the area of two palms.

The potency of a steroid can be enhanced by the base used: for example, an ointment base makes a steroid more potent than a cream or lotion. Additionally, the ability of a topical steroid to be absorbed varies according to the site and the condition of the skin. The diagram below demonstrates these differences.

Practical advice on topical treatments

96



It is important to prescribe complete emollient therapy along with topical steroid therapy as this will help to reduce inflammation and dryness.

Caution

Topical steroids are contraindicated in some skin conditions, including: acne; rosacea; bacterial infections; infestation; leg ulcers; and viral infections.

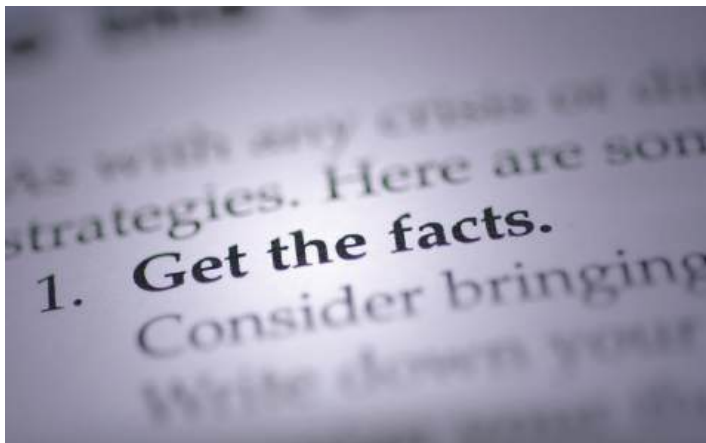 **DO NOT** apply steroids to the eyelids.

Section 08

Glossary







Describing a lesion (morphology)

Lesion

A single area of altered skin: it may be solitary or multiple.

Abscess

Pus-filled lesion (>1cm).

Blister

Fluid-filled lesion (any size).

Bulla

Fluid-filled lesion, circumscribed elevation (>1cm).

Cyst

A closed cavity or sac lined with epithelium containing fluid, pus or keratin.

Glossary

100

Macule

Flat circumscribed area of discolouration (<1cm).

Nodule

Round elevated solid lesion (>1cm).

Papule

Any raised lesion or scaly, crusted, keratinised or macerated surface (<1cm).

Patch

A large macule, change in colour only, surface is always normal (>1cm).

Plaque

Raised, flat-topped lesion (>1cm).

Pustule

Pus-filled lesion (<1cm).

Vesicle

Fluid-filled lesion (<1cm).

Alopecia

Hair loss.

Annular

Round or ring shaped.

Atrophy

A diminution of tissue.

Burrow

Linear lesion caused by parasites.

Callus

Hyperplasia of the stratum corneum due to physical pressure.

Cellulitis

An inflammation of cellular tissue.

Comedone

Papule plugging sebaceous follicle containing sebum and cellular debris.

Crust

Accumulation of dried exudate.

Erythema

Redness of the skin caused by vascular congestion or perfusion.

Erosion

Loss of epidermis which heals without scarring.

Excoriation

Loss of skin substance produced by scratching.

Extensor

Extensor surfaces (e.g. elbows and knees).

Fissure

A linear gap or slit in the skin's surface.

Flexor

Skin fold (e.g. back of knees).

Folliculitis

Inflammation of the hair follicles.

Keloid

Elevated progressive scar without regression.

Linear

Straight line, often caused by scratching.

Lichenification

A flat-topped thickening of the skin often secondary to scratching.

Milium

A tiny white cyst containing lamellated keratin.

Glossary

102

Nummular/discoid

Disc shaped.

Oedema

Tissue swelling.

Petechia

A punctated haemorrhagic spot 1–2mm in diameter.

Polymorphic

Lesions have varied shapes.

Purpura

Discolouration of the skin or mucosa due to extravasation.

Rash

A widespread eruption of lesions.

Scab

A hard crust of dried blood and serum which forms over a wound during healing.

Scale

Visible and palpable flakes due to aggregation and/or abnormalities of shed epidermal cells.

Scar

Fibrous tissue replacing normal tissue destroyed by injury or disease.

Striae

A linear, atrophic, pink, purple or white streak or band on the skin due to changes in the connective tissue.

Telangiectasia

A visible vascular lesion formed by dilatation of small cutaneous blood vessels.

Ulcer

Loss of epidermis (often loss of underlying dermis and subcutis).

Umbilicated

Papules or vesicles with a central dell or hollow.

Weal

Central itchy white plaque surrounded by an erythematous flare.

Glossary

104





Section 09

Resources







Further reading

Ashton R, Leppard B (2005) Differential Diagnosis in Dermatology 3rd Edition. Radcliff Publishing Limited: Oxford.

Gawkrodger DJ (2007) Dermatology: An illustrated colour text. Elsevier: London.

Graham-Brown R, Burns T (2007) Lecture Notes: Dermatology 9th Edition. University Press: Oxford.

Resources

108

Useful websites

www.dermnetnz.org

This is a dermatology site from New Zealand which provides in-depth information on a wide range of dermatological conditions.

www.bad.org.uk

The website of the British Association of Dermatologists.

www.nes.scot.nhs.uk

The website for NHS Education for Scotland.

www.bnf.org

The British National Formulary.

www.bnfc.org

The British National Formulary for Children.



List of illustrations of conditions in adults

Acne

A diagnosis of acne vulgaris. Primary lesions of excoriation, papule/erythematous, pustule/follicular, comedones on the head/face/cheek.

© www.dermquest.com

Cellulitis (Image 01)

This patient presented with staphylococcal orbital cellulitis. Note the periorbital swelling and erythema. The symptoms associated with cellulitis can evolve and worsen due to systemic bacterial migration via the bloodstream, and include fever, malaise, and chills.

CDC image 2843. Dr. Thomas F. Sellers/Emory University.

© <http://phil.cdc.gov>

Cellulitis (Image 02)

A diagnosis of cellulitis. Primary lesions of crust, erosion/ulceration, plaque/erythematous, erythema on the lower limbs/legs.

© www.dermquest.com

Psoriasis (Chronic plaque psoriasis)

A patient presenting with condition confirmed as a generalised psoriatic dermatitis. Psoriasis is an erythematous skin condition characterised by irregular red patches covered by a dry scaly hyperkeratotic stratum corneum, which usually occur on the elbows and knees, as well as scalp and lower back, but can occur anywhere on the body.

CDC image 4050. Dr. N.J. Fiumara.

© <http://phil.cdc.gov>

Psoriasis (Guttate psoriasis)

A diagnosis of guttate psoriasis. Primary lesions of plaque/erythematous-squamous of the lower limbs/thigh.

© www.dermquest.com

Resources

110

Shingles (herpes zoster)

A diagnosis of herpes zoster in an elderly patient. Primary lesions of crust, vesicles, erythema of the trunk/back. Symptoms of burning and pain.

© www.dermquest.com

Skin cancer (BCC)

A diagnosis of basal cell carcinoma in an elderly patient. Primary lesions of papule/hyperpigmented, plaque/erythematous of the trunk/back. Asymptomatic.

© www.dermquest.com

Skin cancer (SCC)

A diagnosis of hypertrophic actinic keratosis in an elderly patient. This large hyperkeratotic lesion on severely sun-damaged skin was a combination of both hypertrophic actinic keratosis and a squamous cell carcinoma.

© www.dermquest.com

Skin cancer (malignant melanoma)

A diagnosis of malignant melanoma in a patient of undetermined age. Primary lesions macule/hyperpigmented. A superficial spreading melanom level III with 0.55mm of Breslow thickness.

© www.dermquest.com

Vasculitis (Image 01)

Purpuric rash on the abdomen.

© www.dermnetnz.org

Vasculitis (Image 02)

Purpuric rash with some ulceration on the lower leg.

© www.dermnetnz.org



List of illustrations of conditions in children

Chickenpox (Varicella)

A child presenting with the characteristic pancorporeal varicella, or “chickenpox” lesions. The blister-like lesions have a pus-filled centre, appearing on the face, scalp or trunk. Varicella is highly contagious and spreads via coughing or sneezing. Complications include bacterial infection of the skin, swelling of the brain and pneumonia.

CDC image 6121.

© <http://phil.cdc.gov>

Eczema (atopic)

A diagnosis of infantile atopic dermatitis in a child of undetermined age. Primary lesions plaque/erythematous. Symptoms are pruritus (itching), dry skin.

© www.dermquest.com

Henoch-Schönlein purpura

Purpuric rash on the upper thighs.

© www.dermnetnz.org

Impetigo (atopic)

A diagnosis of impetigo in a child of undetermined age. Primary lesions crust, erosion/ulceration. Asymptomatic.

© www.dermquest.com

Impetiginised eczema

Extensive crust and weeping skin around the mouth.

© www.dermnetnz.org

Miliaria

Folliculitis on an infant’s back.

© www.dermnetnz.org

Resources

112

Measles

This child with measles is displaying the characteristic red blotchy pattern on his buttocks and trunk during third day of the rash. Measles is an acute, highly communicable viral disease with prodromal fever, conjunctivitis, coryza, cough and Koplik spots on the buccal mucosa. A red blotchy rash appears around day 3 of the illness, first on the face, and then becoming generalised.

CDC image 4499.

© <http://phil.cdc.gov>

Molluscum Contagiosum

A common skin disorder caused by superficial skin infection by the pox virus

© www.galderma.co.uk

Napkin dermatitis (nappy rash)

Rash over groin with some erosions; the skin folds are spared.

© www.dermnetz.org

Rubella (German measles)

Rash of rubella on skin of child's back. Distribution is similar to that of measles, but the lesions are less intensely red.

CDC image 712.

© <http://phil.cdc.gov>



List of illustrations of conditions in adults and children

Bites (insects)

The arm of a young boy showing 11 mosquito bites.

© www.shutterstock.com

Common warts

A localised growth or growths in the skin caused by infection by the human papilloma virus (HPV).

© www.galderma.co.uk

Eczema herpeticum

A diagnosis of eczema herpeticum in a patient. Primary lesions crust, erosion/ulceration, papule/erythematous, vesicles. Symptoms pain.

© www.dermquest.com

Pruritus

Demonstrating itchy skin with no visible rash.

© www.shutterstock.com

Urticaria

A diagnosis of dermatographia in a woman of undetermined age. Primary lesions dermatographism, plaque/erythematous, erythema, oedema.

Symptoms pruritus (itching).

© www.dermquest.com

Scabies

A diagnosis of scabies in a patient of undetermined age. Primary lesions excoriation, macule/erythematous, vesicles, erythema. Symptoms pruritus (itching).

© www.dermquest.com

Resources

114



Your Dermatology Pocket Guide:
Common skin conditions explained

© NHS Education for Scotland 2014. You can copy or reproduce the information in this document for use within NHSScotland and for non-commercial educational purposes. Use of this document for commercial purposes is permitted only with the written permission of NES.

NHS Education for Scotland
102 Westport
West Port
Edinburgh EH3 9DN
Telephone: 0131 656 3200

www.nes.scot.nhs.uk

