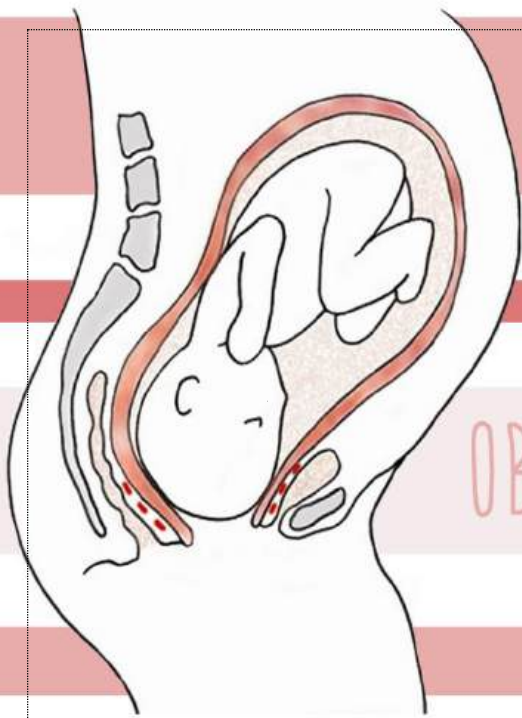

OBSTETRICS AND GYNECOLOGY

OB-GYN OSCE

(Instruments & Physical examination)

Shahd Saleh Al-Awwad

Lama Altawil

Manar Aleid

Shaima Alrefaie

Rehab Alenizi

Lulu Alobaid

Ghadah Alharbi

Latifah Alfahd

Alanoud Alyousef

Dana Aldubaib

Raghad Almotlaq

The physical examination part revised by :

Dr.Hazem Al-Mandeel

Outline & objectives:

Instruments:

- Identify the instrument / treatment
- The uses / indications of the instrument
- Contraindications of the instrument use
- Prerequisites for the use of instrument
- Complications of the use of the instrument
- Points about the disease in relation to the instrument

Physical examination

Obstetrics:

- To be able to understand normal delivery
- To be shown how forceps delivery is conducted, how vacuum delivery is conducted
- To be able to undertake delivering placenta, inspect it with its membranes and to inspect the umbilical cord
- To be shown fetal scalp electrode
- To be able to perform antenatal obstetric examination (Leopold's maneuver)
- To be able to distinguish cervical assessment in labour
- To be shown the different types of episiotomies, their indications, advantages and disadvantages

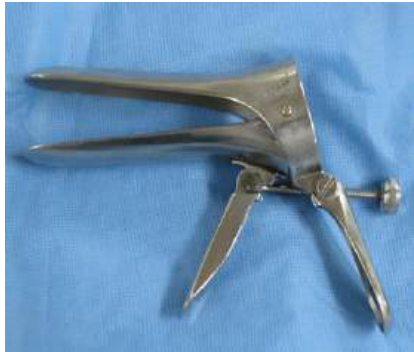Gynecology:

- To be able to identify the different types of speculum; Sim's, cusco's, their uses and how to apply them
- To be able to perform Bimanual pelvic examination
- To be shown how to take a pap smear.

A) Instruments :

Gynecological Instruments:

1] Vaginal Specula:



Inserted closed then opened
once inside

Identify? Cusco's non-fenestrated bi-Valvular self-retaining vaginal speculum.

Indications:

1. It's used to expose the **cervix** (mainly) & the vaginal wall in examination.
2. It allows the application of local instruments to the cervix or obtaining swabs.
3. It allows introduction of the uterine sound, insertion of IUD, performing Hysterosalpingography, taking a premenstrual endometrial biopsy & taking a surface biopsy scraping of the cervix.
4. It's used to expose the 2 sides of a septate vagina, when a blade is inserted in both sides.

Advantage:

1. It's easy to introduce.
2. Self-retaining.
3. Can be adjusted to the size of the vagina

Disadvantage:

1. It hides the anterior & posterior vaginal walls; however, we can overcome this disadvantage by inspecting the vaginal walls during gradual withdrawal.
2. It doesn't offer complete protection of the vaginal walls during cauterization of the cervix.



Identify:

Sim's vaginal speculum.

Indications:

1. It exposes the anterior vaginal wall especially in cases of vesico-vaginal fistulas.
2. It's also used for the diagnosis of prolapsed and for operative repairs like episiotomies.
3. It can also be of value to insert a vaginal pack.

Advantages:

1. It exposes the anterior vaginal wall. It's the only and best one for the vaginal wall visualization
2. The grooved blade directs the blood or the urine outside when it's used in the lithotomic position & provides a space for the operative work.
3. Provides a space for operative work.

Disadvantages:

1. Assistance is required especially when it's used to expose the cervix or during surgical procedures because it's not a self-retaining specula.
2. In the presence of a large cystocele, exposure of the cervix is often difficult.



Identify:

Auvard's self-retaining vaginal
Specula.

Indications:

For most operative procedures performed per vagina.

Advantage:

1. It's self-retaining.
2. It gives good exposure of the anterior vaginal wall & the cervix during operations.

Disadvantage:

1. It may tear, bruise or overstretch the soft tissues of the perineum & posterior vaginal wall.
2. It's difficult to use in nullipara.
3. It hides the posterior vaginal wall.



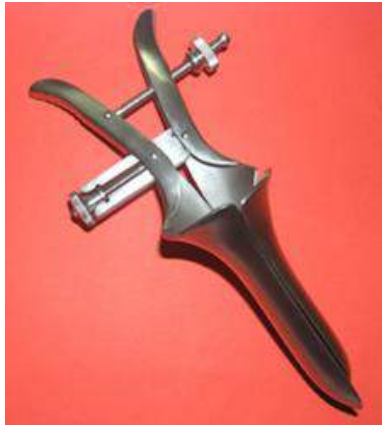Identify:
Grave specula

- Two articulating joint and both joints need to be fixed to visualize
- And the joints are angled

Indications: same as Cusco

Contraindications:

Complications:



Identify:
Devilbiss speculum

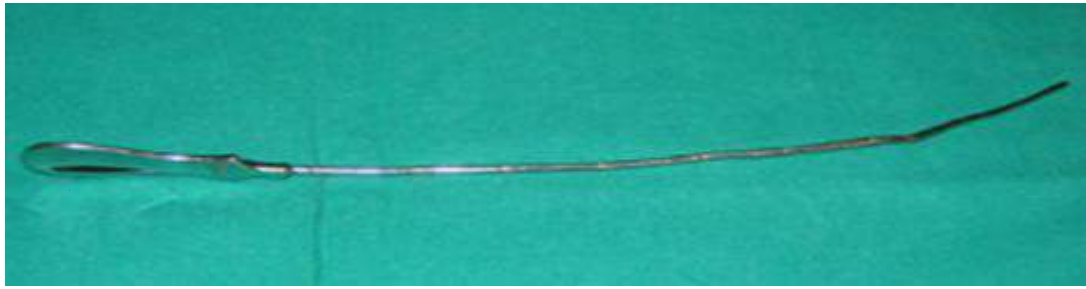- Two articulating joint and both joints need to be fixed to visualize
- Angle is straight

Indications: same as Cusco

Contraindications:

Complications:

2] Uterine instruments:



Identify: Sim's uterine sound

Indications:

To measure uterine cavity length in order for D&C so we avoid uterine perforation.

1. Prior to procedure to determine the size & direction **and length** of the uterus. (e.g. before D & C & after insertion of an IUCD). **To avoid perforation**
2. To differentiate uterine inversion from a Submucous fibroid.
3. To differentiate between a uterine polyp (can go around it) & a cervical polyp (can't go around it).
4. It determines the relation of the uterus to any pelvic mass.
5. Cervical stenosis.
6. Primary dymenorrhea.

Complications:

1. Disturbance of an undiagnosed pregnancy.
2. **Perforation** of the cervix or body of the uterus.
3. Ascending infection.

Contraindications:

1. Suspicion of pregnancy.
2. Soft uterus (malignancy, infection or molar pregnancy).



Identify: Hegar's uterine dilator

Describe: -They are used to gradually dilate the uterus, can be single or double ended. They are 15. Graduated by a number written on them ranging from 0 to 14.

Indications:

a) Diagnostic:

1. Cervical incompetence.
2. To diagnose intrauterine lesions & septa.
3. Prior to insufflations or Hysterosalpingography in cases with a narrow external cervical os.
4. to diagnose Spasmodic dysmenorrhea

b) Therapeutic:

1. Cervical stenosis.
2. Dysmenorrhea
3. Drainage of a hematometra or pyometra.
4. Cervical abortion.

c) As a step in the course of other operations:

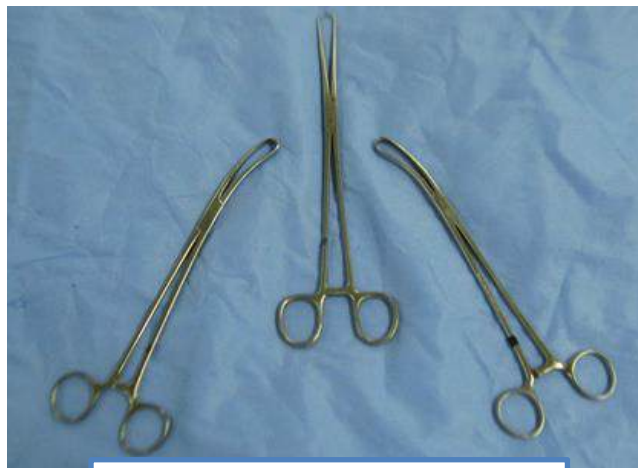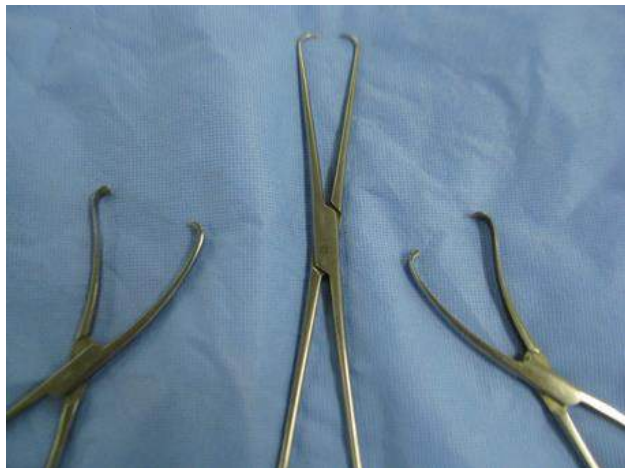1. **Prior to D & C or evacuation.**
2. Vaginal hysterectomy.
3. Removal of a fibroid or an endometrial polyp.
4. Before the insertion or removal of certain contraceptive devices.

Complications:

1. **Perforation** of the cervix or body of the uterus.
2. Cervical incompetence & habitual abortion (Most Common).
3. Ascending infection (cervicitis, endometritis, salpingitis, peritonitis & parametritis).
4. Laceration of the cervix.

Contraindications:

- Active Genital infection.
- Normally pregnant uterus.
- Never in labor or OB only gyn cases



Cervical clamps have 2 types, see next picture.

Identify: Tenaculum / Vulsellum

Types:

1. **Single** toothed (bullet forceps) **tenaculum**.
2. **Double** toothed (fentons bull dog **vulsellum** or the lions forceps).
3. Multiple toothed vulsellum .

Indications:

1. To **grasp or handle the anterior lip of the cervix**.
2. **During vaginal operations for e.g. D & C** and repair of prolapsed.
3. To help in the correction of RVF.
4. To grasp a prolapsed Submucous myoma during a vaginal myomectomy.
5. During a hysterectomy.

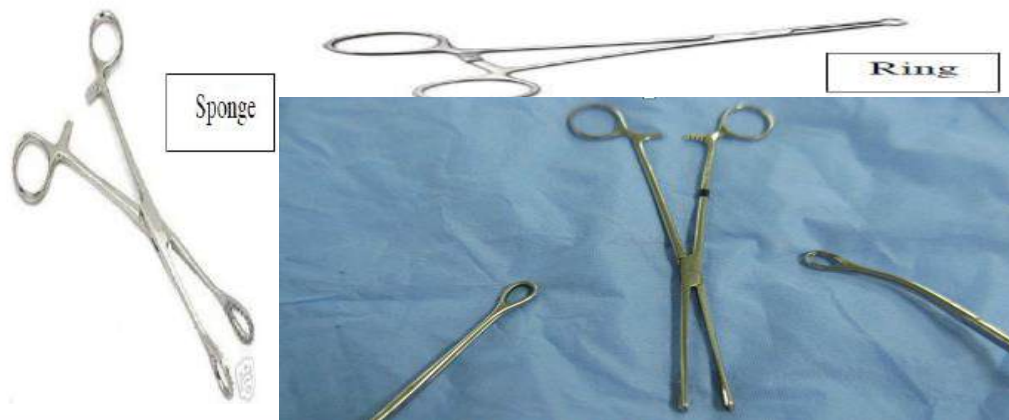Complications:

1. Laceration of the cervix.
2. Infections.
3. Bleeding from the site of the bite of the teeth of the vulsellum.

Contraindications:

1. The soft pregnant cervix. **However you will use it in an incomplete abortion or cervical cerclage → still there is a risk of bleeding**
2. Infections.

3. Suspicious malignancy of the cervix.



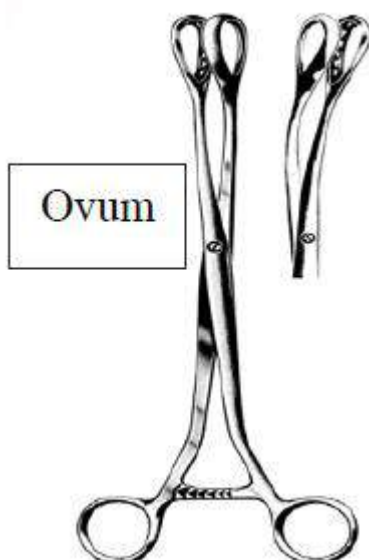
Identify:

Ring & sponge forceps:

- The jaws are either smooth or serrated, rounded or oval in shape

Indications:

1. To grasp the soft lips of the cervix & evacuate **a pregnant uterus** per vagina. **So it's preferable in pregnant women**
2. It's used to remove corporeal & cervical polyps.
3. Can be used as a sponge carrier.

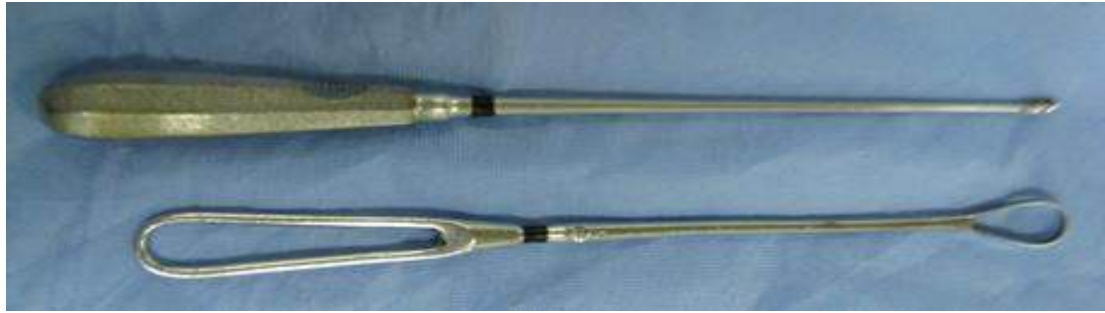

Identify:

Ovum

Forceps,

- It's a miniature of the obstetric forceps.
- Each branch has a handle, a shank & a blade. The 2 branches are attached by a screw joint & have no lock.
- It's used to remove an intact separated ovum. It's also used to evacuate the uterine content after D & C.
- Also used to remove IUCD & conception products.



Identify: Uterine curette. Sharp in non-pregnant gyn case , blunt in pregnant

Describe:

- Single ended corrugated sharp or blunt
- Each curette consists of 3 parts: the handle, the shank & the curetting end.
- The curetting end may be sharp or blunt & some are spoon shaped.

Indications:

Diagnostic curettage:

- a) Bleeding.
 1. Dysfunctional uterine bleeding. (DUB)
 2. Suspected uterine malignancy.
 3. Secondary post partum & post abortive bleeding.
 4. Cervical adenomatous polyps.
- b) Amenorrhea.
 1. Atrophic endometrium.
 2. PCO.
 3. TB endometrium.
- c) Sterility.
 1. Anovulation.
 2. TB endometrium.
 3. Non-responsive endometrium.
 4. Hormonal function of the ovaries.

Therapeutic curettage:

1. For temporary or permanent cure of non-malignant uterine bleeding for e.g. metropathia hemorrhagica & other types of functional bleeding & secondary post partum & post abortive bleeding.
2. Membranous dysmenorrhea.
3. Removal of endometrial polyps.

Complications:

1. Sepsis: Infection can lead to acute endometritis, salpingitis &/or peritonitis.
2. Perforation of the uterus which is the most common complication.
3. Permanent amenorrhea & sterility can occur from vigorous over curettage. (e.g. **Asherman syndrome**)
4. Excessive bleeding may occur in cases of uterine body carcinoma.
5. The use of flushing curette may push endometrial tissue through the fallopian tubes leading to pelvic endometriosis or peritonitis.

Contraindications:

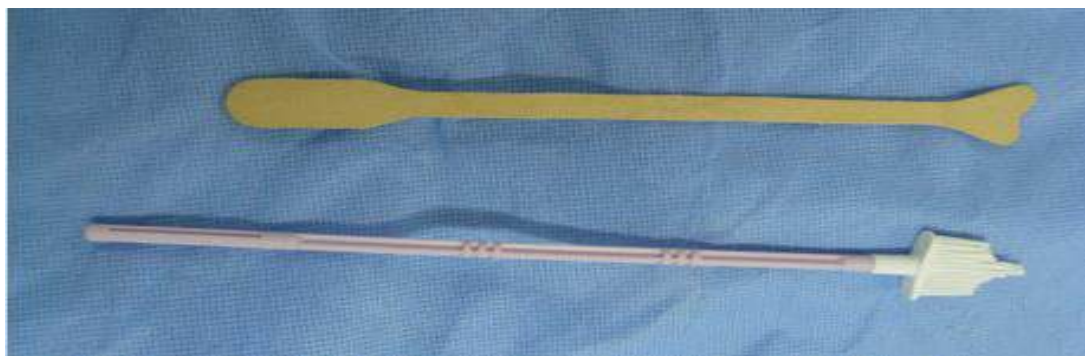Absolute contraindications to dilation and curettage include the following:

- Viable desired intrauterine pregnancy
- Inability to visualize the cervical os
- Obstructed vagina

Relative contraindications to dilation and curettage include the following:

- Severe cervical stenosis
- Cervical/uterine anomalies
- Prior endometrial ablation
- Bleeding disorder
- Acute pelvic infection (except to remove infected endometrial contents)
- Obstructing cervical lesion

<http://emedicine.medscape.com/article/1848239-overview>



Identify:

Wooden spatula & Roller(Cervical -Cyto) brush

Indications:

-For endocervical sampling (**PAP smear**). For screening & diagnosing cervical cancer which is most commonly caused by Human Papilloma Virus (HPV). The most common subtypes to cause that are HPV-16 and 18.

- The sample is taken from the squamo-columnar junction of the cervix. (the transformation zone).
- It's neither a true biopsy nor a smear. It's a scraping.
- In post coital bleeding.

Risk factors of cervical cancer:

1. Old age.
2. White women.
3. Early sexual activity.
4. Multiple sexual partners.
5. Smoking.

-No absolute contraindications

-Complications:

- The Pap smear is only a screening test. False-negative rates are high.
- Minor spotting and occasional uterine cramps commonly follow Pap smear sampling.

- <http://www.proceduresconsult.com/medical-procedures/pap-smear-FM-020-procedure.aspx>

3] Urinary instruments:



Identify:

Metal urinary catheter: These are of 2 forms: Straight & curved (S-shaped).

And Foley catheter (rubber)

Indications:

- We can use it in **induction of labor**. (The foley) and its called mechanical dilation

1. Before any gynecological or obstetric examination.
2. Used in the 1st stage of labor to prevent uterine inertia.
3. Used in the 3rd stage of labor to prevent retention of the placenta & guard against post partum hemorrhage.
4. Used in the diagnosis of urinary fistula.

Complications of metal :

1. Introduction of sepsis.
2. False passage in the urethra or perforation of the bladder wall.
3. Urethral shock & fever.

Complications of folley's catheter:

1. Infections.
2. Injury to the urethra

Advantages:

Advantages of metal over Folly's catheter: Less induction of infections & pressure necrosis.

Contraindications:

Traumatic injury to the lower urinary tract (eg, urethral tearing) is a contraindication for urethral catheterization in women.

<http://emedicine.medscape.com/article/80735-overview#a4>



Identify:

Hodge or Ring Pessary

Indications:

1. Symptomatic uterine prolapsed. And she's not candidate for surgery.
2. Pelvic support defect or weakness.
3. Vaginal prolapse.

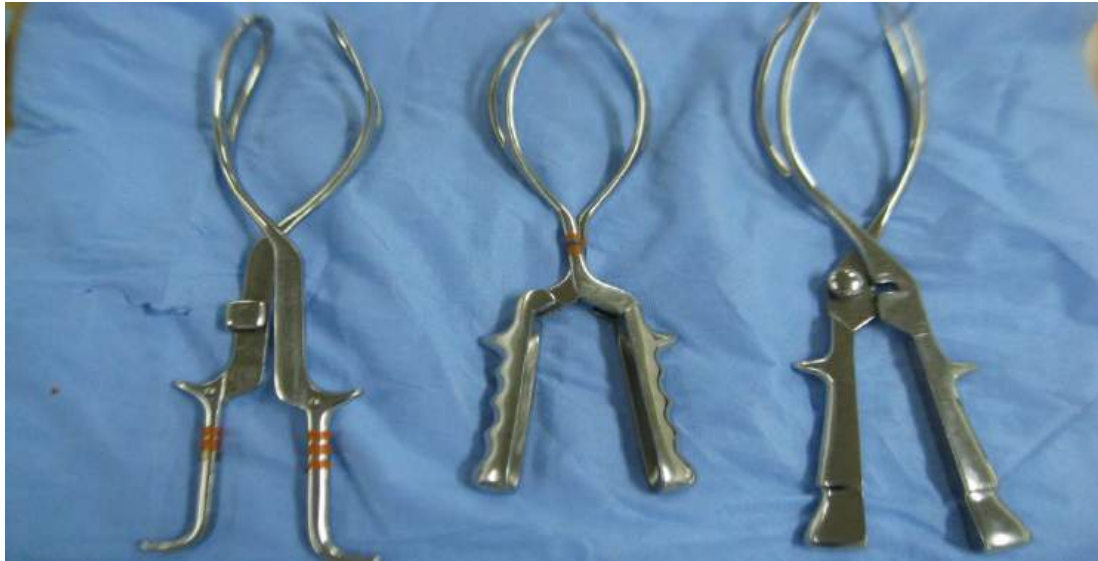Complications:

- Pressure necrosis.
- Allergic reactions.
- Needs a careful follow up. (changed every 3 months)
- Infection
- If there is HX of atrophic vagina you must watch for erosions

Contraindications:

1. Active infections of the pelvis or vagina.
2. Patients who are noncompliant or unlikely to follow up.
3. Allergy to the product.

1] Obstetric forceps:



Definition:

-an instrument to offer traction and rotation of the fetal head when the mother's expulsive forces are not sufficient to accomplish a safe delivery of the fetus.

Pre-requests:

1. Cephalic presentation (BUT piper forceps is used for breech). And **occipito-anterior**, if occipito-posterior I need to rotate the baby
2. Head is engaged 0-2.
3. A **fully dilated cervix**, otherwise it might cause cervical trauma (cervical tears) or uterine prolapsed (remote complication).
4. **Ruptured membranes.**
5. **Empty bladder & rectum.**
6. **Adequate Anesthesia.**
7. **Adequate pelvis**
8. **Need episiotomy.**
9. **Make sure you lock the device before using it**
10. **Experienced operator**

Types:

1. Short curved Wrigley's obstetric forceps. **Outlet forceps**
2. Long curved Simpson's obstetric forceps. **For traction only, we can use it in breech presentation baby who delivered vaginally even in CS (midway forceps)**

3. Long straight kiellands obstetric forceps. For **rotation (only one) and traction** when head above 0 station, **only one with a sliding lock not used anymore due to high risk of vaginal lacerations and fetal injuries**
4. Piper : after the coming of the head in a vaginal breech baby
5. Barton : to deliver an occiput transverse position with a platypelliod pelvis



Classification :

- Outlet: fetal head is at the pelvic floor
- Low: fetal head is below +2 station
- Mid: fetal head between 0 to +2 station
- High : fetal head unengaged (not approached anymore)

Indications for forceps delivery:

1- Maternal:

A. Dangers for the mother (prophylactic forceps):

- Toxemia of pregnancy (pre-eclampsia & eclampsia).
- Previous C-section.
- Weakness in the abdominal wall (hernias & Hx of a recent abdominal operation).
- An associated disease Diabetes ,heart disease, lung disease, chronic nephritis, HTN ... etc.

B. Maternal distress.

2- Fetal:

- Dangers for the fetus (prophylactic forceps), as in the case of prolapsed of a pulsating umbilical cord.
- Abnormal presentations & position: occipito-posterior ,deep transverse arrest, face presentation & after-coming head.
- Large sized fetal head.

- Fetal distress or impeding fetal compromise .
- 3- Prolonged 2nd stage of labor:
- Over 1hr or 2 hrs with anesthesia in multiparae
 - 2hrs or 3 hrs with anesthesia in primigravidae.
 - When the head is on the perineum for 1 hour or more.

-we can use it in C-section, to pick the head up

Complications:

A. Maternal:

- Risks of anesthesia.
- Traumatic lesions of the lower uterine segment, cervix, vagina & perineum.
- Sepsis.
- Obstetric shock.
- Bone injuries: Separation of the symphysis – Dislocation of the sacro-iliac joint – fracture of the coccyx or its dislocation.
- Post partum hemorrhage (traumatic or atonic).
- Vesico-vaginal fistula & stress incontinence.

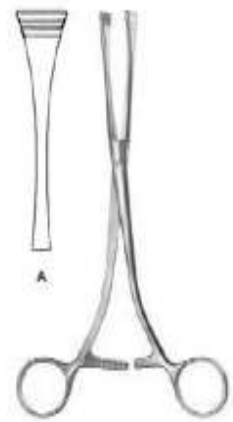
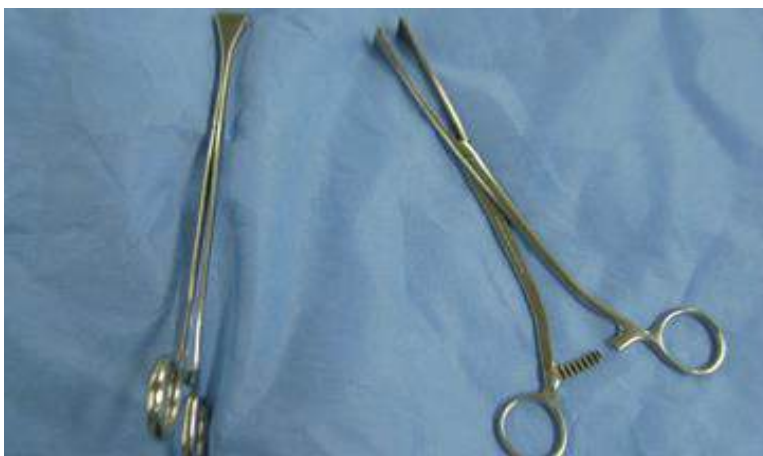B-Fetal:

- soft tissue compression or cranial injury due to incorrectly placed forceps blade , so before pull make sure the blades are closed and locked

Contraindication:

Hx. Of cephalo-pelvic disproportion.

2] Green Armytage forceps:



Indications:

it's a long forceps with **flattened serrated tips** that serve as a

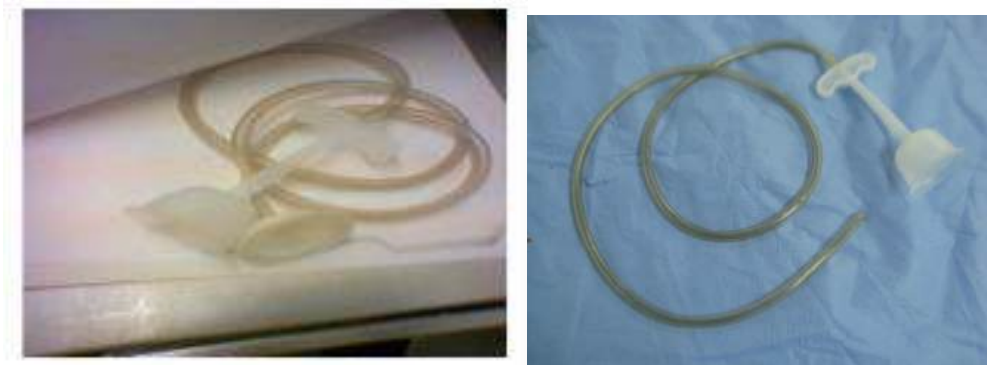holding & as hemostatic instrument.

It's usually used during the operation of the lower uterine segment C-section to hold the flaps of the uterine incision to **control bleeding from the edges & to help in their suturing.**

Complications:

Non

3]The vacuum extractor or ventouse:



Definition: A cup like instrument held against the fetal head for suction under the aid of the mothers pushing

Two types:

- Metal cup ventouse
- plastic cup ventouse.

- Note/ Please remember to write the type of the ventouse in the exam. It's of extreme importance. (e.g. Plastic)

Prerequisites :

- Clinically adequate pelvic dimension
- Experienced operator
- Cervix fully dilated
- Engaged fetal head
- Gestational age greater than 34 wks
- **Fetal head direction not important**

Indications:

- All the indications of forceps delivery EXCEPT face presentation & after- coming head in breech.
- To increase flexion in deflexed head & to help in the forward rotation of the Occiput in occipitoposterior & deep transverse arrest.
- It can be used to control bleeding by traction on the head in

placenta previa.

- It can be utilized to remove the head out of a lower uterine segment C-section.
- It may help to correct inertia in the 1st stage by pulling the head to be well applied to the lower uterine segment & cervix.

Contraindications:

- Face, breech & transverse presentation of the after coming head.
- Premature babies.
- Moderate or severe cephalo-pelvic disproportion.
- Fetal & maternal distress that requires a rapid delivery.

Complications:

- Increase the risk of cervical incompetence.
- Vaginal laceration may occur. **So after apply ventose we put our finger to detect any vaginal wall entrapped**
- Fetal skull injuries: Cephalohematoma, **intracranial hemorrhage** **so we must not apply it directly on the anterior frontalle** & cerebral irritation, sub-aponeurotic hemorrhage & scalp lacerations, necrosis & alopecia.
- Longer delivery time.

Advantages over the forceps:

Mother:

- Less risk of anesthesia, sepsis & trauma.
- Helps in cervical dilation & increases uterine contractions.
- It doesn't occupy space adjacent to the fetal head less trauma & a smaller episiotomy.
- Fetal head orientation is not necessary

Fetus:

- It corrects **mal-attitudes** of the fetal head.
- **Helps in the rotation** of the head.
- Detachment of the fetal cuff during traction is called? pop-off
- I can Pull & Rotate the fetus

For Ventose and forceps try only 3 times, if not successful Go for C-section.

#For normal labor you need three factors :

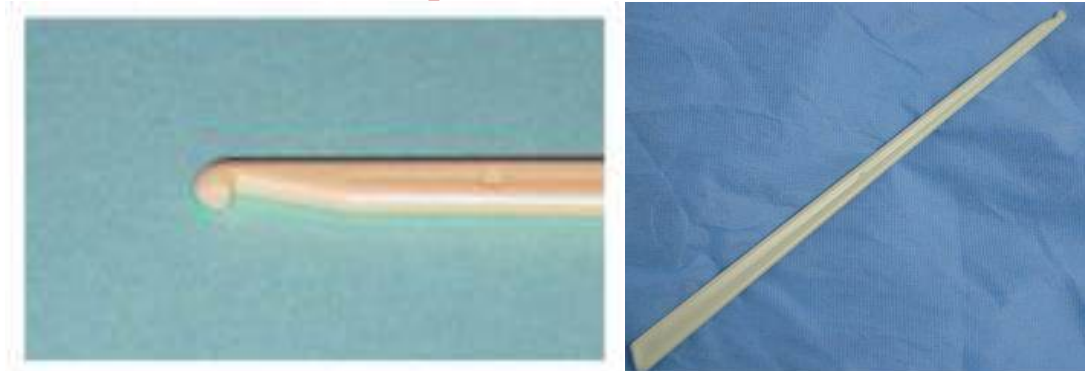
- power , passenger and pelvis

The two important elements for normal progression of labor:

- Engagement
- Cervical dilation

If one of the two is failing you must not use instrumental delivery

4] Amniohook:



It's used for amniotomy. (**Artificial rupture of membranes**).

Indications:

- Prolonged labor, to enhance uterine contractions & fasten labor.
- Fetal distress in CTG in order to check for the presence of meconium. N.B/ After the fetus is engaged & it has been determined that the is in true labor, then the membranes can be ruptured with the Amniohook.

Prerequisites:

- R/O placenta previa to avoid APH
- No infection
- Cervix dilated more than 2cm
- Engagement of the head because if the baby is not engaged may end up by cord prolapse> vasoconstriction of blood vessels (blood vessels inside body is warm, if it goes out – cold environment- it gets restricted, which results in asphyxia.

N.b definition of engagement:

the entrance of the largest diameter of the fetal head into the maternal pelvis

Contraindications:

- Cephalopelvic disproportion.
- Abnormal presentation (with the possible exception of face & breech presentations).
- Unstable lie (for the risk of cord prolapse).
- Fetal distress.
- Placenta previa.
- Vasa previa.
- Cord presentation.
- Invasive carcinoma of the cervix.

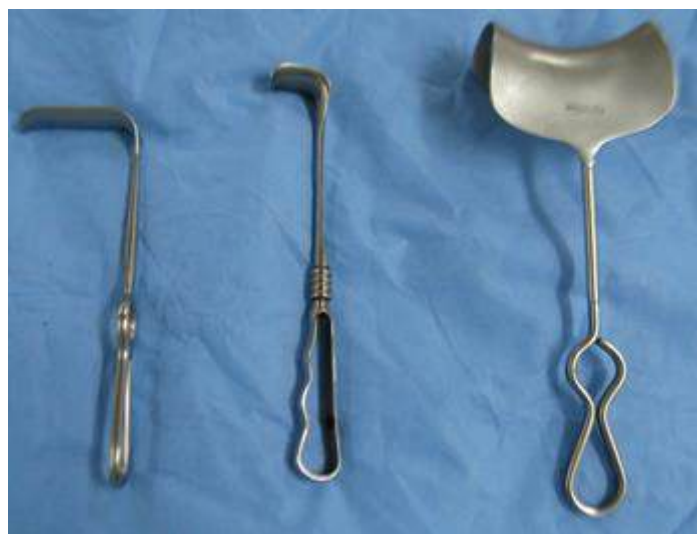Complications:

Trauma, so we cover the head of amniohook by our finger to avoid trauma.

To diagnose “Rupture of membranes”:

- Nitrazine test: It acts according to the pH. It turns the alkaline media from yellow to blue. E.g. Blood, semen & urine. Infection may give a false +ve.
- Ferning test: It's seen by the microscope (by taking a sample from the amniotic fluid & seeing it in the microscope after it dries).

5] Surgical Retractors:



A-Doyn or Doin retractor:

It's used to retract the urinary bladder. And it's used in **C-section** to retract the tissue. They are used to retract the uterus , abdominal wall in abdominal and pelvic surgery

The small one is used for at the uterine angle and so called angled retractor

Requirement: non , only place it correctly

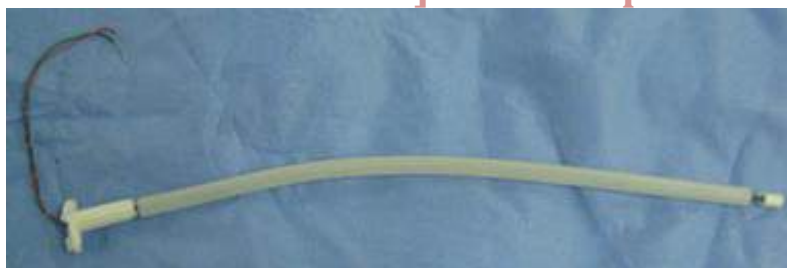Complications: if placed on the uterine segment or retracting the lower abdominal segment may cause bladder contusion and hematuria



Skin retractors:



6] Fetal scalp electrode:



It's used to monitor the baby's heartbeat while he/she is still in the uterus. This device is placed under the skin of the baby's scalp.

prerequisite before application:

- cephalic presentation
- rupture of the membranes

indication:

- fetal heart monitoring
- fetal distress
- accurate fetal surveillance

contraindication:

- face presentation
- active infection in the birth canal

*go over the topic of heart rate monitoring in Kaplan notes pg.125-129

Complications:

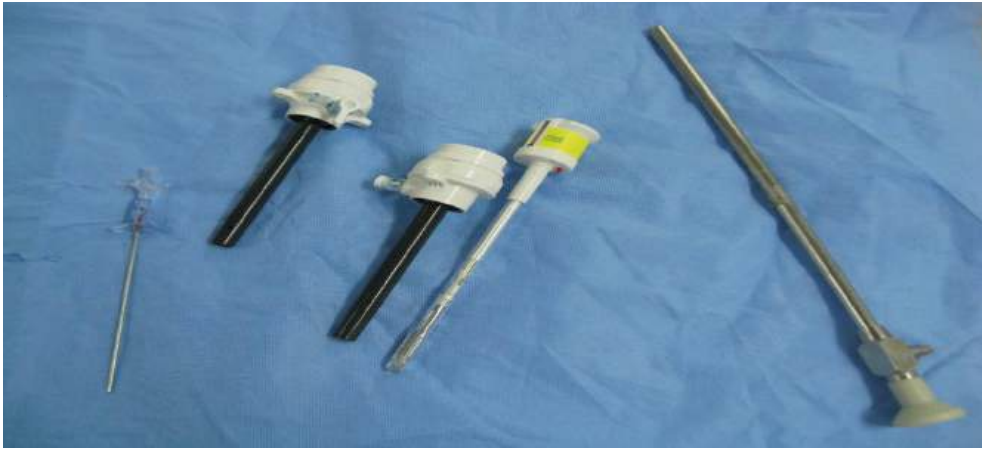- Maternal injury so should be inserted between fingers and in the plastic during insertion.
- Infections (hepatitis , HIV)

7] Pipelle:

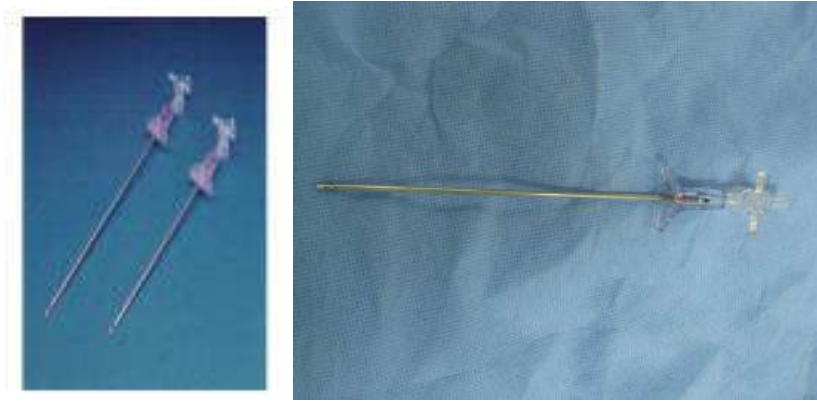


- It's used for endometrial sampling.
- It works by suctioning i.e. -ve pressure.

8] Laparoscopy set:



A-Veress needle:



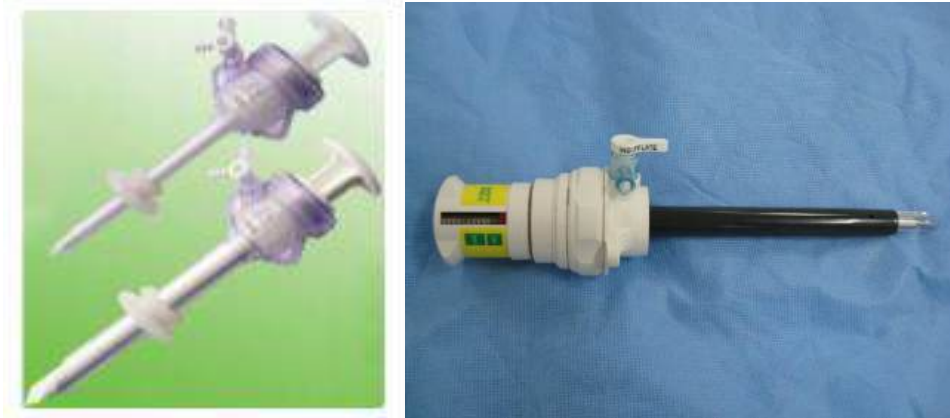Indications of the needle:

- To make the incision in the laparoscopic procedure.
- For **CO₂** inflation of the abdomen prior to laparoscopy. You create Pneumoperitoneum to form a gap between the anterior abdominal wall and the organs → then you place the trochar is used to create a tract → you remove its content and add the laproscope to use the fiber optic lens and create the vision needed to operate

Complications:

- Pneumoperitoneum.
- Injury to a hollow viscous.
- Injury to the vessels in the abdominal wall , bleeding .
- Pelvis inflammatory disease.
- Cervical laceration.
- Uterine perforation.
- Shoulder pain.

B-Trochar (sleeve and needle)& cannula :



C-Laparoscope:



It's used for: Laparoscopy. It is a minimally invasive surgery

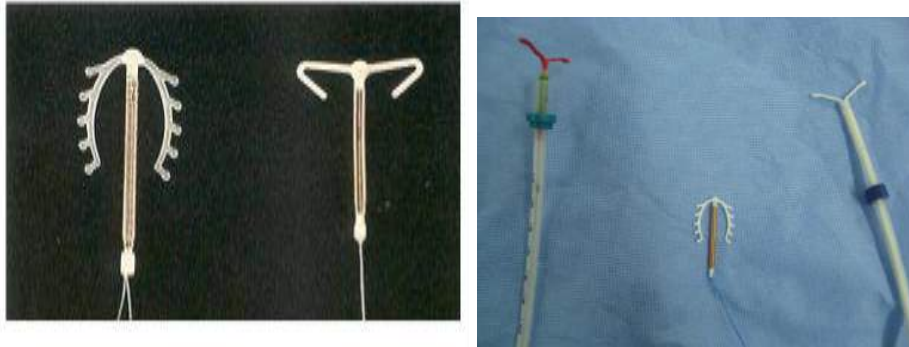Indications:

- 1- Therapeutic: Ectopic pregnancy, tubal ligation and adhenolysis.
- 2- Diagnostic: PID, infertility and endometriosis.

Complications:

- 1- Infection (peritonitis).
- 2- Bleeding (laceration of a vessel).
- 3- Bowel perforation.
- 4- Subcutaneous emphysema.
- 5- Adhesions but more in laparotomy

9] Intrauterine Contraceptive Device (IUCD):



Aim: Contraception.

Types: Hormonal (Mirena and Contains progesterone) and copper. (copper for contraception , hormonal for contraception & patient with abnormal bleeding)

- the thread should be 2-3 cm out of the cervix to pull it when pt wants it out and for checking it every 3 months
- Failure rate 0.3%

Side effects:

- Breast tenderness.
- Pelvic pain.
- Cramping (copper IUCD).
- Increased bleeding during menstruation (copper IUCD).

Advantages:

- 1- It doesn't require daily attention.
- 2- It's immediately effective.
- 3- It's long lasting.
- 4- It's not messy.

Disadvantages:

- It doesn't protect against STDs, including HIV/AIDS.
- Its insertion & removal requires clinical visits.
- Could be expelled.
- May cause difficult menstrual periods.

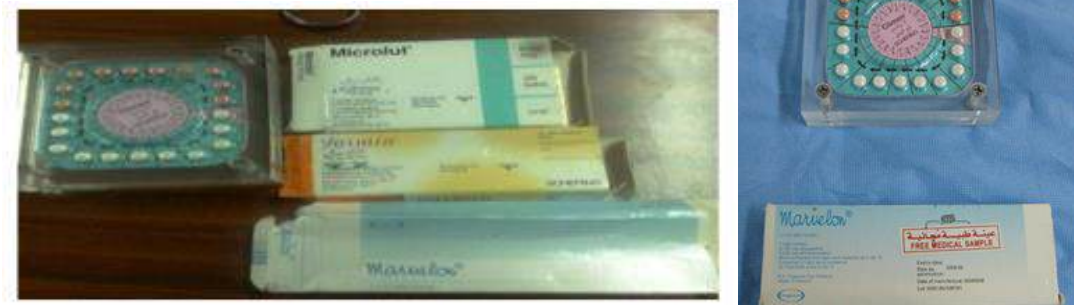Contraindications:

- 1- Pregnancy.
- 2- Current PID.
- 3- Current purulent cervicitis, chlamydial infection or gonorrhoea.
- 4- Undiagnosed vaginal bleeding.
- 5- Previous perforation

Complications:

Perforation, infection & initially both abnormal irregular vaginal bleeding with copper its heavy bleeding

10] Contraceptive Pills:



A-Progestin - only contraceptive pills:

Advantages:

- No estrogen.
- Improve dysmenorrhoea, menorrhagia, PMS & endometriosis symptoms.
- Decreases the risk of endometrial or ovarian cancer.
- Decreases the risk of PID.
- It's compatible with breast feeding.

Disadvantages:

- Menstrual cycle disturbances.
- Weight gain.
- Depression.
- Lack of protection against STDs.

Contraindications:

- Known or suspected pregnancy.
- Unexplained vaginal bleeding.
- Breast cancer.

Medications that cause progestin to be metabolized more rapidly.

- Anti seizure medications: phenytoin, phenobarbital, carbamazepine, primidone & phenbutazone.
- Antibiotics: Rifampin/rifampicine.

B- Combined contraceptive pills:

Advantages:

- Highly effective in preventing pregnancy when taken correctly.
- Not related to coitus.
- Rapid return to fertility after discontinuation. Very safe when prescribed for appropriate users. Can be used throughout the reproductive years.

Health benefits:

- Decreases dysmenorrhea.
- Reduces the risk of developing endometrial & ovarian cancers.
- Suppression of endometriosis.
- Improvement of hot flashes & hormonal fluctuation symptoms in perimenopausal women.
- Improvement of androgen sensitivity or androgen excess conditions (such as PCO).

Side effects:

- 1-Breast tenderness.
- 2-Decrease libido.
- 3-Headache.
- 4-Weight gain.

Disadvantages:

1. Must be taken consistently & correctly to be effective.
2. May interfere with lactation.
3. No protection against STDs.

Complications:

1. Venous thrombosis.
2. MI & stroke.
3. HTN.

Contraindications:

1. Personal Hx of thrombosis & known clotting disorders.
2. Personal Hx stroke & MI.
3. Labile HTN.
4. Active liver disease.
5. Estrogen sensitive malignancy (such as breast cancer).
6. Migraines with focal neurologic symptoms.

How would you differentiate b/w them: Combined always 21 pill.
More than 21 pill = progesterone Only pill.

- Know about the mono di and tri phasic
- Mono only contains progesterone and given to a breast feeding woman where they can't take estrogen as it declines the milk production
- They are given for a 28 days then 5 days after free period they repeat the cycle again whether she gets her period or not
- GO OVER THE DETAILS IN THE LECTURE
- You must know the failure rate of oral contraception and IUD

The doctor said it's very important to know these info. :

COCP: Although the failure rate is 0.1 percent when pills are taken perfectly (same time every day, no missed pills), the actual failure rate is 9 percent over the first year, due primarily to missed pills or forgetting to restart the pill after the seven-day pill-free interval.

Missed pills are a common cause of pregnancy. In general, an active pill should be taken as soon as possible after a pill has been missed. Backup birth control should be used for seven days if more than two pills are missed.

Progestin only pills : are as effective as combination pills when taken at the same time every day, but there is a slightly higher failure rate of the mini pill if the woman is more than three hours late in taking it.

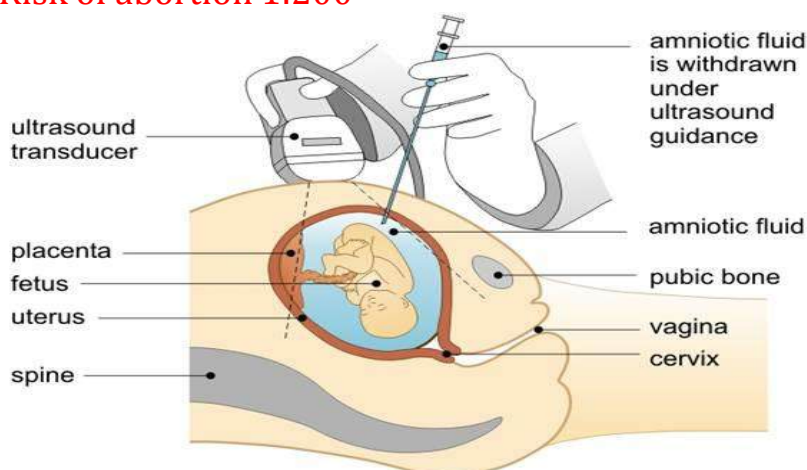
Progestin only pills are taken on a 28-day cycle, and all 28 pills contain hormone. One pill should be taken every day at the same time, and there is no placebo pill week. Breakthrough bleeding or spotting can occur with progestin only pills.

<http://www.uptodate.com/contents/hormonal-methods-of-birth-control-beyond-the-basics>

10] Amniocentesis

- When an US shows abnormal translucency the next step is amniocentesis that is US guided
- It could be diagnostic → 16-20wks → why not before 16wks? High risk of club foot
- Indication :
 - genetic and chromosomal analysis
 - NTD by assessing the AFP levels
 - DNA and assessing inherited disorders like muscular dystrophy
 - RH iso-immunization patients by assessing bilirubin level
 - L/S to assess the fetal lung maturation
- It could be therapeutic → in twin to twin transfusion at any time to reduce the fluid → because they have severe polyhydramnios states and maternal distress
- Its US guided
- Must be away from the placenta and fetus to avoid complications such as → bleeding, fetal head injury
- Anti-d is only given if the mother is RH-ve
- Risks of the procedure include → leaking of the amniotic fluid, abdominal pain, vaginal bleeding, infection, umbilical and fetal head injury, clubfoot (if done before 16 wks), when used therapeutically sudden decompression may cause abruption placenta

Risk of abortion 1:200



Obstetric Procedures:

Cesarean Section

Definition :

the delivery of the fetus through an incision made in the maternal abdomen and uterus

Indications :

- Previous CS
- Dystocia
- Breech
- Fetal distress
- Previous full thickness non-transverse incision through the myometrium (absolute indication)
- Placenta Previa

Contraindications:

- When maternal status may be compromised (eg, mother has severe pulmonary disease)
- If the fetus has a known karyotypic abnormality (trisomy 13 or 18) or known congenital anomaly that may lead to death (anencephaly)

Complications:

- Infection (eg, postpartum endomyometritis, fascial dehiscence, wound, urinary tract)
- Thromboembolic disease (eg, deep venous thrombosis, septic pelvic thrombophlebitis)
- Anesthetic complications
- Surgical injury (eg, uterine lacerations; bladder, bowel, ureteral injuries)
- Uterine atony
- Delayed return of bowel function

Postoperative Care:

in the recovery room

- vital signs are taken every 15 minutes for the first 1-2 hours
- urine output is monitored on an hourly basis

- palpate the fundus to ensure that it feels firm
- Pay attention to the amount of vaginal bleeding.
- if a patient did not receive a long-acting analgesic or had general anesthesia, administer narcotics either intramuscularly (IM) or intravenously (IV)

in their room once stabilized :

- vitals
- urine output
- fluids
- the pt should be encouraged to ambulate
- the catheter should be removed
- the staples should be removed on the third day unless there is a risk factor

Types :

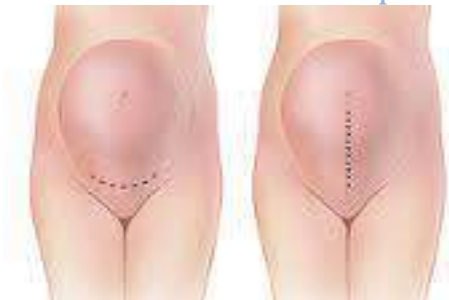- It is classified based on the uterine incision not skin incision 1- low transverse CS → its advantages include lower chance of uterine rupture as opposed to the classical , bleeding , paralytic ileus ,peritonitis , and bowel adhesion

disadvantage: fetus maybe in a longitudinal lie and they will have to change the procedure to classical

- the incision is made in the non-contractile portion

2-classical vertical CS → its indications include : preterm breech with an underdeveloped lower uterine segment , poor access to the lower segment due to a myoma or adhesions or planned hysterectomy .

- the incision is made in the contractile portion



B) Physical examination

Gynecological examination:

Prerequisites:

- 1- Done in special examining room.
- 2- Dorsal position usually “ in vesico-vaginal fistula best done in semi-lateral position”
- 3- The examination done in a good light.
- 4- The patient’s bladder should be empty.

The General examination:

A. WIPE:

- ✓ Wash your hands (bring your own disinfectant)
- ✓ Introduce your self (name & medical student)
- ✓ Permission (explain the procedure & patient consent)
- ✓ Privacy (mention if not applicable)
- ✓ Position of physician (right side of the patient)
- ✓ Position of patient (lying down flat with slightly raised head on a pillow)
- ✓ Exposure (expose abdomen from xiphisternum to pubic symphysis) & mention that a chaperone should be present through the examination

B. General examination:

*(Tell the doctor that you leave it to the end for the sake of time if you do not think you will have time to finish)

1) General appearance: (ABCD)

- ✓ Appearance (age, consciousness, alertness)
- ✓ Body built (thin, normal, obese)
- ✓ Connection (in lines, monitors, mask, chest tube)
- ✓ Color /Complexion
 - Pallor: best seen in the inner surface of the lower lip
 - Jaundice: best seen in the sclera of the lower forinex

- Cyanosis: seen in under surface of the tongue, conjunctiva in central cyanosis & tip of the nose, ear pinna, nails in peripheral cyanosis.

- ✓ Distress (use accessories muscles)

OBGYN specific appearance:

A- Constitution

1. Average feminine constitution

- ✓ Average height (150-200cm)
- ✓ Well developed female sex characters (feminine fat distribution, well developed breast, developed pubic and axillary hair.
- ✓ Pelvic girdle > shoulder girdle

2. Infantile constitution

- ✓ Short < 150cm
- ✓ Undeveloped female sex characters.

3. Masculine constitution

- ✓ Tall
- ✓ Male sex character (hoarseness of voice, hirsutism, muscle bulk)
- ✓ Shoulder girdle > pelvic girdle

B- Weight

- ✓ Determined by thickness of the skin folds or BMI.

✓
$$BMI = \frac{\text{Weight (Kg)}}{\text{height (meters)}^2}$$

- Underweight = <18.5
- Normal weight = 18.5–24.9
- Overweight = 25–29.9
- Obesity = BMI of 30 or greater

- ✓ Normally the weight of a pregnant female increases 2-2.5 kg/month

Excessive weight gain	Excessive weight loss or no gain
Polyhydramnios Multiple pregnancies Occult oedema	Oligohydramnios Intrauterine fetal death Intrauterine growth restriction

C- Height

- ✓ May be
 - Average (150-200cm) - Tall >200cm - Short <150
- ✓ Dystrophia dystocia syndrome
 - Occurs in short stocky patients
 - Signs:
 - Delayed puberty - hirsutism - contracted pelvis - small uterus
 - During pregnancy she is more liable to abortion, PCT and malpresentation
 - During labor she is more liable to
 - Prolong labor - laceration - premature rupture of the membrane
 - Surgical interference (forceps and CS)
 - During Puerperium more liable to puerperal sepsis

D- Gait

- ✓ To comment on the gait the patient must be walking
- ✓ The gait is normal in pregnancy except in late weeks of pregnancy which becomes:
 - Waddling gait: (spinal lordosis and abduction of the thigh) due to engagement mainly in in last few weeks of the primigravida. In the multigravida engagement occurs in the second stage of labor.
 - Limping gait: denotes abnormal pelvis as oblique contracted pelvis.

2) Vital signs:

- ✓ **Pulse**
 - rate ,rhythm, volume, character (character &volume better assessed at the carotid)
 - 60 - 100 beats per minute
 - slight increase of 10-15/min may occur > physiological changes of pregnancy
 - Abnormal pulse maybe (tachycardia , bradycardia, irregular or weak pulse)
- ✓ **Respiratory rate**
 - obtain while taking the pulse

- 16-20 breaths per minute
- **Pregnancy usually associated with hyperventilation**
(progesterone action)
- ✓ **Blood pressure**
 - (90-140/60-90 mm/Hg)
 - Normally the blood pressure during pregnancy tend to hypotensive side due to placental A-V shunt and hemodilution
 - Hypertension during pregnancy may be one of the following (essential hypertension, PET or chronic nephritis)
- ✓ **Temperature**
 - normally 36.6-37.2 c
 - Abnormal increase denote infection

3) Head, neck, chest, back, upper & lower limbs examination:

1) Head

- ✓ Face (acne, hirsutism, malar flush, cyanosis, pallor, jaundice)
- ✓ Mouth (pallor and cyanosis)
- ✓ Eye
 - Sclera (jaundice)
 - Cornea and conjunctiva (anemia, vit A deficiency)
 - Puffiness of the eyelid (early in the morning in chronic nephritis)
- ✓ Lymph nodes submandibular, preauricular, postauricular and occipital (for enlargement)

2) Neck:

- ✓ Thyroid gland (for enlargement)
- ✓ Neck veins (congestive in semi sitting position in heart failure)
- ✓ Lymph nodes (for enlargement)
- ✓ Webbing neck

3) Chest:

- ✓ Thoracic cage (pigeon shaped chest in rickets)
- ✓ Lungs (bronchitis, asthma, TB, emphysema)
- ✓ Heart (HF, valvular disease)

4) Breast examination:

- ✓ Nipple examination (proturtion, retraction, fissure, milky discharge)
- ✓ Scars (previous surgery), palpable mass(tumor), infection (mastitis, abscess)
- ✓ Signs of pregnancy:(enlargement, fullness, increase vascularity, pigmentation of the primary aerola, montgomery sign)

5) Back:

- ✓ Any deformities (kyphosis, sclerosis)
- ✓ Spina bifida
- ✓ Costovertebral angle tenderness (pyelonephritis)

6) Upper & lower limbs:

- ✓ Hirsutism, muscular development in android pelvis, lymph nodes
- ✓ Hand examination
- ✓ In lower limb signs of DVT (swelling, tenderness),oedema ,varicose vein

C-The local examination includes:

A-Inspection.

B-Digital palpation (PV examination)

C- Bimanual examination

D-Speculum Examination

E-Rectal Examination

F-Combined recto-vaginal examination.

A-Inspection:

1. **Mons veneris** (for hair distribution and nodules)

Mons veneris:

the fatty cushion of flesh in human females situated over the junction of the pubic bones.

2. **Clitoris:**

- ✓ Usually removed with the upper part of the labia minora in circumcision
- ✓ Clitoral cyst may be present.

- ✓ Any clitorimegaly should be noted.

3. **Labia majora and minora:**

- ✓ For any swellings, ulcerations, atrophy, degree of development or neoplastic lesions.

4. **Perineum:** (The area between foresheet and anus)

- ✓ Inspected for recto-vaginal fistula or short perineum.

5. **Anal orifice:**

- ✓ Should be inspected.

6. **Vestibule:**

- ✓ Done by gentle separation of two labiae by two fingers.
- ✓ Inspect the triangular area between clitoris above and foresheet below.
- ✓ Inspect external urethral meatus for any redness, discoloration and caruncles (which are benign, distal urethral lesions that are most commonly found in postmenopausal women, although a case of urethral caruncle has also been described in a male)
- ✓ Inspect vaginal orifice for any discharge, bleeding and swelling.
- ✓ Ask the patient to cough or strain and comment on genital prolapse and stress incontinence.

B-digital Palpation

Procedure:

- ✓ Separate the labia majora and minora by the left hand fingers
- ✓ Introduce the lubricated index and middle fingers of the right hand into the vagina with the thumb kept extended.

Palpate and examine the following:

1. **Vaginal wall:** for ulceration, solid tumors and cysts.
2. **Structures related to vagina**
 - ✓ Urethra, bladder palpated through the anterior Vaginal wall.
 - ✓ The rectum palpated through the post. Vaginal wall.

3. Tone of the levator ani:

- ✓ By asking the patient to hold herself, then feel the tone of the muscles.

4. Vaginal fornices:

- ✓ As the vault of the vagina divided by the cervix into anterior, posterior and 2 lateral fornices
- ✓ Examine for (nodules, masses and tenderness)

5. Cervix: Palpated as a projection in the vaginal vault.

- ✓ External Os: in nullipara is a circular pinhole and in multipara in a transverse slit.

- ✓ Direction:

- In ante-version you feel the ant. lip first (the external os directed towards the post. Wall)
- In retro-version you feel the post. Lip first (the external os directed towards the Ant. Wall).

- ✓ Level:

- normally, the lower-end at the ischial spine level, in the presence of prolapse it decreases below this level.

- ✓ Size, Shape:

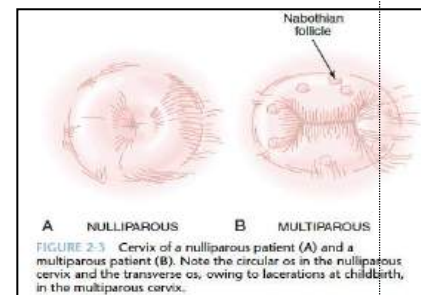
- Chronic cervicitis (enlarged and hard)
- Underdeveloped uterus (long and slender)

- ✓ Mobility: (it can move form side to side without pain)

- Ectopic pregnancy and acute salpingitis cause severe pain on movement.

- ✓ Consistency: (usually firm like the tip of the nose)

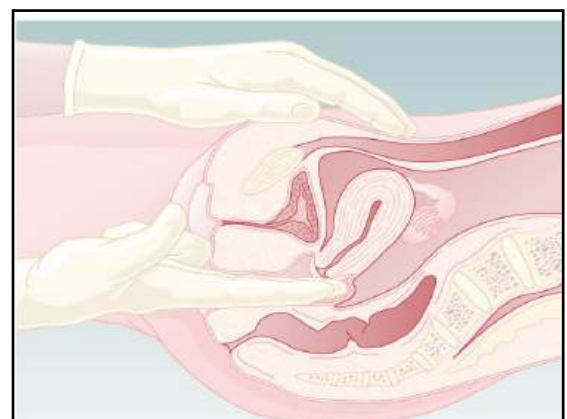
- In pregnancy, it is soft
- In cancer, it is fixed, indurated and friable.



C-Bimanual Examination:

The bimanual pelvic examination provides information about the uterus and adnexa (fallopian tubes and ovaries). The urinary bladder should be empty.

A. Cervix: The cervix is palpated for consistency, contour, size, and



tenderness to motion. If the vaginal fornices are absent, as may occur in postmenopausal women, it is not possible to appreciate the size of the cervix on bimanual examination. This can be determined only on rectovaginal or rectal examination.

B. Uterus: Examine it for → shape, position, mobility, size, tenderness and consistency.

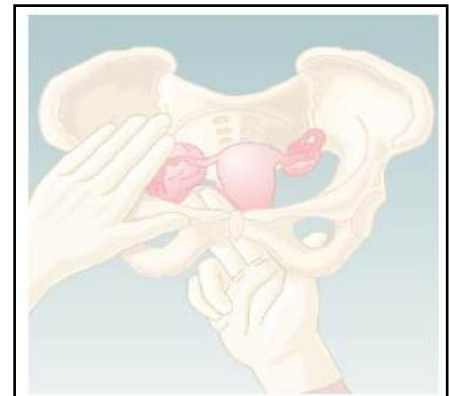
If the muscles of the abdominal wall are not compliant or if the uterus is retroverted, the outline, consistency, and mobility must be determined by ballottement with the vaginal fingers in the fornices; in these circumstances, however, it is impossible to discern uterine size accurately.

Procedure:

1. Place the 2 fingers of the right hand gently below the cervix in the ant. Fornix.
2. Place the flat left hand just above the symphysis pubis.
3. Lift the uterus upward towards the ant. Abdominal wall by the right two fingers.
4. Press both hands together
 - ✓ Ante-verted uterus can be felt between the fingers of both hands
 - ✓ In retro-verted uterus, you will feel the abdominal thickness only

A. For Adnexia (appendages):

Generally, left adnexal masses are more difficult to evaluate than those on the right because of the position of the sigmoid colon on the left side of the pelvis.



Procedure

1. Elevate one of the lateral fornices by the 2 right fingers and the other hand should be presented externally on the lateral uterus.
2. Ovary can be felt in thin female as (small, oval, movable structure)
3. Healthy fallopian tubes are not palpable.

B. For abnormal pelvic swelling

- ✓ Examine for → size, shape, consistency, mobility, tenderness and attachment

C. For blood or discharge

- ✓ Examine for its (odor, consistency and color)

D-Speculum Examination:

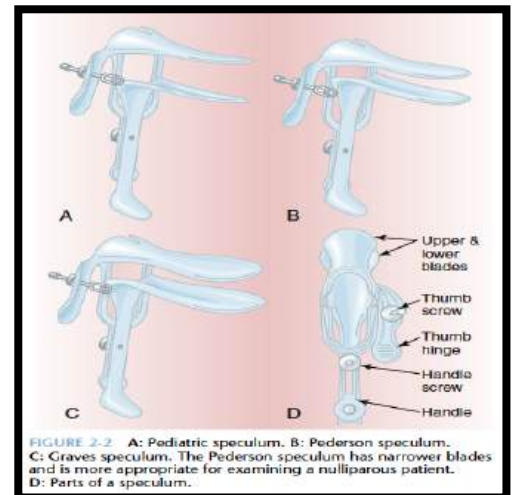
Aims:

1. Inspect the wall of the vagina and cervix for any ulcer, polyp, erosion, cervicitis or tumor.
2. For exposing the external os for the uterine sound

Uterine sound: These sounds or dilators are intended for probing a woman's uterus through the cervix, to measure the length and direction of the cervical canal and uterus, to determine the level of dilation, or to induce further dilation (like in embryo transfer)

3. For exposing the cervix for special tests such as colposcopy.

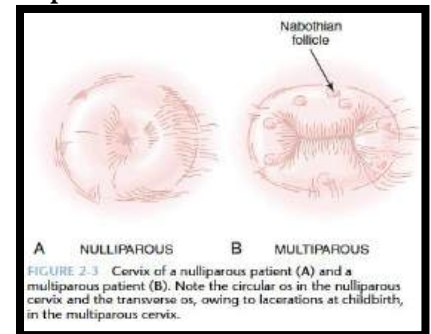
Colposcopy: s a medical diagnostic procedure to examine an illuminated magnified view of the cervix and the tissues of the vagina and vulva.



Procedure:

1. Inspect the wall of the vagina and cervix with an appropriately sized bivalve speculum for any ulcer, polyp, erosion, cervicitis or tumor.
2. The speculum should be warmed and lubricated with warm water only.
3. Gently spreading the labia to expose the introitus.
4. Insert the speculum with the blades entering the introitus transversely.
5. Direct the speculum posteriorly in the axis of the vagina with pressure exerted against the relatively insensitive urethra.
6. As the anterior blade reaches the cervix, the speculum is opened to bring the cervix into view.
7. As the vaginal epithelium is inspected, it is important to rotate the speculum through 90 degrees, so that lesions on the anterior or posterior walls of the vagina ordinarily covered by the blades of the speculum are not overlooked. Examine the vaginal discharge (amount, consistency, color, character)

8. Vaginal wall relaxation should be evaluated using either a Sims' speculum or the posterior blade of a bivalve speculum. The patient is asked to bear down (Valsalva's maneuver) or to cough to demonstrate any stress incontinence. If the patient's complaint involves urinary stress or urgency, this portion of the examination should be carried out before the bladder is emptied.
9. The cervix should be inspected to determine its size, shape, and color.
 - a) The nulliparous patient generally has a conical, unscarred cervix with a circular, centrally placed os
 - b) The multiparous cervix is generally bulbous, and the os has a transverse configuration
10. Any purulent cervical discharge should be cultured. Plugged, distended cervical glands (nabothian follicles) may be seen on the ectocervix.
11. In **premenopausal** women, the squamocolumnar junction of the cervix is usually visible around the cervical os, particularly in patients of low parity.
12. **Postmenopausally**, the junction is invariably retracted within the endocervical canal.
13. A cervical cytologic smear (Papanicolaou, or Pap, smear) should be taken before the speculum is withdrawn.



E-Rectal Examination:

Indicated in:

1. Virgin, a plastic vagina.
2. Recto-vaginal fistula.
3. Diagnosis of rectocele
4. Cervical cancer
5. Patient with rectal complaint
6. Masses in the pouch of Douglas.

Inspect for:

- ✓ Inspect hemorrhoids, lesions, inflammation.
- ✓ Rectal sphincter tone should be recorded and any mucosal lesions noted.
- ✓ A guaiac test should be performed to determine the presence of occult blood.

F-Recto-vaginal Examination:

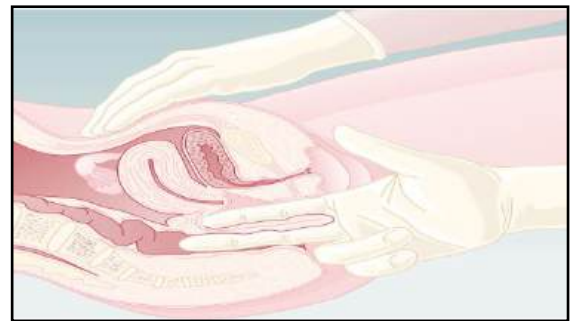
- A rectovaginal examination is helpful in evaluating masses in the cul-de-sac, the rectovaginal septum, or adnexa.
- essential in differentiating between rectocele & an enterocele, so during valsava's maneuver, an enterocele will separate 2 fingers.

Procedure:

- ✓ By inserting the index finger into the vagina and the middle finger into the rectum.

Indications:

In case of masses in pouch of Dougl.



Obstetrics physical examination:

A. WIPE:

- ✓ As In Gynecology part.

B. General examination:

As In Gynecology part. Should be performed as early as possible in the prenatal period so we have the opportunity to detect previous unrecognized abnormalities and have the baseline.

The local examination

1) pelvic examination:

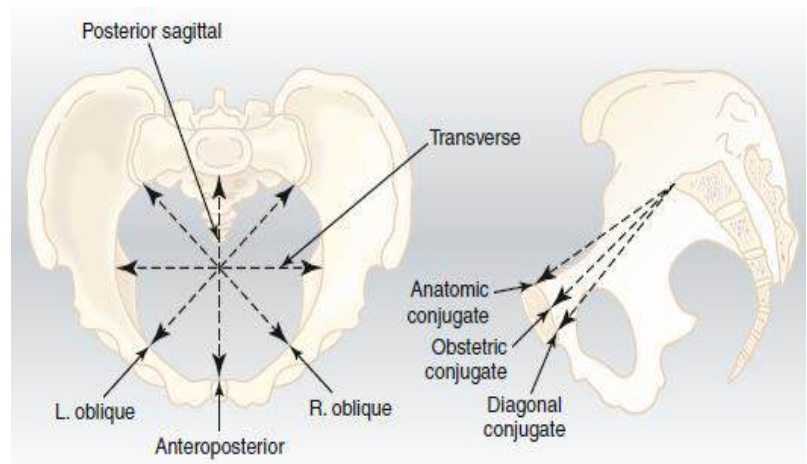
- ✓ The initial pelvic examination should be done early in the prenatal period
 - ✓ It includes: no. 1-3-5 explained in the gyne examination part
1. Inspection of the external genitalia, vagina and cervix
 2. Collection of cytologic specimens from the endocervical canal
 3. Palpation of the cervix, uterus and adnexa
 4. Clinical pelvimetry
 5. Rectal and rectovaginal examination

Clinical pelvimetry

- It is carried out following the bimanual pelvic examination and before the rectal examination
- It is carried out either on the first prenatal visit or later in pregnancy

a. Assessing the pelvic inlet:

- The pelvic inlet is evaluated for its anteroposterior diameter
- The obstetric conjugate can be estimated by subtracting 1.5-2 cm, depending on the height of the pubis from the diagonal conjugate
- The diagonal conjugate: it is estimated by measuring from the lower border of the pubis to the sacral promontory using the tip of the second finger and the point where the base of the index finger meets the pubis (figure)
- If the diagonal conjugate is greater or equal to 11.5 it is considered adequate
- The anterior surface of the sacrum is palpated to assess its curvature: concave (usual), convex (constriction), flat (constriction)



b. Assessing the midpelvic

- Cannot be measured but estimated
- The pelvic side walls: to determine whether they are convergent rather than having the normal almost parallel configuration
- The ischial spines prominence: several passes are made between the spines to determine the bispinous diameter
- The length of the sacrospinous ligament: by placing one finger in the ischial spine and one finger on the sacrum midline the average length is 3 fingerbreadths

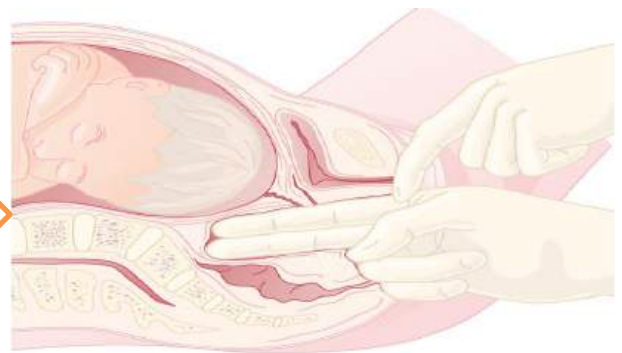
- The sacrospinous notch: is located on the lateral of the ligament if it accommodates 2 and a half fingers its adequate

c. Assessing the pelvic outlet

- Transverse and posterior sagittal measurements: by placing a fist between the tuberosities, transverse: 8.5 cm, posterior sagittal: >8 cm
- Infra pubic angle: by placing a thumb next to each inferior pubic ramus then estimating the angle <90 degree is a contracted pelvis

- Indications for radiological assessment of the pelvis (obstetric history suggestive of pelvis abnormality- pelvic trauma

Clinical estimation of the diagonal conjugate diameter of the pelvis.

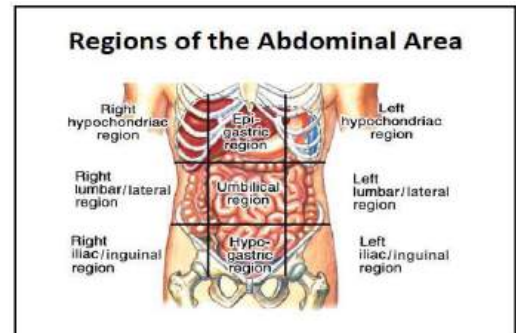
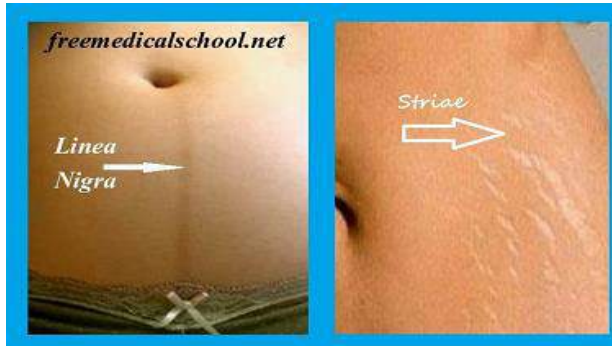


2) Abdominal examination:

General instruction

- ✓ You should be on the right side of the patient to facilitate the movement of the right arm.
- ✓ Examination done by the palm of the hand rather than the tips of the fingers with warm hands (except in some maneuvers)
- ✓ Engage the patient in conversation to decrease the rigidity of the abdominal wall
- ✓ Examine the inguinal canal and inguinal lymph nodes
- ✓ Position and exposure:
 - The patient lies flat with slightly raised head on a pillow
 - Her knees drawn up to decrease rigidity of the abdominal wall.
- ✓ The abdomen is divided into 9 quadrants by two vertical lines (mid clavicular plain which extends from mid clavicular to the mid inguinal) and two horizontal lines the upper horizontal line

(transpyloric plain at the level of the first lumbar vertebra bisects the distance between the umbilicus and xiphisternum)
the lower horizontal line (inter-crestal plane extend between the highest points on the iliac crest)



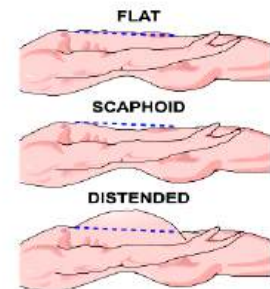
A) Inspection:

1/abdominal contour:

- 1) normally scaphoid
- 2) generalized abdominal bulging (vertical > transverse) in pregnancy
- 3) protuberant (ascities)

2/respiratory movements:

Thoracoabdominal respiration, the abdomen normally moves freely with respiration



3/abdominal skin:

- scars of previous operation (CS, hysterotomy)
- pigmentation (linea nigra, striae gravidarum, pigmentation around the umbilicus)
- stria (rubra (redish), albicans (white))
- dilated veins, fistula, sinuses
- oedema of the abdominal wall

4/umbilicus:

Site, shape (inverted, flat, everted), discharge, discoloration, swelling, nodule

5/hair distribution

- feminine (trisangular with horizontal upper border)
- masculine distribution (extension of the pubic hair towards the umbilicus)

6/hernial orifices

cough impulse : ask patient to cough and look at the hernial orifices (umbilical, paraumbilical, inguinal, incisional)

7/divarication of the recti

Causes of abdominal enlargement (7F & ovarian tumor)

(fetus, false pregnancy, flatus, fat, full bladder, fluid, fibroid, ovarian tumor)

B) Palpation:

1/ superficial palpation:

By using the flat of the hand gently looking for tenderness or rigidity

2/deep palpation:

a-palpation abdominal organs(liver,spleen ,kidney)

b-palpation of pregnant uterus:

1)fundal level:

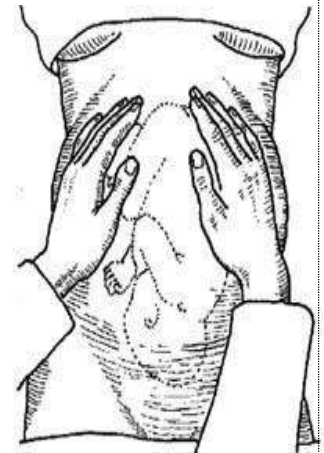
Maneuver: (palpation done by the ulnar border of the left hand from the xiphisternum downward to feel the first resistance which is the fundus

Determined the gestational age as follow:

- ✓ At 12 w....felt at the upper border of symphysis pubis
- ✓ At 24 w..felt at the level of umbilicus
- ✓ At 36 w..felt at xiphisternum
- ✓ After 36 w especially in primigravida the level of the fundus descend in the last few weeks duo to engagment of the presenting part to the level coincide with the fundus at the level of 32 weeks so you should differentiate between them

	Uterus at 32 wk	Uterus at 40 wk
History		
LNMP	Since 32 wk	Since 40 wk
Quickening	Since 12-14 wk	Since 20-22
Lightening	(-)ve	(+)ve
Pelvic pressure symptoms	(-)ve	(+)ve
Examination		
Uterus	No shelving	Broad, large,shelved
Head	Not engaged	Engaged
Tone of foetus	Soft	Firm
Amount of liquer	small	great
investigations	Ultrasonography	

Shelving of uterine fundus: at 40th week fundus sinks down below 36th week but lies above 32 week. Shape of uterine fundus becomes spherical near term pregnancy compared to cylindrical shape upto 38th week.



2) Fundal grip : 1st Leopold's maneuver

Maneuver:

by grasping the fundus of the uterus by the palms of the 2 hands with your fingers quite close together

Aim of fundal grip: to determine which part of the fetus occupying the fundus

- ✓ **In the transverse lie**..... empty 0.5%
- ✓ **In the longitudinal lie**.....breach 96%, head 3.5%

You can differentiate between head & breech :

	Head	Breech
Shape, size	-Round,regular, small	Irregular, large
Consistency	hard	Soft
Tenderness	Cause tenderness	No cause
Ballotable	ballotable	not ballotable
Change of contour with Foetus movement	No change	Change in shape and contour
Foetus movment	Away from the examining hand	Under the examining hand

- ✓ If you feel :soft bulky irregular ,not tender, not ballotable.....it is a BREECH
- ✓ If you feel : hard ,small, regular, tender, ballotable.....it is a HEAD

3)umbilical grip : 2nd Leopold's maneuver

by 2 methodes

1- first method :

One hand used to support the uterus and the level of the umbilicus,other hand is used to palpate the

other side of the uterus from above downwards in three lines (paramedian, midclavicular, midaxillary)
2-second method:

Two hands are laid side by side at the level of the umbilicus and palpate the structure underneath them, one hand supports and the other palpates the uterus and compare

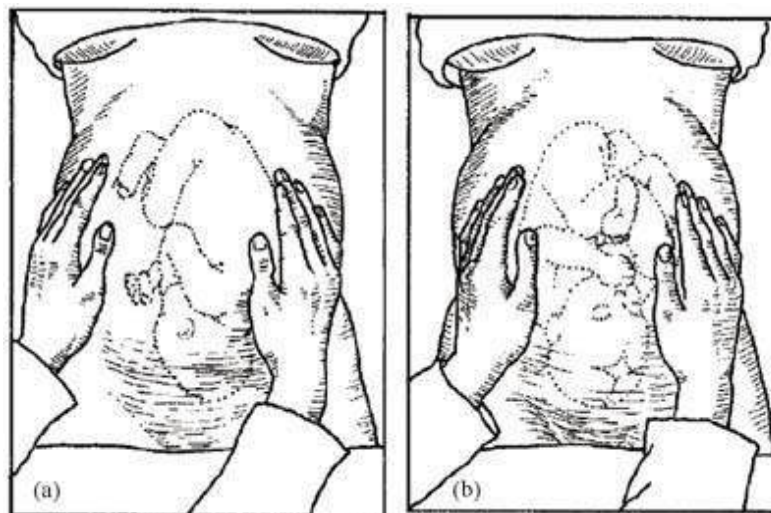
Aim from umbilical grip:

1-determine the position of the fetal back (anterior or posterior & whether right or left)

The back is felt as a smooth continuous curve from head to the breech

2- determine the position of the head and breech in transverse lie

3-site of the anterior shoulder to hear the (FHS)



4) First pelvic grip: 3rd Leopold's maneuver (Pawlick's grip)

Maneuver

1. by sitting beside the patient while she is supine with flexed hip and knee
2. try to catch the lower uterine segment by the right hand which the palm resting on the symphysis pubis
3. the thumb is parallel to the right inguinal ligament and the other four fingers is parallel to the left inguinal ligament
4. try to feel the presented part between the thumb and other 4 fingers

Aim from first pelvic grip:

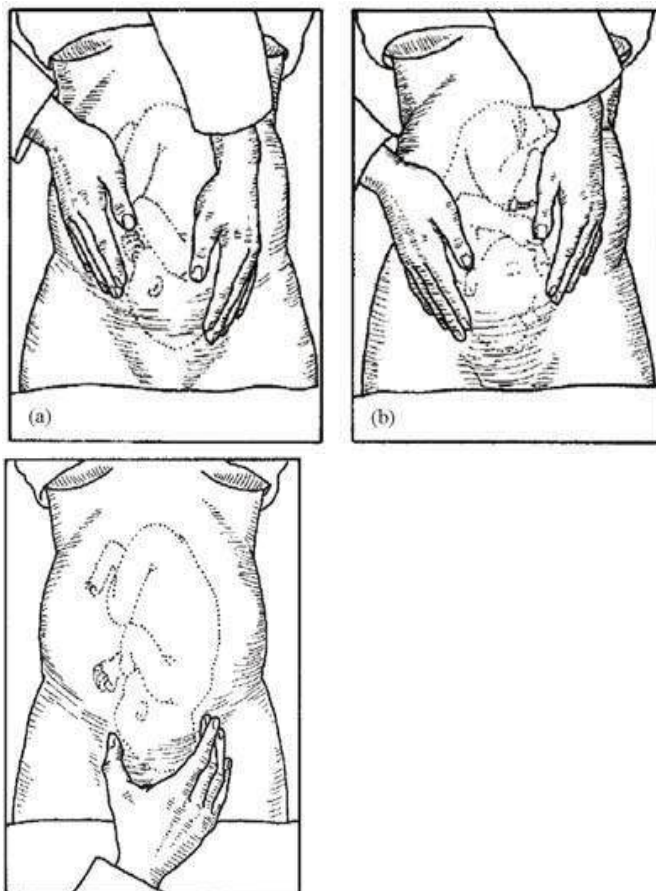
1. To determine the presenting part (head, breech)&
2. To determine the relation of the presenting part to pelvic inlet
3. N.B all the previous maneuvers done with looking towards the patient's face

5) Second pelvic grip: 4th Leopold's maneuver:

1. now you turn your face towards the patient's feet
2. the two hands are placed flat on both sides of the lower part of the abdomen and push there downward towards the pelvis and feel the sides of the presenting part by your fingers

Aim from second pelvic grip:

1. To determine the attitude of the head
 - completely flexedocciput lower than the sinciput
 - completely extended.....occiput higher than sinciput
 - military(deflexed)occiput &sinciput at the same level
2. To determine the engagement

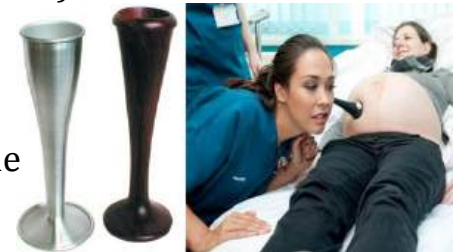

C) Percussion:

- ✓ The normal abdomen is resonant on percussion because the intestine are full of gases
- ✓ Ascitis give central resonance and dull flanks as the fluid fill the flanks and the intestine float on the fluid to be central
- ✓ Shifting dullness...by asking the patient to lie in one side after fixing the head on the oppisit side,the flanks become resonant
- ✓ Fluid thrillfound in (ascitis,internal hemorrhage ,hydramnios,distended bladder,large unilocular ovarian cyst)

D) Auscultation:

1. normally the intestinal sound ,aortic pulsation(in thin female) are heard
2. value of the intestinal sound:
Absent in (paralytic ileus,peritonitis)
Aggravated in (mechanical intestinal obstruction)
3. uterine souffle&funic souffle
4. fetal heart sounds(FHS) heard by:
 - ✓ 1)pinards fetal stethoscope
 - ✓ 2)sonicaid by using ultrasound principle



Importance:

1. Sure sign of pregnancy
2. Sure proof of a living fetus
3. To confirm the fetal presentation
 - ✓ CephalicFHS heard below the umbilicus
 - ✓ Breech.....FHS heard above the umbilicus
 - ✓ Transverse lineFHS heard on one side of the umbilicus
4. Determination of the fetal position
5. To diagnose twins in which 2 fetal heart sounds with difference of 10 beats/min or more heard by 2 physicians at the same time

Helpful vedios:

<https://youtu.be/GSshV8k3JWM>

<https://youtu.be/xb12lkpbfTQ>

signs of pregnancy

presumptive signs

- ✓ are non specific skin and mucos changes
- ✓ discoloration and cynosis of the vulvua, vagina and cervix
- ✓ Chadwick sign: dark discoloration of the vulva and vaginal wall
- ✓ Linea nigra: pigmentation in the midline of the lower abdomen
- ✓ Chloasma/ mask of pregnancy: pigmentation under the eye

Probable signs

- ✓ Are related to the uterine changes
- ✓ In early pregnancy: the uterus changes in size(enlarges anteroposterior), shape(globular) and consistency(soft).
- ✓ Hegar's sign:the uterus is soft you can palpate/ compress the connection between the cervix and fundus
- ✓ Asymetrical implantation: one cornuo of the uterus enlarges (piskacek's sign)

Positive signs

- ✓ Are fetal heartbeat and fetal movment
- ✓ Fetal heartbeat: using doppler heartbeats postive at (9-12 wk) using the stethoscope (16-20wk)
- ✓ Fetal movment: multiparous (15-17wk) primigravida (18-20 wk)

PV examination during labour:

A:

1. Check the woman understands the purpose of the examination.
2. Ask if she has had a vaginal examination before, and discuss any concerns regarding her previous experience.
3. Inform the woman that the examination should not be painful but may be uncomfortable and take the consent.

Note:

-Why to use P.V in Labor?

1. To assess changes to the cervix (e.g. dilation)
2. To assess how far the baby has moved down into the pelvis
3. To determine the presenting part of the baby; whether the baby is (cephalic) or (breech)
4. To check the position of the umbilical cord once the waters have broken

B:

-Inspect the external genitalia and note any

- Blood loss
- Evidence of amniotic fluid- noting color
- Discharge- amount, color, odor
- Lesions on the perineum
- Oedema , -Varicosities
- Separate the labia with the non examining hand, gently insert lubricated fingers into the vagina.

Notes:

- Vaginal examinations shall NOT be carried out if :
 1. Ruptured membranes in women who are not in labor.
 2. Presence of active Herpes Simplex Virus (HSV) lesions in a woman with ruptured
 3. membranes unless the woman is in labor.
 4. Unknown placental localization.
 5. Placenta praevia

C:

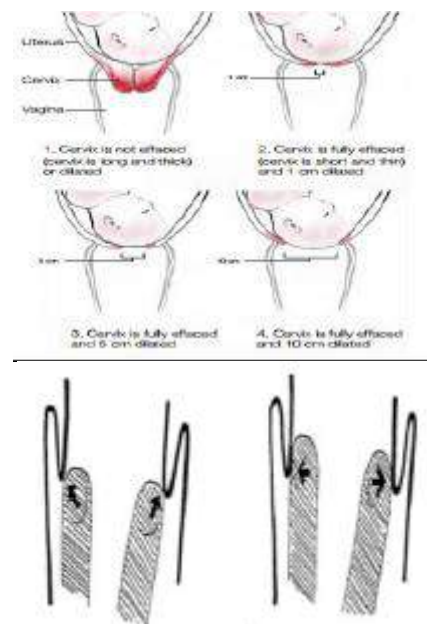
Locate the cervix and determine:

- Length
- Position (Anterior, posterior)
- Consistency (soft, hard)
- Dilatation
- Leakage of fluid

Notes:

- When the cervix is fully effaced there will be no endocervical canal, only a ring of thin cervix.
The length of the cervix is measured in centimeters

- Dilatation must be assessed in centimeters



D:

Assess the presenting part

Notes:

-When palpating the presenting part on vaginal examination, there are 4 important questions that you must ask yourself:

1. What is the PRESENTING PART, e.g. head, breech or shoulder?
2. If the head is presenting, what is the PRESENTATION, e.g. vertex, brow or face presentation?
3. What is the POSITION of the presenting part in relation to the mother's pelvis?
4. If the presentation is vertex brow, is MOULDING present?

E:

Assessment of the membranes

Notes:

(intact or ruptured)

F:

palpate the ischial spines to determine the station .

Notes:

(-3,-2,-1,0,+1,+2,+3)

To complete the examination:

1-wash hands

2- Summarize the findings: (eg:- “fundal height is 36cm which is in keeping with the current gestation. The fetus is in a longitudinal lie, with cephalic presentation, 2/5th’s palpable with a regular heart rate)

3- Re-cover patient - allow patient to re-dress in privacy

4- Thank the patient

Delivery of the placenta

- ✓ Separation occurs 2-10 min of the end of the second stage of the labor
- ✓ **Signs of placenta separation**
 1. a fresh show of blood from the vagina
 2. the umbilical cord lengthens
 3. the fundus of the uterus becomes firm and globular
- ✓ only when these signs have appeared you should attempt traction of the cord
- ✓ **method** : Once signs of separation have occurred the placenta may be delivered .the left hand is placed suprapubically holding the uterine fundus in the abdomen. The right hand is placed on the cord and gentle downward traction

- ✓ **after separation**: look for any bleeding that may originate from the implantation site, uterine contraction may be induced to reduce bleeding by uterine massage and the use of oxytocin
- ✓ the placenta should be examined to ensure its complete and to detect for any abnormalities
- ✓ Blood loss should be estimated; it is usually between 100 and 300ml
- ✓ Any tear or episiotomy should be carefully repaired under local anaesthetic

- ✓ **manual removal indications**: risk of postpartum hemorrhage (multiple gestation- hydromnios- prolong labor)

*Wish You All The Best,
For mistakes or feedback;
Shahdalawwad94@gmail.com*