

**Dorel Sâmpolean**

**Călin-Vasile Vlad**

# **CLINICAL SEMIOLOGY**

*First English edition*

Bioflux Publishing House, Cluj-Napoca, 2019

ISBN 978-606-8887-48-7

Dorel Sâmpolean, Călin-Vasile Vlad, editors

## **Clinical Semiology**

*First English edition*

**2019**

### **Translated and revised from:**

*"Semiologie Clinică Medicală", 2013, "Iuliu Hațieganu" University  
Publishing House, Cluj-Napoca, Romania, ISBN: 978-973-693-549-7*

### **Contributing authors:**

Dorel Sâmpolean

Călin Vasile Vlad

Lorena Ciumărnean

Mircea Vasile Milaciu

Mirela-Georgiana Perné

### **Translation:**

Ioana Robu

### **Scientific reviewers**

Dr. Ștefan Cristian Vesa, "Iuliu Hațieganu" University of Medicine and  
Pharmacy

Dr. Sonia Irina Vlaicu, "Iuliu Hațieganu" University of Medicine and  
Pharmacy

## **Author`s affiliation**

### **Dorel Sâmpolean**

*Associate Professor, IVth Medical Clinic, Department of Internal Medicine, "Iuliu Hațieganu" University of Medicine and Pharmacy, Cluj-Napoca, Romania*

### **Călin Vasile Vlad**

*Senior Lecturer, IVth Medical Clinic, Department of Internal Medicine, "Iuliu Hațieganu" University of Medicine and Pharmacy, Cluj-Napoca, Romania*

### **Lorena Ciumărnean**

*Senior Lecturer, IVth Medical Clinic, Department of Internal Medicine, "Iuliu Hațieganu" University of Medicine and Pharmacy, Cluj-Napoca, Romania*

### **Mircea Vasile Milaciu**

*Assistant Lecturer, IVth Medical Clinic, Department of Internal Medicine, "Iuliu Hațieganu" University of Medicine and Pharmacy, Cluj-Napoca, Romania*

### **Mirela-Georgiana Perné**

*Assistant Lecturer, IVth Medical Clinic, Department of Internal Medicine, "Iuliu Hațieganu" University of Medicine and Pharmacy, Cluj-Napoca, Romania*

# Table of Contents

<b>CHAPTER 1. GENERAL SEMIOLOGY .....</b>	<b>8</b>
1.1. INTRODUCTION .....	8
1.2. ANAMNESIS (PATIENT HISTORY).....	9
1.3. GENERAL PHYSICAL EXAMINATION.....	19
1.3.1. METHODS AND TECHNIQUES.....	19
1.3.2. CONSTITUTIONAL TYPE.....	25
1.3.3. THE CONSCIOUS STATE AND ITS SYNDROMES .....	26
1.3.4. ATTITUDE .....	29
1.3.5. WALKING DISTURBANCES .....	32
1.3.6. INVOLUNTARY MOVEMENTS .....	33
1.3.7. THE FACIES.....	34
1.3.8. THE COLOR OF SKIN AND MUCOSAE .....	47
1.3.9. CUTANEOUS HEMORRHAGE (PURPURA) .....	64
1.3.10. SKIN LESIONS .....	68
1.3.11. COLLATERAL CIRCULATION .....	78
1.3.12. TROPHIC DISORDERS .....	83
1.3.13. EDEMA .....	94
1.3.14. THE NUTRITIONAL STATUS .....	102
1.3.15. THE ADENOPATHIES .....	107
1.3.16. THE MUSCULAR SYSTEM.....	113
1.3.17. THE OSTEOARTICULAR SYSTEM.....	115
1.3.18. CHANGES OF BODY TEMPERATURE .....	122
<b>CHAPTER 2. THE RESPIRATORY SYSTEM .....</b>	<b>127</b>
2.1. ANAMNESIS .....	127
2.1.1. CHEST PAIN .....	130
2.1.2. DYSPNEA.....	135
2.1.3. HEMOPTYSIS .....	141
2.1.4 COUGH.....	145
2.2. GENERAL PHYSICAL EXAMINATION.....	150
2.3. PHYSICAL EXAMINATION OF THE UPPER AIRWAYS.....	153
2.4. PHYSICAL EXAMINATION OF THE CHEST .....	153
2.4.1. INSPECTION .....	153
2.4.2. PALPATION.....	157
2.4.3. PERCUSSION.....	160
2.4.4. AUSCULTATION.....	163

**CHAPTER 3. CLINICAL RESPIRATORY SYNDROMES..... 169**

3.1. PULMONARY CONDENSATION SYNDROME..... 169  
3.1.1. PULMONARY CONDENSATION SYNDROME THROUGH INFILTRATION..... 169  
3.1.2. PULMONARY CONDENSATION SYNDROME THROUGH ATELECTASIS ..... 171  
3.1.3. PULMONARY CONDENSATION SYNDROME IN PNEUMONIA..... 173  
3.1.4. SYNDROMES IN LUNG CANCER..... 176  
3.2. PLEURAL EFFUSION SYNDROME ..... 178  
3.3. BRONCHIAL SYNDROME..... 185  
3.3.1. BRONCHIAL SYNDROME IN ACUTE BRONCHITIS ..... 186  
3.3.2. BRONCHIAL SYNDROME IN CHRONIC OBSTRUCTIVE PULMONARY DISEASE..... 186  
3.3.3. BRONCHIAL SYNDROME IN BRONCHIAL ASTHMA ..... 190  
3.4. CAVITARY SYNDROME..... 194  
3.4.1. CAVITARY SYNDROME THROUGH LUNG CAVITIES .... 194  
3.4.2. CAVITARY SYNDROME IN PNEUMOTHORAX OPEN INTO A BRONCHUS ..... 194  
3.4.3. BRONCHOPULMONARY SUPPURATIONS..... 195  
3.4.4. CAVITARY SYNDROME IN LUNG ABSCESS ..... 195  
3.4.5. BRONCHIECTASIS ..... 197  
3.5. MEDIASTINAL SYNDROME..... 199

**CHAPTER 4. THE CARDIOVASCULAR SYSTEM ..... 201**

4.1. ANAMNESIS ..... 201  
4.2. CARDIAC SYMPTOMS ..... 206  
4.2.1. CARDIAC DYSPNEA ..... 206  
4.2.2. PALPITATIONS ..... 208  
4.2.3. CARDIOVASCULAR PAIN ..... 208  
4.3. PHYSICAL EXAMINATION ..... 211  
4.3.1. GENERAL PHYSICAL EXAMINATION..... 211  
4.3.2. PHYSICAL EXAMINATION OF THE HEART ..... 213  
4.4. SEMIOLOGY OF THE ARTERIES ..... 220  
4.4.1. ANAMNESIS..... 220  
4.4.2. PHYSICAL EXAMINATION ..... 222  
4.5. SEMIOLOGY OF THE VEINS ..... 228  
4.5.1. ANAMNESIS..... 228  
4.5.2. PHYSICAL EXAMINATION ..... 229

<b>CHAPTER 5. CLINICAL CARDIOVASCULAR SYNDROMES</b> .....	<b>233</b>
5.1. MYOCARDIAL SYNDROME.....	233
5.2. HEART FAILURE .....	235
5.2.1. LEFT VENTRICULAR FAILURE .....	239
5.2.2. RIGHT VENTRICULAR FAILURE.....	243
5.2.3. GLOBAL HEART FAILURE .....	246
5.3. VALVULAR SYNDROMES.....	248
5.3.1. MITRAL STENOSIS.....	248
5.3.2. MITRAL INSUFFICIENCY .....	252
5.3.3. AORTIC STENOSIS .....	254
5.3.4. AORTIC INSUFFICIENCY .....	257
5.4. PERICARDIAL SYNDROME.....	259
5.4.1. ACUTE FIBRINOUS PERICARDITIS .....	259
5.4.2. CHRONIC CONSTRICTIVE PERICARDITIS.....	261
5.5. ISCHEMIC HEART DISEASE.....	262
5.5.1. ANGINA PECTORIS .....	262
5.5.2. ACUTE MYOCARDIAL INFARCTION.....	267
5.6. RHYTHM AND CONDUCTION DISORDERS .....	272
5.6.1. SUPRAVENTRICULAR TACHYARRHYTHMIA .....	273
5.6.2. VENTRICULAR TACHYARRHYTHMIA .....	275
5.6.3. BRADYARRHYTHMIA.....	277
5.7. SHOCK, SYNCOPE, LIPOTHYMIA .....	278
5.8. ARTERIAL HYPERTENSION.....	281
5.9. CHRONIC OBLITERATING ARTERIOPATHY OF THE LOWER LIMBS .....	284
5.10. THROMBOTIC SYNDROME.....	286
<b>CHAPTER 6. THE RENAL-URINARY SYSTEM</b> .....	<b>291</b>
6.1. ANAMNESIS .....	291
6.2. RENAL-URINARY SYMPTOMS.....	293
6.3. GENERAL OBJECTIVE EXAMINATION .....	297
6.4. THE OBJECTIVE EXAMINATION OF THE URINARY SYSTEM .....	298
6.5. DIURESIS DISORDERS.....	301
6.6. HEMATURIA .....	303
6.6. PYURIA and LEUKOCYTURIA.....	305
<b>CHAPTER 7. CLINICAL RENAL SYNDROMES</b> .....	<b>307</b>
7.1. ACUTE RENAL FAILURE.....	307
7.2. CHRONIC RENAL FAILURE .....	309

7.3. THE NEPHRITIC SYNDROME .....	312
7.4. THE NEPHROTIC SYNDROME .....	316
7.5. ACUTE PYELONEPHRITIS .....	317
7.5. CHRONIC PYELONEPHRITIS .....	319
<b>CHAPTER 8. THE GASTROINTESTINAL SYSTEM .....</b>	<b>321</b>
8.1. SEMIOLOGY OF THE ORAL CAVITY AND THE PHARYNX ...	321
8.1.1. Patient history .....	321
8.1.2. Symptoms of the diseases of the oro-pharyngeal cavity .....	323
8.1.3. Clinical examination of the oral cavity .....	325
8.1.4. Paraclinical investigations .....	336
8.2. SEMIOLOGY OF THE ABDOMEN .....	337
8.2.1. SYMPTOMS IN ABDOMINAL DISEASES .....	337
8.2.2. OBJECTIVE EXAMINATION OF THE ABDOMEN .....	344
8.3. DYSPEPTIC SYNDROMES .....	358
8.4. SEMIOLOGY OF THE ESOPHAGUS .....	359
8.5. SEMIOLOGY OF THE STOMACH AND THE DUODENUM .....	361
8.6. SEMIOLOGY OF THE INTESTINE .....	370
8.7. SYNDROMES IN INTESTINAL DISEASES .....	379
8.7.1. THE DIARRHEIC SYNDROME.....	379
8.7.2. CONSTIPATION SYNDROME .....	381
8.7.3. ANO-RECTO-SIGMOID SYNDROME .....	382
8.7.4. ACUTE PERITONEAL SYNDROME.....	383
8.8. SEMIOLOGY OF THE LIVER .....	385
8.9. SEMIOLOGY OF THE GALLBLADDER .....	394
8. 10. SEMIOLOGY OF THE EXOCRINE PANCREAS.....	398
<b>CHAPTER 9. THE BLOOD FORMING SYSTEM .....</b>	<b>405</b>
9.1. Patient history .....	405
9.2. GENERAL OBJECTIVE EXAMINATION .....	406
9.3. EXAMINATION BY BODY SYSTEMS .....	408
9.4. HEMATOLOGICAL TESTS .....	408
<b>BIBLIOGRAPHY .....</b>	<b>411</b>

# CHAPTER 1. GENERAL SEMIOLOGY

## 1.1. INTRODUCTION

**Semiology** is the clinical discipline which deals with the study, description and interpretation of symptoms and signs of the ill person (*semeion*=sign, *logos*=science)

### **Objective**

- To establish the *diagnosis* (diagnosis=critical thinking) with its two components:
  - Positive diagnosis, exact determination of the disease;
  - Differential diagnosis, differentiating the disease from other disorders with similar manifestations.
- To evaluate the *evolution* and the *prognosis* of the disease.

Semiology constitutes the “ABC and grammar of the clinic” (I. Goia).

### **Method and contents**

There are:

- Clinical methods: anamnesis, objective examination (clinical, physical)
- Complementary methods: laboratory, para-clinical data (various explorations)

### **Clinical data:**

- Subjective: they represent the complaints of the patient, experienced and told by the patient and are called symptoms (eg. pain, nausea, dyspnea).
- Objective: they are the findings obtained by the doctor through examining the patient and are called signs (pallor, edema, obesity).



It is wrongly assumed that any symptom is a manifestation of a disease, although a symptom can sometimes coincide with a sign (eg.: sudden pain + symptom and pain caused at palpation=sign).

Complementary data: obtained through various technical methods of investigation (biochemical, bacteriological, radiological etc.) these explorations do not replace the clinical data but instead follow and complete them.

Establishing the diagnosis is done according to clinical and complementary data and is carried out through an analysis and synthesis process called logic or medical thinking having as a result the establishing of groups of symptoms and signs with a common pathophysiological mechanism and different causes called *syndromes*.

The syndrome represents a collection of symptoms and signs which can be encountered in one or several diseases (e.g. the anemic syndrome, the pleural fluid syndrome).

*Medical propedeutics* assimilates the analytical aspect (collecting, studying and interpreting symptoms, signs and para-clinical data).

**The clinical diagnosis** implies establishing the diagnosis solely on the basis of clinical data (for example, the pleural syndrome: thoracic cramp, fever, dry cough, dullness, diminished vesicular murmur).

**Positive diagnosis** (disease) is formulated on the basis of para-clinical explorations (e.g.: pleural syndrome – pleuresia) and comprises several aspects: etiologic diagnosis, anatomy, functional, progressive, of morbid complications and associations. The positive diagnosis is followed by establishing a *therapy* and a *prognosis*.

## **1.2. ANAMNESIS (PATIENT HISTORY)**

Anamnesis (ana + mnesis = remembering) represents the totality of data obtained by the practitioner during their conversation with the

sick patient or his acquaintances. The importance of anamnesis in the diagnosis is very high due to the fact that it:

- helps highlight the symptoms in the initial stages of the disease, when morphological changes can be minimal, not evidenced by the objective exam
- may represent the only method of diagnosing a disease (e.g. angina pectoris)
- sometimes indicates the cause of disease: trauma, professional noxes
- steers the objective exam
- assists therapy through the trust invested in the doctor by the patient

There are two ways of establishing the anamnesis:

- the monologue: the patient tells the reasons for presenting to the doctor and is patiently questioned; the doctor asks short, clear questions, the patient answers by detailing the symptoms
- dialogue: this is an “enquiry” or “cross-investigation” between doctor and patient; precise questions are asked which follow a specific scheme

The anamnesis is carried out according to a staged plan:

- personal data: sex, age, home address, profession, civil status
- reasons for admission to hospital: arranged into system categories and apparatuses.
- family and personal pathological and physiological history
- living and working conditions: nutrition, work-place, living conditions
- history of the disease: onset of disease, symptoms, evolution, treatment

## **STAGES OF ANAMNESIS**

**AGE** is very important because:

- Some diseases have an increased prevalence or incidence at certain ages
- Diseases can evolve differently at different ages
- The same clinical picture has different etiologies at different ages (e.g. The pleural syndrome in young people is most often susceptible of TBC etiology)

Diseases which appear most frequently at certain ages:

- Newborns (0-30 days): obstetric trauma, infections of the umbilical cord, congenital malformations
- Infant (1 month-1 year): digestive troubles, septicemia
- Child: infectious-contagious eruptive diseases (rubeola measles, scarlet fever, small pox), acute infectious diseases (angina, otitis, acute infections of the upper respiratory tracts)
- Teenager: lung tuberculosis, streptococci angina, acute articular rheumatism, acute glomerulonephritis
- Adult: cardiovascular diseases (HTA, valvulopathies, ischemic cardiopathy); respiratory diseases (chronic bronchitis); digestive diseases (gastro-duodenal ulcer, biliary lithiasis); endocrine diseases (diabetes mellitus, hyperthyroidism)
- The elder person: chronic, degenerative diseases (atherosclerosis, arthrosis), lung emphysema, senile involution diseases, cardiac insufficiency, neoplasms.

## **GENDER**

There are certain diseases with more frequent or exclusive onset in one of the genders:

<i>Diseases</i>	<i>More frequent in women</i>	<i>More frequent in men</i>
Cardio-vascular	Mitral stenosis, thrombophlebitis	Aortic, mitral insufficiency, chronic lung chord
Respiratory	Bronchial asthma,	Chronic bronchitis,

	Tuberculosis	lung emphysema, lung neoplasm
Digestive	Gastric ulcer, biliary lithiasis	Duodenal ulcer, gastric neoplasm
Renal	Urinary infections	Renal lithiasis, acute glomerulonephritis
Endocrine	Hyperthyroidism	Addison disease
<i>Exclusive diseases in women</i>		<i>Exclusive diseases in men</i>
Menstrual cycle troubles, metroannexites, ovarian cancer		Prostate adenoma, orchiepididymitis

In women, atherosclerosis is rare before menopause however the ratio between sexes is then balanced out. Women are predisposed to functional and endocrine troubles, also autoimmune diseases.

### **PLACE OF BIRTH AND PLACE OF LIVING**

In certain geographical areas certain diseases are encountered more frequently:

- Endemic thyreopathic dystrophy (endemic gout) which appears in certain areas which lack in iodium (Apuseni Mountains, Maramureş)
- Balkan endemic nephropathy which appears in the Danubian areas
- Exotic disease which can be “imported” by inhabitants of tropical areas who travel in our geographic area

### **HEREDO-COLLATERAL HISTORY (FAMILY HISTORY)**

“**Family aggregation**” is formed though the onset of a disease in several members of a family through **hereditary transmission or cohabitation**.

- Diseases with dominant autosomal transmission (is also manifested in heterozygotes): e.g. of single gene inherited

disease: adult polycystic renal disease, Huntington's disease, myotonic dystrophy, neurofibromatosis

- Recessive autosomal transmission diseases (manifested in homozygotes): e.g. of single gene inherited disorders: cystic fibrosis, sickle cell anemia, alpha thalassemia, alpha-1-antitrypsin deficiency, albinism.

If there is a suspicion of an inherited disorder, e.g. Huntington disease or hemophilia, family history should go back at least three generations with details of racial origin and consanguinity. In these circumstances ask if your patient or any close relative has been adopted.

- Sex-linked recessive diseases: haemophilia
- Through cohabitation, because of the same environmental conditions, an intra-familial contagion is produced (eg. TBC, infectious diseases, parasite diseases).

Congenital diseases represent disorders which are manifested even since birth, the consequence of an intrauterine ailment of the foetus, such as congenital lues, post-rubella malformations.

Certain diseases are transmitted only as a "predisposition", up to the point of manifesting themselves or not, depending on the influence of endogenous or environmental factors. For example: HTA, coronary artery disease, duodenal ulcer, billiary lithiasis, diabetes mellitus, epilepsy, schizophrenia, thyroid disease, etc. Many illnesses, e.g. thyroid disease, coronary artery disease, may be associated with a positive family history but are not due to a single gene disorder, and so family history is just one risk factor.

## **PERSONAL PHYSIOLOGICAL HISTORY**

The age of onset of the first menstruation is noted, data about the menstrual cycle, the number and type of births, peri- and postnatal events, weight of the newborn, number and type of abortions, the month of pregnancy during which the abortion took place, the age at which menopause set in, disorders relating to pre- and post-menopause.

- *The menarche* signifies the first menstruation
- *Amenorrhoea* is the absence of the menstrual cycle either through its non-installation (primary amenorrhoea), or through its interruption at a certain moment (secondary amenorrhoea), for example in pregnancy, breast-feeding, endocrine diseases, psychic disorders

Menstrual cycles are consecutive, every 28 days (21-32 days) and have an average span of 3 to 4 days. There are numerous modifications in the characteristics of the menstrual cycle:

- *Tachimenorrhoea* = high frequency of menstrual cycles
- *Bradimenorrhoea* = more dispersed succession of menstrual cycles. Both are encountered in endocrine diseases and disorders of the genital organs (metronexite, ovarian tumors)
- *Polymenorrhoea* = higher than average duration of menstrual cycle
- *Oligomenorrhoea* = lower than average duration of cycle
- *Menorrhagia* = uterine bleeding accompanied by clots, outside of the menstrual cycle. It usually indicates a fibrome or uterine neoplasm, developing abortion
- *Hypomenorrhoea* = discharging a low quantity of menstrual blood – in multiparas, women going through pre-menopause
- *Dysmenorrhoea* = signifies a painful menstruation and appears in neuroendocrine disorders, genital inflammations
- *Premenstrual syndrome consists of:* pain in the lower abdomen and breasts (mastodynia), maleolar and periorbital oedemas (water retention), psychological mood irritability associated with possible biliary dyskinesia, intestinal transit disorders. These signs and symptoms appear just a few days before menstruation and most often, they require medication.

Repetitive abortions, premature births, intrauterine fetus deaths are encountered in the maternal lues, Rh incompatibility, maternal diabetes mellitus. The birth of macrosomal children (weighing more

than 4 kg) attracts the attention to another pre-diabetes of the mother. Repetitive births, perineal ruptures predispose the woman to a uterine prolapse.

- *Menopause* appears around the age of 50 and consists of the onset of a secondary permanent amenorrhea accompanied by a hormonal, psychological and metabolic “storm”. The symptoms of menopause consisted in hot flushes, sweating fits, depression as well as onset or aggravation of HTA, obesity, diabetes mellitus, thyroid function troubles, dyslipidemia.

Personal physiology history in men refers to the age of puberty onset, sexual dynamic troubles, onset of andropause and related disorders.

*Sexual history* (if it is relevant for clinical condition) must be discrete but detailed (number and sex of sexual partner(s), barrier contraception, sexually transmitted infection, etc).

## **PERSONAL HISTORY OF DISEASES**

The importance of pathological history in anamnesis consists of the consequences that the former may subsequently have in the health state of the patient. Chronologically, all diseases are noted or the patient is questioned about the most frequent disorders based on systems and topographic regions.

- *acute infectious diseases*:
  - streptococcal angina, scarlet fever can be aggravated by acute rheumatic fever, acute diffuse glomerulonephritis and subsequently rheumatoid valvulopathy. Acute diffuse Glomerulonephritis can in turn transform itself in a chronic form which can evolve towards renal insufficiency.
  - Rubella can be aggravated with bronchopneumonia or can determine the activation of lung TBC, being an energizing disease

- Diphtheria, typhoid fever can evolve towards acute myocarditis
- Acute viral hepatitis type B, C, D show a potential of chronicization, being able to lead to the development of chronic hepatitis, followed by liver cirrhosis and hepatic insufficiency, hepato-carcinoma.
- *chronic infectious diseases:*
  - pulmonary TBC has tropism even for serous parts (pleura, pericardium), lymphatic ganglions and other organs
  - syphilis in tertiary phase determines a complex visceral tableau with affectation of the central nervous system (tabes, general progressive paralysis), of the heart (aortic insufficiency), of the vessels (syphilitic arteritis)
  - chronic infectious foci (dental, tonsil) predispose to renal and joint disorders
  - chronic suppurations favor the onset of amyloidosis
  - gonorrhea can have local determinations (chronic prostatitis and urethral strictures)

- *organic diseases*

All morbid circumstances on apparatuses and systems are retained: cardio-vascular, respiratory, digestive, renal, osteo-articular, endocrine, metabolic, neurological etc.

*Surgical interventions* suffered are also acknowledged, *traumas*, *intoxications* which can be responsible for the presence of current trauma in the morbid picture of the patient.

In this chapter of anamnesis, it is important to avoid transcribing diagnostics enounced by the patient. In order to verify the authenticity of the data, the doctor can have recourse to previous documents (outpatient slips, analysis bulletins, medical prescriptions).



## LIVING AND WORKING CONDITIONS

- *Living spaces* – insalubrious, cold, with dampness, family crowded predispose to numerous diseases: acute infections of the upper respiratory tracts, angina, tuberculosis, articular rheumatism, bronchial asthma. The presence of pets in the house favors zoonosis.
- *Lifestyle* – of the patient, nutritional habits, toxic consumption (alcohol, tobacco) are all disease or health factors
- The excess of sugars, lipids and calories is generally interesting, associated with sedentary life it represents a risk factor for diabetes mellitus, HTA, obesity, dyslipidemia, atherosclerosis and its complications
- The vitamin deficiencies affect growth and development in children, determining a drop in the body's resistance in general.
- Deficient nutritional hygiene, with an irregular eating timetable, tachyphagia (rapid ingestion of food), consumption of foods which are too cold or too hot and consumption of spices favors the onset or aggravation of some dyspeptic troubles
- Consumption of toxic foods takes into consideration the intake of alcohol, coffee, tobacco, drugs, quantities, duration and frequency of consumption
- *Alcohol consumption* favors: digestive diseases (ethylic gastritis, alcoholic hepatitis, hepatic ethanolic cirrhosis, pancreatitis); neuro-psychiatric diseases (ethanolic cardiopathies); metabolic diseases (obesity or, on the contrary, denutrition).
- *Smoking* represents a major risk factor for: lip epithelioma (in pipe smokers), chronic tabagic bronchitis, bronchial-pulmonary neoplasm, atherosclerosis, vascular accidents, hypertension, and oral cancer in cigarette smokers. A smoking history should include the ages when smoking commenced and was given up and average tobacco consumption over the years in terms of

cigarettes per day or ounces of tobacco per week. Calculate pack year consumption: smoking one pack of 20 cigarettes a day for a year is equivalent to “one pack year”. Patients with COPD usually have a consumption of greater than “20 pack years” (pg. 70).

- Coffee abuse can lead to irritability, insomnia, palpitations, and tachycardia.
- *Drug history*: the patient is questioned about *drug abuse*, such as: analgesics, tranquilizers, over the counter remedies, and alternative medicine treatments, particularly herbal or homeopathic remedies, laxatives, analgesics and vitamin/mineral supplements, as well as *drug consumption*. Note the name of each drug, the dose, regimen and duration of treatment along with significant side-effects.
- *Drug allergies/reactions*: record true allergies prominently in the patient’s case records and drug chart. In particular enquire about previous reactions before prescribing an antibiotic, particularly penicillin. Ask about other allergies, e.g. foodstuffs, animal hair, pollen or metal. Clarify exactly what patients mean by reporting allergy, as this term is used loosely.
- *Travel history*: travel to hot climates are at risk of contracting tropical infections, and air travel itself may increase the risk of certain conditions e.g. middle ear problems and deep venous thrombosis. Ask about the country your patient visited, type of accommodation (e.g. a five-star hotel or a tent), and activities undertaken, e.g. water sports, sexual contacts while abroad.
- *Professional anamnesis* refers to working conditions: physical effort, microclimate conditions (temperature, humidity, and noise pollution), work programme, exposure to toxic materials and whether other workers have become ill. Remember that *hobbies* may also be associated with certain illnesses e.g. psittacosis pneumonia and extrinsic allergic alveolitis in those

who keep birds. Symptoms which improve over the weekend or during holidays should always suggest an occupational disorder.

- *Psychiatric history*: has three core purposes: to obtain a history (including premorbid personality, other sources of information, sensitive issues, etc.), to assess the mental state of the patient (main areas are: appearance, behavior, mood, speech, thought content, perception, cognitive function: memory, orientation, general knowledge and intelligence), and to establish rapport that will facilitate further management. We can use psychiatric rating scales, e.g. CAGE and FAST (alcohol problems), Hospital Anxiety and Depression Scale (HADS - mood disorders), and the Abbreviated Mental Test (AMT - organic brain disorders); they should never replace standard psychiatric interviewing!

### **1.3. GENERAL PHYSICAL EXAMINATION**

- The objective (clinical) examination is a clinical method of exploration, with the help of human senses, indicating the signs of disease.
- There is a general objective examination (all encompassing) and one for the different body systems.

#### **1.3.1. METHODS AND TECHNIQUES**

##### **Inspection**

- Inspection consists of the visual observation of certain signs of a disease.
- The patient is completely undressed. The oral cavity and perineum are also visualized, thus dealing with the patient's shyness.
- They are examined in an appropriate light (natural, strong, good incidence), sources of error are avoided: fluorescent light which

accentuates cyanosis, incandescent bulbs which diminish the intensity of the jaundice.

- The inspection technique:
  - The patient is lying down, the inspection is topographic and comparative (symmetrical). For example, the head, hair, eye, conjunctive tissue, nose, lips, mouth; physiognomy – facies – mimicry; neck, thorax, upper limbs, abdomen etc.
  - The patient is sitting down – posterior inspection
  - Mobilization on segments and walking

### **Palpation**

- Palpation uses the tactile and kinesthetic sensibility of the hands
- Palpation is superficial or profound
- Palpation is performed using the soft finger pads, the palm of the hand and without applying any pressure
- Types of palpation:
  - Simply using the finger pads: appreciates consistency, sensitivity of tissues, bone prominences, bone line, localization of certain modifications
  - With the whole palm of the hand: in order to distinguish the pectoral or cardiac murmur, pulsating formations; rotating and superficial for the state of teguments
  - Grasp between fingers: the adipose tissue, mobility or consistency of a tumor
  - Massage: rotating, superficial, using the finger pads senses the teguments, the subcutaneous cell tissue and muscle tissue
  - Palpation of profound organs, for example the abdominal organs through gliding or rolling on a hard plane; requires an adequate position, muscle relaxation



**Figure 1. Bimanual palpation of the liver**

- Criteria or semiological palpatory elements of the tumors (TUs), tumefactions (abscesses), formations (ganglions):
  - Topographic localization
  - Volume: small, medium, large, in centimeters or by comparison
  - Form: organ shaped, round, ovular, irregular
  - Consistency: fluctuating (abscesses, cysts), soft, elastic, as if made of stone (malignant tumors)
  - Contours or margins: clear, blurred contours (malignant TU), rounded or sharpened margins)
  - Sensitivity: when present (inflammation), absent (insensitive)
  - Mobility: free (benign TU) or adherent (malignant TU) on the superficial or profound planes; muscular TUs become resistant to muscle contractions; pulsating TU:

aneurisms, through transmission; TU modifying its location, volume in breathing, deglutition, coughing

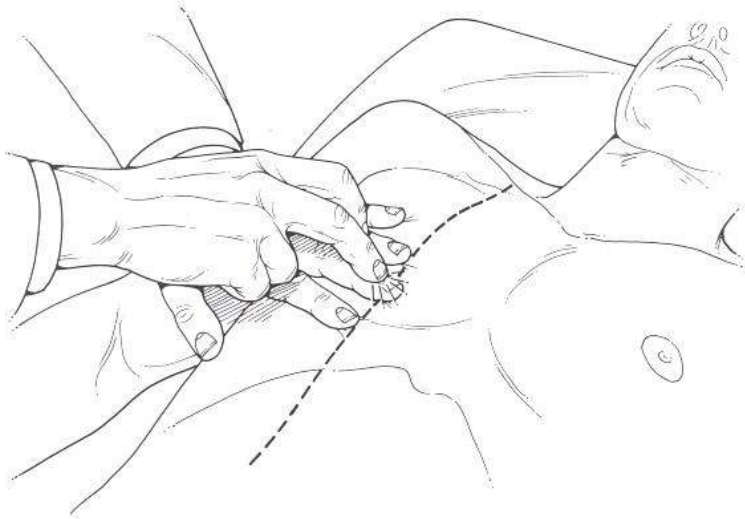- The state of the super-adjacent tegument: redness, orange peel aspect, fistulae etc.

## **Percussion**

Percussion consists of the causing of vibrations by hitting the surface of the body and thus appreciating acoustically the subjacent physical state.

Methods:

- Indirect percussion (mediated) carried out with the plessimeter and hammer – abandoned
- Direct percussion: digito-digital with the middle finger of the left hand applied on skin (plessimeter) and the middle finger of the right hand as percussional (hammer) the correct technique is the following:
  - The plessimetrous finger distanced from the others, applying soft pressure
  - The percussional finger flexed from the interphalangeal articulation
  - Perpendicular hitting, short, rare, rhythmic, applying equal force
  - From the radiocarpal joint, perceptible sound
  - Potential errors are: incorrect application on the examined region, oblique hitting action and from the elbow, shoulder (rigid) (the elbow is closer to the body), hard, precipitated percussion



**Figure 2. Percussion technique**

Percussion also appreciates the resistance and elasticity of the examined area. The explored territory: depth of 5-7 cm, 3-6 cm extension. Percussion can be:

- Superficial (with superficial hitting, appreciating depth at 3-5 cm)
- Profound (with intense hitting movement, when it estimates a depth of maximum 7 cm, the percussion finger being flexed at 90 degrees)
- Palpatory: the percussion finger is extended, soft hitting movement which determines barely perceptible vibrations
- Orientation percussion (whole) for an extended space (thorax-abdomen), “of the triage type”, methodical, rigorously comparative, of medium intensity
- Topographic percussion having as its objective to delimit the projection of two neighbouring organs (lungs, liver, heart)

which have different percussion sounds; it is superficial, performed from a “step-by-step” approach

- The percussion sound is directly proportional to the intensity, tonality, pitch and duration of the vibrations produced; it is also influenced by the quantity of air or dense tissue, distribution or pressure (tension) of the compressed air.
- Examples of sounds at percussion:
  - *The matte sound* (dullness): low intensity, short duration, notably raised tonality due to the lack of air (muscles, liver, heart), replacement of air with liquid, tumours, infiltrations
  - *The loud sound*: increased intensity, long duration, low tonality, characters proportional with quantity, distribution, air pressure in the percussed tissues; other variants are:
    - The ear-drum sound (ear-drumming): intense, musical pitch (of the ear-drum); it is exerted on organs which enclose air in the circumscribed spaces, with regular walls, such as: lung caverns, pneumothorax, relaxed lung (“Skodism”) or on the normal abdomen; its tonality is directly proportional with the size of the cavity, form, regular or irregular walls, air pressure, communication with the outside and its dimensions. For instance: the stomach and the large bowel determines a low tonality, the small bowel a high tonality, the small cavern – ear-drumming, over 6 cm cavern and regular walls – *metallic resonance* (with musical pitch and high tonality), while the cavity with narrow communication – *cracked pot resonance*
    - Non-drumming sound (*pulmonary sonority*): on the normal lung (of low intensity and non-musical pitch), or hyper-sonority in the pulmonary emphysema (due to the low pressure air)



- Sub-matte sound (sub-dullness): a blend of matte and loud sounds due to some territories with and without air or on the brink of (oblique) separation among dense or air-impregnated organs (liver, lung, heart).

### **Auscultation**

- Auscultation consists of listening to the physiological or pathological sounds made by the internal organs (lung, heart, digestive tube etc.) which can be:
  - Direct: with the ear to the chest;
  - With the stethoscope (stetho=chest, skopein= to examine) (Laennec) monoauricular for fetal heartbeats or flexible bi-auricular with funnel for low-pitched noises or capsule with elastic diaphragm for high-pitched noises; technical conditions for auscultation: quiet environment, air-tight and fixed adaptation of olives and the receptor.

### **1.3.2. CONSTITUTIONAL TYPE**

Constitution represents the psycho-somatic and metabolic aspect of the individual.

Constitutional types:

- According to Hippocrates: sanguine, choleric, phlegmatic, melancholic
- According to Sigaud: respiratory, digestive, cerebral, muscular
- According to Kretschmer: athletic, pycnic (small, crouched), leptosomous (thin, tall)
- According to endocrine and psychological criteria: introverted, extroverted, normal
- Sheldon differentiates between:

- The endomorphic type: picnic, extroverted, predisposed to atherosclerosis, diabetes mellitus, gout, HTA, biliary lithiasis
- The ectomorphic type: leptosomous, introverted, predisposed to ulcers, TBC, schizophrenia
- The mesomorphaic type: stenic, intermediary predisposed to rheumatism, myopathies

### 1.3.3. THE CONSCIOUS STATE AND ITS SYNDROMES

Through state of consciousness one can understand the degree of presence in the environment and the response capacity to external stimuli. In determining the conscious state, several factors intervene, such as attention, concentration capacity, memory, orientation. A normal person, without consciousness disorders is present in the environment and responds correctly and adequately to stimuli. The main perturbations of consciousness (and of the waking state, respectively) are the following:

- **Torpor:** it is characterized through a decrease in volitional-emotional tonus, a lack of initiative, indifference, apathy. Patients act like sleepy people, there is a delay of response to diverse stimuli, but the answers develop correctly. It appears in breakdowns, febrile diseases
- **Obnubilation:**
  - Psychological functions are slowed down, the frame of perception is high, the question is not understood, the answer is absent or inappropriate; the patient gives the impression of being lost.
  - Appears in the febrile period of an infectious disease (typhoid fever, exanthematic typhus), acute intoxications with alcohol, with carbon oxide, with certain drugs etc.
- **Stupor:** it is characterized by complete indifference to everything surrounding it, temporal-spatial disorientation;

patients are immobilized with a fixed stare and only perceive what is happening around them in a limited way. It is also encountered in severe infectious diseases, severe toxic states, schizophrenia and melancholy.

- **Lipothymia or fainting** is a sudden, partial loss of short span of consciousness, with partial or complete muscular relaxation, vegetative functions are not abolished, only slowed down.
  - It is generated by the express reduction or arterial tension, with reduction of the blood flow to the head. It usually appears in patients with neurovegetative instability being favored by prolonged standing, by an unfavorable, warm and humid atmosphere or by tense states.
  - Symptomatology preceding lipothymia is represented by: feeling of sickness, dizziness, epigastralgia, nausea, ringing in the ears, sensation of having blurred vision, increased pallor, and diminished amplitude pulse, arterial hypertension. Loss of consciousness immediately follows and is not total or profound. The patient regains consciousness in a few seconds if placed in dorsal decubitus
- **The syncope:** is a sudden loss of short duration (seconds, minutes) of consciousness and locomotion, with abolition of vital functions accompanied by a sudden drop (but not brutal) and non-traumatizing (as in epilepsy). It ends either through regaining consciousness, or through death. It is the consequence of transient cerebral ischemia or of a change in the composition of blood which irrigates the brain. The causes of syncope are numerous:
  - **Vascular causes:** vaso-suppressive syncope (vasovagal syncope), syncope through orthostatic (postural) hypotension, sinocarotid syncope, coughing syncope etc.

- **Cardiac causes:** aortic stenosis, atrial myxoma, pulmonary embolism, paroxysmal tachyarrhythmia, IIIrd degree AV block etc.
- **Other causes:** hysteria fits, hypoxia, CO<sub>2</sub> diminution (through hyperventilation), hypoglycemia etc.

Loss of consciousness is preceded by a feeling of sickness, dizziness, blurred vision, auricular noises, nausea, and pallor with cold sweats; followed by non-traumatizing drops. The patient lies inert, hypotone, but without sphincter relaxation; arterial hypertension drops, pulse is faint, teguments are cold and humid. Coming out of the state of syncope is rapid, usually without residual symptoms.

- **Coma:**

Coma is a disorder characterized by the complete or partial, lengthy loss of consciousness, voluntary motility and sensitivity, with maintenance of the vegetative functions (circulation and respiration) which are modified. The comatose patient shows signs of a man in a state of deep sleep, a state from which the patient can only seldom come out of and only using very strong exciters (pinching, piercing) to which s/he reacts through reflex movements or muttering.

**Classification of comas** depending on their gravity:

- **The pre-comatose state** during which the patient is in a state of obtundation, incoherent in thinking and expression, but also reacts to strong excitants.
- **Vigil coma or locked-in syndrome** the patient is unable to answer questions, does not execute orders, only painful stimuli determine certain reactions. Eye movement reflexes and deglutition are still present. It can also involve agitation and delirium
- **Profound coma (carus)** is manifested through the complete loss of consciousness, muscular relaxation, loss of sensitivity and reflexes, accentuated perturbation of circulation and respiration

- **Irreversible coma or brain death** is characterized by complete suppression of nervous functions as well as vegetative ones, the patient being kept alive only using artificial means
- **Glasgow score** (between 3 and 15) is helpful for evaluating the depth of the coma, assigning a different number of points for examination results in three different categories: opening the eyes (1-4), verbal response (1-5), and motor response (1-6), profound coma is assigned a score of three.

#### **The origin of coma:**

- Comas of **cerebral** origin are generated by:
  - Cerebral vascular accidents (cerebral hemorrhage, embolism or thrombosis)
  - Cranial-cerebral trauma
  - Cerebral inflammatory processes (encephalitis, meningitis, cerebral abscesses)
  - Tumoral processes
  - Epilepsy, hysteria
- **Metabolic** comas:
  - Diabetic coma (acidocetotic, hyperosmolar), hypoglycemic coma
  - Uremic coma, hepatic coma
- **Endocrine** comas: Addisonian, Basedowian, myxedematous
- **Toxic** comas: intoxications with carbon monoxide, alcohol, drugs, organic-phosphoric substances, food intoxications (fungus etc.)

### **1.3.4. ATTITUDE**

Attitude is the position that the patient tries to adopt in the bed or when standing. Attitude can be active, passive, or forced.

- **An active attitude** implies the possibility of movement (ambulatory patient) or bed movements; it usually appears in light diseases.

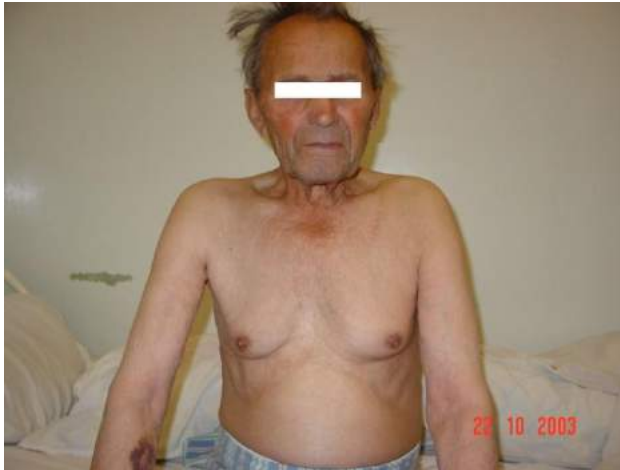- **A passive attitude:** the patient is grounded to the bed, lies inert, without muscular tonus, incapable of adjusting his position. Passive attitude is recorded in serious diseases or in comatose states.
- **Forced (imposed) attitudes** are due to:
  - The immediate need to calm an unpleasant symptom such as pain (antalgic attitudes), dyspnea (anti-dyspneic attitudes), cough (anti-cough attitudes) etc.
  - Muscular contractions which reside in articular modifications determining axial deformities of the skeleton

### Examples:

- **Antalgic attitudes:**
  - In pleuritis: contralateral decubitus in order to calm the thoracic stabbing pain exacerbated by pressure
  - In penetrative ulcer: crouched with the fist pushing upon the epigastrium
- **Antidyspneic attitudes:**
  - The orthopnea position: patient sitting (on a chair, on the edge of the bed) or half-sitting (in the bed, with 2-3 pillows under his/her head) with hands gripping the chair or bed

Orthopnea appears in *left acute ventricular insufficiency* of various origin, *mitral stenosis* or *bronchial asthma in crisis*.

Orthopnea diminishes the pulmonary stasis and favors pulmonary ventilation (setting in motion the accessory respiratory musculature).



**Figure 3. Patient with left heart failure and lung tumor sitting in orthopnea position**

- The genu-pectoral position (or Mahommedan prayer position) consists in bending forward of the torso, with bending of the lower limbs, the upper limbs are gathered behind the knees; it appears in acute pericarditis, favoring the lowering of pressure in the pericardial sac (due to force of gravity)
- The crouched position (or *scatting*), or “the curled down position” adopted by children with congenital malformations during effort, because it eases dyspnea
- The homolateral decubitus (on the same side) adopted by patients with exudative pleurisy because it favors wide respiratory movements leaving the hemithorax unaffected
- **Anti-coughing attitudes:**
  - In bronchiectasis the patient seeks a position which can prevent the release of bronchial secretions towards the cough-prone areas

- Forced attitudes through **muscular contraction**:
  - In tetanus: the *opisthotonus* position appears or “the arched position” (leaning on the back of the neck and heels) which is due to the generalized contraction of the extensor muscles. The *trismus* defines an attitude with the mouth clenched through the muscular contraction
  - In tetania: *the Trousseau sign*, characterized by the contracting of the muscles of the hand by opposing the finger pads or “the carpo-pedal spasm”, or the same type of contracture at lower limb level, respectively
  - In bacillary meningitis (TBC) the patient adopts the “arching rooster” position through hyper extending of the head, the triple flexing of the limbs and lateral decubitus
  - In lumbar disc hernia: the “bayonet attitude” through compensated scoliosis by the neighboring segments.

### 1.3.5. WALKING DISTURBANCES

Walking disturbances include a number of modifications:

- Slow, fatigue induced walking, with frequent stops usually accompanies asthenia, the Addison disease, convalescence
- Intermittent claudication in obliterating arteriopathies
- Dizzy walking (staggering): unsure, uncoordinated movements, tilting forth and backwards of the head; it occurs in alcohol intoxications or with barbiturates
- Cerebellar walking: unsure, with a large support platform, feet wide apart
- Precipitated walking, with small steps, body leaning forward (according to the centre of gravity); occurs in the Parkinson`s disease
- Senile walking with small, shuffled, unsure steps; it is normally observed in elder patients, suffering from atherosclerosis, the pseudo-bulbar syndrome



- Stepped, equine walking: the patient touches the ground with the tips of their toes then with their heel, in the same way as a circus horse; it is observed in the paralysis of pre-tibial and peroneus muscles (due to the paralysis of the external sciatic popliteal nerve) in poliomyelitis, paralyzing sciatic
- The scything walk (spasmodic) which occurs due to spastic hemiplegia: consists in bringing forward the foot through a movement of circumduction (arched movement) caused by the impossibility of flexing the lower limb

### 1.3.6. INVOLUNTARY MOVEMENTS

Involuntary movements are due to unwanted muscle contractions:

- **Fibrillations and fasciculations:** rapid contractions, limited to the surface of the muscles, without mobilization of the segment; they appear in exogenous, endogenous intoxications, uremia, hepatic insufficiency, respiratory insufficiency
- **Tremors:** fine, rapid movements, localized in the upper extremities (in emotions, overworking, coffee abuse, smoking, hyperthyroidism, alcoholism, neurosis) or generalized (in shivers, hypoglycemia, cold weather) egs.
  - The hepatic tremor (or *flapping tremor*) is due to acute hepato cellular insufficiency, hepatoportal encephalopathy. It is a rapid, irregular tremor, accentuated by the extension-flexing of the arms, with spreading out of the fingers and which disappears when hepatic coma onsets
  - The Parkinsonian tremor, observed in the Parkinson disease. It is characterized by sporadic, rhythmic, equal movements, in the state of relaxation; it fades

out in voluntary movements. It is evidenced at upper limb level, head, toes (the croupier sign, of counting banknotes)

- In chorea minor, striated body lesions, lethargic encephalitis, involuntary, ample, rapid, arhythmic movements, of short duration can be detected
- **Athetotic movements** which occur in degenerative diseases of the central nervous system. They are permanent, slow, winding, and prevent the body from gaining its stability
- **Convulsions** which occur in epilepsy, intracranial hypertension due to meningitis, encephalitis, cerebral vascular accidents, hypertensive encephalopathy. They are ample, repetitive, disorganized, generalized, in crisis movements, with alternating tonic-clonic contractions and de-contractions
- **Myoclonias** represent rapid, partial, repetitive muscular contractions (shudders) which appear after light muscular percussion in encephalitis, hypoglycemic coma, neurological diseases
- **Spasms:** involuntary movements of a given muscle group, such as the spasmodic torticollis, the facial hemi-spasm, professional cramps
- **Tics:** they represent in a sudden, involuntary and repeated manner a gesture or a well defined act. They often are of psychogenous origin.

### 1.3.7. THE FACIES

By **facies** we mean the anatomical region of the face.

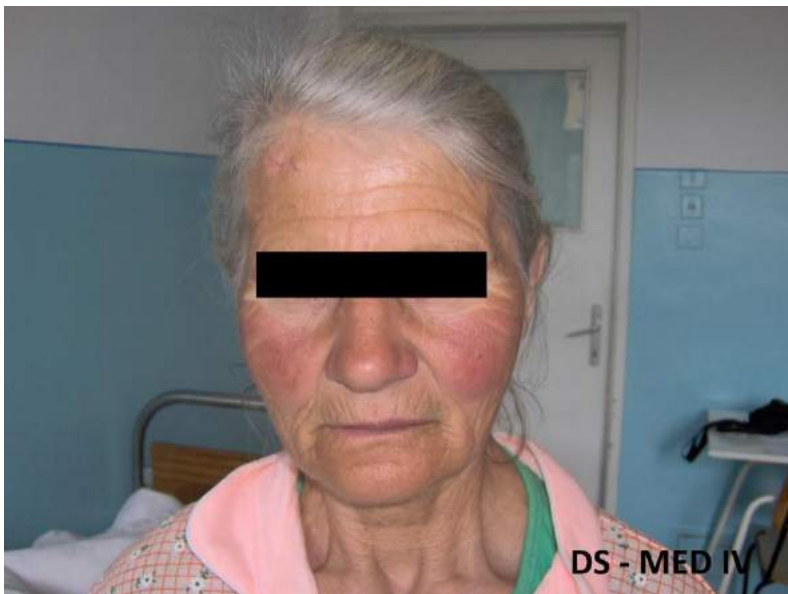The **physiognomy** consists of the totality of facial features and its derived expression thereon (happiness, sadness).

The **facies** represents the change in facial aspect which appears as a result of the onset and development of a disease. Certain diseases

have such typical facies that the diagnosis can be established simply based on inspection of the face. It is the imprint of a disease on physiognomy and/or mimicry (pathognomic for the respective disease).

- The facies in **cardiac diseases**:
  - **The mitral facies**: pathognomic for mitral stenosis, mitral valvulopathies. It consists of cyanosis of the lips, cheeks, nose, ears (“mitral beauty”, doll aspect) and appears due to pulmonary stasis (pulmonary hypertension).

**Figure 4. Mitral facies in mitral stenosis**

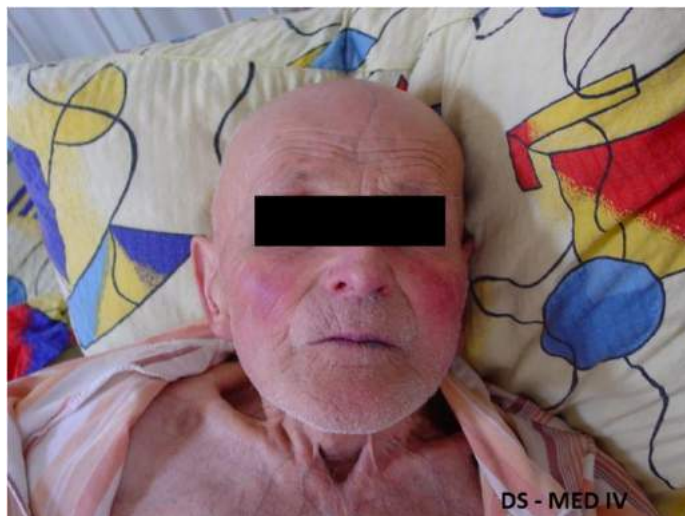

**Figure 4. Mitral facies in mitral stenosis**

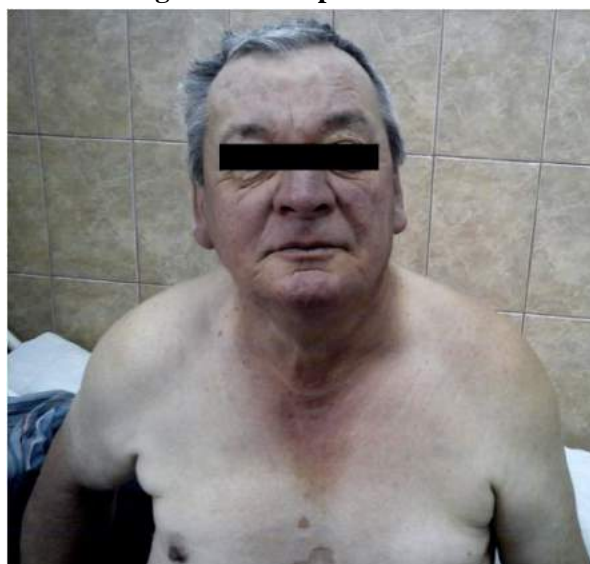- **“the mitral mask”** appears in mitral stenosis with cardiac insufficiency in the advanced stages: cyanotic, bloated face
- **Aortic facies**: in aortic insufficiency: pale teguments at face level, observed arterial carotid dance (ample pulsations, visible at carotid level)

- **The Corvisart facies:** in severe cardiac insufficiency: the face is cyanotic, edematous, bloated, anxious
- **The facies in acute myocardial infarction with collapse** is pale, covered in cold sweats
- **The facies of the chronic pulmonary chord with severe respiratory insufficiency:** intense cyanosis of the cheeks (through hypoxic polyglobulinism), tumefaction of the eyelids, injected bulbous conjunctivitis, sinuous venectasias at cheek level
- The facies in **respiratory diseases:**
  - **The congested facies:** in acute pneumonia or other febrile diseases. The diffuse congestion of the cheeks is observed, labial herpes
  - **Phthisis facies** resulting from pulmonary tuberculosis; the teguments are pale-tern at face level, sunken cheeks, red and cyanotic cheek bones, bright shiny eyes
  - **“Pink gasping” facies (pink-puffer):** from chronic obstructive pulmonary disease type A (through pulmonary obstructive emphysema)
  - **“Blue bloated” facies (blue-bloater):** from chronic obstructive pulmonary disease type B (through chronic obstructive bronchitis)
- The facies in **digestive and abdominal diseases:**
  - **Peritoneal facies (hippocratic):** in acute peritonitis (through perforations, ulcers, appendicitis, ileus, choleperitonaeum), food intoxications. It consists of the earthy pallor of the face, cold sweats, eyes crammed deep into the eye sockets and with blue dark circles, a pointy nose, anxious stare, dry lips
  - **Zygomatic facies:** in duodenal ulcer with pyloric stenosis: the face is sunken, earthy, prominent cheek bones

- **Cirrhotic facies:** in advanced hepatic cirrhosis; the teguments are yellowish-brown, the face sunken, carmine lips, depapillated lacquered tongue, dry and frail hair, vascular stars

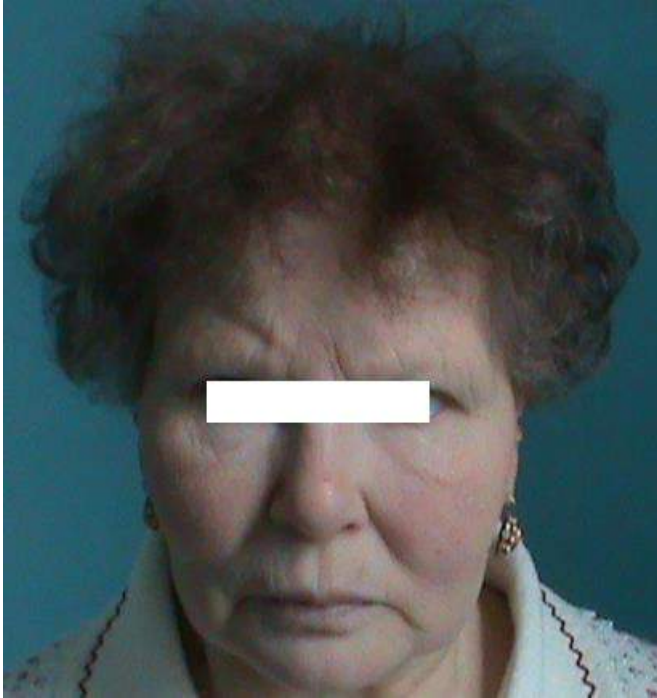

**Figure 5. Pink-puffer facies**



**Figure 6. Blue-bloater facies**

- The facies in **endocrine diseases**:
  - **Hyperthyroid facies (Basedowian)**: in the Basedow diseases; the face expresses fear, anxiousness; it is a “scared facies” with exophthalmia (visible protrusion of the eye bulbs), scintillating “intelligent” eyes, visible sclerotic above the cornea – iris (the Dalrymple sign). Other signs: gout, warm, humid teguments, tachycardia, psychological instability, irritability, fine tremors, weight loss, diarrhea. Other visible signs are: the *Stellwag* sign: sporadic blinking and retraction of the upper eyelid (through hypertonia of the levator palpebrae superioris of the lid); the *Moebius* sign: the lack of convergence on staring at small distances; the *Graefe* sign: lack of synergy between the eye bulb and the upper lid on looking downwards; the *Rosenbach* sign: tremor of the lids; the *Jellinek* sign: periocular pigmentation
  - **Mixedematous facies** (hypothyroid) of “**a full white moon**”: in hypothyroidism. Face teguments are pale, rough, thickened by the accumulation of mucous substances in the subjacent tissues. The forehead is wrinkled, the eyes are inexpressive, infrequent eyebrows (the *Hertoghe* sign) in the external half, tri-lobed nose, intensely thickened lips, macroglossia. Other signs are: apathy, bradypsychism (slow thinking), bradylalia (slow talking), obesity, constipation



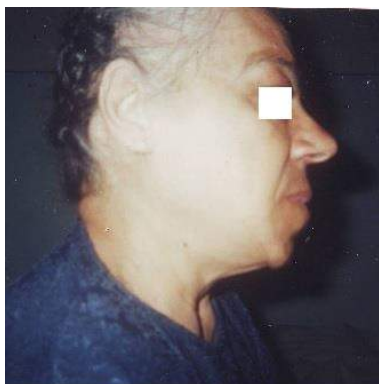**Figure 7. Mixedematous facies**

- **Cushigoid “full red moon” facies:** in the Cushing syndrome or disease; round facies, red swollen, oedematiated cheek bones (falsely considered healthy); the head is rounded with a short and thick neck. Other signs: hypertrichosis, purple stretch marks (on the abdomen and hips), arterial hypertension, android obesity, diabetes mellitus, menstrual disorders



**Figure 8. Cushingoid aspects of the face**

- **Acromegalic facies:** in acromegaly. Big nose, wide jaw, projected forward, like a galosh (prognathism), ears are wide, cheek bones large and prominent, thick lips turned down, wide tongue, enlarged frontal bulges (protuberances), Other signs: enlarged, widenend hands and feet (the “glove, shoes, hat” sign)

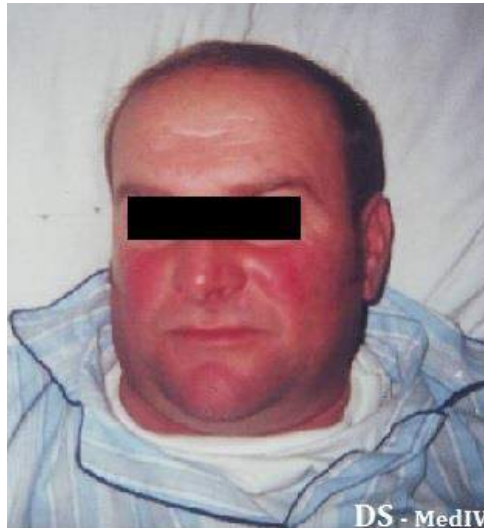

**Figure 9. Acromegalic facies**

- **Diabetic facies:** it is more frequently found in juvenile diabetes mellitus. It manifests itself in redness of the face

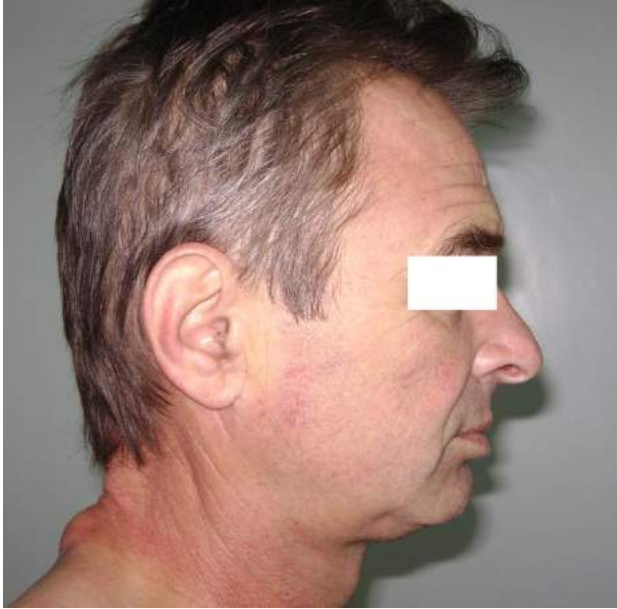

(especially cheek bones, forehead) due to visibility of certain venous capillary plexuses (through hyperglycisty)



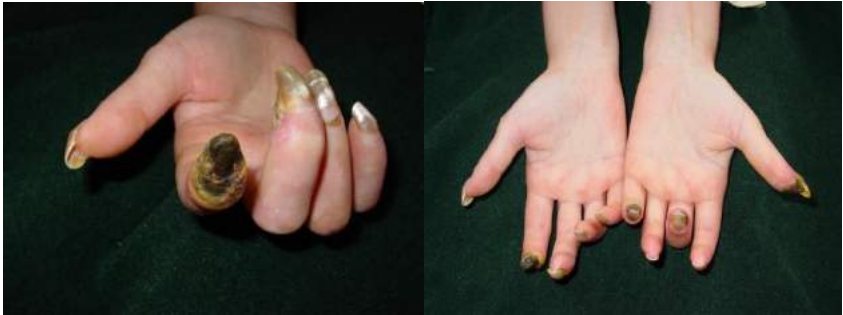**Figure 10. Diabetic facies**

- **Addisonian facies:** found in the Addison's disease. The brown hyperpigmentation of the face appear and of the uncovered teguments (neck, shoulders, forearms), hyperpigmentation of the mucuses (the tongue, gums), of the cheeks (pigmentation spots of different sizes) other signs: asthenia, adynamia, arterial hypotension, lack of appetite, nausea, vomiting, diarrhea
- **Carcinoid facies:** in carcinoid tumours with hepatic metastases. Intermittent (in crisis) the red coloration of the skin is observed, accompanied by the sensation of heat and/or tearful eyes with or without bronchospams though the release of serotonin from the tumor



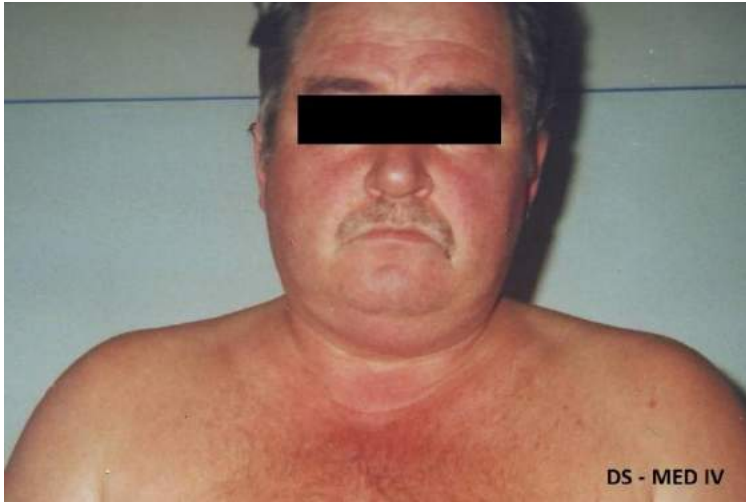**Figure 11. Carcinoid facies – typical flushing**

- The facies in **collagenoses**:
  - **The “masked facies”**: in generalized scleroderma (through sclerosis of the skin). The facies is immobile like a mask. The facial skin tissue is very frail and thin, like parchment paper, making speech and eating difficult; in the advanced stages the narrowed oral slit appears, the sharp nose (the “*bird of prey*” or the “*Byzantine icon*” facies (because the skin does not plicate). Other signs are as follows: dysphagia, the Raynaud syndrome followed by sclerodactyilia and necrosis of the finger pads (figure 12).

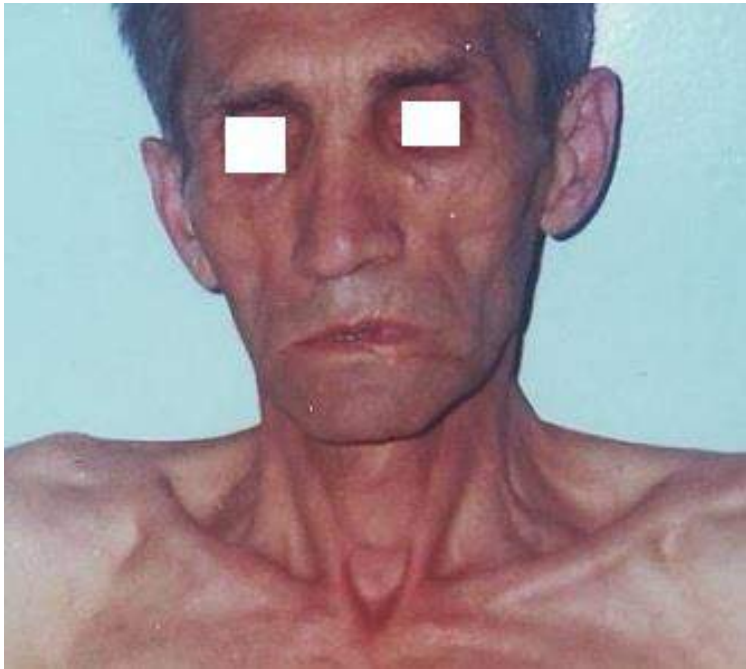

**Figure 12. Sclerodactyilia and necrosis of fingerpads in scleroderma**

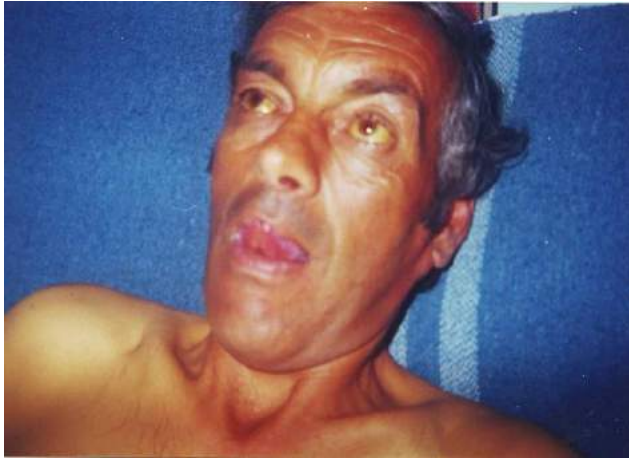- **The facies in disseminated lupus erythematosus:** an eruptive placard appears, symmetrical to the cheek bones, in the form of a butterfly with stretched-out wings (“vespertillio”)
- **The facies in dermatomyositis:** the lilac color of the eyelids appears
- **The facies in neurological diseases:**
  - In the Parkinson disease: the loss of mimicry, fixated facies (immobile, stiff, inexpressive)
- **The facies in other diseases:**
  - In congenital lues: “the saddle nose”
  - In polyglobulia: red-cyanotic coloring of the face and lips (*plethoric facies, figure 13*)
  - In leukaemia: leonine aspect (infiltrated)
  - In tetanus: the *trismus* appears – clenching of the mouth by contracting the masseter muscles and the *risus sardonicus* – the mouth, eyes, while nostrils are shaped as if for laughter while the lower half of the face appears to be sad.



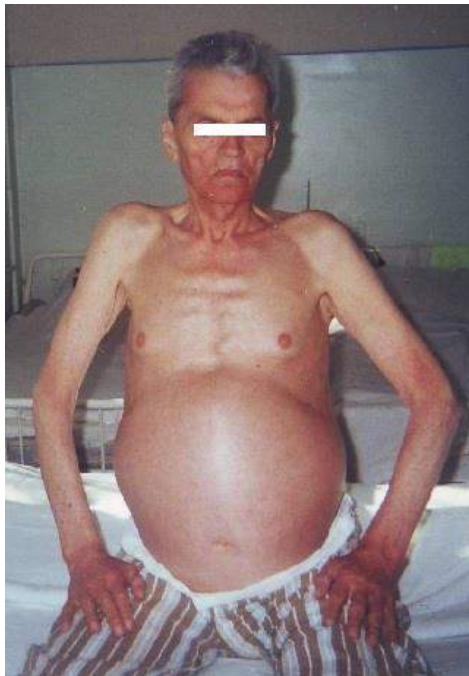**Figure 13. Plethoric facies in polyglobulia and hypertension**



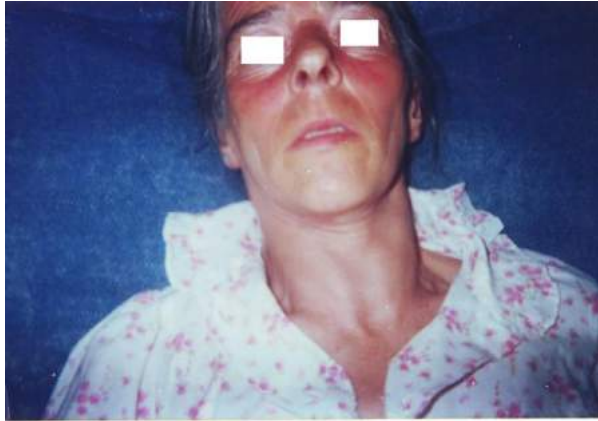**Figure 14. Zygomatic facies in a patient with gastric cancer**



**Figure 15. Cirrhotic facies with intense jaundice**

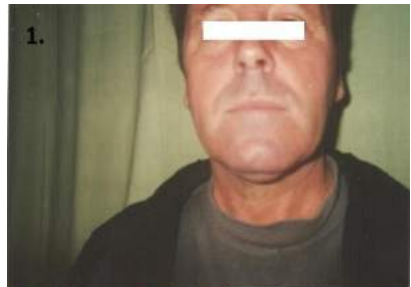

**Figure 16. Cirrhotic phenotype with ascites and typical facies**

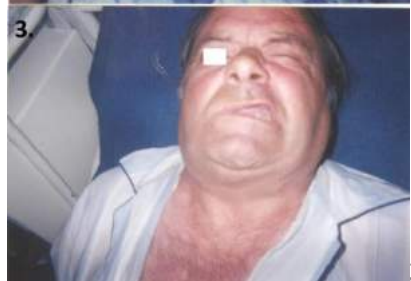
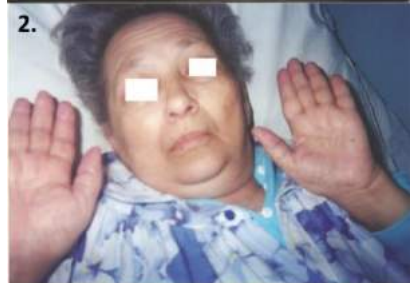
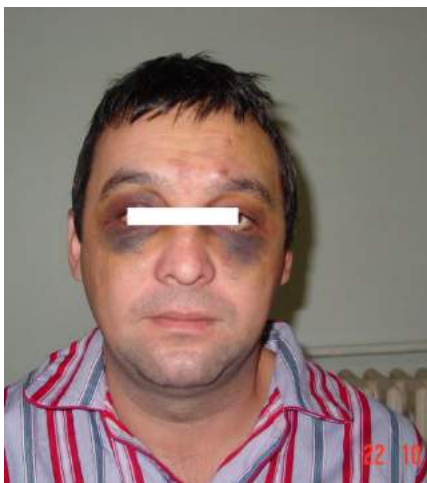**Figure 17. Hypertiriodian facies with periocular hyperpigmentation**

**Figure 18. Different types of facieses (in carcinoid syndrome - 1, a pale facies - 2 and a particular facies due to facial palsy)**



**Figure 19. Bilateral peri-ocular post-traumatic ecchymosis**



### 1.3.8. THE COLOR OF SKIN AND MUCOSAE

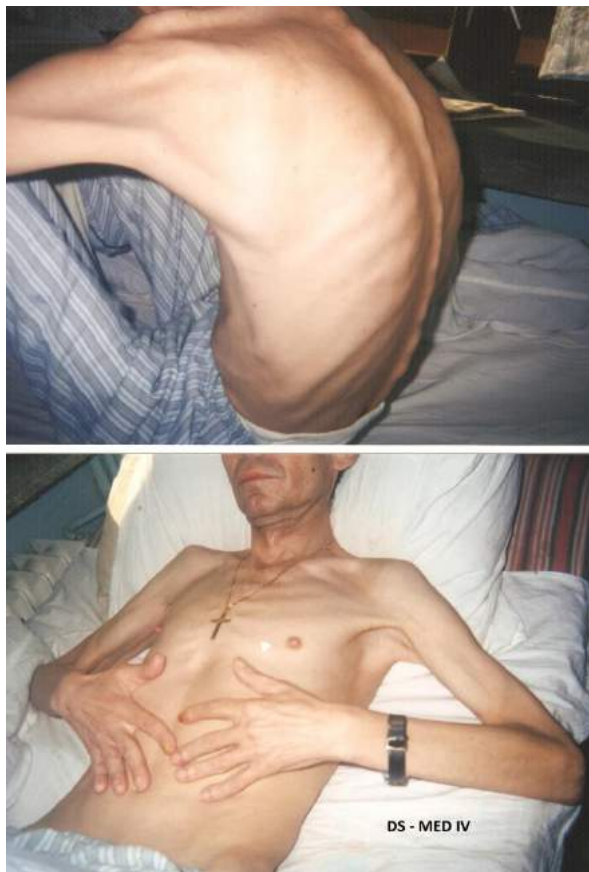#### PALLOR

Pallor represents the light coloring of the skin which appears in thickening of the tegument (myxedema), hypoglobulinemia (anemias), vasoconstriction, ischemia (shock), diminishing of the capillary network (hypogonadism).

In order to highlight pallor, the palms of the hands are examined, the nail bed and the mucous (conjunctive, oral) at normal temperatures. It is considered that the pallor of palm creases indicates a severe degree of anemia (hemoglobin below 7 g %).

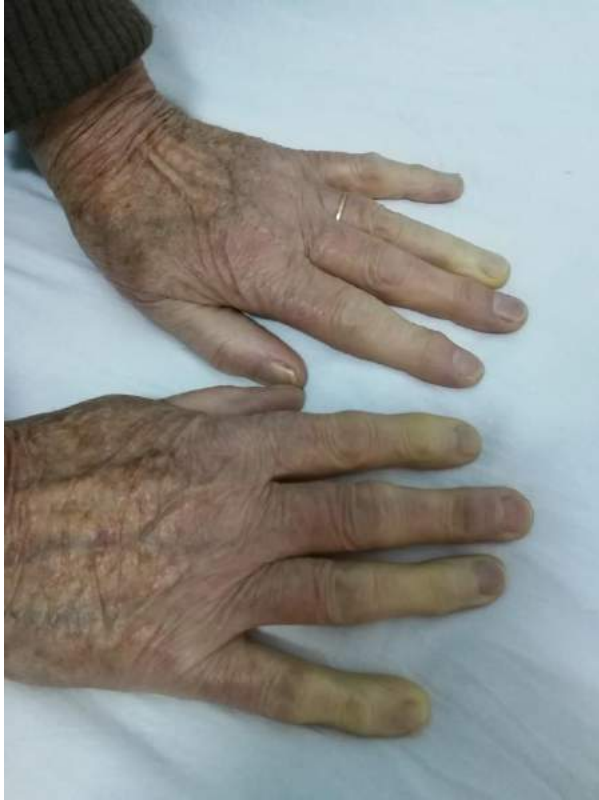- **Generalized pallor** can occur in:
  - The Biermer anaemia (megaloblastic): yellowish “waxy” pallor. It is associated with other disorders (the Hunter glossitis: red depapillated tongue); neurological disorders
  - Posthaemorrhagic anaemia: a “paper-like” pallor associated with sweats, arterial hypotension
  - Chlorosis: greenish pallor
  - Iron-deficiency anemia: whitish pallor, dry, frail hair, koilonychia, dysphagia
  - Haemolytic anaemia: association in pallor with the flavinic jaundice (lemon yellow)
  - Bacterial endocarditis: “milk coffee” pallor aspect
  - Neoplasia: earthy pallor
  - Malignant HTA, aortic insufficiency, arterial hypotension
  - Acute infectious diseases (typhoid fever, malaria) and chronic (TBC, chronic suppurations)
  - Hypogonadism, hypothyroidism
  - Chronic glomerulonephritis, nephritic syndrome, chronic renal insufficiency
  - Leukosis, reticulosis, collagenases
- **Localized pallor** can occur in:

- The Raynaud's syndrome: symmetrical pallor fits localized at the extremities followed by cyanosis and redness
- Arterial embolism at onset
- Acute thrombophlebitis (white *phlegmasia dolens*)



**Figure 20. Generalized earthy pallor (malignant lung tumor)**





**Figure 21. Raynaud phenomenon after cold exposure**

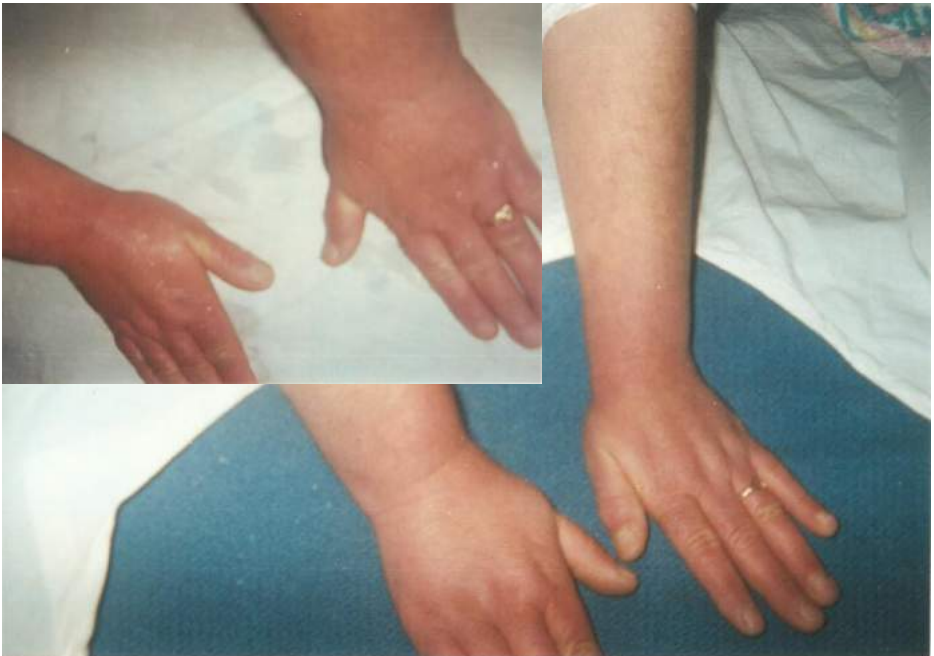## **REDNESS**

Redness appears in the dilation of cutaneous vessels and increase in hemoglobin quantities in peripheral circulation blood.

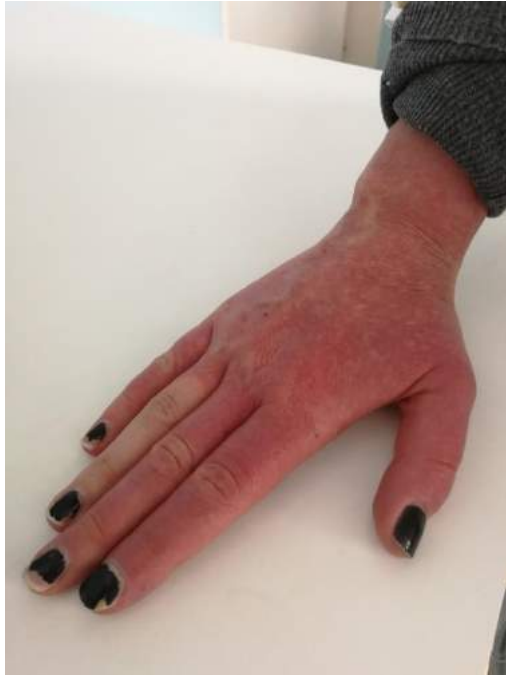- **Transient redness (the erythema)** represents a vivid redness, which disappears on pressing (eg.: shame erythema, solar erythema, feverish erythema). Transient erythema also appears in tumours which secrete serotonin, localized inflammatory processes, carbon oxide intoxication.

There are diseases which evolve with specific **erythematous eruptions**, such as:

- Measles, rubella, scarlet fever, typhoid fever, exanthematic typhos
- Erysipela: the red area with elevated margins, ulcer-like
- Nodular erythema: red dermo-hypodermic, warm, painful nodules, localized at calf level
- Persistent redness lasts longer and is found in: essential or secondary polyglobulitis (purplish-blue redness of the extremities), diabetes mellitus (redness of the face – diabetic rubeosis), the Cushing disease, chronic alcoholism, liver cirrhosis (redness situated at the level of palm eminences and the fleshy parts of the fingers), chronic lympholeukosis etc.



**Figure 22. Localized redness – erythromelalgia**



**Figure 23. Localized erythema – congenital red hyperpigmentation of the hand**

### **CYANOSIS**

It is a coloration disorder of the teguments and mucosae consisting of a bluish-purple coloration induced by the increase of reduced hemoglobin in the blood (over 5 g %), by the presence of certain abnormal hemoglobin (e.g. the Kansas hemoglobin) or of certain rare components of hemoglobin (met-hemoglobin, sulph-hemoglobin).

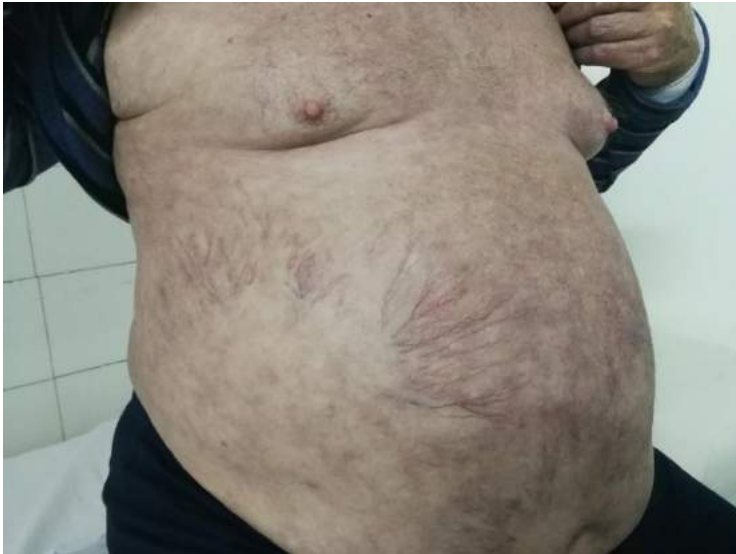Cyanosis needs to be differentiated from pseudo-cyanosis which is a coloration similar in aspect, which appears in several situations: blueberry consumption, black cherry consumption (the pseudo-cyanosis of the lips), argyrrhosis (the setting of silver salts in the tegument), arsenic melanosis.

**The intensity of cyanosis** depends on the thickness of the tegument, the degree of capillarization of the skin, the filling and dilation of the capillary vessels and venules, pigmentation of the skin, the hematite count (it is best observed in patients with polyglobulitis and is hard to discern in those suffering from severe anemia).

- **Central cyanosis:** is due to insufficient oxygenation at pulmonary level or of a left-right intracardiac shunt.

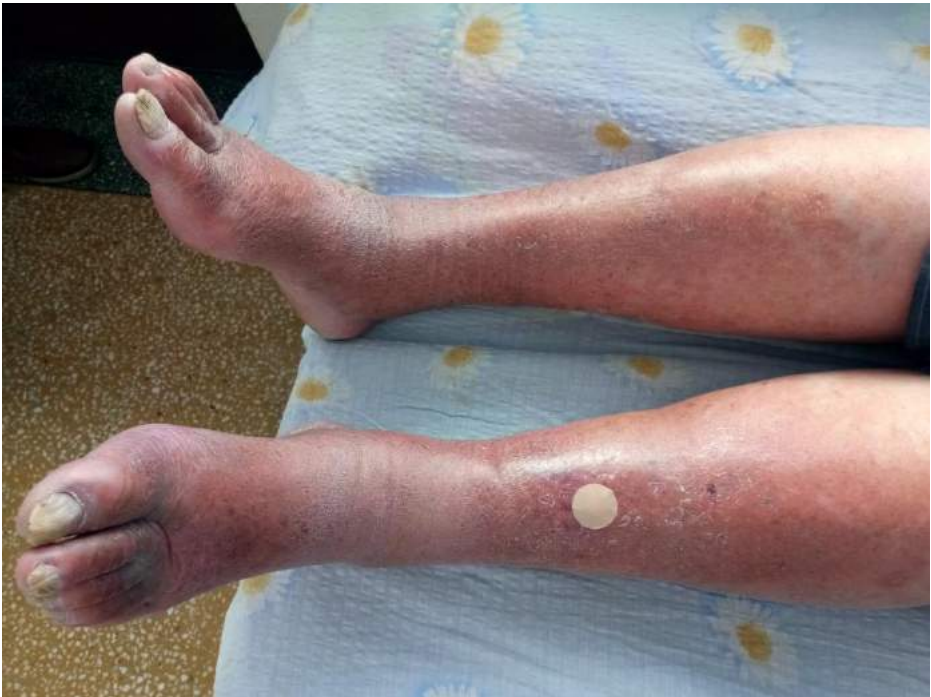Semiological characteristics of central cyanosis are the following:

- It is generalized
- It is warm
- It concerns both the skin and the mucosa
- It increases with effort
- After applying digital pressure it is recovered without having to pass through transient redness
- On massaging the ear lobe it does not disappear (the Lewis test)



**Figure 24. Generalized cyanosis in a patient with severe COPD; multiple angiectasis disposed "in bouquet"**

- **Peripheral cyanosis:** is induced by vaso-constriction and stasis, which enable an increased supply of oxygen by tissues in the arterial blood. It can be both generalized and localized:
  - **Generalized peripheral cyanosis** is found in chronic cardiac insufficiency and shock (through cutaneous vasoconstriction), in tricuspid insufficiency and constrictive pericarditis (through the increase in venous pressure)
  - **Localized peripheral cyanosis** can occur due to a arterial circulation deficit (exposure to cold, Raynaud syndrome), arterial obstruction (atherosclerosis, Buerger's disease, vasculitis), venous circulation deficit (profound thrombophlebitis, varices, chronic venous insufficiency)



**Figure 25. Peripheral cyanosis in a patient with both chronic arterial obstruction and chronic venous insufficiency**

**Semiological characteristics of peripheral cyanosis are:**

- It is cold
- It only concerns the teguments
- After applying digital pressure, it heals through transient redness
- It disappears after massaging the ear lobe

**JAUNDICE**

Jaundice represents the yellow coloration of the scleras, the teguments, mucuses determined by the rise in bilirubin in the blood over and above normal values and its storage in the tissues (normal values 0.5 – 1 mg %).

The yellow coloration of the teguments becomes visible when seric bilirubin goes beyond 2.5 – 3 mg % (50 umols/l); the conjunctive or sublingual subjaundice is visible for values above 1.5 – 2g%.



**Figure 26. Jaundice more evident on sclera than on skin**

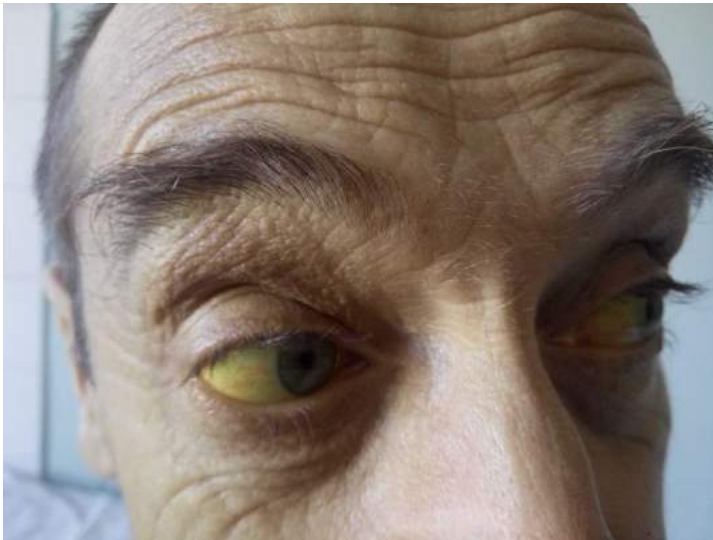The jaundice (sign) is accompanied by other symptoms, signs, biochemical modifications, forming the icteric syndrome which has various causes.

Semiological aspects in the icteric syndrome are:

- **The examination technique:**

Examination of the jaundice is performed in natural lighting (15-20% of moderate jaundice can escape in fluorescent lighting). The examination of the scleras and the oral cavity palate (through raising the tip of the tongue) is necessary for discerning the small degrees of jaundice (in hyperpigmented patients and with increased subconjunctive fat). Impregnation of the teguments and the mucuses with biliary pigments does not disappear in vitro or on applying digital pressure.

**Figure 27. Subjaundice (evident only on scleras)**

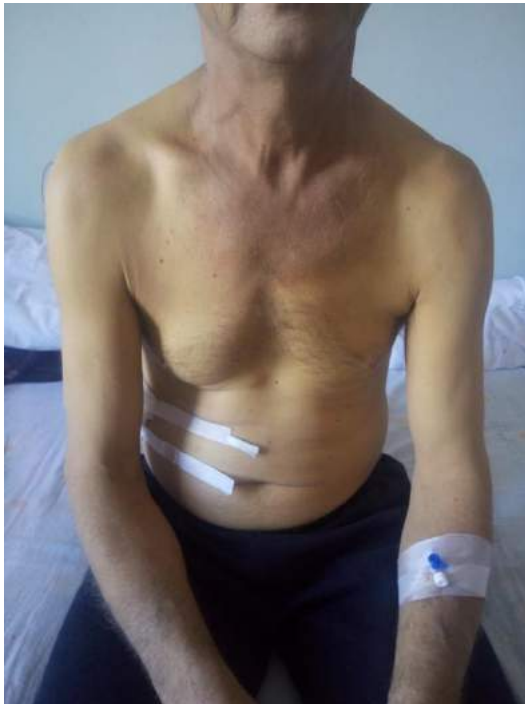

**Figure 27. Subjaundice (evident only on scleras)**

- **The shade of the jaundice:**

There are four shades of the jaundice:

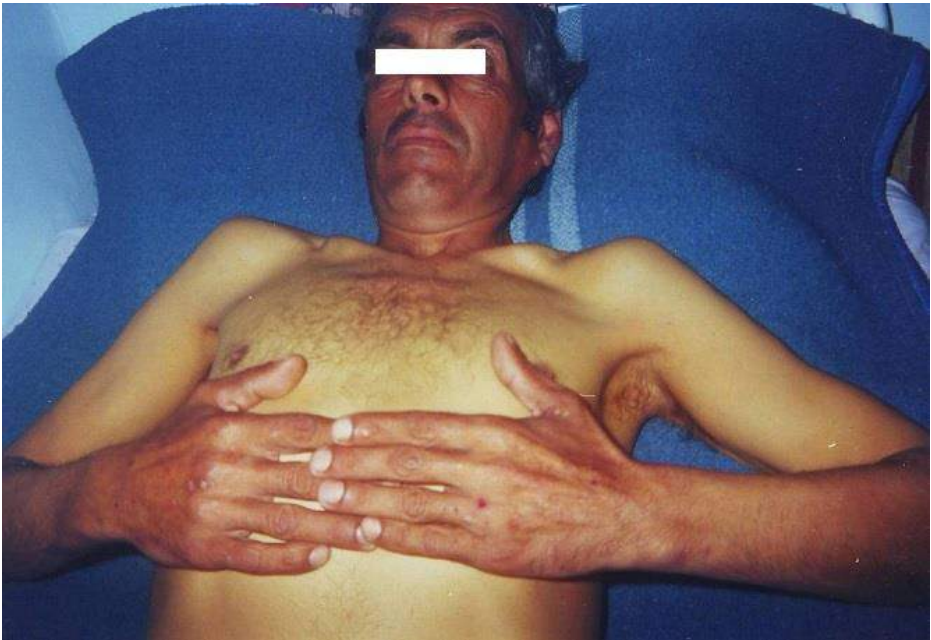- Citrine jaundice: light yellow (pale as a lemon). This is the haemolytic jaundice which results from a mixing of pallor (anaemia) and jaundice
- Green jaundice: greenish (greenish-brown), appears though the transformation of bilirubine in billiverdine. It is an obstructive jaundice (cholestatic) or severely hepatocellular
- Rubinic jaundice: yellowish-ruby (orange), jaundice with tegumentary febrile hyperemia. It is found in haemorrhagic spirochetosis (leptospirosis), hepatic jaundice.
- Melas or black jaundice: there is a very high chronic retention of billiary pigments transformed in billiverdine, such as cancer of the pancreatic head.



**Figure 28. Jaundice more evident on the thorax, in a patient with recent liver puncture for investigation of a possible hepatocarcinoma**



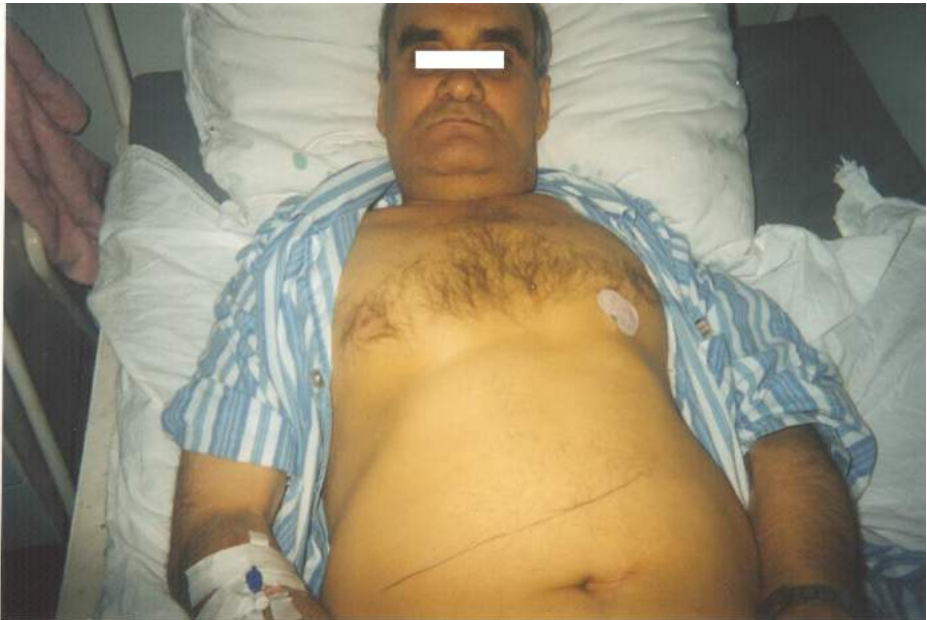- **Intensity of the jaundice** is directly proportional to the production/elimination ratio, sometimes resulting in the dissociation between serum bilirubin levels and sclerogegumentary jaundice.
  - Moderate jaundice: occurs in haemolysis, bilirubin  $< 100 \mu$  mole/l is associated with pallor, normal urine levels, normal stool
  - More severe jaundice: appears in the hepatobiliary disease, is associated with dark urines, discolored stools, generalized pruritus and /or steatorrhea, obstruction of a bile duct which also determines abdominal pains, while in the hepatic neoplasm the onset of fever is also observed



**Figure 29. Generalized rubinic jaundice, leuconichya**

- **Other causes** of yellow color of the teguments (but not of the scleras):

- Administration of mepacrine (atebrine), vitamin A, pyric acid, fluorescein, acryflavine (in pharmacological doses)
- Excessive carrot, pumpkin and tomato consumption determines yellowness of hands through carotene and lycopene storage
- Subconjunctive pallor or fat in the hyperpigmented patients
- The **onset and evolution** stages, other symptoms and accompanying signs



**Figure 30. Green jaundice (verdinic jaundice) due to cholestasis; gross tumoral enlargement of the liver**

- **Biochemical explorations and modifications:**

<i>Type + mechanism</i>	<i>Site of alteration</i>	<i>Cause</i>	

Prehepatic Bi overproduction	Hgb ↓ Billirubine ↓	Haemolysis Hemoglobinopathies	Absence of hepatic affection Bil. I ↑
Hepatic Alteration of uptake + transport; conjugation	conjugation ↓	Family jaundice (Gilbert) Hepatitis alcohol drugs cirrhosis	Ibid  Clinical hepatic + biochemical affection ↑ Bil. D + I
Cholestatic (posthepatic) Intrahepatic obstacle or on the evacuation ducts	hepatocytes canaliculi release ↓ ductules ↓ Bile ducts ↓ pancreas ↓ Duodenum	drug Dubin Johnson Rotor CBP, CSP  cancer – lithiasis  head pancreas cancer Vater's ampulloma	Bil. D ↑ + pigm.

### Evolution of disorders in cholestasis

Obstacle in the elimination of the bile



Reduction of biliary acids in the intestines --> skin accumulation --> pruritus



Deficit of fat emulsification



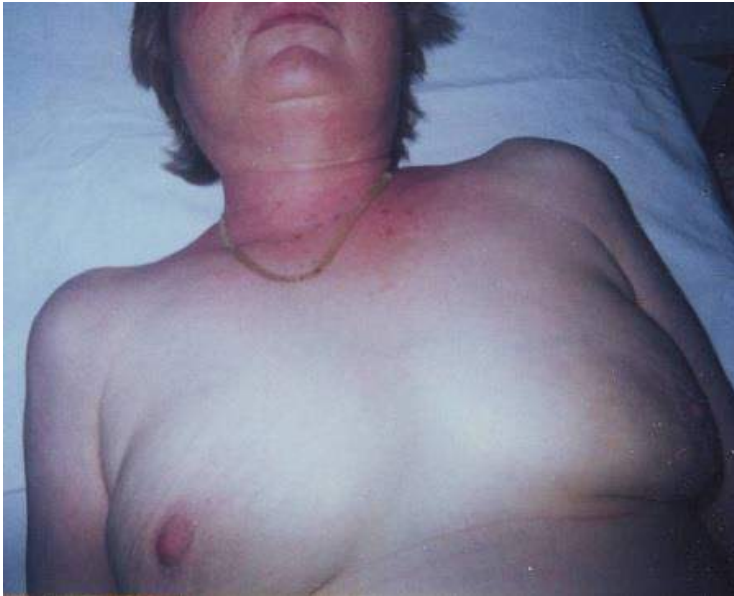steatorrhea --> diarrhea, malabsorption, weight loss, pigmentation of the teguments, hippocratic fingers, diminution of plasmatic proteins



Faulty absorption of vitamins: A – sight problems; D și C - osteomalacia, fractures; K – coagulation disorders; E – muscle asthenia

## **HYPOPIGMENTATIONS – DEPIGMENTATIONS**

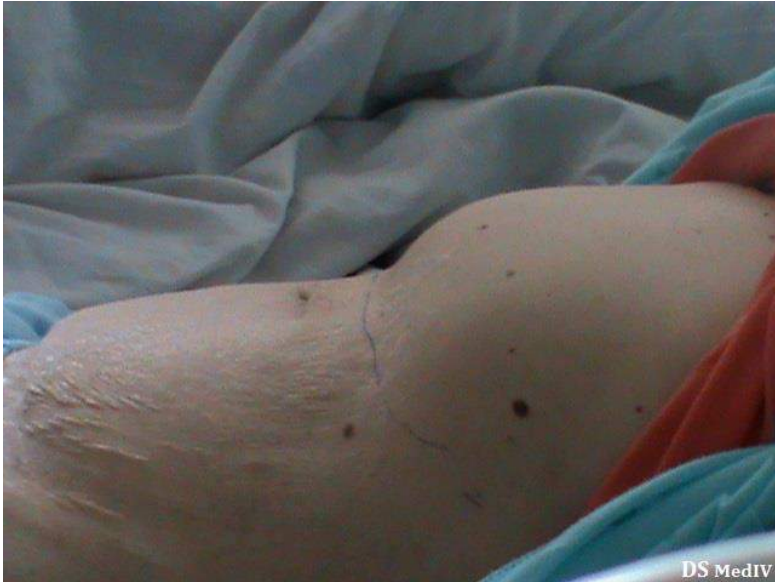- **Albinism** – while color of the skin caused by the lack of melanin secretion, which can be total or circumscribed; total albinism concerns the teguments, the eyes and the hair and is genetically determined



**Figure 31. Albinism, liver cirrhosis**

- **Vitiligo** – skin depigmentation (and of the hair strands) is clear cut, symmetrical and surrounded by an area of hyperpigmentation; it appears in pernicious asthenia, epilepsy, autoimmune hepatitis etc.; it is acquired.

- **White stretch marks** – linear depigmentation of the conjunctive tissue, occurring in pregnancy or rapid weight loss

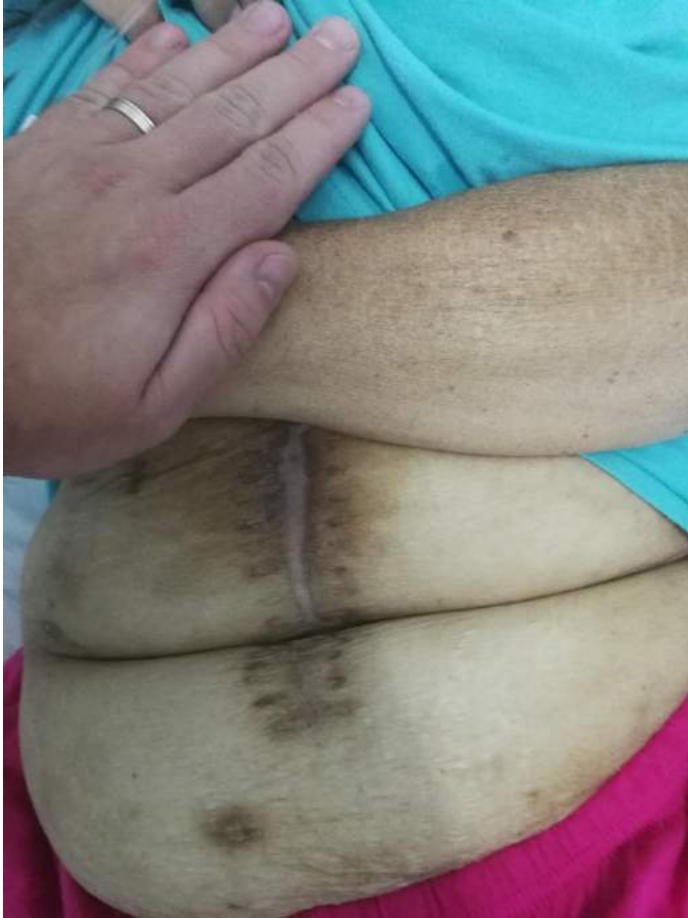

**Figure 32. White stretch marks**

## **HYPERPIGMENTATIONS**

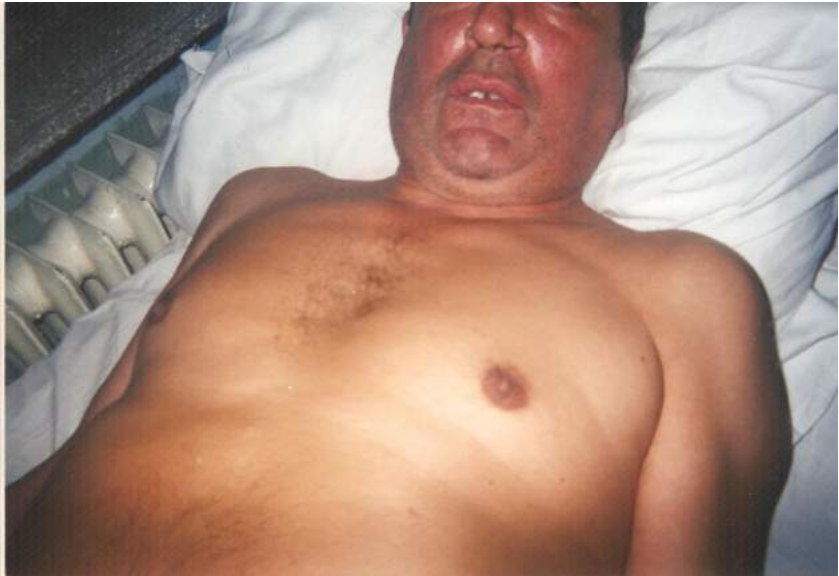Hyperpigmentations are diffuse or regional, due to excessive pigmentation at skin level.

- Diffuse hyperpigmentations through melanic pigments:
  - In the Addison's disease – it interests the nipple, underarms, genital organs. The palmoplantary regions, eyelids and nails retain their normal pigmentation. It appears through excessive pituitary melanotrope hormone production
  - Chronic intoxications with gold, silver, corticoid therapy, chronic renal insufficiency, ovarian insufficiency can all determine pseudo-Addisonian hyperpigmentations



**Figure 33. Pseudo-Addisonian hyperpigmentation**

- **Diffuse, non-melanic** hyperpigmentation: in haemochromatosis (bronzed diabetes) through hemosiderin storage in skin, mucuses and several organs
- **Diffuse constitutional (racial)** hyperpigmentations: in the African Black race, dark-haired individuals, ephelis (freckles) in certain blond individuals (which become visible in summer through sun exposure and during pregnancy)

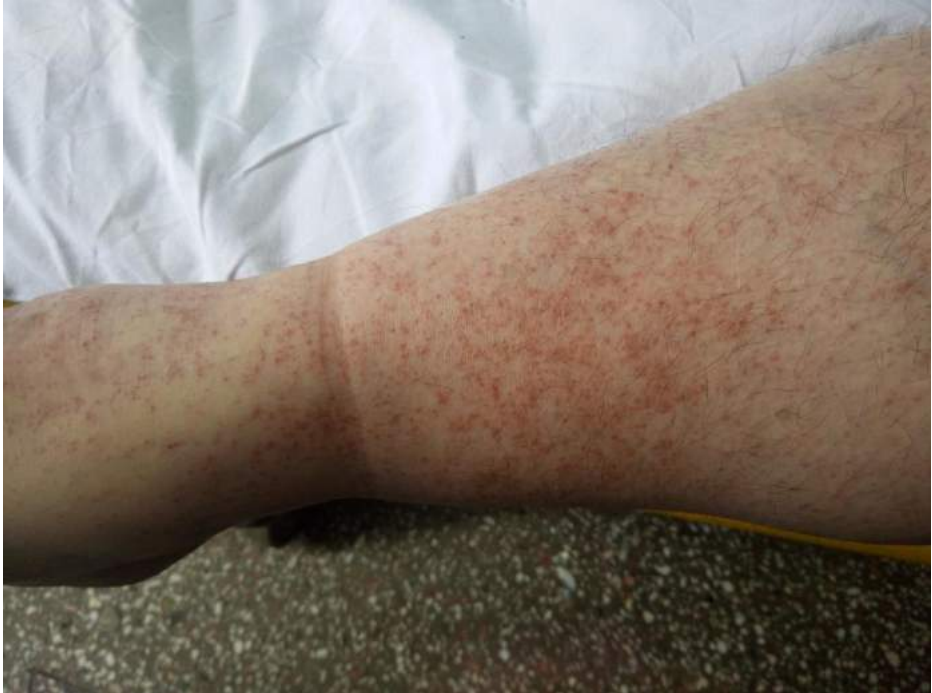

**Figure 34. Melanoderma (bronzed diabetes)**

- **Regional hyperpigmentations:**
  - Pregnant chloasma: consists of brown spots situated on the forehead, the temporal region, the cheekbones, over the nose, nipples and the white line, which appears in the first months of pregnancy or in premenopause, ovarian tumours, malaria, hepatopathies
  - Pigmentary nevi: blackened brown spots on the face, the periorbital and perioral regions (Peutz-Jeghers syndrome – evolves with gastric and recto-colic polyposis)
  - In vitamin deficiencies, pellagra, chronic alcoholism, hyperpigmentation can appear at dorsal face level on the hands, neck
  - In certain chronic intoxications (silver, gold, arsenic) regional pigmentations are observed

### 1.3.9. CUTANEOUS HEMORRHAGE (PURPURA)

- **Purpura** is a cutaneous hemorrhage (blood extravasation) and mucous hemorrhage with sudden onset (or occurring in minimal trauma).
  - **Simple purpura** is localized on the tegument.

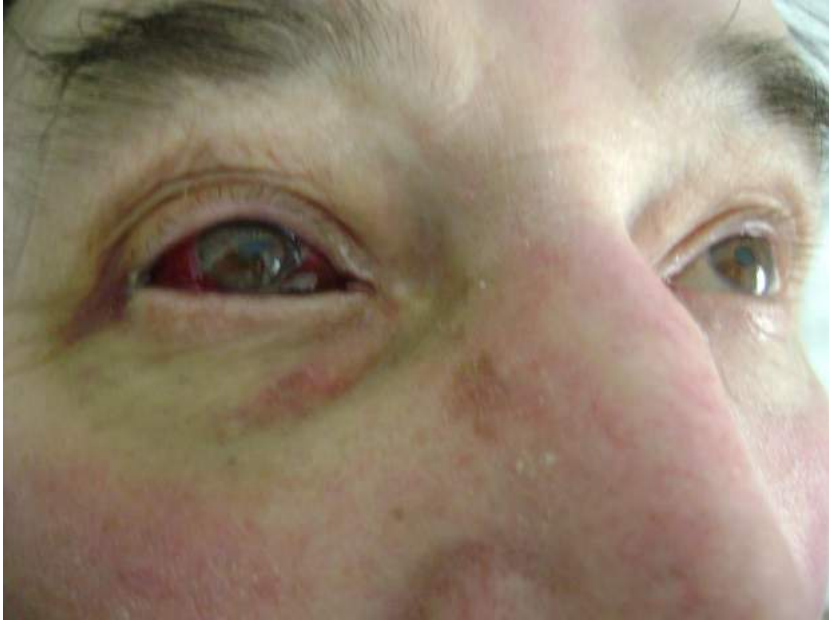

**Figure 35. Purpura of the lower limbs (petechiae)**

- **Hemorrhagic purpura** is localized in the mucous or serous teguments. Examples:
  - epistaxis – nasal hemorrhage
  - gingivorrhagias - stomatorrhagia – hemorrhage of the gums
  - hematemesis, melena (upper digestive hemorrhage) – blood release through vomiting or stool from the esophagus, stomach, duodenum



- haematuria – urine with blood
- haemothorax - hemorrhage in the pleural cavity
- hematrosis – hemorrhage in the articulations
- hematoma – organ, tissue and sometime cutaneous hemorrhage

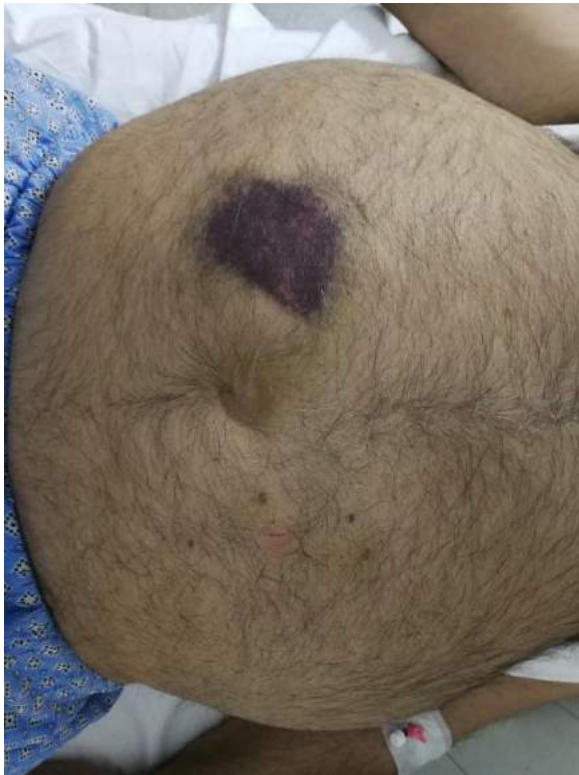

**Figure 36. Hemorrhagic purpura (anticoagulant overdose)**

**Semiological characteristics of purpura:**

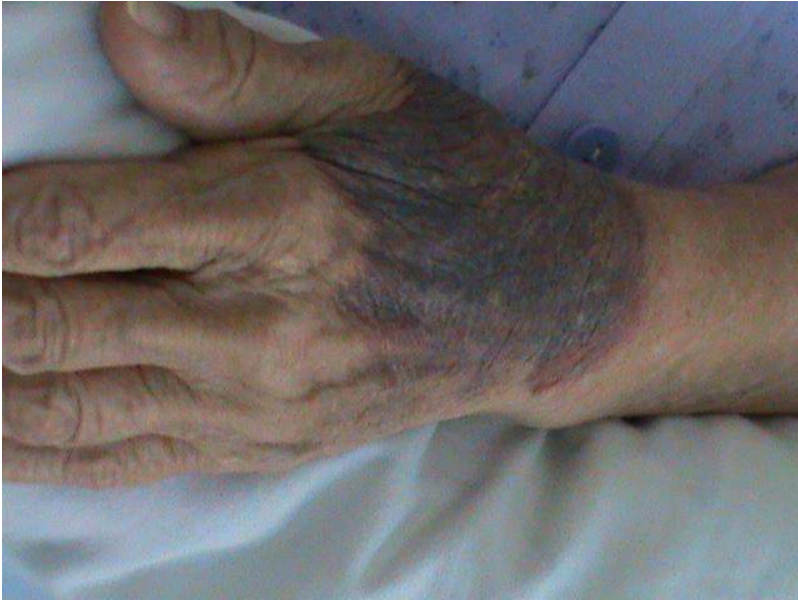- appears spontaneously, in any area or in minimal trauma
- appears more frequently at lower limb level due to the rise in hydrostatic pressure
- it does not disappear on applying pressure (digital, vitropressure). This fact constitutes a diagnosis factor differential to eruption
- purpura is level (at tegument level), with the exception of purpura Henoch Schonlein

- the color: red -> bluish/purple -> yellow -> it disappears, due to the transformation of hemoglobin. The color is an indication of the time the lesions were produced
- it usually disappears without trace or becomes brownish in color through hemosiderine storage
- it has different forms and sizes:
  - **petechiae**: purple round oval marks smaller than 1 cm (usually in the form of a dot); these appear more frequently in haemorrhagic thrombocytopenic or vascular syndromes
  - **ecchymosis**: larger than 1 cm (sanguine extravasations), more profound



**Figure 37. Abdominal ecchymosis due to anticoagulant injections**

- **suffusions:** wider, more extended surface, they appear more frequently in coagulopathies, fibrinolysis



**Figure 38. Suffusion post-catheterization**

- **vibix:** linear cutaneous hemorrhage (like in horse whipping), more frequent at flexion fold levels

Simple or hemorrhagic purpura appears in hemostasis disorders and is called **hemorrhagic diathesis** or **hemorrhagiparous syndrome**.

Hemostasis disorders can be: vascular, thrombocytar and coagulation disorders.

- **Vascular purpura** is caused by:
  - Structural anomaly of the vascular walls (Rendu-Weber-Osler disease).
  - Increase of capillary fragility through infectious factors (Schonlein-Henoch purpura), degenerative (senile purpura), deficient (vitamin C deficiency in scorbutus)

etc. it is a superficial purpura, localized in the calves, gluteus, forearms, arms (areas exposed to mechanical trauma)

- **Thrombocyte purpura** appears in the following:
  - Quantitative platelets affectations (thrombocytopenia): the Werlhof disease, secondary thrombocytopenia
  - Qualitative platelets affectations: congenital thrombopathy, acquired thrombopathies (the Glanzmann disease, the von Willebrand disease)

It is a hemorrhagic purpura, with mucous petechiae and hemorrhages on the exposed areas.

- **Coagulopathies** can appear in:
  - The lack of certain coagulation factors such as thromboplastin, hemophilia A (VIII), B (IX), C (XI)
  - Prothrombin deficit (synthesis diminishes, low vitamin K levels) or fibrinogen.

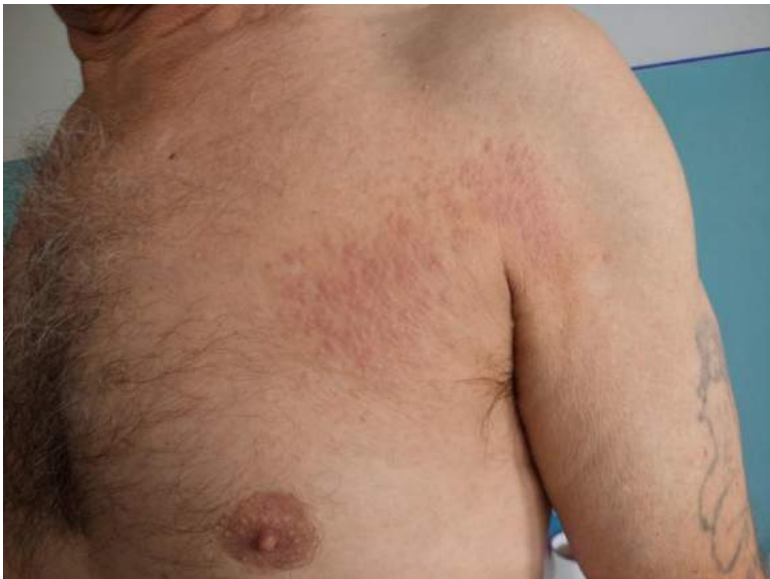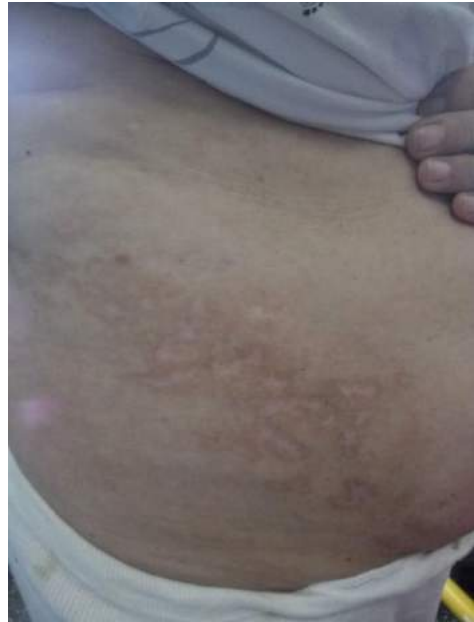It has the aspect of a hemorrhagic purpura with ecchymoses, suffusions and hematomas.

### 1.3.10. SKIN LESIONS

- **Primary:** they manifest spontaneously as a consequence of a local or general pathological process.
- **Secondary:** they result from the late evolution of primary lesions or their treatment
- **Skin rash** consists of the sudden appearance on the skin surface of formations with various colors, shapes and sizes and is called *exanthema*. When the rash develops in the mucosae, it is called *enanthema*.
- **Elementary skin lesions:**
  - ⇒ **Macule (spot):** a change in color, of variable size, smooth, non-elevated

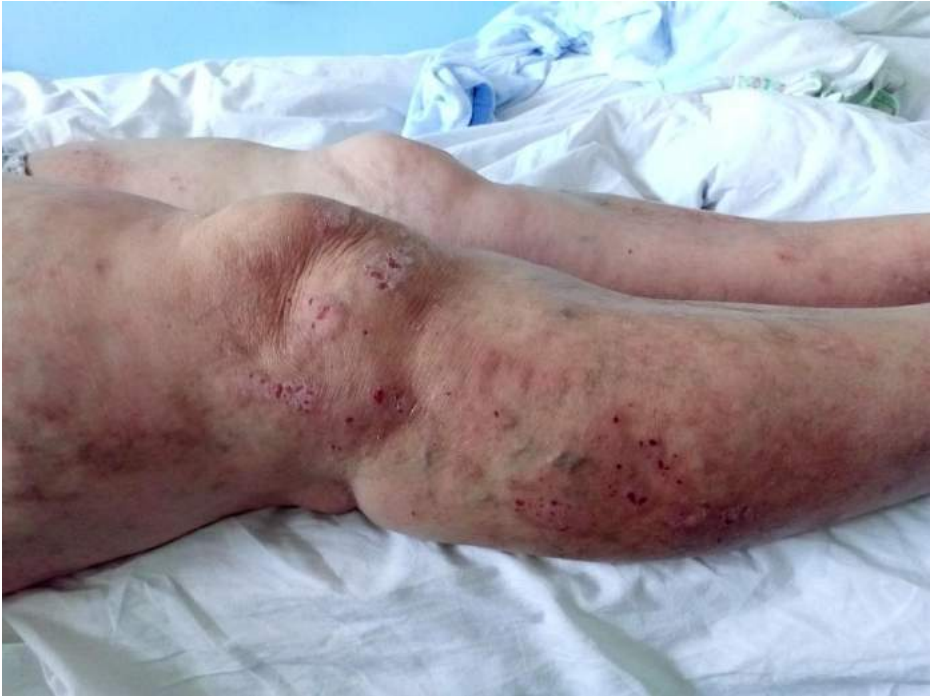**Figure 39. Confluent hypopigmented macules with hyperpigmented borders (remnants after the healing of an abdominal Zona-Zoster)**

⇒ **Papule:** a slight prominence above the plane of the skin over a small area (less than 0.5 cm<sup>2</sup>), palpable by a slight touch of fingers over the region



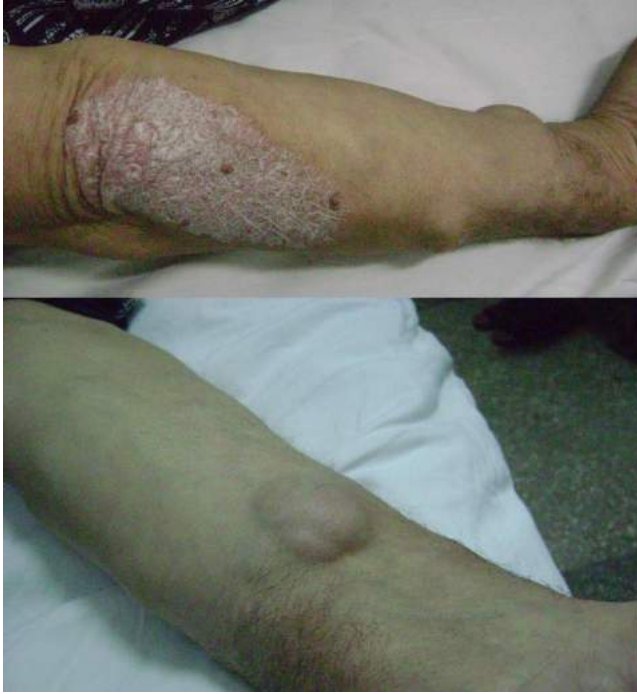**Figure 40. Multiple papular lesions in an allergic eruption**

⇒ **Plaque:** a well circumscribed skin prominence, with sizes >1cm

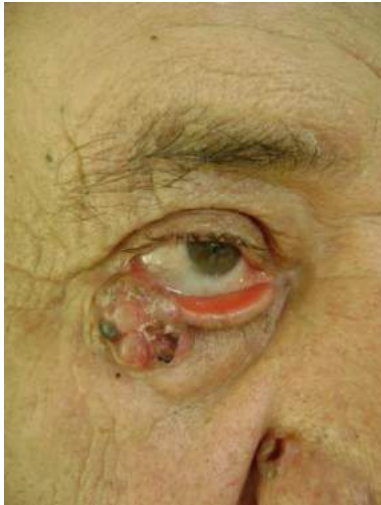

**Figure 41. Multiple plaques and macules – scratch lesions in a patient with pruritus**

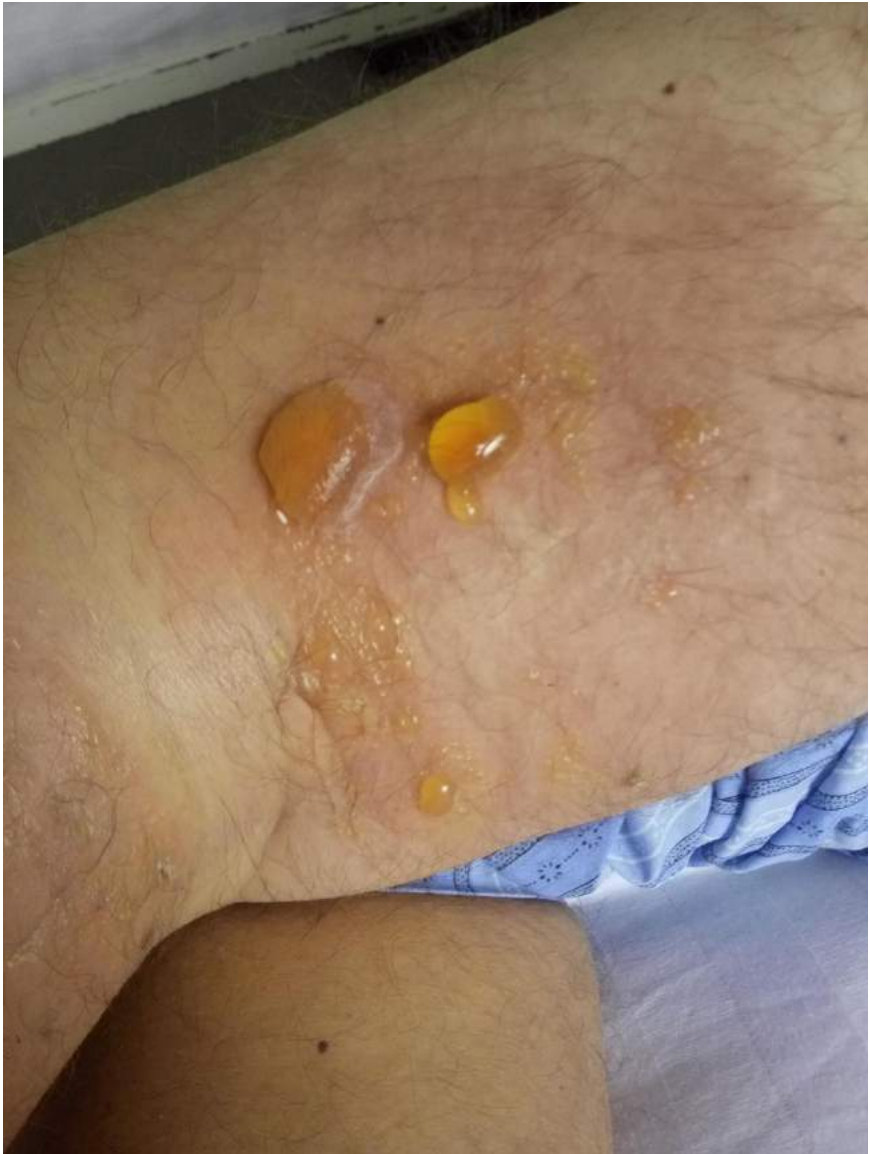- ⇒ **Nodule and tumorette:** well delimited elevated dermal-hypodermal formations, of variable sizes
- ⇒ **Vesicle:** a well circumscribed, elevated formation, less than 1 cm in size, which contains clear or slightly opalescent fluid
- ⇒ **Pustule:** a vesicle with a cloudy or purulent content
- ⇒ **Bullae:** the same appearance as the vesicle but with sizes >1cm and serous content
- ⇒ **Cyst:** an encapsulated collection of fluid or semifluid content



**Figure 42. Typical psoriasis plaque (elbow region) and a forearm tumorette**

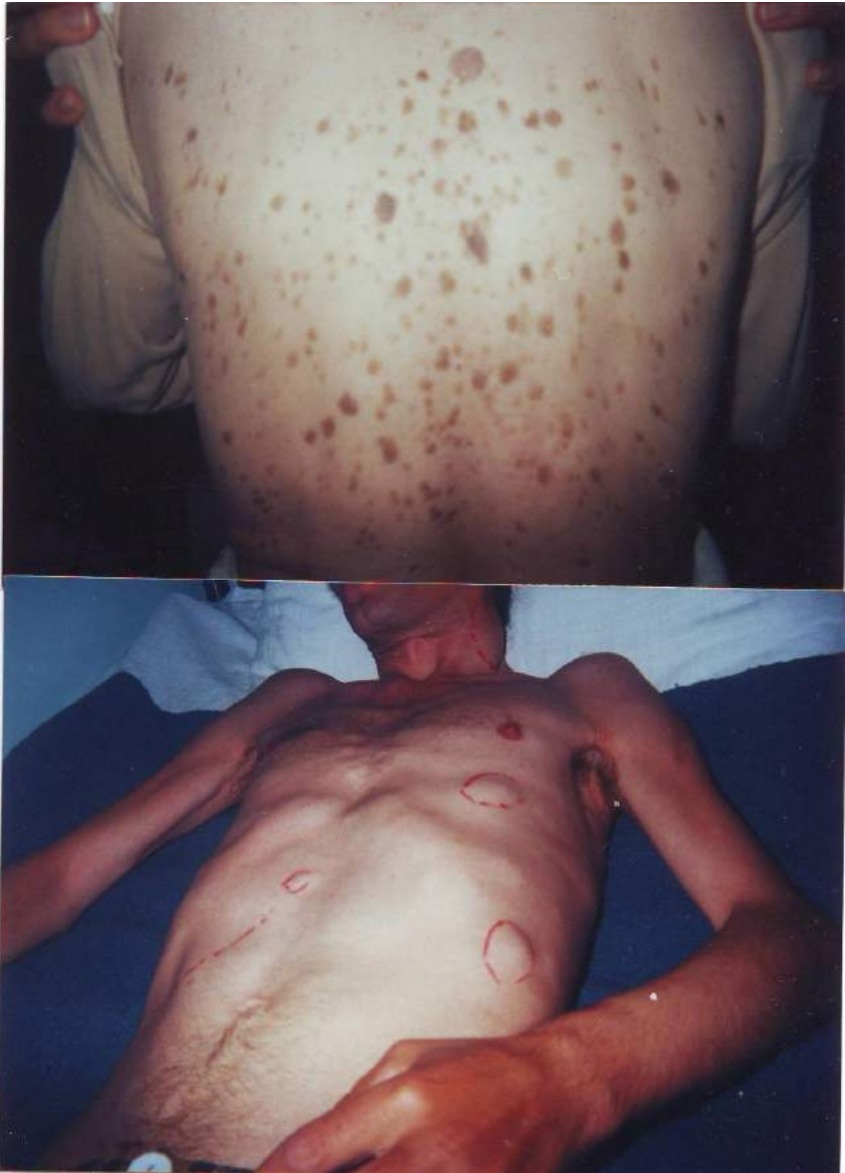

**Figure 43. Tumorette of the lower eyelid**



**Figure 44. Multiple vesicles and bullae on an erythematous plaque (healing of an atypical erysipelas)**





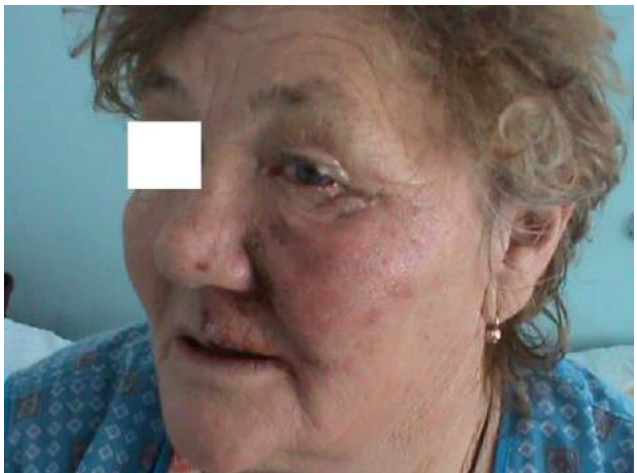**Figure 45. "Café au lait" spots, multiple nevi and nodules – von Recklinghausen`s disease**

- **Skin rashes in infectious diseases:**

- ⇒ **Scarlet fever:** A micropapular eruption on a hyperemic background of scarlet red color, spread over the entire body surface, which gives a “boiled crawfish” appearance. On palpation, skin is rough. The eruptive elements spare the face. At this level, diffuse cheek redness occurs in contrast to the perioral, perinasal and periorbital pallor, forming the *Filatov mask*. The eruption is more severe at the level of flexion folds, sometimes even hemorrhagic, which represents the *Pastia Grozovici* sign. At the end of the eruptive period, skin desquamation occurs. There are also tongue changes: the “*raspberry*” tongue through the hypertrophy of lingual papillae on the background of a hyperemic mucosa.
- ⇒ **Rubeola or measles:** A maculopapular rash, of pink color, with onset in the cephalic extremity (behind the external ear and on the forehead at the limit of the hairy region), which rapidly extends to the body and limbs. Skin is soft on touch. The eruptive elements disappear in the order of their appearance. Enanthema that precedes the skin rash is pathognomonic: on a hyperemic background, slightly elevated white spots appear (like semolina grains) on the inner side of the cheeks and in the gums, at the level of the molars – *Koplik sign*.
- ⇒ **Rubella:** The rash resembles the measles rash. A small number of pink macules appear in the cephalic region, extending downwards. These are slightly pruriginous and have a short evolution (they disappear in 2-3 days). Associated micropolyadenopathy is characteristic.
- ⇒ **Varicella:** A skin rash develops over the entire skin surface, which is more severe on the body, also affecting the hairy skin of the head and the mucosae. Initially, disseminated red macules appear, which change into papules, then vesicles (with clear

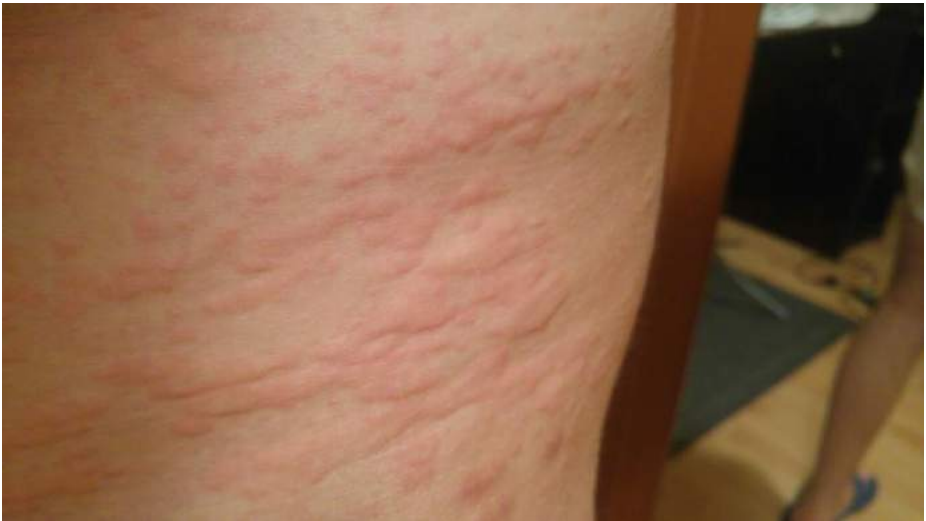content like “dew drops”). These turn into pustules that undergo an umbilication process with fluid resorption and the appearance of crusts, after which non-permanent scars are left. Lesional polymorphism, i.e. the concomitant presence of eruptive elements at various evolution stages, is characteristic.

- ⇒ **Smallpox:** A skin rash similar to the varicella rash, which does not spare the mucosae and the hairy skin of the head. The eruptive elements tend to group at the extremities, where all elements are at the same evolution stage. Vesicles are hard on palpation (like “glass pearls”). Crust shedding leaves permanent scars.
- ⇒ **Herpes:** The rash starts with a pruriginous maculopapule or plaque that shortly changes into vesicles with a clear, then opalescent fluid. After the rupture of the membranes, a wet denuded surface appears, which is covered with a crust. After crust shedding, a more pigmented area can be left. The rash is located in mucocutaneous zones (labial, nasal, genital).
- ⇒ **Herpes zoster:** The rash is similar to the herpes rash. The eruptive elements are numerous, grouped unilaterally in the cutaneous territory of a nerve (intercostal, abdominogenital, ophthalmic, otic). The rash is preceded, accompanied or followed by (sometimes atrocious) neuralgic pain and regional adenopathy.



**Figure 46. Healing of  
on ophthalmic Zona  
Zoster**

- ⇒ **Erysipelas:** It is diffuse skin lymphangitis that appears as an extensive bright red patch, with well demarcated, slightly raised borders that are termed bourrelet. The area is painful, sensitive and hot. It is predominantly located in the extremities or the face, adjacent to small skin lesions (entrance gate) that frequently remain unseen.
- ⇒ **Typhoid fever:** The rash consists of rare, small lenticular spots (macules) on the abdomen and chest. These are termed typhic rose spots and appear late during the disease evolution.
- ⇒ **Exanthematic typhus:** A macular, sometimes hemorrhagic rash appears on the body, which spares the face, the neck and the nape.
- **Other skin rashes:**
  - ⇒ **Urticaria:** white yellowish papules or plaques surrounded by a pink-red halo. The eruptive elements are extremely pruriginous, they appear and disappear rapidly. They are the cutaneous expression of an allergy to food, foreign proteins, drugs.



**Figure 47. Urticarian eruption in an adolescent allergic to peanuts**

- ⇒ **Drug eruptions:** their aspect is extremely different depending on the type of reactivity of the body. Lesions can be urticaria-like, scarlet fever-like, measles-like, vesicular or hemorrhagic.
- ⇒ **Erythema nodosum:** it manifests by nodules of various sizes, of pink-yellowish, then purple color, painful on palpation, located particularly in the calves. They are accompanied by fever and articular pain. They occur in: allergic drug reactions, acute articular rheumatism, TB, sarcoidosis.
- ⇒ **Xanthomas** are dermal nodules formed by lipid material of variable sizes, which develop along tendons or palmar folds.
- ⇒ **Xanthelasma** is located in the inner angle of the upper eyelid. It occurs in hypercholesterolemia, hyperlipoproteinemia.



**Figure 48. Xanthelasma in a patient with familial hypercholesterolemia**

- ⇒ **Dermographism** consists of the appearance of red marks when the skin is slightly scratched, indicating a reactive hypersensitivity of vasomotor nerves in people with

neurovegetative lability. It occurs in neurological diseases such as: meningitis, myelopathies (Trousseau's marks).

### 1.3.11. COLLATERAL CIRCULATION

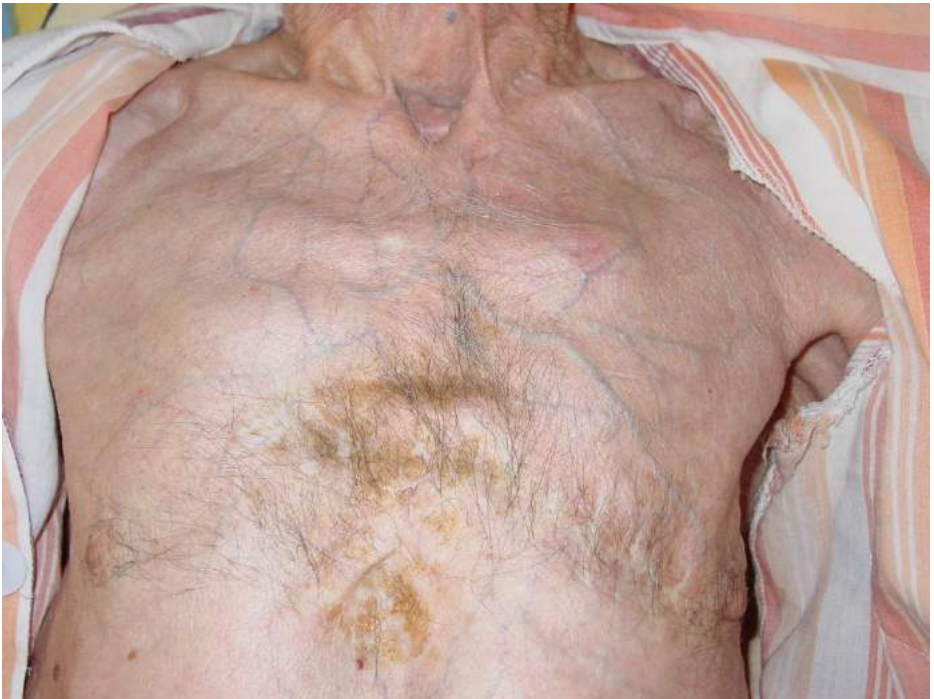The arterial blood supply and venous drainage of organs are not only ensured by the main vascular trunks, but also by collateral pathways that are normally not functional or visible. The partial or total obstruction of a large vessel determines the opening of anastomoses with other vessels, which results in collateral circulation.

- **Arterial collateral circulation:** it is more rarely found; it manifests by pulsatile arterial cords in the intercostal spaces and the interscapulovertebral space. Due to the strong pulsations, radiologically visible rib erosions can occur; this type of circulation is pathognomonic of the disease called **aortic coarctation**. The narrowing of the lumen of the aorta at the level of the isthmus partially shunts blood to the brachiocephalic trunk, the left subclavian artery and the first intercostal arteries.
- **Venous collateral circulation:** it is much more frequently found; it occurs in the case of an obstruction at the level of the three main venous trunks: the superior vena cava, the inferior vena cava and the portal vein.

⇒ **superior cavo-caval** circulation

It occurs when there is an obstruction of the superior vena cava. Blood circulates counter-current through the azygos vein, the hemiazygos vein towards the intercostal veins, the lumbar vein and then the inferior vena cava. Turgescient venous cords are formed in the flanks, hypochondria, the lateral regions of the chest, which disappear in the axillary areas. Associated jugular turgescence and upper thoracic venectasia occur; in advanced disease cases, cyanosis and “mantle” edema develop. The palpation of the venous cord shows that blood circulates from up to down. This type of circulation appears in mediastinal syndrome, in

which the compression of the superior vena cava occurs (tumors, adenopathies, goiter).



**Figure 49. Superior cavo-caval circulation**

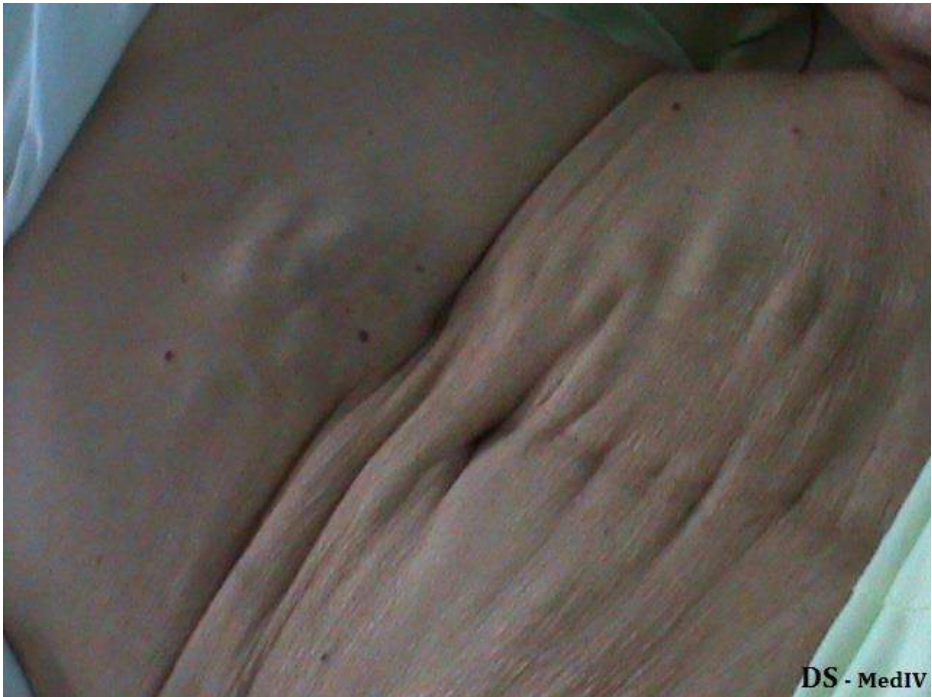⇒ **inferior cavo-caval** circulation

It is caused by the obstruction of the inferior vena cava and has a similar appearance to superior cavo-caval circulation, but cyanosis and “mantle” edema affect the lower half of the body. Blood circulates from down to up. The most frequent causes of this type of collateral circulation are the thrombosis of the inferior vena cava and its extrinsic compression through abdominal tumors.

⇒ **porto-caval** circulation

It develops when there is an obstruction of the portal vein. Blood is shunted through the internal collaterals (stomachic coronary veins, esophageal veins with the development of esophageal varices,

hemorrhoidal veins with the occurrence of hemorrhoids) and through anastomoses between retrocolic and peritoneal veins. At the same time, external venous collateral circulation is initiated through the repermeabilization of umbilical veins, with the typical “**medusa head**” appearance, given by vein dilation from the umbilicus to the periphery, radially, in which blood circulates towards the margins. **Causes:** liver cirrhosis, suprahepatic vein thrombosis (Budd-Chiari syndrome), portal vein thrombosis (pylethrombosis).



**Figure 50. Collateral circulation due to repermeabilization of the umbilical vein**

- **Telangiectasias** consist of permanent dilations of the dermal capillaries, sometimes also visible in the mucosae, which occur:  
⇒ in alcoholics at facial level (paper money skin)

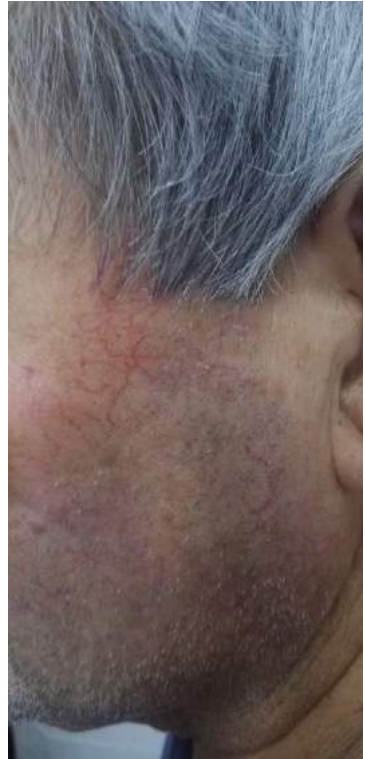

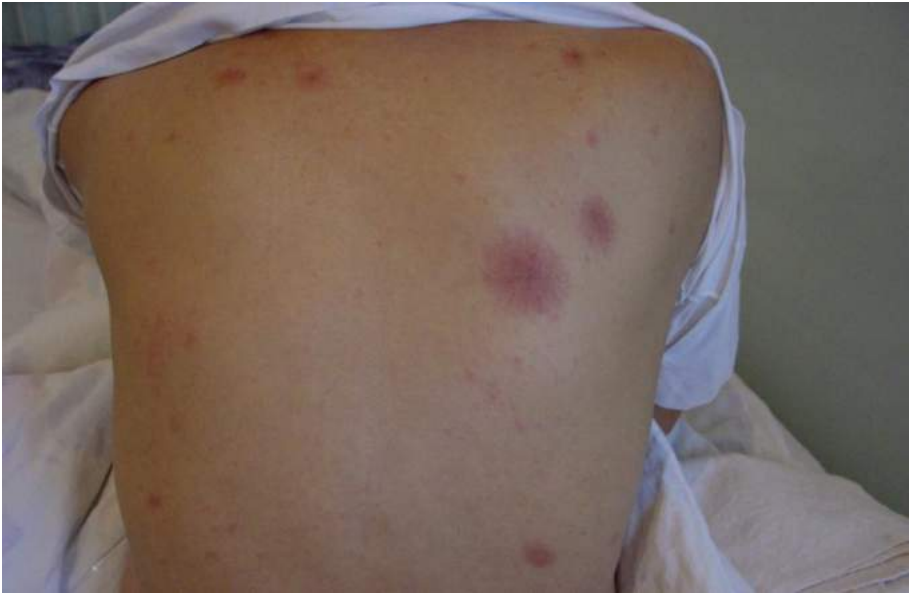⇒ in Rendu-Osler disease (hereditary hemorrhagic telangiectasia), in which telangiectasias develop in the face and mucosae (oral, nasal, digestive).

**Figure 51. Telangiectasias in an alcoholic patient**

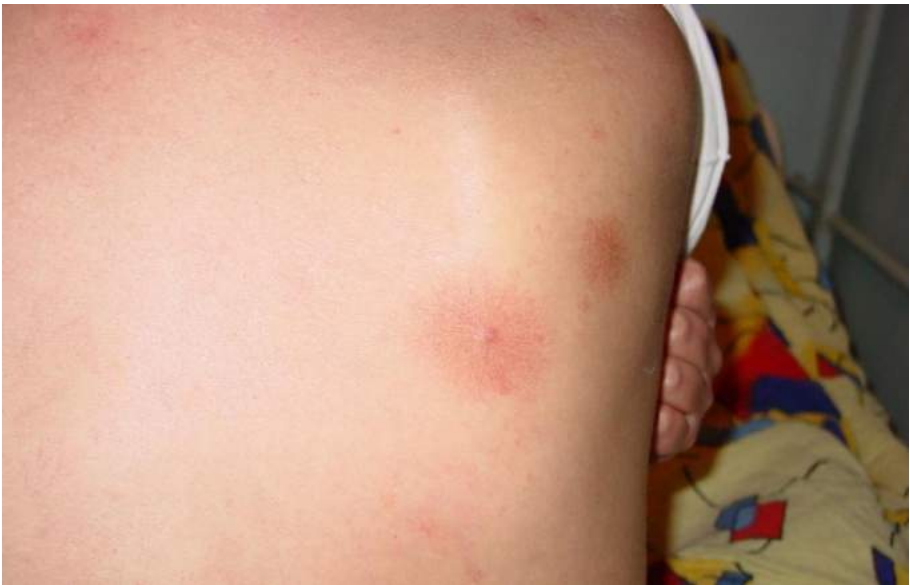- **Vascular spiders/spider angiomas (spider nevi)** are represented by a more dilated central vessel, from which fine branches start, located in the face and chest. The branches empty on vitropressure.

They occur in chronic hepatopathies (through hyperestrogenism or sometimes during the acute evolution of hepatopathy, as a vascular star explosion) and in pregnancy.





**Figure 52. Spider nevi in a cirrhotic patient**



**Figure 53. Spider angiomas – detail**

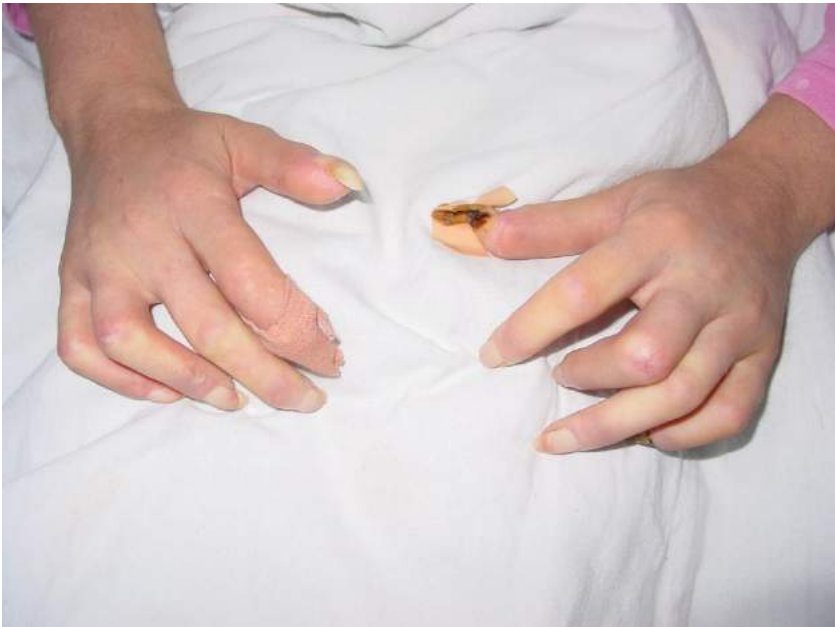### 1.3.12. TROPHIC DISORDERS

They are changes in skin, skin appendages and subjacent tissues due to quantitative or qualitative changes in constitutional elements, as a consequence of the disturbance of local trophicity.

- **Trophic disorders of the skin**

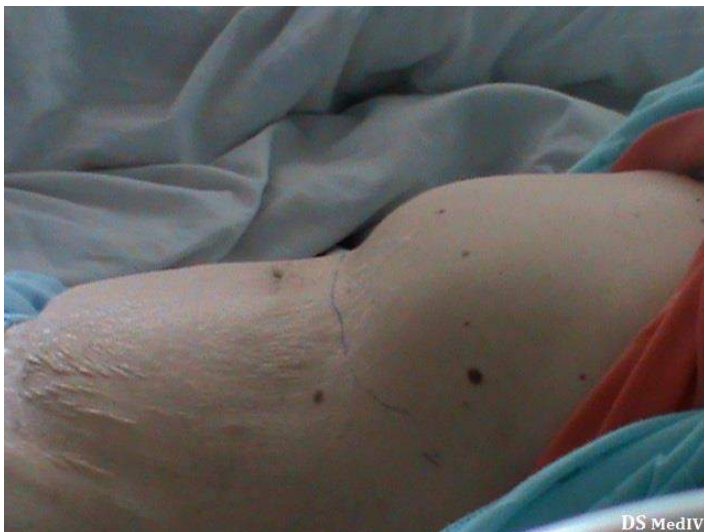⇒ **Atrophy:** skin is thin, smooth, transparent; hair follicles, sebaceous and sudoriparous glands are absent. It occurs in:

- prolonged subnutrition states, iron-deficiency anemia
- scleroderma: thin, dry skin, adherent to subjacent planes.
- diabetes mellitus: atrophy areas with a yellow-waxy core and erythematous halo
- in chronic obliterating arteriopathy of the lower limbs the skin is pale, atrophic, hairless.

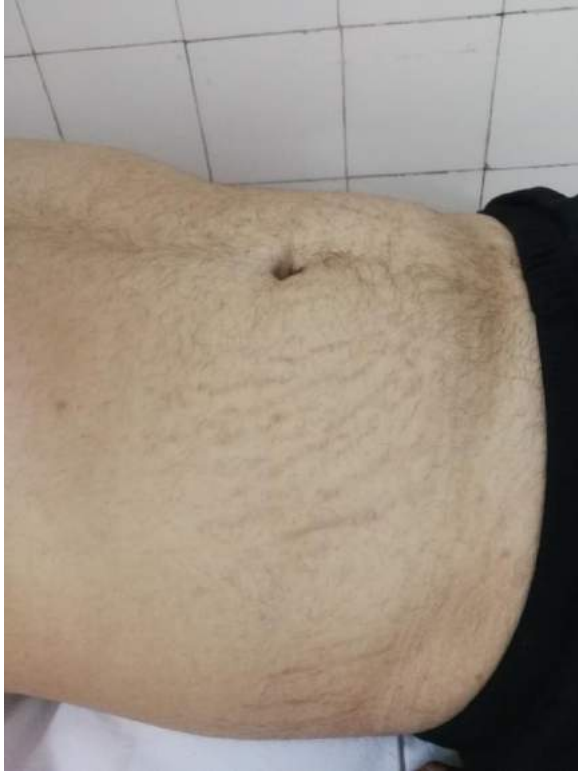

**Figure 54. Atrophy of the skin and sclerodactilia in a patient with systemic sclerosis**

- ⇒ **Striae atrophicans, stretch marks:** atrophy bands in which skin is thinned, wrinkled. A depression is palpated. It is due to the rupture of the elastic fibers of the dermis, either by traction or local protein loss.
- ⇒ **White stretch marks:** they develop on the thighs, buttocks at puberty, or on the abdomen, breasts during pregnancy. They also occur when one of the mentioned regions rapidly increases in volume (ascites, edema, rapidly developed obesity).
- ⇒ **Red stretch marks:** they are due to an excess of endogenous glucocorticoids (Cushing disease) or exogenous glucocorticoids (prolonged corticotherapy).
- ⇒ **Fissure (rhagade):** a linear lesion that reaches the dermis, surrounded by an inflammatory border. It appears in the area of skin folds or commissures (palpebral, labial). It is secondary to infectious processes (rhagade in streptococcal infections) or dystrophic processes (hypovitaminosis B).

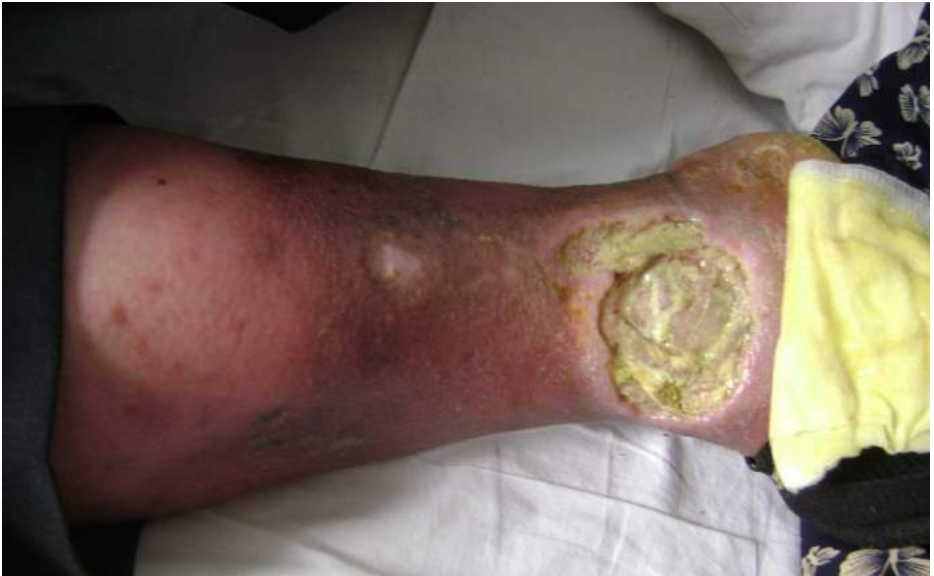

**Figure 55. White stretch marks in a cirrhotic patient with ascites (after treatment)**



**Figure 56. Red stretch marks in a young adult with Cushing syndrome**

- ⇒ **Erosion:** superficial substance lack that only affects the epidermis.
- ⇒ **Ulceration:** deep substance lack that also affects the dermis due to the deficient blood supply of a limited skin area. Arteriolar or venous cause.

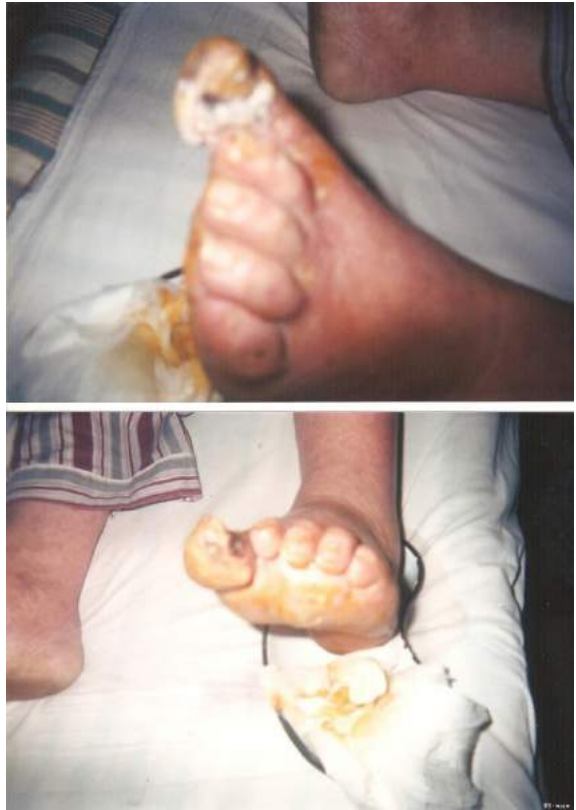

**Figure 57. Venous ulcer of the medial tibial malleolus**

- ⇒ **Perforating ulcer of the foot** (*malum perforans pedis*) is located in the sole, in the distal part of the 1<sup>st</sup> and 5<sup>th</sup> metatarsal bones or calcaneus, due to neurotrophic disorders that occur in tabes, syringomyelia, diabetes mellitus with polyneuropathy.
- ⇒ **Gangrene:** a process of mortification (*necrobiosis*) of the skin and deep tissues caused by ischemia
- dry gangrene (*mummification*): it can lead to spontaneous amputation
  - wet gangrene: it develops under the conditions of bacterial superinfection or concomitant venous stasis
  - gas gangrene: a tissue infection caused by *Clostridium* bacteria, producing crepitations on palpation (like a snowball)

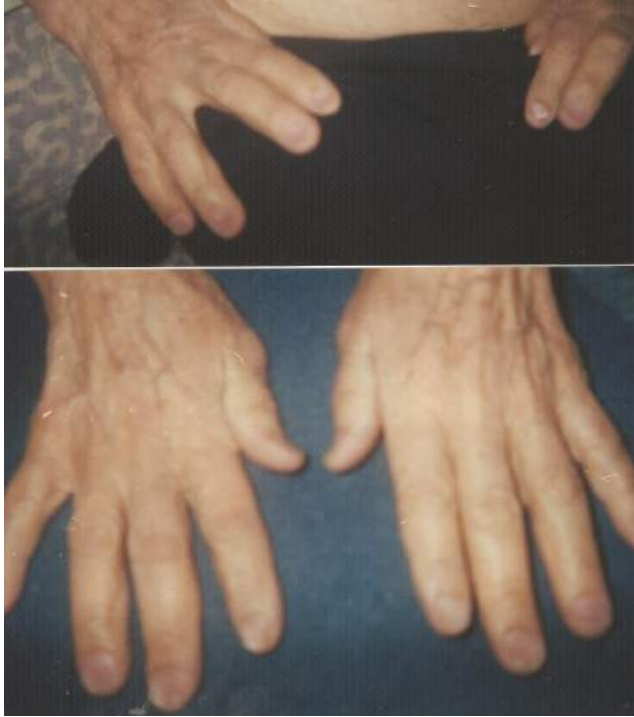**Figure 58. Gangrene of the feet in a patient with severe ischemic disease of the lower limbs**

⇒ **Eschar:** it is decubitus gangrene

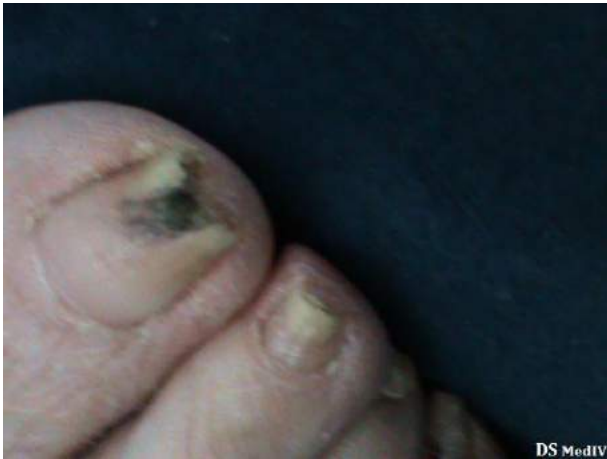

- **Trophic disorders of the nails**

- ⇒ **Koilonychia:** thin, fragile nails, concavely curved as a spoon. It occurs in iron deficiency anemia.
- ⇒ **Neuronychia:** altered nails, detached from the nail bed, cracked due to subungual bed inflammation, trauma or mycosis. Neuronychia leads to nail loss.
- ⇒ **Anonychia:** the congenital absence of nails
- ⇒ **Onychoaplasia:** atrophy of nails during the course of life
- ⇒ **Onychogryphosis:** increase in the normal convexity of the nail



**Figure 59. Koilonychia**

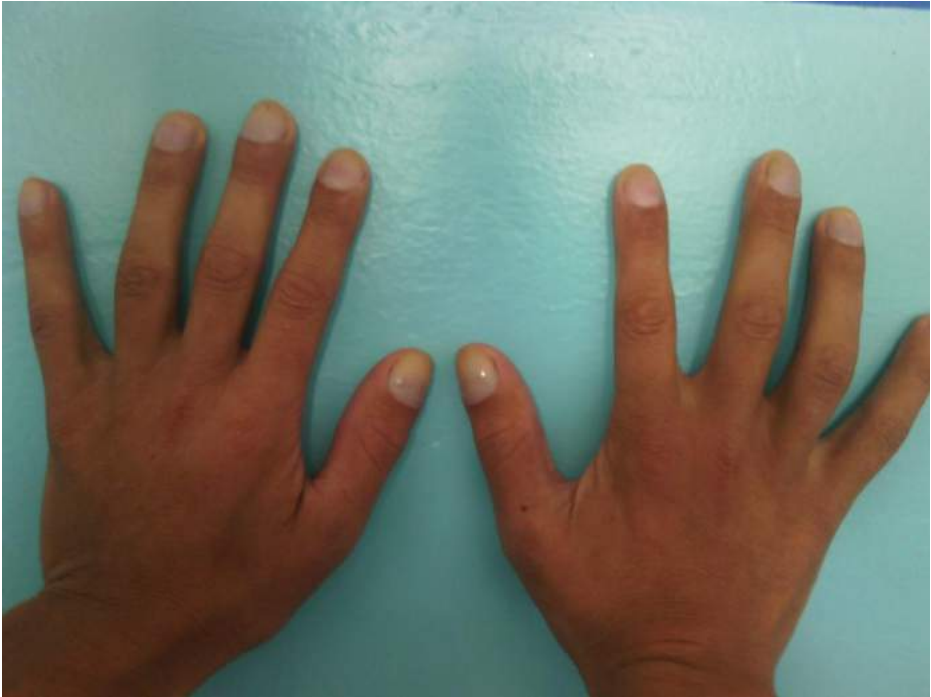

**Figure 60. Neuronichia**



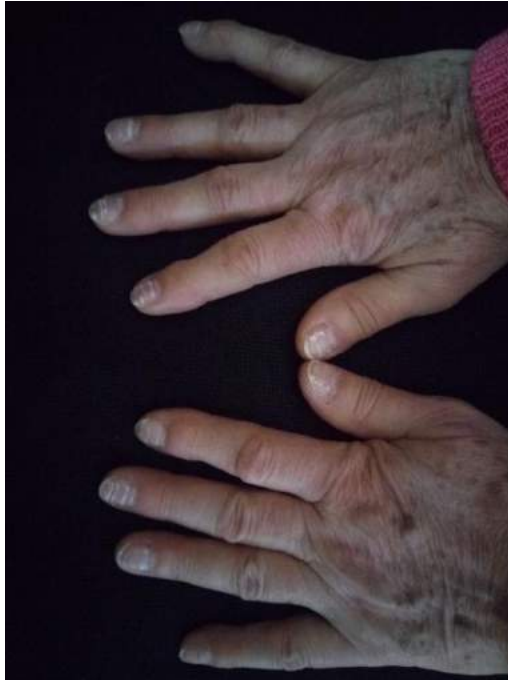- **Other disorders of the nails:**

⇒ white nails (leukonychia) in liver cirrhosis and Addison's disease



**Figure 61. Leukonychia and nail clubbing in a cirrhotic woman**

- ⇒ blue coloring of nails in argyria
- ⇒ brown coloring of nails in hemochromatosis, lead poisoning
- ⇒ abnormal development of the nail bed in acromegaly, myxedema
- ⇒ transverse grooves (Beau-Reil) in severe infectious contagious diseases, severe digestive disorders
- ⇒ friable nails in: infections, poisoning, avitaminoses
- ⇒ Muehrcke's nails: pale, transverse bands in hypoalbuminemia



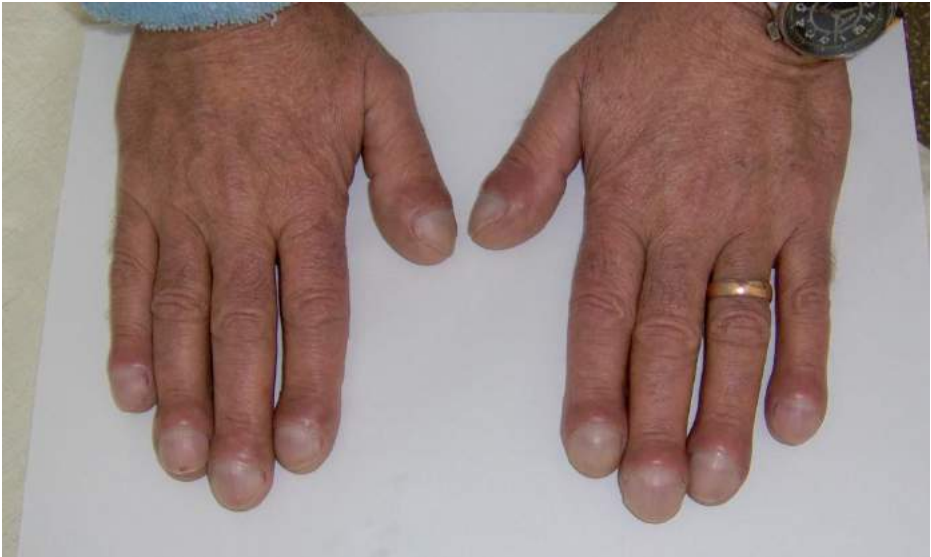**Figure 62. Muehrcke's nails**

- **Digital Hippocratism (nail clubbing):** it consists of the hypertrophy of the last phalanges of the fingers, which affects the entire thickness of the soft parts, the finger having a drumstick or club appearance. The nails concomitantly become convexly curved and in advanced stages they take a parrot's beak appearance (longitudinal curving) or a watch glass appearance (longitudinal and transverse curving)

**Causes of nail clubbing:**

- ⇒ unilateral nail clubbing: subclavian artery aneurysm, apical pulmonary neoplasm, Pancoast-Tobias syndrome
- ⇒ digital Hippocratism in the lower limbs: patent ductus arteriosus
- ⇒ symmetrical bilateral digital Hippocratism:

- **respiratory system diseases:** chronic suppurative bronchitis, bronchiectasis, lung abscess, interstitial pulmonary fibrosis, pulmonary TB, sarcoidosis, pulmonary empyema, bronchopulmonary neoplasm
- **cardiovascular system diseases:** congenital cyanogenic heart disease (tetralogy, pentalogy of Fallot), subacute bacterial endocarditis, congestive heart failure, pulmonary artery stenosis, ventricular septal defect (VSD), atrial septal defect (ASD)
- **digestive system diseases:** intestinal polyposis, Crohn disease, ulcero-hemorrhagic rectocolitis, primary biliary cirrhosis, liver cirrhosis, intestinal neoplasm
- **hematopoietic system diseases:** primary and secondary polyglobulia
- **hypertrophic pulmonary osteoarthropathy** (Pierre-Marie Bamberger syndrome): it consists of the hypertrophy of phalangeal soft tissues and bone due to periostitis ossificans with distal arthropathy and neurovascular disorders. The disease can be hereditary or acquired.



**Figure 63. Nail clubbing in a patient with lung cancer**

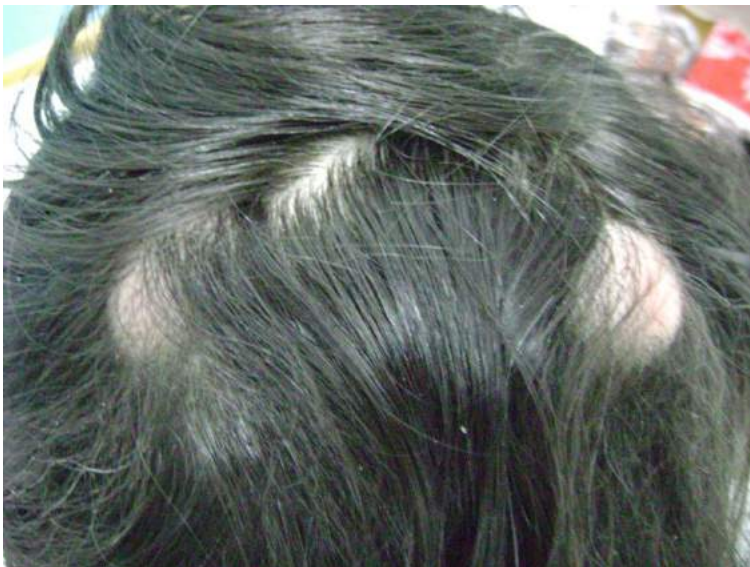- **Trophic disorders of the hair**

- ⇒ **Qualitative:**

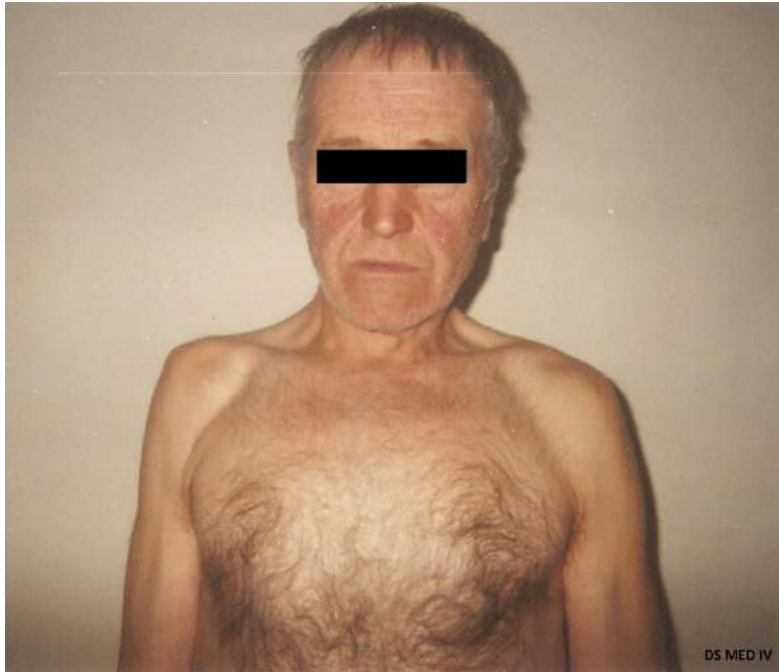
- in hyperthyroidism: thin, shiny, soft hair that loses its pigment (canities or graying of the hair)
- in hypothyroidism: thick, dull, coarse, dry, friable hair
- in iron deficiency anemia: thin, dull, friable hair that falls out easily
- hair hyperpigmentation is found in Addison's disease, congenital porphyria
- hair hypopigmentation or depigmentation occurs in kwashiorkor, albinism
- canities is progressive hair depigmentation. It can be physiological, with aging, or pathological, when it occurs early

⇒ **Quantitative and distributional:**

- hypotrichosis: hair thinning. It occurs in hypothyroidism, Addison's disease, hypoparathyroidism, gonad insufficiency. It affects more or less all the body areas
- baldness: loss of hair over a limited area
- alopecia: loss of hair due to the destruction of the hair root. It can be frontoparietal or central. Causes: genetic, excessive seborrheic secretion, mental or neurovegetative imbalance, infectious diseases (exanthematic typhus), systemic diseases (systemic lupus erythematosus), after radiation therapy, cytostatics
- hypertrichosis: excessive hair development with the maintenance of normal distribution
- hirsutism: excessive hair that also develops in areas where it should not normally appear. It can be idiopathic (after menopause) or secondary (Cushing syndrome, androgen or anabolizing steroid treatment)



**Figure 64. Alopecia areata**



**Figure 65. Hipertrichosis and hirsutism, barrel chest**

### **1.3.13. EDEMA**

Edema (also spelled edema) is an excessive accumulation of fluid in the interstitial space. It can be generalized when it involves the interstitium of the entire body or localized when it affects only a part of the body. Edema is not a disease, but a sign that reflects fluid accumulation.

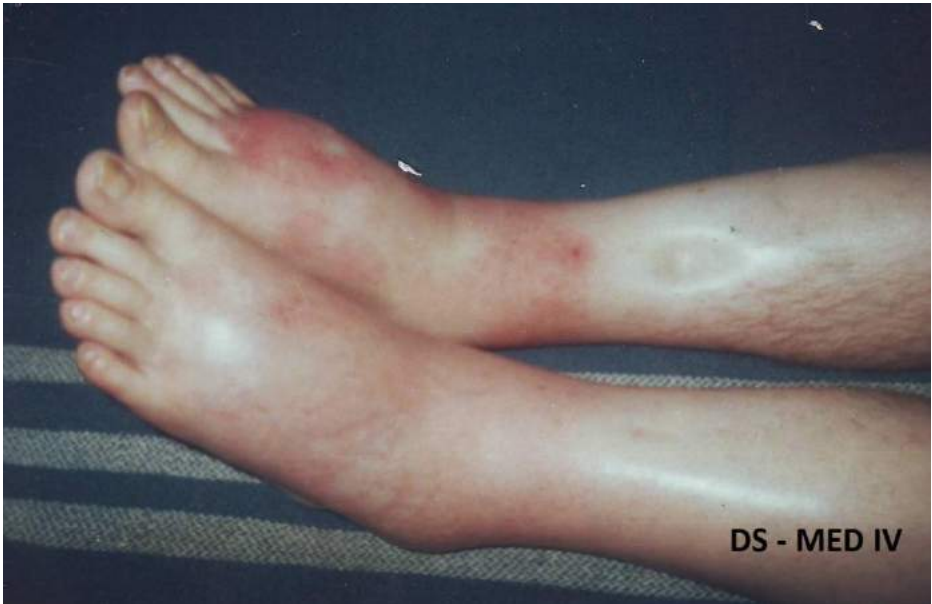#### **Mechanisms of edema formation:**

- **Generalized edema** is caused by:
  - ⇒ increased hydrostatic pressure in the capillaries (congestive heart failure)
  - ⇒ water and sodium retention (renal disorders, congestive heart failure, pregnancy, administration of estrogens, corticoids)

- ⇒ expansion of the intravascular volume by the too rapid administration of fluids that the kidney cannot eliminate
- ⇒ decreased osmotic pressure through hypoproteinemia and particularly hypoalbuminemia (nephrotic syndrome, hepatic disorders, loss of proteins by digestive route)
- ⇒ capillary membrane permeability disturbances (immunological causes, idiopathic edema)
- ⇒ antidiuretic hormone hypersecretion, increased tissue hydrophilia (endocrine edema)
- **Localized edema** is determined by:
  - ⇒ increased hydrostatic pressure in the capillaries (thrombophlebitis, chronic venous insufficiency, external venous compression)
  - ⇒ involvement of lymphatic circulation (lymphangitis, external lymphatic vessel compression – the interstitial fluid that cannot be drained by lymphatic route enters the capillaries and causes an increase in hydrostatic pressure)
  - ⇒ capillary membrane permeability disturbances (infections, burns, trauma)

On inspection, skin is stretched, shiny, skin folds disappear.

On the pressure of the edematous area with the thumb in a hard plane (bone), a transient depression is formed – the **pitting sign**. In the case of a long duration edema, due to hypoxia there is fibroblast proliferation in the interstitium, so that the pitting sign is negative or the formed depression disappears very rapidly. In chronic edema, hypoxia is also responsible for the appearance of trophic skin disorders – ulcerations, fissures etc.



**Figure 66. Edema with a positive pitting sign**

- **The evolution of generalized edema** occurs in three stages:
  - ⇒ the initial stage consists of a weight gain (4-7 kg)
  - ⇒ the stage of clinically manifest edema
  - ⇒ the stage of generalized edema with the involvement of the serosas (hydrothorax, hydropericardium, ascites) called anasarca

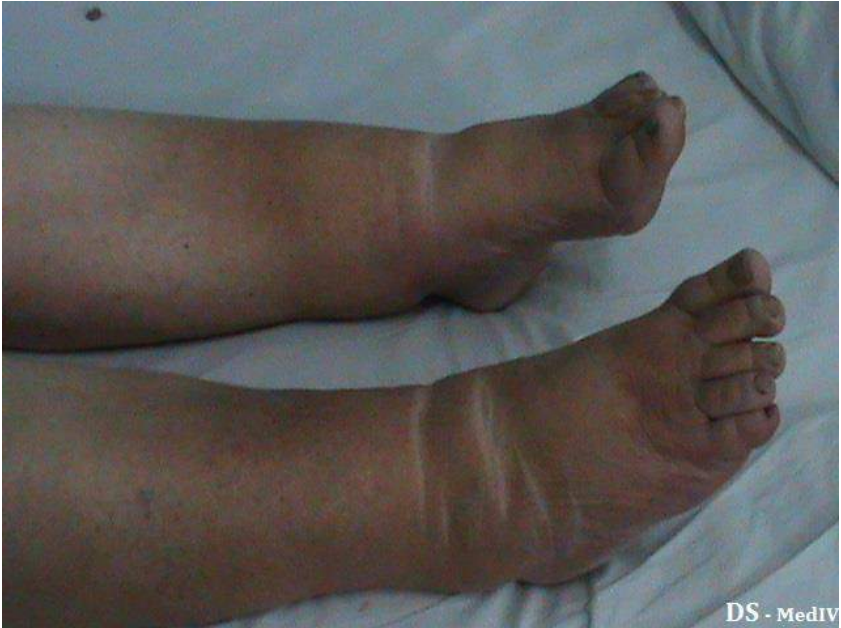- **Cardiac edema**

Cardiac edema has the following **characteristics**:

- ⇒ it occurs in congestive heart failure and right ventricular failure
- ⇒ it initially affects the lower part of the body (lower limbs, with perimalleolar onset, or the sacral region in patients immobilized in bed)
- ⇒ it appears in the evening and disappears by morning in the initial stage, subsequently it becomes permanent
- ⇒ it is symmetrical
- ⇒ initially it is white, then cyanotic because of stasis



⇒ initially it is soft, subsequently it becomes resistant to pressure



**Figure 67. Permanent cardiac edema**

The main mechanism is water and sodium retention caused by aldosterone hypersecretion. Other mechanisms are: venous hypertension, capillary membrane permeability disturbances (due to hypoxia), increased tissue hydrophilia, hypoproteinemia, lymphatic circulation disorders and ADH hypersecretion.

- **Renal edema**

Renal edema has the following **features**:

- ⇒ it affects from the beginning the areas rich in loose connective tissue (eyelids, scrotum)
- ⇒ it is more marked in the morning, when the patient wakes up, and disappears in the evening in the initial stage of the disease
- ⇒ it is white, soft, fluffy, painless

⇒ **Nephritic edema:** it occurs in acute glomerulonephritis, chronic glomerulonephritis etc.

The mechanisms involved are: increased capillary membrane permeability and increased water and sodium retention (as a result of aldosterone hypersecretion, caused by increased renin release, which is caused in its turn by the decrease of sodium concentration in the macula densa and the reduction of effective kidney blood supply – the renin-angiotensin-aldosterone system)

⇒ **Nephrotic edema:** it occurs in nephrotic syndrome (proteinuria > 3.5 g/24 hours). It is caused in the first place by a decrease in oncotic pressure (due to albumin loss in particular)

- **Hepatic edema**

Hepatic edema **is characterized** by:

⇒ its appearance in liver cirrhosis in particular, but also other hepatic disorders (acute, chronic hepatitis etc.)

⇒ it is soft, white, pasty, of lower intensity, it worsens with the progression of the disease, and is predominant in the lower half of the body. It is associated with ascites and right hydrothorax

**The pathophysiological mechanisms** involved are:

⇒ hyperaldosteronism – the main cause, due to the hypersecretion induced by the decrease of the effective circulating volume (because of ascites and the retention of a large blood amount in the portal territory) and to the incapacity of the liver to metabolize this hormone (which is also true for ADH, estrogen)

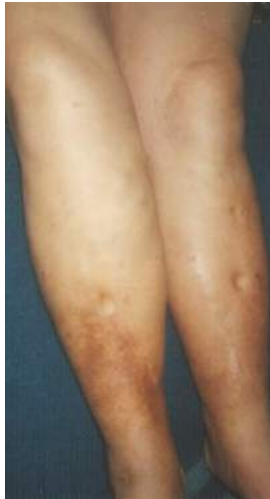⇒ hypoproteinemia (decreased liver capacity to synthesize proteins)

⇒ capillary membrane permeability disturbances and others

- **Venous edema**

Venous edema is localized and occurs in thrombophlebitis, venous trunk obstruction, lower limb varices, postthrombotic syndrome, etc.

- ⇒ in **deep thrombophlebitis**, edema is painful, hot, cyanotic due to venous stasis or white in the case of the association of lymphangitis and the compression of skin capillaries (phlegmatia alba dolens). If edema is not very expressed in deep calf thrombophlebitis, it can be evidenced by the measurement of the circumference of the affected calf compared to the healthy calf. Because of edema, the circumference of the affected calf will be larger. Edema in deep thrombophlebitis is due to inflammation and venous stasis.
- ⇒ in **superficial thrombophlebitis**, the affected venous cord is evidenced, which is painful, cyanotic or bright red, edema being less expressed
- ⇒ in **superior vena cava obstruction** (pulmonary neoplasm, compressive hilar adenopathies), “mantle” edema and cyanosis are found (the face, neck, upper limbs and upper half of the chest are affected). Cavo-caval circulation is also present.

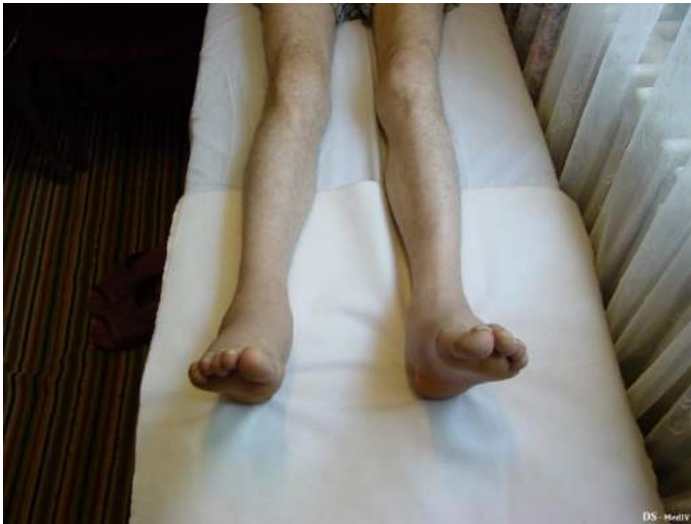

**Figure 68. Edema in postthrombotic syndrome**

- ⇒ in **the postthrombotic syndromes of the lower limbs**, because of the destruction of the swallow nest shaped valves that ensure the segmentation and antigravitational flow of the blood, edema occurs due to stasis. It is cyanotic, more marked in orthostatism, particularly prolonged orthostatism, and it improves but does not disappear at rest. It is hard, persists for a long time and is frequently accompanied by trophic skin disorders (ulcerations, fissures).
- ⇒ in **lower limb varices**, edema is unilateral, perimalleolar. It is initially white, then it becomes purple and is more marked in orthostatism.

- **Protein deficiency edema**

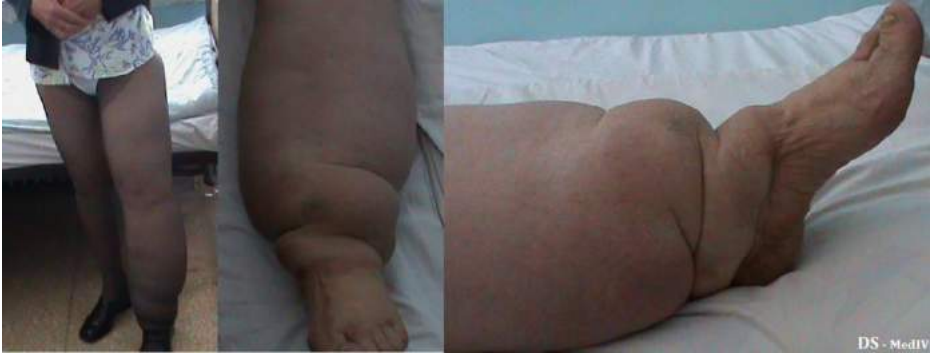It develops because of a dietary protein deficiency (hunger edema) or when there is exaggerated protein catabolism (cachectic edema). The mechanism consists of a decrease in oncotic pressure. It is white, soft, painless, with onset in the calves and face and a tendency to generalization.



**Figure 69. Cachectic edema**

- **Lymphatic edema**

It occurs because of lymphatic circulation disorders (lymphangitis or lymphatic vessel obstruction through compression – tumors, adhesions, radiation, tuberculosis, lymph nodes etc.). It is white, hard and painless. In the case of lymphangitis, inflammation signs can be associated.



**Figure 70. Congenital lymphatic edema (elephantiasis)**

- **Endocrine edema**

It is generalized edema that can develop in myxedema, hyperthyroidism, Cushing disease, in conditions that evolve with hyperfolliculinism, hyperestrogenism etc.

⇒ in myxedema, the skin is infiltrated with hyaluronic acid. Edema is white, painless and leaves no fingerprint mark. It induces a full-moon facies appearance.

⇒ in hyperthyroidism, edema due to hypoproteinemia secondary to exaggerated protein catabolism may develop

- **Allergic edema**

It is white, soft, transient and can be accompanied by pruritus or other allergic manifestations. Allergic facial edema is called **Quincke edema**.

The mechanism consists of a sudden increase in capillary permeability.

- **Inflammatory edema**

It develops as a result of increased capillary permeability, but other mechanisms also occur. It is accompanied by the other signs of inflammation (*rubor, calor, dolor* and *functio laesa*).

### 1.3.14. THE NUTRITIONAL STATUS

It defines the current relationship between (caloric and qualitative) dietary intake and energy expenditure, which builds mass (weight) and develops the body, but is different depending on age and sex.

**A normal state of nutrition** means a balance between food intake and energy consumption on the one hand, and anthropometric indices corresponding to the statistical population mean.

Adipose tissue represents 16-20% (complex evaluation is required for accuracy) and muscle mass approximately 50% of total body weight. In practice, the estimation of subcutaneous cellular tissue as part of the general objective examination involves the monitoring of volume, distribution, the comparison of body mass to height.

This method overlooks perivisceral fat and possible water retention (edema).

Subcutaneous adipose tissue volume: it is assessed by general somatic inspection, by pinching the subcutaneous fold thickness in election areas (the arm triceps area).

#### **Calculation of ideal weight**

⇒ weight and height can be measured using different formulas

⇒ Broca index: ideal person (kg body weight) = height in centimeters minus 100 ( $G = \hat{I} - 100$ ).

⇒ Lorenz formula brings a correction factor:  $G = \hat{I} - 100 ((I - 150)/a)$ , where:  $a = 4$  for men and  $2$  for women.

- **Overweight and obesity**

Overweight on account of adipose tissue is called **obesity**.

An excess of body weight:

⇒ higher than 20% compared to the ideal weight according to Broca is called obesity.

⇒ of 10-20% compared to the ideal weight is called overweight.

The body mass index:  $BMI = G \text{ (kg)} / I \text{ (m)}^2$ . BMI values  $\geq 25$  define overweight and more than 30 define obesity.

On the **inspection** of obese patients, the following are detected:

⇒ abundant subcutaneous cellular tissue, with the disappearance of bone prominences.

⇒ round face, short neck, double chin etc.

⇒ in more severe forms, there are frequent caricatural, monstrous aspects, adipose tissue folds hanging in various regions.

According to the **distribution of adipose mass**, the following are differentiated:

⇒ android obesity: it involves the neck, nape, back, predominantly the upper half of the body.

⇒ gynoid obesity: it develops in the abdomen, breasts, buttocks, thighs, predominantly in the lower half of the body.

⇒ mixed obesity



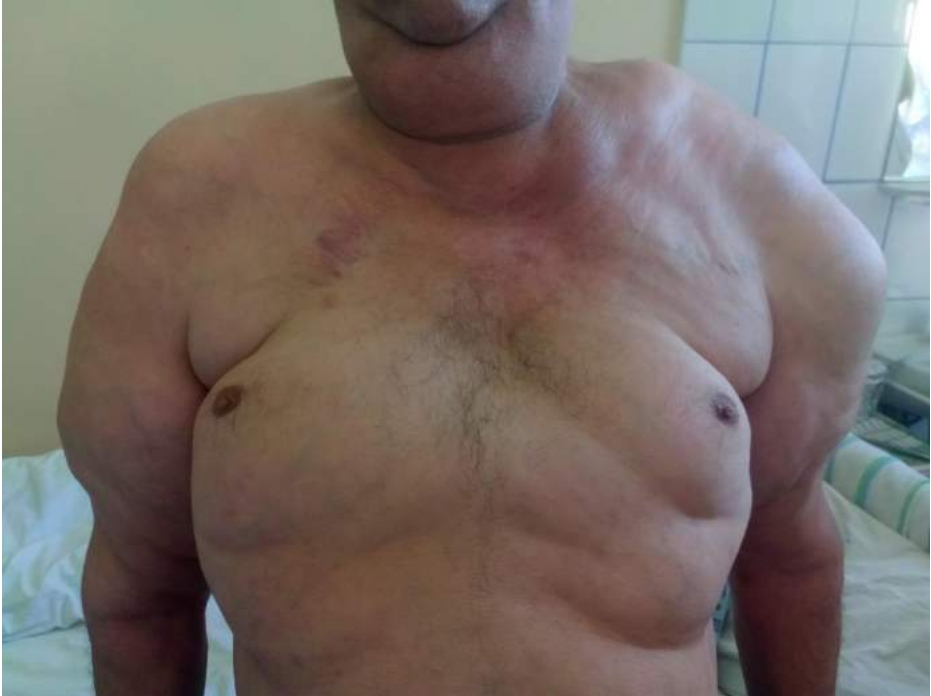**Figure 71. Morbidly obese woman**

### **Android obesity:**

⇒ it is more frequent in men

⇒ it also occurs in women with Cushing disease (hypercorticism), the adipose tissue involving the nape (buffalo hump)

⇒ it has an increased risk for metabolic complications: type 2 Diabetes Mellitus, atherosclerosis (ischemic heart disease, cerebrovascular accidents), arterial hypertension, hyperinsulinemia (metabolic syndrome), gout, biliary lithiasis



**Figure 72. Particular disposition of android obesity in a patient with Madelung's disease**

### **Gynoid obesity**

- ⇒ it is predominant in women
- ⇒ it can develop in hypogonadal men (eunuchs, eunuchoids, adiposogenital dystrophy or Babinski-Frohlich syndrome)
- ⇒ it causes mechanical complications: arthrosis (of weight bearing joints), varices, thrombophlebitis, flat feet etc.

### **Causes of obesity:**

- ⇒ mainly excess caloric intake



⇒ favoring factors: hereditary, endocrine, metabolic

**Primary obesity:** it depends on hyperorexia (exaggerated appetite), a genetically determined psychosomatic disease (alteration of the function of appetite-regulating centers).

**Obesity secondary** to other diseases (morbid obesity):

⇒ endocrine: hypothyroidism (myxedema), hyperinsulinemia, hypercorticism

⇒ diencephalic: compressive pituitary tumors, craniocerebral trauma, encephalitis

A particular type of obesity is described – *Pickwick syndrome*, with the following characteristics:

⇒ it occurs in boys or young men with marked trunk obesity, with respiratory and cardiocirculatory disorders

⇒ it is associated with hypoventilation (hypercapnia and hypoxemia), obstructive sleep apnea, diurnal somnolence, dyspnea, cyanosis, cardiac rhythm disorders and heart failure, muscle cramps

The mechanism consists of a dysfunction of respiratory muscles accompanied by an alteration of the function of respiratory centers.

### • **Subnutrition**

Subnutrition consists of a weight loss. The following are described:

⇒ weight loss: up to 15% of the ideal weight

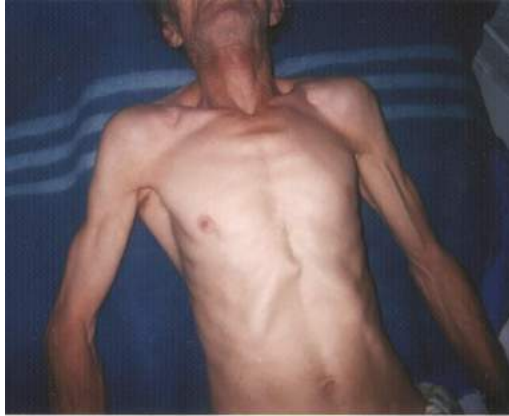⇒ emaciation: weight loss between 15-30% of the ideal weight

⇒ cachexia: weight loss of more than 30% of the ideal weight (according to Broca)

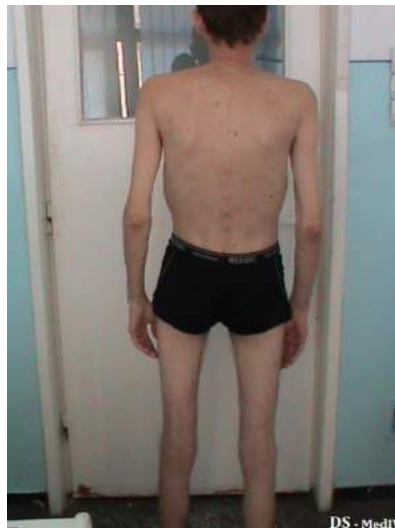**Emaciation:** subcutaneous cellular tissue is diminished or absent, prominent cheekbones with sunken cheeks, visible intercostal spaces and supraclavicular fossae, retracted abdomen, thin limbs, atrophic skin, easily wrinkling skin.

**Cachexia:** there is no adipose tissue and there is severe muscle hypotrophy of Bichat's fat pad. Sometimes cachectic or protein deficiency edema is associated, which can mask weight loss.

It should be mentioned that weight loss must not be confused with primary muscle atrophy (a disease per se).



**Figure 73. Emaciated patient with gastric ulcer**



**Figure 74. Cachectic patient with chronic pancreatitis**

### Causes of weight loss:

- ⇒ low dietary intake (unusual eating habits, eating fashions, excessive fasting, religious beliefs, calamities, hunger, refugee camps)
- ⇒ digestive diseases (with maldigestion and/or malabsorption):
  - esophageal, pyloric, intestinal stenosis (vomiting)
  - exocrine pancreatic insufficiency (losses by chronic diarrhea)
  - small intestine diseases (chronic diarrhea)
- ⇒ endocrine diseases: Basedow's disease (hypercatabolism), Addison's disease, primary hyperparathyroidism, pituitary insufficiency (Simmonds disease), Sheehan syndrome
- ⇒ consumptive diseases: chronic infections (TB, AIDS), advanced cancer (through anorexia, vomiting, diarrhea)
- ⇒ losses of plastic substances: nephrotic syndrome (massive albuminuria), intestinal protein exudation, extensive burns
- ⇒ mental diseases: schizoid, manic-depressive states, mental anorexia (particularly in women who severely reduce dietary intake)
- ⇒ anorexia caused by chronic alcoholism, cerebral atherosclerosis.

### 1.3.15. THE ADENOPATHIES

Lymph nodes are lymphoid structures located along lymphatic vessels. They are superficial (accessible by objective examination) and deep (inducing indirect clinical manifestations through the compression of adjacent organs and accessible only by paraclinical explorations).

**Clinical features:** 0.5-1 cm in size, elongated ovoid shape, elastic, mobility in superficial and deep planes, painless.

The alteration of any of these features is pathological, defining lymph node syndromes or **adenopathies** (adenomegalies).

Lymph nodes cannot normally be palpated, except in very lean persons, but the normal palpatory features are those mentioned above.

The examination of lymph nodes is only accessible for superficial lymph nodes and is performed by two methods: inspection (less important) and palpation (the main examination method). Clinical examination is performed systematically, from up to down, starting with the cephalic extremity up to inguinal lymph nodes, using specific palpation methods for each lymph node group. Adenopathies raise difficult etiological diagnosis problems; sometimes the precise diagnosis cannot be made even by anatomopathological examination.

From the very beginning, the diagnosis of **adenopathy** should establish whether this is:

- ⇒ localized – including a single lymph node group, consequently drawing attention to a local pathological process (usually infectious or tumoral)
- ⇒ multiple or generalized – drawing attention to a general cause of lymph node involvement

### **Classification of adenopathies:**

- ⇒ infectious adenopathies
- ⇒ adenopathies through malignant lymphoreticular proliferation
- ⇒ metastatic adenopathies
- ⇒ non-specific inflammatory adenopathies in collagen diseases
- ⇒ allergic adenopathies
- ⇒ adenopathies in thesaurismosis
- **Infectious adenopathies:** bacterial, viral, mycotic; localized or generalized; acute or chronic.
  - ⇒ **Localized (regional) infectious adenopathies:**
    - **Non-specific adenopathies** (staphylococcus, streptococcus): they have a cutaneous and mucous entrance gate (panaritium, abscess, erysipelas, acute tonsillitis, dental infections). They are usually accompanied by neighborhood

adenopathy with the following features: lymph nodes are moderately enlarged (they do not have the time to reach very large sizes), soft, even fluctuant, with periadenitis, consequently with the loss of mobility in superficial and deep planes, painful, sometimes accompanied by lymphatic vessel inflammation (lymphangitis), in the form of a painful, hot, red cord between the entrance gate and the affected lymph node station.

- **Specific adenopathies**

**Syphilitic adenopathy:** it has an inguinal location, most frequently unilateral, it is polyganglionic, non-inflammatory (painless, with maintained mobility in the superficial and deep plane).

**Tuberculous adenopathy:** preferentially located in the cephalic extremity (laterocervical, submandibular). Lymph nodes have variable sizes (up to the order of centimeters), increased consistency, slightly painful, non-adherent to each other and to superficial and deep planes. They can evolve towards lymph node sclerosis or caseification (more frequently), when they become soft, painful, tending to adhere to each other and to superficial and deep planes, with external fistulization. Healing is slow, with retractile scars.

**Inguinal adenopathy** that accompanies soft chancre (Ducrey's bacillus): it has inflammatory characteristics – painful, adherent and evolving towards fistulization.

**Cat claw disease:** it is localized adenopathy, depending on the site of the scratch, of viral etiology, with the following characteristics: moderate size, elastic or slightly increased consistency, slightly sensitive, adherent to the surrounding planes. Evolution can be in 50% of the cases towards fistulization. It can be accompanied by general signs: subfebrility, asthenia.

**Benign lymphogranulomatosis** (Nicolas-Favre disease): venereal disease caused by *Chlamydia trachomatis*, with a small genital ulceration as the entrance gate, which is usually not noticed and whose major manifestation is adenopathy, usually inguinal, multiple, inflammatory, which evolves towards multiple fistulization and heals with retractile inguinal scars.

⇒ **Generalized infectious adenopathies:**

- *Infectious mononucleosis*: an acute infectious disease of viral etiology, common in adolescents (“kissing disease”). It predominantly affects cervical lymph nodes that are moderately enlarged, painful, non-adherent, of increased consistency, non-fistulizing. It is accompanied by high fever, splenomegaly, angina and monocytosis.
- *HIV infection*: it causes symmetrical generalized adenopathy, of moderately increased size, painless, non-adherent and persistent. In fact, the presence of adenopathy in at least two lymph node groups, which persists for at least three months, without any other apparent cause, makes obligatory the performance of HIV testing.
- *Rubeola*: associated polyadenopathy with retroauricular, occipital onset, of moderate sizes, painful, non-adherent, which precedes by several days the skin rash.

• **Adenopathies through lymphatic tissue proliferation**

⇒ **Malignant lymphoma (Hodgkin’s disease)**: adenopathy usually starts in the laterocervical area, it is unilateral, asymmetrical, subsequently extending to other superficial and deep lymph node groups. The number and location of the affected lymph node stations allow the staging of the disease.

**Characteristics of adenopathy:** variable, sometimes large sizes, becoming obvious on inspection, when it can alter the neck appearance

(proconsular neck); variable consistency, from normal to firm; they are conglomerated into lymph node packages, being compared to “nuts in a bag”; they are not adherent to superficial and deep planes; they are painless, but can become painful with alcohol ingestion.

⇒ **Malignant non-Hodgkin lymphoma:** although the onset of the disease is usually deep, superficial adenopathy can also occur, which is hard on palpation, adherent, painless, large in size.

The differential diagnosis between the two types of lymphomas is clinically suggested but can only be made by lymph node biopsy.

⇒ **Chronic lymphocytic leukemia:** its main manifestation is symmetrical generalized adenopathy, of moderately increased size (less than 5 cm), firm, elastic, painless, non-adherent to superficial and deep planes, without forming lymph node blocks.

- **Metastatic adenopathies:** these are regional adenopathies, secondary to the dissemination of cancer, usually at an advanced stage.

**The characteristics of metastatic adenopathy are:**

⇒ variable, generally moderately increased size

⇒ hard, wood-like consistency

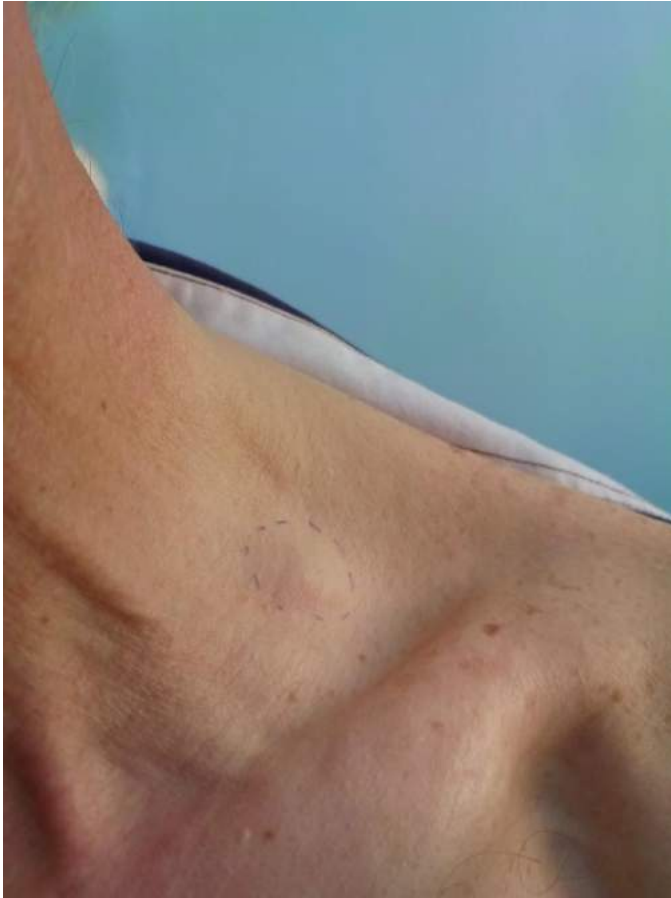⇒ lymph nodes that are usually painful spontaneously and on palpation

⇒ adherent to each other – they form hard lymph node blocks, adherent to superficial and deep planes

⇒ on biopsy, they have the histological structure of the tissue of origin

- **Virchow-Troisier adenopathy:** it was classically described as related to gastric cancer, but it can have other locations (prostate, ovarian cancer). It signifies the presence of a hard small lymph node group, located in the left supraclavicular

area, close to the sternocleidomastoid insertion, non-adherent to adjacent planes.



**Figure 75. Virchow-Troisier lymphadenopathy**

- **Strauss adenopathy:** it was also described in relation to gastric cancer. It is evidenced by rectal touch, it is located on the anterior side of the rectum, with all the characteristics of malignant adenopathy
- **Laterocervical adenopathy:** in tonsillar, laryngeal, pharyngeal cancer



- **Axillary adenopathy:** in breast cancer
- **Supraclavicular adenopathy:** in bronchial cancer
- **Inguinal adenopathy:** in prostate, ovarian, left colon cancer
- **Non-specific inflammatory adenopathies in collagen and granulomatous diseases**
  - ⇒ **Rheumatoid polyarthritis**, disseminated lupus erythematosus: painless, firm, non-adherent micropolyadenopathy occurs. Adenopathy is not in the foreground of the clinical picture of this disease but suggests active disease forms.
  - ⇒ **Sarcoidosis:** it evolves with deep and superficial generalized adenopathy with moderately increased, painless, non-adherent lymph nodes of firm consistency.
- **Adenopathies in allergic diseases**
  - ⇒ Serum disease (determined by circulating immune complexes): painless, mobile generalized micropolyadenopathy, with fugacious evolution
  - ⇒ Allergic reactions to various drugs: adenopathy has similar characteristics to serum disease

- **Adenopathies in thesaurismosis**

Theaurismosis is a rare familial disease, caused by alterations in the degradation of cerebrosides, phospholipids and cholesterol, with the deposition of these substances in lymph node, splenic, hepatic, renal, medullary macrophages.

Adenopathy is one of the manifestations of the disease, it is medium in size, elastic, painless, non-adherent.

### 1.3.16. THE MUSCULAR SYSTEM

It may evidence alterations in volume, contractility, tone.

- **Changes in volume**
  - Generalized muscular hypertrophy

- physiological: in people doing intense physical labour and sportsmen
- pathological

**In acromegaly:** due to excess somatotrope hormone hyperplasia and hypertrophy of the muscle cells occurs

Hypersecretion of androgen hormones (Cushing's disease) determines generalized muscular hypertrophy in men and virilization in women, who present well defined muscular masses

- Localized muscular hypertrophy:
  - physiological: excessive physical exercising of one or several muscle groups (weight lifters)
  - pathological: associated with debilitating diseases requiring wheelchair pushing or walking stick support
- Generalized muscular hypotrophy (*amyotrophy*): found in the context of cachexia or in persons not moving due to inactivity
- Localized muscular hypotrophy
  - by lack of exercise, motor nerves, or low trophic control by the nervous system
  - in **polymyositis** hypotrophy affects the muscle groups from the limb roots
  - in **rheumatoid polyarthritis** the changes are distal: hypotrophy and even atrophy of the inter-bone hand muscles
- **Modifications of muscular contractility:**
  - muscle contractility may be abolished (e.g. paralysis), or impaired (paresis, myopathy)
  - **Myasthenia** represents the decrease of muscular contractility after beginning of the voluntary movement with progressive aggravation. Occurs in myasthenia gravis, botulism
  - **Myotonia:** represents the delayed muscle relaxation after prolonged contractile activity. In case of myotonia direct

percussion determines a contraction of the respective muscle, which recovers slowly

- **Modifications of the muscular tone:**

**Muscular tone represents the involuntary contraction at rest;** the muscular tone may be assessed by palpation

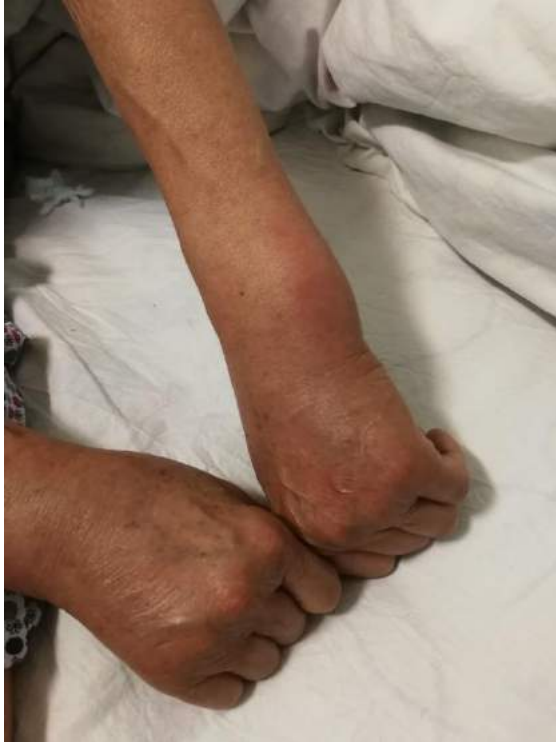- **Generalized muscular hypotonia** is found with injuries of the extrapyramidal system or in syncope
- **Localized muscular hypotonia** is caused by the injury of the peripheral motor neuron, giving the aspect of flaccid paralysis
- **Generalized muscular hypertonia** occurs in tetanus, tetania, ventricular hemorrhage, Parkinson's disease
- **Localized muscular hypertonia** may be evidenced in torticollis, vertebral disk injuries or injuries of the central motor neuron, which give the aspect of spastic paralysis

### 1.3.17. THE OSTEOARTICULAR SYSTEM

- **Fractures** are recognized based on the following:
  - bone crepitation when moved
  - abnormal mobility
  - no transmission of movements or vibrations
- **Deformities** are caused by:
  - abnormal development of the bones in prenatal life or after birth
  - tumoral proliferation, endocrine or metabolic disturbances
    - in **acromegaly** the patient presents a monstrous development of the bones of the face and limbs
    - in **Paget's disease** cranial bone changes occur, kyphosis, curving of the lower limbs

At the level of the joints the objective examination checks: periarticular tissues, sensitivity, volume, mobility, deformities.

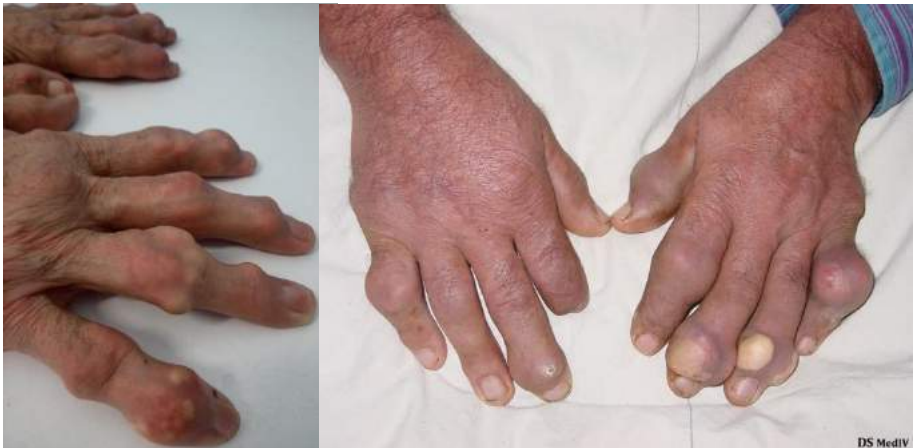- **Periarticular** area: skin and subcutaneous tissues may present the following changes:
  - redness in case of arthritis (acute articular rheumatism, gout)



**Figure 76. Acute reactive arthritis with redness of the forearm and hand**

- echymosis after local trauma
- hyperpigmentation after healing of the acute inflammatory process
- lipomatosis in hypercholesterolemia and hyperlipidemia
- periarticular nodules:

- **Meynet's nodules** in acute rheumatism are round, mobile, painless, symmetrically located near the joints, mainly around the large joints
- **Rheumatoid nodules** in rheumatoid polyarthritis are small, insensitive, scattered and adhering to the periostium
- **Gout tophi** are deposits of uric acid crystals round the joints. They are round, unique or multiple, color of the skin or reddish, with pale areas where the crystals are, hard, insensitive. Sometimes they ulcerate and eliminate a white crystalline substance



**Figure 77. Gross gout tophi of the hands**

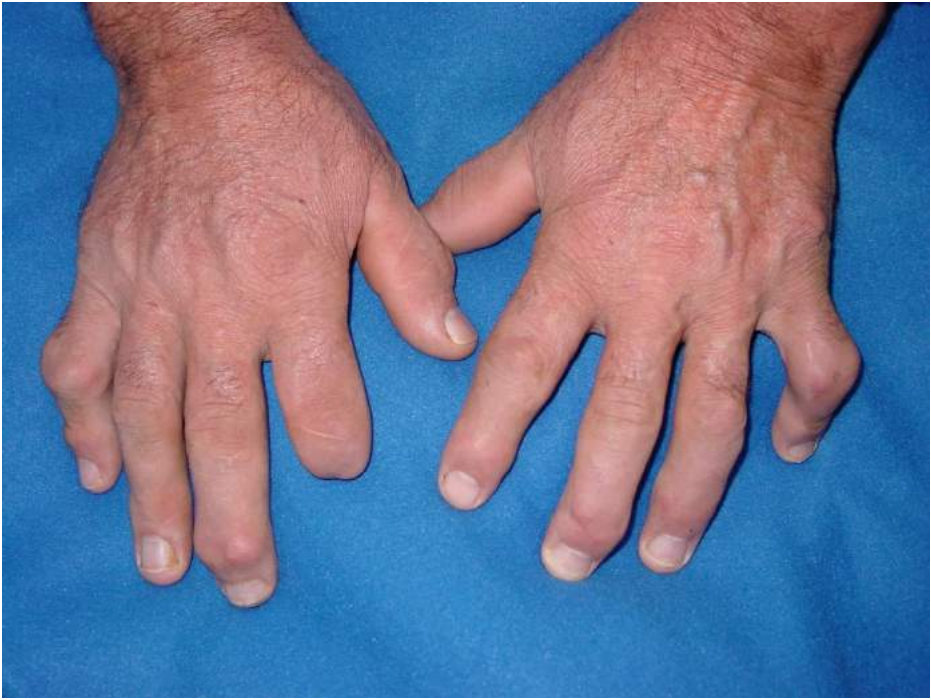- **Articular sensitivity** may be evidenced by direct palpation or pressure on the areas of ligament and tendon insertion, as well as by actively moving the joint. Joints are painful in arthritis, arthosis, acute rheumatic fever.

- Increase of the joint volume is called **articular tumefaction** and is produced by capsule-synovial hypertrophy or fluid accumulation
  - a typical aspect of articular tumefaction is found in rheumatoid arthritis: increased volume of the proximal joints of the fingers, giving an aspect of spindle fingers, as well as tumefaction of the radius-carpal and metacarpo-phalangeal joints, giving the aspect of camel humps or the shape of the letter “M”.

The accumulation of fluid in a joint cavity is called **hydrarthrosis**. It is evidenced by the **wave sign**. In the knee joint the fluid accumulation may also be evidenced by the **knee-cap shock**. Hydrarthrosis occurs in acute arthritis, recurrent arthrosis, local trauma or repeated mechanical stress on the joint.

- **Articular deformities**

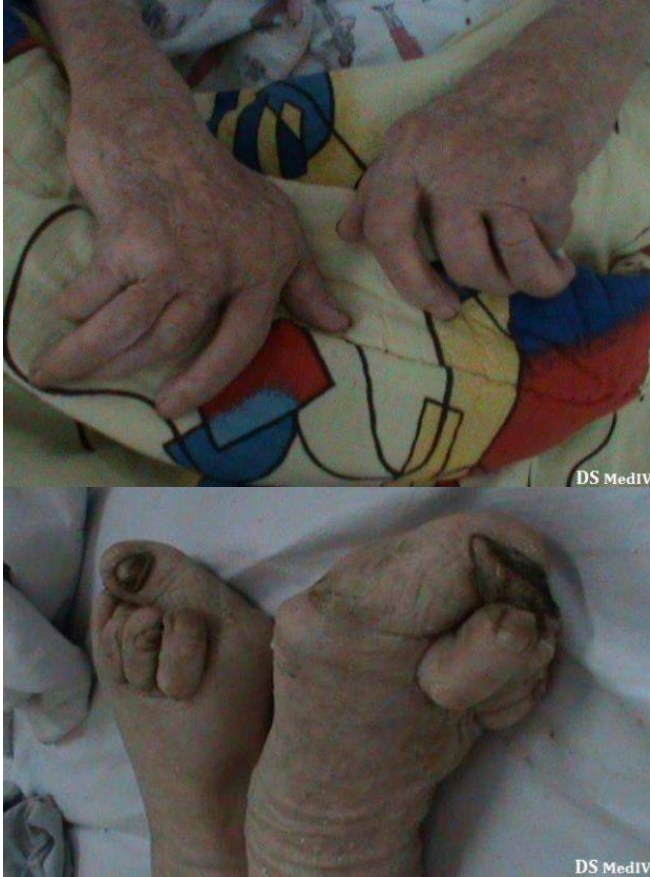- **Osteophytes** are marginal bone projections or spurs which cause joint deformity, along with muscular contractions and apo-neurotic tractions. Examples:
  - **Heberden’s nodules** (distal inter-phalangeal joints)
  - **Bouchard’s nodules** (proximal inter-phalangeal joints) occurring in finger arthrosis.



**Figure 78. Heberden and Bouchard nodes**

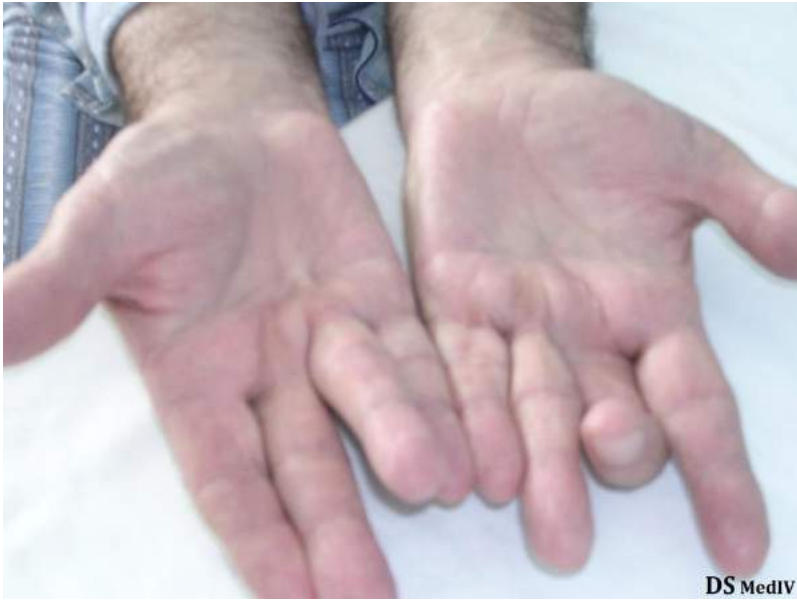In advanced stages, deformities lead to **axis deviation and vicious positions** of certain body segments:

- in rheumatoid arthritis: cubital finger deviation
- in knee arthrosis: aspect of *genu valgum* or *genu varum*
- in Dupuytren's disease (retraction of the palmar aponeurosis), fingers 4-5 are fixed in flexed position
- in lumbar disc herniation the patient presents a deformity called "bayonet back"



**Figure 78. Severe hand and feet deformities in rheumatoid arthritis**





**Figure 80. Dupuytren contracture**

**Articular mobility** is assessed by active or passive movements

**Decreased mobility** may be due to articular or extra-articular causes

- extra-articular causes: shortening of the capsule-ligament, muscle, tendon, induration, skin thickening (scleroderma)
- articular causes: hydratrosis, osteophytosis, intraarticular foreign bodies (cartilage, meniscus fragments)

When the mobility of the joint is abolished we refer to **ankylosis**, which occurs when the bone ends are fused by fibrous tissue (pseudo-ankylosis) or by bony tissue (true ankylosis).

**Increased mobility** in the joints is encountered in hereditary connective tissue diseases causing hyperlaxity (e.g. Marfan's syndrome). The patient may perform movements that exceed the anatomical frame, often presenting bone ends sliding. The appearance of **articular crepitation** during the movement betrays irregular bone surfaces and is found mainly in arthrosis.

The objective examination of the osteo-articular system is based on **clinical measurements**:

- articular tumefaction, hypertrophy, hypotrophy may be evidenced by symmetrical measurements, comparing lengths with the measuring tape
- **Schober's test** assessed the lengthening of the lumbar spine during bending forward. From L5, the reference point, 10 cm are marked above. When bending the distance between the two points normally becomes 15 cm.
- **the fingers-to-floor test** also measures the mobility of the spine

These tests are modified in ankylosing spondylitis.

### 1.3.18. CHANGES OF BODY TEMPERATURE

- Thermometer technique
  - temperature is measured with the mercury thermometer
  - in the armpit (arm against the body, dry skin) – peripheral temperature is measured for 5-10 min
  - in the mouth, rectum, vagina central temperature is measured for 5 min
  - thermometry is performed twice a day (6-7 a.m., 5-6 p.m.) or every 2 hours, recording the values on the case sheet (thermal curve)
  - normal values: 36-37° C in the armpit, 37.5° C in the rectum
  - pathological values > 1 degree between peripheral and central values occur in abdominal inflammatory processes (rectal temperature increases) or in shock/collapse (axillary temperature decreases)

#### - **Fever**

Defines the temperature increase over normal (37° C) accompanied by local or general changes: chills, headache, fatigue, peripheral

sweating, tachypnea, anorexia (vegetative and metabolic manifestations).

- **Classification:**

- sub-fever condition 37-38° C
- moderate fever 38-39° C
- high fever 39-40° C
- hyper-pyrexia > 41° C

Fever occurs by the action of exogenous (bacteria, viruses, foreign proteins) or endogenous substances (tissue necrosis, neoplasia) on the polymorphonuclear cells, with their phagocytosis and secretion of pyretogenic substances which act on the hypothalamus and produce fever.

- **Causes of fever**

- infections, inflammations
- neoplasm
- malignant blood diseases
- nervous system, psychiatric diseases
- endocrine, allergic conditions
- tissue necrosis
- drugs

- **Semiological aspects of fever**

- **Onset** may be:
- **abrupt:** chills – in acute infectious diseases (flu, erysipella, scarlet fever, angina, malaria)
- **slow:** more frequent in TB typhoid fever, neoplasms, endocarditis
- **Duration:**
- **short:** (several days) – usually infectious causes
- **prolonged** (over 2-3 weeks) – prolonged fever syndrome
- **Evolution of fever:**
- increase (onset) – *stadium incrementi*

- plateau = acme, fastigium
- end – *stadium decrementi*: sudden (in crisis) or gradual

The **fever bout** is associated with sweat, polyuria, normalization of breathing and heart beat (e.g. in pneumonia)

**Lysis** occurs in: typhoid fever, septicemia and may be preceded by large temperature oscillations (amphibole)

- The **degree of fever** has diagnostic value:
  - **sub-fever** occurs in small infections, localized, “focused” (teeth, sinuses, gallbladder, annexes), TB (evening fever and night sweats), anemia, hyperthyroidia, bacterial endocarditis, neoplasm, and in the elderly (due to low reactivity)
  - **high fever** occurs in infectious diseases, Hodgkin’s, acute leukemia, suppuration (abscess, pyelitis etc.)
- **Aspect of the thermal curve:**
  - **continuous fever:** over 1 C difference between morning and evening, occurs in typhoid fever already set on, pneumonia, other infectious diseases
  - **remitting fever** > 1 C in TB, septicemia, typhoid fever (occasionally)
  - **intermittent fever:** normal in the morning and very high in the evening (preceded by chills)
  - **reversed fever:** high in the morning and normal or low in the evening: in deep suppurations (lungs, urinary), septicemia, advanced cavitary TB
  - **periodical fever:** intermittent fever occurring at one, 2, or 3 days interval. Typical for malaria
  - **recurrent fever:** lasting for several days followed by days without fever – Hodgkin’s disease (Pel-Ebstein fever), leptospirosis, pulmonary TB etc.
  - **waving fever:** fever for a few days alternating with low fever days: brucellosis, Hodgkin’s

- **irregular fever:** none of the above

The diagnosis of the fever cause involves all the semiological aspects described, organ manifestations (pulmonary, cardiac, urinary, digestive, serous etc.)

**Hypothermia** means body temperature below 36 C

- **Causes**

- infectious diseases in convalescence (transient hypothermia) (e.g. after thermal crisis in the pneumonia of the elderly, a depression occurs manifested by low blood pressure, tachycardia, weak pulse, cold sweats, pale, cyanotic skin)
- collapse: in any type of shock: hemorrhagic, acute myocardial infarction, coma, peritonitis
- cold, starvation, cachexia
- myxedema
- severe hepatocellular insufficiency
- drug poisoning: morphine quinine, fever-lowering drugs

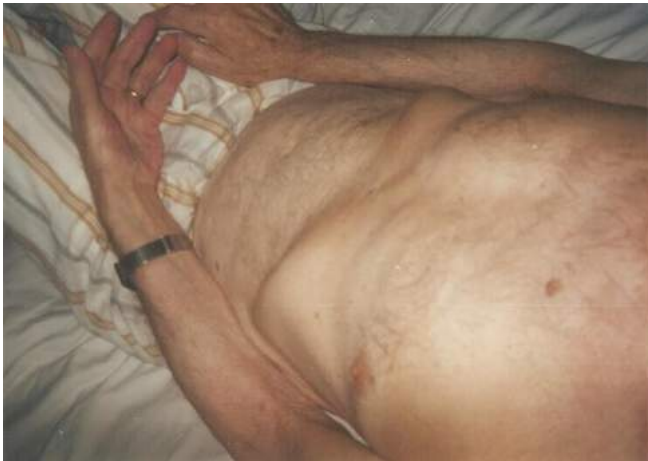

# CHAPTER 2. THE RESPIRATORY SYSTEM

## 2.1. ANAMNESIS

- **Age:** Some disorders occur with an increased incidence in relation to age
  - ⇒ **newborn:** respiratory distress, prematurity apnea, aspiration
  - ⇒ **infant:** airway infections, bronchopneumonia
  - ⇒ **early childhood:** more frequently, acute respiratory infections (rhinopharyngitis, bronchitis, pneumonia), cystic fibrosis
  - ⇒ **puberty:** more frequently, tuberculosis (TB) primoinfection
  - ⇒ **adult age:** respiratory disorders, chronic bronchitis, asthma, bronchiectasis
  - ⇒ **elderly:** bronchopneumonia (with insidious onset, severe evolution), tuberculosis (chronic evolution), bronchopulmonary neoplasm (that can occur at any age)
- **Gender:** determines the frequency of some diseases:
  - ⇒ men: chronic bronchitis, emphysema, bronchiectasis, neoplasm
  - ⇒ women: asthma, embolisms, tuberculosis
- **Family history:** cystic fibrosis and alpha-1-antitrypsin deficiency have recessive inheritance; there is an inherited predisposition for bronchial asthma, and a family history of asthma, eczema and hayfever is common (take care with “asthma” in parents or grand parents who were smokers because it may have been misdiagnosed COPD!). Diseases such as COPD, lung cancer and tuberculosis often “run” in families, more often as an increased likelihood of children smoking when parents smoke, than as subtle genetic susceptibilities. Tuberculosis may reactivate later in life after past family exposure.

- **Physiological personal history:** pregnancy/puerperium predispose to tuberculosis with pleurisy
- **Personal history of diseases:** relatively frequent, previous diseases are the cause of the current disease:
  - ⇒ chronic rhinitis, naso-pharyngeal polyps, nasal septum deviation predispose to chronic bronchitis, bronchiectasis
  - ⇒ eruptive infectious diseases, viroses (anergizing) can determine pulmonary tuberculosis, severe pneumonia (gram-negative staphylococci), bronchopneumonia
  - ⇒ convulsive cough, repeated acute bronchitis favor bronchiectasis, diabetes mellitus, tuberculosis by decreasing resistance to infection
  - ⇒ cardiac involvement (e.g. mitral stenosis) through pulmonary stasis, pulmonary hypertension and repeated infections cause the “cardiac lung”
  - ⇒ chronic bronchitis in a smoker suggests the presence of a lung neoplasm, and pneumonia that is sometimes repeated in the same territory suggests peribronchiectasis congestion
  - ⇒ rickets results in chest cage deformities (see Figure 81)



**Figure 81. Ribcage deformity due to rickets (*sulcus Harrison*)**



- ⇒ corticotherapy may reactivate tuberculosis, prolonged antibiotherapy favors the appearance of mycosis, and chest traumas suggest the presence of fractures or hematomas
- **Living and working conditions:** they can be determinant or risk factors of the current disease:
    - ⇒ physical, intellectual overexertion, unsanitary dwellings, chronic alcoholism lead to decreased body resistance
    - ⇒ **smoking** is an etiological factor of chronic bronchitis, bronchopulmonary neoplasm, COPD
    - ⇒ **profession:** occupational history must be detailed and thorough including all occupations, full and part time, held since the patient left school and the number of years spent in each job, length of any exposure, knowledge of recognised hazardous exposures, relationship between symptoms development in other workers, and the time in the job. Some occupational diseases are worse at the beginning of the working week(bissinosis, humidifier fever) while occupational asthma is characteristically worse at the end of the working week, with symptoms usually improving during holidays.
      - workers in glass factories (“glass blowers”), woodwind instrument players are predisposed to pulmonary emphysema
      - workers exposed to humidity, cold, bad weather, intense physical exertion develop acute infections, rhinitis, bronchopneumonia
      - workers in chemical industry, cement, ferrous and non-ferrous ores, flour milling are predisposed through the alteration of secretion/cilia to acute and chronic infections
      - prolonged exposure to mineral powders induces pneumoconiosis (silicosis, asbestosis, kaolinosis)

- exposure to organic substances favors occupational bronchial asthma, rhinitis, allergic alveolitis
- exposure to pets because of their association with asthma(dogs, cats, rodents, horses), allergic alveolitis(birds) and psittacosis pneumonia(parrots and parakeets)
- **The history of the current disease** includes the onset, symptoms, evolution of the disease.
  - ⇒ *the onset* of respiratory disorders can be acute, insidious, chronic, inapparent, depending on the type, severity, reactivity of the organism, the association with other diseases.
  - ⇒ *complaints*: general symptoms: fever, shivering, asthenia, perspiration, weight loss, or local symptoms: chest cramp, dyspnea, coughing, hemoptysis.

### 2.1.1. CHEST PAIN

Chest pain can originate from the pleura, the chest wall, and mediastinal structures; the lungs are not a source of pain because of their exclusive autonomic innervation. A careful history of chest pain should include: site, radiation, mode of onset, duration, severity, and aggravating/relieving factors including the effects of breathing and movement.

#### Chest pain - causes

##### A. *Non-central*

##### *Pleural:*

- *infection*: pneumonia, bronchiectasis, tuberculosis
- *malignancy*: lung cancer, mesotelioma, metastatic
- *pneumothorax*
- *pulmonary infarction*
- *connective tissue disease*: rheumatoid arthritis, systemic lupus

## **Chest wall:**

- *malignancy*: lung cancer, mesothelioma, bony metastases
- *persistent cough/shortness of breath*
- *muscle sprain/tears*
- *Bornholm's disease (Coxsackie B infection)*
- *Tietze's syndrome (costochondritis)*
- *Rib fracture*
- *Intercostal nerve compression*
- *Thoracic shingles (herpes zoster)*

## **B. Central**

- **Tracheal**: infection, irritant dusts
  - **Cardiac**: massive pulmonary thromboembolism, acute myocardial infarction/ischemia
  - **Oesophageal**: oesophagitis, rupture
  - **Great vessels**: aortic dissection
  - **Mediastinal**: lung cancer, thymoma, lymphadenopathy, metastases, mediastinitis
- **Chest pain of respiratory origin**: in pleuropulmonary, tracheobronchial disorders
    - ⇒ **Stabbing chest pain**
      - it occurs through the irritation of parietal pleura; irritation of the parietal pleura of the upper six ribs is perceived as a localized pain, whereas irritation of the parietal pleura overlying the central diaphragm innervated by the phrenic nerve is referred to the neck or shoulder tip; the lower six intercostal nerves innervate the parietal pleura of the lower ribs and the outer diaphragm, and hence pain from these sites may be referred to the upper abdomen
      - it is of high intensity, with dyspnea
      - stitch-like pain

- amplified by coughing, sneezing, palpation of the region
- **causes:** pneumonia, embolism, pneumothorax, pleurisy  
*in lobar pneumonia:* violent stabbing pain; below the nipple, after shivering, fever, it resolves in 2-3 days  
*in pulmonary thromboembolism:* sudden, intense, with dry cough, marked dyspnea, with polypnea, cyanosis, followed by hemoptoic sputum, fever  
*in spontaneous pneumothorax:* violent, below the nipple/subscapular, after intense physical exercise, with the patient's immobilization, marked dyspnea, proportional to the pneumothorax size  
*serofibrinous pleurisy:* in the dry phase (pleuritis): diffuse pain, with contralateral decubitus and superficial breathing, dry cough; it decreases with the appearance of fluid
- interlobar pleurisy: "painful sling"
- mediastinal pleurisy: retrosternal, with sensitive phrenic points in the anterior costal region
- diaphragmatic pleurisy: in the lower hemithoracic 1/3; radiation to the shoulder
- purulent pleurisy: violent, persistent, superficial stabbing pain increased by minimum pressure (with cutaneous hyperesthesia)  
*gangrenous pulmonary suppurations:* intense, persistent pain precedes the opening into the bronchus, then it is rapidly relieved  
*tuberculosis, apical cancer (Pancoast-Tobias):* stabbing pain in the apex of the lung

⇒ **Tracheobronchial pain:** originating from tracheobronchial tree, with a raw burning character, restrosteral pain (in the middle 1/3), greatly worsened by coughing, and produced by tracheal mucosal inflation due to infection or inhalation of irritant dusts

- **Chest pain in chest wall disorders:** is caused by skin disorders, neuralgia, myalgia, bone pain; not uncommonly patients with chronic cough or breathlessness (e.g. COPD or asthma) develop a generalized feeling of chest tightness or diffuse pain, although they rarely mention it, if not asked
  - ⇒ *skin disorders*: burning pain (herpes zoster)
  - ⇒ *cellulitis*: erythema, edema accompanied by intense pain on palpation
  - ⇒ *pleurodynia*: intense, violent pain, increased by breathing, movements, coughing, palpation; stabbing pain; severe pain with chest immobilization, thigh flexion and/or muscle contracture and fever
  - ⇒ *intercostal neuralgia*: irritation of the intercostal nerve, sudden, intense stabbing pain or burning/crushing pain along the nerve, increased during inspiration, by movements, coughing, palpation of the Valleix points: parasternal, axillary, paravertebral (cutaneous branches of the intercostal nerve); intercostal neuralgia a frigore through the compression of the intercostal nerve in spinal disorders, mediastinal tumors (permanent refractory pain and dry cough), in herpes zoster (superficial burning pain, persisting after eruption, thoracic dermatomal distribution)
  - ⇒ *radicular pain*: through nerve root compression: spondylosis, discopathy, tuberculosis, spondylitis, metastases, tumors: pain in the spine, symmetrically radiating to the shoulder girdle, increased by spinal movements, dermatomal distribution; the sudden onset of localized pain after vigorous coughing or direct trauma is characteristic of rib fractures or intercostal muscle injury

- ⇒ *myalgia*: muscle pain in: ischemia, trichinellosis, dermatomyositis, excessive coughing; it is increased during respiration, palpation
- ⇒ *bone pain*: periosteal (localized), endosteal or in the bone marrow (diffuse); it has many causes: fractures, infections, metastases, tumors, multiple myeloma, sarcoma
- ⇒ *Tietze syndrome*: tumefaction of chondrocostal joints I, II; spontaneous pain/palpation and/or arthrosic nodules
- ⇒ *malignant chest wall pain* due to lung cancer, mesothelioma, or rib metastases is typically dull, aching, or gnawing in nature, unrelated to respiration, progressively worsening and eventually disrupting sleep. The pain of Pancoast's tumor of the lung apex is due to erosion of the first rib and is often referred down the medial aspect of the arm because of invasion of the lower roots of the brachial plexus
- ⇒ *mastodynia*: in breast disorders: mastitis, tumors, premenstrual tension; its persistence and skin induration in a young woman is an alarm signal for breast cancer

- **Diaphragmatic chest pain**

- ⇒ *phrenic neuralgia*: sharp pain, radiating to the left shoulder, neck, trapezius muscle
- ⇒ *intercostal neuralgia*: epigastric, upper abdominal pain, along the costal margins (pain in the shoulder girdle, in the last intercostal spaces)
- ⇒ *other causes*: pleuritis, diaphragmatic pleurisy, subphrenic abscesses, hepatic abscesses, hepatic inflammation, mediastinal/thoracic spinal tumors

- **Chest pain from other intrathoracic organs:**

- ⇒ *cardiac pain*: angina pectoris, acute myocardial infarction, pericarditis, mitral stenosis (atrial pain), massive pulmonary

thromboembolism (central chest pain resembling myocardial ischemia)

- ⇒ *aortic pain*: luetic aortitis, dissecting aneurysm: aortic dilation/chest compression
- ⇒ *digestive disorders* of the esophagus, stomach, gallbladder
- ⇒ *mediastinal disorders*: mediastinal pain is typically central, retrosternal and unrelated to respiration and cough described like retrosternal weight, oppression and coughing with associated dyspnea and dysphagia
  - spontaneous mediastinal emphysema: after exercise, breaking of an emphysema bulla; intense pain, radiating to the shoulders, lasting for hours, accompanied by subcutaneous crepitations (neck, shoulders)
  - acute mediastinitis: severe retrosternal pain, increased by deglutition, sudden movements (in esophageal ruptures)
  - chronic mediastinitis: tuberculosis
  - malignancy invading mediastinal lymph nodes or enlarging thymoma may produce a dull, aching retrosternal pain that progresses to disturb sleep

### **Important semiological features of chest pain:**

- ⇒ *site +/- radiation*: nipple (painful sling), basal (in the neck), right/left shoulder, retrosternal, interscapulo-humeral
- ⇒ *intensity +/- character*: atrocious, intense, shocking, diffuse, burning, stabbing
- ⇒ *relationship with breathing and movement, palpation of the area*: increased by breathing, immobilizing, exacerbated by compression

## **2.1.2. DYSPNEA**

Dyspnea (breathlessness) is difficult breathing; *subjectively*: sensation of difficult breathing, suffocation, breathing effort, thirst or

lack of air; *objectively*: changes in the rhythm, rate, amplitude of breathing movements. Patients may use terms such as ‘shortness of breath’, ‘difficulty getting enough air in’, feeling puffed’ or ‘tiredness’.

**Dyspnea** represents all the alterations of breathing in terms of rhythm, rate, intensity (including heavy breathing)

- Normal: 14-18 respirations/minute during rest, effortless; 500-600 ml (current respiratory volume)
- Pathological: dyspnea occurs by affecting: the lung, pleura, respiratory muscles, bulbar centers, centrifugal/centripetal nerve pathways:
  - ⇒ stimuli that increase respiratory rate: hypoxemia, hypercapnia, acidosis, muscle exercise, fever, hypermetabolism, arterial hypotension, increased pressure in the pulmonary capillary, in the vena cava, in the right atrium and right ventricle
  - ⇒ stimuli that decrease respiratory capacity: muscle disorders
  - ⇒ thoracic cage abnormalities, decreased total lung volume, increased airway resistance.

***Respiratory causes of dyspnea***

***Airways:*** laryngeal tumor, foreign body, asthma COPD, bronchiectasis, lung cancer, bronchiolitis, cystic fibrosis

***Parenchyma:*** pulmonary fibrosis, alveolitis, sarcoidosis, tuberculosis, pneumonia, diffuse infections(pneumocystis jiroveci pneumonia), tumor(metastatic, lymphangitis)

***Pulmonary circulation:*** pulmonary thromboembolism, pulmonary vasculitis, primary pulmonary hypertension

***Pleural:*** pneumothorax, effusion, diffuse pleural fibrosis

***Chest wall:*** kyphoscoliosis, ankylosing spondylitis

***Neuromuscular:*** myasthenia gravis, neuropathies, muscular dystrophies, Guillain-Barre syndrome.



## CLINICAL FORMS OF DYSPNEA:

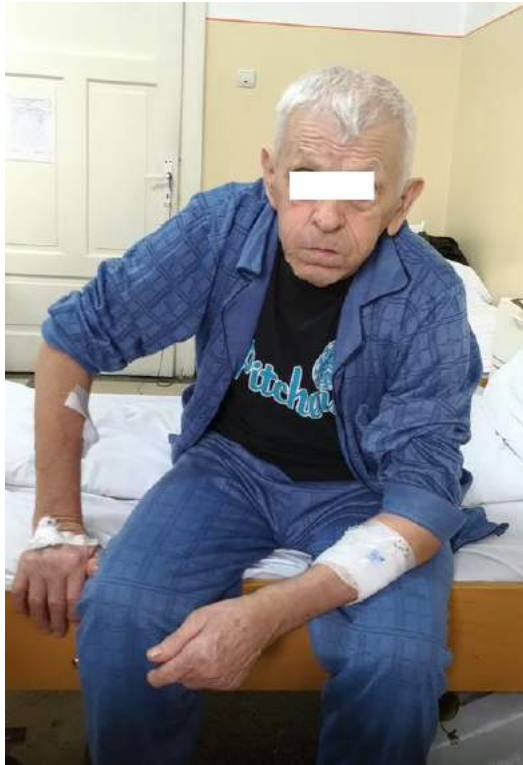- *depending on frequency*: dyspnea with polypnea, dyspnea with inspiratory or expiratory bradypnea

⇒ **polypnea**: increase in the respiratory rate to 50-60 resp./min: superficial amplitude

### Causes:

- excitement, intense exercise, nervous excitability, febrile disorders cause transient, short duration dyspnea
  - disorders accompanied by a decrease in the amplitude of breathing movements: rib fractures, intercostal neuralgia
  - disorders that diminish the respiratory surface: bronchopneumonia, pulmonary infiltration, extensive pleurisy, pneumothorax, abdominal distension, obesity
  - cardiovascular disorders: heart failure, severe anemia
- ⇒ **inspiratory bradypnea** in upper airway obstruction: foreign bodies in the larynx, trachea, diphtheric croup, vocal cord paralysis, allergic glottic edema, laryngeal stenosis, mediastinal tumors or adenopathies
- it manifests by: prolonged active, forced inspiration, inspiratory whistling sound (*cornage*) and inspiratory *stridor* (sternal, suprasternal, intercostal retraction of soft parts)
- ⇒ **expiratory bradypnea**: it occurs in the case of pulmonary airflow obstruction
- *acute*: bronchial asthma, acute bronchitis;
  - *chronic*: chronic bronchitis, pulmonary emphysema (COPD)
  - it manifests by: difficult whistling expiration (wheezing) in asthma, expiration through pursed lips (pink-puffer) in emphysema and type A COPD. Wheeze is a high-pitched whistling sound produced by air passing through narrowed small airways, typically limited to, and louder during,

expiration. Wheeze on exercise is a common symptom of asthma and COPD, and wheezing which causes night waking is a feature of asthma, while wheeze after waking in the morning suggests COPD. A common mistake is failure to distinguish wheeze from inspiratory stridor caused by the partial occlusion of a large airway by tumour or foreign body.



**Figure 82. Orthopnea and pursed-lips respiration in a patient with COPD**

- *depending on evolution:* acute (paroxysmal - in episodes) or chronic (COPD): continuous, during exercise

⇒ **Acute dyspnea:**

- it occurs in: foreign body bronchial obstruction: inspiratory dyspnea, bradypnea, suprasternal retraction, cyanosis, refractory cough, cornage
- laryngeal causes: children with laryngeal spasm, glottic edema: inspiratory dyspnea, bradypnea, suprasternal retraction, cornage
- bronchial asthma: noisy forced expiratory dyspnea, bradypnea, wheezing
- spontaneous pneumothorax, acute bronchopneumopathies, pulmonary embolism: dyspnea with cyanosis, stabbing chest pain, polypnea.

⇒ **Chronic dyspnea:**

- in chronic bronchopneumopathies: continuous dyspnea exacerbated by acute episodes or exercise
- in emphysema: expiratory bradypneic dyspnea, pink-puffer
- advanced pulmonary fibrosis: inspiratory dyspnea, with polypnea.

A careful history of breathlessness covers mode of onset, duration, progression, variation, aggravating/relieving factors, severity and associated symptoms.

- *Mode of onset, duration, progression:*

**Minutes:** *pulmonary thromboembolism, pneumothorax, acute left ventricular failure, asthma, inhaled foreign body*

**Hours to days:** *pneumonia, asthma, exacerbation of COPD*

**Weeks to months:** *anemia, pleural effusion, respiratory neuromuscular disease*

**Months to years:** *COPD, pulmonary fibrosis, pulmonary tuberculosis*

- *Aggravating/ alleviating factors, variability* could suggest etiology. Left ventricular failure and respiratory muscle weakness commonly present with breathlessness when lying flat (orthopnea). This is due to inability of the left ventricle to compensate for the normal increased venous return to the heart on lying down or to embarrassment of the diaphragm in respiratory weakness. Orthopnea can be a feature of any severe lung disease. Paroxysmal nocturnal dyspnea, a milder clinical form of left ventricular failure is typical also for asthma(when awake the patient between 3 and 5 a.m. and is accompanied by wheezing). Dyspnea that is worst first thing on waking in the morning is more typical of COPD and may settle after coughing up sputum. Asthma is suspected when breathlessness is associated with exposure to allergens(e.g. animals, shaking bedding, hoovering, mowing the lawn), irritants with smoke, perfumes, fumes, cold air or drugs(e.g. aspirin) or non-steroidal anti-inflammatory drugs or exercise(when continue to worsen for 5-10 minutes after stopping activity). Breathlessness that improves at the weekend or on holiday is suggestive of occupational asthma or extrinsic allergic alveolitis.
- *Severity* is important to be determined and the restrictions it imposes on a patients everyday activities and hobbies, especially in insidious progressive diseases, e.g. COPD and pulmonary fibrosis.
- *Associated symptoms* and time course of dyspnoea with or without various combinations of cough, sputum, haemoptysis, chest pain and wheeze narrow the list of possible diagnoses, e.g. in acute breathlessness the associated pleuritic chest pain points to pneumonia, pneumotorax, pulmonary embolism while it's absence suggests more often metabolic acidosis, shock or pulmonary edema. Wheeze and cough are associated with COPD and asthma and central chest pain with myocardial

infarction with left ventricular failure or massive pulmonary embolism/infarction, as a cause of acute dyspnea.

### 2.1.3. HEMOPTYSIS

Hemoptysis is the expectoration (coughing up) of aerated, fresh red blood from the alveoli, tracheobronchi and/or parenchyma.

- **Circumstances of occurrence:**
  - ⇒ intense persistent cough
  - ⇒ intense physical exercise, prolonged sun exposure
  - ⇒ excitement with arterial hypertension
  - ⇒ sudden change in atmospheric pressure
  - ⇒ premenstrual period
- **Prodromal phenomena:**
  - ⇒ sensation of retrosternal heat
  - ⇒ laryngeal tracheal "tickle"
  - ⇒ altered general state with anxiety, cephalgia, dizziness
  - ⇒ painful chest tension
  - ⇒ metallic or blood taste in the mouth
- **Hemoptysis:**
  - ⇒ brutal expectoration of blood after coughing
  - ⇒ blood is red, aerated, foamy and/or mixed with sputum, fluid, with low coagulation capacity
  - ⇒ pale, anxious patient, with cold sweat, variable dyspnea, tachypnea and/or lipothymia and/or tachycardia, TA proportional to expectoration and/or fever (it precedes, coexists with, or follows hemoptysis) (diagnostic value)
  - ⇒ the amount of blood varies (small, moderate, abundant), hemoptysis can occur several times a day for days
  - ⇒ at the end of hemoptysis, expectoration diminishes, becoming darker (due to the evacuation of blood left in the bronchi) (diagnostic value)

- **Classification of hemoptysis depending on the blood amount:**

- ⇒ *very abundant hemorrhage* (very severe) – more than 500 ml expectorated blood and hemorrhagic shock, marked paleness, cold extremities, intense thirst, hypotension, collapse, death

- ⇒ *fulminant hemorrhage* (>1000 ml), cataclysmic: asphyxia, hemorrhagic shock and sudden death

- ⇒ *extensive, severe hemorrhage* (up to 500 ml). Coughing up large amounts of pure blood is rare; the most frequent causes are bronchiectasis, tuberculosis, and lung cancer. Less frequent is encountered in pulmonary infarction, lung abscess, mycetoma, cystic fibrosis, aorto-bronchial fistula and Wegener's granulomatosis.

- ⇒ *moderate hemorrhage* (approx. 100-200 ml)

- ⇒ *small hemorrhage* (approx. 50-100 ml): expectorate fractions of 15-20 ml dark red blood following coughing episodes, frequently the first sign of pulmonary neoplasm.

- **Differentiation from other types of hemorrhage:**

*It is important to determine if blood has been coughed up from respiratory tract, been vomited from the upper gastrointestinal tract or has suddenly appeared in the mouth without coughing, suggesting a nasopharyngeal origin!*

- ⇒ Anterior or posterior *epistaxis* and flowing of blood in the oropharynx;

- ⇒ *stomatogingivorrhagia*: it occurs in gingivitis, tooth abscess, stomatitis, tonsil abscess, diphtheria, hemorrhagic diathesis, oral telangiectasia: blood mixed with unaerated saliva, without coughing or posterior secretion;

- ⇒ *hematemesis* is the vomiting of blood (from the esophagus, stomach, duodenum), having digestive causes (with symptoms):

varices, ulcer, gastritis, post-NSAIDs, Mallory-Weiss syndrome; unaerated, dark brown blood ("coffee grounds"), which coagulates rapidly with or without food remnants and/or acid pH, being followed by melena

⇒ *abundant hematemesis* (arterial blood from esophageal varices) externalized by red blood with or without aspiration in the airways (followed by coughing, expectoration of aerated foamy blood)

⇒ *extensive hemoptysis* (or any other bleeding from the mouth), followed by swallowing, hematemesis and/or melena.

- **Causes of hemoptysis:**

⇒ open or closed chest traumas resulting in rib fractures, pleuropulmonary, bronchial ruptures

⇒ foreign body, toxic gas inhalation determining mucosal traumas

⇒ hematological: blood dyscrasias, anticoagulation

⇒ respiratory infections or inflammations (*respiratory hemoptysis*):

- tuberculosis: the most frequent cause; in all its stages, even in non-evolutive TB; hemoptysis can be a revealing symptom, it may occur in evolutive episodes, it can be mortal in cavitory TB
- bronchiectasis: a very frequent cause of hemoptysis, it occurs during suppuration periods (through ulcerative mucous lesions) as purulent sputum
- lung abscess: preceded by vomica
- acute and chronic tracheobronchitis: through hyperemia and violent coughing
- pulmonary hydatid cyst: it can be a revealing symptom
- bacterial pneumonia (rarely): pneumococcal, staphylococcal, Friedlander's pneumonia

- pulmonary mycosis: actinomycosis, aspergillosis, mycetoma etc.
  - lung cancer: the most frequent cause of hemoptysis in men after the age of 50 years, smokers, black currant jelly appearance (rarely), more frequent in (diagnosed) exulcerated cancer or after radiotherapy. *Streaking of clear sputum with blood or presence of blood clots in the sputum for more than a week is suggestive of lung cancer!*
- ⇒ in cardiovascular disease (*cardiovascular hemoptysis*):
- mitral stenosis: in acute pulmonary edema and pulmonary infarction; through the rupture of bronchial pulmonary anastomoses
  - pulmonary embolism: after deep thrombophlebitis, pulmonary infarction
  - acute pulmonary edema: in acute left ventricular failure; sometimes hemorrhagic as diffuse staining with blood (pink froth)
  - aortic aneurysm: ruptured in the bronchial tree
  - primitive pulmonary hypertension, high arterial hypertension, Rendu-Osler telangiectasia due to arteriovenous fistulas
  - autoimmune diseases: Goodpasture syndrome, Wegener granulomatosis, panarteritis

*Amount and appearance and duration and frequency* of sputum as described by patient and documented by physician are important clues to etiology! Hemoptysis with purulent sputum, occurring intermittently for a few years, usually in association with a respiratory tract infection occurs in bronchiectasis. Daily hemoptysis with clear sputum or clots, for a week or more is common symptom of lung cancer, other causes include tuberculosis or lung abscess. Single large hemoptysis, associated with pleuritic chest pain or dyspnea, suggest pulmonary thromboembolism and infarction.



## 2.1.4 COUGH

Cough is the most common symptom of respiratory disease; most acute episodes are self-limiting and caused by infections, usually viral. Cough is usually an involuntary reflex but may be a voluntary act; its function is to remove secretions or particles from pharynx and airways. Involuntary cough is a reflex action initiated by stimulation of sensory receptors from the pharynx to the alveoli. It starts with contraction of respiratory muscles against closed glottis and rapid increase in intrathoracic pressure followed by an explosive release of air into the upper airway as glottis opens.

### *Causes of cough:*

- **Sinuses:** infection
- **Larynx, trachea, large airways:** infection, tumors (benign, malignant, primary, secondary), aspiration, gastro-esophageal reflux, foreign body, irritant dusts
- **Small airways:** asthma, post-viral airway reactivity, COPD, bronchiectasis, bronchiolitis, irritant dusts
- **Alveoli:** drugs, e.g. ACEI, infection: pneumonia, tuberculosis, alveolitis, left ventricular failure, irritant dusts

### *Classification:*

⇒ depending on productiveness:

- *dry cough:* dry timbre, without expectoration, short, repeated, tiring. It occurs in: pleurisy, pneumothorax, pulmonary fibrosis, pulmonary neoplasm, mediastinal tumors, aortic aneurysm, pneumonia (initial phase), neurosis, otitis, subdiaphragmatic irritation. A dry centrally painful and nonproductive cough is a feature of tracheitis and pneumonia. A paroxysmal dry cough in patients with asthma may follow a viral respiratory infection and lasts several months. A chronic dry cough is common in interstitial disease, e.g. cryptogenic fibrosing alveolitis.

Angiotensin-converting enzyme inhibitors may cause a dry cough, particularly in women.

- *moist, productive wet cough* usually indicates secretions in the upper and larger airways, and is followed by expectoration, occurring in bronchial infection and bronchiectasis: acute tracheobronchitis, chronic bronchopneumopathies, bronchiectasis, tuberculosis. A persistent moist “smoker’s” cough first thing in the morning is typical of chronic bronchitis, and any change in the pattern of this cough may indicate the development of lung cancer.

⇒ depending on evolution:

- *acute*: recent bronchopulmonary disorders, paroxysmal; short duration, it disappears with the disappearance of the cause
- *chronic* in: chronic bronchitis, chronic obstructive bronchopneumopathy, smokers, cardiovascular disease complications

⇒ depending on frequency: rare and quasi-permanent, determining insomnia, asthenia.

⇒ depending of *sound of cough*: a feeble non-explosive “*bovine*” *cough* with hoarseness may occur with respiratory muscle weakness but is more usually associated with lung cancer invading the left recurrent laryngeal nerve with resultant paralysis of the left vocal cord; a rare cause is thoracic aortic aneurysm. COPD and asthma patients often have prolonged wheezy coughing, and sometimes cough syncope. The cough of laryngeal inflammation, infection or tumor tends to be harsh, *barking* or painful and may be associated with hoarseness and stridor.

⇒ depending on the time of appearance:

- *morning cough*: bronchiectasis, chronic bronchitis, bronchorrhea, lung abscess, morning "toilet of the bronchi". Occult gastro-esophageal reflux is a common cause of daytime cough, as is chronic sinus disease with associated postnasal drip.
- *evening cough*: it is accompanied by fever, after 17:00-18:00, it occurs in pulmonary tuberculosis
- *nocturnal cough*: cardiac, in left ventricular failure, mitral valve diseases, with pulmonary stasis, pulmonary secretion. A nocturnal cough causing sleep disturbance is a common symptom of asthma
- *exertional cough*: emphysema, asthma, decompensated cardiovascular diseases, pulmonary stasis, bronchial congestion.
- *postural cough*: bronchial, pulmonary suppuration when the patient adopts anti-cough postures
- *coughing during and after swallowing liquids* suggests neuromuscular disease of the oropharynx
- *cough as a symptom* – "signal" during pleural puncture and in pleurisy, occurring through the mechanical irritation of visceral pleura, acute pulmonary edema "*ex-vacuo*" due to capillary distension

⇒ *particular forms*:

- *dull, faint cough*: low intensity, aphonous, occurring in: vocal cord disorders - croup, laryngitis, neoplasm, tuberculosis
- *barking cough*: high intensity, noisy, barking pitch, occurring in: stridulous laryngitis, tuberculous mediastinal adenopathies (child), tracheal compression/bronchi (adenopathies, aortic aneurysm, mediastinal tumors)

- *bitonal cough*: high and low tones, determined by the irritation or paralysis of the recurrent nerve. It occurs in: mediastinal tumors, aortic arch aneurysm, mediastinal adenopathies
- *cavernous cough*, metallic; empty sensation, caused by caverns provided they are >6 cm in size and the drainage bronchus is free, acting as a “resonance box”. It occurs in: tuberculosis, ulcerated pulmonary neoplasm
- *coughing fits*: in paroxysmal episodes, e.g.: convulsive cough
- *emetic cough*: followed by vomiting. It occurs in: convulsive cough, tuberculosis, tracheobronchial adenopathies, swallowing of sputum
- *irritating cough*: dry, uninfluenced by relieving medication
- incidents of coughing: hoarseness, insomnia, vomiting, muscle pain
- accidents of coughing: fractures (on pathological ground, during coughing fits), syncope (in patients with chronic bronchitis, long history of coughing, through increased intrathoracic pressure, decreased venous return), hemoptysis, embolism, emphysema bulla rupture, mediastinal emphysema

### **Sputum production**

Expectorated respiratory secretions are known as sputum or phlegm and need to be specifically asked about, because it may be regularly swallowed by children and women or patients find it difficult to discuss sputum production because of natural reluctance.

#### *Color*

Clear or ‘*mucoïd*’ sputum is produced by patients with COPD without active infection; the first sputum produced in the morning by a patient with COPD may be green because of nocturnal stagnation of neutrophils.

*Yellowish sputum* is found in acute lower respiratory tract infection (live neutrophils) and also in asthma (eosinophils). *Green sputum* (lysed neutrophils and their green-pigmented enzyme verdoperoxidase) indicates chronic infection as in exacerbations of COPD, bronchiectasis, etc. In the red hepatization phase of pneumococcal pneumonia sputum may be characteristic *rusty red* color. In coal miners with pneumoconiosis the rupture of necrotic areas of pulmonary fibrosis can result in the expectoration of black sputum (*melanoptysis*).

#### *Amount*

Regular coughing up of large volumes of purulent sputum influenced by posture is characteristic of bronchiectasis. The sudden production of large amounts of purulent sputum on single occasion suggests the rupture of a lung abscess or empyema into the bronchial tree ('vomica'). Large volumes of watery sputum with a pink tinge in acutely breathless patients suggests pulmonary edema, whereas large volumes of watery sputum for weeks (bronchorrhea) is a symptom of alveolar cell cancer.

#### *Taste, smell and content*

'Foul' or 'vile' tasting or smelling sputum suggests anaerobic bacterial infection and can occur in bronchiectasis, lung abscess and empyema; sometime a change of sputum taste suggests infective exacerbation in bronchiectasis. In asthma and allergic bronchopulmonary aspergillosis viscid secretions can accumulate in airways, and are coughed up as worm-like structures that are *casts of bronchi*. Other *solid matter* that may be coughed up includes necrotic tumor and inhaled foreign bodies such food, teeth and tablets.

**Apnea** is defined as involuntary absence of breathing for 10 seconds or more, usually occurring during sleep, when the retropharyngeal airways collapses and obstructs the upper airways. The bed partner usually describes a very loud snoring followed by an absence of breathing associated with increasing abdominal and thoracic movements and a grunting noise and recurrence of snoring at the end of apneic episode.

Consider a diagnosis of *apnoea/hypopnoea syndrome* when apnoea is associated with daytime sleepiness e.g. falling asleep in the morning, after meals, in public places, in meetings, in the evening watching television or when reading. *Central apnoea* is neuromuscular in origin, and, usually not associated with snoring. Apnoea may also be voluntary or can alternate with periods of hyperventilation in *Cheyne-Stokes breathing*.

## **2.2. GENERAL PHYSICAL EXAMINATION**

### **2.2.1. ATTITUDE**

- Forced antalgic attitude: contralateral decubitus in pleuritis
- Forced antidyspneic postures: orthopnea in acute pulmonary edema, spontaneous pneumothorax; contralateral decubitus in exudative pleurisy
- Forced antitussigenic postures: in bronchial dilation
- The degree of dyspnea assessed indirectly through the patient's mobilization capacity (e.g.: rising, dressing, moving in bed)

### **2.2.2. FACIES**

- Flushed facies: pneumonia
- Facial pallor, shining eyes in young people with pulmonary TB
- Earthy facial pallor, eye circles: chronic tb, pulmonary suppuration
- Butterfly eruption: lupus with respiratory involvement (pleurisy, interstitial pneumonia)
- Beating of nasal wings and polypnea in bronchopneumonia in children
- Keratoconjunctivitis, iridocyclitis: pulmonary tb, sarcoidosis
- Anisochoria: apical TB (irritation – cervical sympathetic nerve injury)

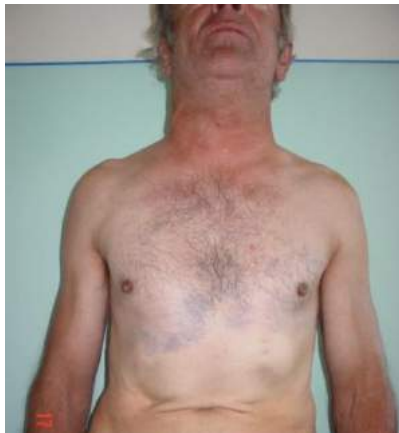- *Pancoast-Tobias syndrome*: pain in the shoulder – brachial plexitis, bulging of the supraclavicular region, upper limb hypotrophy, unilateral Hippocratic fingers
- *Claude-Bernhard Horner syndrome* on the affected side: myosis, enophthalmia, palpebral fissure narrowing

### 2.2.3. MENTAL STATE

- Delirium, delusions, hallucinations: in severe pneumonia (in alcoholics, elderly), influenza
- Tussigenic syncope: short duration loss of consciousness during coughing fits

### 2.2.4. CHANGES IN SKIN APPENDAGES, MUCOSAE, SKIN

- Cyanosis: central: common to respiratory diseases with respiratory failure: COPD, status asthmaticus
- Cyanosis, mantle edema: superior vena cava compression syndrome – mediastinal disorders
- Red-purple coloring of skin, particularly facial skin: polyglobulia in pulmonary diseases, it increases cyanosis – COPD



**Figure 83. Cyanotic thorax and superior cava-cavum collateral circulation in a patient with mediastinal syndrome**

- Generalized pallor: after hemoptysis, in chronic anemia in suppurations, infections
- Hyperpigmentation: Addison's disease (more frequently adrenal gland tb with associated pulmonary tb)
- Nasolabial herpes: pneumonia, influenza
- Erythema nodosum: TB primo-infection, sarcoidosis, streptococcal infections
- Intercostal herpes zoster: intercostal neuralgic pain and characteristic eruption
- Hippocratic fingers, hypertrophic osteoarthropathy: bronchiectasis, lung abscess, empyema, bronchopulmonary neoplasm, pulmonary fibrosis

### **2.2.5. EDEMA**

- Dependent subcutaneous edema with hydrothorax: right ventricular failure in respiratory diseases (cor pulmonale: COPD, bronchial asthma, pachypleuritis)
- Mantle edema: superior vena cava obstruction and/or chemosis: dilations and conjunctival edema
- Quinke and/or glotic edema: severe inspiratory dyspnea
- Revealing edema: of the chest wall in subcutaneous empyema, rarely

### **2.2.6. VENOUS COLLATERAL CIRCULATION**

- On the anterolateral chest wall: superior vena cava compression syndrome (branches of the subclavicular/axillary vein; downward flowing direction)

### **2.2.7. ADENOPATHY**

- Supraclavicular/laterocervical: tb, sarcoidosis, bronchopulmonary neoplasm and/or mediastinal adenopathy



- Palpation technique: behind the clavicle, sternocleidomastoid insertion, head flexion

### **2.2.8. OTHER GENERAL CHANGES:**

- fever
- voice changes: dysphonia in laryngitis; nasal voice in nasal obstruction; bitonal voice in recurrent nerve paresis
- fetid odor of the expired air: bronchiectasis, pulmonary gangrene

## ***2.3. PHYSICAL EXAMINATION OF THE UPPER AIRWAYS***

- Larynx: tumefaction in glottic edema; “softening” in relapsing polychondritis
- Trachea: palpation (approximately 4-5 cm); contralateral deviation: tumors, pleurisy, pneumothorax; ipsilateral deviation: atelectasis

## ***2.4. PHYSICAL EXAMINATION OF THE CHEST***

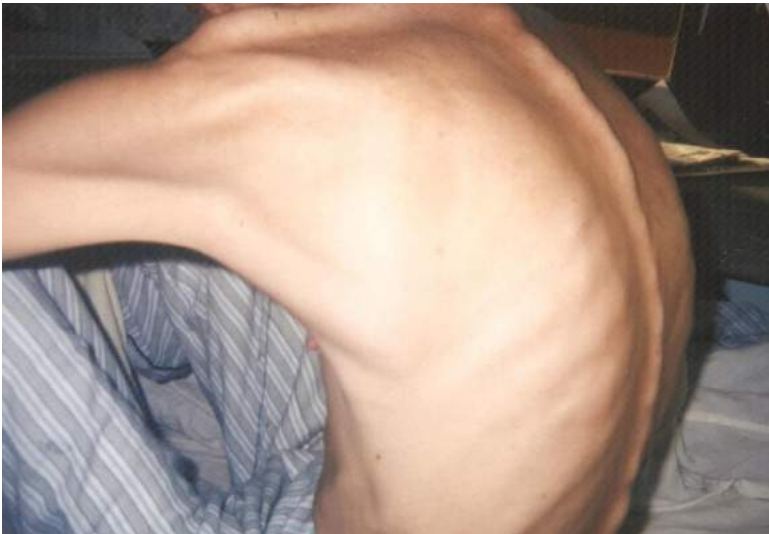**Normal:** symmetrical, angle of Louis, epigastric angle 70-110°, costal angle 45°, joined shoulder blades, cone-shaped appearance 1:2/5:7

### **2.4.1. INSPECTION**

#### **Global symmetrical deformities**

- **Emphysematous chest** (barrel chest, during forced inspiration – pulmonary emphysema): short globular chest, increased anteroposterior diameter, epigastric angle greater than 90°, horizontalized ribs, enlarged intercostal spaces, short neck, head sunk between the shoulders, effaced supraclavicular, infraclavicular fossae, prominent sternum with extremely prominent angle of Louis, limited respiratory movements

- **Paralytic chest:** the opposite, it occurs in asthenic constitution, acquired in TB: elongated chest, reduced anteroposterior diameter, epigastric angle smaller than  $90^\circ$ , very visible intercostal spaces, excavated supraclavicular, infraclavicular fossae, descending shoulders, long neck, flat sternum, visible shoulder blades (wing-like)
- **Rachitic chest:** in rickets: prominent chest, pectus carinatum (pigeon chest), chondrocostal nodosities, “rachitic rosary”, frequent kyphosis



**Figure 84. Asthenic thorax in an emaciated patient**

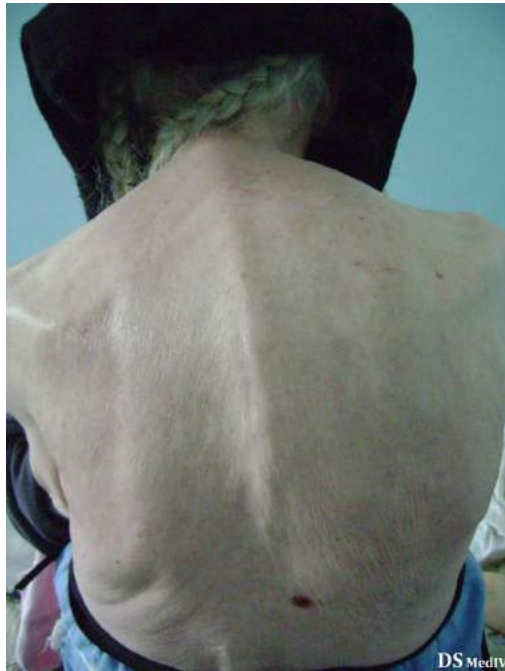- **Cone-shaped chest:** in meteorism, ascites, hepatosplenomegaly, large abdominal tumors: dilated base of the chest, normal upper chest
- **Adenopathic chest:** in adenopathies, bronchial tumors in childhood: increased chest volume, upper globular chest with a circular submammary depression below the xiphoid appendix

### **Asymmetrical global deformities:**

- They occur through changes in the spinal curvature: inadequate postures, rickets, TB, rheumatism, age e.g.: kyphosis (posterior convex angulation), scoliosis, lordosis, gibbus (sharp angled kyphosis), kyphoscoliosis determine ventilatory, circulatory disorders

### **Unilateral deformities:**

- **Bulging of a hemithorax:** pleurisy, hydrothorax, pyopneumothorax, tumors, hepatosplenomegaly lead to the enlargement/bulging of intercostal spaces, scoliosis and an elevated shoulder on the affected side



**Figure 85. Severe kyphoscoliosis with thorax deformity**

- **Retraction of the hemithorax:** in pachypleuritis, pleural symphysis, unilateral fibrothorax, pulmonary sclerosis, determining decreased perimeter, reduction of intercostal spaces, scoliosis and a lowered shoulder on the affected side
- **Localized prominences** occur in: osteoperiostitis, lues, tumors, cysts, empyema
- **Localized retraction** appears in: pleural symphysis, mediastinopericarditis, pulmonary atelectasis, infundibuliform chest deformity: hollow xiphoid appendix – congenital or in shoemakers

### **Respiratory chest movements:**

- **Normal:** in women: upper costal type; in men, children: costo-abdominal, diaphragmatic, abdominal; adolescents: lower costal type
- **Pathological:** altered respiratory type, changed amplitude, depressions or bulging

#### ⇒ **Alteration of the respiratory type:**

- **In men:** upper costal respiration occurs in: basal pleurisy, subdiaphragmatic infections/tumors, herpes zoster, ascites, meteorism through the immobilization of the diaphragm
- **In women:** lower costal respiration: by the decrease in the amplitude of the upper chest respiratory movement (neuralgias, fractures)

#### ⇒ **Alteration of the amplitude of respiratory movements:**

- *Reduction:*
  - bilateral in pulmonary emphysema
  - unilateral in main bronchus obstruction, stabbing chest pain, extensive pneumonia, large tumors, pleurisy, extensive symphysis, resulting in asynchronism, asymmetry between the hemithoraces

#### ⇒ **Inspiratory depressions:**

- *Retraction* meaning the long duration intercostal, supraclavicular, suprasternal, epigastric inspiratory depression of soft parts, due to decreased alveolar pressure in: upper airway obstruction (glottic edema, diphtheric croup, tumors, external compression, foreign bodies), uni- or bilateral bronchial, tracheal obstruction: goiter, aneurysm

⇒ **Expiratory bulging:**

- Pulmonary emphysema at the level of the supraclavicular fossae
- Empyema necessitatis

⇒ **Respiration types:**

- KUSSMAUL respiration in acidosis: diabetes mellitus, uremia, intoxication
- CHEYNE-STOCKES respiration: in left ventricular failure, intracranial hypertension, renal failure
- BIOT respiration: in meningitis, bulbar lesions

## 2.4.2. PALPATION

### MORPHOLOGICAL DATA:

- The local bulging or retraction of one or both hemithoraces
- Localized fluctuations: wall suppuration (abscess), pleural suppuration (empyema), aortic aneurysm (pulsatile tumor, anteriorly), subcutaneous crepitations (subcutaneous emphysema)
- Muscle tumors: fibrous node in ossifying myositis, trichinella larvae
- Bone tumors (ribs, sternum, vertebrae) or fractures, intercostal, phrenic neuralgias (Valleix points or sensitive phrenic points), chostocondritis of Tietze syndrome (localized tenderness over the II-IV costal cartilages)

**Upper mediastinal shift** causes deviation of trachea assessed by palpation at suprasternal notch.

- *Causes of tracheal deviation towards the side of the lung lesion:*

Upper lobe or lung collapse, upper lobe fibrosis, pneumectomy

- *Causes of tracheal deviation away from the side of the lung lesion:*

Tension pneumothorax, massive pleural effusion

- *Upper mediastinal mass:* retrosternal goitre, lymphoma, lung cancer

**Lower mediastinal shift** displaces the cardiac apex, without tracheal deviation, as in scoliosis, kyphoscoliosis, severe pectus excavatum or any left ventricular enlargement. Cardiac apex beat may be difficult to localize in obesity, pericardial effusion, poor left ventricular function or patients with lung hyperinflation as in COPD. The heave of right ventricular hypertrophy, found in severe pulmonary hypertension, is best felt at left sternal angle.

*The distance between the suprasternal notch and cricoid cartilage is normally three to four fingers breadths. Reduction in this distance suggests lung hyperinflation. A ‘tracheal tug’ can be found in severe hyperinflation when fingers resting on trachea move inferiorly with each inspiration.*

**AMPLITUDE OF RESPIRATORY MOVEMENTS** should be equal on both side of thorax, and could be low unilateral or bilateral symmetrical:

- *Bilateral symmetrical:* obstructive pulmonary emphysema
- *Unilateral:* partial/total unilateral bronchial obstruction (it decreases during inspiration), massive parenchymatous processes: pneumonia, tumors; extensive pleural processes: pleurisy, pneumothorax, tumors, pachypleuritis; immobilizing parietal processes: pain, paralysis; in the apex: apical TB, pulmonary apical tumors
- *Reduced expansion of one side of the upper lobes* indicates abnormality on that side, e.g. pleural effusion, lung or lobar collapse, pneumothorax and unilateral fibrosis, and is assessed by observing the clavicles from behind during tidal breathing.

- *Bilateral reduction in chest wall movement* is common in advanced COPD and diffuse pulmonary fibrosis

### **VOCAL VIBRATIONS (PECTORAL FREMITUS): “33”**

Vocal vibrations are transmitted from the vocal cords through the airways and the pulmonary parenchyma to the wall, where palpation is performed on symmetrical areas with both palms or with one palm or with the cubital edge.

#### ***PHYSIOLOGICAL VARIATIONS:***

##### *Increased vibrations:*

- In lean individuals, with a thin wall
- In individuals with low pitched voice, distinct pronunciation
- Right suprascapular area (shorter caliber bronchus)
- Subclavicular, interscapulovertebral area

##### *Decreased vibrations:*

- In women compared to men
- Above the shoulder blades and at the base of the chest

#### ***PATHOLOGICAL CHANGES:***

#### • **INCREASE IN PECTORAL FREMITUS:**

- Pulmonary condensation processes with a permeable bronchus: pneumonia, bronchopneumonia, pulmonary infarction, infiltrative tb
- Cavitory processes (more than 6 cm in diameter, smooth elastic walls, less than 6 cm depth): tb caverns, emptied pulmonary abscess, emptied hydatid cyst
- Compensatory hyperventilation areas around an extensive pathological process: large tumors, massive pneumonia

#### • **DIMINUTION OF PECTORAL FREMITUS:**

- Incomplete obstruction of the bronchus: tumor, foreign body, pathological secretion
- Compression of the bronchus involved in massive condensation processes: large tumors, massive pneumonia

- Decrease in the elasticity of lung parenchyma: pulmonary emphysema
- Interposition of fluid, air in the pleural space: small pleural collection amounts, pachypleuritis
- **SUPPRESSION OF PECTORAL FREMITUS:**
  - Laryngeal disorders with aphonia
  - Complete obstruction of a bronchus: exudate, bronchial cancer, foreign body
  - Complete extrinsic compression of a bronchus: proximity adenopathy
  - Interposition of fluid, large amounts of air in the pleural space: massive pleurisy, valve pneumothorax

### 2.4.3. PERCUSSION

*NORMALLY*, a prolonged sonorous, relatively low pitched sound, spanning the surface of the lung fields is obtained, which is called *PULMONARY RESONANCE*, having the following limits: the lung apical part (with the Kronig bands), cardiac dullness, the lower margins of the lungs and Traube's space (delimited by the heart, spleen, left costal margin, left lung).

#### **PATHOLOGICAL CHANGES IN PULMONARY RESONANCE:**

- Pulmonary bands can be enlarged (having 2/3 resonant sounds) in emphysema or diminished (dull) in condensations (tb, tumor-like) or pachypleuritis
- Cardiac dullness can be increased or diminished
- The lower limits of the lungs can be **low** bilaterally in emphysema or unilaterally in pneumothorax, or they can be **high** in: abdominal pathological processes that move the diaphragm upwards (ascites, tumors, hepatomegaly, meteorism, diaphragmatic paresis) or supradiaphragmatic processes with dullness: pneumonia, pleurisy, tumors, pachypleuritis; sometimes reduced diaphragmatic mobility



is found (*HIRTZ maneuver*): in pneumonia, pachypleuritis, small pleurisy, phrenic paresis.

- The pulmonary resonance intensity can be diminished or marked
- **The diminution of pulmonary resonance** produces a sound called *SUBDULLNESS*, when aerated areas are predominant, such as in early pneumonia, segmental atelectasis, pulmonary infarction, corticopleuritis or chest wall changes (excessive adipose tissue, edema), or *RELATIVE DULLNESS* if non-aerated areas are dominant such as in extensive pulmonary condensation: pneumonia in the hepatization stage, extensive pulmonary infarction, bronchopneumonia, tumors, tb, fibrothorax, lobar atelectasis, hydatid cyst or large lung abscess or pleural collections (pleurisy, hydrothorax, hydropneumothorax); *ABSOLUTE DULLNESS* perceived as a short, dry, non-resonant sound due to the disappearance of air in abundant pleural collections, lobar pneumonia, confluent bronchopneumonia, atelectasis through complete main or lobar bronchus obstruction; semiological description includes: location, form, extension, causes, as in the following situations:

⇒ ***DELIMITED, SUSPENDED DULLNESS:***

- Causes: pulmonary congestion, pneumonia, pulmonary infarction, encysted pleurisy, cyst, lung abscess, tumor
- In pneumonia: it is situated above a lobe (lobar), not decided dullness (relative)
- In bronchopneumonia: there is subdullness (small foci), which is difficult to detect
- In infiltrative tb: maximal subdullness, at the lung apices
- In pulmonary tumors: decided, dry, resistant, wood-like dullness
- In encysted interlobar pleurisy: dullness along the interlobal fissure

- In abscesses or hydatid cysts: subdullness when they are large (>6 cm), superficial, full

⇒ **EXTENSIVE BASAL DULLNESS:**

- Causes: most frequently pleurisy
- In moderate pleurisy: relatively decided dullness (between pneumonia and tumor), the upper limit takes the form of *DAMOISEAU's curve* (slanting from the spine to the middle axillary line and descending towards the sternum), delimiting the *GARLAND triangle* (triangular paravertebral dullness on the same side), the *GROCCO-RAUCHFUSS triangle* (paramedian on the opposite side), respectively; in left pleurisy, dullness covers *TRAUBE's space* and in right pleurisy, dullness moves up and down with the fluid when the chest rises or falls (*PITRES sign*)
- In extensive pleurisy, dullness becomes horizontal
- In hydropneumothorax, the upper limit is horizontal, with hyperresonance above
- In extensive pulmonary condensation, skodaic resonance occurs suprajacent to dullness by compensatory hyperactivity

⇒ **LIMITED BASAL DULLNESS:** Causes: diaphragm elevation (through intraabdominal processes) when dullness is accompanied by active mobility (positive Hirtz maneuver) or thoracic processes when active mobility is absent.

- **Increased pulmonary resonance** produces tympanism, amphoric resonance, cracked pot sound or skodaic resonance.

⇒ **TYMPANISM** is a high intensity, low pitched, musical sound, similar to the percussion of *TRAUBE's space* or intestines, which occurs in diffuse or circumscribed pulmonary emphysema or pneumothorax.

- ⇒ AMPHORIC RESONANCE represents low pitched, musical, metallic hyperresonance that occurs in large superficial caverns or diffuse and encysted pneumothorax.
- ⇒ THE CRACKED POT SOUND is perceived above caverns that communicate with a narrowed bronchus and in pneumothorax with a subclavicular bronchopleural fistula.
- ⇒ SKODAIK RESONANCE is a higher pitched variety of tympanicity detected above functional compensatory areas such as those situated in the proximity of extensive parenchymatous or pleural processes.

#### 2.4.4. AUSCULTATION

One should listen with the bell of the stethoscope (as most sounds are low frequency), patient being relaxed and breathing deeply (but not prolonged to avoid tetany). Auscultate both sides alternatively, avoiding within 3cm of the midline (as this areas may transmit sounds directly from the trachea or main bronchi), comparing findings over a large number of equivalent positions (listen anteriorly from above the clavicle down to 6th rib, laterally from the axila to the 8th rib and posteriorly down to the level of the 11th rib) to ensure that localized abnormalities are not missed. In each area listen to the quality and amplitude of normal breath sounds (*fundamental breathing*). Identify any gap between inspiration and expiration and listen for any added sounds (*crackles, wheeze, pleural friction rub*). Finally, asses the quality and amplitude of vocal resonance by asking the patient to say "one, one, one"; in the normal lung a whispered note will not be heard but over the consolidated lung, as in pneumonia, the sound is transmitted producing, "whispering pectoriloquy".

*Normal breath sounds* heard at chest wall are caused by turbulent flow in large airways, and have a rustling quality and are said to be "vesicular"; during expiration and in their passage through normal lung

their intensity and frequency are decreased; the pattern and intensity of breath sounds reflect regional ventilation (they are loudest at the apex in early inspiration and at the bases in mid inspiration).

**A. FUNDAMENTAL BREATHING (normal)** consist of physiological bronchial murmur (bronchial breathing) and vesicular murmur (vesicular breathing)

- **Physiological BRONCHIAL MURMUR (bronchial breathing):**  
A sound like blowing in a tube, **like** pronouncing the sounds “h, g”, inspiratory and expiratory glottic sound; perceived above the larynx, trachea, sternum, between the scapulae (D4). Bronchial breathing is characterized by breath sounds that are high pitched with a hollow or blowing quality similar to those heard over the trachea and larynx during tidal breathing. The breath sounds are of similar length and intensity in both inspiration and expiration and have a characteristic pause between.
- **Pathological BRONCHIAL MURMUR (bronchial breathing)**  
occurs whenever normal lung tissue is replaced by uniformly conducting tissue, whether through consolidation, fibrosis or collapse and the relevant major bronchus is patent (and, therefore, its presence tends to exclude the possibility of an obstructing lung cancer); it is confirmed by finding whispering pectoriloquy (e.g. both may be heard at the top of a pleural effusion); vocal resonance is also increased over consolidated lung. Bronchial breathing, therefore, appears in:
  - ⇒ *CONDENSATION OF THE LUNG PARENCHYMA* in:  
Pneumonia (hepatization phase), pulmonary infarction, TB;  
Moderate parapneumonic pleurisy (pleural sound: diminished intensity, as from a great distance)
  - ⇒ *PULMONARY CAVITIES* (*cavernous, amphoric murmur*)  
more than 5-6 cm in size, superficial, empty, with a permeable drainage bronchus, surrounded by condensed lung tissue,

cavities that occur in pulmonary TB (in the apex), lung abscess, hydatid cyst, excavated lung cancer, bronchiectasis (at the base of the lung)

**Egophony** is a bleating or nasal sound heard over consolidated lung or at the upper level of a pleural effusion. It is due to enhanced transmission of high frequency noise across abnormal lung with lower frequencies filtered out.

- **VESICULAR MURMUR ('vesicular' breathing)**

- ⇒ It is an aspirated sound (like pronouncing "a, f"), with an inspiration/expiration ratio 3:1, audible throughout the chest, a bronchoalveolar sound that is heard during the passage of air between the bronchiolar lumen and the alveolar sacs.

- ⇒ The intensity of vesicular murmur relates to airflow and the tissue through which the sounds travels, so, the changes can be:

- INCREASED VESICULAR MURMUR in the compensatory hyperactivity of the lung or in children;
- DIMINISHED/SUPPRESSED VESICULAR MURMUR in *reduced conduction*, as in: obesity/thick chest wall, pleural collections, pneumothorax, pachypleuritis or *reduced airflow*-generalized: e.g. COPD, or localized e.g. collapsed lung due to bronchopulmonary cancer, foreign bodies in the airways, external compression;
- PROLONGED EXPIRATION MURMUR in bronchial asthma, obstructive emphysema.

- **WHISTLING BREATHING ('mixed' breathing)**

- ⇒ It is a mixed sound (bronchial murmur and vesicular murmur); expiration is whistling;

- ⇒ It is found in: bronchopneumonia, congestion/resorption of pneumonia, pulmonary infarction, above a pleural effusion

## B. ADDED BREATH SOUNDS (rales or crackles)

### • BRONCHIAL or DRY RALES (“rhonchus”)

- ⇒ *SONOROUS* rales (*RONCHII*): low pitched; like snoring; they occur in the large bronchi;
- ⇒ *SIBILANT* rales (*WHEEZES*): like wind whistling; high pitched; in the small bronchi;
- ⇒ They are both heard during inspiration (sonorous rales first) as well as during expiration (whistling rales first);
- ⇒ They occur in acute and chronic bronchitis, bronchial asthma (throughout the chest surface) and in bronchiectasis (localized);
- ⇒ They are increased in mouth breathing, being altered by cough;
- ⇒ They are produced by the vibration of viscous secretion in the bronchi with breathing.

### • ”WET” RALES: CREPITANT AND BULLOUS RALES

- ⇒ *CREPITANT RALES (CRACKLES)*: they are heard during inspiration; they are small, equal, numerous, increasing after coughing; they are produced through the detachment of the alveolar walls that are partially filled with secretions; they occur in: pneumonia during the induction and relapse phase, acute pulmonary edema, pulmonary infarction, heart failure (stasis rales), following hemoptysis
- ⇒ *FINE, MEDIUM OR COARSE BULLOUS RALES*:
  - FINE OR SUBCREPITANT BULLOUS RALES: they are perceived during inspiration and expiration; they occur in bronchopneumonia, pneumonia (in resorption), acute pulmonary edema
  - MEDIUM BULLOUS RALES: “like air bubble breaking”, unequal, discontinuous, they disappear after cough; they are produced by the vibration of secretion in the medium bronchi in acute bronchitis, bronchopneumonia, bronchial asthma

- **COARSE BULLOUS RALES:** they are heard in bronchiectasis; rare.

**Crackles** are interrupted non-musical sounds, usually resulted from loss of stability of peripheral airways, which collapse on expiration; with high inspiratory pressures air enters rapidly into these airways with abrupt opening of alveoli and small bronchi, producing the characteristic crackling noise. **The terms rales and crepitations should be abandoned (Macleod Clinical Examination, 2006)**

***Phase of inspiration and causes:***

***Early:*** small airways disease as in bronchiolitis

***Middle:*** pulmonary edema

***Late:*** pulmonary fibrosis (*fine*); pulmonary edema (*medium*); bronchial secretions in COPD, pneumonia, etc. (*coarse*) lung abscess, tubercular lung cavities (*coarse*)

***Biphasic:*** bronchiectasis (*coarse*)

Fine late inspiratory crackles, which sound similar to rubbing hair between the fingers, are characteristic of pulmonary fibrosis. Crackles may also be heard when air bubbles through secretions in major bronchi, dilated bronchi as in bronchiectasis or in pulmonary cavities; these crackles sound coarse, have a gurgling quality and change with coughing if secretions are dislodged.

**Wheeze** is a musical quality sound, which tends to be louder on expiration, when airways normally narrow. Inspiratory wheeze therefore implies severe airway narrowing. The sound is due to continuous oscillations of opposing airway walls and implies airway narrowing. High-pitched wheeze arises from smaller airways and has a whistling quality, while low-pitched wheeze originates from larger bronchi. In severe airways obstruction wheeze may be absent because of reduced airflow producing a 'silent chest'. Wheeze is characteristic of asthma and COPD; when is localized, with a single musical note, that does not clear on coughing is due to a fixed bronchial obstruction, most

commonly due to lung cancer. **The term ‘rhonchus’ should be abandoned! (Macleod Clinical Examination, 2006).**

- **SUPERADDED SOUNDS - *THE PLEURAL RUB*:** it occurs through the friction of rough pleural surfaces in pleuritis, which creates a creaking sound similar to that produced by bending stiff leather, best heard on deep breathing at the end of inspiration and beginning of expiration, discontinuous, hardening on pressure with diaphragm of the stethoscope, disappearing if an effusion separate the pleural surfaces; it is usually associated with pleuritic pain over the inflamed pleura in pulmonary thromboembolism, pneumonia and pulmonary vasculitis.



# CHAPTER 3. CLINICAL RESPIRATORY SYNDROMES

## *3.1. PULMONARY CONDENSATION SYNDROME*

Pulmonary condensation syndrome includes physical and radiological signs common for pulmonary condensation (loss of air from the lung parenchyma that becomes more compact)

- ⇒ pulmonary condensation through **infiltration**, i.e. by the replacement of air in the alveoli with an infiltrate
- ⇒ pulmonary condensation through **atelectasis**, i.e. by the resorption or expulsion of alveolar air; the signs are different

### **3.1.1. PULMONARY CONDENSATION SYNDROME THROUGH INFILTRATION**

- Pulmonary condensation syndrome through infiltration occurs in:
  - ⇒ pulmonary congestion, pneumonia, bronchopneumonia, abscess, pulmonary gangrene in which air is replaced by an acute inflammatory exudate;
  - ⇒ in TB infiltrates and pneumonia in which alveolar air is replaced by a chronic infiltrative exudate;
  - ⇒ pulmonary infarction, when the alveoli are filled with blood;
  - ⇒ massive tumors in which the lung parenchyma is replaced by neoplastic proliferation;
  - ⇒ pulmonary edema, when the alveoli are filled with a transudate
- **Functional and general symptoms:**
  - ⇒ they are extremely varied, depending on the causative disease, evolutive stage, etc.

⇒ they are not common; they are not included in the discussion of the syndrome;

- **Physical signs:**

*Inspection, palpation:*

⇒ breathing movements on the affected side have low amplitude and are more accelerated

⇒ pectoral fremitus is augmented

*Percussion: dullness*

⇒ condensation in the area

⇒ lower intensity than in pleurisy

⇒ intensity depends on: the size of the infiltrate and its distance from the wall: examples: central hilar infiltrates do **NOT** produce dullness; **subdullness** in pneumonia at the beginning of the formation of the infiltrate or during its resorption, because the alveoli are not filled with exudates; **subdullness** in bronchopneumonia, where nodular infiltrates alternate with normal parenchyma.

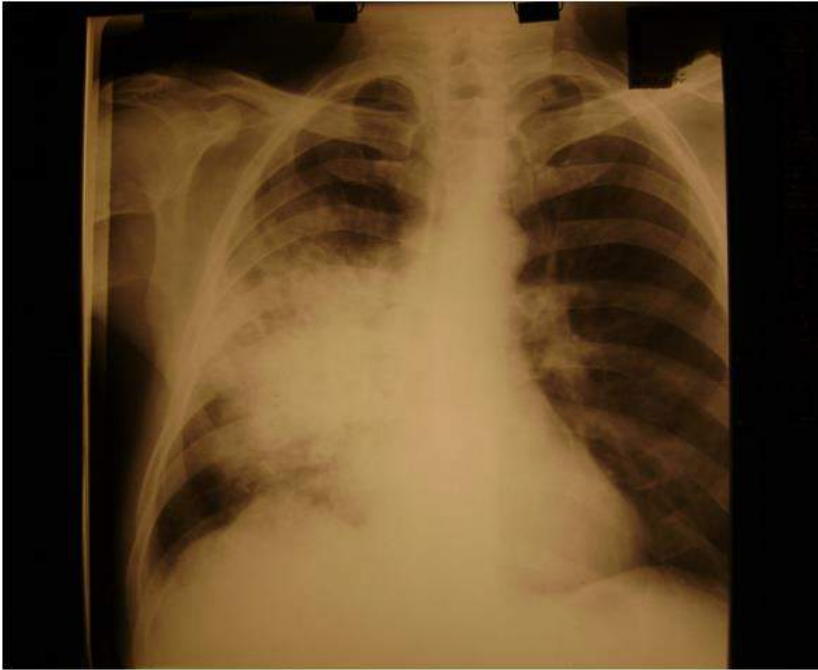
*Auscultation:*

⇒ **BRONCHIAL MURMUR**: if the infiltrate is large, it completely fills the alveoli; it is superficial; the airways are permeable (e.g.: hepatization of pneumonia)

⇒ **WHISTLING BREATHING** (mixed): if the alveoli are partially filled with exudate

- + crepitant rales (the phase of induction, resorption of pneumonia, certain phases in TB, pulmonary infarction, pulmonary edema)
- + subcrepitant rales
- ± absence of auscultatory changes = in central hilar infiltrates, pleural thickenings or associated pleurisy (**RESPIRATORY SILENCE**)

- **Radiological examination:** inhomogeneous shadowing of the (airless) lung, of subcostal intensity, without the shift of the mediastinum; small clinically undetected central hilar condensations are also evidenced.



**Figure 86. Condensation syndrome – radiographic findings in pneumonia**

### **3.1.2. PULMONARY CONDENSATION SYNDROME THROUGH ATELECTASIS**

Pulmonary condensation syndrome through atelectasis occurs in:

- obstruction (airway obstruction);
- obturation or compression of the bronchus corresponding to a pulmonary territory through: bronchial cancer or extrabronchial tumor (ganglion, aneurysm) that compresses it:  
⇒ air is resorbed from the non-ventilated territory

- compression of the lung through: abundant pleural exudate; pneumothorax:  
⇒ air is expelled from the compressed territory
- **Functional and general symptoms:** various, depending on the cause of atelectasis.
- **Physical and radiological signs:** different depending on the type of atelectasis

***Inspection:***

- ⇒ the affected hemithorax is retracted, the intercostal spaces are narrowed (in atelectasis through obstruction).
- ⇒ the affected hemithorax is bulging (in atelectasis through compression)
- ⇒ breathing movements are reduced (in both, even paradoxical in atelectasis through obstruction)

***Palpation, percussion, auscultation***

- the above table summarizes the clinical findings from palpation, percussion and auscultation:

	<b><i>Atelectasis through obstruction</i></b>	<b><i>Atelectasis through compression</i></b>
<b><i>Palpation</i></b>	abolished pectoral fremitus	augmented pectoral fremitus
<b><i>Percussion</i></b>	dullness if air is completely resorbed / hyperresonance – incompletely resorbed air	dullness if air is completely resorbed / hyperresonance – incompletely resorbed air
<b><i>Auscultation</i></b>	vesicular murmur abolished	pleuritic sound in moderate pleurisy amphoric murmur in pneumothorax open into a bronchus

### **Radiological examination:**

- Narrowing of spaces + shift (attraction) of the mediastinum to the affected side + condensation shadow;
- Pneumonia + pleurisy.

### **3.1.3. PULMONARY CONDENSATION SYNDROME IN PNEUMONIA**

Pneumonia is an inflammatory process of the lung caused by various etiological agents: infectious (bacteria, viruses etc. – 95%) and non-infectious (toxic substances, radiation etc.).

#### **A. Bacterial pneumonia**

**Pneumococcal pneumonia:** lobar pneumonia

- **Clinical picture:**

*Symptoms:*

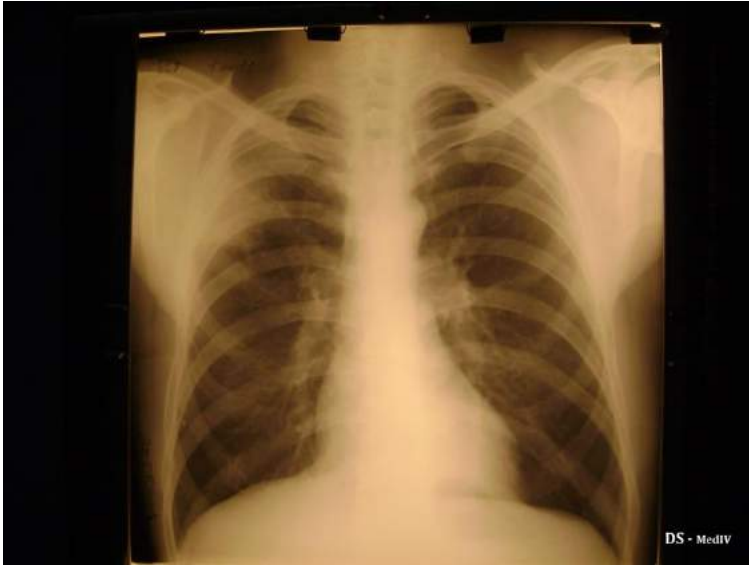
- ⇒ sudden onset, with fever 39-40°C, sudden chill, stabbing chest pain below the nipple, dyspnea
- ⇒ dry cough, followed by a small amount of rusty red sputum
- ⇒ agitation, delirium in alcoholics, elderly patients

*Signs:*

- ⇒ flushed facies (congested cheekbones), labial herpes
- ⇒ equal, fine crepitant rales in the congestion phase
- ⇒ dullness + bronchial murmur (condensation syndrome) in the hepatization phase
- ⇒ unequal, coarse crepitant rales in the resorption phase
- ⇒ normal chest examination in central pneumonia (central focus)

- **Complementary explorations:**

- chest X-ray: triangular lobar or segmental opacity
- increased ESR, leukocytosis with neutrophilia, pneumococcus in the sputum

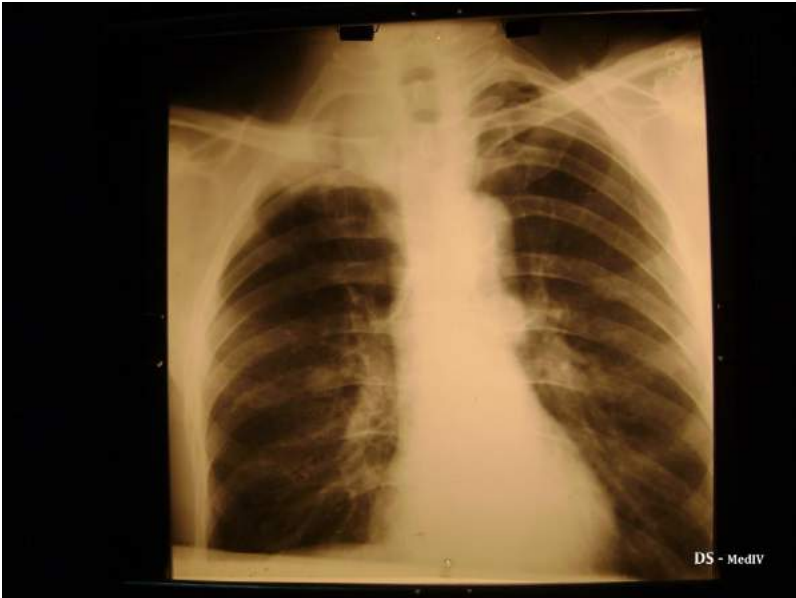


**Figure 87. Segmental pneumonia in the upper lobe of the right lung**

### **Non-pneumococcal bacterial pneumonia**

- **Etiology:**
  - staphylococcus aureus, *Hemophilus*, *Klebsiella*
  - the germs originate from the airways, hospital environment, blood
  - they occur in a locally or generally changed background
- **Clinical picture:** most frequently bronchopneumonia
  - most frequently the clinical picture is severe or more severe than in pneumococcal pneumonia (with respiratory failure, toxic shock etc.)
  - sudden onset: fever, repeated shivering, cough with purulent or hemorrhagic expectoration
  - insidious onset: patients with severe disorders + picture of the preexisting disease

- local signs depend on the location, number, size of bronchopneumonia foci: multiple areas of subdullness + crepitant/subcrepitant rales, rarely condensation syndrome
- **Complementary explorations:**
  - chest X-ray: bronchopneumonia appearance
  - increased ESR, examination of the sputum (or hemoculture) identifying the bacterial agent



**Figure 88. Pneumonia in the upper lobe of the right lung (*Klebsiella Pneumoniae*)**

### **B. Atypical pneumonia**

- **Etiology:** mycoplasma, rickettsias, viruses etc.
- **Clinical picture:**
  - epidemic occurrence or in contact with animals
  - reduced symptomatology of acute airway infection

- gradual fever 1-2 weeks, cephalgia, myalgia, dry cough, normal objective examination
- **Complementary explorations:**
  - chest X-ray: interstitial pneumonia appearance
  - normal ESR, serological tests for etiological agents.

### 3.1.4. SYNDROMES IN LUNG CANCER

#### Lung cancer classification

- *non-small-cell lung cancer*: the most common type (more than 80% of cases); can be either squamous cell carcinoma (60% of cases, mainly in smokers), adenocarcinoma or large-cell carcinoma
- *small-cell lung cancer*: less common type (less than 20% of the cases), occurs frequently under the age of 40 (aggressive, the dissemination is faster than non-small-cell lung cancer)

**Etiology and pathogenesis:** unknown; genetic background + exogenous risk factors: smoking (1 pack of cigarettes/day increases risk 15 times, 2 packs of cigarettes/day increase risk 54 times), pollution, ionizing radiation, exposure to chromates, iron, arsenic, radioactive ores (uranium), chronic pulmonary processes (fibrosis, sclerosis etc. - “scar cancer”).

**Clinical picture:** it is 4-6 times more frequent in men, 55-65 years of age, urban environment.

**Symptoms:** initially asymptomatic, subsequently polymorphic manifestations

**Onset** is more frequently accompanied by pulmonary symptoms, or is a radiological discovery, and extrapulmonary manifestations or metastases are less common at onset.

Initially, only one *respiratory symptom* occurs, which is persistent:

- cough: 50% at onset, in the central form (irritation), dry, irritating
- chest pain: early (20%), peripheral form, initially localized, subsequently diffuse



- hemoptysis: unpredictable (several days)
- dyspnea: persistent, without cause, rare at onset

Subsequently, complex syndromes occur (“cancer masks”): bronchitis, bronchial obstruction, suppuration (abscess), pleurisy, compression etc. The mentioned pulmonary symptoms occur by local growth or regional invasion.

***Extrapulmonary symptoms***

- asthenia, weight loss, anemia, fever, sweating (malignant impregnation)
- paraneoplastic syndromes (“oat grain” cancer): endocrine, neuromuscular, connective tissue, dermatological
- symptoms due to metastases (lymphatic hematogenous dissemination)

***Signs: absent at onset***

- incomplete bronchial obstruction: sibilant rales + persistent wheezing in a limited area, complete obstruction: segmental/lobar atelectasis
- pleural syndrome: dullness, silence, hemorrhagic exudate ± malignant cells
- compression of the superior vena cava, sympathetic chain (Claude Bernard Horner), esophagus, diaphragm, larynx, brachial plexus + sympathetic chain (Pancoast-Tobias: enophthalmia, myosis, arm edema + brachial neuralgia)

**Complementary explorations:** chest X-ray, tomography, bronchoscopy + biopsy, examination of sputum, examination of pleural fluid, ganglia, ESR.

**Positive diagnosis:** is based on:

- persistent respiratory symptoms: cough, hemoptysis, dyspnea.
- pulmonary syndromes (bronchitis, pleural, suppurations, etc.) and extrapulmonary symptoms (compression, metabolic, etc.)
- general symptoms (of malignant impregnation)

- risk factors: smoking, toxic agents, pollution, chronic pulmonary lesions
- complementary explorations: radiography, bronchoscopy

**Differential diagnosis:** benign tumors, TB, chronic pneumonia, pulmonary fibrosis, chronic bronchitis, sarcoidosis, malignant granulomatosis, endocrine diseases etc., which all have a different evolution and risk factors are absent.

### ***3.2. PLEURAL EFFUSION SYNDROME***

Pleural effusion syndrome develops by accumulation in the pleural cavity of:

- *inflammatory exudate*: serous citrine, purulent, hemorrhagic etc.
- *transudate*: congestive heart failure, renal failure with anasarca, liver cirrhosis
- *blood*: hemothorax through trauma, hemorrhagic diathesis
- lung compression, atelectasis, maintenance of bronchial permeability, shift of the mediastinum towards the healthy side, downward movement of the diaphragm

**Functional and general symptoms:** they vary depending on etiopathogeny, on the size of fluid collection.

**Physical and radiological signs:** common, regardless of etiology

#### ***Inspection***

- ⇒ bulging of the affected hemithorax
- ⇒ extension of the intercostal space
- ⇒ limited or no movements of the hemithorax concerned + increased respiratory amplitude in the healthy hemithorax.

#### ***Palpation***

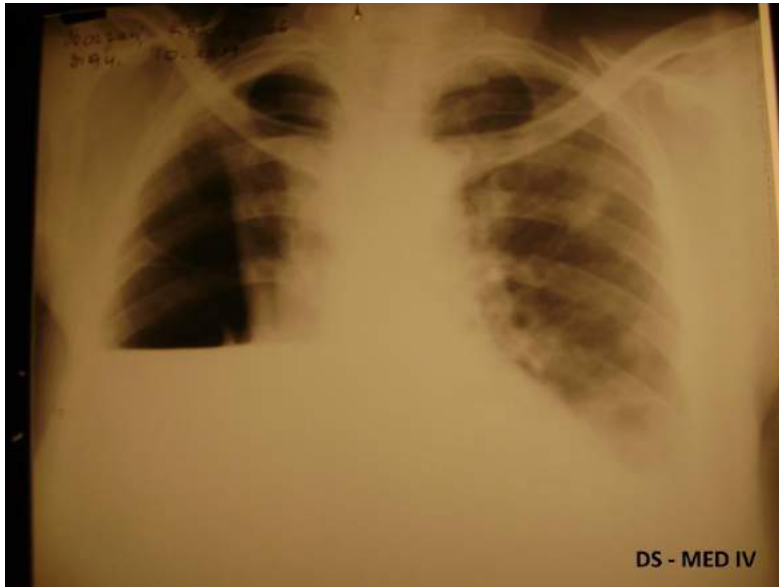
- ⇒ diminished or no pectoral fremitus (depending on the amount of fluid);
- ⇒ reduced chest elasticity

## ***Percussion***

- ***Dullness***
  - localized in the fluid
  - with the upper limit:
    - (1) in the form of Damoiseau's curve (if the fluid is in moderate amount)
    - (2) immobile, in case of exudate (due to adhesions)
    - (3) mobile/movable with the patient's posture: transudate (hemothorax)
- ***Subdullness/Hyperresonance/Skodaic resonance/Dullness*** --> above the fluid, depending on the amount of fluid + degree of atelectasis by compression;
- Movement of adjacent organs (heart, liver, mediastinum)
- Disappearance of Traube's space (stomach gas bubble) in left pleurisy

### ***Auscultation:***

- abolished/diminished vesicular murmur depending on the amount of fluid
- pleuritic sound above the fluid in moderate pleurisy
- more intense and coarse breathing of the opposite lung
- **Radiological examination:**
  - ⇒ quasitriangular shadow, of costal intensity, homogeneous at the base and limited at the upper part by Damoiseau's curve
  - ⇒ the mediastinum is displaced to the opposite side
  - ⇒ the diaphragm is lowered
- **Pleural puncture:**
  - ⇒ confirms the presence of fluid collection
  - ⇒ establishes:
    - the nature of the fluid: exudate/transudate
    - the aspect of the fluid  $\pm$  etiology



**Figure 89. Right pleural effusion**

### ***PLEURAL SYNDROME IN PLEURISY***

Pleural collections consist of the accumulation of fluid between the pleural layers.

- **Pathophysiology**

Pleural fluid is produced by the visceral and parietal pleura through systemic circulation, being absorbed by the lymphatics (90%); it is accumulated by:

- increase in hydrostatic pressure (heart failure)
- decrease in oncotic pressure (nephrotic syndrome), having the character of a transudate (hydrothorax)
- increase in vascular permeability (pneumonia, tumors) and lymphatic obstruction, when it has the character of an exudate (pleurisy)
- **The clinical picture** is dominated by the pleural syndrome, which consists of:

***Pleural pain:***

- ⇒ in acute inflammation: it occurs through the irritation of the parietal pleura (sensitive fibers), intermittently, as stabbing chest pain, amplified by inspiration, cough, chest movements and pressure, usually localized, unilateral (at the base), radiating to the shoulder, neck or abdomen, with the immobilization of the chest and rapid superficial breathing (dyspnea), accompanied by pleural rub (during inspiration and expiration ± transient, ± localized)
- ⇒ in malignant tumors: continuous dull pain

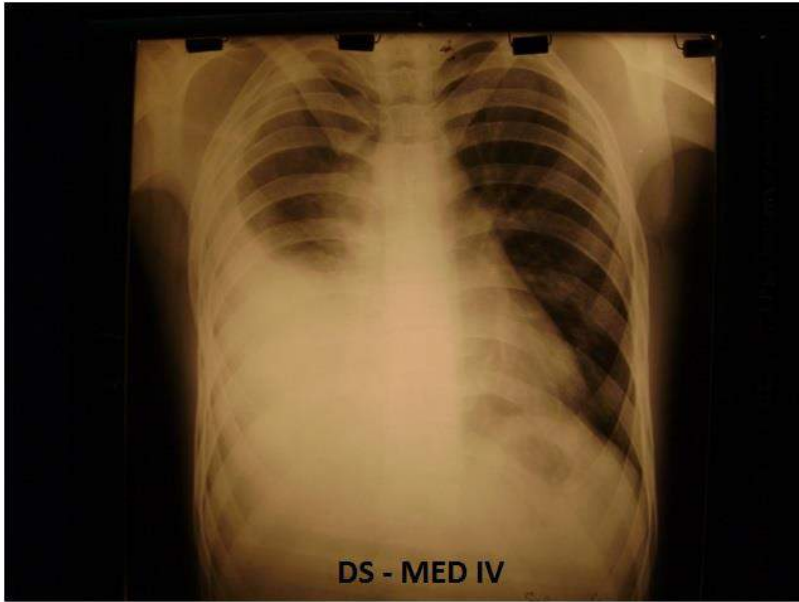
***Cough:*** dry, irritating

***Symptoms due to pleural collection:***

- ⇒ dyspnea directly proportional to the amount (it requires the evacuation of 300-500 ml for diminution)
- ⇒ decrease in the amplitude of breathing movements in large collections
- ⇒ shifting dullness, diminished fremitus, respiratory silence ± pleuritic sound

• **Complementary explorations**

- ⇒ Thoracocentesis differentiates the exudate from the transudate, provides diagnosis, etiology, evolution
- ⇒ Chest X-ray: detects 100-150 ml fluid in lateral decubitus, 250 ml in orthostatism by changing the costodiaphragmatic angle, increased gas bubble (in left pleural collections), rib companion shadow appearance
- ⇒ Pleural biopsy: required in the case of an exudate of unknown cause (TB, neoplasm), for small encysted pleurisy (under ultrasound guidance); it requires multiple samples



**Figure 90. Right pleural effusion**

### **3.2.1.1. Postpneumonic pleurisy**

**Classification:** with germs in the pleural fluid (empyema) or without germs in the pleural fluid.

**Etiology:**

- more frequently bacterial pneumonia (1/3 of the cases, pneumococcal or with gram negative bacteria)
- more rarely in viral/mycoplasma pneumonia.

**The clinical picture** consists of:

- fever, pleuritic pain and increased coughing
- on the objective examination: condensation syndrome and pleural syndrome

**Paraclinical explorations:**

- chest X-ray: it confirms pleurisy ± condensation
- pleural fluid: exudate, polymorphonuclears

**Diagnosis:**

- clinical context of bacterial pneumonia or bronchopneumonia
- exudate with polymorphonuclears ± germs

**3.2.1.2. Neoplastic pleurisy**

**Etiology:** bronchopulmonary cancer, breast cancer, lymphoma

**Pathophysiology:** local invasion (lymphatic obstruction, bronchial obstruction + pneumonia/atelectasis) ± secondary pulmonary embolism

**Clinical picture:**

- pleural syndrome + serohemorrhagic fluid, with rapid restoration and neoplastic cells
- clinical picture of primary cancer, usually at an advanced stage

**Explorations:** pleural fluid with malignant cells, hemorrhagic exudate

**Diagnosis:** primary tumor + malignant cell pleurisy

**3.2.1.3. Tuberculous pleurisy**

**Etiopathogeny:** by hematogenous, lymphatic dissemination, or contiguity of Koch's bacillus in the pleura as a hypersensitivity reaction

**Clinical picture:**

- it occurs more frequently at the age of 15-30 years (under 40 years); more frequently in men
- acute onset (50% of the cases) with: stabbing chest pain, fever, dry cough, dyspnea ± TB impregnation syndrome
- more rarely subacute, insidious or asymptomatic onset
- on the objective examination, pleural syndrome depending on the amount of fluid

**Complementary explorations:**

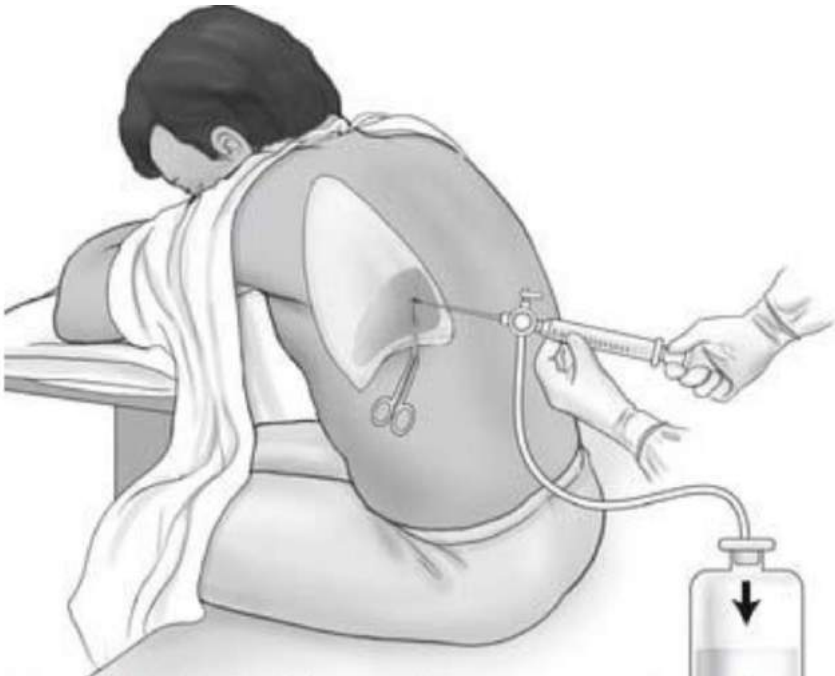
- chest X-ray: rib companion shadow depending on the amount of fluid

- positive IDR to tuberculin
- the QuantiFERON-TB test (more accurate than IDR)
- pleural puncture: serous citrine fluid, positive Rivalta test, significantly increased lymphocyte count

**Positive diagnosis:**

- presumptive diagnosis: age under 40 years, bacillary history, history of active TB or contact with the bacillus, serous citrine fluid with lymphocytes more than 80% and glucose less than 0.8 mg%, healing with sequelae, intensified IDR after 4-6 weeks of treatment
- certainty diagnosis: positive QuantiFERON-TB test, specific granuloma (histology), Koch's bacillus present in the fluid, sputum, biopsy or cultures

**Differential diagnosis:** neoplastic, bacterial, viral pleurisy, collagenases etc.



**Figure 91. The technique for pleural puncture**



### 3.3. BRONCHIAL SYNDROME

Bronchial syndrome occurs in bronchial asthma, COPD due either to reversible, incomplete acute obstruction, or irreversible chronic obstruction in the medium bronchi, bronchioles, followed by hyperinflammation, chronic respiratory failure, chronic cor pulmonale.

- **Symptoms:** they depend on the causative disease, e.g.: bronchial asthma (dyspnea) episodes/ acute COPD phenomena (expectoration).
- **Signs:** mostly common; those referring to bronchial obstruction, hyperinflation.

#### **Inspection, palpation:**

⇒ chest blocked during inspiration/emphysematous chest: emphysema, mixed COPD, bronchial asthma episodes.

#### **Percussion:**

⇒ hyperresonance: asthma, emphysema, mixed COPD; diminished cardiac dullness; lowered inferior limits of the lung, diminished active mobility

#### **Auscultation:**

- diminished vesicular murmur: asthma, emphysema, mixed COPD
- ± prolonged expiration = asthma, emphysema
- bronchial rales: asthma, chronic obstructive bronchitis ± mixed COPD
- (± bullous rales: asthma)
- **Ventilation tests (Spirometry):** FEV1; FEV1/FVC (Tiffeneau index): obstruction, hyperinflation
- Chest X-ray: emphysema, bronchiectasis.

### 3.3.1. BRONCHIAL SYNDROME IN ACUTE BRONCHITIS

Acute bronchitis is the inflammation (infection) of the bronchial mucosa ( $\pm$  tracheal mucosa - tracheobronchitis).

#### **Clinical picture:**

- *the usual form* is the most frequent; it occurs at any age, in epidemic disease in spring and autumn, having a viral etiology
- onset is rhinopharyngeal with coryza  $\pm$  tonsillitis (dysphagia)  $\pm$  laryngitis (dysphonia)

#### **Symptoms:**

- retrosternal pain (burn) and dry cough in tracheitis
- tracheobronchitis is accompanied by mucous, then mucopurulent expectoration, fever 38°C, shivering, myalgia
- AB evolves in three stages:
  - $\Rightarrow$  premonitory stage: oculonasal catarrh, hoarseness, general phenomena
  - $\Rightarrow$  dry stage: for 3-4 days dry painful cough, retrosternal pain
  - $\Rightarrow$  wet stage: mucous, then abundant purulent expectoration (suggestive of superinfection)

**Signs:** sonorous or whistling bronchial rales

**Chest X-ray:** normal; it excludes lung involvement

### 3.3.2. BRONCHIAL SYNDROME IN CHRONIC OBSTRUCTIVE PULMONARY DISEASE

Chronic obstructive pulmonary disease (COPD) is diffuse bronchiolar obstruction accompanied or determined by alterations of the lung parenchyma, resulting in lung hyperinflation and respiratory failure.

- **COPD** = chronic obstructive bronchitis + obstructive pulmonary emphysema
- **Chronic bronchitis** = cough + chronic expectoration, minimum 3 months/year, 2 years consecutively.

- **Chronic obstructive bronchitis** is accompanied by centrolobular pulmonary emphysema determining the appearance of type B COPD.
- **Obstructive pulmonary emphysema** can be panlobular/essential when it initially affects the periphery of the lobe, then the entire lobe, causing type A COPD.

### **Pathophysiology**

COPD through chronic obstructive bronchitis causes bronchial obstructive syndrome through:

- abundant viscous mucus
- superinfection (bacterial)
- decreased elimination of secretions
- stenosis, angulation of walls etc.
- parietal edema  $\pm$  bronchospasm, elements that increase the content of the bronchi and induce the alteration of the walls
- decrease in the alveolar surfactant, resulting in bronchiolar collapse during expiration

COPD through obstructive pulmonary emphysema causes the alteration of the elastic lung tissue through:

- the appearance of large air spaces (decreased alveolar exchange surface)
- the destruction of bronchiolar support elements accompanied by early collapse during expiration

The result in both cases is bronchiolar obstruction during expiration and air trapping in the alveoli with pulmonary hyperinflation, followed by hypoventilation and alveolar hypoxia (decrease in  $O_2$  and increase in  $CO_2$ ), then hypoxemia (low  $PaO_2$ )  $\pm$  hypercapnia (increased  $PaCO_2$ ) and consequently respiratory failure.

- In chronic obstructive bronchitis, alveolar hypoxia determines alveolocapillary reflex and vasoconstriction in the pulmonary artery branches, with pulmonary hypertension (early, reversible by

bronchial desobstruction) and in time, the appearance of chronic cor pulmonale.

- In obstructive pulmonary emphysema, the destruction of interalveolar septa (with pulmonary artery branches) produces irreversible organic pulmonary hypertension, with the appearance of chronic cor pulmonale.

### **Clinical picture**

#### ***Symptoms:***

- *chronic cough, chronic expectoration:* mucous, mucopurulent; it occurs in chronic bronchitis, in acute episodes, in the morning or at night, in variable amounts (more intense in acute episodes)
- *dyspnea:* it indicates pulmonary emphysema, it initially appears during exercise, then at rest,  $\pm$  at night, disappearing in the morning with the elimination of the sputum  $\pm$  in acute episodes + wheezing in the case of associated bronchial asthma or bronchial spasm

#### ***Signs:***

- subfebrility: inconsistent, in acute episodes
- cyanosis in severe respiratory failure
- emphysematous chest (globular, barrel chest, increased anteroposterior diameter, enlarged costal spaces, horizontalized ribs, bulging fossae, hyperresonance, diminished vesicular murmur and prolonged expiration) in the case of pulmonary emphysema
- normal chest + bronchial rales  $\pm$  subcrepitant rales in acute chronic bronchitis

#### **Complementary explorations:**

- ventilation tests:
  - $FEV1/FVC \times 100$  (Tiffeneau index)  $< 70\%$  = bronchial obstruction in COPD
  - $RV/TLC > 25\%$  = hyperinflation in obstructive pulmonary emphysema = decreased pulmonary diffusion
- low  $PaO_2$ , high  $PaCO_2$  = chronic respiratory failure

- increased pH, AR = alkalosis
- the examination of the sputum shows ordinary flora (saprophytic)
- chest X-ray: pulmonary hypertransparency = obstructive pulmonary emphysema
  - ± thickened bronchial walls = chronic obstructive bronchitis

**Positive diagnosis:** is based on:

- bronchial obstructive syndrome: prolonged expiration ± bronchial rales + chronic coughers ± chronic dyspnea
- confirmed particularly by FEV1/FVC, RV/TLC

**Diagnosis of the COPD type:** initially, chronic obstructive bronchitis or obstructive pulmonary emphysema is predominant; subsequently, they become intermixed.

- **Type A COPD through panlobular or essential obstructive pulmonary emphysema**

- elderly (55-70 years), non-smokers
- pink-puffer (pink wheezing appearance) = dyspnea (respiratory failure) with compensatory hyperventilation
- without cough, preliminary expectoration ± dyspnea (puffing) during exercise
- poor nutritional status (asthenic constitution)
- emphysematous chest, mantle hypertransparency (chest X-ray)
- mild hypoxemia, inconsistent hypercapnia, rare polyglobulia
- long evolution, pulmonary hypertension and rare but irreversible, late chronic cor pulmonale

- **Type B COPD through chronic obstructive bronchitis ± centrolobular emphysema**

- mean age (50 years), smokers, exposed to pollutants
- blue-bloater = cyanosis (respiratory failure), facial edema (chronic cor pulmonale), polyglobulia (purple red)
- chronic expectoration for tens of years, seasonal acute episodes (in winter) from infections, smoking

- worsening of expectoration, subfebrility, respiratory failure, cor pulmonale, with remissions
- good nutritional status (obese), constant cyanosis, variable dyspnea (in acute episodes)
- normal chest, thickened bronchial walls in acute episodes
- important chronic hypoxia, frequent hypercapnia, frequent secondary polyglobulia
- rapid evolution towards partially reversible functional pulmonary hypertension and cor pulmonale

### **3.3.3. BRONCHIAL SYNDROME IN BRONCHIAL ASTHMA**

Bronchial asthma (BA) is a syndrome characterized by paroxysmal expiratory dyspnea episodes, the consequence of the reversible diffuse obstruction of the bronchiolar tree, having spasm, edema and bronchiolar hypersecretion as a substrate. BA is associated with an exaggerated bronchoconstrictor response to stimuli (bronchial hyperreactivity), being currently considered of inflammatory nature, including several distinct conditions.

#### **Classification:**

- allergic (extrinsic): due to allergens inhaled, per os, infections
- infectious (intrinsic): due to infection (usually bronchial)
- mixed (most frequently)

#### **Triggering factors:**

- allergens: inhaled (pollen, feathers, house dust, etc.); ingested (food, drugs: aspirin, penicillin, etc.)
- infections
- irritating substances, physical exercise, emotions, etc.

#### **Age and sex:**

- it occurs at any age: 1/3 up to 10 years of age; 75% under 40 years of age
- more frequent in women after puberty

## **Etiology:**

- heredity: more frequent in certain families (the predisposition to asthma is given by bronchial hyperreactivity)
- allergy: more frequently type I and III:
  - type I (immediate, anaphylactoid, reaginic) occurs through IgE by the following mechanism: the antigen (pollen, house dust) combines with IgE in the mast cell, determining the release of mediators (histamine, serotonin, etc.), which causes bronchospasm, hypersecretion and edema followed by bronchiolar obstruction (asthma episode)
  - type III (semi-delayed), at 4-7 hours
- the vegetative nervous system: acetylcholine induces bronchoconstriction and adrenaline, bronchodilation (beta-adrenergic receptor) or bronchoconstriction (alpha-adrenergic receptor); the theory of the beta-adrenergic blockade considers that there is a reduced response of beta-adrenergic receptors and an augmented response of alpha-adrenergic receptors, and consequently, on the background of bronchial hyperreactivity, bronchial spasm occurs
- bronchial infection: it has a direct (allergic) or indirect action (irritation, decreased bronchial sensitivity, increase in antibodies, etc.)
- mental factors: emotions; neurosis is frequently associated, secondary to chronic disease
- endocrine disorders (thyroid, ovaries, etc.); local lesions (rhinosinusal, bronchopulmonary), favor or aggravate the disease

## **Clinical picture**

- asthma episodes can be preceded (for years) by: allergic rhinitis, rash, etc.
- onset is preceded by: nasal pruritus, rhinorrhea, sneezing, etc.

- classic clinical forms: BA with fits, BA with continuous dyspnea, asthmatic state

**Symptoms:** dyspnea, cough, wheezing.

- *a typical asthma (dyspnea) episode* consists of:
  - nocturnal occurrence, sudden onset, duration longer than 2-3 hours, return to normal
  - it wakes up the patient, with anxiety, suffocation, orthopnea
  - with expiratory bradypnea (short inspiration, prolonged whistling expiration - wheezing) (spasmodic- dyspneic phase)
  - the objective examination shows: distended chest, horizontalized ribs, cyanosis, diminished murmur, prolonged expiration, bronchial rales (variable, from sonorous to whistling and subcrepitant rales, producing the “pigeon house sound”)
- *cough:*
  - precedes, accompanies or ends the episode
  - initially dry, then wet with a low amount of mucous, jelly-like expectoration (“pearly sputum”) (catarrhal expectoration phase)
- other clinical manifestation forms:
  - ***asthmatic attack*** (subintract episodes): repeated episodes over 24 hours, with mild dyspnea between the episodes and prolonged expiration, sibilant rales; reversible under treatment
  - ***bronchial asthma with continuous dyspnea*** (permanent, “subasthmatic state”): in elderly, continuous dyspnea with fits, bronchodilator resistance, chronic respiratory failure, RVF, “wet asthma”
  - ***asthmatic state*** (asthma sickness):
    - it has 3 main syndromes (respiratory, circulatory, neuropsychic): intense permanent dyspnea, hours-days, ineffective fatiguing cough, cyanosis, tachypnea, tachycardia, increased diastolic BP, cold sweating, no relief periods, uninfluenced by usual therapy, severe prognosis, with continuous acute respiratory failure; the objective



examination shows: cyanosis of extremities with facial pallor, sweating, chest blocked during inspiration, ineffective expiration, absent expectoration, disappearance of wheezing, obstructive syndrome of terminal bronchioles, tachycardia, stupor, coma, exitus;

- causes: drugs that inhibit the cough reflex (opioids, sympathomimetics, barbiturics – “addictive asthma”, infection, mental factors, dehydration, allergizing drugs: penicillin, ACTH, etc., excess of desensitizers)

### **Laboratory examinations**

- chest X-ray: hypertransparency of lung fields, horizontalized ribs, lowered diaphragm (during crises)
- *ventilation tests*:
  - low FEV1; diagnostic, prognostic and therapeutic importance
  - FEV1/FVC decrease: mild (> 55%), moderate (40-55%), severe (< 40%)
  - the pharmacodynamic test with: bronchodilator substances (Alupent) makes differential diagnosis with COPD when FEV1 increases by more than 15% non-specific, specific bronchoconstrictor substances (allergens) or acetylcholine (FEV1 decreases by more than 15-20%)
  - respiratory gases: low PaO<sub>2</sub>; high PaCO<sub>2</sub> in the asthmatic state
  - acid-base balance: respiratory acidosis in the asthmatic state
- cutaneous tests: they detect the causative antigen: they have an orienting value in clinical context; allergen extracts are injected in the skin and after 10-20 minutes, an erythema or papule appears
- eosinophilia: blood, sputum, nasal secretion in allergic subjects
- bacteriological examination of the sputum and antibiogram: required for the treatment of infection

### **Positive diagnosis:**

- syndrome (during BA episodes and between episodes)

- etiological (intrinsic BA or extrinsic BA)

### 3.4. CAVITARY SYNDROME

Cavitary syndrome occurs when there are cavities in the lung parenchyma, in pneumothorax open into the bronchi.

#### 3.4.1. CAVITARY SYNDROME THROUGH LUNG CAVITIES

- Cavities occur in the following situations: condensed parenchyma (inflammatory or tumor infiltrates), pulmonary (intercleido-hilar) TB, lung abscess, pulmonary gangrene, evacuated hydatid cyst, bronchiectasis (usually basal), soft cancer
- The syndrome occurs when: cavities (e.g. caverns) are large (>4 cm), superficial, surrounded by condensed parenchyma, with a permeable drainage bronchus, they are not filled with fluid

**Functional and general symptoms:** various depending on the etiology of the cavern

Physical and radiological symptoms: common

**Inspection:** normal; extremely rarely the bulging of the apex of the lung (cavern at the apex)

**Palpation:** augmented pectoral fremitus

**Percussion:** tympanism (metallic resonance)

**Auscultation:** cavernous murmur, or amphoric murmur + cavernous rales and dry rales (due to added bronchitis)

**Radiological examination:** round transparency (oval transparency  $\pm$  fluid content)  $\pm$  condensations

#### 3.4.2. CAVITARY SYNDROME IN PNEUMOTHORAX OPEN INTO A BRONCHUS

**Inspection:** the affected chest can be dilated + enlarged intercostal spaces; very reduced/ no breathing movements

**Palpation:** augmented pectoral fremitus

**Percussion:** tympanicity or metallic resonance

**Auscultation:** amphoric murmur.

### 3.4.3. BRONCHOPULMONARY SUPPURATIONS

Bronchopulmonary suppurations (BPS) are purulent inflammations of the lung parenchyma and/or bronchi manifesting by purulent bronchorrhea.

**Classification:**

- *primitive BPS:* they occur in a normal lung; they are not circumscribed: bronchogenic lung abscess (produced by bronchial aspiration) and hematogenous lung abscess (in sepsis) and diffuse suppurations: pulmonary gangrene (necrosing pneumonia)
- *secondary BPS:* when they develop in preexisting pulmonary lesions (cancer, TB, cysts etc.)

### 3.4.4. CAVITARY SYNDROME IN LUNG ABSCESS

Lung abscess is an acute suppurative non-tuberculous inflammation of the lung parenchyma, occurring in a newly formed cavity.

**Clinical picture:**

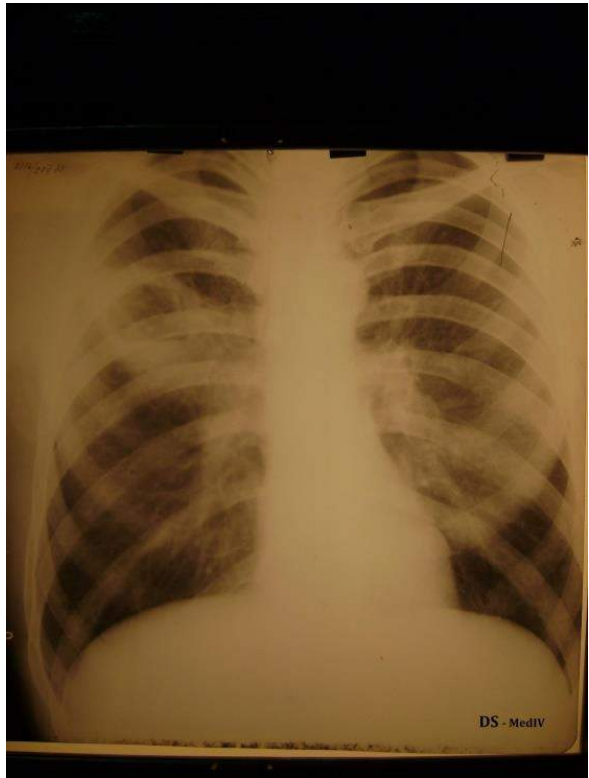- acute pneumonic onset in infections with aerobes (staphylococcus, streptococcus, Haemophilus, Klebsiella)
- insidious onset with general phenomena and reduced symptoms more frequently in abscesses with anaerobes
- 3 clinical stages:
  - *formation, "closed focus":* a 5-7 day evolution, with the clinical appearance of acute pneumonia (fever, shivering, stabbing pain, dry cough ± condensation syndrome), but fever, the stabbing pain persist, the general state is altered (sweating, pallor, weight loss) under antibiotherapy
  - *vomica* appears after 5-15 days: the massive elimination in one or more fractions of a large amount of purulent sputum ±

hemoptoic ± fetid sputum (anaerobes) in a coughing episode ± suffocation; ± preceded by hemoptoic sputum or hemoptysis and followed by the improvement of the general state and of fever

- *open suppuration*: purulent bronchorrhea (100-300 ml/day), fluctuating or irregular fever, sweating, pallor, weight loss (proportional to the state of toxemia and insufficient bronchial drainage); on the objective examination subdullness, wet rales ± cavitary syndrome (rarely): tympanicity + cavernous or amphoric murmur; possibly pleural empyema

**Complementary examinations:**

- chest X-ray: in stage I, round, homogeneous pneumonic opacity; in stage III, hydroaeric image (opacity with a bright central aerial area and a 3-5 cm horizontal fluid level with a long longitudinal axis), more frequently in the right lung, the lower lobe
- biological tests: significantly accelerated ESR >100 at 1 hour, leukocytosis >20,000 with neutrophils >80 %, sometimes with toxic granulations.



**Figure 92. Chest X-ray in a patient with pulmonary abscess**

- examination of the sputum (smear, cultures): polymorphic saprophytic flora, negative culture for *Bacillus Koch*; altered and destroyed leukocytes, elastic fibers
- bronchoscopy: diagnostic, pathogenic and sometimes therapeutic role
- hemoculture: for the diagnosis of sepsis
- other examinations: they evidence the favoring factors: diabetes, renal or hepatic failure

**Positive diagnosis:**

- clinical: infectious syndrome + respiratory symptoms and signs + purulent bronchorrhea
- radiological: hydroaeric image

**Differential diagnosis:**

- with secondary suppurations: bronchopulmonary cancer (bronchoscopy, chest X-ray), cavitory pulmonary TB (KB, X-ray)
- in the second stage with: acute bacterial pneumonia at onset, atelectasis, metastatic suppuration (sepsis infarction; sudden onset, with shivering and fever in a carrier of an infection with metastatic potential: septic thrombophlebitis, tonsillar foci etc.).

### 3.4.5. BRONCHIECTASIS

It represents the increase in the caliber and the deformation of the bronchi, accompanied or not by bronchial inflammation and chronic purulent bronchorrhea.

**Clinical picture:**

- bronchiectasis is asymptomatic for a long time
- onset is insidious, rarely acute and very rarely with hemoptysis
- characteristic symptoms and signs:
  - expectoration: dominant, abundant (bronchorrhea: 50-500 ml/day), stratified (3 or 4 layers: purulent, mucopurulent,

mucous, foamy), unpleasant or fetid odor, with continuous or intermittent elimination (in the morning – bronchial toilet);

- cough: in the morning or when rising from bed due to the mobilization of secretions towards the tussigenic areas, mild or fatiguing ± persistent, diurnal
- fever from retained expectoration or peribronchiectatic condensation, stabbing chest pain, hemoptysis, dyspnea (rarely)
- sonorous, whistling, subcrepitant rales, superior to bronchiectasis
- pulmonary condensation syndrome by peribronchiectatic condensation; pachypleuritis, cavitory syndrome, digital hippocratism (long duration cases)

**Complementary examinations:**

- leukocytosis with polynucleosis in case of infection
- examination of the sputum (smear, cultures):
  - polymorphic flora – aerobic or anaerobic, saprophytic or pathogenic, sometimes 2 or 3 associated germs, negative KB;
  - cautious interpretation is required
- radiological examination: thickened bronchovascular walls with reticulated appearance and false cystic images
- bronchoscopy:
  - diagnostic role (bronchography with a contrast substance shows the location, extension and anatomical type of dilations)
  - therapeutic role (collection of secretion for cultures)
- ventilation tests: restrictive or mixed obstructive syndrome, depending on the extension of lesions
- other examinations: they evidence the associated congenital diseases or abnormalities: diabetes, renal or hepatic failure

### 3.5. MEDIASTINAL SYNDROME

Mediastinal syndrome occurs in expansive / compressive mediastinal processes, goiter, adenopathies (TB, lymphomas), mediastinal tumors, aortic aneurysms, esophageal cancer.

- **Symptoms, signs of the affected organ**
- **Symptoms, signs of compression of the adjacent organs:**
  - ⇒ dyspnea, retraction, dry cough through tracheal/bronchial compression
  - ⇒ dry cough, dysphonia, bitonal voice through recurrent nerve compression
  - ⇒ supraclavicular pain, hiccup, paradoxical breathing through phrenic nerve compression
  - ⇒ collateral circulation, cyanosis, mantle edema, through vena cava and azygos vein compression
  - ⇒ lymphatic edema, chylous collection in the pleura, peritoneum through thoracic canal compression
  - ⇒ dysphagia, regurgitation through esophageal compression
  - ⇒ Claude-Bernhard-Horner syndrome through cervical sympathetic ganglion injury
- **Objective examination:** goiter, aortic aneurysm (murmur, fremitus)





# CHAPTER 4. THE CARDIOVASCULAR SYSTEM

## 4.1. ANAMNESIS

Most chronic cardiac diseases are initially asymptomatic and this silent phase may last for many years. Cardiac pathology may be diagnosed during ‘routine’ examination or because of the development of a complication, e.g. (atrial fibrillation in mitral stenosis). In patients with cardiovascular disorders, anamnesis can provide important information. In certain situations, data regarding sex, age, family and personal history, living and working conditions, and the history of the disease can orient diagnosis from the very beginning. Furthermore, there are few signs to be discovered at physical examination.

- **Gender**

- ⇒ Diseases that are more frequently found in *men* include: ischemic heart disease (angina pectoris, acute myocardial infarction), chronic cor pulmonale (4x), alcoholic heart disease, aortic valve disease (lentic aortic insufficiency), obliterating thromboangiitis, nodular panarteritis
- ⇒ Disorders that are more frequently found in *women* include: mitral stenosis, congenital heart disease, mitral valve prolapse, cardiothyreosis, collagenosis, Raynaud’s disease, pulmonary hypertension
- ⇒ Sex can also determine a particular evolution of the disease, for example arterial hypertension in women is better tolerated; (atherosclerotic) ischemic heart disease is less common before menopause in the absence of risk factors: hypertension, diabetes mellitus, smoking etc.

- **Age**

⇒ In newborns and young *children*, congenital heart disease is more frequently found; in older children and adolescents, rheumatic heart disease (rheumatic carditis with its sequelae – valve diseases), and in people aged *over 50 years*: ischemic heart disease, arterial hypertension, chronic cor pulmonale, and cardiomyopathy.

⇒ In time, the majority of heart diseases lead to heart failure.

⇒ Depending on age, the evolution of some diseases can be different: e.g. arterial hypertension, acute myocardial infarction have a more severe evolution in young people.

- **Family history**

⇒ There is a “*morbid predisposition*” to arterial hypertension, atherosclerosis, primary heart disease, rheumatic carditis.

⇒ Genetic factors are involved in diseases such as mitral stenosis, dysmetabolic heart disease.

### **Genetically determined cardiovascular disorders**

**Single-gene defects:** hypertrophic cardiomyopathy, Marfan’s syndrome, familial hypercholesterolemia, muscular dystrophies, long Q-T syndrome

**Polygenic inheritance:** ischemic heart disease, hypertension, type 2 diabetes mellitus, hyperlipidemia

The genetic factor should be considered in the context of the other factors, depending on which the evolution of the disease can be prevented or changed. Ask if there is a family history of either premature coronary heart disease in a first-degree relative (<55 years in a female or <50 years in a male) or sudden unexplained death at a young age, raising the possibility of a cardiomyopathy or inherited tendency to arrhythmia.

- **Personal history**

⇒ **Physiological history** – the menstrual cycle, pregnancy, and delivery can determine cardiac decompensation ± acute pulmonary edema (e.g.: mitral stenosis, arterial hypertension, ischemic heart disease in the period of premenstrual hyperfolliculinism).

⇒ **Menopause** can aggravate arterial hypertension and cardiomyopathies.

⇒ **Personal history of diseases** – infections can determine the appearance of cardiomyopathies or can aggravate their evolution.

- Any acute viral or bacterial infectious disease can evolve towards myocarditis or endocarditis. The infection with *group A hemolytic β streptococcus* (pharyngitis, tracheobronchitis, scarlet fever) may be complicated by acute articular rheumatism, with the risk of rheumatismal carditis, which frequently heals with sequelae, resulting in rheumatismal valve disease. *Bacteremia* induced by bleeding procedures (e.g. tooth extraction, curettage, instrumental explorations) may complicate valve disease by infective endocarditis. *Lues* can result in aortitis, aortic insufficiency, it affects the His bundle or the arteries, and tuberculosis can be complicated by constrictive pericarditis.
- Among respiratory diseases, *chronic bronchitis*, pulmonary emphysema evolves towards chronic cor pulmonale through pulmonary hypertension and right heart failure. Bronchiectasis, bronchial asthma, pulmonary tuberculosis, chest deformations also aggravate heart diseases.
- Acute or chronic diffuse *glomerulonephritis*, chronic pyelonephritis evolve with secondary arterial hypertension that can decompensate the left heart, determining acute or chronic left ventricular failure.

- *Hyperthyroidism* causes tachycardia, arrhythmia (atrial fibrillation, paroxysmal tachycardia), cardiothyreosis, heart failure; on the other hand, hypothyroidism develops into myxedematous heart disease, hydropericardium. The clinical picture of *pheochromocytoma* includes paroxysmal arterial hypertension and in the case of *Cushing syndrome*, arterial hypertension is omnipresent. *Diabetes mellitus* can be complicated by both microangiopathy, which causes retinopathy, nephropathy and neuropathy, and macroangiopathy responsible for atherosclerosis, acute myocardial infarction (4 times more frequent, earlier onset, more severe evolution). *Obesity* is also complicated by atherosclerosis, heart failure, Pickwick syndrome. Hemochromatosis evolves towards cardiomyopathy and heart failure by iron deposition, diabetes mellitus, cirrhosis, etc.
- Heart disease may be secondary to cytostatic drugs, radiotherapy.
- *Anemia* aggravates heart failure, increasing cardiac output, and polycythemia induces angina pectoris, acute myocardial infarction through hyperviscosity.
- **Living and working conditions.**
  - ⇒ Cold, humidity, intrafamilial contagion lead to streptococcal infections, acute articular rheumatism, rheumatismal carditis.
  - ⇒ *Stress* in persons of behavioral type A favors acute myocardial infarction. Miners can develop silicosis, chronic cor pulmonale.
  - ⇒ *Smoking* is a risk factor for atherosclerosis, arterial hypertension, it determines an unfavorable evolution of coronary disease, cardiac decompensation, the appearance and persistence of cardiac rhythm disorders.

- ⇒ *Alcohol* induces dyslipidemia and secondary atherosclerosis, alcoholic cardiomyopathy, being a direct toxic agent for the myocardium. Drinking to excess is associated with atrial fibrillation, hypertension and, occasionally, dilated cardiomyopathy
- ⇒ *Caffeine* consumption can cause palpitation, and some recreational drugs are associated with cardiac symptoms (e.g. cocaine and chest pain)
- ⇒ *Drugs* may be responsible for, or may aggravate, symptoms such as breathlessness, chest pain, edema, palpitation or syncope

### **Symptoms related to medication**

***Dyspnea:*** beta-blockers in patients with asthma, exacerbation on heart failure by beta-blockers, some calcium channels antagonists, non-steroidal anti-inflammatory drugs

***Dizziness:*** vasodilators, e. g. nitrates, alpha-blockers and angiotensin-converting enzyme inhibitors

***Angina:*** aggravated by thyroxine or drug-induced anemia, e.g. aspirin or non-steroidal anti-inflammatory drugs

***Edema:*** fluid retention from steroids, nonsteroidal anti-inflammatory drugs, calcium channel antagonists (e.g. nifedipine, amlodipine)

***Palpitation:*** tachycardia and/or arrhythmia from thyroxine, beta-2 stimulants (e.g. salbutamol), digoxin toxicity, hypokalemia from diuretics, tricyclic antidepressant drugs

- ⇒ *Coronary risk factors* include: overeating, the genetic factor, hyperlipoproteinemia, stress, arterial hypertension, diabetes mellitus, obesity, sedentary behavior.

### **Occupational aspects of cardiovascular diseases**

*Occupational exposure associated with cardiovascular disease:*

*Organic solvents:* arrhythmias, cardiomyopathy

*Vibrating machine tools:* Raynaud's phenomenon

*Publicans:* alcoholic cardiomyopathy

Cardiac disease may impair patient's physical activity and affect their employment or have medicolegal consequences in certain occupations (e.g. commercial drivers, pilots)

- **History of heart disease**

⇒ **The onset** of heart disease can be sudden, like in acute myocardial infarction, acute articular rheumatism, insidious: in the majority of the disorders, or accidental. Onset can be accelerated by certain situations: stress, physical exercise (in acute myocardial infarction, left heart failure, etc.).

⇒ **The evolution** of heart disease is most frequently chronic, with dyspnea, precordial pain, edemas, etc., continuous or paroxysmal (e.g. angina pectoris, arterial hypertension, arrhythmias, syncope, collapse etc.). The therapeutic effect, the presence of risk factors are also important.

## 4.2. CARDIAC SYMPTOMS

### 4.2.1. CARDIAC DYSPNEA

The sensation of breathlessness (dyspnea) on effort may be normal. It becomes a symptom of disease if it occurs at exercise levels below those expected for the patient's age and degree of previous fitness. Patients may complain of associated fatigue, but symptoms of tiredness or lack of energy are rarely cardiac in origin.

Cardiac dyspnea is of several types: exertional dyspnea, permanent "rest" dyspnea with orthopnea, nocturnal paroxysmal dyspnea, and periodic Cheyne-Stockes dyspnea.

⇒ **Exertional dyspnea** is the first sign of left heart failure. It is *inspiratory dyspnea*, generated by pulmonary stasis in left ventricular failure, mitral stenosis, and pulmonary hypertension. At the time of the appearance of right heart failure, a false improvement occurs, peripheral stasis partially replacing

pulmonary stasis. It has a *progressive character*, initially occurring during intense exercise, subsequently during less and less intense exercise, sometimes in the evening. It is accompanied by tachypnea, hypopnea (decreased amplitude of breathing movements). Differential diagnosis should be made with asthenia (gasp for air), dyspnea in untrained healthy subjects.

- ⇒ **Permanent “rest” dyspnea** with orthopnea is due to pulmonary venous stasis in left ventricular failure, mitral stenosis. It occurs in more severe heart disease with more advanced heart failure (low cardiac output at rest). The patient adopts a sitting or a half-sitting position, with interrupted speech, inspiratory or mixed polypnea with tachypnea and hypopnea.
- ⇒ **(Nocturnal) paroxysmal dyspnea**, the acute form of left heart failure, is found in mitral stenosis, arterial hypertension, acute myocardial infarction, aortic valve disease, paroxysmal arrhythmia/ventricular tachycardia, atrial fibrillation, atrial flutter. Physical exercise, excessive salt consumption, labor, etc. are considered triggering factors. Paroxysmal dyspnea has two forms:
  - *cardiac asthma* (anxiety tachypnea): it occurs due to blood redistribution with nocturnal pulmonary stasis, improved by orthopnea; sometimes bronchospasm ± wheezing occurs, through interstitial infiltration with bronchial compression; it is intense dyspnea that wakes the patient from his sleep, it is accompanied by extreme anxiety, orthopnea ± cough ± sweating
  - *acute pulmonary edema*, the extreme form, which occurs due to the blood transudate that invades the alveoli and airways, evolves with asphyxia, aerated serosanguinolent expectoration. Hemoptoic cough after exertion (in mitral

stenosis) and nocturnal sweating are considered equivalences of acute pulmonary edema.

⇒ **Periodic Cheyne–Stokes dyspnea** occurs in left ventricular failure, sometimes apnea is absent, only tachypnea periods alternating with bradypnea periods are present.

#### 4.2.2. PALPITATIONS

Palpitations (*“palpitare”*- to pulse, to beat) are defined as the unpleasant sensation of the activity of the heart: pulsation, “impact”, emptiness etc. They are due to increased contraction force, increased frequency, increased excitability of the nervous system. Palpitations occur in healthy subjects after exercise, emotions, smoking, alcohol, excessive coffee consumption; in the majority of heart diseases; in paroxysmal arrhythmias (extrasystoles, paroxysmal tachycardia, atrial fibrillation, atrial flutter); or they may have extracardiac causes: neurosis, hyperthyroidism, anemia, fever etc.

#### 4.2.3. CARDIOVASCULAR PAIN

Cardiac pain is most frequently of coronary cause, but it can also be due to pericarditis (through the inflammation of the diaphragmatic parietal or anterior pericardium), aortitis, aortic media dissection etc.

##### Types of cardiac pain

Type	Cause	Characteristics
<b>Angina</b>	<i>Coronary stenosis</i>	<i>Precipitated by exertion, eased by rest/nitroglycerine, characteristic distribution</i>
<b>Myocardial infarction</b>	<i>Coronary occlusion</i>	Similar sites to angina, more severe, persists at rest
<b>Pericardic pain</b>	<i>Pericarditis</i>	<i>Sharp, raw or stabbing, varies with movement or breathing</i>



<b>Aortic pain</b>	<i>Dissection of aorta</i>	<i>Severe, sudden onset, radiates to the back</i>
--------------------	----------------------------	---

- ⇒ **Coronary (originating) chest pain** is mostly due to coronary atherosclerosis and/or thrombosis (95%), but also to spasm, congenital, inflammatory lesions (coronaritis in acute articular rheumatism), embolism, arrhythmia, anemia and hypoxia. All these can lead to the partial obstruction of the coronaries and the loss of coronary dilation capacity during exercise, or to total coronary obstruction followed by necrosis, local acidosis, the release of toxic metabolites that stimulate vascular pain receptors. Ischemia can be painless when it lasts for a short time (seconds) or is under the ischemic threshold. Pain is transmitted through the sympathetic nervous system → C7-T5.
- ⇒ *Coronary pain due to ischemia* has a deep, diffuse retrosternal location, indicated with the palm of the hand, it radiates to the upper limbs (left cubitus), to the shoulders, other areas: cervical, scapular, epigastric; always supraumbilical and identical; rarely, it does not radiate or converge reversely. It is constrictive (squeeze, claw) or compressive (pressure, weight), the sensation of immediate death can be present. It lasts for minutes – up to 20 minutes in *angina pectoris*, hours – up to 30 hours (6-8 hours) in *myocardial infarction*. Intensity is great in *angina pectoris*, it increases with the strain of the heart and decreases/disappears with nitroglycerine administration; it is extreme in acute myocardial infarction, it increases and is maintained, it decreases with opioid administration. Exercise, emotions, cold are triggering factors; pain does not disappear at rest in acute myocardial infarction. It is accompanied by dyspnea, anxiety in *angina pectoris* and sweating, nausea, pallor in acute myocardial infarction. In unstable *angina pectoris*, pain appears during

minimal exertion, at rest (nocturnal), in variant angina (Prinzmetal) it only appears at rest.

**Differential diagnostic: angina vs myocardial infarction**

<b>Description</b>	<b>Angina</b>	<b>Myocardial infarction</b>
<i>Site</i>	retrosternal, radiate to arms, epigastrium, neck	retrosternal, radiate to arms, epigastrium, neck
<i>Precipitated</i>	by exercise or emotion	often no obvious precipitant, at rest
<i>Relieved</i>	by rest, nitrates	Not relieved by rest, nitrates
<b>Severity</b>	mild, moderate severity	Usually severe (may be 'silent')
<b>Anxiety</b>	absent or mild	Severe
<b>Sympathetic activity</b>	No increased sympathetic activity	Increased sympathetic activity
<b>Nausea, vomiting</b>	No	Nausea and vomiting are common

- ⇒ Chest pain in *ascending aortic dissection* is located in the anterior chest, it radiates to the shoulders, then to the interscapulovertebral area towards the loins, it is atrocious, constant, it lasts for hours to days
- ⇒ Chest pain in *pericarditis* is located in the anterior chest, it is dull, moderate, continuous, increased by pressure, breathing and the movements of the trunk.

## 4.3. PHYSICAL EXAMINATION

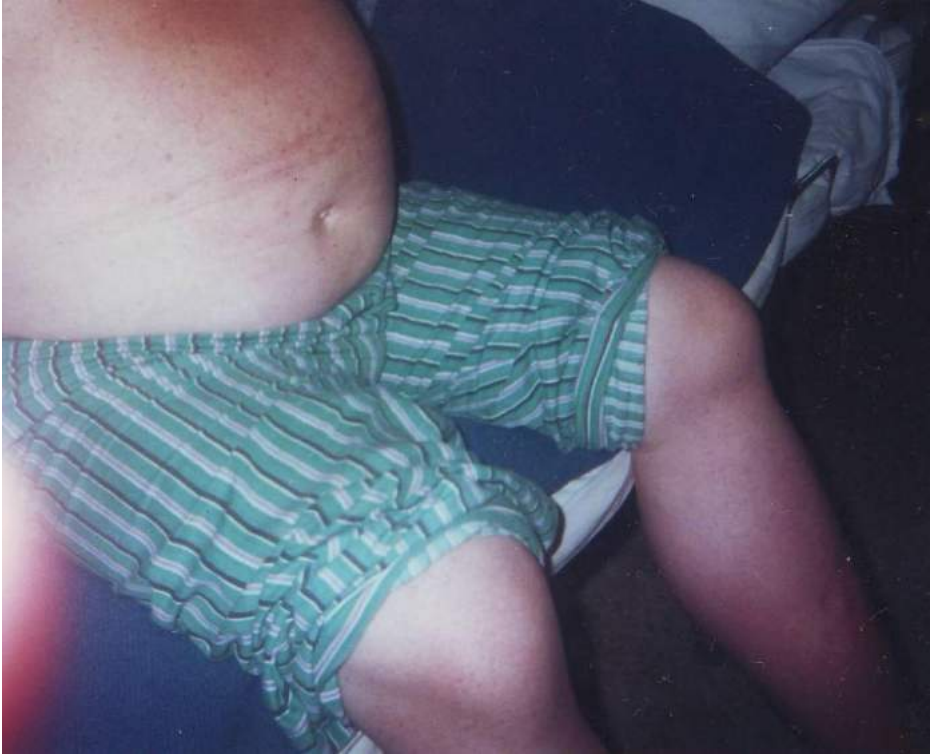### 4.3.1. GENERAL PHYSICAL EXAMINATION

- **Mental state**

⇒ *Syncope*, which is the consequence of a decrease in cardiac output and cerebral blood supply, has several causes:

- postural in cardiac myxoma;
  - exertional in aortic stenosis, pulmonary stenosis, pulmonary hypertension, hypertrophic obstructive cardiomyopathy in young people, hypertrophic cardiomyopathy in the elderly (due to a decrease in cardiac output and peripheral vasodilation);
  - paroxysmal tachycardia through the shortening of the diastole when heart rate is  $>150-180/\text{min.}$ ;
  - bradycardia  $<30-35/\text{min.}$  in sinoatrial block, complete atrioventricular block, Adam Stokes syncope.
- **Constitutional type.** Atherosclerosis is more frequent in individuals with the endomorphic type. Mitral valve disease at young age can predispose to dwarfism.
  - **Nutritional state.** Cachexia may occur in chronic heart failure; also, gaining weight is another characteristic of congestive heart failure, due to edema; the edema can become generalized.
  - **Posture.** In angina pectoris, patients remain immobilized (“*window shopping*”), unlike patients with acute myocardial infarction who are agitated, restless, “cannot find their place”. The leaning forward position, “*the prayer position*”, is an antalgic and antidyspneic position adopted by patients with dry pericarditis or effusive pericarditis. The most *bizarre positions* are found in patients with aortic dissection. *Orthopnea* is typical in acute left ventricular failure or advanced chronic heart failure, being an antidyspneic position. Children with congenital heart/arterial malformations

during exercise adopt the *squatting position*, which allows the redistribution of blood towards the brain.



**Figure 93. Generalized edema and orthopnea in a patient with congestive heart failure**

- **Facies.** In mitral stenosis, typically the mitral facies occurs. Corvisart's facies: the face seems to be swollen from cyanosis and edema. In chronic cor pulmonale, facial cyanosis is intense due to polyglobulia secondary to chronic respiratory failure, eyelid tumefaction is also present; injected, edematous conjunctivae (chemosis), venectasia of the cheekbones. The negroid facies is characterized by cyanosis and swollen lips.
- **Skin and mucosae.** Various types of *cyanosis* can occur. *Pallor* appears in heart failure through decreased cardiac output, in

cardiogenic shock, angina pectoris through vasoconstriction, aortic insufficiency. In infective endocarditis, pallor changes to a *café-au-lait* appearance. *Jaundice* can be evidenced in patients with hepatic stasis in right ventricular failure, constrictive pericarditis. *Melanoderma* is characteristic of hemochromatosis. In patients with acute articular rheumatism, *erythema marginatum* is a red-brown lesion of the trunk, with a clear-cut polycyclic outline, lasting several days; and *Meynet's nodes* are nodular formations several mm in size, mobile, located periarticularly. *Osler's nodes*, found in infective endocarditis, are red, painful, located in the pads of the fingers and toes, being due to septic emboli. Janeway's spots are also found in infective endocarditis as "*splinter hemorrhage*", located under the nails. In chronic cardiovascular disease, *nail clubbing* can be found. In heart failure, *cardiac stasis edema of the lower limbs* can be present.

- **Osteoarticular system.** *Arthritis* in acute articular rheumatism affects the middle joints, it lasts for days, being accompanied by Celsus signs, it has a saltatory character, it is accompanied by fever and other major signs of acute articular rheumatism, it heals without sequelae.

#### 4.3.2. PHYSICAL EXAMINATION OF THE HEART

##### *Inspection*

- The dilations of the heart and exudative pericarditis with abundant pericardial fluid cause *bulgings* of the precordial region when they occur in childhood (elastic chest).
- *Retractions* are evidenced in pericardial symphysis, in constrictive pericarditis with mediastinopericarditis.
- The pulsations of the precordial area can be physiological or pathological.

- *The apex beat (apical impulse)* is part of normal pulsations, being a punctiform, rhythmical bulging, synchronous with the heart beats; it represents the movements of the apex of the heart due to left ventricular contraction, it is situated in the 5<sup>th</sup> left intercostal space, in the midclavicular line.
- The apex beat can be *difficult/impossible to evidence* in obese persons, athletes, women (because of the mammary gland), in emphysematous subjects, or can be *very easily visible* in left ventricular hypertrophy/dilation (visible pulsations in the 5<sup>th</sup>-8<sup>th</sup> left intercostal spaces and outside the midclavicular line), right ventricular hypertrophy/dilation (visible pulsations in the 3<sup>rd</sup>-4<sup>th</sup> right intercostal spaces, epigastrium), ascending aortic dilation, aortic aneurysm (visible pulsations in the 2<sup>nd</sup>-3<sup>rd</sup> right parasternal spaces).

### ***Palpation***

- Palpation completes inspection, providing tactile sensations.
- Palpation is performed with the patient in dorsal/left lateral decubitus, with the palm covering the precordial region or two fingers in the 5<sup>th</sup> left intercostal space, in the midclavicular line (for the apex beat).
- When the patient is in left lateral decubitus, the apex beat is palpated with the palm of the hand/two fingers 2 cm left to the 5<sup>th</sup> space in the midclavicular line.
- The following can be palpated: shock, clicks, fremitus, rub.
- **The apex beat/apical impulse** is the lowermost, leftmost area of cardiac pulsation, 2 cm<sup>2</sup> in size, in the 5<sup>th</sup> left intercostal space in the midclavicular line (4<sup>th</sup> space in children and pregnant women). The palpation of the apex beat is physiologically altered in obese individuals, athletes, women with large breasts, and requires palpation in left lateral decubitus. Pathological changes are as follows:

⇒ **cardiac** diseases that change the position and the volume of the heart: left ventricular hypertrophy/left ventricular dilation, global cardiomegaly (in both directions, 6<sup>th</sup>-7<sup>th</sup> left intercostal spaces and anterior axillary space), dextrocardia (to the right);

⇒ **extracardiac**, e.g. conformation of the chest.

- *Horizontal shifts* occur in pleurisy, pneumothorax, mediastinal tumors (contralateral shift), and in pulmonary atelectasis, fibrothorax (ipsilateral shift).

- *Vertical shifts* are found in hyperinflation from pulmonary emphysema, bronchial asthma (downward shift), in ascites, meteorism, hepatosplenomegaly, tumors that increase pressure in the abdomen (upward shift), in kyphoscoliosis (shift to the most unusual positions).

- **The intensity of the apex beat** depends on the force of contraction of the left ventricle. It physiologically **increases** in athletes, during exercise, in the case of a thin chest wall. It also **increases** in:

⇒ **cardiac causes:** left ventricular hypertrophy ± left ventricular dilation (e.g. arterial hypertension, mitral insufficiency, aortic stenosis, aortic insufficiency – ball-like/dome-like apex beat). The intensity of the apical impulse **decreases** in mitral stenosis, dilated cardiomyopathy, acute myocardial infarction, heart failure. It is not palpated in exudative or constrictive pericarditis.

⇒ **extracardiac causes:** in pulmonary emphysema the intensity of the apex beat **decreases/disappears**. The alteration of its location and intensity also occurs in obesity, the shift of the mediastinum to the right.

Systolic xiphoid impulse (Harzer's sign) is due to right ventricular hypertrophy.

- **Clicks** are the palpation of powerful valve closure (like a shock/blow). Clicks are systolic and diastolic. *Systolic clicks* are

synchronous with the apical impulse or radial pulse. In tight mitral stenosis, the click is palpated at the apex of the heart during systole and represents the closure of the thickened, sclerosed mitral valve (sometimes without other stethacoustic sounds). In the 2<sup>nd</sup> left intercostal space the *diastolic click* is palpated, which is the powerful closure of the pulmonary sigmoid valves in diseases with pulmonary hypertension (mitral stenosis, respiratory diseases, COPD etc.). In systolic hypertension, aortitis, the diastolic click is palpated in the 2<sup>nd</sup> right intercostal space.

- **Cardiac thrill** is the palpation of intense, stenotic, organic murmur (from valvular lesions), with a low frequency of vibrations. For example, in *mitral stenosis* the diastolic rumble is palpated in the 5<sup>th</sup> left intercostal space, being increased in left lateral decubitus and during exertion; in *aortic stenosis* the systolic thrill is palpated in the 2<sup>nd</sup> right parasternal intercostal space, extending to the base of the neck; in *pulmonary stenosis* the systolic thrill is found in the 2<sup>nd</sup> left parasternal intercostal space, increased when leaning forward; in *interventricular septal defect* the systolic thrill is in the 5<sup>th</sup>-6<sup>th</sup> left parasternal spaces; in aortic aneurysms there is a systolic thrill; in *patent ductus arteriosus* there is a systolic-diastolic thrill in the 2<sup>nd</sup>-3<sup>rd</sup> left intercostal spaces.
- **Pericardial rub** occurs in dry pericarditis through the friction of the two pericardial layers thickened by fibrin deposition. It is palpated in the mesocardiac area, it is systolic-diastolic, it is increased when leaning forward and by pressure, it does not disappear during apnea, unlike pleural rub.

### ***Percussion***

It provided few clinical signs and is now abandoned.



## *Auscultation*

- **Technique.** Auscultation can be performed *directly*, by applying the ear to the precordial region (this is no longer used except in exceptional cases), or *indirectly*, using the stethoscope.
- **Auscultation zones (foci)** are well delimited areas on the surface of the anterior chest, within which the acoustic phenomena that are generated at the level of a valve orifice are heard at the highest intensity. The auscultation foci do not correspond to the anatomical projection of the valve orifices. They are represented by the following:
  - ⇒ **the mitral focus:** apex of the heart, 5<sup>th</sup> intercostal (ic) space in the midclavicular line;
  - ⇒ **the tricuspid focus:** the lower portion of the sternal manubrium, above the xiphoid appendix;
  - ⇒ **the aortic zone:** the 2<sup>nd</sup> right parasternal ic space;
  - ⇒ **the pulmonary focus:** the 2<sup>nd</sup> left parasternal ic space. Erb's point is also defined: the 3<sup>rd</sup> left juxtasternal; ic space
  - ⇒ **the mesocardiac focus:** the 4<sup>th</sup> left juxtasternal ic space.
- **The auscultation areas** tend to replace the auscultation foci. They are represented by the following:
  - ⇒ **the left ventricular area:** around the apex beat, the 3<sup>rd</sup>-5<sup>th</sup> ic spaces, from the anterior axillary line up to 2 cm inside the apex beat;
  - ⇒ **the right ventricular area;** the lower 1/2 of the sternum and the 4<sup>th</sup>-5<sup>th</sup> ic spaces on both sides of the sternum over a 2 cm surface;
  - ⇒ **the aortic area:** the 1<sup>st</sup>-2<sup>nd</sup> right parasternal spaces, the sternum, the 2<sup>nd</sup>-4<sup>th</sup> left parasternal spaces;
  - ⇒ **the pulmonary area:** from the left clavicle to the 3<sup>rd</sup> left ic space.

On heart auscultation, sounds and murmurs can be heard.

- **The 1<sup>st</sup> sound ("tūm")** is due to the closure of atrioventricular valves, it coincides with carotid pulse and the apex beat, it has the highest intensity in the mitral and tricuspid foci. The 1<sup>st</sup> sound can have an *increased* intensity: mitral stenosis; *decreased* intensity: mitral valvulitis (acute articular rheumatism, endocarditis), heart failure; or it can be *split*.
- **The 2<sup>nd</sup> sound ("tā")** is due to the closure of the sigmoid aortic and pulmonary valves, it has the highest intensity at the base of the heart. The 2<sup>nd</sup> sound can have an *increased* intensity: essential arterial hypertension (EAHT), pulmonary hypertension; *decreased* intensity: aortic stenosis, pulmonary stenosis; it can be *split*: pulmonary hypertension, atrial septal defect (ASD) – fixed splitting, aortic stenosis – paroxysmal splitting.

A high intensity of the 1<sup>st</sup> and 2<sup>nd</sup> sounds is found in hyperkinetic syndromes: fever, exercise, and anemia.

A low intensity of the 1<sup>st</sup> and 2<sup>nd</sup> sounds is found in infarction, myocarditis, heart failure, effusive pericarditis.

- **The 3<sup>rd</sup> sound** occurs after the 2<sup>nd</sup> sound in protodiastole, in young people with a fever. The 3<sup>rd</sup> sound at the apex of the heart is a sign of left ventricular failure (LVF), it is due to the rapid filling of the left ventricle, and it is also called *protodiastolic gallop*.
- **The 4<sup>th</sup> sound** precedes the 1<sup>st</sup> sound (presystole), it coincides with atrial systole, it is perceived at the apex of the heart, and it is a sign of diastolic dysfunction. It is found in ventricular hypertrophy, and it is also called *presystolic gallop*.
- **Atrioventricular valve opening click.** E.g.: mitral valve opening click: it occurs after the 2<sup>nd</sup> sound, at the apex, in mitral stenosis with mobile valves.
- **Ejection click:** e.g. aortic click, it occurs after the 1st sound, in the aortic auscultation area.

- **Three-beat rhythm.** It can be due to the splitting or the presence of the 3<sup>rd</sup> sound.
- **Cardiac murmurs** are vibrations produced by turbulent blood flowing. They are classified as follows:
  - ⇒ organic murmur: organic valvular lesions
  - ⇒ organic functional murmur: organic ventricular lesions
  - ⇒ functional murmur: hyperkinetic states: anemia, hyperthyroidism, pregnancy etc.
  - ⇒ "innocent" inorganic murmur: children, thin chest (systolic, low degree, non-radiating, without heart disease)
  - ⇒ murmur can be systolic, diastolic, continuous.
  - ⇒ depending on intensity, it is classified as 1<sup>st</sup>, 2<sup>nd</sup> degree (weak), 3<sup>rd</sup>, 4<sup>th</sup> degree (moderate), 5<sup>th</sup>, 6<sup>th</sup> degree (intense).
  - ⇒ phonocardiographic murmur can be "band-like", rhomboid, crescendo, decrescendo.
  - ⇒ pitch can be coarse, whistling, aspirating, musical (squeaking).
- **Systolic murmur** can be of 2 types:
  - ⇒ *ejection murmur*: e.g. in aortic stenosis: coarse murmur, at the base of the heart (aortic auscultation area), it radiates towards the carotids, rhomboid, 5<sup>th</sup>, 6<sup>th</sup> degree, accompanied by thrill
  - ⇒ *regurgitation murmur*: e.g. mitral insufficiency: "vapor jet", at the apex, it radiates to the axillary area, "band-like", 3<sup>rd</sup>, 4<sup>th</sup> degree.
- **Diastolic murmur** can be:
  - ⇒ *atrioventricular valvular stenosis murmur*: e.g. mitral stenosis: rumble (R), apex of the heart, non-radiating, it can be palpated, continuous with presystolic murmur – all sequences create the Duroziez murmur (onomatopoeia)
  - ⇒ *sigmoid aortic/ pulmonary regurgitation murmur*: e.g. aortic insufficiency: soft aspirating murmur, low degree, aortic auscultation area, Erb's point, it radiates towards the apex.

- **Pericardial rub.**

It occurs in dry pericarditis, it is coarse, rough, "rustling of silk", mesocardiac and endoapical, intensity increases on pressure, during apnea, it is "astride" the cardiac sounds.

## ***4.4. SEMIOLOGY OF THE ARTERIES***

### **4.4.1. ANAMNESIS**

- **Sex.** Atherosclerotic obliterating arteriopathy of the lower limbs is more frequently found in the male sex. Disorders more common in women include: embolism in mitral stenosis, Takayasu disease.
- **Age.** In newborns and young *children*, congenital heart diseases are more frequently found; in older children and adolescents, acute articular rheumatism, in *young adults*: Bürger's disease, Takayasu disease, arteritis in collagenases, Raynaud's syndrome, acrocyanosis, erythromelalgia; in individuals aged *over 50 years*: systemic atherosclerosis, chronic obliterating arteriopathy of the lower limbs; *over 60 years*: Horton's arteritis.
- **Family history.** There is a "morbid predisposition" in arterial hypertension, atherosclerosis. The presence of familial aggregation has been found in the case of atherosclerosis, Raynaud's syndrome.
- **Personal history.** Streptococcal, rickettsial infections, bacterial endocarditis can determine arteritis. Arteriopathies are found in acute articular rheumatism, collagenases, frost bites, heavy metal poisoning, hyperlipoproteinemia, diabetes mellitus, arterial hypertension, atherosclerosis.
- **Living and working conditions.**
  - ⇒ Raynaud's syndrome favored by vibrations
  - ⇒ AHT increased by stress
  - ⇒ atherosclerosis caused by excessive eating (calories, fats, carbohydrates), sedentary lifestyle, smoking

⇒ Bürger's disease, atherosclerosis caused by excessive smoking

## **SYMPTOMS**

### • **Pain**

Pain is caused by ischemia, it can be acute or chronic, intermittent or persistent.

⇒ **Intermittent pain – intermittent claudication.** It is found in stage II obliterating arteriopathy, obliterating thromboangiitis, arteritis, diabetes mellitus. It occurs as cramps, weight sensation, during exercise, cold exposure (Raynaud's syndrome), heat exposure (erythromelalgia), it is relieved at rest, it is located in the ischemic muscle situated below the arterial obstruction (e.g.: cramp in the calf during walking, in the toes, leg, thigh, buttock, Leriche's syndrome – bilateral claudication accompanied by impotence, abdominal claudication, masticatory claudication)

⇒ **Acute pain.** Pain is intense, tearing, sudden onset, it progresses in minutes to hours, caused by arterial embolism in the left heart (mitral stenosis, bacterial endocarditis, atrial fibrillation)

⇒ **Persistent pain**

○ Pain in *obliterating arteriopathy* stages III, IV, nocturnal, it is relieved by the declivous position of the lower limbs, subsequently atrocious, it requires opioids

○ Pain in *ischemic polyneuritis* is characterized by the presence of a chronic painful background, on which burning pain, intermittent pulsations, paresthesia occur

• **Paresthesia.** Pin-and-needle, numbness, cold, "dead finger" sensations, found in ischemic neuropathy

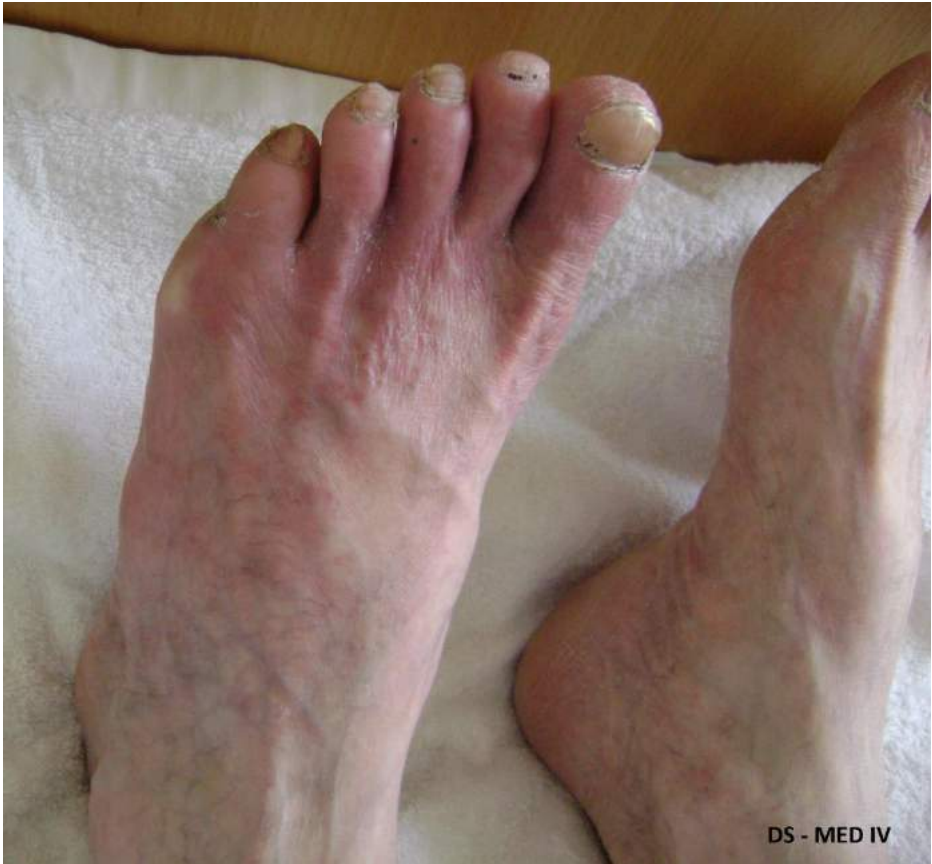• **Asthenia,** equivalent to intermittent claudication or chronic pain

• **Cerebrovascular symptoms** include pulsatile occipital cephalgia in the morning, dizziness; vision disorders ("sparks", "sieve"); hearing disorders (acouphene).

## 4.4.2. PHYSICAL EXAMINATION

- **General physical examination**

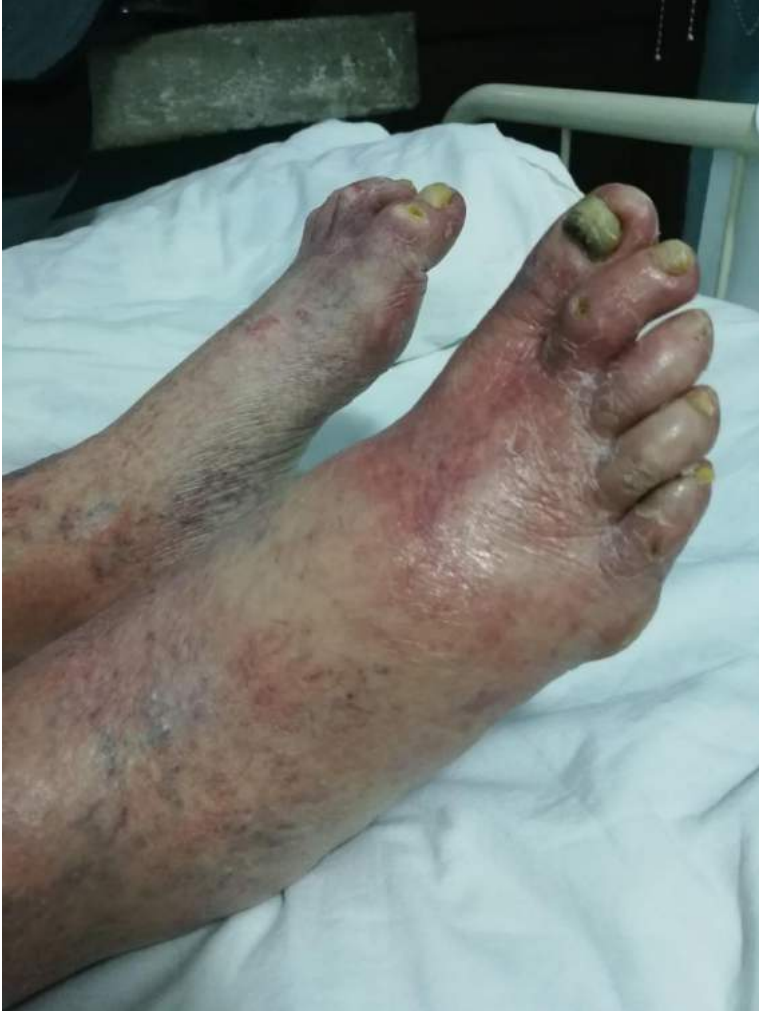- ⇒ **The somatic type:** normal/well developed in the upper ½ – aortic coarctation
- ⇒ **Posture:** antalgic – the lower limb hanging over the border of the bed; restless feet syndrome - nocturnal paresthesia of the lower limbs
- ⇒ **Skin:**
  - *pallor*: embolism and arterial spasm – atherosclerotic arteriopathy
  - limited transient regional pallor → cyanosis
  - Burger's, Ratchoff's postural tests, Allen's test (palm arch) have orientation value
  - *cyanosis*: cold – obliterating arteriopathy, marbled – paralytic capillary vasodilation, acrocyanosis – persistent, symmetrical, in extremities ← spasm of the small vessels in the skin
  - *redness*: erythromelalgia, Raynaud's syndrome, "the sock's sign" – well delimited declivous cyanotic redness, it disappears with the elevation of the extremity



**Figure 94. Pallor and redness in a patient with ischemia of the lower limbs**

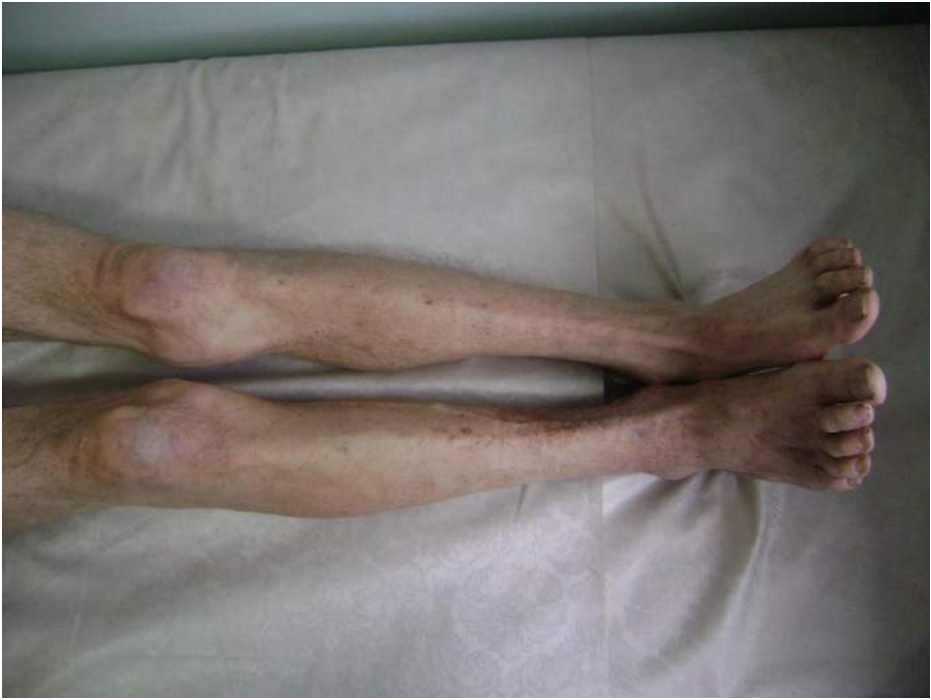- cutaneous *xanthomas*, xanthelasma (HLP II, III), gerontoxon (HLP II) – senile corneal arch
- skin atrophy, loss of hair (Ratchoff's "*bald*" leg), alteration of nails
- *ulcerations*: in the pads of the fingers and toes in Burger's disease, Raynaud's syndrome; at the level of the pressure points of the lower limbs in atherosclerotic arteriopathy

- *gangrene*: dry in acute arterial obliterations (embolism, thrombosis) or chronic arterial obliterations
- Digital clubbing: unilateral – subclavicular artery aneurysm, in the lower limbs – aortic coarctation
- localized *edema*: increased permeability in obliterating arteriopathy



**Figure 95. Chronic ischemia of the lower limbs with cyanosis and scars from healed arterial ulcers (toes)**





**Figure 96. A typical patient with chronic ischemia of the lower limbs due to atherosclerosis (pallor, skin atrophy, bald calves)**

- **The clinical examination of the arteries**

- ⇒ **Inspection:**

- aneurysm pulsations
- carotid arterial dance: aortic insufficiency, aortic coarctation, atherosclerosis, AHT
- "*Hippocratic snake*" – humeral, temporal artery
- peripheral signs of aortic insufficiency: Musset (rhythmic movements of the head synchronous with the pulse); Muller: of the isthmus; "tonsillar pulse"; Minervini "lingual pulse"; Quinke's capillary nail pulse; Landolfi's hippus; the lighthouse sign

⇒ **Palpation:**

- normal: elastic, compressible depending on BP
- in atherosclerosis: hardened, hardly compressible, "goose feather-like", "pipeline"
- in arterial aneurysms: expansible pulsatile dilations
- arterial thrill – equivalent to arterial murmur, systolic vibration
- Arterial pulse:
  - *normal*: symmetrical, centripetal, equal, frequency: 60-90/min.
  - *physiological changes*:
    - increased: children, physical exercise, digestion, emotions
    - decreased: sleep, athletes

***Frequency of the pulse:***

- *sinus tachycardia*:
  - 90-min., rhythmic, accelerated, low amplitude
  - increased during exercise
  - decreased in carotid sinus compression
  - caused by: myocarditis, infarction, pericarditis, endocarditis, valve disease, congestive heart failure, fever, anemia, hyperthyroidism, collapse, poisoning etc.
- *paroxysmal tachycardia*:
  - 160-220/min., weak, filiform, regular
  - fixed (unchanged by exercise, carotid sinus compression)
  - improved by vagal maneuvers: pressure on the globes of the eye, pharyngeal excitation, Valsalva maneuver

- it occurs in: valve disease, AMI, myocarditis, cardiomyopathies, hyperpotassemia, digitalis poisoning
- *sinus bradycardia*: < 60/min; it occurs in digitalis overdose, myxedema, mechanical jaundice, hypervagotonia, athletes, intracranial hypertension, saturnism
- *bradycardia in 3<sup>rd</sup> degree complete AVB*: 20-50-min., fixed, regular, uninfluenced by exercise, carotid sinus compression, Adam Stockes episodes, AMI, myocarditis (diphtheria), digitalis poisoning

### ***Regularity / rhythmicity***

- irregular/arrhythmic
- extrasystolic arrhythmia: physical exercise can suppress occasional extrasystoles / bi-, tri-, quadrigeminy; it occurs in: cardiothyreosis, emotions, excessive coffee, alcohol, tobacco use
- complete arrhythmia: irregular rhythm, different amplitude, different frequency, pulse deficit; atrial fibrillation in: ischemic heart disease, mitral stenosis, acute myocardial infarction; paroxysmal atrial fibrillation: cardiothyreosis

### ***Amplitude (volume)***

- full pulse (large volume pulse): LV dilation: dilated cardiomyopathy, aortic insufficiency, mitral insufficiency, aortic coarctation (in the lower ½ of the body)
- weak pulse: aortic stenosis, mitral stenosis, congestive heart failure, tachycardia, alternating pulse, paradoxical pulse

### ***Pulse tension***

- hard pulse: aortic insufficiency, aortic stenosis, atherosclerosis
- soft pulse: arterial hypertension, collapse, heart failure

### ***Celerity***

- rapid pulse: "saltatory" Corrigan's pulse in aortic insufficiency, "jerky", "water hammer"
- plateau pulse in aortic stenosis
- bisferiens pulse – double, bifid: aortic insufficiency + aortic stenosis, obstructive cardiomyopathy
- dicrotic pulse: arterial hypotension, shock

#### **⇒ Auscultation of the arteries:**

- arterial murmur – significant stenosis 50-90%; arteriovenous fistulas; aneurysm
- rhomboid ejection murmur, radiating along the vessels, coarse, extensive during diastole, with vascular thrill; it occurs in: aortic insufficiency
  - "gunshot" sound - systolic arterial sound, up to the palm arch
  - double arterial murmur (Traube): in the femoral artery; systolic and diastolic sound
  - double crural murmur (Durozier) – systolic and diastolic murmur in the femoral artery

## ***4.5. SEMIOLOGY OF THE VEINS***

### **4.5.1. ANAMNESIS**

- **Sex.** Lower limb varices, thrombophlebitis are more frequently found in women (3/1).

- **Age.** In young children, congenital abnormalities (fistulas, angiodysplasia) are more common; in adults: varicose disease, thrombophlebitis, obliterating thromboangiitis; in the elderly: congestive heart failure.
- **Personal history.** Infectious diseases, hemopathies, neoplasms, congestive heart failure, prolonged immobilization may cause thrombosis.
- **Living and working conditions.** Prolonged orthostatism, a sedentary lifestyle predispose to nervous system disorders.

## ***SYMPTOMS***

- **Pain**

Pain is located in the affected lower limb, it is continuous or intermittent, exacerbated by the increase in venous pressure.

⇒ *Pain in thrombophlebitis* occurs suddenly, it is felt as a muscle weight sensation, it is increased by exercise and cough, it is improved by rest and the elevation of the lower limb

⇒ *Pain in varices.* It is perceived as pressure, it radiates along the axis of the lower limb, it occurs in the evening, increased by prolonged orthostatism

⇒ *Pain in venous insufficiency* has the character of nocturnal cramp, Vaquez venous claudication

- **Paresthesia, hyperesthesia, pruritus** are found in *postthrombotic syndrome*.

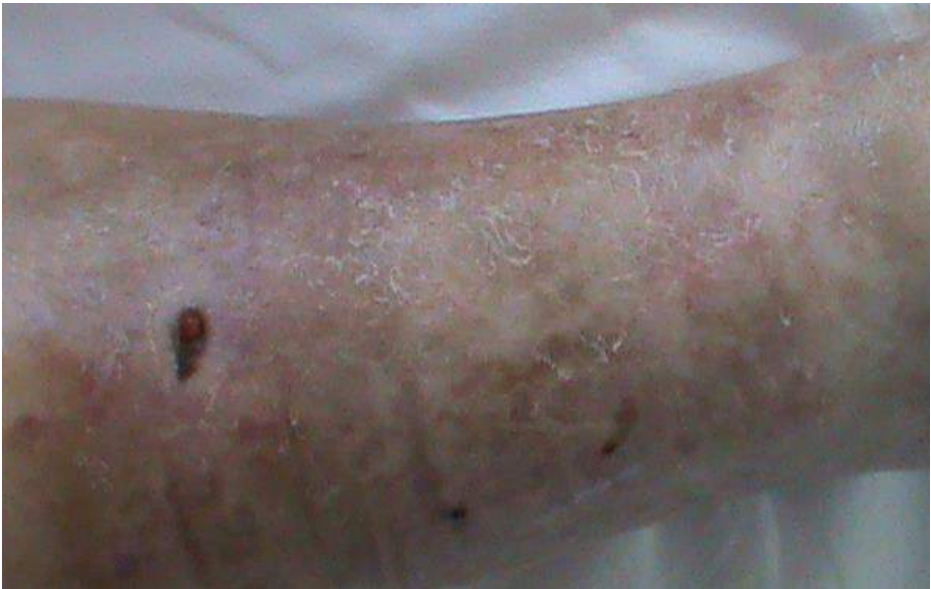## **4.5.2. PHYSICAL EXAMINATION**

- **General physical examination**

⇒ anxiety, agitation: pulmonary microembolism

⇒ hot skin – superficial thrombophlebitis

- ⇒ edema – deep thrombophlebitis: sensitive, refractory massive edema: blue (*phlegmasia caerulea dolens*) or white (*phlegmasia alba dolens*), elastic to hard, increased during orthostatism and walking ± hyarthrosis
- ⇒ skin atrophy: thin, hardened, transparent skin, obvious venous vessels
- ⇒ petechiae, pigmentation disorders, cutaneous infections
- ⇒ atonic superficial ulcerations (*varicose ulcer*), muscle weakness

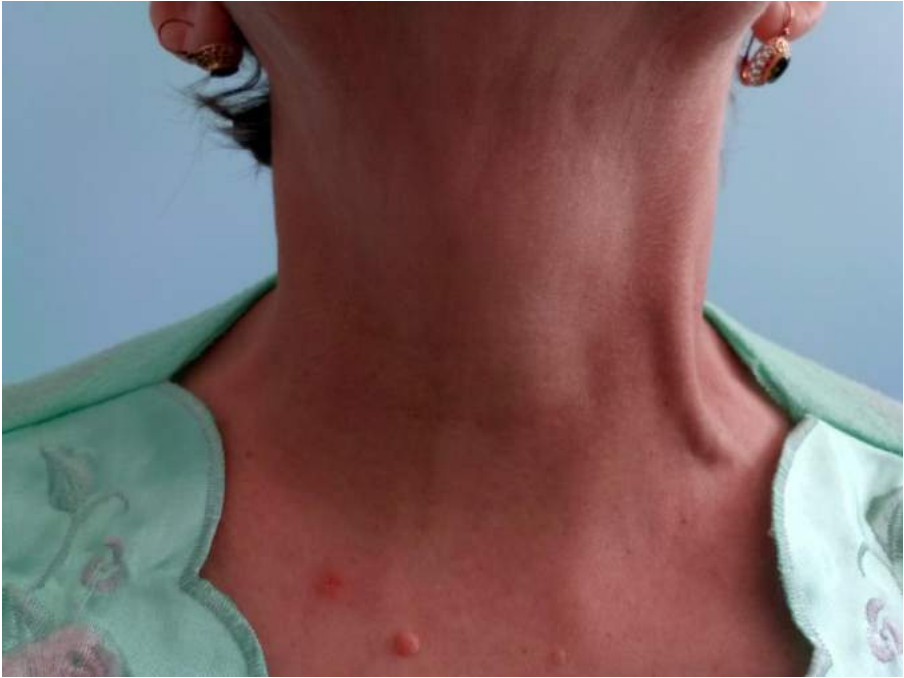

**Figure 97. Skin atrophy, hyperpigmentation and a small ulcer in chronic venous insufficiency**

- **The physical examination of the veins**

- ⇒ red belt, hardened in superficial thrombophlebitis; recurrent (Burger's disease), migratory (*Trousseau's sign*) in digestive, pulmonary cancer
- ⇒ tortuous, dilated, blue varicose tracts, particularly in the lower 1/3 of the calves

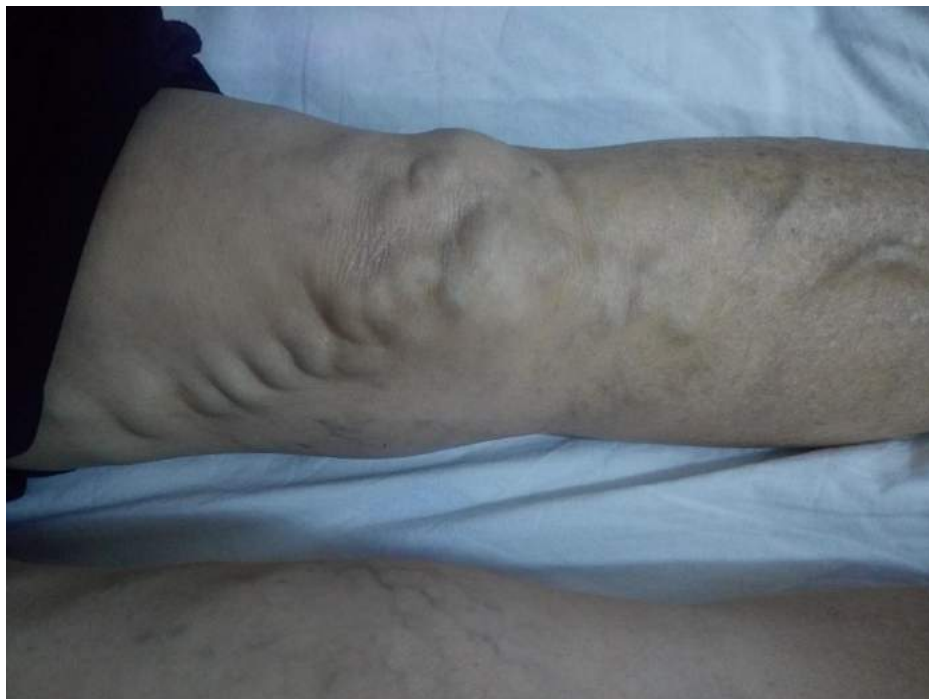⇒ turgescence of the external jugular veins in right ventricular failure, cardiac tamponade, superior vena cava obstruction, COPD



**Figure 98. Unilateral jugular turgescence in an extrinsic compression**

- ⇒ pain caused in deep thrombophlebitis
  - palpation of the vein tract
  - percussion of the tibial crest (Lisker)
  - compression over 180 mmHg (Lowenberg)
  - dorsiflexion of the foot (*Homans*)
- ⇒ superficial/deep venous insufficiency: cough test, Trendelenburg–Brodie test
- ⇒ presystolic, systolic jugular pulse (systolic hepatic expansion)
- ⇒ hepatojugular reflux: right ventricular failure

⇒ venous murmur.



**Figure 98. Varicose veins of the lower limbs in chronic venous insufficiency**



# CHAPTER 5. CLINICAL CARDIOVASCULAR SYNDROMES

## 5.1. MYOCARDIAL SYNDROME

Myocardial syndrome (MS) consists of a global or partial increase in the volume of the heart, manifesting by signs detectable by physical, radiological, electrocardiographic, ultrasound examination, as well as by other less frequently used paraclinical methods.

**MS** is the consequence of a primary involvement of the heart muscle.

Two phenomena can underlie MS:

- an increase in heart muscle mass: **cardiac hypertrophy** that consists of an increase in the mass of the myocardium due to the thickening and elongation of myocardial fibers; hypertrophy can be concentric when the cavity lumen is diminished, wall thickening occurring towards the inside (this is the case of systolic overload and idiopathic hypertrophy) and excentric, in which the cavity lumen is increased, wall thickening occurring towards the outside (this is the case of diastolic overload); hypertrophy is produced by adaptive or compensatory mechanisms (in response to chronic hemodynamic overload) or as an expression of myocardial metabolism disorders;
- an increase in cardiac cavity volume: **cardiac dilation** by an adaptive mechanism (in response to volume overload) or myogenic dilations.

**The increase in the volume** of the heart can be:

- **global**, of the entire heart, with a proportional involvement of all heart compartments

- **partial**, segmental, involving only one cardiac chamber (e.g. the myocardium and/or the volume of the cavity of one ventricle or atrium)

**Symptoms** can be absent or if they exist, they are completely non-characteristic and depend on the causative disease or other associated disorders (palpitations, sensation of discomfort, weight or pressure in the heart region).

**The signs** obtained by physical examination usually appear at heart volume increases that exceed certain limits and are influenced by many other factors (chest conformation, chest wall thickness etc.), which makes data interpretation difficult.

- **cardiomegaly** (hypertrophy and cardiac dilation):
  - ⇒ bulging of the precardiac region (in heart diseases that develop in childhood);
  - ⇒ the apex beat;
    - strong, full ("*lifting*") and globular, perceptible within a larger area, suggestive of LV hypertrophy;
    - it can be diminished in dilated forms;
    - Harzer's sign and the strong right parasternal impulse signifies RV hypertrophy or biventricular dilation;
    - the downward or the downward and outward shift of the apex beat is due to a considerable LV enlargement, to global cardiac dilation.
  - ⇒ increased precordial dullness area in marked cardiomegaly (late sign); cardiac dullness can be increased transversally (RV increases) or longitudinally (LV increases); cardiac dullness becomes at the same time more decided; excessive increases in the RV can produce dullness in the sternal extremity of the right intercostal spaces, starting with the 5<sup>th</sup> space (in this case, diagnosis problems with exudative pericarditis are posed); in children with excessive cardiac dilations, signs of atelectasis

may occur in the posterior base of the left lung, through the compression of the lower lobe.

⇒ echocardiography, radiological examination, ECG assess the size of the heart more accurately.

- **alterations of the cardiac sounds:**

⇒ deaf first sound, presystolic, protodiastolic and summation gallop; the last two are certainty signs of heart failure

⇒ functional mitral and/or tricuspid insufficiency systolic murmur

- **rhythm and conduction disorders:**

⇒ all types of rhythm and conduction disorders can appear

⇒ ventricular and atrial extrasystoles, atrial fibrillation, intraventricular conduction disorders, ventricular fibrillation and sudden death are extremely frequent

- **heart failure:**

⇒ left ventricular or global failure can occur in severe forms, in congestive (dilated) forms, respectively

⇒ hypodiastolic failure is found in restrictive forms.

- **electrocardiographic changes:**

⇒ they are extremely frequent, varied, and in forms frustes they can be the only manifestation

⇒ primary STT changes, usually subendocardial, and the prolonged Q-T interval are most frequently found

There are particular clinical forms: infectious, rheumatismal myocarditis, cardiomyopathies (congestive, hypertrophic, restrictive).

## ***5.2. HEART FAILURE***

Heart failure (HF) is the incapacity of the heart to ensure a satisfactory blood supply to organs and tissues (without the increase in the LV telediastolic pressure), which occurs through the disequilibrium

between the state of the heart and its strain (the decrease in cardiac output through hypovolemia or brutal systemic vasodilation is not HF).

### **Types of HF:**

- *low cardiac output syndrome* through the decrease in cardiac output (CO) (the cardiac index decreases to  $< 2.4$ ); *congestive heart failure (CHF)* through the stagnation of blood behind LV (LVTDP increases to  $> 12$ );
- *systolic HF* through the decrease in the systolic expulsion function; *diastolic HF* through the diminution of the diastolic relaxation function;
- *left, right, global HF* through the involvement of the left heart, right heart, or both;
- *low cardiac output HF* (normal CO = 2.4 l/min/m<sup>2</sup>); *high cardiac output HF* (in hyperthyroidism, arteriovenous fistulas, severe anemia etc.);
- chronic HF; acute HF.

### **Pathogenesis of HF:**

- systolic HF occurs when ventricular performance (and consequently the cardiac index) decreases. Ventricular performance depends on: cardiac contractility, preload (tension of the LV wall at the end of diastole proportional to the return volume and pressure) and postload (tension of the LV wall during systole proportional to BP and LV diameter), heart rate and rhythm;
- in low cardiac output syndrome, the cardiac index decreases to  $< 2.4$  l/min./m<sup>2</sup>;
- in CHF, LVTDP increases to  $> 12$  mmHg (congestion or stasis);

### **Etiology of HF:**

- HF represents a stage of the natural evolution of some heart diseases that affect the myocardium, pericardium, endocardium, PTE, AHT episodes etc.;

- precipitating and aggravating associated factors: myocardial ischemia, arrhythmia, hypoxia, general or endocardial infections, myocardial inflammation, toxic agents, drugs, endocrine, metabolic and neuropsychic factors, AHT, PTE, non-compliance with therapy and diet etc.;

**Pahophysiology of HF:** CO decreases, compensatory mechanisms develop:

- *ventricular hypertrophy* (increase in wall tension, angiotensin II etc.);
- *activation of the sympathetic nervous system* (with tachycardia), of the renin-angiotensin-aldosterone system (dyspnea, edemas), of the arginine-vasopressin system;
- clinical HF manifestations are due to: decreased CO, blood stasis and consecutive compensatory mechanisms.

**Clinical picture:** respiratory, digestive manifestations, edema, renal, cardiovascular manifestations

- ***Respiratory manifestations:*** dyspnea, cough;
  - ⇒ acute dyspnea: orthopnea, nocturnal paroxysmal dyspnea, cardiac asthma, acute pulmonary edema (APE);
  - ⇒ chronic dyspnea: progressive exertional, subsequently at rest;
  - ⇒ cardiac asthma: suffocation crisis + wheezing + bronchial obstructive syndrome with sonorous, sibilant rales;
  - ⇒ APE (acute pulmonary edema): suffocation crisis, rattling breathing, cough + foamy pink expectoration, anxiety, pallor, sweating, cyanosis, crepitant rales at both lung bases that rapidly move to the apex;
  - ⇒ cardiac cough: dry (during exercise, crises) + varied expectoration (in APE, pulmonary infarction, pneumonia, MS, hemosiderosis etc.);
  - ⇒ objective chest examination: condensation syndrome: subdullness + crepitant rales at both lung bases (indicating stasis)

in pulmonary and bronchial circulation); bronchial obstructive syndrome: prolonged expiration + sibilant, sonorous rales (spasm);

- **Digestive manifestations:** inappetence, bloating, weight loss, hepatalgia + jaundice (hypoperfusion + stasis in digestive organs); stasis hepatomegaly: initially smooth, elastic, sensitive, round, accordion-like (it increases and decreases with HF therapy), subsequently firm, insensitive, sharp (in chronic stasis with a year-long duration).
- **Edematous syndrome:** cardiac edemas (declivous, symmetrical, cold, cyanotic), hydrothorax (usually right), ascites, hydropericardium and anasarca.
- **Other HF manifestations:** oliguria, nycturia, skin changes (pallor, cyanosis, coldness etc.), diminished muscle;
- **Cardiac manifestations:**
  - ⇒ tachycardia, ventricular gallop (left or right protodiastolic 3<sup>rd</sup> sound) alternating pulse;
  - ⇒ increased P2, turgescient jugular veins, low BP;
  - ⇒ signs of the background disease that causes HF.

The described clinical picture is grouped into low cardiac output syndrome and CHF as follows:

- ⇒ CHF includes: acute or chronic dyspnea, pulmonary and hepatic (digestive) stasis, edemas, serous collections etc.;
- ⇒ low cardiac output syndrome: asthenia, muscle fatigue, cold skin, cerebral disorders, oliguria, nycturia, tachycardia, arterial hypotension, protodiastolic gallop ± pallor, peripheral cyanosis.

**Paraclinical explorations:** aimed at assessing the decrease in cardiac (LV) performance: LV ejection fraction, cardiac index, LVTDP, blood stasis; chest X-ray; the methods used are: echocardiography (M, 2D, Doppler), left, right cardiac catheterization (Swan-Ganz probe), radioisotopic angiocardiology, phonocardiography, exercise test.

**The diagnosis of HF** includes: the hemodynamic type (acute or chronic CHF, acute or chronic low cardiac output syndrome), acute or chronic ventricular failure, NYHA functional class (for left ventricular failure).

NYHA I = ordinary physical exercise, NYHA II = slight limitation of physical exercise, NYHA III = marked limitation of physical exercise, NYHA IV = discomfort during any physical activity, HF symptoms occur at rest.

*From a clinical point of view, HF represents a way of evolution of an advanced heart disease of any etiology, as well as of an extracardiac state.*

### **5.2.1. LEFT VENTRICULAR FAILURE**

- Acute left ventricular failure (LVF) is more frequently caused by: acute myocardial infarction, acute myocarditis, hypertension crisis, acute glomerulonephritis, paroxysmal tachyarrhythmia.
- Chronic LVF is secondary to: AHT, ischemic heart disease, aortic valve disease, mitral insufficiency, primary and secondary cardiomyopathy, chronic myocarditis, arrhythmia, etc.
- Acute LVF can occur as an acute accident in chronic LVF, under the action of precipitating or aggravating factors (e.g.: arrhythmia, hypertension crisis, coronary accident, severe anemia, etc.).

#### **Clinical picture**

##### **Symptoms:**

- **Dyspnea:** it dominates the clinical picture; it is inspiratory and expiratory with polypnea; the pathophysiological substrate is pulmonary stasis and reduced pulmonary compliance  
⇒ *exertional dyspnea:* the earliest manifestation; it worsens or improves depending on the evolution of heart failure; in mild heart failure, dyspnea manifests during more intense exercise (previously performed without disorders) such as: climbing up

the stairs of several floors, short distance running, more intense professional or domestic exertion; moderate HF is characterized by the appearance of dyspnea during moderate exercise: climbing up a floor, walking up a slope, walking on flat ground at a rapid pace; advanced HF manifests by dyspnea during ordinary daily exercise: walking on flat ground at a normal pace, etc.

⇒ *decubitus dyspnea*:

- orthopnea has a severe prognosis, it occurs in severe HF
- paroxysmal dyspnea: it occurs at night; it has two forms: cardiac asthma and acute pulmonary edema

- **Cardiac asthma:** it occurs in patients with a history of exertional dyspnea, but is sometimes the first manifestation of LVF. The patient is suddenly woken up by the sensation of gasping for air, which makes him take a sitting position, sometimes go to the window. Dyspnea is relieved within minutes, or it may last for half an hour or more. Superficial polypnea, dry cough, crackles at the lung bases are found. Tachycardia is almost constant and heart auscultation frequently detects presystolic or more rarely protodiastolic gallop. Cardiac asthma differentiates from acute pulmonary edema through a less severe character. Some authors call cardiac asthma a particular form of paroxysmal dyspnea in LVF, in which pulmonary stasis is associated with reduced bronchiole caliber through parietal edema, as well as through changed smooth muscle reactivity (bronchospasm). The clinical picture is similar to that of bronchial asthma (expiratory dyspnea, prolonged expiration, sibilant rales), but tachypnea and subcrepitant stasis rales are also found.
- **Acute pulmonary edema (APE):** it has cardiac causes (cardiogenic APE), occurring in mitral stenosis and LVF, or extracardiac causes (non-cardiogenic or lesional APE). It represents a serious medical emergency, as it may result in the patient's death. APE in LVF



usually occurs at night in patients with exertional dyspnea or/and a recent history of cardiac asthma episodes; it can also occur after physical exercise, the administration of large amounts of parenteral fluid or as an inaugural disease. APE brutally wakes up the patient, who becomes extremely anxious, orthopneic, covered with cold sweat, with pale cyanotic skin. The patient's cough is initially dry and cough does not relieve but worsens dyspnea, then characteristic serous sputum consisting of transudated plasma is expectorated, which takes the typical appearance of whipped egg white through air bubbling, sometimes being pink through the extravasation of erythrocytes, rarely hemoptoic. In extremely severe forms, the patient cannot expectorate (the bronchoplegic form). Dyspnea is inspiratory and expiratory with extreme polypnea (more than 40 respirations/minute), but bronchospasm is rare. On lung auscultation, wet stasis rales (subcrepitant, crepitant) are heard, which move up as the clinical picture worsens and down following adequate treatment (like the sea tide). The patient is almost always extremely tachycardic, usually in sinus rhythm (sometimes in atrial fibrillation). BP is usually high (preexisting AHT or a hypertension episode or a blood pressure increase caused by physical pain and anxiety). Severe forms in acute myocardial infarction evolve with cardiogenic shock. Heart auscultation reveals all the signs of LVF that are difficult to detect under the conditions of anxiety and dyspnea. The main element in the onset of APE is the increase of pulmonary pressure to more than 30 mmHg.

- **Cardiac cough** accompanies all forms of LVF
- **Cheyne-Stokes respiration:** it aggravates insomnia and anxiety

#### **Signs of LVF**

- **Extracardiac signs.**

⇒ pulmonary stasis is evidenced by the presence in the lung bases of subcrepitant rales that sometimes can be better heard on the

side of the chest on which the patient lies for a longer time period

- ⇒ cyanosis - frequently present, without being marked
- ⇒ pallor - when present, it is the expression of vasoconstriction in the skin (redistribution of blood for an effective perfusion of vital organs)

- **Cardiac signs**

### **The clinical examination of the heart**

- ⇒ tachycardia is an important clinical sign, being approximately 110-20/minute, without decreasing to less than 80 as a rule. It is a valuable indicator for the monitoring of the evolution of LVF, being a compensatory mechanism initiated by the increase of sympathetic-synergistic activity
- ⇒ palpation of the heart. The apex beat can be displaced downward or downward and outward, having a longer duration. Left parasternal pulsations can also be noted and palpated, as an expression of ventricular dyskinesia
- ⇒ percussion indicates the degree of increase in cardiac dullness
- ⇒ auscultation represents the most important stage of clinical examination. It can evidence: tachycardia, various arrhythmias, increased 2<sup>nd</sup> sound in the pulmonary focus (hypertension in pulmonary circulation), **left gallop** (presystolic, protodiastolic or summation gallop). Presystolic gallop expresses only the systolic overload of LV, while diastolic or summation gallop expresses HF (HF in coronary, hypertensive patients) if there is no diastolic overload (mitral or aortic insufficiency)
- ⇒ alternating pulse is a rare but precious diagnostic sign
- ⇒ blood pressure is frequently increased, AHT + ischemic heart disease being the most common cause of LVF. In severe forms, maximal BP decreases but minimal BP is maintained high (beheaded AHT), with an unfavorable prognosis. The marked

decrease in BP up to collapse occurs in cardiogenic shock in AMI, acute myocarditis, etc.

- **Paraclinical signs**

⇒ Cardiopulmonary X-ray evidences the extension of the lower left arch, along with the signs of pulmonary stasis

⇒ ECG indicates signs of left ventricular overload (QRS axis shifted to the left, tall R waves with ST depression in the left precordial leads)

⇒ Other explorations: carotidogram, phonocardiogram, echocardiography, radioisotopic explorations

## 5.2.2. RIGHT VENTRICULAR FAILURE

### **Classification:**

- Primary right ventricular failure (RVF), in cor pulmonale and right heart valve diseases (pulmonary stenosis, tricuspid insufficiency)
- Secondary RVF, in global heart failure when LVF precedes RVF
- RVF in mitral stenosis, in which it is the consequence of PHT without LVF
- acute RVF, in acute cor pulmonale (e.g.: pulmonary embolism)
- subacute RVF in asthma sickness
- chronic RVF in chronic cor pulmonale in which right ventricular hypertrophy is generated by diseases that affect the lung function and/or structure, except for diseases that primarily affect the right heart or congenital heart diseases.

### **Clinical picture**

#### **Symptoms**

- *dyspnea* usually due to the coexisting pulmonary disorder (cor pulmonale or pulmonary stasis in mitral stenosis)
- *the cyanosis of the face and extremities* is a characteristic sign in RVF; it occurs by a peripheral or mixed mechanism, a central mechanism being added to the peripheral mechanism; the coexisting

anemia diminishes the intensity of cyanosis, and polyglobulia in COPD with cor pulmonale intensifies cyanosis; sometimes subjaundice or terminal jaundice are associated; in cor pulmonale, cyanosis is hot and accompanied by hypercapnic syndrome (acid hypercrinia and symptoms of neuropsychic and hypoxic disorders)

- *digestive symptoms*: exertional hepatalgia generated by stasis hepatomegaly, anorexia, flatulence, nausea, etc., secondary to gastrointestinal venous congestion
- *oliguria and nycturia* through fluid retention, with concentrated urine, moderate albuminuria (lower than 1 g/day); cardiac edemas (visible after an accumulation of 6-5 liters), ascites, hydrothorax (predominantly right)

### **Signs of RVF**

- *peripheral cardiac edemas* represent a basic sign of RVF; they initially occur in the declivous, retromalleolar and pretibial regions, being aggravated by orthostatism and reduced in the morning; subsequently, they extend to the thighs, abdominal wall, genital organs, lumbar region, chest, upper limbs and face; they are usually symmetrical, the obvious asymmetry in one of the lower limbs suggesting the presence of venous obstruction that can suggest lung embolism. *Generalized edemas* are usually accompanied by ascites, pleural effusion (hydrothorax), visceral edemas, representing anasarca. In longer duration edemas there is increased consistence, with hyperpigmentation and local trophic disorders (fissures, eczemas, ulcerations etc.).

### **Extracardiac signs**

- *Stasis hepatomegaly* is constant, accompanied by exertional hepatalgia and the sensation of epigastric tension. The increased liver is painful on percussion and palpation, turgid, its anterior side bulging below the rib margin. Consistence is firm and the anterior margin, rounded. The size of the liver increases with the progression of HF and diminishes with its improvement; these changes can

occur within short time intervals, even from one day to another (*accordion-shaped liver*), which is absolutely characteristic. In chronic liver stasis, particularly in the advanced stages corresponding to cardiac cirrhosis, the liver becomes hard, non-painful, with a sharp anterior margin and no longer decreases in size with hemodynamic improvement. Systolic hepatic pulsations occur in RVF with right ventricular dilation and the appearance of tricuspid insufficiency. Stasis hepatomegaly is accompanied by hepatojugular reflux.

- *jugular turgescence* expresses the increase in venous pressure
- *systolic jugular pulse* characterized by pulsations synchronous with arterial pulse expresses functional tricuspid insufficiency
- *subjaundice* is found sometimes in RVF, frequently in tricuspid insufficiency or can be caused by pulmonary thromboembolism frequently associated with RVF; more rarely, it expresses an associated hepatic disorder
- *ascites* with transudate character is part of the hydropericardial syndrome of RVF, being early and severe in case of tricuspid valve disease or constrictive pericarditis
- the signs of the causative pulmonary disorder in CCP and the signs of pulmonary stasis or chronic mitral bronchopneumopathy in mitral stenosis

### **Cardiovascular signs in RVF**

- palpation evidences the increase in the right heart through:
  - ⇒ the outward (or downward) shift of the apex beat
  - ⇒ Harzer's sign (pulsations of the hypertrophied right ventricle in the epigastrium below the xiphoid appendix)
  - ⇒ left parasternal pulsations in the 3<sup>rd</sup>-4<sup>th</sup> spaces caused by the increase in RV

- percussion may indicate an extension of the cardiac area, predominantly transversally, but difficult to find in pulmonary emphysema in the case of cor pulmonale
- auscultation can evidence:
  - ⇒ rhythm disorders, particularly supraventricular
  - ⇒ presystolic or protodiastolic gallop with the highest intensity in the xiphoid appendix area and increased during inspiration (right gallop), which confirms RVF
  - ⇒ functional tricuspid insufficiency systolic murmur in the tricuspid focus in the case of marked RV dilation
  - ⇒ characteristic stethacoustic signs in the case of valve diseases

### **Paraclinical signs of RVF**

- standard cardiopulmonary X-ray can evidence the increase in RV, the bulging of the middle arch or an apparently normal heart
- ECG indicates signs of right ventricular overload (tall R waves in the right precordial leads, sometimes right bundle branch block, pulmonary P)
- laboratory explorations indicate an increase in venous pressure, polyglobulia, hemoconcentration, increased blood viscosity, to which spirometric changes, and possibly altered hepatic tests, are added.

### **5.2.3. GLOBAL HEART FAILURE**

Global heart failure (GHF) clinically represents the association of left HF signs with right HF signs, with the predominance of ones over the others.

- Biventricular HF can be concomitant from the point of view of evolution, when left and right HF signs develop simultaneously, such as in: acute myocarditis, increased cardiac output heart failure (anemia, pregnancy + heart disease, arteriovenous fistulas, hyperthyroidism etc.)

- Successive biventricular HF, when left HF signs initially occur, after which right HF develops, such as in: AHT, ischemic heart disease, mitral insufficiency, aortic valve disease; mitral stenosis associates pulmonary stasis with right heart failure, having to a large extent the clinical appearance of global heart failure.

### **Signs and symptoms**

GHF associates LVF signs (pulmonary stasis-dyspnea) with RVF signs (systemic venous stasis, edemas, turgescient jugular veins, stasis hepatomegaly, serous effusion, etc.). Sometimes, the appearance of RVF improves the symptoms of LVF.

The clinical picture is dominated by exertional dyspnea and cardiac asthma episodes. Orthopnea is the expression of chronic pulmonary stasis, associated with the presence of hydrothorax. Cheyne-Stokes respiration is particularly found in arterial heart disease. In global heart failure, acute pulmonary edema is rare (but occurs in the case of thromboembolic pulmonary infarction or acute pneumopathy).

Hydrothorax is frequent in GHF, it is right or bilateral, with serous citrine fluid and negative Rivalta's test (2-3 g% protein). In the case of pulmonary infarction, serofibrinous or serohemorrhagic pleurisy occurs. Ascites has the same characteristics as hydrothorax, being predominant in cardiac cirrhosis, tricuspid lesions, and constrictive pericarditis. Hydropericardium is frequent but moderate.

**Cardiac signs:** they reveal global cardiomegaly

- the apex beat is displaced downward and outward on palpation
- global heart increase on percussion
- gallop, functional mitral and tricuspid insufficiency, extrasystolic tachycardia or arrhythmia or atrial fibrillation, auscultation signs of the underlying disease

**Paraclinical signs:**

- the cardiopulmonary X-ray evidences cardiomegaly and pulmonary stasis

- ECG shows biventricular hypertrophy elements
- ultrasound assesses the size of the heart and provides certain etiological clues
- increased venous pressure, increased circulation times, etc.

### **5.3. VALVULAR SYNDROMES**

#### **5.3.1. MITRAL STENOSIS**

Mitral stenosis (MS) represents the narrowing of the mitral orifice accompanied by discomfort when blood passes from the left atrium to the left ventricle.

##### **Etiology**

- organic MS: AAR (almost always), congenital, rare causes: lupus erythematosus, rheumatoid polyarthritis, etc.
- relative (functional) MS: obstructions of the mitral orifice (left atrial myxoma, thrombi, vegetations, etc.), increased cardiac output through the mitral orifice (left-to-right shunt)

##### **Pathological anatomy**

Rheumatismal MS (the most frequent): thickened, fused, funnel-shaped or fish mouth-shaped valves, which do not close or open completely; significantly dilated, hypertrophied LA, normal or diminished LV; pulmonary changes secondary to mitral obstruction (fibrosis, hemosiderosis, etc.)

##### **Pathophysiology**

- mitral obstruction determines the increase of pressure in the left atrium and pulmonary veins followed by venous and subsequently arteriolar PHT (pulmonary arteriolar obstruction), right ventricular failure
- delayed and reduced left ventricular filling during diastole causing low cardiac output syndrome



- the clinical and hemodynamic picture of MS is determined by the degree of stenosis (symptoms occur at  $< 1.5$  cm), cardiac output level, pulmonary vascular resistance

### **Clinical picture**

**Symptoms:** palpitations, dyspnea, cough, precordial pain, hemoptysis, embolism, right ventricular failure.

MS represents 40% of all rheumatismal valve diseases, of which 2/3 occur in women aged less than 45 years. MS develops 3-10 years after the onset of AAR; 50% of MS cases in adults have a history of AAR episodes. Symptoms develop 10-20 years after the onset of MS (usually 25-40 years), initially during intense exercise, pregnancy, hyperthyroidism, fever; wide MS is asymptomatic.

**Dyspnea** is the most common, due to PHT, acute pulmonary edema (e.g. during labor), and improves with the onset of right ventricular failure.

**Cough:** dry, due to stasis and enlarged left atrium, or mucopurulent in stasis bronchitis.

**Hemoptysis:** it occurs in acute pulmonary edema (pink sputum), embolism and bronchitis (hemoptoic sputum), after anticoagulant therapy, in bronchial vein rupture or without an apparent cause.

**Chest pain** is the consequence of PHT, coronary embolism, coronary hypoperfusion in the context of ATH and low cardiac output (angina pectoris) or interscapulovertebral Vaquez pain (marked left ventricular hypertrophy).

**Palpitations** are due to rhythm disorders (more frequently atrial fibrillation), **dysphagia** to esophageal compression by the enlarged left atrium, and **dysphonia** (Ortner syndrome) to recurrent nerve compression by the enlarged left atrium and dilated pulmonary artery.

**Systemic embolism** (in atrial fibrillation and considerably enlarged left atrium) is more frequently cerebral and in the peripheral arteries of the limbs.

Right ventricular failure and low cardiac output syndrome have specific symptoms and signs.

**Signs:** general and cardiovascular

- mitral dwarfism in severe and early forms, malar erythrocyanosis (mitral facies)
- signs of pulmonary hypertension and low cardiac output
- parasternal and epigastric pulsations of the right ventricle (Harzer sign)
- apex beat: diminished or displaced outward (enlarged left atrium, right ventricle)
- apical fremitus palpated in left decubitus and presystolic gallop
- cardiac auscultation in MS is diagnostic:
  - ⇒ increased 1<sup>st</sup> sound (mobile valves)
  - ⇒ increased 2<sup>nd</sup> sound, split in the pulmonary focus (PHT)
  - ⇒ mitral valve opening click (MVOc): short, intense, high, at the apex, occurring 5-12 seconds after A2, inversely proportional to severity, wide radiation towards the base of the heart, it disappears with valvular fibrosis or calcification
  - ⇒ **diastolic rumble:** it starts after MVOc; at the apex, characteristic low pitch, duration correlated with severity (holosystolic in tight MS)
  - ⇒ **presystolic murmur** due to the acceleration of blood flow in LV during left atrial contraction; it disappears in atrial fibrillation
  - ⇒ rumbling, presystolic murmur increased in left decubitus, during exercise, inspiration
  - ⇒ **pulmonary hypertension signs:** increased P<sub>2</sub>, pulmonary click; right 4<sup>th</sup> and 3<sup>rd</sup> sounds, Graham Steel functional pulmonary insufficiency diastolic murmur, relative pulmonary stenosis systolic murmur, functional tricuspid insufficiency systolic murmur (sometimes).

### **Paraclinical explorations:**

**ECG:** LAH, LVH, RBBB; mitral P: wide, bifid in D I and D II; atrial fibrillation occurs.

**Chest X-ray:** large LA, large RV, increased PA, signs of stasis pulmonary hypervascularity (venous, capillary, arteriolar; e.g.: increased hilar shadows, marked vascular network up to the periphery, Kerley B, A lines), mitral calcifications.

**Mechanophonocardiogram:** absence of the rapid ventricular filling slope, MVOC at 0.04-0.12 seconds after A<sub>2</sub> (Wells index), rumbling, 1<sup>st</sup> sound.

### **Echocardiography:**

- it allows to make the diagnosis of MS (in M mode) (valve synchronism, velocity, EF slope < 35 mm/second, thickening, calcifications, LA, RV dilation, mitral orifice surface area < 1 cm<sup>2</sup> – tight MS, 1-1.5 cm<sup>2</sup> – moderate MS, > 1.5 cm<sup>2</sup> – wide MS).
- transesophageal: thrombosis in the left auricle
- Doppler: size of the LA – LV gradient.

**Catheterization and angiography:** they can be sometimes required.

### **Positive diagnosis:**

- clinical (rumbling, MVOC, accentuated 1<sup>st</sup> sound)
- echocardiography and/or other explorations (for associated lesions, the degree of lesion)

**Differential diagnosis:** from other lesions with similar stethacoustic findings:

- atrial septal defect: fixed 2<sup>nd</sup> sound splitting, ultrasound diagnosis
- constrictive pericarditis: extrinsic MS, ultrasound diagnosis
- tricuspid stenosis: increased rumble during inspiration, in the right parasternal area
- atrial myxoma: intermittent obstruction, ultrasound diagnosis

- Austin-Flint phenomenon: diastolic murmur (mitral rumble) in severe AI
- other: hyperkinetic syndrome, primary or secondary PHT, mitral disease, etc.

### 5.3.2. MITRAL INSUFFICIENCY

Mitral insufficiency (MI) consists of the incomplete closure of the mitral orifice followed by the regurgitation of blood from LV to LA.

#### **Etiology**

- organic MI: AAR, bacterial endocarditis, ATH or acute myocardial infarction with papillary muscle rupture, mitral valve prolapse, traumas
- functional MI: AHT, ischemic heart disease, aortic valve disease, cardiomyopathy (through the dilation of the valvular ring)

**Pathological anatomy:** lesions depend on etiology: valve shortening, fusion, thickening, perforation, lesion of chordae tendinae and papillary muscles.

**Pathophysiology:** changes depend on the amount of blood regurgitated into LV.

- increased pressure in LA and pulmonary veins (venous PHT), followed by arteriolar PHT and right ventricular failure
- LV volume overload (increased telediastolic volume) and left heart failure
- the degree of regurgitation and the etiology of MI determine the clinical appearance

#### **Clinical picture**

**Symptoms:** absent in mild, moderate MI

- fatigue, exertional dyspnea and orthopnea in severe MI
- palpitations (due to extrasystoles or fibrillation), more rarely hemoptysis or systemic embolism; APE more frequent in acute MI
- RVF and LVF and/or complications occur - bacterial endocarditis.

### ***Signs:***

- Cyanosis of the lips, nose and ears in severe MI
- Normal or low apex beat (enlarged LV); purring systolic thrill at the apex, increased in left lateral decubitus ± left parasternal pulsation
- Diminished 1<sup>st</sup> sound (rheumatismal MI through valve stiffness, merging with the murmur)
- Normal 2<sup>nd</sup> sound, increased or split due to PHT (± ejection click, pulmonary valve closure, left parasternal pulsation of LV)
- **Systolic murmur:** at the apex, holosystolic, regurgitation murmur (band-like, related to the 1<sup>st</sup> sound), it radiates to the axilla, as a “vapor jet”; other features (more rarely, depending on the cause): telesystolic + click (valve prolapse), crescendo appearance and radiation towards the sternum (involvement of the posterior valve), squeaking or rough (papillary muscle rupture, sclerosed valves)

***Clinical forms of mitral insufficiency:*** depending on etiology, degree of regurgitation, association (most frequently with mitral stenosis): MI in AAR, acute MI, MI in cardiomyopathy, MI in mitral valve prolapse (MVP), with different clinical pictures.

### ***Paraclinical explorations:***

***ECG:*** LVH, rarely LA overload (mitral P) signs of PHT, RVH, rhythm disorders: atrial fibrillation; various aspects depending on etiology.

***Chest X-ray:*** enlarged LA, LV, rarely PA bulging (PHT), RVH

***Phonocardiogram:*** band-like holosystolic murmur, related to the 1<sup>st</sup> sound, which continues after the aortic component of the 2<sup>nd</sup> sound in rheumatismal MI.

***Echocardiography:*** increased LA, LV, abrupt EF slope, wide septal movements, mitral annular calcification, chordae tendinae rupture, vegetations, MVP (etiological diagnosis).

***Doppler ultrasound:*** it detects and quantifies regurgitation.

**Positive diagnosis:**

- holosystolic murmur at the apex radiating to the axilla
- increased LA and LV and presence of reflux evidenced by explorations

**Differential diagnosis:** with other causes of systolic murmur at the apex:

- functional: short, protomesosystolic, non-radiating, normal cavities, without the alteration of heart sounds, varying with posture and breathing
- tricuspid insufficiency: in the xiphoid area, increased during inspiration, expansible liver
- aortic stenosis: see below
- interventricular communication: holosystolic, left parasternal area, radiating to the entire precordial area, high intensity

**5.3.3. AORTIC STENOSIS**

Aortic stenosis (AS) is an obstruction of blood flow from LV to AO. AS can be valvular, supra- and subvalvular and obstructive hypertrophic cardiomyopathy; AS is organic or functional.

**Etiology**

- Valvular AS: congenital, degenerative (ATH), rheumatismal
- Functional AS (enlarged aorta and LV): lues, ATH, Marfan syndrome, AI

**Pathological anatomy**

- Congenital AS: bicuspid valve 50% of the cases; valves become fibrous, rigid and calcified
- Acquired AS: AAR, ATH of the aorta and large arteries; it becomes calcific (annulus, coronaries, valves)

**Pathophysiology**

- LV pressure overload + concentric hypertrophy, LV decompensation

- Low systemic output: BP, pulse changes, cerebral, coronary ischemia
- Clinical manifestations depend on the degree of stenosis: LV dilation, LVF occur at a late stage

### **Clinical picture**

**Symptoms:** angor, dyspnea, syncope and acute exertional pulmonary edema

- symptoms occur during the 5<sup>th</sup>-7<sup>th</sup> decades, after many years of evolution, LVF phenomena are difficult to influence by treatment
- risk of death 2 years after the onset of heart failure, 3 years after syncope, and 5 years after exertional angina

### **Signs**

- Pulsus parvus et tardus, convergent arterial hypotension
- Apex beat shifted anteriorly and laterally (LVH + double apex beat (atrial, ventricular systole))
- **Aortic systolic thrill** and carotid thrill, aortic click
- Normal 1<sup>st</sup> sound, diminished 2<sup>nd</sup> sound (moderate forms, calcific valve)
- Late 3<sup>rd</sup> sound, prominent 4<sup>th</sup> sound
- **Systolic murmur:** at the base, radiating to the carotids, ejection murmur (crescendo-decrescendo, unrelated to the 1<sup>st</sup> or 2<sup>nd</sup> sound, rhombic); coarse, rough, 4<sup>th</sup>-6<sup>th</sup> degree, increased in sitting position with the chest leaning forward or after amyl nitrite administration, diminished in heart failure, shock, fibrillation, etc.; musical (Galavardin murmur) in the case of unfused, mobile, calcific valves in calcific ATH MS

**Paraclinical explorations:** ECG, chest X-ray, phono/carotidogram, catheterization.

**ECG:** endurance LVH ( $\pm$  LAH)

**Chest X-ray:** increased LV and poststenotic aortic dilation  $\pm$  calcifications

**Carotidogram:** characteristic aspect: prolonged notched ascending slope (cock's comb-like) due to the prolonged LV ejection.

**Phonocardiogram:** systolic murmur, alteration of sounds, click.

**Echocardiography:** calcifications, incomplete opening, aortic dilation, LVH.

**Doppler ultrasound:** it calculates the LV/AO pressure gradient.

**Catheterization, ventriculography, coronarography:** site, severity, LV function, etc.

**Positive diagnosis** is based on:

- aortic ejection systolic murmur, radiation to the carotid; fremitus (paradoxical splitting)
- LVH demonstrated clinically and by complementary explorations
- characteristic changes of carotid pulse
- ultrasound: calcifications, reduced diameter, thickened LV walls and septum, gradient by Doppler

**Differential diagnosis:** other systolic murmurs: MI, TI, PS, ASD, VSD, HOCM, etc.

- subvalvular AS has no: click, calcifications, poststenotic dilations; it occurs in childhood, membrane obstruction
- supravalvular AS: membranous or tubular, early intense coronary ATH (ECG), no ejection click, poststenotic dilation, 2<sup>nd</sup> sound, AI, systolic murmur in the 1<sup>st</sup> intercostal space, no radiation towards the apex, low LV-AO gradient
- subaortic AS through idiopathic hypertrophy: hypertrophied posteroseptum, bulging in LV during systole: syncope, angor, dyspnea + arrhythmia during exertion and stress; diagnosis: no click, poststenotic dilation, calcifications; mesocardiac murmur, no radiation; ECG: septal hypertrophy (QS), carotidogram: “rabbit ears”



### 5.3.4. AORTIC INSUFFICIENCY

Aortic insufficiency (AI) consists of the incomplete closure of the sigmoid aortic orifice during diastole with the consecutive reflux of blood from AO to LV.

#### **Etiology**

- congenital: bicuspidia, aortic coarctation, VSD
- chronic AI; acquired acute AI: rheumatismal, BE, lues, aneurysm, AO dissection, AHT, traumas, ATH, collagenosis, Marfan syndrome
- organic AI; functional AI
- lesional AI:
  - ⇒ shortening, deformation, rupture of sigmoid valves
  - ⇒ involvement of the valve annulus
  - ⇒ involvement of the aorta: aortitis (inflammatory), non-inflammatory "aortopathy"

**Pathological anatomy:** depending on etiology.

#### **Pathophysiology:**

- LV volume overload --> dilation + LV hypertrophy --> HF
- increased LV stroke volume --> increased systolic BP, wide pulsations
- the AO – LV blood reflux --> decreased systolic BP, coronary insufficiency

Clinical manifestations depend on the degree of the reflux, the orifice diameter, VA, (systemic) BP.

**Clinical picture:** AI occurs more frequently in men.

**Symptoms:** dyspnea, angor, palpitations, sweating, signs of HF, APE.

AI is well tolerated for a long time (approximately 10 years), with good exercise tolerance, cardiomegaly without heart failure; death 2-3 years after decompensation. Symptoms occur in severe AI:

palpitations, nocturnal paroxysmal dyspnea, and nocturnal angina pectoris with sweating

**Signs:** general, cardiac

*General signs:* pallor, divergent blood pressure, hyperpulsatility, arterial dance, pulsus celer et altus (Corrigan's pulse)

- *Divergent BP:* systolic BP increases, diastolic BP decreases proportionally to regurgitation.
- *Arterial dance:* visible wide pulsations of large arteries: carotids
- *Hyperpulsatility:* rhythmic movements, transmitted through arterial pulsations to the head (Musset), uvula (Muller), liver, spleen
- *Capillary pulse (Quincke)*
- *Double arterial sound (Traube)*
- *Double crural murmur (Duroziez)*
- *Pallor:* it is not present in the conjunctivae; it occurs by adrenosympathetic release stimulated by the systolic-diastolic action on receptors

*Cardiac signs:* diastolic murmur,  $\pm$  A<sub>O</sub> systolic murmur, 3<sup>rd</sup> sound, Flint rumble, A<sub>O</sub> click, dome-like shock, arterial dance, diminished 1<sup>st</sup> sound, diminished 2<sup>nd</sup> sound (A<sub>2</sub>)

- **diastolic murmur:** cardinal sign of the diagnosis of AI; the right 2<sup>nd</sup> intercostal space and the left 3<sup>rd</sup>-4<sup>th</sup> intercostal spaces in arterial AI or rheumatismal AI; merged with the 2<sup>nd</sup> sound, protomesoholodiastolic, proportional to the degree of AI; low intensity, soft, aspirating (exception: calcific, ruptured valves, lues, BE); radiation towards the apex, accentuated by increased BP, sitting, leaning forward position;  $\pm$  associated functional AS, MI, MS murmurs (presystolic Austin Flint murmur)

**Typical forms:**

- *rheumatismal:* in young people, diminished A<sub>2</sub>, high differential pressure
- *ATH:* in the elderly, accentuated A<sub>2</sub> (clangor)

- lumatic: associated aortitis (aneurysm), ostial coronaritis (nocturnal PA) low differential pressure, poor prognosis

**Complementary explorations:** ECG, X-ray, US, Phono, catheterization + angiography

**ECG:** diastolic LVH

**Chest X-ray:** "aortic heart", increased LV, dilated A<sub>o</sub>, pulsations

**Ultrasound:** LV, A<sub>o</sub> dilation, incomplete closure of AoV, AMV flutter (AI is frequently associated with MS and they mask each other); quantification of regurgitation (Doppler)

**Angiography:** it shows regurgitation (1<sup>st</sup>, 2<sup>nd</sup>, 3<sup>rd</sup> degree), ejection fraction, HF, telediastolic LV pressure, associated lesions.

**Positive diagnosis:**

- diastolic murmur, high differential pressure, hyperpulsatility
- LV increase and overload (on explorations)

**Differential diagnosis:** other diastolic murmurs: MS (Graham Steel), PI, TS, PDA, AOPF (systolic-diastolic)

- murmurs in the coronary, mammary arteries

## 5.4. PERICARDIAL SYNDROME

Acute pericarditis (AP) is the inflammation of the pericardium manifesting by precordial pain, pericardial rub and ECG abnormalities.

### 5.4.1. ACUTE FIBRINOUS PERICARDITIS

Acute fibrinous (dry) pericarditis can be the onset of effusive pericarditis or it may stop at this stage.

**Clinical picture:** pericardial syndrome: pain, pericardial rub, electrocardiographic changes

**Symptoms:** pain, dyspnea, fever, cough, weight loss

**Pain:**

- it occurs in infectious, autoimmune AP; sudden or progressive onset

- located in the precordial, retrosternal or hemithoracic area, lancinating, radiating to the back, scapular, neck region; sometimes constrictive retrosternal like in prolonged angina (without radiation to the arms)
- accentuated during inspiration, coughing, posture changes, dorsal decubitus
- improved while leaning forward
- cause: irritation of the pericardium (only the lower 1/3 has partial sensitive innervation) and of the surrounding tissues

*Dyspnea*: superficial, aggravated by fever or large collection.

**Signs**: pericardial rub (pathognomonic)

Pericardial rub:

- it allows for the certainty diagnosis of pericardial involvement (thickening of the serosa, fibrin deposit, false membranes)
- it is auscultated in the lower left margin of the sternum (mesocardiac area), during accentuated inspiration, expiration, in sitting and leaning forward position; superficial coarse character
- unrelated to systole or diastole, “floating” over heart sounds
- it has three components (recorded phonocardiographically): atrial systole, ventricular systole, rapid LV filling during protodiastole
- it changes qualitatively from one examination to the other
- differential diagnosis with murmurs (particularly mitral or tricuspid regurgitation systolic murmur) through: use of physical exercise, absence of radiation, accentuation by Valsalva maneuver and deep inspiration, different ECG and ultrasound changes

**Explorations**: ECG, X-ray, leukocytosis and increased ESR, etiological (IDR for TB, hemocultures for bacterial etiology and ASLO for AAR)

**ECG**: it shows dynamic ST-T changes; it occurs hours/days after the onset of pain, there are four evolution stages

- I. elevation of ST-T, with upper concavity + positive T wave in all the leads
- II. recovery of flattened ST-T + T, after several days
- III. isoelectric ST-T + negative T
- IV. normalization of T after weeks/months

ECG differential diagnosis with acute myocardial infarction, where there are changes in some leads, upper convexity, reciprocal changes, amputated Q or R waves.

#### 5.4.2. CHRONIC CONSTRICTIVE PERICARDITIS

Chronic constrictive pericarditis (CP) develops by the healing with fibrous tissue and the obliteration of the pericardial cavity of dry or effusive pericarditis of various etiologies.

##### **Etiology of CP:**

- TB (the most frequent: 30-70% of all cases)
- posttraumatic hemopericardium (cardiac surgery, anticoagulants)
- other less common causes: septic, viral, collagenosis, radiotherapy, etc.
- unknown: relatively frequent

**Pathophysiology:** altered ventricular filling due to pericardial stiffness

##### **Clinical picture**

**Symptoms and signs:** venous stasis (hepatic ascitic asystole with small heart described by Pick)

- edemas, ascites, hepatomegaly, dyspepsia (systemic venous congestion)
- exertional dyspnea, cough, orthopnea (pulmonary congestion)
- fatigue, weight loss, muscle wasting (low cardiac output)
- turgescient jugular veins in sitting position and during inspiration
- systolic retraction of the apex, pericardial click

- hepatomegaly with hepato-jugular reflux + congestive splenomegaly
- ascites, jaundice, vascular stars, palmar erythrosis + lower limb edema
- cachexia predominant in the upper half of the body

**Explorations:** X-ray (calcifications), ECG, cardiac ultrasound, other explorations.

**Diagnosis:** jugular distension, unexplained pericardial collection, hepatomegaly and ascites.

## 5.5. ISCHEMIC HEART DISEASE

Ischemic heart disease (IHD) is the ischemic disease of the myocardium, being most frequently caused by atherosclerosis.

### 5.5.1. ANGINA PECTORIS

Angina pectoris (AP) is short duration coronary pain caused by myocardial ischemia that stops before the appearance of cell lesions.

**Classification:**

- *Stable exertional AP* that occurs constantly during exercise of a certain intensity.
- *Unstable AP* that frequently evolves towards AMI.
- *Unstable (crescendo angina):* angina of increasing frequency and severity; occurs on minimal exertion or at rest; associated with increased risk of MI.
- *Decubitus angina:* precipitated by lying flat.
- *Variant (Prinzmetal's angina):* caused by coronary artery spasm (rare, may coexist with fixed stenosis).

**Causes**

Mostly atheroma. Rarely: anemia, aortic stenosis; tachyarrhythmias; HCM; arteritis/small vessel disease (microvascular angina/cardiac syndrome X).

## *Stable exertional angina pectoris*

### **Pathophysiology of stable exertional AP:**

- it occurs when myocardial oxygen demand (consumption) is higher than supply (myocardial ischemia)
- the angina threshold is the level of exercise at which AP develops, being expressed by the “double product” (systolic blood pressure x heart rate)
- there is a fixed angina threshold when the degree of coronary obstruction and oxygen consumption are constant
- superadded **coronary** spasm causes AP during less intense exercise
- AP pain is triggered by ischemia through the production of some substances: adenosine, bradykinin, histamine and is projected onto the peripheral territory corresponding to the medullary segment that innervates the heart

### **Clinical picture of stable exertional AP**

Coronary pain in AP has the following characteristics:

- location: typically, retrosternal; or anywhere between the umbilicus and the maxilla
- typical radiation to the cubital margin of the left upper limb; also to the left shoulder, interscapular, maxillary, epigastric area, upper limb, right shoulder
- duration: up to 15 minutes
- character: pressure, squeezing
- circumstances of appearance: triggered by exercise of a certain intensity, for example: walking, running, climbing stairs, digestive or sexual exertion, emotions, cold weather, etc.; the angina threshold can be fixed or variable (due to associated factors)
- circumstances of disappearance: cessation of exercise (or its decrease below the angina threshold), 1-5 minutes after sublingual nitroglycerine administration

- associated phenomena: anxiety, dyspnea, eructations, palpitations, polyuria, sweatiness, faintness, nausea

AP can be "atypical" through the character of pain or the nature of the triggering factors.

**The objective examination of the heart:** it can be negative during crisis or the following occur: tachycardia, 4<sup>th</sup> sound, 3<sup>rd</sup> sound, systolic murmur (functional MI) and other signs of the background disease or extracardiac manifestations.

**Paraclinical examinations:**

**ECG at rest:** it shows ventricular myocardial ischemia (subendocardial area).

- horizontal or slanting ST depression > 1 mm in bipolar chest leads, > 2 mm in unipolar chest leads.
- it can be **normal** – it does not refute the diagnosis of AP.

**Exercise test:**

- maximal (ventricular rate = 220 - age), submaximal (85% of maximal test), limited by symptoms: AP, dyspnea, fatigue, arrhythmia, etc.
- it indicates: the presence, severity, extension of coronary ATH (prognostic significance); the normal test does not exclude ischemic heart disease.
- it is useful in AP + normal rest ECG, atypical AP, typical AP
- changes suggestive of AP: horizontal ST depression (> 2mm) or descending depression (> 1mm)
- false positive and false negative results are possible, they will be excluded.

**Contrast substance coronography:**

- it shows atheromatous coronary stenosis + distal and collateral circulation.
- indications: refractory AP (for surgery), negative test AP (for diagnosis), AP with severe ischemia.



**Biochemical tests:** normal cardiac enzymes  $\pm$  hypercholesterolemia (HLP II, IV), diabetes mellitus or decreased glucose tolerance.

**Differential diagnosis:** it is that of chest pain:

- retrosternal esophageal pain in reflux esophagitis (burn and postural regurgitation), in esophageal spasm
- intercostal neuralgia, myalgia, spondylosis: weather sensitive, increased by spinal movements, long duration, not improved by nitroglycerine
- TIETZE syndrome: chondrocostal pain
- digestive causes: ulcer, biliary lithiasis (rhythmic pain accompanying eating)
- other forms of pain: pericarditis, pleurisy, pneumonia, pulmonary infarction, pneumothorax (considered for the first AP episode)
- AMI (prolonged AP)
- AP may coexist with other diseases: digestive, vertebral, etc.

## **ACUTE CORONARY SYNDROMES (ACS).**

ACS includes unstable angina and evolving MI, which share a common underlying pathology-plaque rupture, thrombosis, and inflammation. However, ACS may rarely be due to emboli or coronary spasm in normal coronary arteries, or vasculitis.

Usually divided into *ACS with ST-segment elevation or new onset LBBB* - what most of us mean by acute MI; and *ACS without ST-segment elevation* - the ECG may show ST depression, T wave inversion, non-specific changes, or be normal (includes non-Q wave or subendocardial MI). The degree of irreversible myocyte death varies, and significant necrosis can occur without ST elevation.

### ***Unstable angina pectoris***

Unstable AP (UAP) is a severe form of AP, with a high risk of developing into MI

## **Etiopathogeny of UAP**

- multitruncular coronary ATH with complicated atheroma plaques associated with
- coronary spasm, platelet aggregation, non-occlusive thrombi

### **Clinical forms of UAP:**

- aggravated exertional angina pectoris ("crescendo angina"): exertional AP with more frequent, more severe episodes, more difficult to influence by treatment
- de novo exertional AP: AP starting in the month preceding the consultation occurs during minimal exertion
- rest (spontaneous) AP
- AP occurring soon after MI
- Braunwald's classification of UAP: depending on severity, clinical circumstances of appearance and intensity of treatment

### **Clinical picture:** pain in UAP has the following characteristics:

- it is more intense, it has a longer duration (it can reach 30 minutes)
- it improves with difficulty, incompletely and temporarily by nitroglycerine administration
- it changes its character as follows: the angina threshold suddenly decreases, frequency, severity and duration increase, it radiates to a new or additional site, new elements appear: sweating, nausea, palpitations

The objective examination is non-characteristic, like in exertional AP or in AMI

### **Paraclinical explorations:**

#### **ECG at rest:**

- normal or with ischemia (significant ST-T depression)
- changes are variable and reversible

**Exercise test:** performed after stabilization by treatment (prognostic role)

**Coronarography:** UAP refractory to therapy.

**Prinzmetal angina:** is due to coronary spasm, which can occur even in normal coronary arteries. Pain usually occurs during rest (rather than during activity). Patients usually do not have the usual risk factors of atherosclerosis. Treatment: calcium channel blockers+/-long acting nitrates. Aspirin can aggravate the ischemic attacks and betablockers (nonselective) can increase vasospasm in these patients. Prognosis is usually very good.

## 5.5.2. ACUTE MYOCARDIAL INFARCTION

Acute myocardial infarction (AMI) is the ischemic necrosis of a myocardial area due to a sudden decrease in coronary blood flow or a sudden increase in myocardial oxygen demand.

### **Etiology:**

Coronary ATH + risk factors for ATH: HLP, AHT, DM, smoking, obesity.

**Clinical picture:** coronary pain, complications (shock, arrhythmia, LVF).

### **Symptoms:**

- pain: dominant, it can be typical (location, radiation, surface area like in AP):
  - ⇒ duration longer than 30 minutes (hours, absent 1/3)
  - ⇒ high intensity, atrocious, more severe than the previous
  - ⇒ retrosternal, radiating to the shoulder and arms; crushing, constriction
  - ⇒ it does not respond to nitroglycerine, relieved by opioids
  - ⇒ frequent associated phenomena: sweating, palpitations, extreme asthenia, dyspnea, dizziness, dyspeptic disorders, great anxiety, agitation in search for a position
- complications:
  - ⇒ shock, hypotension, arrhythmia or blocks: intense asthenia, dizziness, cold sweating, confusion, lipothymia

⇒ nausea, vomiting: vagal hypertonia

⇒ dyspnea: left VF

**Signs:** suggestive but non-specific

- temperature: sometimes subfebrility after 24 hours; fever in extensive forms; it persists up to 7-10 days
- pulse: tachycardia, bradycardia or normal
- blood pressure: it usually decreases progressively (it can be high at onset)
- the respiratory system: dyspnea and stasis rales (LVF)
- examination of the heart
  - ⇒ decreased apex beat
  - ⇒ paradoxical mesocardiac pulsations (aneurysm, dyskinesia in previous MI)
  - ⇒ deaf heart sounds
  - ⇒ paradoxical splitting of the 2<sup>nd</sup> sound (prolongation of LV ejection)
  - ⇒ 4<sup>th</sup> sound (decreased compliance, usually in AMI)
  - ⇒ 3<sup>rd</sup> sound (gallop, it clearly shows LVF, poor prognosis, high mortality)
  - ⇒ transient systolic murmurs (crus muscle dysfunction, papillary muscle ischemia, LV dilation)
  - ⇒ permanent systolic murmurs (crus muscle rupture, septal rupture)
  - ⇒ pericardial rub: transient, during presystole, systole, protodiastole; suggestive of AMI, it indicates epistenocardiac pericarditis
- examination of carotids: it shows output (amplitude), rapid pulse in septal rupture, MI
- examination of jugulars: turgescence, collapsed, systolic pulse
- examination of peripheral arteries: associated arteriopathies, embolism

- examination of the abdomen: for the exclusion of abdominal disorders
- pallor, neuropsychic disorders

**Paraclinical explorations:**

**ECG:** it allows for positive diagnosis, location, extension, some complications (arrhythmia); it requires repeated recordings; normal ECG does not exclude diagnosis.

*"direct" changes* (recorded by the electrodes corresponding to the infarction area)

- ⇒ the first hours: elevated ST with the concavity, then the convexity upward (lesion aspect)
- ⇒ after 8-12 hours: pathological Q wave (> 0.3 sec., amplitude > 3mm, > 1/3 of R) or QS (necrosis aspect)
- ⇒ T waves become negative, symmetrical, sharp (ischemia aspect)

The characteristic ECG aspect of AMI is: necrosis, lesion, ischemia.

- ⇒ during evolution (days): Q and T become deeper, R waves decrease progressively, ST decreases progressively (at 10-14 days isoelectric ST)
- ⇒ finally: pathological Q, small r, ischemic T (they persist or partially disappear)

- *"indirect" changes:* mirror changes in the opposite leads
- the location and extension of direct changes are indicative of the location and extension of AMI, e.g.:
  - ⇒ lower AMI: DII, DIII, aVF
  - ⇒ anterior AMI: DI, DII, aVL, V<sub>1-6</sub>.
- the absence of the pathological Q wave (with enzymatically demonstrated necrosis) occurs in "non-Q" AMI
- diagnosis of AMI at a stage useful for reperfusion therapy: coronary pain > 30 minutes, significantly elevated ST (lesion)

**Enzyme changes:** they indicate myocardial necrosis; CPK-MB, LDH<sub>1</sub> isoenzyme, ASAT, myoglobin, troponins.

- **CPK:** it increases at 3-6 hours, with normalization after 3-4 days, CPK-MB is specific for myocardial necrosis
- **LDH:** it increases at 24-48 hours, with normalization after 8-14 days, useful for retrospective diagnosis
- **ASAT:** it increases at 8-12 hours, with normalization after 8-14 days
- **Myoglobin:** it increases at 30-60 minutes
- **Troponins T and I:** specific and sensitive, they occur early and last for days

**Radioisotopic explorations:** necrosed myocardium (pyrophosphate), viable (thallium).

**Coronarography:** it determines stenosis, it allows angioplasty as a first therapeutic option.

**Other examinations:** leukocytosis, hyperglycemia, increased ESR; US, phono, catheterization etc. (sometimes).

**AMI diagnosis:** coronary pain + myocardial necrosis (pathological Q wave, high enzymes, isotopic).

- typical pain: more than 30 minutes, intense, extensive, uninfluenced by NTG/rest;
- atypical forms of manifestation:
  - ⇒ atypical pain: epigastrium --> biliary colic, ulcer, acute pancreatitis
  - ⇒ shoulder --> periarthritis
  - ⇒ absence of pain
  - ⇒ Predominance of complications: LVF, CVA, shock, arrhythmia, CHF, asthenia, etc.
  - ⇒ predominance of digestive manifestations

**Atypical AMI picture (no pain - 20%):**

- cerebral forms (ictus, agitation, confusion, drowsiness)
- forms with APE or CHF with sudden onset

- forms with extreme physical asthenia
- pseudoinfluenza forms
- digestive forms (dyspepsia, acute abdomen)
- forms with cardiogenic shock
- forms with rhythm disorders or atrioventricular blocks
- forms with sudden death

**Differential diagnosis of AMI:** with AP, other cardiac, thoracic, digestive diseases

- with AP: duration less than 30 minutes, improved by NTG/rest, normal enzymes/no necrosis on ECG
- massive pulmonary embolism: embologenic context (thrombophlebitis), ECG: right loading
- acute pericarditis: absence of mirror changes, diffuse ECG changes, fever from onset
- aortic dissection: severe AHT + atrocious pain + shock appearance + acute AI
- neuromyalgia and chest cellulitis: local sensitivity increased by breathing, absence of necrosis
- spontaneous pneumothorax: tympanicity + respiratory silence + dyspnea + characteristic chest X-ray
- pleurisy (pleurodynia): infectious context, increased by breathing, absence of necrosis
- acute pancreatitis: difficult diagnosis with lower AMI; absence of necrosis; increased amylase levels
- perforated ulcer: pneumoperitoneum.

## 5.6. RHYTHM AND CONDUCTION DISORDERS

Cardiac arrhythmias (CA) are cardiac rhythm abnormalities derived from disorders of the emission or conduction of the electric stimulus initiating cardiac activity.

CA can be tachyarrhythmias or bradyarrhythmias; conduction disorders represent slowed conduction by normal or aberrant pathways.

**The causes of CA** are various (single or multiple), like the mechanisms of CA, usually being an epiphenomenon of other cardiac or extracardiac diseases (“complications”).

**The consequences of CA** are the appearance or aggravation of acute or chronic HF (“mechanical risk”), of chronic or acute coronary, cerebral ischemia (“ischemic risk”), of other more severe arrhythmias (“electrical risk”) or of systemic embolism (“embolic risk”).

### **General clinical picture of CA**

#### **Symptoms:**

- asymptomatic or palpitations, irregular cardiac rhythm
- low cardiac output manifestations: dizziness, weakness, sensory disorders
- cerebral, coronary, peripheral ischemia manifestations

**Signs:** they can be missing between arrhythmia episodes.

- Specific signs of CA:
  - ⇒ premature beats followed by pauses, on a regular or variable (sinus) rhythm background
  - ⇒ regular variable tachycardic rhythm (during breathing, movement) or fixed tachycardic rhythm (fixed tachycardia)
  - ⇒ completely irregular rhythm (complete arrhythmia)
  - ⇒ regular bradycardic rhythm: regular variable (with breathing, exercise) or regular fixed or regular with intercalated pauses



⇒ vagal maneuvers used: the massage of the carotid sinus, the pressure of the eyeballs, the Valsalva maneuver can improve or temporarily reduce to half the heart rate

- signs or symptoms of the background cardiac disease or CA complications: acute or global LVF, low cardiac output, shock, coronary ischemia, etc.

### **Approach and clinical diagnosis of CA**

The diagnosis of CA establishes: its nature (tachy-/bradycardia, supra/ventricular, excitability/conduction), severity, consequences, heart status, causes.

CA are complications of other cardiac or extracardiac diseases.

**Paraclinical explorations:** ECG, Holter, exercise, esophageal, high resolution, intracavitary, programmed endocavitary electrical stimulation.

## **5.6.1. SUPRAVENTRICULAR TACHYARRHYTHMIA**

Paroxysmal supraventricular tachycardia (PSVT)

**Etiology:** idiopathic, without severity significance

It starts in childhood, repeated well tolerated episodes until ischemic heart disease develops.

**Pathogenesis:** re-entry mechanism, pathological or postpotential automatism.

### **Clinical picture**

- palpitations suddenly occurring during the crisis, lasting for minutes-hours.
- they cease suddenly, spontaneously or following vagal maneuvers + postcritical polyuria
- tachycardia 150-220/minute, fixed, with a regular rhythm

### **ECG:**

- fine basal QRS, at rigorously exact time intervals, high rate
- P are absent or precede, follow QRS

## ***Atrial fibrillation (AF)***

AF involves the cessation of the activity of the sinoatrial node (and consequently the disappearance of sinus rhythm) and its replacement by very many atrial depolarizations that cause ineffective atrial contractions (cardiac output decreases by 30%).

### **Etiopathogeny**

The electrophysiological substrate of AF consists of multiple re-entry circuits; part of atrial stimuli are transmitted to the ventricle so that ventricular rate can be high, medium, low.

### **Causes**

- Paroxysmal AF (with onset less than 6 weeks): chronic respiratory failure, heart diseases with atrial hypertrophy, in healthy subjects in stress.
- Chronic AF: mitral valve disease, ischemic heart disease, hyperthyroidism, AHT, cardiomyopathy, idiopathic.

**Clinical picture:** complete arrhythmia  $\pm$  its consequences: HF, shock, ischemia, embolism.

**ECG:** it confirms diagnosis by:

- absence of P waves, their replacement by extremely frequent, irregular, very "small" waves;
- Completely irregular QRS.

## ***Atrial flutter (AFL)***

### **Etiopathogeny**

The electrophysiological substrate of AFL consists of the replacement of sinus rhythm by approximately 300 atrial depolarization waves/minute (re-entry mechanism); transmission to the ventricle is 2:1 or 4:1 (ventricular rate 150 or 75).

### **Etiology:**

- Organic heart disease, mitral valve disease, ischemic heart disease, cardiomyopathy, chronic respiratory failure, hyperthyroidism, etc.

- Atrial flutter is usually paroxysmal and more rarely chronic (it develops into AF during the course of a week)

**Clinical picture:**

- regular, fixed tachycardia 150/minute (2:1) or 75/minute (4:1) or complete arrhythmia (irregular atrioventricular transmission)
- vagal maneuvers can temporarily change AFL from 150 to 75

**ECG:**

- it provides the diagnosis of AFL
- where F (instead of P waves) are regular, equal, without an isoelectric line, 300/minute, saw teeth-like, in DII, III, aVF, V1.
- QRS 150 or 75/minute, regular or irregular.

**5.6.2. VENTRICULAR TACHYARRHYTHMIA**

*Ventricular extrasystoles (VEx)*

**Etiopathogeny**

VEx occur by a re-entry mechanism (they have a fixed coupling) or by an automatic mechanism (parasystole; through “en entry block”). Differential diagnosis with “escape beats”: they occur in bradyarrhythmia; they are atrioventricular, junctional or ventricular.

**Etiology:** organic heart disease (80% in AMI), as well as in healthy subjects.

**Clinical picture:** palpitations (premature beats + pauses), dizziness.

**ECG:** wide QRS  $\geq 0.14$  sec., bizarre, secondary ST-T deviation + pause, P are not visible.

**Classification:** with fixed coupling, with variable coupling (“summation beats”), interpolated, bigeminy, trigeminy, paroxysmal ventricular tachycardia, monomorphic or polymorphic, unifocal or multifocal.

LOWN classification (class): 0, 1, 2, 3, 4A, 4B, 5; classes 2-5 are considered "complicated" due to the risk of “malignant” ventricular

tachyarrhythmia; the (altered) myocardial background is a major determinant of the significance of VEx.

### ***Paroxysmal ventricular tachycardia (PVT)***

PVT is the regular and rapid succession of ectopic ventricular beats more than 100/min.; it occurs in the His bundle (below the bifurcation) and branches, in the ventricle or both; by re-entry mechanism, automatism or both.

**Etiology:** severe myocardial lesions (severe organic heart disease: myocardial infarction, aortic valve disease, cardiomyopathy) more frequently in active coronary ischemia, hemodynamic deterioration.

PVT can be:

- sustained (more than 30 sec. or severe hemodynamic disorders)
- unsustained (less than 30 sec. or without severe hemodynamic disorders)

**Clinical picture:** it depends on the duration of PVT, frequency, the background heart disease (e.g. severe heart disease + PVT determines: syncope, shock, left ventricular failure); on objective examination: regular and fixed tachycardia  $\pm$  "cannon noise", pathological 3<sup>rd</sup> sound (LVF)

ECG:

- certainty diagnosis
- wide QRS, with VEx appearance, mono/polymorphic, P are not visible.
- differential diagnosis with: PSVT, AFL with WPW syndrome, complete right or left bundle branch block (there are multiple ECG differentiation criteria)

### 5.6.3. BRADYARRHYTHMIA

#### *Sick sinus syndrome*

Sick sinus syndrome (SSS) occurs through the degenerescence of the SA node, manifesting by:

Bradycardic rhythm: bradycardia, sinus arrest, sinoatrial block

- + validation of rapid supraventricular rhythm (PSVT, AF)
- + atrioventricular blocks through the alteration of the AV node
- + alternance of bradycardia and tachyarrhythmia (bradycardia-tachycardia syndrome).

#### **Clinical picture**

##### *Symptoms:*

- small cardiac output syndrome (fatigue)
- congestive heart failure, cerebral circulatory insufficiency, etc.
- dizziness and syncope (more than 3 sec. pause)

*Signs:* sinus bradycardia, long or intermittent pauses (in blocks)

##### *ECG:*

- basal QRS sinus bradycardia less than 60/min.
- sinoatrial block: changed P-T intervals; progressive elongation + pause fixed elongation 2:1
- Holter monitoring: for intermittent arrhythmia, coincidence of symptoms
- Atrioventricular blocks (AVB)

##### **Etiopathogeny:**

- coronary ischemia: lower AMI (junctional block), anterior AMI (subjunctional block – with more severe evolution)
- degenerescence and idiopathic fibrosis of the excitoconductor system (Lenegre disease)
- vagal hypertonia, overdose: Verapamil, Digoxin, beta-blockers
- myocardial inflammation (diphtheria, AAR, viral), myocardial infiltration; congenital AVB

## Clinical picture

- asymptomatic
- symptoms and signs: CHF, low cardiac output, Adam-Stokes syncope: sudden loss of consciousness, pallor, seizures, bradycardia or cardiac arrest.
- other manifestations: in 2<sup>nd</sup> degree block, pauses occur; in 3<sup>rd</sup> degree block, there is fixed bradycardia 40-60/min. (junctional AVB), less than 40/min. Subjunctional AVB + “cannon noise”, echo systoles, isolated systolic AHT.

### ECG:

- 1<sup>st</sup> degree AVB: elongated PR more than 0.20 sec.
- 2<sup>nd</sup> degree AVB:
  - ⇒ Mobitz I: Wenckenbach periods occur: prolonged elongation of PR + pause (absence of P)
  - ⇒ Mobitz II: normal PR + pauses (absence of P)
  - ⇒ high degree: 2:1, 3:1, 4:1, i.e. the regular blockage of the P wave
- 3<sup>rd</sup> degree AVB: atrial activity (P) unrelated to ventricular activity (QRS); fixed bradycardia 40-60/min. + basal QRS; less than 40/min + widened QRS;
- the intracavitary ECG of the His bundle determines the location of AVB: sub-, intra-, suprahisian.

## 5.7. SHOCK, SYNCOPE, LIPOTHYMIA

### 5.7.1. SHOCK

Shock is a syndrome characterized by low tissue perfusion, acute and persistent decrease in effective circulating blood volume followed by tissue hypoxia and its consequences; it is an acute hemodynamic and metabolic process resulting from a disequilibrium between the vascular bed and intravascular fluid volume and,

consequently, not the decrease in BP, but the state of tissue blood supply is characteristic of shock.

**Etiopathogeny:** four types (forms) of shock:

- hypovolemic: through blood and plasma, water and electrolyte losses
- Cardiogenic through AMI, mechanical factors, rhythm disorders, etc.
- septic: in severe, usually gram-negative infections
- through the pooling of blood at the periphery: anaphylactic, vasogenic, neurogenic, peritonitis, acute pancreatitis

**Pathophysiology:** four links that appear in the chain:

- neuroendocrine with the triggering of compensatory reactions:
  - ⇒ increase in sympathetic tone and circulating catecholamines with arteriolar vasoconstriction
  - ⇒ “centralization of circulation” in the brain, heart and the “sacrificing” of some territories: skin, muscle, viscera (kidney, liver)
  - ⇒ the endocrine phase: ACTH, cortisone for the protection of carbohydrate reserves, Na retention
  - ⇒ the prolongation of this phase causes cellular and visceral lesions in the deprived organs
- hemodynamic with the diminution of (capillary) tissue blood flow and pooling
- metabolic with hypoxia and acidosis
- morphofunctional visceral lesions due to stasis, hemoconcentration (sludging), hypoxic endothelial lesions, disseminated coagulation, consumption coagulopathy

**Clinical picture**

*Symptoms:*

- asthenia, faint whispering voice, thirst, the patient is walking
- anxiety, agitation, then torpor, coma

### **Signs:**

- skin: pale, cold, sweating at the extremities, then marbled, gray, cyanotic (except for toxic infectious shock, when it is warm, pink)
- clinical assessment elements: temperature, increased weak pulse, systolic BP < 80, diastolic BP < 50, collapsed veins, tachypnea, oliguria

### **Paraclinical explorations:** they assess severity:

- leukocytosis, eosinopenia, hyperglycemia
- serum enzymes, serum electrolytes, renal function, blood gases, pH
- chest X-ray, ECG, CVP + PAP, bacteriological examination
- the number and results of the explorations depend on the type of shock, although some changes are common: acidosis, hypoxia, etc.

**Evolution** is from the “compensated” phase through the “centralization of circulation” to aggravation, passing to the reversible phase (hypotension, severe hypoxemia) and finally, to the irreversible phase (organ failure).

## **5.7.2. SYNCOPE, LIPOTHYmia**

**Syncope** is a syndrome that consists of the sudden loss of consciousness and locomotion, with the suppression of vital functions, lasting for seconds.

**Lipothymia** or fainting is the incomplete loss of consciousness (obnubilation), with the slowing, not the suppression of vegetative functions, lasting for minutes (exceptionally hours).

### **Classification of syncopes:** pathogenetic:

- circulatory: inadequate vasoconstriction, hypovolemia, reduced venous return, decreased cardiac output, rhythm disorders, cerebral circulatory disorders
- metabolic: hypoxic, hyperventilation, hypoglycemic

### **Clinical picture**

**Syncope:** loss of consciousness, pallor, muscle flaccidity, insensitivity to stimuli + seizures, mydriasis (after 10 seconds) and



death or recovery; collapsed BP, imperceptible breathing, absent or weak pulse.

**Lipothymia:** it has a more graded, less dramatic picture; there is a prodrome with dizziness, asthenia, vision disorders; the loss of consciousness is neither total nor profound; there are perceptible breathing movements or heart beats; decubitus does not improve symptoms; a degree of obnubilation, asthenia persist.

**Diagnosis:** anamnesis and objective examination allow the diagnosis of non-cardiac synopes, some cardiac synopes, etc.; explorations depend on the clinical context, the degree of emergency (for example, glycemia, ECG, etc.).

## 5.8. ARTERIAL HYPERTENSION

Arterial hypertension (AHT) is the increase of systolic and/or diastolic blood pressure to values that determine the increase of risk for cardiovascular events.

Normal BP values: systolic BP < 130 mmHg, diastolic BP < 85 mmHg; AHT: systolic BP > 140 mmHg, diastolic BP > 90 mmHg.

### Classification of AHT:

- depending on BP values:

<b>normal BP (mmHg)</b>	<b>systolic BP &lt; 130</b>	<b>diastolic BP &lt; 85</b>
normally high BP	130 - 139	85 - 89
mild AHT (1 <sup>st</sup> stage)	140 - 159	90 - 99
moderate AHT (2 <sup>nd</sup> stage)	160 - 179	100 - 109
severe AHT (3 <sup>rd</sup> stage)	180 - 209	110 - 119
extremely severe AHT (4 <sup>th</sup> stage)	≥ 210	≥ 120

- systolic and diastolic; isolated systolic (sBP > 160 mm Hg)

- sBP 140 – 159 mmHg and dBP 85 – 94 mmHg with oscillation represent border AHT

### **Etiopathogeny:**

Normal BP depends on: cardiac output, systemic arteriolar and large vessel (aortic) resistance, circulating blood mass; their changes cause: elasticity BP (sBP increases), resistance BP (dBP increases most frequently), output BP (sBP increases).

- **Etiopathogenic classification:**

⇒ *systolic and diastolic AHT* (peripheral arteriolar resistance usually increases)

⇒ *essential AHT* (primary, idiopathic): 92 - 94% of the cases

⇒ *secondary AHT:*

- renal (3-4%): parenchymatous nephropathies (CPN, CGN, AGN), polycystic kidney, DM, renovascular, TU, renoprival nephropathy
- endocrine: acromegaly, hyperthyroidism, Cushing disease, primary aldosteronism, hypercalcemia, etc.
- aortic coarctation, pregnancy, neurological diseases: acute intracranial hypertension, tetraplegia, porphyria, etc.
- acute stress, ethylism, etc.

⇒ *systolic AHT*, with large systolic-diastolic difference

- decrease in aortic compliance (arteriosclerosis)
- increase in cardiac output: AI, hyperthyroidism, fever, arteriovenous fistulas.

### **Clinical picture of essential AHT:**

AHT occurs more frequently at 30 years of age; there is a family history of AHT in parents, blood relatives.

*Symptoms:* absent or occipital cephalgia, more frequently in the morning, dizziness, palpitations, sharp precordial pain and various complications of AHT: angina pectoris, dyspnea and HF, CVA, intracranial hypertension.

**Signs:** increased dBP  $\pm$  sBP, higher in the morning  $\pm$  nycthemeral oscillation, even AHT crises ("pressure Holter "). Signs can be absent or present, accentuated 2<sup>nd</sup> aortic sound + left 4<sup>th</sup> sound  $\pm$  accentuated apex beat, over a large area  $\pm$  obesity, plethoric facies  $\pm$  rhythm disorders or murmurs, LV gallop, central paresis or paralysis (representing complications or associations of AHT).

**Explorations:**

**ECG:** LVH  $\pm$  ischemia when ischemic heart disease is associated.

**Chest X-ray:** LV dilation

**Echocardiography:** thickening of the LV wall, enlarged LA, diastolic function disorders.

**Ophthalmoscopic examination:** increased BP CR + eye fundus changes of various degrees (1-4 according to Keith Wegener): progressive reduction of the artery/vein ratio, arterial spasm, hemorrhage, exudates, papillary edema (1<sup>st</sup> degree: decrease in the artery/vein ratio, 2<sup>nd</sup> degree: + artery/vein crossing sign, arterial spasm, 3<sup>rd</sup> degree + hemorrhage and exudate, 4<sup>th</sup> degree + edema of the optic nerve papilla).

Exploration of the renal function, laboratory examination of complications and associated diseases (diabetes mellitus, dyslipidemia, hyperuricemia, etc.).

**Diagnosis of AHT:**

- *Positive diagnosis:* presence of AHT, its character: related to resistance, elasticity or output, severity and cardiovascular risk (pressure level, crises and oscillations, reaction to treatment)
- *Etiological diagnosis:* essential, supported by history, absence of a cause, obesity, diabetes mellitus, associated or secondary dyslipidemia (age < 20 or > 50 years, BP > 180/110 mmHg, clinical and paraclinical elements for a certain cause: renal, endocrine, etc., rapid evolution, with visceral repercussions and complications)

- *Diagnosis of evolution, consequences and complications:* according to WHO classification: 1<sup>st</sup> degree (absence of organic changes), 2<sup>nd</sup> degree (arterial spasm, LVH, proteinemia  $\pm$  increased creatinine levels – one of these), 3<sup>rd</sup> degree (cerebral hemorrhage, hypertensive encephalopathy, LVF, renal failure, etc.).
- *Diagnosis of morbid associations:* obesity, ATH, diabetes mellitus, hyperuricemia, etc.

## **5.9. CHRONIC OBLITERATING ARTERIOPATHY OF THE LOWER LIMBS**

Chronic obliterating arteriopathy of the lower limbs is the stenosis or obstruction of arteries with secondary ischemia.

**Etiology of ATH:** (>90%) more frequent location in the terminal aorta of the lower limbs; arteritis: with giant cells (Burger, Horton, Takayashu disease), in collagenosis.

**Pathophysiology:** calcium is deposited in atheroma plaques, the thinning of the media and the formation of thrombi occur. This will lead to arterial obstruction or stenosis, with symptoms appearing at a 75% decrease in the vascular lumen, which will result in the reduction of blood flow distal to the obstruction and the increase of collateral circulation.

### **Clinical picture**

There are four stages (Leriche and Fontaine):

I: asymptomatic: diminution of arterial pulse, arterial murmurs.

II: intermittent claudication: pain when walking up a slope, then walking on flat ground, located in the muscle below stenosis: buttock, thigh, calf. The “walking perimeter” (claudication index) is proportional to the severity of stenosis: more than 500 m IIA, less than 500 m IIB.

III. the stage of decubitus pain, in which pain occurs at rest, at night, late or early after clinostatism and is improved when the leg is lowered at the margin of the bed.

IV. the stage of trophic disorders: ulcer or gangrene through severe ischemia.

**Objective examination:** diminished pulse, arterial murmurs, skin alterations with the socket sign (pallor when the leg is elevated and redness through reactive hyperemia when it is lowered). Skin and muscle atrophy with thinned, shiny, dry, cold, pale skin, hair loss, as well as thickened and deformed nails.

**Paraclinical explorations:**

- peripheral arterial Doppler examination in order to identify stenosis
- measurement of distal arterial pressures (posterior and anterior tibial, dorsalis pedis arteries) with the Doppler probe
- the treadmill walking test (coupled with the Doppler determination of distal pressures) – normally, distal pressure after exercise increases slightly; in arteriopathic patients it decreases
- arterial ultrasound, including color Doppler – e.g., in stenosis there are turbulent flows with a mosaic of colors, in thrombosis there is no flow and the collaterals appear as multiple small areas with continuous flow
- measurement of the systolic pressure of the hallux using plethysmography (in diabetic patients!)

**Chronic critical arterial ischemia** indicates extremely severe ischemia in which there is a risk for the amputation of the affected limb (persistent rest pain requiring medication for more than 2 weeks or trophic disorders such as ulcer or gangrene).

- plain abdominal X-ray: calcifications of the abdominal aorta
- peripheral arteriography - Seldinger's technique via the femoral vein is indicated if revascularization is considered (angioplasty, surgical bypass), particularly in the case of chronic critical ischemia
- biochemical examination: full blood count, thrombocytes, glycemia, electrolytes, cholesterol, TG, HDL, fibrinogen, ESR, QT

### **Differential diagnosis:**

⇒ other arteriopathies:

- young smoking men with obliterating thromboangiitis
- collagenosis: SLE, PAN, SD
- infectious diseases: syphilis, rickettsiosis

⇒ other diseases that mimic arterial pathology: sciatica, coxarthrosis, gonarthrosis.

## **5.10. THROMBOTIC SYNDROME**

Clinical consequences of an intravascular thrombus in veins.

### **Factors:**

- determining factors:
  - ⇒ parietal lesions, traumas, i.v. injections
  - ⇒ venous stasis: congestive heart failure, hypovolemia
  - ⇒ alteration of the fluid – coagulant balance: hypercoagulability, thrombocytes
- triggering factors: trauma, surgical/obstetric interventions
- favoring factors: pregnancy, cardiovascular disorders, obesity, diabetes mellitus, atherosclerosis, neoplasms, infections, drugs (diuretics, digitalis, cortisone, etc.)
- formation of the venous thrombus: phlebothrombosis

### **Superficial thrombotic syndrome**

- on a varicose background, secondary to trauma, surgical interventions: fever/subfever, venous pain, red hot skin, pain on palpation, hard and painful cord, local edema
- post-drug superficial thrombosis after i.v. injections with irritating substances/catheterization
- migratory superficial thrombosis: latent infections, neoplasms, Burger's disease

### **Deep thrombotic syndrome:**

- at the level of the deep calf veins:
- spontaneous/induced pain: paresthesia, weight, pain in the calf, increased by orthostatism, walking, manual compression
- at the level of pelvic veins: uterine, urinary, hemorrhoidal veins
  - ⇒ urinary symptoms: pollakiuria, dysuria, urinary incontinence/retention
  - ⇒ anorectal symptoms: pain, tenesmus, hemorrhoidal crises, constipation
  - ⇒ pain in the pelvis of the kidney
- Mikaelis fever, Mahler pulse
- pain on palpation: pretibial, internal retromalleolar groove, medial calf area, Scarpa's triangle
- hard stasis edema, pitting sign, painful white-shiny-waxy edema, initially the limb circumference increases, then the lower limb is deformed

### **Postthrombotic syndrome:**

- deep thrombosis sequelae
- localized, cyanotic, pigmented chronic phlebedema
- varicose ulcer, secondary varices
- postthrombotic superficial phlebitis
- skin changes: sclerosis, pigmentation, purpura, eczema, mycosis, etc.

*Superficial vein thrombosis (SVT)* is a parietal inflammatory process accompanied by a perivenous dermo-epidermal reaction and secondary thrombotic participation (“superficial thrombophlebitis”)

#### **Etiology**

- trauma: venous puncture, venous catheter
- chemical infectious: contrast substances, i.v. diazepam

- blood hypercoagulability (rarely): hereditary (e.g.: antithrombin II, protein C or S deficiency) or acquired (e.g.: carcinoma: lung, prostate, breast, etc., myeloproliferative syndrome, lupus)
- Buerger's disease, Behcet's disease, vasculitis, collagenosis, etc.

### **Diagnosis**

- clinical: local pain or tension along the tract of a vein + hardened, hot, erythematous venous cord
- venous ultrasound: it confirms diagnosis + it excludes deep thrombosis

*Deep vein thrombosis (DVT)* consists of the presence of a thrombus inside a deep vein (of the limbs, pelvis or abdomen).

**Etiopathogeny:** it associates hypercoagulability with venous stasis and parietal lesion:

- blood hypercoagulability: local (surgical, obstetric interventions, trauma), general (hereditary, hypoxia, infections)
- local venous stasis (venous compression through plaster cast, bandage, TU, etc.), general (CHF, shock, hyperconcentration)
- venous parietal lesion: vein ligation or venipuncture
- DVT occurs at valve level; the recent or floating thrombus has a risk of pulmonary embolism; complete obstruction develops with pain + edema + superficial collateral circulation; the lysis of the thrombus destroys the valves and causes postthrombotic syndrome
- there are triggering factors (surgery, trauma, obstetric maneuvers, venous stasis) that overlap favoring factors (age over 60 years, varices, obesity, smoking, neoplasms: pancreas, lung, prostate, breast, stomach, hemostasis abnormalities, venulitis, local stasis, etc.) and trigger DVT

### **Clinical picture**

*Symptoms and signs* (occurring in less than 50% of the cases):



- spontaneous pain (unchanged by rest) or pain caused by compression, dorsiflexion (Homans sign), percussion
- muscle thickening, increased circumference, edema, venous collateral circulation
- subfebrility, discordant tachycardia (“climbing pulse” – Mahler)
- more frequent location: calf, popliteal, femoral DVT having two forms: phlegmatia alba dolens (white, highly edematous lower limb) and phlegmatia coerulea dolens (blue lower limb through associated arterial ischemia)

### **Explorations**

- venous Doppler examination + venous ultrasound: it identifies the thrombus + floating thrombus (emboligenic risk), it assesses therapeutic effectiveness
- phlebography: it assesses topography, the aspect of the thrombus and collateral circulation
- increased ESR, leukocytosis

**Positive diagnosis:** based on clinical picture and explorations.



# CHAPTER 6. THE RENAL-URINARY SYSTEM

## 6.1. ANAMNESIS

- **AGE:** more frequent diseases by age groups:
  - ⇒ **newborn:** external malformations (phimosis, epispadias, hypospadias), congenital hydronephrosis, vesico-ureteral reflux
  - ⇒ **young children:** hereditary tubulopathies: Fanconi syndrome, cystinuria, nephroblastoma (Wilms tumor) < 5 years
  - ⇒ **childhood/adolescence:** poststreptococcal glomerulonephritis after beta-hemolytic group A streptococcal angina
  - ⇒ **adult:** renal lithiasis, chronic glomerulonephritis, ascending urinary infections (women), polycystic kidney, renal abnormalities with obstructive uropathy
  - ⇒ **elderly:** prostate adenoma/neoplasm, CRF (renal sclerosis), renal neoplasm, dysectasia of the bladder neck
- **GENDER:** it can cause an increased prevalence of some diseases:
  - ⇒ **men:** more frequently: acute diffuse glomerulonephritis, renal lithiasis, prostate disorders
  - ⇒ **women:** ascending infections, pyelonephritis (most frequently), cystitis
- **REGION:** endemic tubulointerstitial nephropathy (Banat, Mehedinti county)
- **Family history:** hereditary transmission:
  - ⇒ *autosomal dominant:* renal agenesis/hypoplasia, renal tubular acidosis, Fanconi syndrome, hereditary nephrotic syndrome, Alport syndrome
  - ⇒ *autosomal recessive:* polycystic kidney
  - ⇒ *predisposition (or common eating):* urinary lithiasis

- **Previous related conditions:**
  - ⇒ septic abortion can induce ARF, sepsis
  - ⇒ pathological pregnancy causes eclampsia
  - ⇒ early/late pregnancy toxemia evolves with AHT, albuminuria, edemas
  - ⇒ genital inflammation/tumors can evolve with PN
- **Personal history of diseases** with subsequent renourinary involvement includes:
  - ⇒ acute infections: scarlet fever, erysipelas, streptococcal pharyngitis induce postinfectious acute diffuse glomerulonephritis, intrainfectious interstitial nephritis or can aggravate RF/GN
  - ⇒ chronic and focal infections (renal tb, syphilis, malaria, chronic suppurations) evolving in time towards renal amyloidosis and possibly CRF
  - ⇒ AHT evolving towards nephroangiosclerosis occurs in GN, PN, RF, prolonged hypotension causes ARF; CHF or CCP induce albuminuria
  - ⇒ collagenosis: lupus, panarteritis, rheumatoid arthritis
  - ⇒ malignant hemopathies: myeloma, lymphoma
  - ⇒ metabolic diseases: diabetes mellitus develops into diabetic nephropathy (PN, nephrotic syndrome), gout may cause uric lithiasis
  - ⇒ toxic agents, drugs – analgesics (phenacetin nephropathy), cytostatics, rifampicin
  - ⇒ transfusion, urological maneuvers
- **Living and working conditions**
  - ⇒ cold wet dwellings predispose to streptococcal infections, trench nephritis (cold, humidity)
  - ⇒ food: uric lithiasis (meat), oxalic lithiasis (vegetal food)
  - ⇒ high temperature, sweating, fluid restriction favor lithiasis

- ⇒ Pb, Hg, phosphorus: tubular, glomerular, interstitial nephropathies
- ⇒ vibrations: they trigger lithiasis colic

## 6.2. RENAL-URINARY SYMPTOMS

**PAIN:** diffuse; colic; hypogastric pain; pelviperineal pain

- **Diffuse lumbar pain**

- ⇒ *acute*: acute pyelonephritis, acute glomerulonephritis, perinephretic phlegmon
- ⇒ *chronic*: tubulointerstitial nephropathies, chronic glomerulonephritis, coraliform lithiasis
  - it occurs due to the co-involvement/distension of the renal capsule/pelvis of the kidney
  - its character: more frequently discomfort, pressure, distension in the renal lodge (between the 12<sup>th</sup> rib and the iliac crest)
  - radiation to the flank
  - accentuated by orthostatism, vibrations, diminished by clinostatism
  - location:
    - bilateral: in acute, chronic glomerulonephritis, PN, polycystic kidney
    - unilateral: in hydro/pyonephrosis, tb, neoplasms, renal lithiasis, perirenal abscess, embolism, thrombosis, renal ptosis
  - other causes: spine, pancreas, genital organs

- **Renal-ureteral colic**

It occurs due to the sudden/considerable distension of the renal pelvis/calices by acute ureteral obstruction.

## Causes:

- ⇒ calculus (90%), blood clot, caseum, tumor sphacelus (intrinsic organic obstruction)
- ⇒ superadded spasm of the parietal musculature

## Semiological characteristics:

- ⇒ violent pain, as tension, traction, tearing, burn
- ⇒ in the lumbar region unilaterally
- ⇒ downward radiation, along the ureteral tract, towards the external genital organs, root of the thigh
- ⇒ continuous character, with high intensity exacerbations (intermittent paroxysms)
- ⇒ accompanied by **urinary** phenomena: pollakiuria, tenesmus, oliguria, macroscopic hematuria (renal lithiasis, tu, tb, trauma); **digestive**: nausea, vomiting, meteorism+/- paralytic ileus
- ⇒ antalgic posture (bizarre postures, “agitated colic”)
- ⇒ sudden onset, related to: exercise, vibrations, diuretics, etc. (mobilizing the calculus)
- ⇒ duration: several hours; it is improved by heat, antispastics
- ⇒ ending with polyuria +/- elimination of the calculus
- ⇒ increased by the palpation of the lumbar region, percussion, coughing, sneezing, deep breathing

**Causes:** renal lithiasis (>90% of the cases), tb, neoplasms, papillary necrosis, obstructive pyelonephritis, ptosis, bending, compression, malformations, infarction, polycystic kidney

- **Hypogastric pain** occurs in:
- urinary bladder disorders, cystitis (non-specific cystitis, tb cystitis, endocrine cystitis, urinary bladder lithiasis, neoplasms), lithiasis (**cystalgia**)
- **acute urine retention** induces urinary bladder distension, causing hypogastric pressure/distension with radiation to the meatus

(women), gland (men) +/- tenesmus, continuous during the day/night, it disappears on urinary bladder catheterization

- **Pelvipерineal pain**

⇒ it occurs: in the disorders of the terminal ureter, prostate, seminal vesicles, urinary bladder

⇒ character: stinging pain, tension; radiating towards the gland

⇒ accompanied by micturition disorders (pollakiuria, dysuria); accentuated by palpation/touch/walking

## **URINARY SYMPTOMS: MICTURITION DISORDERS**

- **Pollakiuria:** increased frequency of micturition, with small amounts

**Normal:** 3-5 /day spontaneous, painless, complete, controlled by will

It occurs due to:

⇒ urinary bladder and tract disorders (with reduced capacity): cystitis; tu; urinary bladder residue (subvesical obstruction), external compression

⇒ hyperreflexia of the detrusor muscle (internal sphincter): calculus, extravescical inflammation

⇒ secondary to polyuria (frequent micturition with normal amounts): edema resorption, diabetes, renal failure

It can be: diurnal, nocturnal, continuous +/- other general, urinary manifestations

**Nocturnal pollakiuria** (it requires differential diagnosis with nycturia):

nocturnal micturition, increased frequency, low urine amount: it occurs in prostate adenoma, tb

**Pseudopollakiuria:** more frequent micturition, initiated voluntarily, in order to prevent dysuria (in dysectasia of the bladder neck)

- **Infrequent micturition** < 3/day: oliguria, detrusor areflexia (diabetic cystopathy); megabladder +/- large diverticula; with oliguria: AGN, ARF.

## **URINARY SYMPTOMS: PAIN DURING MICTURITION** (painful micturition)

- **Pain in the pelviperineal, hypogastric region, along the urethra** occurs in relation to micturition as follows:
  - ⇒ initially (at the beginning of micturition) in: prostate adenoma, posterior urethritis
  - ⇒ terminally (at the end of micturition) in: cystitis
  - ⇒ throughout micturition, as burning pain along the tract of the urethra: urethritis
  - ⇒ after the cessation of micturition: in pericystitis
  - ⇒ associated symptoms: dysuria, pollakiuria, imperative micturition
- **Vesical tenesmus:**
  - ⇒ intense hypogastric pain, necessity to urinate
  - ⇒ repeated elimination of several drops of urine
  - ⇒ sensation of incomplete bladder emptying
  - ⇒ in acute cystitis, posterior urethra disorders, pelvic malformations

## **URINARY SYMPTOMS: DYSURIA**

Sensation of difficult elimination of urine +/- painful; throughout micturition or at the beginning/end

### **Causes:**

- ⇒ urinary bladder lithiasis, dysectasia of the bladder neck, foreign bodies, bladder stenosing tumors cause terminal dysuria
- ⇒ prostate adenoma/neoplasm, the most frequent cause of initial dysuria, “drop by drop”, weak, interrupted urine jet
- ⇒ urethritis, stricture, urethral calculus, neurological diseases: dorsal tabes, multiple sclerosis induce total dysuria

Dysuria is accompanied by:

- ⇒ alterations of the urine jet: weak, filiform (strictures), bifid, spiral shaped (calculi) – intermittent stoppage with resumption



following exercise or change of position (inclavated stone, tu, sphacelus)

⇒ exertion (leaning forward, abdominal pressure)

⇒ +/- uni-/ bilateral lumbar pain: vesicoureteral reflux

### **URINARY SYMPTOMS: URINARY RETENTION**

⇒ impossibility of emptying the bladder by spontaneous normal micturition, requiring differential diagnosis with oligoanuria (absence/diminution of urine secretion)

⇒ acute, chronic retention causes “vesical globe” (bladder distension +/- rupture)

⇒ **Causes:**

- urethral obstruction: prostate adenoma/neoplasm, strictures/calculi, invasive tumors
- urine reflux/micturition disorders: dysectasia of the bladder neck; detrusor areflexia; medullary lesions, toxic states; surgery, pelvic trauma

### **URINARY INCONTINENCE**

Loss of bladder control, conscious/unconscious; permanent/intermittent: during coughing, laughing, weight lifting

**It occurs in**

⇒ sphincter insufficiency: pregnancy, after delivery, pelvic surgery, inflammation

⇒ neurological diseases: pudendal nerve, spinal cord (S3-S5); mental diseases: psychosis, hysteria

## **6.3. GENERAL OBJECTIVE EXAMINATION**

### **• Posture and mental state**

⇒ the impossibility to find an antalgic posture in renal ureteral colic leads to the adoption of bizarre postures

⇒ fibrillation and fasciculation: uremia

- ⇒ tonic-clonic seizures: cerebral edema in NS, eclampsia
- ⇒ asthenia/passive attitude: CRF with uremic coma
- ⇒ micturition syncope: vago-vagal, morning/nocturnal through nocturnal hypervagotony, rapid bladder emptying
- **Skin changes**
  - ⇒ yellowish/earthy pallor, more obvious in the face: in AGN – by vasoconstriction; CGN – anemia, high urochromogen levels
  - ⇒ “uremic frost”, “powdered patient” – uremia – elimination of urea by skin
  - ⇒ dry, dehydrated skin, with purpura (low thrombocytes)
- **Subcutaneous cellular tissue**
  - ⇒ emaciation: CRF, renal cancer
  - ⇒ renal edema
  - ⇒ pathological fractures: hemodialyzed CRF
  - ⇒ **fever**: PN, pyonephrosis, prostatitis, hypernephroma, peri-/pararenal abscess
- **Extrarenal manifestations of uremia (renal failure syndrome)**
  - ⇒ cardiovascular: pain, rub, HF
  - ⇒ respiratory: Kussmaul respiration, “uremic lung”
  - ⇒ digestive: nausea, vomiting, inappetence, uremic factor

#### ***6.4. THE OBJECTIVE EXAMINATION OF THE URINARY SYSTEM***

- **INSPECTION**
  - ⇒ bulging of the lumbar region: large hydro/pyonephrosis, Wilms tumor, peri/pararenal abscess
  - ⇒ +/- asymmetry of breathing movements
  - ⇒ +/- (revealing) lumbar region edema in peri/pararenal abscess
  - ⇒ bulging of the hypogastric region: large “vesical globe”
  - ⇒ bulging of the flanks: polycystic kidney; large tumors

⇒ congested, tumefied urinary meatus: acute urethritis, +/- urethral secretion

- **PALPATION:** kidney, lumbar region, painful areas

**Normal:** lower pole of the right kidney in asthenic patients, weak abdominal musculature

**Pathological:** ptosed kidneys; enlarged kidney volume

### **Palpation techniques**

**GUYON:** with two hands, one anteriorly, the other posteriorly, the following are assessed: lumbar contact, ballottement, capture, “gliding”, and passive mobility

**GLENARD:** monomanual, by pinching between the thumb and the index

**ISRAEL:** bimanual, in lateral decubitus

- **Elements suggesting kidney involvement:**

⇒ posterior position and lumbar contact; palpation with both hands

⇒ absent +/- passive mobility

⇒ characteristic “bean seed” shape with clear-cut limits

⇒ +/-sensation of micturition +/- posterior sensitivity

- **Diseases evolving with palpable (enlarged) kidneys**

⇒ polycystic kidney: bosselated surface; bilateral +/- large size

⇒ malignant tumors: Wilms tu - nephroblastoma +/- large volume, Grawitz tu - hypernephroma: hard, sensitive, irregular kidney

⇒ gr. I renal ptosis: lower pole, smooth, elastic, insensitive; gr. II: the entire kidney; gr. III: significantly displaced

⇒ massive hydronephrosis/large pyonephrosis: smooth, elastic, sensitive/extremely sensitive, +/- tu, it disappears after the elimination of the obstruction

- **Sensitivity of the lumbar region; painful areas; hypogastrium**

⇒ **Giordano** method: percussion of the lumbar region with the cubital margin of the hand, vibrating, progressive intensity

⇒ **Sensitive renal areas**

- **Costovertebral:** at the top of the angle between the 12<sup>th</sup> rib and the spine
  - **Costomuscular:** at the top of the angle between the 12<sup>th</sup> rib and the paravertebral musculature mass
- ⇒ **Sensitive ureteral areas** in cystopyelitis (bilateral); ureteral lithiasis
- **upper u.** (paraumbilical BAZIN) at 4-5 cm paraumbilically, horizontally
  - **middle u.** (TOURNEAUX): bispinoiliac, middle 1/3 of the crural arch
  - **lower u.:** endorectal, vesical
- ⇒ **sensitive hypogastrium:** cystitis, bladder neoplasms
- **Palpation of the urinary bladder in: "vesical globe", neoplasm, pericystitis**
    - ⇒ hypogastric tu: hemispheric, suprapubic ("like the rising sun"), superficial, clearly delimited, smooth, elastic, sensitive, immobile, need to micturate on palpation (vesical globe)
    - ⇒ hard, irregular tu (neoplasm)
    - ⇒ thickening (pericystitis)
  - **Endorectal palpation**
    - ⇒ Large prostate, clearly delimited, elastic, painless, without a median groove - *adenoma*
    - ⇒ Asymmetrically enlarged prostate +/- nodular, the median groove is maintained - *neoplasm*
    - ⇒ Sensitive prostate - *prostatitis*
    - ⇒ Extremely sensitive prostate, reduced consistency - *abscess*
  - **Urethral palpation:** sensitivity, induration (urethritis, stricture, +/- inclavated stones)

- **Percussion:** vesical globe, extremely large tumors produce dullness
- **Auscultation:** renal artery stenosis/aneurysm

## 6.5. DIURESIS DISORDERS

- **POLYURIA** > 2L/ 24 hours

⇒ **Transient:**

- physiological: high amount of fluids, cold, stress
- pathological:
  - convalescence of infectious diseases: pneumonia, malaria, hepatitis, typhoid fever
  - acute glomerulonephritis (recovery), ARF (polyuric phase)
  - after jaundice, seizures, PT, AP, diuretics, edemas

⇒ **Permanent:**

- CRF in the steady state period; compensatory; uninfluenced by fluid ingestion restriction; pale urine, low density, 2.5-4 l, elimination independent of fluid ingestion
- DIABETES INSIPIDUS: 10-30 l/day, colorless urine (like water), extremely low density, without sediment; ADH deficiency, irresistible polydypsia, unsatisfied by ingestion
- DIABETES MELLITUS: 3-6l l/day, glycosuria, high density – likewise in azoturic diabetes, phosphaturia, other tubulopathies
- POTOMANIA (thirst psychosis): enforced thirst reduces diuresis

- **OLIGURIA:** <400-500 ml/24 hours

⇒ **Physiological:** low ingestion, excessive sweating, dark urine, increased density

⇒ **Pathological:**

- **RENAL**

- reflex in renal colic, tubular obstruction (Hgb, myoglobin)
- development of nephrotic edema: acute GN, some types of PN +/- tubulointerstitial nephropathies
- ARF at onset, advanced CRF (uremia)

- **EXTRARENAL:**

- vomiting, diarrhea (toxic infection, pyloric stenosis)
- hydrosaline retention (HF, HC)
- AHT, increased aldosterone, increased ADH, increased folliculin

- **OLIGURIA:**

- ⇒ with high density ( $D > 1025$ ) - extrarenal
- ⇒ with low density ( $\sim 1010$ ) - renal

- **ANURIA:**  $< 100$ - $150$  ml/24 hours, suppression of diuresis + lack of urine in the bladder by lack of secretion: terminal ARF, CRF

- ⇒ **transient:** reversible ARF
- ⇒ **permanent:** irreversible ARF; CRF

**Functional** causes: hypovolemia, AHT, water electrolyte imbalance

**Organic** causes:

- acute tubular, interstitial, vascular, glomerular nephropathies
- urinary obstruction, chronic bilateral renal lesions

- **NYCTURIA**  $> 1/4$  nocturnal micturitions

- ⇒ Renal: CRF with polyuria, incomplete urinary obstruction
- ⇒ Extrarenal: edemas, HF, HC due to nocturnal clinostatism: increased renal flow, increased glomerular filtrate

- **OPSIURIA:**  $> 5$ - $10$  hours elimination of ingested fluids ( $N < 4$  hours)

**Causes:** hepatic insufficiency, AHT, aldosterone, ADH, estrogen disorders

## 6.6. HEMATURIA

It is defined as the micturition of urine with blood (originating above the anterior urethra)

Urethrorrhagia: bleeding from the anterior urethra

- **Other causes** of red urine color:
  - ⇒ ubg în hepatopathies; bilirubin in mechanical jaundice
  - ⇒ urochrome in hyperconcentrated urine; urates in hyperuricemia
  - ⇒ myoglobin in crush syndrome; hemoglobin in hemolytic syndromes, paroxysmal hemoglobinuria, posttransfusion accidents
  - ⇒ porphyrins in late cutaneous porphyria
  - ⇒ drugs: aminophenazone (Algalmin), noraminophenazone, rifampicin
  - ⇒ foods: red beet, blackberries

Microscopic hematuria (100-1000 h/cm<sup>3</sup>/min)

Macroscopic hematuria (> 1 million)

- **Site of hematuria:** the three-glass test (collection of urine in three glasses)
  - ⇒ H. in the first glass (initial) - of urethral prostatic cause
  - ⇒ H. in the last glass (terminal) - vesical
  - ⇒ H. in all three glasses (total) - renal parenchymatous, pyelic or urethral
- **MAIN CAUSES OF HEMATURIA**
  - ⇒ **GENERAL:**
    - hematologic disease: hemophilia, thrombocytopenia, leukemia, hemoglobinosis
    - systemic vasculitis: PN, Goodpasture syndrome
    - collagen diseases: DLE
    - iatrogenic causes: anticoagulants, dicumarinics, cytostatics, cyclophosphamide

⇒ **RENAL-URINARY:**

- renal: acute, chronic glomerulonephritis, tu, tb, polycystic kidney, interstitial nephropathies, vascular diseases
- pyelo-urethral: lithiasis, infections, tu
- vesical: acute, chronic infections, tu, lithiasis
- urethral-prostatic: prostate adenoma/carcinoma, urethritis, polyps

• **Clinico-etiological correlations**

1. Colic followed by hematuria → renoureteral lithiasis; physical exercise/vibrations followed by hematuria → reno-ureteral lithiasis
2. H.+ colic + fever and diabetes mellitus suggest papillary necrosis
3. Diurnal H., relieved by rest +/- hypogastric pain → urinary bladder lithiasis
4. H.+ shivering + pollakiuria, dysuria → cystitis
5. H.+ fever, shivering, pollakiuria + positive Giordano sign → acute pyelocystitis/pyelonephritis
6. H.+ urine retention + elderly men → prostate adenoma
7. H. at 10-21 days after streptococcal infection + edemas, AHT, proteinuria → AGN
8. H. + large, bosselated, painless kidneys → polycystic kidney
9. H. + irregular, hard, unilateral nephromegaly → renal neoplasm
10. Irregular, painless, total H. → quasi-pathognomonic for renal neoplasm
11. H. + weight loss + altered general state → neoplasm (kidney, ureter, urinary bladder)
12. Irregular H. + shivering +/- fever, weight loss → renal neoplasm
13. Long evolution H., pollakiuria, dysuria, urinary retention → frequently urinary bladder neoplasm
14. H. + hemorrhagic/parous manifestations → hemorrhagic/parous syndrome, leukemia



## 6.6. PYURIA AND LEUKOCYTURIA

It defines the presence of pus in urine

**Macroscopic P.:** cloudy, opaque urine

**Microscopic P.:** presence of isolated/grouped leukocytes → urine without lustre/transparency

**Normal:** leukocyturia > 5-10 L/mm<sup>3</sup> (Stansfeld-Webb test)

(quantitative urinary sediment) > 5000-6000 L/min/ml (Addis-Hamburger test)

Pyuria > 100 000 L/mm<sup>3</sup>

- **Site of pyuria:** the three glass test

- **MAIN CAUSES OF PYURIA**

- ⇒ **Parenchymatous:** interstitial nephritis, renal tb, renal neoplasm, superinfected lithiasis

- ⇒ **Vesical causes:** cystitis, urinary bladder tb, superinfected urinary bladder lithiasis, malformations, diverticula

- ⇒ **Urethral-prostatic causes:** prostatitis, urethritis

**Clinico-etiological correlations:**

1. P. + dysuria + pollakiuria → acute cystitis

2. P. + dysuria + pollakiuria + positive Giordano sign → ac pyelonephritis/ac pyelocystitis

3. "Sterile" P.+ acid pH + hematuria + nocturnal pollakiuria → vesicorenal tb

4. Persistent P. + alkaline pH + lithiasis → Proteus infection + phosphate lithiasis

5. Persistent P/L. + proteinuria + decreased renal concentration capacity → chronic pyelonephritis



# CHAPTER 7. CLINICAL RENAL SYNDROMES

## 7.1. ACUTE RENAL FAILURE

Renal insufficiency (RI) is an advanced stage of kidney disease in which the kidney proves incapable of clearing the metabolic decomposition products. Acute renal failure (ARI) or acute kidney failure is an abrupt loss of kidney function, defined as below.

**Definition:** humoral and urinary clinical syndrome determined by the abrupt discontinuation, complex and potentially reversible, of the kidney functions.

**Classification:** pre-renal, renal, and post-renal.

### 7.1.1. Pre-renal acute renal failure

**Causes:**

Severe dehydration by: vomiting, diarrhea, sweating, e.g.:

- intestinal occlusion, pyloric stenosis, gastro-enterocolitis
- abuse of diuretics, diabetes mellitus with severe polyuria
- Abrupt decrease of arterial tension: acute myocardial infarction; severe rhythm disturbances; septic shock, severe hemorrhage

**Clinical picture:**

- in dehydration: deep set eyes, persistent fold, dry mucosa
- arterial hypotension: low AT, pallor, cold extremities, tachycardia

**Paraclinical findings:**

- Anemia, increased nitrogen level, oligoanuria. Replenishing the blood volume and restoring AT is followed by the restoration of AT and decrease of nitrogen levels.

### 7.1.2. Renal acute renal failure

#### *Cause:*

- Acute tubulo-interstitial **nephritis** (ATIN), or acute kidney injury (AKI), due to:
  - ischemia (hypovolemic, cardiogenic, septic shock)
  - nephrotoxicity
    - drugs (sulphamides, iodine contrast substances)
    - lead, gold, venom poisoning
    - after incompatible transfusions
    - myoglobin in the crushing syndrome

#### *Clinical picture:*

Symptoms of the underlying disease + evolution by 4 stages:

- **Pre-anuria stage** – lasts 3-5 days. The signs of the underlying disease and renal signs (lumbar pain, oliguria, increased blood urea)
- **Anuria stage** – lasts 5-15 days
  - anuria, blood urea and creatinine increase (progressively)
  - edema is absent
  - signs and symptoms of distress of all organs (respiratory, cardiovascular, digestive etc.)
  - oligoanuria = <200 ml/24h, anuria = <50 ml/24h
- **Stage in which diuresis is resumes** – over 1000 ml/24h
- **Healing and recovery** – last up to 12 months, it is complete, rarely with sequelae
  - Difference must be made between anuria and urine retention (vesical globe + catheter urine)

### 7.1.3. Post-renal acute renal failure

#### *Causes:*

- renal lithiasis
- clots
- compression

- prostate adenoma
- surgical ligation of the ureters
- tumor

***Clinical picture:***

- oligoanuria after renal colic + hematuria
- palpable, sensitive kidney, positive Giordano sign
- remission after deobstruction

## **7.2. CHRONIC RENAL FAILURE**

Chronic renal insufficiency (CRI) or chronic kidney disease (or failure) is a syndrome defining the whole cluster of clinical and biological manifestations due to the incapacity of the kidneys to ensure its functions following the slow and progressive destruction of the nephrons by irreversible and progressive organic injury caused by one or both diseased kidneys.

***Etiology:*** any cause of extensive destruction of the parenchyma

- glomerular nephropathy (25%); chronic glomerulonephritis, DM-induced nephropathy
- interstitial nephropathy (20%; chronic pyelonephritis etc.
- tubular nephropathy: lead, drug poisoning
- vascular nephropathy (20%); nephro-angiosclerosis
- polycystic kidney (15%), tuberculosis, cancer
- chronic obstruction of the urinary path, prostate adenoma, renal lithiasis etc.

***Patho-morphology:*** most commonly renal sclerosis occurs (after chronic glomerulo-nephritis or pyelo-nephritis), evolving towards CRI; size of the kidney is directly correlated with the cause.

***Pathogenesis:*** the theory of the remaining “untouched nephron”, becoming hypertrophic by polyuria, “fixed” nitrogen retention, uremia.

**Classification of CRI:** based on clinical, functional, humoral criteria - 4 stages, as follows:

- **stage I, full compensation:**
  - 50% undamaged nephrons, normal function at rest, but CRI when over-strained (PSP, HAP clearance)
  - normal homeostasis: urea below 40%, creatinine below 1.4 mg%, density < 1022, normal diuresis
- **stage II, compensated:**
  - 25-50% undamaged nephrons, normal function at rest, exercise-induced homeostasis disturbances (transient)
  - compensation mechanisms occur:
    - polyuria and nicturia (first phase) + density 1018 (hypostenuria), slightly decreased glomerular filtrate
    - fixed nitrogen retention: 50-80 mg%, creatinine 1.4-3 mg% (second phase) – density 1010 (isostenuria), much lower glomerular filtration
- **stage III or uncompensated (pre-uremia)**
  - 10-25% undamaged nephrons, compensating mechanisms are depleted, nitrogen is high, symptoms + pseudo-normal urine excretion, followed by oliguria + isostenuria
  - severely altered functional renal tests: urea > 100 mg% (300 mg% on average), creatinine 3-10 mg%
- **stage IV or uremia: final stage of all kidney diseases**
  - nephrons under 10%
  - urea over 300 mg%, creatinine over 10 mg%, densities 1009-1010, oliguria
  - clinical manifestations occur due to nitrogen retention, electrolytes and acid-base balance are altered, signs of multiple organ failure appear:

cerebral, cardiovascular, respiratory, digestive, hematological etc

- uremia is therefore not equivalent to nitrogen increase

***Current classification***, by stages of evolution:

- incipient CRI – creatinine 1-3 mg%
- moderate CRI - creatinine 3-7 mg%
- severe CRI - creatinine > 7 mg%

***Clinical picture***: appears in stages III and IV. Extra-renal manifestations:

- general: asthenia, headache, apathy
- cutaneous: earth-like pallor, dry skin, desquamation, scratching injuries, uremides, pyoderma, hemorrhagic syndrome
- respiratory: urinary breath (foetor uremicus) by transformation of urea into ammonia, Kussmaul respiration, bronchopneumonia
- cardiovascular: hypertension, rhythm disturbances, ECG, HF, VSI, uremic murmur (Bright) in the final stage
- digestive: appetite loss, hiccup, nausea, vomiting, diarrhea, hemorrhage (digestive elimination of urea)
- osteoarticular: osteomalacia, osteoporosis through calcium metabolism alteration
- neuro-psychiatric: obtundation alternating with agitation, uremic coma (“queit”, dry), polyneuritis
- endocrine: gonadic, growth in children
- humoral: highly increased urea, creatinine, uric acid, also increased potassium, while sodium, calcium and alkaline reserves are low
- hematological: anemia, leukocytosis (non-infectious), low platelet level
- reno-urinary manifestations: oliguria, hypo- or iso-stenuria, reduced proteinuria, hyaline or granular cylinders (induced by

kidney failure); hematuria or leukocytes and bacteria in the urine, depending on the cause and stage of CRI; altered functional tests).

***Positive diagnosis:***

- clinical, functional humoral and morphological criteria
- includes the CRI, stage (based on creatinine level and clearance), causing kidney disease, aggravating or favoring factors

***Differential diagnosis: depends on the CRI stage!***

- with other polyurias
- “fixed nitrogen retention”
- uremic coma
- oligoanuria

### ***7.3. THE NEPHRITIC SYNDROME***

It is the most common manifestation of the post-streptococcal diffuse acute glomerulonephritis (PSDAGN), caused by type A12 beta-hemolytic streptococcus.

- In the class of post-streptococcal diseases along with AAR (after 2-3 weeks of angina dominated by asthenia -> AAR with DAGN).
- The nephritic syndrome is characterized by: edema, cardiovascular syndrome, urinary syndrome, nitrogen retention syndrome.

The intensity of these within the nephritic syndrome varies; there are **complete forms** (typical), in which all the signs are present, but also **incomplete forms** (less symptomatic) or atypical – ARI, isolated hypertension, polyuria and/or isolated hematuria, hematuria and hypertension.

- **Edema** – decreased elimination of Na and water, due to low renal excretion by reduced total filtration glomerular surface, not



by hypoalbuminuria, like in the nephritic syndrome. Retention of salt and water will lead to heart failure, intensified by edema.

- **Cardiovascular syndrome:** hypertension and bradycardia
  - occurs with increase of the circulating volume due to hypernatremia (by water and salts retention), sometimes high blood pressure with: tension headache, heart failure (EPA), eclampsia and convulsions
- **Urinary syndrome:**
  - oliguria (400-600 ml/day)
  - hematuria + leukocytes in urine (less than blood)
  - hemic cylinders + discolored erythrocytes (indicating the upper origin)
  - severe proteinuria, over 150 mg/day
  - absence of proteinuria excludes the glomerular nature of proteinuria
- **Nitrogen retention syndrome:** increased urea and sometimes ARI
  - The nephritic syndrome may evolve as several variants:
    - acute: sudden onset, preceded by microbial infection; develops toward cure or sometimes ARI
    - subacute
    - chronic
      - slow and deceitful onset with proteinuria + hematuria + hypertension and renal function alteration
      - slowly progressive -> after 5-10-15 years of evolution, towards terminal ARI

### 7.3.1. POST-STREPTOCOCCAL ACUTE GLOMERULONEPHITIS

Post-streptococcal acute glomerulonephritis (PSAGN) manifests by an acute nephritic syndrome occurring 1-3 weeks after an infection.

**Etiology:** group A beta-hemolytic streptococcus, pharyngeal and skin infections.

#### **Clinical picture:**

- Represents the majority of infectious glomerulonephritis (50-75%)
- the most frequent between 2-6 years old boys (rarely < 2 years and > 20), poor nutrition, mainly in spring and autumn (cold and wet weather)
- 3 stages:
  - o streptococcal infection: angina, fever, dysphagia
  - o latent period (post-angina syndrome) – formation of antibodies and CIC
  - o disease is present, onset after 6-12 days (mean 10 days), manifested by:
    - **complete acute nephritic syndrome** with a slow onset, more rarely abrupt, with: bilateral lumbar pain, swollen face and eyelids, oliguria under 500 ml/24h, hypertension, bradycardia, macroscopic or microscopic (more often) hematuria, with or without hematic cylinders, proteinuria < 3g/day with or without hyaline cylinders
    - sometimes the **nephritic syndrome** is **incomplete** (hematuria + proteinuria), with insidious onset; to mention that lumbar pain is inconstant (capsule distention), hypertension is moderate (max. 200/120 mmHg), severe acute renal failure is rare, while left tachycardia announces LVI

- nonspecific *infectious symptoms* may be also associated: fever, headache, asthenia; signs and symptoms disappear within a few weeks

***Additional tests:***

- biological tests of acute inflammation: ESR, fibrinogen, increased alpha-1 and alpha-2, leukocytosis, increased CRP, anemia
- evidence of streptococcal infection: NFS with present beta hemolytic streptococcus, high ASLO (between 2 weeks and 12 months), low complement (up to 8 weeks), increased immune complexes, positive anti-streptozine test
- renal functional tests are poor, kidney puncture biopsy is not mandatory
- other examinations: ECG, chest x-ray, renal US, urography FO

***Positive diagnosis:***

- acute nephritic syndrome
- pharyngo-tonsillar infection 1-3 weeks before
- evidence of streptococcal infection: increased ASLO
- non-specific inflammatory syndrome: increased ESR, fibrinogen, CRP
- immune syndrome: low C3, high CIC
- oliguria with reduced glomerular filtration
- enlarged kidneys with typical PRB

**7.3.2. POST-STREPTOCOCCAL CHRONIC GLOMERULONEPHRITIS**

Chronic post-streptococcal glomerulonephritis is the consequence of an uncured acute post-streptococcal glomerulonephritis; evolution toward chronicity progresses to chronic renal insufficiency in 1-2 years or slowly, after the acute phase is improved through renal insufficiency, hypertension with or without nephritic syndrome over decades.

**Laboratory investigation** is not characteristic:

- proteinuria + hyaline cylinders constant, of varying intensity
- hematuria + hematic cylinders more marked during acute bouts, diagnostic value
- leukocyturia + granulated cylinders less than hematuria
- normal or increased ESR in nephritic syndrome, pyelonephritis, complications
- anemia more intense at advanced stages, with leukocytosis
- nitrogen and creatinine increase with the degree of the chronic renal insufficiency

**Clinical forms** depend on the dominant manifestation:

- latent or stationary
- hypertensive, nephritic or both

**Evolution:**

- rapid (6-24 months) towards death
- slow (3-30 years, mean 15):
  - o slow stage (years) without symptoms, but with hematuria ± cylinders, proteinuria, renal insufficiency
  - o manifest stage: renal symptoms (hypertension, nephritic syndrome), acute bouts and remissions
  - o advanced stage: chronic renal insufficiency
- toward stabilization

## **7.4. THE NEPHROTIC SYNDROME**

The nephrotic syndrome (NS) includes glomerular diseases with marked glomerular permeability disturbances. The NS involves preproteinuria above 3.5 g/day/1.73 sq.m (mainly albuminuria), with its consequences: albuminemia <2.5 g%, total proteins <6 g%, alpha-2 globulins >15%, dysproteinemia, often high lipids, cholesterol and nephritic edema

### **Clinical picture:**

- **pure NS** (e.g. lipoidic nephrosis): proteinuria (selective), low albumin, low proteinuria, nephritic edema high lipids
- **impure NS** (usually secondary, to DM for example): additional findings: hematuria >10,000/min, non-selective proteinuria, hypertension, functional alterations: increased nitrogen, low glomerular filtrate
- **nephritic edema:** white, painless, declivity-induced, mobile, varying intensity to anasarca, with or without digestive edema: nausea, vomiting, abdominal pain. Pathogenesis of edema includes: marked proteinuria followed by albuminemia and low oncotic pressure, onset of edema and decrease of the circulating volume that determines water and salt retention due to the renin-angiotensin-aldosterone-catecholamine system which determines the vasoconstriction of the incoming glomerular artery, decrease of glomerular filtration, therefore oliguria and increased ADH and aldosterone, which perpetuates water and salt retention and consequently edema.

### **Diagnosis of the NS. Stages:**

- evidence of the NS (edema dominates the clinical picture)
- demonstration of the presence and nature of glomerular injury (pure or impure NS)
- establishment of the NS etiology, primary or secondary, based on the clinical context and paraclinical examinations
- evidence of the morphological basis: kidney puncture biopsy

## **7.5. ACUTE PYELONEPHRITIS**

Acute pyelonephritis (APN) is an acute infectious bacterial tubulo-interstitial kidney disease.

### **Factors favoring APN:**

- obstruction of the urinary tract: stenosis, calculi, strictures

- bladder-ureteral reflux
- non-sterile manoeuvres on the urinary tract
- gender: female (shorter urethra), male (enlarged prostate)
- diabetes mellitus, immune suppression pregnancy

**Clinical picture:** high temperature, lumbar pain, urinary disturbances (infection):

- body temperature 40°C, chills, altered state, digestive complaints
- lumbar pain in one or both sides, dull, colic-like, positive Giordano's sign
- urinary infection: polyakiuria (frequent urination), dysuria (painful urination, burning, discomfort), pyuria (cloudy, smelly urine)
- occurs more often in women
- duration: 6-7 days; pyuria and bacteriuria may persist if not treated

**Additional examinations:** indicate the upper infection (renal):

**Urine test:** marked leukocyturia + pyuria + leukocytic cylinders ± hematuria

**Urine culture:** bacteriuria > 100,000 germs/ml (proof of urinary infection), of upper origin of germs (bacterial immunofluorescence etc.)

Increased ESR, leukocytosis with neutrophilia

**Positive diagnosis:**

- based on the triad: fever, lumbar pain, urinary infection, plus leukocyturia, leucocytic cylinders, bacteriuria and urinary tract abnormalities (x-ray) in secondary APN
- germs and leukocytes come from the upper urinary tract and the infection affects the kidney

## 7.5. CHRONIC PYELONEPHRITIS

Chronic pyelonephritis (CPN) is a multifocal chronic tubulointerstitial kidney disease due to a bacterial infection affecting the pyelocalice and kidney in a limited way.

**Factors favoring CPN:** bladder-ureter reflux – main cause, secondary hypertension, CRI, urinary tract obstruction, DM, nervous system diseases etc.

**Clinical picture:** not characteristic, attenuated, slow evolution (years):

- personal history: favoring factors, recurrent urinary infections
- general manifestations: asthenia, weight loss, headache, mild fever, dyspeptic disturbances
- renal manifestations: lumbar pain, dull, positive Giordano's sign, urinary manifestations: polyuria, nocturia (low density), polakiuria, dysuria, clear discolored urine or smelly and cloudy + chronic renal failure in the advanced stages
- hypertension, anemia

### Complementary tests

- anemia, ESR, leukocytosis in acute CPN
- low Na, high K, increased nitrogen and creatinine in CRI
- renal and urinary tests:
  - o leukocyturia + leukocytic cylinders: in acute bouts; more than hematuria
  - o bacteriuria > 100,000 germs/ml in 2 successive urine cultures; may be absent
  - o low densities  $D < 1025$  (decreased concentration capacity, isostenuria ( $D=1010-1011$ ), hypostenuria ( $D=1018-1015$ ), sub-isostenuria ( $D=1007-1005$ ))
  - o abnormalities of the excreting pathways, kidney parenchyma, bladder-ureter reflux (urography)
- US: small, asymmetric kidneys, unequally thinned parenchyma, pyelo-caliceal alterations, signs of obstruction, calculi etc.

- urography: defects of excretion and concentration

### **Positive diagnosis**

- urinary infection of bacterial origin for more than 3 months: bacteriuria, leukocyturia, cylinders
- kidney parenchyma is affected

### **Differential diagnosis**

- Between the lower and upper urinary tract infection. Criteria for the upper urinary infection: history, repeated acute bouts, fever, lumbar pain, leukocytic cylinders, low densities, typical urography
- Chronic glomerulonephritis, nephro-angiosclerosis, or other interstitial kidney disease.



# CHAPTER 8. THE GASTROINTESTINAL SYSTEM

## 8.1. SEMIOLOGY OF THE ORAL CAVITY AND THE PHARYNX

### 8.1.1. Patient history

#### Age:

- Newborn
  - congenital malformations, hare lip, wolf's palate (cheilognato-palatoschisis), *lueta bifida* – disturbances in the infant's feeding
- Childhood
  - dental abnormalities – deciduous or definitive (shape, position, number)
  - congenital syphilis
  - sequelae / injuries of acid, bases, salts poisoning
  - rhino-pharyngitis, stomatitis, acute throat infections, candidiasis (secondary to antibiotics)
- Adults
  - pulpitis, glossitis, stomatitis, focal infections
  - inflammations of the oral mucosa following occupational poisoning (ulcerations)
  - trauma
- Elderly
  - edentation
  - neoplasia of the lips, tongue, nose, pharynx
  - candidiasis

#### Personal history of pathological events:

- Local trauma of the following nature

- mechanical – irritation due to dentures
- thermal – hot food or liquid
- chemical – acids, bases resulting in burns and then ill scarring
- General causes
  - diabetes mellitus – diabetic periodontal disease
  - vitamin deficiency – scurvy, pellagra
  - certain infectious diseases
    1. enanthema – measles (Koplick’s sign)
    2. scarlet fever – strawberry tongue
    3. syphilitic lesions – perforation of the palate
  - collagen diseases
    1. Sjogren’s syndrome – xerostomia, mycosis
    2. disseminated lupus erythematosus
    3. dermatomyositis – swallowing disorders
    4. scleroderma – mouth orifice diminished (artificial nutrition)
  - other diseases
    1. anemia: iron-deficiency, megaloblastic – Hunter’s glossitis
    2. hemorrhagic diathesis – bleeding gums
    3. leukemia – ulcerations, gingival hypertrophy
    4. liver cirrhosis – red tongue without papillae, red lips

**Living and working conditions:**

- sweets and pastry shops – intake of sweets -> dental decay
- typographic industry – occupational poisoning with Bi, Cr, Pb, Hg – oral symptoms
- smoking – stomatitis; pipe smoking – lip cancer

### **Family history:**

- hare lip or other malformations – heredity load
- infectious diseases evolving with oral lesions having a wide family and population contagion (scarlet fever, diphtheria, viral or streptococcal amygdalitis, infectious mononucleosis)

### **8.1.2. Symptoms of the diseases of the oro-pharyngeal cavity**

#### **A. Pain**

- Located at the oral level: spontaneous, caused by food ingestion
- Causes:
  - o local
- dental disorders: pulpitis, ill fitted dentures
- glossodynia (tongue pain): (a) disorders of the tongue: glossitis, ulcerations, tumours, burns, local injury; (b) neighbouring disorders with repercussion on the tongue
- oral mucosa disorders: stomatitis – viral, mycotic, post-radiotherapy
  - o general
- Biermer's anemia (B12 deficiency)
- iron-deficiency anemia
- B2, B6, PP deficiencies
- Behcet's disease
- Hg poisoning
- uremia
- diabetes mellitus
- epilepsy
- food allergies
  - o glosso-pharyngeal and trigeminal neuralgia (ophthalmic, maxillary, mandibular nerves)

## B. Taste changes

- taste loss – AGEUSIA, like in neurological and cerebral disorders
- unpleasant taste
  - dental caries and alveolar infections
  - dental prostheses
  - pharyngitis, tonsils infections
  - broncho-pulmonary suppurations – bronchiectasia
- Taste alteration – DYSGEUSIA
  - sour, acid – acid regurgitation – reflux esophagitis and duodenal ulcer
  - bitter taste: biliary lithiasis, chronic gallbladder disease, neurasthenia
  - radish taste – advanced liver failure
  - metal taste – chronic metal poisoning (Pb, Cr)
  - pregnancy, menopause – funny tastes

**C. Oro-pharyngeal dysphagia:** painful difficulty in swallowing (occurs during the oral-pharyngeal stage of swallowing)

- Causes

- local – act by mechanical obstruction or causing local pain (e.g. acute angina, tonsil phlegmon)
- neighbouring – act by compression or distension, with deformation sometimes with pain (e.g. latero-pharyngeal phlegmon, laryngeal tumours, goiter)
- general – act by reflex, by spastic or paretic effect (e.g. spasmophilia, glosso-pharyngeal nerve paresis)

## D. Disturbances of salivation:

- Hypersalivation

- dental eruption in children
- pregnancy
- acute oral inflammations: stomatitis, gingivitis

- local cancers
- gastroesophageal reflux, esophagitis
- heavy metal poisoning: Hg, Pb, drugs
- rabies, tabes
- chronic alcoholism
- Hyposalivation – feeling of dry mouth - xerostomia
  - massive dehydration
  - atropine, opiates poisoning
  - Sjogren’s syndrome
  - acute diseases evolving with high temperature

### **8.1.3. Clinical examination of the oral cavity**

#### **Odor of the mouth and of the expired air**

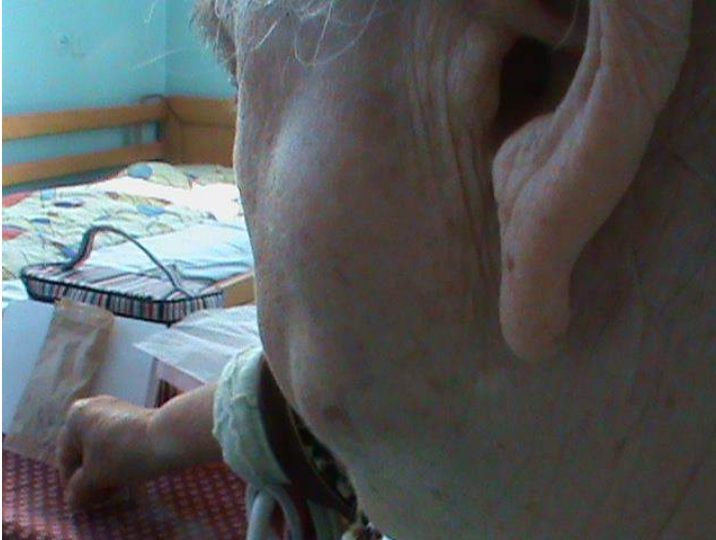- Local causes: bad breath (foetor oris)
  - poor local hygiene
  - tooth decay
  - alveolar pus
  - dental abscesses
  - ulcerous, gangrenous stomatitis
  - suppurating chronic rhino-sinusitis
  - ulcerous-necrotic angina
  - mechanisms: development of putrefaction flora – anaerobic fermentation – volatile sulfur compounds, aggravated by xerostomia
- General causes – volatile substances in the expired air
  - respiratory infections – fetid, repulsive smell filling the patient’s room
    1. long-term chronic purulent bronchitis, stasis
    2. bronchiectasis with bronchorrhea
    3. lung abscesses with inadequate pus drainage
    4. lung gangrene
  - digestive diseases

1. intestinal occlusion – fecaloid smell
2. acute fulminant hepatitis with acute liver failure – indole, scathol, radish smell – “foetor hepaticus”, or fresh liver
3. in acute alcoholic gastritis the smell of aldehyde may be encountered
  - poisoning
    1. with phosphorous or selenium – garlic smell
    2. with lead (Pb) – metallic smell
  - other causes
    1. diabetic keto-acidosis – acetone or rotten apples smell
    2. renal failure in the uremic phase – ammonia smell
    3. menstruating women have a specific odour of the mouth
    4. diphtheria and Plaut-Vincent’s angina – sugary odour

### **Salivary glands**

Swelling of the 3 salivary glands:

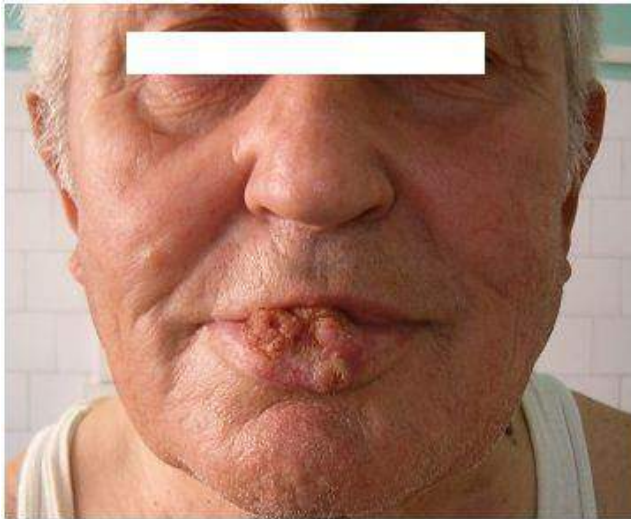
- sialadenitis
- sarcoidosis
- salivary lithiasis – calculus trapped in the canal, tumours
- in epidemic parotiditis the painful swelling of the parotid glands on both sides occurs
- simultaneous involvement of the salivary and lacrymal glands – Sjogren’s syndrome, chronic lympholeukosis, Mikulicz’s syndrome (in chronic lymphocytic leukemia: hypertrophy of the salivary and lachrymal glands on both sides with reduction to almost disappearance of the secretions).



**Figure 99. Tumor of the parotid gland**

**Lips:** volume, color, aspect changes, ulcerations, eruptions, scars

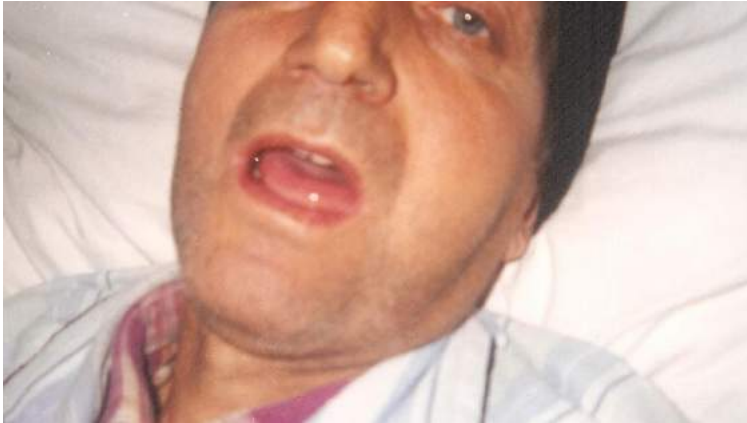- **Volume:** individual and race features: enlarged in: myxedema, accromegaly, tumours, hemangiomas, Quincke's oedema



**Figure 100. Tumor of the inferior lip**

- **Color**

- pale in anemias
- red in liver cirrhosis



**Figure 101. Red (carminated) lips in a cirrhotic patient**

- cyanotic
  - a) superior vena cava syndrome
  - b) heart diseases: heart failure, valve diseases
  - c) asphyxia
  - d) chronic cor pulmonale
  - e) broncho-pulmonary disease
- reddish-purple: polycitemia vera
- **Aspect:** in dehydration: cracked dry lips, brownish-black adherent crusts in severe poisoning, typhoid fever, typhos
- **Eruptions:** labial and/or nasal herpes
- **Ulcerations.** Causes
  - vitamin B deficiency
  - trauma / injuries
  - neoplasm
  - fissures at lip corners in anemia by iron-deficiency



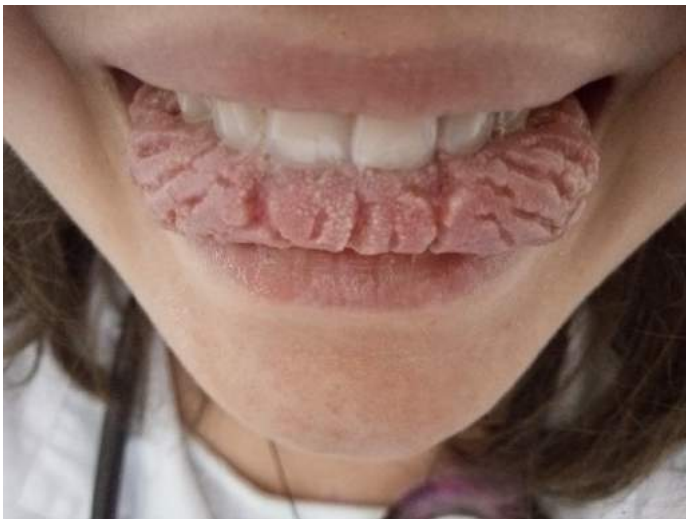- angular cheilitis – curb bit – is an infectious pyodermitis (streptococcus plicatilis). In the beginning small blisters occur, which break and leave a deep painful and persistent fissure
- primary syphilis (hard chancre) may be located at the lips in the form of small red ulcerations, round or oval, with slightly raised, hard margins, accompanied by satellite adenopathy
- spindle cell carcinoma of the lips – occurs in elderly men, pipe smokers; initially as an apparently common fissure, painless, hardenend, extremely persistent
- **Scars** – radial to the mouth corner or starting from the chin to the lower lip – congenital lues

## **Tongue**

The objective examination of the tongue aims at checking: mobility, volume, aspect (color), ulcerations

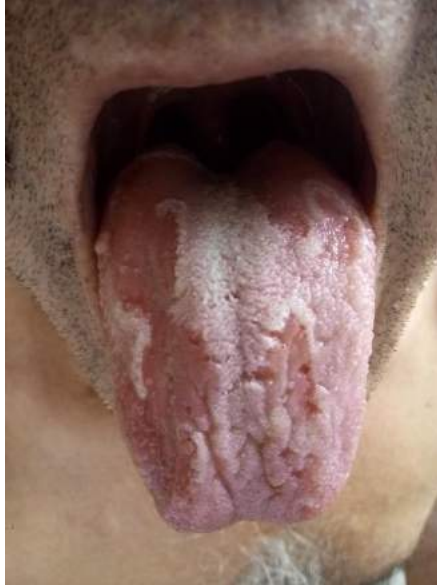- **Mobility**: assessed by inviting the patient to put out his/her tongue and perform movements on command
  - impossibility to put out the tongue – hypoglossus nerve paralysis
  - difficulty in moving the tongue accompanied by fine tremor occurs on severe toxic states and hypoglossus paresis
  - lateral deviation of the tongue – toward the affected side in case of unilateral hypoglossus paralysis by hemorrhage of brain tumours
  - a trembling tongue may be a sign of intoxication with Hg, alcohol, generalized progressive paralysis, multiple sclerosis and brain tumours
- **Volume**
  - macroglossia – enlarged tongue
  - may be permanent in accromegaly, myxedema, amyloidosis

- transient in glossitis, Quincke's edema, lymphoma
- tongue atrophy: bulb, hypoglossus injuries, tabes
- **Aspect**
  - charged (saburral) tongue – with the dorsal surface covered by a whitish, yellowish layer formed of exfoliated cells – occurs in cases in which natural grating by salivary flux decrease cannot be achieved: high body temperature, dehydration, mastication disorders (typhoid fever – parrot tongue, thick, dry, brownish black layer)
  - dry or scorched tongue, with low humidity, occurs in high body temperature, dehydration (diabetic ketoacidosis, diarrhea, uncontrolled vomiting, heavy sweating, Sjogren's syndrome)
  - fissured tongue – numerous grooves 2-5 mm deep on the whole surface – scrotal tongue or leaf-like tongue (like the veins of a leaf) in congenital abnormalities or familial aggregation



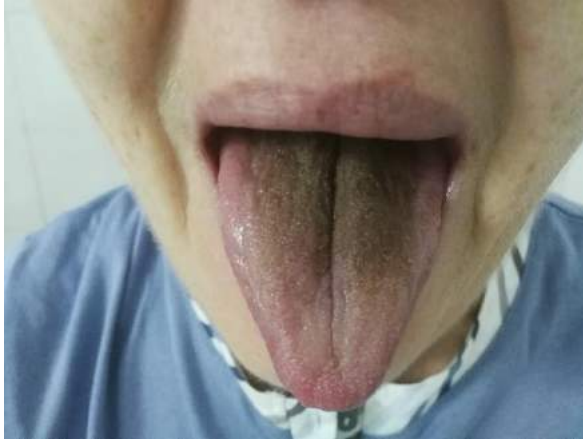**Figure 102. Fissured tongue in a teenager**

- geographic tongue – aspect of a superficial desquamated or depapillated areas alternating with areas without desquamation but covered by whitish deposit – aspect of a geography map, allergic background



**Figure 103. Geographis aspect of the tongue**

- melanoglossia – black or hairy tongue, due to the hypertrophy or hyperkeratosis of the papillae after antibiotic therapy – the tongue surface appears as covered by entangled hairs



**Figure 104. Black hairy tongue – poor local hygiene**

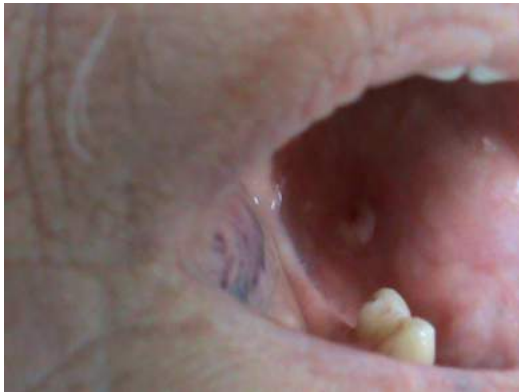- strawberry tongue – desquamation phase in scarlet fever – bright red color with enlarged papillae
- smooth tongue – red with smooth surface (papillary atrophy). This aspect associated with tongue pain – Hunter’s glossitis – occurs in Biermer’s anemia – an early sign.
- wooden tongue – in amyloidosis, with reddish-purple color and enlarged infiltrated tongue
- tongue leukoplakia – characterized by round or oval plaques on the surface, white and shiny, an aspect found in lues or after irritations, bad teeth, smoking, alcoholism – it represents a precancerous state
- **Ulcerations of the tongue**
  - **traumatic:** dental caries, faulty dentures, self-biting during epileptic bouts, or rupture of the frenulum in children with whooping cough
  - **chemical:** Hg poisoning, ingestion of caustic substances, topical drugs
  - **infectious;** lues – hard chancre (round or oval ulceration with raised margins, with a whitish aspect, the lesion is

not sensitive, located on the tip of the tongue, accompanied by cervical adenopathy; in secondary syphilis mucous plaques occur, painless, superficial that become ulcerous; tertiary ulcer is the syphilitic tongue. In tuberculosis ulcerations occur on the dorsal surface and on the tip, long-shaped with ragged very painful margins, no lymph node swelling being associated.

- **tumoral** – crater-like aspect, irregular contour, hard and thickened margins, the lesion covered by a grayish matter. Lesions are painful, bleed easily and are accompanied by foul mouth, adenopathy and sialorrhea – acute leukemia.

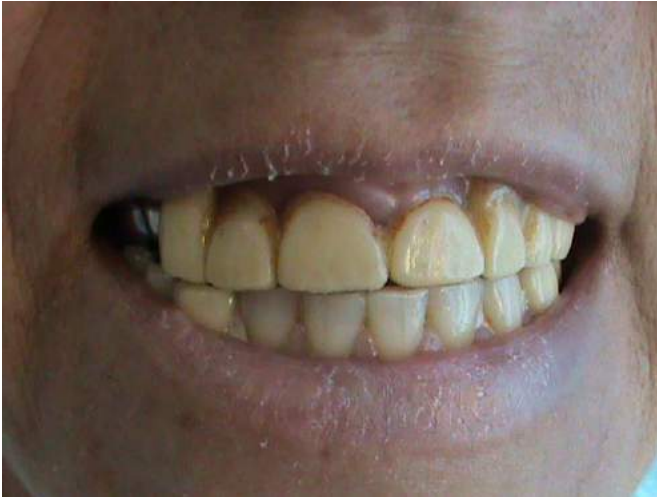### **Internal surface of the cheeks**

- color: pale, cyanotic, red
- aspect: altered in stomatitis
  - erythematous: smoking, caries, prostheses
  - erythematous-purulent: erythematous aspect with white-yellow spots
  - mycotic: white deposits, continuous or in plaques: Candida
  - aphtous: vesicles that break – painful superficial ulcers



**Figure 105. Aphthous ulcer of the internal surface of the left cheek**

- ulcerous-membranous – necrosis and mucosal tearing – irregular ulcerations covered by a grey mass with a red halo - association with fuso-spirillar
- gangrenous – children with impaired health, infectious causes: streptococcus, fuso-spirillar
- eruptions: in measles on the mucosa or the gingivo-labial groove at the level of the upper molars – small white spots surrounded by a red halo – ***Koplick's sign*** – early diagnostic value and differential from rubella
- pigmentary plaques in **Addison's disease**, brown-grey spots on the internal cheek surface and gums – early sign



**Figure 106. Hyperpigmentation in Addison disease**

### **The soft palate**

Paralysis of the palate: bulbar-pontile syndromes, brain tumours, encephalitis

- in case of bilateral paralysis, the soft palate and the uvula hang flaccid and are motionless, while fluids swallowed come back through the nose. Patients complain of dysarthria and the palatal reflex is abolished

- in unilateral paralysis – curtain sign (the soft palate raises only on the unaffected side and the uvula moves to the same side when pronouncing the vowel “a”).
- in Quincke’s edema the soft palate and the uvula are much enlarged and a glottic edema is present leading to the patient’s asphyxia

**The pharynx.** Inflammation of all the visible structures (exposed + Waldeyer’s lymphatic ring) -> ANGINA – pharyngo-amygdalitis

- **Erythematous angina** – simple, catarrhal – red tonsils, pharyngeal passage, soft palate and uvula
  - o **Etiology:** bacterial: streptococcus, viral (isolated, or within other infectious diseases: scarlet fever, measles, influenza, infectious mononucleosis)
- **Purulent angina – follicular.** Initially occurs as erythematous, followed by small white-yellowish spots, creamy-like due to the exudates in the tonsil’s crypts. The causes are similar with those of erythematous angina
- **Phlegmonous angina**
  - o complication of erythematous angina
  - o manifested as a tonsillar or peri-tonsillar phlegmon and may occur with diphtheria or the following symptoms:
    - intense pulsating pain radiating to the ear
    - local swelling or deviation of the soft palate
    - marked dysphagia
    - trismus
    - high fever 39-40 Celsius, shivers, altered state, tachycardia, pallor, asthenia

Objective examination: painful neighbouring adenopathy; locally: if the patient can open the mouth the tonsil appear tumefied, intensely red.

- **Vesicular angina**
  - herpetic, aphthous (herpangina), or more rarely due to small pox
  - on the diffusely erythematous surface small vesicles appear, that break and form superficial multi-cycle ulcers. This type of angina quickly becomes ulcerous and ulcero-membranous
- **Ulcerous angina** occurs in the 2<sup>nd</sup> week of the typhoid fever, with superficial oval ulcers on a grey background, located mainly on the anterior pillars of fauces
- **Pseudo-membranous angina:** diphtheria, scarlet fever, rarely tonsillar syphilitic chancre  
**Prototype:** diphtheric angina (*Corynebacterium diphtheriae*): pharynx is red, edematous, tonsils with white exudate, detachable in the beginning then adherent – false white membranes, smooth opal-like aspect, covering the mucosa gradually and extending to the larynx. Associated with painful adenopathy. The patient’s mouth has a sugary smell. Extension to the larynx leads to the diphtheric croup manifested by dysphonia and laryngian obstruction
- **Ulcero-membranous angina:** Plaut Vincent IMN
  - tonsillar ulcerations on a hyperemic erythematous background, dirty grey deposit, mucosa bleeds when detached
- **Necrotic angina** – acute leukemia, agranulocytosis
  - necrotic areas at the tonsil level progressing deeper

#### 8.1.4. Paraclinical investigations

- ENT
- Dental
- Oral and maxillofacial surgery
- X-ray



- Bacterial: smears, cultures
- Serum: ASLO titre, IMN
- Blood counts
- Biopsy for tumours

## 8.2. SEMIOLOGY OF THE ABDOMEN

### 8.2.1. SYMPTOMS IN ABDOMINAL DISEASES

#### *Abdominal pain*

- common symptom of most diseases involving organs in the abdomen or vicinity
- 2 types of pain:
  - **Visceral:** reduced intensity, longer duration, vague location: **Exception: colic**, due to a strong stimulation of the visceral pain receptors. Colic is an intense visceral pain, more precisely localized, similar to a cramp, torsion or tear, radiating in a somatic area (dermatome/sclerotoma), accompanied by vegetative manifestation (pallor, sweating, vomiting, hypotension)
  - **Somatic:** in its superficial form – cutaneous, it is precisely localized in a dermatome. The source of the pain stimulus: skin, subcutaneous tissue, muscle, tendons, fascia, parietal peritoneum
- **Diffuse abdominal pain** occurs in:
  - diseases of the **peritoneum:** acute peritonitis, primary or secondary to cavity organs perforations
  - **intestinal** diseases
    - enterocolitis
    - food poisoning
    - typhoid fever
    - cholera

- ileus
- **acute and chronic intoxications**
  - mercury
  - insecticides / fungicides
  - fungi
  - lead
- **Mesenteric vessels obstruction** (atherosclerosis, thrombosis, embolism, panarteritis nodosa) – intestinal-mesenteric infarction; **sclerosis, dissecting aortic aneurysm.**
- **general diseases** evolving with abdominal pain:
  - porphyria
  - Henoch’s purpura
  - tabes
  - hyperthyroidism
  - adrenal insufficiency
- **The pain located** exclusively or predominantly at the level of one of the abdominal regions generally correspond to disorders in that area. This rule has numerous exceptions:

<b>Region</b>	<b>Causes</b>
Epigastrium	Gastric and duodenal ulcer, gastric neoplasm, pyloric stenosis, gastric volvulus, hiatal hernia Acute cholecystitis, lithiasis, biliary colic Liver enlargement due to stasis Acute and chronic pancreatitis
Right hypochondrium	Acute and chronic hepatitis, liver abscess, peri-hepatitis, liver enlargement due to stasis, liver cancer Biliary disorders Subphrenic abscess, duodenal ulcer, neoplasm

	of the colic right angle, appendicitis (subhepatic)
Left hypochondrium	Splenic abscess and infarction Ulcer of the small gastric curve, gastric air Blocked arocholia, cancer of the left colic flexure Subphrenic abscess
Umbilical	Peptic ulcer, acute and chronic pancreatitis, acute enterocolitis, intestinal or transversal colon stasis, sclerosis of the abdominal aorta or of the mesenteric vessels, abdominal aorta aneurysm
Sides	Reno-urethral colic, pyelitis, urinary lithiasis, colitis
Hypogastrium	Acute and chronic cystitis, bladder lithiasis, bladder neoplasm and tuberculosis Metro-annexitis, perimetritis, uterine neoplasm, pelvi-peritonitis Sigmoiditis and peri-sigmoiditis
Right iliac fossa	Appendicitis, typhlitis, urinary lithiasis, orchiepidydimitis
Left iliac fossa	Sigmoiditis, peri-sigmoiditis, dysentery, sigmoid neoplasm, metro-annexitis, ovarian cyst, left extrauterine pregnancy

**Nausea:** unpleasant feeling generated by the repulsion to ingest food and the need to vomit, but not necessarily followed by vomiting, accompanied by other various disorders:

- hypersalivation
- hyper-sweating
- bradycardia
- hypotension

- pallor

**Causes:**

- pregnancy in the first trimester
- digestive diseases: appendicitis, cholecystitis, gastro-duodenal ulcer, digestive cancer
- non-digestive diseases: chronic renal failure, migraine, vertigo (kinetosis), drug-induced disorders (digoxin, morphine, antibiotics)

**Vomiting:** sudden emptying of the stomach or even bowel through the mouth; reflex somato-visceral act

- with the vomiting center situated in the bulb
- receptors:
  - internal receptors: esophagus, stomach, intestine, appendix, diaphragm, peritoneum
  - sensory receptors: smell, taste, sight, vestibular
  - afferent impulses from visceral receptors
  - sensory impulses: foul smell, sight of altered food
  - mental stimulation

**Causes:**

- central vomiting
  - not preceded by nausea, explosive, spontaneous
  - tumours, cerebral abscesses and hemorrhage, cranio-cerebral trauma, meningitis, hypertensive encephalopathy, internal ear disorders, migraine
  - endogenous poisoning: uremia, diabetic ketoacidosis, toxic pregnancy
  - exogenous poisoning: morphine, antibiotics, cytostatics
- peripheral vomiting
  - preceded by nausea, produced by a reflex mechanism

- in digestive disorders
  - a) gastro-duodenal diseases, gastro-duodenal ulcer, gastric cancer, pyloric stenosis, acute and chronic gastritis, food poisoning
  - b) intestinal diseases: occlusions, gastro-intestinal fistula
  - c) liver and biliary diseases: acute hepatitis, acute cholecystitis with or without lithiasis
  - d) surgical acute abdomen: appendicitis
  - e) acute pancreatitis
  - f) digestive perforations
- in non-digestive diseases
  - a) reno-urethral colic
  - b) pregnancy
  - c) pelvic tumours and inflammation
  - d) labyrinth disorders: flying, car sickness, vestibular syndrome
  - e) heart failure
  - f) septicemia
  - g) nauseating cough

### **Semiological analysis of vomiting**

#### *Vomiting timetable*

- morning: alcoholism, pregnancy, uremia
- early after meals: acute gastritis
- 1-2 h after meals: gastric ulcer, cancer, gastric atonia
- 2-4 h after meals: duodenal ulcer, gastric dilation
- very late: pyloric stenosis

#### *Frequency*

- rare, sporadic: dyspepsia
- frequent: acute gastritis, pregnancy, pyloric stenosis

- uncontrollable: severe dysgravidia, uremia

*Quantity*

- abundant: pyloric stenosis, intestinal volvulus, high intestinal stenosis

*Smell and taste*

- sour: acute gastritis, duodenal ulcer
- bland: gastric achylia
- rancid: pyloric stenosis, gastric stasis
- fecaloid: gastro-colic fistula, peritonitis
- green apple smell: diabetic ketoacidosis
- bitter: gallbladder disorders

*Content*

- watery, mucous: pregnancy, gastritis, gastric cancer
- food: pyloric stenosis, gastro-duodenal ulcer
- bile: acute and chronic cholecystitis
- fecaloid: intestinal occlusion, gastro-colic fistula
- ground coffee or blood: hematemesis of various causes
- pus: phlegmonous gastritis

***Hematemesis and melena***

- **Hematemesis** – elimination of fresh or digested blood from the upper GI tract in the vomit
- **Melena** – elimination of digested blood through stools – pitch black, soft, shiny, coming from the upper GI tract

**Hematemesis should be differentiated from:**

- swallowed posterior nose bleeding
- hemoptysis (elimination of red oxygenated blood mixed with saliva through cough, absence of food)
- bleeding from the gums

Melena to be differentiated from: dark stools caused by the ingestion of black berries, beetroot, food rich in iron, food containing blood

Melena follows hematemesis when the blood amount exceeds 80 ml, it may occur without hematemesis

Hematemesis and melena may have an abrupt onset or may be preceded by symptoms and signs indicating post-hemorrhagic acute anemia (palpitations, sweating, vertigo, pallor, tachycardia)

- 100-200 ml blood lost – arterial hypotension
- 500 ml blood lost – hemorrhagic shock

### **Causes of upper GI hemorrhage**

- esophagus: ruptured esophageal varices, esophageal cancer, esophagitis, esophageal ulcer
- stomach and duodenum: acute gastric and duodenal ulcer, hemorrhagic acute gastritis (post NSAIDs), gastric cancer
- small bowel: malignant tumours, intestine-mesenteric infarction, diverticulitis, intestinal Crohn's disease
- malignant tumours of the bile ducts
- blood vessels disorders: hereditary hemorrhagic teleangiectasia, aortic aneurysm ruptured into the digestive tract, hemangioma

### ***Appetite disorders***

- **Hunger** – sensation of epigastric emptiness and need to ingest food; triggered spontaneously. **Satiety** – sensation opposed to hunger, occurring after a certain amount of food
- **Appetite** – pleasure to eat
- **Hyperorexia** – exaggerated hunger, occurring in:
  - duodenal ulcer
  - hyperthyroidism
  - intestinal parasitosis
  - uncompensated diabetes mellitus
- **Bulimia** – absence of the sensation of satiety after eating; mental disorders
- **Anorexia** – absence of hunger

- complete – for all foods
- selective – certain foods (cancer and fats – gastric cancer)

*Anorexia nervosa – psychiatric disease encountered in young women*

*Anorexia and weight loss – alarming symptoms of severe disorders!*

- **Sitophobia:** failure to feed because of abhorrence of food, fear of food-induced pain
- **Perverted appetite:** craving for chalk, wood, earth
  - pregnancy
  - mental disorders

### *Hiccups*

- short and brisk in-breaths determined by spastic contractions of the diaphragm

#### **Causes:**

- esophageal tumours
- gastric distension: abundant meal, aerophagia
- perforated gastroduodenal ulcer, gastric cancer
- intestinal occlusion
- acute peritonitis
- subphrenic abscess
- extra-digestive causes: alcoholic intoxication, diabetic ketoacidosis, brain tumours, neurotic states

## **8.2.2. OBJECTIVE EXAMINATION OF THE ABDOMEN**

Clinical topography of the abdomen:

- 9 topographic areas
- 4 lines – 2 horizontal
  - the upper line at half distance between the upper manubrium sterni and the pubic bone, the lower one unites the fore upper iliac crests
  - 2 vertical: passing through the middle of the crural arches



## ***EXAMINATION OF THE ABDOMEN***

The following are of interest: shape, volume, the position and aspect of the umbilical scar, aspect of the skin, pulsations, peristaltic movements and the way the abdomen participates in the breathing movements.

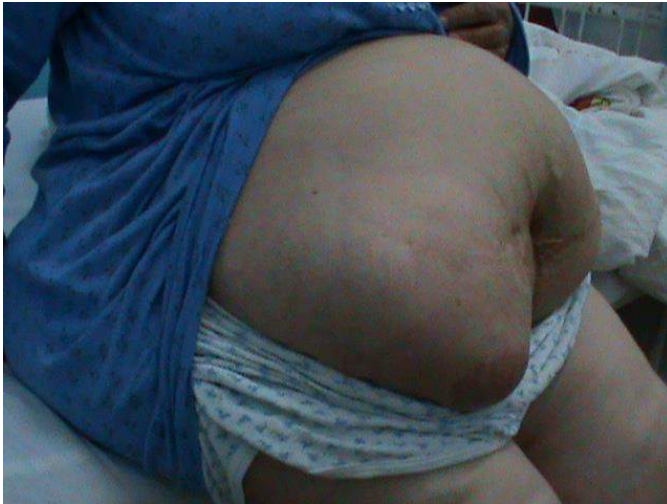- **Shape and volume**

- ⇒ vary with age and gender

- ⇒ balloon-like in children

- ⇒ flat in adults

- ⇒ in elderly persons and multiparous women the volume increases when the wall muscles relax



**Figure 107. Abnormal abdomen due to obesity and multiple surgical antecedents**

- **Swelling up of the whole abdomen** occurs in:

- ⇒ obesity

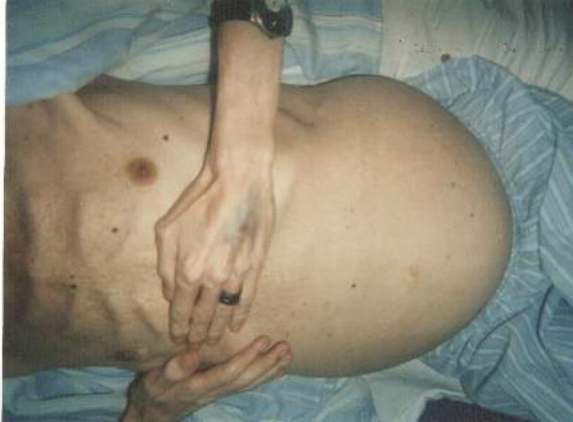- ⇒ anasarca (dropsy)

- ⇒ ascites

- ⇒ meteorism

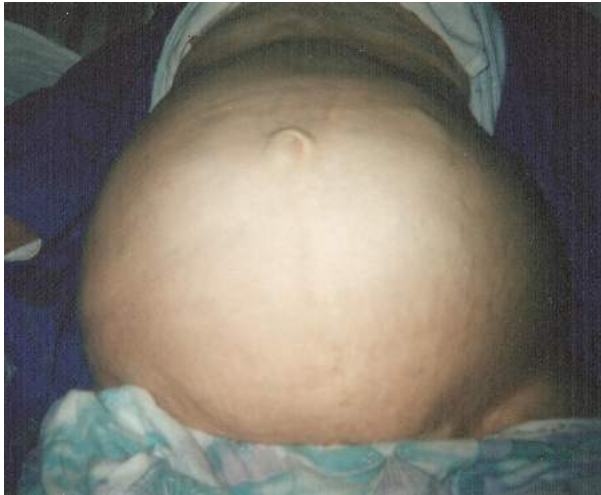- ⇒ ileus
- ⇒ pneumoperitoneum
- ⇒ giant ovarian cyst
- ⇒ large abdominal tumours

In ascites moderate collections tend to occupy mainly the sides and the hypogastric area (dorsal decubitus), due to gravity – *toad abdomen*



**Figure 108. Ascites in a cirrhotic patient**

Abundant collections lend an aspect of balloon-like abdomen.



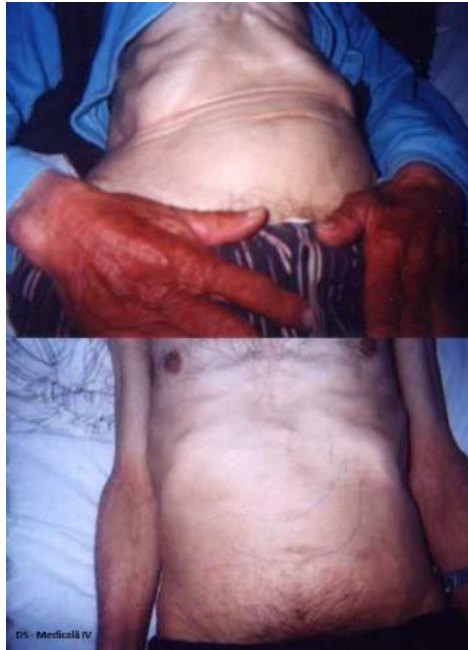**Figure 109. Massive ascites in a cirrhotic patient**

Unlike the regular swelling in ascites, giant intra-abdominal tumours will create an *irregular contour*.

**Regional swelling** makes the abdomen to appear asymmetrical.

**Causes:**

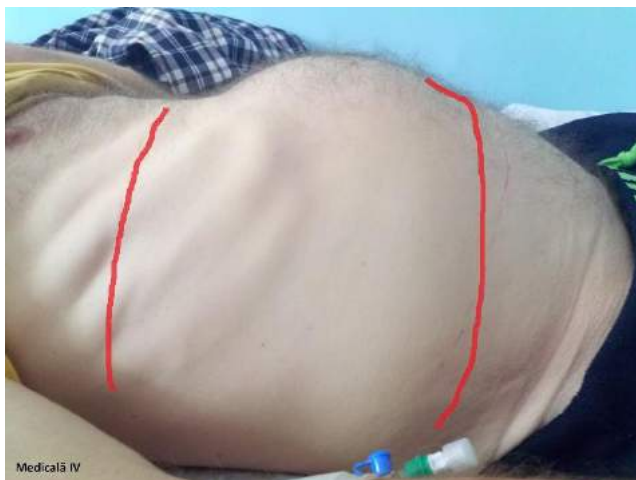- pyloric stenosis
- acute stomach dilation, gastric tumours



**Figure 110. Regional abdominal swelling in pyloric cancer**

- tumours of the pancreas of left liver lobe
- giant hepatomegaly
- hydro-cholecyst
- giant splenomegaly
- kidney tumours, polycystic kidney
- pyelo-nephrosis on a sagging kidney
- tumours of the ascending colon
- umbilical hernia

- postoperative eventration
- tumours of the descending colon
- pregnancy
- uterine fibroma
- ovarian cyst
- tumours of the urinary bladder
- urine retention

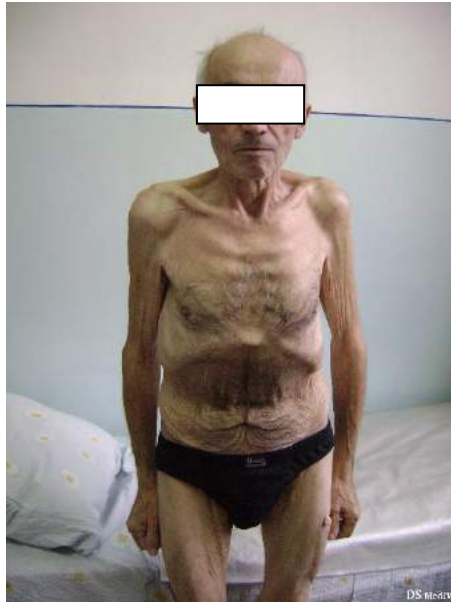

**Figure 111. Giant hepatomegalia in hepatocellular carcinoma**

**Delimited swelling** is due to abdominal hernias. They are round or oblong, with various volumes and are increased by standing up or after coughing, while lying down makes them appear smaller.

**Total abdomen retraction** makes more visible the xyphoid appendix, the ribcage borders, iliac crests, crural arches, with a general aspect of a boat – *scaphoid abdomen*. Found in hunger, cachexia, saturnine colic, the first stage of acute generalized peritonitis.

**Retraction of the upper part of the abdomen**, in the shape of a bag when the patient stands – *pending abdomen* – occurs in visceroptosis (visceral sagging) in multiparous women.



**Figure 112. Scaphoid, retracted abdomen**

### **Position and aspect of the umbilicus**

Normally the umbilical scar is slightly below the abdominal wall plane, situated on the median line, half way between the xyphoid appendix and the pubic bone.

- absent when surgically excised
- deeply set in obesity and anasarca
- pops out like a glove finger in large ascites

### **Aspect of the abdominal skin**

- skin is pale, shiny and stretched in ascites
- hyperpigmentation of the median line indicates Addison's disease
- jaundice may be more obvious at the abdominal level
- postoperative scars provide information on the history of anamnestic or comatose patients
- the sides and the hypogastrium may indicate a sudden increase in the abdominal volume (pregnancy, obesity, ascites) –white

parallel pearly lines due to the rupture of elastic and muscular fibers in the dermis, called stretch lines

- violet bluish lines are seen in Cushing's disease and after long-term corticotherapy

### **Pubic hair**

- appears in adolescence and is sex specific
- women with adrenal virility have a masculine type pubic pylosity
- absence or disappearance of pubic hair occurs in cirrhosis, hypopituitarism and hypogonadism

### **Skin rashes**

- typhus roseolae
- abdominal-genital Zoster herpes

**Collateral abdominal circulation** is found in portal vein obstruction, the medusa head with the flowing direction of the centrifuge blood, as well as in inferior vena cava obstruction – tortuous veins on the sides with blood flowing upwards.

**Abdominal aorta pulsations** are visible in case of aneurysm, aortic insufficiency, in emaciated patients with scaphoid abdomen or ptosis of the viscera.

**Respiratory movements of the abdomen** (swelling of the upper half when breathing in) are normal and are more obvious in men and children (costal-abdominal respiration).

- reduced respiratory movements are found in meteorism or ascites
- absence of movements indicates an inflammatory process under the diaphragm, subphrenic abscess, acute peritonitis
- in phrenic nerve paralysis the participation of the abdomen in respiration is paradoxical – swell in expiration and shrinks in inspiration

## ***PALPATION OF THE ABDOMEN***

### **General technique**

Palpation is performed in dorsal and lateral decubitus and with the patient standing

- with the patient in dorsal decubitus, ensure that the wall muscles relax completely, head and trunk being supported, thighs slightly bent toward the abdomen, with soles resting on the bed
- the physician will avoid any action entailing sudden reflex contraction of the abdominal muscles (cold hands, hasty palpation, induction of pain)
- palpation is systematic, starting from an area remote from the one indicated as painful by the patient; neighboring areas are explored one after the other
  - superficial palpation targets abdominal wall structures
  - deep palpation targets the internal organs
- palpation is performed with one or two hands, the latter allowing a quick review of the whole abdomen, locating formations or fighting the resistance of the abdominal wall.

### **Superficial palpation of the abdominal wall**

- abdomen skin is elastic and mobile in the deep layers, but loses elasticity and becomes flaccid in emaciated, dehydrated or multiparous patients
  - non-suppurative inflammation of the subcutaneous tissue – *cellulites*, makes the skin appear red, edematous, sensitive, aspect of orange peel
- pinching the subcutaneous abdominal flap provides information on the nutritional state
  - in anasarca the skin and subcutaneous tissue are infiltrated, keeping the pressure finger imprint longer

- tumours of the fatty, muscular tissues are easier to evidence when the patients starts raising from the bed
- normal muscular tonus confers the feeling of supple, elastic abdomen
  - in disease it may be:
    - relaxed – multiparous, emaciated patients
    - resistant – hyperexcitable patients who cannot relax the abdomen during palpation. Extreme gentleness but firmness is required by the physician, who may even engage in conversation in order to distract the patient’s attention
    - resistance may be felt in areas corresponding to organs that are tender due to inflammation: pancreatitis, intestinal-mesenteric infarction or tumours
    - the extreme form of abdominal wall contraction is *muscular defense*, a sign of acute peritonitis. The feeling is of hypertonia, then wood-like resistance that cannot be overcome. Palpation causes intense pain and cutaneous hyperesthesia is usually present.
- hernial tumours are soft, regular when they contain bowel and irregular when containing epiploon. Some may be reduced by palpation.

***Induced pain:*** found in visceral or parietal abdominal complaints

### **Cutaneous hyperesthesia**

- type of pain caused by visceral irritations or inflammations: cholecystitis, appendicitis, ulcer
- limited in *Head’s areas* corresponding to the organ affected according to a precise topography
- patients perceive a superficial pain, sometimes like a burn, sometimes simply unpleasant, caused by the contact with



clothes or bedding; the physician may induce it by slightly brushing the area with the finger tips or a cotton swab.

### **Sensitive points and areas**

- xiphoid – under the xyphoid appendix
  - sensitive in the disorders of the eso-gastric junction, the cardia
- epigastric – where the upper one third joins the xypho-umbilical middle third
  - gastric and duodenal ulcer
- solar – between the upper one third with the lower third of the xypho-umbilical line
  - corresponds to the solar plexus, sensitive to painful diseases of the abdomen or the small pelvis
- cholecyst – under the right ribcage margin
  - cholecystitis, bile lithiasis, dyskinesia
- Cahuffard's pancreato-gallbladder triangle – between the xypho-umbilical line and the line uniting the umbilicus with the right rib cage margin, 45 degrees angle from the preceding one
  - common bile duct lithiasis, duodenal ulcer, acute pancreatitis, pancreatic head cancer
- mesenteric points – on both sides of the umbilicus
  - sensitive in inflammations of the mesentery or –epiploon
- there are 3 appendiceal points, sensitive in acute and chronic appendicitis
  - *McBurney's point* – external 1/3 with middle 1/3 of the line between umbilicus and the right iliac spine
  - *Moris's point* – on the same line 3-4 cm from the umbilicus
  - *Lanz's point* – it is situated on a line connecting the two anterior superior iliac spines one third of the distance from the right spine

- tubal-ovarian points – at the middle of the perpendicular lines between the umbilicus and the crural arches
  - o sensitive in annexites and extra-uterine pregnancy

### **Blumberg's maneuver (rebound tenderness)**

- decompression of the abdomen by sudden lift of the hand
- the patient complains of more pain than when the area is pressed
- positive in peritoneal irritation

**Mendel's sign** (the sign of the bell) – tapping on the abdomen with the finger causes intense pain in the area corresponding to the perforated organ

### **Palpation of intra-abdominal organs**

Besides the usual palpation technique, the organs accessible to this method are the left liver lobe, the lower pole of the right kidney, the aorta, the transversal and sigmoid colon, urinary bladder before urination, pregnant uterus after the 3<sup>rd</sup> month

- **Thickening:** feeling of dull resistance determined by non-suppurative inflammation of the peritoneum near an abdominal organ – perivisceritis
- **Wave sign** – present in ascites

### **PERCUSSION OF THE ABDOMEN**

- normally the percussion sound is *tympanism*, due to air-containing organs: stomach, bowels; over the full stomach or descending colon the sound is dulled; the liver and the spleen are dull, the pancreas and the kidneys are not accessible
- *hypersonority* happens in increased gas content; aerogastria, acute gastric dilation, meteorism, aerocholia, intestinal occlusion and pneumoperitoneum. In the latter the sound is accompanied by the disappearance and decreased liver or spleen dullness

- *dullness and sub-dullness*
  - obtained when bowels are empty (hunger) or full (constipation, megacolon), over large non-gaseous abdominal masses in contact with the abdominal wall (solid tumours, cysts, urinary globe, pregnant uterus, liver and spleen enlargement), in ascites, tuberculous peritonitis
- percussion sound in ascites depends on the amount of fluid in the peritoneal cavity
- in the beginning, when fluid is less, it accumulates in the declivity areas. Dullness will be in the sides if the patient is in dorsal decubitus, in the hypogastrium if standing, in the umbilical area if on the knees and arms.
- dullness changes its shape with the patient's position
- in large ascites the whole abdomen becomes dull, except a central area of tympanism
- hypogastric dullness in ascites has a round contour with the concavity upwards, while in the urinary globe, fibroma, pregnancy, ovarian cyst, the concavity is distal.
- in the fibro-caseous form of peritoneal tuberculosis, the intestinal loops containing air are brought together by exudative processes, which results in an alternation of tympanism and dullness similar to a chess board.

### ***ABDOMINAL AUSCULTATION***

- limited usefulness
- important in diseases of the esophagus, ileus, aortic aneurysm (intense holosystolic murmur), stenosis of the mesenteric arteries
- peritoneal brushing occurs in perihepatitis, spleen infarction and liver metastases

- in the fibro-caseous form of peritoneal tuberculosis, crepitation may be perceived due to the rubbing between the false membranes formed of the fibrinous exudates. They may be also palpated under the form of “snow crepitation”.

## ***ADDITIONAL EXAMINATIONS IN ABDOMINAL DISEASES***

### **Peritoneal puncture (abdominal paracentesis)**

- for exploratory or therapeutic purposes
- indications:
  - ⇒ evacuation of compressing ascitic fluid
  - ⇒ severe edema of the lower limbs
  - ⇒ for introducing air or drugs
- Contraindicated in patients with fever, altered general state, recent digestive hemorrhage. Not performed in acute peritonitis, nor chronic if there is suspicion of adhesions fixing the intestinal loops, because of the risk of perforation
- **Puncture technique**
  - ⇒ long syringe needle with short oblique tip
  - ⇒ trocar
  - ⇒ patient in dorsal decubitus
  - ⇒ performed on the Monroe Richter line uniting the umbilicus with the left upper anterior iliac spine
  - ⇒ wide local disinfection with iodine and checking of dullness
  - ⇒ local anesthesia with xylocaine 1%
  - ⇒ puncture is perpendicular on the skin plane until the feeling of emptiness

### ***Accidents***

- white puncture
  - incorrect diagnosis
  - faulty needle position

- obstruction of the cannula by fibers or epiploon
- collapse when large amounts of fluid are drawn
- after repeated evacuation of protein-rich fluid (cirrhotic patients), hypoproteinemia is more marked

## Examination of the ascitic fluid

### Types:

- **serocitrine** – peritoneal transudates (cirrhosis, portal hypertension), nephritic syndromes, heart failure, one third of neoplastic ascites, connective tissue diseases
- **serofibrinous, hemorrhagic, chylous** – peritoneal tuberculosis and carcinomatosis
- **chylous ascites** – dense fluid, yellowish, cloudy – neoplasms ruptured into the thoracic canal, peritoneal tuberculosis, filariasis
- **purulent fluid** – peritonitis with pyogenic germs

**Transudate fluid** – protein content < 1.5 g/100 ml

**Exudate fluid** – proteins > 1.5 g/100 ml, rich cellular sediment

- microscopic examination
- bacteriological test

#### *Neoplastic ascites*

- exudate
- sediment with tumoral cells, erythrocytes, PMN cells
- negative bacteriological test

#### *Tuberculous ascites* (intestinal TB)

- exudate
- cellular sediment rich in lymphocytes (> 80%)
- positive Koch bacillus in cultures

#### *Bacterial ascites*

- exudate
- PMN cells sediment

- positive bacteriology

### **Radiological examination of the abdomen**

- no contrast substance (on empty stomach)
  - hydro-airy images (upside down swallow nests)
    - intestinal occlusion
  - air in the peritoneal cavity – pneumoperitoneum
    - cavitory organ perforation
  - gallstones, kidney stones, foreign bodies – opaque

### **Abdominal ultrasound**

### **Abdominal CT**

### **Laparoscopy**

## **8.3. *DYSPEPTIC SYNDROMES***

**Dyspepsia = difficult digestion = indigestion**

**Dyspeptic syndrome** = pain or abdominal discomfort located in the upper abdomen

### **Classification of dyspeptic syndromes**

1. Acute < 2-3 weeks
2. Chronic > 3-4 weeks

### **I. Organic dyspeptic syndromes**

- esophageal
- ulcerous
- biliary

### **II. Functional dyspeptic syndromes**

Defined as:

- no organic or biochemical changes are evidenced by clinical, endoscopical or lab examinations

- dyspepsia lasts for at least 12 weeks (not necessarily consecutive) in the past 12 months, persistent or intermittent
  - ⇒ Ulcer-like dyspeptic syndrome (hyperstenic)
  - ⇒ Dismotility-like syndrome (hypostenic)
  - ⇒ Unspecific dyspeptic syndrome

## **8.4. SEMIOLOGY OF THE ESOPHAGUS**

- **Patient history (anamnesis)**
  - ⇒ **Age:** children: malformations: atresia, stenosis, fistula, foreign bodies, ingestion of caustic substances; > 50 years: esophageal cancer; adults: esophagitis, primary or secondary motility disorders associated with: diabetes mellitus, scleroderma. esophageal cancer
  - ⇒ **Gender:** women: psycho-emotional instability, functional esophageal disorders
- **Family history:** esophageal cancer, polyps, diverticuli, achalasia
- **Other conditions:**
  - ⇒ hazardous or deliberate ingestion of caustic substances lead to esophageal stenosis
  - ⇒ chronic diseases affecting the esophagus: diabetes mellitus, scleroderma, iron-deficient anemia, liver cirrhosis or other causes of portal hypertension, muscle disorders, anxiety
  - ⇒ trauma
  - ⇒ repeated vomiting: Malory-Weiss syndrome
  - ⇒ strenuous vomiting: Boerhave syndrome
  - ⇒ obesity -> hiatal hernia, GE reflux

- **Living and working conditions**

- smoking (amount, type, duration), alcohol consumption (amount, type, duration)
- nutrition, environment of activity

## ***SYMPTOMS***

### **Dysphagia: difficulty in swallowing**

Causes: *functional disease*: achalasia, diffuse esophageal spasms

*organic diseases*: esophageal cancer, benign caustic stenosis

### **Esophageal pain**

**Pyrosis**: retrosternal burn

- acid reflux
- alkaline reflux
- mixed reflux

Causes:

- GE reflux disease -> reflux esophagitis -> Barrett's esophagus

Causes of reflux: hiatal hernia, cardia relaxation, gastric stasis, abdominal compressions (ascites, abdominal tumours, pregnancy, obesity)

**Odynophagia**: pain during swallowing

**Causes**: achalasia ("vigorous")

- inflammation
- foreign bodies
- tumours

Requires differential diagnosis with angina pectoris

**Regurgitation**: return of food in the mouth without vomiting

- immediate: upper stenosis
- late: lower stenosis

**Sialorrhea**: reflex, starting in the esophagus



## ***OBJECTIVE EXAMINATION***

- direct: only for the cervical esophagus
  - ⇒ deformation of the cervical region
  - ⇒ palpation: tumor. Zencker's diverticulum
- indirect: subcutaneous emphysema (perforation), lateral cervical or supraclavicular adenopathy
- Percussion, auscultation – no value

## ***EXPLORATION OF THE ESOPHAGUS***

- endoscopy
- x-ray
- echo-endoscopy
- manometry
- pH-metry
- esophageal scintigraphy
- Bernstein's test
- chest CT
- US of the abdomen and the low anterior cervical area

## ***8.5. SEMIOLOGY OF THE STOMACH AND THE DUODENUM***

### ***PATIENT HISTORY (ANAMNESIS)***

- **Age**
  - ⇒ newborn, infant -> atrophic pyloric stenosis
  - ⇒ adult, elderly:
    - duodenal ulcer (20- 45 years)
    - hiatal hernia
    - gastric ulcer
    - gastric cancer (>45 years)

- **Gender:**
  - ⇒ Men: duodenal ulcer, gastric cancer
  - ⇒ Women: gastric ulcer, chronic atrophic gastritis, gastric ptosis
- **Family history**
  - ⇒ duodenal ulcer more frequent in the OI blood group
  - ⇒ gastric cancer more frequent in the AII blood group
- **Previous diseases**
  - ⇒ gastro-duodenal diseases: Helicobacter pylori infection
  - ⇒ diseases favoring gastro-duodenal diseases
  - ⇒ acute infectious diseases: typhoid fever, food poisoning with staphylococcus aureus – acute gastritis
  - ⇒ previous gastric diseases
    - gastric cancer – malignant pyloric stenosis
    - pre-pyloric ulcer, duodenal ulcer – benign pyloric stenosis
    - atrophic gastritis, gastric polyposis – gastric cancer
    - operated stomach – risk of gastric cancer
  - ⇒ uremia – chronic uremic gastritis
  - ⇒ Biermer’s anemia – atrophic and hypochloric gastritis
  - ⇒ drug intake: NSAIDs, corticosteroids, cytostatics, digoxin, antibiotics
  - ⇒ multiple pregnancies
- **Living and working conditions**
  - ⇒ Nutritional profile: food types, time table, food cooking, amount ingested, tachyphagia
  - ⇒ Coffee in excess
  - ⇒ Alcohol in excess
  - ⇒ Smoking
  - ⇒ Stress

- ⇒ Ingestion of caustic substances
- ⇒ Working in the lead industry
- ⇒ Poor living conditions – favor *Helicobacter pylori* infection

- **Symptoms of gastric and duodenal diseases**

- ⇒ alteration of the feeling of hunger and appetite; weight loss
- ⇒ epigastric pain
- ⇒ nausea and vomiting
- ⇒ eructation
- ⇒ gastric regurgitation
- ⇒ hematemesis
- ⇒ feeling full

## **OBJECTIVE EXAMINATION**

### **General objective examination**

- anti-pain posture, crouched, with the fist pressing the epigastric area – gastro-duodenal ulcer in the painful stage, during penetration crisis
- facies
  - *zygomatic* – duodenal ulcer complicated with pyloric stenosis
  - *peritoneal (hippocratic)* – perforated gastric/duodenal ulcer with acute generalized peritonitis
- *skin palor, chalk-like* – Biermer's anemia
- *emaciation* -> cachexia: pyloric stenosis, gastric cancer
- *metastatic left supraclavicular adenopathy* – gastric cancer – Virchow Troisier sign

## **Objective examination of the stomach and duodenum**

### **Symptoms**

## **Pain**

- *Time pattern*
  - “small periodicity” – pain occurs a certain time after meals
    - a) early, 20-30 minutes after meals – ulcer of the cardia
    - b) not too late, 1-2 h – gastric ulcer of the small curvature
    - c) late, 3-4 h – antro-pyloric gastric ulcer
    - d) very late, 5-6 h – duodenal ulcer
    - e) in gastric ulcer: food – pain – calming down
    - f) in duodenal ulcer: pain – food – calming down
  - big periodicity – seasonal pattern: spring and autumn
- *Intensity and character*
  - GU – less intense than in DU
  - painful discomfort, heartburn, painful hunger
  - severe and constant during penetration crisis
  - pain at night mainly in DU
- *Location*
  - epigastrium – GU
  - right hypochondrium – DU
- *Radiation*
  - to the back – DU (sign of penetration)
  - both sides of the chest
- *Pain subsides*
  - after meals through vomiting, antacids
- **Vomiting** – postprandial, abundant, acid, semi-digested food calms the pain
- **Pyrosis** – sometimes in the absence of pain, due to GE acid reflux
- **Acid regurgitation** – accompany pain and heartburn

- **Other symptoms:** eructation, nausea, constipation (DU), low appetite, weight loss, postprandial fullness

### **Objective examination**

- asthenic body type – DU
- ulcerous facies
- examination of the abdomen: sensitivity at stomach palpation (epigastric point, solar point)

### **Causes**

- gastric ulcer
- duodenal ulcer
- gastritis
- gastric cancer
- Zollinger-Ellison syndrome
- gastric motility disorders
- irritable bowel

### ***PARACLINICAL EXAMINATIONS***

- **Endoscopy** + biopsy for Hp
  - ⇒ organic injury – sample from the lesion
  - ⇒ in the absence of an organic injury, the following tests are indicated
    - barium enema
    - manometry
    - exploration of the secretory function
- **Abdominal US, CT** (imaging diagnosis of organic lesions)
- **Laboratory tests:** pepsinogen I, gastrin, anti-Hp antibodies, anti-intrinsic factor, anti-parietal cells antibodies.

## ***SYNDROME OF GASTRIC EMPTYING INSUFFICIENCY***

**Definition:** the whole cluster of symptoms and signs associated with the difficulty or impossibility of emptying the stomach

### **Symptoms:**

- **vomiting:**
  - repeated, abundant
  - acid and food content (ingested 24-48 hours before)
  - no bile reflux
  - food stagnation => rancid unpleasant smell
- feeling of **epigastric fullness** after meals disappears after vomiting
- other symptoms:
  - fetid eructation
  - regurgitation
  - appetite loss
  - constipation
  - epigastric pain according to the causing disease

### **Objective examination:**

- weight loss – emaciation
- dehydration – dry skin, hypotension, oliguria
- distended epigastric area
- peristaltic waves visible in the epigastrium
- sometimes the distended stomach is visible
- stomach clatter in fasting conditions in the morning

### **Investigations:**

- biological: anemia, hypoproteinemia with low albumin, metabolic alkalosis, hypokaliemia, hyponatremia, nitrogen retention
- gastric probe in fasting conditions: food remnants and abundant secretion
- **endoscopy** (after stomach emptying) evidences:

- stenosis
- its degree
- its cause (macroscopic and bioptic sample for pathology)
- x-ray: on empty, with contrast (barium, gastrographin) – stopped by stenosis

## **Causes**

- organic benign pyloric stenosis
  - antropyloric GU – retractile scar
  - DU
  - muscular hypertrophy of the pylorus in the newborn or infant
- functional benign pyloric stenosis
  - muscular spasm
  - antropyloric edema in acute GU or bulbar/post-bulbar edema in acute DU
- malignant pyloric stenosis
  - antropyloric gastric cancer
  - pancreatic disease: pancreatic cancer with antropyloric invasion
- other causes: gastric TB, gastric syphilis, Crohn’s disease

## ***UPPER GASTROINTESTINAL HEMORRHAGE***

- **Definition:** blood loss at the level of the upper GI tract (esophagus, stomach, duodenum down to Treitz’s ligament)
- **Clinical manifestations**
  - **hematemesis** – elimination by vomiting through the mouth
    - red fresh blood, sometimes clots
    - ground coffee
  - **melena** – elimination of digested blood through stools
    - black, shiny, soft, like crude oil

- at least 50-60 ml blood are necessary for evidence
- loss over 1000 ml blood or very strong bowel peristalsis –fresh red blood elimination
- **occult** – iron-deficiency anemia
- **Causes of upper GI hemorrhage (UGIH)** - classification according to etiology, clinical manifestation, prognosis, therapeutic management
  - ⇒ esophageal, gastric varices (liver cirrhosis, prehepatic non-cirrhotic portal hypertension)
  - ⇒ non-variceal
    - *frequent causes*: GU, DU, Mallory Weiss syndrome, erosive gastritis, erosive esophagitis, gastric or esophageal tumours
    - *rare causes*: benign tumours (leiomyoma, adenoma, neurinoma, hemangioma), vascular abnormalities)
    - *very rare causes* < 1%: erosive duodenitis, Meckel's diverticulum, aorto-enteric fistulae, Crohn's disease, metastatic tumours

- **Clinical forms**

**Acute UGIH**

- mild < 1000 ml
- moderate 1000-2000 ml
- severe > 2000 ml

**Symptoms** (occur with > 500 ml blood)

- headache
- vertigo
- increased heart beat (moderate > 100/min; severe > 120/min)



- decreased blood pressure (moderate 100 mmHg; severe < 100 mmHg)
- signs of hemorrhagic shock (severe hypotension): cold sweat, general pallor, BP < 80 mmHg, pulse > 120/min, oligoanuria
- signs of the causing disease
- clinical: hematemesis and/or melena

## **Chronic UGIH**

### **Symptoms**

- cerebral manifestations: headache, vertigo, fainting, acuphenes, phosphenes
- pallor
- clinical manifestations of the upper GI tract
- angina pectoris, dyspnea
- clinical: occult hemorrhage more often

### **Diagnostic tests in UGIH or suspicion of UGIH**

- laboratory; Hb, hematocit, VEM, sideremia, urea
- aspiration catheter
- emergency eso-gastro-duodenal endoscopy ! for diagnosis and hemostasis
- barium enema: NOT in emergency, limited value
- arteriography

### **Diagnostic stages in UGIH**

- certainty: is it or not UGIH?
- location of the source of bleeding
- diagnosis of severity
- etiology of the UGIH

## 8.6. SEMIOLOGY OF THE INTESTINE

### Patient history

- **Age:**
  - ⇒ newborn or infant: diarrhea of various causes (wrong food, infections) -> toxicosis with dehydration and convulsions
  - ⇒ children, adolescents, young adults -> acute appendicitis
  - ⇒ adults > 50: colon cancer, mesenteric atherosclerosis, constipation
- **Family history:**
  - ⇒ hereditary transmission:
    - digestive enzymes defects (maltase, lactase)
    - celiac disease
    - intestinal polyposis – rectocolic cancer
- **Previous history of diseases:**
  - ⇒ acute infectious diseases: typhoid fever, dysentery, food poisoning lead to organic injuries of the bowel followed by functional alterations and motility disorders
  - ⇒ intestinal tuberculosis: stenosis, external / other organs fistulae
  - ⇒ digestive diseases (cholecystitis, gallstones, gastritis, pancreatitis, visceropoptosis) cause secondary intestinal distress
  - ⇒ abdominal surgery – adhesions – stenotic intestinal complications
  - ⇒ heart failure, chronic renal failure – uremia – intestinal complaints
- **Living and working conditions:**
  - ⇒ sedentary -> constipation
  - ⇒ diet: no fibers -> constipation

- ⇒ laxative abuse – functional constipation
- ⇒ occupational lead poisoning -> saturnine colic, atonic constipation

## ***SYMPTOMS IN INTESTINAL DISEASES***

### **Intestinal pain:**

Mechanisms and causes:

- visceral pain – intestinal colic
- excitation of the parietal peritoneum – inflammation
- mesenteric circulation disorders
- pain related to defecation (disease of the terminal intestine)

### **Intestinal colic**

- triggered by the spasm of smooth intestinal muscles and/or bowel distention – common features of colic
- associated with: transit disorders of gas content
- **Acute enterocolitis** (infectious diseases, parasitoses, intoxication etc.)
  - diffuse abdominal pain coming in waves
  - sudden onset – violent cramps with hydro-air noises, diarrhea, vomiting fever
- **Appendiceal colic** – acute appendicitis
  - initially (distension and appendiceal muscular spasm): located in the lower epigastric and periumbilical regions, intermittent, progressively aggravating
  - subsequently: peritoneal inflammation – pain is confined to the right iliac fossa, maximal intensity, continuous, associated with nausea, vomiting, diarrhea (children) or constipation, fever (acute localized peritonitis)

### **Mechanical ileus**

- mechanism: hyperperistalsis and distention of the bowel segment before the obstacle

- phase 1: localized pain, intense, continuous, associated with fecaloid vomiting and transit blocked for feces and gas
- phase 2 (after 24h): generalized pain, intense, continuous, associated with fecaloid vomiting and transit blocked for feces and gas

### **Intestinal subocclusion syndrome (Konig)**

- colicky pain, occurring intermittently, sometimes regularly, located in the obstruction area, aggravates progressively with the swelling of the area where peristaltic movements appear visible (dilated loop with mechanical hypercontractility – in order to overcome the obstacle), disappears suddenly and simultaneously with a strong hydro-air noise (intestinal content passes the stenosed area)
- causes: intestinal stenoses: intestinal tuberculosis, Crohn's disease (chronic intestinal inflammatory disease), benign tumours, malignant tumours of the small bowel, colon cancer (more often descending, sigmoid colon, right or left flexure);

### **Intestinal pain by perforation – irritation and inflammation of the peritoneum**

- occurs suddenly, very intense, like stabbing
- initially localized (corresponding to the perforated segment), then generalized (see acute peritoneal syndrome)
- causes: acute perforated appendicitis, perforated diverticulitis, perforated colon cancer, Crohn's disease

### **Vascular pain**

- **intestine-mesenteric infarction**
  - occurs abruptly in the epigastrium and round the umbilicus, very intense, associated with nausea, vomiting bloody stools – followed by ileus – shock
- **intestinal angina**
  - located in the center of the abdomen

- occurs early after meals
- constrictive character
- cause: chronic mesenteric insufficiency – atherosclerosis of the mesenteric arteries

### **Rectal tenesmus**

- sore burning pain with an imperious need to pass stool, reduced elimination of stool, mucus and gas, sometimes blood, followed by a feeling of incomplete defecation;
- cases: rectitis, anal fissure, ulcero-hemorrhagic rectocolitis, anorectal cancer

### **Transit disorders**

- **ileus** – suppression of intestinal transit for feces and gas
  - **functional (dynamic)** – intestinal muscles paresis (accompanies colic)
  - **mechanical** – occlusions by strangulation, volvulus, invagination
- **diarrhea**
- **constipation** (see syndromes)

### **Disturbances of the gas content**

- *Meteorism* – increased gas content in the bowels
  - feeling of distention and abdominal fullness – hydro-air noises
  - diffuse: aerophagia, food rich in cellulose, heart failure, portal hypertension
  - localized: mechanical ileus – loop before the obstacle
- *Flatulence* – repeated passing of large amount of gas through the anus
  - occurs in all cases of meteorism, except ileus

### **Intestinal hemorrhage**

Lower GI hemorrhage (LGIH) caused by an origin below Treitz's ligament

Manifested as:

- *Melena* – rarely an expression of LGIH – when bleeding is slow and sufficient to change the stool, slowed colic motility
- *Rectoragia*
  - elimination of fresh red blood through the rectum
  - origin in the small bowel, colon, rectum
  - stool color:
    1. black, shiny, soft – melena: probably UGIH, more rarely LGIH (small bowel, ascending colon)
    2. red blood in large amounts – LGIH – colon
    3. blood mixed with stool – rectal or colic lesion
    4. not mixed with blood: anus, rectum, sigmoid (hemorrhoids, anal fissure, anorectal tumours)

## ***OBJECTIVE CLINICAL EXAMINATION IN INTESTINAL DISEASES***

### **General examination**

- **Peritoneal facies** – acute generalized peritonitis
- **Attitude**
  - ⇒ passive, motionless, dorsal decubitus with thighs on the abdomen, superficial breathing – acute generalized peritonitis
  - ⇒ agitated – initial phase of intestinal occlusion
- **Skin and mucosa**
  - ⇒ general pallor: anemia secondary to colon cancer, digestive bleeding
- **Subcutaneous cellular tissue** – poorly represented – intestinal cancer, malabsorption syndrome
- **Metastatic adenopathy** – metastatic intestinal neoplasm

## Examination of the abdomen

- **Inspection:**

- ⇒ swollen abdomen

- entirely – diffuse meteorism
- by region – initial phase of mechanical ileus, intestinal stenosis determining subocclusive syndrome, large tumours

- ⇒ abdominal caving

- entirely – scaphoid abdomen – after abundant diarrhea

- ⇒ peristaltic movements – subocclusive syndrome, mechanical ileus

- **Percussion**

- ⇒ hypersonority – meteorism, pneumoperitoneum

- ⇒ dullness – ascites, large tumours

- **Superficial palpation**

- ⇒ flaccid wall, rag-like, no elasticity or muscular tone – chronic diarrhea, malabsorption

- ⇒ abdominal sensitive spots

- ⇒ defense or abdominal wall contraction – acute peritonitis, intestinal perforation

- ⇒ peritoneal irritation signs: Bloomberg's sign, bell sign, Javorski-Lapinski maneuver, Rovsing's maneuver – acute appendicitis

- **Deep palpation**

- ⇒ *dullness* – right iliac fossa –perityphlitis (inflammation round the caecum). left iliac fossa – perisigmoiditis

- ⇒ shirt front / *appendicular block* – hardened, sensitive: abscess of the appendicular area, abscessed colon neoplasm

- ⇒ palpation of the intestinal tube:

- spastic sigmoid colon, colic chord, sensitive, in the left iliac fossa (irritable bowel)
- distended caecum as a sack in the right iliac fossa- palpation causes sensitivity and hydro-air noises (caecal stasis)

⇒ large mass – fecaloma, intestinal tumours

⇒ intestinal clatter: pathological sign indicating complete (mechanical ileus) or incomplete obstruction of the bowel (intestinal stenosis)

- **Auscultation**

⇒ silence – dynamic ileus, advance stage of mechanical ileus

⇒ mid-right systolic murmur – stenosis of the mesenteric artery

- **Rectal palpation**

- evidence of diagnostic signs

- stool aspect

- rectal vegetative formations, sometimes bleeding or stenosing (rectal cancer)

- external or internal hemorrhoids

- Douglas's pouch – sensitive and swollen in acute peritonitis

- pre=sacrum adenopathy – Strauss's sign (gastric cancer)

- prostate



## **COMPLEMENTARY INVESTIGATIONS IN BOWEL DISEASES**

### **Stool examination**

#### **A. Macroscopic examination**

##### **Volume:**

- depends on:
  - quantity and quality of food ingested
  - digestion and absorption
  - speed of transit
  - intestinal diseases
- large
  - diet rich in fibers
  - digestive secretory insufficiency

##### **Color**

- influenced by certain foods (blackberries, beetroot, red sausages – may mimic melena)
- white-grey, clay-like: statorrhea, fats insufficiently digested and absorbed (exocrine pancreas insufficiency)
- diarrhea stools color:
  - dark yellow – colic fermentation
  - dark brown – colic putrefaction
  - yellow-organe – destruction of the bacterial flora after large-specter antibiotic therapy
- discolored stools (acholic) – mechanical jaundice – absence of bile pigments
- drugs (iron, bismuth: black; barium: white)

##### **Form and consistency**

- diarrhea: creamy, fluid
- constipation: formed mass: fecaloma, fecalites etc.
- rectal stenosis; pencil-shaped stools, long and thin

##### **Smell**

- depends on content and intestinal processes

- putrid: colon diseases with putrefaction
- acid: colon diseases with fermentation
- rancid: steatorrhea
- no smell: destruction of bacterial flora after antibiotics

### **General aspect**

- Homogeneous
  - Heterogeneous: false diarrhea, lientery
- Presence of pathological content
  - blood: melena (digested blood), hematokesia (fresh blood)
  - pus: ulcerous colitis, dysentery, infected neoplasms
  - mucus: irritative processes of intestinal mucosa

### **Physical and chemical examination**

- pH:
  - normal 0 alkaline or neuter
  - acid – fermentation
  - very alkaline: putrefaction
- fermentation acids level: acetic, lactic, formic, succinic
- ammonia level – putrefaction processes (vn 3 ml/g feces)
- albumins – increased in intestinal inflammatory processes
- biliary pigments – absent in mechanical jaundice (acholic stool)
- Adler's reaction, Gregersen's reaction: occult digestive hemorrhage

### **B. Microscopic examination**

- animal
  - muscular fibers
  - fats
  - connective tissue elements
- vegetal
  - starch
  - cellulose

**Copro-parasitologic examination** – evidence of intestinal parasites in larval form, cysts, or adult forms

**Bacteriological examination**

- culture from feces samples

**Endoscopy** – visualization of the large bowel for diagnostic (examination and bioptic samples) and therapeutic purposes

- recto-sigmoidoscopy
- total colonoscopy
- video probe

**Radiological examination**

- on empty – intestinal occlusion – hydro-air levels
- with contrast substance – irrigography (barium enema) – length, caliber, ptosis of the bowel, tumours, diverticuli

## **8.7. SYNDROMES IN INTESTINAL DISEASES**

### **8.7.1. THE DIARRHEIC SYNDROME**

**Definition:** frequent elimination (> 3 stool/day) of unformed stools, accompanied by *incomplete digestion*

Differentiated from:

- false diarrhea – mixed stools – solid and liquid, but with complete digestion
- fecal incontinence
- passage of frequent stools in small amounts – irritable bowel syndrome
- rectal tenesmus with frequent elimination of only blood and mucus

**Mechanisms**

- increased intestinal motility

- increased intestinal secretion
- presence of pathological products: blood, pus, mucus

## **Causes**

- *digestive diseases*
  - infectious diseases: typhoid fever, paratyphoid, dysentery
  - parasitic diseases: ascariidosis, trichinella, tape worm, lambliasis
  - gastrogenous diarrhea: achlorhydria, gastrectomy, vagotomy
  - enterogenous diarrhea: secretory enzymes insufficiency (disaccharidases)
  - biliary diarrhea: mechanical jaundice, biliary dyskinesia
  - pancreatogeneous diarrhea: exogenous pancreatic insufficiency
  - post-antibiotic therapy diarrhea: intestinal dysbiosis
  - localized pathological processes: TB, Crohn's disease, rectocolitis, polyposis, diverticulitis
  - all cases of malabsorption
- extra-digestive diseases
  - nervous, emotional disturbances
  - endocrine: hyperthyroidism, diabetes mellitus
  - renal: chronic renal insufficiency
  - mesenteric atherosclerosis

## **Symptoms**

- general symptoms:
  - fever
  - anorexia
  - weight loss
  - dehydration
- functional symptoms
  - abdominal pain

## Paraclinical investigations

- stools examination
- endoscopy
- tests of intestinal absorption and pancreatic functions

## 8.7.2. CONSTIPATION SYNDROME

**Definition:** delayed evacuation of the large bowel content (< 3 stools/week), followed by coprological syndrome characterized by reduced amount (<100 g/day) and hard consistency of feces, difficult defecation

**Dyschezia** – rectal constipation – delayed elimination of feces from the rectum, transit through the large bowel being normal

### Mechanisms

#### Constipation

- *transport constipation*
  - o by atonia of the colon: myxedema, diabetes
  - o by hypersegmentation of the colon: saturnism, vagal hypertonia
- *by obstruction:* intrinsic (colonic neoplasms), or extrinsic (adhesions)
- *by retention:* structural anomalies of the colon and rectum (dolocolon)
- *by evacuation:* disappearance of the recto-anal reflex triggered by the feces passing into the rectum

### Causes

#### Primary (habitual) constipation

- functional disturbance of the colon
- disturbances of defecation
- sedentary life style
- diet poor in fibers

## **Symptomatic constipation: functional or mechanical**

- *digestive diseases*
  - anorectal diseases: anal fistula, stenosis, prolapse, perianal abscess, neoplasms
  - colon: irritable bowel syndrome, strictures, diverticulitis, volvulus
- *extra-digestive diseases*
  - pelvic causes: pregnancy, postpartum, ovarian, uterine tumours, endometriosis
  - neuro-muscular diseases: Hirschprung's disease, multiple sclerosis, SLE, stroke, Parkinson's disease
  - mental disorders: depression anorexia nervosa
  - endocrine and metabolic diseases: DM, hypercalcemia, hypothyroidism
  - drugs: anesthetics, analgesics (opiates), antacids (Al, Ca), anticholinergic drugs
  - lead poisoning

### **8.7.3. ANO-RECTO-SIGMOID SYNDROME**

**Definition:** clinical syndrome including symptoms and signs common to the distal bowel segment: pain at defecation, rectal tenesmus, faeces with blood or pus.

#### **Causes:**

- inflammatory diseases: non-specific ano-recto-sigmoiditis, ulcero-hemorrhagic rectocolitis
- parasites: pinworm
- neoplasm
- vascular diseases: internal or external hemorrhoids

#### **Symptoms**

- rectal tenesmus
- pain at defecation

## **Objective examination**

- inspection: hemorrhoids, fissures, fistula, abscesses
- endorectal palpation: tumours, hemorrhoids, peri-rectal abscesses

## **Investigations – ex. of the feces, endoscopy, recto-sigmoidoscopy**

### **8.7.4. ACUTE PERITONEAL SYNDROME**

Includes the cluster of symptoms and signs produced by the inflammation of the visceral and parietal peritoneum, following chemical irritation and/or bacterial infestation

#### **Causes:**

- perforation of abdominal cavitory organ (stomach, duodenum, gastric or duodenal ulcer, appendicitis, gallbladder, bowel)
- intraperitoneal rupture of abscesses – hepatic, splenic, pancreatic, renal, duodenal
- abdominal surgery or obstetrical manoeuvres
- penetration wounds
- primary bacterial peritonitis

#### **Symptoms**

##### **Pain:**

- major symptom, sudden onset, initially located in the region corresponding to the perforated organ, then generalized
- radiates differently: shoulder, shoulder blade
- high intensity: perforated ulcer, stabbing pain
- improves a few hours from onset – false calming

##### **Accompanying signs**

- nausea
- vomiting (food, bile, fecaloid)
- hiccup – sign of peritoneal irritation
- dynamic ileus

## General objective examination

- peritoneal facies
- position in bed: passive, motionless, on the back, superficial breathing
- cold extremities
- preserved consciousness

## Examination of the abdomen

- *inspection*: no abdominal movement, initially retracted, then swollen due to meteorism
- *palpation*: in early stages
  - o *muscular defense* – palpation causes pain to which the patient reacts by contracting the abdominal muscles, relaxes when palpation is interrupted
  - o *Bloomberg's sign* – positive – sharp pain at the sudden decompression of the abdominal wall
  - o Positive sign of the bell
  - o *Muscular contraction* – constant increase of muscular tone – early or late onset – the most important sign!
    - when generalized -> aspect of wooden abdomen
- *percussion*
  - o pneumoperitoneum with disappearance of hepatic dullness, e.g. perforated ulcer
  - o dullness – intraabdominal fluid
- *auscultation*; silence – dynamic ileus

## Paraclinical investigations

- abdominal x-ray on empty: pneumoperitoneum
- blood test: leukocytosis with neutrophils



## **8.8. SEMIOLOGY OF THE LIVER**

### **8.8.1. PATIENT HISTORY**

#### **Age**

- newborn – physiological jaundice in the first days of life, subsides after 1-2 weeks
- childhood and adolescence: jaundice by absorption disorders, bilirubin conjugation and excretion at the hepatocyte level (Gilbert's disease, Crigler Najjar, Nubin Johnson, Rotor syndromes)
- acute viral hepatitis – epidemic – common in children, adolescents and young adults
- chronic hepatitis B, C and liver cirrhosis frequent in adults
- liver cancer in the elderly

#### **Gender**

- primary biliary cirrhosis – almost excluded for women
- hemochromatosis – in men (more frequent than liver cancer)
- pregnancy – cholestasis

#### **Family history**

- familial jaundice – previously described enzyme deficiencies
- acute viral hepatitis – familial contagion to several family members

#### **Personal history of pathological events**

- virus B, C, B+, D hepatitis – after many years they turn into chronic hep and liver cirrhosis
- common bile duct and intrahepatic gall ducts lithiasis – secondary biliary cirrhosis by bile stasis
- right heart insufficiency by hepatic stasis causes fibrosis (cirrhosis) of the heart
- acute infectious diseases affect the liver
- septicemia – liver abscess

- chronic suppurations (lung abscess, bronchiectasia, osteomyelitis) – amyloidosis
- chronic infections (TB, syphilis) – secondary liver disease
- DM, obesity, high hypertriglycerids – non-alcoholic fatty liver
- blood transfusions, surgical manouvres if not accurately performed may pass hepatitis viruses B, C

### **Living and working conditions**

- alcohol – acute alcoholic hepatitis, alcoholic fatty liver and cirrhosis
- poor food hygiene, unauthorized water supplies and poor personal hygiene favour transmission of hep A virus through feces
- veterinary doctors and technicians, animal breeders – hydatid cyst of the liver

### **Symptoms in liver diseases**

#### **Pain**

- mechanism: distension of Glisson's capsule or inflammation of the peritoneal serosa enveloping the liver
- location: right hypochondrium, epigastrium, base of posterior right hemithorax
- radiates to the right shoulder blade
- intensity: low (discomfort, heaviness, pressure) – acute, chronic hepatitis, liver enlargement due to stasis
- worsens
  - o with strain, after meals
  - o sharp: liver abscess, primary hepatocarcinoma

#### **Dyspeptic syndrome**

Dyspeptic phenomena associated or not with pain: chronic hepatitis, liver cirrhosis

- permanent feeling of being swollen up, accentuated after meals
- flatulence
- diarrhea or constipation

- appetite loss
- intolerance to fats, bitter taste

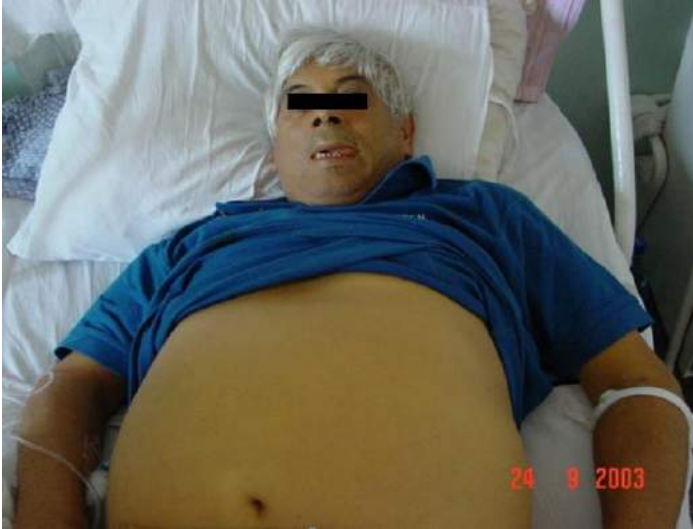### **Symptoms from other organs in liver diseases**

- asthenia, tiredness
- decreased concentration or work capacity
- sleepiness during the day
- pruritus – due to cholestasis
- joint pain – acute viral hepatitis
- amenorrhea, sexual dynamic disorders

## **8.8.2. OBJECTIVE EXAMINATION**

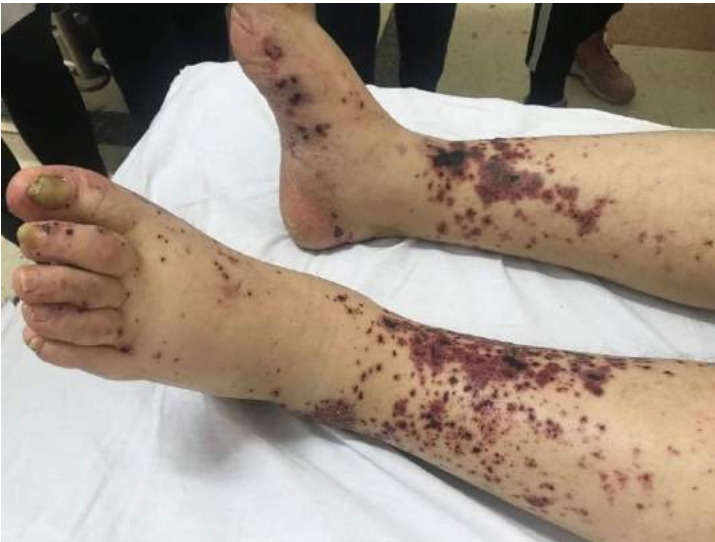### **General objective examination**

- face: vascular stars, telangiectasia on the cheeks, red lips – chronic hepatitis, liver cirrhosis
- attitude: passive, neuro-psychiatric sign (agitation, confusion, sleepiness to the level of coma) in liver failure associated with fulminant acute hepatitis, liver cirrhosis complicated with portal encephalopathy
- skin and mucosa
  - pale – after UGIH by rupture of esophageal varices in cirrhotic patients
  - sub-jaundice or jaundice
    - reddish – acute viral hepatitis
    - greenish – mechanical jaundice (common bile duct lithiasis)
    - grayish – liver cirrhosis, neoplasm, hemochromatosis
  - vascular stars
  - palmar and plantar erythema
  - gynecomastia, minimized axillary and pubic hair, testicular atrophy – in men with liver cirrhosis
  -



**Figure 113. Typical cirrhotic patient with jaundice and ascites**

- hemorrhagic purpura – chronic hepatitis and liver cirrhosis
- portocaval collateral circulation – portal hypertension



**Figure 114. Purpura in a cirrhotic patient (C virus + cryoglobulinemia)**

- Hippocratic fingers (clubbing)
- liver oedema – white, soft, located while lying on the back -> advanced stages: anasarca (dropsy)
- nutritional state:
  - o emaciation, cachexia – l. cirrhosis, neoplasm
  - o aspect of “child-drawn man”: swollen belly because of ascites, thin limbs, face with no adipose tissue

## **Objective examination of the liver**

### **Inspection**

- examination position: dorsal decubitus, legs bent -> relaxed wall
  - o ascites signs: enlarged abdomen, like a frog’s
  - o porto-caval collateral circulation (portal hypertension)
  - o swelling in the right hypochondrium, epigastrium – liver carcinoma – in conditions of emaciation; hydatid cyst; liver enlargement due to stasis

### **Palpation**

The liver is not normally palpable (perhaps a small portion of the left lobe)

Method: the patient lying on the back, legs bent, is asked to breathe deeply

- the technique with both hands is simple – palpation is performed with the fingers of both hands parallel with the median line of the abdomen, finger pointing towards the head
- with one hand:
  - o handgrip – the fingers of the right hand are shaped like a claw and inserted under the ribcage; in deep inspiration the liver descends, the inferior margin is palpated
  - o by tapping – in ascites -> the liver moves like floating ice with the movement of the palpating hand
- the following are determined
  - o size

- consistency
- lower margin
- sensitivity
- surface
- mobility
- **hepatomegaly** – increase of the liver in volume
  - *diffuse*
    - acute hepatitis
    - chronic hepatitis
    - stasis hepatomegaly
    - thesaurismosis
  - *asymmetrical*
    - increase due to one lobe
      - a) hydatid cyst
      - b) liver neoplasm
      - c) liver abscess
- **Decreased liver volume**
  - atrophic cirrhosis, acute liver dystrophy

<b>Criteria</b>	<b>Stasis hepatomegaly</b>	<b>Cholestatic liver</b>	<b>Liver cirrhosis</b>	<b>Liver neoplasm</b>	<b>Liver abscess</b>
Increase pattern	Left lobe, then overall	Overall	Overall	Overall or zonal	Overall or zonal
Consistency	Soft -> firm	Firm	Firm -> hard	Hard -> stony	Elastic or fluctuating in the affected area
Sensitivity	Initially sensitive, then insensitive	Mildly sensitive	Insensitive	Sensitive or not	Very sensitive

Anterior surface	Smooth	Smooth	Fine or large granulation	Nodular or smooth	Smooth or swollen
Lower margin	Rounded	Rounded	Sharp	Rounded	-
Other features	Hepato-jugular reflux	Pruritus	No hepato-jugular reflex	Rapid increase, murmur	Sensitivity to percussion
Associated manifestations	Cyanosis, Oedema, Jugular turgescence	Jaundice Discolored stools, Colored urine	Ascites, Splenomegaly, Collateral circulation	Emaciation	Fever

- **False hepatomegaly** – normal volume, but the liver is pushed down by the right diaphragm
  - o right pleurisy, right pneumothorax, lung emphysema
  - o palpatory – characteristics of normal organs (smooth, elastic, insensitive)

## Percussion

Percussion limits:

- upper
  - o 4<sup>th</sup> space on the right parasternal line
  - o 7<sup>th</sup> space on the right median axillary line
- lower: right ribcage margin
- vertical diameter on the right mid-clavicular line < 12 cm

## Area of liver dullness

- *increases* in hepatomegaly
- *decreases* in atrophic cirrhosis, acute dystrophy
- *disappears*, replaced by tympanism
  - o pneumoperitoneum (cavitary organ perforation)
  - o intense meteorism

## Auscultation

- systolic murmur in the hepatic dullness area

- liver carcinoma
- friction with breathing
  - peri-hepatitis in liver cirrhosis, liver cancer

### 8.8.3. *PARACLINICAL EXAMINATIONS*

#### **Functional and biochemical tests for liver diseases**

- grouped by biological syndromes related to the liver function alterations occurring in the various hepato-biliary disease

#### *Hepatocytolysis syndrome*

- results from aggression on hepatocytes, of various degrees -> necrosis with blood content release
- **transaminases:** ASTA (5-40 UI/I), ALAT (5-40 UI/I)

Serum level increase occurs in diseases evolving with hepatocytic necrosis:

- acute viral and alcoholic hepatitis > 10x normal values (nv)
- chronic active hepatitis and liver cirrhosis, steatohepatitis, drug-induced hepatitis (statins, cytostatics) – mild to moderate increase
- mechanical jaundice: moderate increase
- stasis hepatomegaly (congestive heart failure), hepatic ischemia
- same significance: increase of serum vitamin B12 and iron

*Bile excretion syndrome:* explores the biliary secreting and excreting functions and cholestasis enzymes

#### **\*in the blood**

- **bilirubinemia:** total (sum of conjugated and unconjugated BI), nv = 0.3-1 mg%, unconjugated BI < 0.7 mg%, conjugated BI < 0.3 mg%
- increased total BI:
  - excessive BI production – unconjugated component increases



- hepatocellular disease: uptake, conjugation and secretion of BI
- intra- and extra-hepatic bile ducts obstruction with bile outflow into the blood – increased BID
- hepato-cellular jaundice (acute and chronic hepatitis, liver cirrhosis)
- obstructive jaundice (liver cancer, common bile duct lithiasis, extrinsic compression of bile ducts)
  - conjugated BI is mainly increased
- hemolytic anemia – unconjugated BI increase – pallor and mild jaundice
- **serum bile salts** – cholemia -> itching – obstructive jaundice
- cholestasis enzymes: **alkaline phosphatase, gammaGT**

#### **\*in the urine**

- **BI** normally absent
  - present: hepatocellular and obstructive jaundice

#### **Urobilinogen**

- increased in hemolytic anemia, acute and chronic viral hepatitis, LC
- absent: bile ducts obstruction

#### **bile salts** (cholaluria) normally absent

- present: hepatocellular and obstructive jaundice

#### ***Hepato-deprivation syndrome***

- alteration of the synthesis of albumins, alpha and beta globulins, coagulation factors, serum pseudocholinesterase, disturbances of lipid and sugar metabolism
- serum albumins: nv 3.5 – 5.5 g/dl
  - hypoalbuminemia: acute and chronic hepatitis, LC -> liver oedema
- coagulation factors
  - deficient synthesis -> hemorrhagic syndrome

- fibrinogen: nv 200-450 mg%, low in LC
- prothrombin time (nv 12-14 s) – prolonged
- serum pseudocholinesterase – low

### ***Inflammatory syndrome***

- increased ESR and gamma-globulins – chronic hep, LC

### ***Immune syndrome***

- viral markers (VHA, VHB, VHC, VHD)
- autoantibodies -> autoimmune hepatitis

### **Morphological tests**

- abdominal US
- abdominal CT
- liver scintigraphy
- liver puncture biopsy

## ***8.9. SEMIOLOGY OF THE GALLBLADDER***

### **Patient history**

- **Age:**
  - children, adolescents
    - malformations of the GB and bile ducts (BD)
    - hereditary hemolytic anemia – pigmentary lithiasis
  - adults – more commonly in women >40 – gallstones
  - elderly: GB cancer
- **Gender**
  - in women GB disease frequency is 5 times higher than in men (due to estrogens)
- **Family history**
  - biliary lithiasis – more frequent in certain families

- **Other diseases**

- ⇒ acute digestive diseases – inflammation of the extrahepatic BD – angiocholitis
- ⇒ diseases of neighbouring organs – pancreas stomach, duodenum – secondary involvement of the BD
- ⇒ hemolytic anemia – pigmentary lithiasis
- ⇒ obesity, DM, dyslipidemia favour bile lithiasis

- **Living and working conditions**

- ⇒ mental stress – biliary dyskinesia
- ⇒ diet rich in fats – predisposes to GB disease

- **Symptoms**

- ⇒ biliary dyspepsia
- ⇒ biliary cholic

- **Biliary dyspeptic syndrome**

- ⇒ painful discomfort in the right hypochondrium,
  - continuous
  - radiation to the shoulder, shoulder blade
- ⇒ nausea, bitter taste
- ⇒ regurgitation, eructation
- ⇒ intestinal transit disturbances, flatulence
- ⇒ migraine, nervousness, asthenia
- ⇒ urticarial
- ⇒ Manifestations enhanced by food intake, mainly those triggering GB movements (fats)

### **Biliary cholic**

- onset: sudden
- precipitated by: food intake, mainly those triggering GB movements (eggs, sauces, mayonnaise)

- favored by stress, hormonal disorders
- location: right hypochondrium
- intensity: high, sometimes unbearable, paroxistic
- determines anti-pain position or psycho-motor restlessness
- radiation: to the back round the waist and ascending to the right shoulder
  - more rarely in the epigastrium or left hypochondrium
- duration: minutes, hours (max. 6 hrs)
- subsides: spontaneously or to analgesic and antispastic medication
- accompanying symptoms: nausea, vomiting (food and bile), meteorism, difficulty to breathe deeply
  - sometimes shivers and fever
- the association pain-fever-jaundice – *Charcot's triad* – significant for angiocholitis secondary to common bile duct obstruction

### **General objective examination**

- in biliary cholic
  - psycho-motor restlessness
  - superficial breathing
  - antialgic position
- jaundice – obstructive mechanism; subsequently the hepatocellular mechanism may occur, secondary to biliary stasis
- fever
  - moderate and transient – may accompany biliary cholic
  - high, persistent, preceded by shivers – acute gallstone cholecystitis and acute angiocholitis

### **Examination of the abdomen**

#### **Inspection**

- swelling in the right hypochondrium

- bladder hydropsy, enlarged GB (pancreatic head cancer)

## Palpation

- dorsal decubitus, bent legs, HCD palpation with the right hand
- difficult – besity, meteorism -> left lateral decubitus or sitting and bent forward
- normal – GB is not felt by palpation
- **superficial**
  - abdominal wall resistance – muscular defense with sensitive skin – acute cholecystitis with peritoneal reaction
  - cystic point – sensitive in acute cholecystitis, biliary cholic, GB lithiasis
  - pancreatic and common bile duct area – sensitive in the choledochus lithiasis
  - *Murphy's maounvre*: when the cystic point is pressed with the finger tips, deep inspiration causes a sharp pain and sudden arrest of breath; positive in acute and chronic cholecystitis, sometimes acute viral hepatitis
- **deep palpation**
  - GB is felt in
    - obstruction of the terminal choledochus due to pancreatic head cancer –GB is large, elastic, mobile, painless, in the right hypochondrium, associated with jaundice – *Courvoisier Terrier sign*
    - GB cancer – GB is hard, irregular shape, painless
    - *Vesicular hydropsy* – by obstruction of the cystic canal by a gallstone – GB is large, oval, piriform, sensitive, moves with breath
    - gallbladder shirt front – subhepatic area – deep thickening – in acute cholecystitis with peri-cholecystitis

## ***PARACLINICAL INVESTIGATIONS***

**Dudenal catheter** assesses:

- GB permeability
- composition and content of bile is assessed
  - macroscopically (quantity, color)
  - microscopically (crystals, parasites)
  - chemically (pigments, bile salts, cholesterol)
  - bacteriologically (bile culture)
  - cytologically (leukocytes, erythrocytes, tumoral cells)

**Abdominal ultrasound**

- GB and CBD lithiasis
- acute, chronic cholecystitis
- malformations
- GB cancer

**Abdominal CT scan**

**Abdominal x-ray on empty**

- radio-opaque gallstones
- china GB

**Intravenous cholangiography and retrograde endoscopy**

- visualizes the biliary tree

**Laparoscopy**

**GB scintigraphy**

## ***8. 10. SEMIOLOGY OF THE EXOCRINE PANCREAS***

**Patient history**

- **Age:**
  - ⇒ infant, small children: mucoviscidosis
  - ⇒ childhood: pancreas is affected in infectious diseases (mumps, measles, chicken pox)
  - ⇒ adult: acute and chronic pancreatitis

- ⇒ after 60 years: pancreatic neoplasm
- **Gender:**
    - ⇒ men: more frequently acute and chronic pancreatitis, pancreatic cancer
    - ⇒ women: more frequently acute pancreatitis due to biliary disease, lithiasis
  - **Family history**
    - ⇒ mucoviscidosis – autosomal recessive
  - **Other conditions**, favouring acute and chronic pancreatitis:
    - ⇒ chronic biliary disease (lithiasis, dyskinesia, angiocholitis) -> duodeno-choledococcus reflux
    - ⇒ gastric ulcer
    - ⇒ gastric and biliary surgery
    - ⇒ abdominal trauma
    - ⇒ infectious diseases: mumps, typhoid fever, food poisoning
    - ⇒ hyper-triglyceridemia
    - ⇒ hyperparathyroidism
    - ⇒ certain drugs: glucocorticoids, immunosuppressants, sulphasalazine
    - ⇒ acute pancreatitis -> pancreatic abscess, pancreatic pseudocyst
  - **Living and working conditions**
    - ⇒ alcoholism – favours acute and chronic pancreatitis
    - ⇒ meals rich in fats and alcohol – often precede acute pancreatitis
    - ⇒ chronic poisoning with lead, mercury -> pancreatic injury

## ***SYMPTOMS IN PANCREATIC DISEASES***

**Pain:** in acute/chronic pancreatitis, pancreatic cancer

- **Pain in acute pancreatitis:**
  - ⇒ pain mechanism: capsule distension and irritation of the solar plexus
  - ⇒ location: upper abdominal area, *banister-like*
  - ⇒ fan-like radiation – left, under the rib cage margin, on the side, lumbar region, shoulder
  - ⇒ character: often colic-like
  - ⇒ onset: sudden, progressive intensity – minutes or hours at the most – remains on a plateau for a few days, subsides slowly
  - ⇒ intensity: lying on the back and breathing – unbearable intensity
  - ⇒ subsides when sitting
  - ⇒ accompanying symptoms: nausea, vomiting, swelled tummy, paralytic ileus -> shock (by massive loss of fluids in the peripancreatic space)
  - ⇒ **Triad: pain, vomiting, shock**
- **Chronic pancreatitis**
  - ⇒ pain – persistent or intermittent
  - ⇒ location: epigastrium, umbilical area
  - ⇒ radiates to the back and whole abdomen
  - ⇒ character: pressure or distension
  - ⇒ intensity: variable
  - ⇒ onset: sometimes after meals
  - ⇒ subsides: sometimes after passing stool
- **Pancreatic neoplasm**
  - ⇒ dull pain



- ⇒ location: epigastrium, left hypochondrium (pancreatic tail neoplasm)
- ⇒ radiation: lumbar region
- ⇒ more marked at night when lying on the back
- ⇒ pancreatic head neoplasm: violent pain

### **Pancreatic dyspepsia**

- more frequent in *chronic pancreatitis*
  - appetite loss, selective anorexia to meat, bread, fats
  - morning salivation
  - nausea, eructation
  - meteorism
  - diarrhea

### **Intestinal transit disturbances**

- diarrhea: chronic pancreatitis
- paralytic ileus: acute pancreatitis
- mechanical ileus: meconium ileus (often sign of mucoviscidosis onset)

## ***OBJECTIVE EXAMINATION OF THE PANCREAS***

### **General objective examination**

- antalgic posture: in acute pancreatitis: crouched, egg-like: legs bent, head buried between the knees
- Hippocratic facies: severe forms of acute pancreatitis with shock
- weight loss: emaciation -> cachexia, muscular hypotrophy – chronic pancreatitis, pancreatic neoplasm
- pallor – absorption and digestive disorders in exocrine pancreatic failure
- mechanical jaundice – pancreatic head neoplasm
- oedema of the lower limbs – protein depletion or compression on the inferior vena cava

## Objective examination of the pancreas

### Inspection:

- swollen epigastric region – pseudocysts, hematoma, large tumours
- diffuse abdominal swelling – meteorism due to paralytic ileus or ascites (portal hypertension)
- scaphoid abdomen – advanced pancreatic neoplasm
- ecchymosis – round the belly button (*Cullen's sign*) or on the sides (*Turner's sign*) – in acute hemorrhagic pancreatitis

### Palpation

- **superficial**
  - cutaneous sensitivity half-round the waist from the anterior middle line – left hypochondrium – T10-T12 vertebrae – acute necrotico-hemorrhagic pancreatitis
  - sensitivity in the pancreatic-common bile duct region and in the pancreatic point: chronic pancreatitis
  - sensitivity in the left costa-muscular point (*Mayo Robson sign*) – acute pancreatitis
- **deep**
  - pancreatic tumours – difficult to access by palpation
    - head, corpus – in the epigastrium
    - tail: left hypochondrium
    - character
      - a)** deep set
      - b)** fix in relation to respiration, attempt to move
      - c)** consistency: hard (neoplasm), elastic (pseudocysts), fluctuating (abscesses)
  - **Courvoisier Terrier sign:** the gallbladder is palpated in pancreatic head neoplasm

**Percussion:** of little use

- dullness “suspended” above the umbilicus – pancreatic neoplasm
- abdominal hyper-sonority – acute pancreatitis
- percussion signs of ascites

**Auscultation:** murmur in the epigastric area with pancreatic neoplasm – compression of the neighboring vessels (splenic artery trunk)

### ***COMPLEMENTARY TESTS***

#### **Functional exploration**

- enzymes in the blood
  - o serum amylase (nv 50-200 UI/I) – increased in acute pancreatitis (AP)
  - o serum lipase – increased in AP
- urine tests
  - o amylase increased in AP
  - o tripsin increased in AP
- duodenal juice tests
  - o stimulation of pancreatic secretion with secretin and pancreozymin – harvesting the secretion with the duodenal catheter and assess the secretion volume, concentration of pancreatic bicarbonates and enzymes- amylase, lipase, tripsin
  - o in pancreatic cancer the secretion volume is reduced, bicarbonates are normal
  - o chronic pancreatitis – significant decrease of bicarbonates
- **stool testing**
  - o macroscopy: abundant stools, shiny, white-yellowish – statorrheic – exocrine pancreas failure associated with chronic pancreatitis

- microscopy: exocrine pancreas failure with steatorrhea – incompletely digested muscular fibers appear and drops of fat
- biochemical dosage of stool fats in steatorrhea indicates excretion of  $> 6\text{g fats}/24\text{h}$  = chronic pancreatitis

### **Morphologic explorations**

- **X-ray on empty**
  - pancreatic calculi, pancreatic calcification – chronic pancreatitis
  - paralytic ileus in AP – jejunal hydro-air levels
- **barium enema**
  - enlargement of the duodenal loop and irregular contour of the internal margin in pancreatic tumours or inflammatory processes
- **ultrasound**
  - pancreatic pseudocysts, tumours, abscess
  - dilation of the bile ducts – in obstructive jaundice secondary to pancreatic head cancer
- **endoscopic pancreatography**
  - visualization of the pancreatic duct
- **CT scan**
  - AP, CP, pancreatic neoplasm
- **US- or CT-guided puncture biopsy**

# CHAPTER 9. THE BLOOD FORMING SYSTEM

## 9.1. PATIENT HISTORY

### Age.

- Hematological diseases more frequently encountered in:
  - ⇒ **children:** hereditary spherocytosis, acute leukoses, hemophilia, Henoch-Schonlein purpura
  - ⇒ **adults:** polyglobulia, infectious mononucleosis, liver diseases, chronic renal failure
  - ⇒ **elderly:** Biermer's anemia, lymphoma, senile purpura
- **Gender.** Iron deficiency anemia, Biermer's anemia, Werlhof's disease, disseminated intravascular coagulation are more frequent in women. Lymph proliferation diseases (e.g. acute T lymphoblastic leukemia, A and B hemophilia) are predominant in men
- **Personal history of diseases**
  - ⇒ Anemias occur in chronic infections, infestation, poisoning, NSAIDs, hemodialysis, digestive neoplasm, liver cirrhosis, autoimmune diseases, malabsorption.
  - ⇒ Purpura is found with streptococcus infections, septicemia, viruses, drug-induced, poisoning, liver cirrhosis, dysglobulinemia, hypersplenism
  - ⇒ Splenomegaly is found in acute and chronic infections, parasitoses, portal hypertension, hemolytic anemia, lymphoproliferative syndromes, Werlhof's purpura.
- **Family history**

Inherited diseases that predispose to blood disease are hereditary spherocytosis, chronic myelomonocytosis (ph-1), A and B hemophilia

(chromosome X), Rendu-Osler teleangiectasia, thromocytic disease (Glanzman's disease).

- **Living and working conditions**

- ⇒ X-rays and toxic substances are considered leukogenic factors. Prolonged standing predisposes to orthostatic purpura.
- ⇒ Other diseases in which living and work factors are important are splenic hydatid cysts and brucellosis.

- **Symptoms**

- ⇒ in anemia
  - dizziness, asthenia, headache, scotoma, tinnitus, fainting
  - paresthesia, muscle weakening in the lower limbs (Biermer's)
  - dyspnea, palpitations, angor pectoris
  - glossodynia (Biermer's) sideropenic dysphagia (Plummer Winson), non-systematic dyspepsia
- ⇒ bone pain – multiple myeloma
- ⇒ itching: Hodgkin's disease
- ⇒ joint pain: Henoch-Schonlein purpura
- ⇒ hemarthrosis,, hematoma, hemorrhage: hemophilia
- ⇒ pain in the left hypochondrium: splenomegaly, splenic infarction, spleen rupture

## ***9.2. GENERAL OBJECTIVE EXAMINATION***

**Pallor** is present in anemia, taking several hues according to the etiology

- ⇒ straw-like - Biermer's

- ⇒ dirty, earth-like – neoplasms, suppuration, chronic poisoning
- ⇒ chalk-like – acute hemorrhage
- ⇒ lemon-like (+jaundice) – hemolysis
- ⇒ milky coffee – subacute bacterial endocarditis
- ⇒ +bright red tongue (shiny) – Hunter’s glossitis (Biermer’s)

**Redness**, when purplish and in the skin and mucosa – polyglobulia; aspect of “red man” is encountered in chronic lymphocytic leukemia

- In iron-deficiency anemia skin annexes are affected: brittle or claw-like nails, alopecia, brittle hair.
- In hereditary spherocytosis the head is shaped like a tower, with a high forehead.

**Adenopathy** may be localized in lymphomas; generalized in chronic lympholeukosis, mononucleosis (micro-polyadenopathy), or both (Hodgkin’s). Adenopathy accompanied by fever is found in Hodgkin’s disease, acute leucosis

- Purpura may be simple (affected only skin) or hemorrhagic (mucosa also)
  - petechia on the trunk, limbs, smooth, painless, oropharyngeal and connective suffusion – thrombocytopenia (Werlhof’s disease)
  - Henoch-Schonlein rheumatoid purpura: maculopapulous U+ vesicles on the lower limbs, symmetrical, painless; fever preceded by Quincke’s urticaria; accompanied by mucosal and visceral hemorrhage
  - extensive cutaneous, mucosal suffusions, hemarthrosis (knees), muscular (biceps, quadriceps) and cerebral hematoma.

### **9.3. EXAMINATION BY BODY SYSTEMS**

- tachypnea, tachycardia, arterial hypotension, accidental murmurs – in anemia
- signs of the disease causing anemia: e.g. infections, poisoning, hemodialysis, neoplasm
- splenomegaly: Biermer's anemia, hemolytic anemia, lymphoma, mononucleosis, Wrlhof's disease, hypersplenism
- mouth, pharyngeal ulceration, gum hypertrophy, acute leukemia, agaranulocytosis
- visceral hemorrhage (coagulation, trombocytic diseases): hemodialysed patients, hemoptysis, intra-articular hemorrhage, cerebral hemorrhage

### **9.4. HEMATOLOGICAL TESTS**

- *Normal values:*
  - ⇒ Erythrocyte count:
    - Women – 4500000/mm<sup>3</sup>
    - Men- 5000000/mm<sup>3</sup>
    - Hemoglobin- 14-16 g%
  - ⇒ Hematocrit:
    - Women - 40%
    - Men - 45%
  - ⇒ Reticulocytes count – 5-15 ‰
  - ⇒ Leucocytes count: 5000-7000/mm<sup>3</sup>
  - ⇒ Platelet count: 150000-350000/mm<sup>3</sup>
  - ⇒ Bleeding time: 2-5 minutes, Coagulation time: 6-12 minutes

Medullogram:

- hyperplasia/aplasia
- megaloblastosis



- *Leucocytosis* ( $>9000/\text{mm}^3$ ): bacterial infections, leukemia ( $>150000/\text{mm}^3$ )
- *Leucopenia* ( $< 5000/\text{mm}^3$ ): viral infections, typhoid fever, brucellosis, infestations, hypersplenism, Biermer's anemia, agranulocytosis
- *Neutrophils count* ( $>70\%$ ,  $>9000/\text{mm}^3$ ): bacterial infections, poisoning, necrosis (infarction), chronic myelo-leukosis
- *Neutropenia* ( $<50\%$ ,  $<3000/\text{mm}^3$ ): viral infections, typhoid fever, brucellosis, granulia, Biermer's anemia, aplastic anemia, agranulocytosis, cytostatic treatment
- *Eosinophilia* ( $>3\%$ ,  $>300/\text{mm}^3$ ): strongyloidosis, trichinelosis, echinococcosis, ascarioidosis, allergies (asthma, urticaria), colagenosis, Hodgkin's disease, acute leukemia
- *Eosinopenia* ( $<7\%$ ,  $<500/\text{mm}^3$ ): Gramm infections, shock, Cushing's disease
- *Lymphocytosis* ( $>30\%$ ,  $>3000/\text{mm}^3$ ): viral infections, brucellosis, tuberculosis, chronic lympholeukosis ( $>100000/\text{mm}^3$ )
- *Lymphopenia* ( $<1000/\text{mm}^3$ ): neutrophil disease, irradiation, pancytopenia, leucosis
- *Monocytosis* ( $>7\%$ ,  $>500/\text{mm}^3$ ): mononucleosis, Epstein-Barr virus infection, tuberculosis, syphilis, monocytic leukemia
- *Other tests:*
  - ⇒ globular resistance
  - ⇒ erythrocyte life time – low in hemolytic anemia
  - ⇒ sideremia – low in anemia by iron deficiency
  - ⇒ vitamin B12, folic acid – deficient in macrocytic anemia
  - ⇒ lymph node, medullar, splenic puncture biopsy
  - ⇒ broad bones x-ray (skull, pelvis)
  - ⇒ the garrot test



## BIBLIOGRAPHY

1. Sâmpolean D, editor. *Semiologie Clinică Medicală. "Iuliu Hațieganu"* University Publishing House, Cluj-Napoca, 2013.
2. Becker S. *Hepatology for Clinician: A Problem-Oriented Approach*. Alan R. Liss Inc. New York 1989.
3. Boloșiu HD. *Semiologie medicală*, Medex Cluj-Napoca 1994.
4. Bucur Gh. *Curs de semiologie medicală*. IMF București 1983.
5. Castaigne A, Godeau B, Lejong JL, Schaffer A, *Semiologie Medicale, Initiation a la physiopathologie*. Editions Sandoz, 1989.
6. Goldman L, Schafer AI. *Goldman's Cecil Medicine, 24th Edition*, Elsevier, 2011.
7. Dușu AI, Motocu M, Boloșiu HD. *Curs de semiologie și propedeutică, aparatul digestiv, sistemul hematoformator*. Lit. IMF 1984.
8. Dorca N. *Curs de propedeutică medicală*. Litografia IMF Cluj 1973.
9. Drossmann DA. *Chronic Functional Abdominal Pain*, Am. J. of Gastroenterol 1996, 91, 11:2270-2281.
10. Farmer RG, Achkar E, Fleshler B. *Clinical Gastroenterology*, Raven Press New York 1993.
11. Grigorescu M, Pascu O. *Tratat de gastroenterologie clinică*, vol. 1. Ed. Tehnică, București 1996.
12. Gitnick G, La Brecque DR, Moody FG. *Diseases of the Liver and Biliary Tract*, Mosby Year Book Inc. 1992.
13. Grigorescu M, Pascu O. *Tratat de gastroenterologie clinică*, vol. 1. Ed. Tehnică, București 1996.
14. Goia I. *Propedeutică medicală*. Ed. Didact. și Pedag. București 1970.
15. Longo et al. *Harrison Manual de medicină*. Editura All, 2014.

16. Haubrich WS, Shaffner F, Berk JE. Bockus Gastroenterology, WB Saunders, 1995 și 1985.
17. Hassanein T, Van Thiel DH. Biochemical Abnormalities in Liver Disease. Bailliere's Clinical Gastroenterology 1995, 9, 4:679-688.
18. Huntley CA, Cutaneous Manifestations of Diabetes Mellitus, Diabetes Metabolism Reviews, 1993, 9, 3: 161-176
19. McIntyre, Benhamou JP, Bircher J, Rizzetto M, Rodes J. Oxford Textbook of Clinical Hepatology, Oxford University Press, 1991-1992.
20. McGee SR. Percussion and Physical Diagnosis: Separating Myth from Science, Disease - a - Month 1995, oct, XLI, 10:641-692.
21. McLeod J, Munro J. Clinical Examination Seventh and Eleventh Edition, Churcill Livingstone 1986, 2007.
22. Pascu O. Curs medicină internă - gastroenterologie I și II. 1995, 1996, 1999.
23. Păunescu-Podeanu A. Bazele clinice pentru practica medicală. Ed. Medicală București, 1990
24. Renner EL. Liver Function Tests. Bailliere's Clinical Gastroenterology 1995, 9, 4:661-677.
25. Robert JJ. Methodes de Mesure de la Resistance a l insuline, Clamp Hyperinsulinemique Euglycemique. Presse Med. 1995, 24: 730-734.
26. Curs de semiologie medicală. Vol. II. IMF București, 1986.
27. Silen W. Cope's Early Diagnosis of the Acute Abdomen. Oxford University Press, 1991.
28. Sleisenger MH, Fordtran JS. Gastrointestinal Disease. Pathophysiology, Diagnosis Management. WB Saunders 1993.
29. Simpson KJ, Finlayson NDC. Clinical Evaluation of Liver Disease Bailliere's Clinical Gastroenterology 1995, 9, 4:639-659.
30. Șerban VV. Progrese în Diabetologie, Edit. de Vest, Timișoara 1991.

31. Tobkes AI, Juergen Nord H. Liver Biopsy: Review of Methodology and Complication. *Dig Dis* 1995, 13, 267, 274
32. Thompson ABR, Shaffer EA. *First Principles of Gastroenterology. The basis of disease and approach to management*, University Toronto Press Inc. 1992.
33. Tytgat GNJ, Mulder CJJ. *Procedures in Hepatogastroenterology*, AMC Amsterdam 1993.
34. Weatherall DJ, Ledingham JGG, Warrell DA. *Oxford Textbook of Medicine*. Oxford University Press 1996, 2006.
35. Longmore M, Wilkinson I, Turmezei T, Cheung CK. *Oxford Handbook of Clinical Medicine*, Oxford University Press, 2007-12-22.
36. Model D. *Making sense of clinical examination of the adult patients*, Hodder Arnold, 2006.
37. Talley NJ, Martin C. *Clinical Gastroenterology*. 2nd Edition, Churchill-Livingston, 2006.
38. Ballinger A, Patchett S. *Clinical Medicine*, 6th Edition, Saunders, 2004, 2007.

