



"Manual of Practical Parasitology"

University of Mosul

College of Veterinary Medicine

Department of Microbiology

Collected By :

Prof. Dr. Ahlam Fathi Al-Taee

Assit. Prof. Dr. Manal Himmadi Hasan

Assit. Prof. Dr. Sura Salim Aghwan

Assit. Prof. Eman Ghanim Suleiman

Assit. Prof. Dr. Nadia Sultan Al-Hyali

Dr. Lyan Yassin Khalil Lecturer

Entessar Toma Butty Lecturer

Assit. Prof. Dr Wasan Amjed Ahmed



This manual was prepared to help the student at third class in the College of Veterinary Medicine /university of Mosul in more understand the of practical parasitology. The manual includes essential diagnostic tools and laboratory methods for detection of parasites in deferent organs, tissues, fluids, secretion, excretion, and how to deal with it.

It also helps the student for studying the morphology, of the parasites, their life cycles, and their clinical sings and pathogenesis that could produce in intermediate and final hosts of farm animals.

The optical microscope, often referred to as the "light microscope", is a type of microscope which uses visible light and a system of lenses to magnify images of small samples. Optical microscopes are the oldest design of microscope and were designed around 1600. Basic optical microscopes can be very simple, although there are many complex designs which aim to improve resolution and sample contrast. Historically optical microscopes were easy to develop and are popular because they use visible light so the sample can be directly observed by eye .

Single lens (simple) microscope (Fig: 1-A)

A simple microscope is a microscope that uses only one lens for magnification, and is the original design of light microscope

Compound microscope (Fig :1-B)

A compound microscope is a microscope which uses multiple lenses to collect light from the sample and then a separate set of lenses to focus the light into the eye or camera. Compound microscopes are heavier, larger and more expensive than simple microscopes due to the increased number of lenses used in construction



Components

All modern optical microscopes designed for viewing samples by transmitted light share the same basic components of the light path, listed here in the order the light travels through them:

- Light source, a light or a mirror
- Diaphragm and condenser lens
- Objective
- Ocular lens (eyepiece)

In addition the vast majority of microscopes have the same 'structural' components:

- Objective turret (to hold multiple objective lenses)
- Stage (to hold the sample)
- Focus wheel to move the stage (- coarse adjustment, - fine adjustment)

Dissecting microscope (Fig: 2)

Fluorescence microscopy :

Modern biological microscopy depends heavily on the development of fluorescent probes for specific structures within a cell. In contrast to normal transilluminated light microscopy ,in the fluorescence microscopy the sample is illuminated through the objective lens with a narrow set of wavelengths of light. This light interacts with fluorophores in the sample which then emit light of a longer wavelength. The emitted light will makes up the image

Electron microscopy

Main article: Electron microscope



Chapter One: Introduction



Until the invention of sub-diffraction microscopy, the wavelength of the light limited the resolution of traditional microscopy to around 0.2 micrometers. In order to gain higher resolution, the use of an electron beam with a far smaller wavelength is used in electron microscopes.

- Transmission electron microscopy (TEM) is quite similar to the compound light microscope, by sending an electron beam through a very thin slice of the specimen. The resolution limit in the year 2005 was around 0.05 nanometer and has not increased appreciably since that time.
- Scanning electron microscopy (SEM) visualizes details on the surfaces of cells and particles and gives a very nice three dimension view. It gives results much like those of the stereo light microscope, and, akin to that, its most useful magnification is in the lower range than that of the transmission electron microscope.



Laboratory diagnosis of parasitism

Samples collection and examination

Diagnostic stages of most parasites can be detected in :

1. Feces : used to diagnose parasite eggs, larvae, oocysts, cysts, Trophozoites, cestode segments adults.
 2. Blood : used to diagnose blood parasites: *Babesia*, *Theileria*, *Trypanosoma*, *Dirofilaria immitis*.
 3. Sputum : used to diagnose lung parasite eggs, larvae for example *Dictyocaulus* species (eggs) in cattle and sheep.
 4. Urine : used to diagnose eggs in urinary system for example : *Dioctophyma renale* (giant kidney worm), *capillaria* species in dogs and cats.
 5. Skin : used to diagnose external parasites such as : Mange (*Sarcoptes*, *Psorptes*).
 6. Autopsy : from dead animals
 7. Biopsy from live animals.
- } used for studying the pathological changes and diagnosing some parasites such as : *Eimeria*, *Toxoplasma*, *Theileria*.

*** Collection and submission of samples**

1. Fecal Samples :

- ❖ Fecal exams should be conducted for fresh fecal material.
- ❖ In large animals : feces should be collected directly from the rectum by using disposable plastic glove.
- ❖ In small animals feces should be collected immediately after defecation.
- ❖ Feces should be placed in a sealed glass or plastic container, clearly marked (Label) with the :
 1. Time and date of collection.
 2. Species of animal, sex, age.



3. History of clinical disease.
 4. Owner's name , and any other information relevant to the case.
- ❖ If collected feces can not be examined within a few hours, the sample should be stored at 4C⁰ until examined.
 - ❖ Feces should not be frozen, because freezing can distort parasite eggs and trophozoites .
 - ❖ If feces inspected for the presence of protozoan Trophozoites (e.g. *Giardia*, *Trichomonad*) should be examined immediately after collection
 - ❖ When the material is to be sent to another laboratory it should be packaged in cold packs, helminthes eggs may also be preserved in equal volum of 10% formalin or 70% isopropyle alcohol

Examination of the fecal samples :

There are several procedures commonly used to examine feces for internal parasites :

1. Gross examination of feces :

- ❖ Consistency : The condition of the feces that is : soft, watery (diarrheic) or very hard soild , this description will vary with the animal species , for example , cattle feces are normally softer than those of horses or sheep .
- ❖ Color : Unusual fecal colors should always be reported.
- ❖ Mucous : Mucous on the surface of fresh feces may be associated with intestinal parasitism or some other metabolic diseases .
- ❖ Blood :blood may indicate severe parasitemia.
- ❖ Age of feces : If the feces appear old and dry , this should be noted in aged sample, parasite eggs have embryonated or larvated , oocyst may have sporulated or pseudo parasites may be present .



- ❖ Gross parasites : Tapeworm segments , round worms , and larval arthropods (bots) may be present .

Microscopic examination of feces :

1. Direct smear :

procedure of direct smear :

1. Small amount of feces placed directly on the microscope slide ,by a stick
2. Dilute this quantity with water or normal saline .
3. Mixed by using applicator stick.
4. A cover slip is applied and the smear is examined under the microscope.

The advantages of this method are : short of time and minimal equipment needed and coster.

Disadvantages : negative result with this method is not always reliable and the animal may be incorrectly assumed to be free of parasite. This method also leaves a lot of fecal debris on the slide.

2. Concentration methods for fecal examination :

A. Qualitative methods : these methods used for determination the types of infection

1. Fecal flotation : this procedure based on differences in specific gravity of parasite eggs and larvae and that of fecal debris.

Specific gravity refers to the weight of an object (for example : parasite eggs) compared with the weight of an equal volume of pure water. Most parasite eggs have a specific gravity between 1.1 and 1.2, whereas tap water is only slightly higher than 1, therefore, parasite eggs are too heavy to float in tap water, to make the eggs float, a liquid with a higher specific gravity than the eggs must be used, such liquid are called flotation solution



consist of concentrated sugar or salts solution added to water to increase its specific gravity.

Flotation solution usually have specific gravity between 1.2 and 1.25.

Flotation method is used to diagnose the nematode eggs, oocyst and cysts.

Procedure of flotation :

1. put about 2 gm. of the fecal sample in 100 ml glass beaker.
2. Add 15-30 ml of flotation solution
3. Mix the feces solution with solution .
4. Strain the solution through a fine sieve (tea strainer) to remove the layer objects .
5. Pour the mixture in to (10 ml) test tube and fill the tube to the top.
6. Place a glass cover slip gently on the top of the fluid and allow the cover slip to remain for 10 to 20 minutes.
7. Remove the cover slip carefully and immediately place it on the microscope slide.
8. examine the area of the slide under the cover slip with the microscope.

2. Sedimentation :

This method is suitable for trematodes eggs and some cestodes and nematodes whose eggs do not float readily in common flotation solutions .

Procedure of sedimentation :

1. Place 3-6 gm of the fecal sample in 100 ml glass beaker.
2. Add 30-40 ml of tap water or normal saline
3. Mix the water with the feces.
4. Strain the solution through a fine sieve
5. Pour the strained mixture to the centrifuge tube and centrifuged for 1-2 minutes on 1500 rpm, if a centrifuge is unavailable, allow the mixture to sit undisturbed for 20-30 minutes.



6. Pour off the liquid in the top of the tube without disturbing the sediment at the bottom.
7. Using the pastour pipette, transfer a small amount of the top layer of the sediment to a microscope slide.
8. Apply a cover slip to the drop and examine the slide microscopically.

3. Baermann method :

- ❖ This method used for detection the lung worm larvae and cultural method for specific identification of the third larval stage of the Strongyles and Trichostrongyles.
- ❖ Baermann apparatus consist of :
 - a. A funnel clamped to a metal stand
 - b. A short piece of tubing with a clamp is attached to the end of the funnel(Fig 3).



Procedure of Baermann technique :

1. Apply 5-20 gm of fresh feces or any suspected soil to a gauze and placed it in the funnel.
2. The sample is covered by the warm water.
3. Let the apparatus at room temperature for 8-24 hours.
4. Release the clip and collect the first 3-4 drops of water on a microscope slide and examine the slide, or collect 10 ml into a centrifuge tube, spin in the centrifuge for several minutes and examine the sediment.

4. Fecal culture :

is used in diagnostic parasitology to differentiate parasites whose eggs and cysts can not be distinguished by examination of fresh fecal sample. For example eggs of some nematodes like *Strongylus* species in horses. The feces allowed to incubate at room temperature for several days until the eggs hatched and the larvae developed to infective third stage (L3).

Procedures of fecal culture :

1. Place 20-30 gm of fresh feces in a jar and moisten slightly with the tap water, until it become soupy.
2. Place the jar on a shelf, away from direct sun light and for 7 days at room temperature if the culture is dried add few drops of water . .
3. After incubation, concentrate the larvae by means of the Baermann technique and examine .

Quantitative fecal examination :

Quantitative procedure indicate the number of eggs or cyst present in each gram of feces (severity of infection). Several procedures are used to estimate the numbers of parasite eggs per gram of feces, including :

1. Stoll's technique.



2. McMaster technique.

Stoll technique:

1. Place 5 gm of fresh feces sample in 100 ml graduated measuring cylinder.
2. Add 0.1 N (4%) solution of NaOH (sodium hydroxide) in water up to 75 ml .
3. Shaking the liquid with glass beads .
4. By a graduated pipette, apply 0.15 ml suspension immediately to a microscopic slide and cover the liquid with a cover slip(22x45) and examine the slide.

It is advisable to check four, preparations the average number of eggs multiplied by 100, equals the number of eggs per gram feces (EPG,).

Larvae (LPG)

$$Y \times \frac{75}{5} \times \frac{1}{0.15} = Y \times 100 \quad (y = \text{Number of eggs})$$

McMaster technique:

Used the counting slide (McMaster slide) procedure of Mc- Master method (Fig 4)

1. Two gm of fresh feces are dissolved in 60 ml saturated solution (flotation solution) such as sodium chloride.
2. Strain the mixture through a fine sieve.
3. Using a Pasteur pipette, fill one compartment of the counting cell at once
4. Repeat the same operation to fill the second counting chamber.
5. After a few minutes, the eggs float up to the surface of the concentration solution and stick to the cover glass.

2 gm 60 ml

1 gm. 60 ml/2

each champartment contains 0.15 ml liquid.



$$\frac{60}{2} \times \frac{1}{0.15} = 200$$

EPG = Y × 200 in which Y (number of eggs).

Blood sample

- Collection of blood from animal should be performed aseptically.
 1. Swabbing the skin over the vein with alcohol (Ethanol) and using a sterile needle.
 2. Blood may be drawn with a standard needle and syringe or a vacuum collected tube.
 3. If the blood is used immediately for tests direct smear is made to diagnosis microfilariae and *Trypanosoma*.
 4. But if the blood is used to obtain serum, it must be allowed to clot.
 5. If the tests cannot be performed immediately or if some of the blood must be reserved for further testing, clotting must be prevented by addition of anticoagulant (EDTA), Ethylene diamine tetra acetic acid.
 6. Blood samples should always be labeled with owner's name and the date of the collection.
- **Examination of blood**
- **Blood smear (Fig 5)**

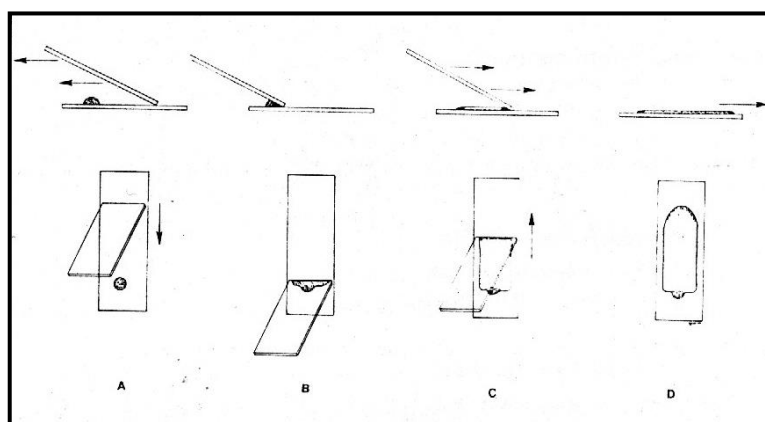
1. Thin blood smear :

This procedure is prepared for white blood cell differential count, protozoa *Babesia* sp., *Leucocytozoon* and Nematodes (larval stages of *Setaria equine* and *Dirofilaria immitis*).

- a- Place clean glass microscope slide on the bench surface and place a small drop of the blood sample near the short end of the slide.



- b- Place the short end of a second slide (the spreader slide) near the middle of the bench surface slide out the blood drop , and hold it a 35- 45 degree angle.
- c- The spreader slide is then smoothly and rapidly slide forward the length of the surface slide, producing a smear with a feathered edge or tongue shaped.
- d- Allow the surface slide to air dry and then stain with Field or Wright's or Leishman or Giemsa' s stain in the following steps.



Giemsa stain

- Fix in absolute methanol for 1-5 minutes.
- Wash in tap water.
- Air dry.
- Dilute stock Giemsa stain 1:20 with distilled water and place slide in staining jar for 30 minutes.
- Wash stain a way gently with tap water.
- Air dry. Examine the slide with the 10X objective for microfilariae or *Trypanosoma*. The 100X (oil-immersion) may be used for the intracellular parasite (*Babesia*, *Theileria*).

2. Thick blood smear



- a- Place 2-4 drops of the blood sample together on a glass slide spread them with a wooden stick to an area about 1.5-2 cm diameter.
- b- Allow the smear to air dry.
- c- Wash the smear with distilled water (hypotonic solution).
- d- Immerse it for 10 minutes in methyl alcohol. Stain with Giemsa stain for 30 minutes. Wash excess stain with tap water.

Note: this method can't be used for the blood of bird because it have a nucleus in R.B.Cs.

• **Testing of blood for detecting microfilariae**

1- Direct microscopic examination. These procedure for detecting the movement of microfilariae.

- Place a drop of fresh blood or heparinized blood on the microscopic slide, and then covered with cover slide.
- Examine at 4X, you can add one drop of 10% formalin at the side of cover slide.

2- Modified knott's test

- Mix 1ml of blood with 9ml of a 2% formalin (mixed well).
- Centrifuge the mixture at 1500 rpm for 2-5 minutes and discard the supernatant fluid.
- Add 1 drop of 0.1% methylene blue to the sediment to a microscope slide using a Pasteur pipette.
- Examine the slide for the presence of microfilariae using 10X objective lens.

3- Hematocrit method or Buffy coat method

- Fill a hematocrit tube with the whole blood sample.
- Hematocrit centrifuge tube for 5 minutes.
- Observe the location of the buffy coat layer between the red cell layer and the plasma.



- Using a glass cutter, deeply scratch the hematocrit tube at the level of the buffy coat. Immediately take the part of buffy coat add to a center of a microscope slide.
- Add a drop of normal saline and a drop of (methylene blue stain) and cover with cover slip using 10X objective lens, examine the slide for the presence of microfilariae
- **Other methods for the diagnosis of protozoan infections**
- Animal inoculation in the diagnosis of protozoa infection such as (Leishmaniasis, Toxoplasmosis).
- Serological methods for the diagnosis of protozoan infections such as (agglutination, Immunofluorescence complement fixation, gel diffusion).
- **Preparation of tissue smears(impression smear)**
- The material obtained by Biopsy (live) Autopsy or Necropsy (postmortem examination), is an important method for diagnosing parasitism of the digestive tract or brain, kidney, and muscles.
- The cut surface should be touched with filter paper to remove excess blood.
- The cut surface should be pressed gently on to a slide to leave an impression.
- Treated as a thin blood smear.
- **brain smear**
- place a small piece of brain near the one end of slide then crush by using other slide.
- Spread by slipping the slide and then treated as thin blood smear (same procedure).
- **Diagnosis of parasitism of urinary system**



Collection the urine sample for parasitological examination may be done during normal urination or catheterization:

- A waxed paper cup 3-5 ml with a lid or other clean container may be used for collection.
- Urine sample should be labeled and refrigerated.
- Methods for diagnosis .

a- Direct method.

b- Urine sedimentation.

- **Diagnosis of parasitism of the skin**

- Skin scraping for evaluating animals with dermatologic problems

Equipment required includes : an electric clipper with no 40 blade scalpel no 10 or spatula 165 mm stainless steel, mineral oil, and compound microscope.

- The average area scraped should be 6 to 8 cm square.
- The depth of the scraping varies with the typical location of the parasite in question.
- The skin should be scraped until a small amount of capillary blood oozes from the area (*Sarcoptes spp.* , *Demodex spp.*).
- All of the scraped debris on the forward surface of the blade is then spread in a drop of mineral oil on glass microscope slide.
- Cover slip is placed on the material.
- Examination using 4X objective lens.
- **Gross specimens**

Other ecto – parasites like ticks, lice, fleas, chigger mites ... are collected from the surface of the animal's skin by using a piece of cotton dipped in 70% of ethyl alcohol and kept in 10% formalin for shipment to a diagnostic laboratory.

- **preparation of the histopathological section**



- Fixation of the affected organs in 10% neutral buffered formalin for 48-72 hours.
- Dehydration in ethyl alcohol with different concentrations from 70%, 80%, 90%, 100%.
- Cleared in xylol
- Embedded in paraffin.
- Sectioned at 4 μm – 6 μm .
- Stained with Hematoxylin and Eosin stain.
- Tissue sections then examined microscopically.
- **Examination of sputum**
- The larvae and eggs of respiratory parasites have the same characteristics as those found in the feces. *Dictyocaulus* species, lungworms of cattle and sheep, which are usually seen in the sputum as eggs containing larvae rather than as free larvae in the feces.
- A drop of sputum or nasal discharge on a microscope slide is easily examined.
- Several slides should be examined

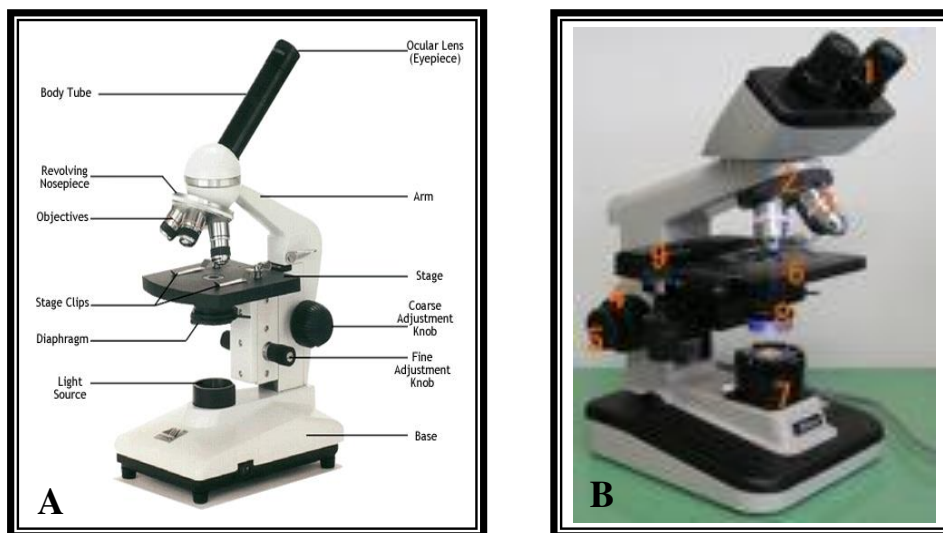
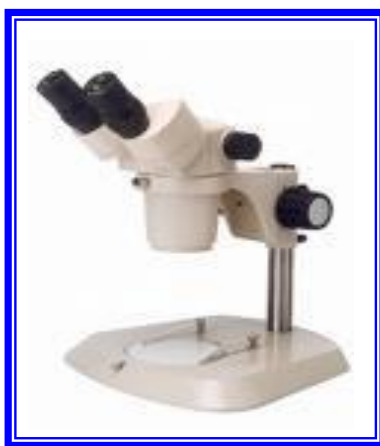

Fig (1) :
A : Single lens (simple) microscope
B: Compound microscope



Fig(2)Dissecting microscope



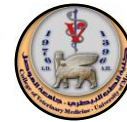

Fig (3) : Baermann Method




Fig (4) : Mc Master slide

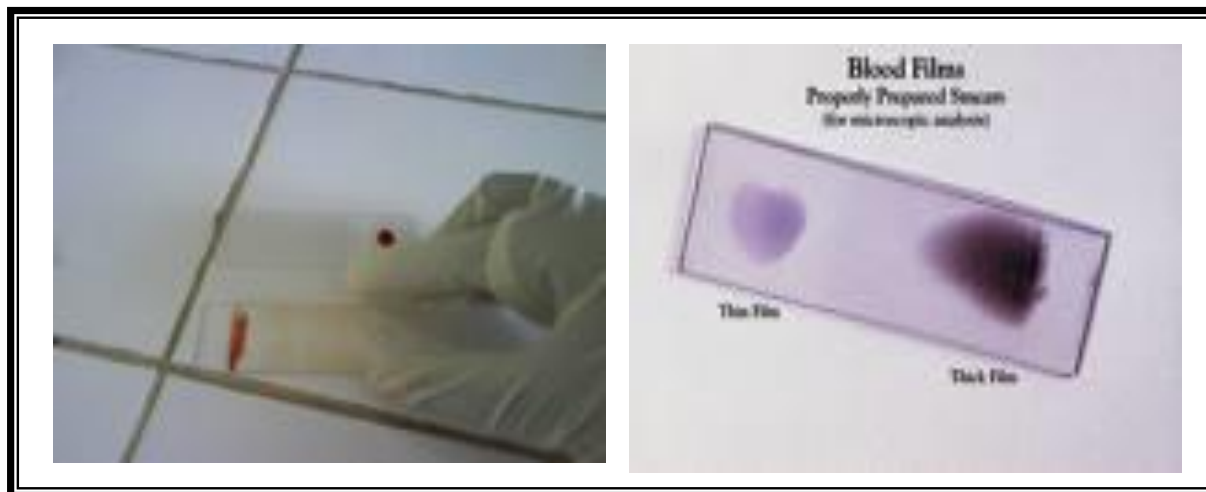


Fig (5) : Thin Blood smear



Phylum : platyhelminthes

This phylum include two classes of flat parasitic worm which called Trematoda and Cestoda .

Class : Trematoda

This class divided into two main of subclasses :

1. The monogenea which have a direct life cycle , that found in fish.
2. The digenea " Flukes " which they commonly settled in bile ducts and alimentary tract and circulation ,have adirect life cycle.

The most important families of class Trematoda :

Fasciolidae, Dicrocoeliidae, Heterophidae, Paramphistomatidae Schistosomatidae .

Family : Fasciolidae

Genus : Fasciola (liver flukes)

Fasciola hepatica :

The fluke parasitizing in bile ducts of sheep, cattle and wide range of mammals, immature stage of this parasite is found in liver parenchyma.

Shape of parasite : (Fig 6)

Gross : Adult worms leaf-shaped, grey-brown in color and is around 3.5 cm in length and 1.0 cm in width, the anterior end is conical and marked off by distinct shoulders from the body.

Microscopic : The tegument is covered with backwardly projecting spines. An oral and ventral sucker may be readily seen, ventral sucker is situated at the level of the shoulders and is about as large as the oral, alimentary tract consisting of pharynx, esophagus and two caecae which



have numerous branches and extend far back. The fluke hermaphrodite. Testes are much branched, filling the median field in about the second and third quarters of the body.

The ovary is situated to the right of the middle, anterior to the testes, and is branched. Genital opening located in front of the ventral sucker, also vitelline glands consist of fine follicles filling the lateral field. The uterus lies anterior to the testes.

Life cycle : (Fig 7)

How the infection with *Fasciola hepatica* occur ?

By eating the metacercariae with green grass or water from the final host.

Pathogenesis :

1. **Acute fascioliasis :** Occurs 2-6 weeks after ingestion of large numbers of metacercariae , usually over 2000 , and its due to the severe haemorrhage which results when the young flukes, migrate in the liver parenchyma , rupture of blood vessels .

Clinical finding :

- 1- Sudden death
- 2- Blood and other fluids coming out from the body opening.

2. **Chronic Fascioliasis :** Occurs 4-5 months after the ingestion of moderate numbers , 200-500 of metacercariae , and developing to adult flukes which settled in bile ducts , commonly its found in cattle.

Clinical findings :

1. Loss of appetite .
2. Pallor of mucous membrane .



3. Oedema is the most characteristic signs of chronic fascioliasis , its locate in submandibular region , known as bottle jaw .

Diagnosis :

a. Acute fascioliasis :

1. Clinical signs .
2. At necropsy findings which representing by enlargement of liver and haemorrhage also fibrinic exudate with young worms could be seen when we squeeze the liver tissue .

b. Chronic fascioliasis :

1. Examination of faecal samples by sedimentation test to investigate the eggs of *Fasciola hepatica* .
2. At necropsy findings, representing adult flukes in bile ducts with enlargement in the walls of these ducts . appearance of liver fibrosis . In the cattle the pathological changes characterize by that there is serial steps of calcification in bile duct wall. Finally making the liver look's like pipe-stem.
3. Serological techniques :

***Fasciola gigantica* (Fig 13).**

It called a giant liver fluke , this parasite settled in bile ducts of ruminants , most continents , does not occur in western in Europe. Intermediate host snails of genus *Lymnaea*, *Lauricularia* species , its aquatic snail and could be differ from *F. hepatica* in some points :

1. *F. gigantica* larger than *F. hepatica* and can reach 7.5 cm in length .
2. The shape is more leaf – like .
3. The conical anterior end is very short and the shoulders characteristic of *F. hepatica* are barely perceptible .
4. The eggs are larger than those of *F. hepatica* .



5. life cycle is similar to *F. hepatica* , the main differences being in the time scale of the cycle . Most parasitic phases are longer and the prepatent period is 13-16 weeks .

Family : Dicrocoeliidae

Genus : Dicrocoelium

D. dendriticum (D.lanceolatum)

Occurs in the bile ducts of the sheep goat , cattle , deer , pig, dog , donkey , hare , rabbit and rarely man .

Shape of parasite :

Grossly :The fluke is less than 1cm in long, the body is elongate , narrow anteriorly and widest behind the middle.

Microscopically: The oral sucker is smaller than the ventral .The cuticle is smooth . The intestinal caeca are simple . The testes are slightly lobed and lie almost tandem , immediately posterior to the ventral sucker , with the ovary directly behind them . The vitelline glands occupy the middle third of the lateral fields . Behind the gonads the central field is occupied by the transverse coils of the uterus (Fig . 14)

Life cycle :

In direct, two intermediate hosts : a snail and an ant are required.

eggs → have been swallowed by the snail → They hatch → miracidium → tow second generation of sporocysts Cercariae →Clump together in masses called slime- balls in the pulmonary chamber of the snail (200- 400 cercariae) →expelled from the snail→adhere to vegetation→The slime→balls are eaten by ants



→ metacercariae are produced in the abdominal cavity → The final hosts are infected by swallowing infected ants .

Diagnosis :

Examination of the fecal samples for eggs . The measure of eggs 36-45 by 20-30 μm and are operculate and embryonated when laid (Fig . 15).

Family : Heterophidae

G : Metagonimus

Metagonimus yokogawai

Occurs in the small intestine of the dog, cat, pig, man.

Morphology :

Grossly : Parasite is small size (1-2.5 by 0.4-0.7 mm) and is wider posteriorly than anteriorly.

Microscopically : The cuticle is armed with spines, a long oesophagus, the ventral sucker is situated to the right of the median line and the genital pore opens in a sinus immediately anterior to it. The tests are slightly oblique in position. The ovary is median and the vitelline glands are composed of coarse follicles lying in the posterior parts of the lateral fields (Fig . 16).

Life cycle : In direct, and the intermediate hosts are : snails and fish

The final host infects itself by eating the fish contain the metacercariae under the scales or in the tissue of the gills, fins or tail.



Family : Paramphistomatidae

1. These trematodes are usually thick and circular in transverse section.
2. The ventral sucker is situated at or close to the posterior extremity (Posterior sucker). and may be very strongly developed .
3. A pharynx is absent.
4. The intestinal caeca are simple
5. The cuticle is spineless.
6. The testes are lobed and usually anterior to the small ovary, The uterus runs for wards in the dorsal part of the body and is coiled.
7. The vitelline glands are lateral and are , as arule .
8. The intermediate hosts are water snails.

Genus : Paramphistomum

P. cervi

Occur in the rumen and reticulum of domestic and wild ruminants it is of the (Conical flukes).

The measure about 5-13 by 2-5 mm.

The eggs are clear (unlike those of *Fasciola spp*). Operculate .
(Fig. 17) .

Genus : Cotylophoron

C. cotylophorum

Occurs in the rumen and reticulum of the sheep, goat, cattle, it closely resembles *P. cervi*, but there is a genital sucker surrounding the genital pore (Fig.18).



Genus : Gigantocotyle

G. explanatum

Occurs in the bile ducts, gall bladder and duodenum of buffalo and less commonly in cattle. The posterior sucker occupies the large area of the posterior part of the body.

Life cycle :

The life cycle of the three species is generally similar and it is direct and the intermediate host is a snail . Infection of the final host is by: ingestion of the metacercariae with herbage.

Diagnosis :

1. Clinical signs .
2. History of the area .
3. Examination of the feces by sedimentation method.
4. At post mortem a marked enteritis is evident and large number of brownish pink parasites (immature forms) are found on the mucosa and in the intestinal contents.

Order: Strigeatida

Suborder: Schistosomata

Family: Schistomatidae

Genus: Schistosoma .

Final host:

All domestic mammals mainly important in sheep and cattle, usually found in mesenteric veins ,one species occurs in nasal veins.

Intermediate host :Water snails *Bulinus* and *Physopsis spp* are particularly important in the transmission of bovine and ovine schistosomiasis.



Species and distribution:

Schistosoma bovis: Ruminants in Africa ,Middle East ,Asia ,Southern Europe , occurs in the portal and mesenteric veins of cattle ,sheep, and goats.

Schistosoma japonicum: occurs in the portal and mesenteric veins of both man and animals in the Far East.

S.mansoni: occurs in the mesenteric veins of man in Africa, South America and the Middle East.

S. haematobium: occurs in the posterior mesenteric arteries and the eggs are laid in the walls of the bladder in man and animals.

Morphology :Fig(19)

- 1- These are elongate ,unisexual and dimorphic trematodes ,which inhabit the blood vessels of their host .
- 2- The female is slender and usually longer than the male.
- 3- The female of some species is usually carried ,especially during copulation by the latter in a ventral gutter –like groove ,the gynaecophoric canal ,formed by the incurved lateral edges of the body.
- 4- The suckers are weak and close together or absent.
- 5- There is no pharynx and the intestinal branches usually unite posteriorly to form a single tube which extend to the hind end .
- 6- The genital pore lies behind the ventral sucker.
- 7- The testes form four or more lobes ,situated anteriorly or posteriorly.



- 8- The ovary is an elongate ,compact organ ,lying in front of the posterior union of the intestinal branches .
- 9- The vitelline glands occupies the part of the body behind the ovary.
- 10- The eggs are thin- shelled and have no operculum ,those of some species have a lateral or terminal spine .they are laid by the females in the small blood vessels of the intestinal wall or the urinary bladder and pass through the tissues ,leaving the host with the faeces or urine.(Fig. 20,21,22,23)
- 11- The cercariae are furcocercous ,without a pharynx ,and develop from sporocysts without a redia stage.(Fig .24), They enter the host through its skin and do not encysted.

LIFE CYCLE (FIG. 25)

Diagnosis :

1. This is based mainly on the Clinical sings such as diarrhea ,wasting and anemia .
2. The demonstration of the characteristics eggs in the faces and urine (*S.haematobium*) .
3. Postmortem examination.

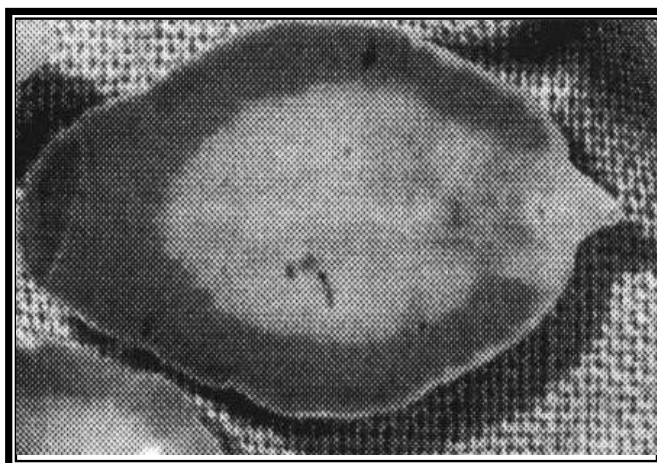


Fig (6) : *Fasciola hepatica*

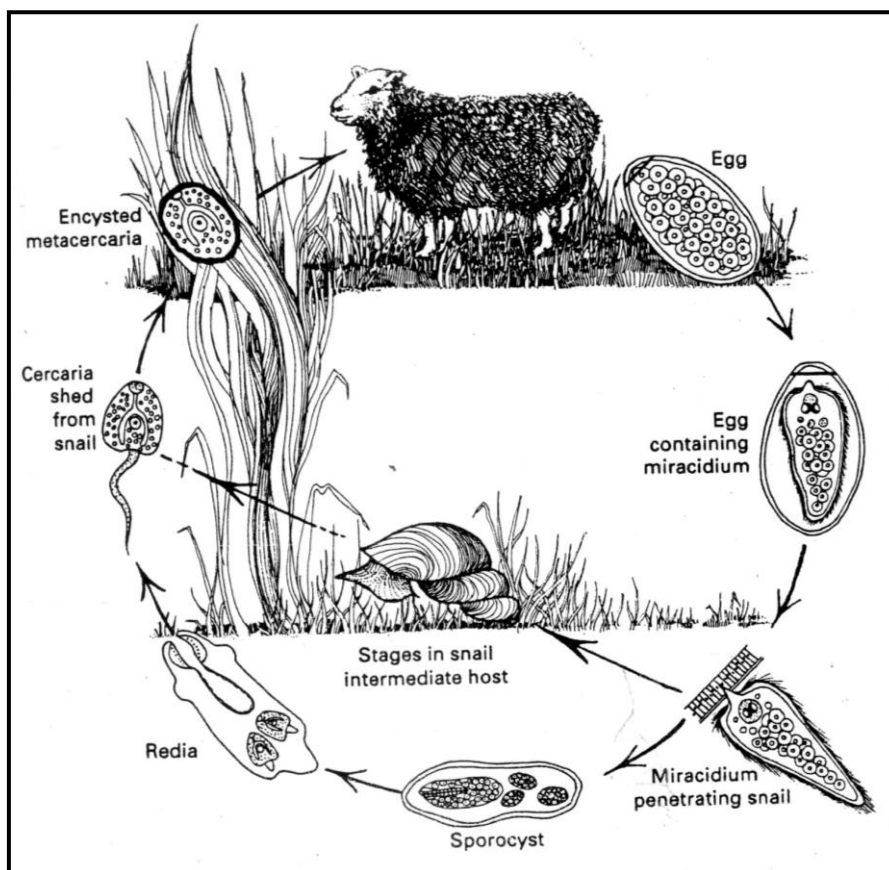


Fig (7) The life cycle of *Fasciola hepatica* .

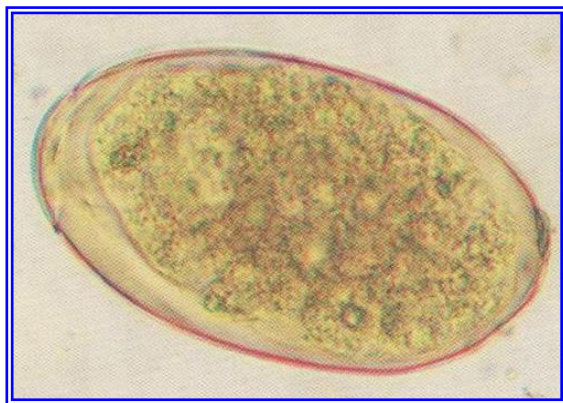


Fig (8) : eggs of *Fasciola hepatica*

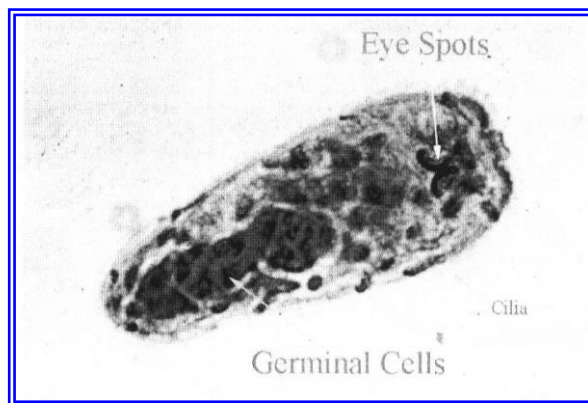


Fig (9) : Miracidium

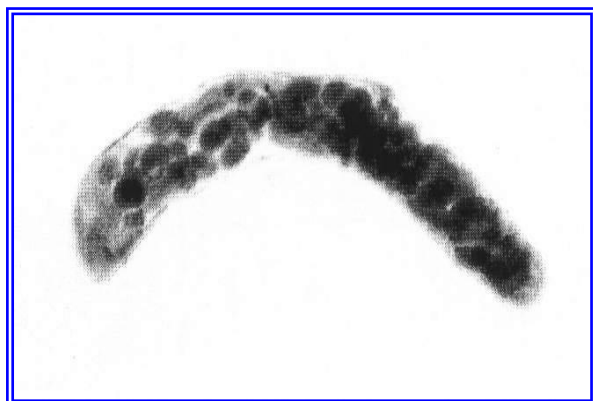


Fig (10) : Redia

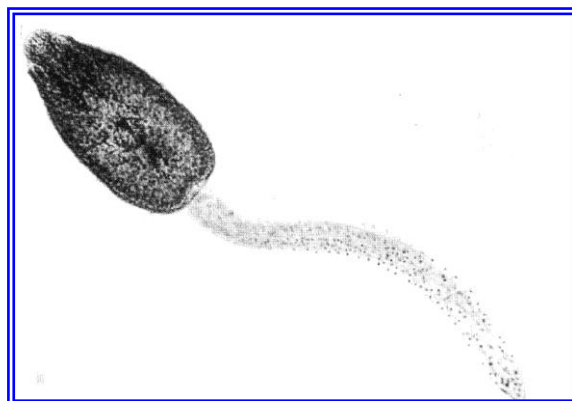


Fig (11) : Cercaria

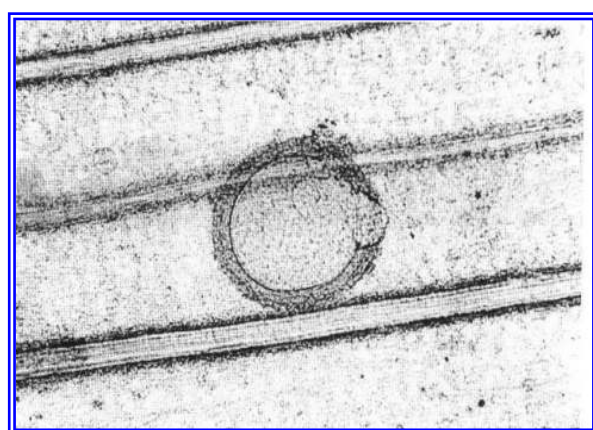


Fig (12) : Metacercaria

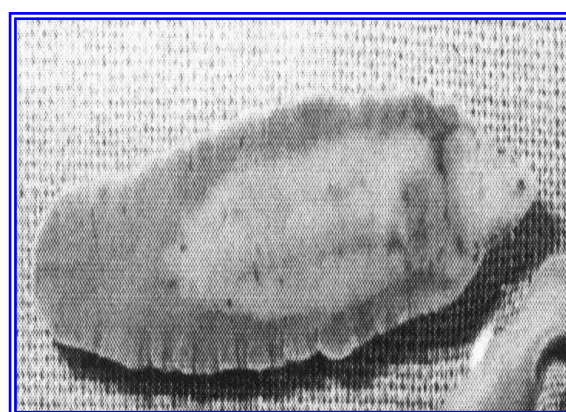
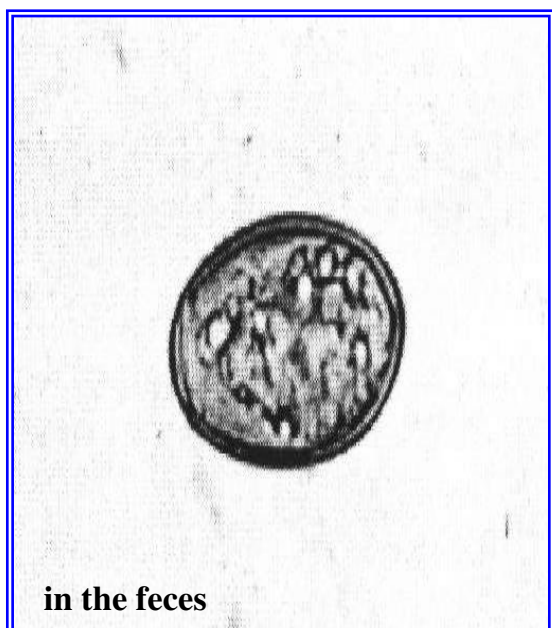
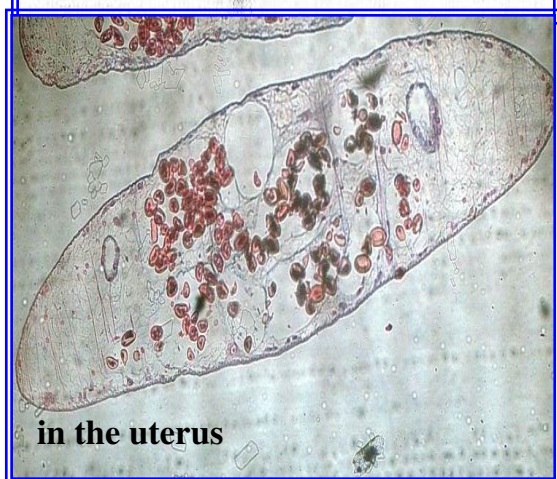


Fig (13) : *Fasciola gigantica*



in the feces



in the uterus

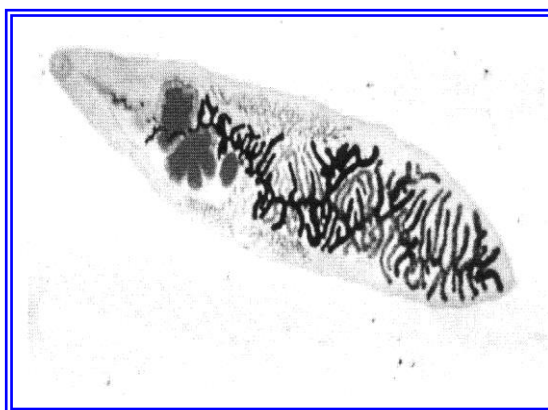


Fig : 14 *D. dendriticum*

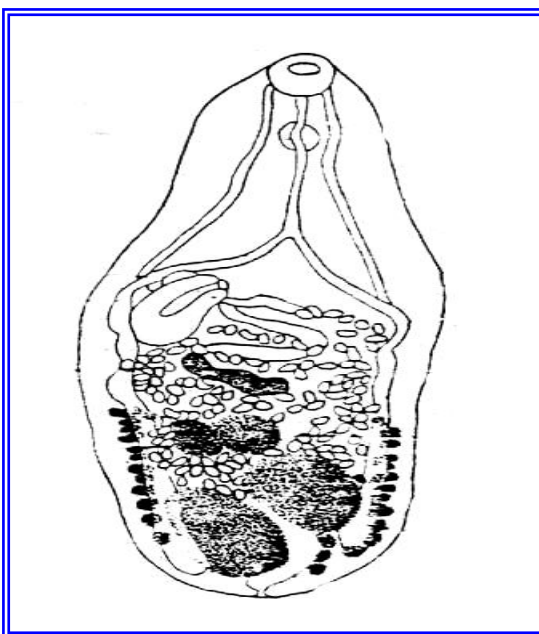


Fig (16) :*Metagonimus yokogawai*

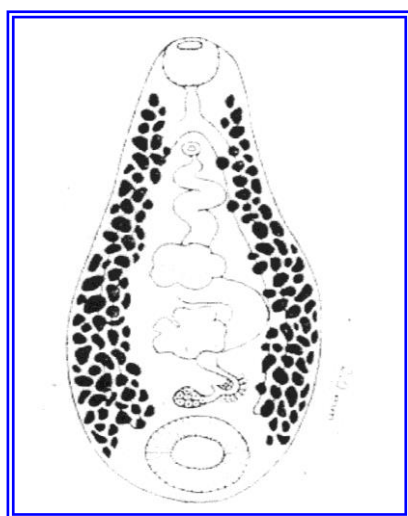


Fig (17) :*Paramphistomum cervi*

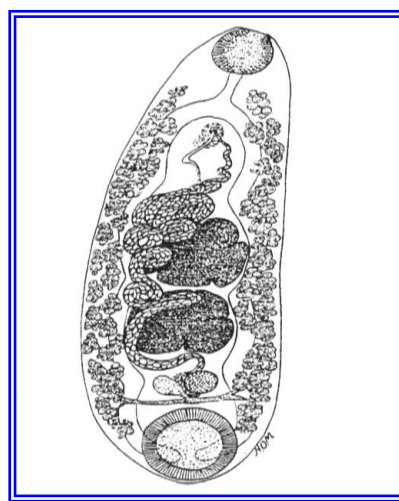
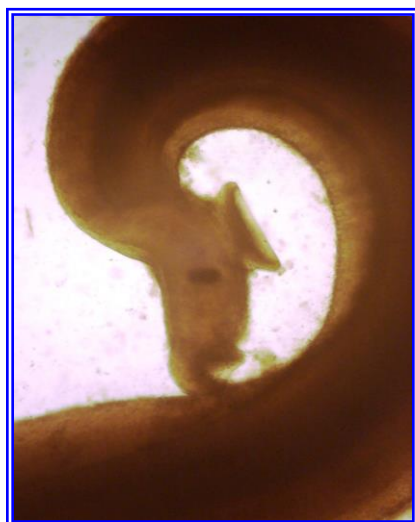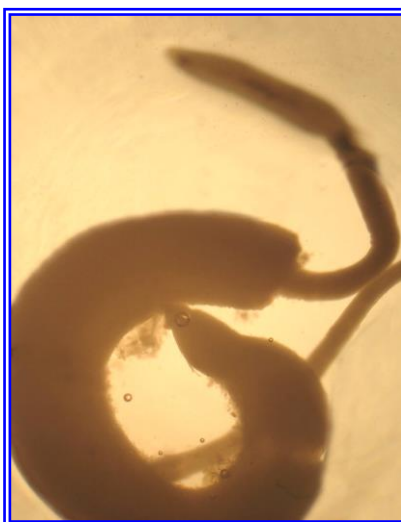


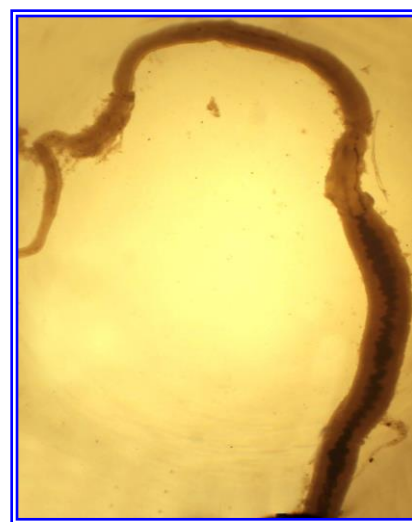
Fig (18) :*Cotylophoron cotylophorum*



Male of *Schistosoma*



Male and Female of *Schistosoma* in copulation



Female of *Schistosoma*

Fig : 19

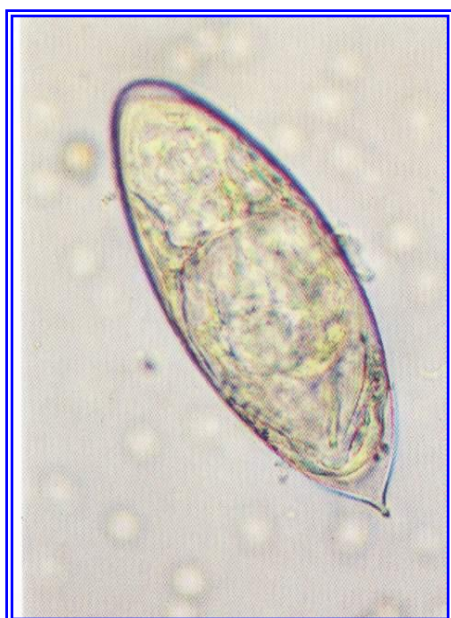


Fig (21) : eggs of *S.haematobium*

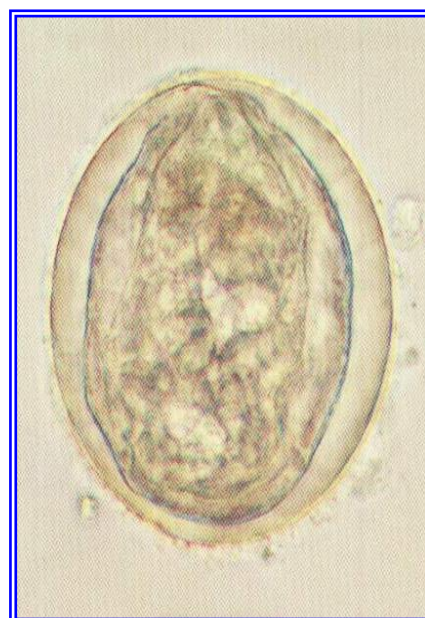

Fig (20) : eggs of *S.japonicum*

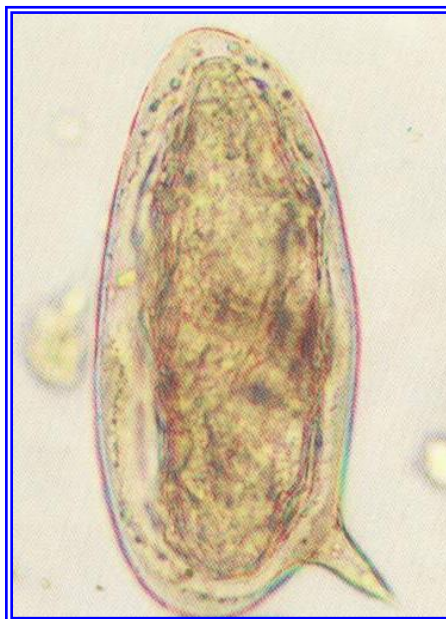

Fig (22) : eggs of *Schistosoma mansoni*

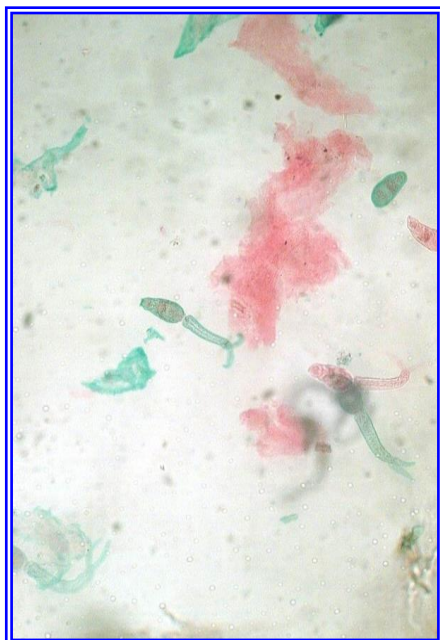

Fig (24) : Cercaria of *Schistosoma*

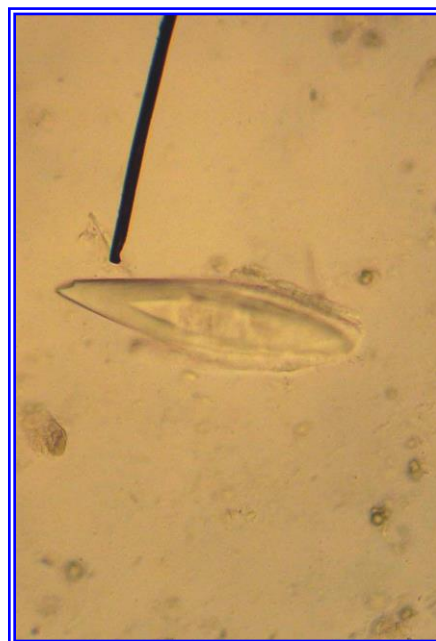

Fig (23) : eggs of *S.bovis*

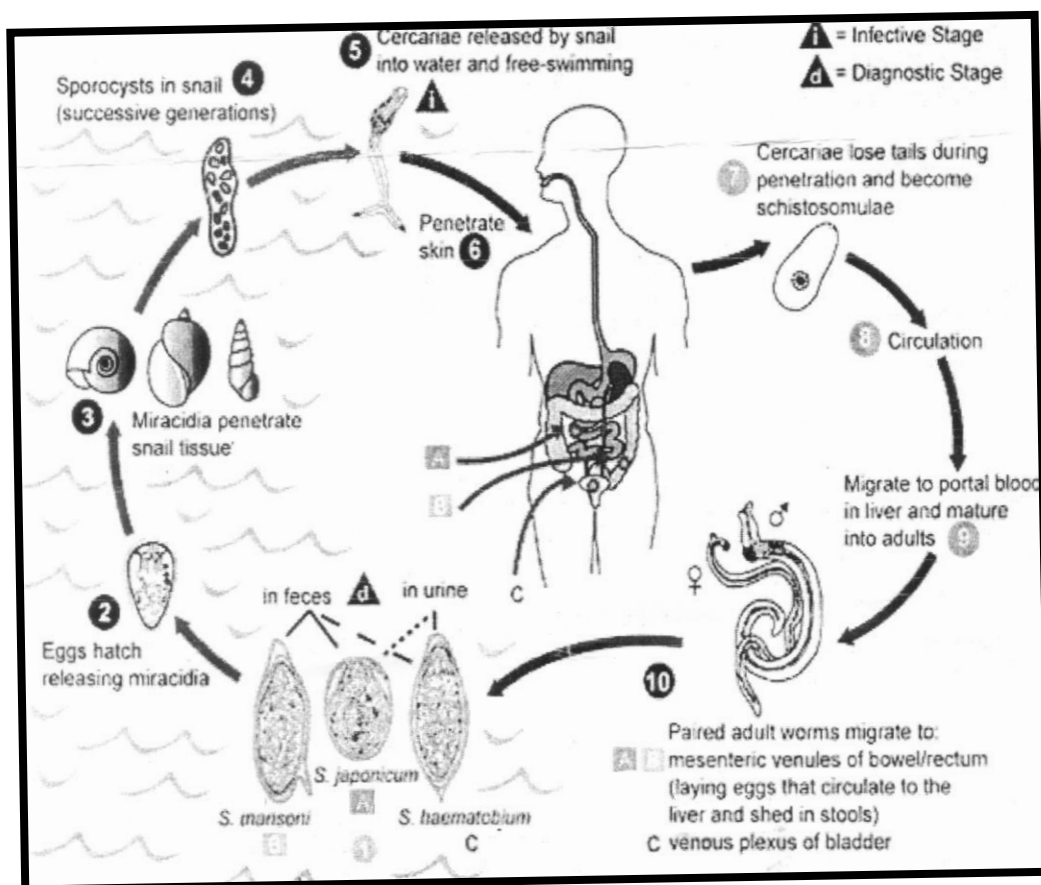


Fig (25) :Life cycle of *Schistosoma* spp



Phylum : Platyhelminthes

Class :Cestoda

Order Cyclophyllidae

This class differs from the trematoda in having a tape like body with no alimentary canal.

Adult cestode consists of a head or scolex bearing attachment organs (Suckers) and these may bear hooks and the scolex usually bears anteriorly a mobile protrusible cone or rostellum and in some species this may be also armed with one or more concentric rows of hooks which aid in attachment.

A short unsegmented neck and a chain of segments the chain is known as a strobila and each segment as a proglottid.

Each segment containing one and some times two sets of male and female reproductive organs (hermaphrodite). The genital pores usually opening on the lateral margin or margins of the segment, both self-fertilization and across-fertilization between proglottids may occur.

The body is covered by tegument and the tegument of the adult tape worm is highly absorptive.

The life cycle is indirect, one intermediate host

Egg → ingested by the intermediate host



the gastric and intestinal secretion digest the embryo → activate the oncosphere



reach blood or lymph stream





onchosphere loses its hooks → develops depending on the spp. into one of the larval stages.

(Cysticercus, Coenurus, Hydatid cyst, Cysticercoid)

Family : Anoplocephalidae

Genus : Anoplocephala

Spp. : *A. perfoliata* (Fig: 26)

Occurs in the large and small intestine of the horses and donkeys.

Adults are up to (5-8) cm in length and 1.2 cm in width

The Scolex is (2-3) mm in diameter and is provided with a (Lappet) behind each sucker.

The proglottids are wider than long and each containing a single set of reproductive organs.

Life cycle : Indirect

Mites serve as intermediate hosts.

Diagnosis :

Examination of fecal sample for eggs.

Genus : *Moniezia*

Spp. : *M. expansa* (Fig: 27)

- Occurs in the small intestine of sheep, goat, cattle and several other ruminants.
- It may reach a length of (600) cm and width 16 cm.
- Scolex is (0.36-0.8) mm with prominent suckers.



- There are neither rostellum nor hooks.
- Segments, contain two sets of genital organs with marginal genital pores.
- The ovaries and the vitelline glands forms a ring on either sides, median to the longitudinal excretory canals.
- While the testes are distributed through out the central field.
- At the posterior border of each proglottid there is a row of (rosette-like) inter proglottidal glands.
- The eggs are triangular in shape containing well-developed pyriform apparatus.

Life cycle : Indirect

Intermediate host:- mites

Diagnosis : Presence in the faeces of ripe segment which resemble cooked rice grains and from which *Moniezia* eggs.

Genus : *Moniezia*

Spp. *M. benedeni* (Fig :28)

Occurs in ruminants chiefly cattle and differs from *M. expansa* in being broader up to 2.6 cm and in having the inter proglottidal glands arranged in a short continuous row close to the mid-line of the segment.

Genus : *Avitellina*

Spp. : *A centripunctata* (Fig :29)

- Occurs in the small intestine of sheep and other ruminants.
- Adults reach 3 meter in length and are about 3 mm wide.



- Proglottides are short and not well marked.
- The genitalia are single and the pores alternate irregularly.
- The uterus lie transversely in the middle portion of the proglottid and eggs then pass into a thick-walled paruterine organ in which the eggs lie in capsules..
- The uterus and par-uterine organs show as an opaque line in the medial portion of the proglottids.
- The eggs which have no pyriform apparatus.

Life cycle : Indirect.

Book lice, dust lice may serve as intermediate hosts.

Diagnosis :

Examination of fecal sample for presence eggs, gravid segments.

Genus : *Thysaniezia*

Spp. : *T. giardi* (Fig :30)

- Occurs in the small intestine of sheep, goat and cattle.
- It grows to about 200 cm long and 12 mm wide.
- The segments are short and each contains a single set of genital organs.
- The pores alternating irregularly.
- The testes are lateral to the excretory canals.
- The side of the segment which contain the cirrus-sac bulges out, thus giving the margin of the worm an irregular appearance.



- The eggs which have no a pyriform pass from the uterus into a large number of small par-uterine organs.

Life cycle : *Indirect*.

Lice have been as intermediate hosts.

Diagnosis :

Examination of fecal sample for presence eggs.

Family : Davaineidae

- Mainly parasites of birds.
- These tape worms usually have rows of hooks (like hammer) on both rostellum and suckers.
- The mature segments have a single set of male and female reproductive organs.
- The eggs are found in eggs capsules.

Genus: Raillietina

Species: *R. tetragona* (Fig :31)

- Occurs in the posterior half of the small intestine of chickens, pigeon and other birds.
- It is world wide in distribution.
- It is one of the largest of fowl tape worms.
- Adult reach up to 25 cm in length.
- The scolex is smaller than that of *R. echinobothridia* and has a long neck.
- The rostellum is armed with one or two rows (100 hooks) and suckers are oval and armed with 8-10 rows of small hooks.
- The genital pores are usually unilateral.
- The mature segments have one set of male and female of genital organs, genital pore lie in one side. (Fig :32)



- The gravid segments have a large number of eggs capsule (eggs are found in eggs capsules) each containing 6-12 eggs. (Fig :33)
- The eggs are 25-50 μm in diameter.
- Life cycle.
- Indirect.
- The intermediate host ants and domestic fly.
- The infective stage (cysticercoids).
- The prepatent period in the chicken is 13 days-3 weeks.

Species: *Raillietina echinobothridia* (Fig :34)

- Occurs in the small intestine of chicken and turkey in most parts of the world.
- In shape and size it resembles of *R. tetragona*.
- It is distinguished by a more heavily armed rostellum (400 hooks) with two rows of hooks.
- The suckers are circular and armed with 8-10 rows of small hooks.
- Gravid proglottids frequently separate in the middle forming small "windows" in the strobila.

Life cycle:

- Indirect the intermediate host: (ants).
- Cysticercoid (infective stage) occur in ants.
- The prepatent period is 20 days.

Species: *R. cesticillus*

- It is very common through out the world in domestics, poultry (chicken, turkey).
- Occurs in small intestine.
- It has no neck.
- It is 4 cm rarely 15 cm long.



- It has a large scolex with wide rostellum armed with 400-500 small hooks.
- The suckers are in conspicuous and un armed.
- The eggs 7.5-8 μ m in diameter, occur singly in egg capsule.

Life cycle :

- In direct, the intermediate hosts are beetles and domestic fly (*Musca domestica*)
- Infective stage is cysticeroids.

Diagnosis :

- 1- Clinical signs (in appetite, anemia, reduce in egg production and weakness).
- 2- Presence the large number of a gravid proglottids or eggs are passed in faeces.
- 3- P.M.

Family: Dilepididae

- In this family the rostellum is usually armed with one, two or more crowns of rose thorn shaped hooks.
- The suckers may be armed or not.
- Genital organs are single or double.
- The uterus may be sac-like or the eggs may pass into egg capsule or a par-uterine organs.
- Adult are parasitic in birds and mammals.

Genus: *Dipylidium*

Spp: *D. caninum* (Fig :35)



- Occurs in the small intestine of dog , cat, fox and occasionally man.
- The parasite may be up to 50 cm long.
- The retractable rostellum has three or four rows of rose- thorn shaped hooks.
- Each proglottid contains two sets of genital organs.
- The ovary and vitelline gland form a mass on either side resembling a bunch of grapes.
- Eggs lie in egg capsules, each containing up to 30 eggs.
- Mature and gravid proglottids have a characteristic elongate, oval, shape, resembling cucumber seeds.

Life cycle of *D. caninum*

- In direct. The intermediate hosts are fleas (*Ctenocephalides canis* , *Ctenocephalides felis*).
- Larval fleas ingest eggs and the cysticercoids develop in the adult flea.
- The definitive hosts are infected by swallowing infected fleas.

Family : Hymenolepididae

- The worms of these family have a rostellum bearing a single circle of hooks and with Four unarmed suckers.
- There is a single set of reproductive organs per proglottid and the genital pores are unilateral .
- The intermediate hosts are arthropods in which cysticercoids develop and adult are found in birds and mammals.

Genus: Hymenolepis



- The genus contains a large number of species. Which occur chiefly in domestic animals and wild birds.
- The worms are usually narrow and thread-like in appearance.

Species: *H. nana* (Fig :36)

- The dwarf tapeworm infects rodents and man.
- Adults are slender and 25-40 mm long.
- The egg is oval the oncosphere possess three pairs of hooks.
- Mature proglottid has 3 tests, one ovary rounded in shape.
- Cirrus sac and seminale vesicles are large in size.

Life cycle In human

- Direct and cysticercoids develop in the villi of the small intestine.
- Prepatent period is 16 days.
- Autoinfection these has also been recorded .

In rodents

- the life cycle can be direct or indirect (beetles or fleas as intermediate hosts)

Diagnosis: Presence the eggs in the feces.

Family : Taeniidae

The adults of this family are large in size , the rostellum is usually present and may be absent and armed with double row of small and large hooks .

Head have four suckers (hold fast organs) and the mature segment have one group of genital organs male and female .

Ovary lie in the posterior portion of this segment and the uterus could be define as a cystic structure with many numbers of testes , while



the gravid segment consist of lateral branches of uterus , the variation in branch's determine the species of the worm .(Fig : 37, Fig: 38).

Life Cycle :

Larval stage of these worms varied according to the species it called *Cysticercus bovis* of *T. saginata* species while it called *Coenurus cerebralis* to *T. multiceps* sp., also it called hydatid cyst of *Echinocoecus granulosus*.

The eggs surrounded with two shields separated by septum , so the egg shield looking hard and have a bicycle like shape and having an onchosphere .(Fig: 39)

Genus : Taenia

Species : *T. saginata*

Shape :

The adult worm parasitizing in small intestine of human while the immature stage is found in the cattle and called *Cysticercus bovis* , this stage is rounded or oval structures (5.5 x 9-9.5) mm . Its normal sites are muscles , liver , lung , kidney , diaphragm and heart , length of adult worm 4-8mm , the head have no rostellum , no hooks 1.5-2 mm in width .

Mature segment have only one group of male and female system with many testes , gravid segment measure 16-21 mm in length and 4-7 mm in width each one contain 100,000 egg uterus also divided to 15-35 lateral branch or more .

Life cycle and how the infection Occur ?

Cattle play an important role as intermediate host due to the larval stage *Cysticercus bovis* could be found in masseter muscle , heart ,



diaphragm and tongue also it could be found in any body muscle , goat and sheep also could play an important role as intermediate host , the final host (man) infected by eating of infected meat with *cysticercus bovis*.

Diagnosis :

Slaughter the animals and searching until reach to the larval stage, also using serological techniques to diagnose infection and detection of eggs in faeces of infected man.

Species : *T. hydatigena*

It is a worm of small intestine of dog and other carnivorous adult worm measure between 75-500 cm in length, head small in size with rostellum armed with two rows of hooks between 26-44 hook, and the mature segment consist of one group of genital organs, while the gravid one measure between 10-14 cm in length and 4-7 mm in width and there is 5-10 lateral branch of uterus.

Life cycle :

The larval stage of this species usually found in peritoneal cavity of sheep goat cattle (intermediate host) and it called *Cysticercus tenuicollis*, the infection occurred by eating these immature stage by dogs (final host).

4. Diagnosis :

detection of gravid segment in faeces and flotation test to identify the eggs in the feces.



T. pisiformis

Shape :

It occurs in small intestine of dogs and foxes rarely in cats, it reach 200 cm in length, rostellum having double row of hooks range between 34-38 hook (Fig: 40) gravid segment measuring 8-10 mm in length, 4-5 mm in width also there is 8-14 lateral branches of uterus.

Life cycle :

Rodents, rabbits and wild rabbits playing as intermediate host, larval stage (*Cysticercus pisiformis*) could be find in peritoneal cavity adhering with the viscera, final host infected by eating larval stage.

Species : *Taenia multiceps*

Shape :

This worm occurs in small intestine of dogs and other carnivorous, adult worm measuring 40-100 cm in length and have a small head holding 22-32 hook, mature segment have one genital group while gravid consist of uterus which divided into 9-26 branch in each side.

Life cycle :

Coenurus cerebralis develop in brain and spinal cord of sheep and goat also cattle and another animals leading to gid disease in intermediate host (Fig: 41) while final host (dogs) having the infection by eating the larval stage .



Genus : *Echinococcus*

Spp. Echinococcus granulosus

Final hosts : dog and many wild canids

Intermediate hosts : domestic ruminants, man, pigs and wild ruminants : horses and donkeys are resistant.

Site :

Adults in the small intestine and hydatid cysts mainly in liver and lungs.

Identification

Gross :

The entire cestode is only about 2-7 mm long, and is therefore difficult to find in the freshly opened intestine. It consists of a scolex and three or four segments, the penultimate proglottids mature and the terminal proglottid is gravid and usually occupying about half the length of the complete tapeworm.

Microscopic :

The scolex has two rows of hooks. The ovary is kidney-shaped. Genital pores alternate irregularly and normally open in the posterior half of the mature gravid proglottids. The uterus of the gravid proglottids has well developed diverticula's. (Fig: 42) the embryophore is similar to that of *Taenia* spp., radially striated and containing a six-hooked onchosphere.



Life cycle:

The larval stage of *Echinococcus granulosus* is called hydatid cyst (Figs.43,44,45) which present in the intermediate host (domestic ruminants, man, pigs, wild ruminants), the hydatid cyst settled mainly in the liver and lungs and also may be occur in the other organ of the body, the final host (dogs) infected by eating the organs infected with hydatid cyst while the infection in the intermediate host occurs by eating the food or water contaminated with the eggs.

Diagnosis :

1. In the final host :

Fecal examination.

2. In the intermediate host :

a. Diagnosis of hydatidosis in domestic animals is rarely made ante-mortem.

b. Serological tests such as complement fixation or immunoelectrophoresis.



Family : *Mesocestoididae*

Genus : *Mesocestoides*

Spp. : *Mesocestoides lineatus*

The adult cestodes are found in the small intestine of dogs, cats and wild carnivores .

Identification

Gross :

They are up to 40 cm in length.

Microscopic :

The scolex is unarmed and has four elongate oval suckers and no rostellum each proglottids contains a single set of reproductive organs and the genital pore opens on the dorsal surface. (Fig: 46) In gravid proglottids the oncospheres pass from the uterus into a para uterine organs. (Fig: 47)

Life cycle :

The life cycle of the parasite requires two intermediate hosts, mites the first intermediate host contains the cysticercoid , when the infected mite is eaten by a second intermediate host (amphibian , reptiles, birds and mammals such as rodents , dogs and cats). atetrathyridium is formed, when tetrathyridia are ingested by the definitive host they become adult .



Order : *Pseudophyllidea*

Family : *Diphylobothriidae*

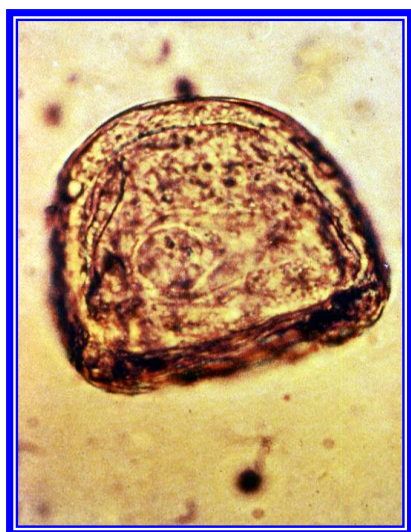Genus : *Spirometra*

Spp. : *Spirometra mansoni*

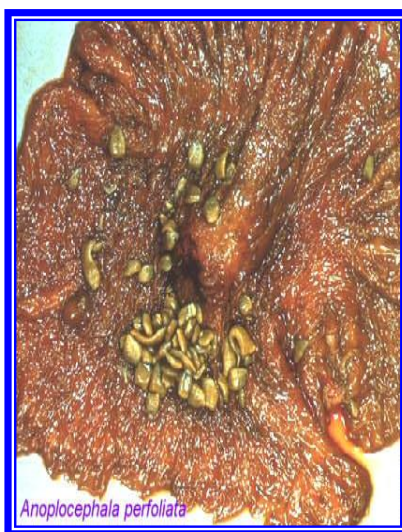
Adult *Spirometra* are found in the intestine of dogs, cats and wild carnivores . Adult are 2-12 m long, yellowish-grey in color with dark (Fig: 48), the uterus is spiraled and not rosette-form in arrangement, the uterus and vagina open separately on the ventral surface of the proglottids. (Fig: 49)

The life cycle :

Eggs are passed in the faeces and develop to produce a coracidium which, if ingested by a crustaceans, develops into the first parasitic larval stage a procercoid. The procercoids being found in crustaceans in the genus cyclop and the plerocercoids or spargana in a wide variety of hosts including amphibian, birds and mammals.



eggs



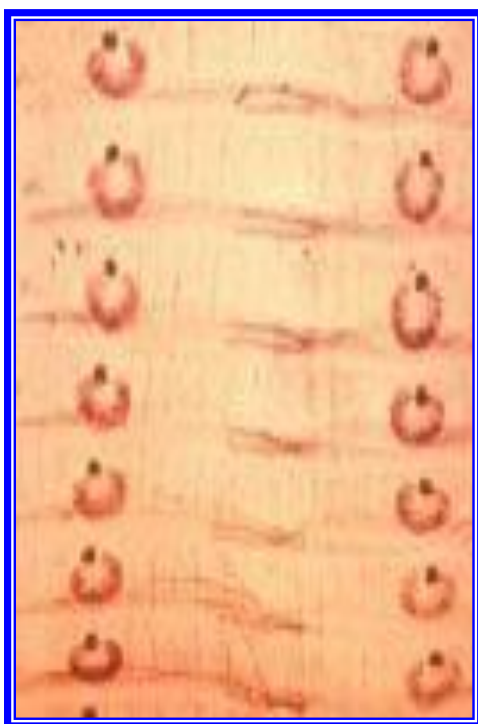Anoplocephala perfoliata

Adult tape worm

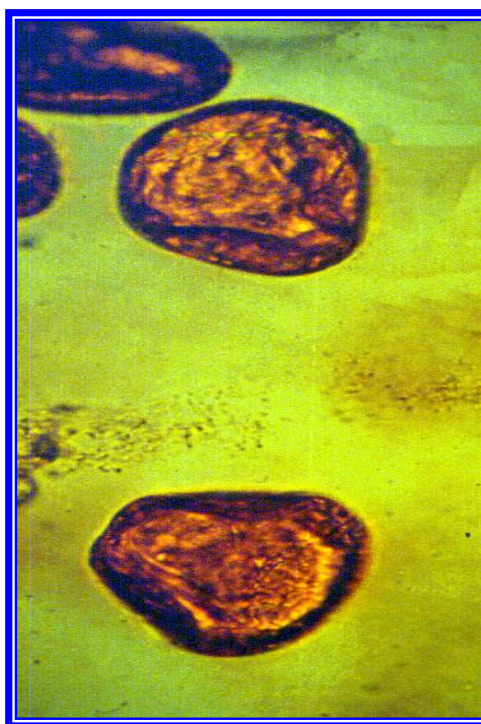


adult tapeworm

(Fig: 26) *Anoplocephala perfoliata*

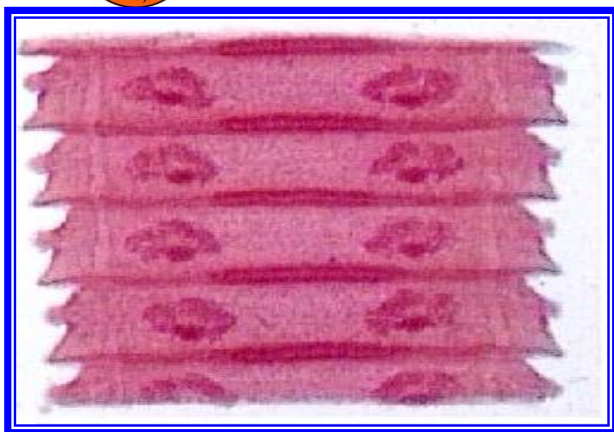

Mature segments

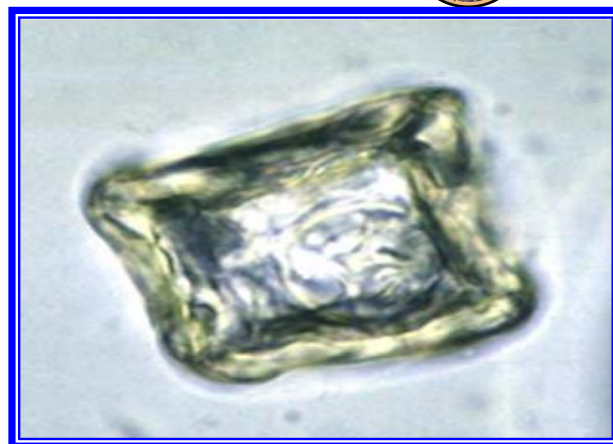

eggs

(Fig: 27) *Moniezia expansa*

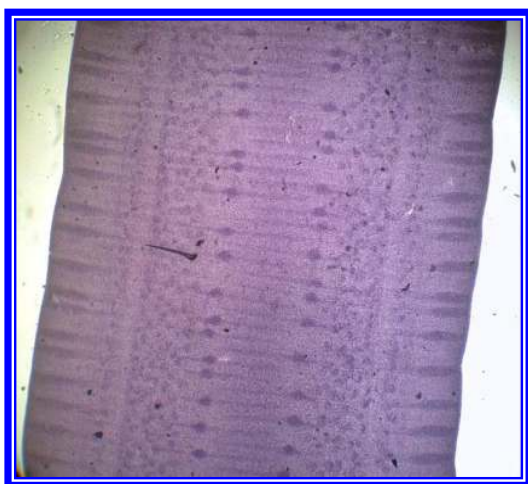


Mature segments

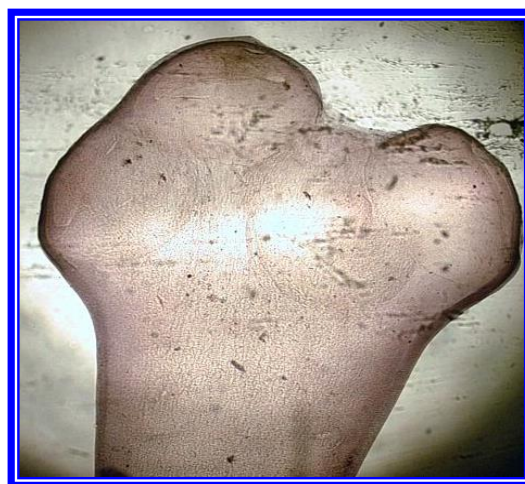

eggs

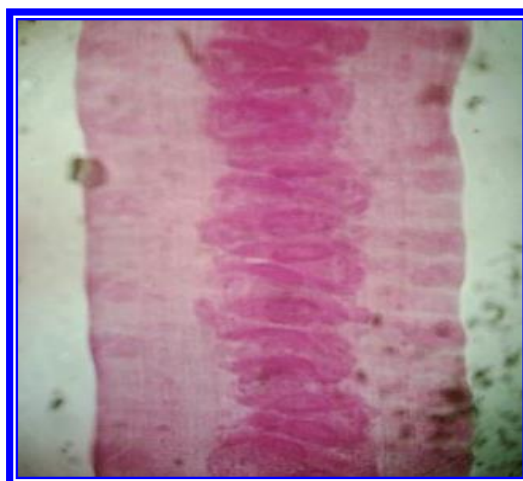
(Fig: 28) *Moniezia benedini*



Mature

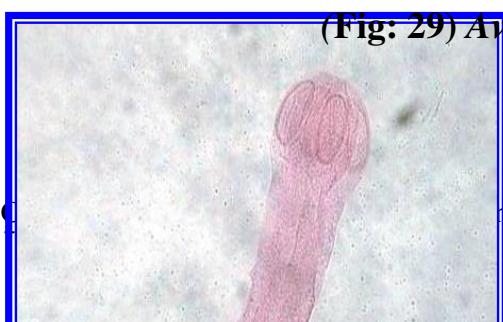

scolex

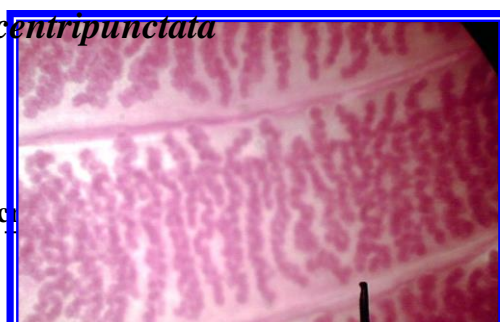


gravid segments

(Fig: 29) *Avitellina centripunctata*



02
ment of mic

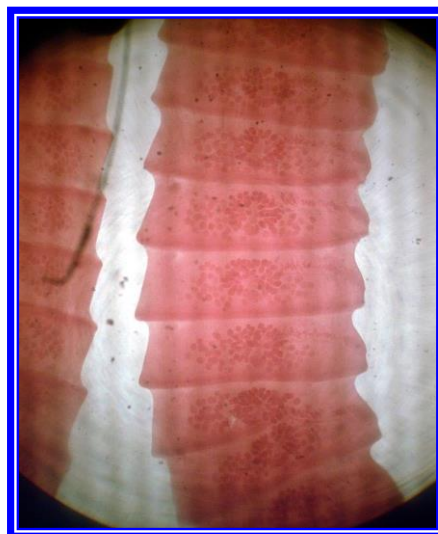



(Fig: 31) scolex of
Raillietina tetragona

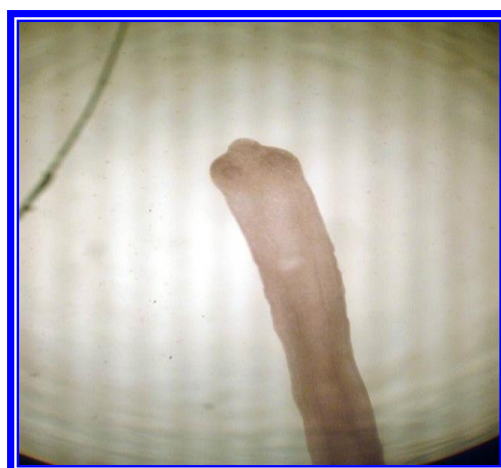

(Fig: 30) gravid segment of
Thysaniezia. giardi



(Fig: 33) gravid seg of
Raillietina spp.

(Fig: 32) mature seg of
Raillietina spp.



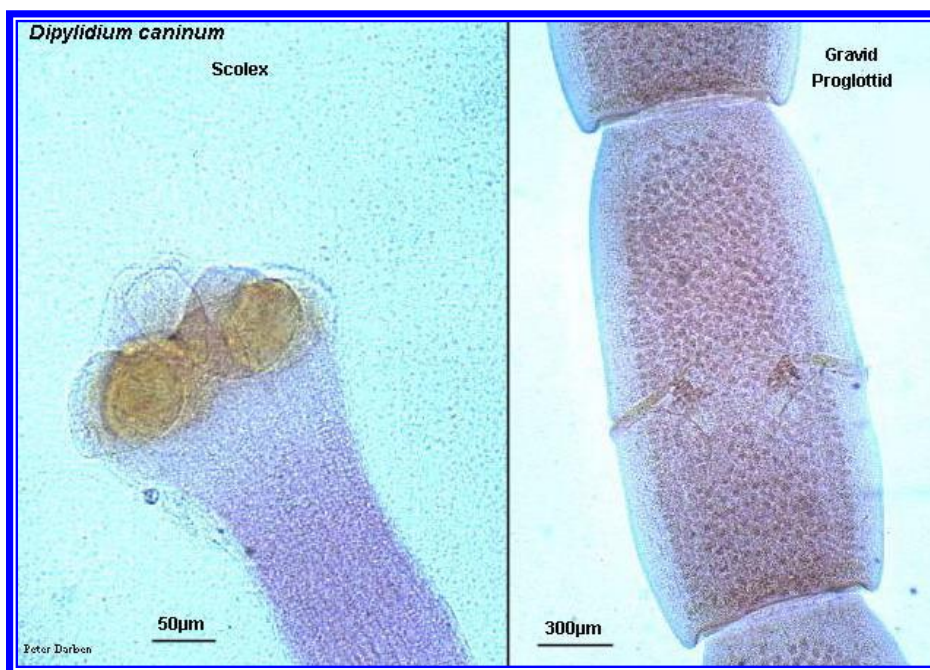(Fig: 34) scolex of *Raillietina echinobothrida*





eggs

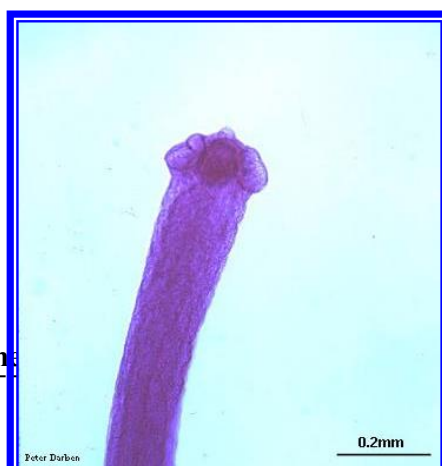
Adult



scolex

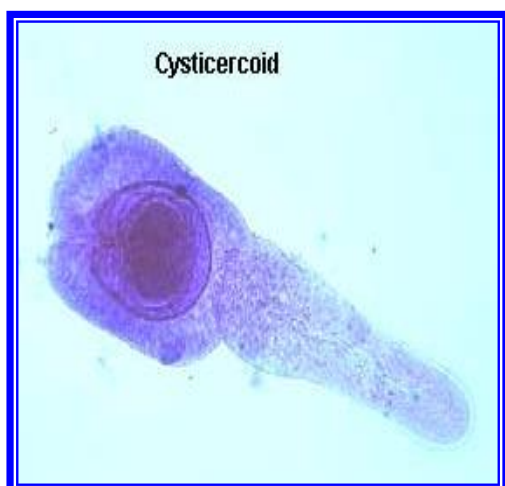
Gravid segment

(Fig: 35) *Dipylidium caninum*

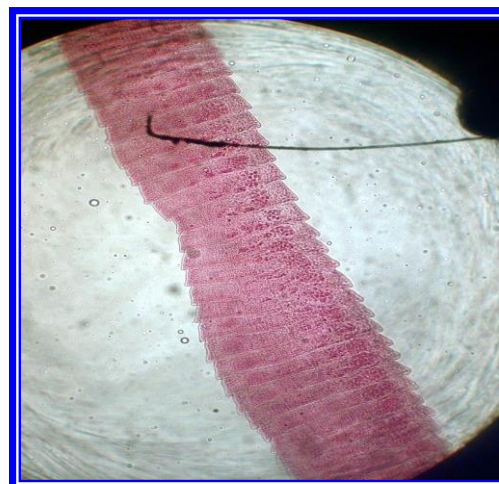




scolex

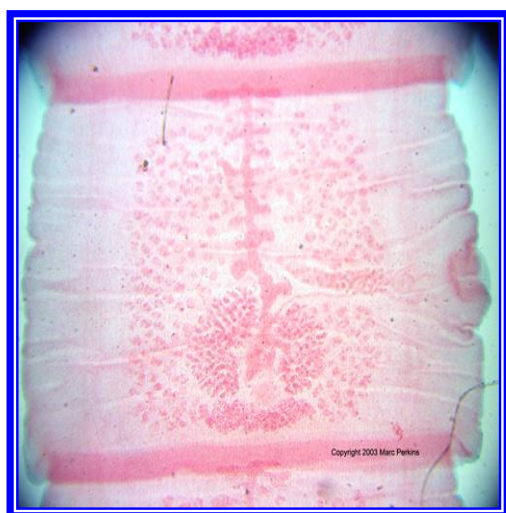


Cysticercoid

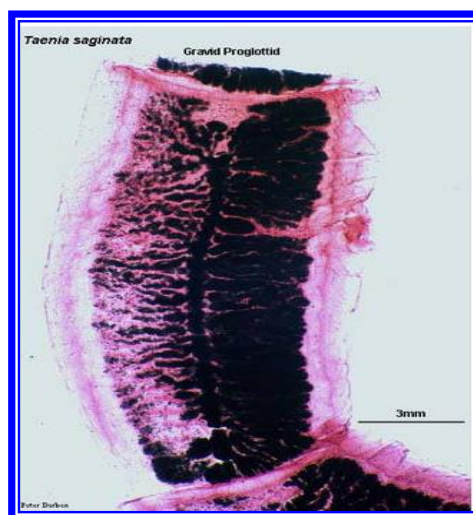


Gravid seg.

(Fig: 36) *Hymenolepis nana*.



(Fig:37) mature seg
of *Taenia*

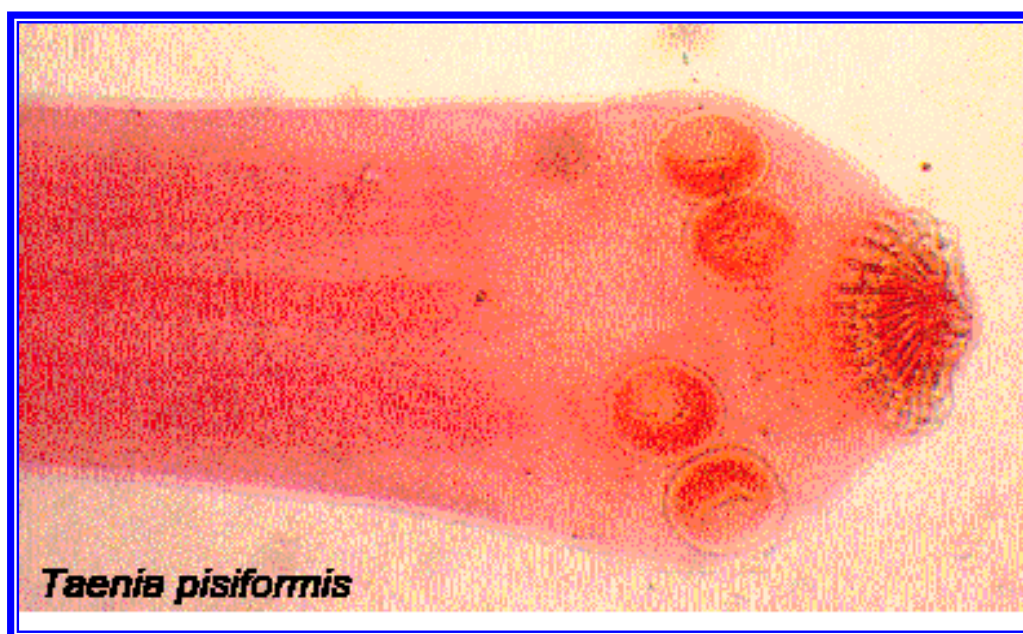

(Fig:38) gravid segment
of *Taenia*

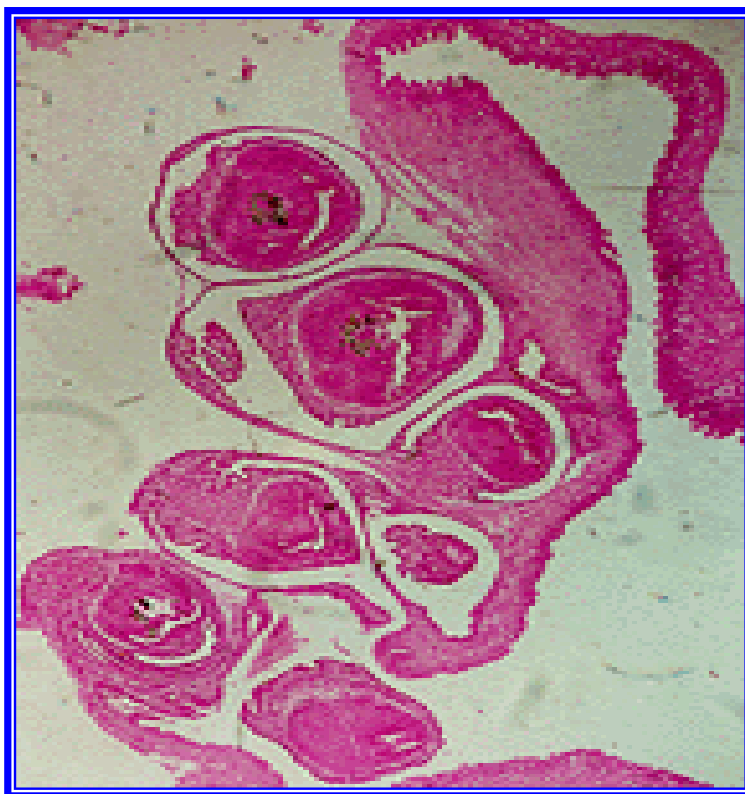




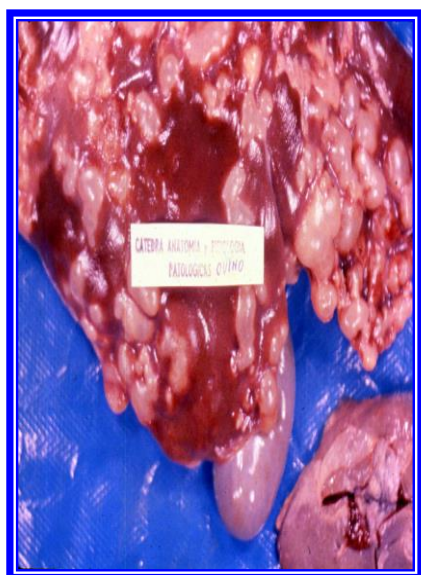(Fig:39) eggs of *Taenia spp*



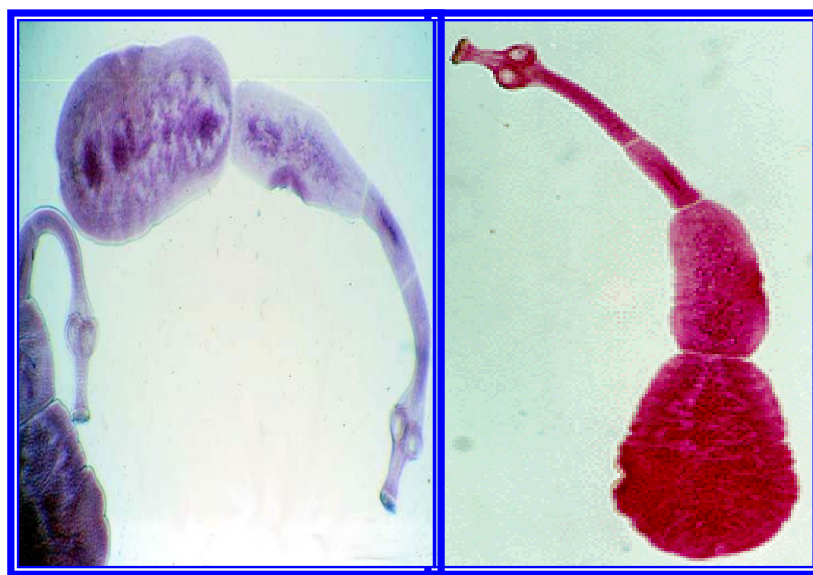
(Fig:40) scolex of *Taenia pisiformis*



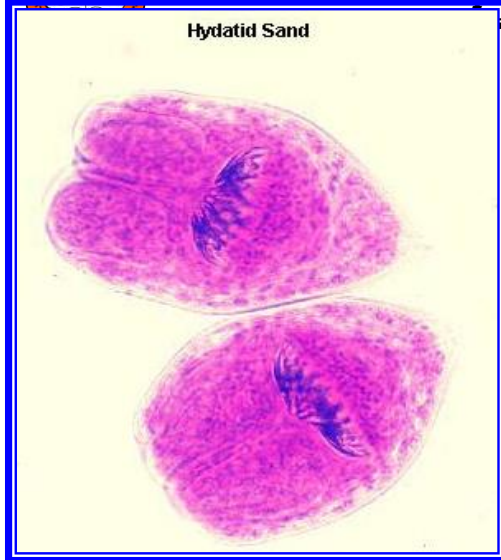
(Fig:41) *Coenurus cerebralis*



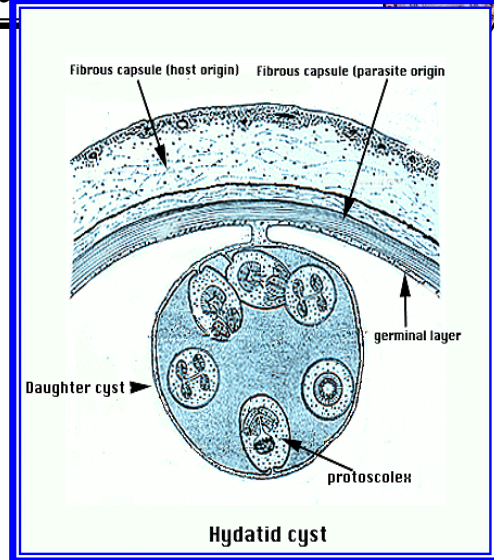
(Fig:43) hydatid cyst



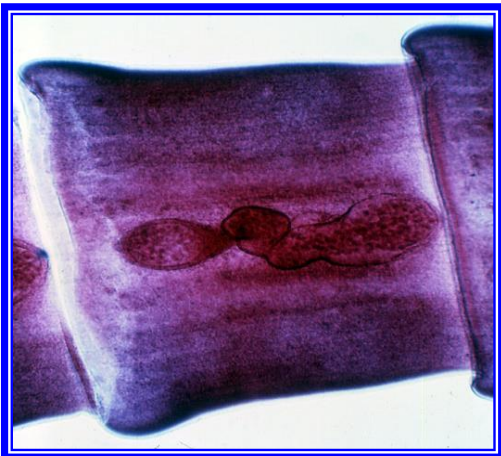
(Fig:42) *Echinococcus granulosus*



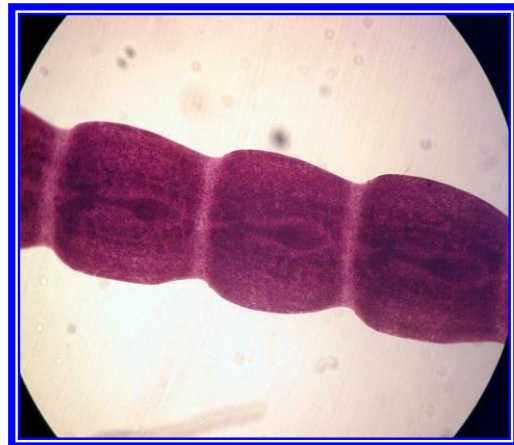(Fig:45) Protoscolex



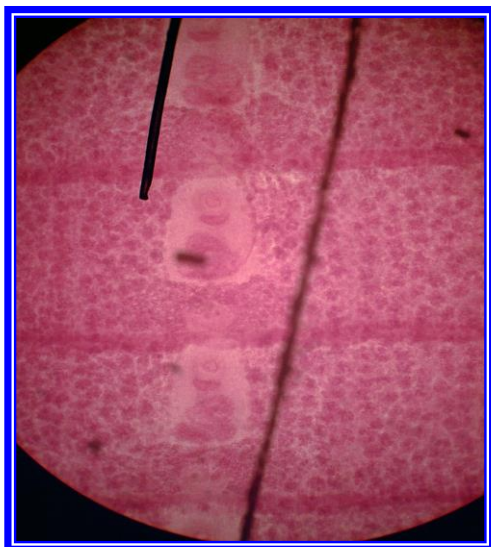
(Fig:44) Hydatid cyst



(Fig:47) gravid seg of Mesocystoides



(Fig:46) mature seg of Mesocystoides



(Fig:49) matur seg of Spirometra



(Fig:48) adult of Spirometra



Phylum : Nemathelminthes

Class: Nematoda

Order: Ascaridida

Superfamily: Ascaridoidea

Family : Ascarididae

Identification:

The genera of importance are *Ascaris*, *Parascaris*, *Toxocara*, they are :

1. Large worm which inhabit the small intestine.
2. There is no buccal capsule, the mouth consisting simply of a small opening surrounded by three lips, one dorsal and two subventral, each of which usually bears two papillae. No pharynx. The oesophagus is usually club shaped, muscular and without a posterior bulb.
3. The vulva of the female is in front of the middle of the body. The female are oviparous and produce a large number of eggs . The eggs are oval or subglobular and the shell is thick. (Fig: 50, 51)

Infective stages:

The common mode of infection is by ingestion of the thick shelled egg containing the L2 (Larvae 2).

Genus: Ascaris

Ascaris lumbricoides: occurs in the small intestine of human.

Ascaris suum: occurs in small intestine of pigs.

G.Parascaris.equorum : occurs in the small intestine of equines.

- 1- This is a rigid, stout worm with large head. The three main lips are conspicuous, separated by three small intermediate lips and divided into



anterior and posterior portion by horizontal grooves on their medial surfaces.

- 2-The males are 15- 28 cm and the female up to 50 cm. The male tail has small lateral alae. There are two double and three single pairs of post cloacal papillae.
- 3-The life cycle is direct. A female may lay as many as 200 000 eggs per day up to 2 million eggs may be produced daily. The eggs are very resistant to adverse condition, like drying or freezing, and to chemicals, they may remain viable for as long as five years.
- 4-The infection usually takes place through ingestion of the eggs with food or water with second stage larva with the sheath of the first stage larva as the infective form.

Toxocara canis:

Occurs in the small intestine of the dog and fox, commonly called arrow worm.

1. Large cervical alae are present and the body is anteriorly bent ventral.(Fig: 52)
2. The male tail has a terminal narrow appendage and caudal alae and spicules.
3. The life cycle is similar to that of Ascaris, also have prenatal (transuterine) and (lactogenic).

Diagnosis: is on the basis of the :

1. Clinical signs.
2. Examination of faeces.



Superfamily: *Oxyuroidea*

Family: *Oxyuridae*

Genus: *Oxyuris*

Sp. : *Oxyuris equi*

occurs in the large intestine of equines

Identification:

Commonly called Pin worm {seat worm} because of the pointed tail of the female parasite.

- 1- The oesophagus is narrow and the bulb is not distinctly marked off.
- 2- The tail male has one pin shaped spicules and bears two pairs of large and few small papillae. (Fig: 53)
- 3- The young females are almost white in colour, slightly curved and have relatively short, pointed tails. The mature females have brownish colour and narrow tails which may be more than three times as long as the rest of the body.
- 4- The eggs are elongate, slightly flattened on one side, provided with a plug at one pole. (Fig: 54)
- 5- cause anal pruritus produced by the egg laying females.

Diagnosis: Examination of the perineal region where cream coloured masses of eggs can readily be removed with the help of a piece of transparent adhesive tape and stuck on a slide for microscopic examination.



Superfamily: *Subuluroidea*

Family : *Heterakidae*

Genus: *Heterakis*

SP.: *Heterakis gallinarum*

occurs in the caeca of the fowl, turkey, duck and numerous other birds.

1. The oesophagus has a strong posterior bulb. (Fig: 55)
2. The tail of the male is provided with large alae, a prominent circular pre-cloacal sucker and twelve pairs of papillae. The spicules are unequal, the right longer being slender and 2 mm long, while the left has broad alae and measures 0.65-0.7mm
3. The infective stage is second larval stage.
4. The main principle economic importance of *H. gallinarum* lies in its role as a carrier of *Histomonas meleagridis* the causal agent of entero hepatitis of turkeys.

Diagnosis: is made by finding the eggs in the faeces.

***Ascaridia galli* :**

occurs in the small intestine of the fowl.

Identification:

1. There are three large lips and the oesophagus has no posterior bulb. (Fig: 56)
2. The tail of the male has small alae and bears ten pairs of papillae, and a circular pre-cloacal sucker with a thick cuticular rim, the spicules are sub-equal. (Fig: 57)
3. The eggs contain a fully developed second stage larva.
4. Causes hemorrhage, enteritis, anemia, diarrhea.



***Subulura brumpti* :**

occurs in the caeca of the fowl, turkey.

Identification:

1. The small buccal capsule has three teeth at its base .
2. The oesophagus has a small swelling posteriorly, followed by a deep constriction and then a spherical bulb. (Fig: 58)
3. The tail of the male is provided with large lateral alae, and pre-cloacal sucker is an elongate slit, surrounded by radiating muscle fibers, there are ten pairs of small caudal papillae and spicules are equal. (Fig: 59)
4. The life cycle is indirect, the intermediate hosts are various beetles and cockroach.

Order : Strongylida

Family : Strongylidae

Genus : Strongylus

Spp. : *S. equinus*

S. edentatus

S. vulgaris

These three species occur in the large intestine of equines. There is a well-developed globoid buccal capsule. The anterior margin of the buccal capsule usually bears leaf-like cuticular structures called the leaf-crowns, there may be an external and an internal leaf-crown, teeth may be present in the depth of the buccal capsule. Copulatory bursa on the posterior end of the male worms are well developed.



S.equinus

The buccal capsule is oval in outline and there are external and internal leaf crown .At the base of the buccal capsule there is a large dorsal tooth with a bifid tip and two smaller subventral teeth. (Fig: 60)

S. edentatus

The buccal capsule is wider anteriorly than at the middle and contains no teeth. (Fig: 61)

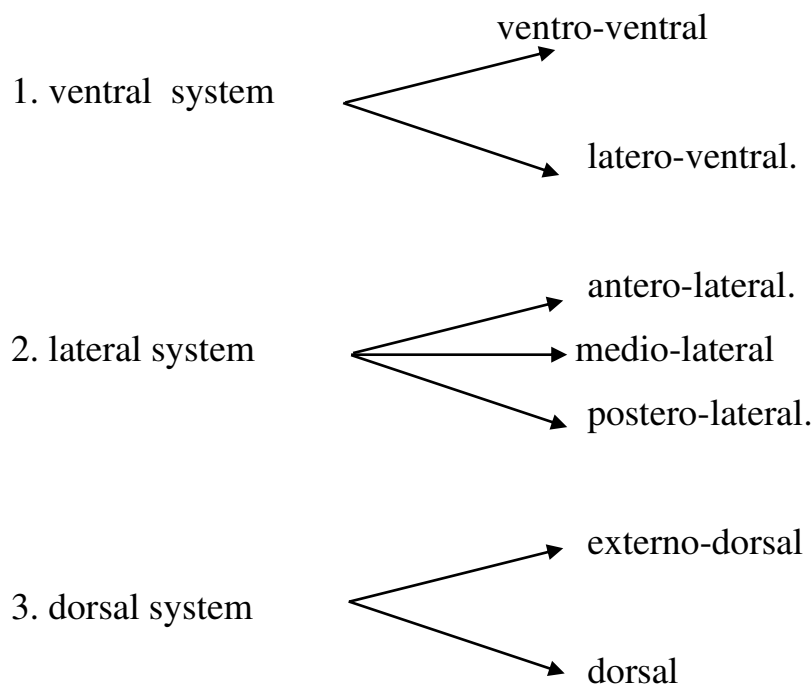
S. vulgaris

The buccal capsule is roughly oval and contain two ear-shaped dorsal teeth at its base. (Fig: 62)

The posterior end of male worms consist of:

1. Copulatory bursa :

consist of cuticular alae usually form two lateral lobes and a dorsal lobe enclosing the posterior extremity, and are supported by modified caudal papillae known as "the bursal rays" . these rays contain muscle fibers and are arranged in a definite order : Fig (63)





2. Two equal spicules:

Life cycle : This is direct and the infective stage is third stage larva.

The eggs are passed in the faeces → Hatching → L₁ → L₂ → L₃ (infective stage) → swallowed with herbage or water → liberation of the L₃ from the retained sheath of the second-stage larva (exsheathment) occurs in the small intestine. In *S. equinus* → L₃ penetrate the mucosa of the caecum and colon → formation of nodules → L₄ occurs in the nodules → peritoneal cavity → liver → peritoneal cavity → L₅ → large intestine lumen.

In *S. edentatus* L₃ → travel via the portal system → liver → L₄ → L₅ → large intestine .

In *S. vulgaris* L₃ penetrate the intestinal mucosa → L₄ → enter small arteries → cranial mesenteric artery and its main branches (Formation of thrombus and aneurysms) → L₅ → colon



Genus : Chabertia

Spp. : *C. ovina*

Occurs in the colon of sheep, goats, cattle. The buccal capsule which is bell shaped, has a double row of small papillae around the rim, there are no teeth. (Fig: 64) The male bursa is well developed and the spicules are equal. (Fig: 65)

Life cycle : This is direct, infective stage (L₃) which ingestion with water or herbage.

Family: Ancylostomatidae

Genus : Ancylostoma

Spp. : *A. caninum* (Hook worm).

Occurs in the small intestine of the dog, fox. The buccal capsule is large with marginal teeth. The ventral margin of buccal bears three teeth on either side, in the depth of the capsule there is a pair of triangular dorsal teeth and a pair of centrolateral teeth (Fig: 66). The male bursa is well developed.

Life cycle : This is direct, infective stage L₃.

Rout of infection :

1. Oral infection.
2. Skin penetration.
3. Prenatal infection of the fetus by intra-uterine infection.
4. Colostral or lactogenic infection of pups by passage the larvae through milk to the suckling puppy .



Genus : Bunostomum

Spp. : *B. trigonocephalum* (Hook worm)

Occurs in the small intestine of sheep, goats cattle. The large buccal capsule bears on the margin a pair of cutting plates and internally a large dorsal cone (Fig: 67). The bursa is well developed .

Life cycle : This is direct . Infection with the L₃ may be percutaneous or oral.

Family: Trichostrongylidae

Genus: Haemonchus

Spp: *Haemonchus contortus*

It occurs in the abomasum of sheep ,goats, cattle and numerous other ruminants .

It is commonly known as the stomach worm or wire worm of the ruminants and is one of their most pathogenic parasites .

Males are 10-20mm long and females 18-30mm.

The male has an even reddish color ,while in the female the white ovaries are spirally wound around the red intestine ,producing the appearance of a barbers pole.

The cervical papillae are prominent and spine –like.

A small buccal cavity is present ,containing a dorsal lancet.

The vulva of the female is usually covered by a lingual process (vulva flap which is usually large and prominent. (Fig: 68)

The male bursa has elongate lateral lobes supported by long, slender rays, the small dorsal lobe is asymmetrically situated against the left lateral lobe and supported by a Y-shaped dorsal ray. (Fig: 69)

The spicules provided with a small barb near its extremity.



Life cycle : is direct and L3 is the infective stage.

Diagnosis:

- 1- Examination of the fecal samples for detection of eggs by flotation technique.
- 2- Identification of larvae in fecal culture.

Genus :Ostertagia

The species of this genus which occur in the abomasums and rarely the small intestine of sheep ,goats ,cattle ,and other ruminants, usually known as brown stomach –worms ,because they have this color when they are fresh .

The male bursa has lateral and dorsal lobes and an accessory bursal membrane situated anteriorly on the dorsal side, distinguish between the male for this species of genus *Ostertagia* from the shape of the spicules.

Ostertagia ostertagi

The spicules have three bluntly- hooked in each end .

Ostertagia circumcincta

The spicules are slender, each ends in a large knobbed and small ,acute process. (Fig: 70)

Ostertagia trifurcata.

Each end of spicules has a stout ,knobbed tip ,while just behind the middle two sharp spurs are given off medially.

Life cycle *Ostertagia spp*: is direct ,third stage larvae is the infective stage.



Dignosis:

- 1- Diagnosis is based on grazing history
- 2- Clinical signs
- 3- Fecal examination .

Family :Dictyocaulidae

Genus :Dictyocaulus(lung worm)

Spp : *Dictyocalus filaria* in sheep

Spp : *Dictyocaulus viviparous* in cattle

Spp : *Dictyocalus arnifeildi* in horse and donkey

Dictyocaulus filaria

Occurs in the bronchi of sheep ,goats ,and some wild ruminants, the worms have a milk white color and the intestine shows as a dark line, there are four very small lips and a very small shallow buccal capsule.

In the male bursa the medio- and postero- lateral rays are fused together except at their tips, the externo dorsal arise separately and the dorsal ray is cleft right from its tips ,the spicules are stout ,dark –brown- boot shaped. (Fig: 71)

Life cycle:

Eggs →hatch in the lung→L1→Swallowed→Pass through the feces →L2→L3→Mouth(ingestion) →Penetrate into the intestine wall→Lymph vessels→L4→Lung(male and female in the bronchi of the host).

Diagnosis:

- 1- Finding the first –stage larvae in the fresh feces (can easily recognized by presence of small cuticular knob at the anterior extremity) by Baermann method .
- 2- The eggs may be found in the sputum or nasal discharge



Class: Spiurida

Family: Spiruridae

Genus: *Habronema*

This genus contain three species:

Harbonema muscae

Harbonema microstoma

Harbonema megastoma

Harbonema muscae

- Occur in the stomach of equines.
- Male 4-18mm long and female 13-22mm.
- There are two lateral lips, each being trilobed.
- The pharynx is cylindrical and provided with a thick cuticular lining.
- Esophagus divided into two parts, first one is musculature and the posterior part glandular.
- The male has wide caudal alae, four pairs of precloacal papillae and one or two papillae behind the cloacal.
- The left spicule is slender and 2.5mm long, the right stouter and 0.5mm (the right is longer than left and more thickness). (Fig: 72)
- The vulva is situated near the middle of the body.
- The eggs have thin shells and measure 40-50 by 10-20µm eggs or larvae may be found in the faces.

H. megastoma

- Occur in nodules in the stomach well.
- The pharynx is funnel-shaped.
- The male has four pairs of precloacal papillae.
- The left spicule is 0.46mm long and the right 0.24mm.



H. microstoma

- Occurs in the stomach of equines.
- Males being 16-22mm long and female 15-22mm.
- The pharynx contains a dorsal and ventral tooth in its anterior part.
- The male has four pairs of precloacal papillae.
- The left spicules measures 0.76-0.8mm and the right 0.35-0.38mm.
- The posterior end of female in the three species have no any structure.

Life cycle :

Indirect, intermediate host for *H. muscae* , *H. magastoma* in house fly (*Musca domestica*), while for *H. microstoma* stable flies (*Stomoxys calcitrans*).

The worms reach the infective stage in the maggots at about the time when the latter pupate. In the adult fly the larvae occur in the haemocoel and pass forwards into the proboscis. The larvae are deposited on the lips, nostrils and wounds of the horse when the fly feeds.

Diagnosis:

The gastric infection is difficult to diagnose because few eggs larvae are passed, some worms or larvae may be gastric lavage through a stomach tube.

Family: Thelaziidae

Genus: *Thelazia* spp.

Parasite of the conjunctival sac or lacrimal duct of mammals and birds. Body may be transversely striated. (Fig: 73)

Life cycle: Indirect. Intermediate host is *Musca domestica*



Diagnosis:

1. 1-A definitive diagnosis is made by the detection of the parasites in the conjunctival sac.
2. 2-Examination of the lacrimal secretions may reveal eggs or first-stage larvae.

Genus: *Setaria*

Spp. *S. digitata*

- Occur in the peritoneal cavity of cattle, buffalos.
- Long worms with filiform shape, anterior have dorsal prominences make the shape of worms a sit holding a crown, while posterior end of female having a button and pair of lateral projections also ten pairs papillae. (Fig: 74)
- Male have pair of spicules unequal in length.

Life cycle:

Indirect. The intermediate host is Mosquito The infective stage is Microfilaria having sheath and found in blood of host causing enzootic cerebrospinal nematodiasis. (Fig: 75)

Diagnosis:

Knott's methods: 1 ml of blood and 9 ml of 2% formalin are mixed and centrifuged for 5 minutes. The sediment is stained with methylene blue 1:1000.

Family: Onchocercidae

Genus: *Onchocerca*

Spp.: *O. armilata*

- Occurs in the aorta of cattle, buffalo, sheep and goat.
- Males are about 7 cm long and females up to 70 cm.



- The microfilariae are unsheathed 285-300µm by 6µm and are found primarily in the skin of the hump, also on the neck, dewlap and umbilical area.

Life cycle: is unknown.

Order: Enoplida

Super family: Trichuroidea

Family: Trichinellidae

Genus: *Trichinella*

Spp.: *T. Spiralis*

- Occurs in the small intestine of man, pig, rat and many other mammals.
- The male is 1.4-1.6mm long and the female 3-4mm.
- The body is slender and oesophageal portion is not markedly longer than the posterior part.
- The hind end of the male bears a pair of lateral flaps with two pairs of papillae behind them.
- There is neither a spicule nor a sheath.
- The eggs measure 40 by 30µm and contain fully developed embryos when in the uterus of the female.

Life cycle:

Engulphing of cystic larvae which found in muscle → releasing of these larvae due to effect of digestive enzymes → the first two moults are completed within 26 hours and fourth moult in less than two days in small intestine of host → adult worm → copulation occur about 40 hours after infection → male die and the females → produce eggs L1 → Thoracic duct → lymph → upper left vena cava → blood → striated muscles → surrounded by capsule → muscle calcification → larvae have



no development until eating. (Fig: 76)

Diagnosis:

Larvae may be demonstrated in muscle taken by biopsy the sample being examined either microscopically when pressed between two pieces of glass or after digestion in an acid pepsin (1%) solution.

Family: Trichuridae

Genus: *Trichuris*

Spp.: *T. trichura*

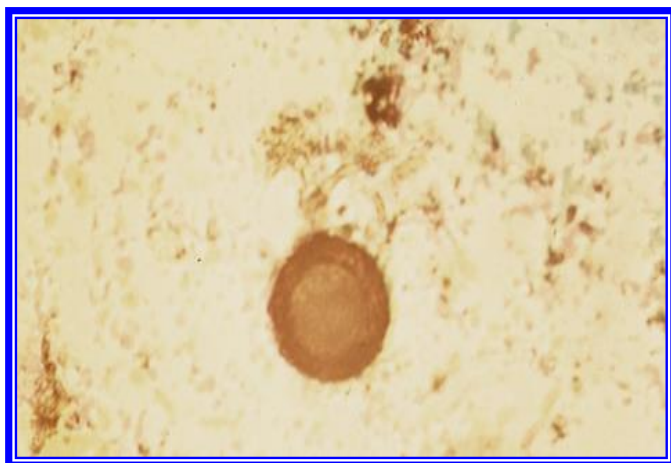
- Occurs in large intestine of human, known as **whip -worms** since the anterior end thicker is long and slender , while the posterior end is much thicker .
- The posterior end of male have one spicule surrounded by sheath which is armed with cuticular spines. (Fig: 77)
- The eggs are brown, barrel-shaped with a transparent plug at either pole and measure 70-80 by 30-42µm, they contain an unsegments embryo when laid. (Fig: 78)

Life cycle:

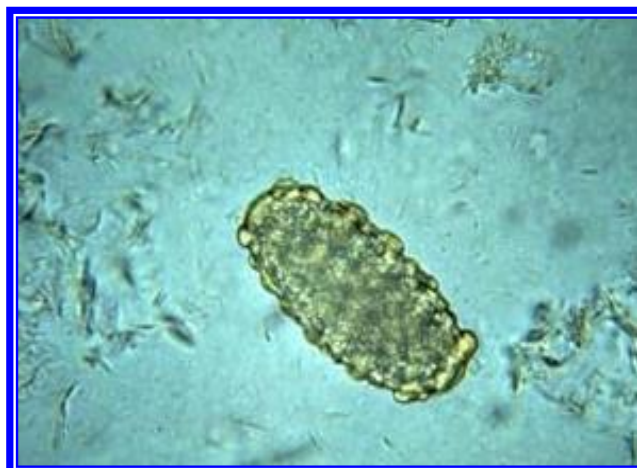- The life cycle is direct.
- The host acquires the infection occurs by ingesting the eggs and the larvae penetrate the anterior small intestine for two to ten days before they move to the caecum where they develop to adults.

Diagnosis:


Is made by demonstration of the characteristic barrel shaped egg in the faeces.



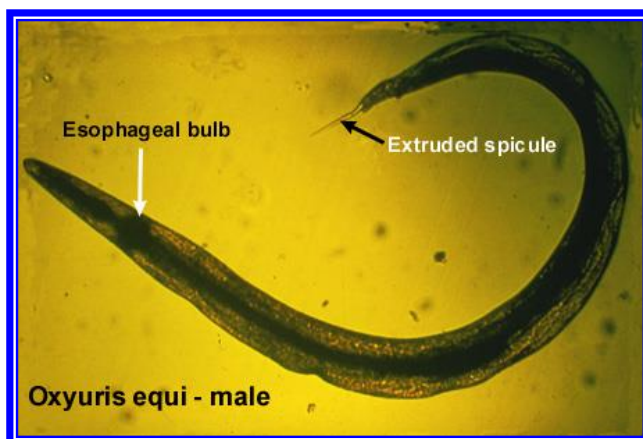
(Fig: 50) Ova of *Parascaris spp*



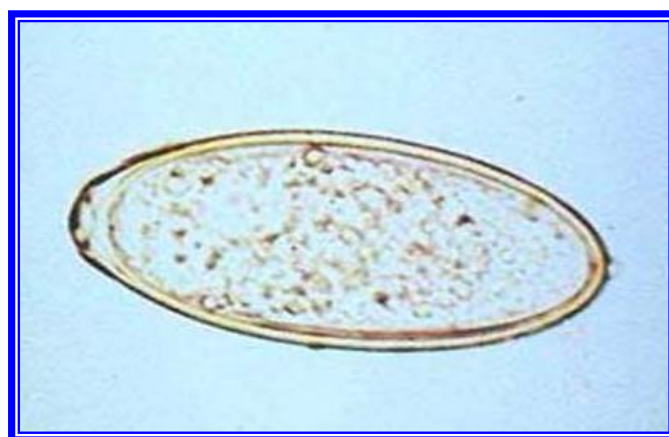
(Fig: 51) Ova of *Ascaris spp*



(Fig: 52) anterior end of *Toxocara canis*



(Fig: 53) *Oxyuris equi*



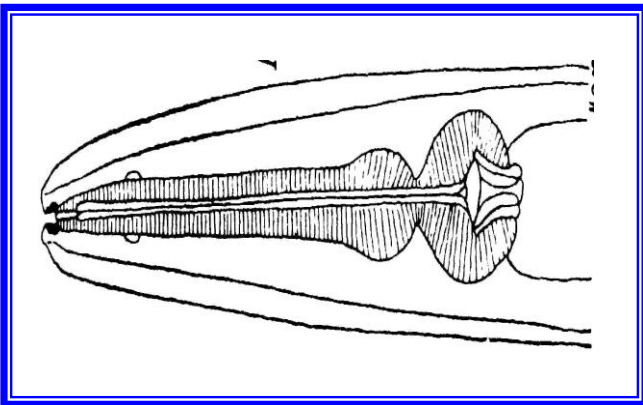
(Fig: 54) Ova of *Oxyuris equi*



(Fig: 56) anterior end of *Ascaridia galli*



(Fig: 55) anterior end of *Heterakis gallinarum*



(Fig: 58) anterior end of *Subulura brumpti*



(Fig: 57) posterior end of male of *Ascaridia galli*

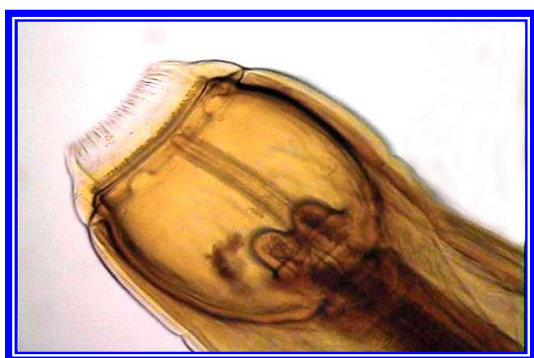

(Fig: 59) posterior end

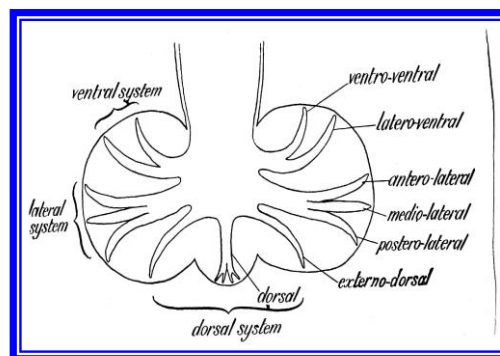




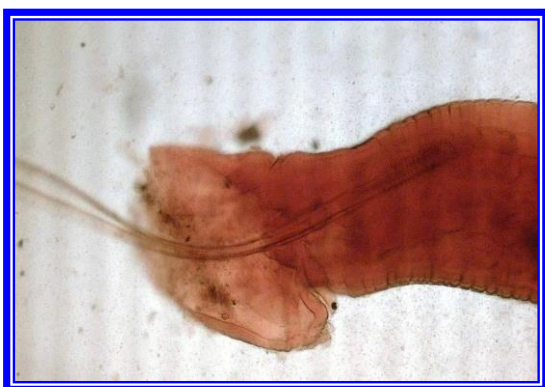**(Fig: 61) anterior end of
*Strongylus edentatus***



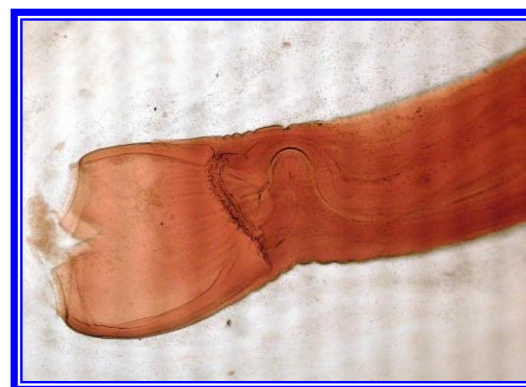
**(Fig: 60) anterior end of
*Strongylus equinus***



**(Fig: 62) anterior end of
*Strongylus vulgaris***



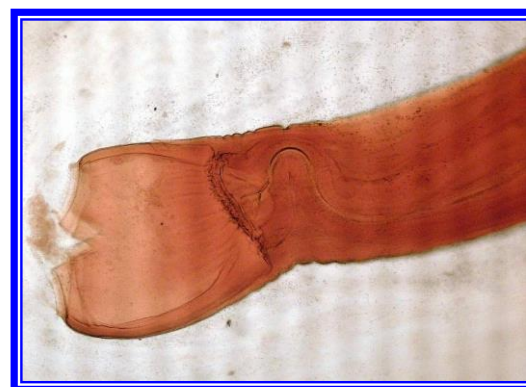
**(Fig: 63) copulatory bursa of
Genus *Strongylus***

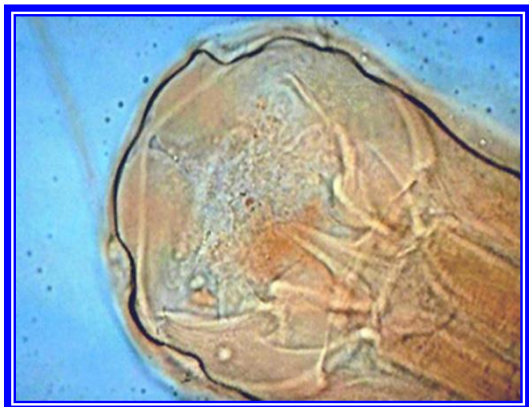

**(Fig: 65) posterior end of
*Chabertia ovina***

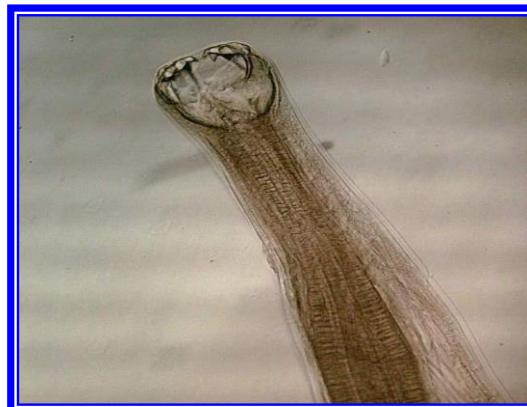


**(Fig: 64) anterior of
*Chabertia ovina***

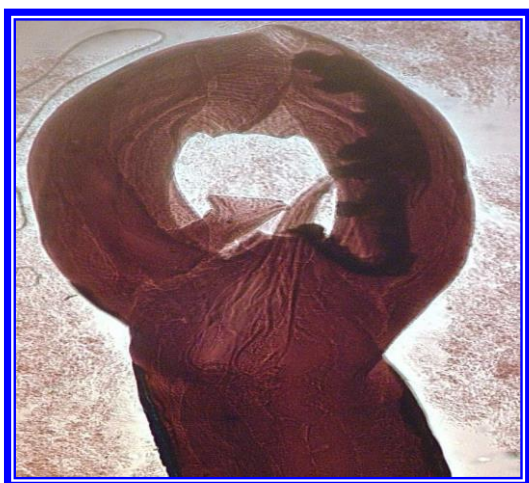



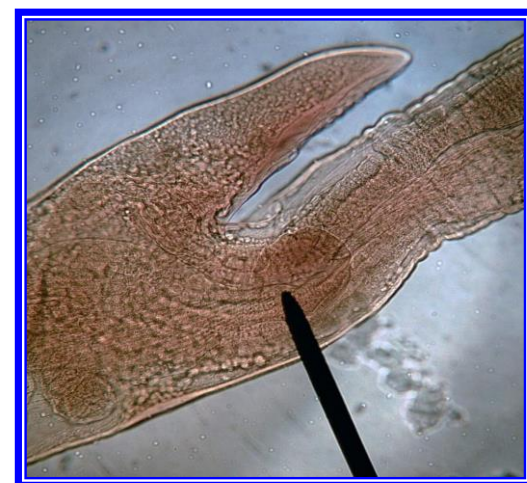**Fig(67)anterior end of
*Bunostomum***



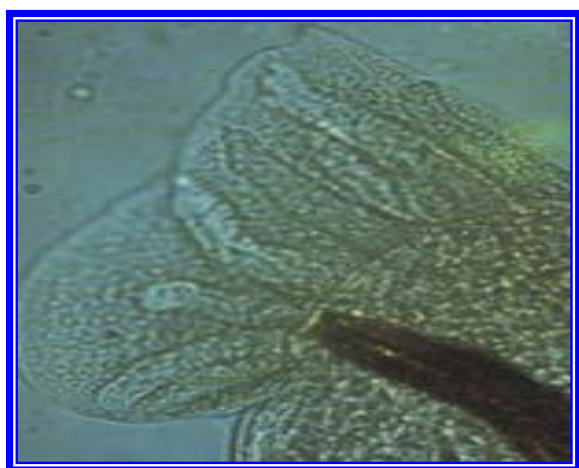
**(Fig: 66) anterior end of
*Ancylostoma caninum***



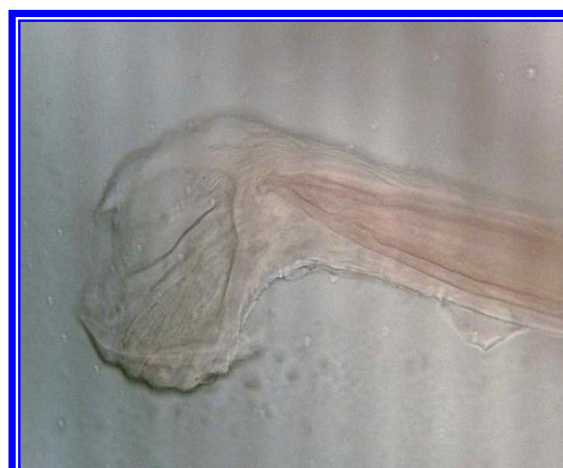**(Fig: 69) posterior end in male
*Haemonchus contortus***



**(Fig: 68) vulva covered by flap in the
female of *Haemonchus contortus***



**(Fig: 71) posterior end of male
*Dictyocaulus filaria***

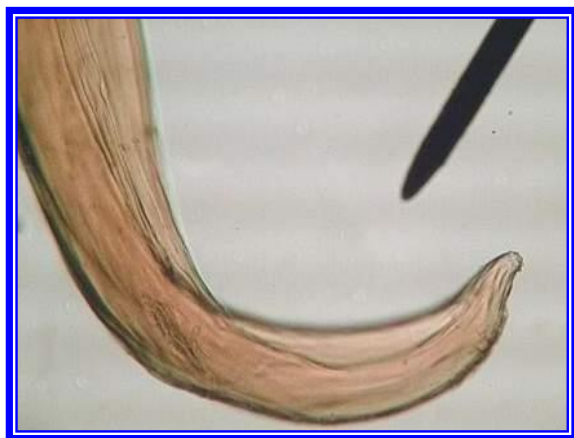


**(Fig: 70) posterior end of male
*Ostertagia circumcincta***

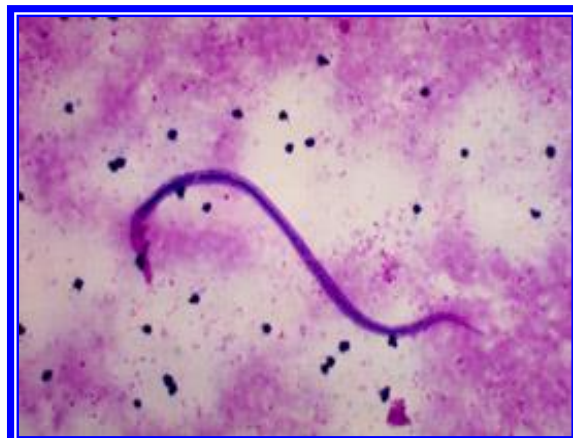



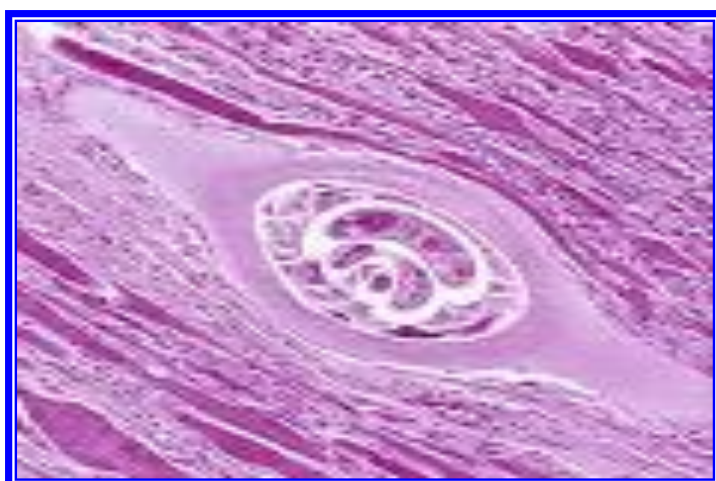(Fig: 72) posterior end of male *Habronema muscae*



(Fig: 73) anterior end of Thelazia



(Fig: 74) posterior end of *Setaria digitata*



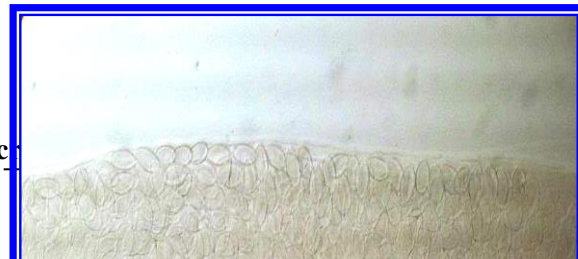
(Fig: 75) microfilaria of seteria



(Fig: 76) *Trichinella spiralis* larvae in striated musculature



٧٩
t of mic





Chapter Four : Nematoda



(Fig: 77) male of *Trichuris trichura*

(Fig: 78) egg of *Trichuris trichura*



Phylum:Protozoa

Subphylum: Sarcomastigophora

Class: Mastigophora

Genus :Trypanosoma

Members of this genus are found in the blood stream and tissues of vertebrates.

Leaf –like in shape they have a single flagellum and this is attached to the body of the organism by an undulating membrane

Transmission:

1. Cyclical transmission: the trypanosomes transmitted by tsetse flies in which the trypanosomes multiply, undergoing a series of morphological transformation before forms infective stage. Multiplication occurs in the midgut before migrating forward to the salivary glands (anterior station development) (Salivaria group). In other trypanosomes, multiplication and transformation occurs in the gut and the infective forms migrate to the rectum and are passed with the faeces, this is posterior station development (Stercoraria).
2. Non cyclical transmission (mechanical transmission) .the trypanosomes are transferred from one mammalian host to another by the interrupted feeding of biting insects ,notably tabanids and *Stomoxys*

Stercoraria group:

Morphology :

1. kinetoplast large and not terminal
2. posterior extremity tapering
3. free flagellum present
4. 4-undulating membrane not well developed



5. Metacyclic trypanosomes in posterior station in arthropod host and transmitted by contamination through faeces ,often non pathogenic but the only species *T.cruzi* causes the disease in man

T. cruzi (This is the main pathogenic species in stercoraria)

Cause of chagas disease in man.

Transmitted by kissing bugs (Reduviidae)

In the blood smear: (Fig: 79)

Monomorphic ,16-20 μm in length, and crescent shaped with a pointed posterior end ,the kinetoplast is large and subterminal ,the nucleus is midway along the body and there is a moderately well-developed undulating membrane and free flagellum

Salivaria group

1. Kinetoplast smaller .
2. Terminal or subterminal .
3. Posterior extremity blunt .
4. There may be no free flagellum .
5. Undulating membrane varying in development .
6. Metacyclic stage in the anterior station of the arthropods host and transmission is by inoculation ,frequently highly pathogenic ,some species are transmitted non cyclically by arthropods or by coitus.

Cyclically transmitted trypanosomes forms

T.brucei (Fig: 80)

- 1- This is polymorphic trypanosome(8-39 μm) slender ,intermediate and stumpy forms occurring



- 2- In the slender form has a well developed free flagellum and the undulating membrane is conspicuous while in stumpy form it is either short or absent
- 3- The kinetoplast is small and subterminal and the posterior end is pointed.
- 4- *T.brucei* causes the disease called nagana, transmission by *Glossina spp*

Mechanically transmitted trypanosomes forms

T. evansi (Fig: 81)

Cause of surra disease in horses and camels.

T. evansi is identical in appearance to the slender forms of *T. brucei*, 15-34µm in length, this parasite monomorphic in character but polymorphism occurs sporadically .

Transmitted by biting flies such as *Tabanus*, *Stomoxys*.

T. equiperdum (Fig: 82)

Similar to *T. evansi*.

Causes dourine disease in horses and donkeys , *T. quiperdum* is transmitted by coitus , rarely it is transmitted by biting –flies.

Genus: *Leishmania*

Hosts: man, dog and wide variety of wild animals

Transmitted by sand fly

Cause of Leishmaniasis has both cutaneous and visceral forms.

Site : The protozoa multiply within macrophages which are destroyed, the liberated parasites entering other intact macrophages.

L. tropica which causes cutaneous leishmaniasis or oriental sore , developing at site of the insect bite.



L.donovani causing visceral leishmaniasis or kala-azar, the infection being systemic.

L. braziliensis causing lesion similar to *L.tropica*.

Life cycle : the amastigote form after ingestion by a sand fly, transforms into a promastigote form in the insect gut. (Fig: 83)

Identification and life cycle:

Within the macrophages the organism possess a rod –shaped kinetoplast associated with a rudimentary flagellum which ,however ,does not extend beyond the cell margin , this leishmanial or amastigote form after ingestion by a sand fly ,transforms into a promastigote form in the insect gut in which the kinetoplast is situated at the posterior end of the body, these divide by binary fission ,migrate to the proboscis, when the insect feeds are inoculated into a new host, within a macrophages the promastigote reverts to the amastigote

Diagnosis:

demonstration of the amastigote in smears or scrapings from skin or from lymph node or marrow biopsies.

Trichomonas foetus

Site : In cow , the uterus and vagina of cow, in bulls the preputial cavity.

Identification:

pear shaped 20 ×10 μm and has a single nucleus, and four flagella arising from a basal body situated at the anterior rounded end, three of flagella are free anteriorly, while the fourth extends backwards to form an undulating membrane along the length of the organism and then continues posteriorly as a free flagellum ,the axostyle,a hyaline rod with a



skeletal function ,extend the length of the cell and usually projects posteriorly . (Fig: 84)

Life cycle : during coitus

Class: Sarcodina

Entamoeba histolytica

cause of amoebic dysentery in man which produce a characteristic flask shaped ulcers in the mucosa of the large intestine.

Identification :

- Trophozoite stage ranges in size from 10-60µm, it has finely granular endoplasm and the ectoplasm is hyaline in appearance, pseudopodia appearing suddenly which are long and finger like , single spherical nucleus , active trophozoites also possess food vacuoles which contain red blood cells in the process of digestion. (Fig: 85)
- Cyst stage are spherical , and measure 5-20 µm in diameter, initially the cyst are uninucleate but finally a four nucleate cyst is produced.
- Diagnosis is made by examining faeces for presence the cysts.



Subphylum : Sporozoa

Class : Coccidia

Family : Eimeriidae

Genus : Eimeria

Host : Poultry, cattle, sheep, goats ,pigs, horses, rabbit

Site: Epithelial cells of the intestine and in two species the kidney and liver respectively.

Important species : Chickens : *E.tenella* , *E. necatrix*.

Cattle: *E.zuernii*,*E.bovis* , Sheep :*E.crandallis* ,*E.ovinoidalis*, Goats , *E.arloingi* , Horse : *E.leuckarti* , Rabbits : *E.stiedae* (liver) , *E.intestinalis* (intestine)

Morphology :

Oocyst :

The most common shapes of oocyst are spherical ,ovoid or ellipsoidal , and vary in size(10_50 μ) according to species. The oocyst wall composed of two layers ,in some species it may be yellowish or even green in color. Some species a small pore at one end (micropyle) which is often covered by a polar cap may be prominent. In sporulated oocyst ,four sporocysts are elongate ovoid forms with one end more pointed than other at the more pointed end is the stieda body. An oocystic residual body and a polar granule may also be present in the oocyst. Each sporocyst contain two sporozoites each have a granular cytoplasm and distinctly placed central nucleus. Sporozoite are bent comma shaped and contain a round vacuole at one end. Sporocytic residual body may be present. (Fig: 86)



Life cycle :

Direct, infective stage: sporulated oocyst. Life cycle divided into three phases : (Fig: 87)

1. Sporulation (takes place out with the host).
 2. Schisogony
 3. Gametogony
- } Occur within the host in the intestinal epithelium

Diagnosis:

1. examination faeces for presence of oocyst by flotation method.
2. examination of scrapings or histological sections of affected tissues.

Genus: Cryptosporidium.

Morphology:

The common shape of sporulated oocyst are spherical or ovoid, vary in size(4_4.5 μ) and contain four sporozoites, residual body ,and empty vacuole .The oocyst wall is composed of two layer.

Rout of infection and life cycle (Fig: 88)

The life cycle is direct

The life cycle of *Cryptosporidium* divided into six stages :

1. Excystation (liberation sporozoite form the oocyst).
2. Merogony.
3. Gametogony.
4. Fertilization.
5. Oocyst wall formation .
6. Sporogony.

The life cycle of *Cryptosporidium* differs from *Eimeria* and *Isospora* by :



1. sporulation takes place within the host and become *infected* during passed with the faeces while the oocyst of *Eimeria* and *Isospora* sporulation take place out with the host under suitable condition.
2. *Cryptosporidium* does not enter the cells of the host and the development stage occur within the parasitophorous vacuole near the surfaces of the host cell and the sporozoite invade the microvillous brush border of the enterocytes.
3. *Cryptosporidium* lacks host specificity so that cross infection can occur between domestic and laboratory animals and man.

Diagnosis:

Oocyst may be demonstrated by using Ziehl _Nielsen stained faecal smears in which the sporozoite appear as bright red granules (Fig: 89) or by iodine stain(90)

Family : Sarcocystidae

Genus: Toxoplasma

Species : Toxoplasma gondii

Final host : cat

Intermediate host : mammalian and avian hosts, the cats may also be an intermediate host

Site in final host : Schizonts and gamonts in the small intestine .

Site in the intermediate host : Tachyzoite and bradyzoites in extra- intestinal tissues including muscles , liver, lung, and brain

Morphology :



1. Oocyst :these are found in the faeces of cats, are unsporulated, when sporulated , the oocyst contains two sporocysts,each with four sporozoites.
2. Tachyzoites : are found developing in vacuoles in many cells .measuring (6.0_8.0 μ)
3. Bradyzoite : these are contained in cysts and occur mainly in the muscles , liver , lung , and brain .The bradyzoite are lancet shaped and several thousand may be present in one cyst which can measure up to(100 μ) in diameter (Fig: 91)

Life cycle : indirect or direct.

Infective stage (bradyzoite , tachyzoite ,oocyst)

Final host infected by :

1. ingestion Toxoplasma infected animals usually rodents , whose tissue contain tachyzoites or bradyzoites.
2. ingestion of sporulated oocyst.

Intermediate host infected by :

1. ingestion sporulated oocyst
2. ingestion bradyzoites and tachyzoites in the flesh .of an other intermediate host such as ingestion undercooked meat containing Toxoplasma cyst,in man congenital infection occur only when a woman is exposed to infection for the first time during pregnancy.

Diagnosis:

1. Serological tests.
2. Demosttration of the organisms in tissues of mice inoculated with suspect material.(biological assay).
3. Impression smears from various body organs(brain ,lungs, heart, liver, muscles ,uterus and testes).
4. Trypsin or pepsin digestion .



Chapter Five : Protozoa





Genus: Sarcocystis

Final hosts : dogs, cats.

Intermediate host: ruminants, pigs, horses.

Site in the final host: small intestine.

Site in the intermediate hosts: schizont in endothelial cells of blood vessels, large cyst containing bradyzoites in muscles.

Species in dogs: *S.bovicans*, *S.ovicanis*, *S.eqicanis*, *S.capricanis*.

in cats: *S.bovifelis*, *S.ovifelis*

Species in man *S.bovihominis*

Morphology: (Fig: 92)

1. oocyst sporulated when passed in faeces and contain two sporocysts with four sporozoites
2. Tissue stage: In the intermediate hosts , schizonts found in the endothelial cells are quite small (2_8 μ) in diameter , bradyzoite cyst can be very large and visible to the naked eye as whitish streaks running in the direction of the muscle fibers .

Life cycle and rout of infection (always indirect) :

Final host infected by ingestion cysts in the muscle of intermediate hosts ,sexual phase and sporulation oocyst occur in the final hosts.

Intermediate hosts infected by ingestion of sporocyst and asexual phase and cysts formation occur in the muscles of the intermediate host.

Diagnosis: In intermediate hosts:

1. Meat inspection.
2. Histological examination.
3. Serological tests.

In final host: examination the faeces for presence of sporocyst.



Class: Piroplasmida

Family: Babesiidae

Genus: *Babesia*

- Parasites of the family Babesiidae are round to pyriform, amoeboid forms occurring in the erythrocytes.
- They multiply by binary fission or schizogony in the red blood cells. The vectors are Ixodid ticks.
- Development and transmission of *Babesia spp* in ticks is either by:-
 1. Transovarian transmission The tick development stages occur on the same animal.(host)
 2. Transstadial transmission Stage to stage transmission , with two or three host ticks because the adult stages transmitting infection which they acquired as nymphs , or nymphs doing the same with infection acquired as larva.

Babesia of cattle:

B.bigemina B. major B. bovis B.divergens

***B. bigemina* (Fig: 93)**

- This organism is the cause of cattle tick fever, red water fever, Babesiosis.
- Morphology is a large 4-5 μm in length by about 2 μm in width.
- Pear-shaped and lie in pairs forming an acute angle in the red blood cells.
- This parasite causes haemoglobinuria , marked anemia .



Babesia of sheep and goat:

B.motasi* *B.ovis

B.motasi (Fig : 94)

- Pear shaped (pyriform)
- Measuring 2.5-4 μm by 2 μm .
- They may occur single or in a pairs
- The angle at which they meet being acute.
- The disease caused by *B.motasi* may be acute or chronic similar to that of *B.bigemina*.

Babesia of horses:

B.caballi (Fig: 95) ***B.equi***

- It is a large species , commonly occur in a pairs, pyriform and measure (2.5-4) μm in length.
- The angle formed by the organisms is acute.
- This parasite cause persistent fever and anemia with icterus, disturbances of the (CNS)and may result in posterior paralysis.
- But haemoglobinurea is rare and is not characteristic of the infection.
- **Babesia in dogs: *Babesia canis***

This is a large ,pyriform in shape 4-5 μm in length and round at the other, frequently there is a vacuole in the cytoplasm ,the organism varying from amoeboid to ring forms.

Genus :*Theileria*

- This parasite are round , ovoid ,rod-like or irregular forms ,found in lymphocytes , histocytes and erythrocytes.
- Transmitted by Ixodid ticks.



Chapter Five : Protozoa



- Occur in cattle , sheep ,goats and other ruminants.
- Cause Theileriasis.



Theileria species of cattle

Th.parva* *Th.annulata

***Th.parva*:** (Fig: 96)

Causes the disease east coast fever or Bovine theileriasis. Yellow fever.

Morphology:

- The forms in red blood cells are mainly rod, round ,oval, comma and ring shaped(1.5-2 x 0.5-1 μ m).
- with romanowsky stains they show a blue cytoplasm with a red chromatin granule at one end. Several parasite may occur in individual erythrocytes.
- The actively multiplying forms of the parasite occur chiefly in the cytoplasm of lymphocytes and occasionally in the endothelial cells especially of the lymphatic glands and the spleen.
- These are schizonts or(Koch' blue bodies) circular or irregularly shaped structures about 8 μ m in diameter , with a blue cytoplasm and avaried number of red chromatin granules.

***Thieleria* species of sheep and goat:**

Th.ovis* *Th.hirci

Diagnosis of Theileria

- 1- Giemsa –stained blood smears.
- 2- Biopsy smears of lymph nodes.
- 3- In dead animals in impression smears of lymph nodes and spleen

Class: Haemosporidia

Genus :Plasmodium

Genus: Haemoproteus (Fig: 97)

Genus :Leucocytozoon (Fig: 98)



- These parasites causes of avian (malaria) in domestic and wild birds.
- A disease most common in the tropics and transmitted by dipteran flies.
- The vectors differs, in that avian species.
- *Plasmodium* are transmitted by mosquitoes.
- *Haemoproteus* are transmitted by hippoboscids.
- *Leucocytozoon* are transmitted by *Simulium* spp .
- Chickens ,ducks, turkeys, geese and pigeon may be effected.
- The clinical signs ranging from the pyrexia , anemia , paralysis and
- even sudden death.

Diagnosis :

Depends on the recognition and differentiation of the parasites in the red blood cells of stained blood films.

Order: Rickettsiales

Genus: *Anaplasma* (Fig: 99)

- These parasites found in the red blood cells of cattle, cause Anaplasmosis.
- *Anaplasma* appear as a small, spherical bodies red or dark red in color (inclusion bodies)
- (0.2-0.5) μm in diameter with no cytoplasm but a faint halo may appear around them.

Species: *A.marginale* *A.centrale*

Anaplasma marginale its marginally placed in the erythrocytes.

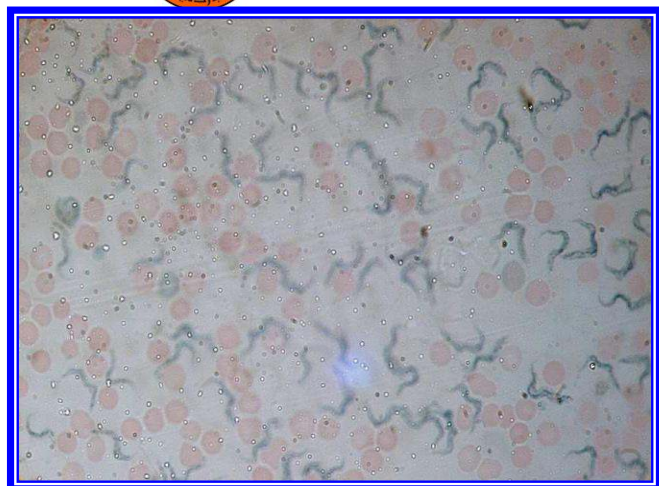
Anaplasma centrale its centrally placed in the erythrocytes.



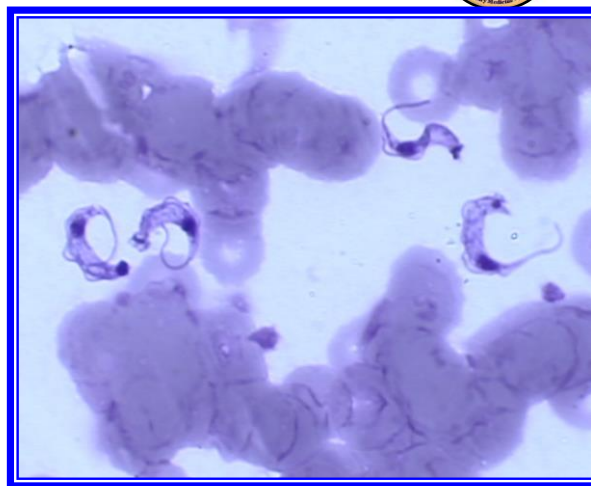
Chapter Five : Protozoa



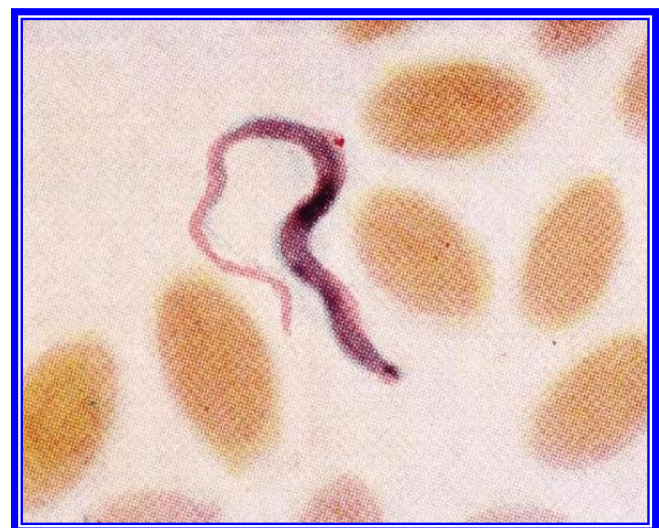
- Infection is transmitted by ticks or mechanically by biting insects or even by contaminated hypodermic needles or surgical instruments.
- Diagnosis: Examination of stained blood film (staining with Giemsa stain) and recognition of the parasite inside the red blood cells .



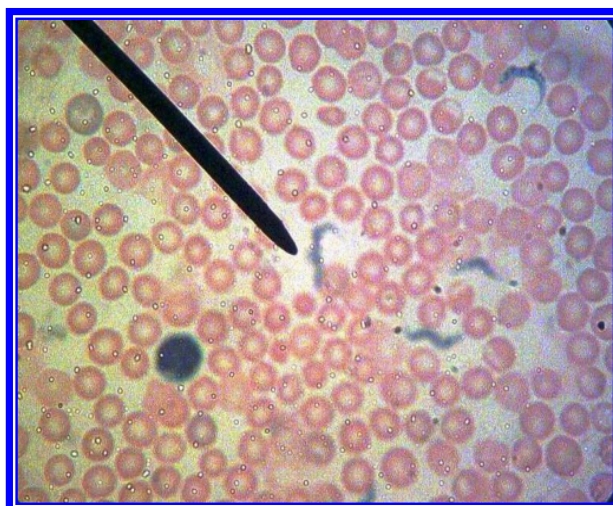
(Fig: 80) *Trypanosoma brucei*



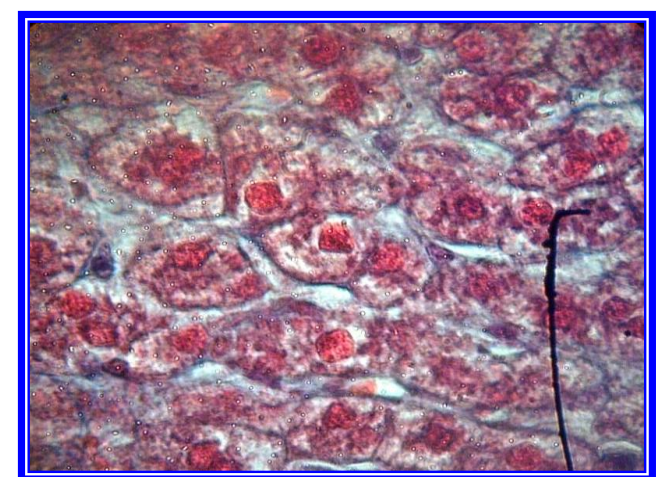
(Fig: 79) *Trypanosoma cruzi*



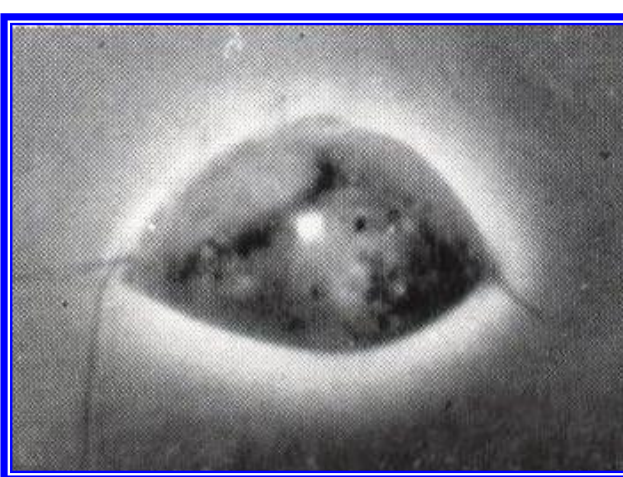
(Fig: 81) *Trypanosoma evansi*



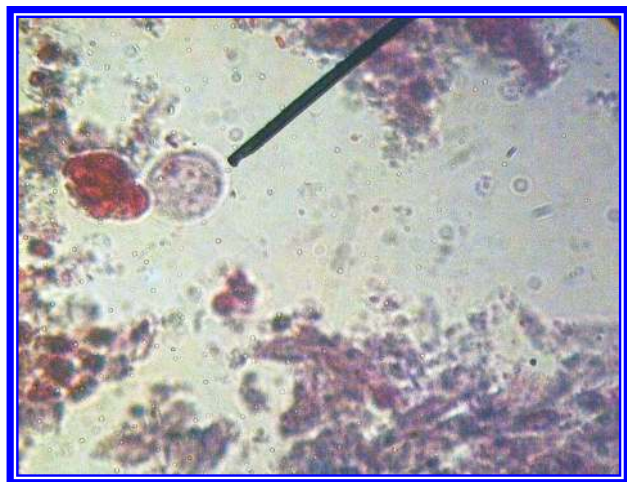
(Fig: 82) *Trypanosoma equiperdum*



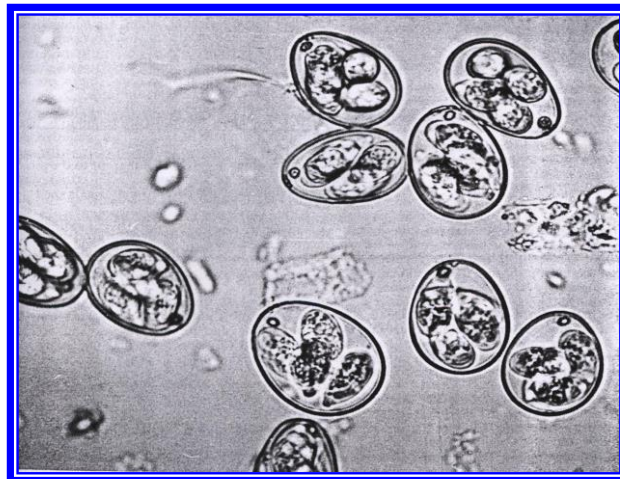
(Fig: 83) *Amastigote of Leishmania*



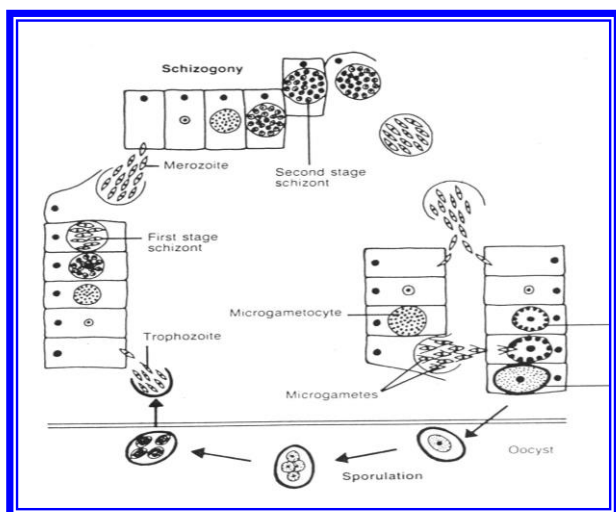
(Fig: 84) *Trichomonas foetus*



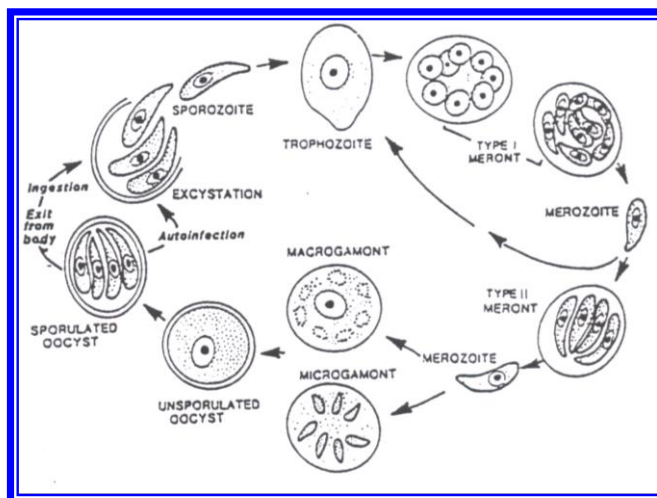
(Fig: 85) Trophozoite of *Entamoeba histolytica*



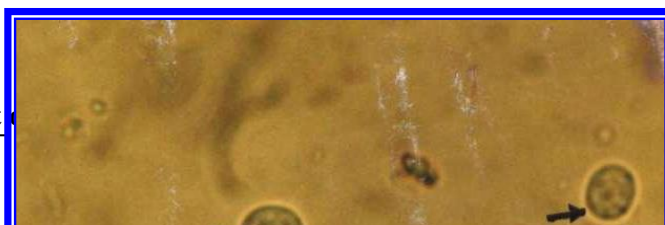

(Fig: 86) oocysts of *Eimeria*



(Fig: 87) Life cycle of *Eimeria* spp



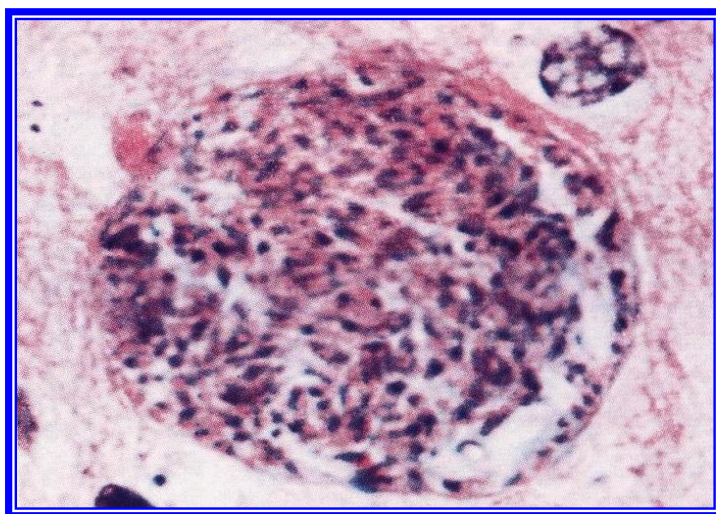
(Fig: 88) Life cycle of *Cryptosporidium*



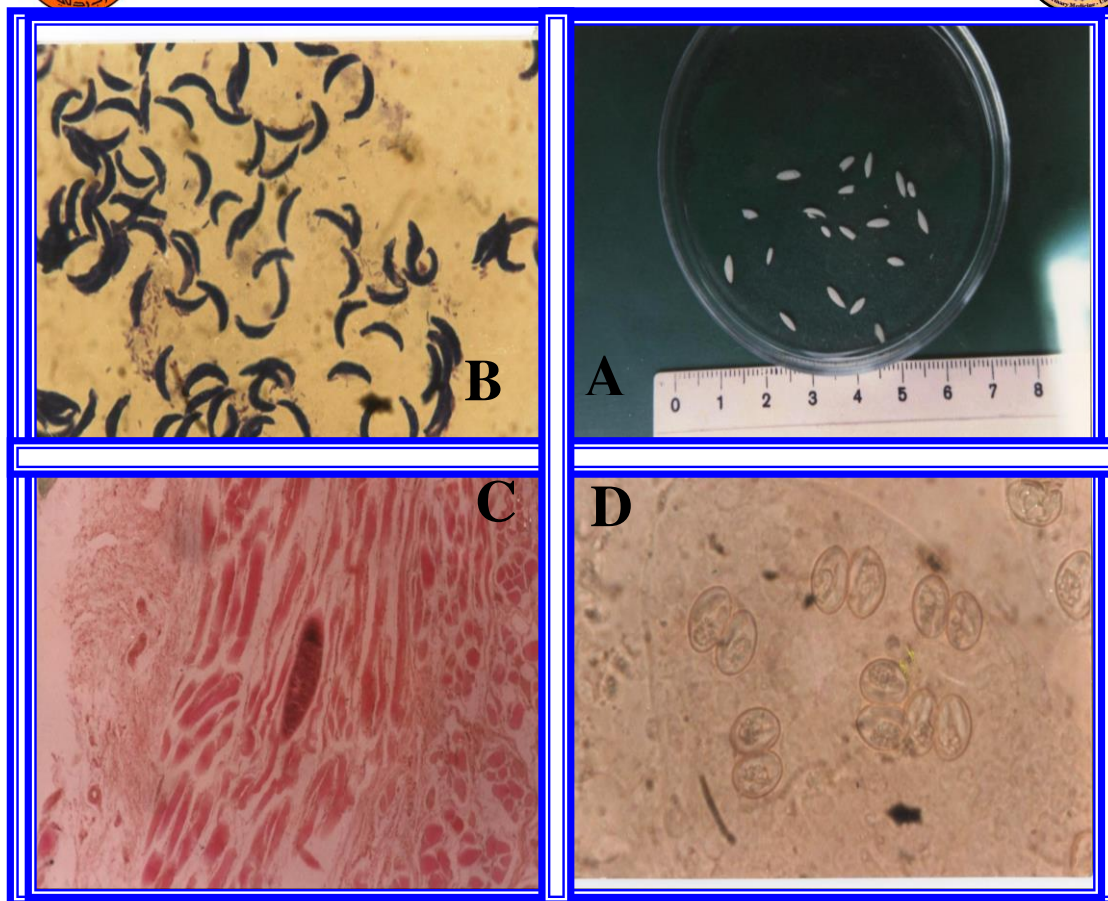


(Fig: 89) oocyst of *Cryptosporidium* by ziehl-Nielsen stain

(Fig: 90) oocyst of *Cryptosporidium* by iodine stain

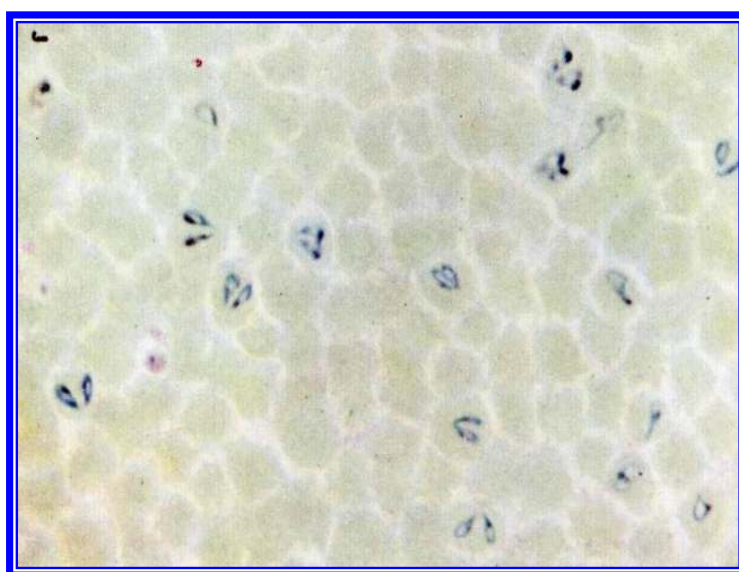


(Fig: 91) tissue cyst of *Toxoplasma gondii*

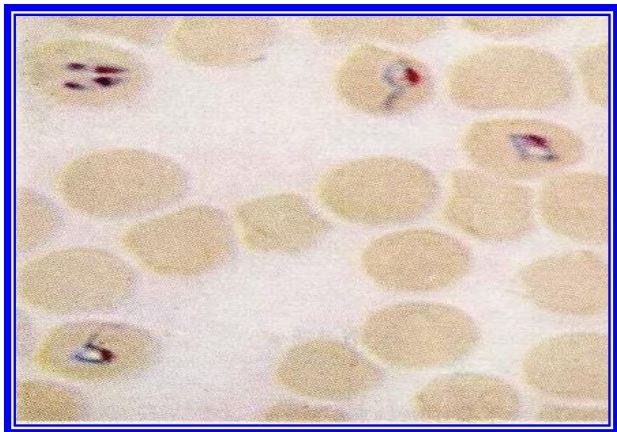


(Fig: 92)

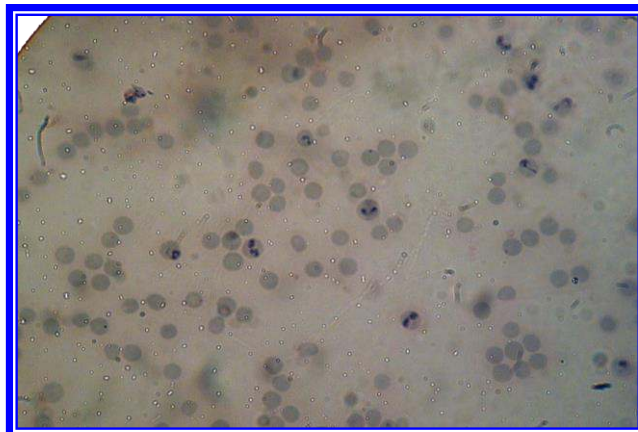
- A- Visible cyst of *Sarcocystis***
- B- Bradyzoite of *Sarcocystis***
- C- Microscopic cyst of *Sarcocystis***
- D- Oocysts of *Sarcocystis***



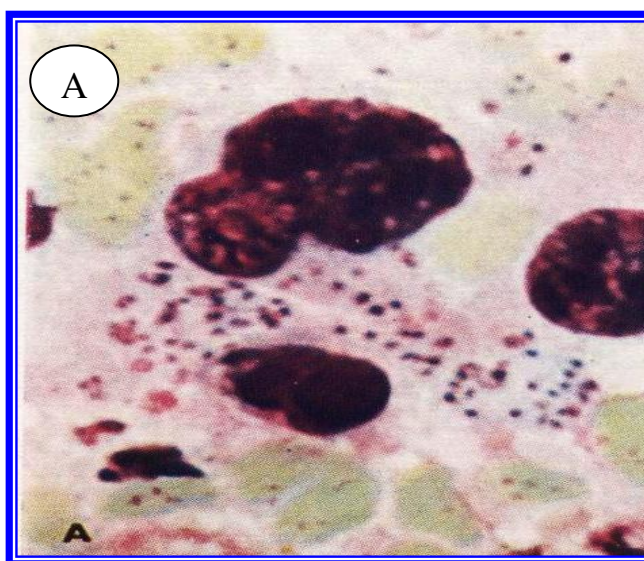
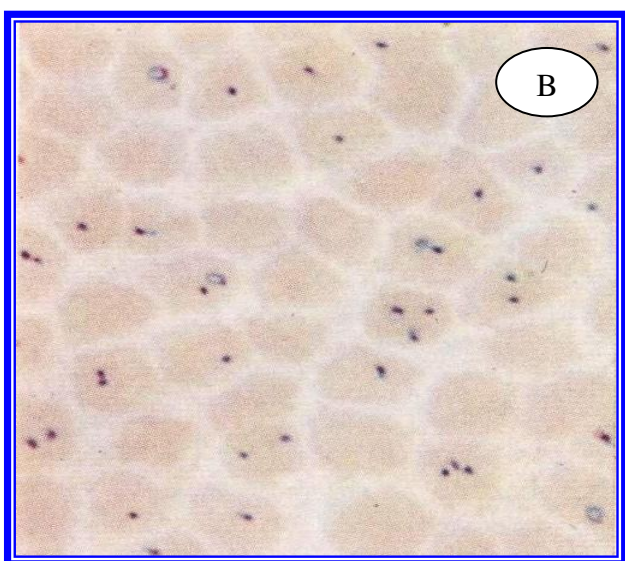
(Fig: 93) *B. bigemina*



(Fig: 95) *B. caballi*

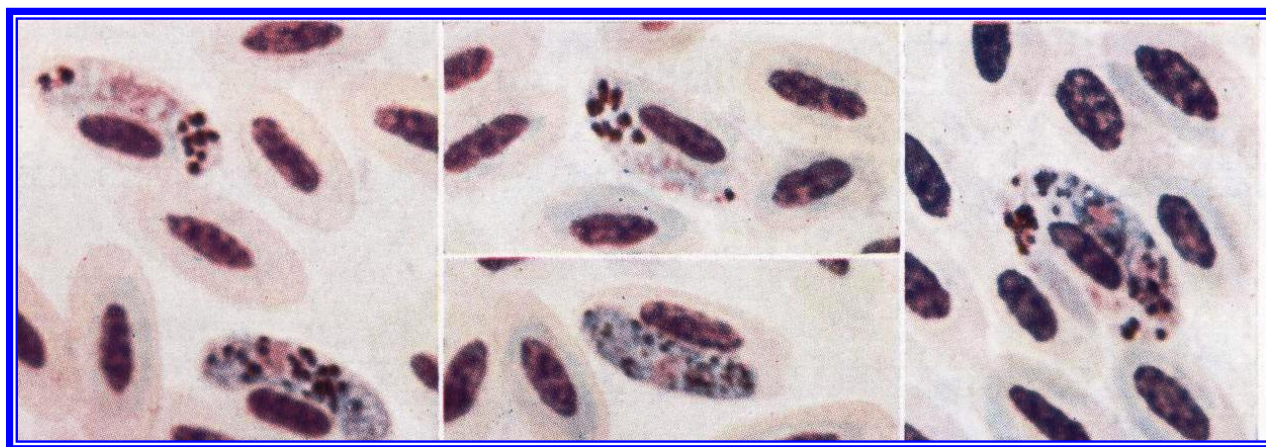


(Fig: 94) *B. motasi*

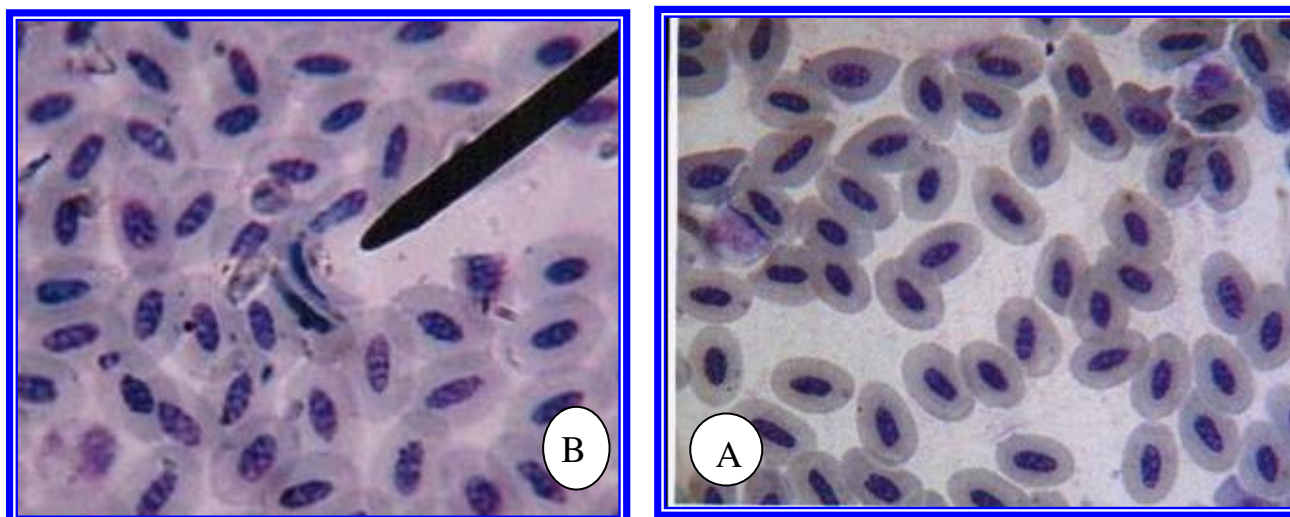


(Fig: 96) A- Koch's blue bodies .

B- *Th. Parva*

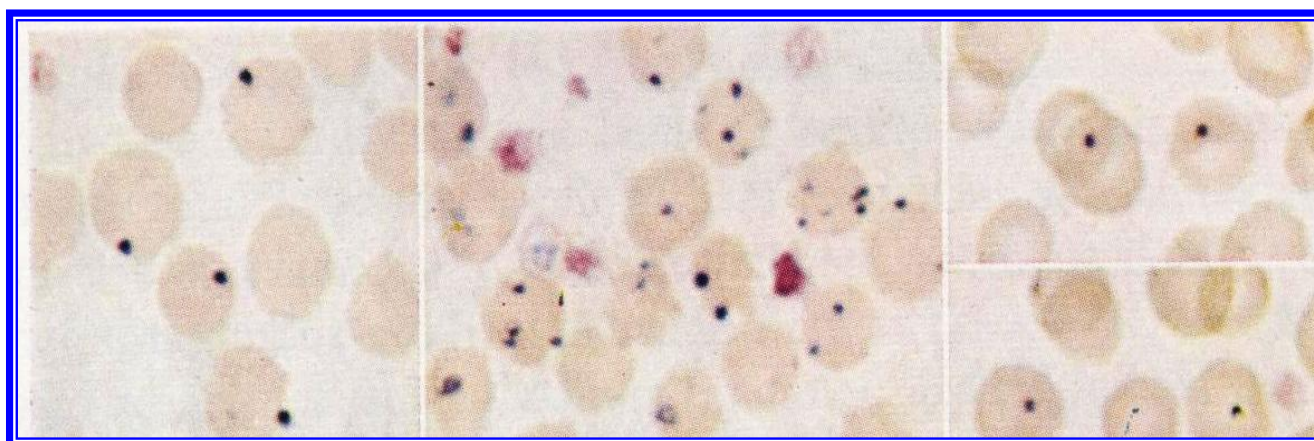


(Fig: 97) *Haemoproteus*



(Fig: 98) A- *Leucocytozoon*.round form

B- *Leucocytozoon* spindle form



(Fig: 99) *Anaplasma*



Phylum: Arthropoda

Class: Arachnida

Order: Acarina

Family: Argasidae

Genus: Argas (the fowl tick)

Spp: Argas persicus (soft tick) (Fig100)

The members of this family characterize by having skin like coat with no scutum, capitulum and mouth parts in nymphs and adult located on ventral surface of the body.

The members of this species called fowl ticks and its commonly distribute in highly and moderate temperate areas its attack chickens, pigeons, ducks and wild birds also could attack human.

Its oval in shape and the anterior part of the body more narrow than the posterior one, engorged female tick have red to blue in color due to the blood which it feed on, while non-engorged one have brown to yellow in color, also dark color of intestine could be seen.

There is a difficulty in recognition between males and females but could be distinguish by the shape of the genital opening which larger in female than male and its locate in anterior portion of the ventral surface in both sex.

Life cycle :

Eggs are laid by females in cracks of the walls of houses, 20-100 egg to each time, then it hatch to larvae with three pairs of legs feeding on host then moult to nymphs, there are two nymph instar feeding also on host moulting after this to adults.



Pathological effects of *Argas persicus* on host:

1. Anemia in case of heavy infestation.
2. sleeplessness, loss of productivity.
3. As a vector of *Borrelia anserina* and *Aegyptianella pullorum*.

Family : Ixodidae (Fig: 101)

1. The species of this family have a hard chitinous layer called scutum which running a long the dorsal aspect of males and only a little anterior part of females, nymphs and larvae.
2. Mouth parts located at the anterior portion of the body and it could be seen when we look it from the upper aspect.
3. When the eyes present, its lie on each side of the scutum and its two in number.
4. Adult have two stigmata found on each side of both fourth coxae.
5. Posterior margin of the tick body were notched so it called festoon.

Life cycle: (Fig:102)

Females put its eggs in hidden areas down of the stones and mud masses also cracks of the walls, eggs hatch to larvae, moulting to nymphs then to adults.

Genus: *Hyalomma* spp.

Properties of this genus:

1. Inornate or ornate some time.
2. Eyes present.
3. Festoons absent or present.
4. Hypostome and palps are long.
5. Spiracles comma shaped in males and triangular in females.



Genus: *Rhipicephalus* spp.

Properties of this genus:

1. Inornate ticks.
2. Eyes and festoons present.
3. Hypostome and palps are short.
4. Spiracles comma shaped , short in the female and long in the male.
5. Coxae 1 with two strong spurs .

Genus: *Boophilus* spp.

Properties of this genus:

1. Inornate ticks.
2. Eyes present and Festoons absent .
3. Hypostome and palps are short.
4. coxae 1 bifid .
5. Spiracles circular or oval.

Important of ticks:

1. Sucking blood.
2. Injuries done by their bites, which may predispose the hosts to attacks by blowflies, screw- worm flies and biting flies generally.
3. transmitting the viruses, rickettsiae (*Anaplasma*), bacteria and protozoa like *Babesia*, *Theileria* .
4. Ticks paralysis: this condition is caused by the injection of a (toxin) by the certain developmental stages of ticks, chiefly the adult female, but some time by the nymph as a *Dermacentor andersoni* .
5. There is a disease called sweating disease caused by ticks *Hyalomma transiens*.

Class :Arachnida



Family :Dermanyssidae

***Dermanyssus gallinae* (Fig: 103)**

1. Attacks the fowl, pigeon, canary and other cage birds and also many wild birds, it may also feed on man.
2. It is called the Red mite of poultry, only red when it has recently fed on its hosts blood, otherwise it is whitish, greyish or black.
3. The engorged female adult is about 1mm long.
4. The dorsal shield does not quite reach the posterior end of the body and its posterior margin is truncated.
5. The setae on it are smaller.
6. The anus is on the posterior half of the anal plates.
7. The chelicerae are long and whip like.

Life cycle:

The eggs are laid, usually after blood meal, in cracks in the walls of the poultry houses, up to seven eggs being laid at a time. The eggs hatch, at outdoor in 48-72 hours, liberating six legged larvae which do not feed. These moult in 24-48 hours to become protonymphs, which feed on the hosts blood and moult to become deutonymphs and these after a blood meal, moult in 24-48 hours to become the adults. The whole life cycle can be completed in seven days under optimal conditions.

Importance of this parasite:

The nymphs and adults causing:

1. Irritation and anemia.
2. Listless.
3. Reduce in egg production.



4. A vector of *Borrelia anserina* the cause of spirochaetosis of the fowl.

D. gallinae may occur as a temporary parasite on humans causing skin lesions.

Diagnosis :

The mites can be seen with the unaided eye, especially when they have fed recently on blood and are red.

Family :Sarcoptidae

Genus :Sarcoptes

S. scabiei (Fig: 104)

1. The cause of scabies (sarcoptic mange) of man, sheep, goats, cattle, pigs, equines, dogs and rabbits.
2. Species of this family burrow more deeply into the skin causing marked thickening rather than the formation of scabs.
3. The body of this mite is globose. The legs are short.

Importance of the parasite :

The predilection sites for the mites are areas such as the ears, muzzle, face and elbows but. irritation, itching, scratching, inflammation of the skin is accompanied by an exudate which coagulates and forms crusts, excessive keratinization and proliferation of connective tissue, result the skin becomes thickened wrinkled.



Family :Psoroptidae

Genus :Psoroptes (Fig: 105)

p. ovis : the body mite of sheep.

P.equi :the body mite of horse.

P.natalensis :body mite of cattle.

P. cuniculi :occurs in rabbit.

1. The cause of Psoroptic mange of the sheep, goats, cattle and equines.
2. The mites do not burrow into the skin, but are parasitic in its surface layers, causing the formation of thick, heavy scabs rather than thickening of the skin.
3. The body is oval.
4. There are no dorsal spines.
5. The legs are longer and project beyond the margin of the body.

Clinical signs :

scab lesion may occur on all parts of the body that are covered with wool or hair, but occur most frequently around the shoulders and along the sides of the body and back in woolled sheep.

In early lesions the wool is disturbed over the lesion by the biting and scratching of the sheep and usually has a lighter colour than the surrounding wool. From about the fifth day onwards the exudates begins to coagulate, forming pale yellow crusts, older lesions are easy to detect on account of the loss of wool and presence of scab.



Life cycle generally :

In female of *Sarcoptes* burrows into the skin to laid the eggs, but in the *Psoroptes* the eggs are laid on the skin at the edges of the lesion, these hatch to produce a six legged larvae and developed to the nymphs which have four pairs of legs, but no genital apertures. Finally, males and females are produced. Infection is spread mainly by contact by wandering larvae, nymphs and fertilized young females.

Diagnosis :

For confirmatory diagnosis, skin scrapings must be examined by use 10% KOH to clearing the skin scrap from debris and fatty materials.

Family : Demodicidae

Genus : Demodex (Fig: 106)

The mites live in the hair follicles and sebaceous glands of various mammals, causing demodectic or follicular mange. The parasites which occur on different species of hosts are usually regarded as distinct species, although it is difficult to distinguish between them morphologically , since the main difference is that of size. Most of the species are called after their hosts, for instance:

D .canis : occurs in dog.

D .ovis : occurs in sheep.

D .caprae:occurs in goat.

D .bovis : occurs in cattle.

D .folliculorum : occurs in man.



Chapter Six : Arthropoda



The parasite are elongate, they have a head, a thorax which bears four pairs of stumpy legs and elongate abdomen which is transversely striated on the dorsal and ventral surface. The mouth parts consist of paired palps and chelicerae and an unpaired hypostome. The eggs are spindle shaped .

Life cycle :

The life cycle is completed in the hair follicles or sebaceous glands. Eggs, larva, protonymph, deutonymph and adult. Infection is transmitted by direct contact.

Diagnosis :

The mites can be found in deep scrapings and in the contents of pustules and abscesses.



Class : Insecta
Order : Phthiraptera (lice)

1. Species of this order are small and wingless, have dorsoventrally flattened bodies.
2. The antennae are short and are composed of 3-5 segments.
3. The eyes are reduced or absent.
4. The segmentation of thorax is indistinct.
5. The tarsi consist of one or two segments and each tarsus bears one or two claws.
6. There is one pair of spiracles situated on the mesothorax and six pairs of abdominal spiracles.
7. The operculated eggs are cemented, without stalks to the hairs or feathers.
8. There is little or no metamorphosis (The phase of the life cycle history that leaves the eggs resembles the adult and is called the first nymph. There are three ecdyses) (eggs → nymph1 → nymph2 → nymph3 →) Uninfected hosts are infected by close contact with infected ones, but lice may also be spread by farm equipment.

The lice are divided into two suborder :

1. Anoplura (sucking lice) : living as ectoparasites on mammals.
2. Mallophaga (biting lice) : living as ectoparasites on mammals and birds.

Anoplura :

1. The mouth parts are adapted for sucking the tissue fluids and blood of the hosts.



2. The sizes of lice up to 5 mm with small pointed head and terminal mouth parts.
3. The two antennae are visible at the sides of the head and usually composed of 5 segments.
4. The thorax is small and its three segments are fused together.
5. the abdomen is relatively large with seven of its nine segments visible, the segment often bear at their sides dark brown areas of thickened chitin, called paratergal plates.
6. The eyes are reduced or absent.
7. The first pair of legs is usually smaller with weaker claws, the third pair of legs is usually the largest.
8. Each tarsus has only one claw.
9. Three families of veterinary importance, namely :

Family : Haematopinidae (Haematopinus), the short-nosed louse, largest louse on domestic mammals, example : *H. suis*. *H. asini*. (Fig: 107)

Family : Linognathidae (Linognathus) long-nose on cattle, sheep and goats. (Fig: 108)

Family : Pediculidae (Pediculus) human head and body lice.

Mallophaga :

1. The mouth parts are adapted for chewing.
2. Species of biting lice up to 3 mm.
3. The head is relatively much larger occupying the width of the body, and is rounded anteriorly with mouth parts are ventral.
4. The antennae may be lie in grooves in the sides of the head or are visible at the sides of the head.



Biting lice on mammals : example

Damalinia (*D. bovis*, *D. equi*, *D. ovis*) Fig(109)

Felicola on cats. (Fig: 110)

Biting lice on birds : example

Menacanthus stramineus (is the yellow body louse of poultry).(Fig: 111)

Order : Siphonaptera

Morphology :

1. Fleas are dark brown, wingless insects, with laterally compressed bodies .
2. Eyes when present are simply dark, photosensitive spots.
3. The antennae are short.
4. The third pair of legs is much longer than the others an adaptation for leaping .
5. The head may bear at its posterior (pronotal) or ventral (genal) borders rows of dark spines called ctenidia or combs (are the most important features used in identification.
6. Both sexes are blood suckers, and only the adult are parasitic.
7. The life cycle (eggs → larvae → puparium → adult)

Fleas on mammals :

Ctenocephalides : *C. canis*, *C. felis* (Fig: 112)

(having genal and pronotal comb)

Xenopsylla cheopis (no having combs) on man. (Fig: 113)



Order : Hemiptera

Family : Cimicidae

Genus : Cimex

Spp. : *C. lectularius* (Fig: 114)

1. The bed bugs attacks man and animals to suck blood.
2. The parasites elongate oval in shape and yellowish brown to dark in color.
3. The head bears a pair of long antennae with four joints.
4. The compound eyes project conspicuously at the sides of the head.
5. The prothoraxis large and deeply notched anteriorly where head is inserted in it.
6. The wings are vestigial.
7. The abdomen has eight segments.
8. The whole body is covered with characteristic spinose bristles and some hairs.
9. The tarsi have three joints.
10. The adult has a pair of ventral thoracic stink glands and the young stages have similar dorsal abdominal glands. These glands are responsible for characteristic odour of the insect. The mouth parts are adapted for piercing and sucking. There are five nymphal stages (eggs → nymph 1 → nymph 2 → nymph 3 → nymph 4 → nymph 5 → adult) .

Order: Diptera



Suborder : Nematocera

* The antennae are long and compose from more than 8 segments (Mosquitoes).

Family : Culicidae

* This family comprises the mosquitoes which are slender Nematocera with small, spherical heads and long legs.

* The antennae of 14-15 segments are conspicuous and plumose in the male.

Distinquishing characters of Anopheline and Culicine mosquitoes

Anopheline (Anopheles)	Culicine (Culex)
Eggs : Laid singly, boat shaped with paired lateral floats	Laid in rafts or singly, No floats
Larva : No siphon tube Palmate hairs on dorsal Surface of abdomen	Well-developed siphon tube No palmate hairs
Pupa : Breathing trumpets short and broad in lateral view.	The pupa has a rounded body which consists of head and thorax and an elongate abdomen. Breathing trumpets long and narrow in lateral view.
Adult : Female palps as long as proboscis(Fig: 115), male palps as long as proboscis clubbed scutellum evenly curved. (Fig: 116)	Female palps very short (Fig: 117)male palps as long as proboscis not clubbed scutellum tri-lobed. (Fig: 118)

* The antennae of both genus in females pilose while in males plumose.



The importance of mosquitoes :

1. Although mosquitoes can be a great nuisance and their bites may cause pain full reaction.
2. They are the intermediate hosts and vectors of several important parasitic and virus diseases of man and domestic animals, thus the definitive hosts of species of the protozoan.

Human Malaria → Plasmodium (Anopheles)

Bird Malaria → Plasmodium (Culex)

Anopheles → Intermediate host of Filariid Nematodes

Family : Simuliidae Fig(119)

- * The species of this family are often called black flies or buffalo gnats.
- * The thorax is humped over the head and the piercing proboscis is short, long antennae, which have 11 segments.

The wings are broad and they are not spotted

They have no scales and they are not hairy except for bristles on the thick anterior

- * The body is covered with short golden or silvery hairs.

Life cycle : (egg → larvae → pupa → adult)

1. The eggs are laid on stones or plants just below the surface of the water in running streams.
2. The larvae are cylindrical and attach themselves by a posterior sucker-like organ which is armed with small hooks, but they are able to move about. Anteriorly are the mouth parts and a pair of brush-like organs, the larvae are carnivorous, near the anterior extremity the ventral surface bears an arm-like appendage called the proleg which has a circlet of hooks at its free end, and the larva uses this when it moves about. Fig(120)



3. The larvae moult six times at the at the last moult the pupa appears, the mature larva spins a triangular cocoon on the surface to which it is attached and in the pupal stage is passed.
4. The pupa has one dorsal and one ventral respiratory tube, the branches of which float out of the cocoon then to the adult on the water surface the fly.

Medical Important of Simulium :

1. The simuliids occur in practically all parts of the world but are trouble some especially in warm countries.
2. The bite on the legs and abdomen or on the head and ears.
3. The bites give rise to vesicles, which burst or wart like papules.
4. Poultry are often attacked and may even become anemic from lose of blood.
5. Simulium spp. Transmits the viruses of Eastern equine encephalitis and vesicular stomatitis, and they also transmit various protozoa and nematodes in cattle (intermediate host) of the Filariid Nematode *Onchocerca gutturosa*, in poultry transmit *leucocytozoon* (Blood protozoa).



Suborder : Cyclorrhapha

Family : Oestridae

1. The adults are hairy flies which have rudimentary mouth parts and do not feed.
2. They usually lay their eggs on animals.
3. The larvae are parasitic maggots and consist of 12 segments, of which the first two are fused together. Oral hooks are usually present, but there is no head.
4. The posterior stigmata open through semicircular plates which may be retractile.
5. The larvae moult twice during their parasitic life and leave hosts when they are full grown to pupate in the ground. They feed on the body fluids of the host or on exudates which surround them.

Genus : Gasterophilus

Members of this genus are commonly referred to as "bot flies", their larvae termed bots, spend most of their time developing in the stomach of equines.

Hosts :

Horses and donkeys.

Major species : *G. intestinalis*

Adults :

Bot flies are robust dark flies 1-2 cm long, has irregular dark, transverse bands on the wings.



Larvae : (Fig:121)

When mature and present in the stomach or passed in the faeces these are cylindrical 16-20 mm long and reddish-orange with posterior spiracles two rows of spines dorsally and ventrally to at least 10th segments, spines blunt-tipped. The adults flies occur during the latter half of the summer and live only a few days.

G. intestinalis deposits its eggs mainly around the fetlocks of the fore-legs, also higher up the legs and in the scapular region the eggs hatch to larvae spontaneously or are stimulated to do so by warmth which may be generated during licking and self-grooming, larvae crawl into → mouth tongue → pharynx → oesophagus → stomach (where they attach to the gastric epithelium) → passed in the faeces → pupation takes place on the ground → adult.

Genus : Oestrus

O. ovis, the "sheep nasal fly" has a dark grey colour with small black spots which are especially prominent on the thorax and it is covered with light brown hairs. They occur from spring to autumn, particularly in summer. The larvae (Fig:122) occur in the nasal passages in sheep and rarely in goats, mature larvae are about 3.0 cm long, yellowish-white, tapering anteriorly with a prominent step posteriorly. Each segment has a dark transverse band dorsally. The females are viviparous and infect the sheep by squirting a jet of liquid containing larvae at the nostrils during flight up to 25 larvae being delivered at a time → 1st larvae migrate → nasal passages → frontal sinuses → L2 → L3 → migrate back to the nostrils → pupating on the ground → adults.



Genus : *Hypoderma*

The members of this genus are the "warble flies".

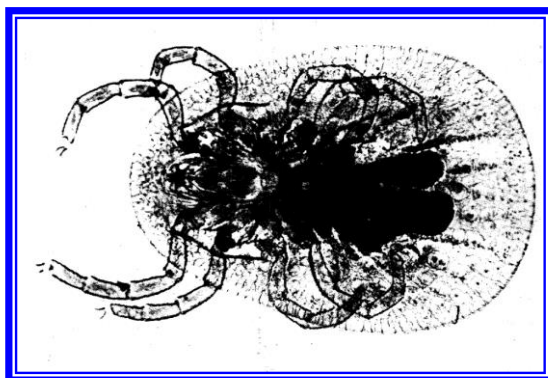
Hosts : Cattle, the larvae occur erratically in other animals including equines, sheep and very rarely, man.

Species : *Hypoderma bovis*, *H. lineatum*


Adults : *H. bovis*, *H. lineatum* resemble bees, but being Diptera, have only one pair of wings, the abdomen is covered with yellow-orange hairs with a broad band of black hairs around the middle.

Larvae (Fig:123) :

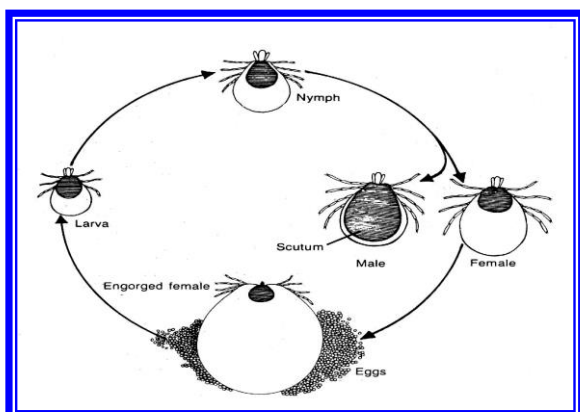
The mature larvae are thick and somewhat barrel-shaped, tapering anteriorly, when mature they are 2.5-3.0 cm long and some segments bear short spines. The color is dirty white when newly emerged from the host, but rapidly turns to dark brown, the pupa is almost black. The flies occur in summer, the female attach their eggs to hairs. *H. bovis* singly on the lower parts of the body and on the legs above the hocks, and *H. lineatum* in rows of six or more on individual hairs below the hocks, first stage larvae penetrate the hair follicles → diaphragm → *H. bovis* (epidural fat in the spinal canal), *H. lineatum* (submucosa of the oesophagus → 2nd larvae → black → L3 (which can be palpated as distinct swelling "warbles") , the larvae breathe by applying their spiracles to the aperture → after about 4-6 weeks in this site they emerge and fall to the ground where they pupate → adults.



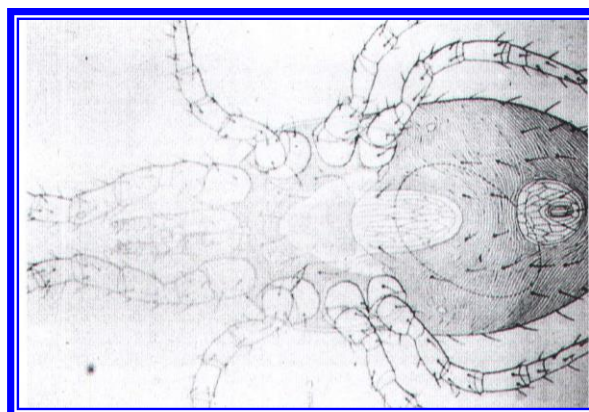
(Fig:100) *Argas persicus*



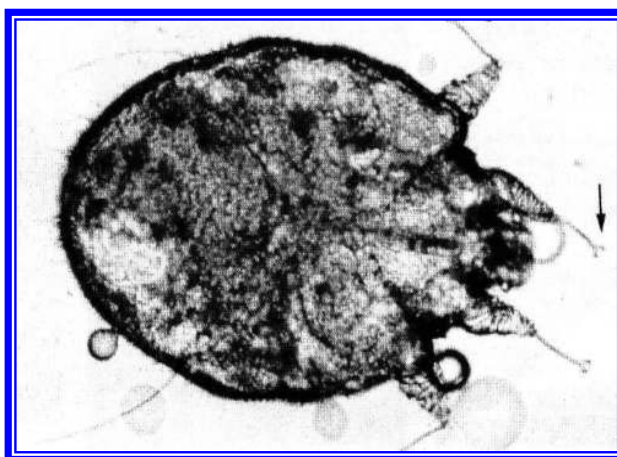
(Fig:101) Female , male and larvae of Tick



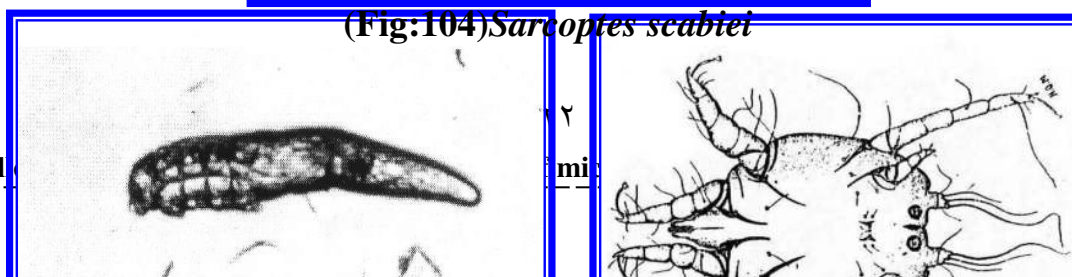
(Fig:102) Life cycle of Tick



(Fig:103) *Dermanyssus gallinae*



(Fig:104) *Sarcoptes scabiei*

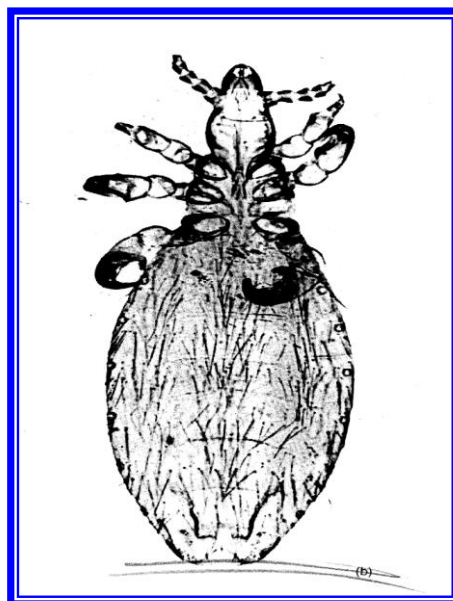





(Fig:106) *Demodex spp*




(Fig:105) *Psorptes*




(Fig:107) *Haematopinus*




(Fig:108) *Linognathus*

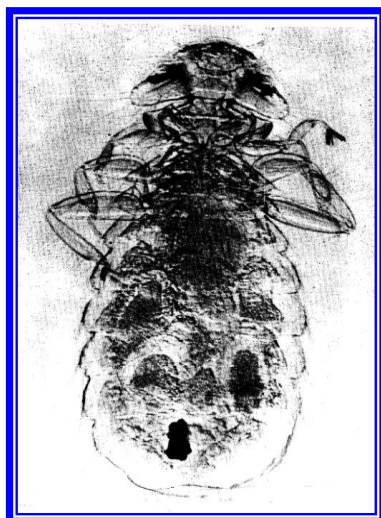


(Fig:110) *Felicola*

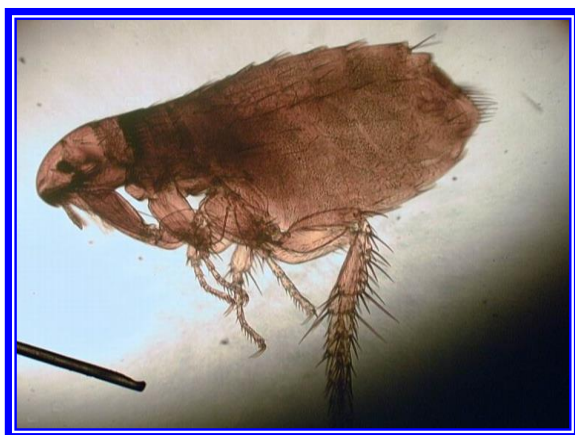

(Fig:109) *Damalinia*





(Fig:111) *Menacanthus*



(Fig:112) *Ctenocephalides canis*



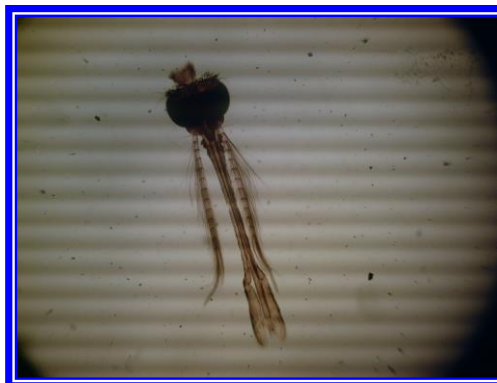(Fig:113) *Xenopsylla cheopis*



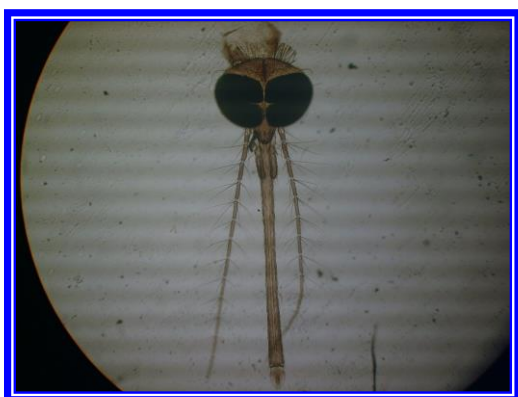
(Fig:114) *Cimex lectularis*



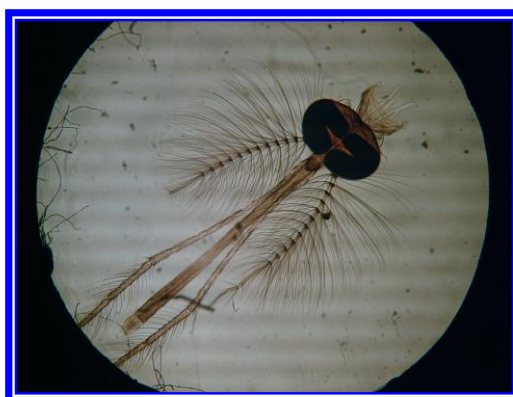
(Fig:115) Female of *Anopheles*



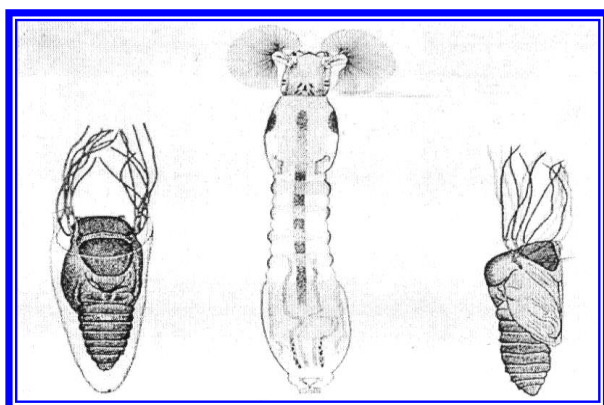
(Fig:116) male of *Anopheles*




(Fig:117) Female of *Culex*



(Fig:118) male of *Culex*



(Fig:120) Larvae of *Simulium* and pupa



(Fig:119) *Simulium* adult



**(Fig:121) larvae of
*Gastrophilus intestinalis***



**(Fig:122) larvae of
*Oestrus ovis***



(Fig:123) larvae of *Hypoderma bovis*



Reference :

- Charles M H. Laboratory Procedures for Veterinarians. .4th ed. Mosby. Elsevier.2000.
- Coles EH. Veterinary Clinical Pathology.4th ed. Sanders W.B. Company. Philadelphia.1986.
- Foreyt WJ. Veterinary Parasitology. Reference Manual.5th ed. Iowa State University Press.U.S.A.2001.
- Kassai T. Veterinary Helminthology.1st ed. Butter worth-Heinmann.1999.
- Luna G. Manual of Histological Staining Methods of Armed Forces Institute of Pathology.3rd ed. McGraw. Hill Book Company. New york.1968.
- Schmidt GD and Roberts LS. Foundation of Parasitology.6th ed. Sinapore.2000.
- Smyth JD. Introduction to Animal Parasitology.2nd ed. New York. United States of America.1976.
- Soulsby EJI. Helminthes, arthropods and protozoa of domesticated animals.7th ed.Philadelphia, lonodon.Bailliere.Tindal.1968.
- Urquhart GM, Armour J, Duncan JL, Dunn AM and Jennings FW. Veterinary Parasitology.2nd ed. Blackwell. Great Britain.1999.