

OphthoBook

Timothy Root, M.D.

**The funniest, cartooniest, most
high-yieldiest book about eye
diseases ever written ever!**

*"This has got to be the
most ridiculous medical
textbook that I've ever read!
Highly recommended!"*

- Chip Oester, M.D.



OphthoBook

www.OphthoBook.com

Written and Illustrated by
Timothy Root, M.D.

Be careful about reading health books. You may die of a misprint.

Mark Twain

Contents

Introduction	5
Chapter 1 - History and Physical	9
Chapter 2 - Basic Eye Anatomy	21
Chapter 3 - Glaucoma	33
Chapter 4 - Retina	47
Chapter 5 - Eye Infections	63
Chapter 6 - Neurology	77
Chapter 7 - Pediatrics	93
Chapter 8 - Trauma	107
Chapter 9 - Optics	117
Chapter 10 - Lens and Cataract	127
Review Questions	143
Videos	155
Appendix	159
A. RootAtlas.com	
B. Flashcards	
C. Reader Comments	
D. Crazy Ophtho Abbreviations	

Introduction



*The gentleman at the bar would like to buy you
either six drinks, or none at all.*

How this “book” came to be

Forward by Tim Root, M.D.

An Unconventional Path

There are traditional ways to write a book. For most people, this involves picking a topic, preparing a rough draft, and submitting a manuscript to publishers around the country. If you're lucky, you'll land a small contract. If you're extremely lucky, Oprah will read your novel and a succession of movies might occur, possibly starring Tom Hanks.

Medical books are a little different. The audience for textbooks is small, so medical books are published in small batches and sold at a premium price. Basic macro-economics tell us that this is the way to maximize profit. Supply and demand, baby!

But what if your goal ISN'T to make tons of money? What if your goal is to reach as many people in the world as possible and teach them about eye disease? That was the dilemma I faced as I finished the original manuscript for OphthoBook. The last thing I wanted was for a publisher to buy the rights to my work, sell a few hundred copies at inflated cost, and then let it go out of print. These “literary stillbirths” are every author's nightmare.

So I took a different path – one both easier and yet more challenging. I published this book on the internet as a free download. Instead of contracts, editors, and book signings, I had to learn website design, search engine optimization, and viral marketing!

Fortunately, this unconventional tactic worked. Over the past four years, approximately two-hundred thousand people have visited my little book's website, watched my video lectures, and downloaded the chapter pdf files. This is an impact orders of magnitude greater than I could have expected had I gone straight to print ... and best of all, it didn't cost anything, except a lot of time!

The mission

My goal with this project was to create the most informative, easy-to-read, and above all the “shortest” ophthalmology textbook ever written. Surprisingly, there aren't that many high-yield books like this in publication. Those other (yawn) inferior textbooks are the size of Webster's Dictionary and read like the Encyclopedia Britannica. Given the dominance of these classic texts, I had to ask myself early on, “is there even a need for a little eye book like mine?”

Fortunately, the positive response from my readers show that OphthoBook does fill a niche for a simple and power-packed ocular textbook that is small enough to fit in a jacket pocket.

Medical schools provide little or no ophthalmologic training in their core curriculum, and students need a concise review of ophthalmology that is approachable and fun to read. I've kept this text short for a reason – seriously, it's been hard to keep this book as brief as it is! I've been tempted many times to expand sections, add chapters, and delve into detail, but have curtailed this impulse. I've made great efforts to keep this book short and relevant for students and non-ophthalmologist. Simplicity is the book's main selling point.

Injections of Humor

To help you digest the material, I've added my own cartoons, quotes, and "fun facts" throughout the printed version. This irreverent approach is not meant to downplay eye disease or disrespect patients. Rather, this teaching method is meant to maintain your interest and help teach difficult ocular topics as quickly as possible. If these cartoons and jokes help another doctor better understand an eye problem, then ultimately they'll be better prepared to help their own patients.

When it comes down to it, this is the book I wish I'd read when I first started my own ophthalmology studies. The book's not perfect. In fact, it is a little silly, and every time I revise chapters I grimace at the poor grammar and spelling mistakes inflicted upon the world. Heck, some of the sections I find downright boring (and I wrote the darn thing)! Just keep chugging through, however, and I think you'll eventually find something worthwhile, or maybe a cartoon that makes you smile.

With that "self-handicapping" out of the way, let me just say preface this introduction with one last qualifier for those reading the "free" version of this book: You're getting what you paid for, so "eye" hope you enjoy it!



Tim Root





Timothy Root, M.D.

Chapter 1

History & Physical

The Eyes Have It

by Tim Root



History and Physical for the Non-Ophthalmologist

by Tim Root, M.D.

A thorough eye exam is important! Not only is the eye the most important organ in the body (of course!), but many common systemic diseases show ocular involvement. In fact, some conditions, like diabetes, may be first detected with the eye exam.

To help organize your eye exam, I've made a sample ophthalmology note on the facing page. Our clinic notes are difficult to interpret as our physical exam is long, specific, and requires many abbreviations to fit on a single page. In many ways, it's a combination of a neurology and a dermatology note. Here's a rundown of the basic ophthalmology note's components.

History of Present Illness:

As with all other specialties, a detailed ocular history is crucial to diagnosis. You should explore every complaint with the "basic questions" -- **when** did it start, **what's** it like, is there anything that makes it **better** or **worse**, are you taking any **medications** for relief, etc..

Specific HPI review of systems should also include these eye specific questions:

- **Floaters and flashing lights:** These are the classic symptoms of a retinal detachment and retinal tears, so ask EVERY patient about these symptoms. Most patients complain of some floaters - see if they're actually new or have worsened recently.
- **Transient vision loss:** Think of migraine vessel spasm in the young and micro-emboli in the elderly. Curtains of darkness might indicate an ischemic event or a retinal detachment, so explore these symptoms in detail.
- **Blurry vision:** Is the vision always blurry? Does it worsen when reading or watching TV? People blink less when watching TV and develop dry eyes. Is this a glare problem at night that might indicate cataracts? Is this a patient with poor glycemic control with resulting hyperosmotic swelling of their lens?
- **Red, painful eyes:** A common complaint. Be sure to ask about the nature of the pain (is this a scratchy pain, aching pain, or only pain with bright light). Is there discharge that might indicate an infection?
- **Chronic itching and tearing:** Think about allergies or blepharitis. Is it in both eyes?
- **Headaches and scalp tenderness:** Think of temporal (giant cell) arteritis and ask about other collaborating symptoms like jaw claudication, polymyalgias, weight loss, and night sweats.

Sample Ophthalmology Note

HPI:

Example: 80 y.o. WF with history of NPDR (non-proliferative diabetic retinopathy) presenting with "blurry vision" in the right eye for the past 3 days. She said she was cleaning in her house, and "might have gotten something in my eye" two days ago. Since then she complains of darkness/blurriness of vision and photophobia. Some watering but no discharge OD. No flashes, possibly? new floaters (denies scalp tenderness, jaw claudication, polymyalgias, weight loss, night sweats, headaches, or any other systemic complaints). There has been no vision change in her left eye.

PMH :

HTN, CAD, DM2
(on oral agents)
asthma/COPD

POH

CE od in 2002
DES (dry eye syn)

V_{cc} { 20/100 (PHNI)
20/20-1

P { 5 to 3 (brisk,
no apd ou)
5 to 3

Tap { 15
14

CF Full ou
EOMI ou

FH

-Grandmother with
glaucoma,
-no blindness
in family

SLE

EXT : wnl ou

L/L : mild meibominitis ou

C/S : 1+inj. od, wnl os

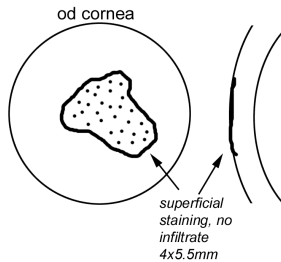
K : see drawing

A/C : deep and quite ou

Iris : flat, round, no NVI ou

Lens : PCIOL od, 2+ NSC os

Vit : PVD ou, no cells ou



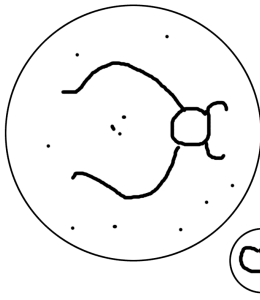
ALL

-PCN (rash)

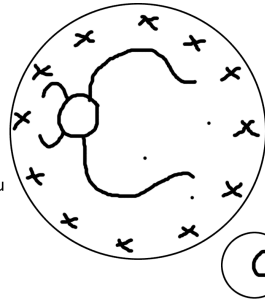
Meds

- ATs
- "BP meds"
- Coumadin

DFE



Macula: mild rpe atrophy OD
Vessels: arteriolar attenuation
and AV nicking ou, no NVE
Periphery: PRP os, few dot-blot
heme ou
Disk: CD ratio 0.3 ou, no NVD ou



A/P:

1. Corneal Abrasion - appears sterile with no infiltrate. Possibly caused by scratch during house cleaning, vs. recurrent erosion, exacerbated by some lid lag. Will treat with emycin qid and qhs and have pt. tape lid at night. Will see daily until defect healed to insure it does not become infected.
2. NPDR - stable. Cont. to follow yearly and consider fundus photos
3. Return to walk-in call clinic tomorrow
4. Pt. seen and discussed with attending

~ Dr. Legible (pager 666)

V_{cc} (vision with glasses), **PHNI** (pinhole no improvement), **P** (pupils) **Tap** (pressure with applanation), **CF** (confrontational fields), **EOMI** (extraocular movements intact), **SLE** (slit lamp exam), **EXT** (external), **L/L** (lids & lacrimation), **C/S** (conjunctiva and sclera), **K** (cornea), **A/C** (anterior chamber), **Vit** (vitreous), **DFE** (dilated fundus exam), **CE** (cataract extraction), **APD** (afferent pupillary defect), **LOL** (laugh out loud)

--- **OD** (right eye) **OS** (left eye) **OU** (both eyes) ----

The “Right Hand Column”

PMH (past medical history):

Past medical history should include the usual health questions, but with the main emphasis on conditions directly contributing to ocular pathology such as diabetes, hypertension, and coronary artery disease. Also, ask about thyroid problems and asthma (you might need to prescribe a beta-blocker and you don't want to set off bronchospasm).

POH (past ocular history):

Ocular history should inquire about past clinic visits and surgeries. Specifically ask about cataract surgeries, eye trauma, and glaucoma. You can often piece together your patient's ocular history by examining their eyedrops.

Family History:

Focus on history of glaucoma and blindness. Patients will often confuse glaucoma with cataracts, so be sure to ask.

Allergies:

List basic allergies and their reaction. Fortunately, there aren't many drug-drug interactions in our field. We sometimes give Diamox to control eye pressure so make sure your glaucoma patient isn't allergic to sulfa drugs.

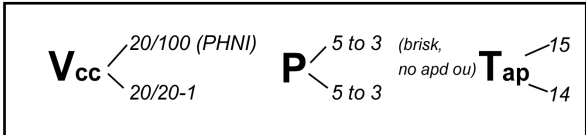
Medications:

Find out what eyedrops your patient is taking, and why. Are they using a regular eyedrop? How about vasoconstricting Visine? Did they bring their drops with them? If your patient can't remember their medications, it often helps to ask about the bottlecap-color of their drops (ex: all dilating drops have red caps). Also, it's nice to know if your patient is taking an oral beta-blocker already, in case you want to start a beta-blocking eyedrop (which usually have yellow caps).

PMH : HTN, CAD, DM2 (on oral agents) asthma/COPD
POH CE od in 2002 DES (dry eye syn)
FH -Grandmother with glaucoma, -no blindness in family
ALL -PCN (rash)
Meds - ATs - "BP meds" - Coumadin

Vision, Pupil, and Pressure ... oh my!

Vision, pupil, and pressure are the “vital



signs” of ophthalmology. After a brief history, I always check these measurements *before* dilating the eyes. This is because dilating drops will effect these measurements - the vision gets blurry, pupils enlarge, and eye pressure goes up. If you ever consult ophthalmology, we will always ask you ...

What's the vision, pupil, and pressure?

It's kind of a mantra. I don't know how many times during my training I've been asked to "get the vision, pupil, and pressure, then dilate them."

Visual Acuity:

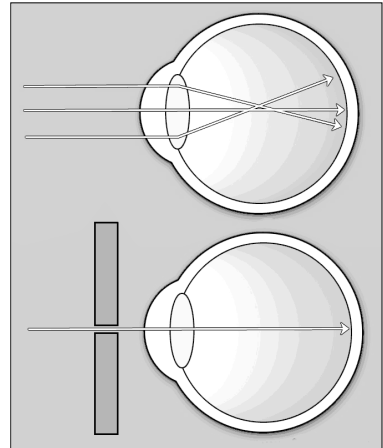
You measure visual acuity with a standard Snellen letter chart (the chart with the BIG E on it). If your patient can't read the E on the top line, see if they can count fingers at different distances. Failing this, try hand motion and light. Poor distance vision usually occurs from refractive error (your patient needs better glasses).



The only vision that matters is the "best corrected vision" so have your patients wear their glasses. You're going to be amazed at the number of people complaining of "blurry vision" who leave their glasses in their car. You'll also be impressed by the number of consults you'll get where the consulting doctor hasn't bothered to check the patient's vision. Remember: "I can't see!" is a relative complaint – for some this means 20/25 vision and for others this means complete darkness.

Das Pinhole!

A quick and easy way to determine whether refraction is the culprit, short of actually testing different lenses, is with the pinhole test. Punch a small hole in a paper card, and have your patient reread the eye-chart while looking through this pinhole. This technique can actually improve vision by several diopters. It works because the paper blocks most of the misaligned rays that cause visual blur, and allows the central rays to focus on the retina. If your patient shows no improvement with **pinholing**, start thinking about other visual impediments like cataracts or retinal problems. Most occluders (the black plastic eye cover used during vision testing) have a fold-down pinhole device for this purpose.



Near Vision

Near vision can be assessed with a near-card or by having your patient read small print in a newspaper. Don't try using the near-card to estimate distance acuity as distance vision is quite different than close-up acuity. That 20/20 marking printed on the near-card only checks "accommodated" near-vision. Remember that older patients can't accommodate well and need a plus-power lens (reading glasses) to help them read the card. Carry a +2.50 lens with you when seeing older inpatients as most of these patients leave their reading glasses at home. We'll cover accommodation and presbyopia in greater detail later in the optics chapter.

Pupils:

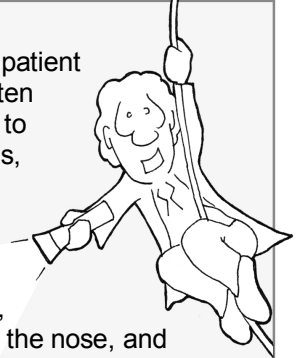
The pupils should be equally round and symmetric with each other. You can test reactivity to light with a penlight, but a brighter light like the one on the indirect ophthalmoscope will work much better. When testing the eyes, you will see a **direct** constriction response in the illuminated eye, and a **consensual** response in the other eye. These should be equal and synchronous with each other. Also, check the pupils with near-vision, as they should constrict with accommodation.

Are you a swinger?

If one eye is injured, or not sensing light, then your patient may have an APD or “afferent pupillary defect.” Often these defects are only partial, making them difficult to detect on casual examination. To detect small APDs, you need to perform the “**Swinging Light Test.**” Here’s how it works:

When you shine a light back and forth between two normal eyes, you’ll find that the pupils constrict, then dilate a fraction as the light beam passes over the nose, and then constrict again. As you go back and forth you’ll see constriction, constriction, and constriction.

Things look different if one eye is partially blind. As before, when you shine the light in the good eye there is constriction. But, when you cross to the other bad eye, both eyes seem to *dilate* a little. The bad eye still senses light and constricts, but not as well. So you see constriction, dilation, constriction, and dilation. This phenomenon is also called a **Marcus Gunn pupil.**



Pressure:

We measure pressure by determining how much force it takes to flatten a predetermined area of the corneal surface. There are several ways to do this and in the eye clinic we use the “Goldman Applanation Tonometer” that is attached to the slit-lamp microscope.

When visiting bedside patients in the hospital, or with patients who are difficult to examine, we can check pressure using a handheld electronic Tono-pen. This little device can be tricky and in the wrong hands becomes a random-numbers generator. I’ll talk more about pressure and its importance within the glaucoma chapter.

Confrontational Fields:

All patients should have their visual fields (peripheral vision) checked. A patient may have great central vision, with perfect eye-chart scores, but suffer from “tunnel vision” resulting from neurological diseases or glaucoma.

Your patient may not even be aware of this peripheral visual loss if it has progressed slowly over time.

Confrontational fields are easy to perform but keeping your patient from “cheating” may be tougher. Have your patient cover one eye, and tell them to look straight at your nose. While fixating on your nose, have them count your fingers as you flash them in different quadrants. Be sure to cover your own eye and hold your hands equidistant between you and the patient. This gives you a better idea of what your patient ought to be able to visualize. If you can see your fingers, your patient should be able to see them as well.

EOMs (extraocular movements):

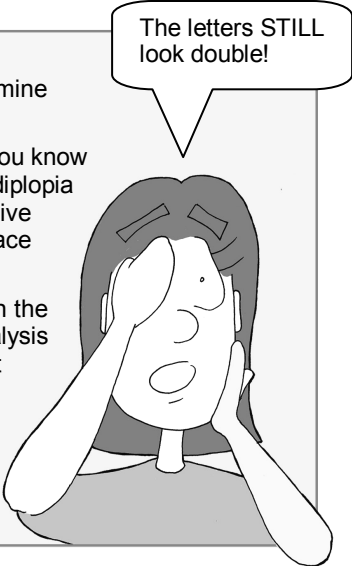
Check extraocular movements by having your patient follow your fingers into all quadrants. If the patient has decreased mobility in an eye from nerve paralysis or muscle entrapment, you may notice this from casual inspection or by more sophisticated cover/uncover testing.

Seeing Double?

When evaluating double vision, you must first determine whether the doubling is *monocular* or *binocular*.

If, after covering an eye, the vision stays doubled, you know you’re dealing with monocular diplopia. Monocular diplopia isn’t a neurological problem, but likely from a refractive error such as astigmatism, cataract, or corneal surface wrinkling.

Binocular diplopia indicates a misalignment between the eyes ... and this is likely due to neuromuscular paralysis or muscle entrapment (if after trauma). To tease out what muscle groups and nerves are involved, you should determine what gaze direction improves and worsens the doubling. We’ll discuss cranial nerve palsies in greater detail in the neuro chapter.



The letters **STILL** look double!

The Slit-Lamp Exam:

It takes several months to become proficient at using the slit-lamp microscope. A lot of eye pathology can be found under the microscope and it’s easy to miss crucial findings. This makes it important to keep yourself organized and describe your findings in the same order with every patient, starting from the outer eyelids and working your way to the back of the eye. Here’s how we do it:

SLE

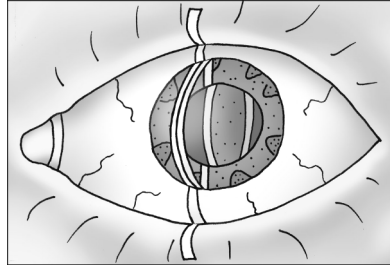
EXT : wnl ou
L/L : mild meibominitis ou
C/S : 1+inj. od, wnl os
K : see drawing
A/C : deep and quite ou
Iris : flat, round, no NVI ou
Lens : PCIOL od, 2+ NSC os
Vit : PVD ou, no cells ou

External Exam (EXT):

With the external exam, make sure the eyes look symmetric and that the patient doesn't exhibit ptosis (drooping of the eye) or proptosis (extruding eyes or "bug-eyes"). If the patient has a conjunctivitis, check for swelling of the pre-auricular nodes (in front of the ear) and the sub-mandibular/mental nodes. This nodal swelling points toward a viral etiology.

Lids and lacrimation (L/L):

Always look at the lid margin and lashes for signs of blepharitis (eyelid inflammation). Evert the lids to look for follicles or papillary bumps on the inside of the lids that might indicate infection or irritation.



Conjunctiva and Sclera (C/S):

Check to make sure the sclera is white and non-icteric, and the conjunctival blood vessels aren't injected (red and inflamed). If they are injected, see if the blood vessels blanch when you dilate the patient with phenylephrine.

Cornea (K):

The cornea is the clear window at the front of the eye. Its optical clarity relies upon a smooth tear-air interface. Look at the corneal surface for erosions and abrasions that might indicate drying or trauma. Does the middle stroma look clear? Look at the back endothelial surface for folds or guttata bumps. Fluorescein dye will make surface abrasions easier to spot.

Anterior Chamber (AC):


Look for cell and flare, which could indicate inflammation or intraocular bleeding. Individual cells are hard to see - you need to turn the lights down and shoot a "ray of light" into the eye. If you think of your microscope slit-beam like the projector beam at a movie theater, then individual "cells" will look like dust flecks while "protein flare" is diffuse and looks like smoke floating in the aqueous. Also, comment if the anterior chamber is deep and well-formed, or shallow and thus a setup for angle-closure glaucoma.

Iris (I):

Make sure the iris looks flat and the pupil round. If your patient has diabetes you should comment whether you see any signs of abnormal neovascularization of the iris.

Lens (L):

Is the lens clear, or hazy with cataract? Are they phakic (they have their own lens), pseudophakic (prosthetic lens), or aphakic (no lens at all)?



Vitreous (V):

Looking behind the lens you can see the dark vitreous cavity that makes up the greatest volume of the eye. If you suspect a retinal hemorrhage or detachment, you may see blood cells floating here.

Retina Exam:

The retina is the only place in the body where you can directly visualize blood vessels and nerves without overlying skin blocking your view. In our notes we typically comment on four retinal findings:

1. **Macula** – Does it look flat? Is there a good light reflex off the surface?
2. **Vessels** – Any signs of AV nicking? Attenuation of the arterioles?
3. **Periphery** – Does it look flat? Any tears or holes?
4. **Disk** – What's the cup-to-disk ratio? Does it look pink and healthy?

It's not easy to examine the retina, especially if your patient doesn't dilate well. You're probably going to be terrible at the retina exam during your first few months, but do your best. There are several methods we use to view the retina:

The Direct Ophthalmoscope

For non-ophthalmologists the most common way to examine the fundus is with the direct ophthalmoscope. This hand-held device is not easy to use, especially in an undilated eye. The key to success with this instrument is to get yourself as CLOSE to the patient as possible. Get really close! Dilating the eye also helps.

Exam Technique


Using that darn direct scope

Switch the light to the highest setting, and rotate the beam to the medium-sized round light. I set my focus ring to "0," but you may need to adjust this to compensate for your own refractive error. Place your hand on your patient's shoulder or head.

Starting far away, find your patient's red-reflex and follow that reflection in as you close in to the eye. Be sure to switch eyes so that you don't end up face-to-face with the patient (unless they are extremely attractive and you remembered to brush your teeth. Just kidding).

It may take you a while to visualize the fundus with the direct scope, especially in undilated eyes, because the field-of-view you get is very small, making it hard to even recognize what you are seeing.

I find it easiest to find a blood vessel and then follow this vessel back to its origin at the optic disk. Inspect the disk margins and the size of the disk cupping. You may be able to pick up AV nicking from high blood pressure and retinal damage in the form of dot-blot spots or flame hemorrhages.



So do you come here often?

At the slit-lamp

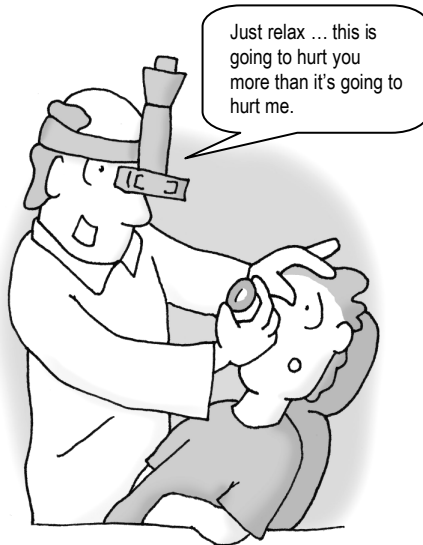
The best way to look at the posterior fundus in magnified detail is with a handheld lens at the slit-lamp. This is how we look at the optic nerve and macula in the clinic, but it takes practice. We use smaller, more powerful lenses such as a 90-diopter lens.

The Indirect Ophthalmoscope

This is how we look at the peripheral retina in the ophtho clinic. The eye needs to be dilated to get a good image, but the field of view is excellent. We use a headlamp and a larger, 20-diopter lens for this.

Other Tests Specific to Ophthalmology:

There are many other exam techniques specific to ophthalmology such as gonioscopy and angiography that you probably won't be exposed to unless you go into the field. I'll cover these topics in later chapters as they become relevant.



Pimp Questions

1. What are the three “vital signs of ophthalmology” that you measure with every patient?

Vision, pupil, and pressure. Some ophthalmologists might say there are five vital signs (adding extraocular movements and confrontational fields.) It's important to check these signs prior to dilation as dilating drops will affect these measurements.

2. What is a Marcus Gunn pupil?

This is simply an APD (afferent pupillary defect). These usually occur with optic nerve/tract lesions or infarcts.

3. How do you perform the swinging light test?

You shine a light back and forth between the pupils. You should see “constriction-constriction-constriction-constriction” as you flip-flop between the eyes. If you see constriction-dilation-constriction-dilation, then something's wrong (you've discovered an APD).

4. What is “pinholing” a patient?

This is the use of a pinhole to decrease the effects of refractive errors causing visual blurring. When patients significantly improve with the pinhole, they probably need an updated glasses prescription.

5. When presented with a complaint of “double vision” what is the first thing you should determine?

Whether the doubling is binocular or monocular, as this distinction will completely change your differential. Monocular diplopia is a refractive error while binocular diplopia is a misalignment between the eyes (and a major headache to figure out the cause – see the neuro chapter).

6. What is cell and flare?

These are descriptive terms to describe inflammation in the anterior chamber. Flare is protein floating in the aqueous that looks like a projector beam running through a smoky room. Cells are individual cells that look like dust-specks floating through that same projector beam of light.

7. You are thinking of starting eyedrops to control the eye pressure in a newly diagnosed glaucoma patient. What medical conditions might you ask about before initiating therapy?

Eyedrops can create pretty impressive systemic side effects as they bypass liver metabolism and are absorbed directly through the nasal mucosa. Be sure to ask your patients about heart problems and asthma before starting a beta-blocker.

8. List the eight structures/areas that we check on the slit-lamp exam.

The slit-lamp exam can be intimidating for the novice student, as there are many structures within the eye that we document within our notes. Working our way from the front to the back of the eyeball, these include:

EXT	(external structures)
LL	(lids and lacrimation)
CS	(conjunctiva and sclera)
K	(cornea)
AC	(anterior chamber)
I	(iris)
L	(lens)
V	(vitreous)

You may want to check out the first video, “History and Physical” at Ophthobook.com – in the last half of the lecture I show real slit-lamp microscopy videos and work my way through these slit-lamp findings.

9. Name the four structures we describe in the retina.

The four structures we examine are:

M	(macula)
V	(vessels)
P	(periphery)
D	(disk)

I use the mnemonic/acronym “MVP” (Most Valuable Player) to help me remember these.

10. What is accommodation?

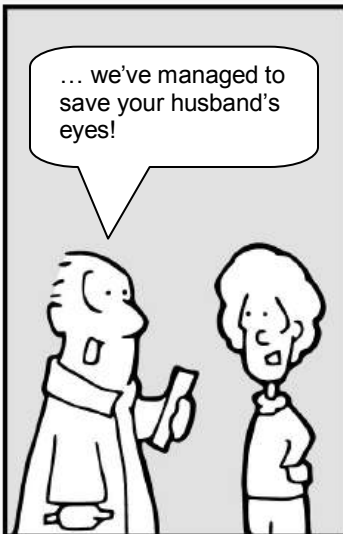
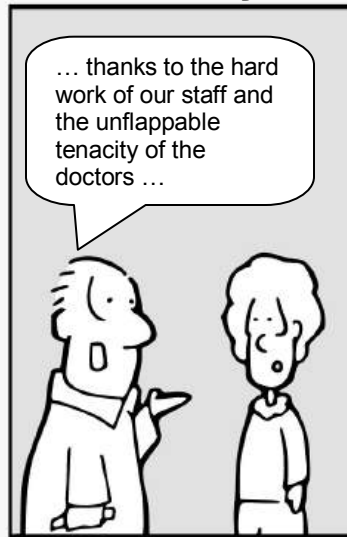
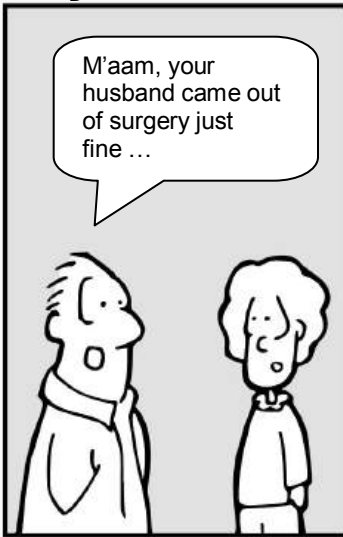This is when the lens changes shape, allowing the eye to focus on near-objects. With age, the lens hardens and we gradually lose our ability to accommodate. We’ll cover this topic in the optics chapter, but I wanted to bring it up in order to emphasize the need for checking both near and far vision during your exam.

Chapter 2

Eye Anatomy

The Eyes Have It

by Tim Root



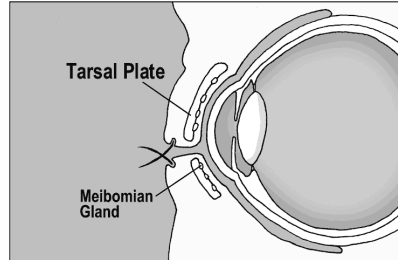
Basic Eye Anatomy

by Tim Root, M.D.

Before discussing conditions affecting the eye, we need to review some basic eye anatomy. Anatomy can be a painful subject for some (personally, I hated anatomy in medical school), so I'm going to keep this simple. Let us start from the outside and work our way toward the back of the eye.

Eyelids

The eyelids protect and help lubricate the eyes. The eyelid skin itself is very thin, containing no subcutaneous fat, and is supported by a **tarsal plate**. This tarsal plate is a fibrous layer that gives the lids shape, strength, and a place for muscles to attach.



Underneath and within the tarsal plate lie **meibomian glands**. These glands secrete oil into the tear film that keeps the tears from evaporating too quickly. Meibomian glands may become inflamed and swell into a granulomatous **chalazion** that needs to be excised. Don't confuse a chalazion with a sty. A **stye** is a pimple-like infection of a sebaceous gland or eyelash follicle, similar to a pimple, and is superficial to the tarsal plate. Styes are painful, while deeper chalazions are not.

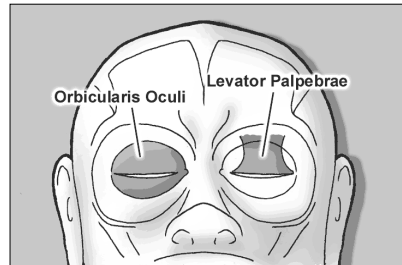
Famous Quotes

You can't depend on your eyes when your imagination is out of focus.

Mark Twain

Eyelid Movement

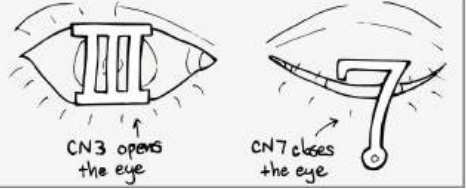
Two muscles are responsible for eyelid movement. The **orbicularis oculi** closes the eyelids and is innervated by cranial nerve 7. Patients with a facial nerve paralysis, such as with Bell's Palsy, can't close their eye and their eyelids may need to be patched (or sutured closed) to protect the cornea from exposure. The **levator palpebrae** opens the eye and is innervated by CN3. Oculomotor nerve (CN3) palsy is a major cause of ptosis



(drooping of the eye). In fact, a common surgical treatment for ptosis involves shortening the levator tendon to open up the eye.

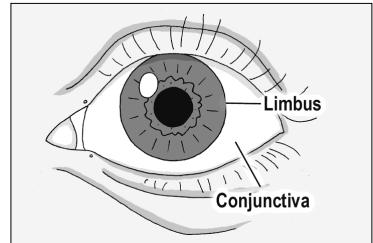
Mnemonic

CN 3 opens the eye like a pillar
CN 7 closes like a fish-hook



Conjunctiva

The conjunctiva is a mucus membrane that covers the front of the eyeball. When you examine the “white part” of a patient’s eyes, you’re actually looking through the semi-transparent conjunctiva to the white sclera of the eyeball underneath. The conjunctiva starts at the edge of the cornea (this location is called the **limbus**). It then flows back behind the eye, loops forward, and forms the inside surface of the eyelids. The continuity of this conjunctiva is important, as it keeps objects like eyelashes and your contact lens from sliding back behind your eyeball. The conjunctiva is also lax enough to allow your eyes to move freely. When people get conjunctivitis, or “pink eye,” this is the tissue layer affected.

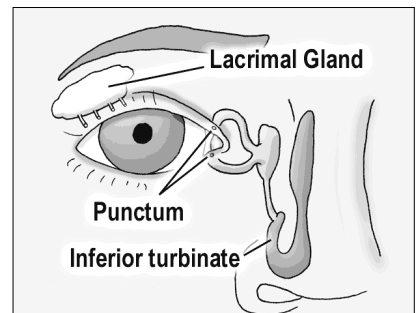


Fun Fact

There is a thickened fold of conjunctiva called the semilunar fold that is located at the medial canthus ... it is a homolog of the nictitating membrane seen on sharks.

Tear Production and Drainage

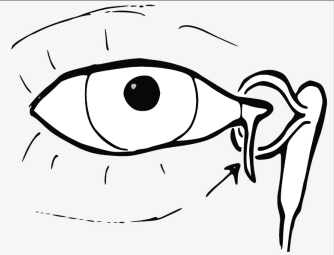
The majority of tears are produced by accessory tear glands located within the eyelid and conjunctiva. The lacrimal gland itself is really only responsible for reflexive tearing. Tears flow down the front of the eye and drain out small pores, called **lacrimal punctum**, which arise on the medial lids. These punctual holes are small, but can be seen with the naked eye.



After entering the puncta, tears flow down the lacrimal tubing and eventually drain into the nose at the inferior turbinate. This drainage pathway explains why you get a runny nose when you cry. In 2-5% of newborns, the drainage valve within the nose isn't patent at birth, leading to excessive tearing. Fortunately, this often resolves on its own, but sometimes we need to force open the nasolacrimal duct with a metal probe.

Eyelid Lacerations

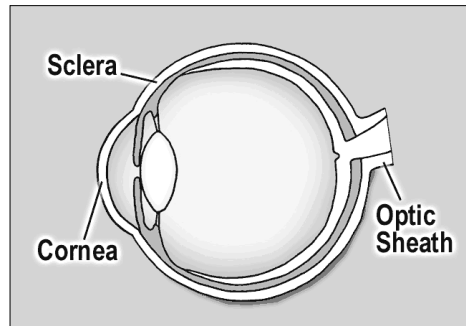
Most lacerations through the eyelid can be easily reapproximated and repaired. However, if a laceration occurs in the nasal quadrant of the lid you have to worry about compromising the canalicular tear-drainage pathway. Canalicular lacerations require cannulation with a silicone tube to maintain patency until the tissue has healed.



Warning: Drug absorption through the nasal mucosa can be profound as this is a direct route to the circulatory system and entirely skips liver metabolism. Eyedrops meant for local effect, such as beta-blockers, can have impressive systemic side effects when absorbed through the nose. Patients can decrease nasal drainage by squeezing the medial canthus after putting in eyedrops. They should also close their eyes for a few minutes afterwards because blinking acts as a tear pumping mechanism.

The Eyeball:

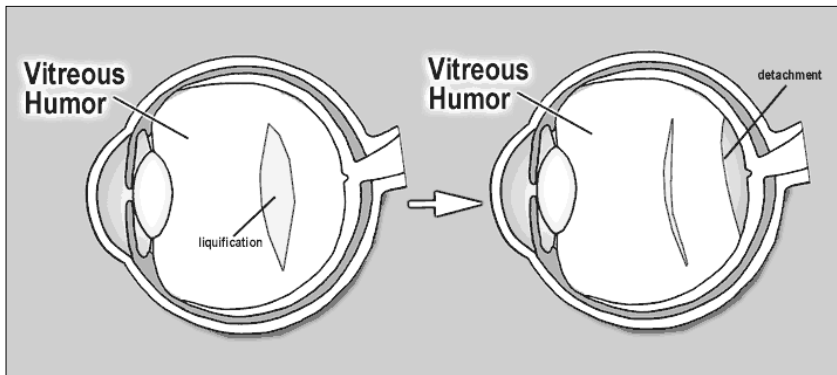
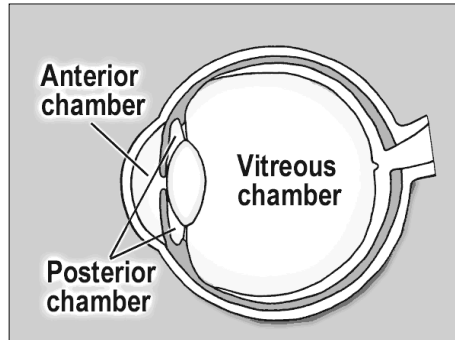
The eyeball itself is an amazing structure. It is only one inch in diameter, roughly the size of a ping-pong ball, and is a direct extension of the brain. The optic nerve is the only nerve in the body that we can actually see (using our ophthalmoscope) *in vivo*.



The outer wall of the eye is called the **sclera**. The sclera is white, fibrous, composed of collagen, and is actually continuous with the clear cornea anteriorly. In fact, you can think of the cornea as an extension of the sclera as they look similar under the microscope. The cornea is clear, however, because it is relatively dehydrated. At the back of the eye, the sclera forms the optic sheath encircling the optic nerve.

The eyeball is divided into three chambers, not two as you might expect. The **anterior chamber** lies between the cornea and the iris, the **posterior chamber** between the iris and the lens, and the **vitreous chamber** extends from the lens back to the retina.

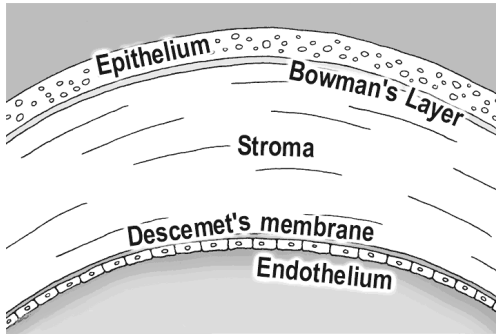
The eye is also filled with two different fluids. **Vitreous humor** fills the back vitreous chamber. It is a gel-suspension with a consistency similar to Jell-O. With age and certain degenerative conditions, areas of the vitreous can liquefy. When this occurs, the vitreous can fall in upon itself – usually a harmless event called a PVD (posterior vitreous detachment). However, this normally benign vitreous detachment can sometimes tug on the retina and create small retinal tears.



Aqueous humor fills the anterior and posterior chambers. This is a watery solution with a high nutrient component that supports the avascular cornea and lens. Aqueous is continuously produced in the posterior chamber, flowing forward through the pupil into the anterior chamber, where it drains back into the venous circulation via the Canal of Schlemm. We'll discuss the aqueous pathway in greater detail in the glaucoma chapter.

The Cornea:

The **cornea** is the clear front surface of the eye. The cornea-air interface actually provides the majority of the eye's refractive power. The cornea is avascular and gets its nutrition from tears on the outside, aqueous fluid on the inside, and from blood vessels located at the peripheral limbus.



On cross section, the cornea contains five distinct layers. The outside surface layer is composed of epithelial cells that are easily abraded. Though epithelial injuries are painful, this layer heals quickly and typically does not scar. Under this lies Bowman's layer and then the stroma. The corneal stroma makes up 90% of the corneal thickness, and if the stroma is damaged this can lead to scar formation. The next layer is Descemet's membrane, which is really the basal lamina of the endothelium, the final inner layer.

The inner endothelium is only one cell layer thick and works as a pump to keep the cornea dehydrated. If the endothelium becomes damaged (during surgery or by degenerative diseases) aqueous fluid can flow unhindered into the stroma and cloud up the cornea with edema. Endothelial cell count is very important as these cells don't regenerate when destroyed – the surviving endothelial cells just get bigger and spread out. If the cell count gets too low, the endothelial pump can't keep up and the cornea swells with water, possibly necessitating a corneal transplant to regain vision.

Mnemonic

To help you remember the corneal layers, you might use this trick:

Decemet's membrane is **D**eep while
Bowman's layer is high up in the **B**ell tower

The Uvea:

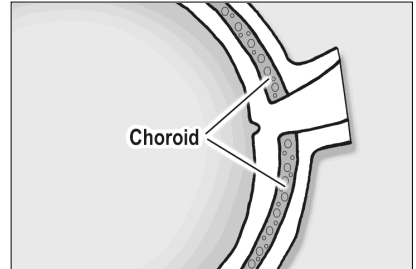
The iris, ciliary body, and the choroid plexus are all continuous with each other and are collectively called the **uvea**. This is an important term, as many people can present with painful "uveitis" - spontaneously or in association with rheumatologic diseases.

The **iris** is the colored part of the eye and its primary function is to control the amount of light hitting the retina. Sympathetic stimulation of the pupil leads to pupil dilation and parasympathetic stimulation leads to constriction. In other words, if you see a bear in the woods, your sympathetics kick in, and your eyes dilate so you can see as much as possible as you run away. I'll be

using this mnemonic/metaphor many times throughout this book to help you remember this concept.

The inner iris flows back and becomes the **ciliary body**. The ciliary body has two functions: it secretes aqueous fluid and it controls the shape of the lens. The ciliary body contains sphincter muscles that change the lens shape by relaxing the zonular fibers that tether to the lens capsule.

The **choroid** is a bed of blood vessels that lie right under the retina. The choroid supplies nutrition to the outer one-third of the retina which includes the rod and cone photoreceptors. Retinal detachments can separate the retina from the nutritious choroid, which is disastrous for the photoreceptors as they quickly die without this nourishment.



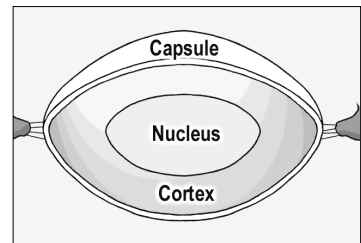
Fun Fact

An ostrich's eye is larger than its brain.

Lens:

The lens is a magnifying glass inside our eye that helps focus light. The lens sits behind the iris and is unique in that it doesn't have any innervation or vascularization. It gets its nourishment entirely from nutrients floating in the aqueous fluid. The lens also has the highest protein concentration of any tissue in the body (65% water, 35% protein).

Though the lens may look solid, it actually has three layers in a configuration similar to a peanut M&M. The outer layer is called the **capsule**. The capsule is thin with a consistency of saran wrap and holds the rest of the lens in place. The middle layer is called the **cortex**, while the central layer is the hard **nucleus**. Cataracts are described by where they occur - such as nuclear cataracts, cortical cataracts, and subcapsular cataracts. With cataract surgery the outer capsule is left behind and the artificial lens is placed inside this supporting bag.



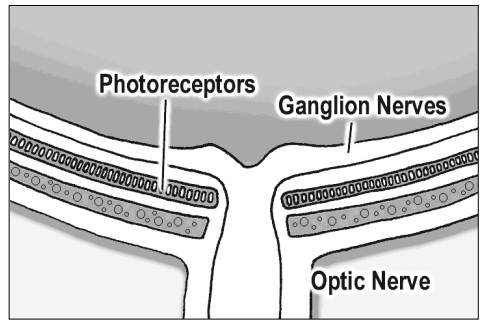
The capsule is held in place by suspensory ligaments called **zonules** that insert around the periphery and connect to the muscular ciliary body. Contraction of the ciliary muscle causes the zonule ligaments to *relax* (think

about that for a minute), allowing the lens to become rounder and increase its refracting power for close-up reading.

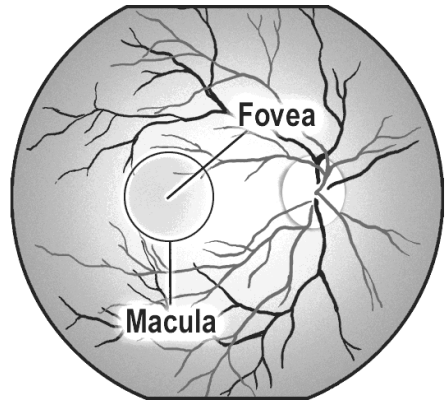
In children the lens is soft, but with age the lens hardens and becomes less pliable. After age 40 the lens starts having difficulty "rounding out" and people have problems focusing on near objects. This process is called presbyopia. Almost everyone over 50 needs reading glasses because of this hardening of the lens.

The Retina:

The **retina** is the sensory portion of the eye and contains layers of photoreceptors, nerves, and supporting cells. Histologically, many cell layers can be seen, but they are not worth memorizing at this point. The important ones include the photoreceptor layer, which is located further out (towards the periphery), and the ganglion nerve layer which lies most inward (toward the vitreous). The key point here is that for light to reach the photoreceptor it has to pass through many layers. After light reaches the photoreceptors the visual signal propagates back up to the ganglion nerves. These ganglion nerves, in turn, course along the surface of the retina toward the optic disk and form the optic nerve running to the brain.



The **macula** is the pigmented area of the retina that is responsible for central vision. Within the central macula lies the **fovea**, which is a small pit that is involved with extreme central vision. The fovea is very thin and derives its nutrition entirely from the underlying choroid, making it especially susceptible to injury during retinal detachments.



The optic disk is the entry and exit point of the eye. The central retinal artery and vein pass through here, along with the the ganglion nerves that form the optic nerve. A physiologic divot or "cup" can be found here that will become important when we talk about glaucoma.

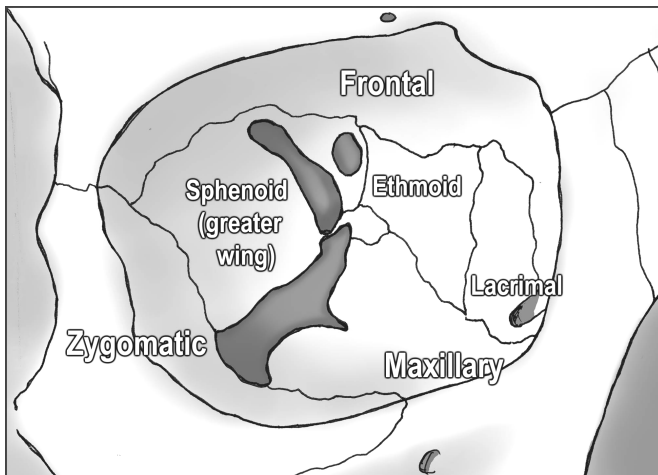
The Orbital Walls:

Seven different bones form the orbital walls. Don't be intimidated by this complexity, however, as these bones are not that confusing when you break them down. For example, the roof of the orbit is a continuation of the frontal

bone, the zygomatic bone forms the strong lateral wall, while the maxillary bone creates the orbital floor. This makes sense, and you could probably guess these bones from the surrounding anatomy.

The medial wall is a little more complex, however, but is mainly formed by the lacrimal bone (the lacrimal sac drains tears through this bone into the nose) and the ethmoid bone. The thinnest area in the orbit is a part of the ethmoid bone called the **lamina papyracea**. Sinus infections can erode through this "paper-thin wall" into the orbital cavity and create a dangerous orbital cellulitis.

Despite the fragility of the medial wall, it is well buttressed by surrounding bones and rarely fractures. The orbital *floor*, however, breaks most often during blunt trauma. The maxillary bone fractures downward and the orbital contents can herniate down into the underlying maxillary sinus. This is called a "blowout fracture" and can present with enophthalmia (a sunken-in eyeball) and problems with eye-movements from entrapment of the inferior rectus muscle. We'll discuss blow-out fractures in more detail in the trauma chapter.



The back of the orbit is formed by the greater wing of the sphenoid bone, with the "lesser wing" surrounding the optic canal. There's also a little palatine bone back there in the middle, but don't worry about that one!

The Apex: Entrance into the Orbit

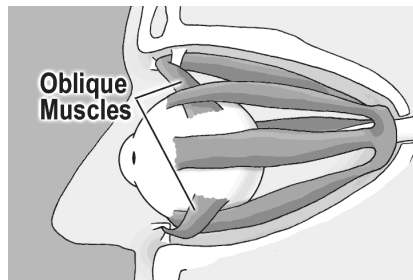
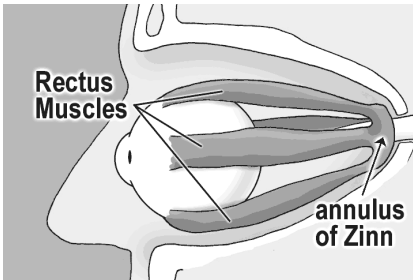
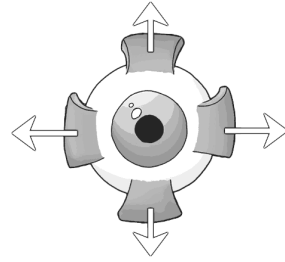
The orbital apex is the entry point for all the nerves and vessels supplying the orbit. The superior orbital fissure lies between the wings of the sphenoid bones, through which many vessels and nerves pass into the orbit.

The "Annulus of Zinn," a muscular band that serves as the insertion point for most of the ocular muscles, rests on top of the superior orbital fissure. The four rectus muscles attach to the annulus and the optic nerve passes right through the middle.

Eye Muscles:

Four **rectus muscles** control each eye. These muscles insert at the sclera, behind the limbus, and each pull the eye in the direction of their attachment.

The superior, medial, and inferior rectus muscles are all controlled by the oculomotor nerve (III). The lateral rectus, however, is controlled by the abducens (VI) nerve, which makes sense as the lateral rectus “abducts” the eye.



The remaining two eye muscles are the superior and inferior **oblique muscles**. The superior oblique also originates in the posterior orbit, but courses nasally until it reaches the trochlea (or "pulley") before inserting onto the eye. The inferior oblique originates from the orbital floor and inserts behind the globe near the macula. Because of these posterior insertions, the oblique muscles are primarily responsible for intorsion and extorsion (rotation of the eye sideways), though they also contribute some vertical gaze action.

Confused yet? Don't kill yourself learning the action of the oblique muscles or nerve innervation as we'll discuss these topics in greater detail in the neurology chapter.

Summary:

That was a ton of anatomy and your head must be spinning by now! There is much more anatomy we could cover, but let's hold off and discuss more detailed anatomy in future chapters as they become relevant.

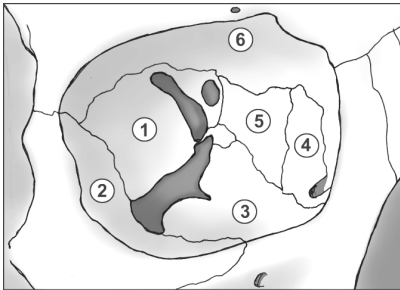
Pimp Questions

1. Why don't objects like contact lens and eyelashes get stuck behind the eye?

Because the conjunctiva covering the front of the eye loops forward and covers the inside of the eyelids as well.

2. How many chambers are there in the eyeball?

Three, actually. The anterior chamber sits in front of the iris, the posterior chamber between the iris and the lens, and the vitreous chamber lies behind the lens filling most of the eye.



3. Name each of the numbered bones.

Which bone is thinnest?

Which is most likely to fracture after blunt injury?

Which is most likely to erode from sinus infections?

The bones are: (1)Sphenoid (2)Zygomatic (3)Maxilla (4)Lacrimal (5)Ethmoid (6)Frontal. The ethmoid is the thinnest bone and most likely to perforate from an eroding sinus infection (this happens mostly in kids). The maxillary floor is most likely to fracture from blunt injury.

3. What is the uvea? What eye structures compose it?

The uvea comprises the iris, ciliary body, and the choroid. They are all connected to each other and are histologically similar. Patients can present with a painful “uveitis,” an inflammation of the uvea, often secondary to rheumatological/inflammatory conditions like sarcoidosis.

4. Where does the retina get its nutrition supply?

The inner two thirds of the retina (inner implies toward the center of the eyeball) gets its nutrition from the retinal vessels. The outer third (which includes the photoreceptors) is nourished by the underlying choroid plexus. A retinal detachment, which separates the retina from the choroid, is particularly dangerous for the photoreceptors. This is especially true for detachments involving the macula as the thin macula gets its blood supply primarily from the underlying choroid.

5. When the ciliary body contracts, how does the lens change shape (does it get rounder or flatter)?

The ciliary body is a round, spincter-like muscle, so when it contracts the zonules actually *relax*, allowing the lens to relax and become rounder. With age, the lens hardens and has a hard time relaxing no matter how hard the ciliary muscle contracts. This aging process is called presbyopia. We're going to review this again in the cataract chapter.

6. Which extraocular muscle doesn't originate at the orbital apex?

Unlike the other muscles, the inferior oblique originates from the orbital floor before inserting on the back of the globe near the macula.

7. Which full-thickness eyelid laceration is more dangerous - medial or lateral lacerations? Why?

You worry about the canalicular tear-drainage system involvement with medial lacerations. You want to repair this system as soon as possible, to avoid chronic epiphora.

8. How many layers are there in the cornea? Can you name them?

There are five: the superficial Epithelium, Bowman's layer, Stroma, Decemet's membrane, and the inner Endothelium.

9. How does the water content of the cornea differ from the rest of the eye?

The cornea is relatively dehydrated, which helps with clarity. If water gets into the cornea, via a disrupted endothelium or a high pressure gradient from acute glaucoma, the cornea turns hazy and white.

10. A pseudophakic (i.e., implanted lens) patient is found to have excellent far vision, but reading is terrible. What's going on?

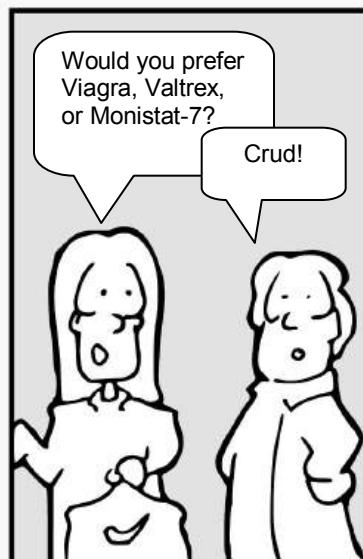
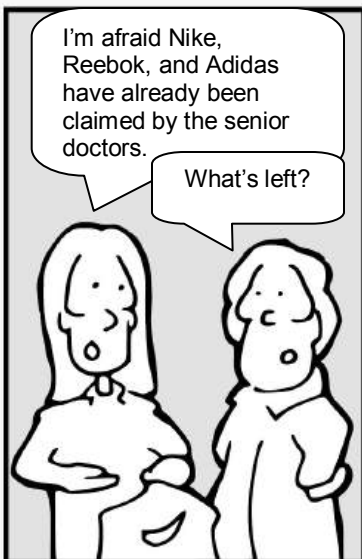
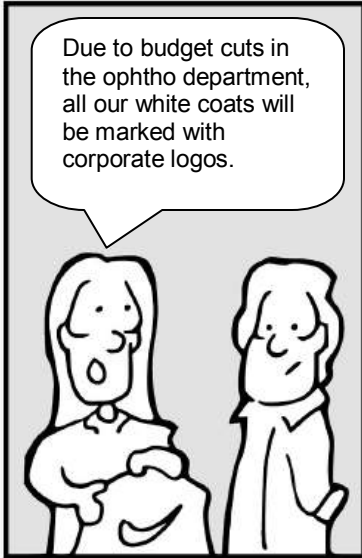As we get older, our natural lens hardens and does not change shape very well, making it hard to accommodate and see near objects. This phenomenon is called presbyopia and is a normal finding in people over 40 years of age. A prosthetic lens is not able to change shape at all, so *all* patients (including small children) with implanted plastic lenses require reading glasses to read.

Chapter 3

Glaucoma

The Eyes Have It

by Tim Root



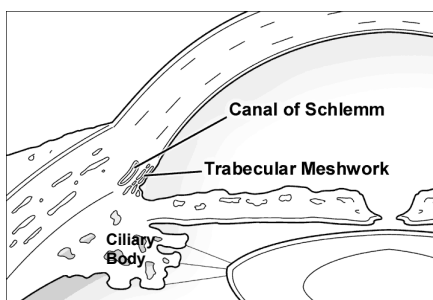
Introduction to Glaucoma

by Tim Root, M.D.

Glaucoma is a disease where the optic nerve dies. We are not sure *why* or *how* this happens (there are many mechanical, vascular, and biochemical theories) but high intraocular pressure certainly seems to be associated, if not entirely the cause of optic nerve death. Glaucoma is one of the leading causes of preventable blindness in the U.S., and patients with *acute* glaucoma can develop irreversible vision loss within a few hours, so it is important that you understand how this disease works and recognize it in your patients.

The Aqueous Pathway

Before continuing we should review the pathway of aqueous humor flow. Aqueous is the fluid that fills the front part of the eye, and it is important for maintaining the shape of the eye and providing nourishment for the avascular lens and cornea. Aqueous humor is first produced by the ciliary body within the posterior chamber.



After filling the posterior chamber, aqueous moves forward around the lens and flows through the pupil into the anterior chamber. As the anterior chamber fills, the aqueous spreads outwards into the angle formed by the iris and cornea. Within this irido-corneal angle the aqueous exits the eye by filtering through the trabecular meshwork into the Canal of Schlemm, where it returns back into the blood circulation. The pressure within the eye is maintained by this steady state of aqueous production and egress, and it is an imbalance in this equilibrium that causes the increased pressure associated with glaucoma.

Open vs. Closed-Angle Glaucoma

There are two categories of glaucoma and they have very different mechanisms. Open-angle glaucoma is the most common type in our country. It occurs from blocked aqueous drainage caused by an unidentified dysfunction or microscopic clogging of the trabecular meshwork. This leads to chronically elevated eye pressure, and over many years, gradual vision loss.

This differs from closed-angle glaucoma, also called “acute glaucoma,” which occurs when the angle between the cornea and iris closes abruptly. With this closure, aqueous fluid can’t access the drainage pathway entirely, causing

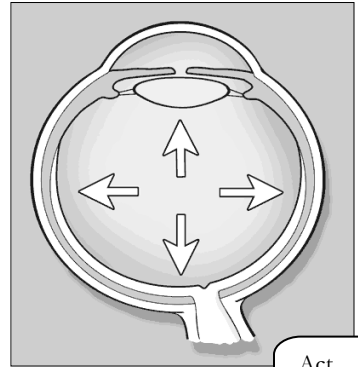
ocular pressure to increase rapidly. This is an ophthalmological emergency and patients can lose all vision in their eye within hours.

Let's examine each of these types of glaucoma in more detail.

Open-Angle Glaucoma

The majority of glaucoma patients (about 80%) have chronic open angle glaucoma. Most patients are over the age of 40. This condition is more common in African Americans, but really anyone can get it. The major risk factors are family history, age, race, high eye pressure, and large vertical nerve cupping. More recently, thin-corneas have been found to be a major risk factor, though this mechanism is not well understood.

The underlying mechanism for open-angle glaucoma involves degeneration of the trabecular meshwork filter, usually by unknown causes, that leads to aqueous backup and chronically elevated eye pressure. With prolonged high pressure, the ganglion nerves in the retina (the same nerves that form the optic nerve) atrophy. The exact mechanism for this nerve damage is poorly understood and proposed mechanisms include stretching, vascular compromise, and glutamate transmitter pathways. As the ganglion nerves are progressively destroyed, vision is gradually lost.



Act casual, say nothing!

Open-angle glaucoma has the reputation of being the "sneaky thief of sight" because the visual loss occurs so slowly that many patients don't realize they have the disease until it is far advanced.

Because the disease is otherwise asymptomatic, detecting open-angle glaucoma requires early pressure screening.



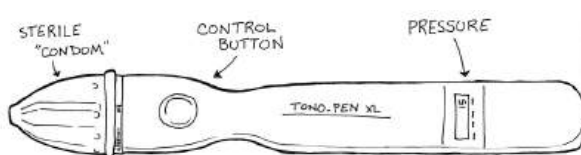
Presentation

Open-angle glaucoma patients usually present with three exam findings: elevated eye pressure, optic disk changes, and repeatable visual field loss patterns.

1. Pressure: The gold standard for measuring eye pressure is with the Goldman applanation tonometer. This is a device mounted on the slit-lamp that measures the force required to flatten a fixed area of the cornea. Normal pressures range from 10 to 22 mm Hg. Keep

in mind that eye pressure can fluctuate throughout the day (typically highest in the morning) so the pressure should be checked with each visit and the time of measurement should be noted. Also, some glaucomatous eyes have a “normal” pressure. In other words, a “good pressure” doesn’t rule out glaucoma, nor does a high pressure necessarily indicate glaucoma.

You can also measure pressure with a device called a “Tono-Pen.” This expensive little gadget is handy for bed-bound patients and down in the emergency room, though it’s inaccurate in the wrong hands!



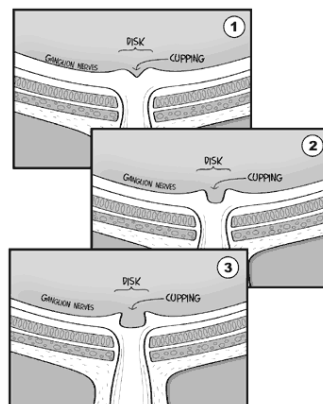
Corneal Thickness can affect your pressure measurement:

When we measure the pressure in the eye, we are actually measuring how much resistance we get when pressing on the cornea. This is analogous to kicking a car-tire with your foot or pressing your hand against a bicycle tire to estimate how much air pressure is inside. We do the same thing with the Goldman applanation tonometer mounted on the slit-lamp - we measure how much force it takes to flatten a 3mm diameter area of corneal surface.

The pressure measurements on the Goldman were calibrated using an average corneal thickness of approximately 540 microns. However, some patients have very thin or thick corneas. I like to describe these as “thin bicycle” or “thick truck-tire” corneas. When you press on a thick cornea (a truck-tire cornea) the pressure will seem higher than it really is! This makes sense ... if you kick a flat truck-tire, it will still hurt your foot because that rubber is so darn thick. The opposite is true for thin corneas - they feel squishy no matter how much pressure is inside.

Knowing corneal thickness is important in a glaucoma clinic so we can calibrate the accuracy of our pressure readings. This is why we always check corneal thickness with an ultrasonic pachymeter on the first visit.

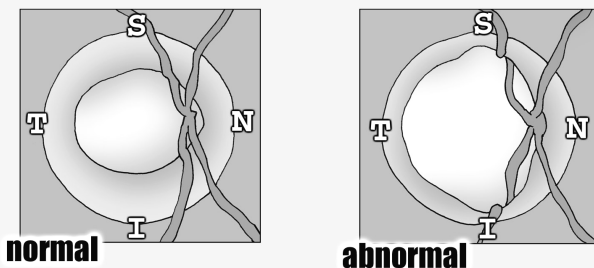
2. Fundus Exam: The optic disk looks striking in advanced glaucoma. In normal patients, the optic disk has a physiological indentation or “cup” that is less than one-third the disk diameter. With glaucoma, the ganglion nerve layer slowly dies away, and, as fewer ganglion nerves course through the optic disk, the amount of cupping increases. A cup to disk ratio greater than 0.5 or an asymmetry between the eyes suggests ganglion atrophy caused by glaucoma.



The I.S.N.T. Rule

When you look at your patient’s optic nerve, you’ll notice that the cup doesn’t sit directly in the middle of the disk. The cup is slightly off-center – this makes sense as the optic nerve enters the back of the eyeball at an angle.

The space between the inner cup and surrounding disk is called the **neural rim** and is comprised of the actual retinal ganglion nerves. In a normal eye, this rim follows the **ISNT rule** of decreasing thickness ... meaning that the **I**nferior rim is thickest while the **T**emporal rim is the skinniest.




With glaucoma, you often see vertical thinning and notching of the inferior and superior rims. This deviation from the ISNT rule is another clue that glaucoma might be killing off the nerve. You can also see undermining of the rim (as in the illustration on the right) where the blood vessels dive out of view under the rim edge.

3. Visual Loss: The vision loss from chronic glaucoma occurs in characteristic patterns that can be followed by automated perimetry (machines that map out the peripheral vision). The central vision is typically spared – in fact, late stage patients may have 20/20 central vision, but be otherwise legally blind because of peripheral blindness.

Fun Fact

The giant squid has the largest eyeball in the world. This enormous deep-sea predator can weigh up to 2.5 tons and 55 feet in length. Its eye can be a more than a foot in diameter! Wow!



Treatment:

Since IOP (intraocular pressure) is the only risk factor we can treat, the primary treatment of glaucoma focuses on decreasing eye pressure to less than 20 mm Hg or even lower, depending upon the severity of disease. Treatment may be either medical or surgical.

Medical Treatment

Topical beta-blockers are the traditional therapy for these patients and have been around for decades. Beta-blockers work by decreasing aqueous humor production at the ciliary body. Unfortunately, systemic side effects can occur from nasal absorption, making it especially important to ask your patients about history of asthma, COPD, and cardiac problems.

These days, many physicians are using newer drugs like topical CAs, alpha-agonists, and prostaglandin analogues for first-line therapy, as they have fewer systemic side effects.

Prostaglandin analogues like latanoprost (Xalatan™) are the newest of these glaucoma drugs, and they are very popular as a first-line agent. They work by increasing aqueous humor outflow. They do have some side effects, though. They can make eyelashes grow longer (many patients actually like this), and in a few patients may darken the iris color, turning green and blue eyes brown.

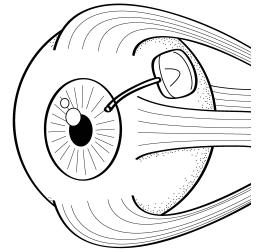
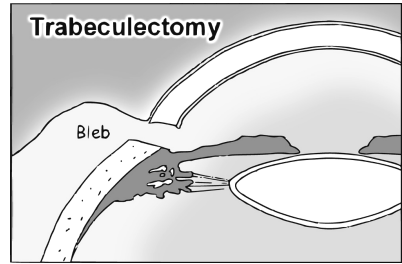
Surgical Treatment for Chronic Glaucoma

If eyedrops aren't working, there are several surgical techniques available to relieve eye pressure.

One common surgery is the **trabeculectomy**, where an alternate drainage pathway is surgically created. A small hole is cut through the superior limbus, so that aqueous can drain under the conjunctiva. This can be very effective in decreasing pressure.

However, if the patient is a rapid healer the conjunctiva can scar down, so anti-metabolites like mitomycin-C are often applied to the site. If this surgery doesn't work, a plastic tube-shunt can be inserted into the anterior chamber that drains to a plate fixed under the conjunctiva further back behind the eye.

Several laser procedures can also help to release pressure. Argon laser trabeculoplasty (**ALT**) can be used to burn portions of the trabecular meshwork itself. The resulting scarring opens up the meshwork and increases outflow. A laser can also be used to burn the ciliary body to decrease aqueous production at its source, but this is usually a last resort.



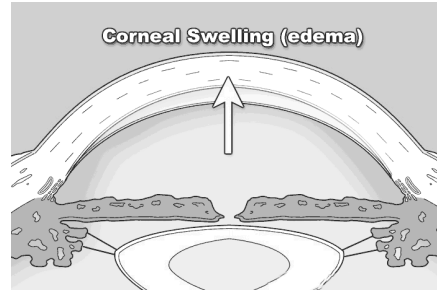
Acute Glaucoma

Acute glaucoma is a medical emergency. The most common mechanism is pupillary block. This occurs when the lens plasters up against the back of the iris, blocking aqueous flow through the pupil. This resistance produces a **pressure gradient** (this is a good buzz word to memorize) across the iris that forces the iris and lens to move anteriorly. When the iris moves forward, the irido-corneal angle closes, blocking the trabecular meshwork. Without an exit pathway, aqueous fluid builds up, eye pressure increases rapidly, and the optic nerve is damaged from stretching and decreased blood supply.

This sequence of events can occur for many reasons, and people with naturally shallow anterior chambers such as hyperopes (far-sighted people with small eyes) and Asians are predisposed to developing angle closure. One inciting condition that is typical in acute glaucoma is pupil dilation -- many patients describe onset of their symptoms occurring while in the dark or during stressful situations. When the iris dilates, the iris muscle gets thicker and the irido-corneal angle becomes smaller, making it more likely to spontaneously close. Along those lines, medications that dilate the eye, such as over-the-counter antihistamines and cold medications, also predispose angle closure.

Presentation

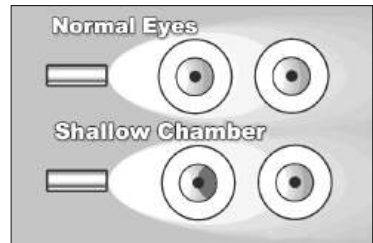
A patient in the middle of an acute glaucoma attack will present with an extremely red and painful eye, often complaining of nausea and vomiting. On exam, you'll find their pupil sluggish and mid-dilated. Pressures in the affected eye can be very high, often 60 mm Hg or higher. The eye will feel rock hard, and you can actually palpate the difference between the eyes with your fingers. One classic sign that patients often describe is seeing halos around lights. This occurs because the cornea swells as water is pushed under high pressure through the endothelium into the corneal stroma. This corneal swelling also makes it hard for you to see into the eye, further complicating diagnosis and treatment.



Acute Glaucoma Exam Techniques:

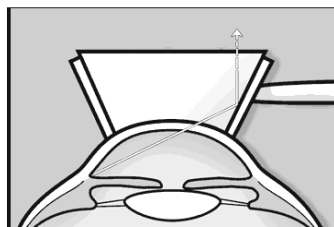
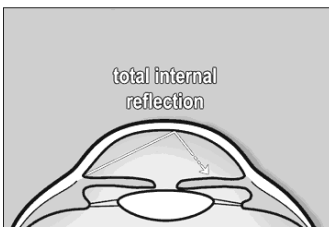
Ophthalmologic examination for acute glaucoma involves measuring the eye pressure, accessing the anterior chamber angle, and a fundus exam.

One trick to determine whether an angle is shallow is to shine a simple penlight across the eyes. If the iris is pushed forward, it will cast a shadow. Additionally, an ophthalmologist can visualize the angle directly through gonioscopy. Here's how it works:



Gonioscopy:

Normally, the inner "iris-cornea angle" cannot be seen with a microscope because the cornea-air interface creates "total internal reflection." However, we can use a goniolens, which is a special glass lens with mirrors on its sides, to look directly at the angle. When the glass lens is placed directly onto the cornea, the cornea-air interface reflection is broken and light from the angle can escape and be seen through the mirrors.



Fun Fact

We can see the concept of “total internal reflection” in nature. For example, if you’ve ever gone snorkeling in water, you may notice that the water’s surface above you looks like a mirror.

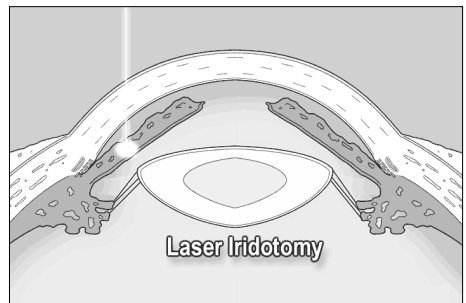
The flying fish uses this phenomenon to escape from predators. When attacked, the flying fish leaps from the water and glides above the surface so the shark can’t see them - effectively disappearing.

This is also how fiber optic cables work, with light bouncing off the walls of the cable.

Acute Glaucoma Treatment

In cases of acute glaucoma, you want to decrease the pressure in the eye as quickly as possible. A “kitchen sink” approach is often used, throwing many treatments on at once. You can decrease aqueous production using a topical beta-blocker like Timolol and a carbonic anhydrase inhibitor like Diamox. Also, osmotic agents such as oral glycerin or IV mannitol (even ethanol, in a bind) can be given systemically to draw fluid out of the eye and back into the bloodstream. Finally, a miotic such as pilocarpine *may* be helpful in certain cases to constrict the pupil and thus open up the outflow angle. You can also use topical glycerin to *transiently* dehydrate/clear the cornea to aid with examination.

Ultimately, these patients need surgical treatment to avoid recurrence of their angle closure. A high intensity laser can burn a hole through the iris and create a communication between the posterior and anterior chambers. This relieves the **pressure gradient** (there’s that buzzword again!) across the iris, and allows it to move back into a normal position. The trabecular meshwork then opens and allows aqueous fluid to flow freely out of the eye. This laser procedure is typically performed on both eyes because these patients are predisposed to having attacks in the other eye as well.



Other types of glaucoma

1. Neovascular Glaucoma:

This can occur in diabetic patients or those with a retinal vein occlusion. VEGF production from areas of ischemic retina can float forward through the

pupil and promote neovascularization of the iris. In the early stages, a fibrous membrane forms on the iris-cornea angle that blocks outflow and forms an open-angle glaucoma. At later stages of neovascularization, the new vessels actually pull the iris forward and cause a closed angle glaucoma that is essentially irreversible. You treat this by lasering the peripheral retina to decrease the angiogenic VEGF production and decrease the rate of neovascularization. Neovascular glaucoma is very hard to treat and most of these patients end up needing a surgical intervention like a tube-shunt.

2. Pigment Dispersion Syndrome (PDS):

This occurs when the pigmented back surface of the iris rubs against the radial zonules supporting the lens. Little flecks of pigment are shed into the aqueous and end up clogging the trabecular meshwork drain. This process usually occurs in young white males with myopic eyes. They suffer from attacks of high pressure after exercise when pigment gets rubbed off and temporarily blocks the trabecular drain. You can see this pigment in the trabecular meshwork on gonioscopy, and even find trans-illumination defects of the iris at the slit-lamp.


Some of the pigment will stick to the inner-corneal surface, and because of convection currents in the aqueous, form a vertical line of pigment on the inner corneal surface called a Krukenberg spindle.

3. Pseudoexfoliation Syndrome (PXF)

In this systemic condition, basement membrane-like material is deposited throughout the body. This material adheres to the anterior lens capsule, creating a rough surface. As the overlying iris dilates and contracts with daily activity, pigment is rubbed off and clogs the trabecular drain. These patients also suffer from zonular instability, making cataract operations difficult.

Summary

That is glaucoma in a nutshell. Chronic, open-angle glaucoma is very common (in this country) and leads to gradual vision loss, while acute closed-angle glaucoma is infrequent but an emergency that needs urgent treatment to avoid blindness.



*It's just as we feared, Superman.
You've got optic nerves of steel!*

Pimp Questions

1. What is glaucoma? What actually causes damage to the neurons and optic nerve with glaucoma?

Nobody is sure exactly “what glaucoma is” but at its most basic, glaucoma is gradual death of the optic nerve. If anyone asks you for the definitive definition (or if a glaucoma specialist corners you), just say “nobody knows” or “death of the optic nerve.” If you say “high pressure” you’ll be laughed at (glaucoma specialists are odd ducks). The optic nerve damage arises from pressure, stretching, sheer forces, vascular compromise, or some kind of hormone regulator - we’re not sure of the exact mechanism.

2. What is the flow-pathway for aqueous fluid? Where is it made, and where does it leave the eye?

Aqueous is first produced by the ciliary body. It then flows forward through the pupil into the anterior chamber. Finally, aqueous drains through the trabecular meshwork and back into the venous system via the Canal of Schlemm.

3. What’s the difference between open-angle and closed-angle glaucoma? How about chronic versus acute glaucoma?

Open angle is a common, **chronic** condition where aqueous drainage is impaired. **Closed**-angle glaucoma is caused by **acute** closure of the irido-corneal angle leading to blockage of ALL aqueous drainage – an ophthalmologic emergency that can quickly lead to blindness.

4. What are the risk factors for developing primary open-angle glaucoma?

This is an important list and since I glossed over them in the chapter, here they are again:

- High intraocular pressure (obviously)
- Age
- Family history
- Race (African American and Hispanics)
- Suspicious optic nerve appearance (large vertical cupping)
- Thin central corneal thickness (** remember this one!)

There are other possible risk factors, but I'd focus on those listed above. These risk factors explain why we always ask our patients about familial history and why we check pachymetry (corneal thickness by ultrasound) on the first glaucoma visit.

5. What do we measure to monitor and follow *progression* in glaucoma patients?

We generally check three things: pressure, disk changes by photograph, and visual fields. Good stereo slides are difficult to obtain, so many doctors use other imaging modalities like HRT or OCT.

6. What does corneal thickness have to do with glaucoma (as far as risk for developing glaucoma)?

The OHTS clinical trial showed that people with thin corneas are at higher risk for developing glaucoma, independent of other risk factors. We're not sure why, but it's believed that people with thin corneas are anatomically predisposed to optic nerve damage. We measure corneal thickness using a small ultrasound probe (this is called pachymetry) with all new glaucoma patients.

7. What's a normal eye pressure? Does a patient with pressure of 14 have glaucoma?

About 10 to 22. While glaucoma is classically associated with high pressure, there is a significant minority of patients with glaucoma who actually have "normal" pressure. Also, pressure fluctuates throughout the day so we typically write down the time in our notes. Some studies have noted higher rates of glaucoma in people with large diurnal shifts in eye-pressure.

8. A glaucoma suspect is found on first visit to have a pressure of 19. Her corneal thickness, however, measures only 450 microns. Do you think her *actual* eye pressure is HIGHER or LOWER than 19?

Definitely higher. This patient has thin "bicycle-tires corneas" that "feel soft" when measured by the Goldman applanation. This woman's corrected pressure is probably well over 22, increasing her risk for glaucomatous progression.

9. What kind of vision loss occurs with glaucoma?

Typically loss of eyesight occurs in the periphery where it is less noticeable. Scotomas (areas of visual field loss) in glaucoma tend to follow certain patterns that start in the mid-periphery. Many patients don't notice visual symptoms until the disease is far progressed. Generally, the central vision is spared until very late stages of glaucoma.

10. Why can't you see the trabecular meshwork with the slit-lamp microscope?

This area is hard to see because the trabecular drain is tucked in the "angle" formed by the iris and inner cornea. We can't see this area directly because of "total internal reflection" at the cornea-air interface. Gonioscopy allows direct visualization of the trabecular meshwork by interrupting the cornea-air interface with a glass lens.

11. What mechanisms do the glaucoma drops use to decrease pressure?

Drops either decrease the amount of aqueous produced at the ciliary body or increase the aqueous outflow from the eye (generally via the uveal-scleral pathway or by direct improvement of trabecular meshwork outflow).

12. What retinal findings do you see with glaucoma?


You see increased cupping of the optic disk, usually in a vertical pattern that goes against the ISNT rule. You can sometimes see hemorrhages at the disk and "undermining" of the blood vessels as they exit the disk.

13. How can diabetes cause acute glaucoma?

Retinal ischemia can produce VEGF. As this molecule floats forward it can cause neovascularization of the iris, forming vascular membranes that cover the trabecular meshwork and clog the drainage angle. This leads to a severe neovascular glaucoma that is hard to manage.

14. You have a patient who appears to have a shallow anterior chambers and occludable angles. Would you use pilocarpine?

In most cases, yes. Pilocarpine will constrict the pupils -- by flattening the iris you potentially open up the drainage angle next to the trabecular meshwork. Pilocarpine will also decrease pressure in the eye by affecting aqueous production and egress. You probably wouldn't use it long term in patients with occludable angles though, as pilo has a lot of side effects such as headache and blurry vision. Ultimately, anyone with occludable angles needs a laser peripheral iridotomy to equalize the pressure between anterior and posterior chambers.



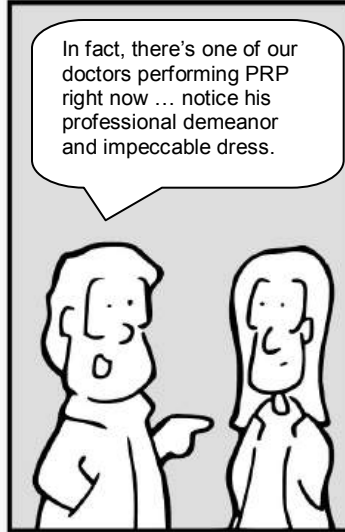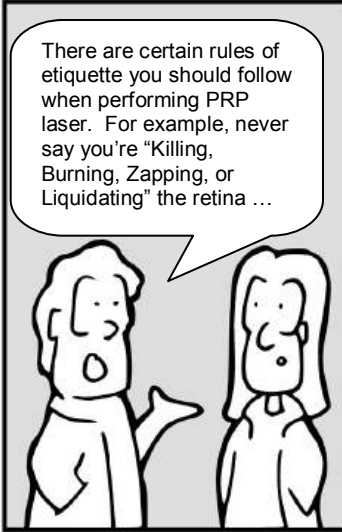
*"The earrings were daring, but
that nose-ring is too much!"*

Chapter 4

Retina

The Eyes Have It

by Tim Root



The Retina

by Tim Root, M.D.

The retina can be intimidating as it's not easy to visualize the posterior pole and there is a bunch of pathology back there. There are many things I could cover in this chapter, but I've decided to keep things simple and only discuss a few topics like diabetic retinopathy and retinal detachments. Other disease processes that involve the retina will be covered in other chapters.

Diabetic Retinopathy

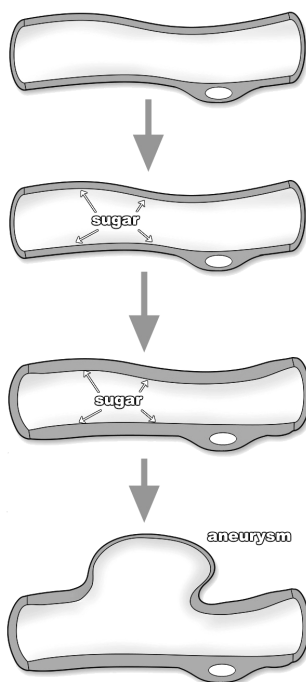
Diabetes is a common disease and many affected patients have vision problems. In fact, diabetics are twenty times more likely to go blind than the general population. **Diabetic retinopathy** is the term used to describe the retinal damage causing this visual loss. Diabetics have a high prevalence of retinopathy, and one out of every five patients with newly diagnosed diabetes will also show signs of retinopathy on exam.

Mechanism of Vessel Breakdown

How are the eyes affected? Basically, diabetes is a disease of blood vessels. With large amounts of glucose coursing through the circulatory system, a **glycosylation reaction** occurs between sugar and the proteins that make up blood vessel walls. Over time, this reaction promotes denatures the collagen protein within the walls, creating capillary thickening and eventually, wall breakdown.

While this process occurs throughout the entire body, the microvasculature of certain organs, such as the kidneys and eyes, are more susceptible to damage. Along these lines, a good predictor of microvasculature damage in the diabetic eye is prior evidence of renal microvasculature disease as measured by proteinuria, elevated BUN, and creatinine.

Because vessel damage accumulates over time, the most accurate predictor of retinopathy is duration of diabetes. After 10 years, more than half of patients will show signs of retinopathy, and after 15 years this number increases to nearly 90%. The relative control of glucose during this time is also important, and studies have shown that patients who



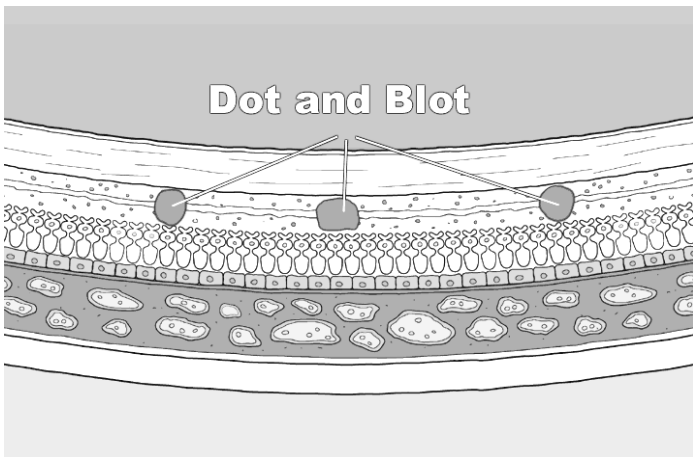
maintain lower hemoglobin A1C levels have delayed onset and slower progression of eye disease.

Two Types of Retinopathy

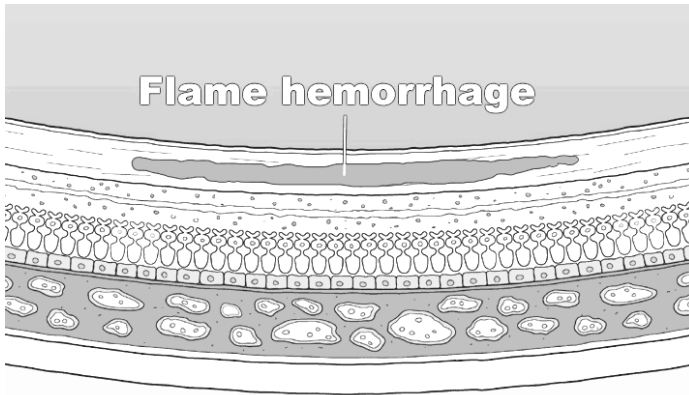
It is useful to divide patients into two categories of retinopathy, as these categories define treatment:

A. Nonproliferative diabetic retinopathy (NPDR)

Most patients (95%) have NPDR. This is the earliest stage of retinopathy and it progresses slowly. Because so many diabetic patients have NPDR, this stage is commonly described as “background retinopathy.” The earliest signs of retinal damage arise from capillary wall breakdown, seen on the fundus exam as vessel microaneurysms. Injured capillaries can leak fluid into the retina and the aneurysms themselves can burst, forming “**dot-and-blot hemorrhages.**”



Dot-blot hemorrhages look small and round because they occur in the deep, longitudinally-oriented cell layers of the retina. This contrasts with the “flame hemorrhages” of hypertension that occur within the superficial ganglion nerve layer, and thus spread horizontally.



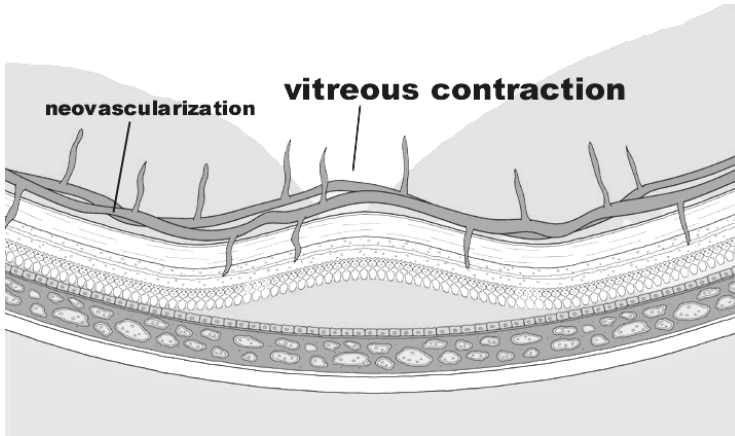
With worsening retinopathy and vessel damage, the retina begins to show early signs of ischemia. **Cotton-wool spots**, also seen with hypertension and venous stasis, are gray spots with soft edges that indicate ischemia/infarction of the superficial retinal nerve fibers. As vessel damage progresses, you can also see beading of the larger retinal veins and other vascular anomalies.

B. Proliferative Retinopathy

With ongoing injury to the retinal vasculature, eventually the vessels occlude entirely, shutting down all blood supply to areas of the retina. In response, the ischemic retina sends out chemicals that stimulate growth of new vessels. This new vessel growth is called **neovascularization**, and is the defining characteristic of proliferative retinopathy. Far fewer patients have proliferative retinopathy, which is fortunate as this stage can advance rapidly with half of these patients going blind within five years if left untreated. The mechanism and complications of neovascularization merit study, so let's take a closer look.

The Mechanism of Neovascularization

With complete vessel occlusion, parts of the retina become starved for nourishment. The ischemic retina responds by releasing angiogenic molecules like VEGF to promote new vessel growth. These new blood vessels serve to bypass the clogged arteries in order to resupply the starved retina.

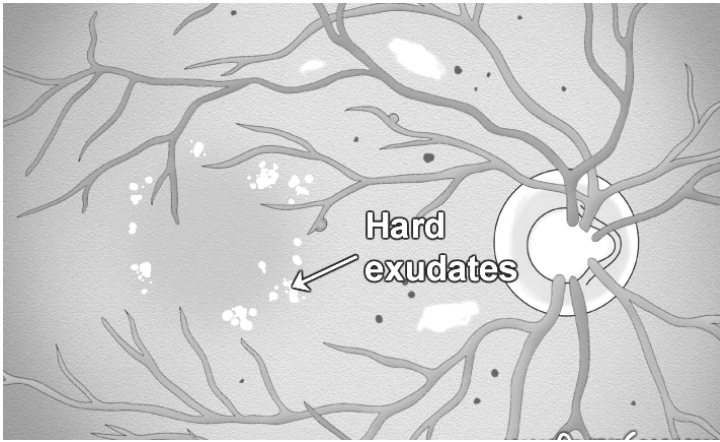


A collateral blood supply seems like a great idea, but unfortunately there is a problem. The newly formed vessels are abnormal in both appearance and function. The new vessels are friable and prone to leaking. They also grow in the wrong place, spreading and growing along the surface of the retina. They can even grow *off* the retina, sprouting up into the vitreous jelly. The vitreous is mostly water, but it also contains a lattice framework of proteins that the new vessels can adhere to. With vitreous movement or contraction, these new connections pull on the retina and the traction can cause a retinal detachment. Since the new blood vessels are also weak, any vitreous traction can break the vessels and create sudden hemorrhaging with subsequent vision loss as the eye fills with blood. Finally, the new vessels can regress and scar down, creating massive traction on the retina underneath.

Neovascularization isn't just limited to the retina, but can also occur on the iris itself. **NVI (neovascularization of the iris)** is an ominous sign, as the new vessels can cover the trabecular meshwork and create a sudden neovascular glaucoma.

Macular Edema

Despite the neovascularization phenomenon and its potential for detachments and hemorrhage, the most common cause of blindness in diabetic patients is from macular edema. This occurs when diffuse capillary and microaneurysm leakage at the macula causes the macular retina to swell with fluid.



Macular edema occurs in about 10% of patients with diabetic retinopathy and is more common with severe retinopathy. On exam the macula looks mildly elevated, and you can see past evidence of edema in the form of yellow-colored **"hard exudates."** These exudates are fatty lipids that are left behind after past macular swelling subsides, similar to a dirt ring in a bathtub.

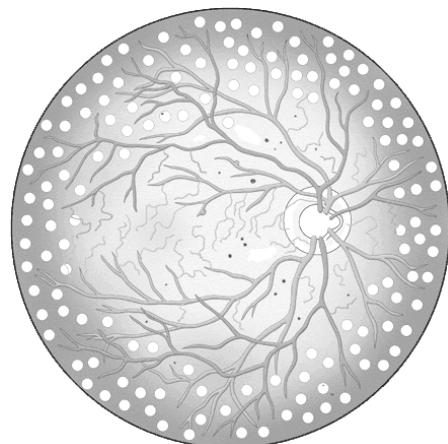
Treatment of DR (diabetic retinopathy)

Preventative medicine with tighter control of glucose is the ideal treatment, but for worsening symptoms, surgical treatment may be necessary. The two main surgeries are laser treatment and vitrectomy.

Laser Treatment

In cases of macular edema, an argon laser can be used to seal off leaking vessels and microaneurysm in the retina by burning them. If the leakage or microaneurysm is small and well-defined, it can be selectively sealed off. With larger areas of leaking capillaries, such as diffuse macular edema, the laser can lay down a "grid photocoagulation" pattern over the entire area.

With advanced retinopathy and neovascularization, a different approach is taken. Instead of individually targeting vessels, **PRP (pan-retinal photocoagulation)** is performed. With PRP, the ophthalmologist burns thousands of spots around the peripheral retina. This destroys the ischemic retina, decreasing the



angiogenic stimulus, and commonly leads to regression and even the complete disappearance of the neovascular vessels. This treatment may seem drastic, but it has proven to be effective. Naturally, there are side effects, with peripheral vision loss and decreased night vision (from the loss of peripheral rod photoreceptors), but this is acceptable if the central vision is saved. I've never seen anyone actually complain of decreased vision, but it's possible and should be stressed during consent.

Vitrectomy

A vitrectomy may be needed and is often done in conjunction with other surgeries. This surgery involves removing the vitreous humor from the eye and replacing it with saline. This allows removal of hemorrhaged blood, inflammatory cells, and other debris that may obscure the visual axis. While removing the vitreous, the surgeon also removes any fine strands of vitreous attached to the retina in order to relieve traction that might have, or will, cause a detachment.

Conclusion

As you can see, diabetic retinopathy is a big problem and very common as a large percentage of our patients have diabetes. Retinal vessel damage leads to edema, and vessel occlusion stimulates neovascularization that can lead to trouble. Fortunately, better glucose control and surgical treatments have significantly decreased the incidence of visual loss in these patients.

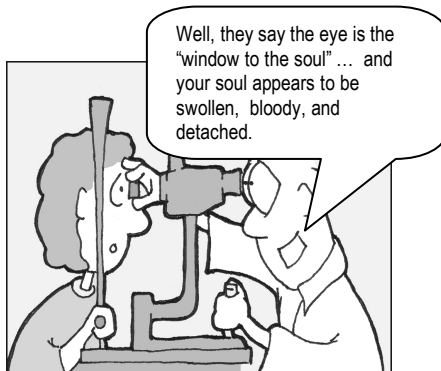
Retinal Detachments

A retinal detachment is an abnormal separation between the sensory retina and the underlying RPE and choroid plexus. If you remember from the anatomy chapter, the outer third (the part furthest from the inner vitreous) of the retina gets its nourishment primarily from the underlying choroids vascular bed. With a detachment, the photoreceptor layer separates from the choroid, and without this blood supply becomes ischemic. The macular retina is especially susceptible to this damage. The prognosis for patients with retinal detachments depends upon the quickness of treatment and whether the central retina is involved; patients with detachments that involve the macula have much worse outcomes.

Risk Factors and Epidemiology

Up to six percent of the general population have retinal breaks of some kind, though most of these are benign atrophic holes. The actual incidence of retinal detachment is only 1 in every 10,000 people. Relative risk is equal between men and women, with higher rates in those of Jewish descent and decreased risk in black populations.

When looking at patients who already have retinal detachments, you begin to see some interesting trends. Many of these patients are myopic (near-sighted). Myopic eyes are physically larger and longer than normal eyes and have thinner retinas at the periphery. This thin retina is more likely to break, forming small holes and tears that may progress to a detachment.

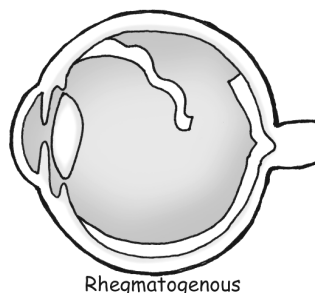


Up to 35 percent of patients with retinal detachments develop them after another eye surgery – typically a cataract extraction. Finally, traumatic sports such as boxing, football, and bungee-jumping predispose younger people to forming detachments.

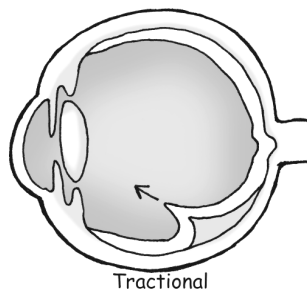
The Three Types of Detachment

Retinal detachments generally occur by three different mechanisms.

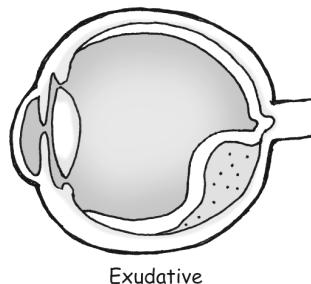
1. The most common detachment is the **rhegmatogenous retinal detachment**. This is an actual tear in the retina, with a full-thickness break through the retinal sensory layers. These tears can occur from trauma, surgery, or extend from preexisting retinal holes. Fluid from the vitreous chamber flows through the tear and collects in the sub-retinal space. Eventually, the retina tears away, peeling off the underlying RPE and choroid. Without treatment, a rhegmatogenous detachment can spread and eventually involve the entire retina.



2. The second type of detachment is from **traction** on the retina. This is when the retina is *pulled* from its base. This can occur from vitreous pulling, or from diseases like diabetic retinopathy where neovascular membranes on the retinal surface contract and tug on the retina with great force.

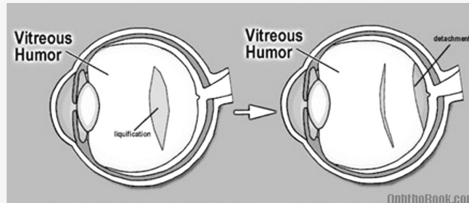


3. A less common mechanism for detachment is from **hemorrhagic** or **exudative retinal detachment**. This occurs when blood or fluid builds up under the retina, slowly pushing the retina upwards. This occurs with dysfunction of the RPE or choroid plexus and can be caused by ocular tumors, inflammatory diseases, or congenital abnormalities that create a breakdown of the blood-retina barrier.



Posterior Vitreous Detachment

One common cause of a retinal tear is secondary to a posterior vitreous detachment. As we age, the vitreous liquefies and contracts in upon itself ... if this occurs suddenly, the posterior vitreous face can suddenly peel off the retina. Usually, this isn't a problem, but if the vitreous is abnormally adherent to the retina the separation may rip a small hole in the retina that progresses into a detachment.



PVDs are very common in people over 65 and are a major source of “annoying floaters” in this population. We check these patients very closely, and, assuming no tears are seen, check them again in a few weeks to insure none have developed.

Symptoms

With detachment, patients often report seeing flashes of light and floaters. Flashing lights, or **photopsias**, are often seen when a detachment first occurs. Photoreceptors are normally triggered by light, but severe mechanical disturbance can stimulate them as well. These flashes look like a camera or lighting flash in the peripheral vision.

Floaters look like dark specks that obscure vision, and patients say they look like a swarm of flies. They are created by objects (blood cells or pigment) floating in the vitreous fluid that cast shadows on the retina. While the presence of a few floaters is normal, the sudden appearance of hundreds of floaters may indicate a vitreous hemorrhage.

A more ominous symptom that is sometimes described is seeing a “**dark curtain**” that obscures peripheral vision.

Most detachments start in the peripheral retina, and as they progress create a dark “shade” across the visual field. Fortunately, this is rare, but the combination of flashing lights and floaters should be considered a retinal detachment until proven otherwise.

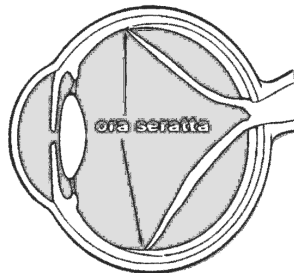


Findings

The definitive way to diagnose a retinal detachment is to actually see it with the indirect ophthalmoscope. If the tear is large enough, it will be obvious as the floating retina contains blood vessels and undulates with eye movement. Suspended pigment particles

may be seen floating in the anterior vitreous (**Shafer's sign**) that is described as “tobacco dust,” and is pathognomonic for a retinal tear.

An ultrasound of the eye may be helpful, especially when the tear is not obvious or when the retina can't be visualized because of hemorrhage or cataracts. An ultrasound can also pick up other pathology such as tumors that might cause an exudative detachment.



This illustration shows an ultrasound of a patient with a complete retinal detachment. The retina looks like a letter V in this picture, because it is still attached at two places – the optic disk and at the peripheral ora seratta. Choroidal effusions can give a similar appearance, but I won't talk about them because it would just be confusing at this point.

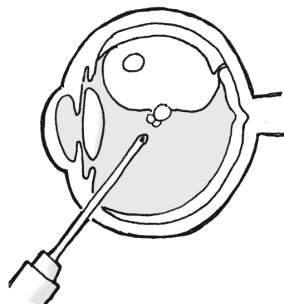
Treatment Options

The treatment for retinal detachment varies. The primary treatment for the majority of retinal tears and traction detachments is surgical. How fast a patient needs surgery depends upon whether the central macula has detached or not. If the macula has detached, the vision is pretty much toast, so it *may* be ok to wait a few days before going to surgery. If the macula is still on, then you want to make sure it STAYS on, so you go to surgery sooner.

If the retina has a tear or hole that hasn't yet detached, the tear can be “pegged down” by welding down the surrounding retina with a **laser**. The retina can also be scarred down by freezing it into place with a **cryoprobe** applied from the outside of the eye.

Scleral buckling is the traditional surgical procedure, and involves encircling the eye with a silicone band that squeezes the eye like a belt. The buckle indents the eye and pushes the RPE into contact with the retina, allowing it to heal into place. Because of the orbital anatomy, scleral buckles are most useful for anterior breaks at the equator because you can't really buckle the back of the eye.

Over the past few decades, **pneumatic retinopexy** has become quite popular. In this procedure, after repairing the retinal tear the surgeon injects a bubble of gas or silicon oil into the globe which acts to push (or tamponade) the retina into position until it heals. There are many different types of gas that we use, but they all eventually absorb back into the body. The disadvantage to this procedure is that patients have to keep their head down for several weeks to keep the bubble in place. This is very taxing

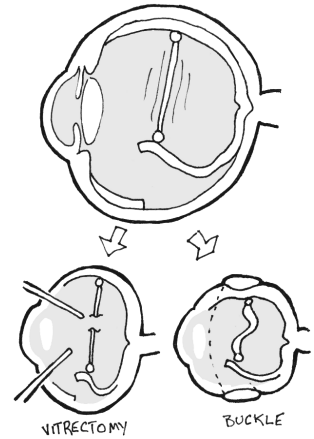


and patients tend to look quite disheveled at their post-op appointments. An oil bubble doesn't require this head positioning, but does require a return to the OR to remove the oil.

If the detachment is severe and complicated, a **vitrectomy** may need to be done. The vitreous fluid is removed, and the retina is manually floated back into position. With access to the inner globe, scar tissue and any other causes of traction, such as the neovascular membranes, can be removed.

Rubber Band Theory

When treating a retinal detachment, a good way to think about traction is the "rubber band" theory. Thus, there is almost always some tension inside the eye that is keeping the retina from laying flat like a rubber band. There are two ways to relieve this tension: you can perform a vitrectomy and "cut" the band, or you can perform an encircling buckle procedure to shorten the band.



RD Summary

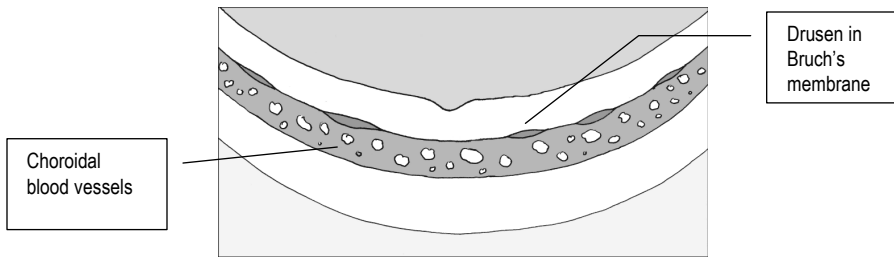
Retinal detachments were once universally blinding, but with modern surgical techniques, sight can now be saved. If you suspect a retinal detachment in your patients, send them to an ophthalmologist right away as their prognosis depends upon the speed in seeking treatment.

ARMD

ARMD stands for Age Related Macular Degeneration and is a common retinal finding in older patients. ARMD is actually the leading cause of blindness in the elderly, at least in developed countries like the USA.

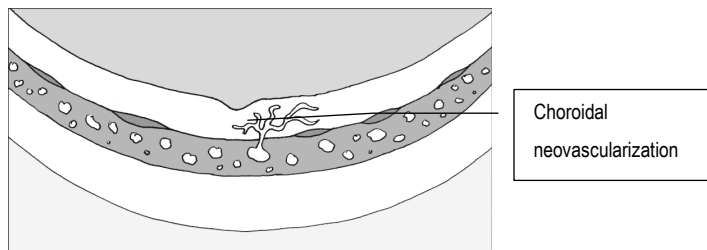
These patients develop extracellular breakdown deposits called "drusen" that form deep in Bruch's membrane. Bruch's membrane is the thin layer that separates the RPE/Retina from the underlying choroidal blood supply. This blockage keeps nutrition from percolating up from the choroid to the retina, and conversely blocks photoreceptor waste products from draining down into the choroidal bed.

On exam you see localized retinal atrophy and pigmentary changes in the macula that correlate with poor central vision. The visual loss occurs slowly, however, and takes many years to progress.



Neovascular “wet” ARMD

If a break occurs in Bruch's membrane, vessels can grow up out of the deep choroidal circulation directly up into the retina! This is dangerous, as this neovascularization can bleed, create edema, and rapidly destroy vision.



Treating this macular neovascularization is tricky - we would love to burn it away with a laser, but those bad blood vessels are often right at the fovea, and you don't want to burn away central vision! Instead, we can use a few other techniques with variable success:

PDT (photodynamic therapy): With PDT, you inject a special chemical into the blood that reacts to specific wavelengths of light. Once the chemical floats within the retinal blood vessels, we then focus light of that desired wavelength directly at the fovea to coagulate the blood vessels without destroying the retina around it. Sounds good in theory, but it sometimes doesn't work well so this technique is not always used.

Injection: You can also inject anti-VEGF drugs like Avastin or Lucentis into the eye to stop angiogenesis. These anti-neovascular drugs also decrease vessel wall leakage and can help with other causes of macular edema.

Monitoring progression

Early, dry ARMD is very common and requires no treatment (other than possibly antioxidant vitamins), but we want to monitor these patients for

progression to wet-ARMD. Patients can monitor themselves with an Amsler grid -- a sheet of straight lines they can look at weekly for new metamorphopsia (distorted lines that might indicate macular edema).

Risk Factors?

So who gets ARMD? This disease occurs most often in elderly Caucasians with a positive family history for the condition. It's almost always bilateral. Disease progression is also highly associated with smoking.

Pimp Questions

1. What is diabetic retinopathy, and by what mechanism does it occur?

This is retinal bleeding, edema, ischemia, and ultimately neovascularization caused by diabetic damage to the retinal blood vessels.

2. What are the retinal signs of diabetic retinopathy. How do they compare to, say, hypertensive retinopathy.

With diabetic retinopathy you typically see a lot of dot-blot hemorrhages, cotton-wool spots, and hard exudates. Hypertension usually has more flame hemorrhages and vascular changes such as arterial-venous nicking and copper/silver wiring.

3. How are angiogenic molecules involved with diabetic retinas?

VEGF production by areas of ischemic retina leads to neovascularization. These new vessels are harmful as they can cause traction, bleeding, detachments, etc..

4. How do we categorize diabetic retinopathy?

As either NPDR (nonproliferative diabetic retinopathy) or PDR (proliferative diabetic retinopathy) depending upon the presence of neovascularization.

5. What are some mechanisms in diabetic retinopathy that might lead to decreased vision? What causes the majority of vision loss in diabetic patients?

There are several mechanisms for potential vision loss in these patients, including:

- Macular edema (probably the leading cause of vision loss)
- Vitreous hemorrhage
- Retinal detachment

6. How do we treat advanced diabetic retinopathy?

Proliferative diabetic retinopathy is treated with PRP (pan retinal photocoagulation). By ablating the peripheral ischemic retina with a laser, we decrease VEGF production and thus decrease neovascularization.

7. A 35 year old man with bad type-1 diabetes presents with a pressure of 65. His anterior chamber is deep but you find neovascularization everywhere - in the retina and on the iris. What do you think is causing the pressure rise, and how do you treat it?

The pressure is up because of neovascularization of the iris angle with blood vessels clogging up the trabecular drain. You treat neovascularization by PRP lasering the peripheral retina to decrease VEGF production. NVA (neovascularization of the angle) is hard to manage and this patient will probably require a surgical drainage procedure in the near future.

8. Describe the three types of retinal detachment?

These include rhegmatogenous detachments, tractional detachments, and exudative detachments.

9. What are the symptoms of a retinal tear or detachment?

Flashes and floaters are the classic signs. With a large detachment your patient may also notice an area of "dark curtain" or "blurry spot" in their peripheral vision.

10. What is a PVD?

This is a posterior vitreous detachment - with aging the vitreous jelly liquefies and contracts. A sudden contraction can cause new floaters. This event is usually harmless, but you should search carefully for retinal tears.

11. An elderly patient presents with a brief episode of flashing and now has a single floater that moves with eye movement. A thorough retina exam reveals no detachment or tear, but you observe a small vitreous opacity floating over the optic disk. What has happened?

This again sounds like a PVD. The floater is a Weis ring, a piece of optic disk debris that has pulled off with the vitreous detachment. PVDs are common and usually harmless, though patients should have a thorough exam for retinal tears and be taught the symptoms of retinal detachment.

12. A patient presents late at night with a large rhegmatogenous retinal detachment. The central fovea is also detached. How soon do you need to go to surgery?

If the macula is off, then the macular photoreceptors are already damaged and it *may* be ok (this is the retina surgeon's call) to schedule repair later when your surgeon is well-rested and you've got your best operating team. However, if the macula is still ON, you want to intervene sooner to make sure the macula STAYS on.

13. What kind of surgeries can we perform to relieve retinal detachments?

You can perform a vitrectomy to clean out the inside of the eye and relieve retinal traction. While in there you can also reappose the retina. You can also perform a scleral buckle or a pneumatic retinopexy.

14. What is Schafer's Sign?


This is when you see retinal pigment particles floating in the anterior vitreous chamber behind the lens. This slit-lamp sign increases your suspicion for a tear or detachment.

15. What's the difference between dry and wet age-related macular degeneration?

Dry ARMD is when you have drusen and macular RPE atrophy. Wet ARMD implies choroidal neovascularization that has grown up through Bruch's membrane and bleed into the retina. "Wet" essentially means "bloody" in this instance.

16. What kind of travel restrictions would you tell a patient who has a pneumatic retinopathy?

You don't want these patients to fly. A decrease in ambient pressure causes gases to expand. If this happens in the eye it could explode! Your patients should also avoid SCUBA diving for similar reasons, as the change in gas volume over the changing atmospheric pressure will cause extreme pain and possible damage.




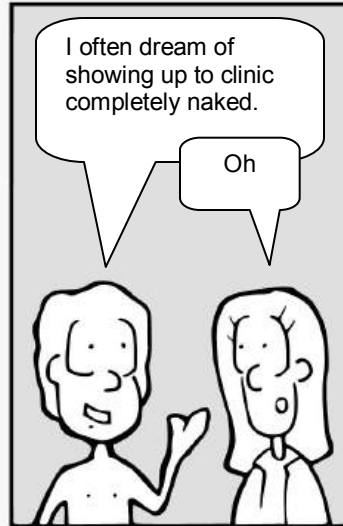

*You swallowed the SCUBA tank
again, didn't you?*

Chapter 5

Infection

The Eyes Have It

by Tim Root



Eye Infections

by Tim Root, M.D.


The eye is well protected from infection by the conjunctiva and the corneal epithelium. In addition, the tear film contains antimicrobials while the tear flow itself tends to wash away pathogens. The eye also harbors a host of non-pathogenic bacteria that competitively prohibit new bacteria growth. However, these eye-defenses can be breached by trauma, improper tearing, or contact lens wear and lead to an infection. An eye infection not only threatens vision, but the orbit can act as an entry portal to the rest of the body and infections can progress to systemic involvement, meningitis, and even death.

You will see a lot of conjunctivitis, blepharitis, and corneal ulcers in an ophthalmology walk-in clinic. Here's a review of the common, less common, and potentially devastating infections you should know about.

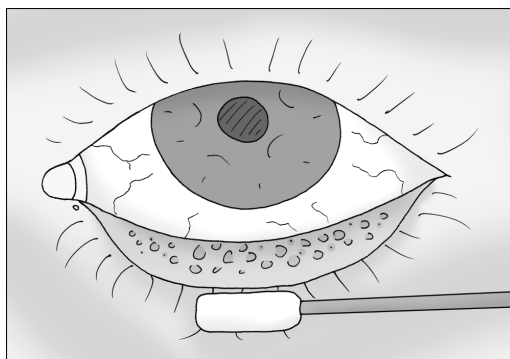
Pink Eye: the three types of conjunctivitis

The conjunctiva is the semi-transparent skin covering the white part of the eye. This layer protects the eye from foreign bodies, infections, and irritants. However, the conjunctiva itself is susceptible to irritation and infection from virus and bacteria. Conjunctivitis, or “pink eye,” is the term used to describe inflammation of the conjunctiva and commonly occurs from three different sources: viral, bacterial, or allergic.

1. Viral conjunctivitis is the most common type, making up half of all cases of conjunctivitis in the adult. It is usually caused by an adenovirus, often following an upper respiratory infection or cold. Viral conjunctivitis is quite contagious and other family members may also complain of having “red eye.” Infected patients typically present with eye *redness* and watery *tearing*, but little mucous discharge. Often, only one eye is infected, but the infection may spread to the other eye. Two specific signs on exam are enlarged follicular bumps on the inside of the eyelids (these look like tiny blisters under the microscope) and swelling of the preauricular node located in front of the ear. Most of these infections clear up on their own within a few days. Like the common cold, treatment is geared toward relieving symptoms. Viral conjunctivitis is so contagious that I also recommend good hygiene and no towel/makeup sharing in the home.



2. Bacterial conjunctivitis presents with a *mucopurulent* (pus) discharge. This creamy discharge may cause your patient to complain of sticky eyelashes, with patients finding their eyes matted shut upon waking in the morning. Bacterial conjunctivitis often develops a papillary conjunctival reaction (red bumps on the inside of the lids) and, unlike viral infections, typically does NOT have preauricular node enlargement. The most common culprits are staph and strep, although with children you should also consider *Hemophilus influenzae* bacteria. In addition, sexually active adults may harbor chlamydial and gonococcal infections (especially with severe or sudden discharge). I treat most conjunctivitis with erythromycin ointment.



3. Allergic Conjunctivitis: Finally, patients with allergic conjunctivitis present with red, watery eyes. The hallmark symptoms of allergy are itching and swelling. On exam you may see swelling around the eyes that we call “allergic shiners.” Patients often have a history of seasonal allergies and will usually present with other allergic symptoms such as a stuffy nose and cough. Treatment for allergic conjunctivitis involves avoidance of the offending allergens. These patients may need antihistamines, mast-cell stabilizers, and possibly steroids.



Why is that eye red?

The cause of conjunctivitis is not always apparent and it's sometimes impossible to determine the cause. Typically, you treat with cool compresses, Tylenol, and vigorous hand-washing. If you suspect bacteria, you treat with an antibiotic like erythromycin. Pathognomonic symptoms include:

1. **Viral:** watering, follicles, swollen lymph nodes
2. **Bacterial:** creamy discharge, unilateral
3. **Allergy:** bilateral itching and swelling

Blepharitis:

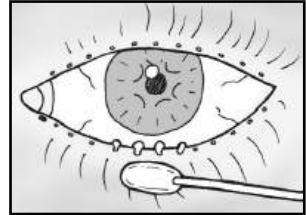
Blepharitis means inflammation (itis) of the eyelids (bleph), specifically the eyelid margin. This condition is a common diagnosis in an eye clinic, with patients complaining of stinging, tearing, and a “gritty” sensation in their eyes. Blepharitis has been classified many ways (seborrheic blepharitis, staphylococcal blepharitis, etc.) but I prefer to distinguish it as either:

A. Anterior blepharitis:

With these patients you’ll find a buildup of debris, or “scurf,” that form as collarets at the base of the eyelashes. Bacteria and irritants live in this debris and constantly shed irritants into the tear film. If severe, you can see small ulcerations and eyelash loss in affected areas.

B. Posterior blepharitis:

This is when the meibomian gland orifices clog up. When examining the eyelids, I always push on the lid edges with a Q-Tip. If pus-like material oozes out of the pores, then I know that the gland isn’t draining properly. I usually note this in the chart as MGD (meibomian gland dysfunction)



The primary treatment for blepharitis involves good lid hygiene. Most cases can be relieved in a few weeks by having your patient wash their eyelashes daily with baby shampoo and a washcloth. Warm compresses will also help as they open up the orifices of the meibomian glands. Tougher cases of anterior blepharitis may require topical antibiotics. You can also use oral doxycycline – which works not by its antibiotic effect, but by changing the fatty acid oil composition of the meibomian glands, allowing the fluid to flow better.

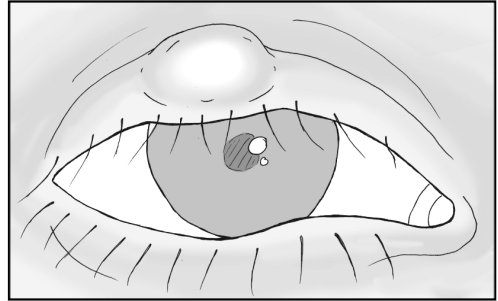
Blepharitis is common and a large percentage of patients seem to suffer from it. This is a chronic irritation such that compresses and lid scrub regimens may need to be continued indefinitely.

Fun Fact

In addition to long lashes, camels have an extra eyelid to protect their cornea from blowing desert sands. This extra eyelid is so thin that the camel can close the lid and still see through it - this is helpful when traveling through sandstorms.

Chalazion:

Chalazions are granulomatous inflammations of the **meibomian gland**. These glands produce the lipid component of the tear film and are deeply located within the supporting tarsal plate of the lid. Chalazions occur when meibomian gland pores become clogged (such as in blepharitis) -- lipid backs up into the gland, and a *noninfectious* inflammatory granuloma reaction occurs.



On exam, the patient will have a firm and mobile nodular bump on their eyelid. When you evert the lid, you'll often see this bump more clearly. They are non-tender and are not painful.

Early treatment involves warm compresses, massage, and lid scrubs in an attempt to reopen the meibomian pore and allow the material to flow out. If this doesn't work, we flip the lid and incise/drain the chalazion from the inner eyelid surface. Some people are more prone to developing chalazions and they tend to reoccur.

Chlamydial Conjunctivitis:

Chlamydia causes two different kinds of conjunctivitis: inclusion conjunctivitis and trachoma. Both of these infections are caused by different serotypes of chlamydia bacteria. We don't see either of these infections often, but they are a major cause of blindness in developing countries.

Inclusion Conjunctivitis:

Inclusion conjunctivitis is the typical "sexual" chlamydial infection of the eye that you're most likely to see here in the US. Patients present with a *chronic* conjunctivitis that has persisted for more than three weeks. As with other bacterial infections, the patient will have injection of the conjunctiva and purulent discharge. They may also show follicular "cobblestoning" that develops on the inner eyelids.

This infection occurs mainly in newborns or sexually active teens with a concurrent genital infection. Migration of the bacteria to the eye occurs from hand-eye transmission and can also spread person to person from shared cosmetics or from improperly chlorinated hot tubs. Newborns can also be infected while passing through the birth tract. The bacteria can be detected with a chlamydial immunofluorescence test or by culture of the conjunctiva. A Giemsa stain will show the classic basophilic inclusion bodies within epithelial cells.

Therapy involves topical antibiotics. Because the bacteria is usually contracted sexually, eyedrops alone won't address the entire problem so oral azithromycin is also given. Sexual partners also need to be treated. Newborns are also treated with systemic erythromycin to avoid chlamydial pneumonitis (chlamydia has a propensity for infecting mucous membranes).

Trachoma:

Trachoma is the "non-sexual" chlamydial infection of the eye that occurs in countries with poor sanitation. In less developed countries, trachoma is the leading cause of blindness. The chlamydia bacteria spreads through contact with family members, and can also spread within communities by flies and gnats.

The disease creates a long-lasting, chronic follicular conjunctivitis that eventually progresses to scarring of the eyelids. This scarring can close off the lacrimal gland pores and lead to chronic dry eyes. Scarring can cause the eyelids to rotate inward (entropion), and change the direction of eyelash growth - a condition called trichiasis. Constant rubbing of the lashes against the cornea leads to corneal scarring and eventually blindness.

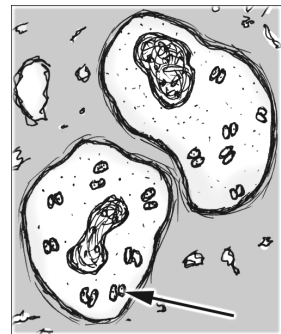
Gonococcal Infection:

While gonococcal infection is much rarer than chlamydial infection, it is very serious as gonorrhea can progress rapidly. These patients will present with redness of the conjunctiva and *profuse* mucopurulent discharge. This is a serious infection, as the organism can penetrate through a healthy cornea and perforate within 24-48 hours, leading to endophthalmitis and loss of the eye. The eye can also act as an entry portal for meningitis and septicemia.

With any severe and profuse exudate you should obtain scrapings and run a culture. A Gram's stain will reveal the hallmark gram-negative diplococci inside infected cells.

Drawing: Intra-cellular gram-negative diplococci, usually inside WBCs

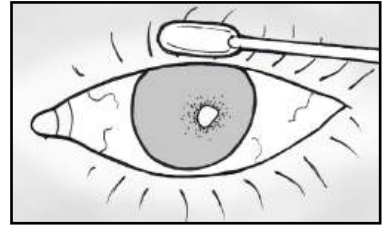
Because the infection advances so rapidly, treatment requires systemic coverage with a drug like ceftriaxone. Topical antibiotics can act as an adjunct but don't work well alone as the diffuse tearing washes the antibiotic away. If there is severe corneal involvement, or you are worried about your patient's compliance, you may need to admit them so they can be followed more closely.



Babies can contract gonococcal infection during birth -- this is why most states require they receive prophylactic silver nitrate or erythromycin ointment after birth. We use erythromycin here because silver is irritating and creates a temporary "chemical conjunctivitis."

Corneal Abrasions and Ulcers:

Corneal abrasions are very common and the most common consult that I get from the ER. Superficial epithelial defects can occur after trauma, infection, or from exposure. The cornea contains more nerve endings per area than anywhere else in the body, so scratches here are painful, and patients will often have photophobia (pain with bright lights) with the sensation that “something is in the eye.” Fortunately, with aggressive lubrication, the superficial epithelial layer heals quickly, literally within a day or two, and the patient feels better. We’ll often treat the eye with empiric erythromycin until the epithelium reforms.



If an epithelial defect has an associated bacterial infiltrate, this is called a *corneal ulcer*. Ulcers are treated aggressively with antibiotics and should be followed closely until the epithelial defect has closed. For straightforward, small ulcers, I typically use a fluoroquinolone like ciprofloxacin or moxifloxacin. If the ulcer is large, centrally located, or not healing, then we culture and tailor antibiotics accordingly.

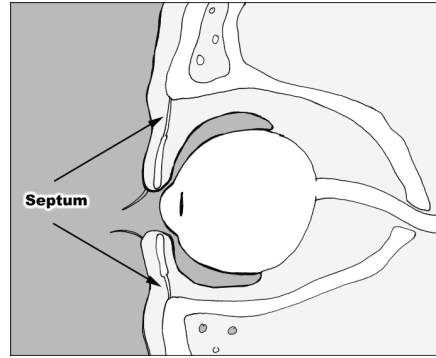
Dirty Contacts

Contact lens wearers are more likely to have a dangerous infection with *pseudomonas*. In these patients, we cover with ciprofloxacin. If the ulcer looks bad, they might need hourly fortified antibiotics (ex: vancomycin and amikacin). Also, we treat any “dirty” ulcer (i.e., caused by tree branch, fingernail, soil) with more aggressive antibiotics.

With sterile epithelial defects you can patch the eye to promote lubrication and speed healing. However, you *don't* want to patch an eye with a potential infection and you should follow patched eyes closely to make sure a perforating ulcer isn't brewing under that patch.

Pre- and Post-septal Cellulitis:

Patients may present with a swollen eyelid that appears to be infected (swelling, erythema, warmth, systemic fever). When approaching a patient with a taut, infected eyelid the important distinction you must determine is whether the infection is located pre- or post-septal.



The “septum” is a layer of connective tissue that runs from the tarsal plate of the eyelid to the surrounding orbital rim. Infections superficial to this septum can look bad, but generally resolve without problems. However, if an infection tracks back *behind* the septum, you’re in trouble and will need to admit the patient for IV antibiotics and possible surgical abscess drainage. Orbital cellulitis occurs most commonly from sinus disease, especially in children, with bacteria eroding through the thin ethmoid bone into the orbit. They can also arise from tooth abscess and even from fungal infections in patients who are immuno-compromised with glycemic problems.

Symptoms of post-septal orbital involvement are pretty obvious: soft-tissue swelling will cause proptosis and chemosis (swelling of the conjunctiva). Intraocular muscle inflammation causes decreased motility and painful eye movement. If the optic nerve is affected they’ll have decreased vision and possibly an APD.

Whenever you see a big swollen eyelid you should always check for these signs of post-septal involvement and if suspected, order a CT scan.

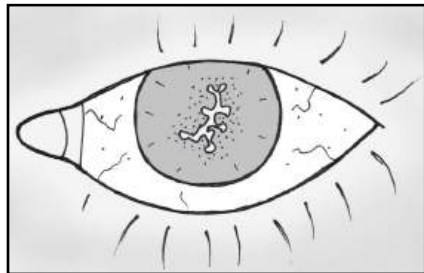
Herpes Simplex Virus:

Herpes infection around the eye is quite common - when herpes attacks the cornea, we call this “herpetic keratitis.”

Herpetic keratitis is caused by HSV Type-1. This is a common virus, and the vast majority of people contract it during childhood with almost 100% of people over 65 years with latent infection. The virus lies dormant in the trigeminal ganglion and can reactivate, causing cold sores in some people.

This reactivation can be triggered by fever, trauma, psychological stress, and UV sunlight. The factors leading to occurrence of the disease in the eye is unclear, though it may have something to do with the virus strain or the patient’s immune system.

Patients will present with a red, injected eye and complain of pain. Patients may



also exhibit the classical vesicular rash near the orbit. The infection almost always occurs in only one eye, though you can see bilateral cases, especially in atopic children. When examining these patients under the slit-lamp, you will see the classic “**dendritic ulcer**” that stains brightly with fluorescein. The initial infection typically involves only the superficial cornea and doesn’t lead to any long-term sequela. Unfortunately, the infection tends to reactivate. With repeat infections, the virus attacks deeper and deeper areas of the cornea and can lead to scarring if the corneal stroma is involved. Deep infection also kills the sensory nerves of the cornea. This decreases corneal sensitivity (you can check with a cotton-swab prior to anesthetic) and can give patients the false illusion that they are getting better.

Treatment is aggressive in order to avoid deeper penetration of the cornea. Debridement of the area with a cotton-tipped swab may help, and topical antiviral drops like Viroptic are always given. Acyclovir is often given orally, and continued prophylactic oral acyclovir may decrease the rate of recurrent outbreaks. I also treat nearby skin lesions with topical acyclovir - this topical drug doesn’t penetrate well into the skin, but may decrease viral shedding into the eye. Topical steroids *must* be avoided in the presence of epithelial defects, as steroids increase viral replication and can lead to a terrible geographic ulcer on the cornea. With significant corneal scarring, these patients may need a corneal transplant to regain sight.

AIDS and the Eye:

Nearly all AIDS patients develop a condition called **AIDS retinopathy**, a relatively benign state that is common with CD4+ counts below 200. On fundus exam, you’ll see cotton-wool spots (infarctions of the surface ganglion nerve layer), microaneurysms, and hemorrhaging. The cotton-wool spots are so prevalent that when finding these spots in a healthy patient without underlying diabetes or hypertension you should consider HIV testing. The mechanism behind AIDS retinopathy is unclear, but may result from immune complex deposition in the retinal vessel walls. While AIDS retinopathy doesn’t cause vision problems itself, its continued presence may indicate poor HIV control.

The **cytomegalovirus (CMV)** is the most common opportunistic infection of the eye and is the leading cause of blindness in AIDS patients. Most people contract CMV during childhood, developing a mono-like illness, and then go on to maintain lifelong immunity with viral suppression. However, the virus can reactivate in AIDS patients because of their decreased immune response. CMV reactivation typically occurs with CD4+ counts below 50; and the overall prevalence of CMV retinitis is rising as better prophylactic treatment for other deadly infections have allowed more AIDS patients to survive with very low CD4+ counts.

CMV typically attacks the retina and creates a necrotizing retinitis. Fundus exam shows peripheral areas of white retinal necrosis and associated

hemorrhaging. The infection is treated with antivirals like gancyclovir or foscarnet. These drugs are only virostatic, though -- they will suppress the infection, but won't eradicate the virus from the eye. Thus, antiviral treatment needs to be maintained to avoid reactivation. The antivirals can be given by IV (you will likely need to admit the patient for gancyclovir induction) with long-term oral maintenance. Also, after induction a gancyclovir implant can be placed inside the eye itself to allow a slow depot release of the drug.

AIDS patients are susceptible to many other eye infections, including herpes simplex of the retina, toxoplasma, zoster, and syphilis. Discussion of these infections is beyond the scope of this book, though, so let's move on.

Endophthalmitis

Endophthalmitis describes a serious infection *inside* the eye and is the dreaded complication we most fear after eye surgery. The eye contains delicate structures and is essentially a large cavity that can quickly turn into an abscess (an eyeball filled with pus). Endophthalmitis can occur for many reasons: after inoculation from trauma or even years after an uncomplicated eye surgery. It can also occur from endogenous infections elsewhere in the body.

While the cause of infection is not always obvious, the infection itself is easy to spot as the eye fills with hazy inflammatory cells and you often can't view the retina. The anterior chamber inflammation may be so bad that a layer of pus (called a hypopyon) forms along the bottom.

Treatment of these patients depends upon their vision ... typically, if they see hand motion or better, we perform a "tap and inject." This is where you put a needle into the eye to draw out a sample for culture and inject broad-spectrum antibiotics back into the eye. If the vision is "light perception" or worse you take the patients to surgery for a vitrectomy to manually clean the eye out. This is only a rule of thumb: the urgency of treatment is also dictated by the cause of infection, such that cataract-induced endophthalmitis is treated differently than glaucoma-surgery induced infection. No matter the cause, however, visual prognosis is universally poor.



"Gretel, do you think it's sanitary to eat the gingerbread out-house?"

Conclusion:

We could discuss many more eye infections, but these are the important entities to know for the wards and your boards. Some of these infections, like blepharitis and corneal ulcers, are very common and you will see these almost daily in an ophthalmology clinic. Others, like gonococcal keratitis and post-surgical endophthalmitis, are rarer, but important to recognize because of their devastating effects if not treated early.

Pimp Questions

1. A patient comes into your office in great distress because their eye looks incredibly red. On exam, you see they have a spot of hemorrhage under the conjunctiva. Is this a problem and should they be worried?

A few drops of blood spread under the conjunctiva looks impressive and can be alarming. Subconjunctival hemorrhage occurs when a conjunctival blood vessel “pops,” usually after a valsalva or when bending over. This is generally benign as the blood will go away in a few weeks. If the hemorrhage is recurrent, though, start thinking about bleeding disorders.

2. What antibiotic would you use for a small corneal ulcer in a contact lens wearer?

While most small ulcers can be treated with erythromycin, you must worry about pseudomonas in contact lens wearers. Treat all CL wearers with ciprofloxacin or moxifloxacin. If the ulcer is large, jump right to fortified antibiotics like vancomycin and tobramycin.

3. Can you patch an eye to promote healing and comfort? Are there situations where you’d avoid patching?

You can patch an eye with an epithelial defect as patching makes the eye feel better and may speed up surface healing by decreasing exposure. However, you definitely don’t want to patch the eye if there is any chance of infection. Thus, you shouldn’t patch anyone with bacterial infiltrate, contact lens, or trauma by “dirty material” such as from vegetable matter, animals, or dirt.

4. What are the three kinds of conjunctivitis? How do you differentiate them on history and physical exam?

The cause of a conjunctivitis is not always obvious. Generally you'll see the following classic findings:

Viral	watery discharge, follicles, enlarged nodes
Bacterial	mucous discharge, often unilateral
Allergic	bilateral itching and swelling

5. What's the most common cause of conjunctivitis? How do you treat it?

Viral conjunctivitis, usually caused by adenovirus, is the most common cause of pink eye in the adult. Adenovirus also causes cold symptoms (rhinovirus actually causes the majority of colds) and these patients will often describe concurrent respiratory illness. You treat these patients supportively with cool compresses, Tylenol, and chicken soup. Warn the patient that they are contagious and encourage them to wash their hands, don't share towels, and throw out their makeup.

6. What's our favorite diagnosis in the eye-clinic (good for explaining chronically irritated, grainy-feeling eyes with stinging and occasional watering). How do you treat it?

This sounds like blepharitis, which, along with dry eye is probably the most common diagnosis in an eye clinic. You treat blepharitis with artificial tears, warm compresses, and lid scrubs. If this doesn't seem to be working, you can try topical erythromycin or oral doxycycline (don't use in kids or pregnant women).

7. What's a chalazion, sty, and hordeolum? How do you treat them?

A chalazion is a non-infectious granulomatous inflammation of a meibomian gland sitting in the tarsal plate (see the anatomy chapter). A sty is like a pimple at the lid margin, usually at the base of an eyelash. A "hordeolum" is a general term that describes an "inflamed gland." It is debatable what this means, so I don't like to use the term "hordeolum" myself but you may run across it.

8. What are the signs/symptoms of herpetic keratitis? How do you treat?

The hallmark of herpetic infection is the classic dendritic ulcer. You treat with oral acyclovir and topical antiviral drops such as Viroptic.

9. You suspect a patient of having a herpetic corneal infection, based on the shape of her epithelial defect, and you are concerned about corneal scarring. Can you use a steroid to decrease inflammation and the resulting scarring?

You should NEVER use a steroid drop in herpetic disease if there is still an epithelial defect, as this will cause the virus infection to worsen and develop into a terrible “geographic ulcer.” You use topical antivirals like Viroptic and oral acyclovir and wait until the epithelium has healed before considering steroids to decrease scarring.

10. Are eyes with herpetic keratitis more or less sensitive to touch?

These eyes are less sensitive to touch as the virus kills the corneal nerves. When HSV is suspected, we check corneal sensitivity with a cotton swab or a monofilament prior to anesthetic. Eye sensitivity is an important component of the protective blink reflex.

11. What’s the difference between a corneal abrasion and a corneal ulcer?

A corneal ulcer is an abrasion PLUS an infectious infiltrate. Ulcers require antibiotic coverage and possible culturing depending upon the severity, size, and location of the lesion.

12. A 21 y.o. man presents with a grossly swollen eyelid – a few days before he had a pimple that his girlfriend popped with nail clippers. Since then his eyelid has swollen, with redness, mild warmth and tenderness to touch. What specific findings would make you concerned for deeper involvement.

This patient sounds like he has an infection of the eyelid. The question is whether he has any post-septal involvement (i.e., orbital cellulitis). You need to check for decreased vision, proptosis, chemosis, decreased eye motion, and pain with eye movement. These findings would suggest a dangerous orbital infection with the need for admission, imaging, abscess drainage, etc..

13. You are considering doxycycline therapy for a patient with blepharitis. What should you warn your patient about this medication?

Doxycycline is not the easiest medication to take! It is inactivated by milk and your patient may be more susceptible to sunlight and be more prone to sunburn. This medication shouldn’t be used in children or breast-feeding women. Finally, tell your patient to avoid using it at bed-time – the tablet can get caught in the esophagus or stomach and ulcer through overnight.





Chapter 6

Neurology

The Eyes Have It

by Tim Root



deformation from an overlying lid lesion or after surgery with tight corneal stitches through the cornea. Other causes of monocular diplopia include cataract irregularities, lens displacement, or primary problems with corneal curvature such as keratoconus.

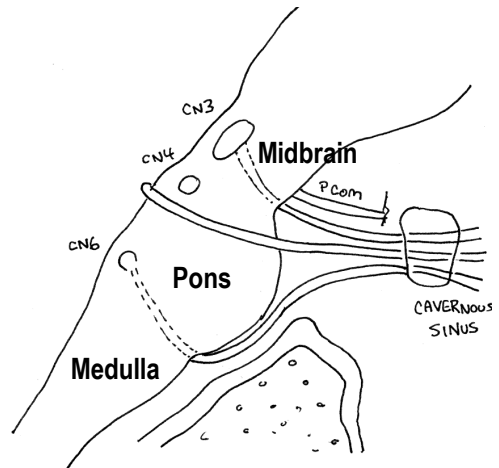
Binocular diplopia, on the other hand, occurs when the eyes do not move in synchrony with each other. This can occur from nerve lesions (a palsy of CN3, CN4, or CN6), extraocular muscle abnormalities (such as the muscle-fibrosis that occurs with Grave's Disease), or derangements at the neuromuscular junction (myasthenia gravis). Let's explore the cranial nerve palsies first.

Cranial Nerves and EOMs

Three cranial nerves control the movement of the eyeballs. The relationships between these muscles can be quite complex as the eyeballs are neurologically "yoked" together and every muscle has multiple vectors of force, depending upon the direction that the eye is looking. In other words, nerve palsies can be challenging to figure out!

There are numerous causes for the individual nerve palsies, including microvascular disease, strokes, tumors, and aneurysms.

You may not be up-to-speed on your neuroanatomy, so I've drawn this cartoon picture of the brainstem for you to reference over the next few pages.



Third Nerve Palsy

Oculomotor nerve palsy is the easiest cranial nerve loss to detect because a complete third nerve palsy looks dramatic. The majority of the extraocular muscles are innervated by CN3, so when knocked-out the eye deviates down and out because of the still functioning abducens and superior oblique muscles. In addition, the levator palpebrae (the main lid retractor) is innervated by CN3 and its paralysis gives you a severe eyelid ptosis. Finally, the parasympathetic pupil-constrictor fibers from the Edinger-Westphal nucleus travel within CN3, and their loss gives you a "blown pupil."

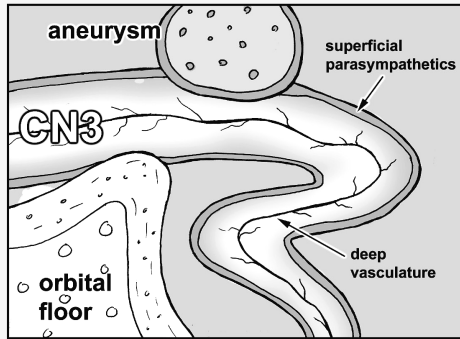


Most third nerve palsies are caused by ischemic events at the nerve secondary to hypertension or diabetes. The one thing you really need to worry about in these patients is a compressive aneurysm pushing on the nerve. These aneurysms occur at the junction of the posterior communicating artery and the internal carotid artery. Compressive lesions usually affect the parasympathetic nerve component: a blown pupil is a potential emergency. Whenever you have pupillary involvement, you need an MRI and angiography to rule out a dangerous aneurysm or tumor.

Pupil Involvement

Oculomotor palsies often have pupillary involvement because the parasympathetic nerves innervating the iris travel with the third nerve. Pupillary involvement is a crucial diagnostic sign -- compressive lesions tend to involve the pupil, while vascular lesions might actually spare it! This picture isn't drawn to scale, but graphically demonstrates what I'm talking about.

As you can see, the parasympathetic nerves course along the surface of the oculomotor nerve making them susceptible to compressive lesions from the outside such as an aneurysm from the posterior communicating artery, bony structures, or the uncus portion of the temporal lobe. Ischemic lesions (caused by HTN and diabetes) occur deeper within the oculomotor nerve and thus spare the superficial parasympathetic fibers.



If you have a patient with CN3 loss and pupillary involvement you should order an MRI and an angiogram to look for the compressive site. If there isn't pupillary involvement, they are probably suffering from a vaso-occlusive problem, so you should check their glucose and blood pressure.

Abducens (VI):

The abducens nerve controls the lateral rectus muscle. Loss of CN6 renders the eye unable to abduct (turn out). Patients will go cross-eyed, so to compensate they may turn their head to avoid double vision.

If you look back in that drawing of the brainstem, you'll see that the abducens nerve is located further down the brainstem, "all by its lonesome" down in the



pons. The nerve root exits the brainstem even further down at the pontomedullary junction and has to run up the floor of the skull to get to the cavernous sinus and into the orbit. Where the nerve enters the cavernous sinus, it makes an abrupt 90-degree bend. Something about this abrupt turn makes the 6th nerve especially susceptible to high intracranial pressure. Patients with high ICP from pseudotumor cerebri commonly have their 6th nerve(s) knocked out – abducens palsy is actually incorporated into the Dandy criteria for diagnosing PTC.

Fun Fact

Crocodiles shed tears, but this isn't a sign of grief. These secretions help shed salt-water from the eye. Thus, the term "crocodile tears" is used to describe false tears. In ophthalmology, we use the term to describe aberrant regeneration after 7th nerve injury - nerves that normally control salivation are routed to the lacrimal gland. This makes you "cry" when you see food. This can be treated by injecting botox into the lacrimal gland.

Aberrant regeneration occurs with other cranial nerve palsies as well -- the most commonly seen is after a 3rd nerve palsy. As the oculomotor nerves grow back to their target muscles they can get mixed up. For example, a patient could look medially (activating their medial rectus) and their eyelid can shoot up (inappropriate co-contraction of the levator palpebrae).

You only get this kind of synkinesis with trauma or mass lesions that disrupt the nerve sheath. Microvascular events occur deeper in the nerve and don't cause aberrant regeneration. If you find aberrant regeneration in a patient you previously assumed was from diabetes, you better get imaging to rule out something more dangerous.

Trochlear Nerve (IV):

The trochlear nerve (CN4) innervates the superior oblique muscle. Trochlear paralysis is the hardest cranial nerve palsy to diagnose and many ophthalmologists and neurologists will miss these! These patients have an upward deviation of the affected eye and a "cyclotorsion" twisting of the eye that makes them tilt their head away from the lesion. Don't try to memorize these deviations: in a few paragraphs I'll cover the anatomy of the superior oblique muscle which will make it easier to conceptualize these findings.



A trochlear nerve lesion is caused by either trauma, an ischemic event, or can be congenitally present with later decompensation. The fourth cranial nerve is the skinniest nerve and runs the longest distance inside the cranial vault. This long passage makes it more susceptible to injury if the brain

sloshes around and bounces against the tentorium. The fourth nerve is also susceptible to being pulled from the root where it exits from the back of the brainstem. The long course also makes it susceptible to neoplasm. If we break down trochlear palsy by cause:

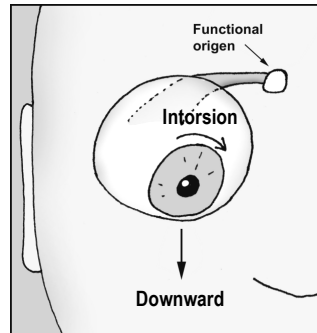
- 1/3rd Trauma
- 1/3rd Congenital
- 1/3rd Ischemic (diabetic)
- 1/3rd Tumor

That's a lot of thirds, I know. That's because reports differ depending upon what age-group you look at: certainly more 4th palsies occur in elderly males from trauma and more congenital palsies are found in the pediatric population. Ask about history of closed-head injuries and check old photographs for head-tilt - this would indicate an old/congenital palsy that has recently decompensated.

Trochlear Muscle Action:

The superior oblique muscle runs from the back of the eye socket, forward through a trochlear "pulley" located next to the upper nasal bridge, before turning back and inserting at the back of the eye. This pulley system completely changes the direction of force of the superior oblique ... you can think of the trochlear pulley as the "functional origin" of this muscle.

As you can see in this picture, the superior oblique muscle inserts onto the back of the eyeball and then yanks the eye into downward gaze. There is also an intorsional component that rotates the 12-o'clock corneal limbus towards the nose. Loss of this intorsion explains the head-tilt these patients develop.

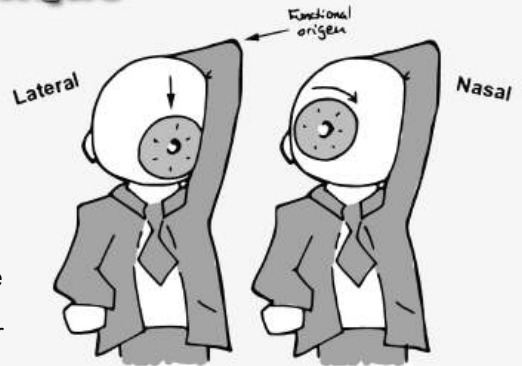


The Superior Oblique

To simulate the action of the superior oblique, you can pretend that your head is a large eyeball. Throw an arm up and wrap it around the back of your head.

Your elbow becomes the trochlear pulley ... if you pull your arm, you're whole head should twist. The direction of head movement, either up-down or rotational, will depend upon which direction you're looking when you start pulling.

The same action occurs in the eyeball, such that your patient will see vertical diplopia when looking medially toward the nose (such as when reading a book) and will see more rotational doubling when looking to the side. Think about that one for a minute!



Summary of the EOMs:

Beyond the information we just discussed, there isn't much to localizing a cranial nerve lesion. Just think about the anatomy: if a single nerve is affected, then you know the problem is somewhere along that nerve's tract. If all three nerves are knocked out, then the lesion is probably near the cavernous sinus where the three nerves are bunched together.

The number one reason that any of the cranial nerves get knocked out is from a vasculitic event, usually from diabetes. Many of these isolated cranial nerve palsies don't need imaging - such as an isolated 6th nerve palsy in an elderly diabetic. However, you don't want to miss an aneurysm or mass lesion, so no one will fault you for over-imaging. Here are the high-yield facts you should know:

CN3: The eyes are “down and out” with a droopy eyelid. Think of an aneurysm if the pupil is blown.

CN4: Patient tilts their head away from the lesion. Think of trauma or a congenital head-tilt that has decompensated with age.

CN6: The patient looks “cross-eyed.” Consider increased intracranial pressure.

Myasthenia Gravis:

Myasthenia gravis is a rare autoimmune disease in which the body develops autoimmune antibodies to the nicotinic acetylcholine receptors located at the neuromuscular junction of striated muscle. This leads to fatigable muscles and often involves the eye, causing diplopia and ptosis.

MG patients develop autoantibodies that actually bind to the receptor and block the receptor binding sites. This eventually destroys the receptor entirely, leaving patients with decreased numbers of working Ach receptors. Once the number drops below 30% normal, then the patient becomes symptomatic and easily fatigued. Interestingly, only striated muscle is affected, as both smooth and cardiac muscle appear to have different antigenicity and are unaffected with this disease. The bulbar muscles, however, are quite susceptible, and the majority of patients with MG have ocular complaints. The ophthalmologist is often the first doctor to diagnose this disorder.

The diplopia and ptosis is usually worse on prolonged upgaze: you can test this by having your patient look at your raised finger to see who tires out first. More definitive diagnosis can be made via the Tensilon test where you give edrophonium chloride (an anticholinesterase) and look for an improvement in symptoms as their Ach levels build up. We don't actually do this test in our office because of the difficulty of starting IV lines and potential toxic reactions such as sweating, salivation, bronchospasm, and bradycardia. More commonly we'll perform a rest-test or ice-test where you have the patient hold an icepack over their closed eyes and then remove it and look for improvement. Neurology can also perform EMG studies and other labwork to help you with this diagnosis.



Systemically, these patients can have problems with mastication, talking, drinking, and swallowing. Aspiration pneumonia and respiratory failure from inability to clear secretions is the big killer with this disease. Remember, if your patient has MG, work them up for a thymoma and check their thyroid levels.

Neuritis and Neuropathies of the Optic Nerve

Personally, I always found this topic confusing because the terms "optic neuritis" and "optic neuropathy" sound very similar. After all, what's the difference between an "itis" and an "opathy?" There's really only three main optic-nerve entities that I think you need to be aware of, and each has a slightly different presentation and mechanism:

1. ON (Optic Neuritis)

An “inflammation” of the nerve, often demyelinating. The cardinal signs in these patients are decreased vision (especially color vision), pain with eye-movement, enhancement of the optic nerve on MRI, and potential association with multiple sclerosis. This occurs in younger patients.

2. ION (Ischemic Optic Neuropathy) ... sometimes called NAION (non-arteritic ischemic optic neuropathy)

This is a localized ischemic event at the junction of the optic nerve as it enters the back of the eyeball. This portion of the optic nerve has no elastic “give” and a small vascular insult here can lead to swelling and vision loss. The hemispheric vascular supply to the optic nerve head usually generates an altitudinal visual defect. This entity usually occurs in middle-age in those with a predisposed crowded optic disk (the so-called “disk at risk”).

3. GCA (Giant cell arteritis) i.e., temporal arteritis

Temporal arteritis occurs as a result of a vasculitis within the medium and small-sized arteries around the head. The vasculitis can lead to a sudden occlusion of the blood supply to the eye leading to sudden and permanent vision loss. This happens in older patients, usually over 70 years of age.

Let’s explore each of these entities in more detail ...

Multiple Sclerosis and Optic Neuritis:

Multiple sclerosis is a demyelinating disease of the CNS that is classically described as “lesions occurring at different times and different places.” It occurs most commonly in young white women from northern climates. If the lesion hits the optic nerve, then we call this finding optic neuritis. About 90% of patients with multiple sclerosis will develop optic neuritis at some point, and conversely, patients with “optic neuritis” sometimes progress to develop multiple sclerosis. Think about that one for a moment!

Signs and symptoms of optic neuritis include:

- Sudden vision loss (central scotoma is classic)
- Decreased contrast and color sensitivity
- Pain with eye movement
- Optic nerve head edema
- Afferent pupillary defect

A patient with optic neuritis needs an MRI of the brain and orbits to look for enhancing lesions. The more demyelinating lesions found on imaging, the higher the chance of later developing multiple sclerosis. Patients with optic neuritis are treated with IV steroids, which will speed recovery, but won’t

ultimately affect the outcome of the disease. **WARNING:** You treat with IV steroids only, as *oral* steroids may actually increase the occurrence of MS! If enhancing lesions are found in the brain, then you can get neurology involved to discuss possible treatment with interferons like Avonex to decrease progression.

Fun Fact

People blink, on average, once every 5-6 seconds.
Women blink almost twice as often as men.

Temporal Arteritis:

Temporal arteritis (also known as giant cell arteritis) is an important syndrome to keep in the back of your head. While not terribly common, you might save a patient from complete blindness or death if you treat them appropriately.

Temporal arteritis is an inflammation that affects the medium-sized blood vessels. This disease process is similar to polymyalgia rheumatica except that the vasculitis affects the arteries supplying the head, face, and eyes. If the blood supply to the eye is affected, then patients can have catastrophic vision loss. These patients are almost always *older* (over 60 and more commonly over 80 years of age) and present with sudden, painless vision loss. Other preceding systemic complaints (these are pathognomonic) include:

- Scalp tenderness and headache
- Jaw claudication
- Polymyalgias of the arms and shoulders
- Fevers, night sweats, weight loss

If you suspect GCA you need to order an ESR and CRP as these are sensitive markers for inflammation. Normal ESR is approximately half the patient's age (i.e., an 80-year-old man can have ESR up to 40).

Unfortunately, these labs aren't very specific and more definitive diagnosis is made via a temporal artery biopsy (dissect out the artery at the temple and send it to pathology). On pathology you'll find disruption of the internal elastic lamina and occasionally giant cells (the presence of these cells isn't actually necessary for the diagnosis).


You treat temporal arteritis with steroids to decrease inflammation. While steroids won't regain lost vision, they will decrease potential vision loss in the remaining eye, which can be affected within days. Unfortunately, steroids also decrease the diagnostic yield on your biopsy. This places you in a pickle: do you hold off steroids until after the biopsy, or start steroids and

potentially alter your biopsy results? The answer is that you start the steroids immediately to keep the other eye from being affected. You don't want to blind your patient - the biopsy can be delayed for up to two weeks and still be ok, despite the steroids.

The Pupil

The pupil is controlled by a steady balance between the parasympathetic (which constricts the pupil) and the sympathetic input (which dilates the pupil). I remember this with the mnemonic:

“If a grizzly bear attacks me in the dark woods, my sympathetic fight-or-flight reflex dilates my eyes so I can see better as I run away.”

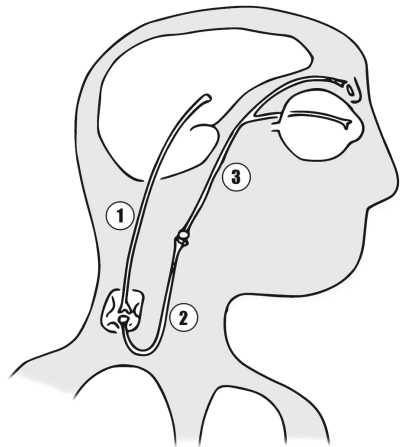


Horner Syndrome

Horners occurs when the sympathetic pathway gets knocked out. Without sympathetic input to the pupillary dilator muscles, the pupil constricts and stays small. Sympathetic loss also creates a mild ptosis from decreased Muller's muscle action in the eyelid and scalp anhidrosis (decreased sweating) on the affected side. As you can see in the picture below, the sympathetic chain is long, complex, and can be damaged at many levels. To localize the lesion we use a series of eyedrops:

Cocaine Test

The first test we perform is the cocaine test - just to decide if this patient REALLY has a Horner's pupil or not. Cocaine stimulates pupillary sympathetics by decreasing norepinephrine uptake at the synaptic cleft. If a patient (a Horner's patient) has no sympathetic tone inside the eye, then cocaine won't have any norepinephrine to build up and thus has no effect on that eye. However, the good eye will dilate like the dickens! It's not always easy to obtain cocaine in private practice, but you should be able to get some in most hospitals as ENT people use it to control nose bleeding during surgery.



Paradrine Test

Now that we know there's a sympathetic palsy, we need to localize the lesion. There are three neurons in the pathway from the brain... just like the motor-innervation throughout the rest of the body. Unlike a leg muscle, however, we can't check the pupillary reflex by hitting it with a hammer. We *can* stimulate that final 3rd order nerve by pharmacologically hammering it with hydroxyamphetamine. This drug forces the end-nerve to fire-away at the pupil. If that pupil *still* won't dilate, then you know the final "lower motor neuron" is dead. If the pupil DOES dilate, then you must have a "higher order" nerve that's out - lots of bad things can occur along this upper-pathway (carotid dissections, pancoast tumors, etc.) so proceed to imaging.

This pharmacological testing is a convoluted topic, and you'll find it difficult to really remember these drops until you see your first Horner's patient. One catch phrase you should remember, though: if a patient complains of a painful Horners think of a carotid dissection and move quickly to rule out this diagnosis.

Adie's Tonic Pupil

An Adie's pupil is the opposite of a Horner's - the *parasympathetic* (constrictor) pathway gets knocked out on its way to the iris sphincter muscles. On exam, the eye looks dilated and doesn't constrict to light (we're blocking the parasympathetic pathway from the Edinger-Westphal nucleus). The pupil will constrict with near vision, but very slowly. That's why we call it a "tonic pupil" - it's tonically slow.

Fortunately for us, the parasympathetic pathway is much shorter than the convoluted sympathetic pathway, so potential causes for damage are more benign. The parasympathetic plexus sits right behind the eye and can be damaged after an otherwise benign viral infection.

Pimp Questions


1. You have a patient with diplopia. His left eye is turned down and out and his lid is ptotic on that side. What nerve do you suspect and what should you check next?

This sounds like a CN3 palsy, and you should check his pupillary reflex. Pupillary involvement suggests the lesion is from a compressive source such as an aneurysm.

2. Why do diabetic patients with oculomotor paralysis have “sparing of their pupil”?

The pupil is typically spared with ischemic third nerve palsies caused by vascular problems. This is because the parasympathetic pupillary fibers run along the surface of the nerve, making them susceptible to aneurysm/tumor compression but resistant to deeper infarction.

3. This 32 year old overweight woman complains of several months of headaches, nausea, and now double vision. What cranial nerve lesion do you see in this drawing. What other findings might you expect on fundus exam and what other tests might you get?



This looks like a bilateral abducens palsy as the patient can't move either eye laterally. While the majority of abducens palsies occur secondary to ischemic events in diabetics and hypertensives, this etiology seems unlikely in a young patient with bilateral involvement. Her symptoms sound suspicious for pseudotumor cerebri (obese, headaches). You should look for papilledema of the optic nerve, get imaging, and possibly send her to neurology for a lumbar puncture with opening pressure.

4. A patient is sent to your neurology clinic with a complaint of double vision. Other than trace cataract changes, the exam seems remarkably normal with good extraocular muscle movement. On covering the left eye with your hand, the doubling remains in the right eye. What do you think is causing this diplopia?

The first question you must answer with any case of diplopia is whether the doubling is monocular or binocular. This patient has a monocular diplopia. After grumbling to yourself about this inappropriate neurology referral, you should look for refractive problems in the tear film, cornea, lens, etc.

5. A patient complains of intermittent double vision that seems to be worse in the evenings. On exam you find a confusing diplopia that doesn't seem to map out to any particular nerve palsy. What else is on your differential as a cause, and what tests might you perform in the office?

Myasthenia gravis and thyroid orbitopathy are both great masqueraders that cause diplopia. Graves patients often have lid retraction and reduced upgaze from inferior rectus muscle restriction. The double vision in myasthenia patients can look like an isolated nerve palsy, a mixture of nerve involvement, or may not fall into any specific nerve combination - a changing palsy is more indicative of a process like MG. You can check for fatiguable ptosis by prolonged upgaze (hold your arm up and see who gets tired first). In addition, you can perform a cold-pack rest test or even a Tensilon test.

6. You are giving a tensilon test to a suspected myasthenia gravis patient and he collapses. What do you do?

Your patient may have a reaction to the anticholinesterase such as bradycardia or asystole. You should have a crash-cart handy and administer atropine. Hopefully, this scenario never happens to you. In this day and age, few ophthalmologists perform the tensilon test, reserving this for neurology (who more often perform EMG studies).

7. A patient with diplopia is finally diagnosed with myasthenia gravis after a positive ice-pack test and a positive acetylcholine receptor antibody test. What else should you work up this patient for.

You should check for a thymoma, which is highly associated with MG. Also, check their thyroid level as 20% of myasthenia patients also have Grave's disease.

8. A 26 year old woman presents with decreased vision in her left eye that has gotten progressively worse over the past week. The eye seems to ache and the vision worsens with exercise. On exam she is found to have 20/200 vision, trace APD, and markedly decreased color vision in the affected eye. The optic nerve is mildly swollen on that side. What does this patient most likely have?

This patient's age, color vision, and progression are all classic symptoms of optic neuritis. She also describes the classic Uthoff phenomenon of worsening symptoms with increased body-temperature (exercise or shower). Many of these patients describe minor pain with eye-movement; the optic nerve is inflamed and any tugging on the nerve with eye movement is going to irritate it.

9. A patient develops optic neuritis. Should you treat with steroids? Would you start with IV or oral steroids? Will the MRI findings of numerous demyelinating lesions change your management? Do you tell the patient that she will develop MS?

The ONTT study has shown that steroids can speed recovery from optic neuritis, but have little effect on long-term visual outcome. Surprisingly, the study also showed that oral prednisone may actually increase reoccurrence of optic neuritis. Therefore, you give IV Solu-Medrol and *don't* give oral prednisone!

The presence of optic neuritis does not necessarily mean the patient will develop multiple sclerosis, especially in the setting of a negative MRI. The patient's long-term risk for developing multiple sclerosis depends upon the number of CNS lesions found on presentation. If there are no CNS lesions, then the future risk is only about 15%. This jumps up to 50% or more with 3+ lesions. In these higher-risk patients, you should get neurology involved to discuss more aggressive treatment with Avonex.

10. An 84-year-old man was out golfing with his buddies and developed sudden vision loss in his right eye. He has no past ocular history, no medical problems. No complaints of flashes or floaters, just that things "look dimmer" in his right eye. What other questions should you ask about his symptoms?


There are many questions you should ask ... but with any elderly person with vision loss, be sure to ask about the symptoms of temporal arteritis. Specifically, scalp tenderness, jaw claudication, and polymyalgias (muscle aches in the shoulders and arms). This sounds like a central retinal artery occlusion, and in a patient this old you need to rule out life- and vision-threatening causes like GCA (giant cell arteritis).

11. The previous patient admits to “not feeling good” and “it hurts my head to brush my hair on the right side” for the past week, but denies all other symptoms. Should you order any labs? Start any medications?

If you have any suspicion for GCA, you pretty much *have* to order a ESR and CRP. Start oral prednisone (about 1mg/kg/day) immediately and set up for temporal artery biopsy within a week or so. Steroids won't help much with his lost vision in these cases, but decreases the risk to the other eye, which can be affected within hours to days.

12. A young man complains of complete vision loss (no light perception) in one eye, however, he has no afferent pupil defect. Is this possible? How might you check whether this patient is “faking it?”

Assuming the rest of the eye exam is normal (i.e., the eye isn't filled with blood or other media opacity) this patient should have an afferent pupil defect if he can't see light. There are many tests to check for malingering and factitious disorders: you can try eliciting a reflexive blink by moving your fingers near the eye. One of my favorite techniques is to hold a mirror in front of the eye. A seeing eye will fixate on an object in the mirror. Gentle rocking movements of the mirror will result in a synchronous ocular movement as the eye unconsciously tracks the object in the mirror.



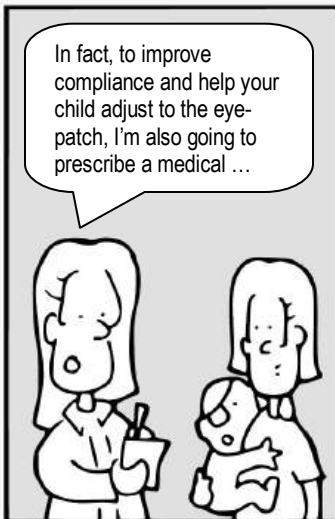
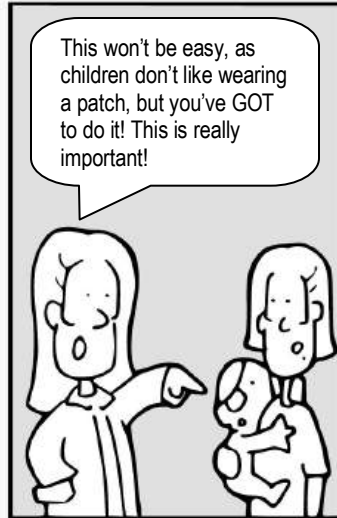What so funny?

Chapter 7

Pediatrics

The Eyes Have It

by Tim Root



Pediatrics

by Tim Root, M.D.

Pediatric ophthalmology is a fascinating field, but can be frustrating for many doctors because children are hard to examine. Despite this challenge, pediatrics is rewarding and is one of my favorite subspecialties.

Famous Quotes

Children today are tyrants. They contradict their parents, gobble their food, and tyrannize their teachers.

Socrates (470-399 B.C.)

The Pediatric Exam:

Examining kids is a difficult prospect, as children are moving targets and universally hate strangers messing with their eyes. You have limited time before your child further decompensates, so it's important to hone in on any eye problems quickly.




Vision testing also depends upon the age of your patient. Young babies may only blink-to-light, but as the child gets older they start to track faces, and eventually identify pictures. It's hard to measure quantitative vision in the young, so focus on *asymmetry* between the eyes. For example, cover each eye and watch how the child reacts and tracks. If a baby is fussier with a particular eye covered, then you may be covering his only good eye! Also, toddlers will cheat when covering the eyes, so watch them closely!

Refractive Error

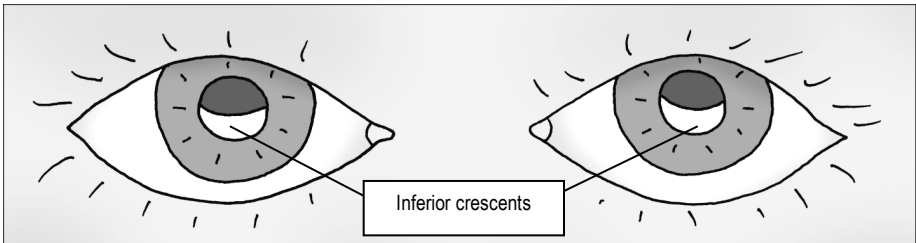
Determining a child's refractive error is even more challenging ... how can you tell if a child is myopic or hyperopic when they can't read the eye chart? Here's how we do it:

Bruchner Test:

One quick method to estimate refractive error is by examining the red-reflex (the red-eye you get in photographs). Hold a direct scope from a distance and shine it so that the circle of light lights up both pupils at the same time.



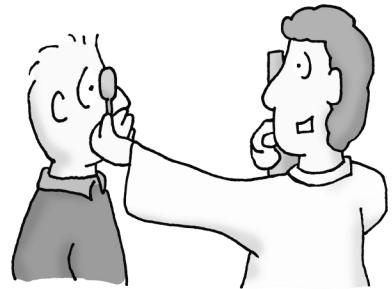
Examine the red-reflex from each eye. Assuming that the child is looking right at you, the placement of the red-reflex gives some clues. Inferior crescents, such as in this drawing, indicate myopia (near-sightedness) while superior crescents indicate hyperopia.



Most children have some degree of hyperopia, as their eyes are small and still growing. This makes the Bruchner test more useful for picking up myopic (near-sighted) errors, but overall the test isn't very accurate in undilated children as they have the ability to accommodate. Also, if the eyes are not well aligned, such as strabismus, the results are inaccurate.

Retinoscopy

Retinoscopy is a much more accurate way to check prescription, and is how we refract all pre-verbal children for glasses. By flashing a beam of light back-and-forth into the eye we can examine how the light bounces off the retina. By holding different power lenses in front of the eye we can figure out what power lens focuses the light properly and neutralizes the red-reflex. This is a difficult skill to learn, but surprisingly useful, even outside of the pediatric realm.



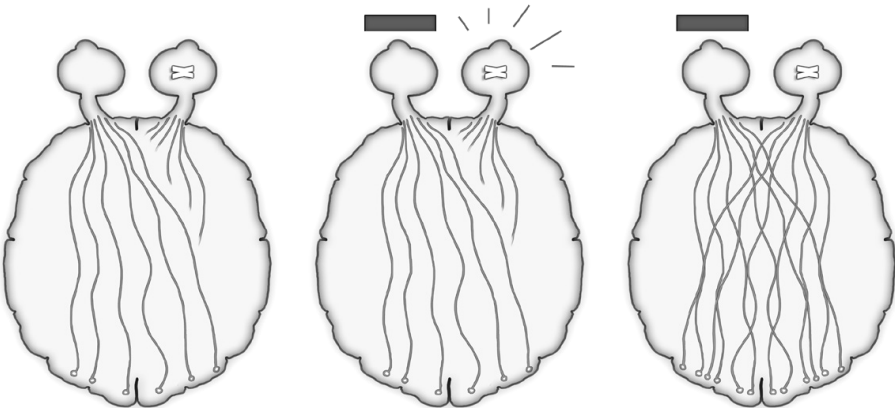
Amblyopia (a.k.a., "lazy eye"):

Amblyopia is decreased vision in an eye because of disuse of that eye during childhood development. The prevalence in the USA is 2-5%, the major risk factors being prematurity, developmental delay, and a family history.

The visual pathway is a plastic system that continues to develop during childhood until around 6-9 years of age. During this time, the wiring between the retina and visual cortex is still developing. Any visual problem during this critical period, such as a refractive error or strabismus (misaligned eyes) can mess up this developmental wiring, resulting in permanent visual loss that can't be fixed by **any** corrective means when they are older.

Competitive Wiring!

If you don't use an eye, the nerve fibers from that eye don't develop ... in fact, the eyes are in **competition** with each other. The afferent nerve connections of the strong eye become numerous while the weak (unused eye) nerves atrophy and decrease in number. In animal studies, occlusion of one eye leads to loss and atrophy of cells in the LGN (lateral geniculate nucleus) associated with that eye.



The wiring doesn't form for the poor-seeing eye

Patch the good eye to force the "lazy eye" to work

Wiring forms properly and visual potential is restored

Fortunately, the situation can be reversed. Penalizing the strong eye, with the use of patches or eyedrops that blur vision, gives the weak eye a competitive advantage and time to re-grow its afferent nerve connections. This regrowth potential decreases with age, and once a child reaches 7-10, very little can be done to improve the amblyopic eye.


How to Detect:

As you can imagine, you want to pick up amblyopia at an early age. Unfortunately, it is exactly these younger children whose vision is most difficult to check. Pediatricians always check vision as part of a well-baby exam, and schools perform vision screenings – but vision assessment in children is tricky, even for trained ophthalmologists. We get many false-positive “poor vision” referrals from these sources, but that’s ok, because early detection is important!

Fun Fact?

The word “lens” is named after the lentil plant (greek name *Lens culinaris*) whose 2 – 9 mm disk-shaped seeds bear a remarkable resemblance in size and shape to the human lens.

The lentil legume was one of the first agricultural crops and was grown over 8,000 years ago. Introduced in the U.S. during the early 1900’s, the “lentil bean” is grown in drier Washington, Idaho, and Western Canada and the seeds can be used in soups, stews, casseroles and salad dishes.



Strabismus:

Strabismus describes when the eyes are not aligned with each other, such as when an eye is turned in (cross-eyed or esotropic) or turned out (wall-eyed or exotropic). Here are some terms we use in ophthalmology to describe misalignments:

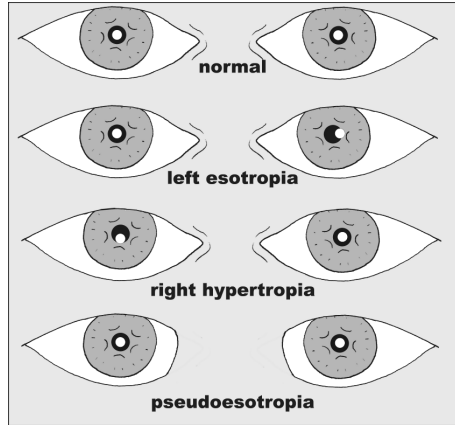
Esotropia (ET): The eyes are turned inwards (cross-eyed) all the time.

Exotropia (XT): The eyes are turned outwards (wall-eyed) all the time.

Eso/Exo-phoria: Phorias are eye deviations that are only present some of the time, usually under conditions of stress, illness, fatigue, or when binocular vision is interrupted.

Detecting Strabismus in babies

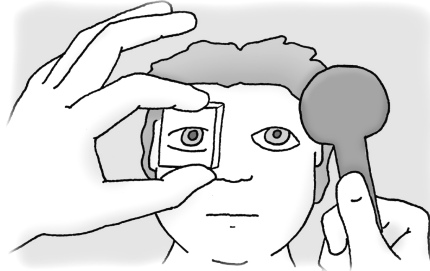
A large percentage of newborn infants will have some tropia at birth that goes away within a few months. A quick way to check alignment in babies is to shine a penlight into their eyes. You can determine alignment by looking at the corneal-pupil light reflex (the light reflection off the cornea) to make sure it is centered over the pupil of each eye.



Don't be fooled by **pseudostrabismus** – this is the illusion of crossed eyes caused by nasal epicanthal skin folds found in many Asian and young children. On casual inspection, less white sclera is seen nasally and the child “looks cross-eyed.” However, closer inspection will reveal normal corneal light reflexes and no refixation on cover testing. Children outgrow these epicanthal folds as the bridge of the nose becomes more prominent.

With younger children who don't track well, but who obviously have misalignment, you can use the **Hirschberg's test** – a quick method to estimate the amount of prism deviation in a misaligned eye. For every millimeter the corneal light reflex is off center, equals approximately 15 diopters of prism.

Ultimately, the most accurate way to pick up subtle phorias and tropias is with the cross-cover test. Since the cross-cover test breaks binocular vision, the phoric eye will wander off axis when it has nothing to focus on. The amount of deviation can be quantified using prisms. This is a difficult technique to describe in words ... basically you alternately cover the eyes with a paddle and hold up prisms until the deviation is neutralized. Detecting and measuring tropias and phorias is much more complicated than this, but I think this is enough for now!



Strabismus as a major cause of amblyopia

If a child has misaligned eyes, they can unconsciously suppress one of their eyes to avoid seeing double. However, this suppression leads to amblyopia and permanent visual loss. Adults don't have this ability to suppress vision and if they develop strabismus (such as from a nerve palsy or trauma) they will permanently see double.

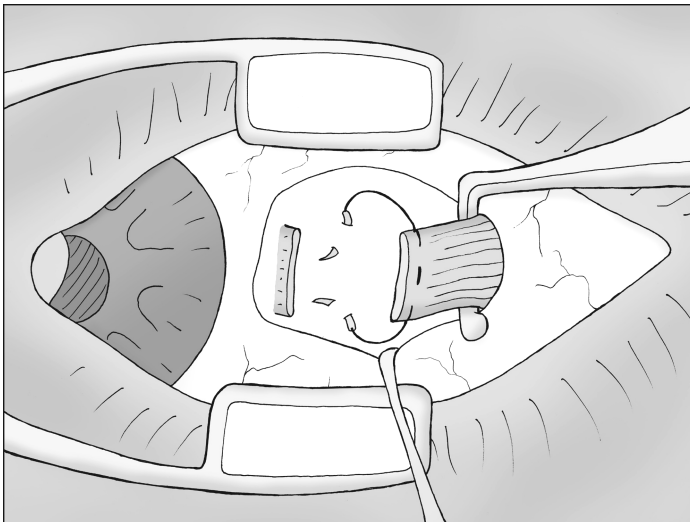
Treatment of Strabismus:

Before taking anyone to surgery, correct all the non-surgical causes of strabismus: check for refractive error and treat any amblyopia - many cases of strabismus will improve or resolve by just doing these things. Eye surgery consists of shortening or relaxing the extraocular muscles that attach to the globe to straighten the eye.

Strabismus Surgery

To correct simple esotropias (cross-eyed) or exotropias (wall-eyed) we can weaken or strengthen the horizontal rectus muscles. A recession-procedure involves disinserting the rectus muscle and reattaching the muscle to the globe in a more posterior position. This effectively weakens the action of this muscle and turns the eye accordingly.

The picture below demonstrates the basic strabismus surgical technique – after exposing the rectus muscle from the overlying conjunctiva and Tenon's fascia, you imbricate the muscle with double-armed vicryl suture, disinsert the muscle from the eye, then reattach the muscle to the globe via scleral passes at a measured distance from the original insertion. A resection procedure strengthens the muscle – you disinsert the muscle, cut off a section, and then reattach the muscle to the original insertion site.



The dangerous step with this surgery is reattaching the muscle - as you don't want your scleral pass to run too deep and pierce the eye! Strabismus surgery isn't technically difficult to perform, compared to cataract surgery, but it does take experience and good pre-op measurements to titrate the amount of recession/resection needed.

Famous Quotes

My mother had a great deal of trouble with me, but I think she enjoyed it.

Mark Twain

The goal of strabismus surgery is correct alignment so that the eyes are properly aligned when looking straight ahead and when reading. No surgery can “fix” the underlying muscle problems, such that the child may not have perfect alignment in *all* gaze directions.

Shaken Baby Syndrome:

This is a depressing topic (I won't be adding any funny cartoons to this section). This terrible condition is important to recognize as it is preventable.

New babies cry a lot - on average three hours a day, and often for no apparent reason. Some babies cry significantly more than this! Frustrated caregivers may pick up the child and shake it if suitably irate. This shaking can become a reinforcing response as the infant becomes somnolent afterwards and stops crying, exactly the response the caregiver was hoping for. Infants are predisposed to physical damage from shaking as they have big heads and weak neck muscles. As the head whiplashes back and forth, the acceleration and deceleration forces traumatize the brain in a big way. Biological fathers and boyfriends are the most common perpetrators of this behavior, but anyone can be the attacker – this phenomenon spares no ethnicity, religion, culture, or social class.

These children are typically 5 to 10 months of age and present with somnolence, seizures or coma. The classic triad of exam findings include:

- 1. Intracranial hemorrhage:** usually a subdural hemorrhage secondary to tearing of the small bridging veins between the dura mater and arachnoid.
- 2. Brain swelling:** from shearing forces, diffuse axonal damage, secondary edema, and infarction.
- 3. Retinal hemorrhages:** specific findings (see below).

The child can also have other physical findings such as bruising of the body trunk (where the shaker grips the child) and fractures of the skull, long bones, or ribs. Remember: be suspicious for abuse when you see many bone fractures at different stages of healing.

Retinal Findings:

An ophthalmologist needs to be called in for any case of potential shaken baby to evaluate the retina. These kids have specific retinal hemorrhages that aren't really seen in any other condition:

1. Large retinal hemorrhages located in *all* quadrants of the eye, located in *all* layers of the retina (subretinal, intraretinal, and preretinal).
2. Retinoschisis cavities. A **schisis** is a split between layers of the retina, and is very suspicious for abuse in this age group.

It's imperative to write a descriptive note in the chart (have the attending write this note for litigation reasons) and document any bleeding with fundus photography. You want to take these photos soon, as hemorrhages can resolve in only a few days!

What about other causes of retinal bleeding?

Studies have found that household injuries, such as a fall from caregiver's arms or furniture, do not usually cause significant retinal hemorrhage. Birth trauma can cause mild retinal bleeding, but this is usually limited and resolves in the first few months. CPR with chest compressions rarely causes significant hemorrhaging. The hemorrhages in SBS are impressive and similar retinal bleeding isn't seen except with big trauma such as a high-speed car wreck or a multi-story fall.

Be sure to look for any coagulopathy with basic lab testing, including CBC, coags, platelet count and bleeding time.

Prognosis:

While a third of these babies have no long term sequela, the long-term prognosis for the majority is bad. Twenty percent of these abused children die outright and the remaining kids end up with life-changing developmental problems, mental retardation, blindness, paralysis, and behavioral changes.

Famous Quotes

Whatever their other contributions to our society, lawyers could be an important source of protein.

Guindon cartoon caption

The Leukocoric pupil:

Every newborn receives a baseline exam by their pediatrician, and part of this exam involves checking for a good red-reflex off the retina. Leukocoria describes a white-colored pupil. This finding should concern you and requires an ophthalmology consult as the causes may be serious. Potential causes of leukocoria that you should look for include:

1. Congenital Cataract
2. Retinoblastoma
3. ROP (retinopathy of prematurity)

There are many other causes for a white pupil, such as persistent hyperplastic primary vitreous, but let's focus on these three:

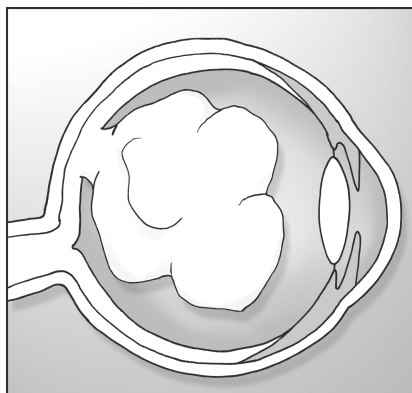
Congenital Cataract

A cataract in a newborn can occur by several mechanisms. They can be idiopathic, genetic, from metabolic disorders, child abuse trauma, or caused by one of the maternal TORCH infections during fetal development. Whatever the cause, it is important to remove these cataracts as soon as possible as they are amblyogenic and will lead to permanent vision loss from visual neglect. Replacing a lens is tricky, however, as babies are tiny, generate an impressive inflammatory response, and their "prescription" is still changing as the eye continues to grow. The cataract is removed as soon as possible, but often the lens implant can be placed at a later date - parents have to deal with aphakic contact lens or thick glasses in the meantime.

Retinoblastoma

Retinoblastoma is a tumor of the primitive retinal photoreceptors. The tumor grows on the retina and forms a white or cream-colored mass that can completely fill the eye, creating a white iris, and often a retinal detachment.

Retinoblastoma is the most common primary malignant ocular tumor in children. That being said, the cancer is still very rare, with only 250-500 new cases reported in the United States each year. You don't want to miss this one, though, as failure to diagnose RB could result in the death of a child.



These children are under 4 years of age, with the average age of diagnosis 18 months. There are different types of RB, and the tumor can arise from a

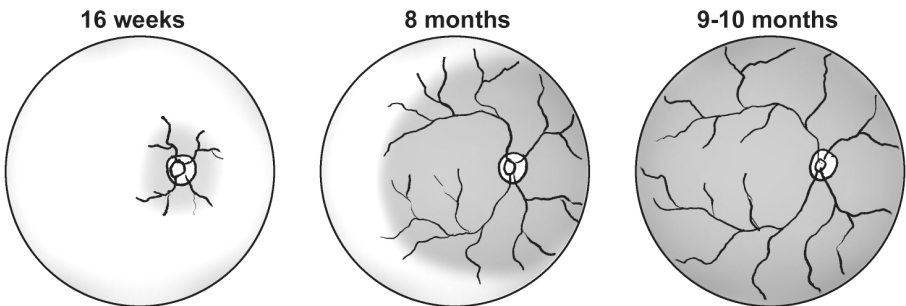
random somatic mutation or develop along several germline inheritance patterns.

Treatment modalities are many, but decisive treatment often involves enucleation (removal) of the entire eye to avoid seeding tumor cells into the orbit. The tumor spreads by extension down the optic nerve toward the brain, so it is important to get a good optic nerve section upon removal with careful microscopic evaluation for margin involvement. The overall survival rate in the US is very good, approaching 90%, but only if the tumor is recognized early.

Retinopathy of Prematurity

ROP is an important disease process that is commonly found in neonatal ICUs. Here's how ROP works:

The retinal blood supply begins formation around week 16 of gestation, with retinal vessels springing forth from the optic disk and spreading outwards in an expanding fan toward the edges of the retina. By the 8th (36 weeks) month this vasculature has reached the nasal retinal-edge, and within a few more months the whole retinal blood supply has formed 360 degrees.



Everything sounds good, right? However, problems can occur if a child is born premature. When the retina is forced to work “before it is ready,” areas of peripheral retina that haven’t yet developed a good blood supply can become ischemic. Ischemic retina produces VEGF with resulting neovascularization. These neovascular vessels can bleed, create traction, and eventually cause retinal detachment. A leukocoric “white pupil” can result if the retinal detachment is big enough. The more premature a child is born, the more likely this unfortunate sequence of events is to occur. For this reason, children born under 32 weeks or less than 1,500 grams are screened to insure their retina is forming properly.

We treat these kids in a similar fashion as proliferative diabetic retinopathy in adults – PRP laser or cryotherapy is used to ablate the peripheral ischemic retina in an attempt to shut down excess VEGF production.

Pimp Questions

1. How is the Bruchner test performed? What will a near-sighted child look like with this exam?

The Bruchner test is a simple method to estimate the refractive error in a child. You look at a child through your direct ophthalmoscope from a distance. Light up the face such that both pupils are lit. Hyperopic children will have superior crescents in their red-reflex, while myopic (near-sighted) children will have inferior crescents.

2. How do you determine the refractive error (glasses prescription) in a pre-verbal child?

By streak-retinoscopy. This is where you flash a light beam across the retina and hold up different lenses in front of the eye until the red-reflex movement is neutralized. Correct for your working distance and you have your prescription.

3. What is amblyopia? What causes it?

Amblyopia is poor vision in an eye from disuse at an early age, usually secondary to strabismus or an unrecognized refractive error.

4. How do you treat amblyopia?

You treat by “penalizing” the good eye. Using a patch over the good eye forces the amblyopic lazy eye to work. Also, you need to treat any underlying cause of the amblyopia such as anisometropia.

5. You suspect a baby of having strabismus, but because of the baby’s age you aren’t able to measure eye deviation with your prism set. How can you estimate the amount of eye deviation?

You can do this by measuring the corneal light reflex in relation to the underlying pupil (Hirschburg test). For every millimeter of light deviation, you have approximately 15 diopters of strabismic deviation.

6. What's the difference between a tropia and a phoria? How can you differentiate this on exam?

This is exactly the kind of question you'll get asked during a pediatric or neuro clinic. A tropia is a deviation that is there ALL the time. A phoria is intermittent, and tends to occur more with fatigue or when one eye is covered.

As for how to pick these up: it's hard to describe, so you might want to watch my video lecture at OphthoBook.com to see how this is done.

Tropias: cover-uncover test

Phorias: cross-cover test

7. An Asian American woman brings in her new baby. She is concerned because her friends think her baby's eyes look "crooked." Casual inspection shows a healthy 12-month old baby who appears mildly esotropic (cross-eyed). How would you measure ocular alignment in this child?

You can check the corneal light reflex with a penlight.

8. The corneal light reflex appears to be correctly centered (normal Hirschburg), yet the child still looks esotropic. In fact, the child looks a lot like her mother. What's going on?

This sounds like pseudostrabismus from epicanthal folds. The nasal skin creates the illusion of crossed-eyes as less white sclera can be seen nasally. As babies get older, the nasal bridge becomes prominent and this appearance usually goes away.

9. What systemic and eye findings will you see with shaken baby syndrome?

In the eye, you will see retinal hemorrhages at "all levels of the retinal in all four quadrants of the eye." Schisis cavities (large splits within retina layers) are relatively specific. Other system findings include intracranial hemorrhage, brain edema, and skull-rib-long bone fractures. On exam you might also find bruising on the body trunk and under the armpits. Supposedly, these kids can have a torn frenulum (the piece of tissue under the upper lip that connects the lip to the gumline), but I've never seen this myself.

10. Parents say that a child fell from her crib and hit the floor. Do you think this would cause a fracture and the retinal findings of shaken baby?

Kids are relatively bouncy, but this story COULD account for the skull fracture. However, it takes a LOT of traumatic force to create large retinal

hemorrhages -- this story sounds a little fishy. An experienced pediatrician and ophthalmologist needs to examine this child.

11. Name three causes for a leukocoric pupil.


Cataract, retinoblastoma, and retinopathy of prematurity.

12. List risk factors for developing retinopathy or prematurity.

Gestational age less than 32 weeks, birth weight under 1,500 grams, and systemic hypoxia.

13. How soon should a congenital (found at birth) cataract be removed?

Soon, in order to avoid amblyopia. Some recommend removing these early cataracts in the first two months.




"Oh Timmy, did you ink in your bed again?"

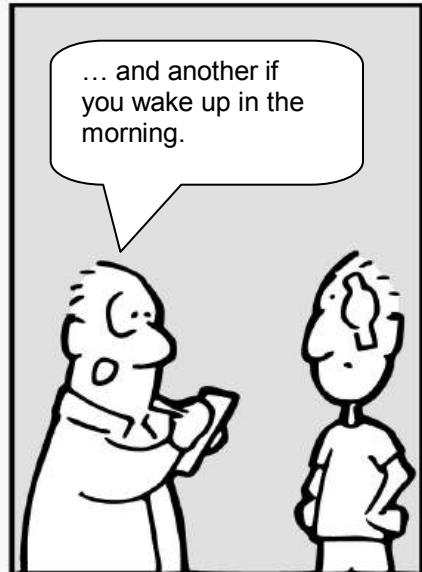
Chapter 8

Trauma

The Eyes Have It



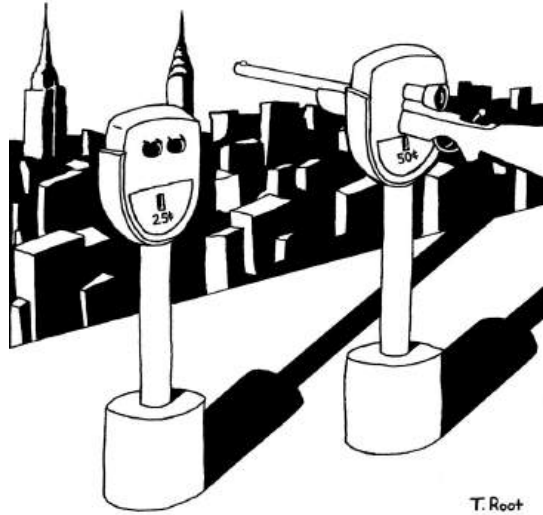
by Tim Root



Eye Trauma

by Tim Root, M.D.

When I picked ophthalmology as a career, I never dreamed there would be so many midnight emergency room consults. Little did I know the number of people out there punching each other in the face and slamming their heads into airbags. Armies of welders, construction workers, and industrial cleaners ply their trade without proper eye-protection. Repeated exposure to this trauma can change your world outlook, such that I now dread baseball season, pellet guns, and fireworks. As odd and random as some of these injuries seem, it's our duty to help these people and save those eyes!



T. Root

Famous Quotes

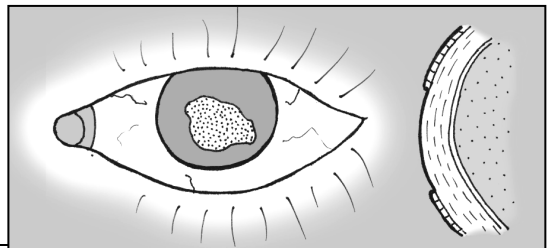
I thoroughly disapprove of duels. If a man should challenge me, I would take him kindly and forgivingly by the hand and lead him to a quiet place and kill him.

Mark Twain

Here are some of the common traumas you'll likely see coming into an emergency room.

Corneal Abrasions:

The surface of the cornea is covered by a thin layer of epithelium. This "rug" of clear skin is only loosely adherent and is easily scraped off. These surface



abrasions are common and we see them daily. The cornea contains more nerve innervation (per surface area) than any other place in the body so these abrasions “hurt like the dickens,” with patients complaining of excruciating pain and intense photophobia. Abrasions are easy to see, even without a microscope, as the raw surface will uptake fluorescein and glow bright green under a blue light.

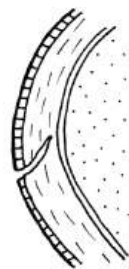Fortunately, abrasions recover quickly and will often completely heal within 24 hours. Until complete epithelial healing you treat with aggressive lubrication and follow these eyes closely to insure the raw wound doesn't become infected. Many physicians will treat an abrasion with empiric erythromycin ointment as well, reserving more aggressive antibiotics like ciprofloxacin for contact lens wearers and “dirty wounds” caused by tree branches, etc. We talked about this in the infection chapter, so hopefully it sounds familiar!

If an abrasion does become infected, you'll see a white infiltrate at the wound. Any abrasion with an infectious infiltrate is officially called a “corneal ulcer.” Depending upon the size and location of an ulcer, you may need to culture the wound and tailor your antibiotic coverage accordingly.

Corneal Lacerations:

Most corneal scratches only involve the surface epithelial layer. If the injury goes deeper into the stroma, then you have a laceration. With any laceration you want to insure that the cornea hasn't perforated. You can check corneal integrity with the “Seidel test.” You wipe a strip of fluorescein paper over the wound and see if dye flows down the corneal surface, indicating leaking aqueous fluid.

If a patient is “Seidel positive” than you have an open-globe injury - time to call in your ophthalmologist for possible surgical repair!




Orbital Wall Fractures:

The bony orbital walls are thin and tend to break with blunt impact to the eye. This is especially true of the orbital floor and medial wall. These orbital fractures are common and you will see them often (they tend to occur at two in the morning).

Bumper Face Theory

The face is designed like a modern crash-tested car, with many areas designed to crumple and diffuse energy upon violent impact. The sinuses are air-filled crumple zones that protect the brain and other vital structures.

When the eye is hit, orbital contents (usually fat) break through and herniate into one of these sinuses. As bad as this sounds, this setup keeps the eye from exploding from high impact pressures.



Most of the time these orbital bones heal fine with no long-term problems, with patients merely having a great deal of orbital and periorbital swelling that resolves over a few weeks. However, sometimes the broken bone creates a “hinge” or “trapdoor” that entraps fat or extraocular muscles. If there is significant entrapment or enophthalmos, we need to repair the break. During surgery we can release the muscle and bolster the floor to keep orbital contents from herniating back through the defect. This surgery is usually performed by an oculoplastics specialist.

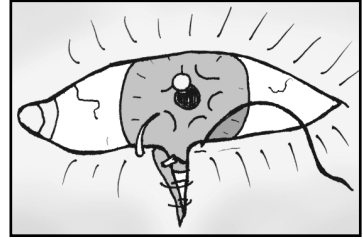
When evaluating orbital fractures, focus on the following exam findings:

- 1. Vision, color:** Make sure the optic nerve isn't involved.
- 2. Extraocular movements:** Usually decreased from swelling or muscle contusion, but make sure there isn't any gross muscle entrapment. If concerned, you can perform forced ductions. This involves pulling on the eye with forceps to see if the eye is mobile.
- 3. Proptosis:** Measure the degree of proptosis or enophthalmos using the Hertel exophthalmometer (a fancy ruler).
- 4. Palpate:** Feel along the orbital rim for step-off fractures and subcutaneous emphysema (air crepitus).
- 5. Sensation:** Check sensation of the V1 and V2 sensation on the forehead and cheek. V2 runs along the orbital floor and can be damaged with floor fractures.

Most of these patients do fine and we see them a week later with marked improvement in swelling and motility. In the meantime, you treat empirically with Keflex or Augmentin, advise Afrin nasal spray, and recommend “no nose blowing” (you don't want to blow air from the sinuses into the orbit).

Lid Lacerations:

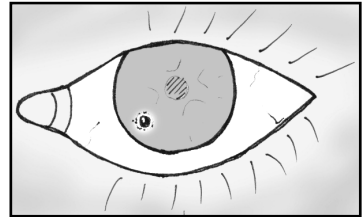
When evaluating lid lacerations, you need to determine if the laceration involves the lid margin and how close the cut is to the canalicular (tear drainage) system. Most of these lid lacerations are straight-forward to repair, though special effort is made to align the lid margins to avoid lid notching and misdirected eyelashes.



If the laceration is medial (near the nose) you need to worry about the canalicular tear system - repair of this drain is much more involved and involves threading silicone tubes down into the nose to keep the canaliculus patent.

Metal on Metal:

Small pieces of metal can fly into the eye – an unfortunate event occurring primarily in welders or construction workers. Particles of metal stick onto the cornea causing small abrasions and discomfort. Metal rusts quickly and will form a rust ring within a day. You can remove metal objects and rust rings at the slit-lamp using a needle. You can also use a small dremel-like drill to drill off the rust-ring. If the rust is deep, or aggressive pursuit seems to be making the situation worse, you can leave the residual rust in place as most of it will eventually migrate to the surface by itself.



Anytime you have metal-striking-metal injuries, you must entertain the possibility of an intraocular foreign body. Small metal fragments can enter the eye at high speed and leave little or no signs of injury. Metal is very toxic to the retina and can kill the retinal cells if not detected. If you have a suspicion for penetrating injury, you should order a thin-slice CT scan of the head to look for metal pieces not obvious on exam. You want to avoid MRI in this setting to avoid creating a moving projectile inside the eye.

Chemical Injuries:

Household cleaners contain abrasive solvents like bleach and ammonia that are extremely dangerous when splashed into the eye. The first thing you do with any chemical injury is:

Irrigate, Irrigate, Irrigate, Irrigate, Irrigate, Irrigate, Irrigate!

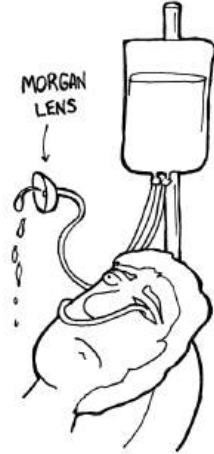
The final visual outcome for a chemical burn is going to depend upon how quickly the chemical is washed out of the eye. If a patient calls you with a chemical conjunctivitis, tell them to immediately wash their eyes out! If the ER calls you with a chemical burn, tell them to start irrigating immediately -

several liters in each eye. Then grab your equipment and pH paper and head on down there!

Acids are less dangerous than bases as acids tend to precipitate denatured proteins and this limits tissue damage. Bases, on the other hand, just keep on going like the proverbial Energizer Bunny so you need to continually irrigate and check the pH until it normalizes.

On exam you want to carefully check the state of the cornea – hopefully, it is still clear. A red, inflamed conjunctiva is actually a good finding: if the conjunctiva is white, that means its blanched out from extreme damage. Be sure to flip the lids and irrigate/sweep the fornices to remove any material that may be retaining chemicals.

Chemical injuries can lead to significant scarring that may require corneal transplant if bad enough, so you want to be very aggressive with that irrigation!! The emergency room has access to a simple device called a Morgan lens to help irrigate via a suspended saline bag. Little kids hate this thing and have to be restrained when using it.

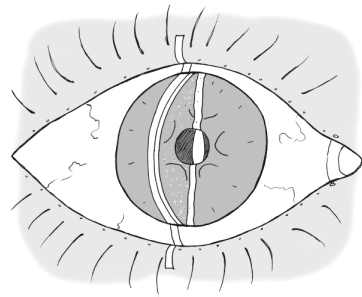


Fun-Fact

Speaking of abrasives: early Romans used human urine as a mouthwash to brush their teeth. The ammonia has strong cleaning powers. In fact, urine was an important component of toothpaste well into the 1700's.

Traumatic Iritis:

Blunt trauma can create swelling and inflammation in the front half of the eye. Because the cornea is clear, we have a direct window through which to view the inflammatory cascade. On exam you can actually see “cell and flare” in the anterior chamber. Cells are individual inflammatory cells floating within the aqueous fluid while “flare” is diffuse protein that has escaped through inflamed blood-vessel walls.

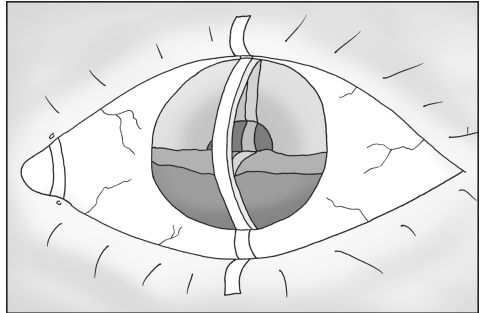


Patients will complain of painful sensitivity to light secondary to iris/ciliary spasm. Individual cells can be difficult to detect at the slit lamp ... and it doesn't help when the photophobic patient is squeezing their eyes shut and yelling at you. You'll find it helpful to turn the lights completely off and to make your light beam narrow, bright, and at an angle (like in this drawing).

Fortunately, traumatic iritis generally runs a benign course with resolution of symptoms within a week of treatment. We give these patients topical steroids to decrease inflammation and a cycloplegic to dilate the eye. I generally use a medium-duration dilator like Cyclogyl several times a day – the induced paralysis of the ciliary muscle makes the patient less photophobic. Also, daily dilation forces the inflamed iris to move and keeps it from sticking to the underlying lens.

HypHEMA:

A hypHEMA describes blood floating in the anterior chamber, a common finding after blunt eye trauma. If the bleed is large, the blood will settle out in a layer at the bottom of the anterior chamber. If the entire AC is filled with blood, you'll see an "8-ball hypHEMA." Most of the time, however, the bleeding is microscopic and can only be seen as "red cells" floating in the aqueous fluid.



Blood typically clears well, though you can get staining of the cornea if the blood is persistent or coexists with high eye-pressure. Encourage your patient to sleep with their head elevated (to help the blood settle) and to avoid straining. I typically give steroids (to decrease the inflammatory response) and a cycloplegic dilating drop to help with photophobia. As with iritis, this dilation also keeps the iris from sticking to the underlying lens and forming synechia. With African Americans, consider checking for sickle cell disease. If they *do* have sickle cell, avoid carbonic anhydrase inhibitors as they cause a local acidosis that worsens sickling.

Follow these patients daily, as the bleeding can get worse. The main danger time is days 3 to 5 because this is when clots can contract and rebleed. You need to monitor their pressure, as blood can clog the trabecular meshwork. After the blood has completely resolved and the eye is quiet, perform a thorough gonioscopy exam to assess for "angle recession." This is when the ciliary body splits from the blunt trauma -- this is a sign (but not a causative factor) that the patient has also likely suffered trabecular meshwork damage and may eventually develop glaucoma in that eye sometime in the future.

Speaking of fluid layering ...

Real World Application

The “black and tan” tradition of beer mixing originated over a thousand years ago when Viking explorers raided the Celtic islands. The Vikings would mix their lighter northern beer with the local dark beers. Later, the term “black and tan” came in use to describe the uniforms worn by cruel British soldiers sent to Ireland in the early 1920’s to suppress uprisings.

A black and tan is most commonly constructed with Bass Ale (an English bitter) and Guinness (an Irish Dry Stout). The Guinness is poured over the lighter colored beer using an inverted spoon to disperse the Guinness and decrease mixing. The beers have different densities and so will remain “layered.”


The “black and tan” is enjoyed by beer enthusiasts who find a straight stout too harsh. However, you may want to avoid ordering one in Ireland because of its historical relevance.



Open Globe Injuries:

The eye can be perforated many ways ... I've seen firecracker explosions, gunshot wounds, car wrecks, and domestic accidents that have perforated the eye. Visual outcome is usually terrible and a blind, painful eye may later need enucleation.

If you suspect an open globe injury you need to evaluate the eye in the operating room. One thing to remember - if you suspect an open globe injury, cover the eye with a shield and don't push on it. You could extrude the eye contents (pop it like a grape) if you push too hard.



*"Thought I was a goner ...
but it was just a paintball!"*

Pimp Questions

1. You have a contact lens wearer with a small corneal abrasion. He is in excruciating pain and requests that you pressure-patch his eye for comfort. Will this speed up healing?

Patching may speed healing by keeping the eye immobile and lubricated - but you should never patch an abrasion that might fester an infection. Thus, you don't patch contact lens wearers as you don't want a pseudomonas infection brewing under that patch! If you decide to patch a patient, you should really follow them closely to make sure they don't develop an ulcer.

2. What's the easiest way to see a corneal abrasion? How often do you need to follow simple, non-infected abrasions?

Abrasions are easiest seen with fluorescein under the slit-lamp microscope, though large abrasions can be detected with only a handlight as the edges of the abrasion create a circular shadow on the iris underneath. You'll want to measure the epithelial defect and see the patient often (sometimes daily), until it heals to make sure they don't become infected.

3. What is the Seidel test?

This is a method to see if a laceration has penetrated completely through the cornea. Basically, you're using fluorescein to look for leaking aqueous fluid.

4. What findings would prompt you to take a patient with an orbital floor fracture to surgery?

If the patient has muscle entrapment or significant enophthalmos. Most patients have some degree of EOM restriction from soft-tissue swelling. Entrapment causing reflexive bradycardia would also push you toward surgery.

5. What portion of the eyelid do you worry about with lid lacerations?

If the laceration is medial (near the nose) it could involve the tear drainage pathway. These canalicular tears are more complicated to repair.

6. A patient accidentally splashes a large amount of bleach-based cleaner in her eye. What should she do?

Wash it out immediately - the faster, the better!!!! If an ambulance picks her up, have the EMTs irrigate in route, and alert the ER to irrigate her eyes as soon as she hits the door.

7. What is the best way to test the pressure in an eye with a likely open-globe injury: with slit-lamp applanation or with the hand-held tonopen?

If you suspect open globe, you don't want to be mashing on the eye, so neither of these is correct. This is a trick question ... hahahahaha! Seriously, though, don't push on the eye.

8. How often should a patient with a hyphema be seen and why?

These patients need to be seen almost daily for the first week to check for pressure. This is especially important on post-trauma days 3 – 5 as this is when clots begin to retract and rebleed.

9. An African American presents with hyphema after trauma. What additional workup might you consider? Are there any medications you would avoid?

You may consider getting basic coagulation labs and a sickle prep. Avoid CAls as these promote acidosis and can worsen sickling of blood in the anterior chamber and worsen glaucoma.

10. What two beers are most commonly used when making a “black and tan.” Which beer goes on top?

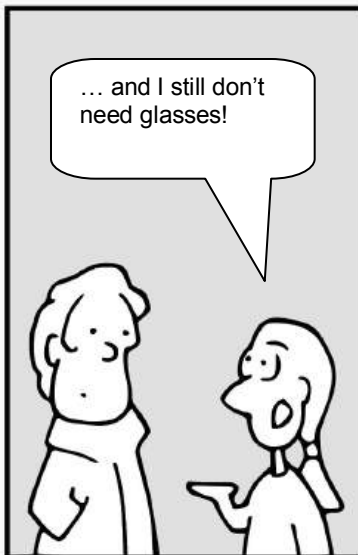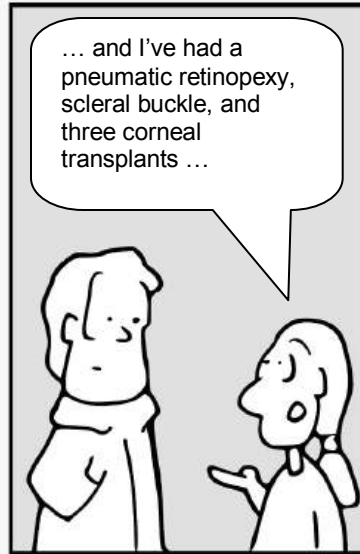
A black-and-tan is made with Bass Ale and Guinness Stout - the Guinness goes on top and is usually poured over a spoon to keep it from mixing.

Chapter 9

Optics

The Eyes Have It

by Tim Root



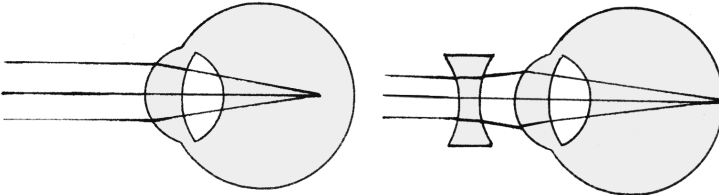
Introduction to Optics

by Tim Root, M.D.

Before I started my ophthalmology residency I didn't know a thing about optics. It was embarrassing during my internship year when friends would ask me to renew their glasses only to discover I hadn't a clue as to how to decipher their prescription! Optics principles are easy to grasp, but I think you'll find it difficult for these concepts to permanently "sink into your brain" until exposed to this stuff on a daily basis. Nevertheless, a review at this point is useful. These are the basics I wish I'd known before my first month as a "prescription-writing resident."

Myopia and Hyperopia

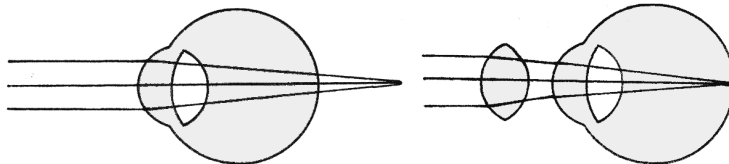
A myopic eye just means a "nearsighted" eye. If we draw a picture of a myopic eye, we see that it looks big (and long) and that light focuses not onto the retina, but in front of the retina within the vitreous jelly! To correct this refractive error we use a minus (concave) lens to diverge the incoming rays of light. This effectively weakens the overall refractive power of the eye and pushes the image back onto the retina where it belongs.



Myopic eyes are big, and powerful, focusing into the middle of the eye.

A minus lens will weaken the overall refractive power and push images back onto the retina.

Hyperopic eyes are small, short eyes. The axial length of these eyes is so short that light focuses behind the eye. To get that image onto the retina we have to add power to the overall refractive power of the eye by using a plus (convex) lens. These convex lenses are basically your traditional magnifying glass and can make your patient's eyes look enormous at high power.

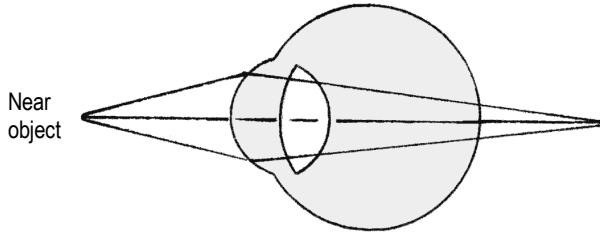


Small, weak-powered eye that focuses light behind the eye.

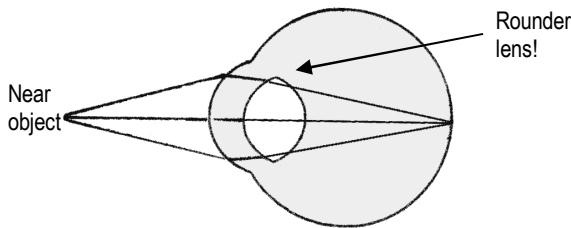
Some extra refractive power (a plus lens) will help bring the image forward onto the retina.

Near-reading and Presbyopia

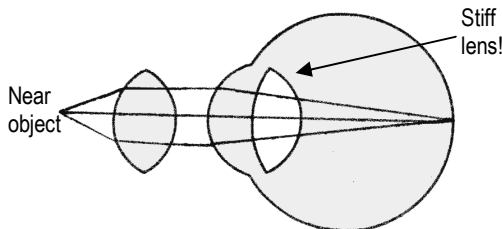
Once we get a patient corrected for distance vision we need to take care of close-up vision. With distance vision, the incoming light rays are coming in parallel before entering the eye. A near object, however, produces expanding *divergent* rays of light. When these rays hit the eye they end up focusing behind the eye.



To get this near object in focus the eye needs some *more* refractive power. Fortunately, we are born with the natural ability to increase the strength of the lens by making it *rounder*. This morphing process is called “accommodation.”




The lens works because it is suspended like a trampoline by surrounding zonular fibers. These fibers attach 360 degrees around the lens and tether the lens to the surrounding ciliary muscle. When the ciliary *sphincter* contracts the zonules relax and the lens becomes *rounder*. This rounding of the lens increases its magnification/refractive power and allows us to see near objects. With age, the lens becomes dense and does not easily round out. This **presbyopia** presents after age 40 and progresses with age, explaining the need for near-reading glasses in this age-group.



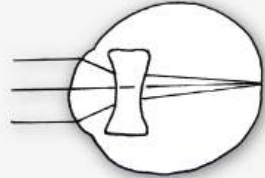
Extra bifocal power allows us to focus on near objects.

Fun Fact

Unlike other vertebrates, the chameleon has a lens that is concave and actually diverges light. This works like a Galilean telescope that magnifies the retinal image compared to a traditional eye. In addition, the chameleon has a large accommodative amplitude that allows it to focus on nearby prey that roams within the field of its elastic tongue. The chameleon uses its finely tuned monocular accommodation and evaluation of retinal size to judge distance. This is very different than the binocular stereoscopic clues that we use to judge distance.



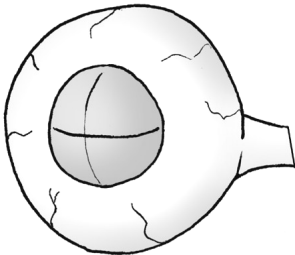
Also, the chameleon tongue is sticky, has suction, and can even grab its prey (kind of like my leather sofa).



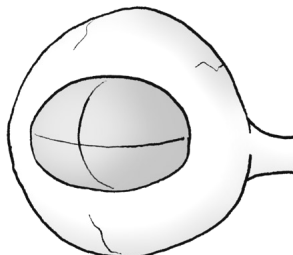
Implanted acrylic/plastic/silicon lenses can't change shape at all, meaning that all post-cataract patients will need reading glasses. However, new lenses are being designed to help with accommodation. Some have concentric fresnel rings that create multiple focal points (one optimized for distance and the other for near vision). Other designs work by moving the lens in an anterior/posterior direction like a telescope. Neat, huh?

Astigmatism

The cornea surface provides the majority of the refractive power of the eye. In the examples above we assumed that the cornea surface was perfectly spherical like a basketball. However, many patients have some degree of **astigmatism**, where the cornea surface is shaped more like a football. Thus, one axis of the cornea is steeper than the other.



Round like Basketball



Round like Football

Spherical correction alone will not work for these eyes. For astigmatism, we need to add a cylindrical shaped lens to correct the refractive aberration along one axis. When we check for glasses, we determine the amount of cylinder power, and the exact angle axis this cylinder needs to be oriented to work. To measure this we use the foropter.

Using the Phoropter:

The phoropter is the mechanical device we use to determine glasses prescription. It's just a big box full of lenses on dials. When manifesting a patient, we go through three steps:

1. Figure out the overall spherical error
2. Figure out the extra cylinder to correct for any astigmatism
3. Tweak the angle of the cylinder correction

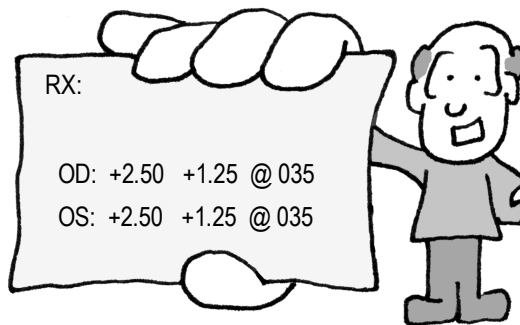
When we're done, the foropter gives us three numbers to write down on a prescription pad:

+1.00	+2.00	at	175 degrees
Sphere	Cylinder		Angle of cylinder

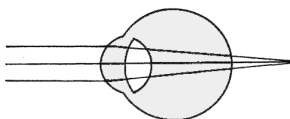
Manifesting is a little more complicated then this, but this is enough to get us started. Let's analyze a few sample patients and maybe this will make more sense.

Patient One

A patient hands us this prescription. He's an engineer, and would like us to explain what the numbers mean.



There are several parts to an eye prescription, so I'll go through them one item at a time. The first number is the spherical error. This patient requires a +2.50 lens ... this tells us that he has a small, hyperopic eye that focuses images behind the retina. He needs a little more "oomph" in his refraction to move everything forward.

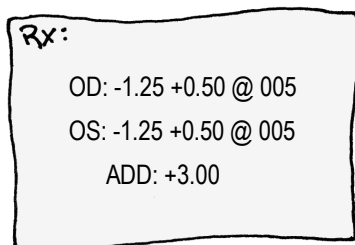


Small hyperopic eye

The second number is the cylinder. This patient needs an additional +1.25 diopters of power to fix the astigmatism in his "football" shaped eye. The last number is the axis angle of how to orient that cylinder. His "football" is tilted at an axis of 35 degrees.

Patient Two

A 61 year old man presents to you with the following prescription after cataract surgery. He wants you to check the numbers to see if they make sense. What do the numbers mean?

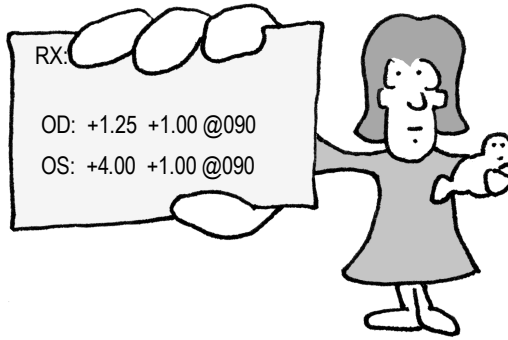


With cataract surgery we go through great pains to calculate the exact power of intraocular lens for implantation, with the desire for emetropia so that the patient doesn't need glasses for distance. In this gentleman's case, he is still a little myopic with a negative sphere of -1.25 . We must have implanted a powerful lens implant that is focusing in the vitreous jelly. To offset this powerful implant, we need to weaken the eye by -1.25 diopters. He also has a little astigmatism of $+0.50$ with a cylinder angle of 5 degrees. The patient probably had this astigmatism before, but you can induce some astigmatic error via corneal incisions and sutures.

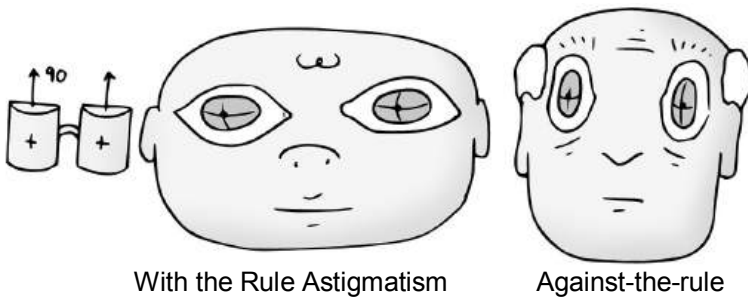
There is another number on this prescription called the "add." This is simply the amount of extra bifocal power needed for reading. This gentleman has a plastic lens in his eye that can't change shape at all, so he needs a $+3.00$ bifocal adjustment if he wants to read at approximately $1/3^{\text{rd}}$ of a meter.

Patient Three

A woman brings you this prescription for her child.



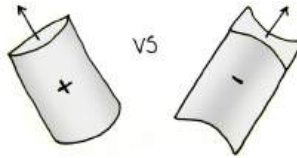
As you can see, the child is hyperopic ... he must have small eyes with images focusing behind the eye. This is a common finding in infants, as their eyes are still growing. His prescription indicates he needs some plus power to pull the image forward onto the retina. In addition, the child has a little bit of astigmatism. The angle of the astigmatism is 90 degrees. We call this “with-the-rule astigmatism” and this is common with children. With-the-rule means that corrective positive-cylinder glasses would place the cylinder axis at 90 degrees. Elderly patients often have “against-the-rule astigmatism” with their glasses having positive cylinder at an axis of 180 degrees. Here’s a picture to demonstrate what I’m talking about:



Don't kill yourself memorizing “with the rule,” as I just wanted to familiarize you with the subject. More importantly, notice that this child has a large difference in prescription power *between* his eyes. This anisometropia is concerning because it can lead to amblyopia if the child begins to favor one eye over the other.

Minus or Plus Cylinder

As you've noticed, astigmatism can be a little confusing. It also doesn't help that ophthalmologists and optometrists like to fix astigmatic errors differently. Ophthalmologists like to correct using a positive cylinder (which is conceptually easier in my mind) while optometrists prefer using minus cylinder (which is more useful when grinding glasses). The phoropter machine comes in both flavors and your office may have both types. They both work and are conceptually the same, but with an axis that is written 90 degrees off.



Converting Cylinder

You can convert a glass prescription from +/- cylinder format by the following method:

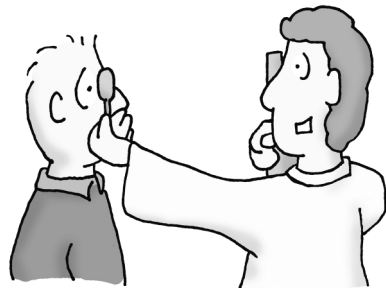
- add the cylinder to the sphere (you remember how to add negatives, don't you?)
- change the sign of the cylinder
- change the axis by 90 degrees

Thus:

+2.00 +3.00 at 170 converts to +5.00 -3.00 at 080

Retinoscopy:

Refracting through that phoropter is great, but what do you do with a child or confused patient who can't communicate? You can actually estimate the refractive power of the eye by examining the foveal red-reflex (the red-eye you see in photographs) as you flash a light over the front of the eye. This technique is important, but tricky to perform on a child. Don't worry too much about retinoscopy until you start your residency and have to do this yourself.



Pimp Questions

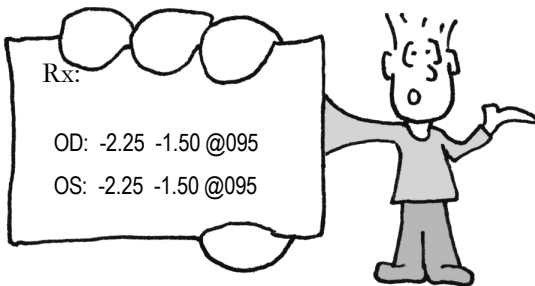
1. What bends light more -- the cornea or the lens? What percentage of the eye's total refractive power does the lens contribute?

The cornea does the majority of the refractive power of the eye, because the air-cornea interface has very different densities. The lens is only important for approximately one third of the overall refractive power of the eye.

2. A child has a cataract operation and a lens implant is inserted. A month after surgery the child sees 20/20 on the distance Snellen chart. Will this child need glasses when he returns to school?

Yes, the child needs reading glasses. An implanted plastic lens can't accommodate (change shape) with near reading, necessitating a +3 lens or bifocal for close-up vision.


3. Your patient hands you the following prescription that they got from the optician at Wal-Mart. The prescription appears to be in minus cylinder while your favorite foropter is based on plus-power cylinder. What would be the equivalent plus cylinder prescription power for this patient?



To switch from plus to minus (or vice versa) you add the cylinder to the sphere, change the polarity of the cylinder, then change the axis by 90 degrees. Thus, the equivalent prescription for this patient is:

$$-3.75 + 1.50 \text{ at } 005$$

4. A patient wants you to grind his eyeglass prescription into his diving mask before his next wreck dive. Your new optical-tech has never done this before, and asks you whether she should grind the lens curvature on the inner or outer surface of the diving mask. Which one is correct?



You have to grind that mask on the inside of the mask so that the lens interface is facing the mask air-bubble. A lens needs a good glass-air interface if it's going to bend light according to Snell's Law.

Note: this is just an example to illustrate Snell's Law. Scuba masks actually have inserts that are ground and placed on the inside.

5. When accommodating to view near objects, does the ciliary body relax or contract? Do the zonules get tighter or looser?


To see close objects, the lens needs to become more powerful and get rounder. To accomplish this, the circular ciliary muscle, which is a sphincter muscle, contracts. This releases tension on the zonules and the lens is allowed to become rounder.

Fun-Fact

The sea nautilus is a great example of eye evolution. The nautilus has neither a cornea nor a lens, but instead has a pinhole that it uses to focus light onto the retina. This concept is similar to the pinholing technique we use when checking vision and pinhole systems that are popular in spy cameras.

This pinhole eye is only a step in the evolution of the visual system: the simplest eye is merely a light-sensitive patch such as that found on the planarian worm. This light-patch can determine light-and-dark only, with no directional component.

The next evolutionary step is to curve the eye into a bowl – since light has to get over the lip of the bowl and hits only *part* of the retina, this conveys some basic directional information. By closing the bowl into a sphere with a pinhole opening (like our nautilus here), we get fine focusing of light. The disadvantage is, of course, that only a small proportion of available light is able to get into the eye through that tiny hole. Our more advanced lens system allows focusing of much more light.

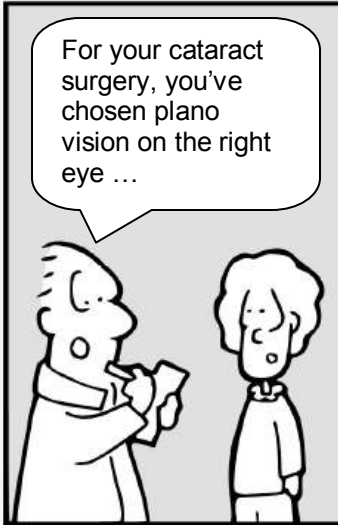



Chapter 10

Lens and Cataract

The Eyes Have It

by Tim Root



Lens and Cataracts

by Tim Root, M.D.

If you hang out with an ophthalmologist long enough, you're going to be dragged into surgery at some point. Cataract surgery is our signature operation, so it's worthwhile to familiarize yourself with basic lens anatomy and surgical goals.

The eye is the most amazing organ in the human body, and the lens is one of the most impressive structures within it! Not only is the lens the densest tissue in the body (highest protein content and lowest water percentage), it also remains optically clear for years despite constant bombardment by light radiation. The lens can even use its mighty-morphing transformer powers to change shape and thus its focusing power! Not bad, eh?

Some Cataract Terminology

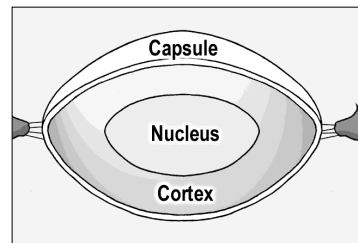
Phakic: When you have your natural lens

Pseudophakic eye: When a cataract is replaced with an artificial lens

Aphakic eye: When a cataract is removed but isn't replaced.

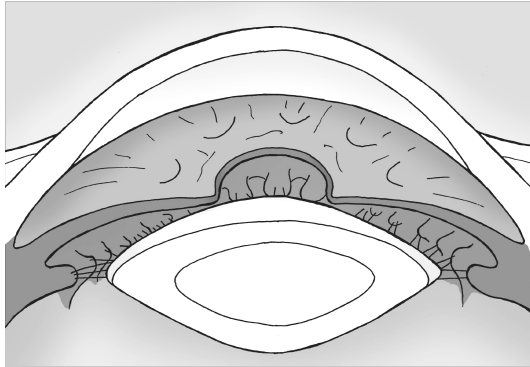
Lens Anatomy

We can't go any further in our discussion without first describing the anatomy of the lens and how it sits in the eye. When conceptualizing the structure of the lens, you may find it useful to think of it like a yummy peanut M&M candy. Thus, there is an outer capsule like a "hard candy shell" that surrounds the lens. Inside you'll find the chocolate layer (the lens cortex) and the inner nut (the hard lens nucleus). These three layers are clear, of course, but that's the general layout.



Cataracts can form at different layers within the lens, and the location can give you clues to the causative insult and explain specific visual complaints. The lens layers become even more relevant during surgery – with cataract extraction, we tear a round hole through the anterior capsule, suck out the cortex and nucleus (the chocolate and the peanut), and inject a prosthetic lens into the remaining capsular bag.

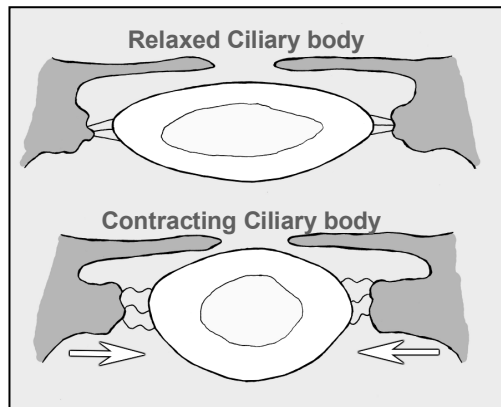
Now, we know the structure of the lens and we know the lens sits behind the iris ... but what keeps the lens from falling into the back of the eye? The lens is actually suspended behind the iris by zonular fibers. These zonules attach at the equator of the lens like trampoline springs and connect the lens to the surrounding ciliary body. The ciliary body is a ring of muscle sitting behind the iris. Trauma and surgical mishaps can break the zonules and cause the lens to de-center or even fall into the back of the eye.



Accommodation

Now, I just said that the lens is suspended by spoke-like zonules to the ciliary body. But what is this mysterious ciliary body? The ciliary body is a ring of muscle that sits directly underneath the iris. You can't see it directly by standard exam without using mirrors, but this ciliary body is important for two reasons: it produces the aqueous fluid that nourishes the eye and it controls lens focusing.

The ciliary muscle can be thought of as a camera diaphragm, or if you prefer a more entertaining description, a sphincter muscle. When this sphincter contracts, the central "hole" gets smaller causing the zonular "springs" to relax. With zonular relaxation, the lens relaxes and gets rounder. This rounding makes the lens more powerful and allows you to read close-up.



Unfortunately, as we age our lens becomes harder and does not "relax" into a sphere very well, no matter how hard the ciliary body contracts. This loss of lens accommodation is called presbyopia and explains why we need the extra power of bifocals to read after the age of 40.

Fun-Fact

Ever wondered how those "blue blocker" sunglasses are supposed to improve vision? You know, those yellow-tinted glasses that sport enthusiasts and hunters wear?

They work because all lens systems, including the eye, suffer from some degree of chromatic aberration. This occurs because some wavelengths of light are bent more when going through a lens or prism system. Red light is bent the least, so the color red tends to focus slightly behind the retina, while blue light bends more, thus focuses in front of the retina. This creates a mild blur because not all colors can be perfectly focused at the same time.

Yellow-tinted glasses only allow certain wavelengths to pass through. This eliminates chromatic aberration and the image appears sharper.

Cataract Types and Mechanism:

The lens begins as a clear magnifying glass inside your eye, but with time can opacify. Most cataracts are of idiopathic etiology, though there are many associated conditions that lead to both congenital and environmentally induced lens opacities. Here is a short summary of the important cataract types:

Nuclear sclerotic cataracts

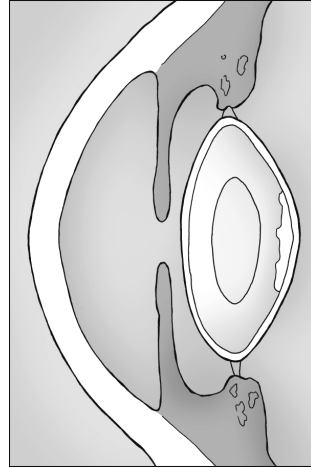
NSCs are the most common type of cataract and many consider them to be a normal maturation of the lens. Over time, the lens becomes larger and brunescens (yellow or brown), especially in the denser central nucleus. If this process goes on long enough the opacity eventually leads to visual obstruction and problems with glare. The lens can become so big that it pushes the iris forward, placing the patient at increased risk for angle closure glaucoma.

With far-advanced cataracts the middle cortical layer (the chocolate layer) can liquefy and become milky white and the nucleus layer (the central peanut) gets hard and falls to the bottom of the capsular bag. These end-stage "Morgagnian cataracts" are rarely seen in this country and are particularly hard to remove at surgery.

Some patients with nuclear sclerotic cataracts will develop so called “second sight” where it seems like the vision improves. This is because the round cataract lens is more powerful and offsets the coexisting presbyopia allowing older patients to read better. Their vision hasn’t really improved, it’s just that their cataracts are working like weak bifocals inside their eyes.

Posterior Subcapsular Cataract:

The PSC cataract forms on the back of the lens, on the surface of the posterior capsule bag. These cataracts tend to occur in patients on steroids, with diabetes, and those with history of ocular inflammation. The opacity looks like breadcrumbs or sand sprinkled onto the back of the lens. This posterior location creates significant vision difficulty despite appearing innocuous on slit-lamp exam. PSC cataracts are quite common, and often occur in conjunction with some degree of NSC.



Location is Everything!

Posterior cataracts cause more visual complaints than anterior cataracts. This is because of the optics of the eye. Advanced optics are beyond the scope of this book. Keep in mind, though, that the eye has an overall refractive power of approximately 60 diopters (40 from the cornea, and 20 from the lens). If you simplify the eye to a single 60-diopter lens system, the important “nodal point” of this system is near the back of the lens.

The closer you get to this nodal point, a greater number of light rays will be affected. Thus, small posterior cataracts are more significant than larger anterior cataracts.

Congenital Cataracts:

Lens opacities in children are of concern because they can mask deadly disease (remember the differential for leukocoria from the pediatric chapter?), and because they have devastating effects on long term vision.

Cataracts in the newborn can be idiopathic or inherited. If small or anteriorly located, they may be visually insignificant. However, when approaching a leukocoric pupil, you should first rule out potentially deadly disease. This

includes cataract masqueraders like retinoblastoma, and deadly causes of cataract like the TORCH infections and galactosemia.

A true cataract needs to be removed quickly, usually within the first two months of life, because they are highly amblyogenic. Cataract surgery is challenging in this age-group as children have impressive inflammatory responses and are not easy to examine pre- and post-operatively. After taking the cataract out, you usually don't implant a prosthetic implant in newborns, but wait a few years because their eyes are still growing. The family must deal with powerful aphakic glasses or contact lens placement until the child is old enough for the secondary lens implantation.

Traumatic Cataract:

A cataract can form after blunt or penetrating injuries to the eye. These traumatic cataracts are more common in young men. When the outer lens capsule breaks, the inner lens swells with water and turns white. The lenses are very soft and easy to suck out, but removal and implant placement can be complicated as the blunt force often tears the zonular support. If the lens is barely hanging in position, it may be safer to consult a retina specialist to remove the cataract from behind (a pars plana approach) to keep the lens from falling back into the eye.

Lens Swelling

The cells that make up the adult lens have no innervation or blood supply, and thus derive their nutrition entirely from the surrounding aqueous fluid. Because of this low O₂ tension, these lens cells survive almost entirely on glycolysis.

Poorly controlled diabetics can have very high levels of glucose. If high enough, the lens metabolism can shunt down a sorbital pathway. Sorbital buildup in the lens can then create an osmotic swelling of the lens with resulting refractive changes!

If a diabetic patient complains of episodic blurring vision, find out what their glucose has been running. If it has been high recently, don't prescribe glasses, as their prescription may still be changing from lens swelling.

Posterior Capsular Opacification (PCO):

A posterior capsule opacification isn't a true cataract, but an "after cataract" that forms after a cataract surgery. I'll be talking about the cataract surgery technique shortly, but basically we suck out the cortex and nucleus (the chocolate and the peanut) and inject a new lens into the remaining capsule (the hard candy shell).

Residual lens epithelial cells are left behind after surgery. These orphaned epithelial cells get confused (and lonely) and can migrate along the back surface of the implant and opacify the posterior capsular bag.

This is a common occurrence and fortunately is easily treated in clinic with a laser. The YAG laser is used to blast a hole in the posterior capsule. We don't break a large hole, as you don't want the implant to fall into the back of the eye, but one big enough to clear the visual access. This procedure is known as a YAG capsulotomy.

One more topic ... Lens Dislocations

As already mentioned, a lens can dislocate from traumatic force (such as a punch to the eye). It can also dislocate because of inherited diseases that affect zonular strength. The two major causes of hereditary lens dislocation are Marfan's syndrome and homocystinurea.

Marfan's disease is an autosomal dominant disease of fibrillin. These patients have tall body habitus, arachnodactyly and can have lens subluxation with the lens dislocating upwards. This can create large astigmatism as the patient is looking through the edge of the lens, and may eventually require cataract extraction.

Fun Fact

Some historians believe that Abraham Lincoln may have had Marfan's syndrome.

Homocystinurea is an autosomally recessive hereditary disorder that results in an absence of cystathionine B-synthetase. This enzyme causes the conversion of homocysteine to cystathionine. These patients have a marfanoid habitus, arachnodactyly, and there is a 50% incidence of mental retardation. The lens zonules are largely composed of cysteine, and without good cysteine, the zonules become brittle and can break. The majority of these patients develop downward lens dislocations. They also have poor peripheral circulation and are subject to thromboembolic events under general anesthesia.

Is your patient “ripe” for surgery?

Most people over 50 have some degree of cataract in their lens. The question then becomes “should you have surgery or not.” This is not always a clear-cut choice: you will be amazed at the dense cataracts that patients are still able to see through, and conversely, the seemingly “wimpy cataract” that causes major visual complaints.

There is a saying in ophthalmology, “If you can see in, than the patient can see out.” That is to say, if you can see the retina clearly with your ophthalmoscope, it is likely that the patient can see clearly through their lens. More objectively, we generally use 20/50 as a guideline for surgery as this is the minimal driving acuity in most states, but patients have different visual needs. A visual acuity of 20/30 is not acceptable for a young commercial airline pilot. Conversely, potentially life-threatening anesthesia might not be necessary for a 20/70 nursing home patient who likes jazz music and is happy with his vision.

Acuity isn’t everything:

One big complaint that people have is glare. In the dark a patient may see fine. But have them drive into the sun or at night with car headlights coming at them, and they become blinded by the scattering of light through their hazy lens. Many patients tell us that they no longer drive at night. We can test glare in the clinic by checking vision while shining a light in the eye. Also, you can formally test glare with the BAT (brightness acuity tester) device. This is a light-bulb illuminated hemisphere with a view hole that induces glare.



Another indication for surgery is the presence of underlying retinal disease such as advanced diabetic retinopathy. If a cataract interferes with careful fundus examination or laser treatment, the lens needs to come out.

Who decides?

Ultimately, it’s our patient’s decision whether to have surgery. In an ideal world without operative complications everyone should have cataract surgery as soon as the vision drops to 20/25. Unfortunately, bad things can happen in surgery, and patients have to decide if their vision is affecting their life enough to take the risk of surgery. Our job is to educate and inform our patients about these risks and their surgical options.

Cataract surgery – a historical prospective:

In Egyptian times, cataract surgery was a primitive affair. Eye “surgeons” would take a sharp needle and shove it into the eye to rip the lens from its zonular support and allow it to fall into the back of the eye. This technique, called “couching,” clears the visual axis, because the lens is now bouncing around in the bottom of the eye. Patients had terrible vision after this (with approximately 20 diopters of hyperopia) but back in those days of ultra-dense cataracts, this was an improvement allowing these early patients to see basic shapes, such as the outline of the pyramids and perhaps their camel.

During World War 2, British fighter pilots suffered from penetrating eye injuries when fragments of their Plexiglas cockpits exploded. Eye doctors of that era found that the eye seems to tolerate plastic, thus spawning the idea of using plastics to create intraocular lens implants to replace the natural lens.

Cataract implants have evolved since then. Now we have lenses made of PMMA plastic, acrylic, and silicone. These implants can be folded through smaller incisions and placed in different positions inside the eye - in the capsule, behind the iris in the “sulcus,” or even sitting on top of the iris in the anterior chamber. We can also perform cataract surgery through much smaller incisions, allowing faster recovery times and lower complication rates.

Preoperative measurements: how to choose your implant power?

Our goal in cataract surgery is to put the ideal power intraocular lens into the eye so that the patient won't need additional glasses for viewing distant objects. This is not always an easy task, as everyone's eyes are different and minor anterior-posterior shifts in the lens placement will severely affect the end refraction. There are many formulas designed from both lens theory and regression analysis to help you choose the correct power lens. We won't be going over these formulas, but keep in mind that we need to measure two things to come up with the right prescription for the implant:

- a. The corneal curvature:** Remember that the cornea-air interface actually performs the majority of the refractive power of the eye. The cornea performs approximately 40-diopters of refraction, while the lens makes up the last 20-diopters. A person with a powerful cornea will need a less powerful lens. We measure the curvature of the cornea with a keratometer.

b. The length of the eye: The shorter the eye, the more powerful lens you'll need to focus images onto the retina. We measure this with the A-scan mode of a hand-held ultrasound.

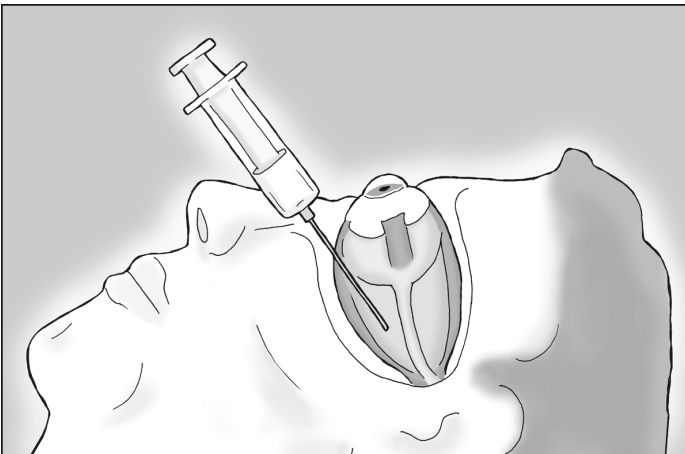
Cataract Surgery – How to Do it!

Cataract surgery is easy in concept, but actually performing this surgery is challenging as you're working under a surgical microscope with delicate ocular structures.

There are many steps to cataract extraction, and many ways to go about it – everyone has their own combination of machine settings, viscoelastics, irrigating fluids, and preferred instruments. Essentially, you can break down the cataract surgery into a few steps:

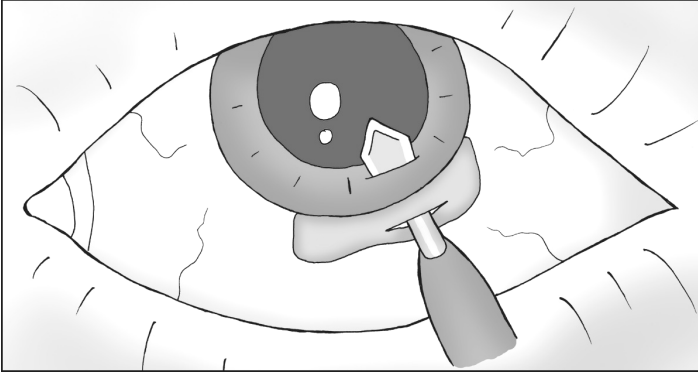
1. Anesthesia

Dilate the pupil, prep, and anesthetize the eye. Anesthetic can be given with simple topical eyedrops like tetracaine and I perform the majority of my cases with topical anesthesia. We can also perform a retrobulbar block by injecting lidocaine/bupivacaine into the retrobulbar muscle cone to knock out sensation through V1, and eye movement by knocking out CN3 and CN6. The trochlear nerve (CN4) actually runs outside the muscle cone, so you can see some residual eye torsion movement after the block. If you've never seen a retrobulbar block, you're in for a treat (it can look gruesome the first time).



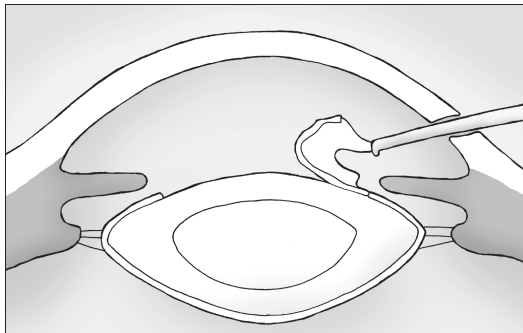
2. Enter the eye

The main surgical entry site can be performed several ways. You can enter the eye by cutting through the cornea, or you can spend more time tunneling in from the sclera. A clear-cornea incision is fastest, while the scleral tunnel takes longer but is easier to extend if you run into surgical complications.



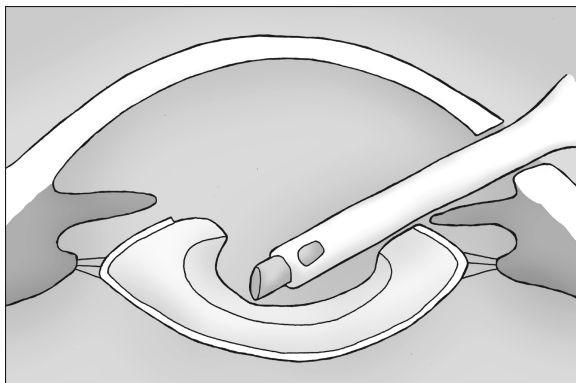
3. Capsulorhexis

To get the lens out you need to tear a hole in the anterior capsule (hard candy shell) of the lens. This step is important to get right, because if the rhexis is too small, it will make cortex and nucleus removal harder. Also, the outer capsule you are tearing is finicky and can tear incorrectly, with a rip extending radially outwards to the equator (not good). If you lose your capsule, you can lose pieces of lens into the back of the eye. Poor capsular support also makes implant placement that much harder.



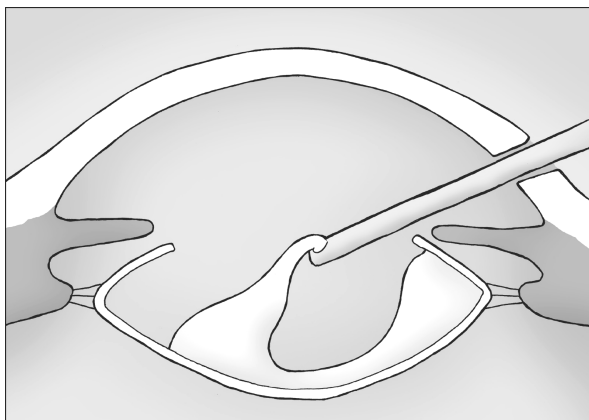
4. Phacoemulsify

We use an instrument called the phaco handpiece to carve up the lens nucleus. This machine oscillates at ultrasonic speeds and allows us to groove ridges into the lens. After grooving, the lens can be broken into pieces and eaten up one-by-one.



5. Cortical removal

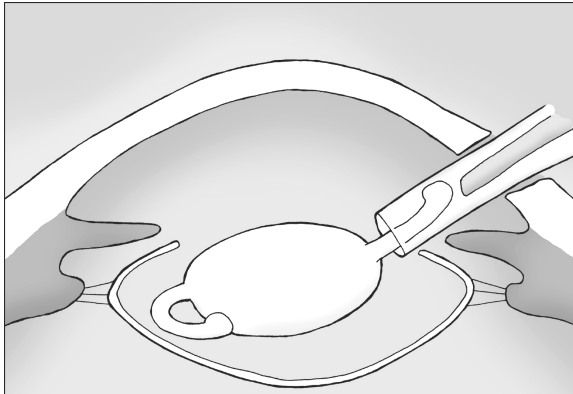
After removing the inner nucleus, we can remove the residual cortex (the middle chocolate layer) of the lens. This cortex is soft but wants to stick to the capsular bag. You don't want to leave too much, as it will cause inflammation and can cause "after cataracts" (posterior capsule opacification). We strip this with suction and vacuum it out.



You need to be careful with your posterior capsule during this cleanup. The surgeon tries to maintain the posterior capsule for a couple of reasons - not only does it create a support structure for the new lens, but it maintains the barrier between the anterior and posterior chambers, keeping the jelly-like vitreous from squeezing into the anterior chamber.

6. Insert the lens

We usually use a foldable lens that can be injected directly into the bag. If we've lost capsular support (for example, we managed to break the posterior capsule during phaco or cortex removal), the lens can be placed on top of the entire capsular bag, right behind the iris. If support for this sulcus placement is questionable (i.e., you've had a LOT of complications with the case), a lens can be placed in the anterior chamber on top of the iris, or sutured to the back surface of the iris (tricky).



7. Close up

You now close the eye. Many small incision corneal wounds are self-sealing, but some require closure with 10-0 nylon suture that will eventually biodegrade.

8. Postop care

Immediately after surgery, antibiotics are dropped and a shield is placed over the eye. The patient is then seen the next day and will use antibiotic drops and a steroid drop to decrease inflammation.

Conclusion: Cataract surgery is not easy

Almost every ophthalmologist performs cataract surgery, so there is a tendency to view this as a simple procedure that only takes a few minutes. Some cataract cowboys are able to perform an extraction in ten minutes and may even downplay the risk.

The reality is that cataract surgery is very difficult. The lens is mostly clear, floating in clear aqueous, supported by a microns-thin clear capsule that wants to tear. The patient is usually awake, so any small movement such as a cough or simple head adjustment looks like an earthquake under the microscope. Cataract extraction involves many steps, and early mishaps at the beginning of the case cascade and make the later steps that much more difficult.

Look at it this way: any surgery that takes over 100 operations to develop basic proficiency has got to be tough. Cataract surgery is like flying an airplane ... it takes many years of training, screening, certification, accreditation to be an accomplished pilot, and most flights are uneventful. But you want a qualified person behind the wheel when you hit turbulence.

Fortunately, most of the time things go just fine.



Would you prefer speed or accuracy?

Pimp Questions

1: What does it mean to have a phakic eye or an aphakic eye?

Phakic means that the patient has their original lens. Pseudophakic means that they have an intraocular lens implant. Aphakic means that their lens was removed, but no replacement lens was placed.

2. What are the layers of the lens?

There are three layers to the lens. The outer capsule, the inner nucleus, and a middle cortex ... in a configuration like a peanut M&M candy.

3. When you accommodate (look at near objects) do the zonules relax or tighten?

The zonules relax. With accommodation, the spincter-like ciliary body contracts, the zonules relax, and the lens relaxes and becomes rounder (thus more powerful). You're going to have to think that one out a few times and look at the drawing in this chapter.

4. What are the two functions of the ciliary body?

The ciliary body changes lens shape, allowing fine focusing and accommodation. It also produces aqueous fluid that inflates the anterior chamber and nourishes the avascular lens and cornea.

5. By what mechanism can a diabetic patient have a temporary refractive error?

Too much glucose will switch the lens metabolism from anaerobic glycolysis to a sorbitol pathway. Sorbitol buildup in the lens creates an osmotic swelling that changes the lens power (the round, swollen lens makes images focus in front of the retina, thus the patient is temporarily near-sighted).

6. Why do yellow sunglasses make images seem sharper?

All lens systems have chromatic aberration because the different colors of light bend differently. This means that images don't focus perfectly on the retina – the blue component focuses slightly in front of the retina, while the red component focuses slightly behind. Tinted glasses limit the spectrum of color that hits the retina, and makes images appear sharper.

7. How soon should a child with a cataract go to surgery?

Soon, as cataracts create a visual deprivation that quickly leads to amblyopia. Some practitioners recommend surgery prior to two months.

8. How can a cataract cause glaucoma?

Many cataracts are large, and this bulk can push the iris forward and predispose to angle closure glaucoma. Also, end-stage cataracts can leak proteins into the aqueous fluid and the resulting inflammatory cells (macrophages) can clog the trabecular meshwork.

9. What measurements must you have to calculate a lens implant power?

You need to know the cornea curvature (because the cornea performs the majority of the eye's refractive power) and the length of the eye.

10. How much of the lens is removed in typical cataract surgery?

With eye surgery, we create a hole in the anterior capsule and suck out the inner nucleus and cortex. The outer capsule is left behind to serve as a pocket to put the new implant into.

11. What's the difference between a PCO and a PSC cataract?

PCO: posterior capsular opacification. This is an "after cataract" that forms on the back surface of the posterior capsule after successful cataract surgery. This opacity can be cleared with a YAG laser.

PSC: posterior subcapsular cataract. This is a cataract that forms on the back portion of the lens. These tend to occur more often in diabetics and those on steroids, and tend to be visually significant because of their posterior position.

12. What does it mean to place a lens "in the sulcus?"

The sulcus is the space between the lens capsule and the back of the iris. If the posterior capsule is torn and can't support the lens, you can often place a lens on TOP of the entire capsule in this potential space.

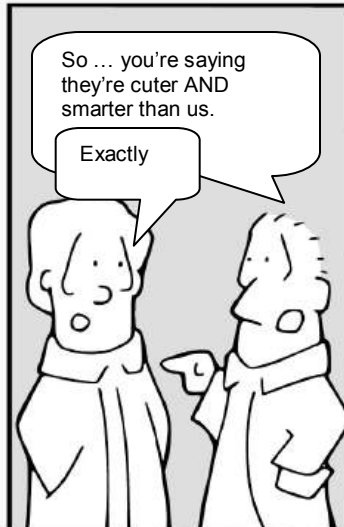

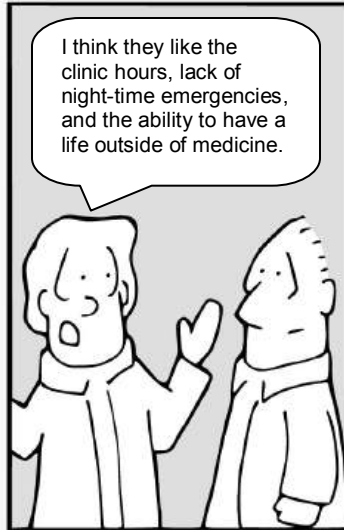

13. What drops are given after a cataract surgery?

Usually an antibiotic, such as ciprofloxacin or vigamox. Also, a steroid is given to decrease inflammation.

Board Review

The Eyes Have It

by Tim Root



Super Review Quiz

by Tim Root, M.D.

It's doubtful that you'll come across many eye questions on your medical boards, but it's always possible. All of the background knowledge needed to answer these questions can be found throughout the prior chapters and I've attempted to keep the difficulty at a student level.

To save you from excessive page flipping, I've listed the answers *after* each question. You may want to put your hand over the answer box as you work through these problems. In the immortal words of Douglas Adams:

Don't Panic!

1. Which conjunctivitis is *least* likely to occur bilaterally?

- a. allergic
- b. viral
- c. bacterial
- d. vernal

Answer: The correct answer is (c) bacterial. Allergies are likely to affect both eyes and present with itching and watering. Vernal is a type of seasonal allergy you see in young boys. Viral conjunctivitis usually starts in one eye, but hops to the other eye as it is very contagious. Bacterial conjunctivitis can occur bilaterally, but of the available choices is most likely to occur in just one eye.

2. You're consulted by an intern from the ICU because his ventilated patient, with a head injury, has a fixed and dilated pupil. The intern is concerned for acute glaucoma. What do you tell him?

- a. find a Tono-Pen and check the pressure
- b. call his upper-level fellow immediately
- c. taper the patient's benzos
- d. increase the PEEP ventilator setting

Answer: Well, you need more history, of course, but any blown pupil in a trauma-ICU should make you think of an uncal-herniation and impending death. Tell him to (b) find his senior resident/fellow/attending immediately and call you back if they still want an eye-consult.

3. Which optic nerve finding is most concerning for glaucomatous damage?

- a. large disk size
- b. horizontal cupping
- c. vertical cupping
- d. disk tilt

Answer: The correct answer is (c) increased vertical cupping, which would go against the ISNT rule (the **I**nferior and **S**uperior neural rim is normally the thickest with the **N**asal and **T**emporal thinner). Many patients have large myopic (near-sighted) eyes with resulting large optic disks and disk “tilting” from the angle at which the nerve enters the back of the eye – these are physiologically normal variants and are not concerning for glaucoma.

4. A young 23-year-old black man presents with a hyphema in the right eye after blunt injury. All of the following are acceptable initial treatments except?

- a. sleep with the head elevated
- b. prednisolone steroid eye drops
- c. cyclopentolate dilating drops
- d. carbonic anhydrase inhibitor pressure drops

Answer: The correct answer is (d). For patients with hyphema (blood in the eye) advise them to avoid straining and sleep with their heads elevated to allow the blood to settle. Use steroids to decrease the inflammation and a medium-acting cycloplegic to dilate the eye for comfort and to keep the inflamed iris from “sticking” to the underlying lens. If the pressure is high, you can use pressure drops, but we avoid CAIs in African Americans as it induces RBC sickling in sickle-cell patients. You can get a sickle prep if you are suspicious for this disease.

5. A 7-year-old boy presents with a grossly swollen eyelid. His mother can't think of anything that set this off. What finding is *most* characteristic of a dangerous orbital cellulitis?

- a. chemosis
- b. warmth and erythema of the eyelid
- c. physically taut-feeling eyelid
- d. proptosis

Answer: The correct answer is (d). With any eyelid cellulitis, you must determine if the infection is pre-septal or post-septal (i.e., orbital cellulitis). While chemosis is certainly seen with orbital infection, a proptotic bulging eye is even more indicative of orbital infection. Other signs include decreased eye-movement, pain with eye-movement, and decreased vision.

6. What location for a retinal detachment would be most amenable to treatment by pneumatic retinopexy?

- a. inferior rhegmatogenous detachment
- b. superior tractional retinal detachment
- c. superior rhegmatogenous detachment
- d. traumatic macular hole

Answer: This question covers several concepts. Rhegmatogenous detachments are the classic detachment occurring from a break in the retina. A pneumatic retinopexy is the technique of injecting a gas bubble into the eye that floats and tamponades the break. Gas bubbles require careful head-positioning and work best for superior breaks (patients can't stand on their heads for weeks for inferior breaks). The correct answer is therefore (c).

7. A mother brings in her two-year old child because she is concerned that her baby is cross-eyed. Which of the following is an *inappropriate* statement:

- a. the baby may maintain 20/20 vision
- b. the esotropia could lead to permanent vision loss
- c. the esotropia might be corrected with glasses alone
- d. surgical treatment should be delayed until adolescence

Answer: Answer (d) is the inappropriate statement. Esotropia (cross-eyed) is a common finding in the pediatric clinic. There are many causes, and one of them is poor vision in one eye. Spectacle vision can help anisometropic eyes fuse images properly and correct the alignment problem. This condition should be treated promptly, via spectacle correction, and possibly patching the strong eye to avoid amblyopia – if the crossing doesn't correct with these measures, then you proceed to surgical options. A child may maintain good vision in each eye if he/she learns to cross-fixate (switch eye dominance depending upon what direction the child is looking). There is no point in waiting until adolescence – you want to avoid an amblyopic eye and give the child a chance to develop good stereopsis at an early age.

8. Which of the following is the biggest risk factor for primary open angle glaucoma?

- a. Asian ancestry
- b. smaller diurnal pressure IOP changes
- c. thin corneas
- d. large optic disks

Answer: Asians are more likely to develop acute angle-closure glaucoma, not POAG. Everyone has diurnal eye pressure changes, and there is some evidence that glaucomatous patients have *larger* shifts in their pressure throughout the day. Large optic disks aren't concerning, though large *cupping* of a disk could indicate nerve fiber loss from glaucoma. Thin corneas ARE associated with glaucoma, as shown by the famous OHTS clinical trial. We measure every new glaucoma patient's corneal thickness with a small ultrasound pachymeter. The correct answer is (c).

9. A 27-year-old contact lens wearer presents to the ER complaining of ocular irritation. On exam he has a small 2mm corneal abrasion. You should

- a. treat with erythromycin ointment
- b. treat with ciprofloxacin drops
- c. bandage contact lens for comfort and speed reepithelialization
- d. patch the eye and follow-up in 72 hours

Answer: You need to be concerned for pseudomonas infection in any contact lens wearer. Erythromycin is great stuff, but these higher risk patients should get something stronger like a fluoroquinolone (cipro). A bandage contact lens can help with painful abrasions, but I'd avoid one in this patient as the abrasion isn't big, and you typically don't patch ulcers. Patching can also be used to help with lubrication and comfort, but I never patch a potential infection, as bacteria like to grow in dark warm environments. If you decide to patch, you need to see your patient daily to make sure nothing is brewing under that patch. The most appropriate answer is (b).

10. A woman presents to you complaining of a red, watering eye for the past two days with stinging and some photophobia. Her vision has dropped slightly to 20/30. She has a history of diabetes and is taking drops for glaucoma, but is otherwise healthy. The most likely cause of her redness is:

- a. angle-closure glaucoma
- b. viral conjunctivitis
- c. diabetic retinopathy
- d. papilledema

Answer: This woman probably has a history of POAG (primary open angle glaucoma) if she is on drops. If she were to have an acute angle closure, her eye would be very painful and the vision would have gotten much worse from corneal edema. Diabetic retinopathy is usually a background finding of leaky vessels in the retina and doesn't create this picture. She merits a full eye exam, but her symptoms are consistent with "pink eye," with viral conjunctivitis being the most common cause in an adult. The correct answer is therefore (b).

11. A patient presents after MVA with a fracture of the orbital floor. What would be the indication for surgery in the near future?

- a. double vision that worsens with upgaze
- b. chemosis and moderate proptosis
- c. restricted forced ductions
- d. decreased extraocular movement

Answer: Floor fractures are very common and these patients always look impressively bad on exam, with marked swelling and subconjunctival bleeding. They can have decreased EOMs and proptosis from this swelling alone, which shouldn't concern you. More worrisome is entrapment of the inferior rectus muscle in the orbital floor – this entrapment can only be determined by forced ductions ... grab the limbus with forceps and tug on the eye to see if movement is restricted. The correct answer is (c).

12. A 64-year-old man presents to you with new onset of “crossed-eyes.” His left eye can't move out laterally and he has a chronic mild headache that he attributes to eyestrain. Which of the following is least likely the cause of his condition:

- a. hypertension
- b. diabetes
- c. aneurysm
- d. increased intracranial pressure

Answer: The most common causes of all the ocular nerve palsies are from vasculitic events secondary to diabetes or hypertension. It sounds like this patient has a CN6 palsy as he can't abduct his eye. With abducens palsy you should always consider increased intracranial pressure. An internal carotid aneurysm *could* hit the 6th nerve in the cavernous sinus, but you would expect other findings with these cavernous lesions. Aneurysms in general cause more third nerve palsies. Thus, the correct answer is (c).

13. The abducens nucleus would be most affected by a brainstem lesion at:

- a. pons
- b. mid-brain
- c. medulla
- d. foramen magnum

Answer: To answer this question you need to know where the 6th nerve nucleus is located. One useful aid is the "4-4 Rule," which states that the bottom four nuclei (CN 12,11,10,9) are in the medulla, while the next four nuclei (CN 8,7,6,5) are in the pons. The correct answer is therefore (a).

14. The pupillary defect that affects the *afferent* arm of the pupillary response is the:

- a. Marcus Gunn pupil
- b. Argyll Robberson pupil
- c. Adies pupil
- d. Horner's pupil

Answer: A Marcus Gunn pupil is the classic afferent pupillary defect (APD) that we check with the swinging light test. The Argyll Robberson is the syphilitic pupil that reacts with near vision, but doesn't respond to light. Horner's and Adies are disorders of the sympathetic and parasympathetic efferent pupil response. The correct answer is (a).

15. Aqueous fluid is produced in which chamber?

- a. anterior chamber
- b. vitreous chamber
- c. posterior chamber
- d. trabecular chamber

Answer: There are actually three chambers in the eye. Aqueous is produced in the posterior chamber where it flows forward into the anterior chamber and drains through the trabecular meshwork into the canal of Schlemm. The vitreous chamber is the big one in the back that is filled with jelly-like vitreous humor. The correct answer is therefore (c).

16. Which orbital bone is most likely to fracture with blunt trauma to the eye?

- a. zygomatic
- b. maxillary
- c. ethmoid
- d. sphenoid

Answer: The orbital floor, which is formed by the maxillary bone, is the most commonly fractured wall of the orbit. Orbital fat will commonly herniate through this bone and muscle can get stuck if the break acts like a trapdoor. The ethmoidal lamina papyracea is also often broken because it is the thinnest, but this occurs less often because of extensive bolstering. The lateral zygomatic component of the orbit is rarely broken, nor the more posterior sphenoid. The correct answer is (b)

17. When a patient focuses on near objects, the lens zonules:

- a. rotate
- b. contract
- c. relax
- d. twist

Answer: The zonules connect to the lens periphery and suspend the lens like a trampoline to the surrounding ciliary muscle. With near vision, the ciliary body contracts like a sphincter, causing the zonules to relax, and the lens to get “rounder.” This rounding of the lens increases its refractive ability and allows focusing on near objects. With age, the lens hardens and loses its ability to round out – a process called presbyopia. The correct answer here is (c).

18. What is glaucoma?

- a. retinal damage from high intraocular pressure
- b. optic nerve death caused by mechanical stretching forces
- c. ischemic nerve damage from decreased blood perfusion gradients
- d. none of the above

Answer: The best answer here is probably the last one, as no one really understands the pathogenesis of glaucoma. Ultimately, it involves death of the nerve fibers and it seems associated with high ocular pressure. However, there are plenty of patients out there with glaucoma damage and normal eye pressure, so pressure isn't the “ultimate cause” – but this is certainly the only risk factor that we can treat. There are many mechanical and biochemical theories that explain glaucoma damage, and each has its merits and faults.

19. Which condition would result in an inaccurately high reading with applanation pressure measurement?

- a. thin cornea
- b. thick cornea
- c. edematous cornea
- d. keratoconus

Answer: We measure pressure by pushing the cornea with a weighted device called an applanation tonometer – a process I compare to kicking a car tire to determine the air pressure. Thick “truck-tire corneas” are going to feel hard when you measure them. Conversely, thin “bicycle-tire” corneas are going to feel softer. Corneal edema also makes the eye feel squishy (giving a falsely low pressure) and patients with keratoconus often have thin corneas. The correct answer here is (b).

20. Gonioscopy overcomes the concept of:

- a. angled biomicroscopy
- b. spherical aberration
- c. total internal reflection
- d. specular microscopy

Answer: The trabecular meshwork can't be visualized directly because light coming from this angle bounces off the cornea (technically, the tear film) back into the eye because of Snell's Law and total internal reflection. By placing a hard glass lens onto the eye, the cornea-air interface is broken and light can escape and be seen through the microscope. The correct answer is therefore (c).

21. A 32-year-old white man with a history of type-1 diabetes presents to you complaining of decreased vision. He has not seen an eye doctor in years. On exam, you find numerous dot-blot hemorrhages, hard exudates, and several areas of abnormal vasculature in the retina. Pan-retinal photocoagulation might be done in this patient to:

- a. kill ischemic retina
- b. tamponade retinal tears
- c. ablate peripheral blood vessels
- d. seal off leaking blood vessels

Answer: PRP is performed to kill areas of peripheral ischemic retina. By doing so, less VEGF is produced, leading to cessation and regression of neovascularization. While it is true that we sacrifice some of the peripheral retina with PRP, it is worth it to save important central vision. Lasers *can* be used to help peg down retinal tears and to help with leaking vessels ... but this is called “focal laser therapy.” The correct answer here is (a).

22. Which of the following is a risk factor for retinal detachment?

- a. black race
- b. male sex
- c. presbyopia
- d. myopia

Answer: The correct answer is (d) myopia. Myopic (near-sighted) eyes are large eyes with a stretched-out retina that is more likely to tear at the periphery. Neither blacks nor males are at higher risk of RD. Presbyopic lens hardening occurs with age and doesn't have anything to do with the retina.

23. A 57-year-old man complains of flashing lights and a shade of darkness over the inferior nasal quadrant in one eye. On exam you find the pressure a little lower on the affected eye and a questionable Schaffer's sign. What condition would lead you to immediate treatment/surgery?

- a. macula-off rhegmatogenous retinal detachment
- b. epi-retinal membrane involving the macula
- c. dense vitreous hemorrhage in the inferior nasal quadrant
- d. mid-peripheral horseshoe tear with sub-retinal fluid

Answer: Schaffer's sign is when you see pigment behind the lens on slit-lamp exam, and occurs when a tear of the retina allows the underlying pigment to release into the vitreous chamber. A macula-off retinal detachment is unfortunate, but isn't an immediate emergency. It certainly needs to be repaired, but can wait for a few days if necessary, as the damage to the detached macular photoreceptors has already occurred. Epi-retinal membranes are common and aren't an emergency unless actively creating a tractional detachment. Vitreous hemorrhage is not an emergency either, assuming there isn't a detachment behind that blood on your ultrasound. Smaller retinal tears, however, need to be treated early to make sure they don't progress and peel off the macula. The answer is (d).

24. Oral doxycycline helps blepharitis patients by:

- a. antibiotic tear secretion
- b. changing lipid viscosity
- c. inhibiting cytokine release
- d. improved lacrimal gland excretion

Answer: Doxycycline changes the lipid viscosity of the meibomian gland secretions, improving oil secretion from the gland into the tear film. This superficial lipid layer is needed to keep the tears from evaporating too quickly. The correct answer is (b).

25. Put the following retinal layers in order from inside (next to the vitreous) to outside:

- a. ganglion nerves, photoreceptors, choroid, then sclera on the outside.
- b. photoreceptors, ganglion nerves, choroid, then sclera on the outside.
- c. choroid, photoreceptors, ganglion nerves, then sclera on the outside.
- d. choroid, ganglion nerves, photoreceptors, then sclera on the outside.

Answer: The correct answer is (a). This question illustrates a few important concepts. The first is that the photoreceptor cells lie relatively deep in the retina, such that light has to pass through many layers to reach them. One of these layers is the ganglion nerve layer, comprised of nerve fibers that course along the surface of the retina toward the optic nerve. The choroid is a deeper bed of blood vessels that nourishes the photoreceptors from below, while the sclera is the tough collagen matrix that forms the outer wall of the eye.

26. In the absence of lens accommodation, a myopic eye focuses images:

- a. in front of the lens
- b. In front of the retina
- c. behind the retina
- d. behind the cornea

Answer: The correct answer is (b). Myopic, or near-sighted eyes, are typically large eyes that focus images in the middle of the eye, in front of the retina within the vitreous chamber. These eyes require a minus concave-shaped lens in their glasses - this effectively weakens the overall refractive power of the eye, allowing images to focus further back on the retina.

27. A man calls the office complaining of eye pain after splashing bleach in his eye. You should instruct him to:

- a. patch the eye and immediately go to the office
- b. irrigate the eye for 15 minutes and then go to the office
- c. immediately apply lubricating ointment and then go to the office
- d. immediately wash the eye with contact saline solution and go to the office if he notices any change in vision

Answer: The final visual outcome for a chemical burn is going to depend upon how quickly the chemical is washed out of the eye, so have your patient wash out their eye immediately! Chemical injury is one of the few eye problems that you treat prior to checking vision. The correct answer here is (b).

28. What antibiotic would you use in a newborn with suspected chlamydial conjunctivitis?

- a. Ciprofloxacin drops
- b. Erythromycin drops
- c. Oral Doxycycline
- d. Erythromycin drops and oral erythromycin

Answer: Chlamydia is one cause of conjunctivitis you should suspect in the newborn. Treatment involves topical drops such as erythromycin and systemic coverage because of concurrent respiratory infections these kids can develop (chlamydia infects mucous membranes and can cause pneumonitis). You don't use doxy in children (especially under the age of eight). Fluoroquinolones might work, but we don't use them in children because of theoretical bone suppression. The correct answer is (d).

29. You are measuring eye deviation in a child with strabismus. The corneal light reflex is 2mm temporal to the pupil in the right eye. How much deviation would you estimate?

- a. 10 diopters esotropia
- b. 20 diopters exotropia
- c. 30 diopters esotropia
- d. 40 diopters exotropia

Answer: You can estimate eye alignment using the Hirschburg rule – for every millimeter the corneal light reflection is decentered, equals 15 diopters of deviation. This child has 30 diopters of esotropia, so (c) is the correct answer.

30. Steroids typically induce what kind of cataract?

- a. Nuclear sclerotic
- b. Posterior polar
- c. Posterior subcapsular
- d. Cortical

Answer: Steroids and diabetes are classically known to cause posterior subcapsular cataracts on the back surface of the lens. Nuclear sclerotic cataracts are common and usually result from aging, while posterior polar cataracts are often congenital. Cortical cataracts are also common and are rather nonspecific. The correct answer is (c).

The
Videos

Video Lectures!

by Tim Root, M.D.

Did you know you can watch videos that cover everything in this book? That's right - I've recorded a short lecture for each chapter that you watch (for free) online at www.OphthoBook.com

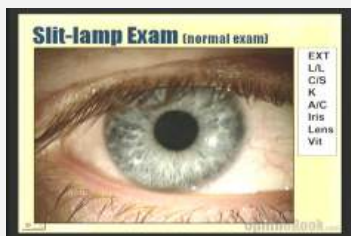Now, these aren't just boring PowerPoint slides. I've filled these lectures with cartoon-animations, full-motion movies, and slit-lamp video showing various eye conditions captured on live patients! I've kept these lectures short (around 25 minutes each) so that they won't be overwhelming. This is high-yield material and well presented.

In fact, looking through my website's visitor statistics, it appears that people might actually like these videos even *more* than the textbook itself. By reading through the visitor comments listed under each video you can see that students seem to really dig them. I hope you also find these mini-lectures helpful!

Video #1: History and Physical

Length: 18 minutes

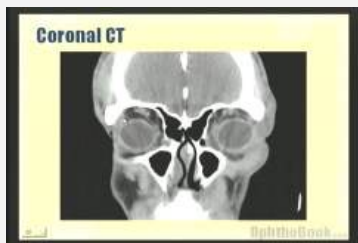This first video covers the basic eye exam with emphasis on common findings and how to check the ocular "vital signs." You may find the first half of the presentation a little slow as it covers basic history and common complaints. The second half picks up, however, with great slit-lamp videos that illustrate each ocular structure you should examine in a systematic fashion.



Video #2: Anatomy of the Eye

Length: 25 minutes

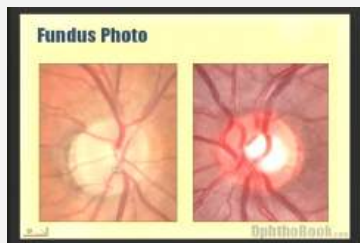
This second video is chock-full of high-yield anatomy facts. The eye is a complex structure with layers, lens, muscles, receptors, and is surrounded by many bones. I keep things simple in this video. This video lecture follows the book closely, with many of the same drawings, but I've also scanned in an entire head CT and included microscopic slit-lamp video to help you correlate the cartoon drawings with real clinical imaging.



Video #3: Glaucoma

Length: 21 minutes

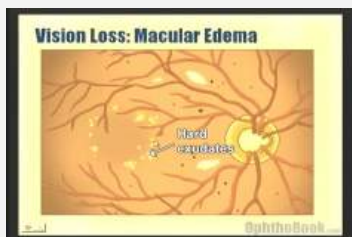A large percentage of our patients have glaucoma and this video explains important pressure concepts. This introductory video covers the basics such as open-angle and closed-angle glaucoma. In addition, exam findings, pressure theory, and treatment options are shown with full-motion video clips. I think you'll find this one entertaining.



Video #4: Retina

Length: 16 minutes

This introduction to the retina covers all the basics: anatomy, diabetic retinopathy, retinal detachments, and macular degeneration. This is a lot of complex material, so I've tried to keep things straightforward and to the point. In fact, this is the shortest lecture of the lot!



Video #5: Eye Infections

Length: 22 minutes

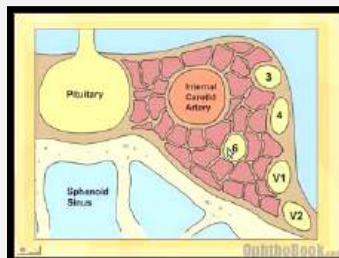
This video illustrates the important infections involving the eye including conjunctivitis, blepharitis, HSV, pre-septal cellulitis, and the dreaded endophthalmitis. I've included full-motion slit-lamp video and animated CT scans demonstrating orbital cellulitis findings.



Video #6a: Neuro-Ophthalmology (Part One)

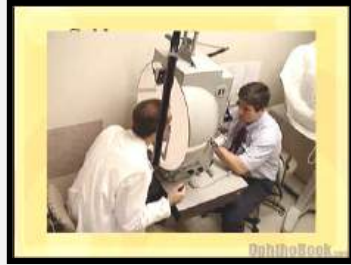Length: 24 minutes

Neurology is so complex, that I had to break this chapter down into two separate lectures to keep it from being overwhelming. The first lecture focuses on eye muscle movements. I begin with the muscle anatomy, and then demonstrate the cranial nerve palsies using animated cartoons. Finally, I give tips on localizing lesions. Great stuff!




**Video #6b:
Neuro-Ophthalmology (Part Two)**
Length: 27 minutes

The second video covers the rest of the material from the neurology chapter with some additional bonuses. Specifically, I show you an easy approach to understanding visual fields and go into detail on specific diseases such as myasthenia gravis, optic neuropathies, and giant cell arteritis. Never has neuro-ophthalmology been this easy!



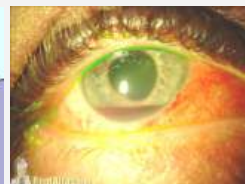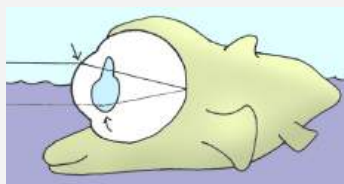
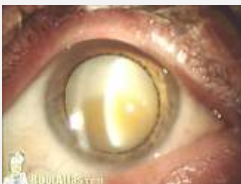Video #7: Pediatrics
(my best lecture to date)
Length: 23 minutes

This lecture is unique for two reasons: the first is an animated cartoon I've created that shows you how to detect phorias, tropias, and measure prism deviations. The second is that I've created an animation showing you how to perform retinoscopy – the hardest exam technique to learn (because it's usually so hard to explain)!



Videos 8-10
Coming soon!

I'm still recording the last three lectures (trauma, optics, and cataract). Perhaps by the time you read this, they'll be posted online!



The Appendix



*We've removed the appendix ... now we're looking
for Dr. Osgood's contact lens!*

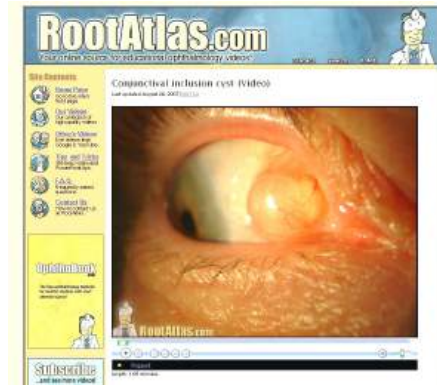RootAtlas.com

More Eye Videos

If you find the video lectures helpful, you might want to stop by and look at my full video collection at RootAtlas.com. This is an online video atlas I've created to post interesting eye findings I've seen under the microscope. Many of these videos can be downloaded to your computer for insertion into your own PowerPoint presentations.

I've uploaded over 70 videos to this site, and I believe this is the largest collection of slit-lamp videos online.

You will be impressed by the pathology I've managed to capture on film. Have you ever seen a video of spontaneous venous pulsations? I think you'll find these microscopic videos much easier to understand than still photographs.



The videos at RootAtlas.com that you might find interesting (since I discuss them in OphthoBook):

- Meibomian gland expression in blepharitis
- Pyogenic granuloma from a chalazion
- Allergic conjunctival chemosis
- Removing a piece of metal from the cornea
- Herpetic dendritic ulcer
- Corneal laceration and the Seidel test
- Hyphema blood layering in the eye
- Hypopyon pus layering in the eye
- Cell and flare – what they actually look like!
- Neovascularization of the iris
- Laser iridotomy to break acute glaucoma
- Mature cataracts
- Pseudoexfoliation of the lens
- Using the applanation tonometer to check pressure

FlashCard Review

Online flashcard questions derived from the OphthoBook!

Apparently, some people are never satisfied. Despite the chapter content, the “pimp questions,” the “Board Review Test,” and the free online video lectures -- some readers have demanded even *more* review material! So, I have combed through OphthoBook and have prepared 121 question-answer flashcards.

You'll find the answers to these flashcard questions at the OphthoBook.com website (look in the “extras” section). I break the questions down by specialty, but here is the entire alphabetical list so you know what to expect, or in case you want to read the questions by themselves.

1. Are babies usually born myopic or hyperopic?
2. By what mechanisms can patients with diabetic retinopathy lose vision?
3. Describe the aqueous pathway from start to finish.
4. Describe the tear pathway from start to finish.
5. Describe two methods to check eye pressure.
6. How are chemical injuries to the eye treated?
7. How are metal foreign bodies removed from the cornea?
8. How are PCO cataracts removed?
9. How do we classify diabetic retinopathy?
10. How do we treat proliferative diabetic retinopathy?
11. How do you diagnose a corneal abrasion?
12. How do you diagnose a corneal perforation?
13. How do you diagnose and treat giant cell arteritis?
14. How do you evaluate a patient with suspected open-globe?
15. How does applanation work?
16. How does neovascular glaucoma occur?
17. How does optic neuritis present?
18. How long is the eyeball?
19. How many chambers are there in the eye?
20. How might an inflamed conjunctiva be a good prognostic sign in cases of chemical eye injury?
21. How might hyperglycemia affect a patient's prescription?
22. Name some oral medications that we check in ophthalmology.

23. Name the layers of the cornea and their function.
24. Name three potential causes of a white pupil in a baby.
25. Retinoblastoma is a tumor of what cell in the eye?
26. What and where is the trochlea?
27. What antibiotic do we use to cover most corneal abrasions?
28. What are drusen?
29. What are hard exudates?
30. What are potential causes of amblyopia?
31. What are some risk factors for closed-angle glaucoma?
32. What are some risk factors for open-angle glaucoma?
33. What are the “three vital signs” of ophthalmology?
34. What are the 8 structures you describe on slit-lamp exam?
35. What are the layers of the lens and which are removed in cataract surgery?
36. What are the symptoms of dry eye?
37. What are the symptoms of retinal detachment?
38. What are the three types of conjunctivitis and how do they present?
39. What CD4 count do patients with CMV retinitis typically have?
40. What chemical is worse to get in the eye, an acid or base?
41. What do you call a layer of white pus in the anterior chamber?
42. What does a fourth nerve palsy look like and what causes it?
43. What does a third-nerve palsy look like and what causes it?
44. What does OU, OS, and OD stand for?
45. What exam findings should you document with an orbital wall fracture?
46. What eye findings are suspicious for shaken-baby syndrome?
47. What eyedrop medication is associated with cataract formation?
48. What four structures do we check on retinal exam?
49. What holds the lens in place?
50. What imaging study is best for orbit, apex, and brain?
51. What is “pinholing” a patient?
52. What is “with the rule” astigmatism?
53. What is a Horner’s pupil?
54. What is a layer of blood inside the anterior chamber called?
55. What is a NSC and who gets them?
56. What is a PCO and who gets them?
57. What is a PSC and who gets them?
58. What is a PVD?

59. What is accommodation?
60. What is amblyopia?
61. What is an Adie's pupil?
62. What is anisometropia?
63. What is applanation and what do we use to applanate?
64. What is cell and flare?
65. What is endophthalmitis and how do you get it?
66. What is glaucoma?
67. What is hyperopia?
68. What is macular degeneration and what causes it?
69. What is more visually significant, an anterior or posterior located cataract?
70. What is myopia?
71. What is PHACO?
72. What is pigment dispersion glaucoma?
73. What is presbyopia?
74. What is pseudoexfoliation syndrome?
75. What is pseudostrabismus?
76. What is ROP?
77. What is the "ISNT rule" in glaucoma?
78. What is the ciliary body and what two functions does it serve?
79. What is the most common type of conjunctivitis in adults and children?
80. What is the surgical approach when sewing up lid-margin lacerations?
81. What is the swinging light test?
82. What is the uvea?
83. What is traumatic iritis, and how do you treat it?
84. What kind of orbital wall fracture needs to be repaired?
85. What kind of workup would you perform for optic neuritis?
86. What layer of the lens is left behind with cataract surgery?
87. What level of the retina do dot-blot hemorrhages occur compared to flame-hemorrhages?
88. What medication should you avoid in a sickle-cell patient with a hyphema?
89. What might make you suspicious for a foreign body inside the eye?
90. What organism do we worry about with contact lens patients?
91. What should you first check with a patient complaining of diplopia?
92. What symptoms might a patient with temporal arteritis complain of?
93. What's a Marcus-Gunn pupil?

94. What's a normal eye pressure?
95. What's normal corneal thickness and why do we check it?
96. What's the difference between a tropia and a phoria?
97. What's the difference between open and closed-angle glaucoma?
98. What's the difference between plus and minus cylinder?
99. What's the difference between the axis and power of a cylinder?
100. What's the Hirschberg test?
101. What's the most problematic location for a lid laceration?
102. What's the significance of pupil involvement with oculomotor nerve paralysis?
103. What's the difference between a corneal abrasion and an ulcer?
104. Where do the cranial nerve nuclei sit in the brain?
105. Where does the nasolacrimal duct drain?
106. Where do the extraocular muscles originate?
107. Which method of retinal examination gives the most magnified view?
108. Which muscles open and close the eyelid?
109. Which orbital bone is most likely to fracture with blunt orbital trauma?
110. Which type of sickle cell patient has more eye problems: type SC or SS?
111. Why are sulfa allergies important to ask about?
112. Why can't we look at the trabecular meshwork directly?
113. Why do we dilate eyes with internal inflammation?
114. Why is the cornea clear and the sclera not?
115. Why is the macula susceptible to ischemia with retinal detachments?
116. You have a patient with a corneal thickness of 600 microns, and measured pressure of 15. Do you think his actual pressure is higher or lower than 15?
117. Put the following retina layers in order from inside to out: photoreceptors, ganglion nerves, sclera, and choroid.
118. What bones form the orbital walls?
119. What does a sixth nerve palsy look like, and what causes it?
120. What findings on exam are consistent with orbital cellulitis?
121. Will a child with cataract implants need glasses?

Unedited Comments

From online readers!

OphthoBook.com is a labor of love and I derive little income from it. However, I DO receive big rewards from this project in the form of feedback. Every morning I receive nice emails from students around the world who have learned something from the website.

While OphthoBook has never been “peer reviewed,” in the traditional sense, thousands of my *online peers* have read it. These nice people leave comments ... and when they find a mistake, they let me know! This interaction has turned OphthoBook into a community project.

These words of encouragement keep me going and I take great satisfaction in making this small impact on the world. I guess you could call this “pride” or “hubris.” Whatever the label, these thankful notes warm my heart and make my coffee taste better in the morning.

I enjoy these messages and thought you might find them interesting as well (some are quite funny). I've randomly selected some of these “testimonials” from my inbox for you to peruse. There are thousands more where these came from! Thank you so much for writing me.

truly commenting, the ophthobook.com could serve an indispensable material for writing thesis on Ocular anatomy. Wish copies could be made available. Thn x

Tim Root: Thanks!

the films are perfect. congratulations.

Tim Root: Thank you, I worked very hard on them.

Dear Tim ,
i like to congratulate you for this nice work. I am pediatric ophthalmology fellow and i watch all your clips , its very nice and very helpful. and i enjoy watching all of them. my best wishes for you were you go, regards

Tim Root: Thank you. I'm glad that you found the videos useful.

A very good, short and informative introduction into ophthalmology for students or primary care physicians. The author has the educational talent to explain things clearly without any fuss. Highly recommended!
GP

Tim Root: As the author in question, I thank you for your kind words!

hey,
thanks i had a test(short notice) and needed a crash program (not recommended) and your book did just that it was concise and straight to the point filled with facts and easy explanations

Tim Root: I'm glad it helped!

Outstanding, I just went through the 5 videos and I'd say I learned as much as I did in my 2 weeks in ophthalmology in my medical school. Outstanding. Looking forward to seeing the other 5 videos and downloading the flash cards.

Tim Root: They're coming soon!

ophthobook.com is a very useful site for optom students-very handy!

Tim Root: I'm glad you liked it and thank you for posting. I'm trying to encourage more optometry students to visit the site!

Tim,
What an extraordinarily benevolent person you must be. This is an incredible work. I just finished watching the "Anatomy of the Eye" video, and I'm sure that I'll watch all of them as I find time.

Tim Root: I'm glad you liked it. It took me a while to draw all that anatomy and scan in those CT slides

... after reading your answer about how and where the nasolacrimal duct drains, and watching the "Anatomy of the Eye" video, my mind is at ease. I was really, really worried. Thank you for your excellent work.

Tim Root: I'm happy that this anatomy knowledge allayed some of your concerns.

This is great. Well Done!

Tim Root: I like mine medium-rare, but thanks!

Your site is invaluable source of information. I understand it is for med students, however, as a newly trained ophthalmic technician this by far has been the most easily understood and fun format for me personally. Thank you so much!

Tim Root: I'm glad you find this format useful.

i am studying sharks in school and i cannot seem to find what is the nasal canthus?

Tim Root: The canthus is where the upper and lower eyelids join together. Nasal means the side closest to the nose.

the website has given facts other then usual textbook. authors sincere efforts towards presentation are worth to applause. however i would surely suggest site for best ophthalmology edutainer site.

Tim Root: Edutainment is important!

Tim, I have always recognized the talent. You have done an original and peak work. Congratulations!!!

Tim Root: Thanks! Do I know you?

SO GOOD. I found these really really useful.

Tim Root: I'm really really glad!

Very useful and didactic!
Congratulations on your good work!

Tim Root: Thank you!

please call me about about setting up
a web site for by business thank you I
will pay you for your services

Tim Root: Hahaha!

Hi, all the way from South Africa.
Writing ophthalmic assistant exam
soon and while searching for review
q&a found you book. Although I'm not
a medical student or ophthalmologist,
I found all you info real handy and
very insightful. Will be a big asset in
my exam prep. Awesome & excellent,
keep up the good work!!

Tim Root: Thank you. Good luck with
your exam!

The author of the book is a very
interesting guy who loves anything
that has an optic system involved.
The book is a very instructional aid for
medical students. Good luck Dr. Root
in your new endeavors!!

Tim Root: Thank you!

hi, your website's great. i hope this
website stays free. Thanks

Tim Root: It should stay free
indefinitely.

it is very useful way of learning by
waching this video.

Tim Root: I agree.

hi, all the way from Philippines. i'm
planning to undergo residency training
in ophthalmology and needed some
resources. thank you so much for this
website. it helped me a lot. God Bless
and more power

Tim Root: Thank you. Good luck with
your residency training –
ophthalmology is a wonderful field.

Great job Tim. I will be recommending
your site to all my students. Billing
and coding personnel need to learn
the clinical side as well and your
information is short, concise and to
the point. A great introduction to the
topic.

Tim Root: I'm glad you are finding it
useful. I tried to make it approachable
to all specialties.

Like the cartoons.

Tim Root: Finally, someone admits to
liking my drawings! I guess that's why
I'm an eye surgeon and not a
cartoonist. Thanks for the affirmation!

Dear Tim,
I'm genior resident of ophthalmology !
thank U on this (free) website
very simple lectures in writing &
explanations
But where U are resident ? what's
actually textbooks U use ?
Best Wishes 4 U

Tim Root: Thanks for the interest.
Check out my bio on the "about page"
of the site.

Good words.

Tim Root: The competition was fierce
so I choose them carefully!

sir
iam from india.doing my clinical
practice. iam preparing for post
graduate entrance..ur services r so
great .it helps me a lot.
thanks a lot sir

Tim Root: Good luck with your
entrance exams, sir!

wonderful site dude, seems to be
written by a professional, and for
dummies. i think every book should
be like this... so simple to understand,
yet comprehensive...keep it up!

Tim Root: Thanks! Interestingly, my
original working title was
"Ophthalmology for Dummies," but I
had to change this for obvious
reasons.

Thanx for gr8 videos, really useful for
undergraduates who have less time
but vast eye syllabus to cover. When
the next 5 videos going to come?

Tim Root: Most of them are already
out, still a few more to record. L8er!

Dear Tim,
I am a student of optometry from
Holland and I bumped on your site by
google. You did great work with this
website it's great and easy to follow, I
would say go on with your work and I
am sure I will use your website a lot
for easy refreshment. Good Job!

Tim Root: Thanks! Always good to
hear from my "Hollish colleagues."

you are sick

Tim Root: Thanks! You are ill!

perfect website with simple words >>>
really it's excellent
good Luck

Tim Root: Not quite perfect, but it is
getting there. Thanks for commenting!

What can I say? It is an incredible
book which helps me a lot to
preparing the application of
Residency. Also, I would like to make
some correction about cornea at Page
32. "Cornea should be measured
around 540µm instead of 540nm".
Same mistakes also in PIMP question
no.8. And, would it be possible to let
me translate the book content to
Traditional Chinese to introduce this
excellent book for the medical
students who speak Chinese?

Tim Root: Thanks for the correction. I
think I'm going to hold off on
translations for now, but I do
appreciate the offer.

thank you very much , this video
helped me a lot in understanding the
anatomy of the eye ... keep going ^-^

Tim Root: I'll keep "going" until they
stop harvesting coffee beans. Thanks
for posting!

thanx , this was wonerful too. :D,
but u didn't talk about styes pretty
much ???

Tim Root: Sorry. Styes are like
pimples. That's about it.

thank you for this excellent resource.
every medical student with an elective
in ophthalmology should read your
site.

Tim Root: I agree. Spread the word!

You know this site is not only useful for med students but the people who are studying orthoptics

Tim Root: I agree. But I draw the line at orthotics.

This is one of the best resources I have read in 4 years of medical school. I highly recommend it for any student wanting to learn ophthalmology. A true benchmark in books for medical students!

Tim Root: Thanks. I'm hoping it will become the book EVERY medical student reads while in training.

Probably being stupid and have just missed it, but is there a section on iritis, scleritis, and episcleritis? Is it in the pipeline? Videos are BRILLIANT by the way!

Tim Root: I left those topics out because the book was getting too long. I don't see those entities often in practice so decided they were low-yield.

Very good words selection. thanks

Tim Root: No problem! Did you know that an appalling 50% of words are below average? I tried to avoid those.

I was afraid of eyes until I saw them in all their glory thanks to your book. In the land of the blind the one-eyed man is King! Looking forward to more videos...

Tim Root: Thanks. Your comment is so profound that I can't think of a witty comeback. How about, "Eye Eye, Captain!"

Did anyone spell check these??
Foropter?? PHROPTER correct spelling

Tim Root: I think you just misspelled phoropter... I guess neither of us is perfect. 😊

i love this site very
muchhhhhhhhhhhhhhhhhhhhhhhh
wonderfull!!!!!!!!!!!!!!

Tim Root: Awwwesommeel!

Excellent videos! Very clear and easy to understand. Looking forward to the rest of the videos, thank you so much for sharing!

Tim Root: Thank you for posting.

dear tim
thanks a lot you did a great job i would like to congratulat you for this job i am an ophthalmic nurse really you helped me a lot for more understanding and more information i need i wish this site will stay free thank you

Tim Root: Thanks and I'm glad you liked it.

Wow, i wish postgraduate studies were that easy. Especially when you have no one to teach you.

Tim Root: Thanks! But, how are you taking postgraduate courses without teachers?

would like to see more!

Tim Root: Make sure your glasses are up to date, and try artificial tears.

thanks ..
i am a medical student ..
this book is sooo great ... it saved my
life thanks again 😊

Tim Root: You owe me one, then! It's traditional in these circumstances to send the "hero" a small gift. Hint Hint!

Very well done. I hope you still plan to publish the other 5 videos. Are you taking donations?

Tim Root: Only two more videos left to record. No donations needed, just spread the word.

SIMPLY ONE AWSSOME BOOK!
I LOVE IT!
(optometry student)

Tim Root: Thanks. You optometrists are enthusiastic learners!

I'm in Ophthalmic assistant, and this video has really explained a tremendous amount of information to me Thanks.

Tim Root: No problem, and I commend you advancing your ophthalmic prowess.

Fantastic videos! And the book too!
Thanks for offering your time and hard work to help out so many medical students in need of a straight-forward explanation of ophthalmology. So glad I found your website!
Give yourself a big pat on the back!:)
You deserve it.

Tim Root: Done!

awesome videos!...there's a mistake in the neuro part II video though. it says loss of parasympathetics (thus pupil constricts)...i think you mean thus pupil dilates

Tim Root: Nice pickup. Unfortunately, it's a lot harder to re-edit video than text, so that blunder will have to stay for now.

How do you pronounce "uterque"

Tim Root: Very carefully.

Dear Tim,

Will use this valuable source to teach our PA students. You did a such great job. May God continue to bless your passion.

Tim Root: Thank you. I've never been to Pennsylvania, but I'm glad I made an impact on their students.

Live in the uk, how do i purchase the book and how much is it?

Tim Root: Should be on Amazon soon. Should be under a thousand dollars American ... so, maybe 10 pounds?

Fantastic videos. Thanks. Now, could you make videos on the rest of medicine.

Tim Root: If only I had the time. I wish there was a repository of all the greatest medical lectures in one place. If you ever get bored and want to see some great video lectures, visit TED.com

excellent question and answer session.reall helped me prepare for my exams.Thank you.

Tim Root: I'm glad my review quiz helped.

Hello Dr, congratulations for this website, it's the most comprehensive resource in ophthalmology. It took me shorter time to understand many subjects than at the medical school!!!!

Tim Root: Thanks. My mom thinks it's great, too!

good

Tim Root: job

love this video as i always like lectures with pictures demonstrating the things..student of MBBS .. i had to study the glaucoma from my boring and complicated notes but when i saw this video it became so clear to me that i just read my notes and i was understanding all the things so clearly....thank u so much...wish all the teachers explain things like u

Tim Root: Glad my explanations helped. I'm not sure what MBBS is, but it sounds impressive!

Advise MEDICAL STUDENTS & ALL OPHTHA RESIDENTS TO READ IN EARLY PRACTICE.simple&cleare but needs more details on medical treatment

Tim Root: Err ... thanks?

Love your site and sense of humor. This has been a great additional help for studing for the COA. Thanks!

Tim Root: At last! I'm glad someone likes my humor!

Great site!! The book and the videos make it really easy to learn.

Tim Root: I think that people learn best when presented info via different methods. The text and video work well together. Thanks for writing!

Love it!! Many thanks from Portugal

Tim Root: Gracias.

Great video, very informative and simple, yet it stopped at 20:19 and didn't finish . Thanks for the effort.

Tim Root: Working on my end. Try it again?

Loved this. Do you have anything similar for oculoplastics?

Tim Root: No. Maybe in "Ophthobook Two – Uveitis Strikes Back"

Super book! Rapid fire revision of Ophthal - extremely well-presented. Thanks!

Tim Root: Thanks!

Your ophonotes are great.Keep up the good work

Tim Root: I will.

i wanted to revise the eye anatomy before starting ophthalmology 25 min worth watching the vidio thank you so much

Tim Root: I'm glad you were able to listen to me for that long!

marvellouss.. sea of knowledge very very best notes

Tim Root: I like the imagery. Not a "fountain" of knowledge, but an actual "sea!" Thanks!

tim your effoets are really admirable. i wanted to do these things with medicine.u made eye very easy and understandable i really apprecite ur endeavour. tim please tell me how to download these videos because i donot have internet access at my home please send me these videos to my email address. wth great regards

Tim Root: I can't email the videos to you as that would be a gigabyte of information and no mail server would accept it.

you are doing a great swervice to the medical profession

Tim Root: Thanks. I try to keep things swimple.

Hello Tim your Web is very funny and entertainment
Pediatric Ophthalmology
Sevilla.Spain

Tim Root: Thank you!

Thanks for making these great videos. I'm starting to like a field of medicine I used to think was so boring.. 😊
Thanks! Since I'm European, I couldn't help but notice a small mistake on the "indications for screening" slide; you might wanna change 1500 kg to 1500 GRAMS, otherwise we're talking about a giant of a baby 😊
Keep up the good work! Best regards
A. (5th year medical student)

Tim Root: That IS a big baby! I've made the correction (dumb metric system) and thank you for noticing!

thank u tim ,for a while I thought that i will never understood neuroophthalmology , great jop

Tim Root: No proplem! Neuro can be difficult if poorly explained. I tried to make it easy.

YOU HAVE A VERY MUCH IMPORTANT INFORMATION, THIS INFORMATION IS RELEVANT PLEASE KEEP THE STANDARD UP.

TIM ROOT: GOT IT! THANKS FOR WRITING!

Exelente sitio!!! sus guias son cortas y precisas y con un diseño a prueba de...

Tim Root: Gracias! Buenos Tacos!

i am a third year medical student from india and i ve seen all ur videos..they r amazing n very useful..thanks n keep up the good work!!!!

Tim Root: LOL. Will do!

it is so succinct. Thank you very much for making this video.

Tim Root: I try to keep all my lectures under 25 minutes to minimize boredom-induced hysteria.

thx guys.....u helped me pass my optho exam.....cheers.....

Tim Root: Congratulations! I love that show!

Thank you so much for sharing your excellent work. As a certified ophthalmic technician with 15 years experience, I have found this site to be extraordinarily helpful when training new staff as well as supplementing my own continued education.

Tim Root: I'm glad to help another educator! Send me your address and I'll mail you free copies for your staff.

thanks, that was just awesome !!! i learned while watching one video, more than i did during two weeks in the opthalmology department. keep going and thanks again

Tim Root: The videos are very high-yield. I'm glad you're liking them.

I've been studying from books for my OMA certification but I've never been able to see the eye pictured like this. It has been a tremendous eye opening help (pun intended). Thank you so much.

Tim Root: Eye am glad you liked my book!

This has been such a wonderful learning tool. I've worked in ophthamology for two years and groan when I get a baby or small child because I just didn't know much about how to examine them or what a doctor was looking for. I've learned so much from your videos. Thank you so much.

Tim Root: Kids are challenging. The cartoon children in the pediatric video lecture are easier to handle. Glad it helped!

This book is so great. Its exactly what I was looking for, and I actually like reading it in my free time. Now I won't feel like an idiot when I shadow the ophthalmologists at school haha. Thanks for the awesome resource!!!

Tim Root: Thank you. And never feel like an idiot ... we're all dumb at something!

waw 😊 amazing video this what I need ..very useful thanks a lot..

oh..no.. why this video not work with me..pleas can you send it to me at my email..I really need it.

Ok..now its work!! 😊 do not know why yesterday didn't open with me!!!

Tim Root: I don't know why your comments amuse me so much, but they do! Thanks for writing!

Keep dropping it like its hot. Great videos.

Tim Root: No problem. I'll also "keep it cool like a fool in a swimming pool."

It's a capsule of knowledge. When a book is so simple to read and understand we must appreciate the tremendous effort of the author, the master teacher. A salute for his efforts. And thank you so much. Medical Student, Malaysia

Tim Root: Thank you for your kind words.

Very short, concise n yet ridiculously simple !!! I like this website!

Tim Root: I tried to keep it short (except for this ridiculous section, of course). Thanks for the shout out.

Although I m a trainee in masters ophthalmology program I found this website very helpful

Tim Root: Is "masters" used the same in your country as it is here? In the US, masters usually means a sporting event with older athletes. Just how old are you? Just Kidding!

Thanks for this excellent resource! I am a 3rd year Family Medicine resident and especially like the cartoons and live videos showing exam techniques and findings. This is better than our ophtho rotation!

Tim Root: Thanks! If you live in Florida, I'll be happy to sponsor a rotation through my Daytona Beach clinic. I promise to send you home by noon everyday (so you can hang out at the beach and read my book)!

thanks from Thailand ^ ^

Tim Root: Your welcome from Floridas!

Thank you soooo much. I spent 2 hours watching your videos, they are very helpful. IMG

Tim Root: Holey Moley! You didn't watch all the videos in one sitting, did you? You've got buns of steel!

Thank you for having these available, I wish I could get them for every specialty! It's made my ophthal revision so much easier.

Tim Root: Glad it helped.

I like the idea of OPHTHOBOOK an i found it interesting and easy to understand. But apart from its goodness, its not complete. like you see in topic of glaucoma, there is no description about the visual feild defects occuring in different types of glaucoma. It must includ other topics like scleral diseases and many others. in last i just want to thanks the OPHTHOBOOK as it has helped me alot!!!

Tim Root: Yes, ophthobook is not all-inclusive. I had to draw the line at glaucomatous scotomas and scleritis.

thank you very very very much! i am a med student and i didn't really understood the eye so good at my ophthalmology classes as I did by watching your videos!thanks

Tim Root: Glad they were useful.

love the book. helped me prepare for ophthalmology residency in Kenya

Tim Root: Cool!

I am a med student from Romania and I have my ophthalmology exam this Friday. My teacher's book is really boring and your videos made me really want to read it, although it is truly madly deeply really boring. I believe you like your job and that makes me think really beautiful things about you as a professional. I would like my teachers to be more like you, I mean I wish teachers to be teachers not only readers, writers and doctors. I think you will become a really good teacher. Congratulations

Tim Root: Thank you. I am thinking really beautiful things about you as a student.

Thanks so much, this has been of so much help. I am a medical student and these topics were not covered sufficiently during the term. However this has made things crystal clear. Thaaaaaaaaannnnkkkkkksssssss

Tim Root: I'm sorry, but I had to remove some of the consonants from your wonderful comment so it would fit on the page. Thanks!

Have to say Dr. your really amazing!! learnt so much with so much ease from all your videos!! God bless you! optometry student

Tim Root: Thanks!

Hi, these videos are awesome. Thank you so much! For some reason the glaucoma video stops at 13 minutes 32 seconds, as mentioned above...

Tim Root: Hmm ... not sure why. Only seems to affect some people.

thanks so much for these excellent talks - you are an excellent teacher and very generous. I take my cap off to you! =)

Tim Root: Thanks!

Thanks a lot for this. Really good and simple explanations, and very good and understandable graphics. This will help me for my clinic exam in optometry today!

Tim Root: Good luck! You'll do great!

wow!!! mind-blowing video.. very helpful

Tim Root: Yes, that video is pretty trippy! Oh wait, are you talking about one of my video lectures? Never mind!

Thank you very very much, the page help me to do the paper for presentation. My interest topic is retinal detachment, it's very useful and easy to read and understand.

Tim Root: I hope you get an "A" or a "check plus!"

absolutely informative! I'm a pediatrician who had little exposure to ophthalmology in medical school and residency. After watching 2-3 videos on this site, I'm already feeling more comfortable with the eye!

Tim Root: Great! My hats off to you pediatricians ... you have a challenging job.

Thanxxxxxxxxxxxxxxxxxxxxxxxxxxxxxxxx

Tim Root: XOXOXO

I saw a trauma case more recently, and sadly, i couldn't help the young girl. hopefully, after i read this chapter, i will feel more confident and comfortable when i encounter another ophthalmology cases and know exactly when to refer immediately. thanks so much for all of your wonderful efforts and the great use of your talent. by the way, are you planning to create a video for this section or will it be too gruesome?

Tim Root: I'm recording the trauma video soon. I've pulled the really gory stuff out.

I am a 4th year medical student. Currently attending eye ward in Pakistan. This video has helped me immensely and it made an impact on my memory (which is a very difficult job to do)...I appreciate the simple explanatory method and awesome slides. You have done great service for humanity...

Tim Root: Thanks. I'm not sure if this little book qualifies as "helping humanity" but thanks!

man u did wrote an awesome stuff... i really love it... made ma concepts all clear in a jiffy.. do inform me if u hv uploaded similar stuff... peace..

Tim Root: Peace, brotha!

Dr. Root,

Just wanted to say a quick thanks for offering this free and informative website to all of us interested in ophthalmology. As a med student, visiting this site from time to time allows me to keep a general understanding of ophthalmology fresh in my mind, and your approach to explaining the material is one of a kind. I look forward to future works.

Tim Root: Thanks. Some of my metaphors are silly, but most are helpful.

Simply excellent... simple but descriptive pictures for creating clearer concepts... ZABARDAST (highest/best)

Tim Root: I googled "zabardast," and it seems to be an Indian movie from 1985 directed by Nasir Hussain.

This is one of the best medical websites I have ever seen.

Tim Root: I'm glad you liked it!

why cant they all teach things like you.....if only the rest of medicine was thought this way! Thanks

Tim Root: I agree. I'm glad you found my teaching style helpful.

the lecture was great and appropriately related all the clinicals.i think all students learning about eye should watch the video.

Tim Root: Thanks. Hopefully, someday they will!

Brilliant - Fair play to you!

Tim Root: Thanks!

super ..when wil lens optics come..i'm waiting.. please put it up soon

Tim Root: Coming soon. I'll email you.

Dear Tim
thhhhhhhhhhhhaaaaaaankkkkkkkkk
u soooooooooo much for these
excellent videos i cannot tell u how
much they have helped prepare for
my exams
really appreciate ur effort n lookin
forward for the rest of da videos soon

Tim Root: Yes, my book is "off da chain."

really I find no words to thank u

Tim Root: None needed. Thank you for writing.

Ophthalmology Abbreviations

A or Acc	accommodation	K	cornea
AC	anterior chamber	KCN	keratoconus
AC/A	accommodative convergence/accommodation ratio	KPs	keratic precipitates
ALT	argon laser trabeculoplasty	L	lens
APD	afferent pupil defect	LASIK	laser in situ keratomileusis
ARMD	age-related macular degeneration	LOL	laugh out loud
ASC	anterior subcapsular cataract	LP	light perception
BAT	brightness acuity test	LPI	laser peripheral iridotomy
BLP	bare light perception	LL	lids and lacrimation
BRAO	branch retinal artery occlusion	LLL	left lower lid
BRVO	branch retinal vein occlusion	LUL	left upper lid
CACG	chronic angle closure glaucoma	MA	microaneurysms
CC	with correction	MP	membrane peel
CE	cataract extraction	NAD	non-accidental trauma
CF	confrontational fields or count fingers	NLP	no light perception
CL	clear, contact lens	NPDR	non-proliferative diabetic retinopathy
CMA	cystoid macular edema	NSC	nuclear sclerotic cataract
CRAO	central retinal artery occlusion	NV	neovascularization
CRVO	central retinal vein occlusion	NVA	neovascularization of the angle
CS	conjunctiva and sclera	NVD	neovascularization of the disk
CSME	clinically significant macular edema	NVE	neovascularization elsewhere
CSR	central serous retinopathy	NVG	neovascularization glaucoma
D	diopter	NVI	neovascularization of iris
DQ	deep and quiet	OD	oculus dexter (the right eye)
DR	diabetic retinopathy	OS	oculus sinister (the left eye)
EOG	electro-oculogram	OU	oculus uterque (both eyes)
EOM	extraocular movements	P	pupils
ERG	electroretinogram	Pap	papillae
ERM	epiretinal membrane	PAS	peripheral anterior synechiae
ET	esotropia	PCO	posterior capsular opacification
EXT	extremities	PD	pupillary distance
FA	fluorescein angiography	PDR	proliferative diabetic retinopathy
FOL	follicles	PED	pigment epithelial detachment
HE	hard exudates	PEE	punctate epithelial defect
HM	hand movement	PH	punctate epithelial erosion
HSV	herpes simplex virus	PHNI	pinhole
HT	hypertropia	PHNI	pinhole no improvement
I	iris	PHPV	persistent hyperplasia of primary vitreous
IMHO	in my humble opinion	PI	peripheral iridotomy
IOP	intraocular pressure	PK	penetrating keratoplasty (corneal xpl)
J1,J2...	Jaeger (near vision scale J1+=20/20)	POAG	primary open angle glaucoma
		PPV	pars plana vitrectomy

PRP	panretinal photocoagulation
PSC	posterior subcapsular cataract
PVD	posterior vitreous detachment
PVR	proliferative vitreoretinopathy
PXS	pseudoexfoliation syndrome
RAPD	relative afferent papillary defect
RD	retinal detachment
ROFL	roll on floor laughing
RLL	right lower lid
ROP	retinopathy of prematurity
RP	retinitis pigmentosa
RPE	retinal pigment epithelium
RT	retinal thickening
RUL	right upper lid
SBS	shaken baby syndrome
Sc	sans correction (no glasses)
SLE	slit-lamp exam
SLK	superior limbic keratoconjunctivitis
SRF	subretinal fluid
Sph	spherical lens
T	pressure
Tap	pressure (applanation)
Tono	pressure (tonopen)
V or Va	vision or visual acuity
Vcc	vision (with correction)
VEP	visual evoked potential
Vsc	vision (sans correction)
VH	vitreous hemorrhage
Vit	vitreous
W&Q	white and quite
WNL	within normal limits
XOXO	hugs and kisses
XT	exotropia



*His cardiologist is on vacation,
so we're leaving a message.*