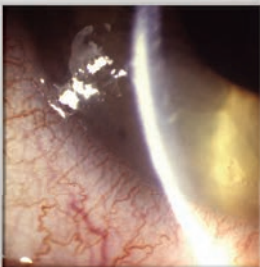
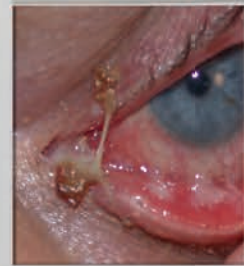
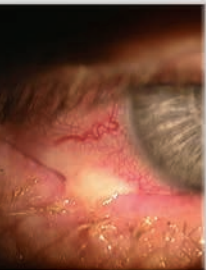
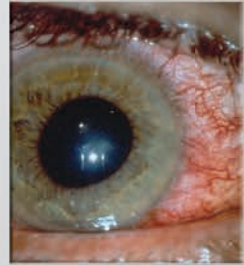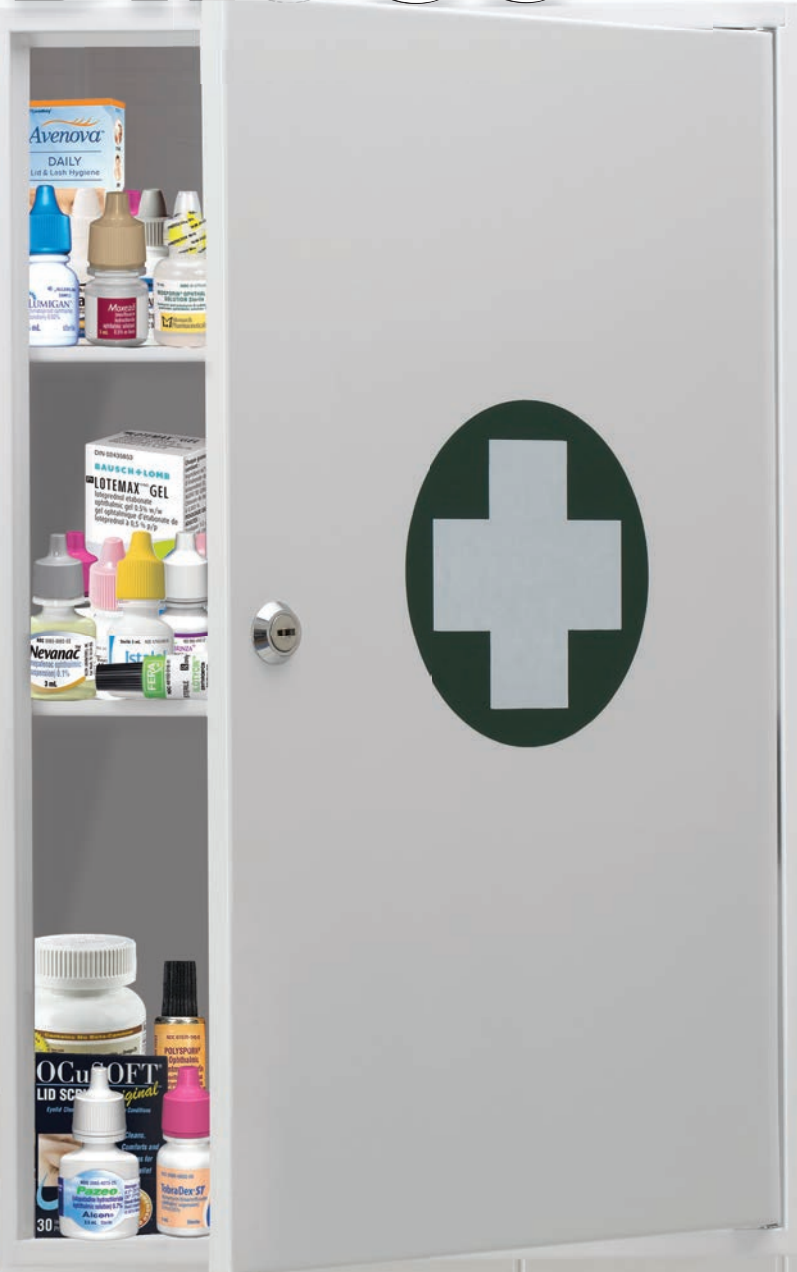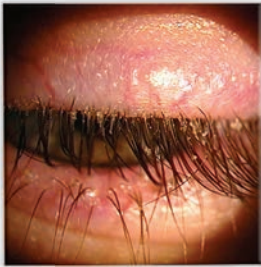# 2016 CLINICAL GUIDE TO OPHTHALMIC DRUGS

20th Anniversary  
Edition



A SUPPLEMENT TO

**REVIEW**  
OF OPTOMETRY<sup>®</sup>

Supported by an unrestricted grant from  
Bausch + Lomb



Ron Melton, OD



Randall Thomas, OD, MPH

## DEAR OPTOMETRIC COLLEAGUES:

Welcome to the 2016 *Clinical Guide to Ophthalmic Drugs*—the 20th Anniversary Edition of this publication.

We are grateful that so many of you who have expressed your appreciation for this guide over the years. Our exclusive focus in this annual publication is to help practicing optometrists provide the highest level of care to their patients. Caring for one another is a high calling, and every effort should be made to achieve this laudable goal. Our hope is that the knowledge you glean from these contents helps move you closer to perfection in patient care. Thank you for taking this journey along with us over these past 20 years.

Notably, 2016 is projected to bring us a newer glaucoma drug and a new drug to help treat dry eye disease. In addition to sharing with you information on these new drugs and their use, we also review how and when to use tried-and-true ophthalmic medications, many of which are now available generically.

We are especially honored this year to have a guest author, Kathleen F. Elliott, OD. The 2014 Oklahoma Optometric Physician of the year and ABO Board Certified optometrist brings us up to date on clinical aspects of pediatric eye care. She can be reached at [drelliott1111@yahoo.com](mailto:drelliott1111@yahoo.com).

We want to sincerely thank the awesome team at *Review of Optometry* for painstakingly working with us to publish the Drug Guide over the past two decades. Obviously, it is expensive to produce a work of this magnitude without corporate support. Without the enduring and consistent educational grant support of Bausch + Lomb (now a Valeant company) each and every year, this guide would not be possible. Life is a team sport, and we are, and have been, honored to work with both *Review of Optometry* and Bausch + Lomb in this endeavor toward the enhancement of patient care.

Having the high honor of seeing patients full-time for a combined 70-plus years now, we have accumulated considerable experience in patient care. We diligently and carefully peruse several journals every month to assure ourselves that we remain on the cutting edge of knowledge, but this guide remains a clinically practical work. Thus, if a statement is made herein that is not referenced, it is to be understood that the statement is based on our extensive clinical experience. Our hope is that, through reading this Drug Guide and taking to heart its contents, you will be better able to provide the highest level of care to your patients.

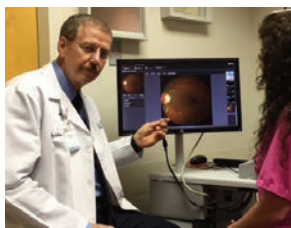
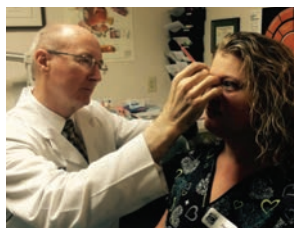Sincerely,



Randall Thomas, OD, MPH



Ron Melton, OD



**Disclosure:** Drs. Melton and Thomas are consultants to, but have no financial interests in, the following companies: Bausch + Lomb/Valeant and Icare.

Note: The authors present unapproved and “off-label” uses of specific drugs in this guide.

Supported by an  
unrestricted grant from  
Bausch + Lomb

## CONTENTS

Allergy Drugs.....	3
Antibiotic Agents.....	6
Dry Eye Therapy .....	13
Nonsteroidal Drugs .....	20
Corticosteroid Use.....	26
Pediatric Pearls.....	33
Glaucoma Care.....	36
Shingles Therapy .....	44
Clinical Insights.....	46



**A PEER-REVIEWED  
SUPPLEMENT**

# ALLERGY TREATMENT: QUELLING THE ITCH

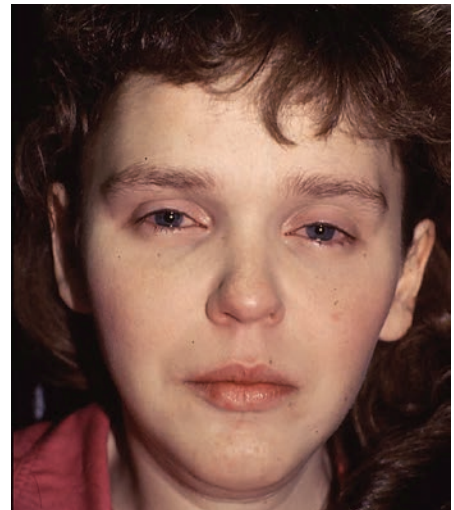Though the condition may be the most harmless one we see, our ocular allergy patients are among our most grateful.

“D octor, my eyes just itch and burn all the time,” the patient says. How many hundreds of times have we heard this lament?

However, this common complaint brings us front and center to the proverbial fork in the road. The first question is basic. Ask the patient, “So, think about this: Is the burning or the itching your main symptom?” Most patients can give a clear answer to this fundamental question.

For the few patients who feel the symptoms of burning and itching are about equal, or who can’t decide which symptom is most bothersome, treatment with a topical corticosteroid will usually quell both complaints. Don’t forget our time-honored advice in these cases: “When in doubt, use a steroid.”

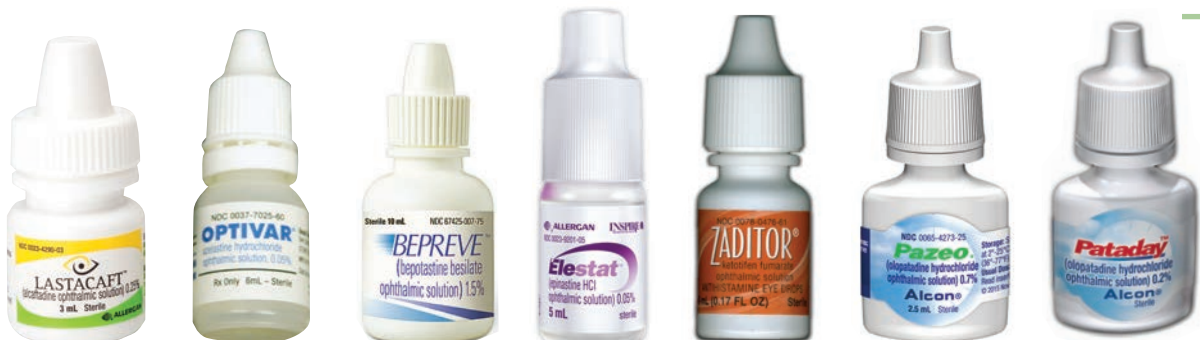If itching is the predominant symptom, our approach to drug selection takes one of the following two routes.



A woman experiencing a severe ocular allergic reaction.

## SYMPTOMS ONLY

If there are minimal associated signs of allergy—such as chemosis, conjunctival injection and/or eyelid edema—an anti-



## OCULAR ALLERGY MEDICINES

BRAND NAME	GENERIC NAME	MANUFACTURER	PEDIATRIC USE	BOTTLE SIZE(S)	DOSING
<b>Acute Care Products</b>					
Acular LS	ketorolac tromethamine 0.4%	Allergan, and generic	3 years	5ml, 10ml	QID
Alaway (OTC)	ketotifen fumarate 0.025%	Bausch + Lomb	3 years	10ml	BID
Alrex	loteprednol etabonate 0.2%	Bausch + Lomb	12 years	5ml, 10ml	QID
Bepreve	bepotastine besilate 1.5%	Bausch + Lomb	2 years	5ml, 10ml	BID
Elestat	epinastine HCl 0.05%	Allergan, and generic	3 years	5ml	BID
Emadine	emedastine difumarate 0.05%	Alcon	3 years	5ml	QID
Lastacaft	alcaftadine 0.25%	Allergan, and generic	2 years	3ml	QD
Optivar	azelastine hydrochloride 0.05%	Meda, and generic	3 years	6ml	BID
Pataday	olopatadine hydrochloride 0.2%	Alcon	3 years	2.5ml	QD
Patanol	olopatadine hydrochloride 0.1%	Alcon, and generic	3 years	5ml	BID
Pazeo	olopatadine hydrochloride 0.7%	Alcon	2 years	2.5ml	QD
Zaditor (OTC)	ketotifen fumarate 0.025%	Alcon, and generic	3 years	5ml	BID
<b>Chronic Care Products</b>					
Alocril	nedocromil sodium 2%	Allergan, and generic	3 years	5ml	BID
Alomide	lodoxamide tromethamine 0.1%	Alcon	2 years	10ml	QID
Crolom	cromolyn sodium 4%	Bausch + Lomb, and generic	4 years	10ml	QID

histamine/mast cell stabilizer is an excellent clinical approach. Within this class, there are six drugs from which to choose:

- **Alcaftadine** (Lastacaft, Allergan)
- **Azelastine** (Optivar, Meda Pharmaceuticals; generic available)
- **Bepotastine** (Bepreve, Bausch + Lomb)
- **Epinastine** (Elestat, Allergan; generic available)
- **Ketotifen** (Zaditor, Novartis; many generics available. This drop is OTC.)

- **Olopatadine** (Patanol/Pataday/Pazeo, Alcon)

Notwithstanding fine differences, all the antihistamine subtype 1 receptor blockers nicely suppress ocular itching. Most are dosed initially BID (except Pataday, Pazeo and Lastacaft, which are dosed once daily). After two weeks at BID, ask the patient to try to reduce the drop to once-daily maintenance therapy. In our experience, once symptomatic itching has been brought under control, it takes less pharmacological

intervention to maintain. However, some patients may have to continue BID therapy.

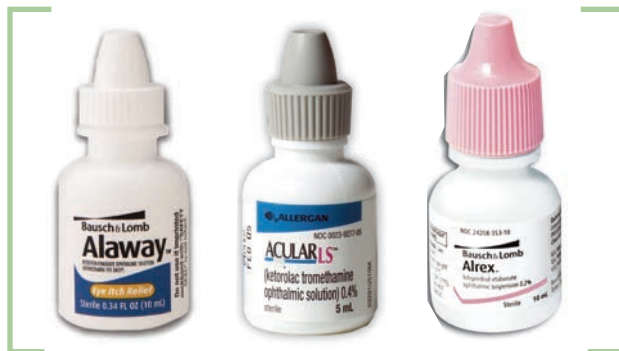Perhaps the best news for the consumer is the loss of patent protection for Zaditor. Since 2007, ketotifen

has been available generically and over the counter. There are several “brand name” OTC ketotifen preparations, such as Alaway (Bausch + Lomb), among others. All come in 5ml bottles except for Alaway, which comes in a 10ml bottle. Interestingly, our casual observations in a variety of pharmacies reveal that the cost of the 10ml Alaway is very near (and occasionally cheaper than) the price of its 5ml competitors. Thus, OTC Alaway is the most cost-effective way to suppress ocular itch.

When a prescription medication is preferred, perhaps a 10ml bottle of Bepreve (using a standard copay) would be of greatest value to the patient, especially with insurance coverage or coupons.

### SYMPTOMS PLUS SIGNS

The other route of allergy presentation is represented by the patient who presents with predominant itching along with one or more



## ISOLATE PATIENT OCULAR ALLERGIES IN YOUR OFFICE

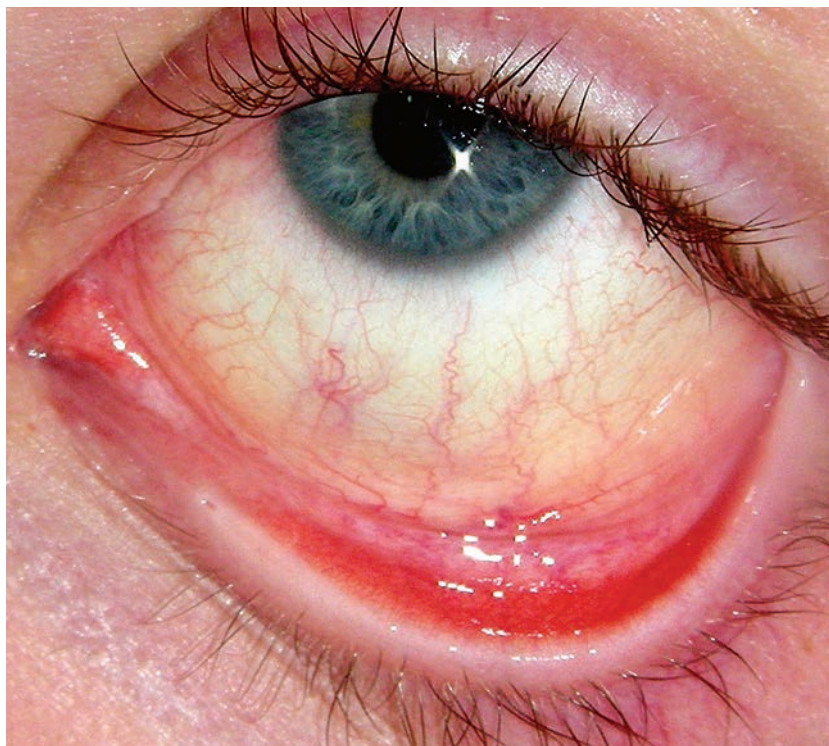A company called Doctor's Allergy Formula has developed a point-of-care diagnostic test to determine specific environmental allergen triggers for ocular allergy. It is a simple, noninvasive (no shots or needles), in-office skin test that tests for 60 regionally specific allergens. Testing can be conducted by the doctor or an assistant, and results are available in about 15 minutes.

However, as in contact lens care, nothing is perfect. There is the highly remote possibility of an anaphylactic reaction, so having an EpiPen in the office is wise. Having diphenhydramine available is also advised.

That being said, this simple test is highly effective in helping determine what is causing the patient's ocular allergy reaction. We encourage our optometric colleagues to carefully investigate this relatively new diagnostic technology via the website [www.drallergyformula.com](http://www.drallergyformula.com) (under construction as of this writing). The company was acquired by Bausch + Lomb in October 2015, and the diagnostic test is being incorporated into the pharma division's offerings.

concurrent signs, such as conjunctival redness, chemosis and/or eyelid edema. For this particular subset of patients, we feel a topical corticosteroid such as Alrex (loteprednol 0.2%, Bausch + Lomb), off-label use of Lotemax gel (loteprednol 0.5%, Bausch + Lomb) or FML ophthalmic suspension (fluorometholone 0.1%, Allergan) is more appropriate treatment.

The only other decision involves the frequency of instillation; we



typically prescribe a steroid Q2H for two days, then QID for one week, followed by BID for one more week. Once the inflammatory signs are controlled, consider switching the patient to an antihistamine/mast cell stabilizer for ongoing symptom control. Long-term treatment with Alrex once or twice daily as maintenance therapy can be done if a steroid is what best controls their disease.

According to a conversation we had with Mark Abelson, MD, a world-renowned ocular allergist at Harvard Medical School, there is little clinical use for pure mast cell stabilizing drugs. He says that the antihistamine/mast cell stabilizer drugs more effectively stabilize the mast cell membranes than stand-alone mast cell stabilizers such as pemirolast (Alamast), nedocromil (Alocril) or cromolyn sodium (generic). Based on this expert opinion, we no longer prescribe these pure mast cell stabilizers.

Remember, allergy is an expres-

sion of inflammation. Cold compresses can be helpful in most all ocular surface inflammatory diseases. In contradistinction, infectious processes are commonly helped by the application of warm soaks.

In summary, if itching is not the primary symptom, be sure to consider dry eye as the foundational condition, and treat accordingly. If itching is primarily expressed, determine if it is an isolated symptom or associated with concurrent inflammatory signs, and then treat accordingly. Remember:

**Symptoms only:** Use an antihistamine/mast cell stabilizer

**Symptoms with signs:** Use a steroid such as Lotemax gel off-label, Alrex or FML

There is no rule in the rulebook that says you can't have two problems at once. Since dry eye is epidemic, identify and manage this disease whether or not it is concomitant with allergic eye disease. If, however, the main symptom is burning, then a thorough dry eye evaluation is in order. ■

# CHOOSING AND USING ANTIBIOTICS WISELY

Success with antibiotics may have more to do with frequency of instillation than selection of the drug, so it's important to know how often to prescribe them.

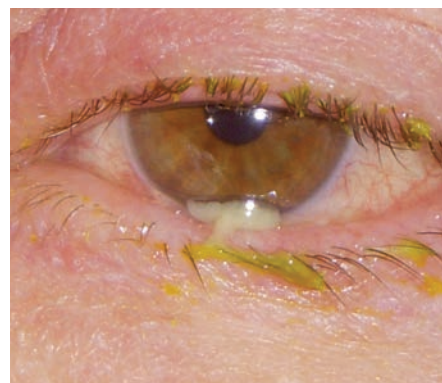
The medical literature bemoans the egregious overprescribing of systemic antibiotics and begs physicians and other health care providers to use great restraint in such prescribing.

The same admonition may be applied to the optometric profession regarding topical antibiotics, but for a different reason. The concern with regard to systemic antibiotics centers on the prevention of resistance. But the concern with optometric use of topical antibiotics is inaccurate diagnoses because the vast majority of acute red eyes are inflammatory, not infectious (with the exception of pediatric patients).

Generally speaking, infectious diseases produce a discharge whereas inflammatory diseases do not. This should quickly separate the sheep from the goats. We opine that such overprescribing is twofold: lack of a firm diagnosis and a seemingly unrelenting reluctance to prescribe steroids.

We have seen hundreds of patients who were treated elsewhere with topical antibiotics by a wide variety of practitioners and who were not getting better. They presented to us as a “second-opinion” visit where we recognized the conditions to be inflammatory, prescribed steroids and the patients were uniformly better within days. It just goes to show: Accurate diagnosis and proper therapeutic intervention are great practice builders. (See “*The Efficient Red Eye Evaluation*,” page 11.)

Thankfully, most of the commonly used antibiotic eye drops are broad spec-



Mucopurulent discharge typical of bacterial conjunctivitis.

trum, and are generally effective against many common bacterial pathogens. We have found frequency of administration—rather than particular drug selection—to be the key determining factor of clinical outcome. Since most (but not all) of the currently approved topical antibiotics possess reasonable antimicrobial abilities, the more frequent the administration of these drops, the greater the clinical result. However, the frequency of eye drop administration depends almost exclusively on the severity of the infectious expression.

When it comes to ocular infections, there are two main routes of antibiotic administration: topical and oral. All topical antibiotic drops are solutions, except besifloxacin, which is a suspension. Oral antibiotics are most commonly prescribed as a tablet, capsule or liquid (the latter used mostly in children).

In our practices, we more commonly prescribe oral antibiotics than topical ones simply because we encounter more patients needing oral antibiotic therapy, such as those with meibomian gland disease (doxycycline), rosacea blepharitis (doxycycline) and internal hordeola (cephalexin [Keflex]). On those relatively uncommon acute bacterial conjunctivitis cases, we typically prescribe generic Polytrim (trimethoprim with polymyxin B), tobramycin or Besivance (besifloxacin).

Now, let's take a more in-depth look at this class of medicines. There are many antibiotics; however, only a few enjoy—or should enjoy—widespread use.

## BACITRACIN

We find this drug to be superbly bactericidal against most all gram-positive bacterial pathogens, and can be used to help treat staphylococcal blepharitis when applied to the eyelids



following eyelid scrubs and/or treatments at bedtime for a week or two. It can also be used at bedtime to provide overnight coverage for moderate to severe ulcerative keratitis. There are two key limitations to its clinical use: It is only available in ointment form, and it has little to no activity against gram-negative bacteria.

On those rare occasions when we encounter a true bacterial corneal infection, we prescribe besifloxacin with Polysporin ophthalmic ointment, which contains bacitracin and polymyxin B, since the polymyxin B is bactericidal against gram-negative pathogens.

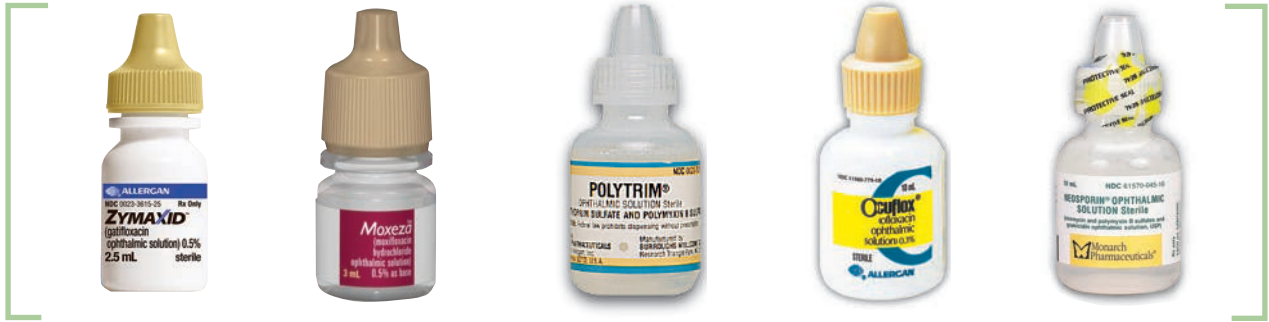## NEOSPORIN

While the previous combination of besifloxacin and Polysporin provides a broad spectrum of antibacterial coverage, perhaps an even better choice may be the triple-antibiotic of neomycin, bacitracin and polymyxin B, commonly known as its original brand name: Neosporin.

Interestingly, both bacitracin and Polysporin are available only as ointments, whereas Neosporin is available both as an ophthalmic solution and an ointment, as the solution contains gramicidin, not bacitracin. We never use the Neosporin in eye drop form, as we prefer generic Polytrim

### TOPICAL ANTIBIOTIC DRUGS

BRAND NAME	GENERIC NAME	MANUFACTURER	PREPARATION	PEDIATRIC USE	BOTTLE/TUBE
<b>Fluoroquinolones</b>					
Besivance	besifloxacin 0.6%	Bausch + Lomb	suspension	≥ 1 yr.	5ml
Ciloxan	ciprofloxacin 0.3%	Alcon, and generic	sol./oint.	≥ 1 yr./ ≥ 2 yrs.	5ml, 10ml/3.5g
Moxeza	moxifloxacin 0.5%	Alcon	solution	≥ 4 mos.	3ml
Ocuflox	ofloxacin 0.3%	Allergan, and generic	solution	≥ 1 yr.	5ml, 10ml
Vigamox	moxifloxacin 0.5%	Alcon	solution	≥ 1 yr.	3ml
Zymaxid	gatifloxacin 0.5%	Allergan, and generic	solution	≥ 1 yr.	2.5ml
<b>Aminoglycosides</b>					
Tobrex	tobramycin 0.3%	Alcon, and generic	sol./oint.	≥ 2 mos.	5ml/3.5g
Garamycin	gentamicin 0.3%	Perrigo, and generic	sol./oint.	N/A	5ml/3.5g
<b>Polymyxin B Combinations</b>					
Polytrim	polymyxin B/trimethoprim	Allergan, and generic	solution	≥ 2 mos.	10ml
Polysporin	polymyxin B/bacitracin	generic	ointment	N/A	3.5g
Neosporin	polymyxin B/neomycin/ gramicidin	generic	solution	N/A	10ml
	polymyxin B/neomycin/ bacitracin	generic	ointment	N/A	3.5g
<b>Other Antibiotics</b>					
AzaSite	azithromycin 1%	Akorn	solution	≥ 1 yr.	2.5ml
Ilotycin	erythromycin 0.5%	Perrigo, and generic	ointment	≥ 2 mos.	3.5g
Bacitracin	bacitracin 500u/g	Perrigo	ointment	N/A	3.5g



(which contains generic trimethoprim with polymyxin B), tobramycin or Besivance, depending on the nature and severity of the infectious condition; but we embrace Neosporin ointment without hesitation for those rare occasions when overnight antibiosis is deemed necessary to enhance a clinical cure.

As we have made clear, neomycin is a wonderful drug, but can on rare occasions cause an annoying type IV delayed hypersensitivity reaction. Given that we have three alternatives (generic Polytrim, generic tobramycin and Besivance) that are much less prone to causing any sort of allergic response, we prefer to follow this simpler path for most patients most of the time.

**MACROLIDES**

The macrolide antibiotics (i.e., erythromycin, azithromycin and clarithromycin) are widely used systemically but have limited use topically.

Regarding erythromycin, many bacteria are increasingly resistant. In like manner, topical azithromycin has been shown to have limited antibiotic efficacy, and the FDA has stated that

it has little or no clinically significant anti-inflammatory properties; therefore, its use in clinical patient care is quite limited.

**BESIFLOXACIN**

Besifloxacin is a highly unique dual-halogenated quinolone that is not used systemically. Clinical studies (see “New Benchmarks on Antibiotic Resistance,” page 10) show it to have low MIC<sub>90</sub> values, very similar to those of vancomycin, the gold standard in treating known gram-positive pathogens. (Vancomycin is not commercially available as an ophthalmic formulation and has to be prepared by a compounding pharmacy.) Besifloxacin also has strong coverage against gram-negative organisms, including *Pseudomonas*. This is true of the aminoglycosides as well.

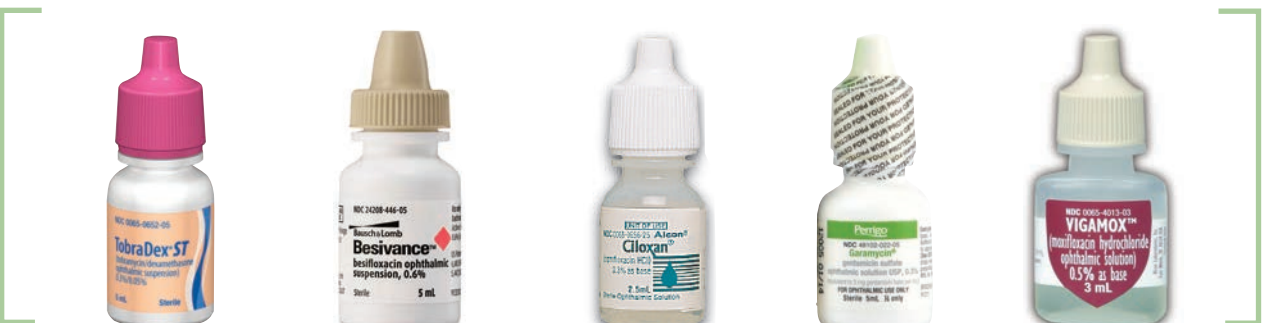Besifloxacin is a 0.6% ophthalmic suspension (the rest are solutions), and it needs to be shaken before each instillation. It is a thick eye drop, so the patient should not blink for a few seconds after instillation to allow the drop to spread out across the ocular surface and remain in the eye.

**NEOMYCIN**

Traditional wisdom with regard to this excellent antibiotic focuses more on the negatives than the positives. Yes, neomycin does possess the ability to cause an annoying, type IV delayed hypersensitivity on rare occasions, but let’s not throw out the baby with the bathwater.

Neomycin itself is broad-spectrum, but it does not cover *Pseudomonas*, which is why it is always packaged with polymyxin B or another antibiotic to cover gram-negative organisms. In our experience, type IV delayed hypersensitivity dermatconjunctivokeratitis reactions are exceedingly rare when the neomycin combination is used for no more than a week.

The exception is the rare patient who has been previously exposed to neomycin and already has immunosensitivity. These patients can react to neomycin in just a day or two, which may also be the result of a type 1 hypersensitivity to initial exposure. Patient management is simply to stop the medication. Again, these are non-serious, annoying, superficial responses. In our many years of





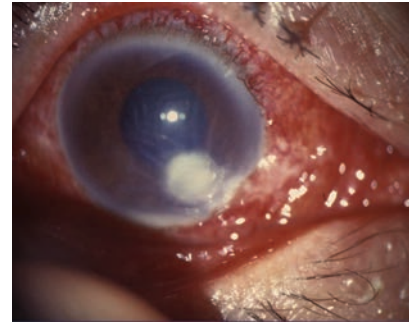
## THERAPEUTIC OPTIONS FOR CORNEAL ULCERS

Thankfully, infectious corneal ulcers are very rare, but when they do occur, they are treated aggressively with topical antibiotic eye drops. For perspective, leukocytic infiltrates also create little white lesions in the anterior stroma that may have a relatively small epithelial defect over the center of the white infiltrate. These infiltrates are often naively and incorrectly referred to as “ulcers,” when in fact, they possess no infectious potential. Rather, these are inflammatory expressions—almost always occurring at or near the limbus—and treatment with a steroid (a combination drug such as Zylet, generic Maxitrol or generic TobraDex) is required to suppress this pathophysiological process.

Infectious ulcers come in two varieties: large, central ulcers; and small-to-large, noncentral ulcers. Central ulcers are most commonly treated with fortified tobramycin (for gram-negative coverage) and vancomycin (for gram-positive coverage). Most eye reference texts, such as the *Wills Eye Manual*, can guide you and the compounding pharmacy on how to make these preparations. Generally speaking, these medicines are used about every 30 minutes for the first few hours, then hourly while awake until obvious healing is occurring; every two hours for another few days; and finally, four times a day for a few more days. Rather than have the patients instill these drops around the clock, we prefer the use of Neosporin ophthalmic ointment at bedtime. Once good healing has occurred, the nocturnal ointment can be discontinued. Some patients are allergic to Neosporin, so alternatives exist (e.g., polysporin and Ciloxan, or even TobraDex ointment).

For noncentral ulcers, we use Besivance (besifloxacin 0.6% ophthalmic suspension) every 30 minutes for a few hours, then hourly, etc., as outlined in the preceding paragraph concerning use of the fortified eye drops. Neosporin (or Polysporin) or TobraDex ointment at bedtime is also used as above.

We always cycloplege these patients, as they invariably will have a secondary anterior uveitis. Either atropine 1% or homatropine 5% is typically used to accomplish this purpose. The standard dosage is cycloplegia two to four times daily, depending upon the severity of the clinical condition.



## CONQUERING BLEPHARITIS

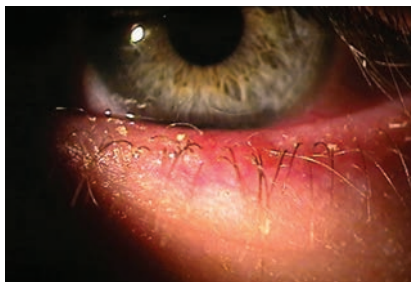Chronic anterior eyelid margin disease is most commonly caused by chronic, low-grade infection of *Staphylococcus aureus* and *Staphylococcus epidermidis* bacteria. These bacteria produce exotoxins, creating secondary inflammation to the adjacent eyelid marginal tissues. (This is distinct from meibomian gland disease, which has a wholly different pathophysiology.) Occasionally, these exotoxins can cause inferior corneal epithelial compromise.

Understanding the cascade of tissue compromise resulting from unchecked *Staph.* populations residing on the anterior eyelid tissues perfectly provides the rationale for using a good antibiotic/corticosteroid combination drug as the treatment of choice for symptomatic blepharitis. No other drug or drug class even approximates the efficacy of such therapeutic intervention.

Any of the available combination drugs would work well short term (less than two weeks), but given that blepharitis is a chronic, recurrent disease, the drug we find best suited for treating blepharitis is a combination of tobramycin (excellent anti-*Staph.* action) with loteprednol (excellent, safe, anti-inflammatory action) known by the popular brand name Zylet.

Initiate treatment with Zylet four times daily for two weeks, depending upon the severity of the clinical disease, then just pulse dose four times a day for a week if or when breakthrough symptoms occur. Such pulse dosing is an effective and “steroid-sparing” therapeutic approach and one that we embrace for almost any chronic, recurrent ocular surface disease.

The combination drugs TobraDex and Maxitrol are both generic and relatively inexpensive, but contain dexamethasone, which limits their usefulness beyond a couple of weeks. One would rarely ever employ dexamethasone for a chronic condition because of its propensity to increase intraocular pressure. All three of these drugs are suspensions and, as such, need to be shaken well.



However, blepharitis is not treated exclusively with any eye drop. Concurrent use of eyelid scrubs is an essential component to not only help control the infectious/inflammatory disease, but as ongoing hygiene to maintain eyelid health. Avenova (hypochlorous acid 0.01%, NovaBay Pharmaceuticals) eyelid and eyelash cleanser has become quite popular, and does seem to help maintain healthy tissues in our patients. Further, with diminution of *Staph.* populations, there is a decreased risk of secondary styes and internal hordeola.

In summary, the combined use of an effective, safe antibiotic/steroid and meticulous eyelid hygiene perfectly embodies rational care for patients with anterior eyelid margin disease.

clinical practice, we have seen only half a dozen such events, mostly with neomycin exposure of greater than a week, and often prescribed by primary care practitioners.

When neomycin is packaged (along with polymyxin B) with a steroid, such as generic Maxitrol, whatever expression of a hypersensitivity reaction that may be occurring typically remains subthreshold, or subdued, courtesy of the concurrent corticosteroid suppression.

The aminoglycosides, used systemically, can cause ototoxicity. For this

reason they are rarely, if ever, used systemically. Any drug actively or passively reserved for only topical use is relatively protected from resistance, thus enabling it to be a powerful chemotherapeutic agent for many decades. For example, bacitracin was brought to market in the 1940s and remains a superb, exclusively gram-positive antibiotic into the 21st century.

In summary, neomycin remains an excellent antibiotic in combination with other antibiotics, such as Neosporin and/or dexamethasone, and when used for about a week. The acute red

eye that one would treat with a combination drug almost invariably requires treatment for no more than a week. These medicines are highly effective, cheap, and they remain workhorse drugs in contemporary eye care.

Last, we stress that bacterial infections are characterized by a mucopurulent discharge. Sometimes this is grossly visible; other times, the discharge is more subtle and is only found via slit lamp observation of microparticulate debris in the lacrimal lake.

Both the aqueous humor and lacrimal lake should be optically empty.



## FROM THE LITERATURE

### NEW BENCHMARKS ON ANTIBIOTIC RESISTANCE

The five-year Antibiotic Resistance Monitoring in Ocular Microorganisms (ARMOR) study data was recently published in *JAMA Ophthalmology* (December 2015). This is reportedly the most robust evaluation of nationwide antibacterial susceptibility of common ocular pathogens to date. Thankfully, resistance rates have remained stable over the past five years of this study.

About half of *Staphylococcus* species are methicillin resistant, meaning they are more difficult to kill than the methicillin-sensitive bacterial pathogens. Minimal inhibitory concentration-90 (MIC<sub>90</sub>) represents how effective a drug is at eradicating a bacterial species—i.e., the lowest concentration of a drug that will inhibit 90% of bacterial isolates. To interpret these results: the lower the MIC<sub>90</sub>, the more effective the drug. Focusing on the most commonly prescribed drugs, the findings are as follows:

Some drugs were not tested against all pathogens,

hence some blanks are present. Also, we did not list methicillin-sensitive *Staphylococcus* species because a clinician does not know the nature (i.e., methicillin sensitive vs. methicillin resistant) of the causative pathogen at clinical presentation, so we need to treat based on a “most difficult to kill” approach. If we treat a presumed *Staphylococcus* infection, and in reality it is methicillin sensitive, it will be quickly eradicated if we are assuming (and treating for) methicillin-resistant species.

Interestingly, MRSA organisms are more common among the elderly and those who reside in the southern portions of the United States. Note that the drug of choice for culture-proven *Pseudomonas* is ciprofloxacin, although the fluoroquinolones and tobramycin performed quite well.

A summary statement says: “Until rapid diagnostic methods are available to guide treatment choices, clinicians should consider these data to guide the empirical treatment of ocular infections.”

Asbell PA, Sanfilippo CM, Pillar CM, et al. Antibiotic Resistance Among Ocular Pathogens in the United States: Five-Year Results From the Antibiotic Resistance Monitoring in Ocular Microorganisms (ARMOR) Surveillance Study. *JAMA Ophthalmol*. 2015 Dec;133(12):1445-54.

### MINIMUM INHIBITORY CONCENTRATIONS (MIC<sub>90</sub>) FOR SELECTED ORGANISMS

	MRSA	MR <i>Staph Epi.</i> *	<i>Strep. Pneumo.</i>	<i>Pseudomonas</i>
Ciprofloxacin	256	64	1	0.5
Gatifloxacin	16	32	0.25	2
Moxifloxacin	16	32	0.12	4
Besifloxacin	2	4	0.06	4
Azithromycin	>512	>512	>128	
Tobramycin	>256	16		1
Trimethoprim	2	>128		
Vancomycin	1	2		

\* There are many organisms which are “coagulase-negative” but *Staph. epidermidis* is by far the most numerous, and therefore we have chosen to use *Staph. epi.* as synonymous with the coagulase-negative *Staph.*

Note that besifloxacin and vancomycin share superb MIC<sub>90</sub> levels, which would portend high clinical efficacy.

Cellular and/or proteinaceous debris in the aqueous humor is exhibited in anterior uveitis and debris in the lacrimal lake is typically seen in more subtle cases of acute bacterial ocular surface infection.

Every time you are uncertain of the diagnosis and are considering prescribing a topical antibiotic, always reconsider this low-yield therapeutic approach. At the very least, consider use of a combination antibiotic-steroid with appropriate follow-up care in two to three days.

### ORAL ANTIBIOTICS

Selecting an oral antibiotic for acute internal hordeola is usually straightforward. We almost exclusively prescribe the first-generation cephalosporin cephalexin (Keflex) at 500mg BID for one week.

If the condition is severe and/or the patient is large in size, then 500mg QID for one week may be indicated.

If the patient has had a true anaphylactic reaction to a penicillin drug, we opt for Levaquin (500mg QD) or doxycycline (200mg/day), or Bactrim or Septra (both common brand names of trimethoprim with sulfamethoxazole) prescribed as two DS (double strength) tablets BID for one week. This “double strength” is the standard, commonly prescribed dosage.



### KEEP IN MIND

### THE EFFICIENT RED EYE EVALUATION

*Each of these procedures generally takes about two to three minutes in most cases.*

- Assess visual acuity (pinhole if indicated)
- Note the degree of conjunctival injection
  - Mild: dry eyes, allergy, chlamydia, mild bacterial infections
  - Marked: acute viral or non-specific bacterial infection, acute iritis
- Note the degree of conjunctival injection pattern
  - Sector injection: corneal infiltrate, episcleritis, phlyctenule, inflamed pinguecula
  - Global injection: uniform—bacterial or viral infection, or uveitis
  - More pronounced in fornices: bacterial infection
  - More pronounced paralimbally: uveitis
- Quality and quantity of discharge if any
  - Watery: viral
  - Mucoid: dry eyes, allergy, chlamydia
  - Mucopurulent: bacteria
- Preauricular lymphadenopathy (not grossly visible)
  - Most commonly, adenoviral
  - Less commonly, chlamydial
  - Rarely, hyperacute conjunctivitis
  - If grossly visible: Parinaud’s oculoglandular syndrome (cat-scratch disease)
- Follicles vs. papillae: clinically virtually meaningless
  - Exception: Giant follicles in the inferior forniceal conjunctiva are highly indicative of chlamydial infection
- Character of cornea: Examine without, then with, fluorescein dye to rule out herpes keratitis, subtle abrasions, ulceration, through-and-through perforation (Seidel’s sign)
- Measure the IOP if no contraindications exist
- Evert the eyelid to rule out conjunctival foreign material or pathology
- Examine the anterior chamber for cells/flare
- Quick ophthalmoscopy to rule out concurrent intraocular disease



### OPHTHALMIC MYTHS: INFECTION CARE

**Myth** Fourth-generation fluoroquinolones are the best, most effective medicines for ocular surface infections.

**Our Take** Several recent studies have documented significant and increasing resistance to this class of medicine. Better choices would be an aminoglycoside, trimethoprim with polymyxin B, or Besivance suspension.

**Myth** Pressure patching abrasions is now obsolete.

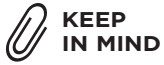**Our Take** Patients with large, painful abrasions may be best treated with therapeutic cycloplegia and a well-placed pressure patch over an antibiotic ointment, such as Polysporin (bacitracin with polymyxin B), at least initially. Most abrasions are treated with a bandage/therapeutic soft contact lens with topical trimethoprim/polymyxin B (Polytrim) eye drops used four times a day until the abrasion is healed. The generic Polytrim is used because it is minimally toxic to the ocular surface, highly effective and affordable.

**Myth** Don’t touch the dropper tip to the eye, as it could cause an infection.

**Our Take** We all know many patients do this routinely, and we have never seen an eye infection from such a behavior. No doubt this has happened to some unlucky soul, but such a complication would be exceedingly rare. The greater risk is the potential for corneal abrasion.

**Myth** Ointments retard re-epithelialization in the setting of corneal abrasion.

**Our Take** This has long been proven to be false.



## HOLD THAT BLINK!

Azithromycin, besifloxacin and some of the lipid-based artificial tears are very viscous eye drops, so it is important to instruct the patient to gently close the eyes and not blink for five to eight seconds after instillation.

This allows the thick drop to spread across the ocular surface and have greater retention; otherwise, the drop could be quickly expelled out of the eye and onto the eyelid or floor.

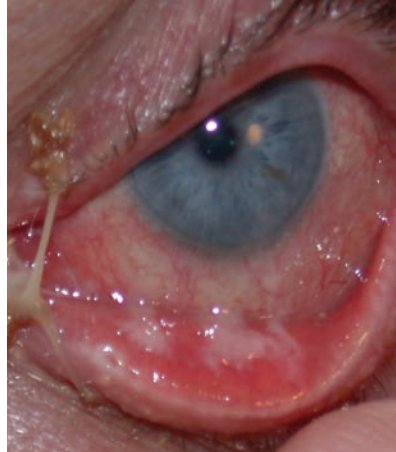If the patient is truly allergic to both penicillin and sulfa, consider oral doxycycline 100mg BID for one week, or the oral fluoroquinolone levofloxacin 500mg once daily for one week. For perspective, the risk of a cross-sensitivity reaction of a cephalosporin in a patient truly allergic to penicillin is about 0.1%, but why ever take this miniscule risk? Just prescribe an alternate class.

## QUOTABLE

**IF THE PATIENT IS TRULY ALLERGIC TO BOTH PENICILLIN AND SULFA, THEN CONSIDER ORAL DOXYCYCLINE 100mg BID FOR ONE WEEK, OR THE ORAL FLUOROQUINOLONE LEVOFLOXACIN AT 500mg ONCE DAILY FOR ONE WEEK.**

Always remember that the aggressive use of warm soaks is essential to maximize restoration to a normal state in acute eyelid infections.

For chronic care conditions, such as meibomian gland disease and rosacea blepharitis, prescribe doxycycline at 50mg daily for three to six months. The dichotomous character of doxycycline (anti-infective at high dosage, and anti-inflammatory at low dosage) requires different dosing based on clinical intent. Some recent research also suggests a five-day course of oral azithromycin can improve MGD.<sup>1</sup>

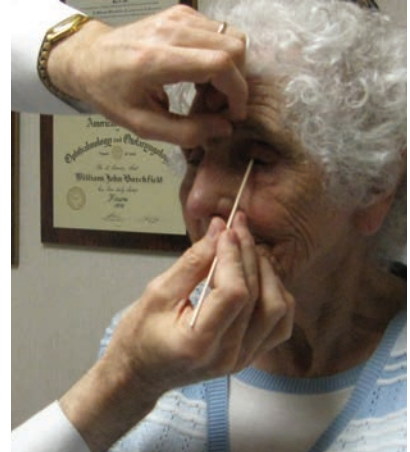

Classic appearance of giant fornix syndrome, a *Staphylococcus aureus* infection in older patients that is more challenging to treat than typical bacterial infections.

As a postscript, pharmacy pricing issues are maddening, and clinicians are constantly faced with dynamic and ever-changing pricing structures. Regarding doxycycline, we have found in several instances that the 100mg units are cheaper than the 50mg units.

Therefore, we occasionally prescribe 100mg doxycycline monohydrate tablets that can be split in half to provide our patients cost-effective treatment. While both doxycycline hyclate and doxycycline monohydrate are well-tolerated, the monohydrate form appears to be a bit better tolerated.

An interesting article in the *Journal of the American Academy of Dermatology* (February 2016) pointed out two noteworthy observations: If a patient's acne is not improved by three to four months of doxycycline, then it should be stopped, and an alterna-



Perform a thorough sweep of the superior cul-de-sac. This can help find elusive foreign bodies or, in this case, remove fixed innoculum debris residing deep in the forniceal conjunctiva.

tive drug selected.<sup>2</sup> This could parallel our use of doxycycline 50mg/day to treat rosacea blepharitis or meibomian gland disease. "Plan B" was minocycline, but since they perform very similarly, the authors recommended trying azithromycin (a different class of antibiotic). The literature also shows that azithromycin 500mg three times/week is as effective as doxycycline in treating rosacea, while 500mg/day for two weeks is effective for cases of intractable rosacea.<sup>3,4</sup> However, dermatologists defaulted to minocycline 80% of the time, and azithromycin 20% of the time.

Overall use of azithromycin among dermatologists is about 3%. Perhaps physicians of all stripes struggle with appropriate drug selection and appropriate duration of therapy. ■

1. Kashkoui MB, Fazel AJ, Kiavash V, et al. Oral azithromycin versus doxycycline in meibomian gland dysfunction: a randomized double-masked open-label clinical trial. *Br J Ophthalmol*. 2015;99(2):199-204.

2. Nagler AR, Milam EC, Orlow SJ. The use of oral antibiotics before isotretinoin therapy in patients with acne. *J Am Acad Dermatol*. 2016;74(2):273-9.

3. Akhyani M, Ehsani AH, Ghiasi M, Jafari AK. Comparison of efficacy of azithromycin vs. doxycycline in the treatment of rosacea: a randomized open clinical trial. *Int J Dermatol*. 2008;47(3):284-288.

4. Kim JH, Oh YS, Choi EH. Oral azithromycin for treatment of intractable rosacea. *J Korean Med Sci*. 2011;26(5):694-696.

# ALL ABOUT DRY EYE

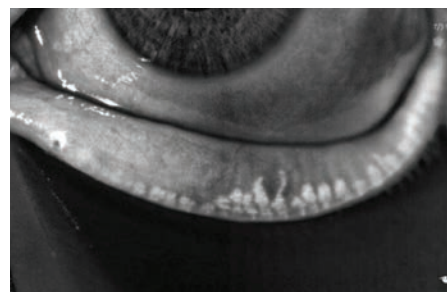We hope that some intervention will soon be found to help the masses who suffer from dry eye. For now, several rational approaches, properly applied, can help most patients.

**D**onald Korb, OD, and Caroline Blackie, OD, PhD, and their research team, along with other researchers around the world, have now shown that the “root of all evil” in dry eye disease is dysfunction of the meibomian glands.<sup>1</sup> Said differently, if we can find ways to embellish and restore normal meibomian gland function, most dry eye disease likely would resolve or not occur at all.

Following along this foundational pathophysiologic pathway, it makes sense that a dysfunction of the lipid layer needs to be secondarily addressed. With this cascade of deterioration of the precorneal tear film, hyperosmolarity occurs because of increased evaporation, which then causes ocular surface inflammation. Such inflammation has been consistently characterized as the epicenter of the pathogenesis of clinically symptomatic dry eye disease.

Let’s try a complex analogous comparison of meibomian gland disease (MGD) to vascular disease: Many factors, such as diet, lifestyle and genetics, determine one’s risk for hypercholesterolemia. Such pathological blood chemistry leads to atherosclerotic plaquing of the intimal lining of arteries. If subsequent cholesterol levels are not stabilized, the risk of arterial occlusion occurs, which can result in a heart attack or stroke.

The cascade of evaporative dry eye dis-



This patient’s lid, imaged with meibography technology, displays severe meibomian gland dysfunction.

ease is comparable. Obviously, the earlier we can intervene in these pathophysiological processes, the better. Different therapies are employed at these different stages.

Until meibography comes into widespread clinical use, which will allow us to stratify proper interventions, we will continue to encounter patients at secondary and tertiary levels of dry eye expression. Interventions could include: inclusion of dietary omega-3 essential fatty acids, such as fish oils or flaxseed oil; use of lipid-based artificial tears to augment the deficient lipid layer; and/or a short course of a topical ester-based corticosteroid to address the inflammatory component. A clear target for intervening at the earliest stages of meibomian gland compromise has yet to be fully elucidated, but it is obvious that supporting meibomian gland

\* Loteprednol (Lotemax) therapy for inflammation due to dry eye disease is considered an off-label use. All mentions of such use herein reflects the views of the authors.

## COMMONLY USED LIPID-BASED ARTIFICIAL TEARS

Brand Name	Manufacturer	Lipid	Lubricants	Preservative
Refresh Optive Advanced	Allergan	castor oil	carboxymethylcellulose, glycerin, polysorbate 80	Purite (stabilized oxychloro complex)
Refresh Optive Advanced Preservative Free	Allergan	castor oil	carboxymethylcellulose, glycerin, polysorbate 80	none
Retaine MGD	OcuSoft	glycerol	light mineral oil, mineral oil	none
Soothe XP	Bausch + Lomb	light mineral oil, mineral oil	polysorbate 80	polyquarternium-1
Systane Balance	Alcon	mineral oil	propylene glycol	polyquarternium-1

function early on is the key to ultimate prevention of dry eye disease.

Aggressive use of warm compresses combined with physical expression of the meibomian glands can go a long way in enhancing proper function. While these maneuvers are indeed helpful, wouldn't it be grand if there were some sort of side effect-free pill we could give patients to prevent MGD and to maintain a youthful, vibrant precorneal tear film?

The current reality is that patients present to us with the downstream symptoms of dry, gritty, burning eyes. So, at least for the time being, we are left having to intervene at these more advanced levels of disease. This is why we commonly use lipid-based artificial tears and pulse-dosing of loteprednol used off-label, along with punctal plugs to address these dry eye symptoms.

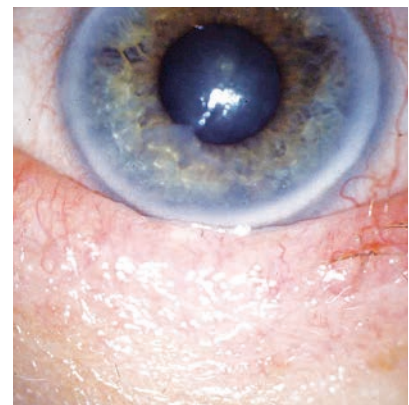
We are hopeful that potential FDA approval of a new drug for dry eye disease, lifitegrast, will be helpful in the amelioration of the signs and

symptoms with which patients present. Interventions such as LipiFlow and intense pulsed light can be introduced earlier in the pathway to hopefully obviate the need for downstream interventions.

We think that as meibography becomes a standard diagnostic tool in the office, and as technology becomes more refined and affordable, meibomian gland disease can be detected earlier, and preventive or enhancement techniques can be employed to massively decrease the clinical presentation of symptomatic dry eye.

### CASCADE OF EVENTS IN DRY EYE DISEASE

We know that desiccatory stress initiates the cascade of events leading to dry eye disease. Clinically, therapeutic intervention is relatively straightforward: Suppress the ocular surface inflammation and augment the precorneal tear film (especially the lipid layer) with lipid-based artificial tears. This latter portion can be further aug-

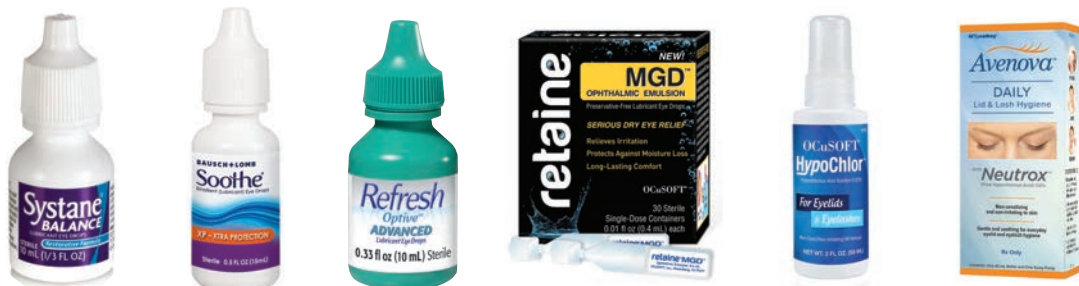

A reduced lacrimal lake and meibomian gland dysfunction, as is seen in this patient, suggests a poor tear film lipid layer.

mented with fish oil and/or punctal plugs.

Although treatment is comparatively basic, the biochemical mechanism is complex—but here is a simplified version:

Intracellular adhesion molecules (ICAM) are found on the surface of





## A LOOK AT SJÖGREN'S SYNDROME

Patients with Sjögren's syndrome (SS) comprise a small subset of the dry eye disease population, yet these patients often have a more debilitating expression of the disease. It is important that we have a contemporary perspective on this condition. An insightful article in *Ophthalmology* (January 2015) made some useful contributions to our knowledge in this area.<sup>1</sup> Excerpts are as follows:

- "Sjögren's syndrome is a multi-system autoimmune disease characterized by lymphocytic infiltration of exocrine glands in other organs."
- "Although common, SS is under-recognized in clinical practice, largely as a result of its diverse presentation leading to a significant delay in diagnosis. This delay is of great clinical significance because patients with SS are likely to have reduced quality of life as a result of pain, fatigue, depressed mood, and cognitive symptoms."
- "Lymphoma is one of the most serious complications of SS, and the primary source of increased mortality resulting from this disease. Multiple studies consistently have identified SS as an independent risk factor for non-Hodgkin's lymphoma."
- "We recommend assessing the presence of SS in patients with clinically significant dry eye because dry eye precedes the occurrence of these manifestations."

Optometry has a unique opportunity to help potential SS patients by being keenly attentive to the history, and care, of patients with dry eye disease. Quite simply, be sure to query patients, particularly women, about "pain, fatigue, depressed mood and cognitive symptoms."

Write down the words "Sjögren's syndrome" for your SS-suspect patients, and encourage them to ask their primary care physician to pursue a diagnostic evaluation. Most physicians, especially rheumatologists, are fully capable of doing this. It is our duty and responsibility to be especially attentive to this cohort of possible SS patients and provide guidance and encouragement to them.

There is a new blood test, Sjö, that any optometrist can order, which uses newer, novel biomarkers than are currently in widespread clinical use. Using this diagnostic assay, SS may be detected five years earlier than with existing testing. At the very least, encourage your SS-suspect patients to seek care from their PCPs or a rheumatologist as this may be critical to their longevity and quality of life.

In addition, guidelines for management of dry eye associated with SS were published in April 2015 in *The Ocular Surface*.<sup>2</sup>

1. Akpek EK, Mathews P, Hahn S, et al. Ocular and systemic morbidity in a longitudinal cohort of Sjögren's syndrome. *Ophthalmology*. 2015 Jan;122(1):56-61.

2. Foulks GN, Forstot SL, Donshik PC, et al. Clinical guidelines for management of dry eye associated with Sjögren disease. *Ocul Surf*. 2015 Apr;13(2):118-32.

epithelial cells, and they are over-expressed in the face of desiccatory stress. T-lymphocytes abound throughout the body, and their activation results in inflammation. When T-lymphocyte cells are activated, they release pro-inflammatory cytokines. These cytokines lead to the development of tissue inflammation. On the surface of T-lymphocytes are receptors called lymphocyte functional associated antigen (LFA). ICAM binds (ligands) to the LFA, thus activating the T-cell lymphocytes, setting the inflammatory cascade in motion.

Investigational data shows that lifitegrast blocks recruitment and activation of T-lymphocytes to the ocular surface by binding to LFA on the surface of T-lymphocytes and preventing LFA from interacting with ICAM on the surface of the corneal epithelial cells and on other immune cells residing in the ocular surface tissue.<sup>2</sup>

Think of IgE receptors on mast

cells as the ligand to antigen, setting in motion degranulation, release of histamines and the start to the allergic cascade.

Topical steroids potently inhibit this process and subdue the inflammation. NSAIDs and Restasis (cyclosporine 0.05%, Allergan) also inhibit this process, but in a more attenuated manner.<sup>3-4</sup> This is why we initiate anti-inflammatory therapy with the most efficacious suppressor of inflammation: a topical corticosteroid. As per our algorithm, we use Lotemax\* QID for two weeks, then BID for two more weeks. Should lifitegrast gain FDA approval, we plan to try using this agent concurrently at the time we reduce Lotemax to BID. The drug's Phase III OPUS-1 trial showed improvement in corneal and conjunctival staining associated with ocular inflammation.<sup>5</sup>

When you understand the basic biochemistry and medicinal chemis-

try, then this inflammatory process and its treatment makes perfect sense.

## PROPER DIAGNOSIS AND TREATMENT

The genesis of most cases of dry eye disease lies in the meibomian glands. Perhaps it is our diets and lifestyles that set the stage for altered meibum function; the pathophysiology has not been fully elucidated.

Not all meibomian gland disease is immediately evident. We can test for "non-obvious" meibomian gland disease by pressing on the meibomian glands to qualify and quantify their secretions. This is a diagnostic maneuver that needs to be a routine part of the comprehensive eye examination.

Performing meibography could/should be entertained as well. Just as OCT has revolutionized posterior pole evaluation, so will meibography for MGD. Unfortunately, just as with asymptomatic glaucoma, it is difficult

## THIS DEVICE IS A REAL TEAR-JERKER

It is well said that “necessity is the mother of invention,” and herein we share just how true this is.

Most chronic conditions present a management challenge. Dry eye is a perfect example. Certainly, we have essential fatty acids to help meibomian gland disease.<sup>1</sup> We have good quality lipid-based artificial tears and good anti-inflammatory medicines. While these can be helpful to many patients, there is always a need for other beneficial interventions.

Enter a new idea currently in clinical trials called *intranasal lacrimal neurostimulation* (ILN). A battery-powered device generates a low-grade electrical current that stimulates lacrimation when applied to the interior aspect of the nose—not copious tearing, but rather more of a physiological enhancement of natural tear production. This genius concept seems to truly help many patients suffering from dry eye disease.

Allergan acquired this technology from the original research and development company Ocuve, and plans to commercialize such a device in the event of FDA approval. In one study, this handheld instrument, self-administered by patients four times a day, showed increased tear production and reduced corneal/conjunctival staining out to

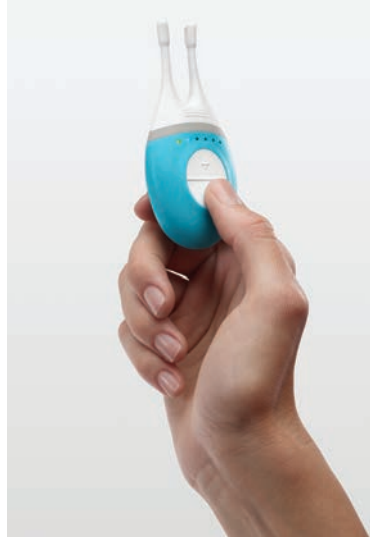

Photo: Allergan

180 days.<sup>2</sup> Specific neurological pathways are crucial to maintenance of a healthy ocular surface. Delivery of low levels of intranasal neuronal stimulation activates these pathways, which stimulates tear production.

The precorneal tear film has three sub-layers, and it is yet to be fully determined if there is an effect on mucin and/or lipid layers in addition to aqueous layer enhancement. A 2016 ARVO abstract, however, does show conjunctival goblet cell degranulation and increased mucin level after ILN.<sup>3</sup>

We foresee a definite, but not yet quantified, role for this device, but we will not know the exact stage of disease or optimum frequency of application until widespread clinical application. We are excited to see the potential of intranasal lacrimal neurostimulation for dry eye treatment.

Trials are ongoing. Hopefully, we will have more to write on this device next year, pending FDA approval.

1. Malhotra C, Singh S, Chakma P, et al. Effect of oral omega-3 Fatty Acid supplementation on contrast sensitivity in patients with moderate meibomian gland dysfunction: a prospective placebo-controlled study. *Cornea*. 2015 Jun;34(6):637-43.
2. Chayet A. Evaluation of the effect of intranasal lacrimal neurostimulation on tear production in subjects with dry eye: nonrandomized open-label study. ASCRS 2016 paper session 3-A.
3. Gumus K, Schuetzle K, Loudin JD, Pflugfelder SC. Randomized, controlled, crossover trial comparing the impact of sham or intranasal neurostimulation on conjunctival goblet cell degranulation ARVO 2016 abstract 2864.

to get patient cooperation in the treatment of asymptomatic dry eye disease. Success in getting patients to consistently use warm soaks, eyelid massage (including LipiFlow, etc.) and fish oil supplementation at these pre-symptomatic stages of dry eye/meibomian gland disease is a challenge. The reality is, early intervention in meibomian gland disease may be ideal, but it is

not wholly practical at this time.

Regarding diagnosis of dry eye disease, the approach we use is profoundly simple:

1. First, take a history of the patient’s symptoms
2. Next, assess the height and volume of the lacrimal lake
3. Stain the cornea with fluorescein or lissamine green dye to assess the

integrity of the epithelial tissue, and measure the tear film breakup time.

As part of our diagnostic protocol for dry eye disease, these three steps offer us the information needed to make the diagnosis and provide superb patient care.

When patients do present with symptomatic dry eye disease, we have quite a few options for resolution.



## FROM THE LITERATURE

### SUPPRESS INFLAMMATION TO TREAT DED

Dry eye is a complex, multifactorial condition of the ocular surface whose pathogenesis can be attributed to two different mechanisms, namely reduced tear production and increased tear evaporation, both inducing increased tear osmolarity and inflammation, according to a recent study in *Ophthalmology*:

“Given the importance of inflammation in dry eye patho-

genesis, various anti-inflammatory agents were used to treat this syndrome. In particular, there is a type I level of evidence on corticosteroids efficacy. Among these, 0.5% loteprednol etabonate was effective in reducing signs and symptoms of dry eye ... Modulating the expression of proinflammatory and proapoptotic molecules may have a therapeutic potential for the treatment of the corneal epithelial disease that develops in dry eye.”

- Aragona P, Aguenouz M, Rania L, et al. Matrix metalloproteinase 9 and transglutaminase 2 expression at the ocular surface in patients with different forms of dry eye disease. *Ophthalmology*. 2015 Jan; 122(1):62-71.





## FROM THE LITERATURE

### DESSICATORY STRESS AND STEROIDS

A recent study sheds light on the environmental factors that can impact our dry eye patients.

- What can treat dry eye in a dry environment? “In this study, we found that dry eye signs and symptoms worsened after exposure to low-humidity environment when subjects were untreated and also when subjects were treated with 2 weeks of artificial tears. However, after 2 weeks of treatment with dexamethasone, subjects reported decreased eye irritation symptoms compared to their initial evaluation, and they had a significantly lower increase in HLA-DR expression and reduced corneal and conjunctival staining after the low-humidity exposure compared to prior expo-

sure. Typically applied corticosteroids can suppress acute environmentally induced ocular surface inflammation.”

- “In conclusion, our study shows that corticosteroids can mitigate the adverse effects of low-humidity environmental stress on the ocular surface in individuals with dry eye disease. This suggests that the increased irritation and ocular surface epithelial disease that develops following a desiccating environmental challenge is attributable to inflammation that can be modulated by a corticosteroid.”

Rather than dexamethasone, we would use either Lotemax gel or generic fluorometholone because of the extended margin of safety.

Moore QL, De Paiva CS, Pflugfelder SC. Effects of dry eye therapies on environmentally induced ocular surface disease. *Am J Ophthalmol.* 2015 Jul;160(1):135-42.

Because almost all dry eye disease is expressed as a result of meibomian gland disease, evidence exists that there is a lipid-deficient dry eye state; so we should, at the very least, start the patient on a lipid-based artificial tear, such as Soothe XP (Bausch + Lomb) or Systane Balance (Alcon).

For those rare patients we encounter who need a preservative-free tear, Retaine MGD (OcuSoft) or Refresh Optive Advanced Preservative Free (Allergan) are excellent. Gel formulations, such as Systane Gel (Alcon) or GenTeal Gel (Novartis) can be used at bedtime if needed, which is not all that often.

If there is concurrent blepharitis, warm soaks followed by meticulous eyelid hygiene can be quite helpful. Hypochlorous acid in solution is an efficient antimicrobial agent, reported to have a >99.99% kill for many pathogens.<sup>6,7</sup> Anecdotally, it appears the newer hypochlorous acid scrubs (e.g., NovaBay, Ocusoft, etc.) work well. The main drawback to these is the necessity for the patient to purchase cotton pads at the pharmacy on which to spray the hypochlorous acid solution prior to performing lid scrubs.

We start almost all of our patients on 2,000mg of fish oil daily, telling them that it may be four to six months before the full benefit of the supple-

ment is achieved. The omega-3 essential fatty acids found in fish (or flaxseed) oil enhance meibomian gland function, and this therapy is likely enhanced with warm soaks.

We guide the patient to consult with a pharmacist regarding a premi-

um-quality fish oil. It is our opinion that a pharmacist should know more about the nuances of fish oil than most clinicians.

For patients with a history of difficulty swallowing large capsules, recommend either Coromega Omega-3



## FROM THE LITERATURE

### EFFICACY OF LOTEMAX GEL FOR EVAPORATIVE DED & MGD

In some big news for treatment of patients with evaporative dry eye (EDE) disease and meibomian gland dysfunction (MGD), a study presented at a poster session at the annual American Academy of Optometry meeting in October 2015 on the efficacy of off-label use of loteprednol etabonate ophthalmic gel 0.5% for treating evaporative DED and MGD found:

- When used twice a day, loteprednol etabonate ophthalmic gel 0.5% significantly improved the clinical signs associated with EDE resulting from MGD.
- Loteprednol etabonate ophthalmic gel 0.5% showed significant reduction in severity of symptoms associated with EDE resulting from MGD.
- Results indicate that loteprednol etabonate gel is a safe and effective treatment option for EDE and MGD.

In this open-label, prospective, multi-centered study, patients with meibomian gland dysfunction were treated bilaterally with loteprednol gel 0.5% twice a day for 30 days. After treatment, all objective parameters evaluated showed a statistically significant improvement, except for Schirmer II and tear osmolarity. Results also showed a significant reduction of patient symptoms as measured by the OSDI and SPEED. IOP and visual acuity were unchanged, and no adverse events took place.



Opitz, DL, Evola C, Paradesi A, et al. (2015, October). Efficacy of loteprednol etabonate ophthalmic gel 0.5% for the treatment of evaporative dry eye and meibomian gland dysfunction. Poster presented at the meeting of the American Academy of Optometry, New Orleans, LA.

Orange Squeeze or Nordic Naturals liquids. The former is flavored as orange sherbet; the latter has a mild lemon flavor.

If the patient is moderately symptomatic at presentation, we don't hesitate to concurrently initiate Lotemax gel QID for two weeks, and then BID for two more weeks. It is well established that inflammation is central to symptomatic dry eye disease, so suppressing the inflammatory component is imperative in effecting relief of symptoms. We strongly prefer loteprednol because of its advanced safety profile. Fluorometholone 0.1% ophthalmic suspension can also be used, but it does not enjoy the same level of safety as the ester-based loteprednol (see "Steroids for Dry Eye Disease—Effective and Safe Long-Term Treatment," page 27). Lotemax gel does not need to be shaken, whereas fluorometholone drops must be shaken well prior to each instillation.

We generally see our dry eye patients back in one month to assess their progress. If dry eye symptoms persist after a month of topical corticosteroid therapy and use of a lipid-based artificial tear, we certainly consider punctal plugs. If all of these measures fail to bring about relief (which sometimes occurs, but uncommonly), do not forget Lacrisert inserts.

For a minority of patients whose symptoms return upon discontinuation of the corticosteroid, we try loteprednol BID for another month, and then once daily for another couple of months, with the goal of trying to find the least amount of drug sufficient to keep the patient comfortable. We have several patients who require Lotemax gel once (or twice) daily to achieve this state. Our patients typically do very well. However, for patients who do not respond well to this therapy, topical cyclosporine (Restasis) can provide modest but long-term suppression of inflammation.<sup>8</sup> We would begin with BID dosing for a few months, then QD for continued maintenance.

One non-coded procedure that we increasingly perform for our dry eye patients involves gently scraping across the top of the eyelid three to five times with a golf club spud. This inevitably seems to make our patients feel better right away (maybe like a back scratch), but its main benefit is to help open the meibomian gland orifices and smooth the top surface of the eyelids, further enhancing meibum secretion flow into the tear film, thereby bolstering the lipid layer.

Patients with persistent photophobia and discomfort/pain may have keratoneuralgia, a highly complex and not well-understood disease. A consult visit with a cornea subspecialist or with a pain management clinic would be in order. Centrally acting medicines such as gabapentin can occasionally be employed in these uncommon situations.

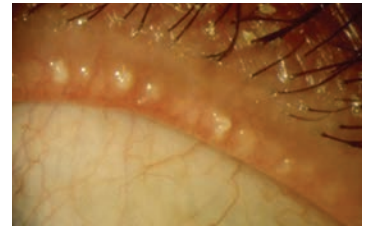
## GETTING CONTROL OF DRY EYE DISEASE

Several pharmacologic options are available (or may soon be) for maintaining symptomatic control of dry eye disease, once it has been achieved.

- *Enduring use of Lotemax\* gel drops once (or twice) daily*
- *Lifitegrast BID (pending approval)*
- *Restasis BID*
- *Pulse dosing of Lotemax\* gel drops*

The last option is likely the best approach in our experience, considering both efficacy and cost. The literature fully supports the concept of pulse dosing. As one example, the Asclepius Panel recommends practitioners begin early treatment with an anti-inflammatory agent (such as Lotemax) four times a day to improve symptoms and to prevent disease progression, reducing frequency to twice daily after two weeks and supplemented with Restasis twice a day.<sup>3</sup> We might see a patient who has achieved good control and comfort, but after several weeks or months her eyes begin to be symptomatic again. Here's where she could use Lotemax\* gel drops three or four times a day for four to seven

## KEEP IN MIND



**Clogged meibomian gland orifices restrict lipid secretion and lead to evaporative dry eye.**

## PERSPECTIVES AND PEARLS ON DRY EYE

Though not a part of the scientific literature, a recent review article offered some practical tips.

- Dry eye "is associated with contact lens use, cigarette smoking, diabetes, prolonged video display viewing and low-humidity environments."
- "The two major types of DED are aqueous tear deficiency and evaporative dry eye." Regarding distinguishing the two, "The reality is that it's pretty hard to tell. There's no sure fire test."
- Because about one in 10 patients with DED may have Sjögren's syndrome, "these patients often complain of dry mouth, fatigue, and joint pain. The clinician should always inquire about these symptoms in assessing dry eye patients." We fully agree.
- For moderate to severe cases of dry eye, "start with a steroid four times a day for two weeks then taper to twice a day for two weeks. No more than two to four weeks of treatment is recommended."
- "If you're going to use punctal plugs, put in the largest plug possible because it's more likely to stay in." Agreed.

Karmel M. A Quick Guide to Dry Eye. EyeNet Magazine. 2014 Jun;19(6)40-6.



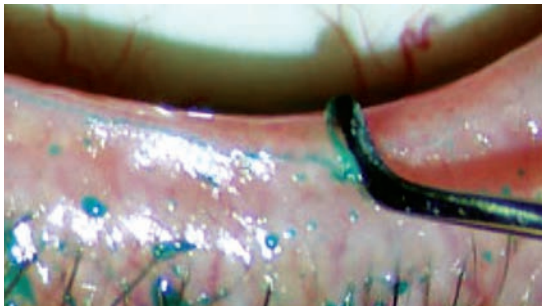
## FROM THE LITERATURE

### DEPRESSION AND DRY EYE: IS THERE A LINK?

An important study found that people with dry eye disease are about the three times more likely to have anxiety and/or depression.

“Perhaps the treatment of dry eye disease, then, would also benefit from treatment of depression and/or anxiety,” the authors wrote. (This is yet to be determined, but is a plausible concept.) By the same token, perhaps proper management of dry eye disease could help to some degree with depression and/or anxiety.

van der Vaart R, Weaver MA, Lefebvre C, et al. The association between dry eye disease and depression and anxiety in a large population-based study. *Am J Ophthalmol*. 2015 Mar;159(3):470-4.



To debride the lower lid margin, gently wipe a golf club spud repeatedly across the margin to remove debris.

days; this almost always regains patient comfort. Most patients need to pulse dose a couple of times a year. It is a steroid-sparing and cost-effective approach. We are hopeful that lifitegrast may give us another option at this stage, pending FDA approval and clinical validation.

in a few cases if patients are not periodically checked for intraocular pressure spikes.

In summary, always inquire of patients about how their eyes feel; select a lipid-based artificial tear, get them on fish or flaxseed oil, consider

The importance of monitoring for potential steroid response, particularly in those patients who use a topical corticosteroid regularly or on pulse dosing, should not go unsaid. Patients have a tendency to become “comfortable” using topical corticosteroids, and a steroid response could lead to ocular hyperten-

a steroid eye drop for a month, and subsequently consider punctal plugs if the aforementioned treatments are not sufficient. Once there’s clinical improvement, be mindful of the need for long-lasting control.

Due to cost concerns, try to keep on hand coupons for all brand-name eye medicines. This will require the optometrist to actively reach out to the various drug companies to request that coupons be made available to them for the benefit of their patients. [www.GoodRx.com](http://www.GoodRx.com) is a resource that can help doctors find the least expensive sources in their areas. ■

- Nichols KK, Foulks GN, Bron AJ, et al. The international workshop on meibomian gland dysfunction: executive summary. *Invest Ophthalmol Vis Sci*. 2011 Mar 30;52(4):1922-9.
- Perez V, Pflugfelder S, Zhang S, et al. Lifitegrast, a novel integrin antagonist for treatment of dry eye disease. *Ocul Surf*. 2016 Epub Jan 22.
- Donnenfeld E, Sheppard JD, Holland EJ, et al. Prospective, multi-center, randomized controlled study on the effect of loteprednol etabonate on initiating therapy with cyclosporin A. Presented at the AAO Annual Meeting, 2007; New Orleans.
- Kim SJ, Flach AJ, Jampol LM. Nonsteroidal anti-inflammatory drugs in ophthalmology. *Surv Ophthalmol*. 2010 Mar-Apr;55(2):108-33.
- Sheppard JD, Torkildsen GL, Lonsdale JD, D’Ambrosio FA, et al. Lifitegrast ophthalmic solution 5.0% for treatment of dry eye disease: results of the OPUS-1 phase 3 study. *Ophthalmology*. 2014 Feb;121(2):475-83.
- Wang L, Bassiri M, Najafi R, et al. Hypochlorous acid as a potential wound care agent: part I. Stabilized hypochlorous acid: a component of the inorganic armamentarium of innate immunity. *J Burns Wounds*. 2007 Apr;6:e5.
- Kim HJ, Lee JG, Kang JW, et al. Effects of a low concentration hypochlorous acid nasal irrigation solution on bacteria, fungi, and virus. *Laryngoscope*. 2008 Oct;118(10):1862-7.
- Food and Drug Administration. Draft Guidance on Cyclosporine. June 2013. Available at: [www.fda.gov/downloads/drugs/guidancecomplianceregulatoryinformation/guidances/ucm358114.pdf](http://www.fda.gov/downloads/drugs/guidancecomplianceregulatoryinformation/guidances/ucm358114.pdf).



## FROM THE LITERATURE

### LONG-TERM PERSPECTIVE ON DRY EYE DISEASE

A study following about 700 patients over a decade of dry eye care suggests that “DED is not necessarily progressive over the long-term, and most men and women report no change or some level of improvement.”

- “Clinical tests in dry eye disease tend to have poor reproducibility, and symptoms and signs may fluctuate. Newer technologies such as in vivo confocal microscopy and tear osmolarity also have limitations.”
- “Even with therapy, dry eye disease tends to persist, but despite data supporting the importance of DED

as a public health problem, the long-term course of the disease is not yet well characterized.”

- “One of the most consistent correlates of worsening was a record of past severe symptoms. This finding is in line with the idea that patients who present with more severe symptoms early in the course of their disease are the ones who are most likely to experience a worsening, usually despite therapy.”

We fervently hope that some sort of intervention will soon be discovered or invented to help the masses who suffer with DED. In the meantime, there are rational approaches as outlined in this drug guide, that when properly applied, can be of significant help to many.

Lienert JP, Tarko L, Uchino M, et al. Long-term natural history of dry eye disease from the patient’s perspective. *Ophthalmology*. 2016 Feb;123(2):425-33.

# CLINICAL UPDATE ON THE NSAIDs

While oral nonsteroidals are heavily used in systemic medicine, topical ophthalmic NSAIDs have limited use in nonsurgical eye care.

The field of nonsteroidal anti-inflammatory drugs has many players. Older drugs have been reformulated and new drugs have come to market. The newest editions, Prolensa (bromfenac sodium 0.07%, Bausch + Lomb) and Ilevro (nepafenac 0.3%, Alcon), are the superstars of this class and need to be used only once daily. This should be a blessing to post-op cataract patients by reducing the intensity of their eye drop regimen.

While oral NSAIDs are heavily used in systemic medicine, topical ophthalmic NSAID use within nonsurgical eye care is relatively limited. The foundational perspective on this class of drugs is the acknowledgement that steroids reign supreme in inflammation control; topical NSAIDs are never an appropriate substitute when the clinical condition merits a topical corticosteroid.

NSAID use has much more applicability in perioperative care than in primary eye care; however, several clinical circumstances merit use of such a drug in order to enhance patient care.

## PHARMACOLOGY OF NSAIDS

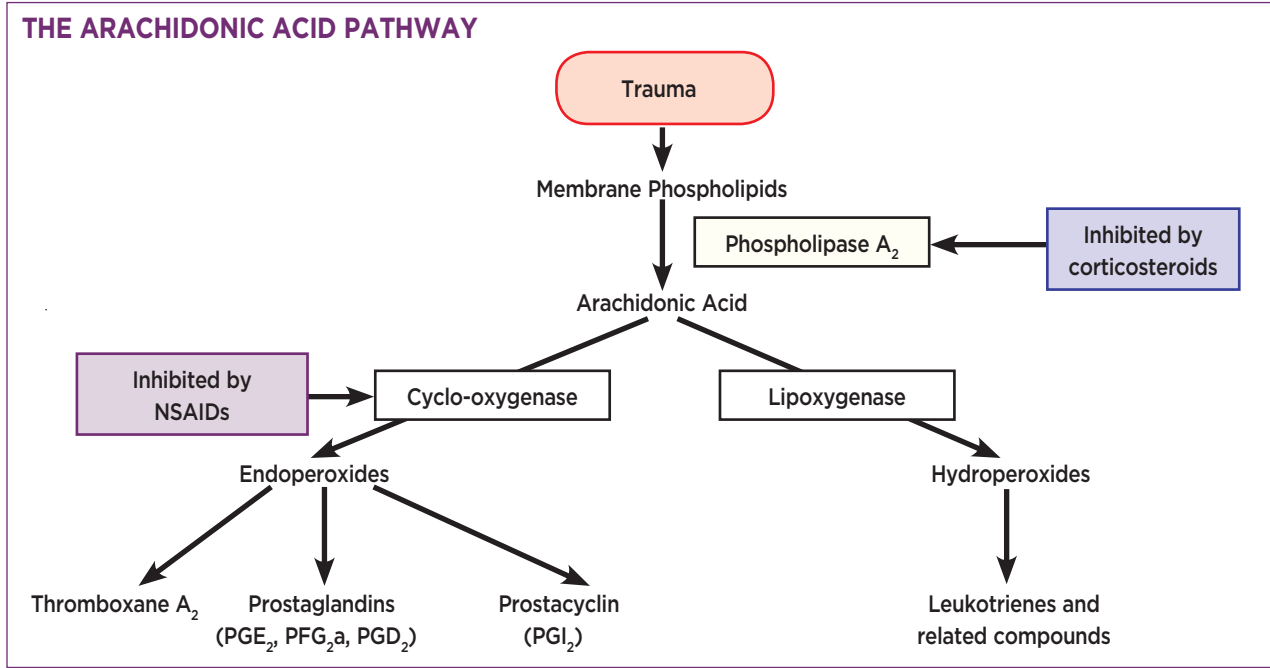
Let's first understand the pharmacology of NSAIDs. First of all, they don't directly reduce inflammation. Rather, they inhibit an enzyme along the synthetic pathway to the production of prostaglandins, which are powerful mediators of inflammation. As doctors, it is vital that we have knowledge of this particular pathway—the arachidonic acid cascade.

As you can see in the diagram (*"The Arachidonic Acid Pathway," page 21*), the origin substrate for inflammatory mediators is phospholipids released from cell membranes as a generic response to multiple causes of cellular microtrauma. Corticosteroids inhibit the conversion of these phospholipids to arachidonic acid (AA) by inhibiting the catalytic enzyme phospholipase A<sup>2</sup> early in this synthetic cascade.

Once AA is formed, two different enzymes convert it to either prostaglandin or leukotriene. Cyclooxygenase converts AA to prostaglandins, and lipoxygenase converts AA to leukotrienes. The key point here is that while NSAIDs inhibit the en-

## NONSTEROIDAL ANTI-INFLAMMATORIES

BRAND NAME	GENERIC NAME	MANUFACTURER	DOSAGE	PEDIATRIC USE	BOTTLE SIZE(S)
Acular LS	ketorolac tromethamine 0.4%	Allergan, and generic	QID	3 years	5ml
Acuvail	bromfenac 0.075%	Allergan	BID	N/A	unit-dose
Bromsite	bromfenac 0.075%	Sun Pharma	N/A	N/A	5ml
Ilevro	nepafenac 0.3%	Alcon	QD	10 years	1.7ml
Nevanac	nepafenac 0.1%	Alcon	TID	10 years	3ml
Prolensa	bromfenac 0.07%	Bausch + Lomb	QD	N/A	1.6ml, 3ml
Voltaren	diclofenac sodium 0.1%	Novartis, and generic	QID	N/A	2.5ml, 5ml



zymatic activity of cyclooxygenase, they have no effect on lipoxygenase, thereby allowing the production of leukotrienes to go unchecked.

For clinical perspective, remember the early days of photorefractive keratectomy where NSAIDs were initially used postoperatively? Patients experienced problems with white blood cell (leukocytic) corneal infiltrates until it was realized that steroids prevented their formation. Why? Because leukotrienes are chemotactic for leukocytes, for which NSAIDs do nothing—they only inhibit the synthesis of prostaglandins and have no activity against lipoxygenase-catalyzed production of leukotrienes. Because steroids work higher up in the AA synthetic pathway, they inhibit cyclo-

oxygenase and lipoxygenase, thus inhibiting production of prostaglandins and leukotrienes.

The AA pathway is more easily grasped by studying the diagram, which illustrates the processes we have just described. Once you have a clear understanding of the AA pathway, then you can prescribe with enhanced clinical authority and precision.

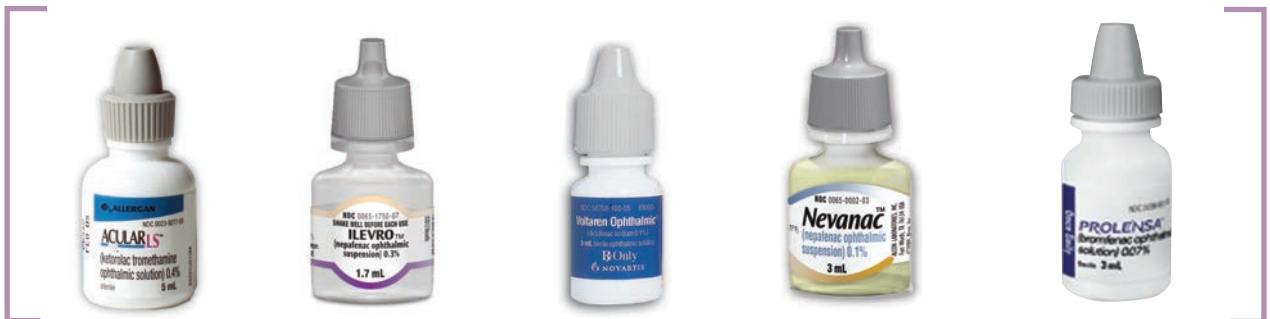Steroids and NSAIDs are thought to demonstrate some synergy, and therefore, might be beneficial used concurrently. For example, standard-of-care treatment of postoperative cystoid macular edema is usually treated with a potent corticosteroid, such as Durezol, and a topical NSAID (dosed at its FDA-approved dosing

frequency). However, this synergy is difficult to reconcile based on the dynamics of the AA cascade previously discussed. Perhaps the rapidity of onset and/or the degree of enzymatic inhibition may be considerations for explanation.

Contrarily, we find no literature supporting the use of both drug groups in the standard initial treatment of anterior uveitis. A great deal remains to be understood in how these drug classes modify tissue responses.

### ROLE OF TOPICAL NSAIDS

Compared to topical corticosteroids, NSAIDs play a limited role in primary eye care. Nonetheless, several situations demonstrate where NSAIDs





FROM THE LITERATURE

## UPDATE ON NSAIDs FOR CME

Cystoid macular edema, known academically as Irvine-Gass syndrome, is the most common cause of post-cataract surgery visual impairment. Are topical NSAIDs of clinically significant value in managing the small subset of postoperative patients who develop cystoid macular edema?

A seminal work addressing this issue appeared in *Ophthalmology* (November 2015).<sup>1</sup> Below are excerpts:

- Because many cases of CME are mild and resolve spontaneously, it remains unknown whether prophylactic NSAID treatment improves long-term visual outcomes. It also remains unclear whether prophylactic treatment prevents the onset of chronic CME (present >six months after surgery) or in some way decreases its severity.

- In conclusion, there is a lack of level I evidence that supports the long-term visual benefit of NSAID therapy when applied solely or in combination with corticosteroid therapy to prevent vision loss resulting from CME after cataract surgery. The implication that the combined effect of NSAID and corticosteroid exceeds the additive effect of these drugs is not supported by the literature. Dosing of NSAIDs before surgery seems to hasten visual recovery after cataract surgery, but does not affect long-term visual outcomes.

Another article, from the *American Journal of Ophthalmology* (November 2015), gave these observations:<sup>2</sup>

- In non-diabetic patients, it was found that topical

NSAIDs significantly reduced the odds of developing cystoid macular edema, as compared to topical corticosteroids.

- Approximately 0% to 6% of non-diabetic subjects develop visual complaints and suffer from clinically significant macular edema. In contrast, incidence rates of clinically significant macular edema are up to 56% in diabetic patients with mild to moderate nonproliferative diabetic retinopathy and no cystoid macular edema preoperatively.

- Results of this meta-analysis show that topical NSAIDs significantly reduced the odds of developing CME, as compared to topical corticosteroids in non-diabetic and mixed populations. Furthermore, a combination of topical NSAIDs and corticosteroids significantly reduced the odds of developing cystoid macular edema in non-diabetic and diabetic patients, as compared to topical corticosteroids in a single drug treatment. Based on an indirect treatment comparison, no difference could be found between topical combination treatment and topical NSAIDs in non-diabetic patients.

As can be seen from these articles, there is no definitive consensus yet on the best therapeutic intervention to diminish or prevent cystoid macular edema. We anticipate that use of NSAIDs and steroids in contemporary cataract care will continue unabated for the foreseeable future.

1. Kim SJ, Schoenberger SD, Thorne JE, et al. Topical nonsteroidal anti-inflammatory drugs and cataract surgery. *Ophthalmology*. 2015 Nov;122(11):2159-68.

2. Wielders LHP, Lambermont VA, Schouten J, et al. Prevention of cystoid macular edema after cataract surgery in nondiabetic and diabetic patients: A systematic review and meta-analysis. *Am J Ophthalmol*. 2015 Nov;160(5):968-981.

can be beneficial. (See “Consider an NSAID For...,” page 23.)

However, be aware that topical and systemic NSAIDs differ some-

what in effect. Systemic NSAIDs are true to their name and do indeed render a significant anti-inflammatory effect, whereas topical NSAIDs have

their forté in ocular surface pain amelioration and provide only limited activity against inflammation.

Diclofenac (Voltaren 0.1%, Novartis) and ketorolac (Acular LS 0.4%, Allergan) have historically been the standard bearers of topical NSAID care. Both are used QID and are largely clinical equivalents. One study that compared ketorolac and diclofenac head to head concluded: “The decrease in corneal sensitivity in normal human corneas is more pronounced and longer lasting with diclofenac than with ketorolac.”<sup>1</sup>

A modification of ketorolac is the development of a 0.45% concentration: Acuvail (Allergan) comes as a preservative-free unit-dose indicated for perioperative use BID one day prior to cataract surgery, and is continued for two weeks postoperatively.

The original formulation of ophthalmic ketorolac (Acular) was a 0.5%

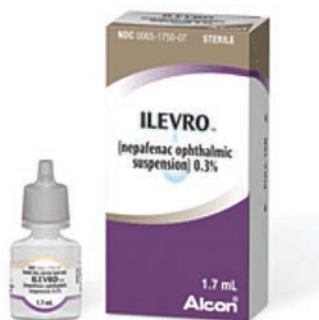## NEW NSAID APPROVED WITH CATARACT SURGERY INDICATION

In early April 2016, the FDA approved BromSite (bromfenac 0.075% ophthalmic solution, Sun Pharma), the first NSAID with the specific indication for preventing ocular pain in patients undergoing cataract surgery. Like other NSAIDs, it's also indicated for treating postoperative inflammation.

BromSite achieves its low 0.075% concentration due to its DuraSite delivery vehicle (developed by InSite Vision), which is believed to extend the drug's residence time on the ocular surface. (Sun Pharma acquired InSite Vision in November 2015.)

In two Phase III clinical trials, a greater number of patients treated with BromSite were pain-free at one day post-op (77% and 82%) compared with those given only the vehicle (48% and 62%). Also, more patients given BromSite were free of inflammation at 15 days post-cataract surgery compared with patients given only the vehicle. Sun Pharma expects BromSite to come to market in the second half of 2016.

InSite Vision Announces FDA Acceptance of NDA Filing for BromSite (0.075% bromfenac). Available at: [www.businesswire.com/news/home/20150817006205/en/InSite-Vision-Announces-FDA-Acceptance-NDA-Filing](http://www.businesswire.com/news/home/20150817006205/en/InSite-Vision-Announces-FDA-Acceptance-NDA-Filing) (last accessed April 25, 2016).



solution, but marked stinging upon instillation was its Achilles' heel. The drug was reformulated several years ago to a 0.4% solution (Acular LS) and is now quite tolerable.

Following these, two more NSAIDs came to market. They were Bromday (bromfenac ophthalmic solution 0.09%, Bausch + Lomb) and Nevanac (nepafenac ophthalmic suspension 0.1%, Alcon).

Bromday is dosed once daily and is well tolerated; however, be aware that Bromday was discontinued in 2013. Be aware that any product containing bromfenac should not be used for a patient with a sulfite allergy.

Nevanac, an ophthalmic suspension, is the first available NSAID product. Upon instillation, nepafenac is enzymatically converted to amfenac sodium, which, like all NSAIDs, inhibits cyclooxygenase. It is dosed three times a day.

### NEWER NSAIDS

In recent years, newer generations of these products came to market. Prolensa (bromfenac 0.07%, Bausch + Lomb) potentiates penetration of the bromfenac molecule, thereby allowing for a decreased concentration (0.07%) while maintaining once-daily dosing. Prolensa contains 22% less drug than Bromday's 0.09% concentration, and its pH has been lowered from 8.3 to 7.8. This pH modification is what enables the lower concentration of Prolensa to clinically perform as well as Bromday. It has 0.005% BAK as the preservative and comes in two sizes: 1.6ml and 3ml,

### KEEP IN MIND

- Corneal abrasions
- Just before and just after in-office Betadine 5% sterile ophthalmic prep solution treatment for acute, symptomatic EKC
- Post-foreign body removal
- Adapting to RGP contact lenses
- Post-anterior stromal puncture procedure
- Post-PKP, or any surface-disruptive laser procedure
- Treating and/or preventing cystoid macular edema
- Adapting to punctal plugs
- Allergic conjunctivitis
- Supplement to steroids in treating recalcitrant uveitis
- Some cases of keratitis-related photophobia
- Post-cataract surgery care
- Supplemental to oral NSAIDs in treating scleritis
- Treating and/or preventing inflamed pterygia and pingueculae
- Quick ophthalmoscopy to rule out concurrent intraocular disease

both in 7.5ml bottles. Because Prolensa is a solution and not a suspension, shaking the bottle before use is not required.

Ilevro (nepafenac 0.3%, Alcon) achieves once-daily dosing by increasing the concentration from Nevanac (nepafenac 0.1%). Ilevro comes in a 1.7ml bottle, whereas Nevanac is dispensed as 3ml in a 4ml bottle. The innovative bottle design of Ilevro is identical to the bottle used by Travatan Z. Because Ilevro is a suspension, the bottle must be shaken before the drop is instilled. Its pediatric indication is down to age 10.

Both these new formulations are FDA-approved to treat pain and inflammation associated with cataract surgery. Both are dosed once daily: the day before surgery, the day of surgery, and for 14 days postsurgically. Both are indicated for pregnancy category C, preserved with 0.005% BAK and have pHs close to 7.

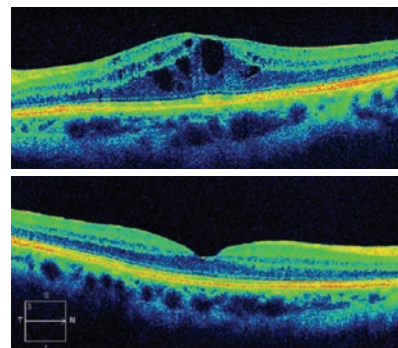
All of these NSAID drugs are generally approved by the FDA for treating postoperative inflammation, and as such, will be used much more in a surgical context. Ketorolac 0.5% is

### CONSIDER AN NSAID FOR...

*These are most common conditions for which topical NSAIDs can play an adjunctive beneficial role.*

also approved to treat ocular allergy, along with a number of other applicable uses for NSAIDs relevant to primary eye care, as enumerated above.

Because of the rare, but real, potential for corneal toxicity and melting, use these drugs cautiously when there is preexisting corneal epithelial compromise. As a general rule, we never prescribe any topical NSAID for use beyond two weeks—with the exception of cystoid macular edema, which we treat with a topical NSAID for a month concurrently with a potent steroid, such as Durezol. While steroids are often initially dosed as frequently



Cystoid macular edema before (top) and after (bottom) therapy.



FROM THE  
LITERATURE

## ESSENTIAL LITERATURE ON NSAIDs

If you want the ultimate review of NSAIDs, we urge you to read “Nonsteroidal Anti-inflammatory Drugs in Ophthalmology,” by Stephen J. Kim, MD, Allan J. Flach, MD, and Lee M. Jampol, MD, in *Survey of Ophthalmology*, March-April 2010. It is excellent. Some quotes (or in-context paraphrases) from this article, and our commentary (indicated in purple), follow:

- “NSAIDs do not inhibit lipoxygenase (LPO) and thus do not typically prevent generation of leukotrienes. This may explain, in part, their decreased anti-inflammatory effects compared to corticosteroids, which inhibit both LPO and COX (cyclooxygenase). However, celecoxib (Celebrex) and diclofenac (Voltaren) are notable exceptions and inhibit LPO by direct and indirect means, respectively. In addition, NSAIDs appear to have anti-inflammatory and anti-angiogenic effects independent of their inhibition of COX. Several reports suggest that ketorolac is the most potent inhibitor of COX-1, while both bromfenac and amfenac have staked the claim as being the most potent inhibitors of COX-2.

“The clinical importance of selective COX-1 and COX-2 inhibition for ocular disease remains to be established.”

*The prostaglandins produced via COX-1 are physiologic in their action, whereas the prostaglandins produced from the upregulation of COX-2 result in pathologic expression of pain and inflammation.*

- “There is good evidence that topical NSAIDs may be used in place of, or in addition to, topical corticosteroids after cataract surgery to avoid excessive inflammation and to improve visual acuity. Although none of the studies reviewed by the FDA used topical NSAIDs more than 24 hours before cataract surgery, well-designed studies suggest potential benefit from preoperative dosing regimens of up to three days. Furthermore, several clinical studies have

reported that concurrent administration of NSAIDs and corticosteroids results in additive effects.

“At present, there is no evidence to suggest one topical NSAID treatment is better than another in controlling post-operative inflammation.”

- “CME remains the most common cause of vision loss after cataract surgery. Despite its significance, the pathogenesis of this syndrome, and its relationship to and its associations with CME in other diseases, is not completely understood.

“Systemic NSAIDs provide insufficient drug levels to inhibit prostaglandin production in the anterior segment, especially when compared to topical administration.

“The true incidence of CME following cataract surgery is not precisely known. Despite this continued uncertainty, recent studies have reported incidences following small-incision cataract surgery as high as 9% to 19% using fluorescein angiography, and 41% as measured by OCT.

“It has long been recognized that the natural history of CME usually includes spontaneous resolution.

“Although there is no FDA-approved treatment for the prevention or treatment of CME following cataract surgery, an extensive review of the world literature ... concluded that prevention and treatment of CME with NSAIDs is beneficial ... Available evidence suggests that topical NSAIDs may prevent and treat CME when used alone or concurrently with corticosteroids.”

*This is another example of where the scientific literature trumps FDA guidelines. “Off-label” use of medicines is becoming more and more commonplace, so don’t let other considerations override sound, rational and prudent use of a helpful drug.*

- “Although no other topical NSAID has been approved for allergic conjunctivitis besides ketorolac, there are studies suggesting that 0.1% diclofenac and 0.09% bromfenac may also be effective.

as hourly for a few days, we recommend that NSAID use not exceed the FDA-approved dosing frequency.

## NOTES ON ORAL NSAIDs

Cyclooxygenase (COX) is the enzyme by which arachidonic acid is metabolized into prostaglandins. Two sub-species of cyclooxygenase are: COX-1 and COX-2.

COX-1 is a constitutive enzyme that synthesizes prostaglandins, which regulate physiological functions such as in the GI tract, kidneys, platelets and vascular endothelium.

COX-2, on the other hand, is an

inducible enzyme, which is primarily activated during inflammatory tissue assaults. As a result, COX-2 inhibitors created great excitement when they came to market years ago because they were purported to address inflammation while sparing the physiological prostaglandins, specifically sparing the GI tract from NSAID toxicity.

Unfortunately, a couple of these products, Vioxx (rofecoxib) and Bextra (valdecoxib), were thought to significantly increase the risk of heart attack and stroke, and were removed from the market.<sup>2</sup> Celebrex (celecoxib) is now used more conservatively, but

appears to be less likely to cause such untoward events. All three of these drugs were FDA-approved around the year 2000.

We rarely prescribe oral NSAIDs, but do occasionally use Celebrex 100mg or 200mg BID to help our patients in whom we have difficulty tapering off oral prednisone when treating orbital pseudotumor, stubborn uveitis or scleritis. For example, if the anterior uveitis tends to rebound when the oral prednisone is tapered below 20mg per day, we have been successful using Celebrex along with prednisolone 20mg for a week, then



“Studies have reported that ketorolac 0.5%, diclofenac 0.1% and bromfenac 0.09% are all effective in treating vernal conjunctivitis.”

*We use a potent topical corticosteroid to gain full control of the vernal conjunctivitis first, and then perhaps try a topical NSAID to maintain that control. One could also consider an antihistamine-mast cell stabilizer, or continue with Lotemax gel once to twice daily to keep the condition suppressed.*

- “Whereas topical corticosteroids are frequently helpful in relieving episcleritis, topical NSAIDs appear to be less effective. Systemic NSAIDs are of value in those unusual cases where topical treatments are ineffective.”

*This is an excellent reminder that when significant inflammation is present, it is a steroid that is needed—not an inferior quasi-anti-inflammatory agent.*

- “Regarding scleritis, although topical NSAIDs are not effective, systemic NSAIDs are used as first-line agents. Although many NSAIDs may be effective, indomethacin at 25mg to 50mg three times daily is most commonly used ... A recent report indicated that the COX-2 selective NSAID, celecoxib, at a daily dosage ranging from 200 to 800mg Q day was effective in controlling diffuse anterior scleritis in 92% of patients without producing any gastrointestinal effects.”

- “There is also evidence that NSAIDs are useful in the treatment of inflamed pingueculae and pterygia.”

*We always use a topical corticosteroid first to get inflammation controlled, then consider an NSAID to help keep the condition under control. We typically just maintain Lotemax gel once or twice a daily for most of these patients.*

- “One in seven Americans receives a prescription for orally administered NSAIDs each year.”

- “The most well known side effects accompanying systemic NSAID use relate to the GI and central nervous system ... Often the GI toxicity can be partially ameliorated by adding an H<sub>2</sub> receptor antagonist, proton pump inhibitor or

prostaglandin analog; however, many patients will require discontinuation of the medicine.”

- “A recent prospective, randomized, placebo-controlled trial observed no adverse events or changes in liver chemistries in a large number of patients treated twice daily for 14 days with topical bromfenac. The off-label use of topical NSAIDs for durations longer than this is common, and clinicians should be vigilant for potential systemic toxicity. In addition, because eyelid closure and nasolacrimal occlusion can decrease systemic absorption of topically applied medications by almost 70%, explaining these techniques to all patients seems prudent.”

- “At present, there is no evidence that one NSAID is less toxic than another.

“The more than two dozen cases of corneal perforations reported with the introduction of topical corticosteroids over 30 years ago were likely related to improper clinical use and patient follow-up. Thus, many topical medications have the potential for toxicity if unmonitored or used inappropriately.”

*Note that “over 30 years ago,” it was not doctors of optometry who performed “improper clinical use and patient follow up.”*

- “Corneal perforations and melts have been reported with the use of topical NSAIDs. Therefore, the routine use of topical NSAIDs in dry eye patients may increase the risk of these adverse events.”

However, “a definite link between NSAID use and corneal melt remains tenuous. Application of topical NSAIDs for reasonable lengths of time in appropriate patients with proper monitoring appears safe. There is, however, evidence of the continued misuse of these medications.”

*As can be seen, there are occasions when a topical NSAID can be useful; however, these uses are dramatically cast in the shadow of corticosteroids. Always keep in mind that the rational, scientifically sound use of a drug “off label” may be in the very best interests of a patient.*

10mg for a week or two, while concurrently using Celebrex for four to six weeks to facilitate the discontinuation of the oral prednisone. Aggressive use of Durezol and therapeutic cycloplegia is foundational to these oral supplementary therapies.

Risk of peptic ulcer disease is increased when using both oral prednisone and an oral NSAID (including Celebrex), so we would likely also prescribe a proton pump inhibitor, such as OTC Prilosec or Prevacid 20mg once daily when we are using such dual therapy. A histamine H<sub>2</sub> receptor blocker such as Tagamet

(cimetadine) similarly protects the gastrointestinal tissues.

With most oral NSAIDs, clinicians should pay heed to the “black box” warning of cardiovascular risk. The FDA is strengthening its existing warning in prescription drug labels and OTC drug facts labels to indicate that oral NSAIDs can increase the chance of a heart attack or stroke. As well, oral NSAIDs can produce hypoglycemia in type 2 diabetics by drug interaction and can decrease renal function in susceptible patients.

In summary, NSAIDs have several off-label uses within the context of

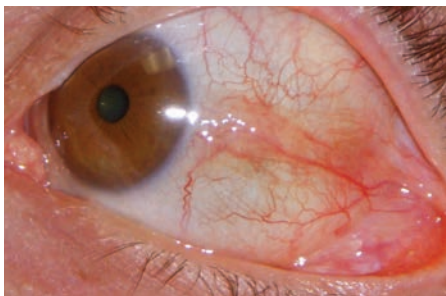
primary eye care. Their main use is in the prevention or treatment of cataract surgery-related cystoid macular edema concurrent with a potent corticosteroid. Topical formulations are far more commonly used in eye care than orals, but the latter do play an important role in tapering patients off oral steroid therapy when needed. ■

1. Seitz B, Sorken K, LaBree LD, et al. Corneal sensitivity and burning sensation: comparing topical ketorolac and diclofenac. Arch Ophthalmol. 1996 Aug;114(8):921-4.

2. US FDA website. FDA Strengthens Warning of Heart Attack and Stroke Risk for Non-Steroidal Anti-Inflammatory Drugs. 2015 July 21. Available at: [www.fda.gov/ForConsumers/ConsumerUpdates/ucm453610.htm](http://www.fda.gov/ForConsumers/ConsumerUpdates/ucm453610.htm) (accessed April 7, 2016).

# UNLEASH THE POWER OF CORTICOSTEROIDS

Topical steroids are the most essential and effective medicines in the treatment of any ocular inflammation.



Treat pingueculae like this one with a topical steroid, then keep the ocular surface properly lubricated to prevent further inflammation.

With more than 70 combined years of intensive clinical care under our belts, we feel we have developed a mature understanding of the clinical reality of corticosteroids.

It is distressing, and ultimately counterproductive to patient care, that the use of steroids is sometimes portrayed in the classroom, at lectures and in the literature as “dangerous.” Steroids are highly effective at treating nearly all aspects of ocular surface and intraocular inflammation; they are extremely safe when used appropriately and, in our clinical experience, rarely cause complications, particularly when used for less than a month. Increased IOP is the most annoying serious adverse effect, but this subsides with taper and cessation of therapy.

Of course, there is always the rare patient who does not respond to therapy as anticipated—and may even worsen. For that reason, we always end our patient treatment encounters with a statement like: “This medicine should help you to be much better in just a couple of days. However, if your eye(s) do not improve, or if you experience any worsening, be sure to let me see you right away.” We say this with confidence and to make sure patients know we have a keen interest in their well-being.

With this enlightened and clinically realistic background, let’s now look at this most helpful class of ophthalmic medicines.

## MAXIMUM EFFICACY STEROIDS

The key to success in suppressing inflammation is to select an appropriate topical steroid medicine and have the patient use it frequently until control is achieved, then tapering can begin as indicated.



### KEEP IN MIND

#### RELATIVE CLINICAL EFFICACY OF TOPICAL STEROIDS

Here, based on our clinical experience and the comparative information we have available, we rate the relative efficacy of the topical steroids, starting with the most efficacious:

1. Difluprednate 0.05%
2. Prednisolone acetate 1%
3. Loteprednol 0.5%
4. Rimexolone 1%
5. Dexamethasone 0.1%
6. Fluorometholone acetate 0.1%
7. Fluorometholone alcohol 0.1%
8. Loteprednol 0.2%
9. Prednisolone 0.125%
10. Hydrocortisone 1%

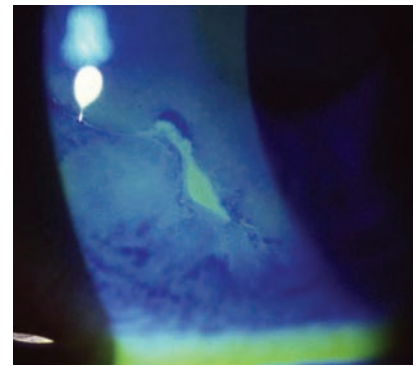
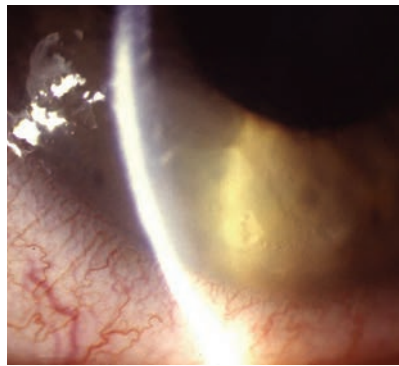
The two most efficacious topical ophthalmic corticosteroids in our experience are Durezol emulsion (difluprednate 0.05%, Alcon) and Pred Forte (prednisolone acetate 1%, Allergan)—but not generic prednisolone acetate. (More on this below.)

- **Durezol.** This drug is an emulsion and does not need to be shaken before instillation. We use it as our “big gun” to treat advanced cases of iritis and episcleritis. Durezol’s longer duration of action permits less frequent dosing than with prednisolone formulations, and provides efficacy.<sup>1</sup> So, typically we dose it every two hours initially, rather than hourly.

But along with Durezol’s increased efficacy comes an increased risk of significant IOP elevation, especially in children.<sup>2</sup> So, be sure to monitor IOP at follow-up visits.

- **Pred Forte.** Prednisolone acetate 1% also has good anti-inflammatory efficacy.<sup>3</sup> Pred Forte is a workhorse and, like Durezol, is used primarily to treat significant cases of anterior uveitis and episcleritis, and other severe ocular inflammatory conditions. Because it is a suspension, instruct your patients to shake it well prior to each instillation.

Some pharmacists will dispense generic prednisolone acetate, even when you have specified “Dispense as Written” on the Rx. Although the generics are considerably less



**LEFT:** There is a large epithelial defect inferiorly. Note that the anterior two thirds of the cornea is heavily infiltrated, which nicely explains why the overlying epithelium is secondarily compromised. This is a non-infectious epithelial defect, most likely as a result of epithelial demise secondary to staphylococcal exotoxins. This defect is near the limbus, which is very fertile soil for inflammatory events. The limbal area has an abundance of blood vessels that carry immune weaponry of both humeral immunity (antibodies) and cellular immunity (leukocytes). This explains why most all events at or near the limbus are inflammatory in nature, and therefore why corticosteroid suppression is so essential to hasten resolution of tissue compromise.

**RIGHT:** After just two days of an antibiotic/steroid combination, the epithelial defect is healing rapidly. The antibiotic is for the benefit of the doctor; the steroid is for the benefit of the patient! It is vital to know *why* there is epithelial compromise. If such is a result of anterior stromal inflammation (as evidenced by the rather profound anterior corneal infiltration as seen in optic section), then a steroid is the drug best suited to help restore these tissues.

expensive, they are also less effective.<sup>4</sup> When the maximum effect is required, nothing surpasses brand-name Pred Forte or Durezol.

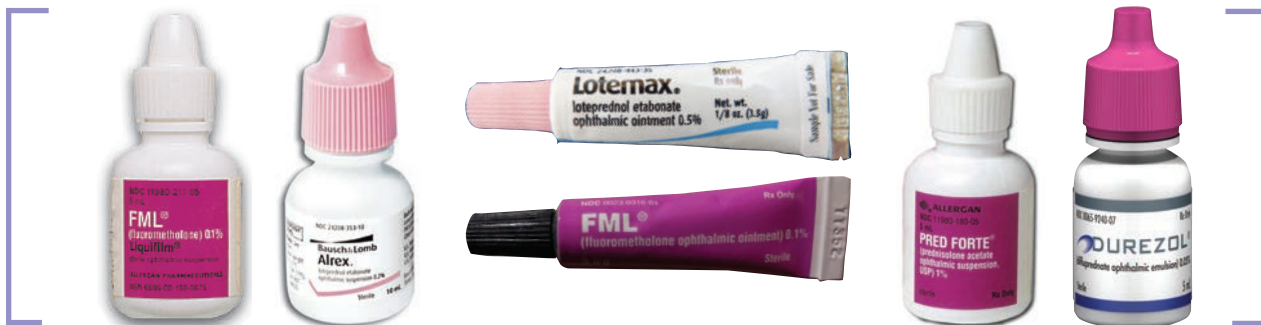### HIGH EFFICACY STEROIDS

Next in clinical efficacy are Lotemax gel (loteprednol 0.5%, Bausch + Lomb), generic prednisolone sodium

phosphate 1% solution (original brand name Inflamase Forte), and generic prednisolone acetate 1%. Dexamethasone, either the solution or suspension form, is also in this category.

- **Lotemax gel.** This non-settling eye drop does not require shaking before instillation. Don’t be confused because it’s called a “gel”—when dispensed

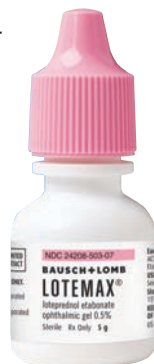TOPICAL CORTICOSTEROID DRUGS				
BRAND NAME	GENERIC NAME	MANUFACTURER	PREPARATION	BOTTLE/TUBE
<b>Maximum Strength Steroids</b>				
Durezol	difluprednate 0.05%	Alcon	emulsion	5ml
Lotemax gel	loteprednol etabonate 0.5%	Bausch + Lomb	gel-drops	5g
Lotemax ointment	loteprednol etabonate 0.5%	Bausch + Lomb	ointment	3.5g
Pred Forte	prednisolone acetate 1%	Allergan + Generic	suspension	5ml, 10ml, 15ml
generic prednisolone sodium phosphate	prednisolone sodium phosphate 1%	generic	solution	5ml, 10ml, 15ml
Vexol	rimexolone 1%	Alcon	suspension	5ml, 10ml
<b>Moderate and Lesser Strength Steroids</b>				
Alrex	loteprednol etabonate 0.2%	Bausch + Lomb	suspension	5ml, 10ml
Flarex	fluorometholone acetate 0.1%	Alcon	suspension	5ml, 10ml
FML	fluorometholone alcohol 0.1%	Allergan + Generic	suspension	5ml, 10ml, 15ml
FML ointment	fluorometholone alcohol 0.1%	Allergan	ointment	3.5g
Pred Mild	prednisolone acetate 0.12%	Allergan	suspension	5ml, 10ml



### LOTEMAX GEL VS. LOTEMAX OINTMENT

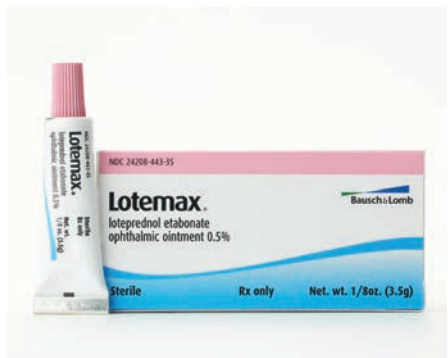Patients, practitioners and pharmacists may mix up these two medicines, so let's set the record straight.

- **Lotemax gel.** Though called a gel, this comes in a dropper bottle, like a solution. However, inside the bottle it is indeed a highly viscous, semisolid gel formulation. But, through a process called adaptive viscosity, it becomes a liquid when squeezed out of the dropper. And upon instillation in the eye, the formulation loses its gel structure altogether as the polycarbophil polymer interacts with the electrolytes in tears. Still, the drop is rather thick upon instillation, and will cause a moment of initial blur until the gel fully converts into a liquid. We advise patients to allow the drop to spread out on the ocular surface for four to five seconds before blinking, so that the initial blink does not displace the drop onto the eyelid.



Because of the nature of this unique gel, the steroid does not settle out of the vehicle, so it does not require shaking. (It is best to tip the bottle back and forth once to make sure the drug enters the tip of the dropper prior to instillation, but no actual shaking is necessary.) Also, unlike suspensions, this delivery system provides a perfectly uniform dose at every instillation.<sup>1</sup>

- **Lotemax ointment.**<sup>2</sup> This preparation comes in a 3.5g tube and contains inactive ingredients of white petrolatum and mineral oil. Because it is an ester-based corticosteroid and also because it is a preservative-free preparation, it may provide a safety advantage over fluorometholone ointment. Lotemax ointment is indicated for the treatment of postoperative inflammation and pain, but is also applicable in many other cases in which an ointment is useful for suppression of inflammation.



1. Marlowe ZT, Davio SR. Dose uniformity of loteprednol etabonate ophthalmic gel (0.5%) compared with branded and generic prednisolone acetate ophthalmic suspension (1%). *Clin Ophthalmol.* 2014;8:23-9.

2. Comstock TL, Paterno MR, Singh A, et al. Safety and efficacy of loteprednol etabonate ophthalmic ointment 0.5% for the treatment of inflammation and pain following cataract surgery. *Clin Ophthalmol.* 2011;5:177-86.

from its dropper bottle, it becomes a viscous liquid (see “*Lotemax Gel vs. Lotemax Ointment*,” left).

We regularly often use Lotemax gel as an off-label treatment for our dry eye patients, but we also use it to treat many other chronic, recurrent, inflammatory conditions such as stromal herpes simplex keratitis, Thygeson’s SPK, uveitis, inflamed pingueculae and pterygia, etc.

While loteprednol may not be quite as efficacious as prednisolone and Durezol, it has significantly lower propensity to cause the unwanted side effects of subcapsular cataracts and increased IOP. In Phase III studies, for instance, only two out of 409 patients on Lotemax gel had an increase in intraocular pressure greater than 10mm Hg.<sup>5</sup> In addition, loteprednol 0.5% suspension was shown to be as effective as prednisolone acetate for post-op cataract surgery inflammation, and with less effect on IOP.<sup>6</sup>

- **Prednisolone sodium phosphate 1%.** This generic steroid is an excellent choice when a potent, relatively inexpensive steroid is needed. Because this is a solution, it does not require shaking and may be an especially good choice for older people with arthropathies for whom shaking a bottle can be a challenge. It’s also good for soft contact lens wearers because it won’t precipitate on the lens as much as other drops.

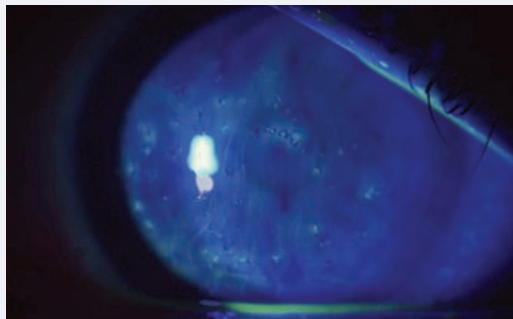
- **Prednisolone acetate 1%.** Generic prednisolone acetate suspension is a reasonable choice for mild to moderate acute inflammatory conditions, especially if cost is a concern—but not



## OPHTHALMIC MYTHS: STEROIDS

**Myth Never use a steroid (even combined with an antibiotic) on a cornea with a staining epithelial defect.**

*Our Take* We have encountered numerous epithelial defects over the years that were non-healing until we added a steroid that quelled the corneal inflammation preventing re-epithelialization. The nature and cause of the epithelial defect must be understood in order to properly select therapeutic intervention. If the epithelial defect is present as a result of subepithelial inflammation, as evidenced by leukocytic anterior stromal disease, then adding a steroid to suppress the underlying inflammatory process can promote re-epithelialization. We know that inflammation and superficial punctate keratitis commonly coexist in dry eye disease, yet the proper application of a steroid can help restore and enhance the integrity of the epithelial tissues.



**A mild steroid will suffice for Thygeson's superficial punctate keratopathy.**

**Myth Steroids should never be used for more than a month.**

*Our Take* There are three conditions in which a topical steroid is commonly used daily for a lifetime: corneal transplants, chronic uveitis and chronic herpetic stromal disease. We have several patients in whom a drop of 0.5% loteprednol is the least frequent dosage that keeps them comfortable with their dry eye disease. We have never had a single problem with this protracted, low-dose approach.

**Myth Never use a steroid eye drop on top of a soft contact lens.**

*Our Take* There are those stubborn patients who simply will not abandon contact lens wear in the face of symptomatic giant papillary conjunctivitis. We reluctantly, but successfully, have had to use a steroid eye drop (loteprednol is our clear favorite here) four times a day for a week or two, then twice daily for an additional week or two, to properly care for such patients. When Dr. Jimmy Bartlett was doing his famed GPC studies, loteprednol drops were used four times daily right on top of dirty soft contact lenses without incident.<sup>1</sup> This does not in any way surprise us. We always try to put the patients in a daily disposable soft contact lens during and after the acute treatment.

**Myth Use steroids with great caution because they can cause glaucoma and cataracts.**

*Our Take* Well, contact lenses can cause corneal ulcers, an extremely serious consequence of lens wear, yet that doesn't seem to halt the use of these wonderful devices in a wholesale manner in the daily practice of optometry. First, steroids, even ester-based steroids, can increase intraocular pressure (usually by less than 10mm Hg), which reverts to baseline upon discontinuation of the steroid drop. For iatrogenic-increased IOP to be allowed to progress to glaucoma (which we have never seen happen) would be egregious. No doubt, this has occurred through patient, pharmacy or doctor incompetence in appropriate patient management, but it is fully preventable.

Regarding posterior subcapsular cataracts, we are unaware of a single case report of cataract formation resulting from the use of loteprednol. Cataract formation would certainly be much more common with the use of older, traditional, ketone-based steroids. We have seen a case of bilateral PSC in a 35-year-old man who used 10 bottles of Tobradex over the span of a year for treatment of allergies, as prescribed by his primary care physician; but a knowledgeable, competent eye doctor would never prescribe in such a manner. The physician, pharmacist and patient were all negligent in this case. The patient should have been asked by his physician or pharmacist about this approach, or perhaps he should have read the package insert himself.

**Myth Oral prednisone should be used with extreme care, as it can have a multitude of side effects.**

*Our Take* This is certainly true for long-term use; however, for short-term use (a few days), this statement is simply false. We have prescribed oral prednisone regularly over our careers with excellent success and no therapeutic "misadventures." The occasional patient might report the prednisone made them jittery or that sleep was difficult, but the index condition was cured. The typical dose is 40mg for three to seven days, then stop. No tapering is needed with such short-term use.

1. Bartlett JD, Howes JF, Ghormley NR, et al. Safety and efficacy of loteprednol etabonate for treatment of papillae in contact lens-associated giant papillary conjunctivitis. *Curr Eye Res.* 1993 Apr;12(4):313-21.



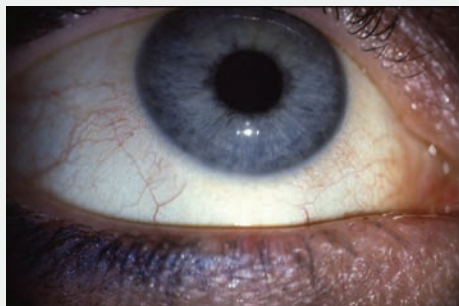FROM THE LITERATURE

## TOPICAL STEROIDS TREAT DRY EYE DISEASE

In our 2015 *Drug Guide*, we reported on a study showing the benefit of topical loteprednol (used off label) in caring for patients with dry eye disease (DED). Another study, published in *Ophthalmology* (January 2016), found, unsurprisingly, a similar effect using fluorometholone 0.1%.<sup>1</sup> The following are excerpts from this randomized clinical trial:

- An important factor contributing to the increased prevalence of DED, and certainly making it a worse problem, is the growing proportion of the population exposed to so-called adverse environments or desiccating stress conditions. We are currently staying longer within artificially created environments, such as office buildings, shopping malls, air-conditioned vehicles and even households. These environments are characterized by low humidity, high temperatures and draftiness—all conditions that cause tear film alterations that usually worsen DED. For many DED patients, these conditions are unbearable. In addition, the number of users of visual display terminals (including tablets and smart phones) and the amount of time spent using them also have increased dramatically. These information technology devices reduce blink rate, causing tear film evaporation that can worsen DED signs and symptoms further.

- Even at low severity level two, anti-inflammatory therapy is indicated, including topical steroids that have been shown to be effective in several studies and clinical trials ... Consequently, the main goal of the



Note the scant tear lake in this patient.

recent clinical trial was not only to assess the clinical efficacy of a three-week fluorometholone 0.1% therapy in DED patients, but more importantly, to determine if this therapy could ameliorate the expected worsening of the ocular surface after exposure to a desiccating stress set in a controlled environmental laboratory.

- Patients randomly received one drop four times daily of either topical 0.1% fluorometholone (FML group) or topical polyvinyl alcohol (PA group) for 22 days ... Liquifilm Tears was selected as the control treatment because it is the vehicle used in fluorometholone.

- No adverse events or treatment-related adverse reactions were observed throughout the study ... In particular, there were no significant changes in IOP and no signs of corneal epithelial healing-related problems or secondary infections as potential side effects from steroid use.

- The FML group, at the end of the study, experienced significant improvement in high- and low-contrast best-corrected visual acuity. In contrast, the control group experienced no change.

- This clinical trial evaluated the efficacy of topical fluorometholone 0.1% in preventing the exacerbation of DED signs

and symptoms that patients experience when exposed to adverse environmental desiccating stress ... Findings confirm the efficacy of topical corticosteroids as a short-term ( $\leq 4$  weeks) DED treatment, as previously shown by other research groups.

- Corticosteroids are among the most effective agents used to treat noninfectious inflammatory diseases, especially those mediated by the immune system. They reduce cel-

in the setting of advanced iritis and episcleritis, as discussed above.

## MODERATE EFFICACY CORTICOSTEROIDS

Moderate efficacy steroids in common use are fluorometholone 0.1% suspension and Alrex (loteprednol 0.2%, Bausch + Lomb) suspension, both of which must be shaken prior to instillation.

- **Fluorometholone 0.1%.** There are two derivatives of fluorometholone 0.1% suspension—the alcohol (FML, Allergan and generic) and the acetate

(Flarex and Alcon). The acetate moiety gives the fluorometholone molecules some additional anti-inflammatory effectiveness over the alcohol moiety.<sup>7</sup>

Fluorometholone is available generically and is thus reasonably inexpensive. (However, there have been sporadic reports of fluorometholone being temporarily unavailable in various parts of the country. When prescribing, be sure to check with your pharmacy for availability.) While fluorometholone has less tendency to increase intraocular pressure than other ketone steroids, we are not nearly as

comfortable using it long-term as we are with the ester-based loteprednol.

FML Forte (fluorometholone 0.25%, Allergan) is not recommended because fluorometholone 0.1% represents the top of the dose response curve—meaning that the 0.25% formulation is no more efficacious than the 0.1%. Moreover, the 0.25% concentration has a greater tendency to raise IOP.<sup>8</sup>

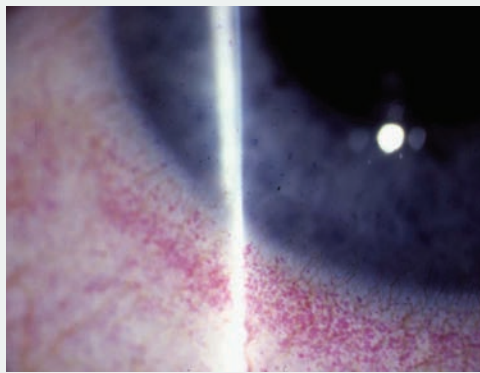
- **Alrex.** For allergic eye disease, prescribe a steroid when itching is accompanied by clinical signs of conjunctival injection, chemosis or eyelid swelling. In these instances, Alrex (or even

lular infiltration, inhibit chemotaxis and restore the appropriate vascular permeability. Corticosteroids also reduce or suppress capillary dilation, fibroblast proliferation and collagen deposition.

- The benefit of corticosteroids in the treatment of DED and in the improvement of both signs and symptoms has been demonstrated in several studies, and these clinical data are consistent with these reports ... Fluorometholone was selected as the study treatment because it was shown previously to be effective in DED therapy. Moreover, 0.1% fluorometholone penetrated the ocular tissues less than other corticosteroids, which minimizes the potential complications of the therapy.

- In this study, after 21 days of treatment, fluorometholone 0.1% reduced corneal and conjunctival staining and hyperemia, whereas no obvious effects were observed with polyvinyl alcohol artificial tears. The clinical improvement in corneal staining was in concordance with previous studies assessing corticosteroids. These results could explain the increase in BCVA ... due to a positive correlation between corneal epithelial damage and visual acuity ... As reported by others, fluorometholone 0.1% decreased conjunctival hyperemia, which is associated with the degree of inflammation. In contrast, polyvinyl alcohol artificial tears had no effect on hyperemia. Both fluorometholone and Liquifilm Tears contain benzalkonium chloride as a preservative. However, the negative impact of benzalkonium chloride in terms of corneal staining can be compensated for by the fluorometholone 0.1% therapy, as observed in this study.

- The ocular surface deterioration observed in the PA group reinforces the fact that DED patients can experience



exacerbations under desiccating conditions and that tear substitutes are not sufficient to protect the ocular surface in these adverse situations. In contrast, there were no significant adverse changes in the FML group after adverse environment exposure, confirming the appropriateness of fluorometholone 0.1% 21-day treatment for preserving the ocular surface.

- In conclusion, the clinical trial showed that three-week topical fluorometholone 0.1% was a safe and effective therapy for DED patients to reduce ocular surface signs after a 21-day treatment. Importantly, fluorometholone 0.1% therapy also can prevent ocular surface worsening in DED patients exposed to desiccating stress. Thus, this treatment could be administered occasionally to such patients expecting to undergo adverse environments during their daily life (e.g., office buildings, shopping centers, movie theatres, air-conditioned vehicles, etc.).

As this study shows, the short-term use of a topical corticosteroid, such as fluorometholone 0.1% or loteprednol 0.5%, can be enormously beneficial to patients with dry eye disease.

Once the ocular surface inflammation is controlled, clinicians should consider ongoing maintenance of inflammation suppression with a drug such as lifitegrast (not yet FDA approved), Lotemax gel or fluorometholone, depending upon patient response.

1. Pinto-Fraga J, López-Miguel A, González-García MJ, et al. Topical fluorometholone protects the ocular surface of dry eye patients from desiccating stress: a randomized controlled clinical trial. *Ophthalmology*. 2016 Jan;123(1):141-53.

Lotemax gel) is our answer. We typically dose Alrex (or Lotemax gel) QID for one week, then BID for one month.

Beyond awareness of the various delivery systems (suspensions, solutions, emulsions, gels and ointments), knowing the clinical efficacy of these drugs is important.

## STEROID OINTMENTS

The ophthalmic ointments enjoy a wide array of clinical indications. Three corticosteroid medicines that merit frequent clinical use in the ointment formulation include:

- **Lotemax ointment.** The only ester-based steroid ointment available is Lotemax ophthalmic ointment (loteprednol 0.5%, Bausch + Lomb). It is indicated for postoperative inflammation and pain, but also has many “off-label” clinical uses: dry eye, allergy, corneal transplant protection, blepharitis, giant papillary conjunctivitis, chronic uveitis, stromal immune herpetic keratitis, Thygeson’s SPK, RCE, augmentation of steroid eye drop therapy in acute advanced uveitis or episcleritis, contact dermatitis and other inflammatory conditions.

- **FML ointment.** FML ophthalmic ointment (fluorometholone 0.1%, Allergan) is used much the same as Lotemax ointment. It is indicated for inflammation of the palpebral and bulbar conjunctiva, cornea and anterior segment of the globe, and any of the off-label uses mentioned above. The only very minor difference is to keep a little bit closer watch on the patient for steroid-related adverse effects since it is a ketone steroid.

- **Triamcinolone 0.1% cream.** This is a dermatologic preparation that works well for periocular dermati-

tis conditions. Triamcinolone 0.1% cream, which became generic long ago, has been our favorite medicine for many years to treat contact blepharodermatitis. It comes in 15g and 30g tubes, each costing less than \$10 in most markets.

Be sure to tell the patient that on the side of the tube is the statement “Not For Ophthalmic Use,” but that the medication is perfectly fine to use as you have prescribed. We explain that triamcinolone, also known by the brand name Kenalog, is frequently used by retina subspecialists for FDA-approved injection into the eye. In other words, if some of the triamcinolone cream gets into the patient’s eyes, it’s nothing to worry about.

Corticosteroids are the most essential and highly prescribed medicines in the treatment of ocular inflammation of any stripe. Their widespread clinical usage confirms that ocular inflammation is the most common clinical manifestation seen in eye care.

It is so important that all doctors of optometry come to terms with this reality and strive to become very comfortable caring for patients with inflammatory eye disease. ■

1. Foster CS, Davanzo R, Flynn TE, et al. Durezol (Difluprednate Ophthalmic Emulsion 0.05%) compared with Pred Forte 1% ophthalmic suspension in the treatment of endogenous anterior uveitis. *J Ocul Pharmacol Ther.* 2010 Oct;26(5):475-83.

## STEROIDS AND CONTACT LENSES

Steroids have two well-known side effects: posterior subcapsular cataract development and ocular hypertension. Notice we did not use the term “glaucoma,” because that is exceedingly rare. Steroid-induced hypertension is rare enough, and is mostly seen with protracted use of ketone-based steroids, most notably dexamethasone, prednisolone and difluprednate.<sup>1</sup> To allow a situation in which ocular hypertension occurs and actually proceeds to frank glaucoma is unconscionable. This would only occur if a doctor did not schedule appropriate follow-up or the patient failed to return for scheduled follow-up visits in a timely manner (or at all), or a naïve, non-optometric physician re-prescribed a steroid. Thus, to say that topical corticosteroids cause glaucoma is an egregious stretch of reality.

Contact lenses have one common indication: correction of ametropias. They are also occasionally used as bandage lenses. In radical contradistinction to corticosteroids, contact lenses can carry many risks: giant papillary conjunctivitis; keratitis; corneal neovascularization; CLARE (contact lens associated red eye); retained lens fragments in the remote recesses of the superior cul-de-sac; corneal infiltrates; infectious keratitis; and other conditions. Patients may suffer unilateral corneal blindness from infectious keratitis, yet we prescribe contacts as if they were 100% safe. Of course, the patient is usually complicit in many of these complications via behaviors such as sleeping in their contacts, or using poor lens hygiene or inconsistent replacement schedules.

In any event, patients rarely have problems with either contact lens wear or use of topical steroids if they are used as prescribed. Proper, timely follow-up and competent optometric oversight typically render both steroid and contact lens use safe, effective therapeutic interventions.

Overall, we would be willing to bet big money that contact lenses cause far more problems than do steroids. So, let’s keep a realistic perspective on the clinical care we provide and not live with an unrealistic fear of the most beneficial class of acute care medicines available to help our patients enjoy a greater quality of life.

Sheppard JD, Comstock TL, Cavet ME. Impact of the topical ophthalmic corticosteroid loteprednol etabonate on intraocular pressure. *Adv Ther.* 2016; Mar 17. [Epub ahead of print].

## STEROIDS FOR DRY EYE DISEASE —EFFECTIVE AND SAFE LONG-TERM TREATMENT

Topical administration of methylprednisolone 1% ophthalmic solution for several weeks provides moderate to complete relief of DES symptoms and reduces corneal fluorescein staining in patients with SS-related DES, suggests research. Pulse treatment with methylprednisolone for two weeks followed by a taper led to improvement in symptoms starting at two weeks, followed by improved TBUT and Schirmer test scores by the end of taper. After the first pulse treatment, mean drug-free remission time was 56.6 weeks; after the second, it increased to 72.4 weeks. No serious complications, including IOP elevation and cataract formation, occurred during the entire follow-up period.

Again, short-term use of topical corticosteroids (used off-label) should be standard-of-care in most symptomatic dry eye patients.

Hong S, Kim T, Chung S-H, et al. Recurrence after topical nonpreserved methylprednisolone therapy for keratoconjunctivitis sicca in Sjögren’s syndrome. *J Ocul Pharmacol Ther.* 2007;23(1):78-82.

2. Slabaugh MA, Herlihy E, Ongchin S, van Gelder RN. Efficacy and potential complications of difluprednate use for pediatric uveitis. *Am J Ophthalmol.* 2012 May;153(5):932-8.

3. Leibowitz HM, Ryan WJ Jr, Kupferman A. Comparative anti-inflammatory efficacy of topical corticosteroids with low glaucoma-inducing potential. *Arch Ophthalmol.* 1992 Jan;110(1):118-20.

4. Roberts CW, Nelson PL. Comparative analysis of prednisolone acetate suspensions. *J Ocul Pharmacol Ther.* 2007 Apr;23(2):182-7.

5. US Food and Drug Administration. Center for Drug Evaluation and Research. Deputy Division Director Review for NDA 202-872. 2012 Sep 27. Available at: [www.accessdata.fda.gov/drugsatfda\\_docs/nda/2012/202872Orig1s000MedR.pdf](http://www.accessdata.fda.gov/drugsatfda_docs/nda/2012/202872Orig1s000MedR.pdf).

6. Lane SS, Holland EJ. Loteprednol etabonate 0.5% versus prednisolone acetate 1.0% for the treatment of inflammation after cataract surgery. *J Cataract Refract Surg.* 2013 Feb;39(2):168-73.

7. Leibowitz HM, Hyndiuk RA, Lindsey C, Rosenthal AL. Fluorometholone acetate: clinical evaluation in the treatment of external ocular inflammation. *Ann Ophthalmol.* 1984 Dec;16(12):1110-5.

8. Kass M, Cheetham J, Duzman E, Burke PJ. The ocular hypertensive effect of 0.25% fluorometholone in corticosteroid responders. *Am J Ophthalmol.* 1986 Aug 15;102(2):159-63.



# KID GLOVES: PEARLS FOR PEDIATRIC EYE CARE

— By Kathleen Foster Elliott, OD —

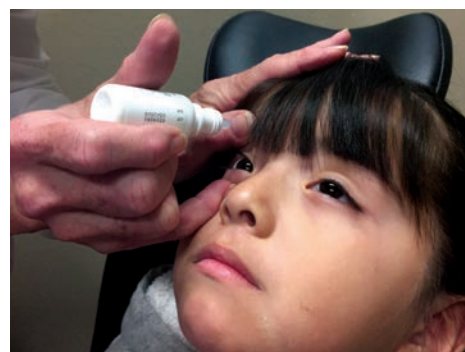Learn some of the foundational and alternative pharmacologic strategies for treating your pediatric patients—an increasingly important segment of your patient population.

**N**ew doors are opening every day for general optometric practitioners to increase their knowledge and skill set in providing pediatric comprehensive care. This article explores ophthalmic indications for pediatric treatment, along with strategies, dosages and side effects.

For non-complicated corneal abrasion, erythromycin ophthalmic ointment is frequently used in pediatric ophthalmology and optometry clinics. Gentle on the cornea, easily accessible, affordable and boasting a 50-year track record of broad-spectrum, gram-positive and chlamydial coverage, the macrolide comes in 0.5% ointment and is safe for all ages down to newborn. It is also used in neonates for prophylaxis against gonococcal ophthalmia neonatorum. It is essential to cycloplege the patient and recommend acetaminophen or ibuprofen for discomfort.

- **For pediatric bacterial conjunctivitis**, the most commonly prescribed medication is Polytrim (polymyxin B sulfate and trimethoprim ophthalmic solution, Allergan; and generic), active against a variety of aerobic gram-positive and gram-negative ophthalmic pathogens. Safety and effectiveness in children below the age of two months have not been established.<sup>1</sup> Instill one drop in the affected eye every three hours (up to six doses per day) for seven to 10 days.<sup>1</sup> A reasonable response time is three to five days.

For mucopurulent conjunctivitis, a preservative-free rinsing solution is recommended. We use Unisol because the design of the bottle lends itself to easy ir-



Drop instillation is challenging in pediatric patients; ophthalmic gel administered at a lower frequency dose can aid in administration in some cases.

rigation. We educate the parent to lavage several times a day before instillation of the medication. Additionally, check for pseudomembranes on the initial slit lamp exam and remove any with a surgical sponge, wet cotton swab, blunt forceps or Alger brush.

- **Corneal ulcers** need fast, viable therapy. Besivance (besifloxacin, Bausch + Lomb) is a newer fluoroquinolone, available in 0.6% ophthalmic suspension, that is highly effective against MRSE and MRSA, according to the ARMOR study (although topical vancomycin is rapidly becoming the drug of choice to target MRSA).<sup>2,3</sup>

This potent, dual-halogenated chlorofluoroquinolone is also highly effective against *Pseudomonas aeruginosa*.<sup>4</sup> Children are at increased risk for this invasive microbe if they have corneal hypoxia, are immunocompromised or are diagnosed with diabetes. Pediatric microbial keratitis treatment

should be coupled with a cycloplegic agent, such as cyclopentolate 1% BID or homatropine 5% QD.

Besifloxacin is safe for use in infants to toddlers one year of age. Dosage is three times a day, four to 12 hours apart for seven days. Around 2% of treated patients will have adverse reactions (e.g., conjunctival redness, blurred vision, eye pain, eye irritation, eye pruritus and headache).<sup>4</sup> No systemic side effects have been reported with besifloxacin on weight-bearing joints, although systemic administration of some quinolones has been shown to cause arthropathy in immature animals, according to the Adverse Event Reporting System study.<sup>5</sup>

Treatment of pediatric microbial keratitis involves an initial application of antimicrobial agents followed by anti-inflammatory agents. Pediatric cases are rare but devastating if not treated properly or quickly.

- For herpes simplex with skin or ocular involvement, oral antiviral therapy with acyclovir is highly effective—more effective than ophthalmic antiviral agents in treating herpetic corneal keratitis.<sup>6</sup> Oral acyclovir reaches therapeutic levels in aqueous and tears, virtually eliminating the need for concurrent use of topical antivirals. It is highly effective for treatment and prophylaxis of herpes simplex epithelial keratitis, and immune stromal keratitis in conjunction with Lotemax, and for prevention of recurrent infectious epithelial keratitis.

Ocular manifestations of herpes simplex virus or herpes zoster virus typically occur later in life, but disease in pediatric patients is often systemic and accompanied by more ocular inflammation and amblyopia risk; quick and effective therapeutic dosing is imperative.<sup>7</sup> Adding a cycloplegic agent such as cyclopentolate 1% BID will help heal and debride the corneal epithelium affected by a dendrite. A moistened surgical sponge, cotton swab or Alger brush can help debride necrotic tissue.

When evaluating for zoster disease,

look for the Hutchison sign—presence of a vesicle on the tip of the nose—signifying greater risk of corneal involvement secondary to herpes zoster. Shingles occasionally manifests in pediatric patients. Treatment options for primary ocular herpes infection include:

- Oral acyclovir (*Zovirax*, Glaxo SmithKline) 200mg capsules or 200mg/5ml (teaspoon) suspension

- Ganciclovir ophthalmic gel 0.15% (*Zirgan*, Bausch + Lomb): five times daily

- Trifluridine 1% ophthalmic solution (*Viroptic*, Pfizer): seven to nine times daily

- Vidarabine 3% ophthalmic ointment: five times daily (must be compounded by an ophthalmic specialty pharmacy)

Oral dosing guidelines for acyclovir are as follows: In patients over two years old, 20mg/kg every eight hours for five to seven days, not to exceed 1g PO every eight hours. For older teens of adult size, the adult dose of 400mg five times daily for 10 days can be administered.

With pediatrics, putting anything in the eye can be challenging; therefore, an ophthalmic gel five times daily makes more sense than drops needed seven to nine times a day. Compared with the standard treatment of trifluridine, ganciclovir is equally effective but less toxic.<sup>8</sup> Ganciclovir ophthalmic gel has low corneal toxicity and less frequent applications. Trifluridine solution and vidarabine ointment are also effective in treating HSV keratitis; however, epithelial toxicity is a frequent adverse effect, especially with prolonged use.<sup>9</sup>

The Herpetic Eye Disease Study Group (HEDS) demonstrated in patients 12 years or older that long-term suppressive oral acyclovir therapy at 400mg BID reduces risk of recurrent HSV epithelial (9% vs. 14%) and stromal (14% vs. 28%) keratitis.<sup>10</sup> So, for patients at risk of developing herpetic eye disease, long-term antiviral therapy is a common approach. In our clinic, we typically comanage these long-term

acyclovir users with pediatricians so proper blood tests and drug interactions can be monitored.

- Preseptal cellulitis is a common pediatric condition that requires an oral agent. It is common clinical procedure to rely on the patient's pediatrician or a pharmacist in determining oral antibiotics dosage for children. Close monitoring is crucial to avoid orbital cellulitis, which requires hospitalization with IV antibiotics. Periorbital cellulitis usually is caused by *Staphylococcus aureus*, *Streptococcus pyogenes* or *Streptococcus pneumoniae*. *Haemophilus influenzae B* is becoming a rare cause because of the prevalence of *H. influenzae* vaccinations.<sup>11</sup>

Common antibiotic treatments for preseptal cellulitis in pediatrics include Augmentin (amoxicillin clavulanate, GlaxoSmithKline) or clindamycin. Augmentin has good broad-spectrum and gram-negative coverage against *Haemophilus influenzae*. In patients less than 90 pounds, dosage is 35mg/kg per day to 40mg/kg per day with three divided doses every eight hours for 10 days. If the patient weighs more than 90 pounds, dose is 250mg to 500mg every eight hours, or 875mg every 12 hours, for seven to 10 days. Maximum dosage should not exceed 2g per day.

Clindamycin is a broad-spectrum alternative to the penicillin-allergic patient. Adverse effects may include nausea and vomiting, diarrhea and abdominal pain. (Bactrim is also a good choice for patients allergic to penicillin, although it does not cover Group A *Streptococcus*—a likely etiology of preseptal cellulitis in pediatric patients.) Clindamycin dosing is as follows: 30mg/kg per day to 40mg/kg per day divided TID or QID for 10 days. Bactrim dosage is 8mg per day to 12 mg per day divided BID for 10 days. If the patient is less than one year old, parenteral antibiotics and/or hospitalization is recommended. For patients allergic to penicillin, the broad macrolides azithromycin (10mg/kg per day for three days) and clarithromycin (7.5mg/kg BID) are safe and effective.

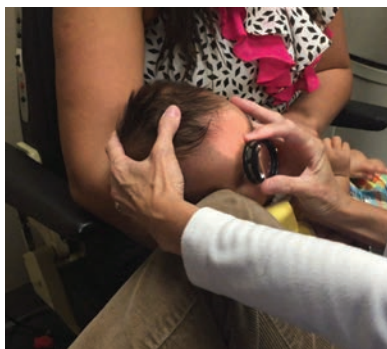- **Treatment of iritis**, especially in juvenile idiopathic arthritis (JIA) patients, takes a joint effort between the optometrist or ophthalmologist, pediatrician, parent and rheumatologist. The devastating effects of iritis and uveitis on a pediatric eye can lead to permanent scarring and blindness if not aggressively treated.

The systemic form of JIA is one classification, but pauciarticular is the most common form of JIA, affecting the large joints. Girls under age eight are most likely to develop this type. Ocular diseases such as iritis, uveitis and glaucoma affect about 20% to 30% of children with pauciarticular JIA. Up to 80% also test positive for antinuclear antibodies (ANA) in the blood, and the disease tends to develop at an early age.

The third classification of JIA is polyarticular, which occurs in 30% of children with JIA. The small joints, such as those in the hands and feet, are most commonly involved, but the disease may affect large joints.<sup>12</sup> Patients with this classification who are ANA positive, female and pauci-jointed are at highest risk for iritis. Monitor them with a slit-lamp exam, observing for early cell and flare, every three months during the first year of diagnosis.

Pred Forte is my drug of choice. (Don't settle for generics, and shake the bottle before usage.) For most iritis cases, dose is every two hours for the first one to two days, then QID for a week, followed by a taper. Be sure to obtain baseline intraocular pressure, with IOP check at follow-ups. Also, topical mydriatic and cycloplegic agents are important to prevent pupillary block.

- **For ocular allergy**, consider a once-daily dosage for efficacy and convenience—because children do not like instillation of eye drops. Two QD options are Pataday (olopatadine) and Lastacaft (alcaftadine). Pataday combines a mast cell stabilizer with an ocular antihistamine. Lastacaft is an H<sub>1</sub> receptor antagonist inhibiting release of histamine from mast cells.



**To view the posterior pole in infants/toddlers, support the patient's head between the clinician's knee and parent's arm, using gentle pressure to bolster.**

- **Superglue** (cyanoacrylate) is part of a family of strong, fast-acting adhesives with industrial, medical and household uses. Change one molecular structure and you have a medical-grade adhesive known as Dermabond (2-octyl cyanoacrylate, Ethicon), which forms a strong bond across apposed wound edges to allow normal healing to occur below. It is marketed to replace sutures 5-0 or smaller in diameter for incisional or laceration repair.<sup>13</sup>

Dermabond has become an efficient way of providing pediatric care for lacerations, especially in the periorbital area. Best-suited for small, superficial lacerations, it may be used with confidence on larger wounds where subcutaneous sutures are needed. Treatment age ranges vary from newborn to age 18, depending on the size and depth of the laceration. Cyanoacrylates have also been successfully used in treatment of corneal lacerations or globe perforations through the cornea.<sup>14</sup>

Alternatives to adhesive management include sutures and Steri-Strips.

- **For moderate to severe seizure disorder**, children are often prescribed Sabril (vigabatrin, Lundbeck). The most common side effect is permanent visual field loss, occurring in one-third of patients. Critically, visual field is irreversible even upon discontinuation of the medicine. Children placed on Sabril must be comanaged by pediatric neurology, pediatric ophthalmology

and optometry to detect of this possible side effect.

Visual fields and retinal analysis are required every three months during drug regimens and three to six months after cessation, then at one year. A thorough retina assessment is essential during instillation. To get thorough dilation, use cyclopentolate 1% along with phenylephrine 2.5%. Children with brown irides may need to be instilled with the dosage twice. In some children, exam under anesthesia is needed.

There has never been a better time for the field of optometry to engage in pediatrics. Arming yourself with facts, techniques and information on prescribing for the pediatric patient will benefit the patient and profession. ■

1. Polytrim (polymyxin B sulfate and trimethoprim ophthalmic solution, USP). Available at: <http://www.drugs.com/pro/polytrim.html> (last accessed April 29, 2016).
2. Asbell PA, Sanfilippo CM, Pillar CM, et al. Antibiotic Resistance Among Ocular Pathogens in the United States: Five-Year Results From the Antibiotic Resistance Monitoring in Ocular Microorganisms (ARMOR) Surveillance Study. *JAMA Ophthalmol*. 2015 Dec;133(12):1445-54.
3. Tarai B, Das P, Kumar D. Recurrent Challenges for Clinicians: Emergence of Methicillin-Resistant Staphylococcus aureus, Vancomycin Resistance, and Current Treatment Options. *J Lab Physicians*. 2013 Jul-Dec; 5(2): 71-8.
4. Besivance (besifloxacin ophthalmic suspension) 0.6% Receives Additional Indications, Including the Treatment of Bacterial Conjunctivitis Infections Due to Pseudomonas aeruginosa. Available at: [www.bausch.com/our-company/newsroom/2012-archive/besivance-additional-indications#.VmW\\_VSZOKnO](http://www.bausch.com/our-company/newsroom/2012-archive/besivance-additional-indications#.VmW_VSZOKnO) (last accessed April 29, 2016).
5. Besivance: Safety Review. Department of Health and Human Services Public Health Service Food and Drug Administration Center for Drug Evaluation and Research Office of Surveillance and Epidemiology Available at: [www.fda.gov/downloads/AdvisoryCommittees/CommitteesMeetingMaterials/PediatricAdvisoryCommittee/UCM255067.pdf](http://www.fda.gov/downloads/AdvisoryCommittees/CommitteesMeetingMaterials/PediatricAdvisoryCommittee/UCM255067.pdf) (last accessed April 29, 2016).
6. Hung SO, Patterson A, Rees PJ. Pharmacokinetics of oral acyclovir (Zovirax) in the eye. *Br J Ophthalmol*. 1984;68:192-5.
7. Myers TM, Wallace DK, Johnson SM, et al. Ophthalmic Medications in Pediatric Patients *Compr Ophthalmol Update*. 2005;6(2):85-101.
8. Topical antiviral gel treats herpetic keratitis. *Healio*. September 10, 2010. Available at: [www.healio.com/ophthalmology/cornea-external-disease/news/print/ocular-surgery-news/%7Bfa6ae2ad-fe4e-4074-b9f1-13cf91e32637%7D/topical-antiviral-gel-treats-herpetic-keratitis](http://www.healio.com/ophthalmology/cornea-external-disease/news/print/ocular-surgery-news/%7Bfa6ae2ad-fe4e-4074-b9f1-13cf91e32637%7D/topical-antiviral-gel-treats-herpetic-keratitis) (last accessed April 29, 2016).
9. Wang JC. Herpes Simplex Keratitis Treatment & Management. Available at: [emedicine.medscape.com/article/1194268-treatment#d1l](http://emedicine.medscape.com/article/1194268-treatment#d1l) (last accessed April 29, 2016).
10. A controlled trial of oral acyclovir for the prevention of stromal keratitis or iritis in patients with herpes simplex virus epithelial keratitis. The Epithelial Keratitis Trial. The Herpetic Eye Disease Study Group. *Arch Ophthalmol*. 1997;115: 703-12.
11. Sadovsky R. Distinguishing Periorbital from Orbital Cellulitis Am Fam Physician. 2003;15(6):1349-53.
12. Types of Juvenile Idiopathic Arthritis. Available at: [www.spineuniverse.com/conditions/spinal-arthritis/jra/types-juvenile-rheumatoid-arthritis](http://www.spineuniverse.com/conditions/spinal-arthritis/jra/types-juvenile-rheumatoid-arthritis) (last accessed April 29, 2016).
13. Bruns TB, Worthington JM. Using Tissue Adhesive for Wound Repair: A Practical Guide to Dermabond Am Fam Physician. 2000 Mar;61(5):1383-18.
14. Eiferman RA, Snyder JW. Antibacterial effect of cyanoacrylate glue. *Arch Ophthalmol*. 1983;101:958-60.

# THE CARE OF PATIENTS WITH GLAUCOMA

Glaucoma is not a disease that progresses quickly, so take the time to make a careful diagnosis and a thoughtful decision regarding initiation of therapy.

**G**laucoma and dry eye disease are the two most poorly cared for chronic eye diseases, yet both conditions can be managed rather easily—as long as you first perform careful and thorough assessment. Here, we review some best practices and reminders for a proper diagnostic glaucoma evaluation.

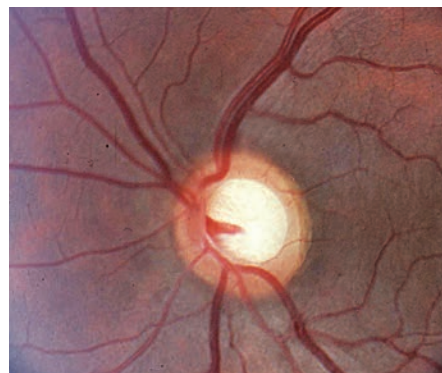
- *Carefully observe the optic nerve head.* By far, the most common diagnostic error we see is losing sight of the essence of glaucomatous optic neuropathy; that is, critically studying and descriptively characterizing the appearance of the optic nerve head. We regularly see patients whose glaucoma has been missed entirely because a “normal” intraocular pressure lured the clinician into optic nerve complacency. Because a large subset of glaucoma patients have normal-tension glaucoma, close observation of the optic nerve appearance is absolutely critical to establishing this diagnosis.

- *Perform tonometry.* In addition to failing to study the optic nerve head, another common error we see regularly is referral for a glaucoma evaluation for patients who have an intraocular pressure in the mid- to upper 20s, with 0.2 or 0.3 central cups and corneal thicknesses of 620 $\mu$ m to 640 $\mu$ m. These patients most commonly have a 100% normal workup. If all optometrists would simply measure the central corneal thickness in these pseudo-ocular hypertensives, it would be an immense service to the patients and our profession.

- *Check central corneal thickness.* Of course, one cannot know with certainty if a patient truly has normal or low-tension glaucoma without the benefit of pachymetry to refine the accuracy of the tonometric reading, as the intraocular pressure without pachymetry is relatively meaningless.

Keep in mind that a physiologically thin cornea appears to be an independent risk factor for glaucomatous optic neuropathy, and this needs to be factored into the patient assessment of risk.

- *Evaluate the neuroretinal rim.* Another key factor in evaluating the optic nerve head is to relatively ignore the actual cup and attentively study the neuroretinal rim tissues. Even in a 0.8 to 0.9 cup, the visual field can look pretty good as long as there is no focal erosion of the rim tissues. However, if such erosion is present, it is most commonly seen at the inferotempo-



This optic nerve head, while considerably cupped, honors the ISNT rule, and therefore highly likely physiologically cupping.

<b>TOPICAL GLAUCOMA DRUGS</b>				
<b>BRAND NAME</b>	<b>GENERIC NAME</b>	<b>MANUFACTURER</b>	<b>CONCENTRATION</b>	<b>BOTTLE SIZE</b>
<b>Beta Blockers</b>				
Betagan	levobunolol hydrochloride	Allergan, and generic	0.25% 0.5%	5ml, 10ml 5ml, 10ml, 15ml
Betimol	timolol hemihydrate	Akorn	0.25% 0.5%	5ml 5ml, 10ml, 15ml
Betoptic-S	betaxolol hydrochloride	Alcon	0.25%	5ml, 10ml, 15ml
Istalol	timolol maleate	Bausch + Lomb	0.5%	2.5ml, 5ml
Timoptic	timolol maleate	Valeant Ophthalmics, and generic	0.25% 0.5%	5ml, 10ml, 15ml 5ml, 10ml, 15ml
Timoptic (preservative-free)	timolol maleate	Valeant Ophthalmics	0.25% 0.5%	unit-dose unit-dose
Timoptic-XE	timolol maleate	Valeant Ophthalmics, and generic	0.25% 0.5%	2.5ml, 5ml 2.5ml, 5ml
<b>Prostaglandin Analogs</b>				
Bimatoprost	bimatoprost	generic	0.03%	2.5ml, 5ml, 7.5ml
Lumigan	bimatoprost	Allergan	0.01%	2.5ml, 5ml, 7.5ml
Travatan Z	travoprost	Alcon	0.004%	2.5ml, 5ml
Travoprost	travoprost	generic	0.004%	2.5ml, 5ml
Xalatan	latanoprost	Pfizer, + generic	0.005%	2.5ml
Zioptan	tafluprost	Akorn	0.0015%	unit-dose
<b>Alpha Agonists</b>				
Alphagan P	brimonidine	Allergan	0.1%, 0.15%	5ml, 10ml, 15ml
Brimonidine	brimonidine	generic	0.15%, 0.2%	5ml, 10ml, 15ml
<b>Carbonic Anhydrase Inhibitors</b>				
Azopt	brinzolamide	Alcon	1%	5ml, 10ml, 15ml
Trusopt	dorzolamide	Merck, + generic	2%	5ml, 10ml
<b>Combination Glaucoma Medications</b>				
Combigan	brimonidine/timolol	Allergan	0.2%/0.5%	5ml, 10ml
Cosopt	dorzolamide/timolol	Akorn, + generic	2%/0.5%	5ml, 10ml
Cosopt PF	dorzolamide/timolol	Akorn	2%/0.5%	unit-dose
Simbrinza	brinzolamide/brimonidine	Alcon	1%/0.2%	8ml

ral and/or superotemporal rim tissues. This is because of relatively sparse glial support tissues in these regions. The ISNT rule (inferior > superior > nasal > temporal) speaks to this anatomic reality, in that in a normal optic nerve head the inferior tissues are usually the thickest, followed by slightly less thick superior rim tissues, then slightly less thick nasal rim, with the temporal rim being the thinnest. This is not a bulletproof concept, but it is a good general guide.

- **Talk about family history.** Because glaucoma tends to run in families, we always ask about siblings. When we have a patient who is a

high-risk glaucoma suspect or who has the disease, we strongly urge them to recommend to their siblings that they seek an optometric glaucoma evaluation in the area where they live. Such screening has been shown to have a quite high yield, and to positively impact public health.

- **Check blood pressure in-office.** Carefully assess the patient's systemic conditions, especially treatment for systemic hypertension. It has been found, particularly in low-tension glaucoma patients, that when blood pressure medicines are taken in the evening or at bedtime, they can pathologically lower nocturnal blood pres-

sure, which can exacerbate glaucomatous progression.<sup>1</sup> We find ourselves more and more often writing letters to primary care physicians explaining this relatively new knowledge and asking them to consider having patients take blood pressure medicines in the morning time. Once the PCPs have this scientific explanation, good cooperation is generally the rule.

Along this same line, many patients with asthma can use a topical beta blocker very successfully. However, we never prescribe a topical beta blocker for such patients without first writing to the primary care physician for clearance, and having a let-



ter (i.e., written documentation) from that doctor to place in our medical records attesting to such. We have, with proper consultative advice, used topical beta blockers for a handful of patients with asthma without incident and successfully obtained target intraocular pressure. (As an aside, we also find ourselves communicating more often with rheumatologists, since many of these specialists have a proclivity to overdose patients taking

hydroxychloroquine.) Sending a copy of the EMR is an extremely poor substitute for a brief letter.

The optometric measurement of systemic blood pressure can accomplish two key goals: screening for the epidemic of uncontrolled (or under-controlled) systemic hypertension, and fine-tuning our understanding of low-tension glaucoma, as many of these patients have blood pressure that is too low, which can often

explain progression of glaucoma, despite achievement of target intraocular pressure. The small, forearm (radial) devices for measuring blood pressure are inexpensive, simple to use by ancillary personnel and can be of enormous value to human health and to glaucoma assessment.

- **Analyze retinal nerve fiber layer, if available.** Additional assessment with retinal nerve fiber layer analysis can be extremely helpful in under-



## FROM THE LITERATURE

### AGING ALONE CAN EXACERBATE “PROGRESSION” IN GLAUCOMA PATIENTS

It stands to reason that natural quantitative loss of optic nerve fibers over time can contribute to glaucomatous optic neuropathy. An article in *Ophthalmology* (December 2015) gives important insights into the impact of natural aging on visual field compromise in the setting of glaucoma progression, per these excerpts:

- “Age-related loss of neuroretinal parameters may explain a large proportion of the deterioration observed in treated patients with glaucoma and should be carefully considered in estimating rates of changes.”
- “Because there is accumulating evidence that aging in otherwise healthy subjects also results in statistically significant change, often with patterns resembling those in glaucoma, the clinical assessment of glaucomatous progression can be challenging.”
- “The effect of IOP variability on ONH parameters is probably related to changes in lamellar position and prelaminar tissue compression.”
- “Because mean deviation (MD) is age adjusted, it is likely that the absence of normal aging effects with this parameter allows better estimates of glaucoma-related damage than with the neuroretinal parameters.”

- “Our findings indicate that aging in healthy control subjects leads to a significant reduction of neuroretinal parameters and may explain a large proportion of the deterioration observed in patients with treated glaucoma. Furthermore, both cross-sectional and longitudinal studies of healthy subjects show patterns of regional loss similar to those in patients with glaucoma, suggesting that age-related regional susceptibility may be accelerated in glaucoma. Because several previous longitudinal studies of structural progression of glaucoma lacked a control population, the observed changes were attributed to glaucoma, perhaps overestimating the rate of change in treated glaucoma. Therefore, without an understanding of the significant normal age-related changes, there could be errors in rate estimates and the diagnostic accuracy of glaucoma-related progression.”

Thankfully, there are many other metrics and parameters to guide us in clinical decision making than just the visual fields. However, this article does serve to make us more analytical in changes in the visual fields. Remember, in order to establish true progression, we would have to do three or four fields about every six to 12 months. This is why it is so challenging and minimally productive to micro-manage the visual field component of the comprehensive glaucoma assessment.

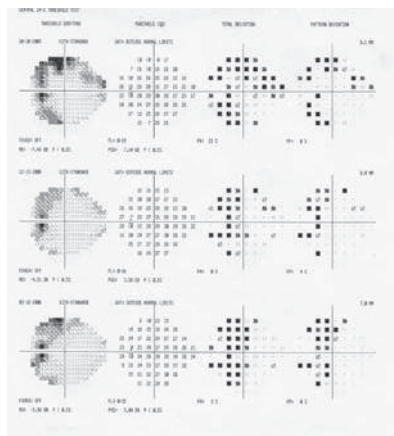
Vianna JR, Danthurebandara VM, Sharpe GP, et. al. Importance of normal aging in estimating the rate of glaucomatous neuroretinal rim and retinal nerve fiber layer loss. *Ophthalmology*; 2015;122(12):2392-8.

standing the microanatomy of the tissues. Such measurements are in no way absolutely diagnostic, but can add information to help the clinician refine assessment of the health status of the optic nerve.

- **Perform perimetry (repeat, if warranted).** Humphrey visual field 24-2 SITA Fast testing remains our visual field assessment of choice. One test result, especially in a naïve-to-visual field test patient, can be confusing unless: (a) it is normal or (b) it is abnormal but corresponds to your assessment of the optic nerve head tissues. The problem is that many initial (and to some degree, subsequent) visual field results are just plain “noisy” and non-constructive in nature.

If you obtain uncertain visual field results, repeat the test in a few weeks to months, depending on the level of risk and/or concern by the doctor and/or the patient for glaucoma disease. Never make a change in medical therapy based on the results of a single visual field test, as it is well-established that repeating visual field testing three to six times is necessary before one can confirm true progression of a visual field. Remember that glaucoma left untreated tends to progress at approximately a rate of 3% per year.<sup>2</sup>

Take note: Glaucoma management is like sailing—there is no wisdom in making rapid changes in course. Such apparent rapid changes are not com-

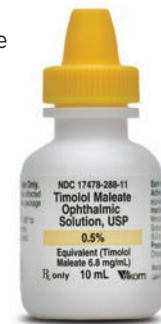

**When in doubt, repeat the field.**

## TIMOLOL EYE DROPS FOR MIGRAINE HEADACHE?

Acute migraine headaches may be reduced in intensity or stopped altogether with beta blocker eye drops. While the daily use of beta blocker pills has proved effective in preventing chronic migraine headaches, they have been unsuccessful in treating acute, sudden-onset migraines. Beta-blocker eye drops, however, are absorbed more quickly than pills by tear duct drainage onto the nasal mucosa, achieving therapeutic plasma levels “within minutes.”

Migliazzo CV, Hagan JC. Beta-blocker eyedrops for treatment of acute migraine. *Missouri Medicine*. 2014; 111(4):283-8.



patible with human biology.

Once a repeatable visual field defect is present, following the patient over time is best done with serial visual fields. Nerve fiber layer analyzers are more helpful in staging risk or helping to detect early glaucoma, whereas serial visual fields are optimal for following patients with established visual field defects.

- **Look at the angle.** Gonioscopy is best accomplished via a four-mirror instrument. The Van Herick assessment is highly accurate but not exact, and the occasional plateau iris can be misleading. Gonioscopy can more completely elucidate the microanatomy of the angle tissues. Such assessment is even more important in patients with moderate to high hyperopia, especially if progressive nuclear sclerotic cataract is further narrowing the iridocorneal angle.

Most patients with pigment dispersion syndrome or pseudoexfoliation are at higher risk for increased intraocular pressure via biologic debris clogging the trabecular meshwork. Screening for pigment dispersion can be accomplished by carefully examining the corneal endothelial tissues and retroilluminating the non-dilated iris to look for radial (or splotchy) iris transillumination defects.

Conversely, pseudoexfoliation can be easily missed unless the pupil is pharmacologically dilated. Otherwise, deposits on the face of the lens can be obscured. Qualifying and quantifying such debris in the angle

can be critically important, especially in the setting of increased or increasing intraocular pressure.

Beyond assessing the patency of the iridocorneal angle is annotating the pigmentation of the angle tissues. This is essential to know when contemplating laser trabeculoplasty because pigments absorb the laser energy, enabling a positive therapeutic response. If there is little or no pigmentation of the trabecular meshwork tissues, there will be little or no therapeutic response to laser trabeculoplasty.

Last, as a clinical pearl, laser trabeculoplasty is more effective in phakic eyes than in pseudophakic eyes. This is critical knowledge to enable maximum clinical patient care. We typically repeat gonioscopy



**FROM THE LITERATURE**

## NEW PERSPECTIVES ON TARGET IOP

- “Meta-analysis shows mean IOP reduction with prostaglandin analogues ranges from 28-33%. Slightly smaller IOP reduction is typically achieved with beta-blockers whereas alpha-agonists and carbonic anhydrase inhibitors will usually reduce IOP by 15-20%.”

Clement CI, Bhartiya S, Shaarawy T. New perspectives on target intraocular pressure. *Surv Ophthalmol*. 2014 Nov-Dec;59(6):615-26.

about every five years, and sooner if there is unexplained increasing intraocular pressure.

Summarizing the diagnostic evaluation: (1) Expectantly study the optic nerve with slit lamp-enabled ophthalmoscopy; (2) note the intraocular pressure; (3) check central corneal thickness.

Beyond these three prime maneuvers, take a careful family history, especially of the brothers and sisters; obtain nerve fiber layer measurements, baseline visual fields and perform gonioscopy. Lastly, check blood pressure, especially in the setting of low-tension glaucoma. By doing all these things, missing glaucoma would be nearly impossible.

**THERAPEUTIC PERSPECTIVES**

Knowing when to initiate therapy is the Holy Grail of patient management. Equally competent doctors have different thresholds and different philosophies. By and large, there is no rush to treat because glaucoma is almost always a slowly progressive neuropathy. The decision to treat requires much care, contemplation and comprehensive assessment. Also, don't forget that we are not treating a condition or disease; we are treating a human patient, so involving them in the decision-making process is appropriate.

This is a drug guide, not a textbook. We assume a significant level of knowledge on the part of the reader. Remember, there can be exceptions to everything said herein, and every patient has to be cared for in a highly individualized manner. That being



**FROM THE LITERATURE**

**STUDY COMPARES FIRST-LINE MEDICATIONS FOR PRIMARY OPEN-ANGLE GLAUCOMA**

This article in *Ophthalmology* (January 2016) definitively confirms what clinicians have witnessed over the last decade: All the prostaglandins work very similarly. Some quotes from this article provide unique insights:

- “The objective of this article is to assess the comparative effectiveness of first-line medical treatments for lowering IOP in patients with POAG or ocular hypertension through a systematic review and network meta-analysis and to provide relative rankings of these treatments. By using a systematic review and network meta-analysis, we estimated the pairwise comparative effectiveness of 14 first-line IOP-lowering drugs used in patients with POAG or ocular hypertension.”
- “Drugs in the prostaglandin class were more efficacious than drugs in other classes, although the within-class differences were generally small. Bimatoprost 0.01% is no more effective than latanoprost or travoprost in lowering IOP at three months. Brimonidine lowered IOP more than apraclonidine; and unoprostone and betaxolol lowered IOP the least.”
- “In conclusion, we found that all active first-line drugs are effective compared with placebo and that prostaglandins were more efficacious in lowering IOP at three months than beta-blockers, alpha-agonists, or carbonic anhydrase. Bimatoprost, latanoprost, and travoprost are among the most efficacious drugs, although the within-class differences were small and may not be clinically meaningful. All factors, including side effects, patient preferences and cost, should be considered in selecting a drug for a given patient.”

This final statement is a clinically practical admonishment. A key factor the authors failed to mention is frequency of administration. While cost is a pre-eminent factor, ease of use is similarly so. We find topical timolol to be cheap, simple and safe (in non-asthmatic patients), which is why we often start there in select patients. It is most definitely our go-to second-line drug when target IOP is not achieved with a prostaglandin.

Tianjing Li, Lindsley K, Rouse B, et al. Comparative effectiveness of first-line medications for primary open-angle glaucoma. *Ophthalmology*. 2016;123(1):129-40.

said, let's take a look at the various glaucoma medications we have in our armamentarium.

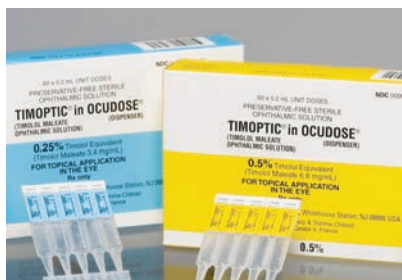**FIRST-LINE THERAPY**

Most of our patients are started on either a prostaglandin or timolol. These medicines typically reduce intraocular pressure by 30% and 25%, respectively. By far, the least expensive glaucoma medicine is generic timolol, which can be critically important since cost is a well-recognized reason for patient noncompliance.

Remember, clinical management occurs within the context of patient management, and multiple factors have to be taken into account to de-

cide which drug is, overall, going to best serve the patient.

Generic latanoprost is a commonly prescribed glaucoma drop, and for many patients most of the time, it is often the best initial choice. However, choosing the right medicine is highly complicated by diverse and ever-changing marketing promotions (e.g., coupons) by the companies manufacturing brand-name products. As a result, there may be situations where a brand-name-protected product, at least initially, can be less expensive. To further complicate matters, different insurance companies have different drug formularies. You're not entirely on your own to navigate this





dynamic and maddening landscape; the app/website [GoodRx.com](http://GoodRx.com) can assist you in your research as you make your way through this convoluted decision-making process.

We have found that prostaglandins perform best when instilled in the evening; however, if a patient tells you they can better remember to use their drop at breakfast, then this is perfectly fine. The difference in morning vs. evening instillation of a prostaglandin is somewhere in the vicinity of 1mm Hg, so good adherence at breakfast is much preferred to poorer adherence in the evening.

Rarely do patients develop significant iris coloration changes, and even more rarely do they develop peri-orbitopathy changes linked to reduction in orbital adipose tissues. Basically, prostaglandins are generally well-tolerated and have minimal side effects.

In our patients, the 0.01% formulation of Lumigan is much better tolerated than the 0.03% (which is generically available), yet there is four times as much benzalkonium chloride (BAK) in the lesser concentrated formula, thus acknowledging that BAK is not as offensive as is commonly touted. However, for those rare patients who truly need a preservative-free option, Zioptan nicely meets this need. The main downside to Zioptan is that, like latanoprost and trifluridine, it has to be stored under refrigeration at the pharmacy.

Another consideration: Though these three medicines are refrigerated during storage, once dispensed to the patient, ongoing refrigeration is not necessary; all three medicines can be kept at room temperature by the patient. However, if a patient is dispensed multiple bottles of these medicines, we advise that the bottles not being used be refrigerated, and the one being used be kept where it is most convenient for the patient's access.

### ADJUNCTIVE THERAPY

Assuming a prostaglandin was pre-

### NEW GLAUCOMA DRUG ANTICIPATED IN 2016

It was 1978 when timolol came to market, and 1996 for latanoprost. After two decades of few innovative advances, we may be on the threshold of an upgrade in clinical efficacy in the care of our patients with glaucoma. Latanoprostene bunod is a unique, single-entity, nitric oxide-donating prostaglandin. Interestingly, it enhances conventional trabecular outflow by relaxing the trabecular meshwork cytoarchitecture and also enhances aqueous outflow through the uveoscleral tissues.

“Despite the availability of various treatments to reduce elevated IOP, the most commonly prescribed glaucoma drugs do not target the compromised function of the trabecular outflow pathway,” investigators recently wrote<sup>1</sup> “Therapeutic use of nitric oxide has the potential to benefit glaucoma patients by reducing IOP via targeting the diseased conventional outflow pathway.”

In early studies, latanoprostene bunod was found to reduce intraocular pressure 1.23mm Hg more than latanoprost.<sup>2</sup> It is to be used once daily. Like the prostaglandins, it is well-tolerated and holds promise to become a major player in glaucoma patient care. Latanoprostene bunod is awaiting FDA approval, which is anticipated in upcoming months.

The brand name for latanoprostene bunod ophthalmic solution is not known at press time, but will be marketed by Bausch + Lomb.

1. Cavet, MP, Vittitow JL, Impagnatiello F, et al. Nitric oxide (NO): an emerging target for the treatment of glaucoma. Invest Ophthalmol Vis Sci. 2014 Aug 14;55(8):5005-15.  
2. Weinreb RN, Ong T, Scassellati Sforzolini B, et al. A randomized, controlled comparison of latanoprostene bunod and latanoprost 0.005% in the treatment of ocular hypertension and open-angle glaucoma: the VOYAGER study. Br J Ophthalmol. 2015;99(6):738-45.

scribed as initial therapy, worked well, yet did not achieve the proposed target range of intraocular pressure reduction, we would, at that juncture, choose a beta blocker as adjunctive therapy.

Typically, this total twice-daily eye drop frequency results in a regimen

and a second drop of brimonidine between 4pm and 5pm in the afternoon. The use of twice-daily brimonidine tends to work well for about eight hours, and does very little during the sleep cycle, thus the late afternoon instillation of the drop rather than instillation closer to bedtime.

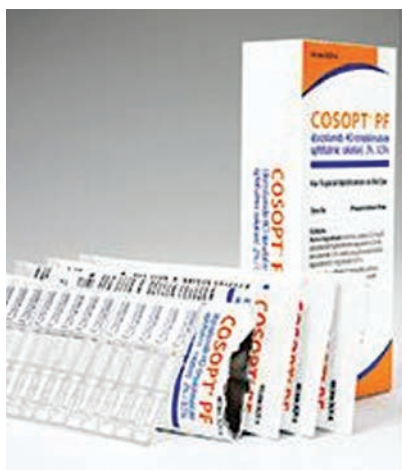### QUOTABLE

DO NOT LOSE SIGHT OF THE FACT THAT BETA BLOCKERS REMAIN AN EXCELLENT CHOICE FOR REDUCING INTRAOCULAR PRESSURE.

of a drop of timolol within 20 to 30 minutes after awakening, and instillation of a prostaglandin drop at night. Most patients can handle this routine easily, and such a combined therapy achieves target IOP most all the time.

If the patient has asthma, consider 0.2% brimonidine as one drop within 20 to 30 minutes after awakening,

Brimonidine is an alpha-2 selective adrenergic agonist medicine that enhances outflow, and to some degree, aqueous production. In our experience, its two main limitations are its twice-daily requirement of administration, and the occasional development of ocular surface allergic disease. While the 0.2% concentration is



more likely to cause allergic disease, it is also less expensive than the generic 0.15% and the brand-name-protected Alphagan-P. So, it is occurring more commonly that we must balance cost to the patient with tolerability—a highly subjective call.

Carbonic anhydrase inhibitors (CAIs) only reduce intraocular pressure about 15% in our experience, and also have to be used twice daily;

both of these factors limit their clinical usefulness. CAIs inhibit aqueous production. Although they have a sulfa side chain, we have observed little or no cross-reactivity in those people who have an allergy to sulfonamide antimicrobials.

This class of drug is represented by the orange-capped bottles of generic dorzolamide and Alcon's Azopt (brinzolamide) suspension. Only Azopt and Simbrinza are glaucoma suspensions, which have to be shaken before each instillation. Brimonidine and dorzolamide are found in combination with 0.5% timolol.

## COMBINATION GLAUCOMA DROPS

Three combination drugs are available: Cosopt (0.5% timolol with 0.2% dorzolamide, Akorn), Combigan (0.5% timolol with 0.2% brimonidine, Allergan) and Simbrinza (0.2% brimonidine with 1% brinzolamide suspension, Alcon).

Simbrinza is the only suspension combination drug. Simbrinza's main

uniqueness is that, unlike Cosopt and Combigan, it does not contain a beta blocker. Thus, for a patient with asthma, or one who is nonresponsive to beta blockers, Simbrinza would likely be an ideal add-on to a prostaglandin drug, once individual trials of both brinzolamide and brimonidine are found to be efficacious. Commonly, if the prostaglandin brought us close to target intraocular pressure but fell short, it is likely that adding generic brinzolamide or generic brimonidine alone will get the IOP to target, and using a more expensive combination drug may not be necessary.

Cosopt is unique in that it is generically available as a traditional bottled product and as a brand name-protected, preservative-free unit dose product. The carbonic anhydrase inhibitors reduce intraocular pressure by suppressing aqueous production, and do so by only about 15%. Like brimonidine, they are approved as TID products, yet we tend to use them twice daily in general clinical care. Dorzolamide is an ophthalmic



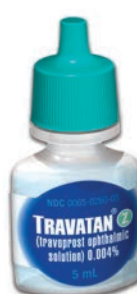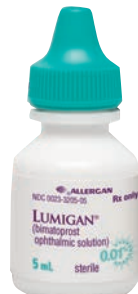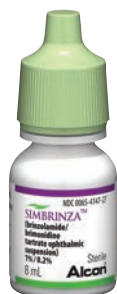## OPHTHALMIC MYTHS: GLAUCOMA

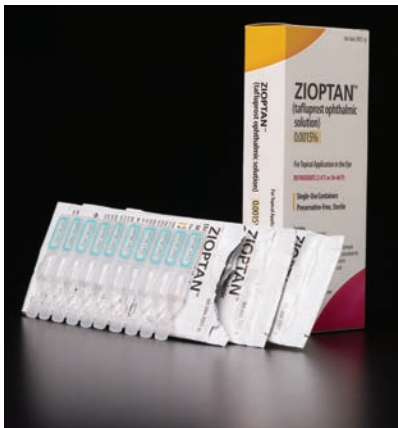### Myth Glaucoma is a blinding disease and should be cared for by glaucoma specialists.

**Our Take** Most people with glaucoma do well with the disease throughout their lives. Total blindness from this disease is exceedingly rare; optometrists should not avoid providing glaucoma care as a result of this fear. Most certainly, in glaucoma patients who are adherent to medication and follow-up visits, blindness is vanishingly rare. Obviously, catching the disease early is of paramount importance. Blindness from glaucomatous disease is a common outcome in some developing countries where there is no infrastructure for care. That said, glaucoma surgical subspecialists should be consulted when medical therapy does not achieve target IOP.

### Myth Never use a topical beta-blocker in a patient with asthma.

**Our Take** With written consultation with the patient's asthma doctor, we have successfully used topical beta-blockers with several patients having asthma. Obviously, it is absolutely essential that you have the full, written consent of the patient's asthma physician before you prescribe a beta-blocker.





**FROM THE LITERATURE**

**HOW TO SAVE MONEY ON GENERIC LATANOPROST AND OTHER DRUGS**

An interesting article in the March 2016 *American Journal of Ophthalmology* is enlightening regarding cost of generic latanoprost. Not every available generic product was tested, but the findings hold practical value.

- “At the time of this study, examining the generic latanoprost availabilities in the southeastern United States, Bausch + Lomb appears to be the most economical (based on [average wholesale price] AWP) of available generics in regard of days-of-use per bottle and price. It did not differ significantly from branded latanoprost in regard to number of drops per bottle, days’ use per bottle, or bottles used per year, but was similarly priced to the least expensive option, costing \$200 per year.”

- “If a patient being treated successfully with a PGA is interested in generic options, one potential solution could be to specify a generic manufacturer on the prescription, as one would typically do for the branded, thus improving the reliability of duration of use for that specific medication.”

- “Practitioners can better advise patients by being aware of these differences, and pharmacy managers can use these data to help select generics contracted.”

Of course, while this peer-reviewed article grants us an updated perspective on these various generic options, it also finds:

- “Prescription plan coverage is a source of drug cost variation. It is difficult to address the true cost-savings/loss for the patient when comparing branded and generic medications owing to the extreme range of coverage per medication per insurance plan, including copayments, coupon cards, etc. In order to have a consistent comparison, we use average wholesale price.”

In light of the above variables relative to access to medicines, it is difficult to know the overall best approach for our patients. Our hope is that this article will, at least, give us some foundation to make rational prescription choices going forward.

Queen JH, Feldman RM, Lee DA. Variation in number of doses, bottle volume, and calculated yearly cost of generic and branded latanoprost for glaucoma. *Am J Ophthalmol.* 2016;163:70-74.

solution (original brand name Trusopt), and brinzolamide is an ophthalmic suspension (original brand name Azopt). When we need to prescribe one of these, we dose the medication twice daily: first dose in early morning, and the second drop about eight hours later (just as we do with brimonidine).

In summary, we typically initiate glaucoma therapy with a prostaglandin, and add timolol 0.25% or 0.5% once daily (in the morning) if target intraocular pressure is not reached with the prostaglandin alone.

We still regularly initiate glaucoma therapy with a beta blocker, particularly when only a 5mm Hg to 6mm Hg reduction in IOP is needed and/or when we believe that cost is a critical factor in patient compliance. A 5mL bottle of timolol is uniformly available for about \$5. Be mindful that we have found prostaglandins generally reduce intraocular pressure by about 30%, whereas nonselective beta

blockers reduce intraocular pressure by about 25%. That’s a separation of only about 1mm Hg to 3mm Hg. Do not lose sight of the fact that beta

blockers remain an excellent choice for reducing intraocular pressure.

Taking this together, it is apparent that initial therapeutic interventions are easy, but if the patient is a prostaglandin nonresponder and/or has active asthma, establishing a therapeutic plan becomes more like a chess game; it involves considerable thought and therapeutic trials until target intraocular pressure is achieved. ■

**KEEP IN MIND**

**FINGERNAIL GROWTH, HEADACHE AND PROSTAGLANDIN EYE DROPS?**

According to general correspondence from the American Glaucoma Society, it appears that prostaglandins, particularly bimatoprost, may cause fingernails to grow a bit faster than normal. This effect might be enhanced with direct application of a prostaglandin to the lunula (the crescent) up to the finger. Further, some patients have noticed an attenuation of their migraine headaches.

We have no idea of the widespread clinical validity of these anecdotal musings, but wanted to lay them out there for general clinical contemplation. It certainly appears that patients taking timolol and a prostaglandin could have improvement with their migraine headaches.

1. Charlson ME, de Moraes CG, Link A, et al. Nocturnal systemic hypotension increases the risk of glaucoma progression. *Ophthalmology.* 2014 Oct;121(10):2004-12.
2. Quigley HA. The progression of glaucoma: it isn't what you think. In *Peril to the Nerve — Glaucoma and Clinical Neuro-Ophthalmology.* Kugler Publications; 1998: 3-11.

# CARE OF THE PATIENT WITH SHINGLES

Antivirals work best during the early phase of the varicella zoster virus.

The varicella zoster virus causes shingles. It only occurs in patients who have had chicken pox, generally during childhood. Fortunately, due to the advent of the childhood Varivax vaccine, which came to market in 1995, there are now generations of people living who will never have shingles because they will never contract chicken pox.

This, however, is a double-edged sword: prior to the Varivax vaccine, there were always children among us with chicken pox in various stages of contagion. This allowed the adult population to come into contact with the virus during the course of daily living, stimulating our immunity against the varicella zoster virus. Since Varivax, that is no longer the case.

Keep in mind that as we age, our immune systems become less robust and, in these “underexposed” individuals, some degree of shingles is even more likely to occur. Thus, we face another 30 to 50 years of increased occurrence of shingles in those

patients who have not had sufficient exposure to boost their immunity against it, so clinicians need to be ready for it.

It is increasingly important that the eye care community become impeccably skilled and adept at caring for patients with shingles. The diagnosis is quite straightforward most of the time. A minority of patients will develop skin pain days or weeks before developing the vesicular eruptions associated with shingles. Zoster disease is most commonly expressed in the trunk area of the body; the second most common site is the first (ophthalmic) division of the trigeminal nerve distribution, which involves the forehead and upper eyelid. The globe becomes involved in about half of these first trigeminal nerve expressions, and there is disease of both the skin and the eyeball. Let’s look at these two case scenarios individually.

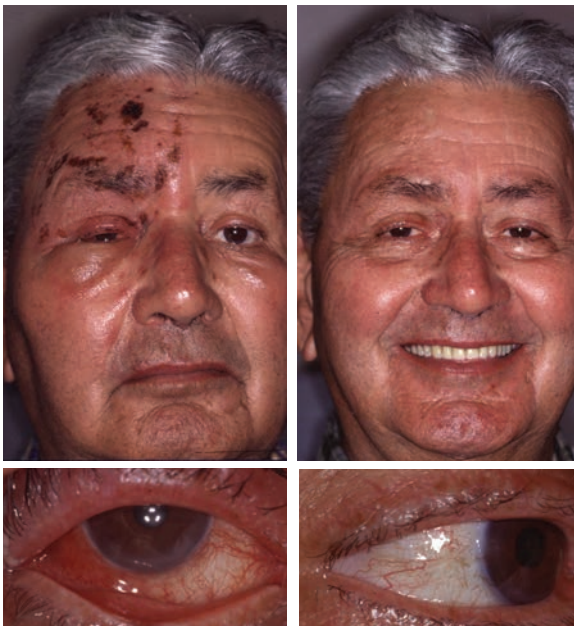## PERIOcular SKIN DISEASE

When shingles presents as an uncomplicated skin disease, as evidenced by pain, erythema and vesicular expression, the treatment is an oral antiviral for seven to 10 days. We find three such medications equivalent in their therapeutic effectiveness:

- *Acyclovir 800mg* five times daily
- *Valacyclovir 1,000mg* three times daily
- *Famciclovir 500mg* three times daily

The latter two have enhanced bioavailability, which enables them to be used less frequently. While all three are available generically, acyclovir is the least expensive.

These medicines nicely subdue a varicella outbreak in most patients, particularly patients who present within the first 72 hours



HZO patient before (left) and after (right) therapy.

of the outbreak. Antiviral medicines work best during the early replicative phase of the infection. This does not mean that after three days, the opportunity for medical intervention has passed—just that there is decreasing clinical efficacy with each day of delay in seeking care. With more virulent expressions, especially in older individuals, concurrent therapy with oral prednisone (usually 40mg to 60mg/day for a week) can be valuable in decreasing the pain and inflammation, and it may dampen the expression of post-herpetic neuralgia.

Remember, herpes simplex and herpes zoster viruses are neurotrophic viruses, and shingles may result in protracted neurological pain in some patients. The key to success in treating all shingles patients is early therapeutic intervention, if at all possible.

## GLOBAL INVOLVEMENT

The plot thickens if the globe of the eye becomes involved. The old teaching was that, if the tip of the nose was involved (Hutchinson's sign, indicating involvement of the nasociliary nerve which innervates corneal and intraocular tissues), the eye is too. A much simpler and better way to determine globe involvement is to directly examine the cornea and the anterior chamber.

When the eye does become involved, it is an inflammatory uveitis or an inflammatory keratitis or both. Uveitic involvement will manifest as inflammatory cells in the anterior chamber; corneal involvement will manifest as stromal inflammation. Occasionally, even the trabecular tissues become inflamed, resulting in increased intraocular pressure. Conjunctival injection, of varying degree, accompanies these inflammatory expressions.

Ocular involvement of the zoster virus requires proper (usually aggressive) treatment with cycloplegia and topical steroids. We prescribe homatropine 5% for use BID to QID, along with Durezol every one to two hours for a few days until the inflammation is well-controlled. Only then begin a taper.

We keep cyclopentolate and atropine in our offices to jump-start the cycloplegic progress, since it may take a pharmacy a day to two to get these medicines if they are not in stock. We also tell the patient to “pharmacy-hop” if their usual drug store does not have them in stock. It is important to start the topical steroid as soon as possible. Remember that Durezol, as an emulsion, does not have to be shaken.

On rare occasions, usually when the patient has delayed seeking care, an episode of subsequent stromal-immune uveitis or keratitis may occur. These cases present with a “hot” eye: very red, very inflamed, and often with increased intraocular pressure. The aggressive use of cycloplegia and Durezol is again deployed. No “antiviral cover” is needed with varicella disease; however, if the keratouveitis does not abate within an expected timeframe, consider another course of oral antiviral for 10 to 14 days.

This small subset of patients may require many months or years of low-dose topical steroid to keep the ocular inflammation from flaring up. Here, once full control is gained with Durezol, we would switch the topical steroid to Lotemax gel off label; the sequence would be something like this: TID for one month, BID for two to four months and then once daily for several more months—always trying to find the least amount of medical intervention while achieving the goal of quiescence. A drop of steroid a day for life for these patients is not unusual in such circumstances. Note that while shingles is an infectious process, the downstream sequelae are expressed out by inflammation.

## SHINGLES VACCINE

The recurrence rate is about 2% to 5%. Having shingles once is much more effective in preventing further outbreaks than is the shingles vaccine—Zostavax—which only reduces the risk of having shingles by about 50%. The Zostavax vaccine is highly recommended for those older than age 60.

The downside of Zostavax is that it only provides relative immunity for about eight years, so repeat vaccination may be wise at that point. Guidelines for repeat vaccinations are now being developed. Since we are older than 50 ourselves, we have been vaccinated. No one wants shingles.

Patients commonly ask, “Should I get the vaccine if I have already had shingles?” There is no definitive answer. It is known that having shingles powerfully reboots the immune system. This explains why shingles is often a one-and-done event. Because the vaccination only reduces the risk of shingles by about 50%, this would yield a risk of 1.5% to 2.5%. Like many aspects of life, it's a gamble. It is our opinion that a patient who develops shingles and is older than age 50 most likely would not benefit from the vaccine because having shingles much more robustly stimulates our immune system than does the Zostavax vaccine.

Oral antivirals are extremely safe and effective. Their only Achilles' heel is that they are metabolized in the kidneys. Thus, if a patient has clinically significant renal disease, the antiviral dosage needs to be reduced. Phone consultation with the patient's primary care physician or nephrologist, or both, is of utmost importance in determining the optimum dosage. Computer programs and mobile apps can calculate the proper dosage based on renal function parameters of creatinine clearance and glomerular filtration rates, which the physician will have on hand. We have never had to have such a consultation, but we are certainly prepared to do so if we encounter such a patient.

As shingles can be devastatingly painful, it is satisfying to provide effective acute care to those who are suffering. The diagnosis is almost always clearly evident, and the medical intervention is straightforward in almost all cases. Treatment of this disease is an area in which we should all be experts, as we are all likely to see more cases in the coming years. ■

# LESSONS LEARNED FROM A LIFE IN THE CLINIC

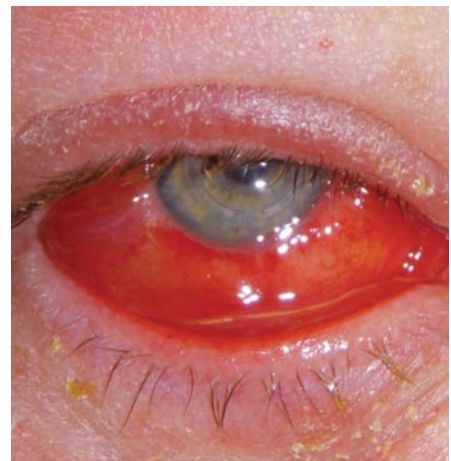Our combined 70 years as optometric physicians have yielded these wide-ranging clinical observations that can hone your response to numerous conditions for improved patient care and outcomes.

■ The attentive study of the optic nerve head is of paramount importance in the **diagnosis and management of glaucoma**. IOP is secondarily important, and relatively meaningless in the absence of pachymetry. A pharmacologically dilated pupil greatly enhances such attentive study and is essential for viewing the nerve in stereo. IOP, OCT, fields and pachymetry are all adjunct tests that will confirm your diagnosis.

■ Use only a modest amount of **fluorescein dye** when evaluating the precorneal tear film. Too much dye can mask the nuances of certain epithelial conditions. Also, unexplained subtle vision loss can result from epithelial basement membrane dystrophy in the visual axis, which can only (or best) be seen with fluorescein dye.

■ Many patients with dry eye disease will benefit from **fish oil supplementation**—usually about 2,000mg per day. Let them know it takes four to six months to gain the therapeutic effect as evidenced by decreasing need to use artificial tears. Further, not all people can swallow these rather larger capsules; for this subset of patients, liquid supplementation will be helpful. We recommend either Coromega Omega-3 Orange Squeeze or Nordic Naturals Omega 3 Liquid.

■ When **inflammation** is a significant component of any anterior segment disease, always consider prescribing a topical corticosteroid. Nonsteroidal anti-inflam-



This patient presented with an acute allergic reaction to an unknown chemical. He was given lavage, cold compresses and topical steroid eye drops.

matory drugs (NSAIDs), the tetracyclines, azithromycin, cyclosporine all have modest anti-inflammatory effects (and as-yet-unapproved lifitegrast is expected to) but do not come close to the efficacy of a steroid. Don't hesitate with inflammation; properly suppress it.

■ **OCT technology** is one of the most helpful ancillary instruments available to analyze and document retinal and nerve changes. It is fast becoming standard of care, if it isn't already. It can be especially helpful for assessing retinal nerve fiber layer thickness in glaucoma evaluations, and retinal evaluations in cases of unexplained vision loss. Subtle epiretinal

membranes and early defects such as macular holes, or central serous retinopathy that may be difficult to see clinically can be more easily revealed with OCT.

■ **Hydroxychloroquine (Plaquenil) screening** is best accomplished with a functional assessment (10-2 visual field) and a structural assessment (HD-OCT). At-risk patients are those with lean, short stature, i.e., a small body. The greater a person's body weight is over 135 pounds, the lower the risk of paramacular toxicity. The easiest way to calculate the lean body is as follows: For women, start at 100 pounds at five feet tall, and add five pounds for every additional inch of height. For example, a woman who is 5'5" has an ideal body weight of 125 pounds, and should not be taking the usual dosage of 400mg/day. For men, start at five feet with 110 pounds, and add five pounds for every additional inch of height. These general guidelines can help stage the degree of risk Plaquenil patients. (See "2016

*Plaquenil Update," below.)*

■ Two technologies to consider: Just as OCT revolutionized retinal (and to some degree, anterior segment) tissue evaluation, we predict **meibography** will be the next major wave of advanced diagnostic technology. The discovery that meibomian gland disease is at the heart of the pathogenesis of most cases of dry eye disease makes assessment a diagnostic imperative.

■ Air puff tonometry is a barbaric, unpleasant and dreaded procedure for most patients. Goldmann applanation tonometry is still the gold standard. Another option is the **Icare tonometer**, a simple, handheld device that requires no eye drops, and is minimally felt, if felt at all. Patient acceptance is excellent, and it greatly enhances the ambience of the optometric practice.

■ Keep on hand a nice array of clinical hand instruments in a stain-

less steel tray with appropriate liquid chemical disinfection. As can be seen in our sidebar on handheld instruments (*page 48*), these can vastly expand your ability to care for a host of patient presentations.

■ **Be available to your patients 24/7.** Develop call groups where six or so optometrists work together to take turns being on-call, usually for a week at a time. Optometric patients should never have to subject themselves to the inconvenience, expense and relative incompetence of emergency departments. Whenever optometric patients call their optometrist's office after hours, they should always get an answering machine/answering service guiding them to an optometrist. It's simply the right thing to do.

■ In the strongest of admonitions, we recommend all optometrists subscribe to one or two **ophthalmology journals**. We generally recommend *American Journal of Ophthalmology*



## FROM THE LITERATURE

### 2016 PLAQUENIL UPDATE

A major article in the *American Journal of Ophthalmology* (September 2015) on hydroxychloroquine (HCQ) merits highlighting. Key findings from this review of patient care at a large, tertiary medical center were eye opening; from these, we provide some clinical pointers (in italics).

- Based on "ideal body weight calculations," 50% of patients were overdosed at the typical dosage of 400mg/day.

- At initial screening visits, about 50% of patients received a 10-2 plus an objective test—usually a HD-OCT.

*This should be a standard baseline work-up for 100% of subjects taking Plaquenil.*

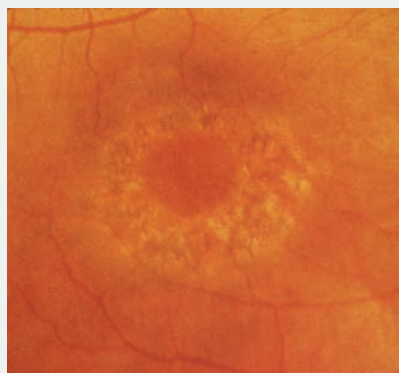
- Diagnostic testing was underperformed. Only a 10-2 or only an objective test (OCT, FAF or mf ERG) was accomplished in about 30% of subjects.

*At least one subjective test (usually at 10-2 with white target) and one objective test (usually a HD-OCT) is*

*considered reasonable care.*

- No testing occurred in 25% of Plaquenil patients. Amsler grid testing is of no value in HCQ testing, yet was done on 40% of subjects.

*Retinal and comprehensive ophthalmologists see the majority of subjects for HCQ screening, but are appropriately screening subjects less than half the time.*



**This is a classic presentation of "bull's eye" maculopathy—a very sad, and very preventable, expression of permanent vision loss from HCQ toxicity.**

The import of all the recent literature indicates that we are failing to provide subjects proper HCQ screening, which is of particular concern given the rising detection rate of toxicity. It is our opinion that evaluating the patient's "ideal body weight," performing the appropriate testing, and communicating with the Plaquenil prescriber perfectly meets the standard of excellence in clinical care. If you do not have the requisite diagnostic instrumentation, then send your patients to an optometrist in your area who does.

Au A, Parikh V, Modi YS, et al. Hydroxychloroquine screening practice patterns within a large multispecialty ophthalmic practice. *Am J Ophthalmol*. 2015 Sep;160(3):561-568.

and *Ophthalmology*. Better yet, form groups of four to six optometrists where journal subscription costs are shared, and meet for two hours once a

month to share and discuss pertinent articles. This is vastly superior to attending any lecture (including ours!). We urge state boards to create poli-

cies where such “journal club” members can receive continuing education credit for such scholarly endeavors. An easy portal to engage such sub-

All instruments pictured are made by Storz Ophthalmic Instruments/Bausch + Lomb Instruments

### HANDHELD INSTRUMENTS IN PRIMARY EYE CARE

Having a variety of essential hand instruments in your examination/treatment rooms can greatly expand your ability to care for a wider array of patient care needs. Some examples are: removing corneal foreign bodies, scraping along the eyelid margin to enhance meibum flow into the tear film, removing erosive concretions from the tarsal conjunctiva, epilating trichiatric lashes, debriding irregular epithelium associated with corneal abrasions, performing anterior stromal micro-puncture, destroying symptomatic lymphangectatic bulbar conjunctival cysts, removing crab lice from infested eyelashes, dilating punctal orifices for punctal plug insertion, irrigating the nasolacrimal system, using an eyelid retractor to enable double eversion, incorporating a metal spatula to accomplish bacterial culturing, corneal rust ring removal, scleral depression, and so on. The following is a more detailed description of some instruments we find useful in everyday practice.

• **Golf club spud.** This instrument is one of the most versatile and widely used tools in all of eye care. Its forté is enabling the removal of corneal foreign bodies; however, more recently, Korb and associates have shown it can be used to gently scrape along the lower eyelid margin to enhance meibum flow posteriorly into the pre-corneal tear film enhancing tear film function.<sup>1</sup> Lastly, it is the instrument of choice in removing transconjunctival erosion of calcium concretion bodies from the tarsal conjunctiva.



• **Kimura spatula.** Our instrument of choice in obtaining corneal tissue associated with bacterial keratitis for gram/gram-stain, and material for bacterial cultures.



• **Iris scissors.** These are perfectly suited for destruction of symptomatic bulbar conjunctival lymphangectatic cysts. Three or four good slices across and through these cysts will not only instantaneously deflate them, but this utter destruction prevents them from reforming. The same can be accomplished by using a sterile needle to deflate the cyst, but without destruction of the cyst, reformation commonly occurs. Beyond topical anesthesia with proparacaine, we also instill 2.5% phenylephrine to minimize any bleeding since these conjunctival cysts often have blood vessels, because they are simply outpocketings of conjunctival tissue.



• **Shahinian cannula.** This blunt-tipped cannula is perfect for irrigating the nasolacrimal ducts when evaluating epiphora associated with nasolacrimal stenosis or obstruction.



• **Jeweler's forceps.** This highly versatile instrument provides multifaceted utility. It can be used to remove corneal foreign bodies, debride

loose or irregular epithelial tissue, remove erosive conjunctival concretions and perform eyelash epilation. This tool is especially helpful in epilating tiny, short, blond lashes.



• **Curved-tip serrated forceps.** This can be used in a wide variety of applications, but works especially well at removing ticks and crab lice from the lid tissues.



• **Epilation forceps.** This instrument is obviously intended for removing trichiatric lashes, and do indeed work well for this purpose. However, for some of the stubby, maldeveloped lashes, jeweler's forceps often work better.

*Wide-tipped:*



*Narrow-tipped:*



• **Stromal puncture needle.** This is a short, 25-gauge needle that has been precisely bent to perform safe application of corneal micro-puncture to treat focal (not diffuse) corneal erosions. If there is a large area of loosely adherent epithelium, debridement and diamond burr buffing or polishing of the debrided surface tissue may best serve the patient. Placement of a bandage/therapeutic soft contact lens after



scriptions is [www.ophsource.com](http://www.ophsource.com). Beyond the two journals mentioned above, consider subscribing to *JAMA Ophthalmology*, *Survey of Ophthalmology*, and *Journal Watch – General Medicine*, a newsletter that helps us keep up with key clinical insights in general medicine.

either of these procedures is typically done for three to four days along with antibiotic eye drops QID. These procedures are generally curative, which is a major blessing for these patients suffering from corneal erosions.



• **Punctal dilator.** It is best to try to insert the largest punctal plug possible to enable retention, so adequate punctal dilation should be done to accomplish this. Punctal sizing gauge devices are available from many punctal plug manufacturers and are highly recommended to facilitate proper size selection.



• **Desmarres lid retractor.** Some foreign bodies are elusive and can only be seen with “double eversion” of the upper eyelid. The Desmarres #2 (15mm) retractor works very well for this purpose, and while not a frequent-use instrument, it can be very helpful when a retro-tarsal conjunctival search is needed.



Other instruments are certainly available, but these are the ones we use most often, and wanted to share with our readers. Having such varied and versatile handheld instruments at the ready can powerfully arm optometrists to serve our patients’ needs in a much enhanced, comprehensive manner.

1. Korb DR, Blackie CA. Debridement-scaling: a new procedure that increases meibomian gland function and reduces dry eye symptoms. *Cornea*. 2013 Dec;32(12):1554-7.

*mology*, and *Journal Watch – General Medicine*, a newsletter that helps us keep up with key clinical insights in general medicine.

■ **Rarely refer patients out;** rather, do phone consults when appropriate. You learn little or nothing through referral, but can grow your clinical skills and comfort level by obtaining verbal guidance and then managing the patient yourself. This is powerful guidance, and holds enormous potential for optometric growth. By the way, when you do refer, strongly consider sending to fellow ODs in your area (or out of your area). We should be a family, a team working together for the common good of our patients and our profession.

■ There are several **default maneuvers** we recommend in patient care. When pondering what to do in any number of circumstances, consider these when debating:

- See patients (when they call with a problem)
- Check pupils, then dilate
- Make a phone call (to get advice)
- Do a visual field
- Evert the eye lid
- Revisit and expand upon the case history
- Try a corticosteroid

■ For the overall benefit of our profession, **join the American Optometric Association (AOA)**, and contribute to your state political action committee and the AOA PAC. Especially for the under-60 crowd, consider becoming board-certified by the American Board of Optometry; we are. It is likely that such certification will become increasingly important.

■ For any patient with a history of transient unilateral visual phenomena/loss (often those over age 50), order a **carotid ultrasound study** within a day or two. Such episodes most commonly represent carotid athero-

matous disease, and put the patient at increased risk of stroke. Such ocular TIAs generally last a few seconds to a couple of minutes, whereas occipital vasospasm (ocular migraine) episodes usually last from 10 to 60 minutes. Always write a brief letter to the patient’s primary physician advising her or him of these findings, and send a copy of the ultrasound report as well.

■ In any patient who presents with a retinal vein occlusion, diabetic retinopathy, hypertensive retinopathy, anterior ischemic optic neuropathy, etc., be sure to check his or her **blood pressure**. Undiagnosed or suboptimally controlled hypertension is common and potentially serious. Checking your patient’s blood pressure (especially in those over age 40) could be life-saving.

 **KEEP IN MIND**

**FISH OIL & EPA-DHA**

Fish oils come in different qualities and their essential fatty acid constituents of eicosapentaenoic acid (EPA) and (docosahexaenoic acid) DHA can vary. As a general guideline, the milligram contents of these compounds must add up to roughly 850mg to have a meaningful effect. These two compounds are concentrated in the outer layers of the photoreceptors and are thought to absorb harmful wavelengths of blue light. Because lutein and zeaxanthin are supplements, you would need to know the dietary and nutritional intake of each patient to properly quantify the precise amount of supplementation necessary. This reality is often lost in the conversation regarding appropriate supplemental recommendations.

Pizzimenti J, Capogna L. Choroid Chronicles. Talk presented at the Optometric Retina Society Eye-Ski Conference. Park City, UT. Feb 23, 2015.

**HOW TO HELP PATIENTS PAY LESS FOR PRESCRIPTIONS**

The expense of medicines today and the various tiers on formularies are great frustrations for the patient and doctor alike. Fortunately, most pharmaceutical companies have developed coupons that enable patients to obtain forbiddingly expensive medicines at a lower cost. Examples include Durezol, Lotemax gel and Zylet; Alcon, Allergan and Bausch + Lomb now have coupons that allow the patient to “pay no more than” \$35 for many of these excellent, state-of-the-art medications.

A fly in the ointment, though, is that these coupons are not valid if the patient is on Medicare or one of many other third-party government programs. You may need to explain to the patient they may be told the coupon is not valid with their insurance, upon presenting one of these coupons to a pharmacy. One way many doctors suggest these patients work around this obstacle is to tell the pharmacist they wish to pay cash and to “forego the insurance.” This works well in many circumstances, but sometimes the pharmacy will not allow the patient to pay out-of-pocket. We always try to keep a variety of these coupons on hand, and then coach patients on how to get the most benefit from them.

You will need to contact the various pharmaceutical representatives of the associated drug companies in order to obtain these coupons for your patients. You might also try searching for the coupons online, as many of them are available electronically.

■ **Preservative-free formulations** are rarely needed. Most people with a relatively normal tear film are not affected by preservatives. The dry eye patient on more than one preserved eye drop may benefit from preservative-free options, but for most patients, preserved formulations do just fine. Generally speaking, “preservative-free” is a marketing tool, not a clinical imperative.

■ Regarding **pupillary abnormalities (anisocoria)**, if there is no ptosis or no extraocular muscle dysfunction, then it is a benign finding. Looking at older photographs can be helpful in cases that do not resolve in a few days, such as accidental contact with an anticholinergic compound such as a scopolamine patch.

■ **Glaucoma is a disease process looking for attentive optometrists.** Our practices are 40% to 50% glaucoma, and we thoroughly enjoy getting to know these patients over the years. Relationships are established, referrals are an annuity and our professional services are fully enhanced.

If we don’t embrace glaucoma, nurse practitioners and physician assistants are waiting in the wings to take our place. A note to most optometrists: Refractive services are performed by talented high school graduates in most ophthalmology practices, and these practices are bursting at the seams. Computer-driven refractions

are already here and become more refined every year. Those ODs steeped in medical eye care will be doing well if “refract-and-refer” practitioners are ever replaced or eliminated. There is an entire universe of medically oriented patient care in need. Just ponder these things, and plan for the future.

■ Regarding treating **ocular allergy**, if there are any signs accompanying symptomatic itching, start with a topical corticosteroid, and over a couple of weeks, switch to an antihistamine/mast cell stabilizing agent, if needed.

■ When a patient has **foreign body sensation** but you find nothing, consider “sweeping” the superior cul-de-sac. Use proparacaine first, then grease the sterile cotton swab with any ointment and sweep the recesses of the upper fornix three to four times. It feels strange to the patient, but can make you a hero. A few years ago, our state’s largest newspaper reported the story of a woman who had consulted 11 different eye doctors (of all stripes) over a two-year period. An optometrist finally thought to sweep her superior cul-de-sac, and out came a folded soft contact lens. There is a reason for everything: Find it. ■

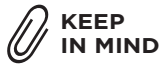**PATIENT “MANAGEMENT” IS NOT SYNONYMOUS WITH PATIENT “TREATMENT”**

Treating a clinical condition is usually straightforward, but patient management is fraught with many challenges: How can we ensure that the patient:

- Gets your prescribed medicine and uses it as prescribed?
- Can adequately instill the eye drop?
- Adequately shakes a suspension medicine prior to instillation?
- Returns for scheduled follow-up visits?

If you are treating a condition that you are a bit nervous about or unsure of, get the patient’s phone number and call them in a day or two to see if there are any questions or concerns, and find out how things are going. Patients love it when their doctors call to check on them, and doctors can sleep better at night knowing their patients are doing well. Taking charge of your patient care is the best way to enhance clinical outcomes, patient satisfaction and all-around positive patient care experiences.

Last, always properly document all patient encounters and activities legibly in your patient’s medical record. Patient “management” is a reflection of comprehensive patient oversight; it is not simply prescribing a medicine in a vacuum.



## WHEN THE PHARMACY OR PATIENT REJECTS YOUR Rx

Too often, we get calls from pharmacies to inform us that Drug Y prescribed for a patient is not on the insurance formulary, and they recommend Drug Z be substituted. At other times, the medicine that would best serve the patient's needs is quite expensive, so the patient rejects the prescription at the pharmacy due to the cost, which prompts yet another call back to the prescribing doctor. We, and no doubt you, are sick of this absurd interference in the care of our patients.

Here is an example of the maddening scenario we all encounter with growing frequency: We recently saw a young woman with chronic, recurrent, bilateral anterior uveitis whose condition was concurrently managed by her rheumatologist, who had placed her on increasingly high doses of methotrexate because we were unable to subdue the uveitis with topical steroids. We prescribed Durezol, the best drug for her, only to get pushback from the pharmacy informing us that Durezol was not on her formulary. They recommended generic prednisolone acetate.

We had no choice but to acquiesce, even though in our clinical experience, the substitute drug would likely require a longer time to gain control of the condition. After weeks of chronic recurrence, we finally provided her with samples of Durezol and, as we expected, this quickly suppressed her uveitis. Once controlled, we had to switch her back to the generic prednisolone acetate because we had no more samples available for her.

Since we don't seem to have leverage to remove all this "red tape," here are some "Plan Bs" that we use to maneuver through and around some of this bureaucracy to provide optimum care for our patients:

**Problem:** When a brand-name prostaglandin is prescribed and denied, and generic latanoprost is recommended: For most patients, this would be fine, but we have anecdotally found some generic varieties of latanoprost to perform less well than others.

**Plan B:** Keep and offer coupons for brand-name, preferred drugs. These can be helpful to some patients, though not all.

**Problem:** You prescribe Combigan only to be told it is not on the patient's formulary, or the patient is paying cash for the medicine and the cost is prohibitive.

**Plan B:** In either case, a viable option is to prescribe the two generic ingredient drugs. In this instance, we would prescribe timolol 0.25% or 0.5% q.a.m., and brimonidine 0.2% q.a.m. Clearly instruct the patient to wait 10 minutes between the use of these two drops. We prescribe a second drop of brimonidine 0.2% to be used around 4pm to 5pm. (Brimonidine only works for about eight hours, thus the need for the second, late-afternoon drop.) Optimally, timolol is used only once daily in the morning.

**Problem:** You prescribe Simbrinza ophthalmic suspension, and are told it is not on the patient's formulary, or that the patient can't afford the cost.

**Plan B:** Default to brimonidine 0.2% and dorzolamide 2% to be used first thing in the morning (be sure to instruct the patient to always wait a few minutes between instillation of the two drops), and then second instillations around 4pm to 5pm. Of note, while brinzolamide is in Simbrinza, when prescribing an individual carbonic anhydrase inhibitor, we default to the generic dorzolamide because it is less expensive and is a solution, thus it requires no shaking before instillation.

**Problem:** You prescribe Lotemax gel drops off label for a patient with dry eye disease, only to be told that it is either too expensive or not on the formulary.

**Plan B:** Try coupons, or default to generic fluorometholone 0.1%. While this medicine is relatively safe, it is not as safe as loteprednol. Be sure to advise the patient that the fluorometholone must be shaken before each instillation.

**Problem:** You prescribe Zylet or generic TobraDex for Staphylococcal blepharitis, only to be told that it is too expensive or not on the patient's formulary.

**Plan B:** Offer coupons if they are available, or default to generic Maxitrol if it will be used for less than two weeks. Be aware that there is a slight potential for prednisone allergic reaction, or increased intraocular pressure from the dexamethasone, which may occasionally be bothersome. Zylet, generic TobraDex and generic Maxitrol are all suspensions, and must be shaken before each use.

**Problem:** You prescribe prednisolone acetate for an episcleritis, but the patient is dismayed by its high price.

**Plan B:** Consider generic Maxitrol, ignoring the antibiotic component; it is a cheap way to get access to a decent steroid when push comes to shove. Another option is generic prednisolone sodium phosphate, which works well for ocular surface conditions and requires no shaking.

**Problem:** You Rx Lotemax ointment or FML ophthalmic ointment, but the expense is a concern for the patient.

**Plan B:** Try generic Blephamide ointment or Maxitrol ointment, ignoring the antibiotic components of these two drugs. If you are treating contact blepharodermatitis, just go with triamcinolone 0.1% cream, proactively explaining to the patient that the tube will state "not for ophthalmic use," but that it is safe to use the drug, as this is a bureaucratic statement, not a clinically relevant one. Note: Kenalog (triamcinolone) is commonly injected intravitreally and we have never seen a problem with use of triamcinolone cream, even if some happens to get in the eyes.

Prescribing has never been so fraught with barriers and inconveniences. It's like playing chess: One must be fully aware of all potential moves of the adversary (in this case, the insurance companies) at all times, and be ready with an effective countermove. This often requires thinking outside the box, and you must have a comprehensive knowledge of all available drugs. Sometimes, after a point-counterpoint with a pharmacist, we finally just say, "Tell me what you have," and work from there to find a medicine that is either affordable or on the patient's formulary.

