
Hill's Atlas

of Veterinary

Clinical Anatomy

Contents

1 Introduction

Cardiovascular and Lymphatic Systems

2 Normal Heart
3 Chronic Valvular Disease
4 Normal Canine Heart
5 Heartworm Disease
6 Normal Canine Heart
7 Canine Dilated Cardiomyopathy
8 Normal Feline Heart
9 Feline Hypertrophic Cardiomyopathy
10 Normal Feline Heart
11 Feline Dilated Cardiomyopathy
12 Normal Lymph Node Architecture
13 Lymphosarcoma

Digestive System

14 Normal Feline Dentition
15 Periodontal Disease
16 Normal Canine Dentition
17 Carnassial Tooth Abscess
18 Normal Stomach
19 Hemorrhagic Gastritis with Ulcers
20 Normal Stomach
21 Gastric Dilatation with Volvulus
22 Normal Small Intestine
23 Foreign Bodies
24 Parvoviral Enteritis
25 Intussusception
26 Normal Canine Colon
27 Chronic Colitis

28 Normal Feline Colon
29 Constipation/Colonic Impaction

30 Normal Pancreas
31 Acute Pancreatitis
32 Normal Pancreas
33 Exocrine Pancreatic Insufficiency

34 Normal Liver
35 End-Stage Liver Disease

36 Normal Liver
37 Hepatic Neoplasia

Integumentary System

38 Normal Skin/Perineal Anatomy
39 Anal Sac Abscess
40 Skin Abscess
41 Flea-Allergy Dermatitis

Musculoskeletal System

42 Normal Vertebrate/Spinal Cord
43 Intervertebral Disk Disease
44 Normal Shoulder
45 Osteochondritis Dissecans
46 Normal Elbow
47 Ununited Anconeal Process/Panosteitis
48 Normal Hip Joint
49 Hip Dysplasia
50 Normal Rear Leg
51 Femoral Fracture

52 Normal Stifle
53 Ruptured Cranial Cruciate Ligament

54 Normal Stifle
55 Patellar Luxation

Respiratory System

56 Normal Mouth/Upper Airway
57 Tonsillitis

58 Normal Canine Thorax
59 Collapsing Trachea

60 Normal Feline Thorax
61 Pulmonary Edema

Urogenital System

62 Normal Canine Kidney
63 Chronic Renal Disease

64 Normal Canine Kidney
65 Acute Renal Failure

66 Normal Urinary Bladder
67 Bladder Stones

68 Normal Canine Lower Urinary System
69 Canine Urethral Obstruction

70 Normal Feline Lower Urinary System
71 Feline Lower Urinary Tract Disease

72 Normal Prostate Gland
73 Benign Prostatic Hyperplasia

74 Ovariohysterectomy
75 Pyometra

76 Canine Castration
77 Testicular Tumors

Special Senses

78 Normal Canine Eye
79 Nuclear Sclerosis/Cataracts

80 Normal Feline Eye
81 Glaucoma

82 Normal Feline Eye
83 Corneal Ulceration

84 Normal Hearing Apparatus
85 Otitis Externa/Media/Interna

Parasite Life Cycles

86 Heartworms
87 *Giardia*

88 Hookworms
89 Whipworms

90 Roundworms
91 Tapeworms (*Taenia*)

92 Tapeworms (*Dipylidium caninum*)
93 Fleas

94 Ticks
95 *Sarcoptes*

96 *Demodex*
97 *Cheyletiella*

98 Ear Mites
99 Bibliography

©2004 Hill's Pet Nutrition, Inc.
Division of Colgate-Palmolive Company.
Published by Veterinary Medicine Publishing Company, Inc.
All rights reserved. Printed in the United States of America.

Introduction

At one time or another, all of us in clinical practice have explained to clients such things as the pathology of a failing heart or a prolapsed intervertebral disk. Oftentimes, we've used radiographs or hand drawings to communicate important points. Irrespective of our artistic skills, such drawings and explanations transfer information to clients not only about specific diagnoses but also about the rationale behind therapeutic plans.

Hill's Pet Nutrition thinks client communication is vital to the success of veterinary practice. In accord with that philosophy, Hill's is proud to present the *Hill's Atlas of Veterinary Clinical Anatomy*[™] - an in-exam room atlas to heighten client communications.

Each illustration in the *Atlas* has been drawn by professional medical illustrators. Generally, the left-hand page depicts normal anatomy, and the right-hand page a pathologic presentation. A brief outline of diagnostic, therapeutic, and dietary plans is included on the right-hand page. This arrangement will allow you to show clients normal anatomy and the pathology affecting their pets while you describe how your therapeutic plan will, if possible, return their pets to health and normal anatomy.

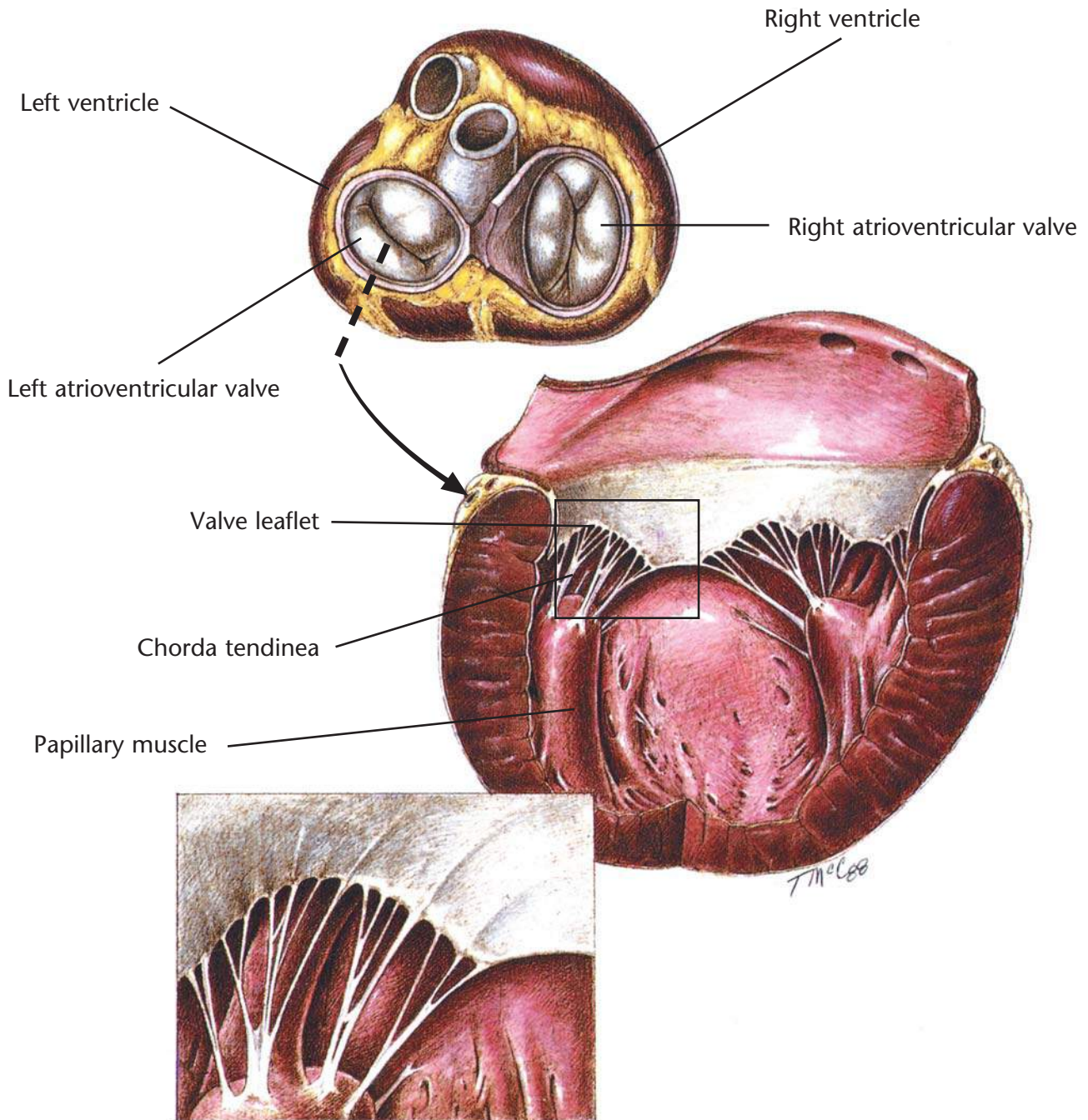
The *Atlas* contains eight sections. Refer to the contents

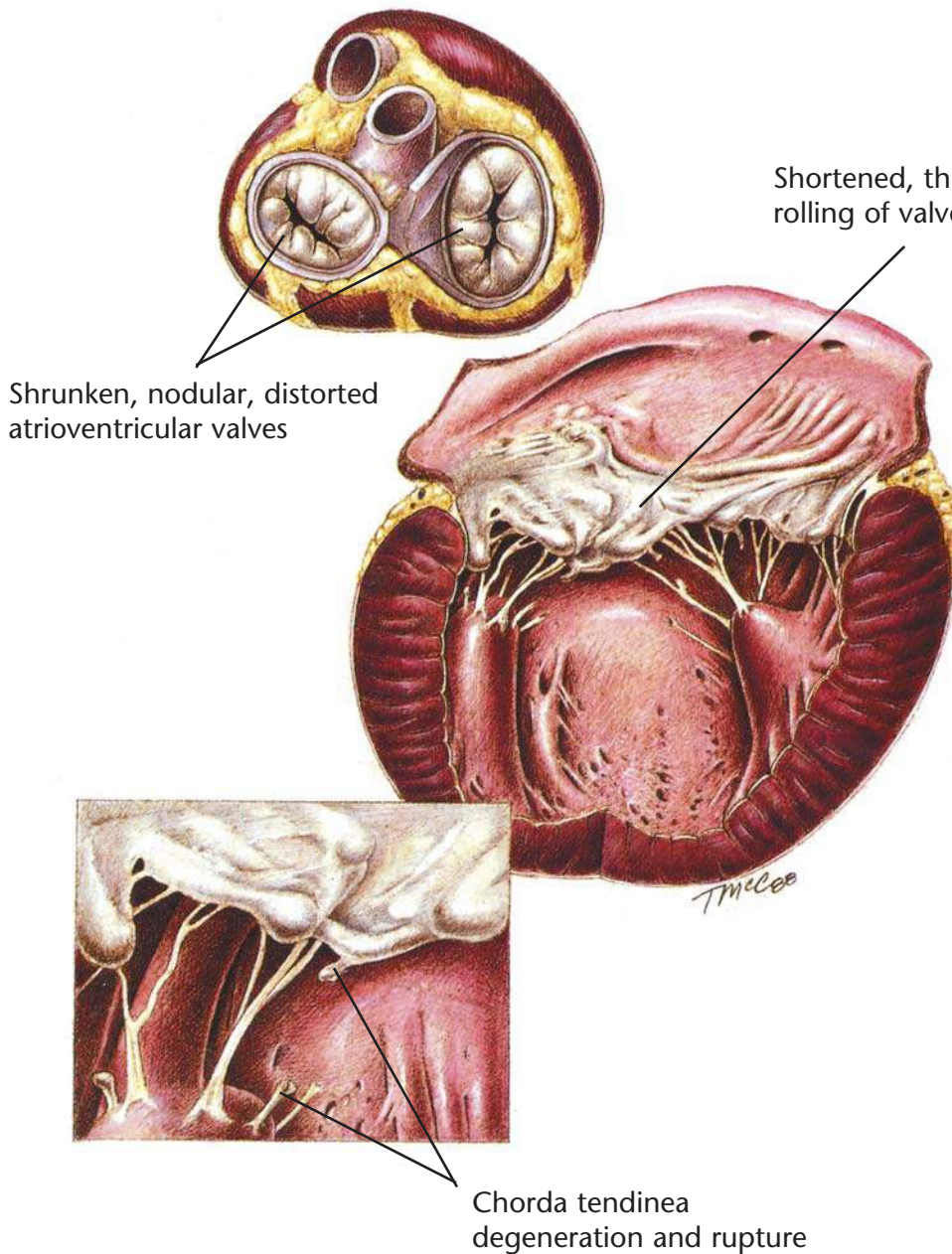
pages for the page numbers and color assigned to each section. These blocks of color are placed around the page numbers at the top of each page. Each section has been assigned a different color for ease of use.

Every effort has been made to ensure the accuracy of the medical illustrations and the diagnostic, therapeutic, and nutritional plans in the *Atlas*. For example, each illustration has been reviewed by appropriate veterinary faculty at the College of Veterinary Medicine, Colorado State University. The *Atlas* is not intended to be an exhaustive review of anatomy, pathology, or medicine. For more information, consult the Bibliography, refer to prescribing information on specific drugs, or call Hill's Veterinary Consultation Service at 1-800-548-VETS (8387) or e-mail vet_consult@HillsPet.com.

The *Atlas* contains illustrations of the most common conditions seen in clinical practice. Therefore, its proper place is in the exam room, so you can use it daily to enhance client education.

Hill's Pet Nutrition, Inc.





Chronic Valvular Disease

Diagnostic Plan

- History
- Physical examination
- Chest auscultation
- Chest palpation
- Blood work
- Urinalysis
- Chest x-rays
- Electrocardiography
- Heartworm check
- Echocardiography
- Angiocardiography

Therapeutic Plan

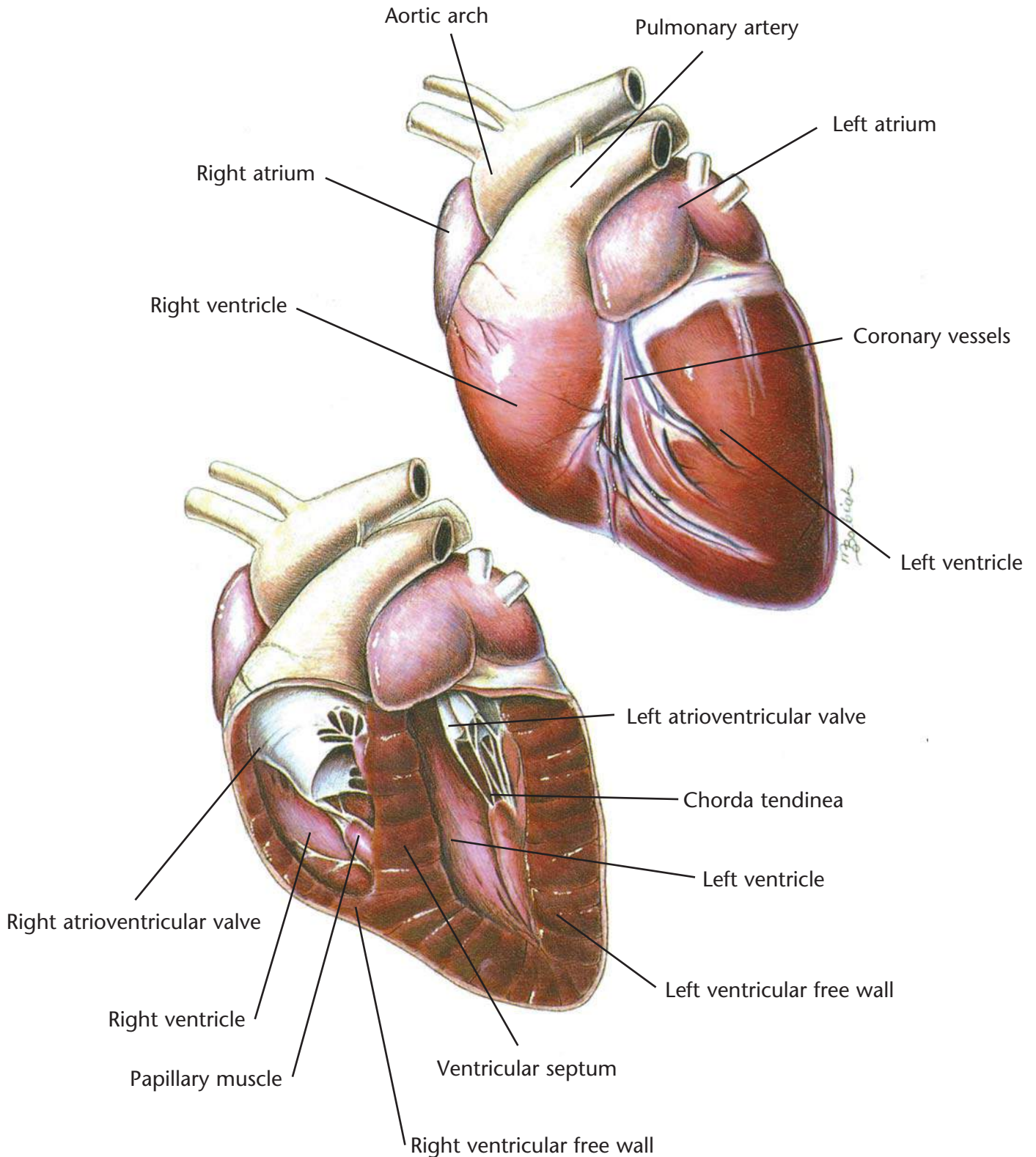
- Drugs to strengthen the heart
- Diuretics
- Drugs that dilate blood vessels
- Drugs that correct abnormal heart rhythms
- Exercise restriction

Dietary Plan

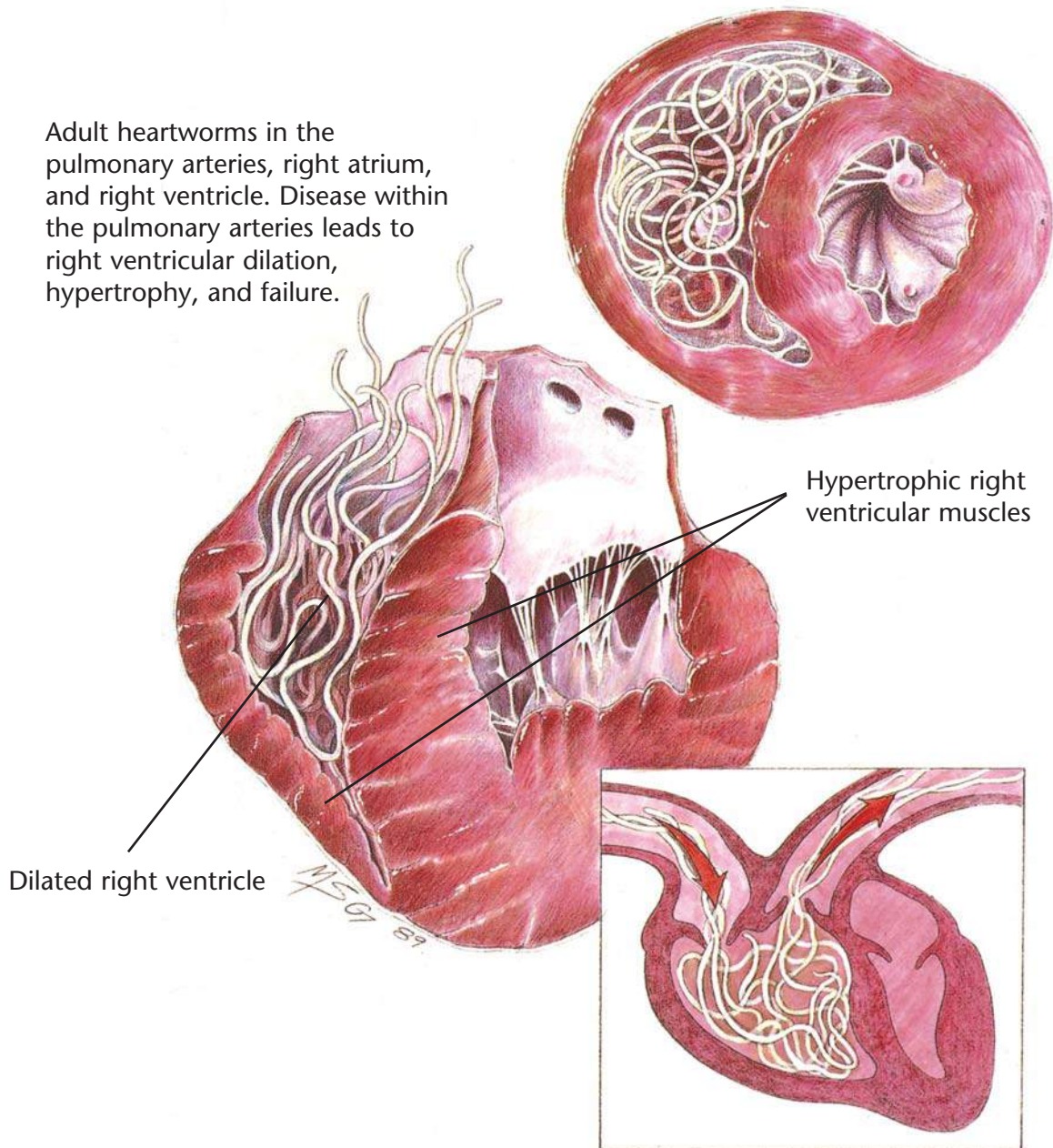
- A mildly restricted sodium diet or a moderately restricted sodium diet
- If necessary, change to a severely restricted sodium diet

Hill's Atlas of Veterinary Clinical Anatomy

Normal Canine Heart



Adult heartworms in the pulmonary arteries, right atrium, and right ventricle. Disease within the pulmonary arteries leads to right ventricular dilation, hypertrophy, and failure.



Heartworm Disease

Diagnostic Plan

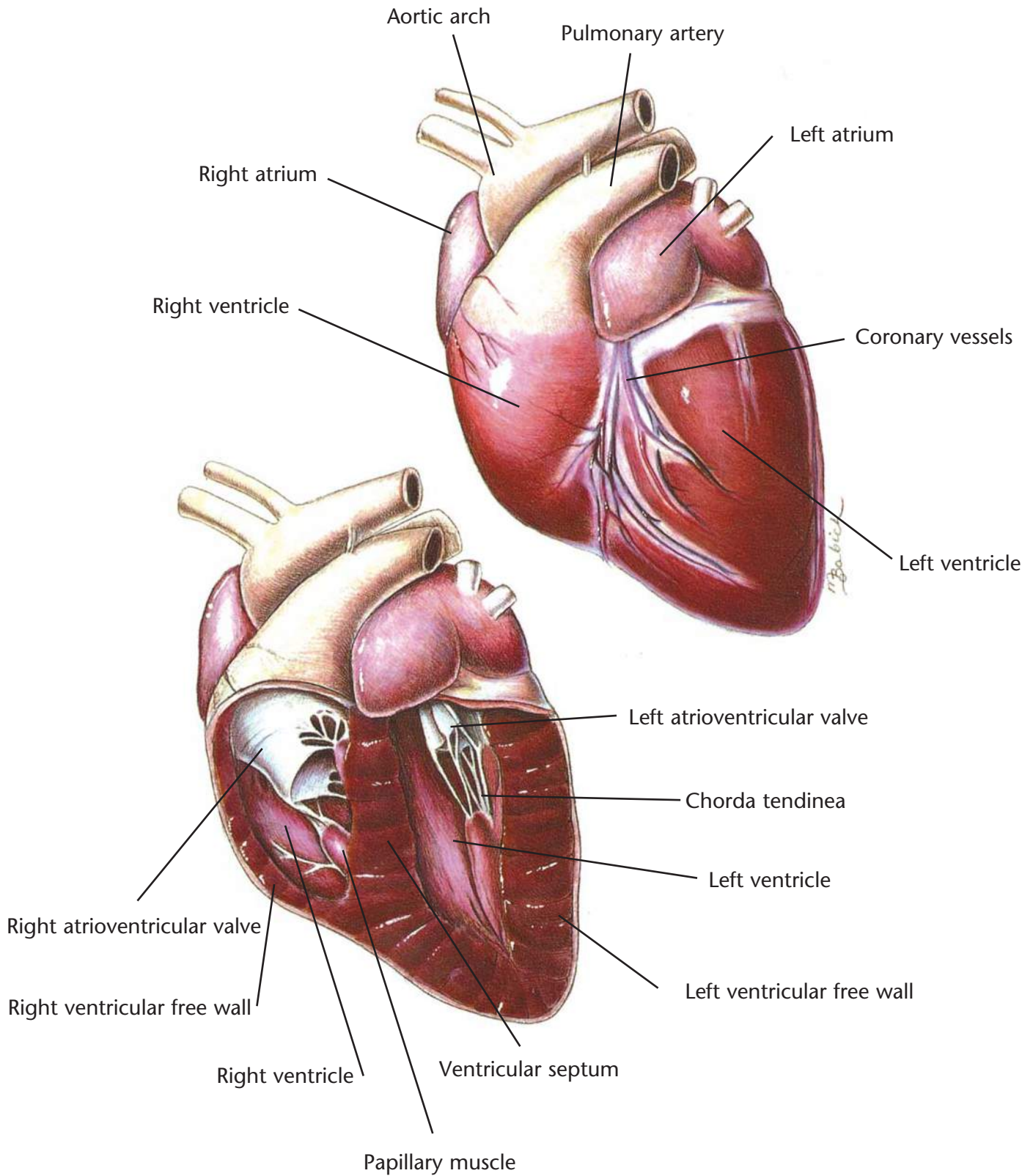
History
Physical examination
Heartworm check
Blood work
Urinalysis
Chest x-rays
Electrocardiography
Echocardiography

Therapeutic Plan

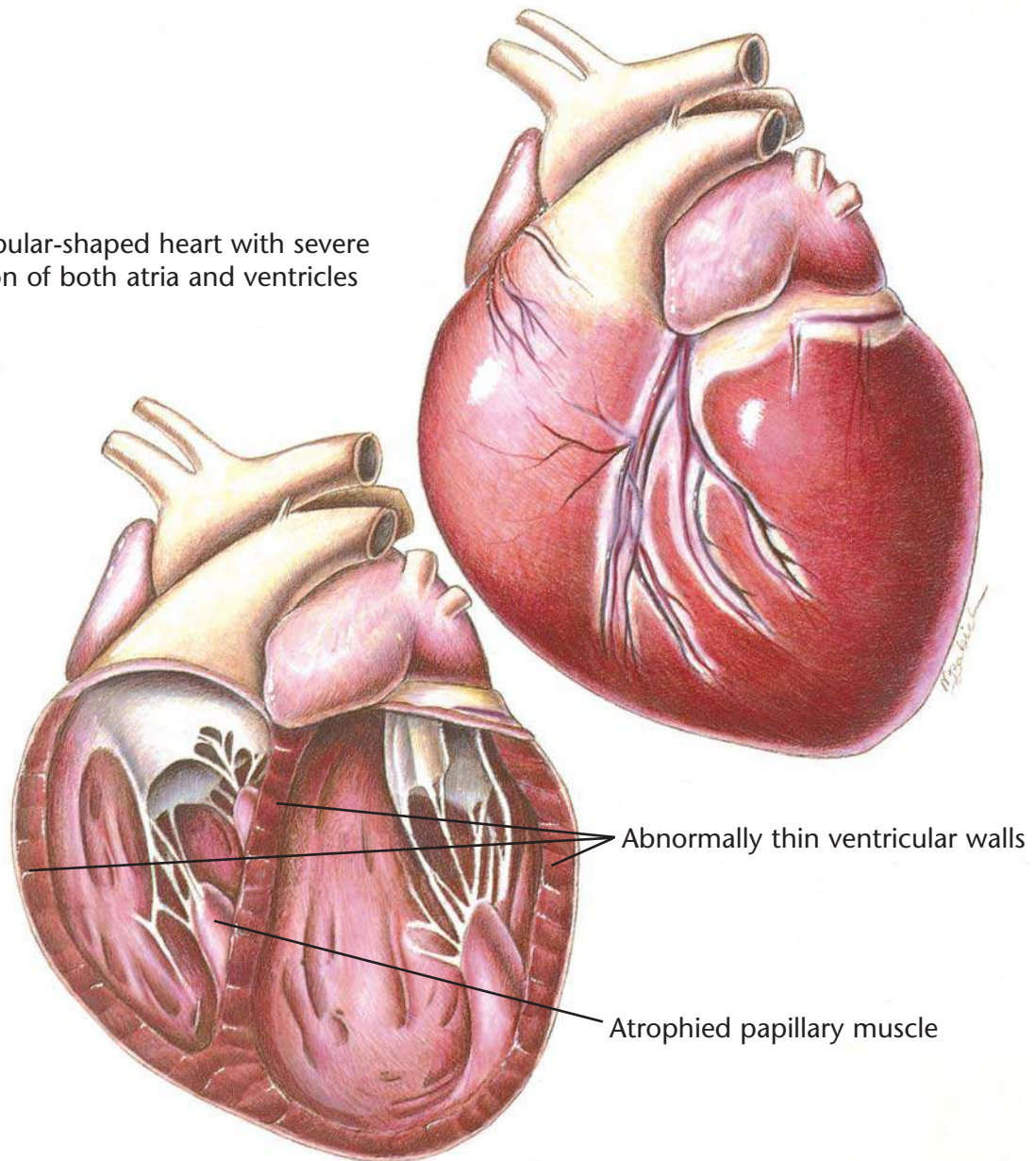
Drugs to kill adult worms
Restricted exercise
Aspirin
Corticosteroids
Drugs to kill larvae
in the bloodstream
Prevention
Surgery

Dietary Plan

A diet with controlled levels of protein, phosphorus and sodium
Consider body condition



A globular-shaped heart with severe dilation of both atria and ventricles



Canine Dilated Cardiomyopathy

Diagnostic Plan

History
Physical examination
Urinalysis
Blood work
Chest x-rays
Electrocardiography
Echocardiography
X-rays of the heart after dye injection

Therapeutic Plan

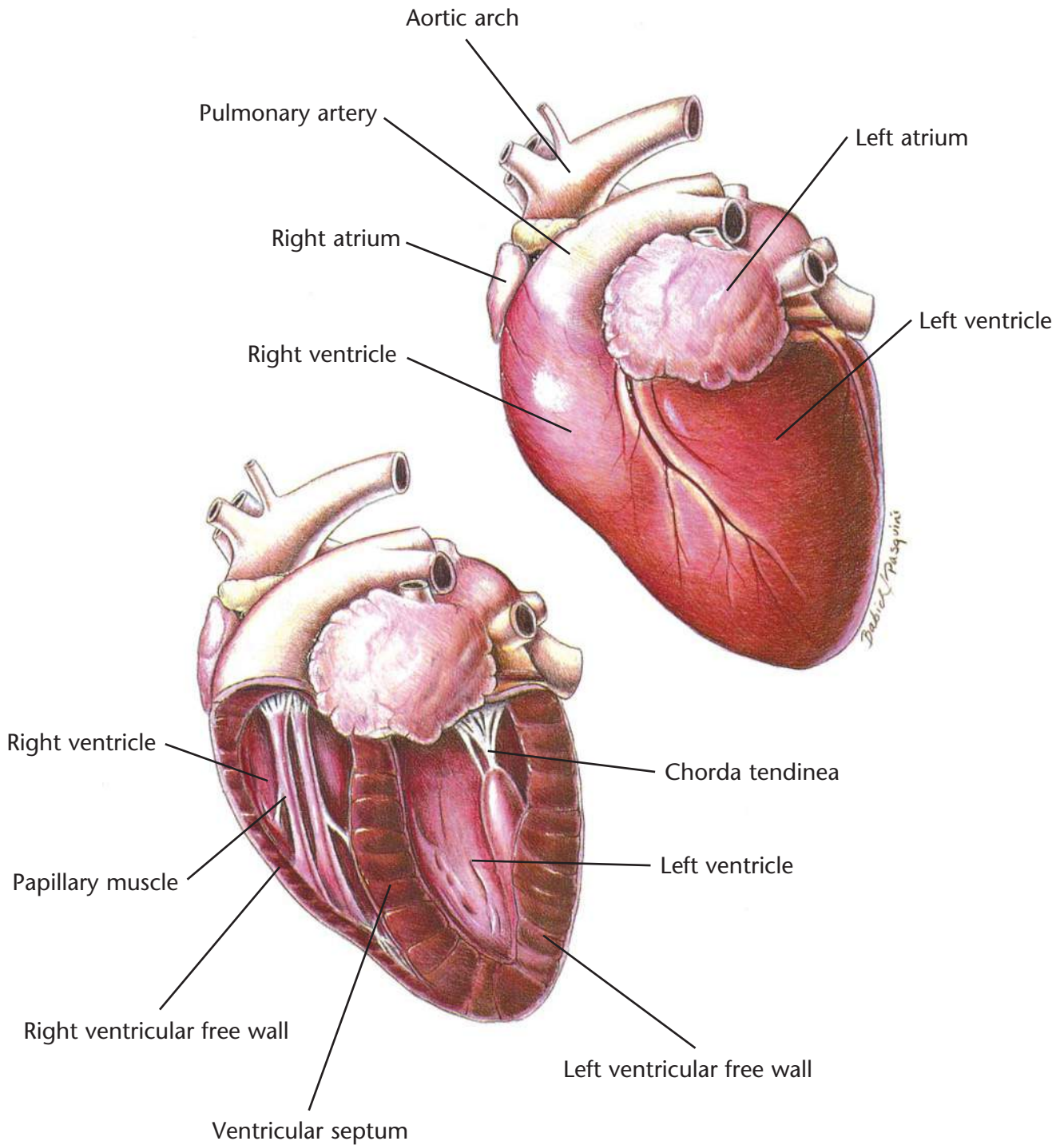
Enforced rest
Removal of fluid from the chest and abdomen
Diuretics
Drugs that strengthen the heart
Drugs that dilate blood vessels
Bronchodilators
Oxygen therapy

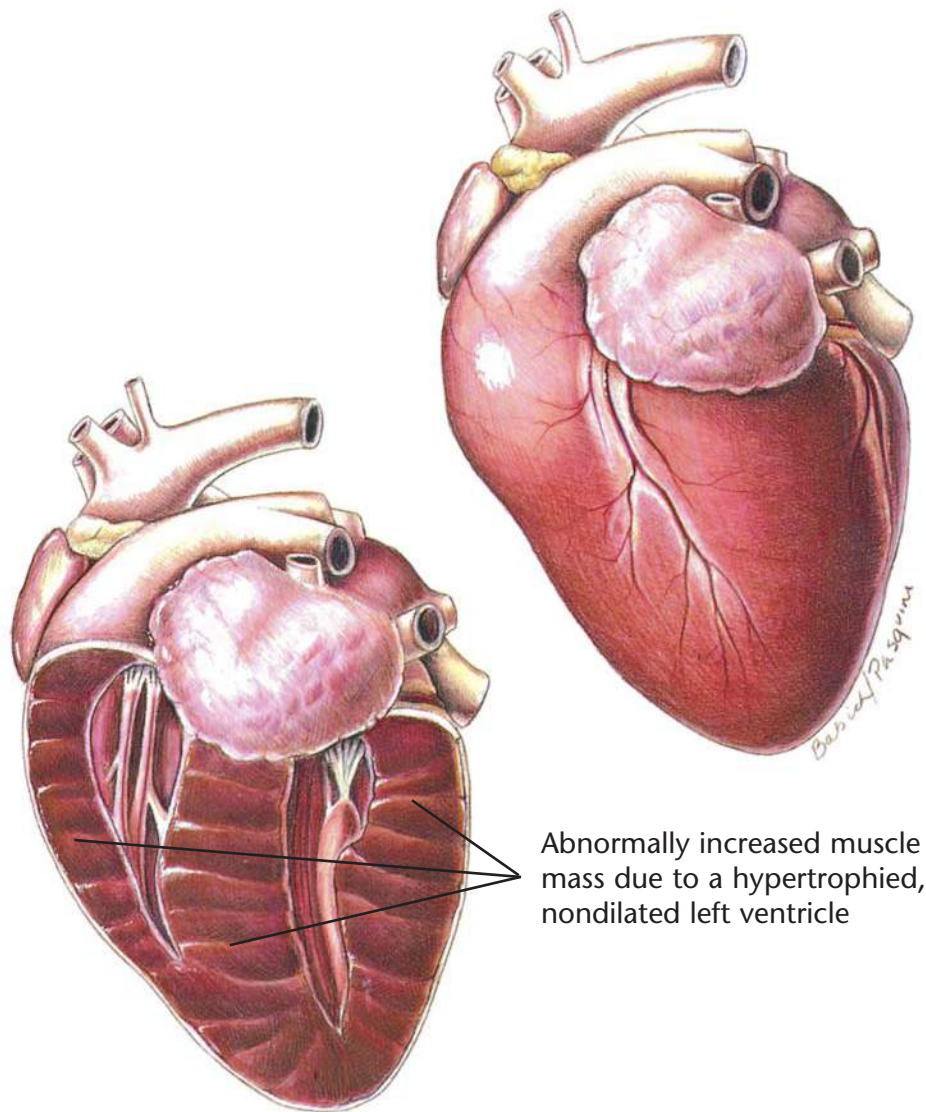
Dietary Plan

A diet that avoids excess levels of sodium

Hill's Atlas of Veterinary Clinical Anatomy

Normal Feline Heart





Feline Hypertrophic Cardiomyopathy

Diagnostic Plan

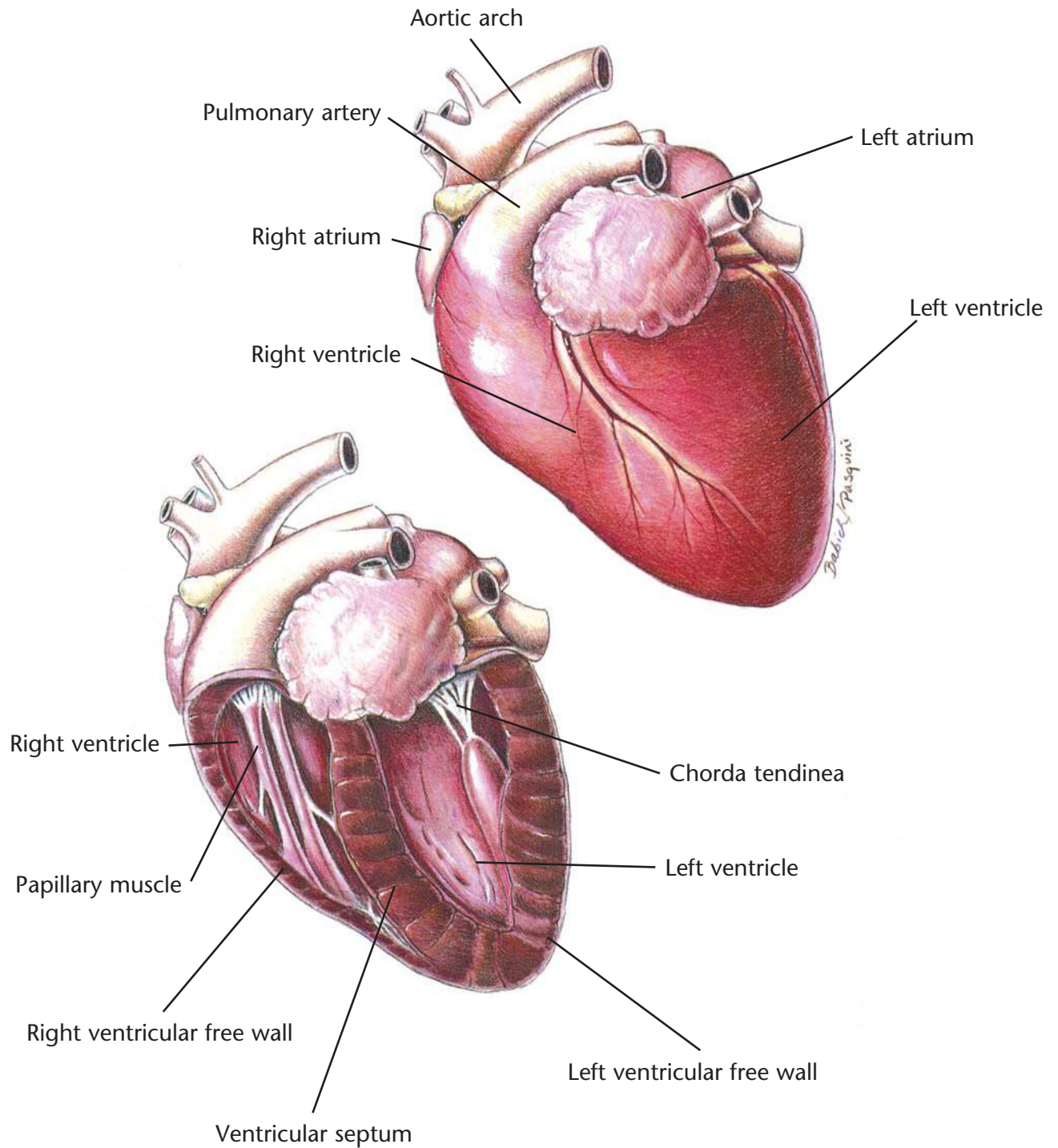
History
Physical examination
Chest auscultation
Palpation of femoral pulses
and hindlimb musculature
Blood work
Urinalysis
Electrocardiography
Chest x-rays
Echocardiography
X-rays of the heart and
abdominal blood vessels
after dye injection

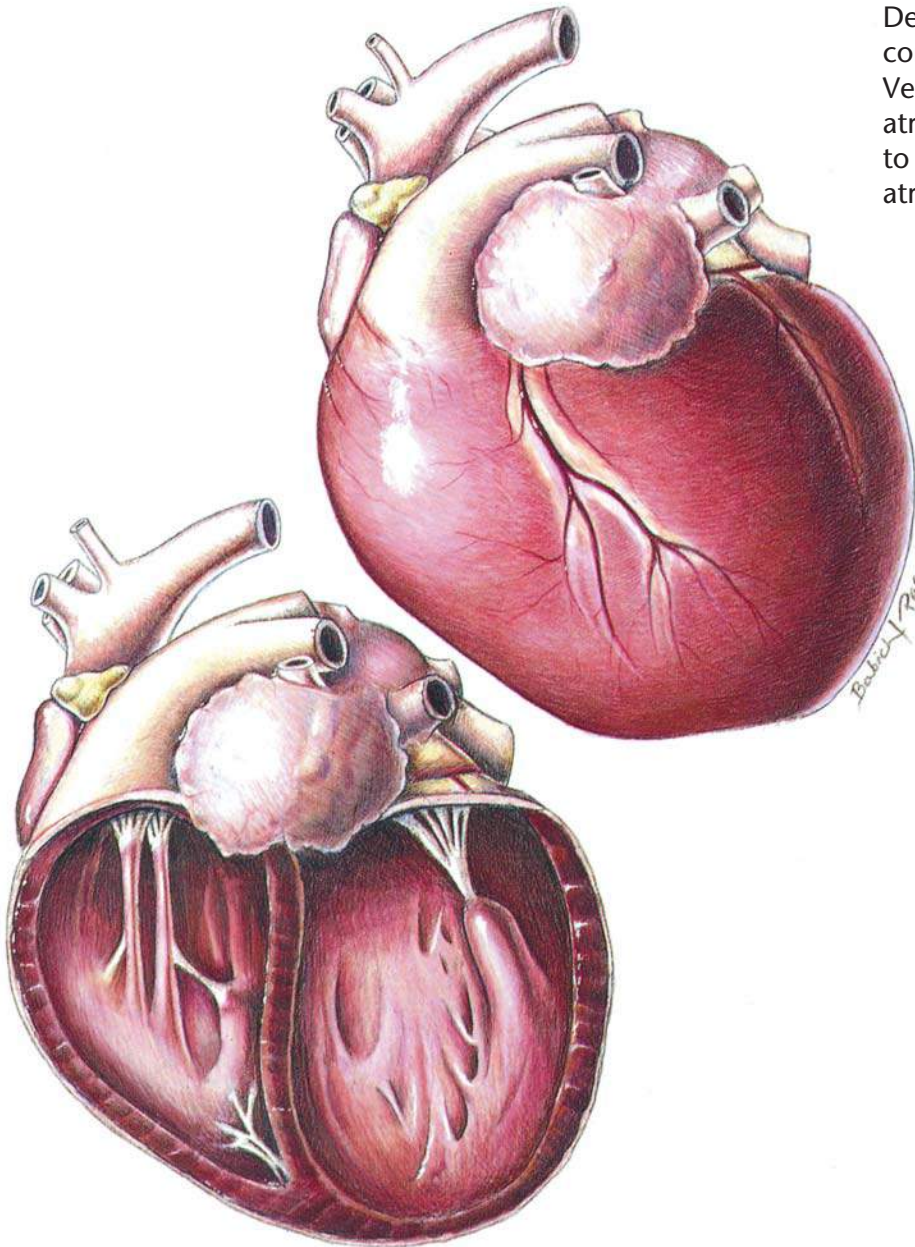
Therapeutic Plan

Enforced rest
Bronchodilators
Oxygen therapy
Removal of fluid from
the chest and abdomen
Drugs that dilate blood vessels
Aspirin
Beta blockers
Heparin
Surgery

Dietary Plan

A diet that avoids excess
levels of sodium





A globular heart with severe dilation of the four chambers. Depressed ventricular contractile performance occurs. Ventricular dilation distorts the atrioventricular valves leading to mitral regurgitation and atrial enlargement.

Feline Dilated Cardiomyopathy

Diagnostic Plan

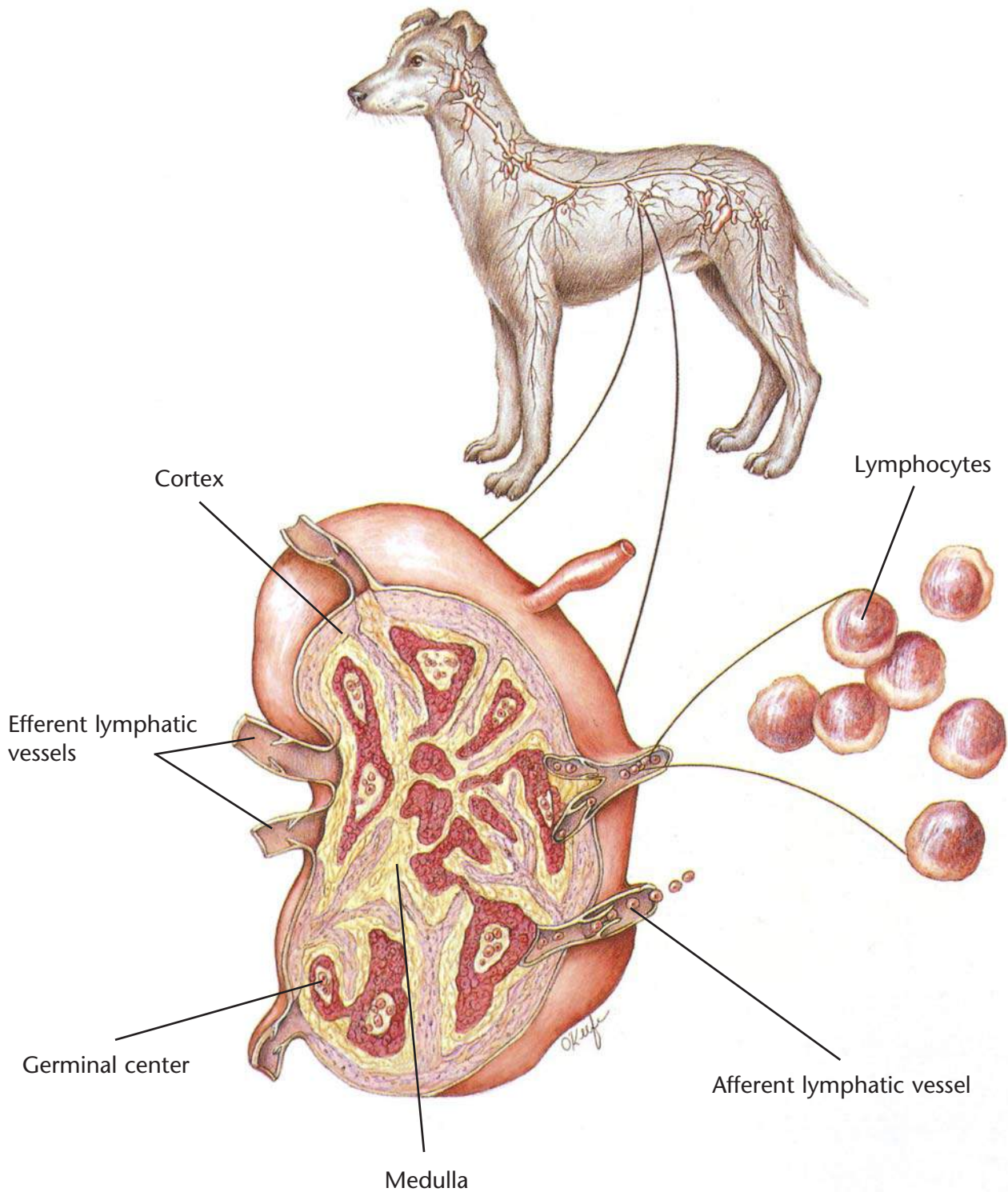
History
Physical examination
Chest auscultation
Palpation of femoral pulses and hindlimb musculature
Blood work
Urinalysis
Electrocardiography
Chest x-rays
Echocardiography
X-rays of the heart and abdominal blood vessels after dye injection
Plasma taurine analysis

Therapeutic Plan

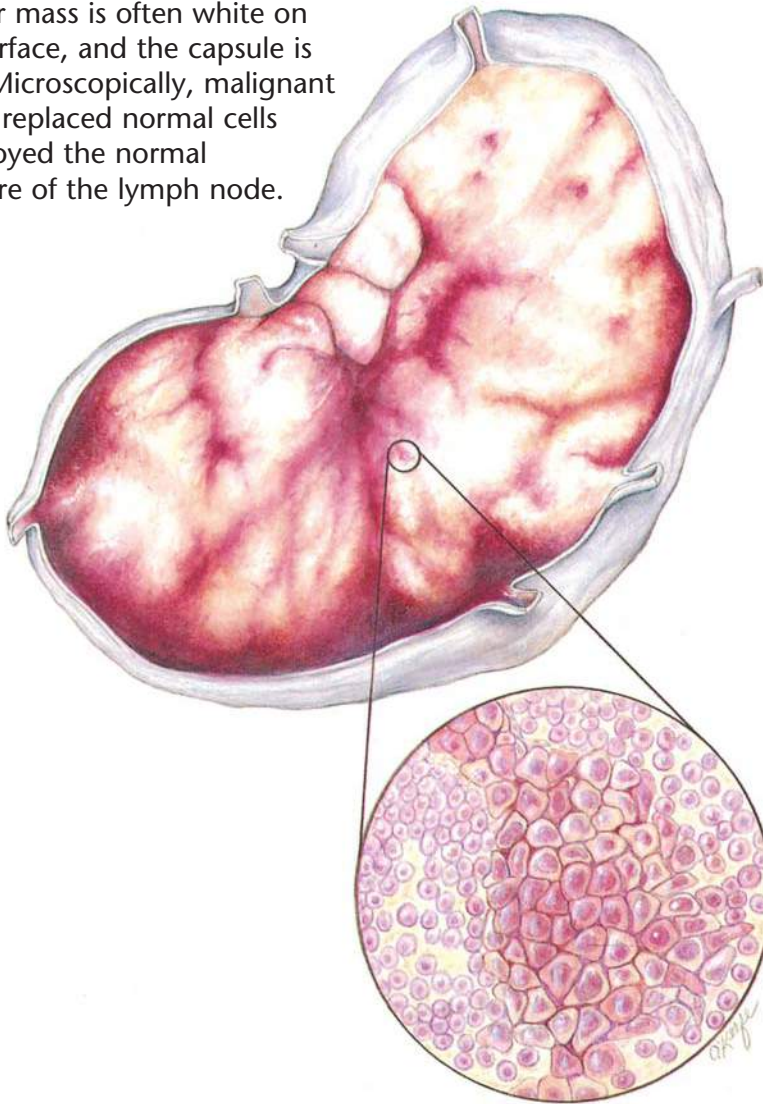
Enforced rest
Diuretics
Bronchodilators
Oxygen therapy
Removal of fluid from the chest and abdomen
Drugs that dilate blood vessels
Drugs that strengthen the heart
Heparin
Surgery

Dietary Plan

A diet that contains adequate levels of taurine and avoids excess levels of sodium



The tumor mass is often white on the cut surface, and the capsule is thinned. Microscopically, malignant cells have replaced normal cells and destroyed the normal architecture of the lymph node.



Lymphosarcoma

Diagnostic Plan

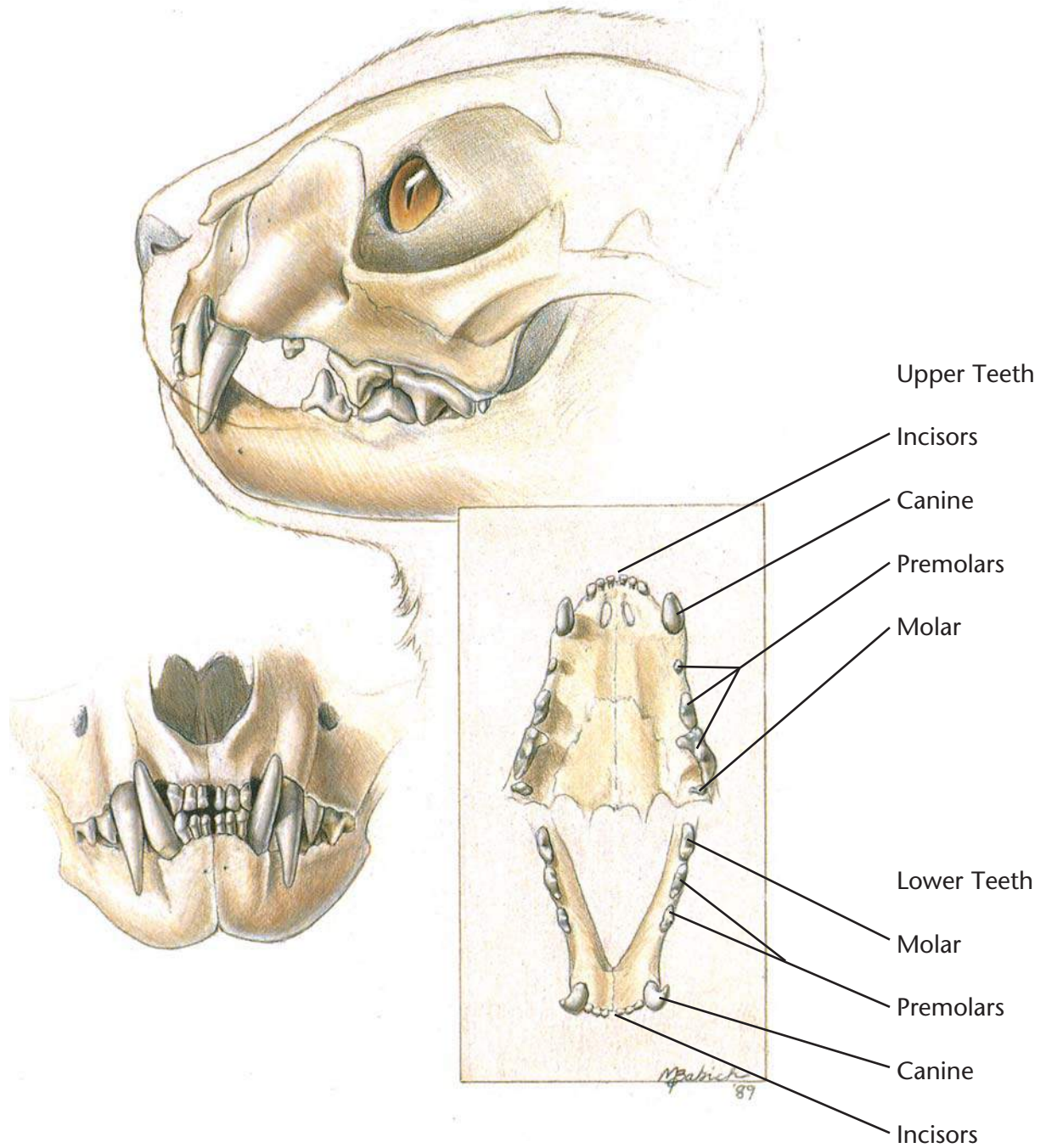
- History
- Physical examination
- Blood work
- FeLV test (for cats)
- X-rays
- Urinalysis
- Biopsy of tissue
- Cell studies
- Endoscopy
- Exploratory surgery
- Examinations of chest and abdominal fluid
- Bone marrow biopsy
- Cerebral spine fluid examination

Therapeutic Plan

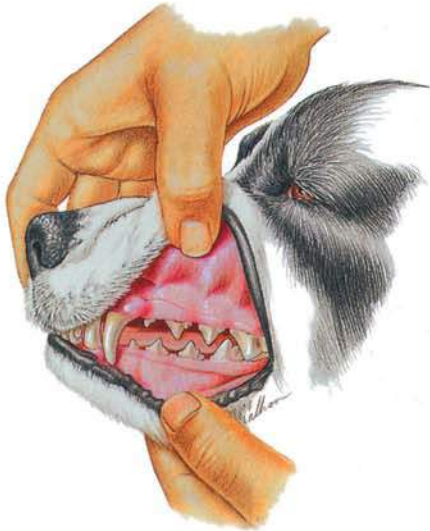- Supportive therapy
- Chemotherapy
- Surgical excision
- Radiation

Dietary Plan

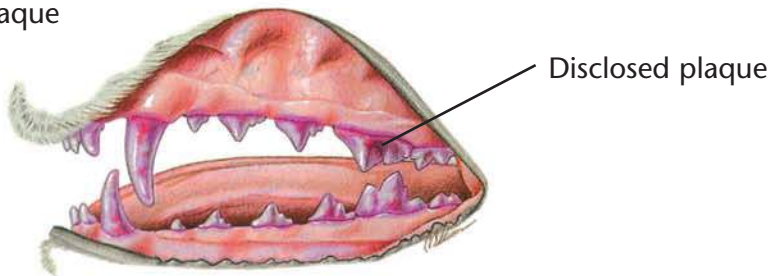
A diet based on individual patient evaluation including body condition and other organ system involvement or disease



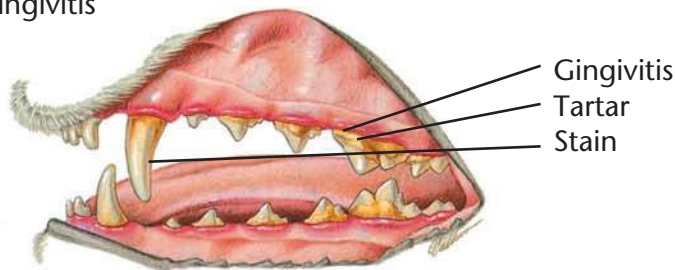
Normal Dental Examination



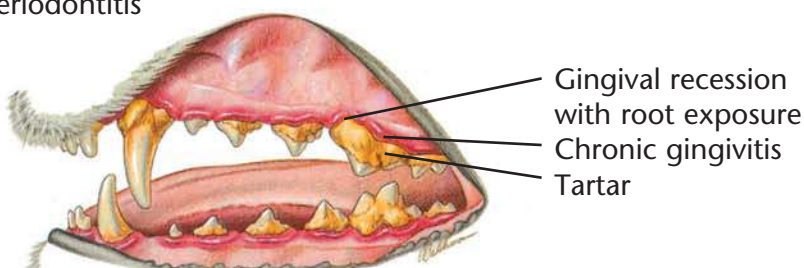
Plaque



Gingivitis



Periodontitis



Periodontal Disease

Diagnostic Plan

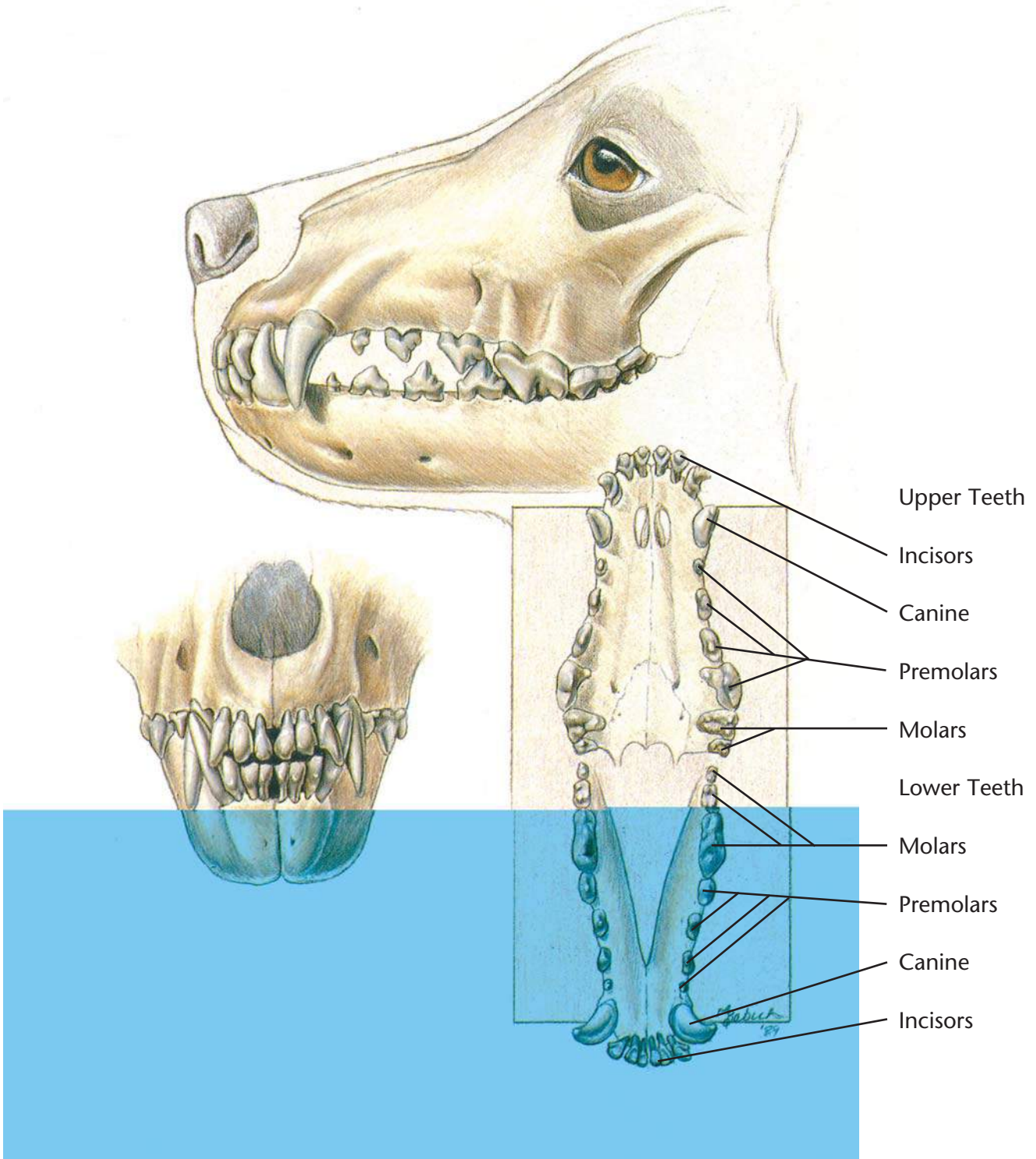
History
Physical examination
Oral examination
Dental x-rays

Therapeutic Plan

Tooth scaling above and below the gumline
Tooth polishing
Extraction
Surgery
Antibacterials
Tooth brushing

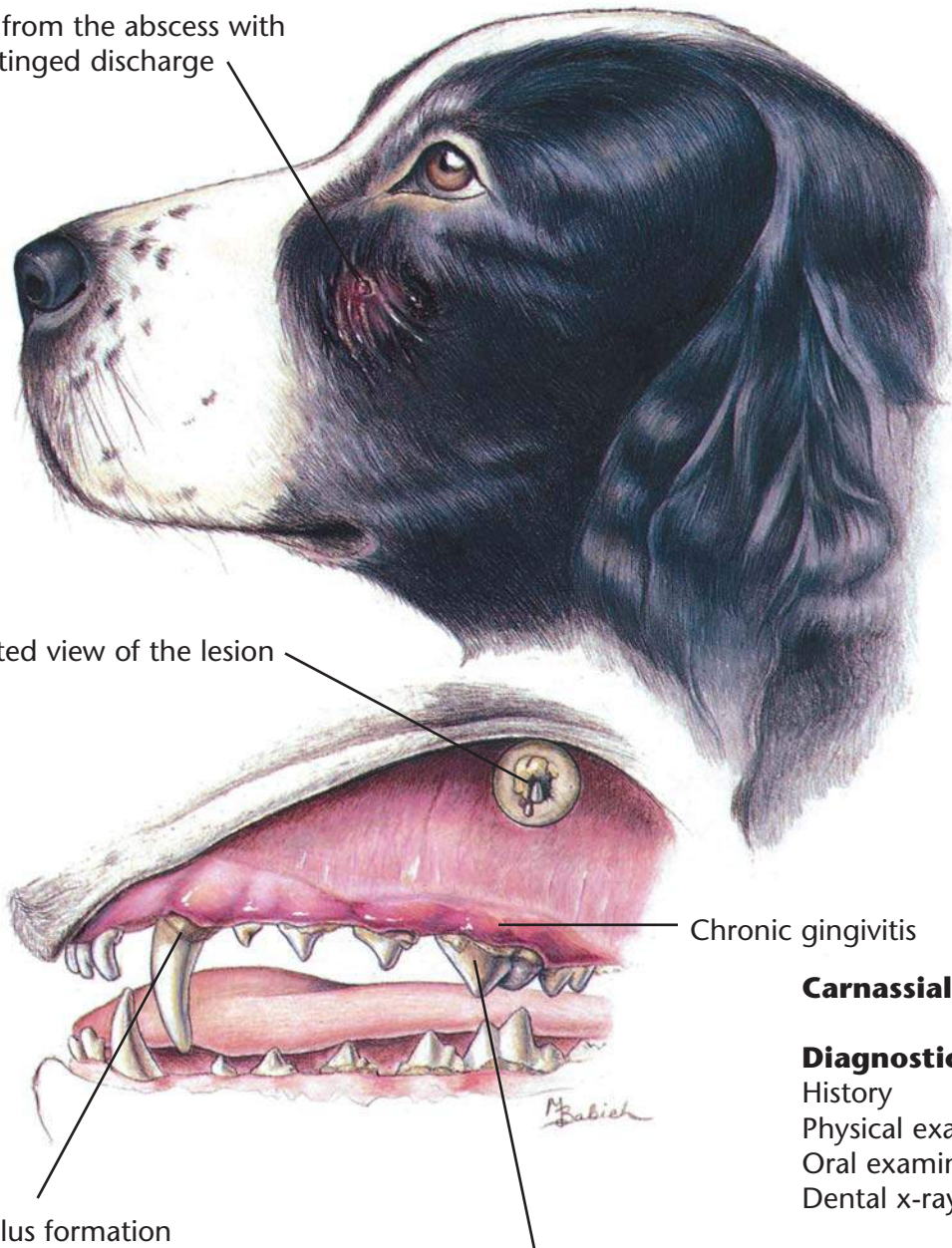
Dietary Plan

Postsurgery or extractions, a food with nutritional characteristics that support tissue repair. A soft food may minimize postprocedural discomfort. Long term, a food with formulation and texture that slows the accumulation of plaque and tartar.



Fistula from the abscess with
blood-tinged discharge

Dissected view of the lesion



Chronic gingivitis

Calculus formation

Carnassial tooth

Carnassial Tooth Abscess

Diagnostic Plan

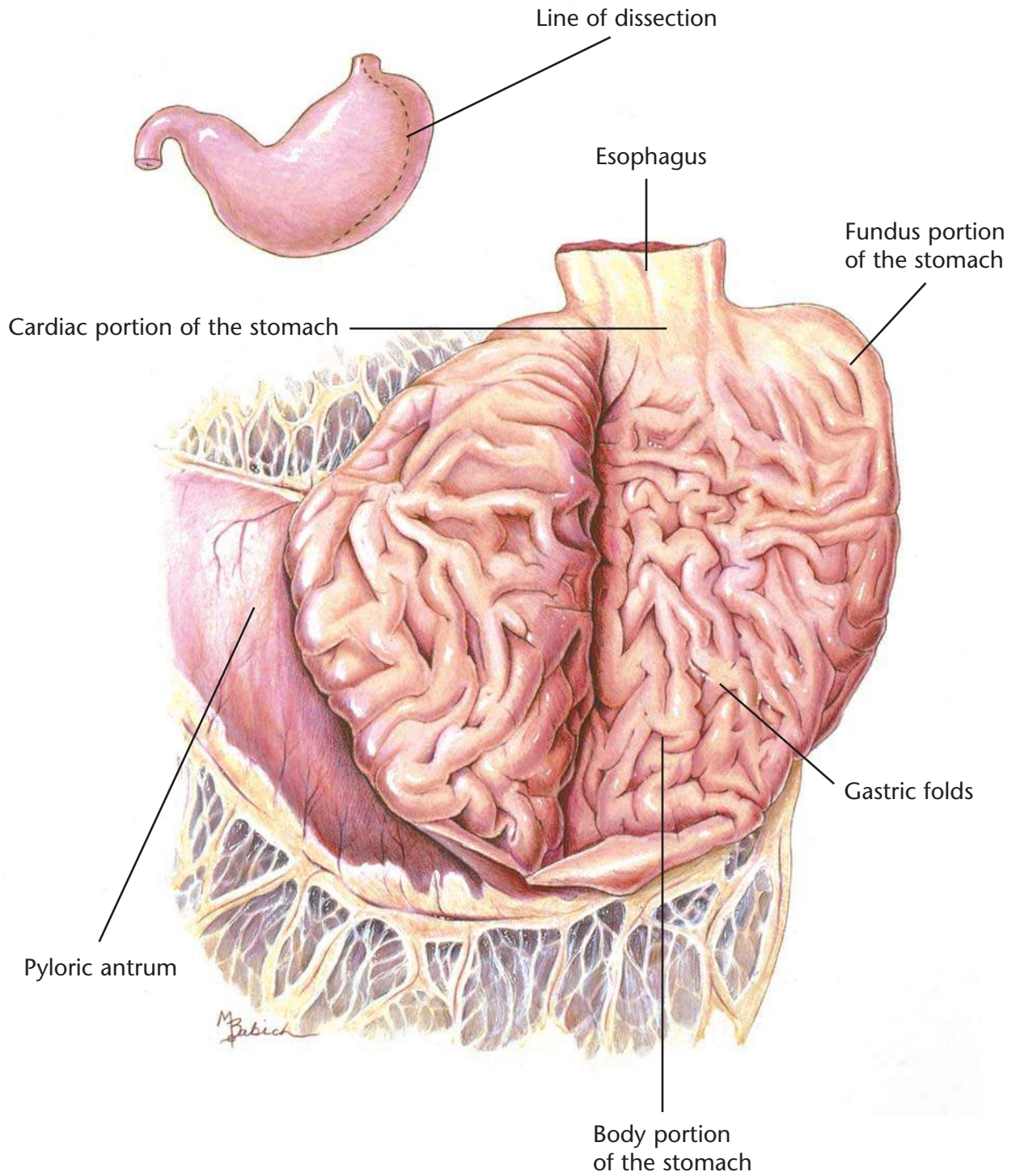
History
Physical examination
Oral examination
Dental x-rays

Therapeutic Plan

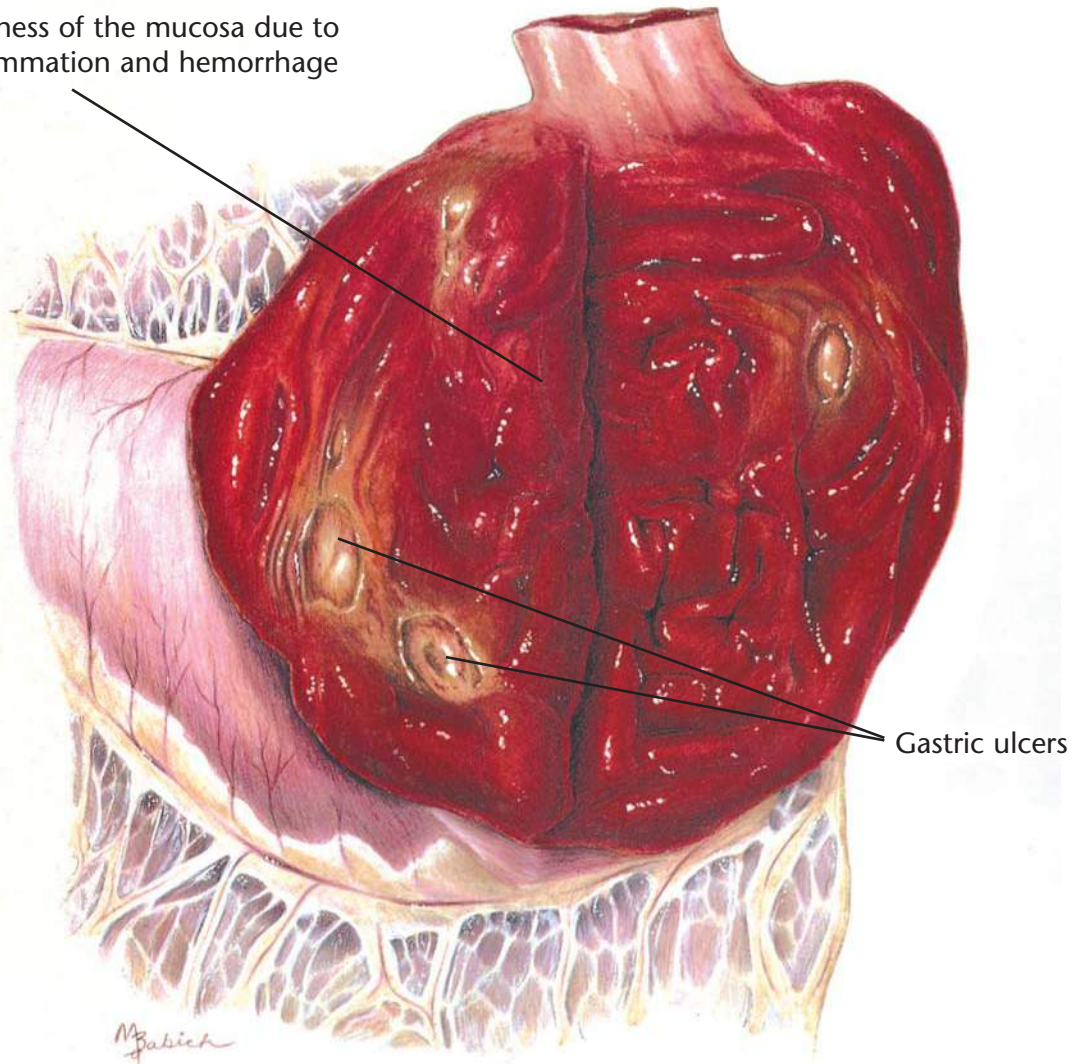
Tooth extraction
Root canals
Antibiotics

Dietary Plan

A diet based on overall patient evaluation including body condition and other organ system involvement
A soft diet may minimize postsurgical pain



Diffuse redness of the mucosa due to active inflammation and hemorrhage



Gastric ulcers

Hemorrhagic Gastritis with Ulcers

Diagnostic Plan

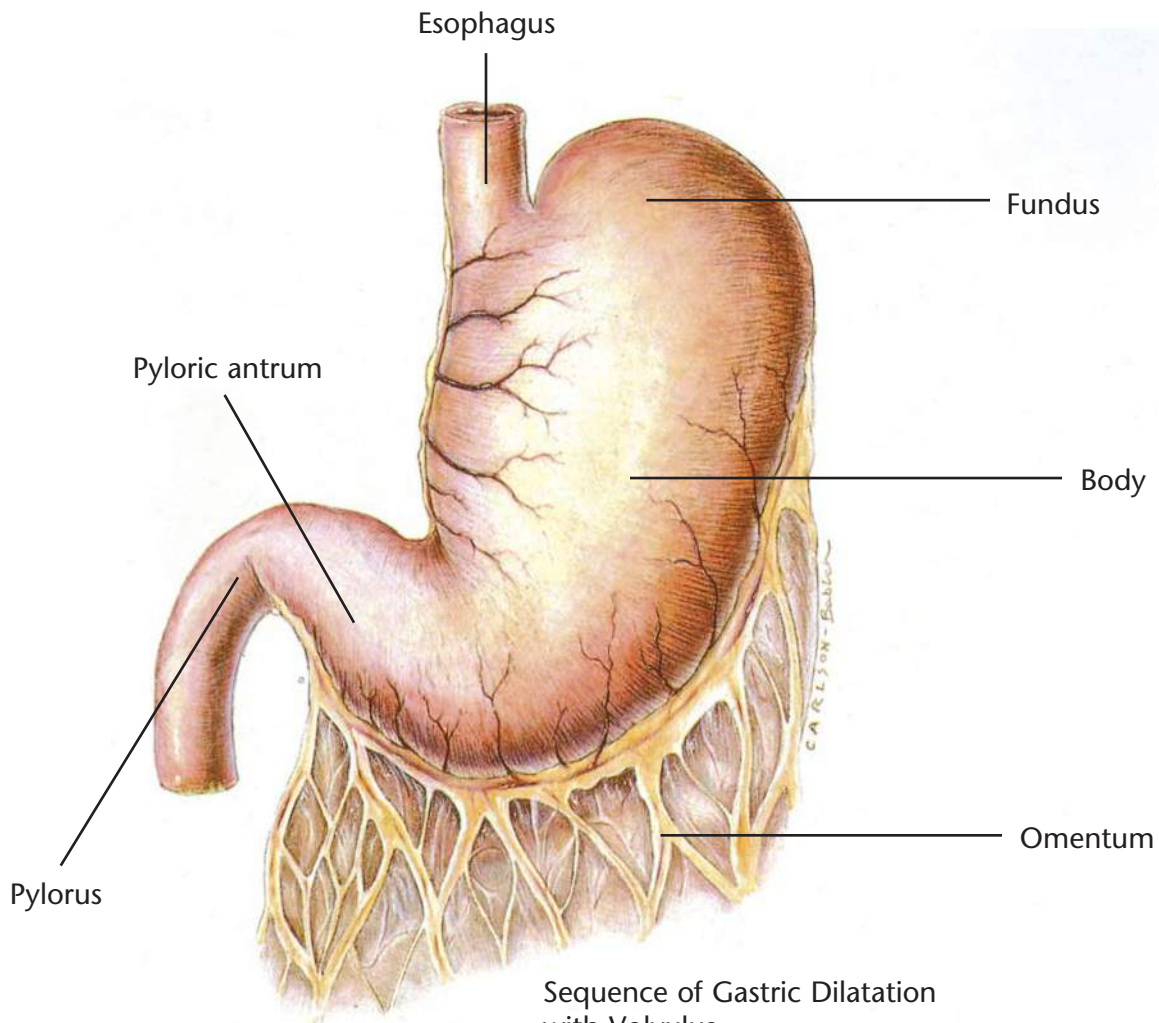
- History
- Physical examination
- Blood work
- Stool check for blood
- Stool check for parasites
- Urinalysis
- X-rays of the stomach
- Endoscopy
- Gastric fluid analysis
- Gastric biopsy

Therapeutic Plan

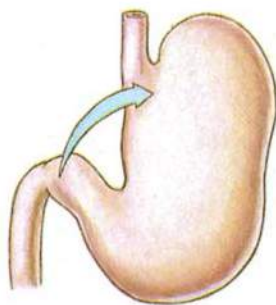
- Nothing orally for 12 to 24 hours
- Fluid therapy
- Gastric lavage
- Antiemetic drugs
- Whole blood
- Drugs to inhibit gastric acid secretion
- Surgery

Dietary Plan

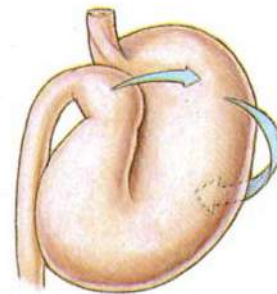
- A diet based on overall patient evaluation including body condition and other organ systems
- A diet with moderate protein and moderate to low levels of fat and fiber to minimize dietary-induced delays in gastric emptying
- For pets with gastritis caused by food allergy, a hypoallergenic diet



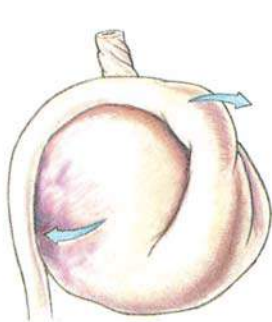
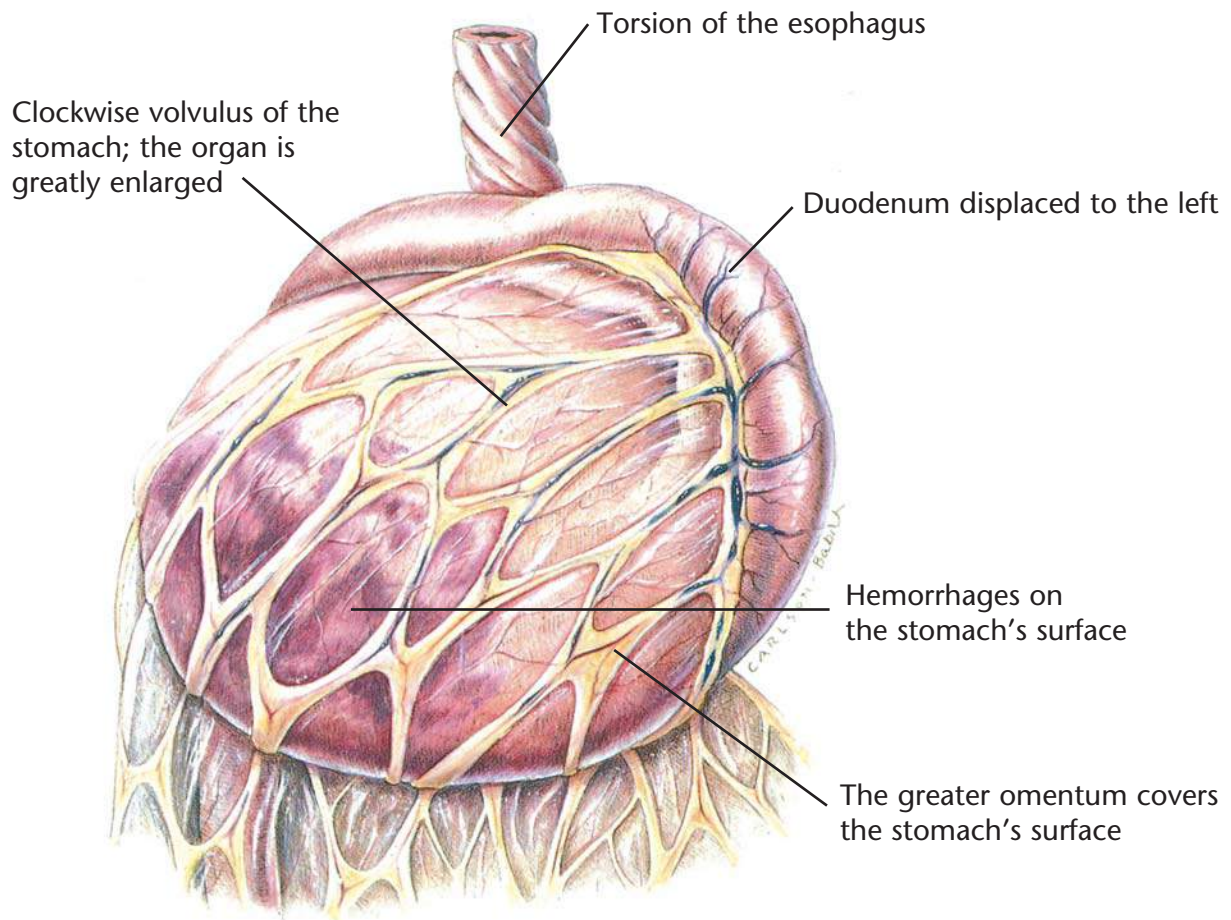
Clockwise rotation as viewed from a ventral position



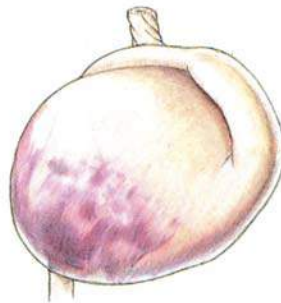The pyloric antrum is displaced downward.



The pylorus crosses the midline, passes underneath the distended proximal part of stomach, and moves upward along the left abdominal wall.



The gastric fundus moves ventrally and becomes located in the ventral abdomen.



The continuing gastric dilatation displaces the greater curvature ventrally.

Gastric Dilatation with Volvulus

Diagnostic Plan

- History
- Physical examination
- X-ray of the stomach
- Blood work

Therapeutic Plan

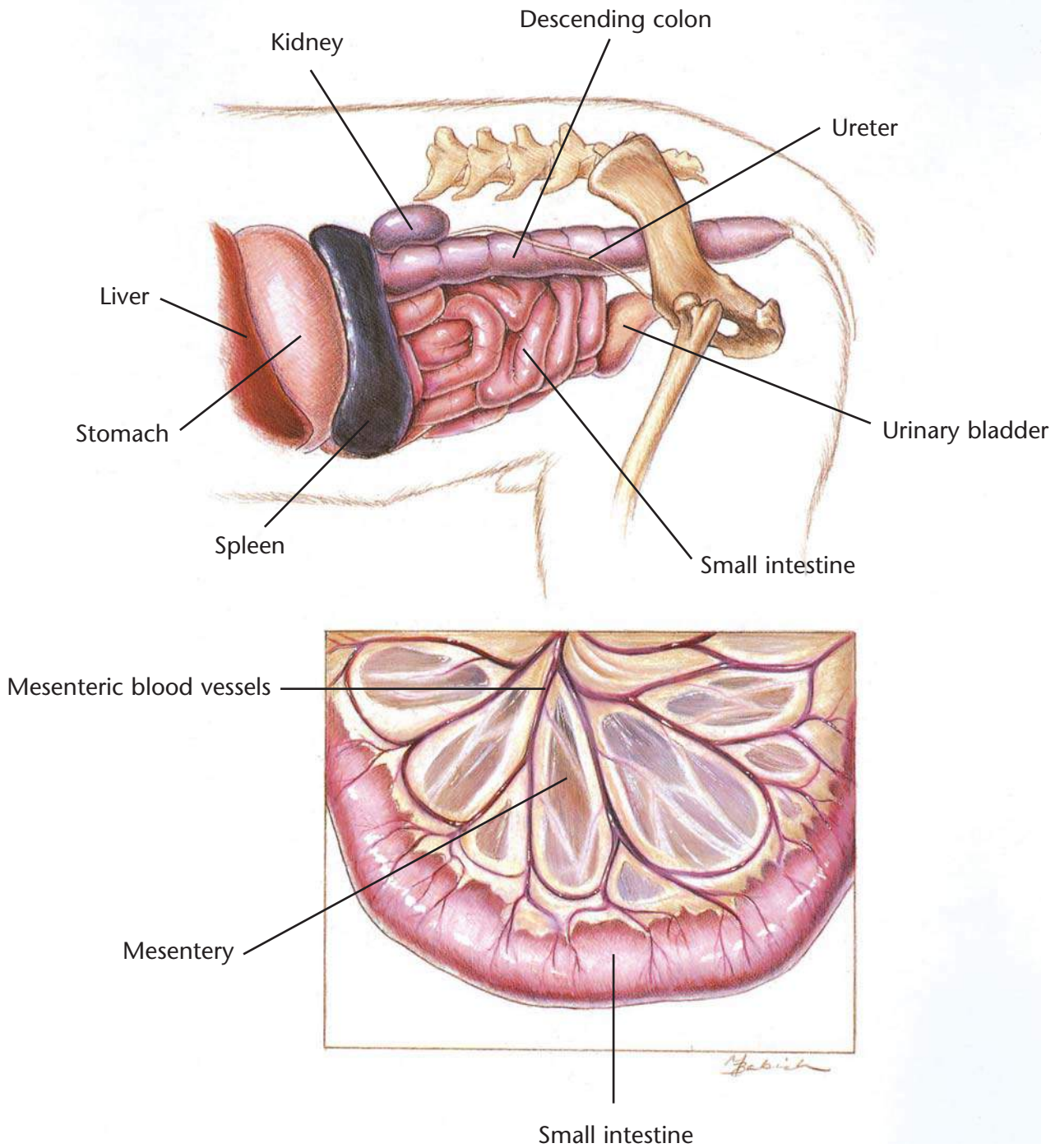
- Stomach distention relief
- Shock therapy
- Surgery

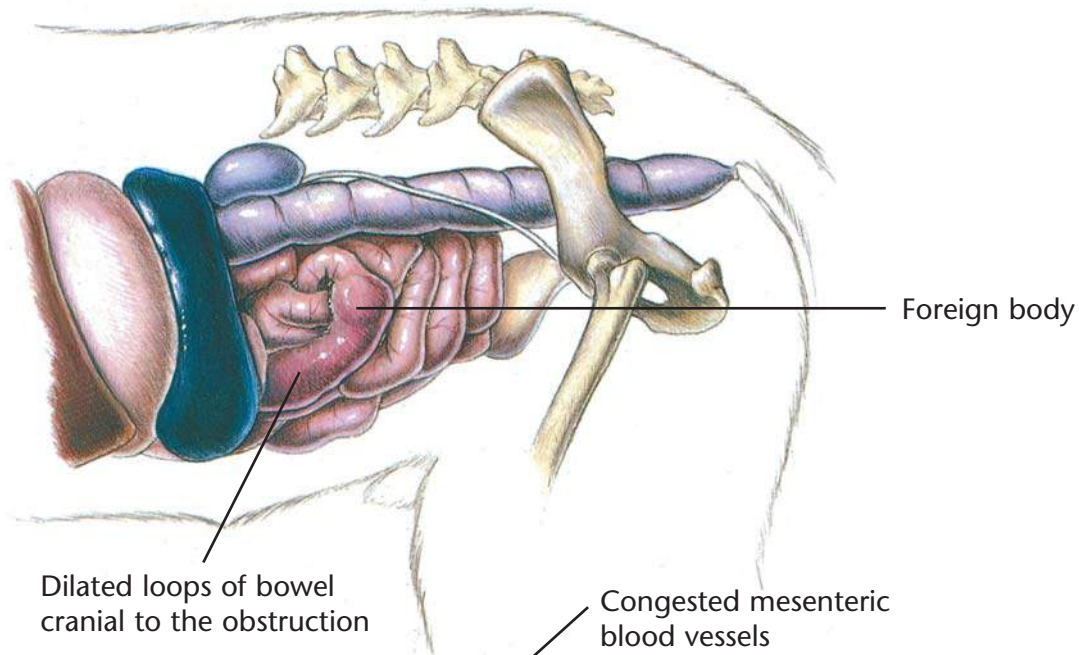
Dietary Plan

- A low-residue diet, fed in small portions
- Avoid excessive postprandial exercise

Hill's Atlas of Veterinary Clinical Anatomy

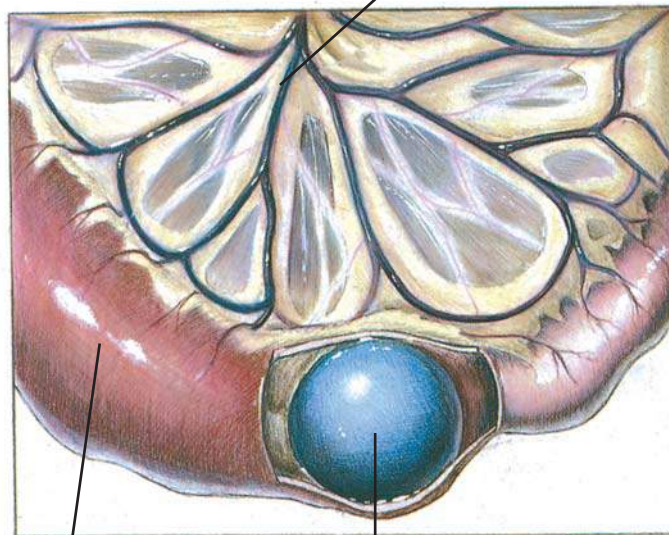
Normal Small Intestine





Dilated loops of bowel
cranial to the obstruction

Congested mesenteric
blood vessels



Dilated loop of bowel

Foreign object (ball)

Foreign Bodies

Diagnostic Plan

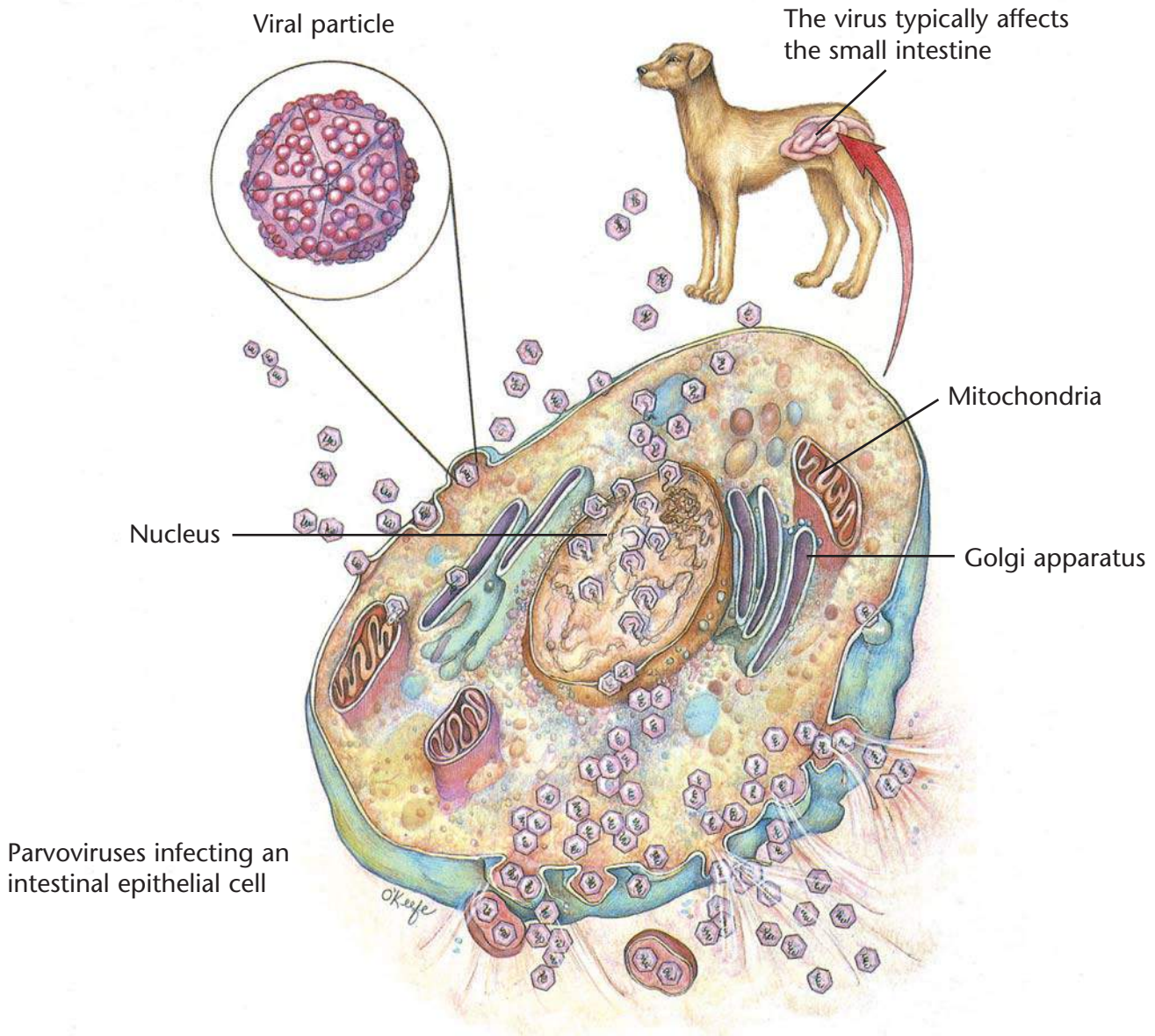
History
Physical examination
Abdominal palpation
Abdominal x-rays
Upper G.I. series
Stool analysis
Blood tests
Urinalysis
Endoscopy

Therapeutic Plan

Fluid therapy
Antibacterials
Surgery (to remove foreign bodies)
Nothing by mouth for 24-48 hours

Dietary Plan

Postsurgically, a low-residue diet fed in small portions
Consider overall patient condition when determining the protein level and caloric density of the diet



Parvoviral Enteritis

Diagnostic Plan

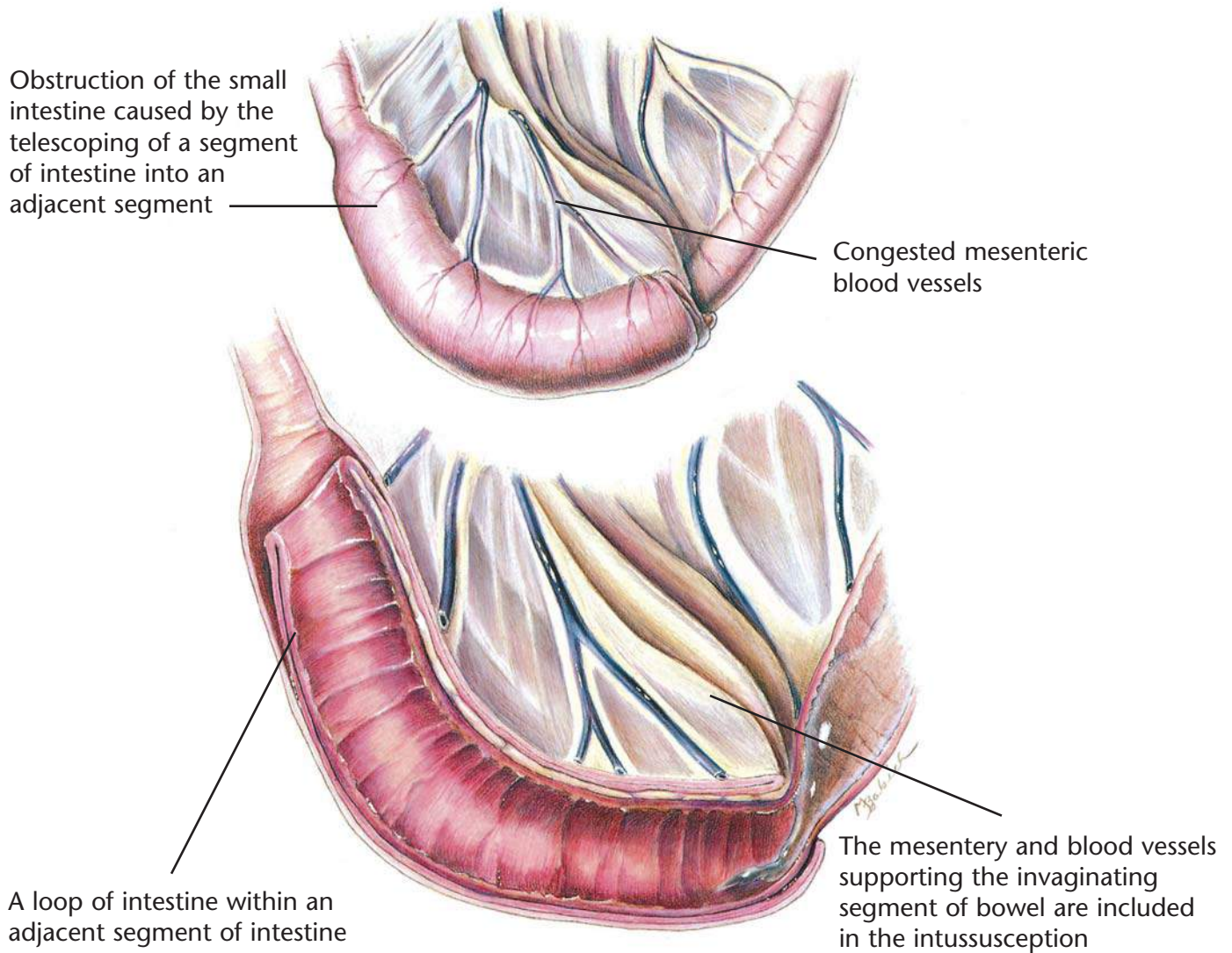
History
Physical examination
Stool analysis
Blood tests
Urinalysis
Abdominal x-rays
Upper G.I. series
Endoscopy with tissue biopsy

Therapeutic Plan

Nothing by mouth
Fluid therapy
Intestinal protectants
Antibacterials
Analgesics

Dietary Plan

A highly digestible diet
Consider overall patient condition when determining the protein level and caloric density of the diet



Intussusception

Diagnostic Plan

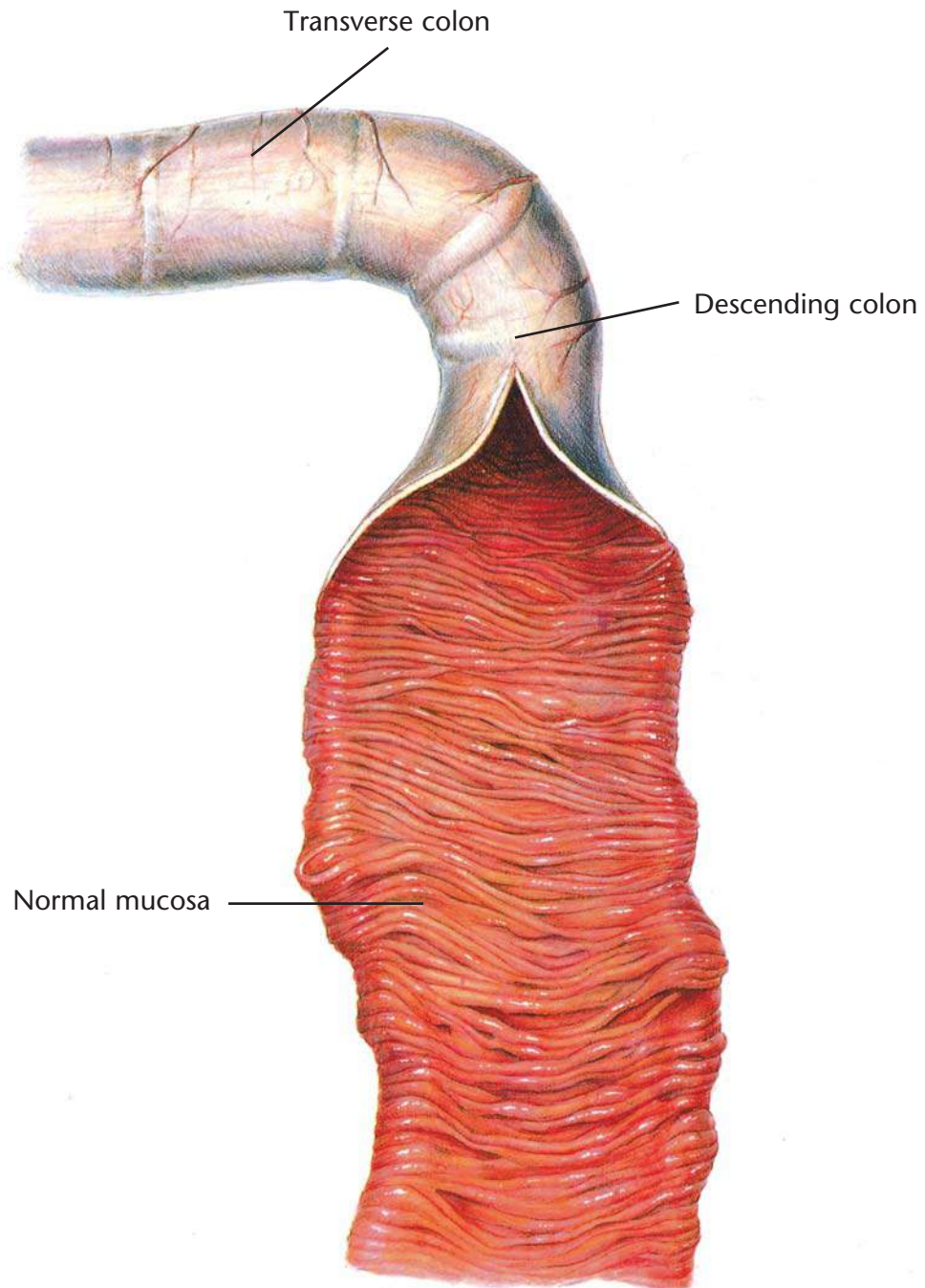
History
Physical examination
Abdominal palpation
Abdominal x-rays

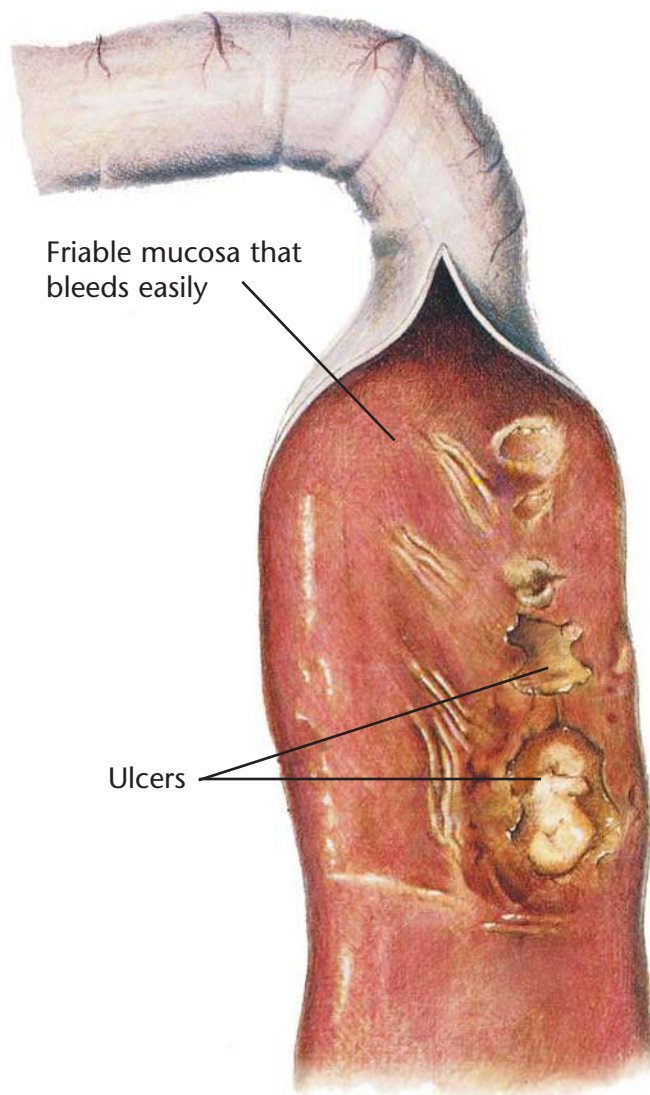
Therapeutic Plan

Fluid therapy
Surgery
Removal of the cause
Nothing by mouth

Dietary Plan

Postsurgically, a low-residue diet fed in small portions
Consider overall patient condition when determining the protein level and caloric density of the diet





Chronic Colitis

Diagnostic Plan

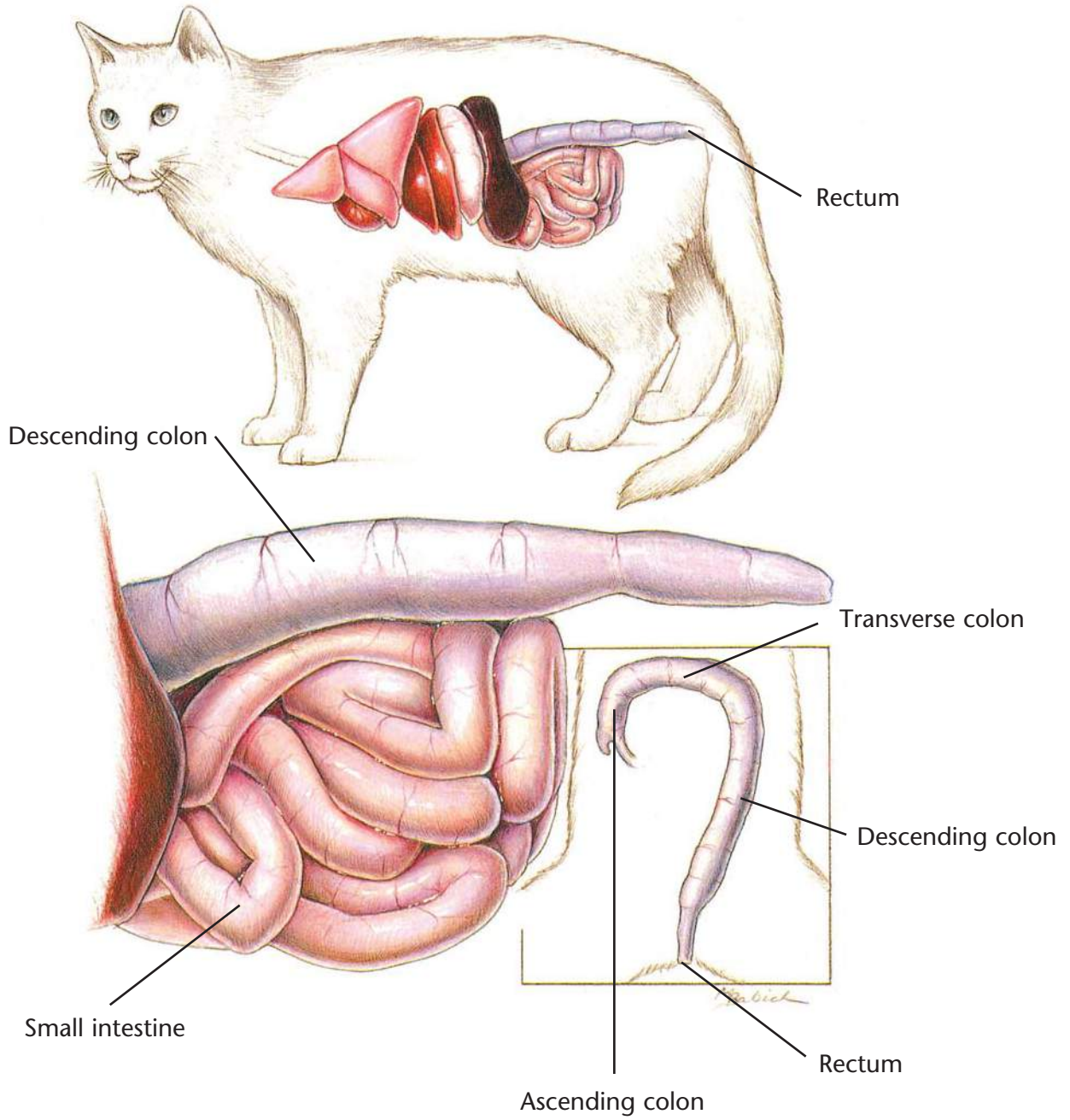
History
Physical examination
Stool analysis
Abdominal palpation
Rectal palpation
Stool culture
Blood work
Urinalysis
X-rays of the colon
Colonoscopy and biopsy

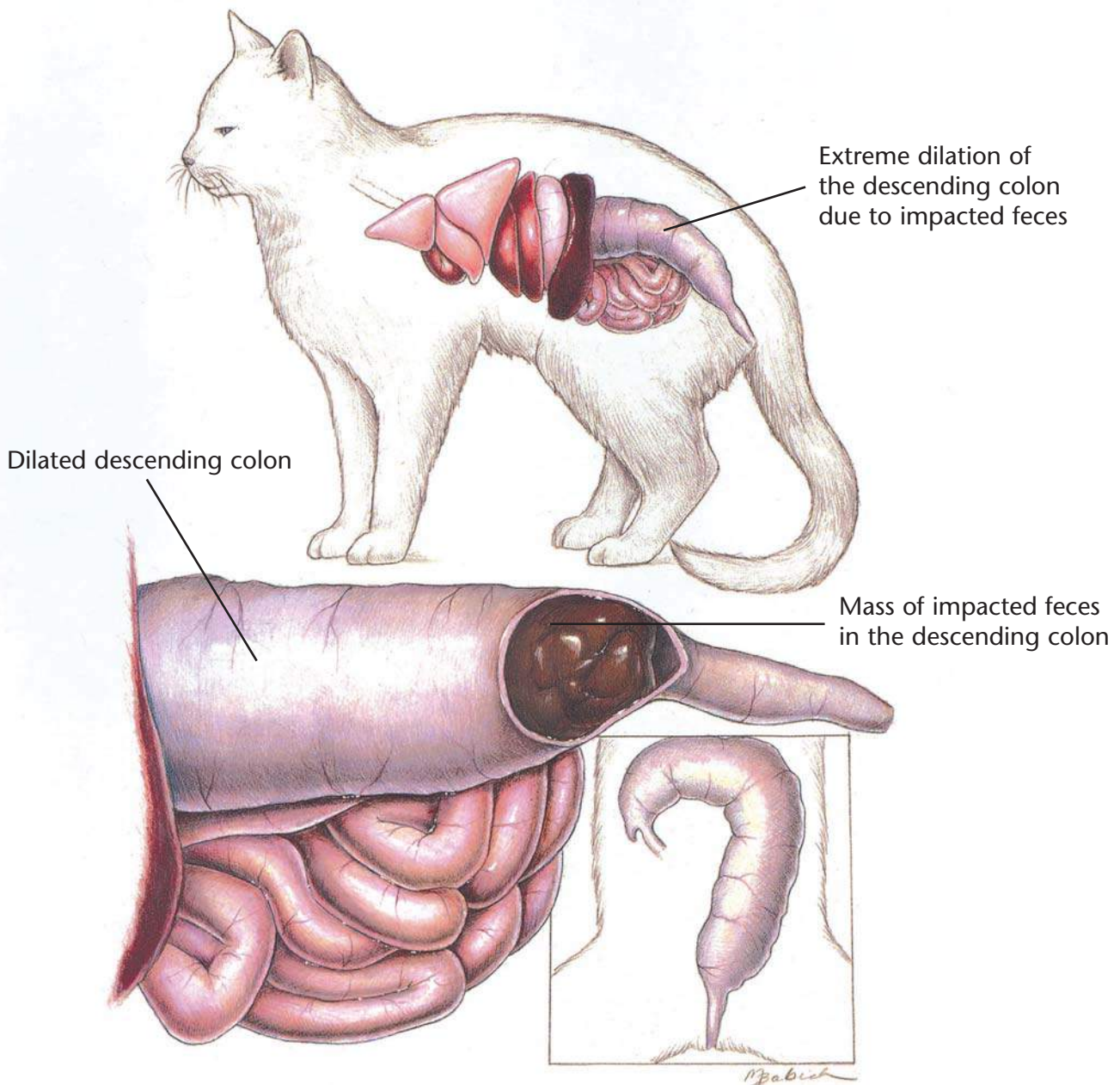
Therapeutic Plan

Antibacterials
Dewormers
Anti-inflammatory drugs

Dietary Plan

High-fiber diets benefit some cases of colitis
If a high-fiber diet is ineffective, a dietary trial using a low-residue diet is indicated
For a food-allergy-induced colitis, a hypoallergenic diet is indicated





Constipation/Colonic Impaction

Diagnostic Plan

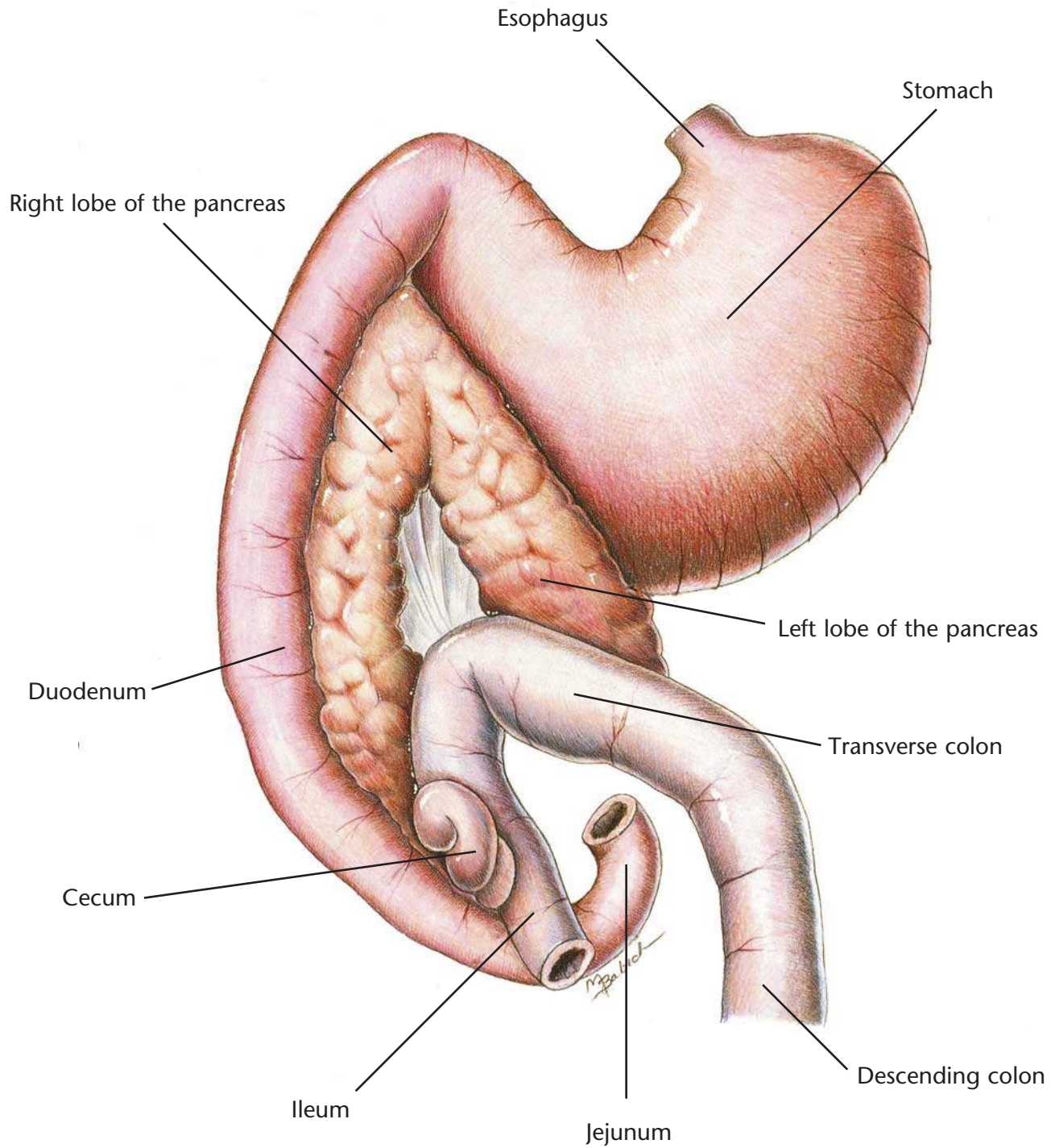
History
Physical examination
Rectal palpation
Abdominal palpation
Abdominal x-rays

Therapeutic Plan

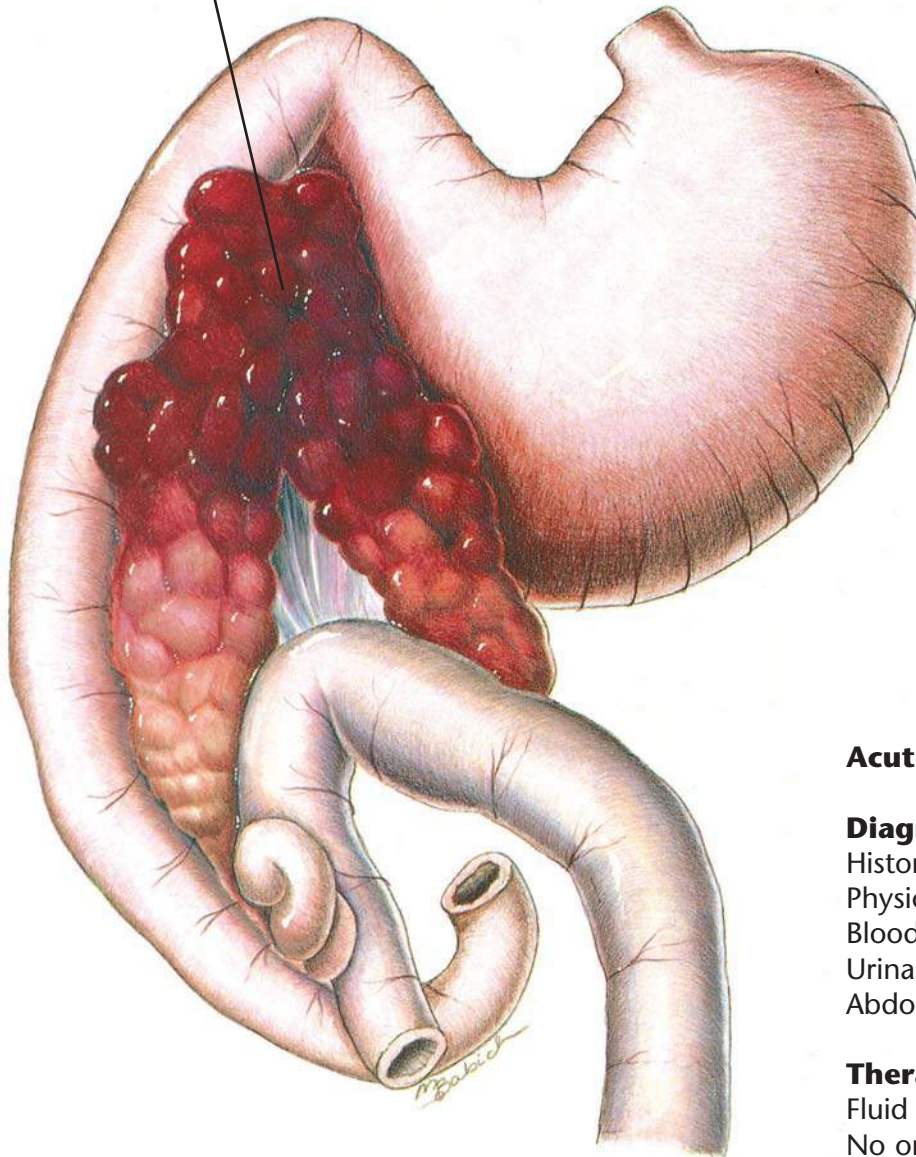
Fluid therapy
Laxatives
Enemas
Manual removal of impacted stool
Surgery
Treat primary cause, if possible
Stool softeners
Pro-motility medication

Dietary Plan

A moderate- to high-fiber diet if no neurologic or obstructive lesions; chronic cases may benefit from low residue food
Ensure adequate water intake



Swollen, inflamed pancreas with areas of hemorrhage



Acute Pancreatitis

Diagnostic Plan

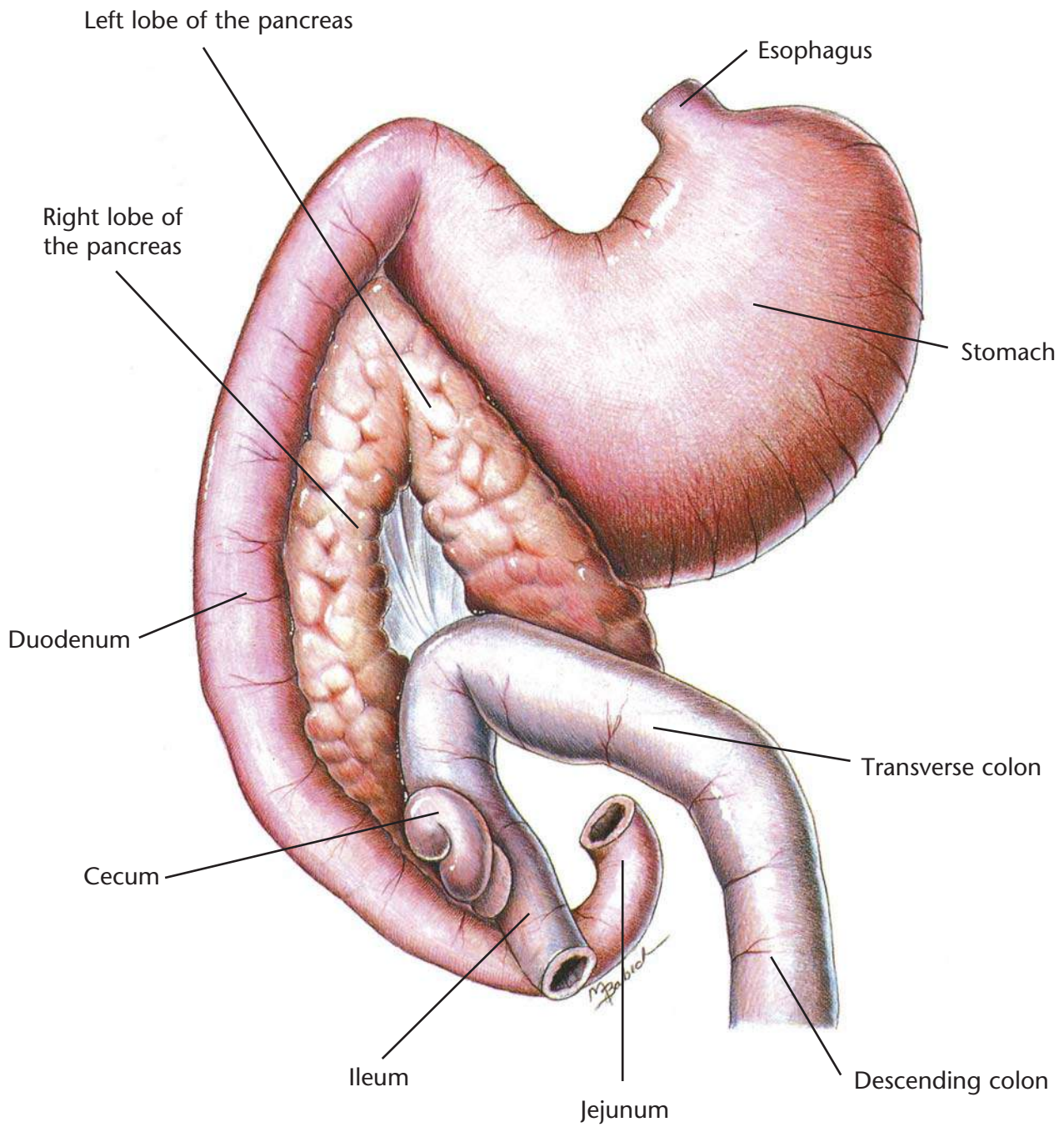
- History
- Physical examination
- Blood work
- Urinalysis
- Abdominal x-rays

Therapeutic Plan

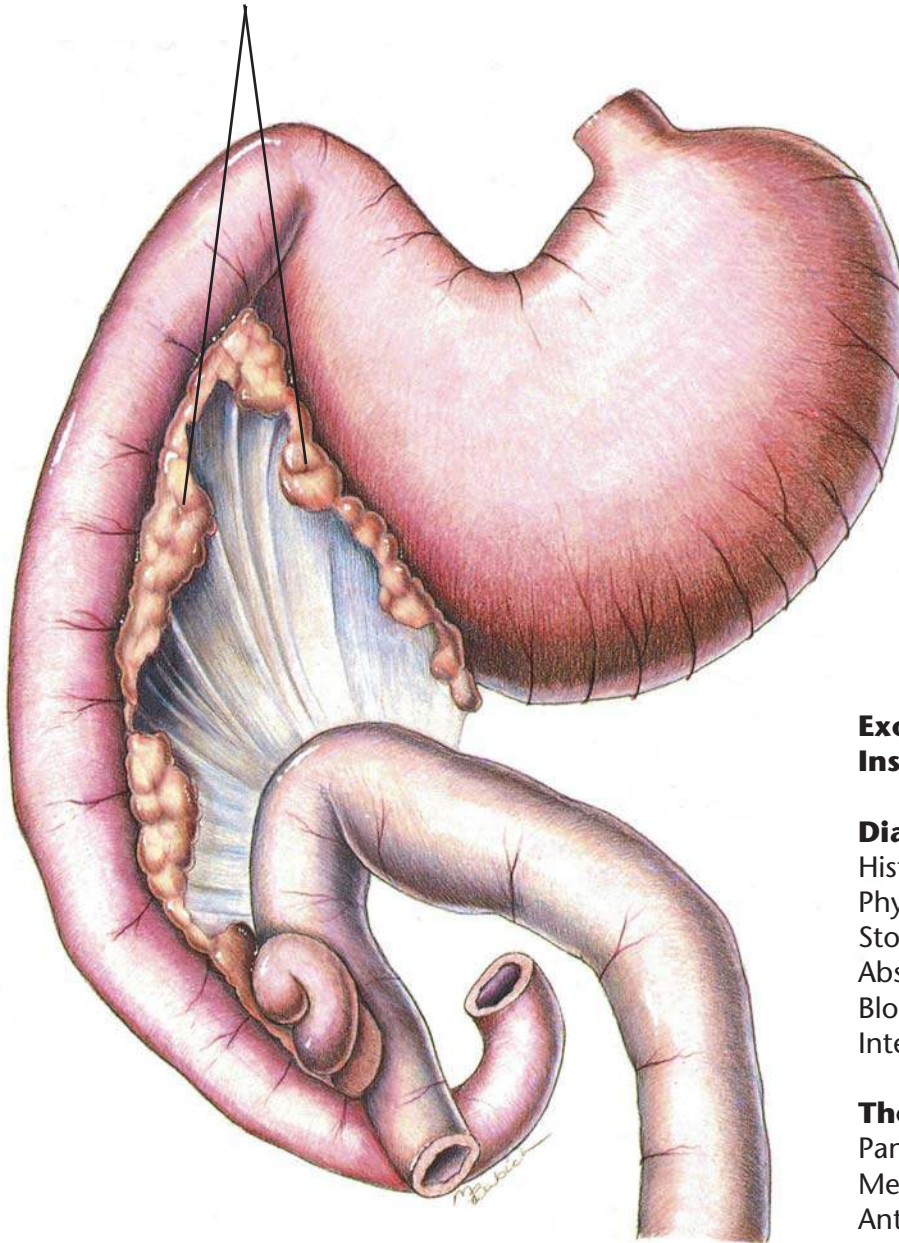
- Fluid therapy
- No oral medication or food
- Antibacterials
- Drugs to suppress vomiting
- Analgesics

Dietary Plan

- When resuming enteral nutrition, small portions of a diet low in fat and residue
- After the initial episode, manage hyperlipidemia, if necessary



Shrunken pancreatic lobes with
reduced production of digestive enzymes



Exocrine Pancreatic Insufficiency

Diagnostic Plan

- History
- Physical examination
- Stool analysis
- Absorption tests
- Blood work
- Intestinal biopsy

Therapeutic Plan

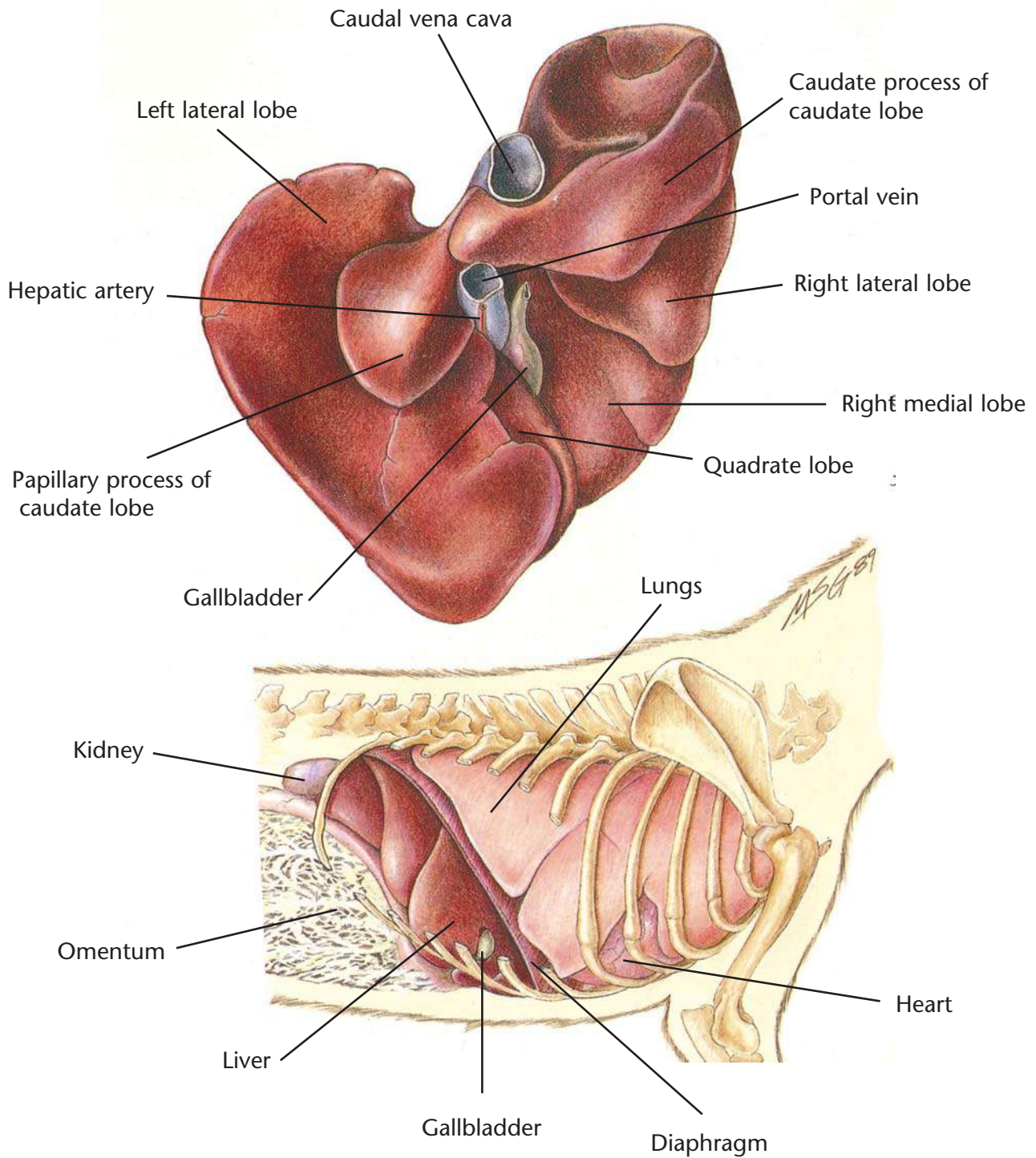
- Pancreatic enzymes
- Medium-chain fats
- Antacids
- Drugs that inhibit acid secretion in the stomach

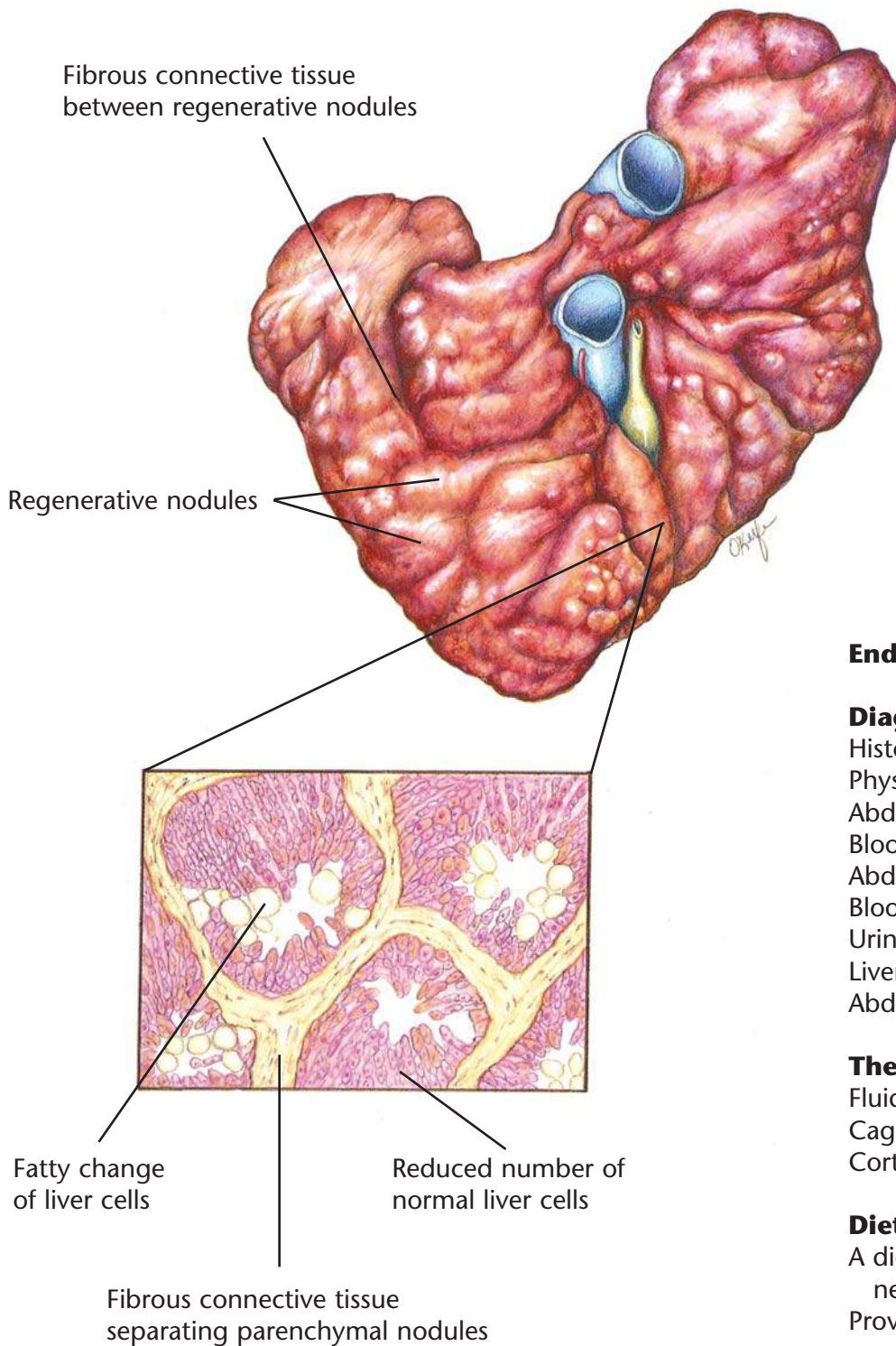
Dietary Plan

- A highly digestible diet
- Consider overall body condition
- Feed quantities sufficient to maintain normal body weight
- Avoid excess fat

Hill's Atlas of Veterinary Clinical Anatomy

Normal Liver





End-Stage Liver Disease

Diagnostic Plan

- History
- Physical examination
- Abdominal palpation
- Blood work
- Abdominal x-rays
- Blood clotting time
- Urinalysis
- Liver biopsy
- Abdominal ultrasonography

Therapeutic Plan

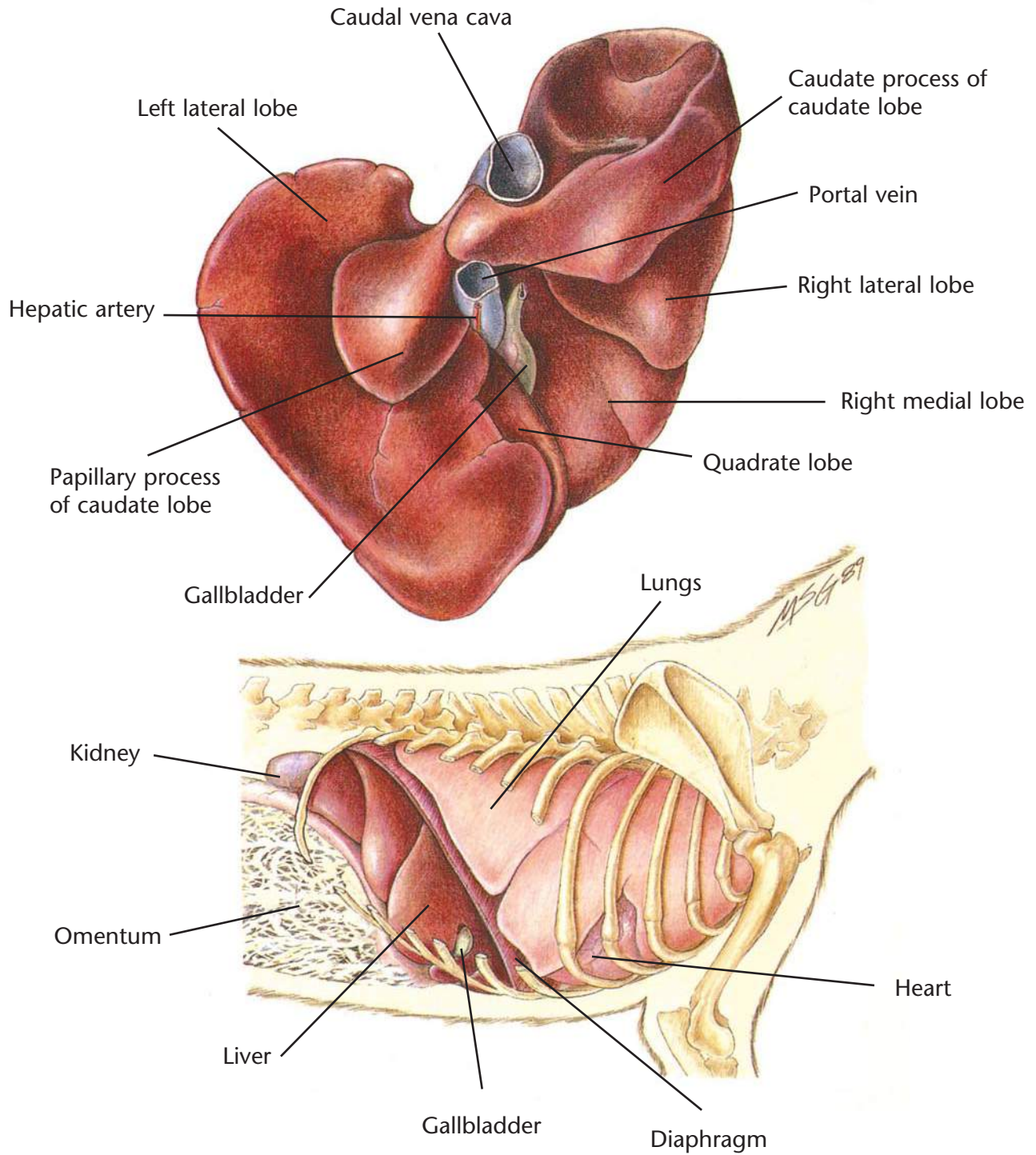
- Fluid therapy
- Cage rest
- Corticosteroids

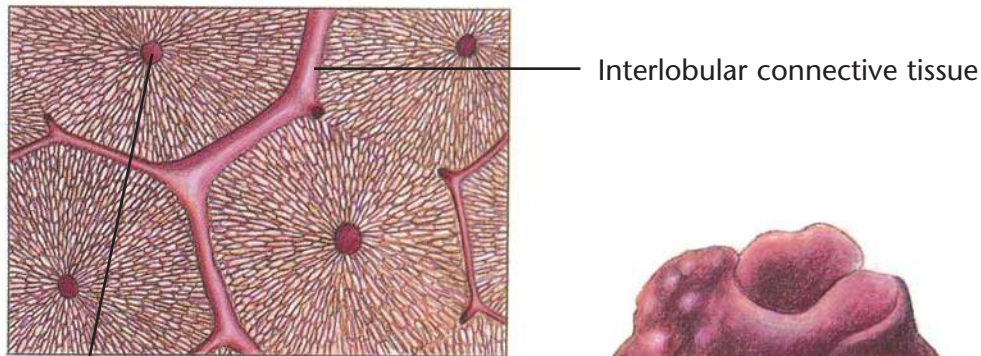
Dietary Plan

- A diet that will reduce the need for certain liver functions
- Provide adequate protein, but avoid excess
- Consider possible need for controlled sodium intake

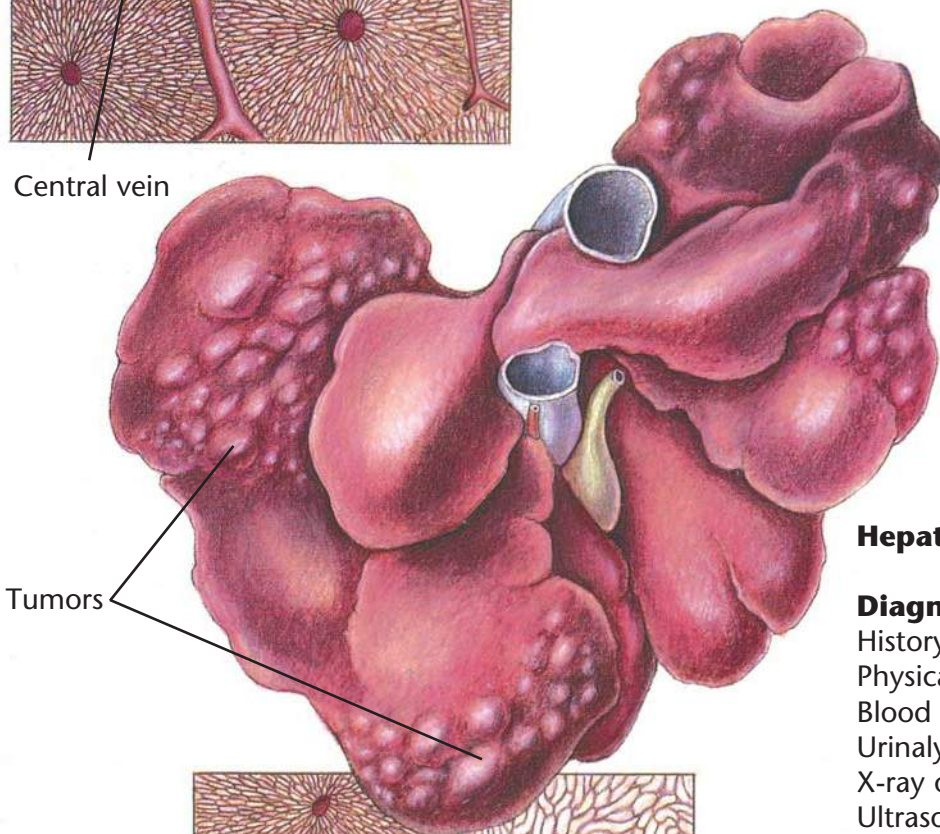
Hill's Atlas of Veterinary Clinical Anatomy

Normal Liver

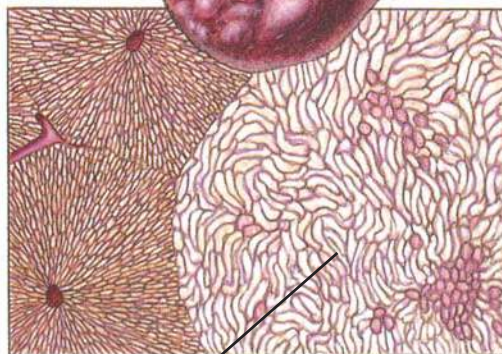




Central vein



Tumors



Disruption of normal liver tissue by sheets of neoplastic cells

Hepatic Neoplasia

Diagnostic Plan

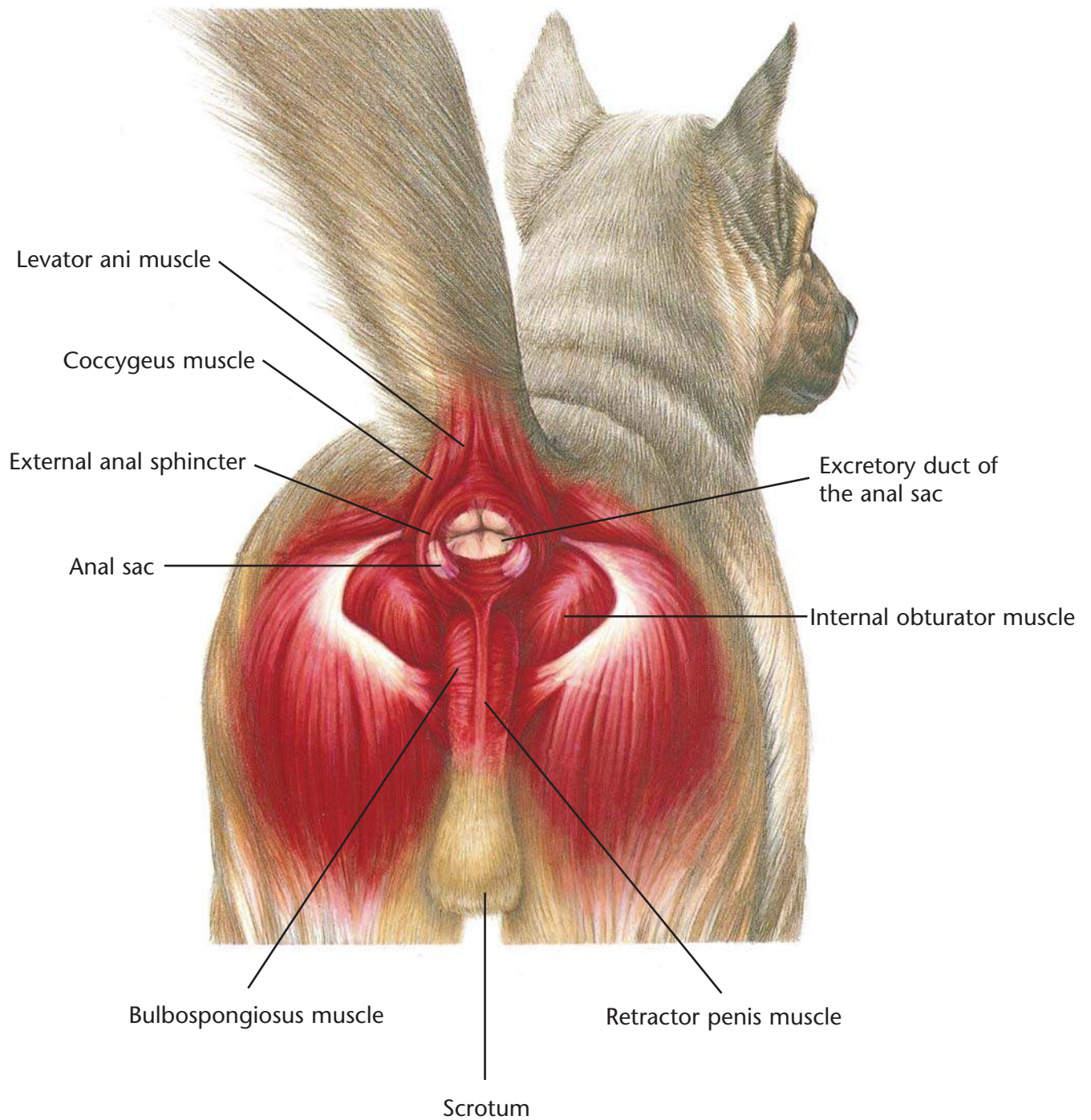
- History
- Physical examination
- Blood work
- Urinalysis
- X-ray of the liver
- Ultrasound
- Liver biopsy
- Exploratory surgery

Therapeutic Plan

- Supportive care
- Chemotherapy
- Surgery

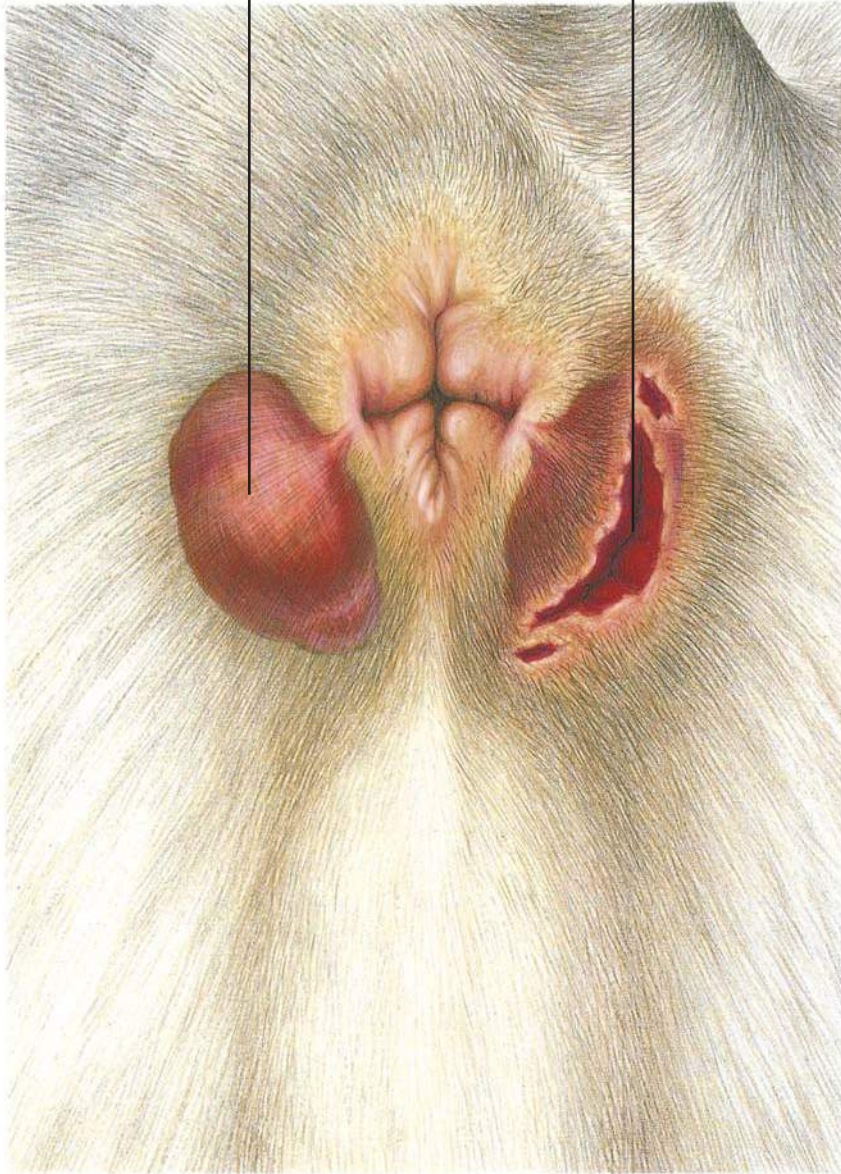Dietary Plan

A diet based on individual patient evaluation including body condition and other organ system involvement. Special attention should be given to protein levels and amino-acid balance of the diet.



Enlarged, inflamed anal sac

Ruptured anal sac abscess



Anal Sac Abscess

Diagnostic Plan

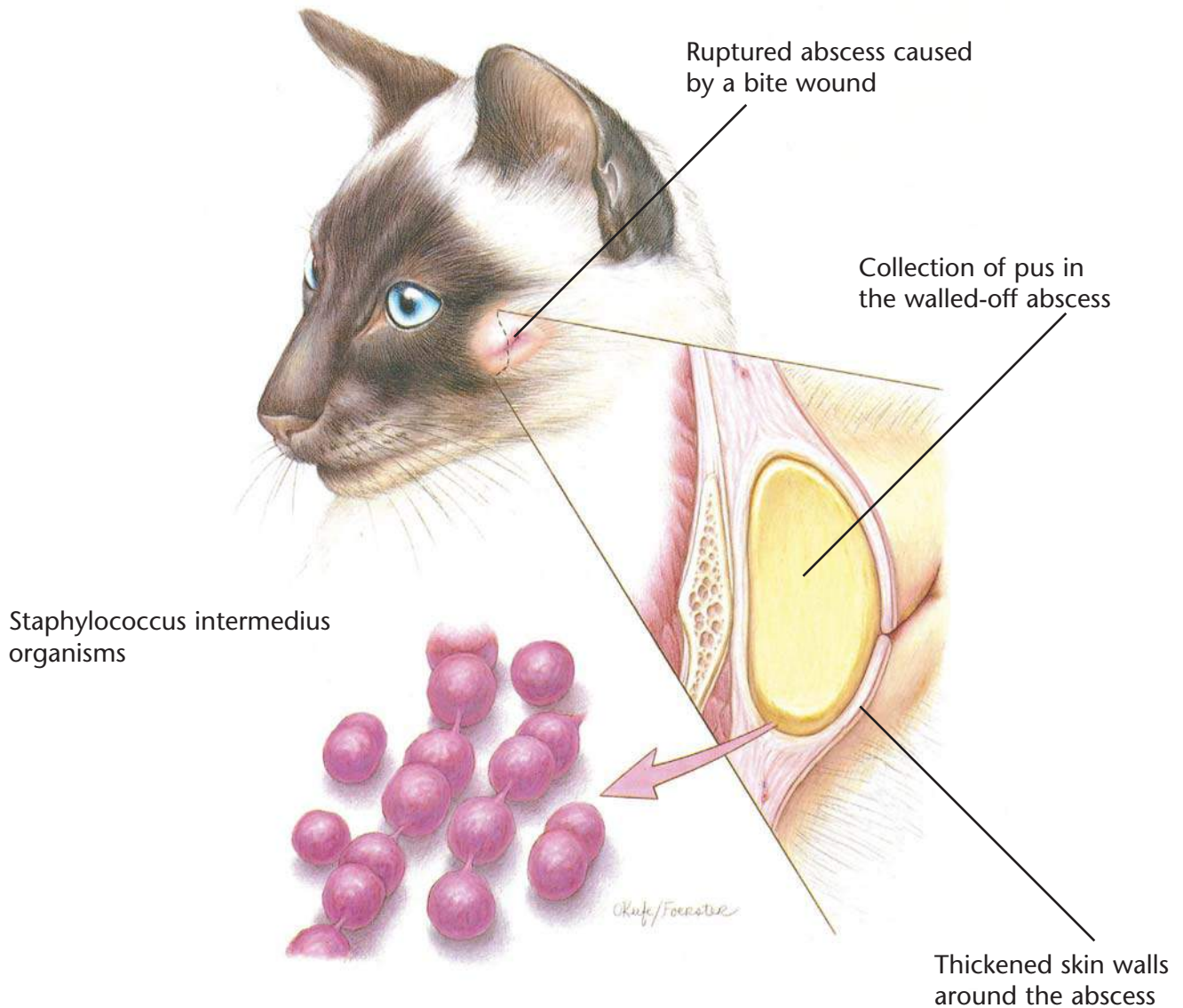
- History
- Physical examination
- Abscess culture

Therapeutic Plan

- Lancing of the abscess
- Anal sac expression
- Hot soaks
- Antiseptic solutions
- Antibacterials
- Anal sac removal

Dietary Plan

- Postsurgically, a diet adequate for tissue repair



Skin Abscess

Diagnostic Plan

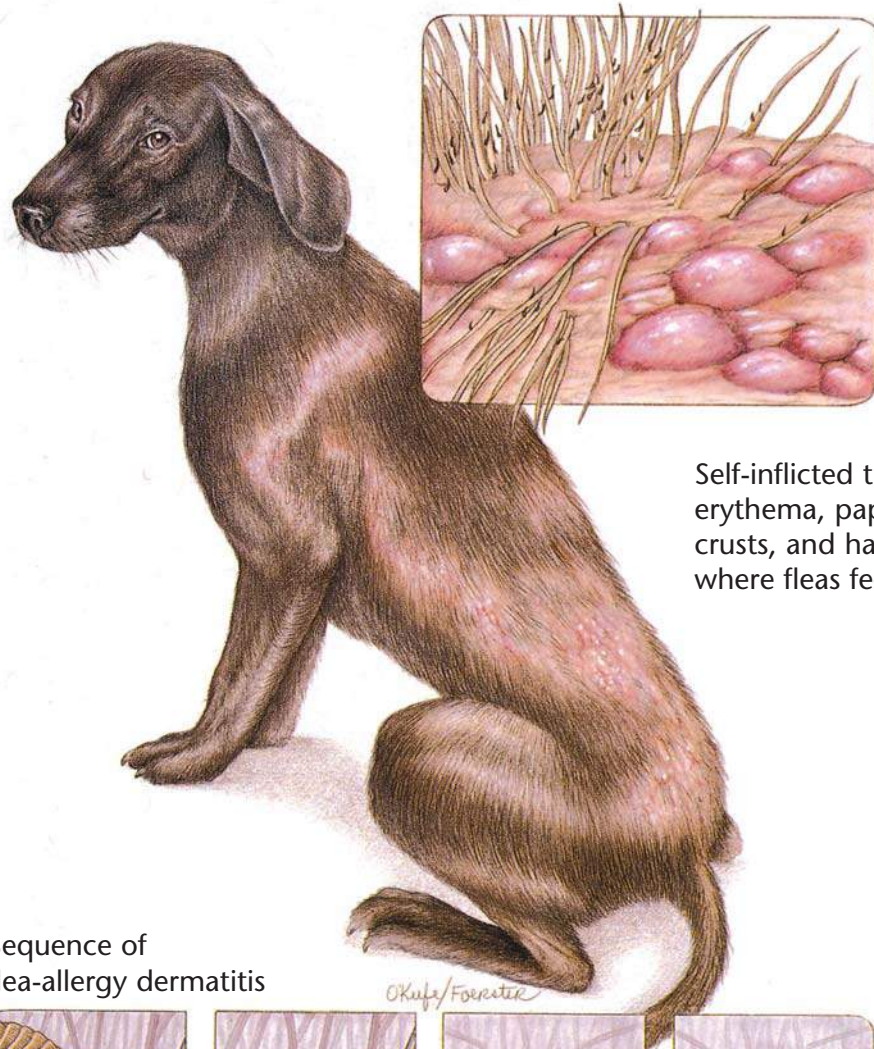
History
Physical examination
Abscess culture
X-rays

Therapeutic Plan

Hot compresses
Abscess drainage
Dead tissue removal
Antibacterial therapy
Surgery

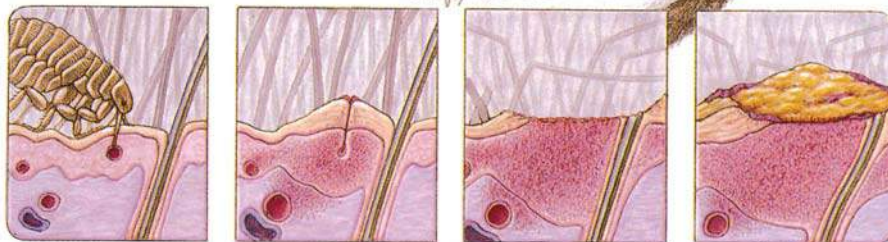Dietary Plan

A diet adequate for tissue repair



Self-inflicted trauma results in erythema, papules, pustules, crusts, and hair loss in areas where fleas feed.

Sequence of flea-allergy dermatitis



Flea punctures skin to feed.

Flea saliva sets up an antigen-antibody reaction.

Excoriation and inflammation result from self-inflicted trauma.

Acute bacterial infection results.

Flea-Allergy Dermatitis

Diagnostic Plan

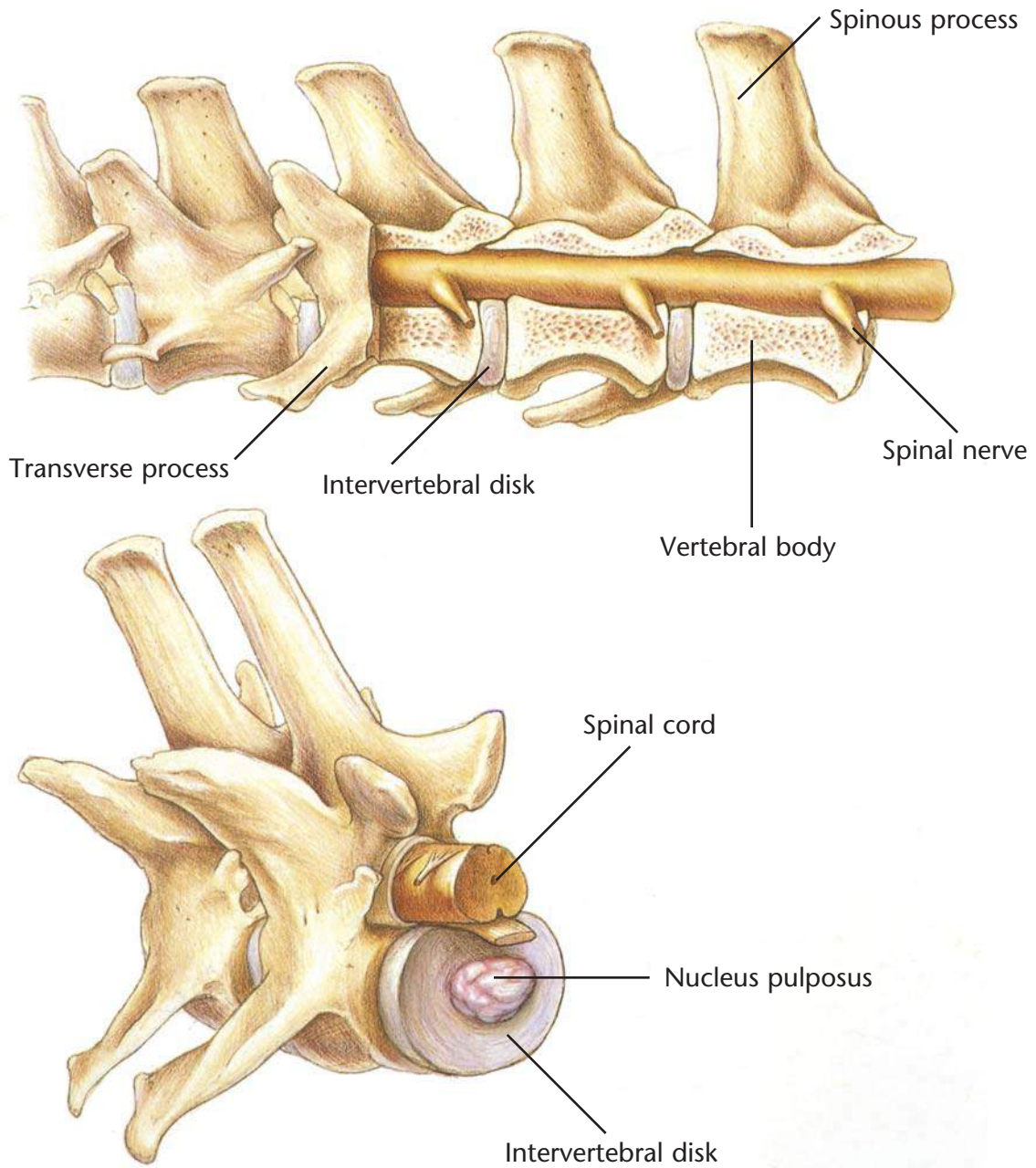
History
Physical examination
Detection of fleas, flea dirt, and tapeworm segments
Intradermal skin testing

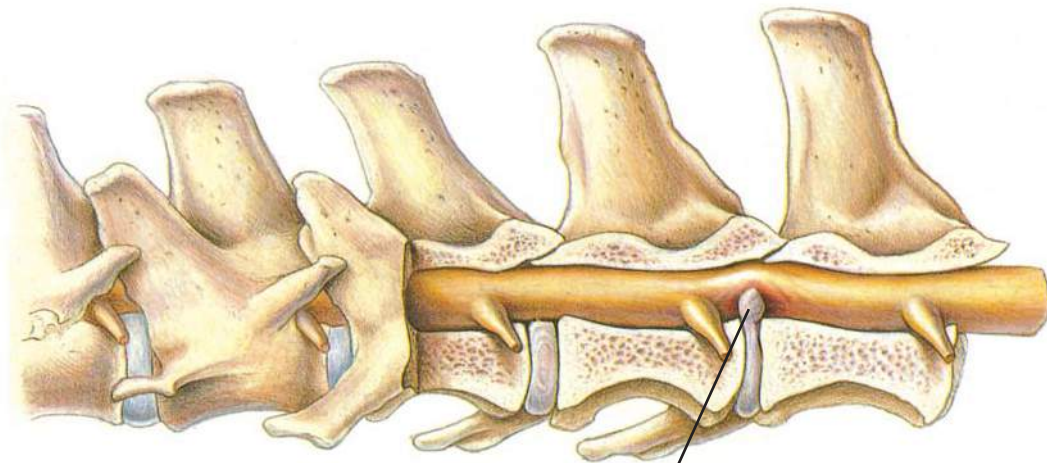
Therapeutic Plan

Flea control
Short-term corticosteroids

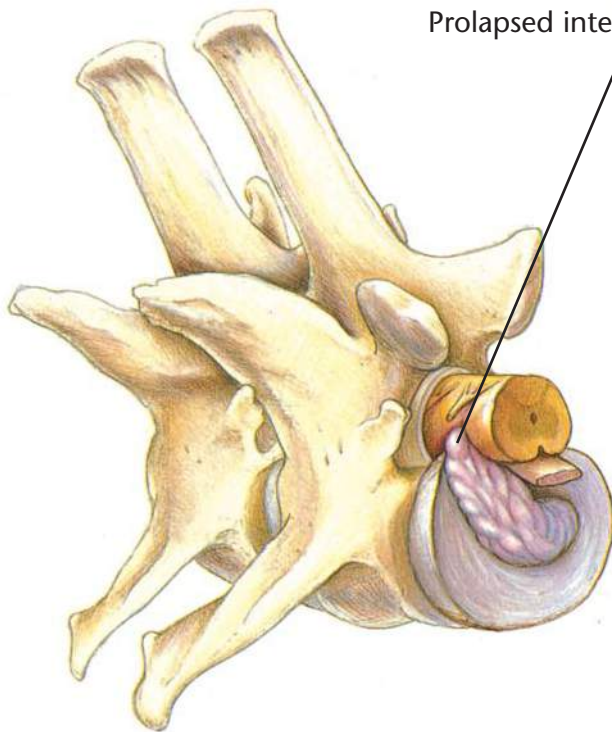
Dietary Plan

A diet adequate for tissue repair





Prolapsed intervertebral disk



Intervertebral Disk Disease

Diagnostic Plan

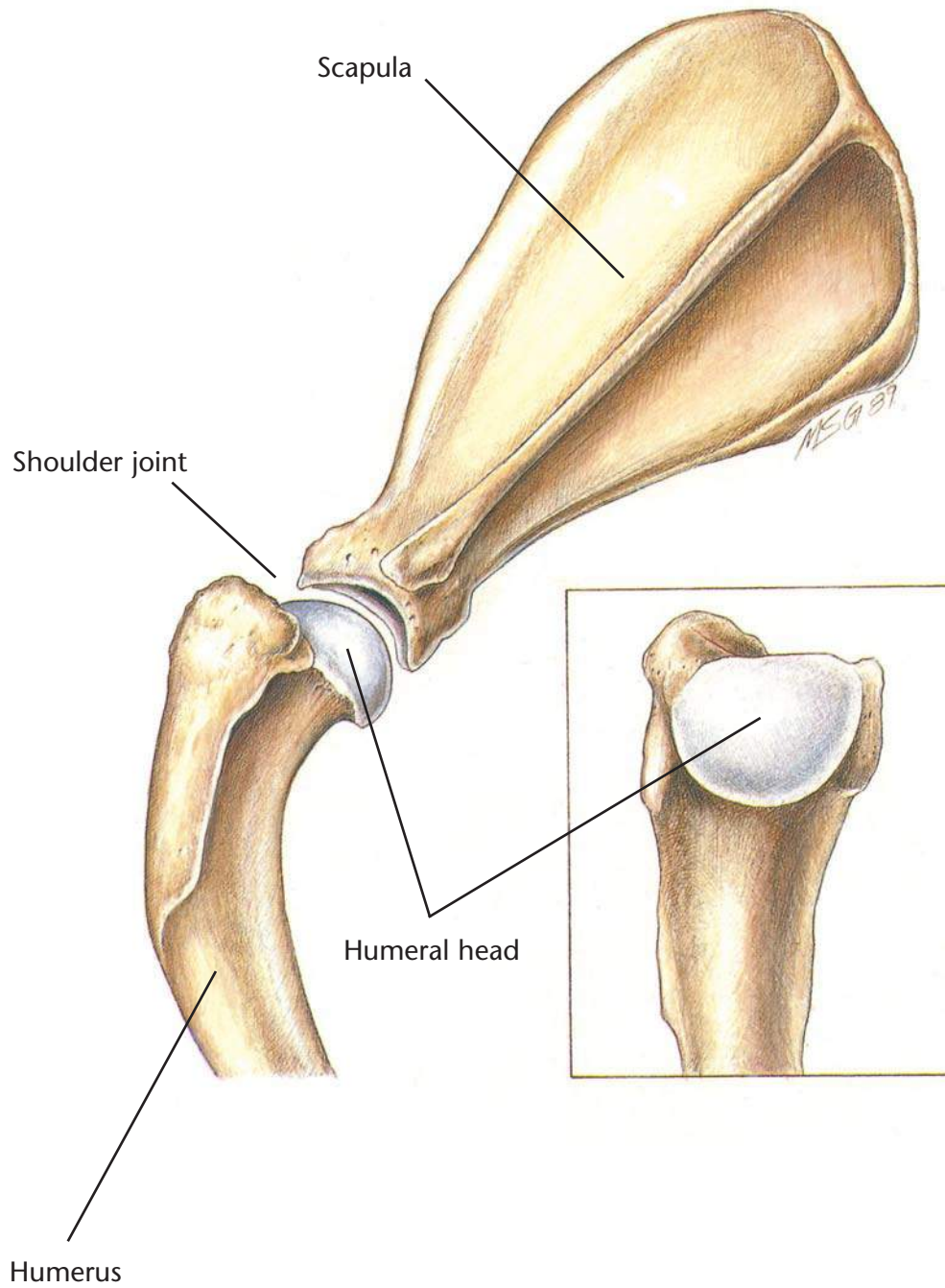
History
Physical examination
Neurologic examination
X-ray of the spine

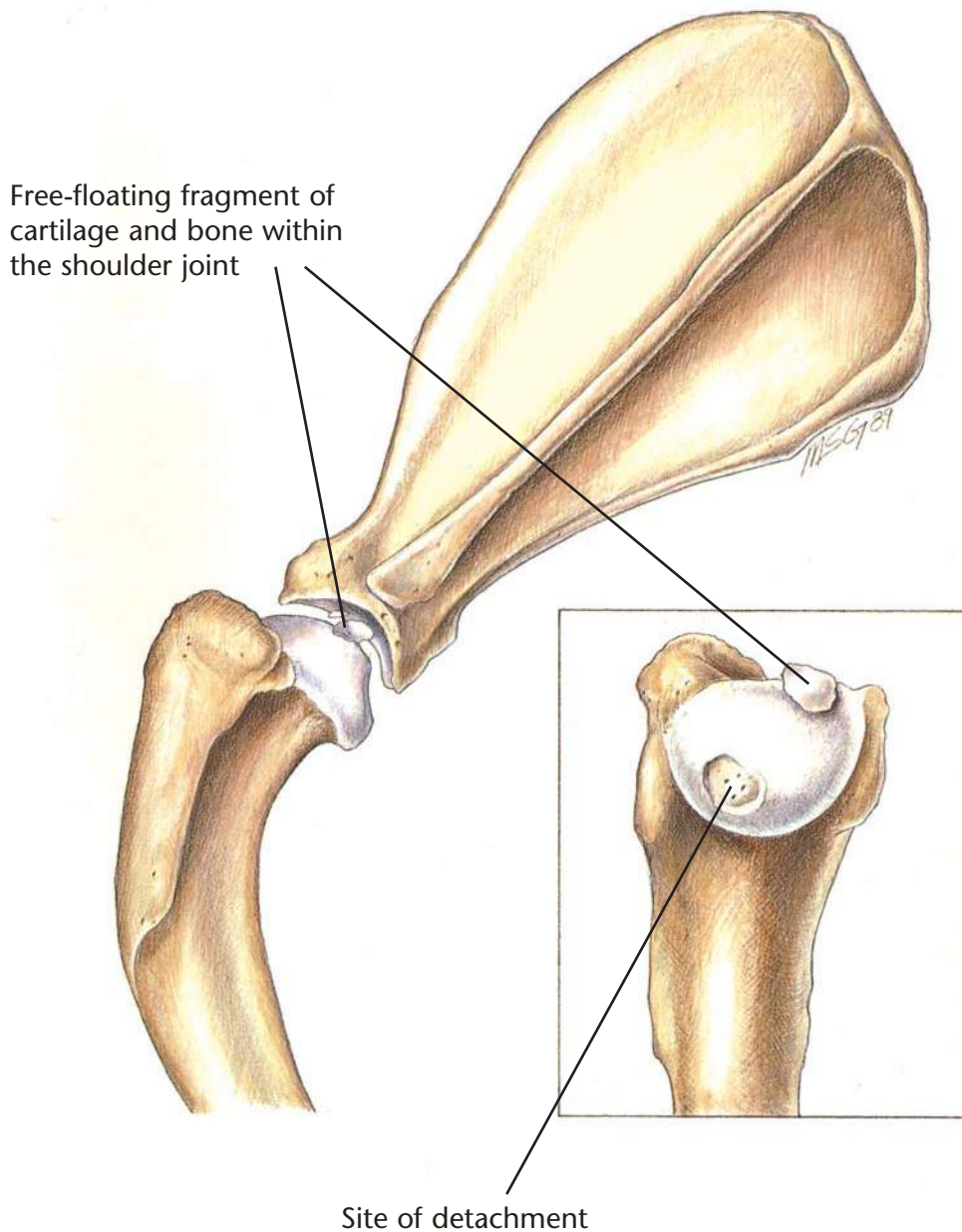
Therapeutic Plan

Enforced rest
Anti-inflammatory drugs
Analgesics
Muscle relaxants
Surgery
Physical therapy

Dietary Plan

Postsurgically, a diet adequate for tissue repair
If obesity is a complicating factor, restrict caloric intake so the patient reaches and maintains an ideal body weight





Osteochondritis Dissecans

Diagnostic Plan

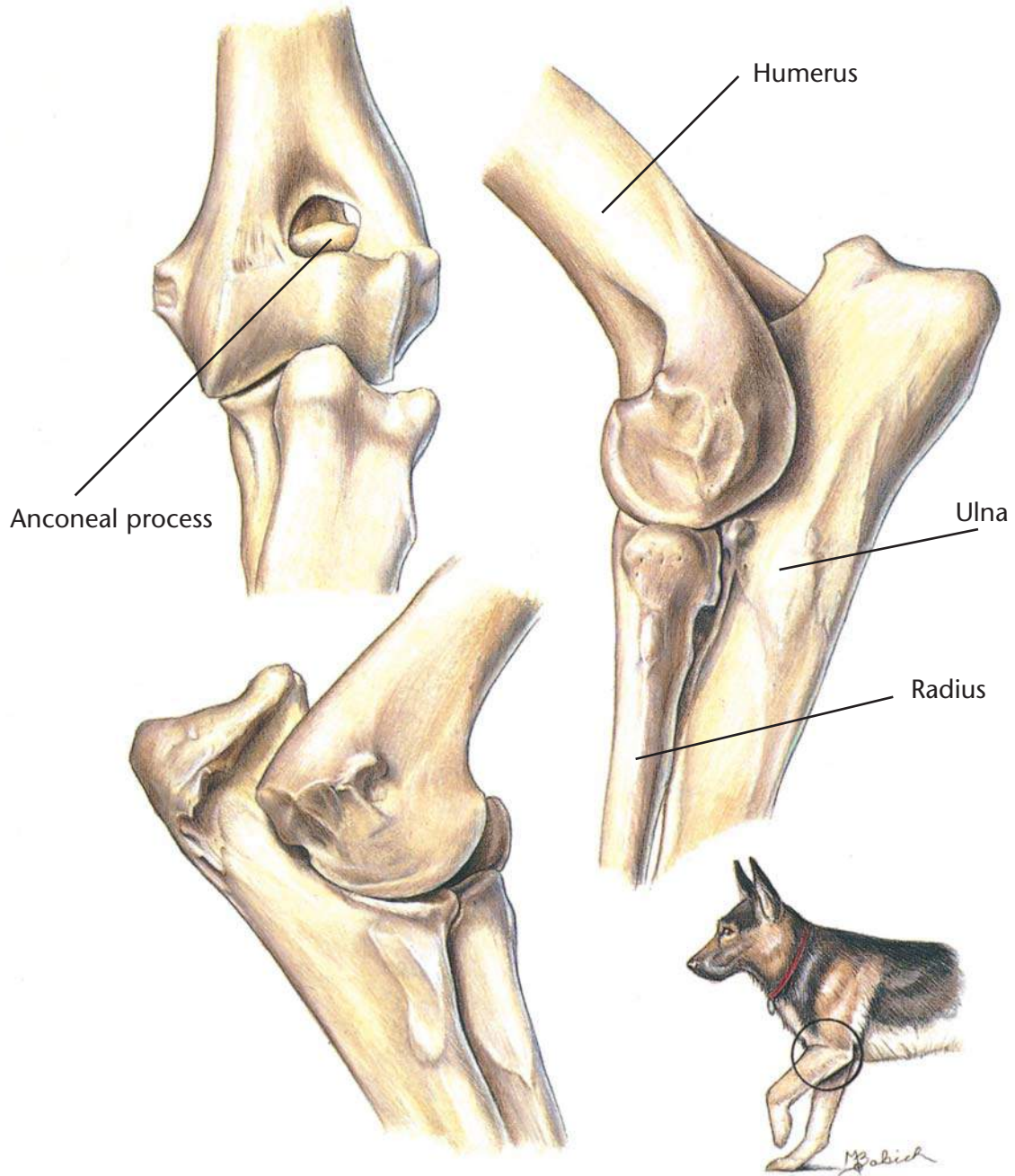
History
Physical examination
X-rays

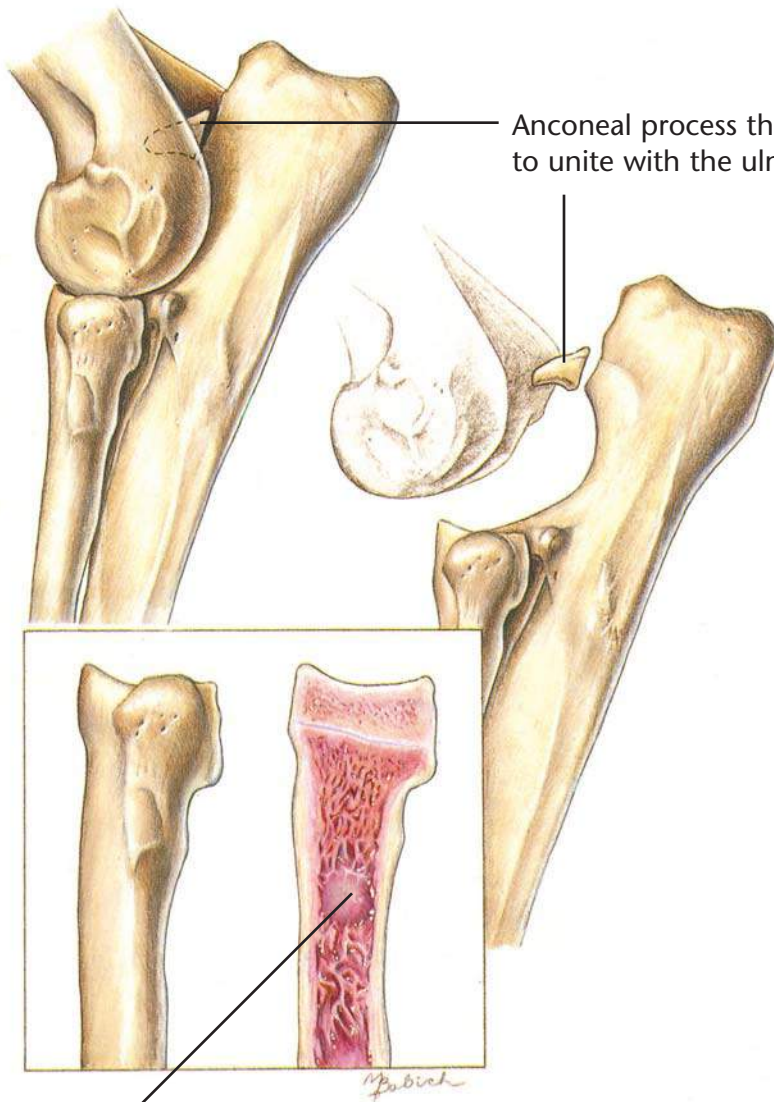
Therapeutic Plan

Surgery

Dietary Plan

Postsurgically, a diet adequate for tissue repair and patient growth
Avoid overfeeding throughout life
Avoid excess calcium and energy in growing large and giant-breed pups





Anconeal process that has failed to unite with the ulna

Lesions of panosteitis in the proximal radius

Ununited Anconeal Process

Diagnostic Plan

History
Physical examination
X-rays of the elbow

Therapeutic Plan

Surgery

Dietary Plan

Postsurgically, a diet adequate for tissue repair and patient growth
Avoid excess calcium and energy in growing large and giant-breed pups
Avoid overfeeding throughout life

Panosteitis

Diagnostic Plan

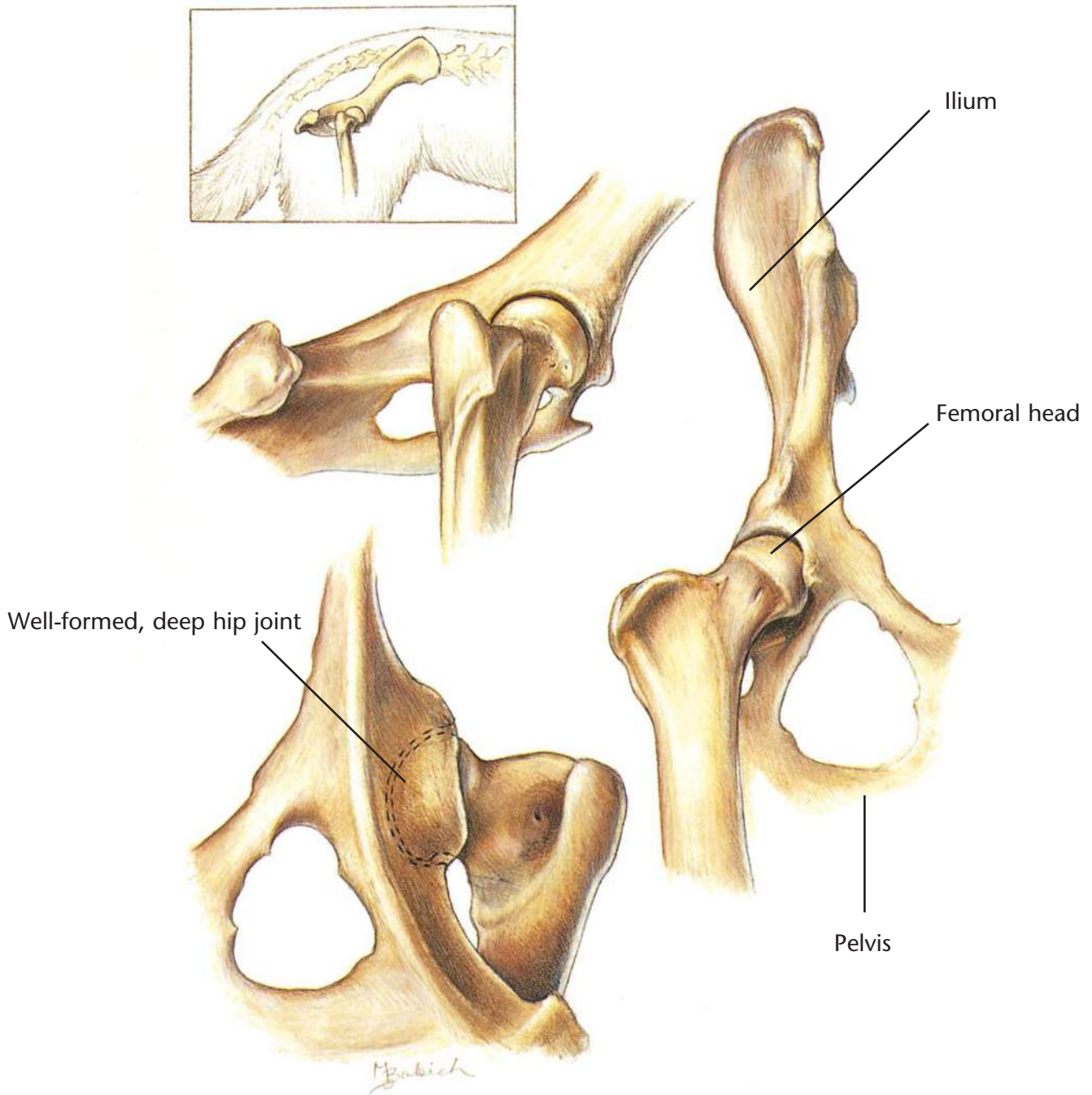
History
Physical examination
Palpation
X-rays

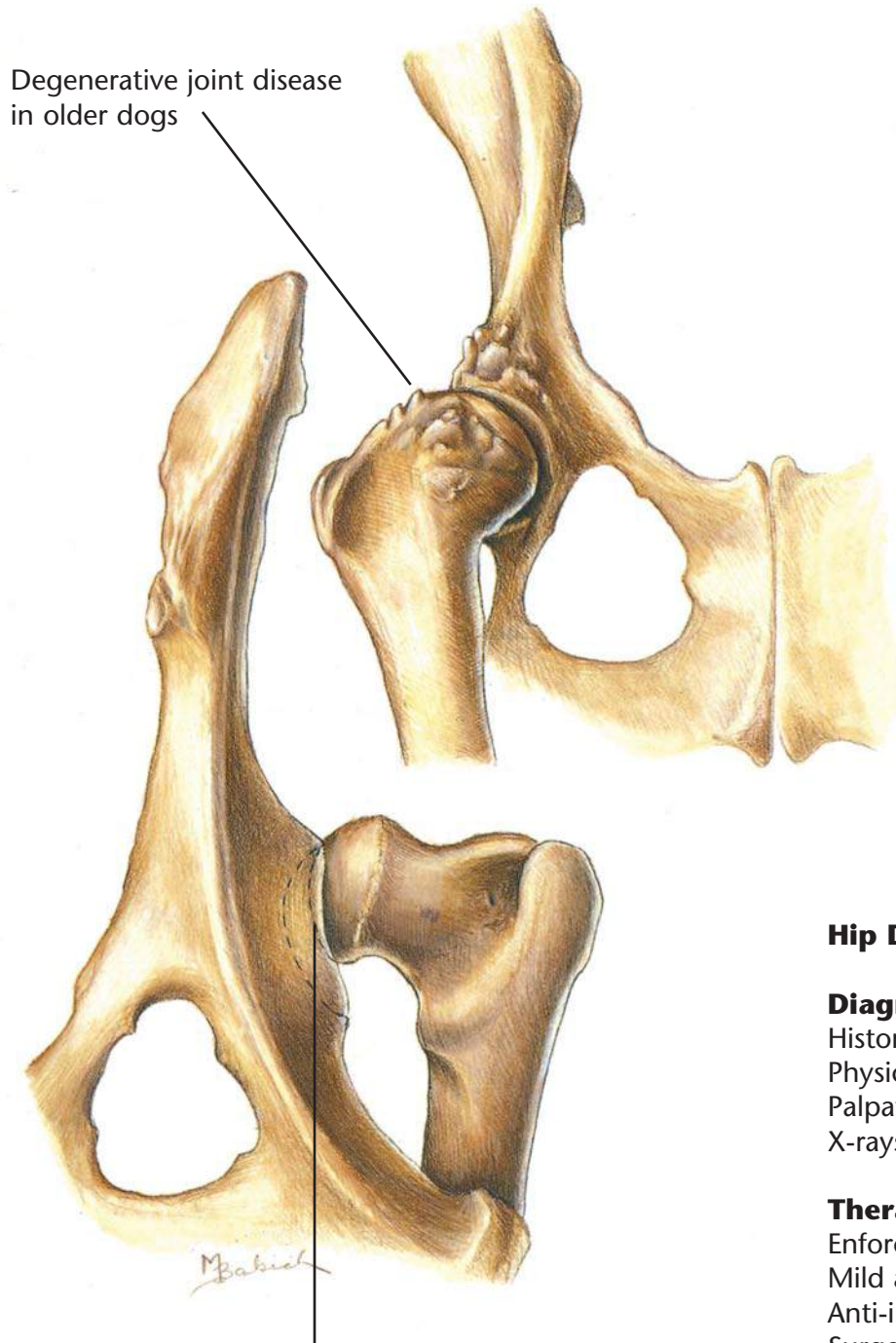
Therapeutic Plan

Analgesics

Dietary Plan

A diet adequate for growth
Avoid overfeeding throughout life





Hip Dysplasia

Diagnostic Plan

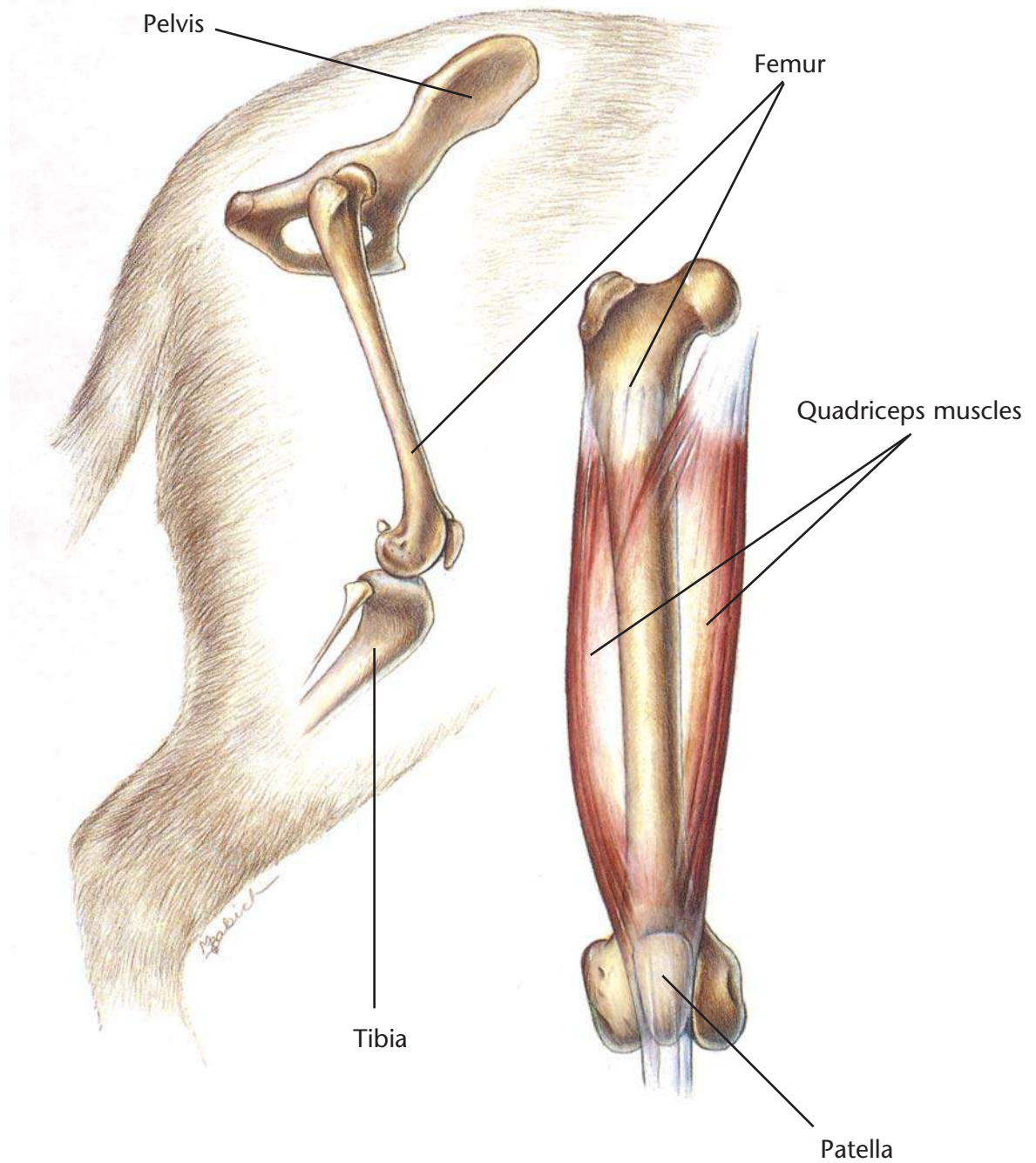
History
Physical examination
Palpation of the hips
X-rays of the hips

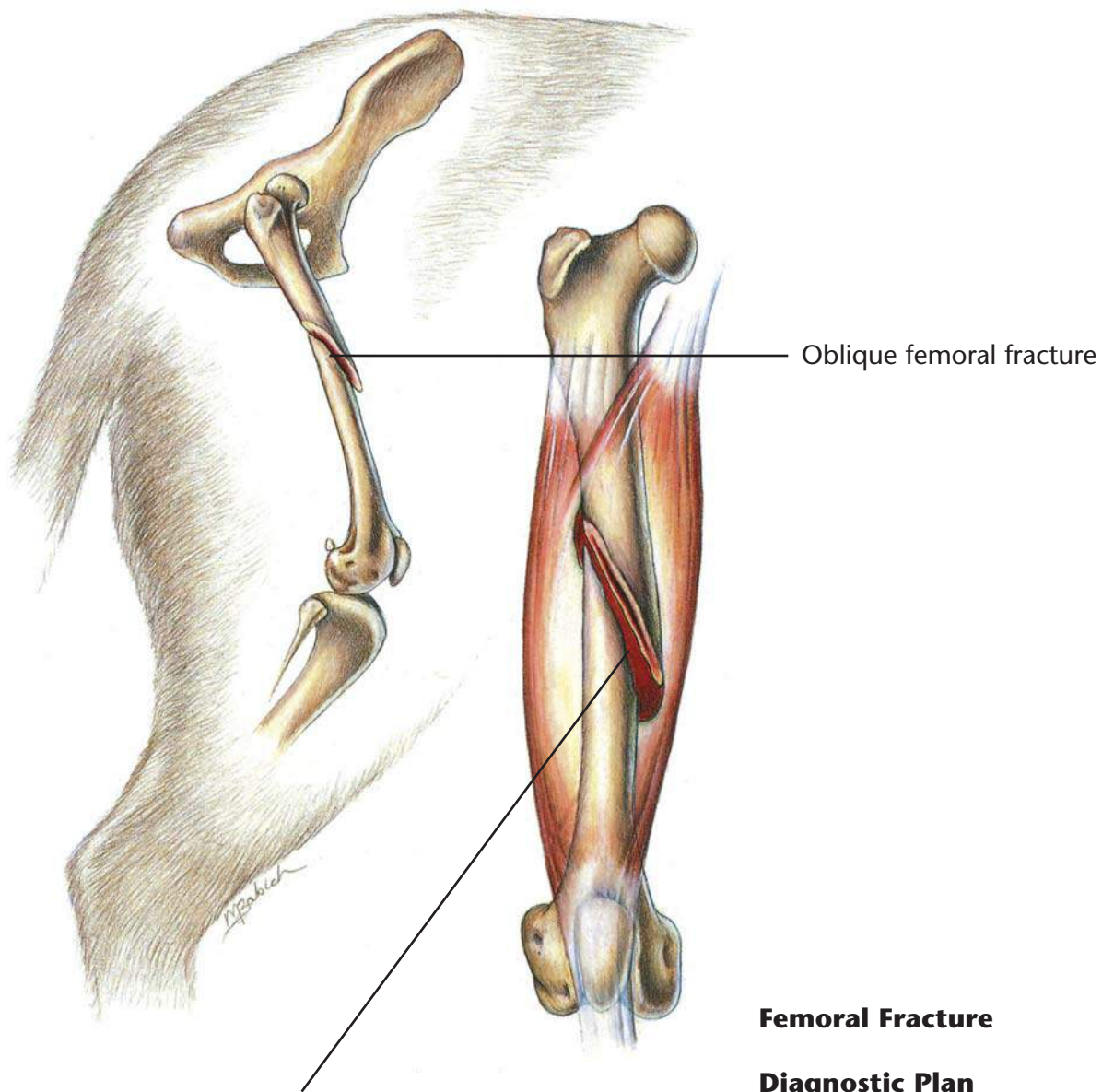
Therapeutic Plan

Enforced rest
Mild analgesics
Anti-inflammatory drugs
Surgery

Dietary Plan

Postsurgically, a diet adequate for tissue repair
If obesity is a complicating factor, restrict caloric intake so the patient reaches and maintains an ideal body weight





Hemorrhage into the muscle

Oblique femoral fracture

Femoral Fracture

Diagnostic Plan

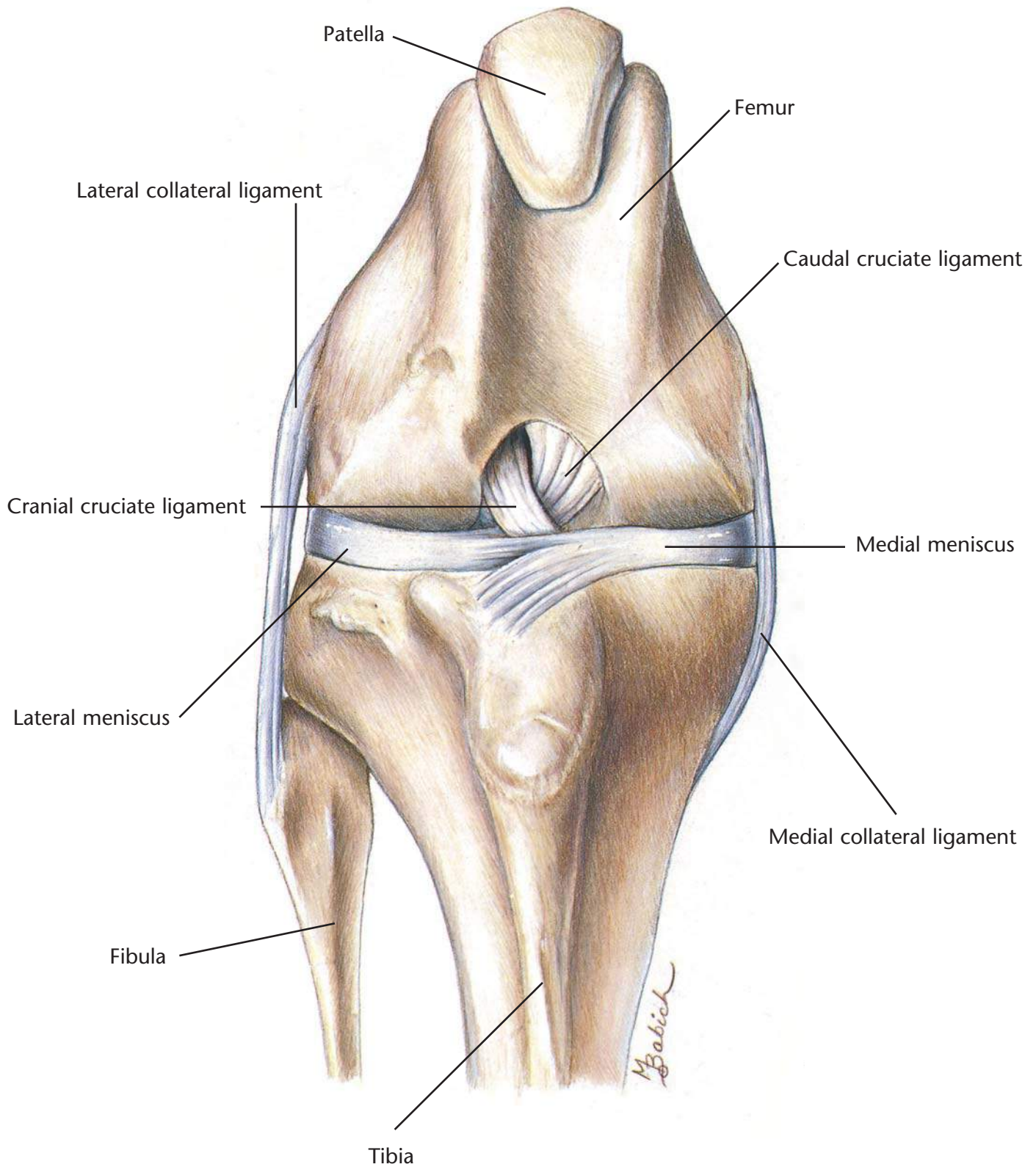
- History
- Physical examination
- Palpation of the femur
- X-rays

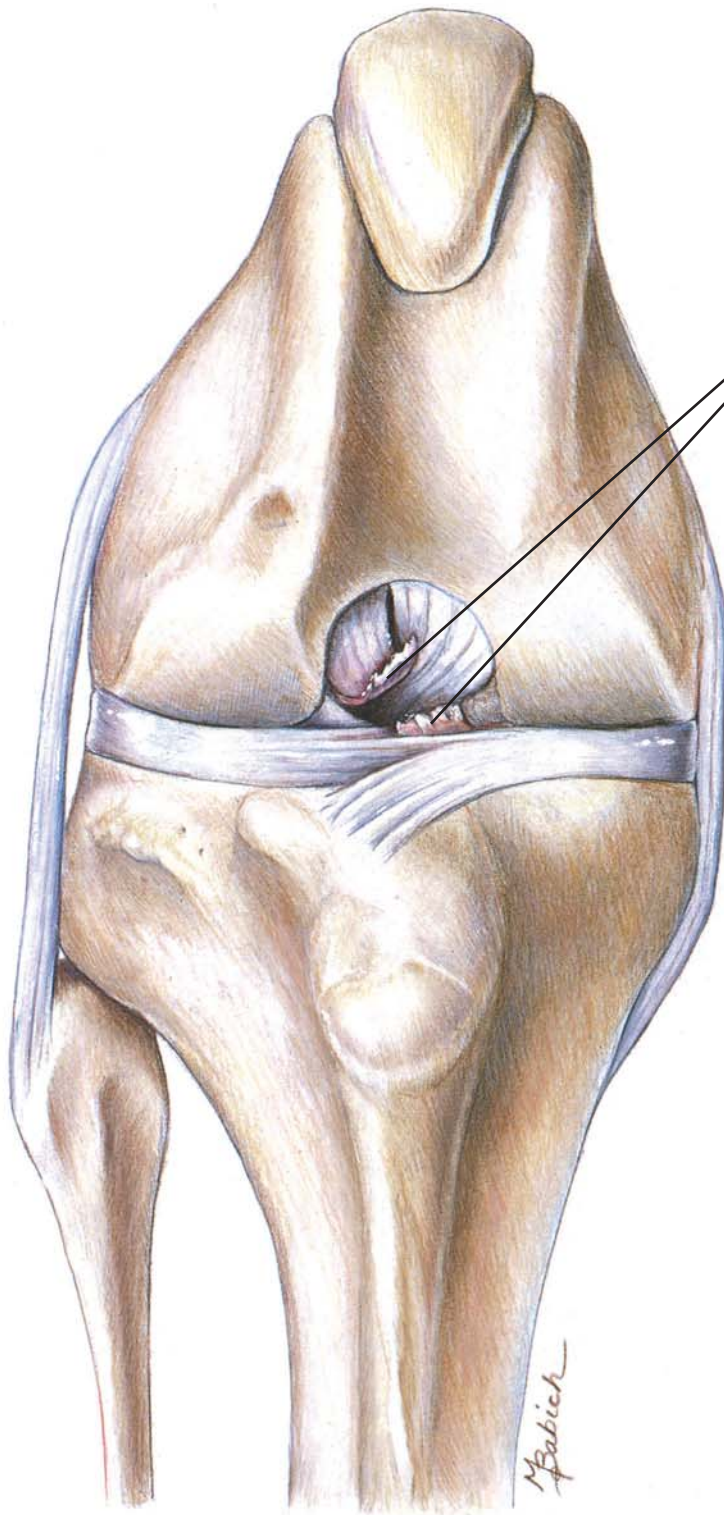
Therapeutic Plan

- Surgery

Dietary Plan

- A diet adequate for tissue repair





Ends of the ruptured cranial cruciate ligament

Ruptured Cranial Cruciate Ligament

Diagnostic Plan

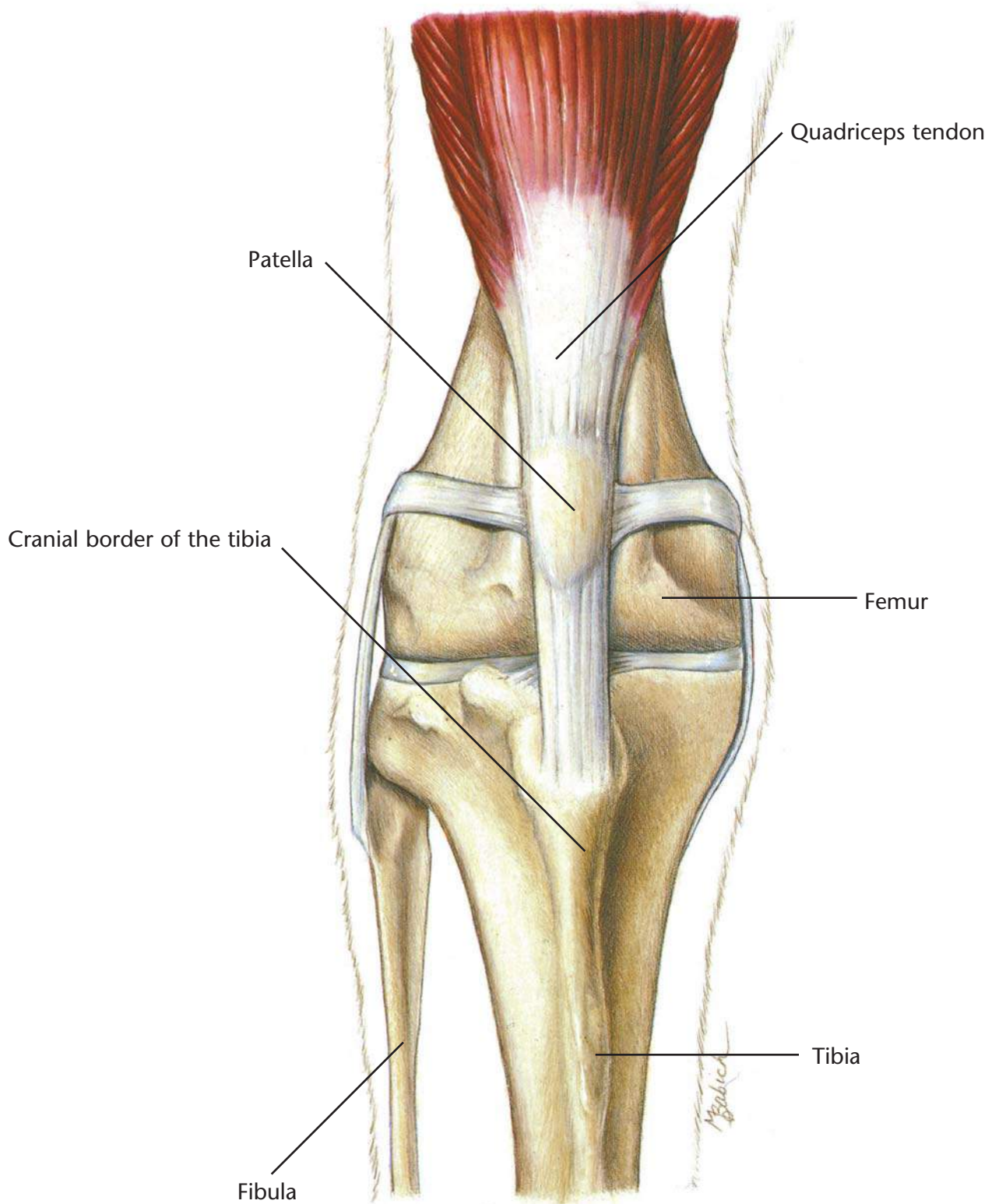
History
Physical examination
Palpation of the knee
X-rays of the knee

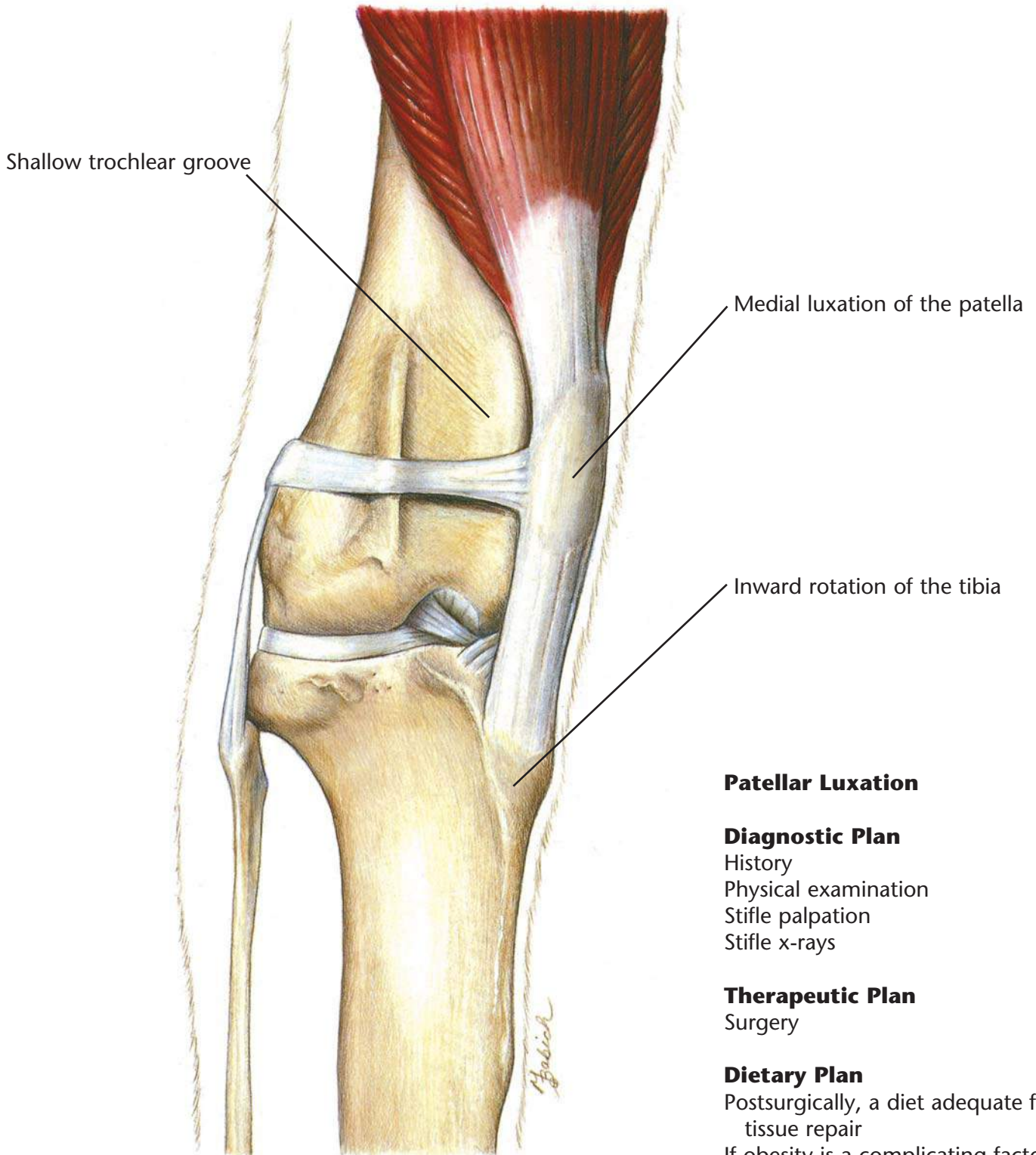
Therapeutic Plan

Enforced rest
Analgesics
Surgery

Dietary Plan

Postsurgically, a diet adequate for tissue repair
If obesity is a complicating factor, restrict caloric intake so the patient reaches and maintains an ideal body weight





Patellar Luxation

Diagnostic Plan

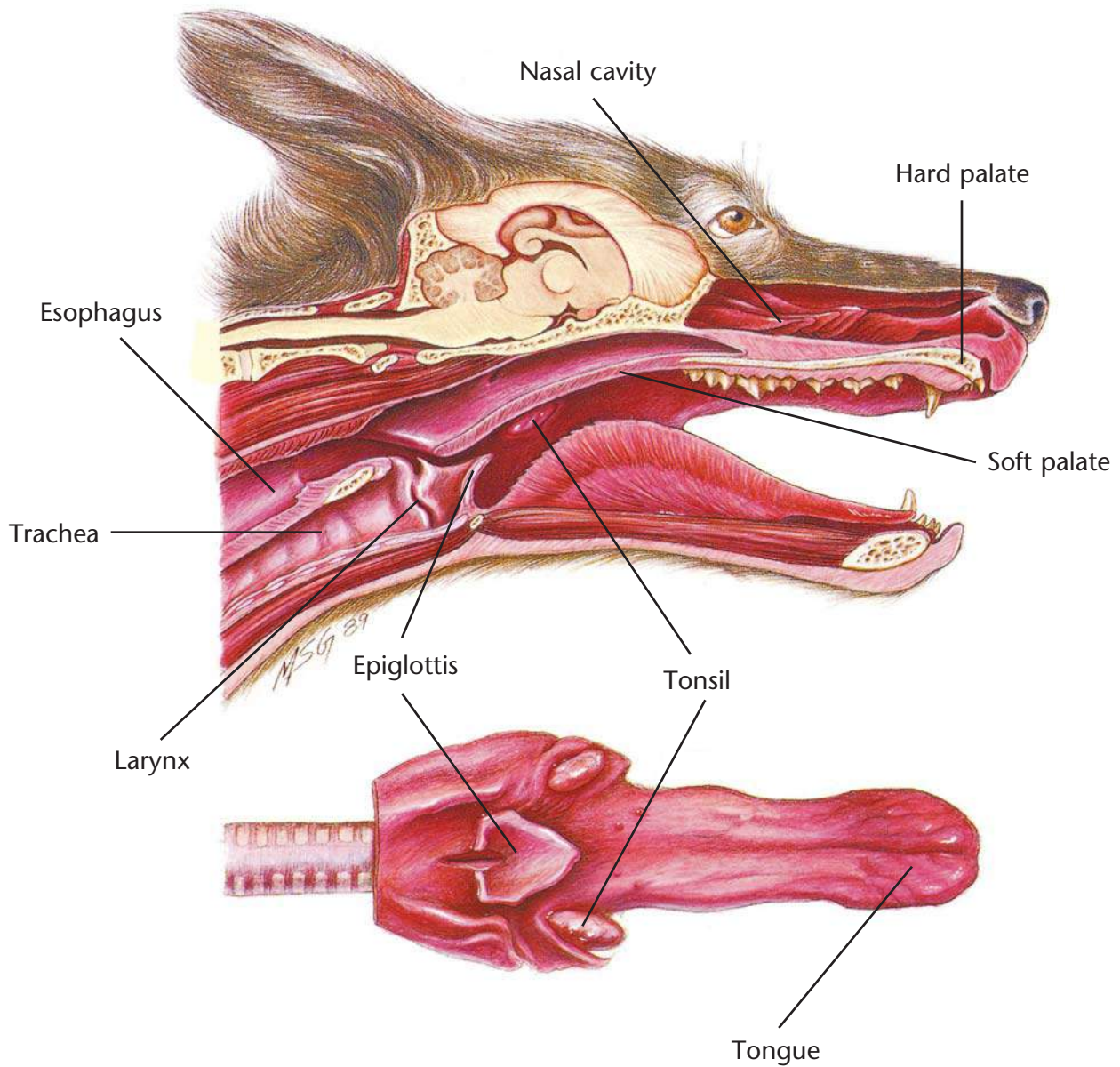
- History
- Physical examination
- Stifle palpation
- Stifle x-rays

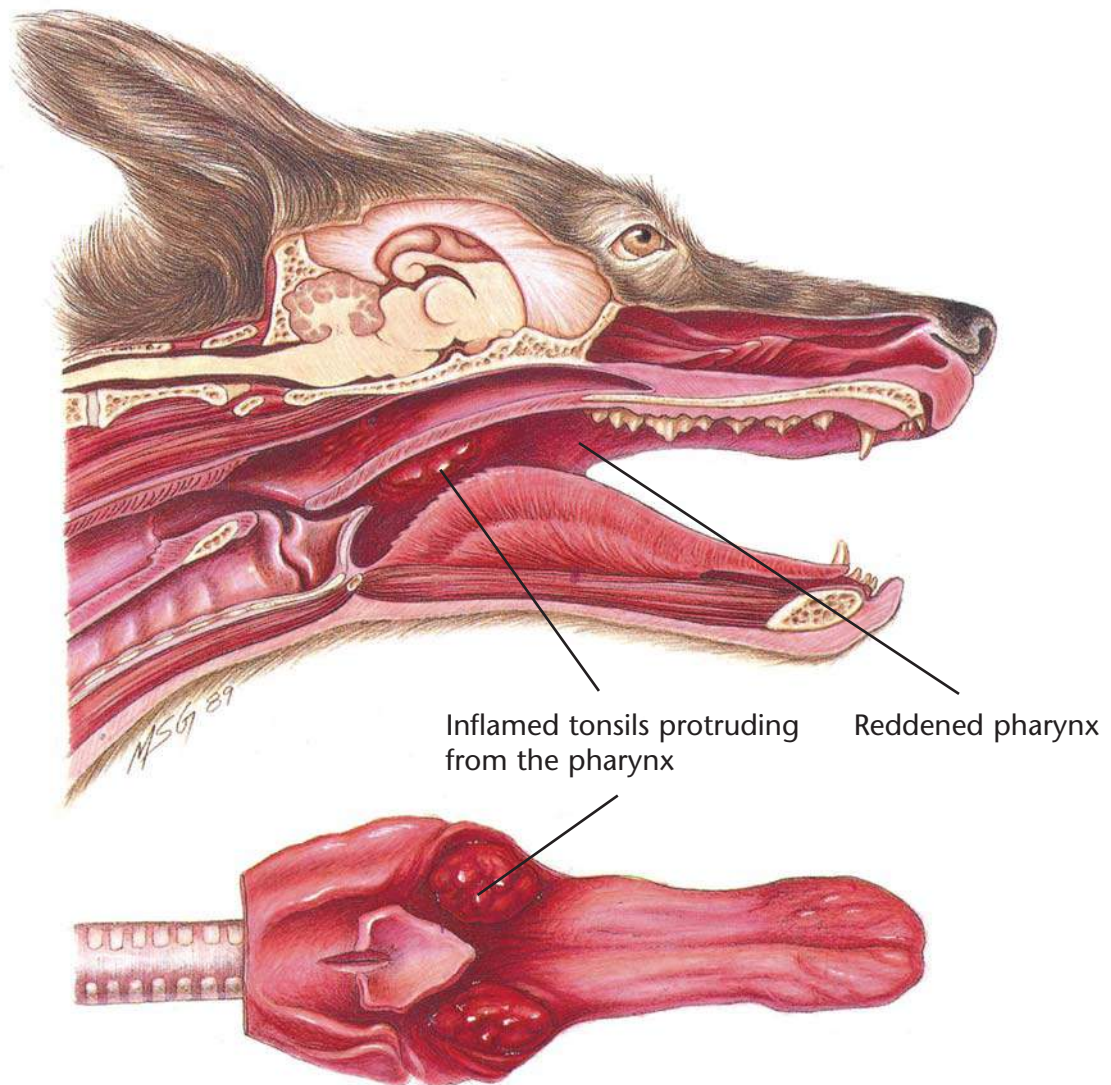
Therapeutic Plan

- Surgery

Dietary Plan

- Postsurgically, a diet adequate for tissue repair
- If obesity is a complicating factor, restrict caloric intake so the patient reaches and maintains an ideal body weight





Tonsillitis

Diagnostic Plan

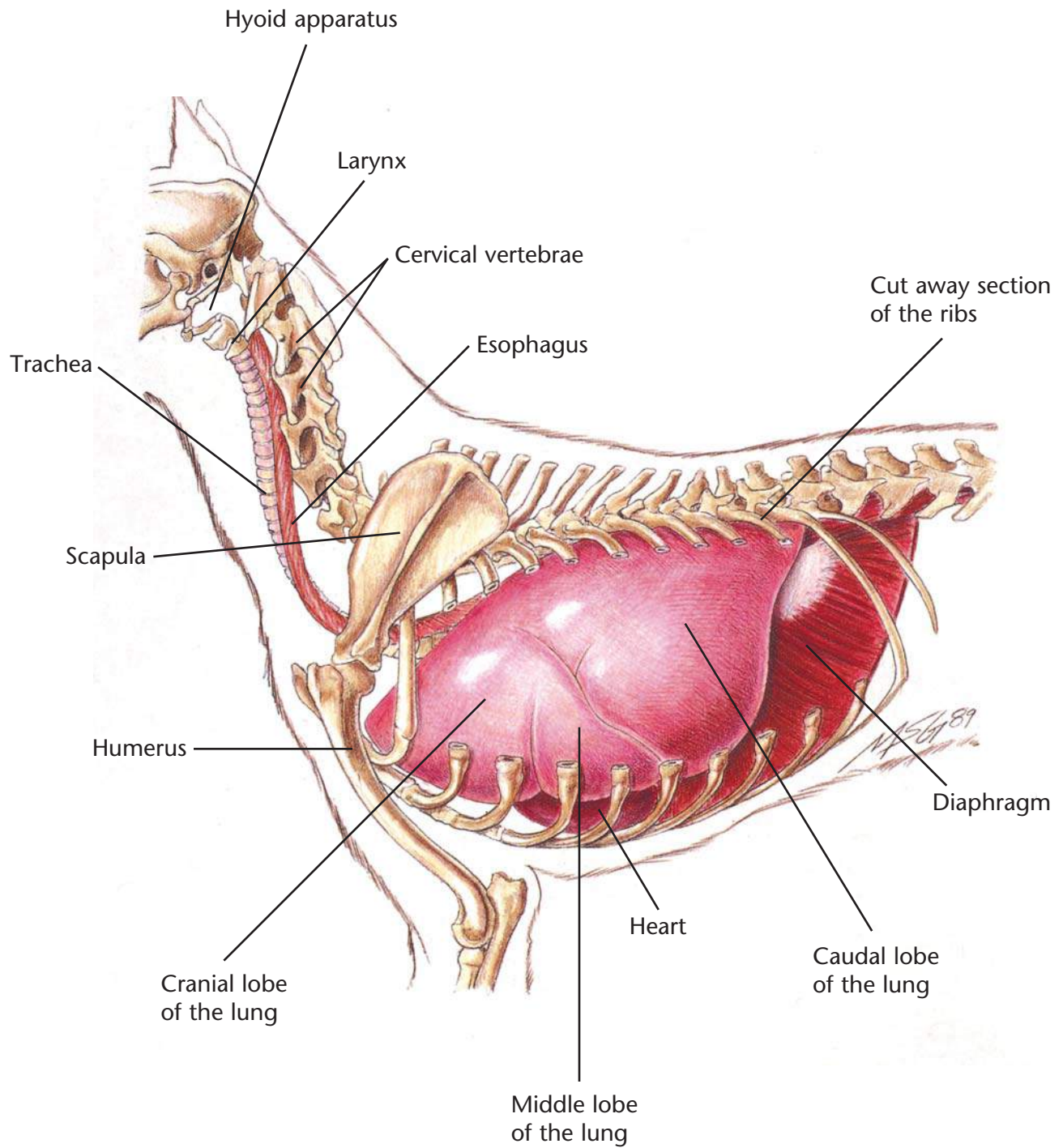
History
Physical examination
Examination of the tonsils
Culture of the tonsils
Cytologic study of tonsillar exudate
X-rays

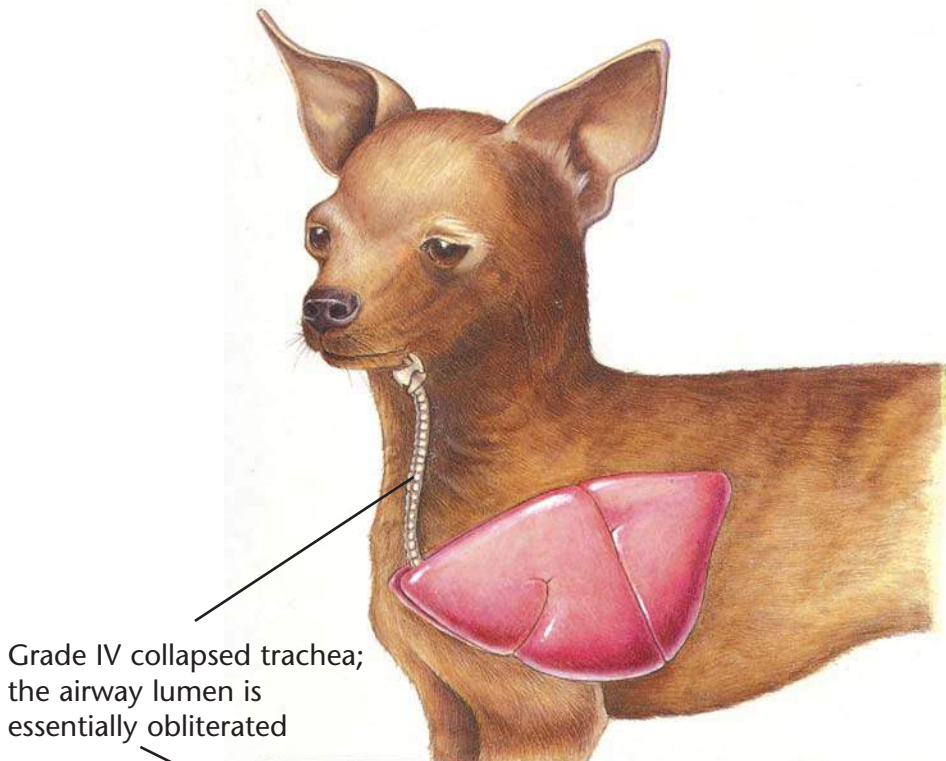
Therapeutic Plan

Elimination of the cause
Antibacterials
Tonsillectomy

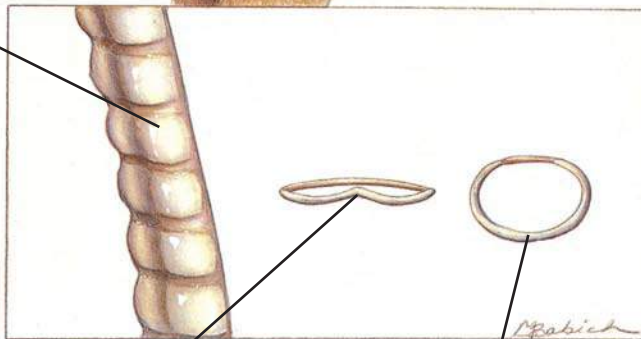
Dietary Plan

A diet based on overall patient evaluation including body condition and other organ system involvement
A soft diet may minimize postsurgical pain





Grade IV collapsed trachea; the airway lumen is essentially obliterated



The tracheal cartilage is inverted dorsally and contacts the tracheal membrane

Normal tracheal ring

Collapsing Trachea

Diagnostic Plan

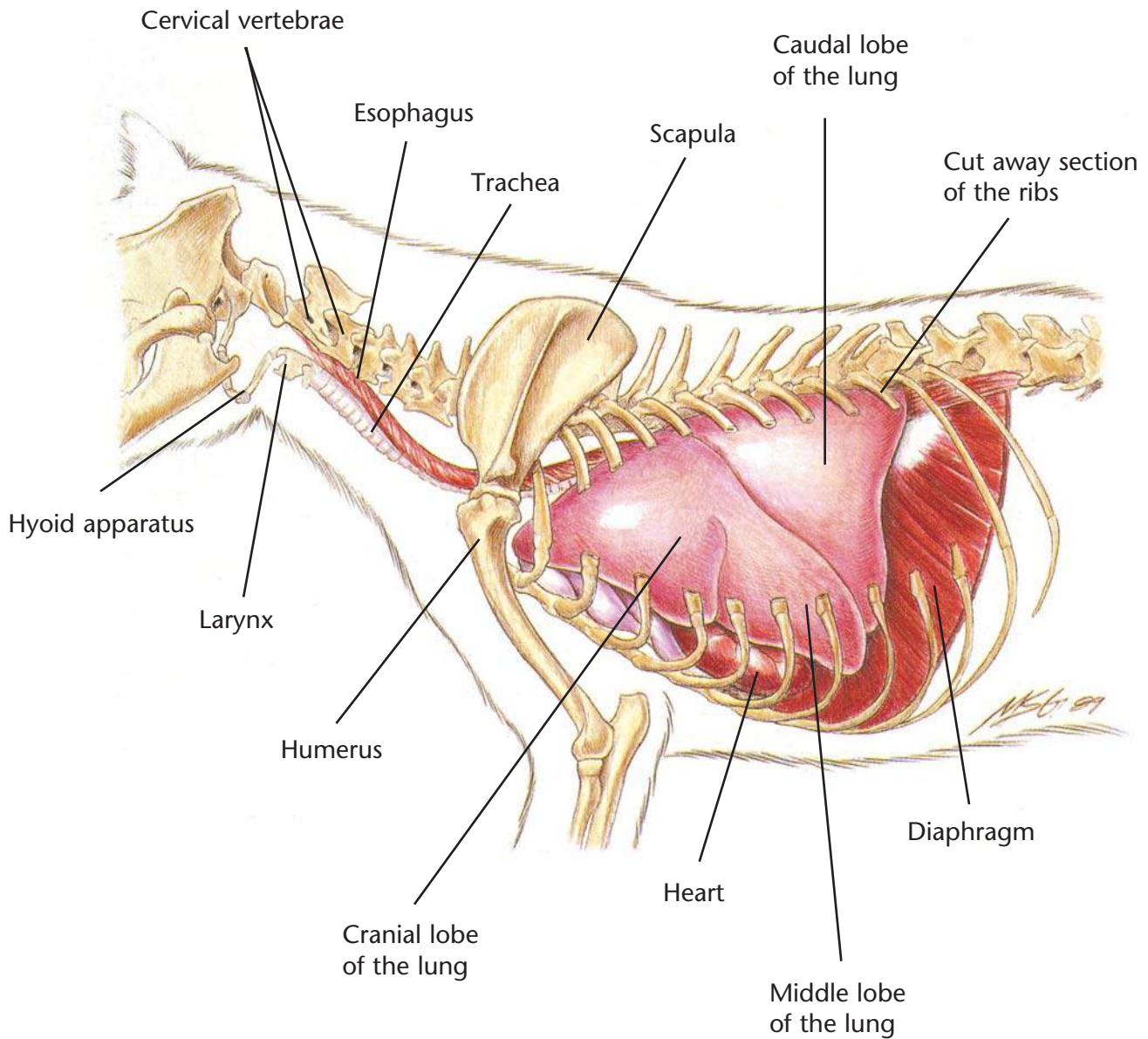
- History
- Physical examination
- Tracheal palpation
- Chest auscultation
- Chest x-rays
- Tracheoscopy
- Cultures of tracheal wash fluid

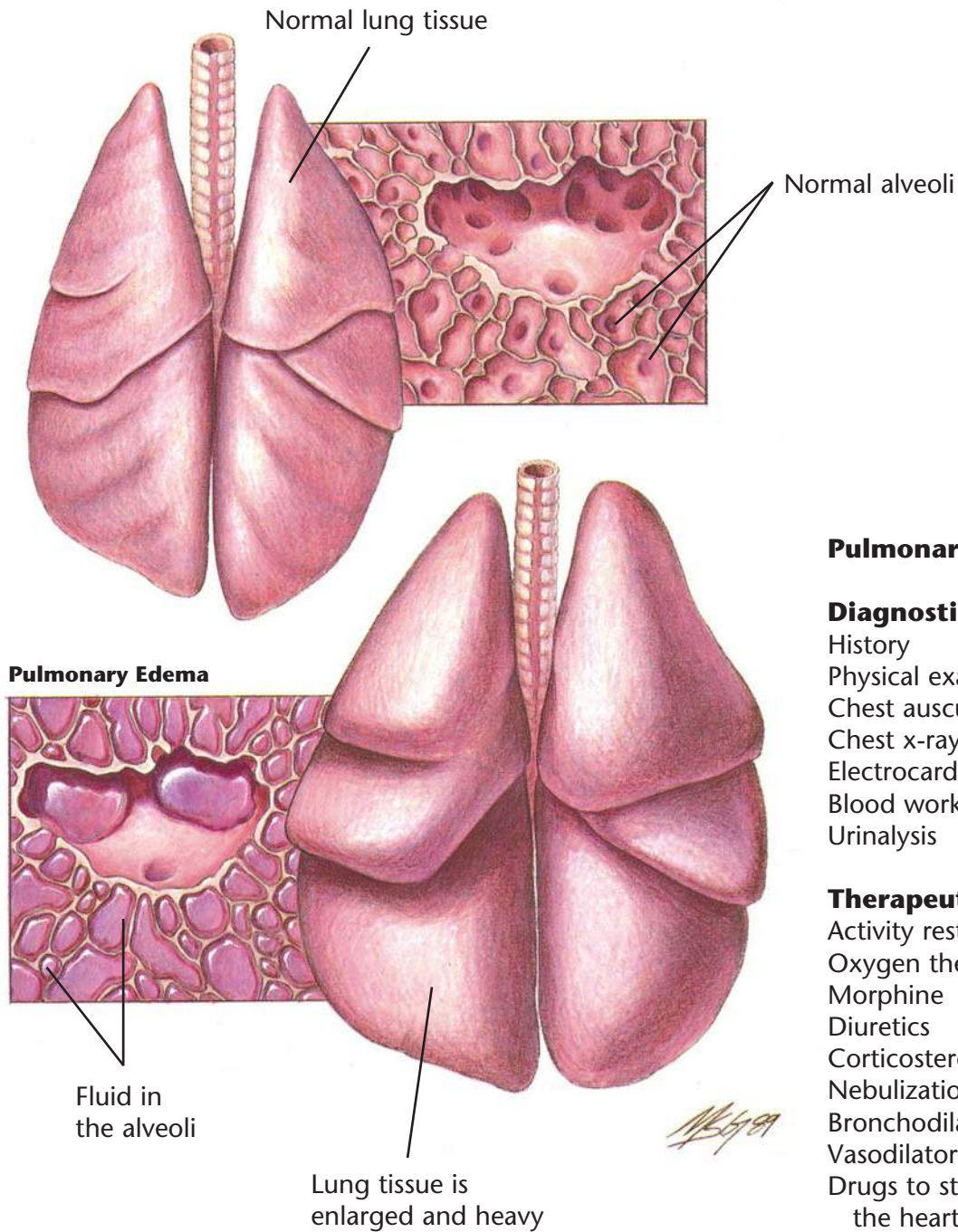
Therapeutic Plan

- Activity restriction
- Corticosteroids
- Steam vaporization
- Bronchodilators
- Antitussives
- Antibacterials
- Surgery

Dietary Plan

If surgery is performed, a diet adequate for tissue repair
If obesity is a complicating factor, restrict caloric intake so the patient reaches and maintains an ideal body weight





Pulmonary Edema

Diagnostic Plan

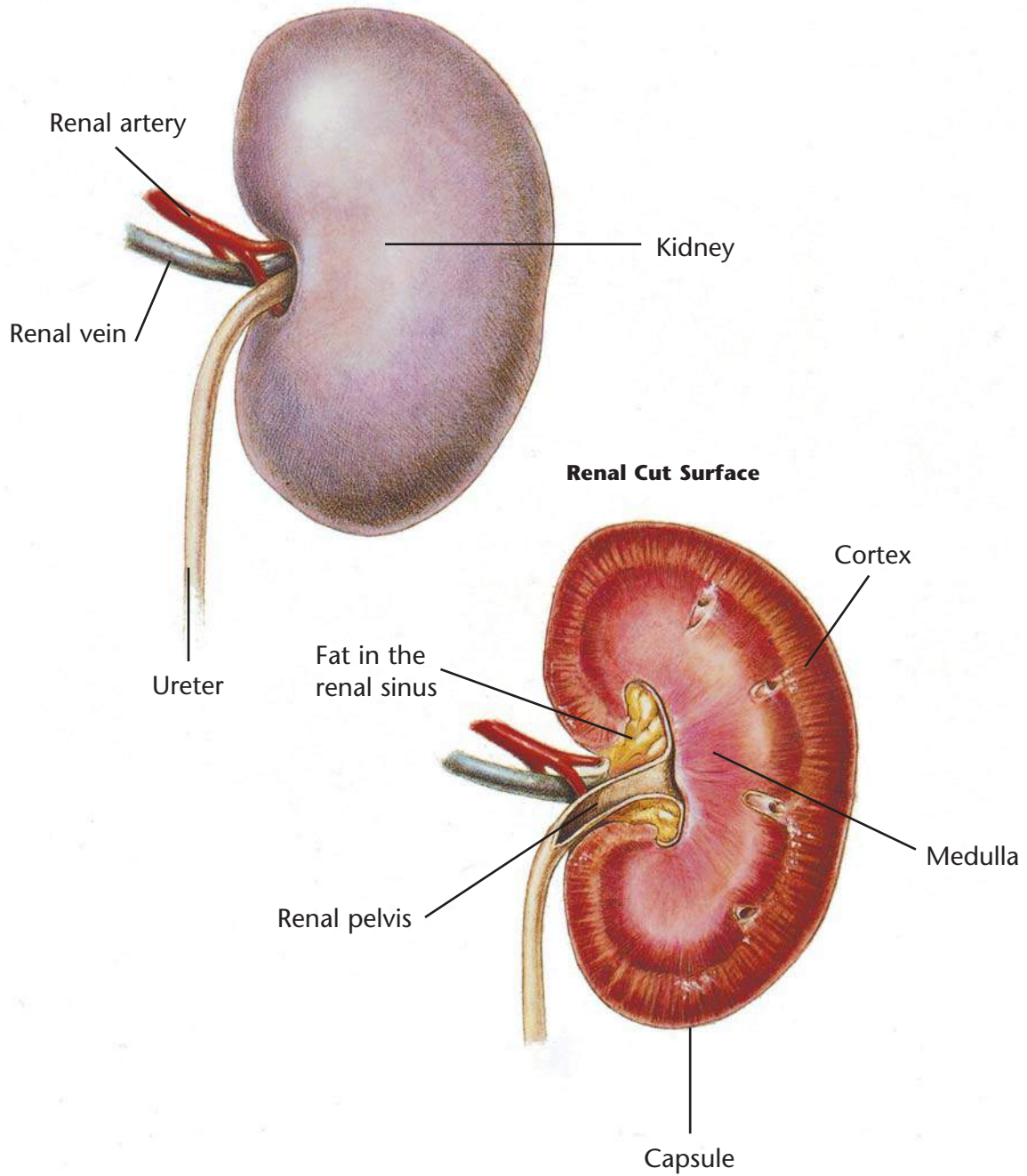
- History
- Physical examination
- Chest auscultation
- Chest x-rays
- Electrocardiography
- Blood work
- Urinalysis

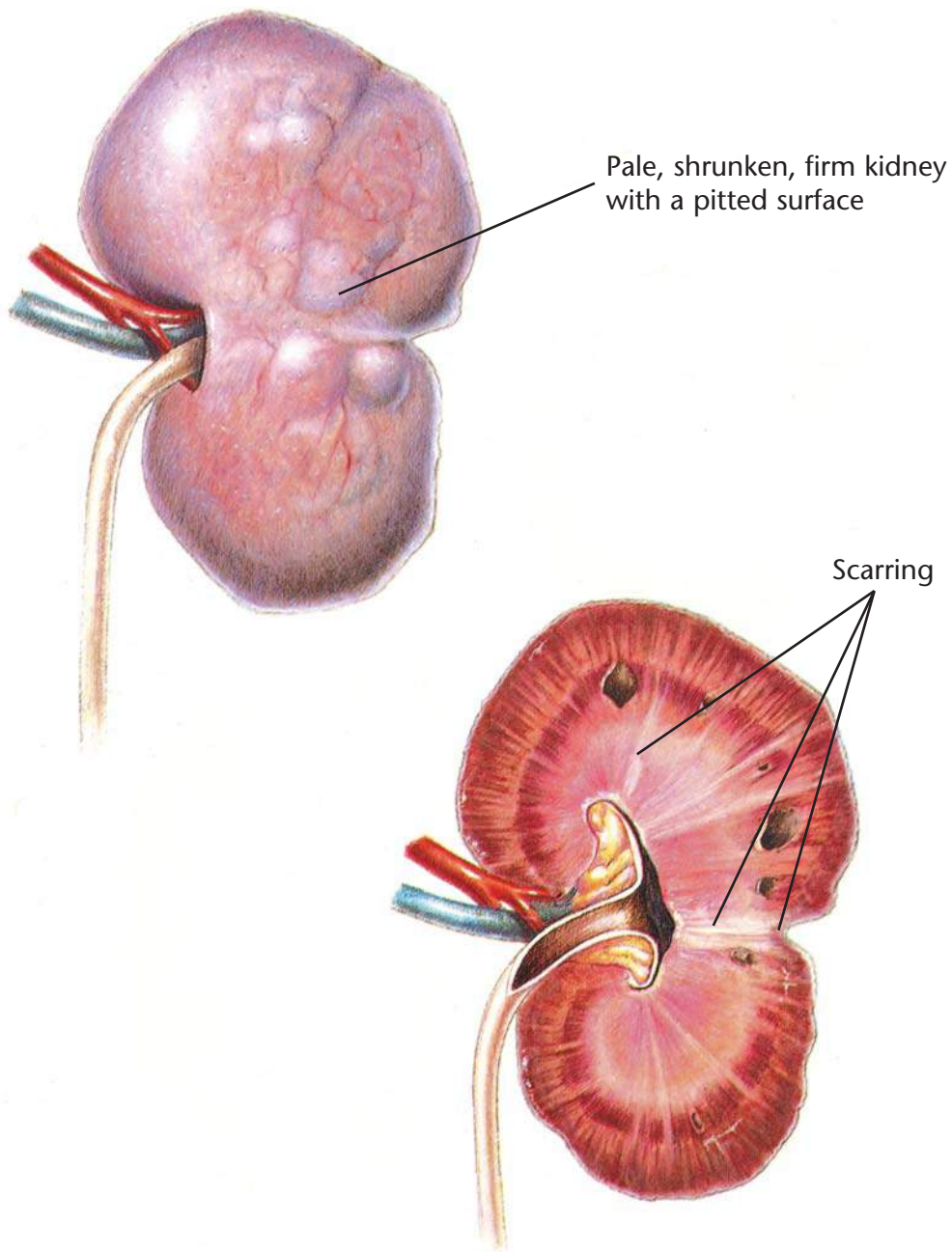
Therapeutic Plan

- Activity restriction
- Oxygen therapy
- Morphine
- Diuretics
- Corticosteroids
- Nebulization
- Bronchodilators
- Vasodilators
- Drugs to strengthen the heart

Dietary Plan

- A diet based on individual patient evaluation including body condition and other organ system involvement or disease
- Avoid excess sodium





Chronic Renal Disease

Diagnostic Plan

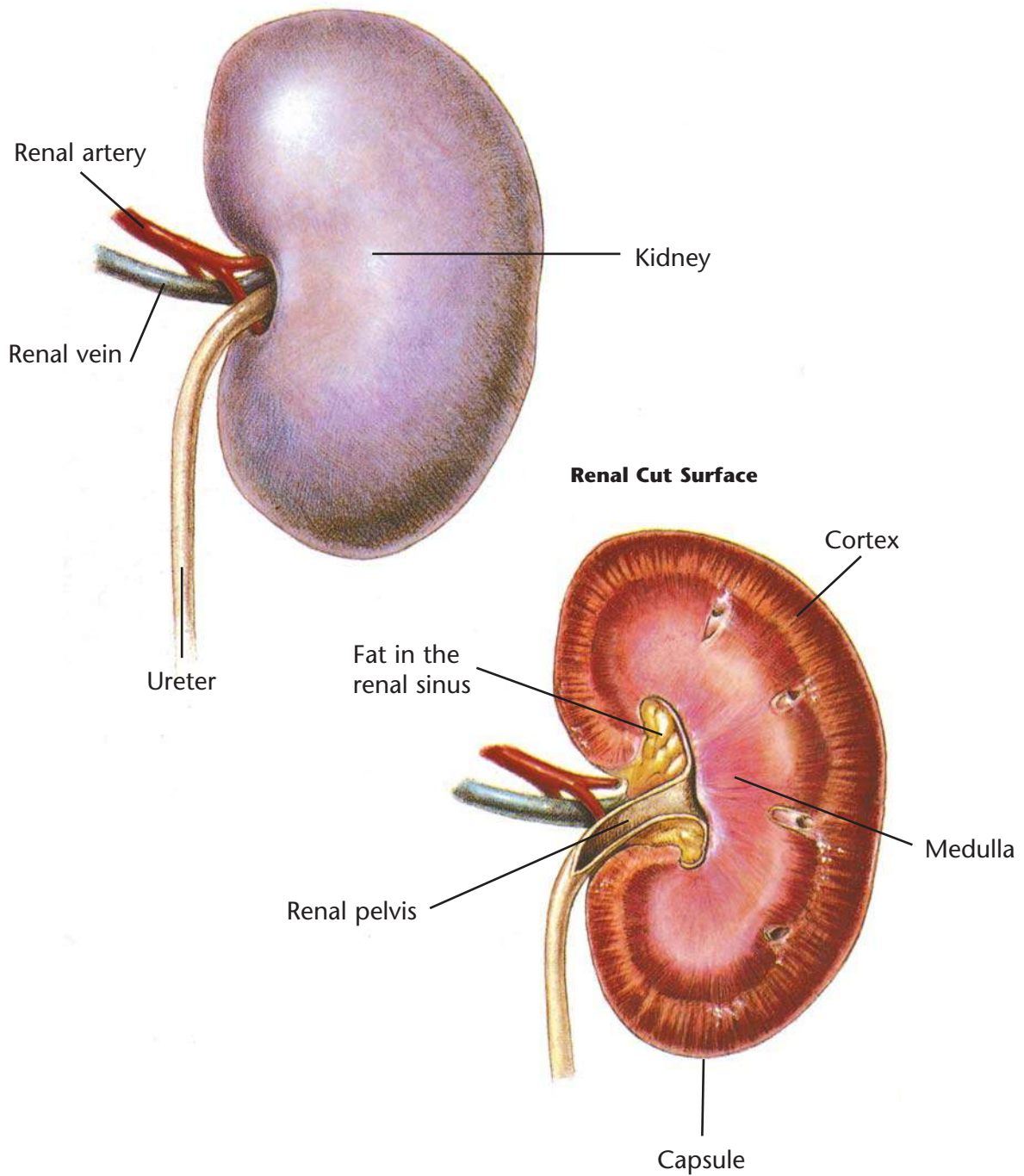
- History
- Physical examination
- Abdominal palpation
- Urinalysis
- Blood work
- Blood pressure measurement
- Abdominal x-rays
- Kidney biopsy
- Ultrasound

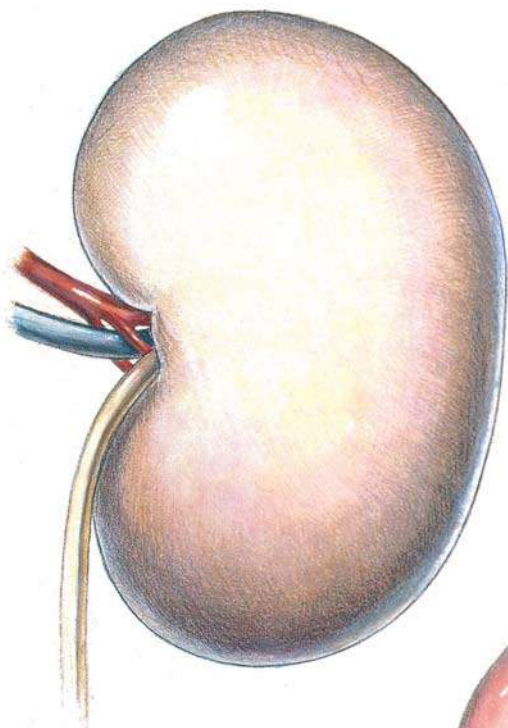
Therapeutic Plan

- Fluid therapy
- Sodium bicarbonate
- Drugs to control stomach acidity
- Phosphate binders
- Blood transfusions
- Anabolic steroids
- Peritoneal dialysis

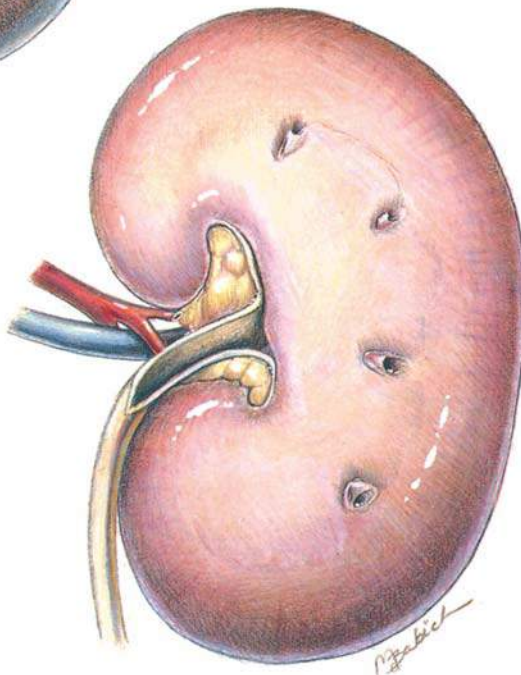
Dietary Plan

A diet with controlled and appropriate levels of protein, phosphorus, sodium, and calories





Pale, swollen kidney



Acute Renal Failure

Diagnostic Plan

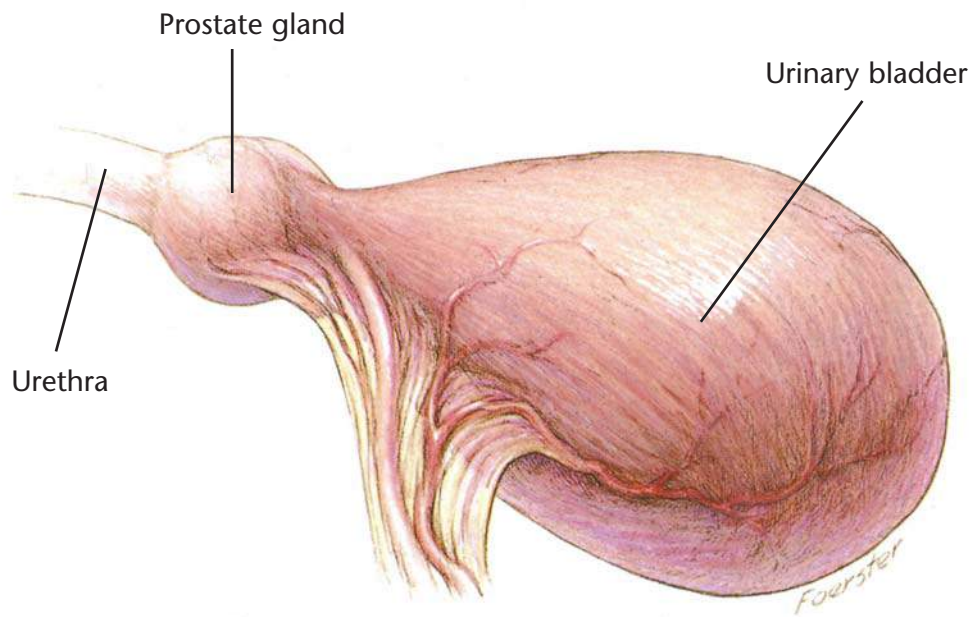
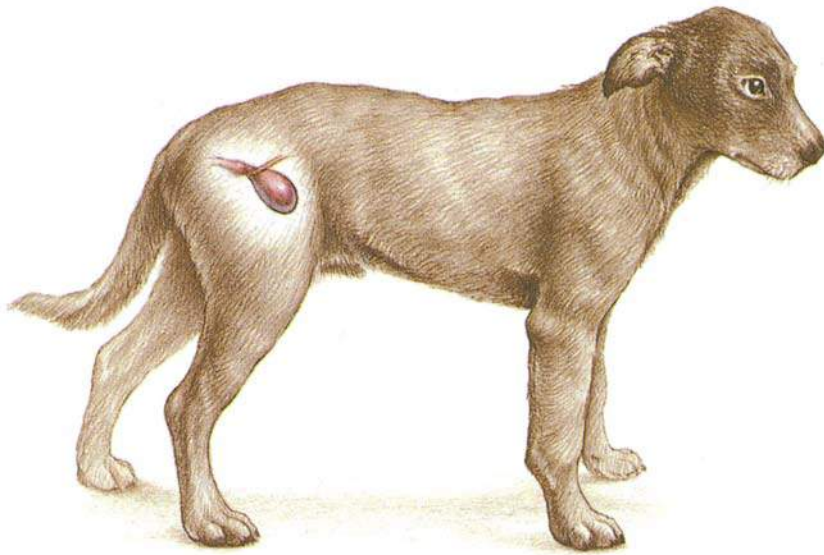
- History
- Physical examination
- Abdominal palpation
- Urinalysis
- Blood work
- Abdominal x-rays
- Kidney biopsy
- Ultrasound

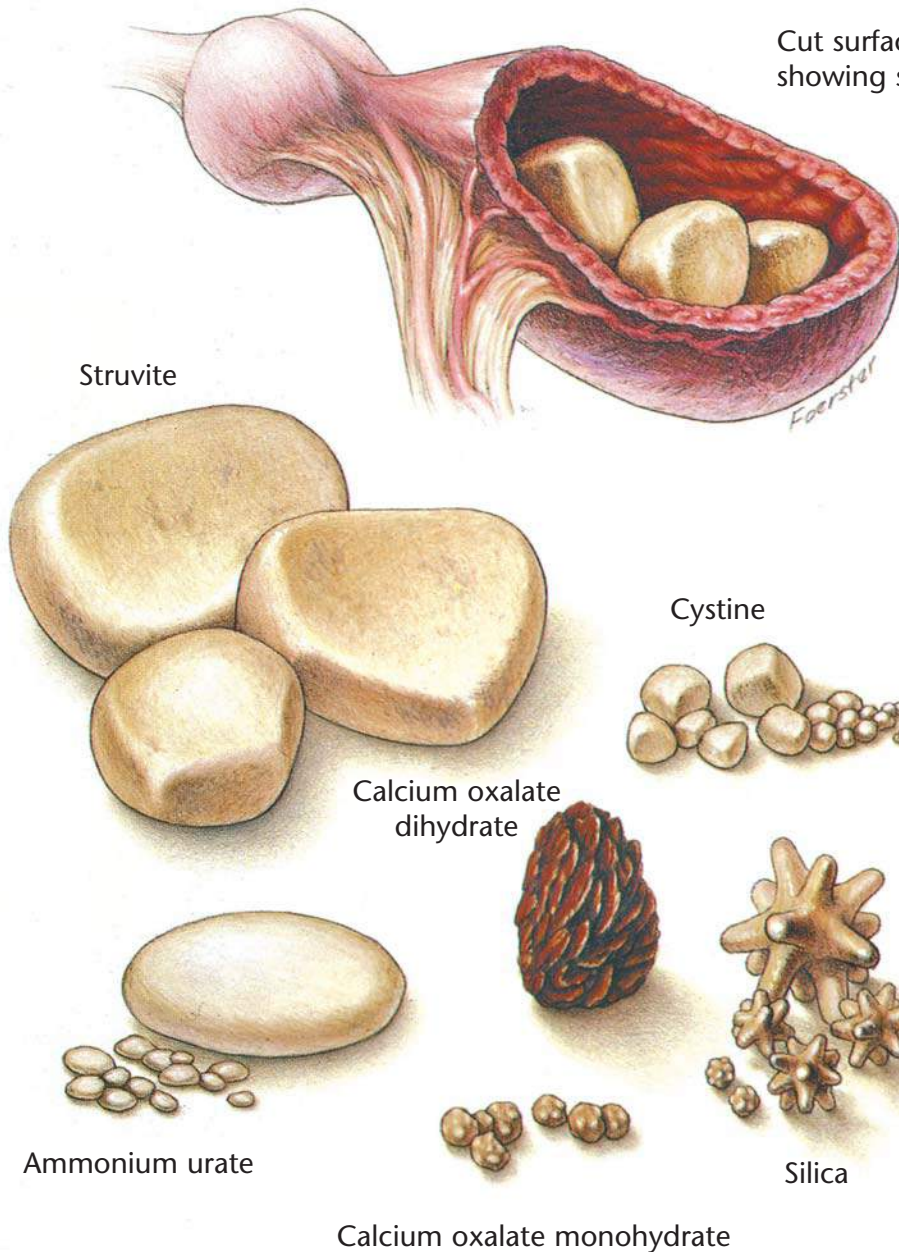
Therapeutic Plan

- Fluid therapy
- Diuretics
- Phosphate binders
- Sodium bicarbonate
- Drugs to control stomach acidity
- Peritoneal dialysis

Dietary Plan

A diet with controlled and appropriate levels of protein, phosphorus, sodium, and calories





Cut surface of a bladder showing struvite calculi

Bladder Stones

Diagnostic Plan

- History
- Physical examination
- Palpation of the urethra and urinary bladder
- Urinalysis
- Urine culture
- Blood work
- X-rays of the urinary tract
- Quantitative analysis of passed bladder stones

Therapeutic Plan*

- Fluid therapy
- Antibacterials
- Urease inhibitors
- Xanthine oxidase inhibitors
- Urine alkalinizers
- Thiol-containing drugs
- Surgery
- Voiding urohydropropulsion

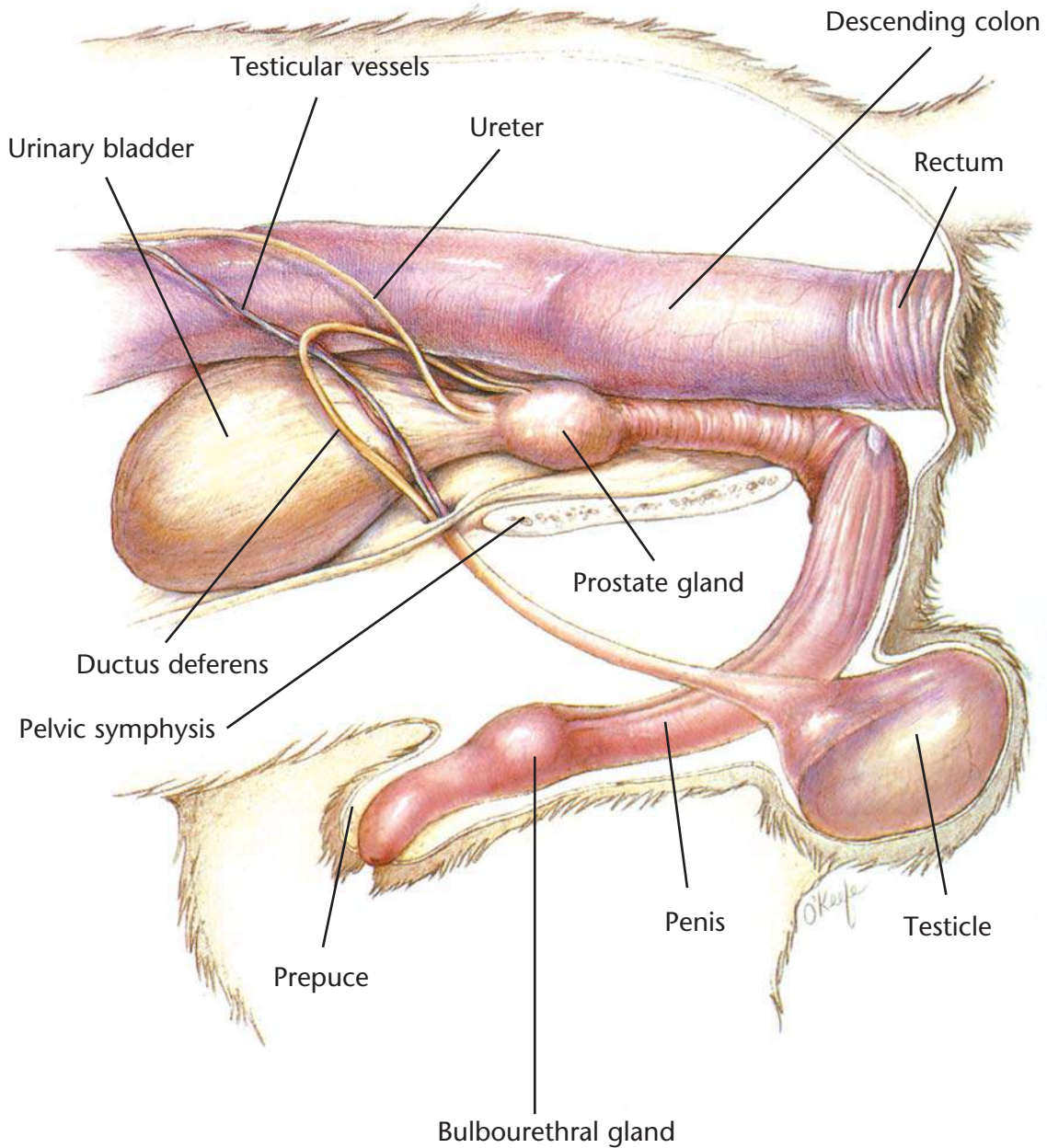
Dietary Plan*

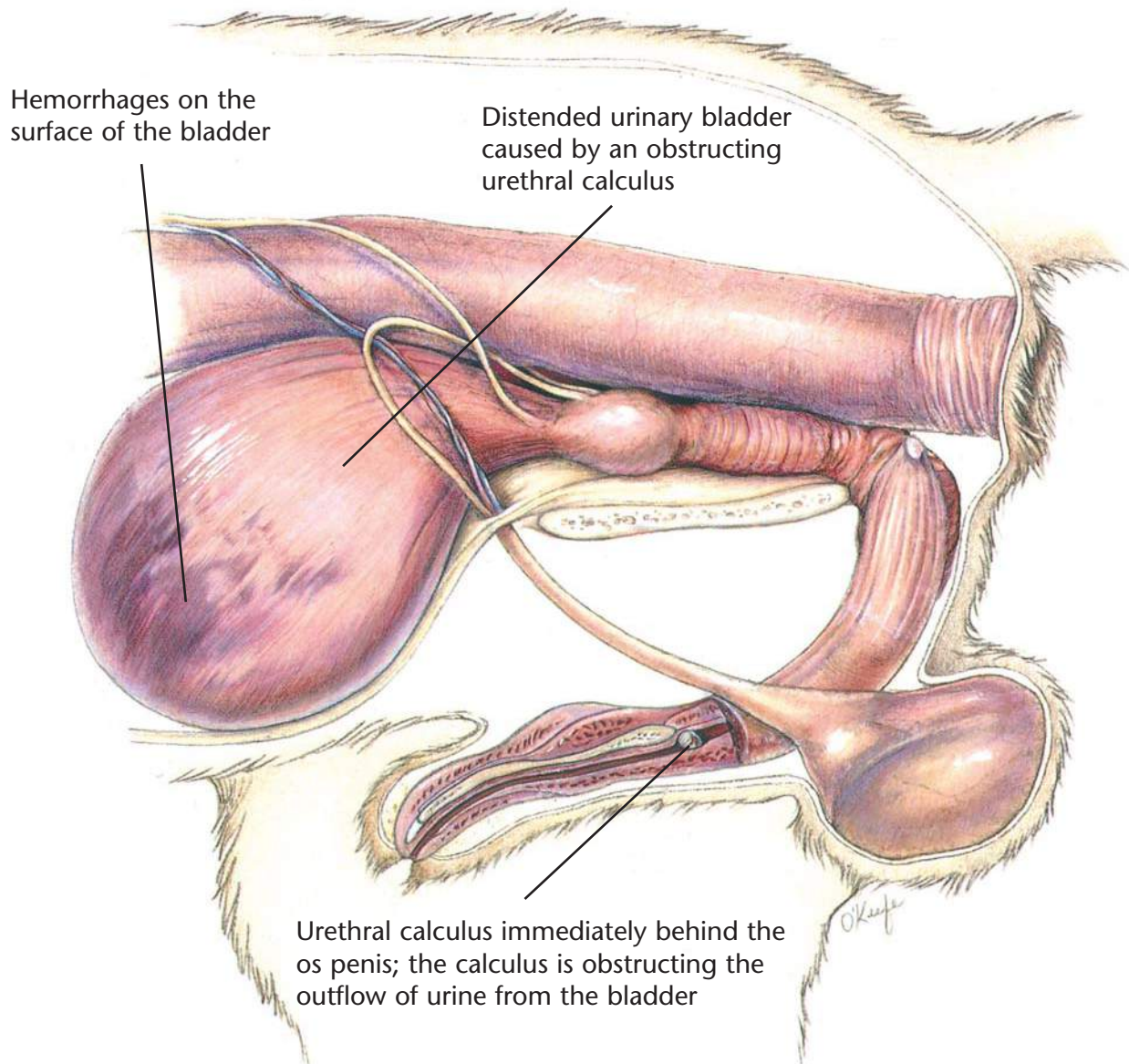
- For dissolution, the proper calculolytic diet
- To aid in prevention or recurrence, a diet that allows the body to produce the appropriate urine pH and avoids excesses of the urolith's precursors
- If surgery is necessary, a diet adequate for tissue repair

*Determined by stone type

Hill's Atlas of Veterinary Clinical Anatomy

Normal Canine Lower Urinary System





Canine Urethral Obstruction

Diagnostic Plan

- History
- Physical examination
- Urethral palpation
- Abdominal palpation
- X-rays of the urinary tract
- Urinalysis
- Urine culture
- Blood work
- Analysis of passed bladder stones

Therapeutic Plan

- Emptying of the bladder
- Fluid therapy
- Flushing of the urethral calculi into the bladder
- Surgery

Dietary Plan

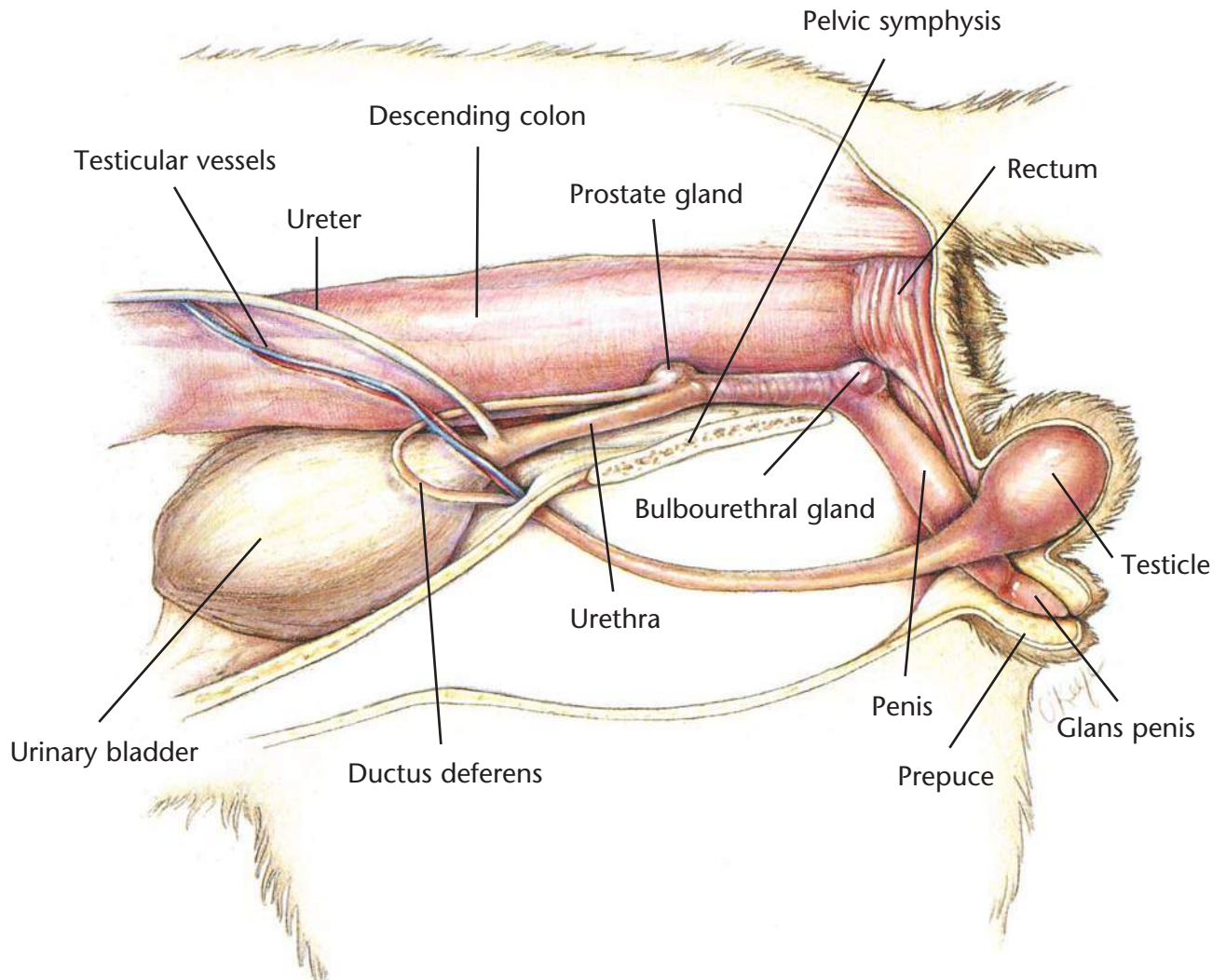
For dissolution, the proper calculolytic diet

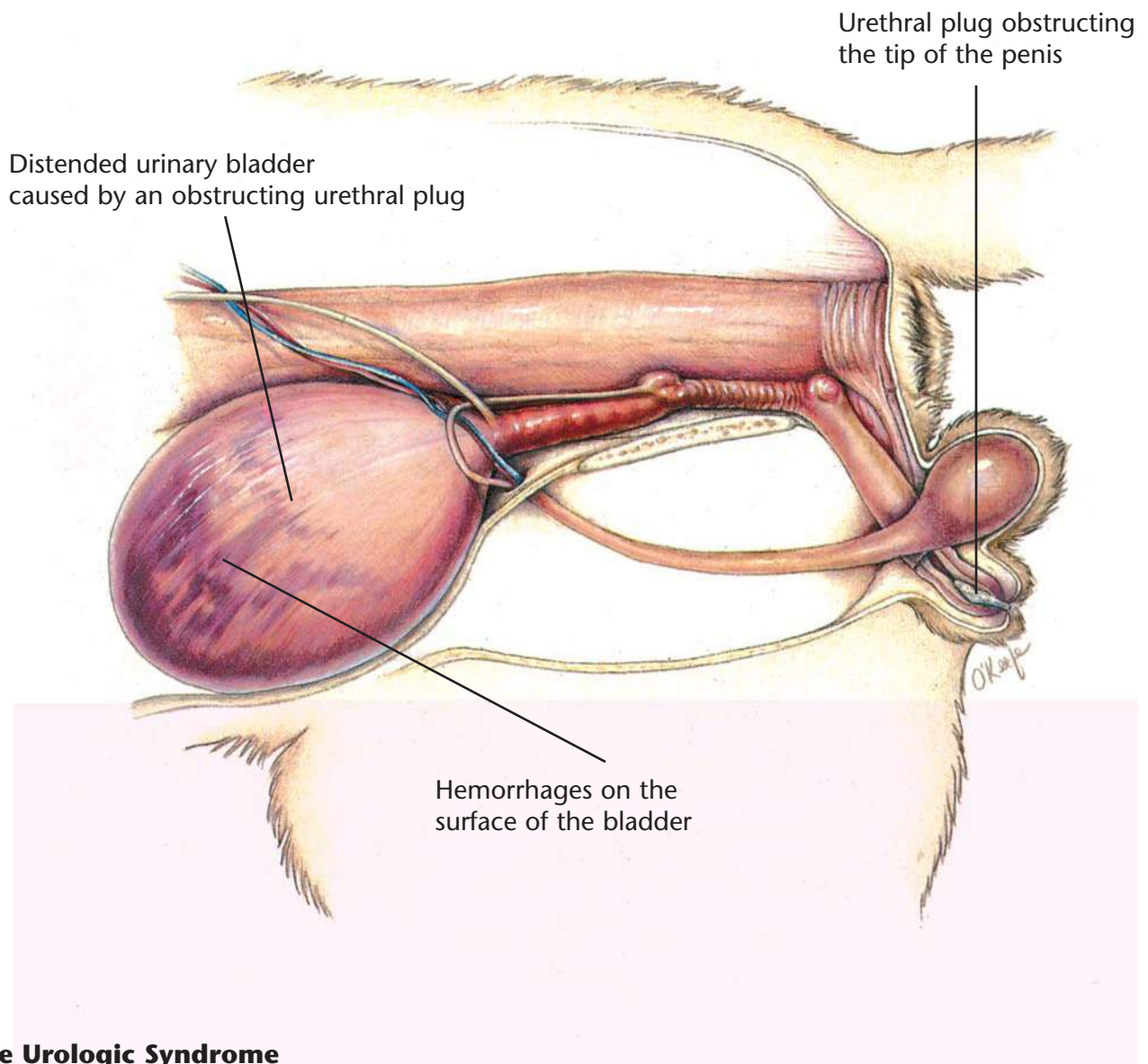
To aid in prevention or recurrence, a diet that allows the body to produce the appropriate urine pH and avoids excesses of the urolith's precursors

If surgery is necessary, a diet adequate for tissue repair

Hill's Atlas of Veterinary Clinical Anatomy

Normal Feline Lower Urinary System





Feline Urologic Syndrome

Diagnostic Plan

- History
- Physical examination
- Abdominal palpation
- Urethral palpation
- Urinalysis
- Urine culture
- X-rays of the urinary tract
- Blood work

Therapeutic Plan

- Emptying of the bladder
- Fluid therapy
- Removal of the urinary obstruction

Dietary Plan

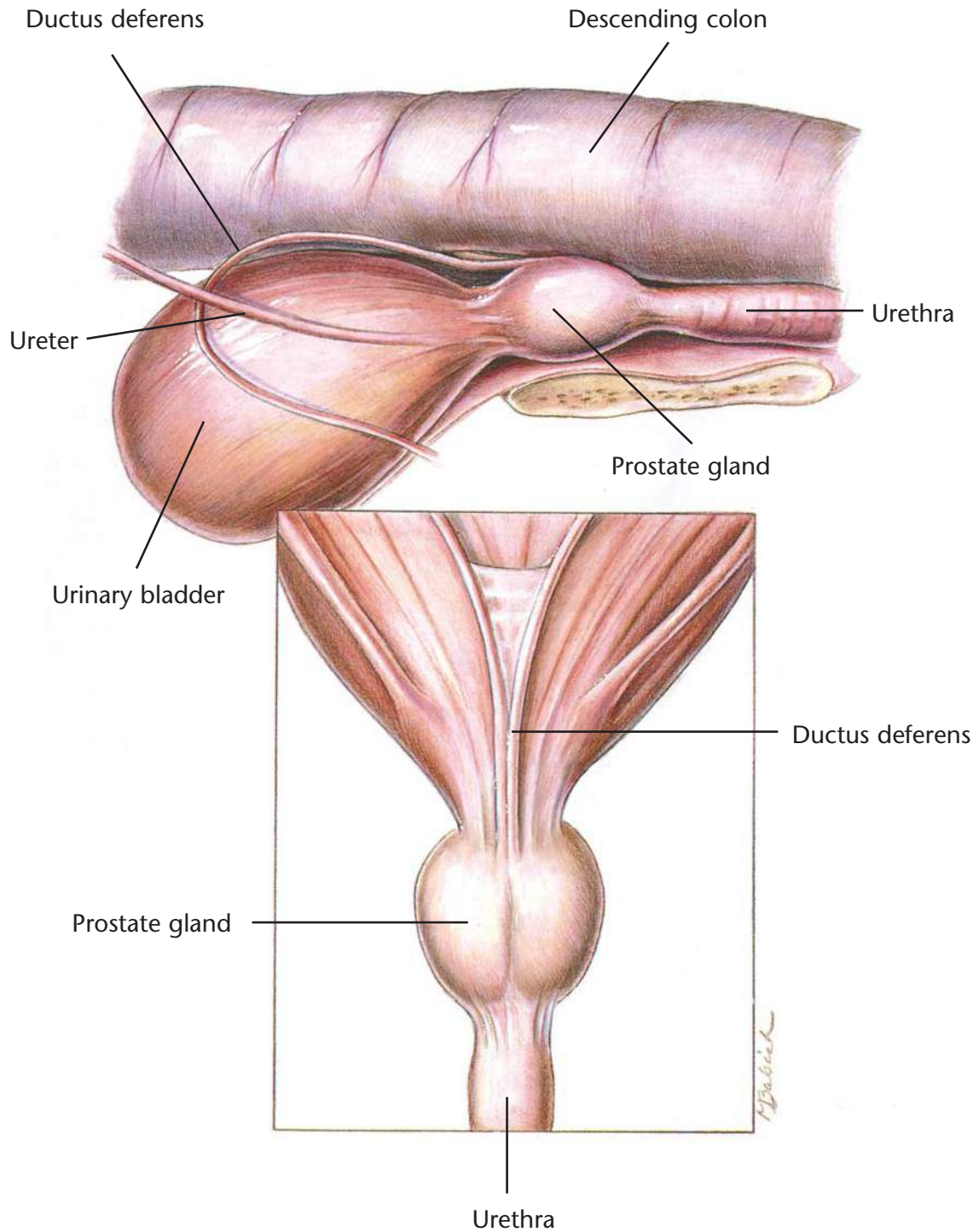
For dissolution, the proper calculolytic diet

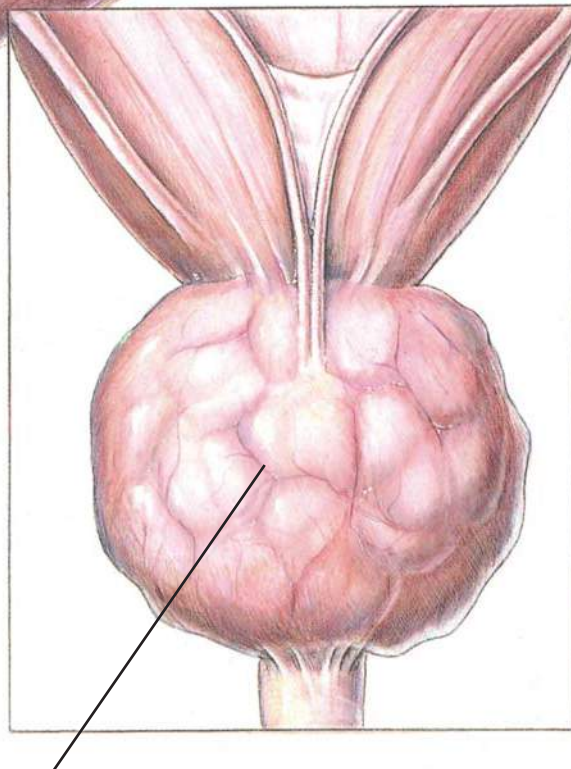
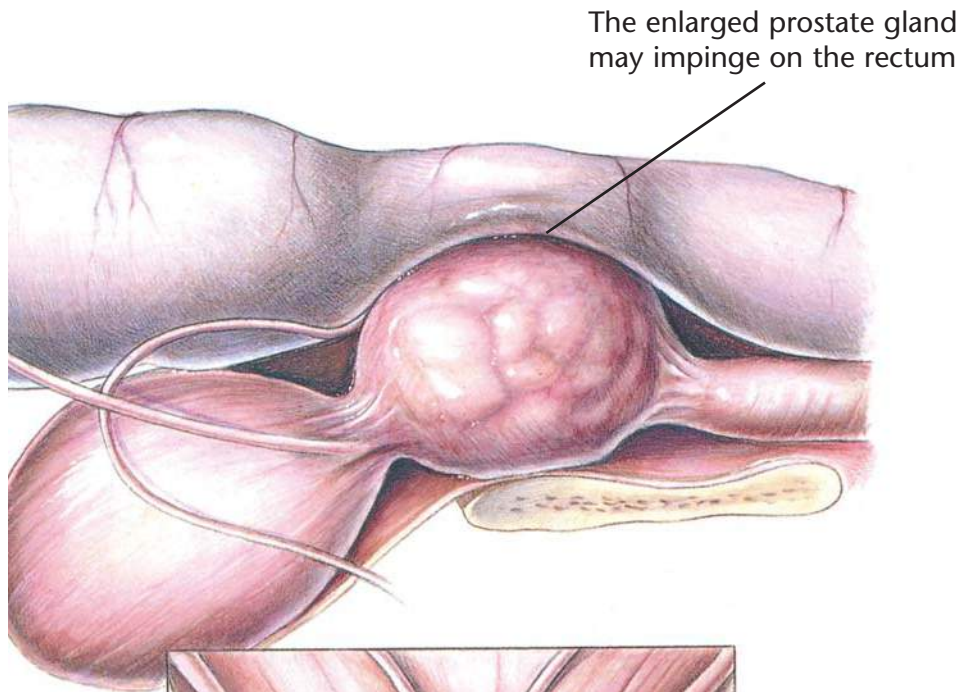
To aid in prevention or recurrence, a diet that allows the body to produce the appropriate urine pH and avoids excesses of the urolith's precursors

If surgery is necessary, a diet adequate for tissue repair

Hill's Atlas of Veterinary Clinical Anatomy

Normal Prostate Gland





Diffuse enlargement of the prostate gland due to epithelial or glandular hyperplasia

Benign Prostatic Hyperplasia

Diagnostic Plan

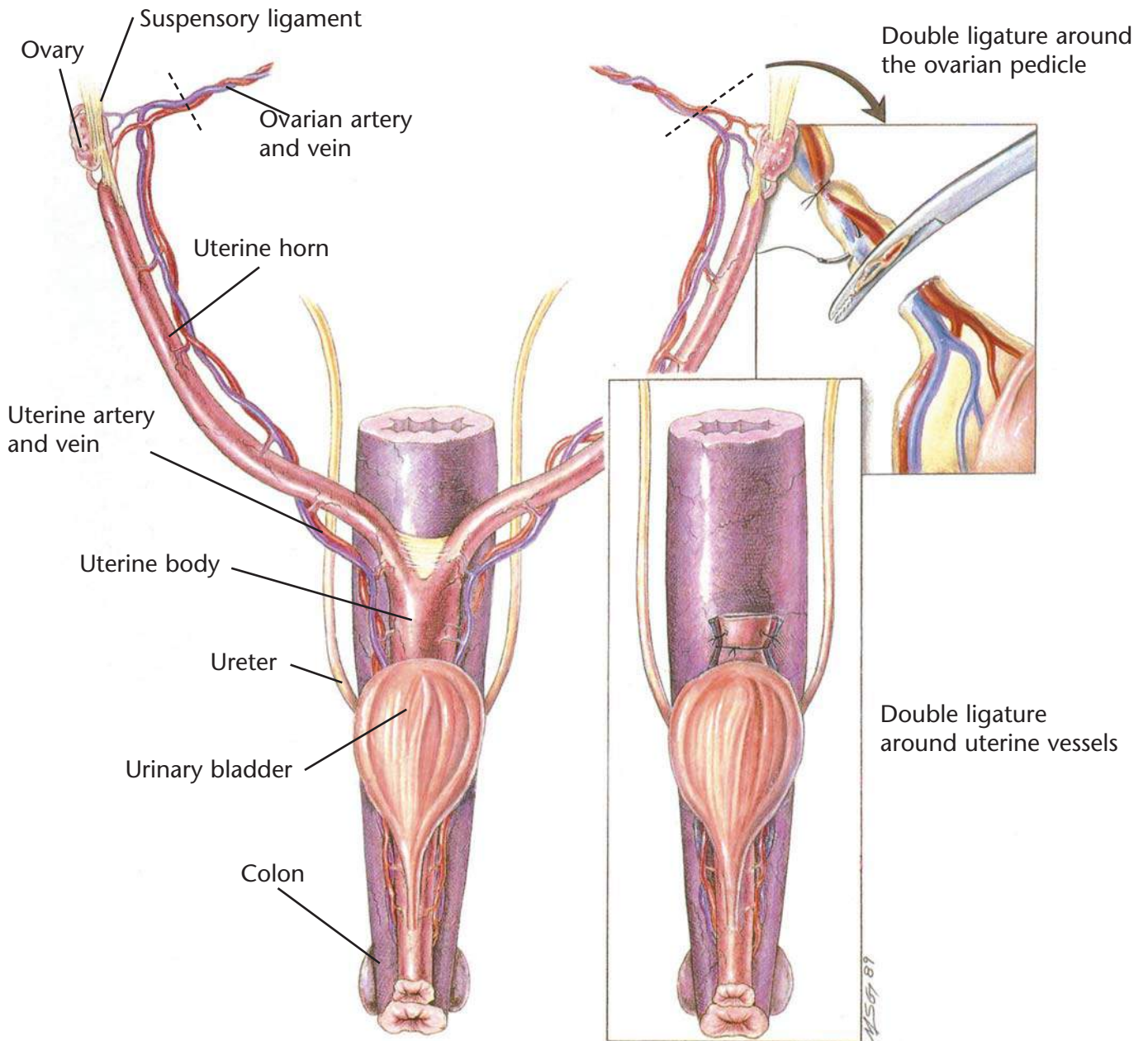
- History
- Physical examination
- Rectal palpation
- Abdominal palpation
- X-rays
- Ultrasound
- Urinalysis
- Urine culture
- Blood work
- Prostate biopsy

Therapeutic Plan

- Emptying of the bladder
- Enemas
- Stool softeners
- Castration
- Medical therapy

Dietary Plan

- If surgery is necessary, a diet adequate for tissue repair
- A low residue food



Ovariohysterectomy

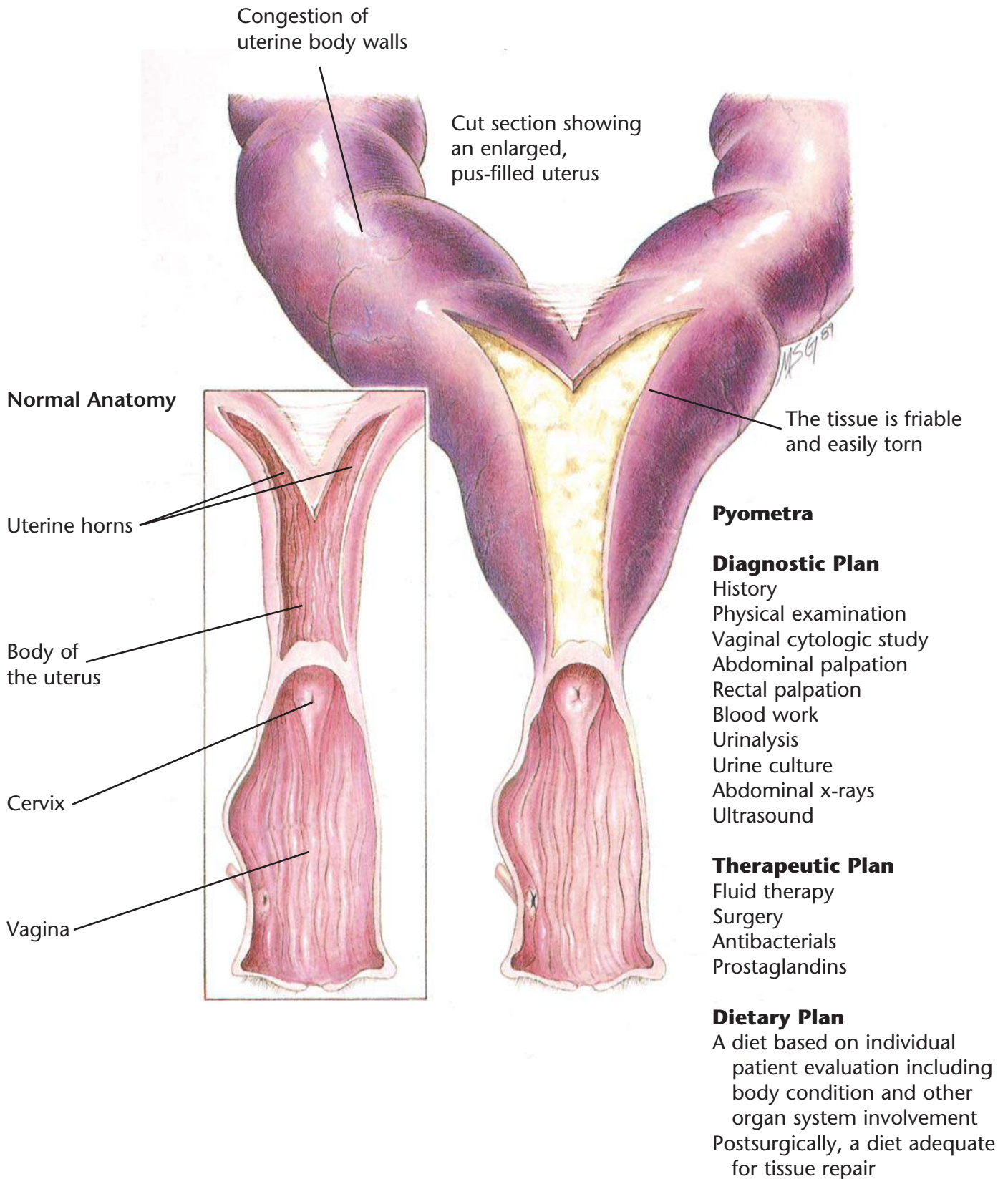
Indications

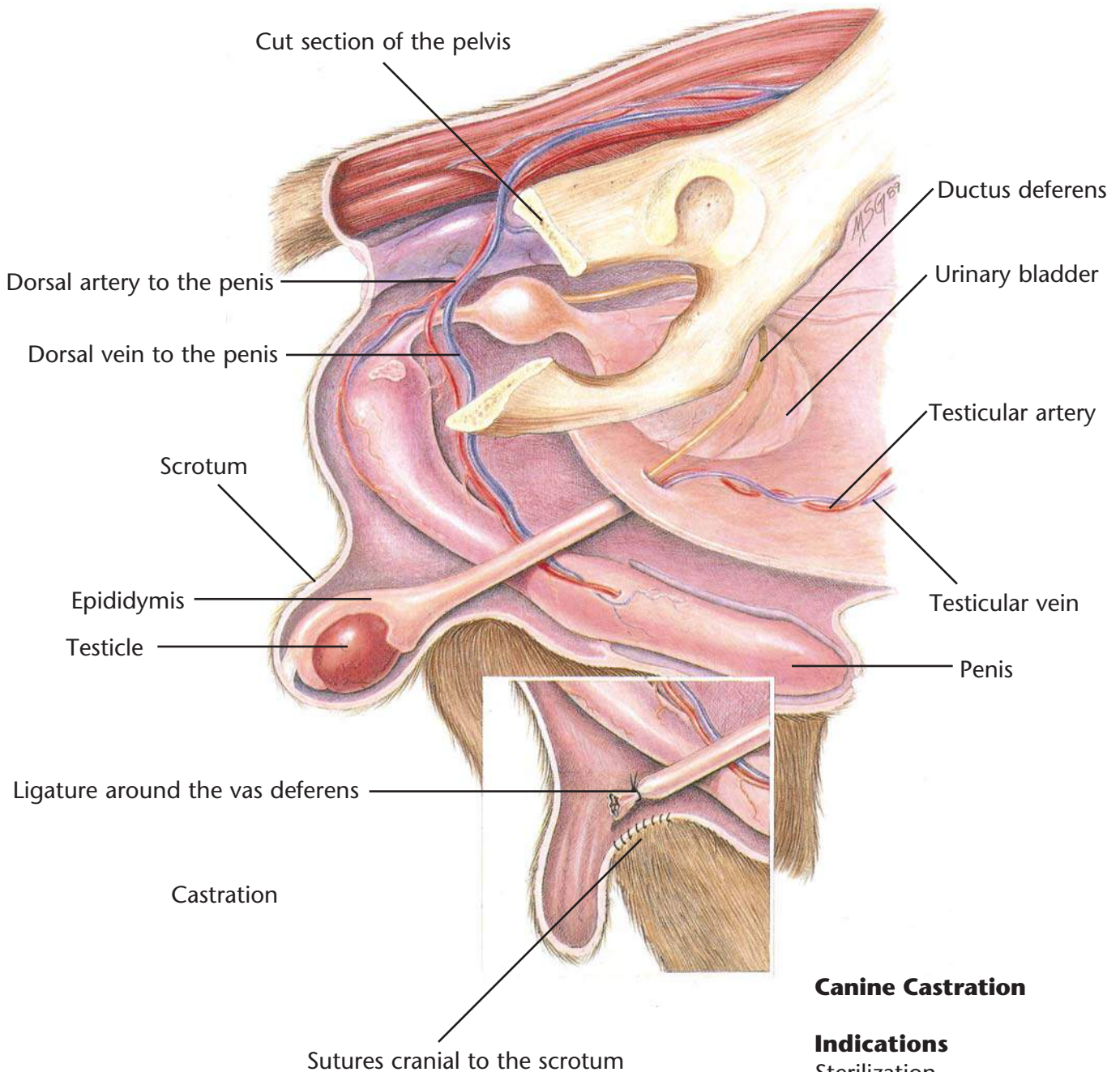
Sterilization
 Ovarian disease
 Uterine disease
 Behavioral problems
 Vaginal hyperplasia
 Diabetes
 Epilepsy
 Mammary tumor prevention

Dietary Plan

Postsurgically, a diet adequate for tissue repair

Pyometra





Canine Castration

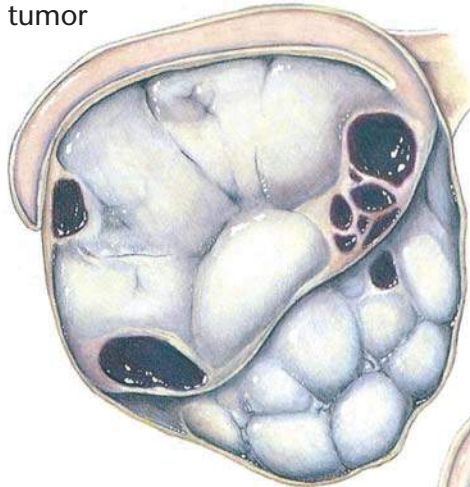
Indications

Sterilization
 Testicular disease
 Prostatic disease
 Behavioral problems
 Retained testicles

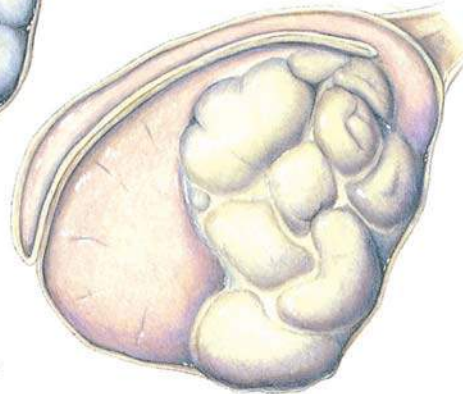
Dietary Plan

Postsurgically, a diet adequate for tissue repair

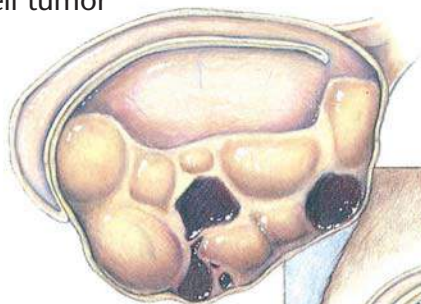
Sertoli-cell tumor



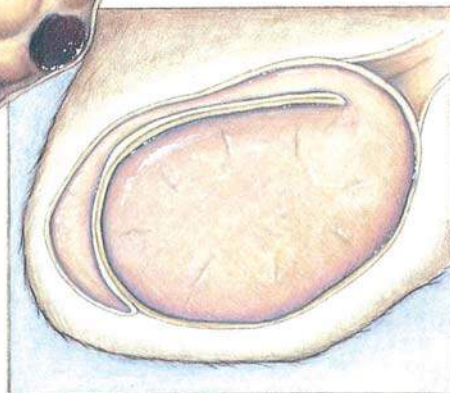
Seminoma



Leydig-cell tumor



Normal testis



Testicular Tumors

Diagnostic Plan


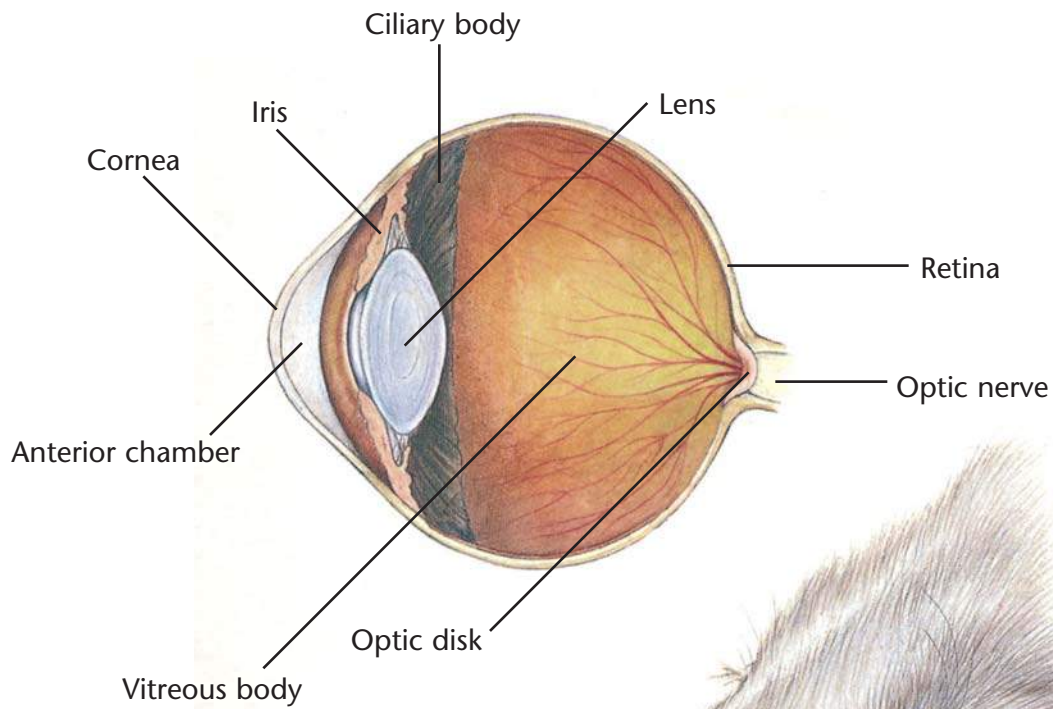
History
Physical examination
Testicular palpation
X-rays of the abdomen
Biopsy

Therapeutic Plan

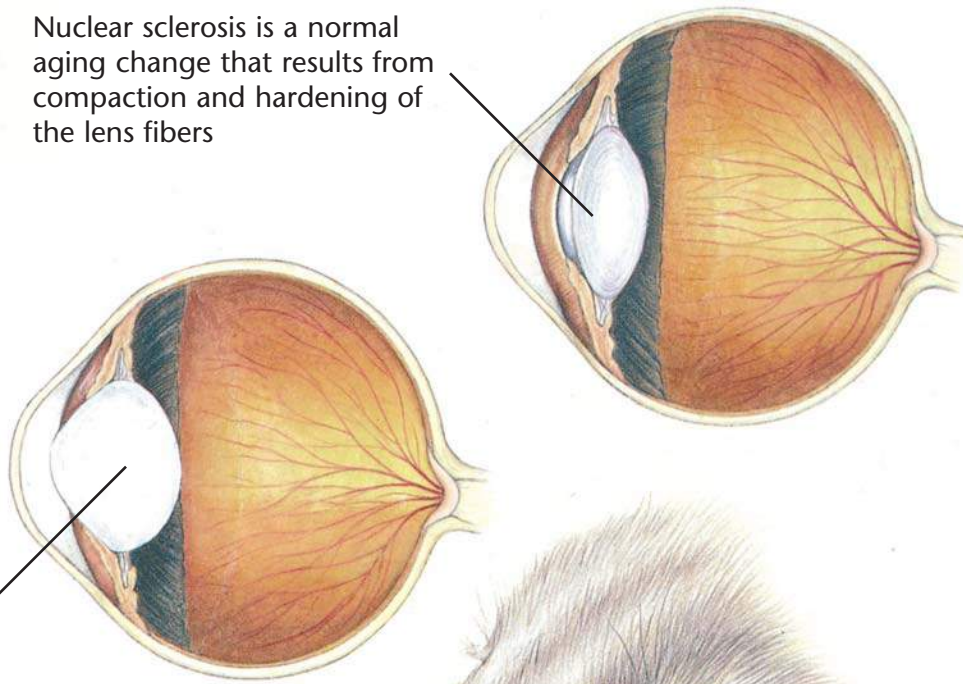
Surgery
Chemotherapy

Dietary Plan

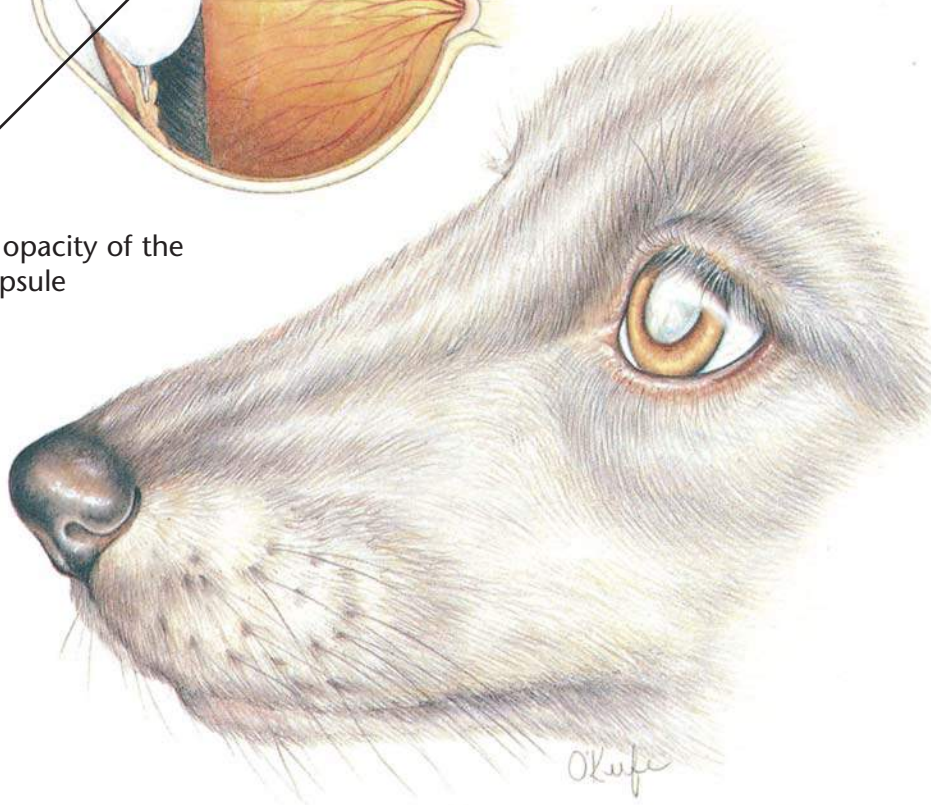
Postsurgically, a diet adequate for tissue repair
Consider body condition; feed a diet appropriate to maintain ideal body weight



Nuclear sclerosis is a normal aging change that results from compaction and hardening of the lens fibers



A cataract is an opacity of the lens fibers or capsule



Nuclear Sclerosis/Cataracts

Diagnostic Plan

History
Physical examination
Ophthalmic examination
Blood tests
Urinalysis

Therapeutic Plan


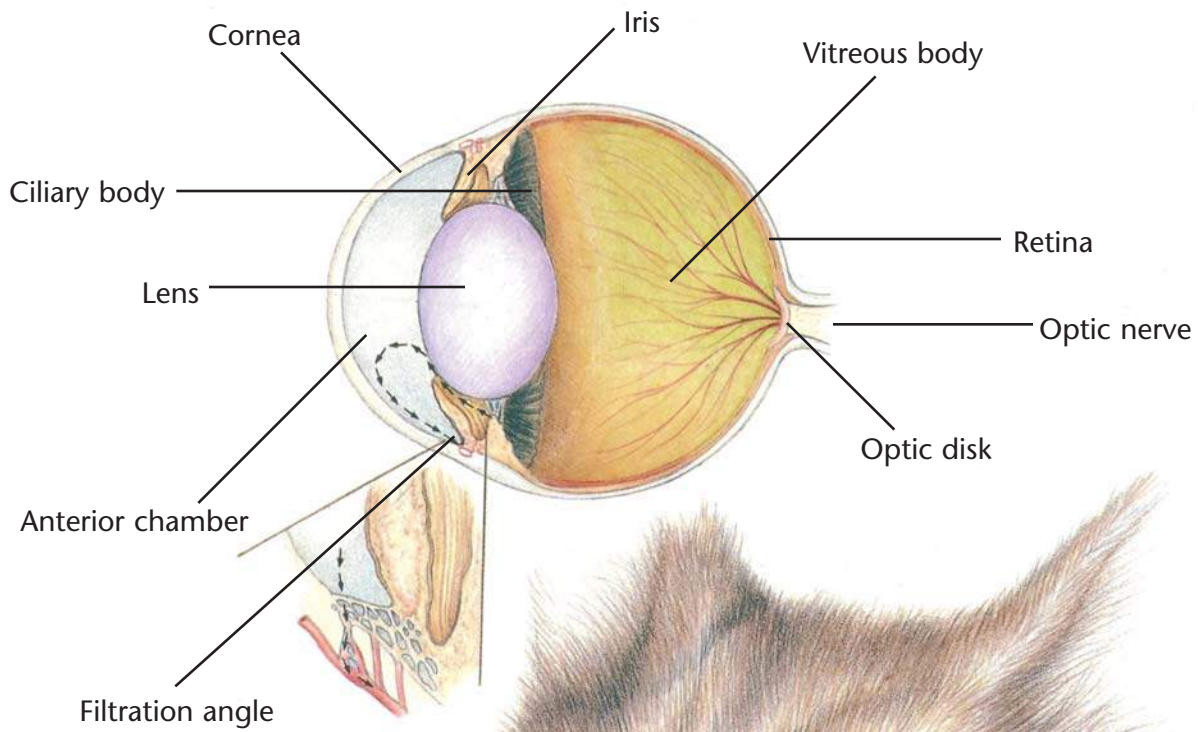
Surgery
Therapy for any concurrent disease
No therapy is necessary for nuclear sclerosis

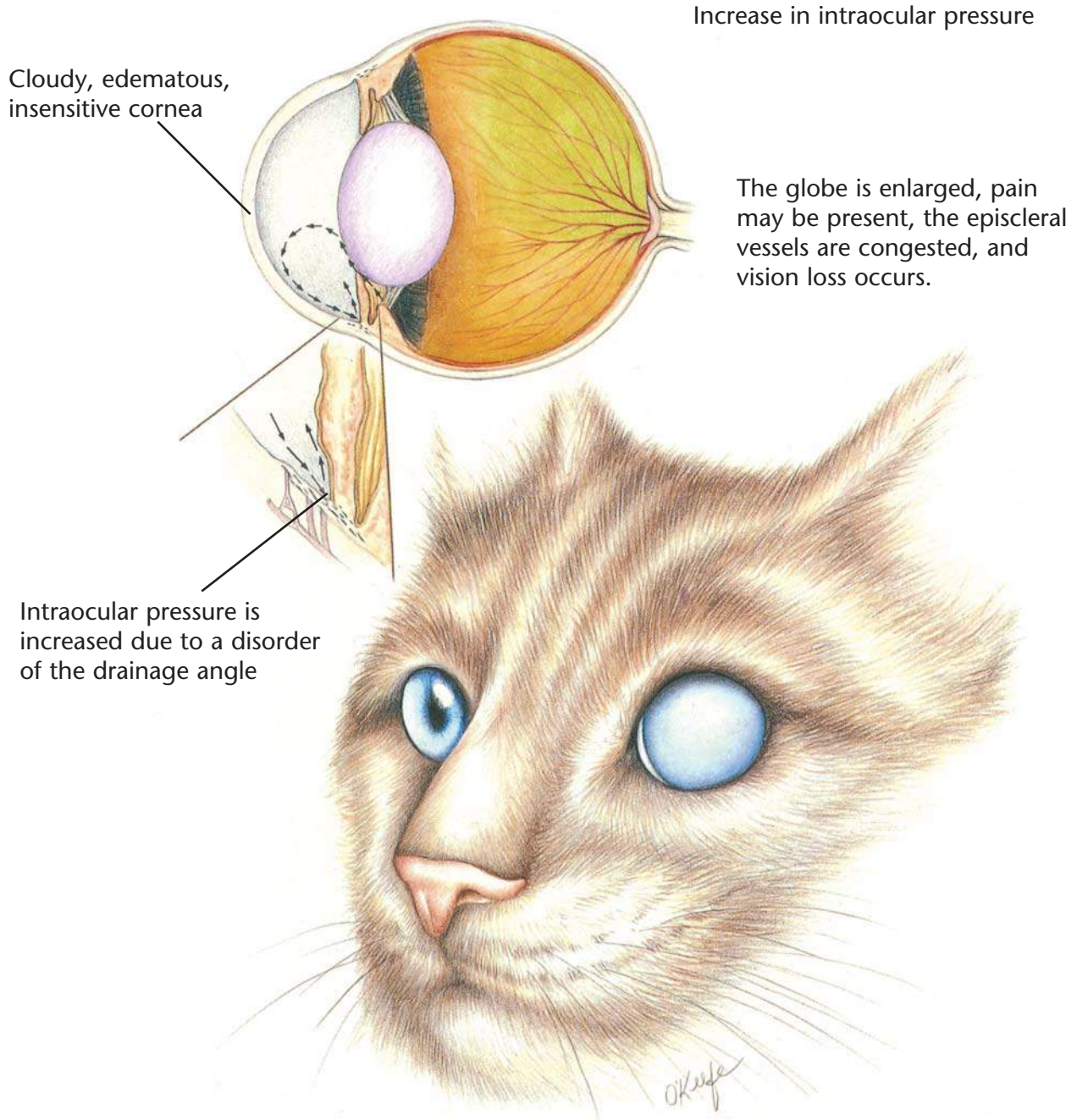
Dietary Plan

A diet based on individual patient evaluation including body condition and other organ system involvement or disease

Hill's Atlas of Veterinary Clinical Anatomy

Normal Feline Eye





Glaucoma

Diagnostic Plan

History
Physical examination
Ocular examination
Measurement of intraocular pressure

Therapeutic Plan

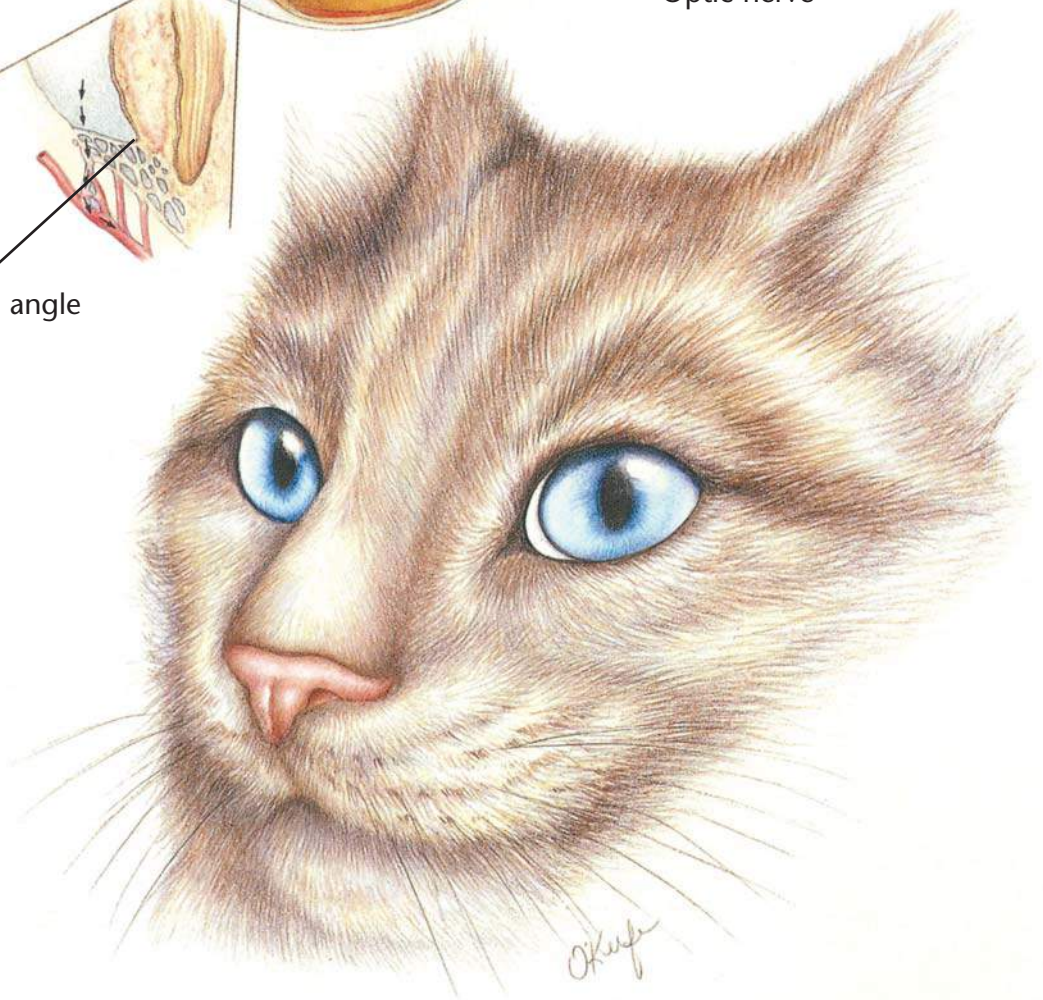
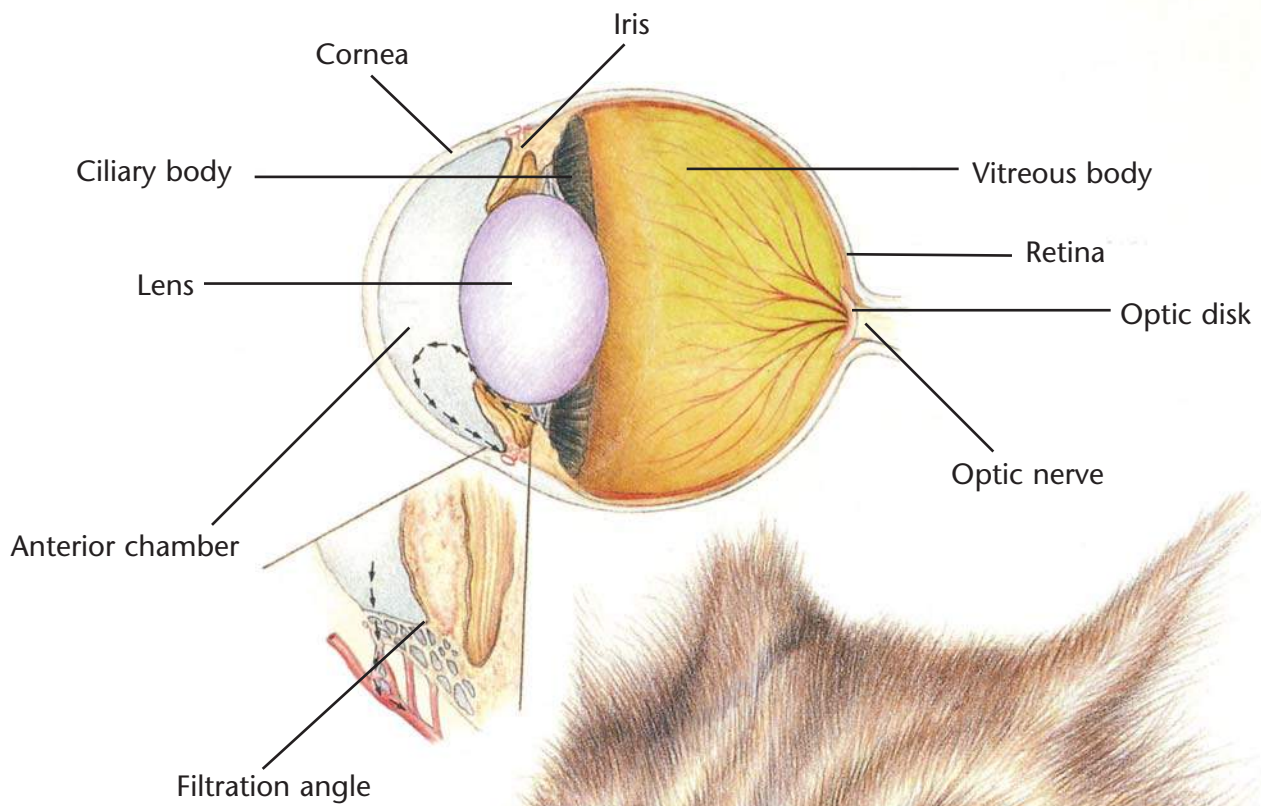
Drugs that relieve intraocular pressure
Surgery

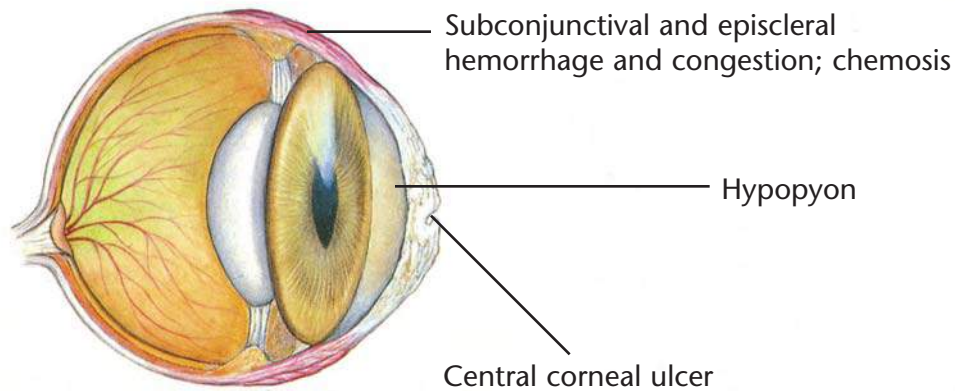
Dietary Plan

A diet based on individual patient evaluation including body condition and other organ system involvement or disease

Hill's Atlas of Veterinary Clinical Anatomy

Normal Feline Eye





Corneal Ulceration

Diagnostic Plan

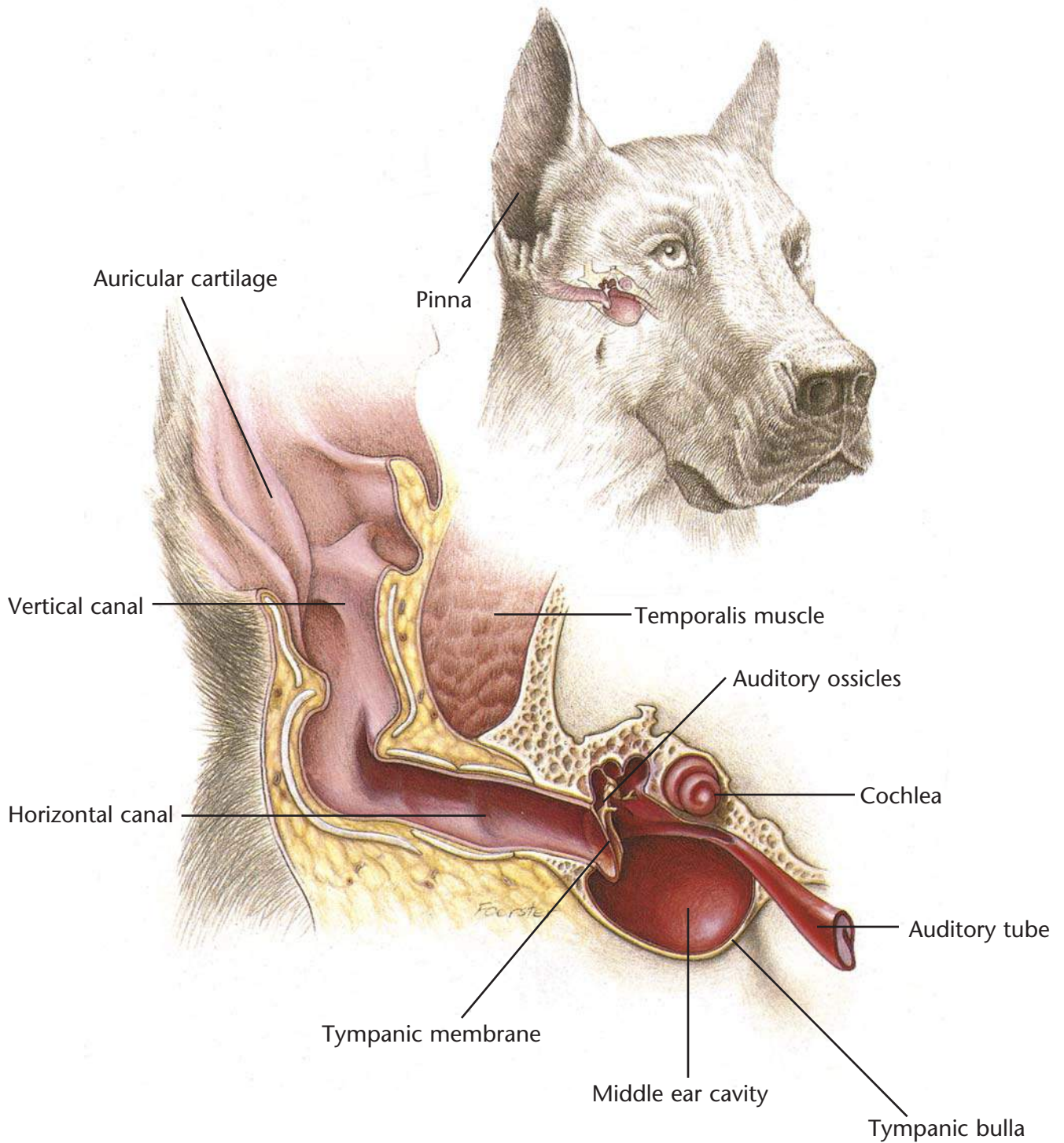
- History
- Physical examination
- Ocular examination
- Fluorescein stain
- Culture
- Cytologic examination

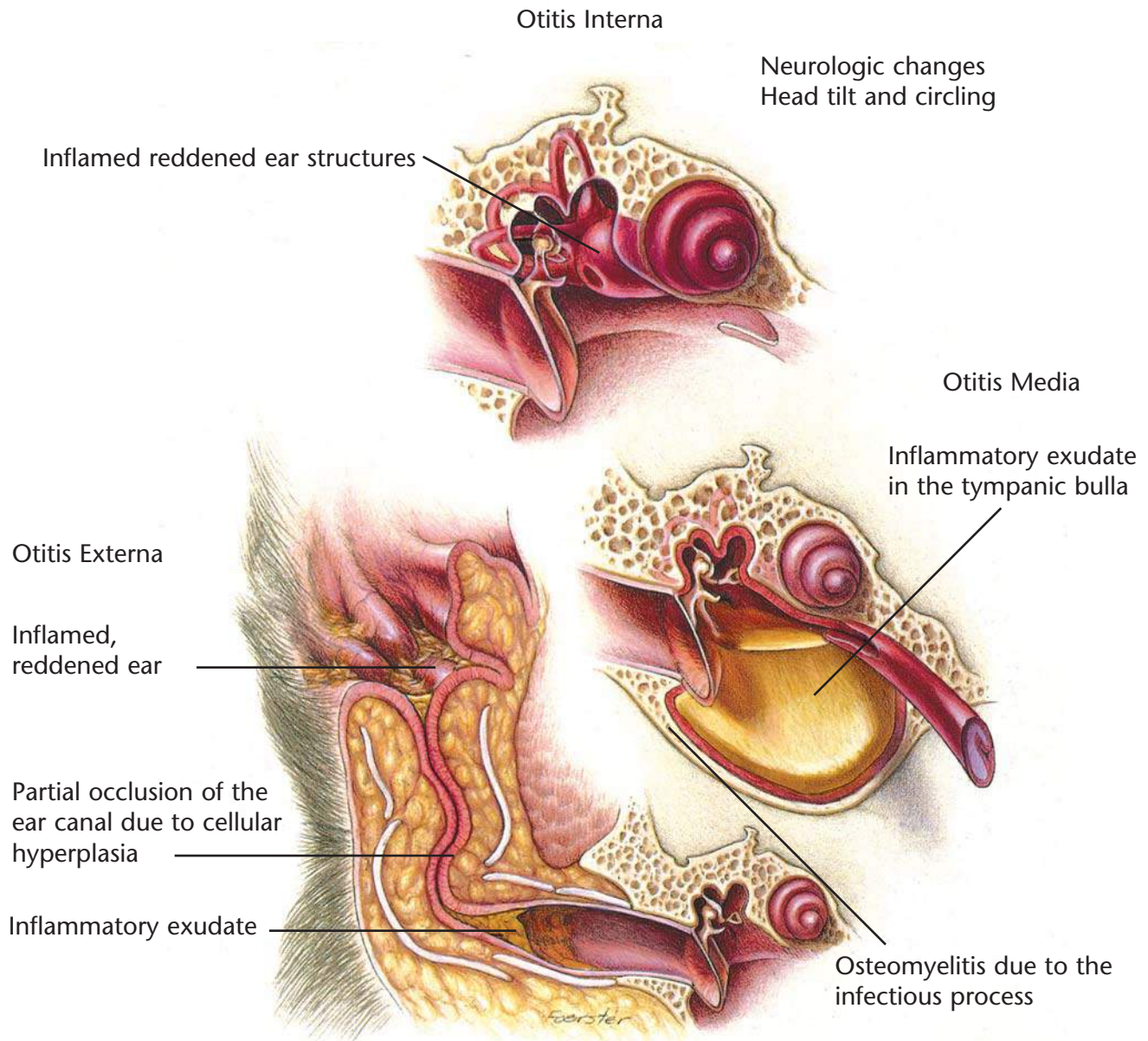
Therapeutic Plan

- Antibacterial ointment and solutions
- Drugs that dilate the pupil
- Surgery
- Drugs to lessen the risk of pigment formation in the cornea

Dietary Plan

A diet based on individual patient evaluation including body condition and other organ system involvement or disease





Otitis Externa, Media, Interna

Diagnostic Plan

- History
- Physical examination
- Ear examination
- Ear cultures
- Thyroid hormone levels
- Intradermal skin testing
- X-rays
- Therapeutic trials with insecticides and hypoallergenic diets


Therapeutic Plan

- Removal of ear canal hair
- Ear cleaning
- Topical application of antibacterials/corticosteroids
- Systemic antibacterials
- Systemic corticosteroids
- Surgery

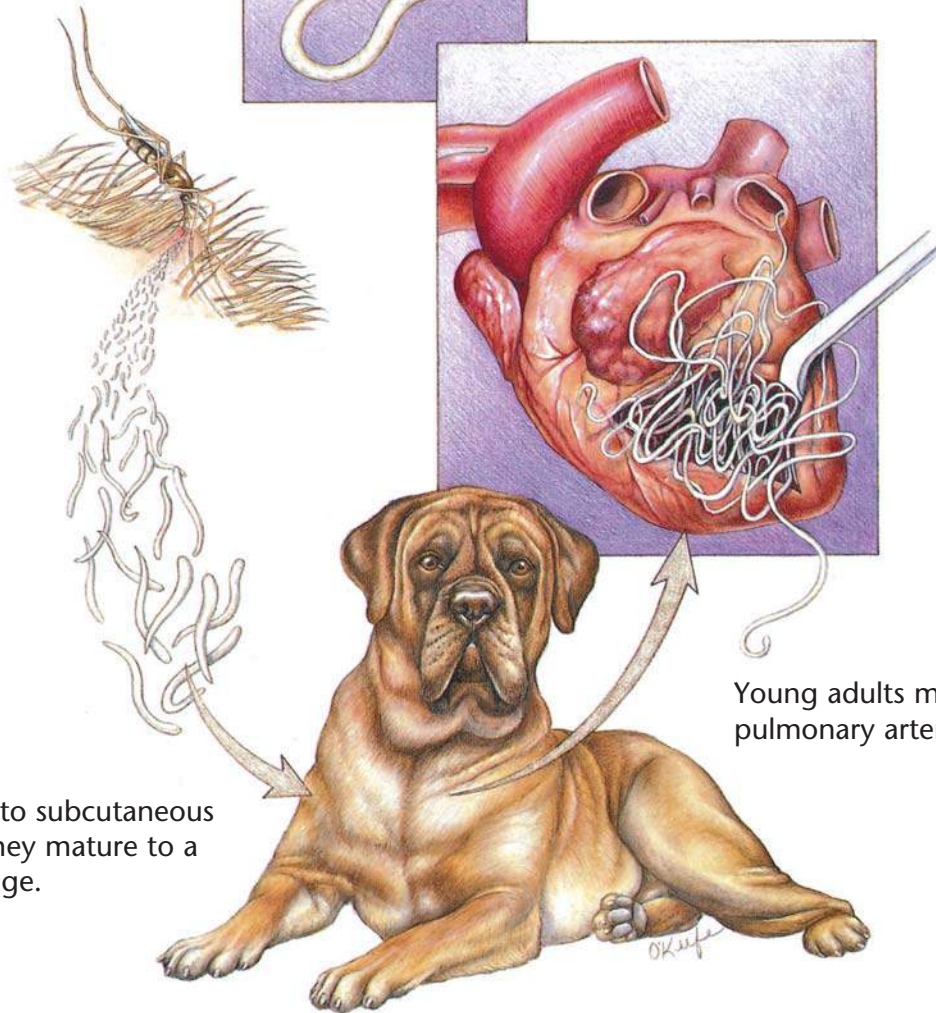
Dietary Plan

- A diet based on individual patient evaluation including body condition and other organ system involvement or disease
- Hypoallergenic diets

Infected mosquitoes deposit heartworm larvae into the animal's hemolymph by puncturing the animal's skin.



Mature females release microfilariae into the bloodstream where they are picked up by mosquitoes.



Larvae migrate to subcutaneous tissues where they mature to a young-adult stage.

Young adults migrate to the pulmonary arteries and heart.

Heartworms

Diagnostic Plan

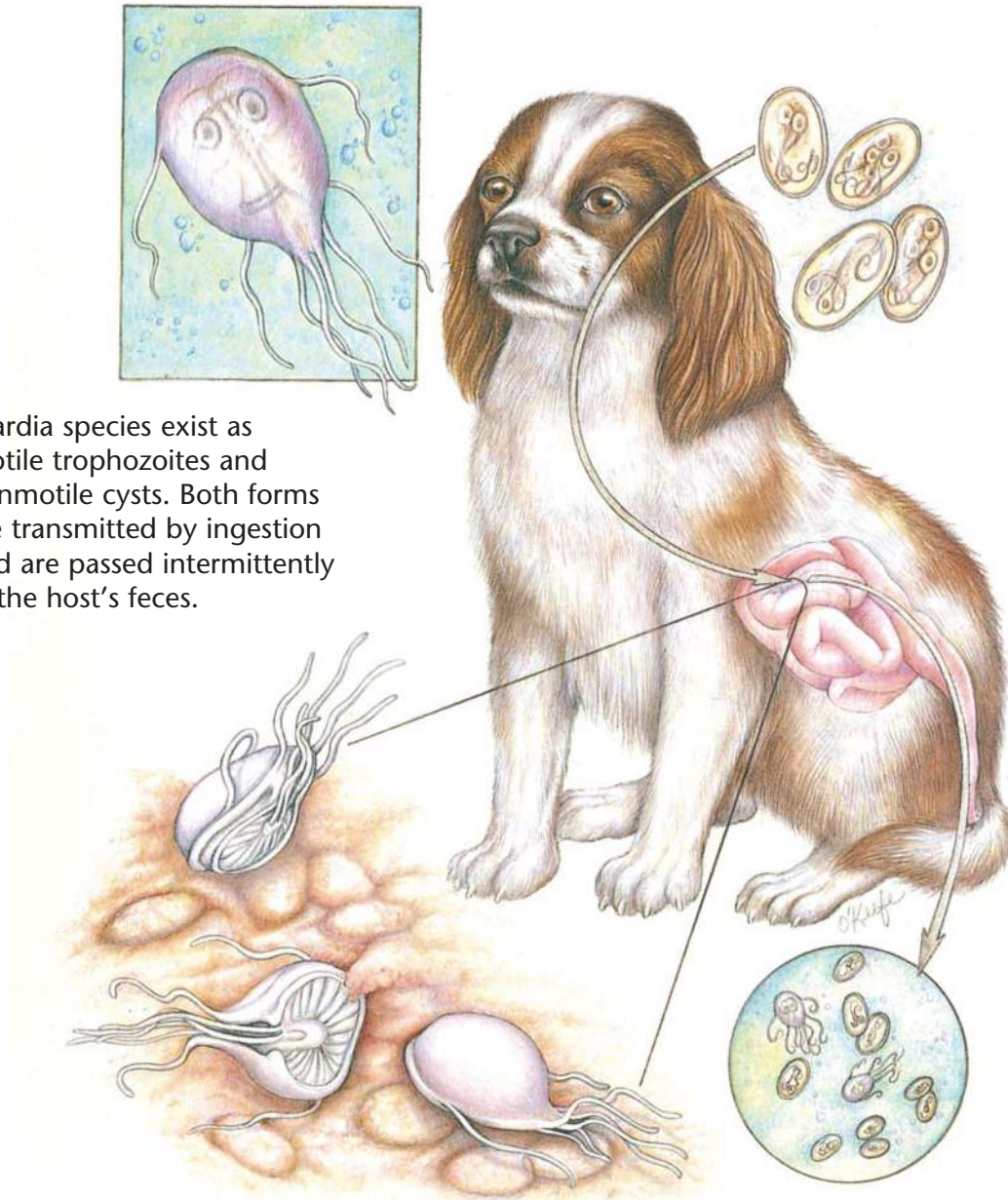
History
Physical examination
Heartworm check
Chest x-rays
Blood work
Urinalysis

Therapeutic Plan

Drugs to kill adult worms
Aspirin
Corticosteroids
Restricted exercise
Drugs to kill larvae in the bloodstream
Prevention
Surgery

Dietary Plan

A diet with controlled levels of protein, phosphorus, and sodium
Consider body condition



Giardia species exist as motile trophozoites and nonmotile cysts. Both forms are transmitted by ingestion and are passed intermittently in the host's feces.

Giardia

Diagnostic Plan

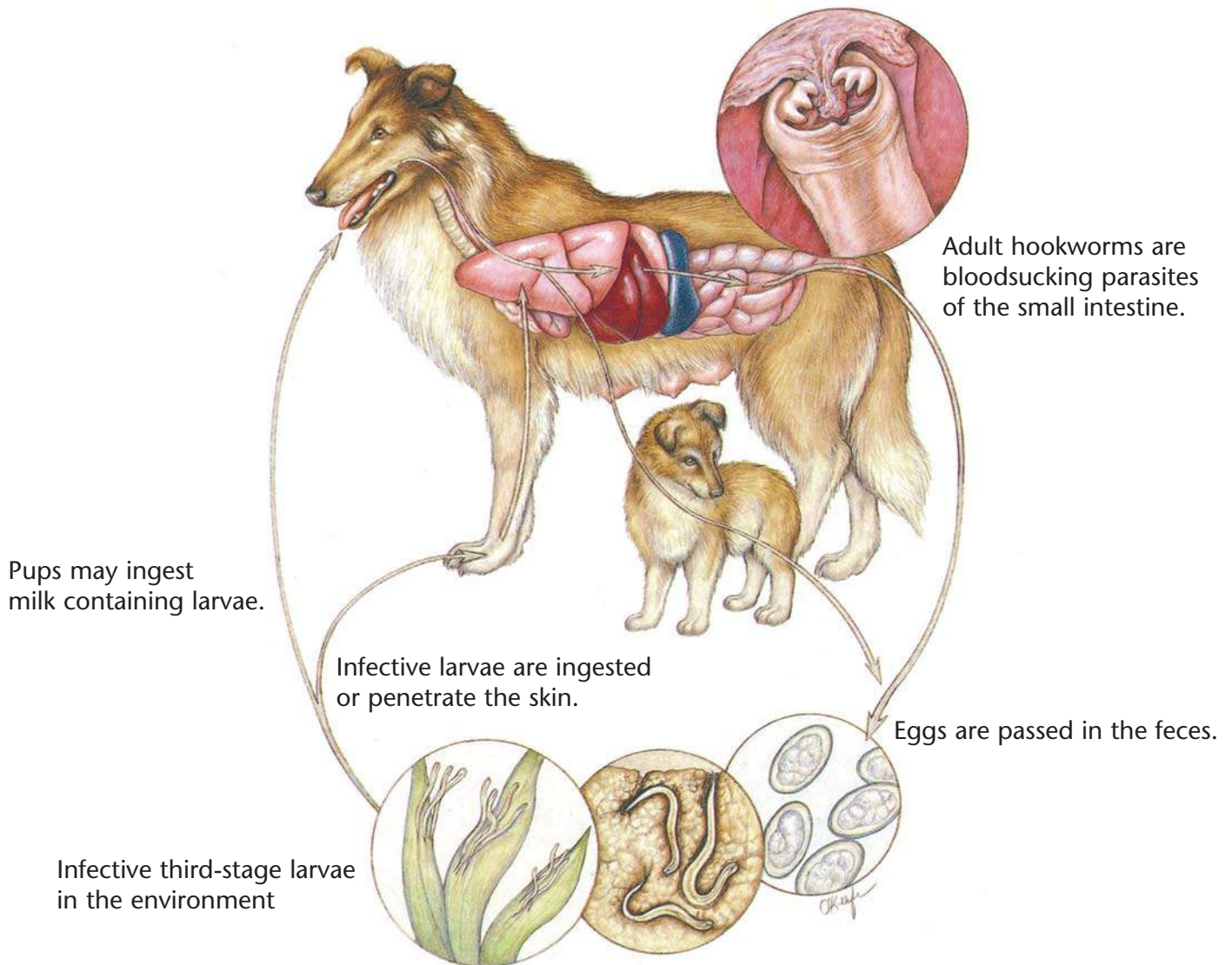
History
 Physical examination
 Stool analysis
 Analysis of intestinal scrapings
 collected during endoscopy
 Blood test
 (Giardia antigen test)

Therapeutic Plan

Drugs to kill the parasite

Dietary Plan

A diet based on individual patient evaluation including body condition and other organ system involvement or disease



Hookworms

Diagnostic Plan

History
 Physical examination
 Stool analysis
 Blood work

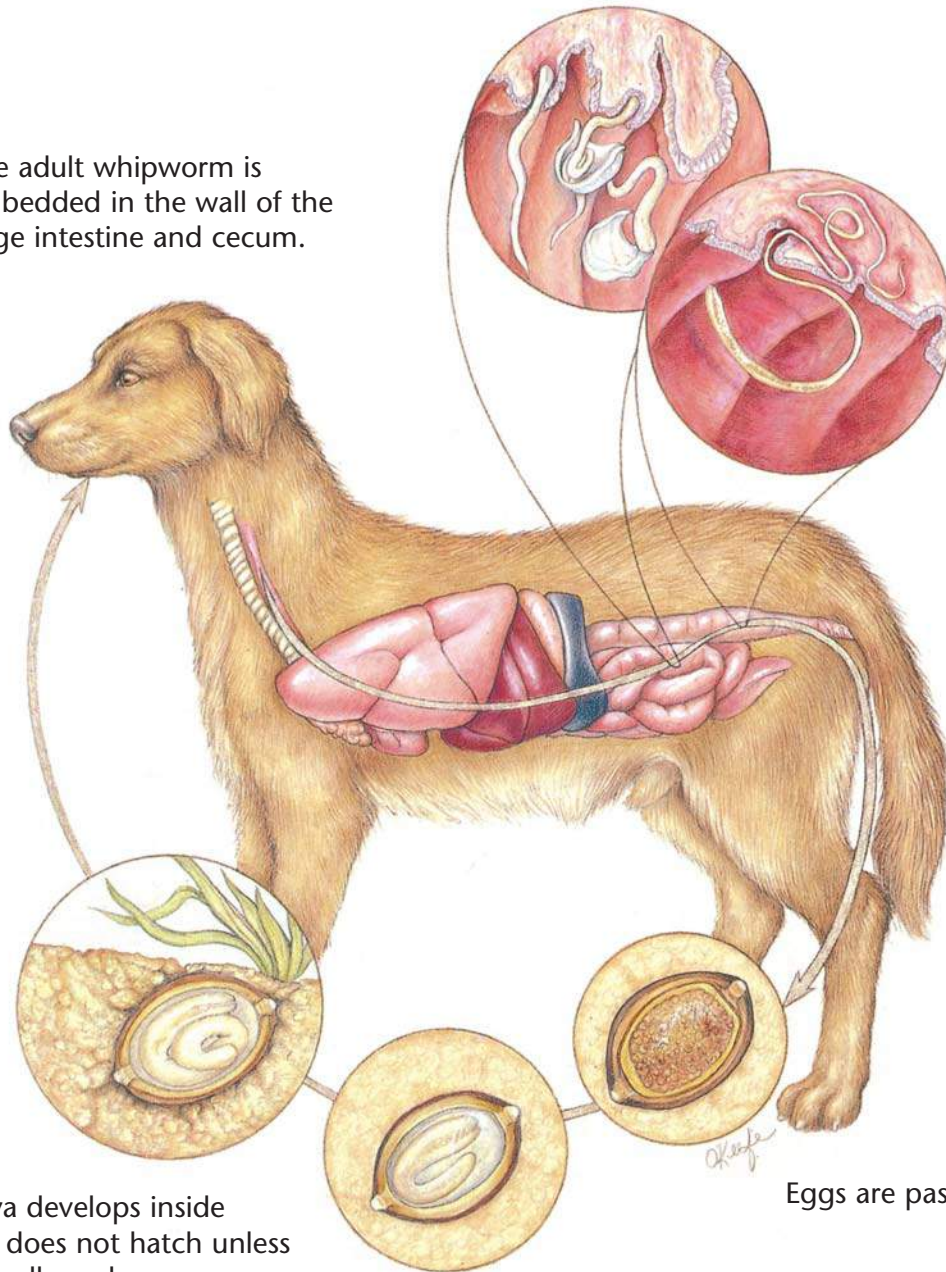
Therapeutic Plan

Dewormers
 Blood transfusions
 Supportive therapy

Dietary Plan

A diet based on individual patient evaluation including body condition and other organ system involvement or disease

The adult whipworm is embedded in the wall of the large intestine and cecum.



Infected larva develops inside the egg but does not hatch unless the egg is swallowed.

Eggs are passed in the feces.

Whipworms

Diagnostic Plan

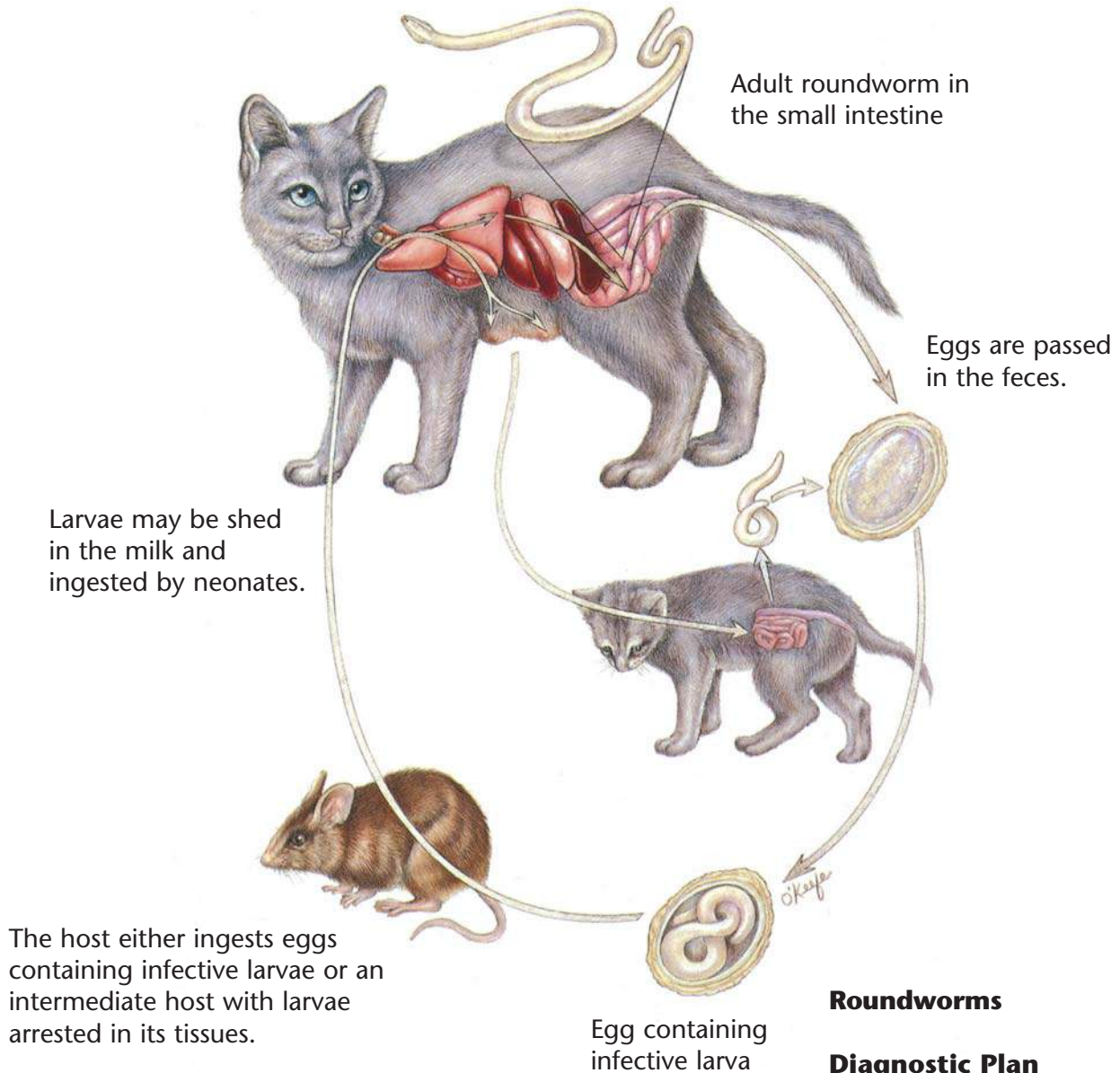
History
Physical examination
Stool analysis
Colonoscopy
Therapeutic deworming

Therapeutic Plan

Dewormers
Supportive therapy

Dietary Plan

A diet based on individual patient evaluation including body condition and other organ system involvement or disease



Roundworms

Diagnostic Plan

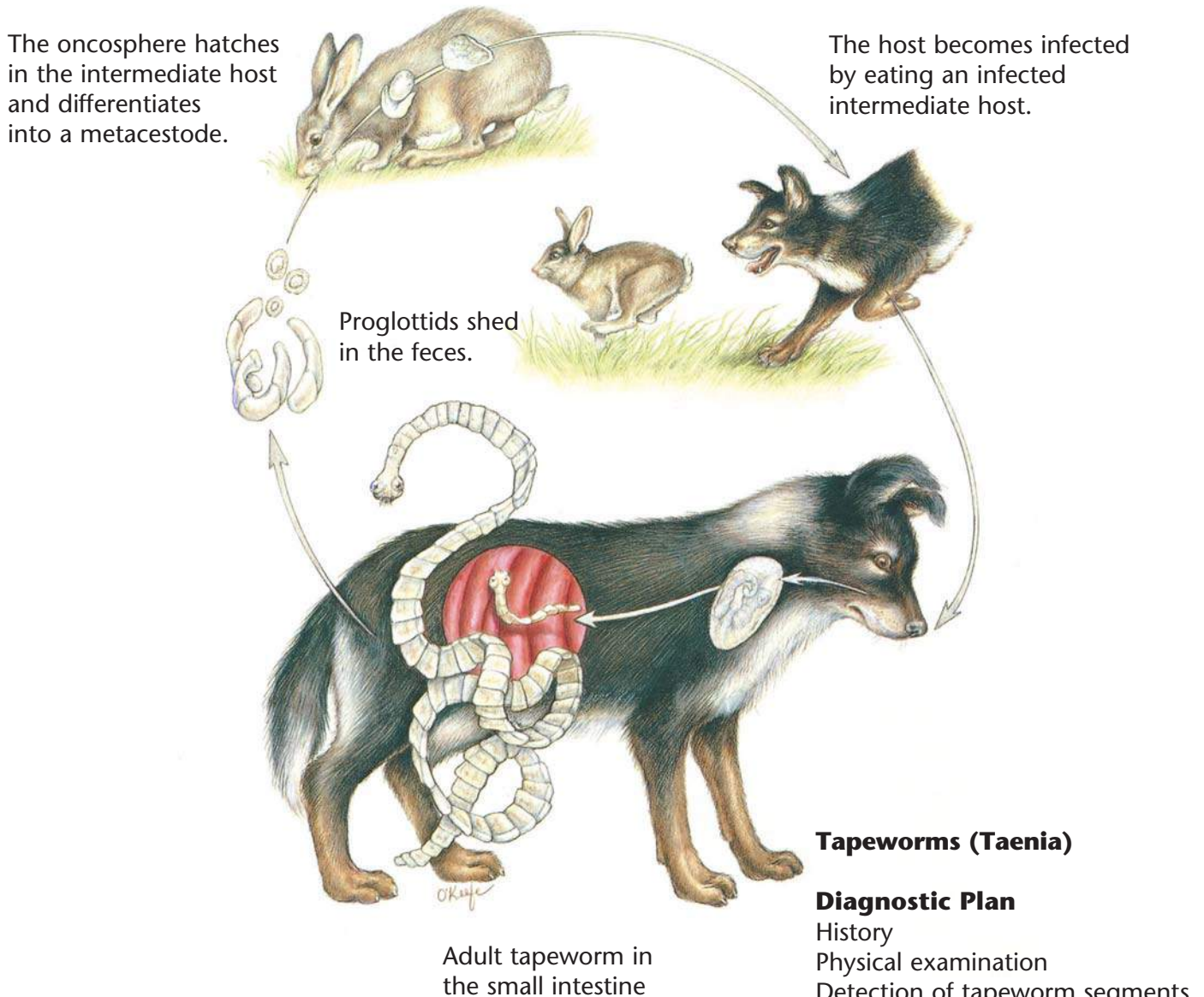
History
Physical examination
Stool analysis

Therapeutic Plan

Dewormers
Supportive therapy

Dietary Plan

A diet based on individual patient evaluation including body condition and other organ system involvement or disease



Tapeworms (*Taenia*)

Diagnostic Plan

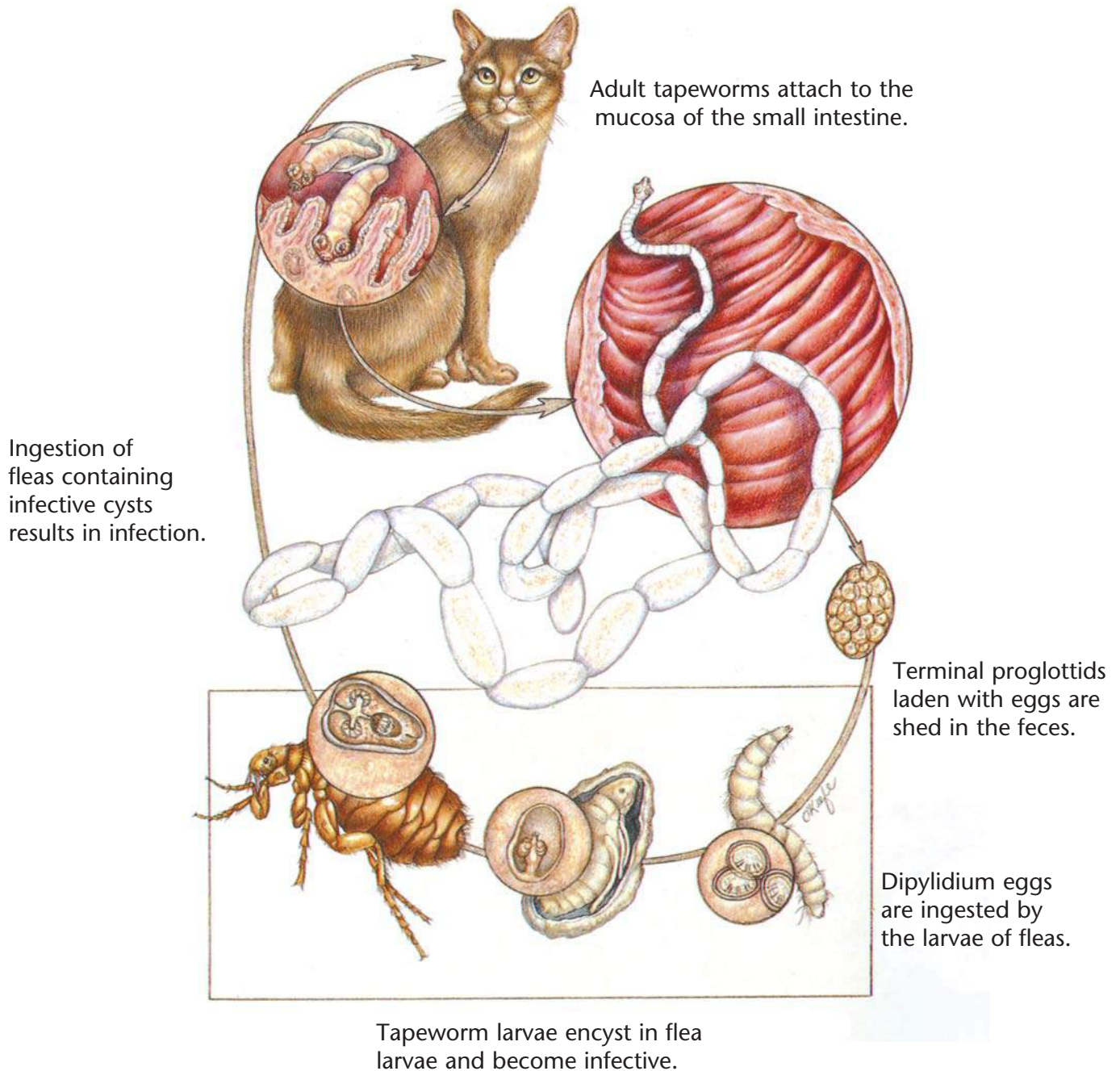
- History
- Physical examination
- Detection of tapeworm segments in the stool

Therapeutic Plan

- Dewormers
- Control of patient's hunting and eating habits

Dietary Plan

A diet based on individual patient evaluation including body condition and other organ system involvement or disease



Tapeworms (*Dipylidium caninum*)

Diagnostic Plan

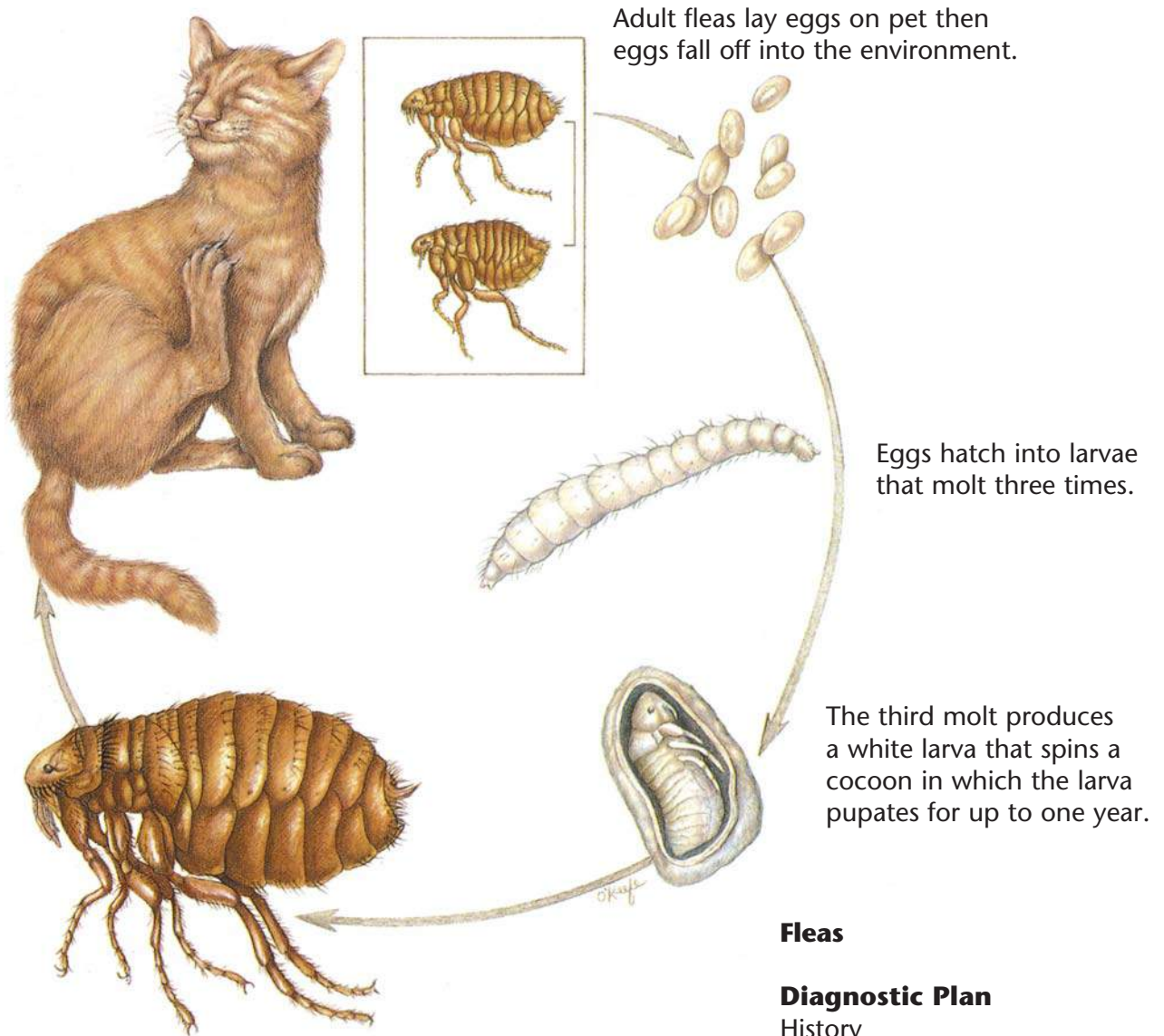
History
Physical examination
Detection of tapeworm segments in the stool
Detection of fleas or flea dirt

Therapeutic Plan

Dewormers
Flea control

Dietary Plan

A diet based on individual patient evaluation including body condition and other organ system involvement or disease



Adult fleas lay eggs on pet then eggs fall off into the environment.

Eggs hatch into larvae that molt three times.

The third molt produces a white larva that spins a cocoon in which the larva pupates for up to one year.

The adult flea emerges from the cocoon and seeks a host on which to feed.

Fleas

Diagnostic Plan

- History
- Physical examination
- Stool inspection for tapeworm segments

Therapeutic Plan

- Flea control

Dietary Plan

A diet based on individual patient evaluation including body condition and other organ system involvement or disease

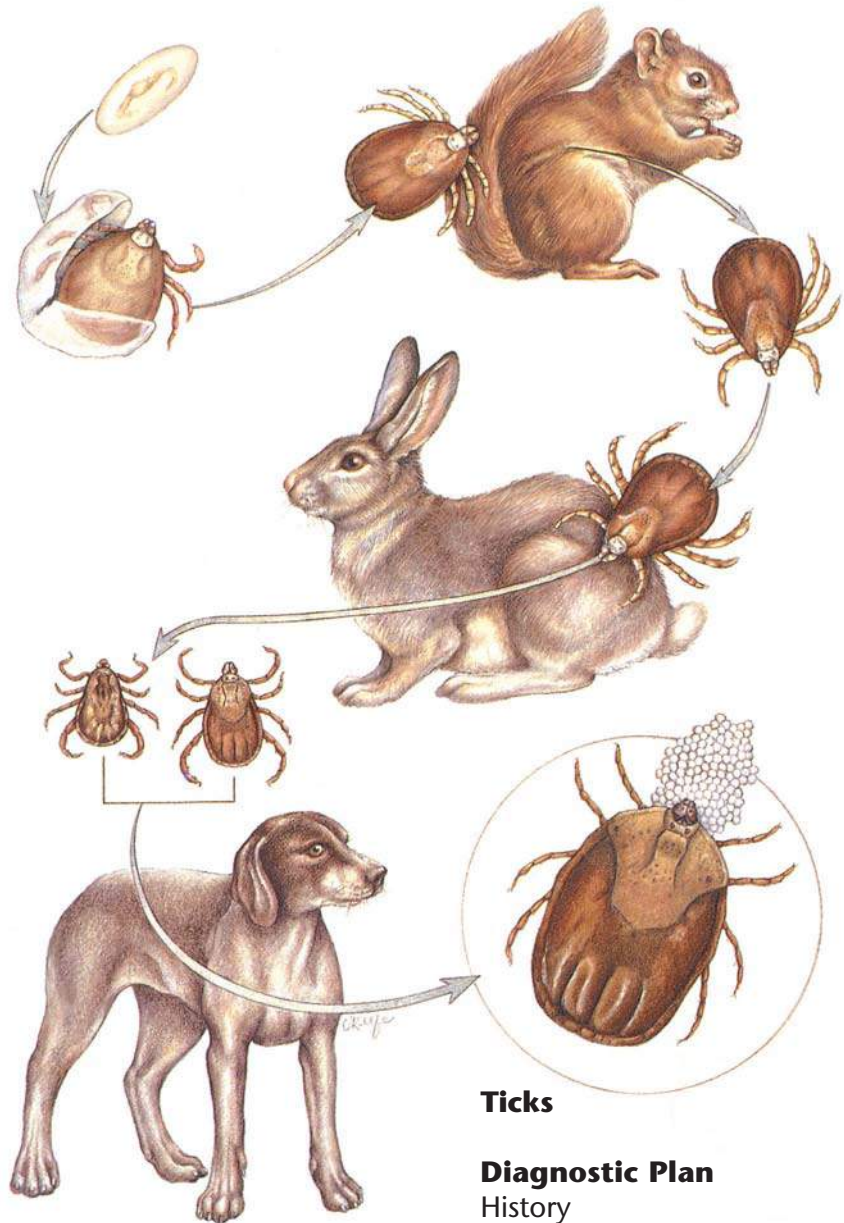
Adult ticks lay thousands of eggs, which undergo two molts: larva to nymph and nymph to adult.

Larvae, nymphs, and adults feed on blood and lymph.

Dermacentor variabilis larvae and nymphs feed on small mammals and drop off between molts.

Adults feed on pets.

Rhipicephalus sanguineus larvae, nymphs, and adults all feed on pets.



Ticks

Diagnostic Plan

History
Physical examination

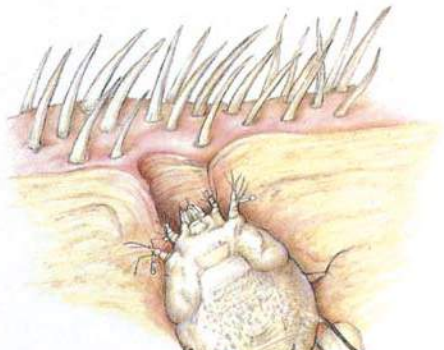
Therapeutic Plan

Tick removal
Insecticide baths or dips
Topical insecticide dips or baths

Dietary Plan

A diet based on individual patient evaluation including body condition and other organ system involvement or disease

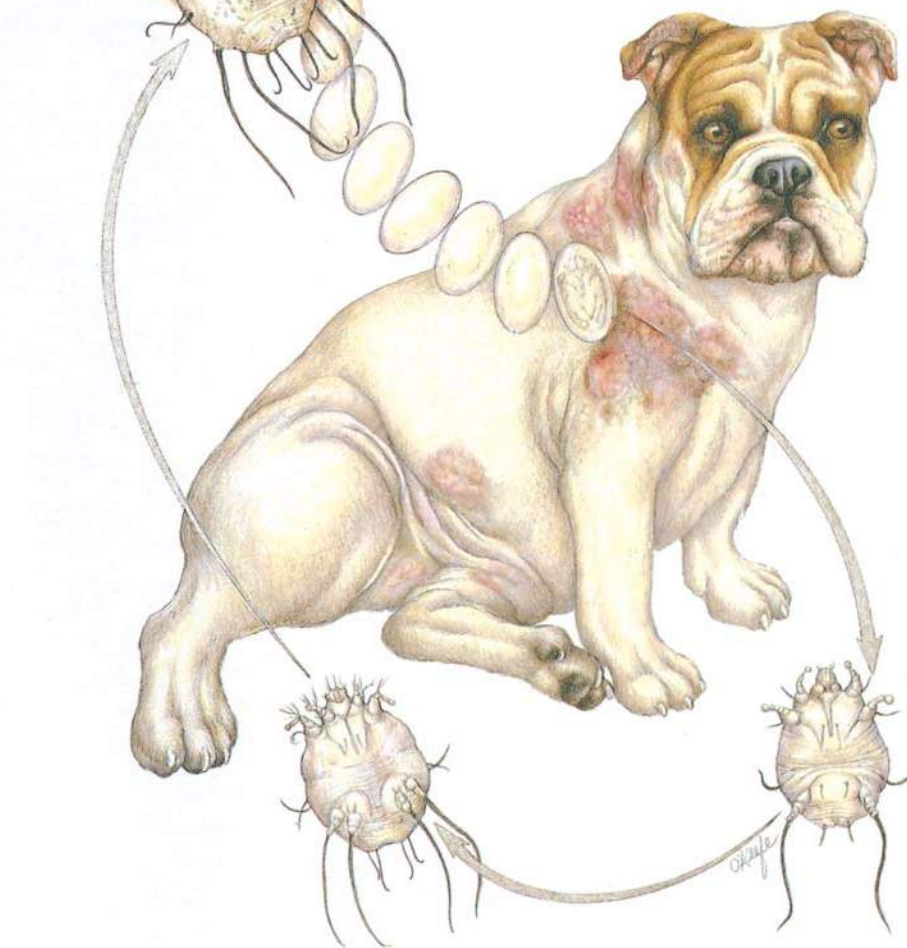Sarcoptes



Female mites burrow into the skin and lay eggs in the tunnels that they form.

Larvae and nymphs develop in these tunnels.

The patient response is often severe self-inflicted trauma.



Sarcoptes

Diagnostic Plan

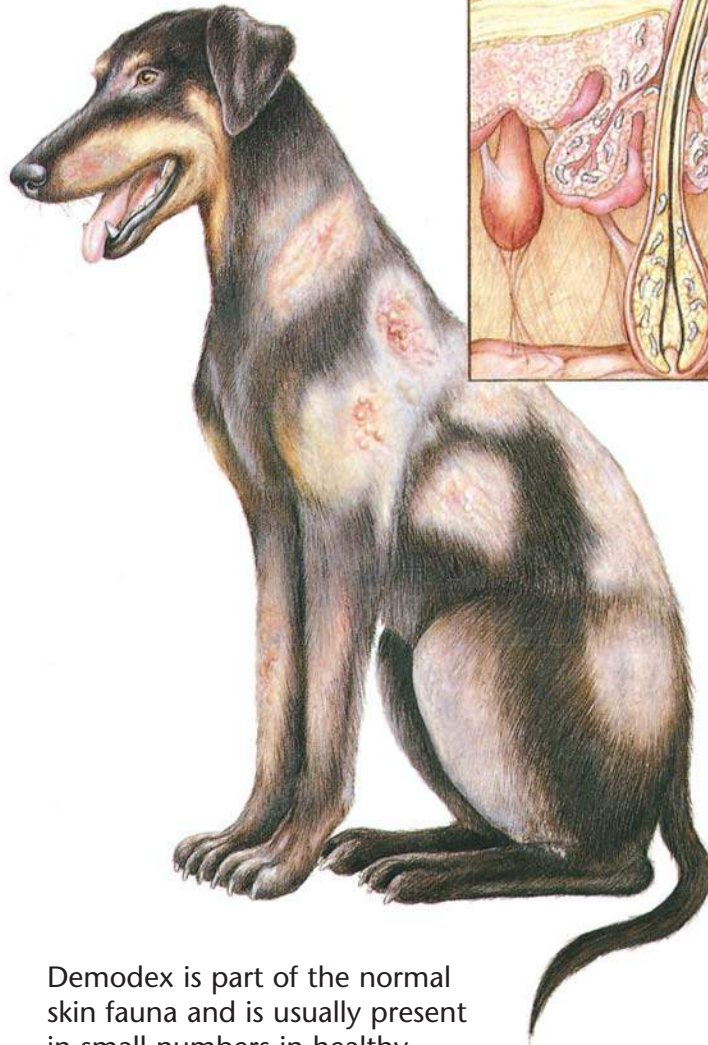
- History
- Physical examination
- Skin scrapings
- Skin biopsy
- Therapeutic trial

Therapeutic Plan

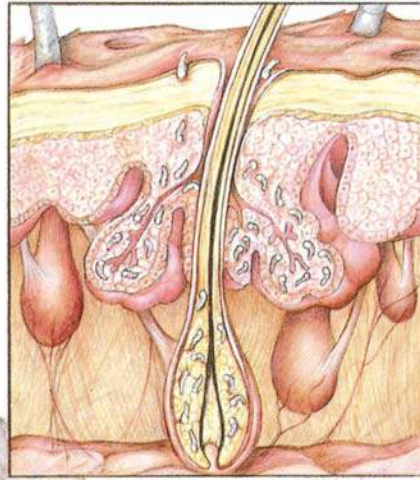
- Coat clipping
- Parasiticial dips
- Antibacterials

Dietary Plan

A diet based on individual patient evaluation including body condition and other organ system involvement or disease



Demodex is part of the normal skin fauna and is usually present in small numbers in healthy animals.



The entire life cycle is spent on the host in the hair follicles or sebaceous glands.



Adult Demodex mite

Demodex

Diagnostic Plan

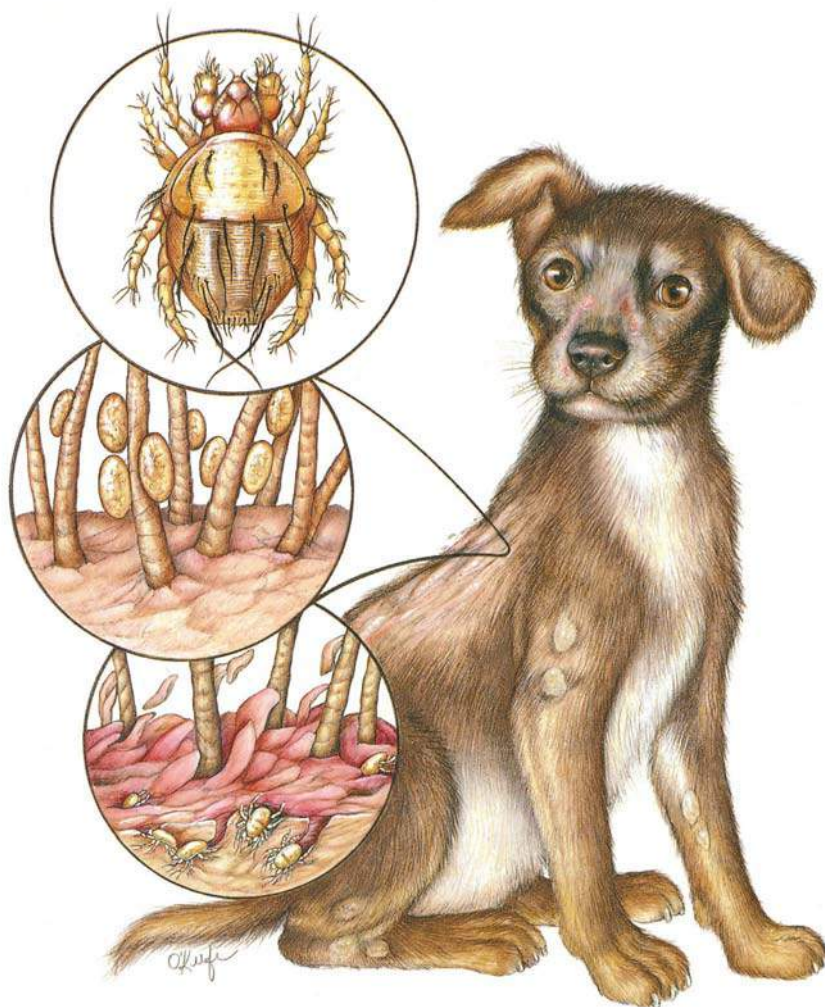
History
Physical examination
Skin scrapings
Skin biopsy
Skin culture

Therapeutic Plan

Topical keratolytic agents
Antibacterials
Topical drugs to kill the mite

Dietary Plan

A diet adequate for tissue repair
A diet based on individual patient evaluation including body condition and other organ system involvement or disease
Medication to kill the mite



These mites live in keratin on the skin's surface and feed on tissue fluids.

The entire life cycle is thought to occur on the host.

Cheyletiella

Diagnostic Plan

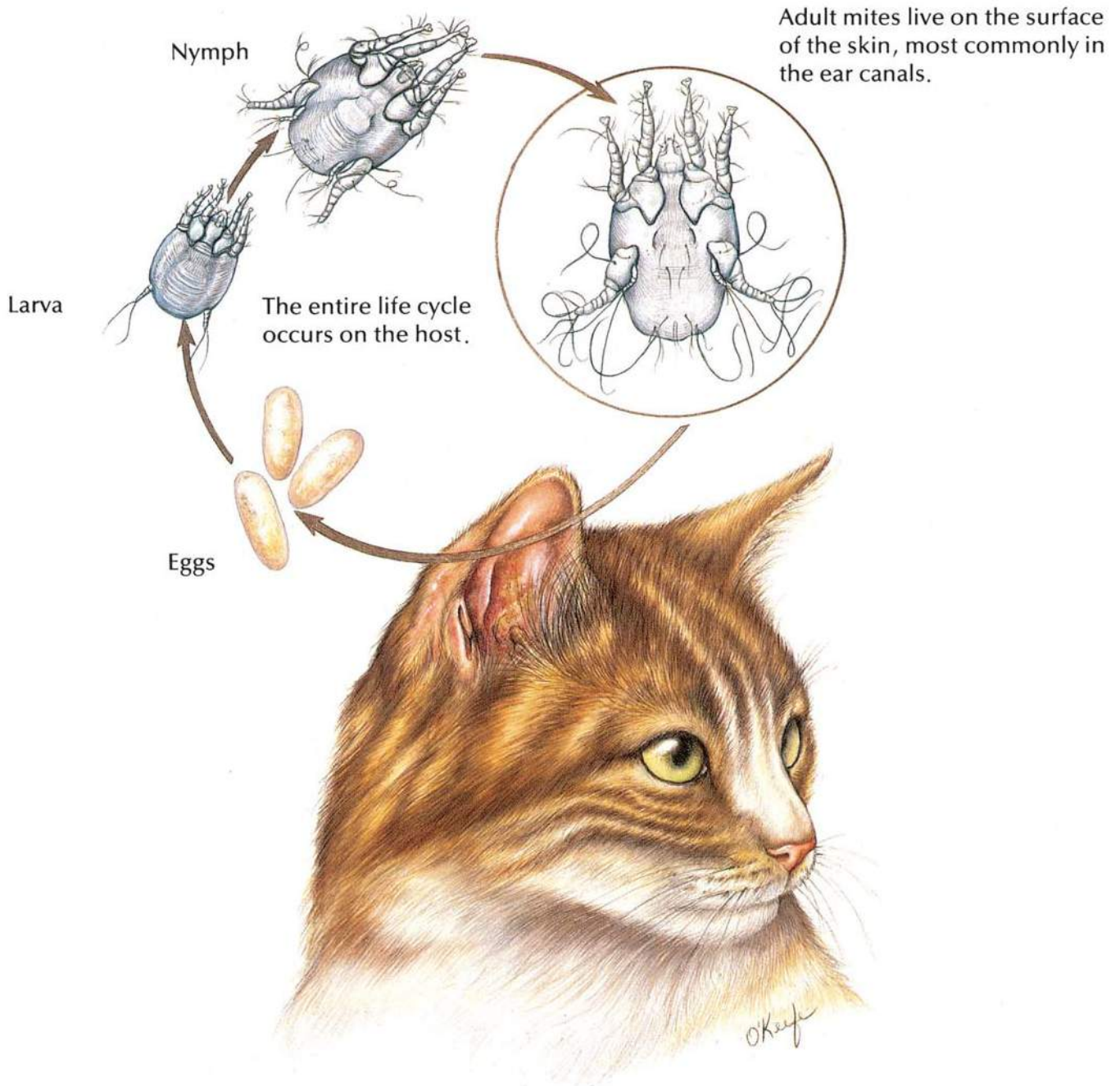
History
Physical examination
Skin scrapings
Skin biopsy
Acetate tape impressions
Direct visualization of the parasite

Therapeutic Plan

Parasiticial dips

Dietary Plan

A diet based on individual patient evaluation including body condition and other organ system involvement or disease



Ear Mites

Diagnostic Plan

History
Physical examination
Ear examination
Microscopic examination
of ear canal exudate

Therapeutic Plan

Ear canal cleaning
Drugs to kill the mites
Surgical repair of
aural hematomas
Antibacterials, if needed

Dietary Plan

A diet adequate for tissue repair
A diet based on individual patient
evaluation including body
condition and other organ
system involvement or disease

Bibliography

1. Evans, H.E.; Christensen, G.C.: *Miller's Anatomy of the Dog*, 2nd Ed. W.B. Saunders, Philadelphia, Pa., 1979.
2. Fox, P.R. (ed.): *Canine and Feline Cardiology*. Churchill Livingstone, New York, N.Y., 1988.
3. Georgi, J.R.: *Parasitology for Veterinarians*, 4th Ed. W.B. Saunders, Philadelphia, Pa., 1985.
4. Harvey, C.E.: *Veterinary Dentistry*. W.B. Saunders, Philadelphia, Pa., 1985.
5. Holzworth, J. (ed.): *Diseases of the Cat: Medicine & Surgery*. W.B. Saunders, Philadelphia, Pa., 1987.
6. Jones, B.D. (ed.): *Canine and Feline Gastroenterology*. W.B. Saunders, Philadelphia, Pa., 1986.
7. *Key to Dietary Management With Prescription Diet® Products*. Hill's Pet Products, Topeka, Kan.
8. Kirk, R.W.; Bistner, S.I.: *Veterinary Procedures & Emergency Treatment*, 4th Ed. W.B. Saunders, Philadelphia, Pa., 1985.
9. Kirk, R.W. (ed.): *Current Veterinary Therapy IX: Small Animal Practice*. W.B. Saunders, Philadelphia, Pa., 1986.
10. Lewis, L.D. et al: *Small Animal Clinical Nutrition III*. Mark Morris Associates, Topeka, Kan., 1987.
11. Magrane, W.G.: *Canine Ophthalmology*, 3rd Ed. Lea & Febiger, Philadelphia, Pa., 1977.
12. *Managing Canine and Feline Urolithiasis*. Veterinary Medicine Publishing, Lenexa, Kan., 1989.
13. *Managing Fiber-Responsive Diseases*. Veterinary Medicine Publishing, Lenexa, Kan., 1988.
14. Morgan, R.V. (ed.): *Handbook of Small Animal Practice*. Churchill Livingstone, New York, N.Y., 1987.
15. Muller, G.H.; Kirk, R.W.: *Small Animal Dermatology*, 2nd Ed. W.B. Saunders, Philadelphia, Pa., 1976.
16. *Proc. 5th Ann. Vet. Med. Forum*, ACVIM. San Diego, Calif., 1987.
17. *Proc. 6th Ann. Vet. Med. Forum*, ACVIM. Washington, D.C., 1988.
18. *Proc. 7th Ann. Vet. Med. Forum*, ACVIM. San Diego, Calif., 1989.
19. Rawlings, C.A.: *Heartworm Disease in Dogs and Cats*. W.B. Saunders, Philadelphia, Pa., 1986.
20. *Scientific Proceedings*, 56th Ann. Mtg., AAHA, St. Louis, Mo., 1989.
21. Sherding, R.G. (ed.): *Medical Emergencies*. Churchill Livingstone, New York, N.Y., 1985.
22. Sherding, R.G. (ed.): *The Cat: Diseases and Clinical Management*. Churchill Livingstone, New York, N.Y., 1989.
23. Slatter, D.H. (ed.): *Textbook of Small Animal Surgery*. W.B. Saunders, Philadelphia, Pa., 1985.
24. Soulsby, E.J.L.: *Helminths, Arthropods and Protozoa of Domesticated Animals*, 7th Ed. Lea & Febiger, Philadelphia, Pa., 1982.

