

Auriculotherapy

Auriculotherapy is an ancient technique initially used to treat back pain. It was rediscovered in the 1940s by French internist Dr. Paul Nogier, who postulated that the ear contains a complete representation of the body with the head down. **Figure 1** shows the first representation proposed by Paul Nogier in 1961.

Embryologically, the external part of the ear only starts to develop in weeks five to six from six hillocks, 1-3 from the first branchial arch and 4-6 (5 does not develop) from the second branchial arch. Each hillock contains cells originating from the mesoderm, ectoderm, and endoderm. The process branches of four cranial nerves (trigeminal nerve (V), facial nerve (VII), glossopharyngeal nerve (IX), vagal nerve (X)) and branches of the superficial cervical plexus innervate the ear. **Figure 2** shows the innervation of the ear (1). The vagal nerve is marked by green, the glossopharyngeal nerve is marked in red, the trigeminal nerve is marked in blue, and the greater auricular nerve, a branch of the superficial cervical plexus, is marked in yellow.

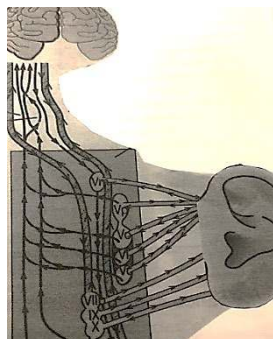


Figure 3. Schematic representation of relationships between the nerves in the ear and their corresponding nuclei in the spinal cord and brainstem.

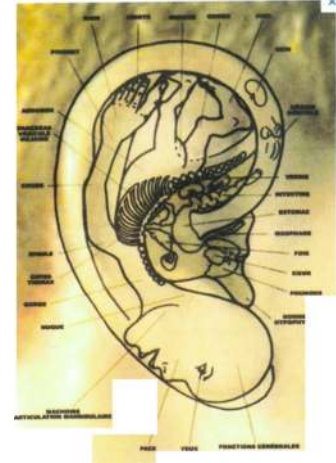

Figure 1.
Representation of Ear
by Paul Nogier

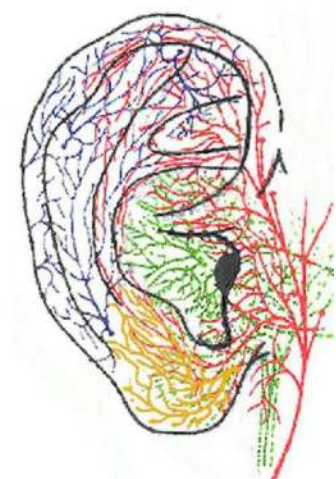


Figure 2. Innervation of
the Ear

The terminal nerve branches at the level of each ear point generate and receive impulses that are transferred to each respective nerve nuclei in the brainstem and spine.

Under these conditions, each point is in constant equilibrium with the part of the body it represents (2). **Figure 3** illustrates a schematic representation of relationships between the nerves in the ear and their corresponding nuclei in the spinal cord and brainstem.

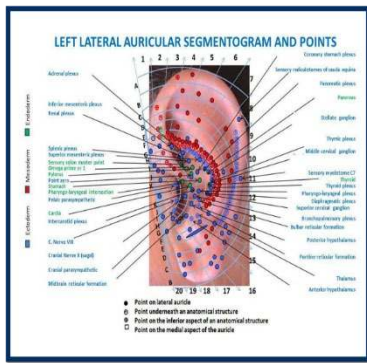


Figure 4. Left lateral cartography of the left ear

The French School of Auriculotherapy is neuro-physiologically based, meaning that treatments are developed based on the physiopathology of a clinical condition. Since the last cartography proposed by Nogier in 1996, several different cartographies of the ear have been proposed (3)—the most recent and scientifically-based cartography uses a segmentogram with the corpus collosum as the center of symmetry.

Figure 4 illustrates the points of the left ear according to the most accepted cartography of the ear. It is

based on 189 points on the lateral aspect of the ear and 89 points on the medial aspect of the ear (3).

Alimi et al. used MRI to demonstrate the validity of several ear points (4). The validation of some points of the cartography are based on clinical responses and in some cases, on MRI studies.

Figure 5 represents the basis of the validation of the thumb point using MRI. This experience was conducted by Alimi et al. and published in 2002. In 2014, Romoli et al. confirmed the finding.

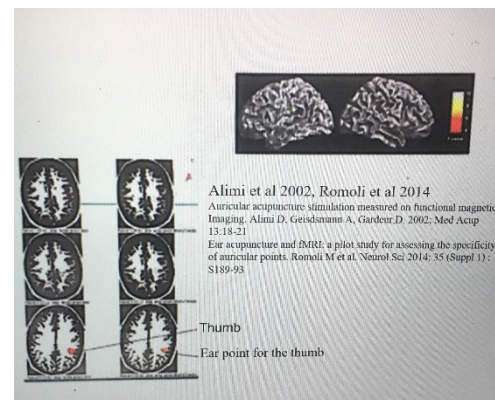


Figure 5. Basis of the validation of the thumb point using MRI.

The nuclei of the trigeminal, glossopharyngeal, facial, and vagus nerves are known to interact with a number of other nuclei and ascending and descending pathways at the level of the spine, brainstem, and central nervous system, including the spine's ascending and descending pain tracts and the limbic system. The result is a complex modulation of all ascendent and descendant signals, which allows the terminal branches of these nerves to transmit impulses from the body to the ear, from the ear to the central nervous system, and then back from the brain to the ear. **Figure 6** represents the complexity of potential interactions between the trigeminal and vagus nuclei and a number of nuclei as the resulting impulse is generated at the level of the ear branches of the vagus and trigeminal nerves. (1)

Therefore, the ear can be compared to the keyboard of a computer, with the brain representing the computer. Accordingly, each ear point is considered a somatotopic representation of the body and is in equilibrium with the body part or function it represents. Each point exists in two configuration states, either the physiologic or pathologic state. Any pathological condition, including mood disorders, is associated with a change in the configuration and electrical property of the corresponding ear points. The fundamental principle of action of auriculotherapy is to produce a reversible invalidation of the pathologic ear point because it is established that according to the second law of Khaler, the brain would reprogram the corresponding ear point in its original physiological configuration, as would be the case for a lost file on a computer. At the same time that the ear point is reconfigured, the corresponding part of the body also returns to its original condition.

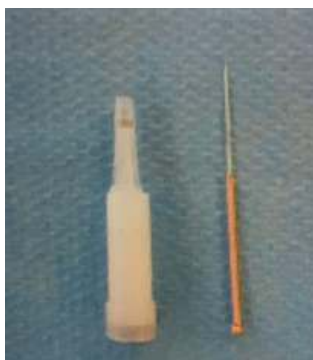

Figure 7. Classic acupuncture needle on the right and an ASP needle in its holder on the left.

Several techniques allow invalidation of an ear point. The most classic is the use of an acupuncture needle, which is placed for 20-40 min and removed, and the use of an “acupuncture semi-permanent (ASP) needle” that is placed and stays on for one or few days and then falls off. **Figure 7** shows a classic acupuncture needle on the right and an ASP needle in its holder on the left. When acupuncture needles are used in a randomized placebo control clinical trial, since their implantation produces a destruction of the ear point, the placebo treatment is placed on points theoretically not “involved in the pathology.” For example, if the protocol involved the treatment of shoulder point,

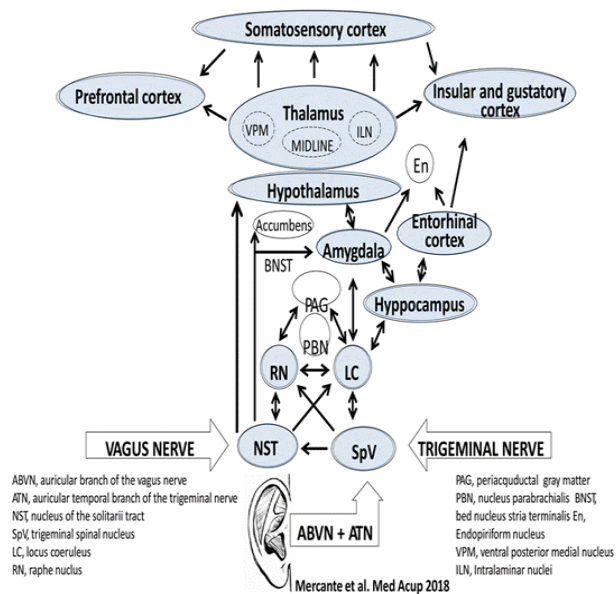


Figure 6. Proposed potential interactions at the level of the central nervous system structures as the result of the stimulation of the ear branches of the trigeminal and vagal nerves. ¹

the point of the knee may be chosen as a placebo for the shoulder. However, it is unclear if the choice of the “placebo point” really has no effect, since they produce destruction of the nerve terminal. This may explain why some placebo controlled acupuncture studies report no differences between treatment and placebo.

Another technique involves the use of a laser. There are different types of lasers. Right now, little is known about which type is more appropriate in terms of color, intensity, and duration of treatment. **Figure 8** illustrates a red laser applied to an ear point.

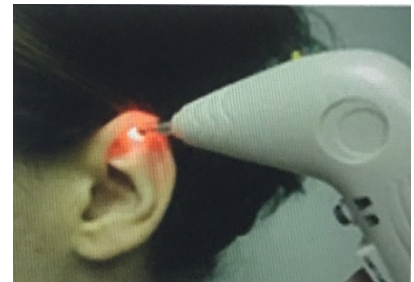


Figure 8. Auriculotherapy using a red laser

Another technique is the use of nitrogen gas. This technique is commonly used in plastic surgery to destroy superficial cutaneous lesions. The technique is based on applying a two-second jet of nitrogen on a specific ear point using a cryopuncator. This technique was developed by Dr. David Alimi and has been shown to produce similar results as the use of ASP needles. However, the advantage of such a technique is that a placebo controlled study can be designed using a true placebo consisting of using an empty canister. This allows preservation of the point that is destroyed in the case of an active treatment. **Figure 9** shows a cryopuncator with its nitrogen canister.



Figure 9. Cryopuncator with its nitrogen canister

Other techniques include the use of electric stimulation of ear points and the use of “beans” used to produce pressure at the ear point to destroy it over time. **Figure 10** illustrates acupuncture beans commercially available to perform acupressure.




Figure 10. Commercially available acupuncture beans used to perform acupressure on an ear point.

References

1. Mercane B, Ginatempo F, Manca A, Francesco Melis F, Enrico P, Franca Deriu F. Anatomic-Physiologic Basis for Auricular Stimulation. *Med Acup*. 2018; 30: 141-50.
2. Alimi D. L'Auriculotherapie medicale. Cartographie Auriculaire. Publisher Elsevier Masson pp 87-99, 2017.
3. Alimi D and Chelly JE. New Universal Nomenclature in Auriculotherapy. *J Altern Complement Med*. 2018; 24:7-14.
4. Alimi D, Geisdschmann A, Gardeur D. *Med Acup*. 2002; 13: 1