

# Dermatology

A handbook for medical students & junior doctors



This publication is supported by the British Association of Dermatologists.

First edition 2009

Revised first edition 2009

Second edition 2014

For comments and feedback, please contact the author at [chiangyizhen@gmail.com](mailto:chiangyizhen@gmail.com).

# Dermatology

A handbook for medical students & junior doctors

**Dr Nicole Yi Zhen Chiang** MBChB (Hons), MRCP (UK)  
Specialty Registrar in Dermatology  
Salford Royal NHS Foundation Trust  
Manchester M6 8HD

**Professor Julian Verbov** MD FRCP FRCPCH CBiol FSB FLS  
Professor of Dermatology  
Consultant Paediatric Dermatologist  
Alder Hey Children's Hospital  
Liverpool L12 2AP

## Contents

<b>Preface</b>	<b>5</b>
<b>Foreword</b>	<b>6</b>
<b>What is dermatology?</b>	<b>7</b>
<b>Essential Clinical Skills</b>	<b>8</b>
Taking a dermatological history	8
Examining the skin	9
Communicating examination findings	10
<b>Background Knowledge</b>	<b>23</b>
Functions of normal skin	23
Structure of normal skin and the skin appendages	23
Principles of wound healing	27
<b>Emergency Dermatology</b>	<b>28</b>
Urticaria, Angioedema and Anaphylaxis	29
Erythema nodosum	30
Erythema multiforme, Stevens-Johnson syndrome, Toxic epidermal necrolysis	31
Acute meningococcaemia	32
Erythroderma	33
Eczema herpeticum	34
Necrotizing fasciitis	35
<b>Skin Infections / Infestations</b>	<b>36</b>
Erysipelas and cellulitis	37
Staphylococcal scalded skin syndrome	38
Superficial fungal skin infections	39
<b>Skin Cancer</b>	<b>41</b>
Basal cell carcinoma	42
Squamous cell carcinoma	43
Malignant melanoma	44
<b>Inflammatory Skin Conditions</b>	<b>46</b>
Atopic eczema	47
Acne vulgaris	49
Psoriasis	50
<b>Blistering Disorders</b>	<b>52</b>
Bullous pemphigoid	53
Pemphigus vulgaris	54

**Common Important Problems 55**

Chronic leg ulcers	56
Itchy eruption	58
A changing pigmented lesion	60
Purpuric eruption	62
A red swollen leg	64

**Management 65**

Emollients	66
Topical/Oral steroids	66
Oral aciclovir	66
Oral antihistamines	66
Topical/Oral antibiotics	67
Topical antiseptics	67
Oral retinoids	67

**Practical Skills 68**

Patient education	69
Written communication	70
Prescribing skills	70
Clinical examination and investigations	71

**Acknowledgements 72**

## Preface

This Handbook of Dermatology is intended for senior medical students and newly qualified doctors.

For many reasons, including modern medical curriculum structure and a lack of suitable patients to provide adequate clinical material, most UK medical schools provide inadequate exposure to the specialty for the undergraduate. A basic readable and understandable text with illustrations has become a necessity.

This text is available online and in print and should become essential reading. Dr Chiang is to be congratulated for her exceptional industry and enthusiasm in converting an idea into a reality.

Julian Verbov

Professor of Dermatology

Liverpool 2009

## Preface to the 2nd edition

Nicole and I are gratified by the response to this Handbook which clearly fulfils its purpose. The positive feedback we have received has encouraged us to slightly expand the text and allowed us to update where necessary. I should like to thank the BAD for its continued support.

Julian Verbov

Professor of Dermatology

Liverpool 2014

## Foreword to First edition

There is a real need for appropriate information to meet the educational needs of doctors at all levels. The hard work of those who produce the curricula on which teaching is based can be undermined if the available teaching and learning materials are not of a standard that matches the developed content. I am delighted to associate the BAD with this excellent handbook, designed and developed by the very people at whom it is aimed, and matching the medical student and junior doctor curriculum directly. Any handbook must meet the challenges of being comprehensive, but brief, well illustrated, and focused to clinical presentations as well as disease groups. This book does just that, and is accessible and easily used. It may be read straight through, or dipped into for specific clinical problems. It has valuable sections on clinical method, and useful tips on practical procedures. It should find a home in the pocket of students and doctors in training, and will be rapidly worn out. I wish it had been available when I was in need, I am sure that you will all use it well in the pursuit of excellent clinical dermatology!

Dr Mark Goodfield

President of the British Association of Dermatologists

## What is dermatology?

- Dermatology is the study of both normal and abnormal skin and associated structures such as hair, nails, and oral and genital mucous membranes.

## Why is dermatology important?

- Skin diseases are very common, affecting up to a third of the population at any one time.
- Skin diseases have serious impacts on life. They can cause physical damage, embarrassment, and social and occupational restrictions. Chronic skin diseases may cause financial constraints with repeated sick leave. Some skin conditions can be life-threatening.
- In 2006-07, the total NHS health expenditure for skin diseases was estimated to be around £97 million (approximately 2% of the total NHS health expenditure).

## What is this handbook about?

- The British Association of Dermatologists outlined the essential and important learning outcomes that should be achieved by **all** medical undergraduates for the competent assessment of patients presenting with skin disorders (*available on: [http://www.bad.org.uk/Portals/Bad/Education/Undergraduate%20Education/\(Link2\)%20Core%20curriculum.pdf](http://www.bad.org.uk/Portals/Bad/Education/Undergraduate%20Education/(Link2)%20Core%20curriculum.pdf)*).
- This handbook addresses these learning outcomes and aims to equip you with the knowledge and skills to practise competently and safely as a junior doctor.



## Essential Clinical Skills

- Detailed history taking and examination provide important diagnostic clues in the assessment of skin problems.

### Learning outcomes:

1. Ability to take a dermatological history
2. Ability to explore a patient's concerns and expectations
3. Ability to interact sensitively with people with skin disease
4. Ability to examine skin, hair, nails and mucous membranes systematically showing respect for the patient
5. Ability to describe physical signs in skin, hair, nails and mucosa
6. Ability to record findings accurately in patient's records

### Taking a dermatological history

- Using the standard structure of history taking, below are the important points to consider when taking a history from a patient with a skin problem (Table 1).
- For dark lesions or moles, pay attention to questions marked with an asterisk (\*).

**Table 1. Taking a dermatological history**

Main headings	Key questions
<b>Presenting complaint</b>	Nature, site and duration of problem
<b>History of presenting complaint</b>	Initial appearance and evolution of lesion* Symptoms (particularly itch and pain)* Aggravating and relieving factors Previous and current treatments (effective or not) Recent contact, stressful events, illness and travel History of sunburn and use of tanning machines* Skin type ( <i>see page 70</i> )*
<b>Past medical history</b>	History of atopy i.e. asthma, allergic rhinitis, eczema History of skin cancer and suspicious skin lesions
<b>Family history</b>	Family history of skin disease*
<b>Social history</b>	Occupation (including skin contacts at work) Improvement of lesions when away from work
<b>Medication and allergies</b>	Regular, recent and over-the-counter medications
<b>Impact on quality of life</b>	Impact of skin condition and concerns

**Examining the skin**

- There are four important principles in performing a good examination of the skin: **INSPECT, DESCRIBE, PALPATE** and **SYSTEMATIC CHECK** (Table 2).

**Table 2. Examining the skin**

<b>Main principles</b>	<b>Key features</b>
<b>INSPECT</b> <i>in general</i>	General observation Site and number of lesion(s) <i>If multiple</i> , pattern of distribution and configuration
<b>DESCRIBE</b> <i>the individual lesion</i>	<b><u>SCAM</u></b> <b><u>S</u></b> ize (the widest diameter), <b><u>S</u></b> hape <b><u>C</u></b> olour <b><u>A</u></b> ssociated secondary change <b><u>M</u></b> orphology, <b><u>M</u></b> argin (border)
<i>*If the lesion is pigmented, remember <b><u>ABCD</u></b></i> <i>(the presence of any of these features increase the likelihood of melanoma):</i>	
	<b><u>A</u></b> symmetry (lack of mirror image in any of the four quadrants) Irregular <b><u>B</u></b> order Two or more <b><u>C</u></b> olours within the lesion <b><u>D</u></b> iameter > 6mm
<b>PALPATE</b> <i>the individual lesion</i>	Surface Consistency Mobility Tenderness Temperature
<b>SYSTEMATIC CHECK</b>	Examine the nails, scalp, hair & mucous membranes General examination of all systems

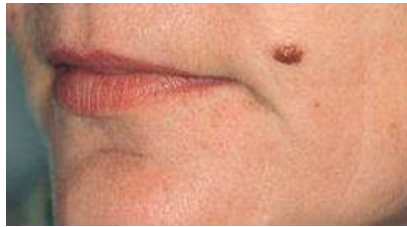**Communicating examination findings**

- In order to describe, record and communicate examination findings accurately, it is important to learn the appropriate terminology (Tables 3-10).

**Table 3. General terms**

Terms	Meaning
Pruritus	Itching
Lesion	An area of altered skin
Rash	An eruption
Naevus	A localised malformation of tissue structures

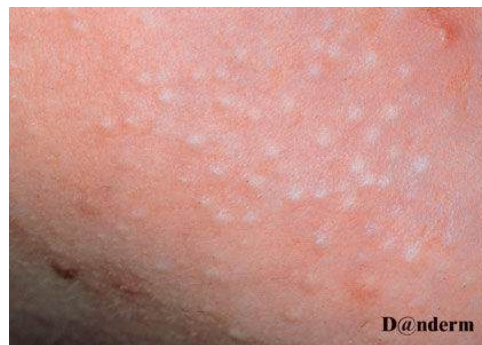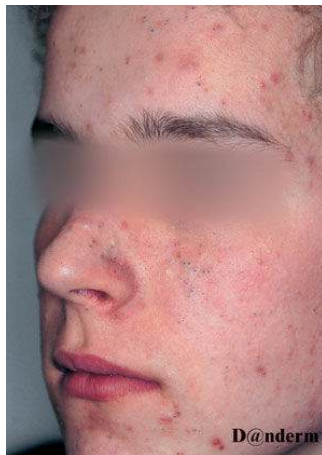Example: (Picture Source: D@nderm)



Pigmented melanocytic naevus (mole)

**Comedone** A plug in a sebaceous follicle containing altered sebum, bacteria and cellular debris; can present as either open (blackheads) or closed (whiteheads)

Example:

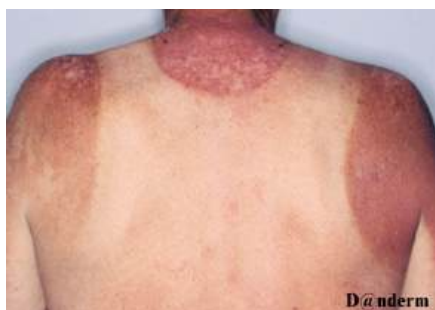

Open comedones (left) and closed comedones (right) in acne

**Table 4. Distribution** (the pattern of spread of lesions)

Terms	Meaning
<b>Generalised</b>	All over the body
<b>Widespread</b>	Extensive
<b>Localised</b>	Restricted to one area of skin only
<b>Flexural</b>	Body folds i.e. groin, neck, behind ears, popliteal and antecubital fossa
<b>Extensor</b>	Knees, elbows, shins
<b>Pressure areas</b>	Sacrum, buttocks, ankles, heels
<b>Dermatome</b>	An area of skin supplied by a single spinal nerve
<b>Photosensitive</b>	Affects sun-exposed areas such as face, neck and back of hands

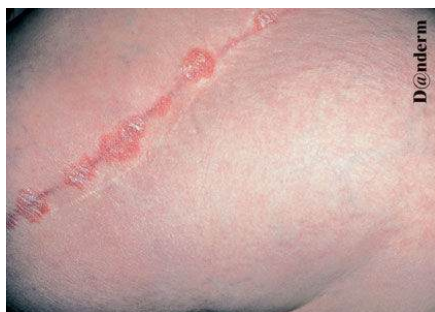Example:



Sunburn




**Köebner phenomenon** A linear eruption arising at site of trauma

Example:



Psoriasis

**Table 5. Configuration** (the pattern or shape of grouped lesions)

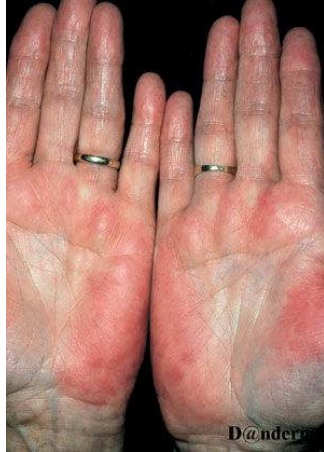Terms	Meaning
<b>Discrete</b>	Individual lesions separated from each other
<b>Confluent</b>	Lesions merging together
<b>Linear</b>	In a line
<b>Target</b>	Concentric rings (like a dartboard) Example:  Erythema multiforme
<b>Annular</b>	Like a circle or ring Example:  Tinea corporis ('ringworm')
<b>Discoid / Nummular</b>	A coin-shaped/round lesion Example:  Discoid eczema

**Table 6. Colour**

Terms	Meaning
-------	---------

**Erythema** Redness (due to inflammation and vasodilatation) which blanches on pressure

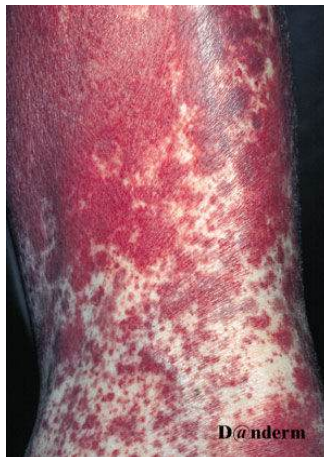Example:



Palmar erythema

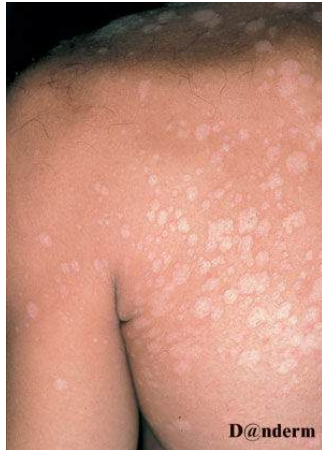**Purpura** Red or purple colour (due to bleeding into the skin or mucous membrane) which does not blanch on pressure – petechiae (small pinpoint macules) and ecchymoses (larger bruise-like patches)

Example:



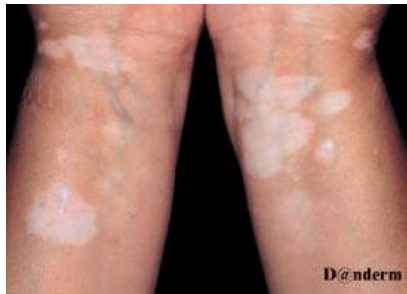
Henoch-Schönlein purpura  
(palpable small vessel vasculitis)

**Hypo-pigmentation** Area(s) of paler skin  
Example:



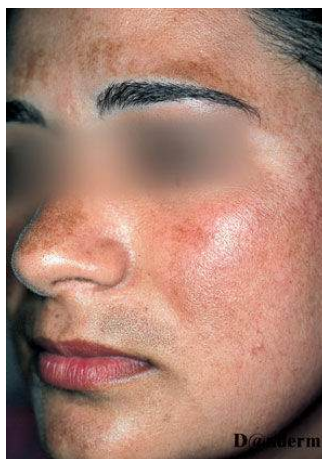Pityriasis versicolor  
(a superficial fungus infection)

**De-pigmentation** White skin due to absence of melanin  
Example:





Vitiligo  
(loss of skin melanocytes)

**Hyper-pigmentation** Darker skin which may be due to various causes (e.g. post-inflammatory)  
Example:



Melasma  
(increased melanin pigmentation)

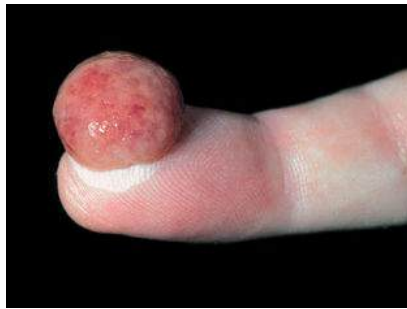**Table 7. Morphology** (the structure of a lesion) – **Primary lesions**

Terms	Meaning
<b>Macule</b>	A flat area of altered colour Example:  Freckles
<b>Patch</b>	Larger flat area of altered colour or texture Example:  Vascular malformation (naevus flammeus / 'port wine stain')
<b>Papule</b>	Solid raised lesion < 0.5cm in diameter Example:  Xanthomata



**Nodule** Solid raised lesion >0.5cm in diameter with a deeper component

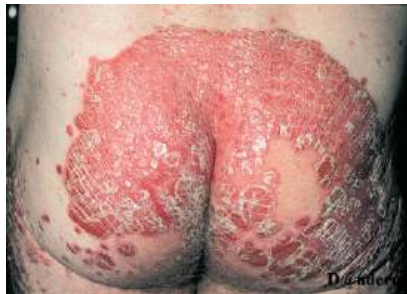Example: (Picture source: D@nderm)



Pyogenic granuloma  
(granuloma telangiectaticum)

**Plaque** Palpable scaling raised lesion >0.5cm in diameter

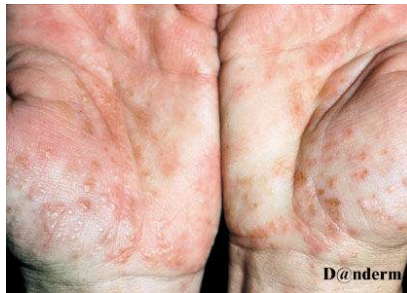Example:



Psoriasis

**Vesicle** Raised, clear fluid-filled lesion <0.5cm in diameter

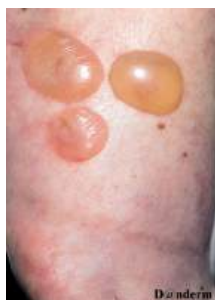**(small blister)** Example:



Acute hand eczema  
(pompholyx)

**Bulla** Raised, clear fluid-filled lesion >0.5cm in diameter

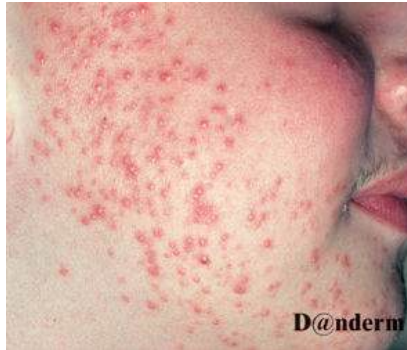**(large blister)** Example:



Reaction to insect bites

**Pustule** Pus-containing lesion <0.5cm in diameter

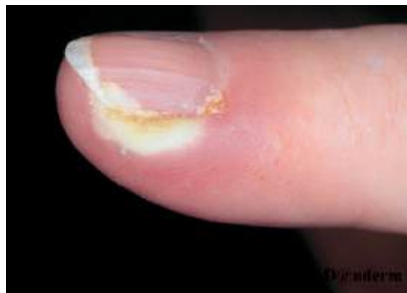Example:



Acne

**Abscess** Localised accumulation of pus in the dermis or subcutaneous tissues

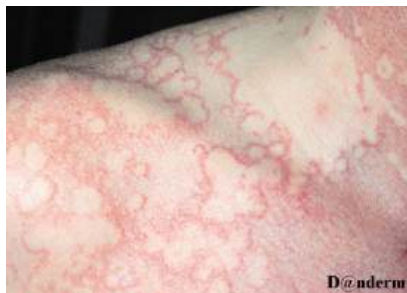Example:



Periungual abscess  
(acute paronychia)

**W(h)eal** Transient raised lesion due to dermal oedema

Example:



Urticaria

**Boil/Furuncle** Staphylococcal infection around or within a hair follicle

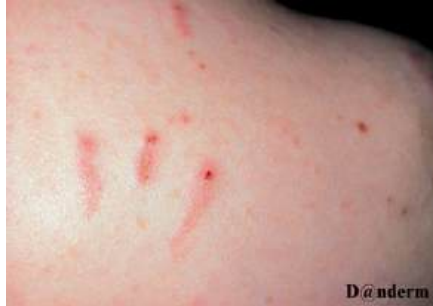**Carbuncle** Staphylococcal infection of adjacent hair follicles (multiple boils/furuncles)

**Table 8. Morphology - Secondary lesions** (lesions that evolve from primary lesions)

Terms	Meaning
-------	---------

**Excoriation** Loss of epidermis following trauma

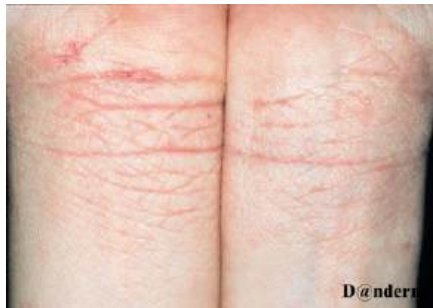Example:



Excoriations in eczema

**Lichenification** Well-defined roughening of skin with accentuation of skin markings

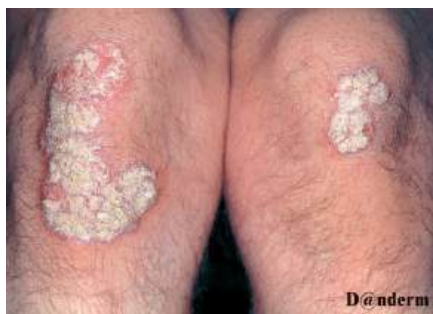Example:



Lichenification due to chronic rubbing in eczema

**Scales** Flakes of stratum corneum

Example:

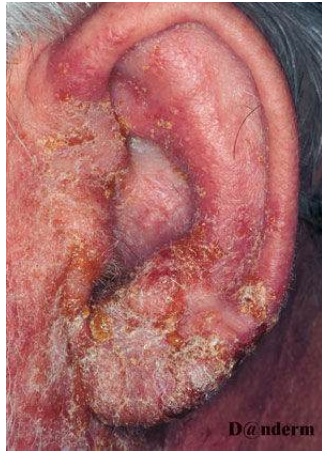

Psoriasis (showing silvery scales)

**Crust**

Rough surface consisting of dried serum, blood, bacteria and cellular debris that has exuded through an eroded epidermis (e.g. from a burst blister)

Example:

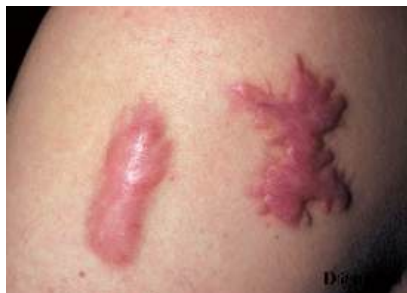

Impetigo

**Scar**

New fibrous tissue which occurs post-wound healing, and may be atrophic (thinning), hypertrophic (hyperproliferation within wound boundary), or keloidal (hyperproliferation beyond wound boundary)

Example:

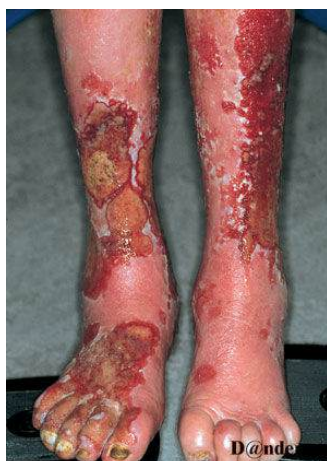

Keloid scars

**Ulcer**

Loss of epidermis and dermis (heals with scarring)

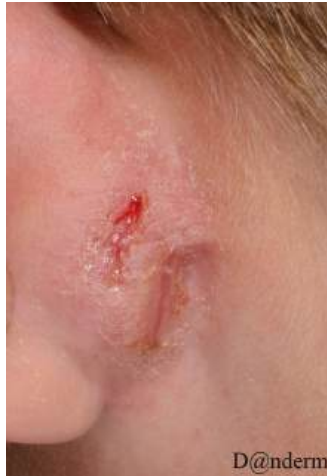Example:



Leg ulcers

**Fissure** An epidermal crack often due to excess dryness

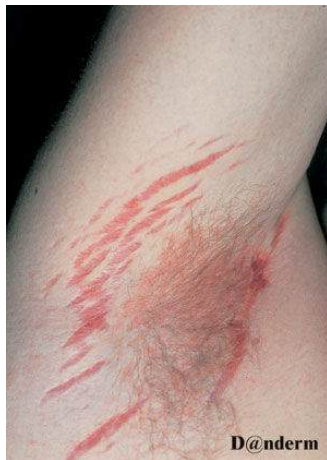Example:



Eczema




**Striae** Linear areas which progress from purple to pink to white, with the histopathological appearance of a scar (associated with excessive steroid usage and glucocorticoid production, growth spurts and pregnancy)

Example:







Striae

**Table 9. Hair**

Terms	Meaning
<b>Alopecia</b> Loss of hair Example: 	Alopecia areata (well-defined patch of complete hair loss)
<b>Hirsutism</b> Androgen-dependent hair growth in a female Example: 	Hirsutism
<b>Hypertrichosis</b> Non-androgen dependent pattern of excessive hair growth (e.g. in pigmented naevi) Example: 	Hypertrichosis

**Table 10. Nails**

Terms	Meaning
<b>Clubbing</b>	<p>Loss of angle between the posterior nail fold and nail plate (associations include suppurative lung disease, cyanotic heart disease, inflammatory bowel disease and idiopathic)</p> <p>Example: <i>(Picture source: D@nderm)</i></p>  <p>Clubbing</p>
<b>Koilonychia</b>	<p>Spoon-shaped depression of the nail plate (associations include iron-deficiency anaemia, congenital and idiopathic)</p> <p>Example: <i>(Picture source: D@nderm)</i></p>  <p>Koilonychia</p>
<b>Onycholysis</b>	<p>Separation of the distal end of the nail plate from nail bed (associations include trauma, psoriasis, fungal nail infection and hyperthyroidism)</p> <p>Example: <i>(Picture source: D@nderm)</i></p>  <p>Onycholysis</p>
<b>Pitting</b>	<p>Punctate depressions of the nail plate (associations include psoriasis, eczema and alopecia areata)</p> <p>Example: <i>(Picture source: D@nderm)</i></p>  <p>Pitting</p>

## Background Knowledge

- This section covers the basic knowledge of normal skin structure and function required to help understand how skin diseases occur.

### Learning outcomes:

1. Ability to describe the functions of normal skin
2. Ability to describe the structure of normal skin
3. Ability to describe the principles of wound healing
4. Ability to describe the difficulties, physical and psychological, that may be experienced by people with chronic skin disease

### Functions of normal skin

- These include:
  - i) Protective barrier against environmental insults
  - ii) Temperature regulation
  - iii) Sensation
  - iv) Vitamin D synthesis
  - v) Immunosurveillance
  - vi) Appearance/cosmesis

### Structure of normal skin and the skin appendages

- The skin is the largest organ in the human body. It is composed of the epidermis and dermis overlying subcutaneous tissue. The skin appendages (structures formed by skin-derived cells) are hair, nails, sebaceous glands and sweat glands.

### *Epidermis*

- The epidermis is composed of 4 major cell types, each with specific functions (Table 11).



**Table 11. Main functions of each cell type in the epidermis**

Cell types	Main functions
Keratinocytes	Produce keratin as a protective barrier
Langerhans' cells	Present antigens and activate T-lymphocytes for immune protection
Melanocytes	Produce melanin, which gives pigment to the skin and protects the cell nuclei from ultraviolet (UV) radiation-induced DNA damage
Merkel cells	Contain specialised nerve endings for sensation

- There are 4 layers in the epidermis (Table 12), each representing a different stage of maturation of the keratinocytes. The average epidermal turnover time (migration of cells from the basal cell layer to the horny layer) is about 30 days.

**Table 12. Composition of each epidermal layer**

Epidermal layers	Composition
<b>Stratum basale</b> (Basal cell layer)	Actively dividing cells, deepest layer
<b>Stratum spinosum</b> (Prickle cell layer)	Differentiating cells
<b>Stratum granulosum</b> (Granular cell layer)	So-called because cells lose their nuclei and contain granules of keratohyaline. They secrete lipid into the intercellular spaces.
<b>Stratum corneum</b> (Horny layer)	Layer of keratin, most superficial layer

- In areas of thick skin such as the sole, there is a fifth layer, stratum lucidum, beneath the stratum corneum. This consists of paler, compact keratin.
- Pathology of the epidermis may involve:
  - a) changes in epidermal turnover time - e.g. psoriasis (reduced epidermal turnover time)
  - b) changes in the surface of the skin or loss of epidermis - e.g. scales, crusting, exudate, ulcer
  - c) changes in pigmentation of the skin - e.g. hypo- or hyper-pigmented skin

**Dermis**

- The dermis is made up of collagen (mainly), elastin and glycosaminoglycans, which are synthesised by fibroblasts. Collectively, they provide the dermis with strength and elasticity.
- The dermis also contains immune cells, nerves, skin appendages as well as lymphatic and blood vessels.
- Pathology of the dermis may involve:
  - a) changes in the contour of the skin or loss of dermis e.g. formation of papules, nodules, skin atrophy and ulcers
  - b) disorders of skin appendages e.g. disorders of hair, acne (disorder of sebaceous glands)
  - c) changes related to lymphatic and blood vessels e.g. erythema (vasodilatation), urticaria (increased permeability of capillaries and small venules), purpura (capillary leakage)

**Hair**

- There are 3 main types of hair:
  - a) lanugo hair (fine long hair in fetus)
  - b) vellus hair (fine short hair on all body surfaces)
  - c) terminal hair (coarse long hair on the scalp, eyebrows, eyelashes and pubic areas)
- Each hair consists of modified keratin and is divided into the hair shaft (a keratinized tube) and hair bulb (actively dividing cells, and melanocytes which give pigment to the hair).
- Each hair follicle enters its own growth cycle. This occurs in 3 main phases:
  - a) anagen (long growing phase)
  - b) catagen (short regressing phase)
  - c) telogen (resting/shedding phase)
- Pathology of the hair may involve:
  - a) reduced or absent melanin pigment production e.g. grey or white hair
  - b) changes in duration of the growth cycle e.g. hair loss (premature entry of hair follicles into the telogen phase)
  - c) shaft abnormalities

**Nails**

- The nail is made up of a nail plate (hard keratin) which arises from the nail matrix at the posterior nail fold, and rests on the nail bed.
- The nail bed contains blood capillaries which gives the pink colour of the nails.
- Pathology of the nail may involve:
  - a) abnormalities of the nail matrix e.g. pits and ridges
  - b) abnormalities of the nail bed e.g. splinter haemorrhage
  - c) abnormalities of the nail plate e.g. discoloured nails, thickening of nails

**Sebaceous glands**

- Sebaceous glands produce sebum via hair follicles (collectively called a pilosebaceous unit). They secrete sebum onto the skin surface which lubricates and waterproofs the skin.
- Sebaceous glands are stimulated by the conversion of androgens to dihydrotestosterone and therefore become active at puberty.
- Pathology of sebaceous glands may involve:
  - a) increased sebum production and bacterial colonisation e.g. acne
  - b) sebaceous gland hyperplasia

**Sweat glands**

- Sweat glands regulate body temperature and are innervated by the sympathetic nervous system.
- They are divided into two types: eccrine and apocrine sweat glands.
- Eccrine sweat glands are universally distributed in the skin.
- Apocrine sweat glands are found in the axillae, areolae, genitalia and anus, and modified glands are found in the external auditory canal. They only function from puberty onwards and action of bacteria on the sweat produces body odour.
- Pathology of sweat glands may involve:
  - a) inflammation/infection of apocrine glands e.g. hidradenitis suppurativa
  - b) overactivity of eccrine glands e.g. hyperhidrosis

**Principles of wound healing**

- Wound healing occurs in 4 phases: haemostasis, inflammation, proliferation and remodelling (Table 13).

**Table 13. Stages of wound healing**

<b>Stages of wound healing</b>	<b>Mechanisms</b>
<b>Haemostasis</b>	<ul style="list-style-type: none"> <li>• Vasoconstriction and platelet aggregation</li> <li>• Clot formation</li> </ul>
<b>Inflammation</b>	<ul style="list-style-type: none"> <li>• Vasodilatation</li> <li>• Migration of neutrophils and macrophages</li> <li>• Phagocytosis of cellular debris and invading bacteria</li> </ul>
<b>Proliferation</b>	<ul style="list-style-type: none"> <li>• Granulation tissue formation (synthesised by fibroblasts) and angiogenesis</li> <li>• Re-epithelialisation (epidermal cell proliferation and migration)</li> </ul>
<b>Remodelling</b>	<ul style="list-style-type: none"> <li>• Collagen fibre re-organisation</li> <li>• Scar maturation</li> </ul>

## Emergency Dermatology

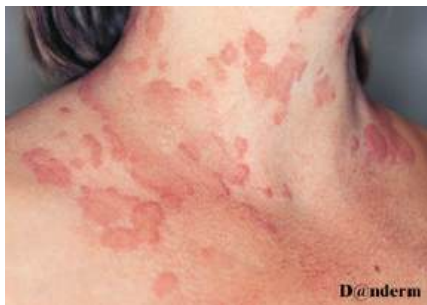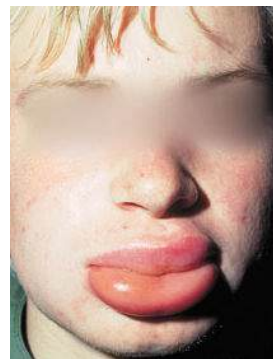- These are rapidly progressive skin conditions and some are potentially life-threatening. Early recognition is important to implement prompt supportive care and therapy.
- Some are drug reactions and the offending drug should be withdrawn.
- The essential management for all dermatological emergencies, like any emergency, consists of:
  - i) full supportive care - ABC of resuscitation
  - ii) withdrawal of precipitating agents
  - iii) management of associated complications
  - iv) specific treatment (highlighted below under each condition)

### Learning outcomes:

1. Ability to recognise and describe these skin reactions:
  - urticaria
  - erythema nodosum
  - erythema multiforme
  
2. Ability to recognise these emergency presentations, discuss the causes, potential complications and provide first contact care in these emergencies:
  - anaphylaxis and angioedema
  - toxic epidermal necrolysis
  - Stevens-Johnson syndrome
  - acute meningococcaemia
  - erythroderma
  - eczema herpeticum
  - necrotising fasciitis

**Urticaria, Angioedema and Anaphylaxis**

- Causes**
- Idiopathic, food (e.g. nuts, sesame seeds, shellfish, dairy products), drugs (e.g. penicillin, contrast media, non-steroidal anti-inflammatory drugs (NSAIDs), morphine, angiotensin-converting enzyme inhibitors (ACE-i)), insect bites, contact (e.g. latex), viral or parasitic infections, autoimmune, and hereditary (in some cases of angioedema)
- Description**
- **Urticaria** is due to a local increase in permeability of capillaries and small venules. A large number of inflammatory mediators (including prostaglandins, leukotrienes, and chemotactic factors) play a role but histamine derived from skin mast cells appears to be the major mediator. Local mediator release from mast cells can be induced by immunological or non-immunological mechanisms.
- Presentation**
- Urticaria (swelling involving the superficial dermis, raising the epidermis): itchy wheals
  - Angioedema (deeper swelling involving the dermis and subcutaneous tissues): swelling of tongue and lips
  - Anaphylaxis (also known as anaphylactic shock): bronchospasm, facial and laryngeal oedema, hypotension; can present initially with urticaria and angioedema
- Management**
- Antihistamines for urticaria
  - Corticosteroids for severe acute urticaria and angioedema
  - Adrenaline, corticosteroids and antihistamines for anaphylaxis
- Complications**
- Urticaria is normally uncomplicated
  - Angioedema and anaphylaxis can lead to asphyxia, cardiac arrest and death

**Urticaria****Angioedema**

## **Erythema nodosum**

### ***Description***

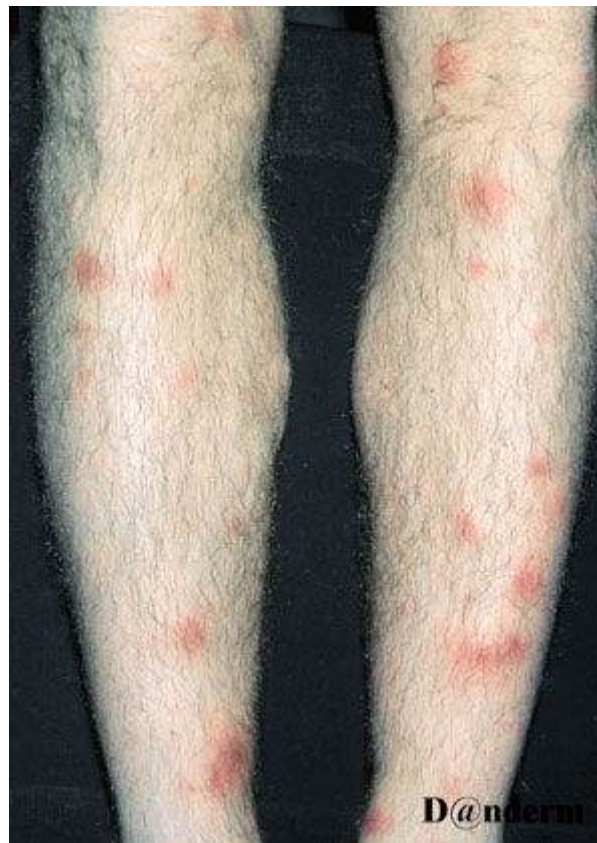- A hypersensitivity response to a variety of stimuli

### ***Causes***

- Group A beta-haemolytic streptococcus, primary tuberculosis, pregnancy, malignancy, sarcoidosis, inflammatory bowel disease (IBD), chlamydia and leprosy

### ***Presentation***

- Discrete tender nodules which may become confluent
- Lesions continue to appear for 1-2 weeks and leave bruise-like discolouration as they resolve
- Lesions do not ulcerate and resolve without atrophy or scarring
- The shins are the most common site



**Erythema nodosum**

**Erythema multiforme, Stevens-Johnson syndrome and Toxic epidermal necrolysis****Description**

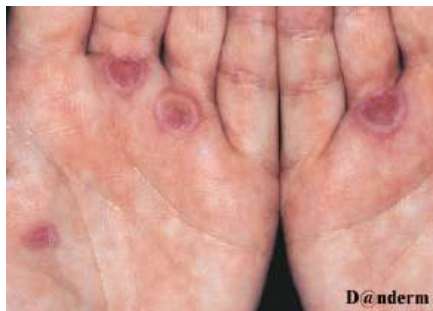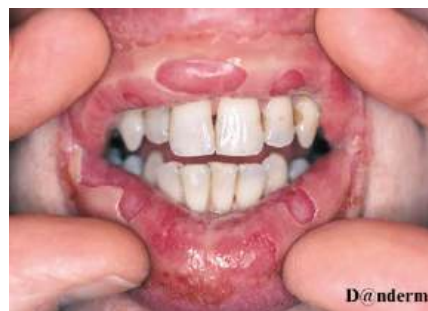- **Erythema multiforme**, often of unknown cause, is an acute self-limiting inflammatory condition with herpes simplex virus being the main precipitating factor. Other infections and drugs are also causes. Mucosal involvement is absent or limited to only one mucosal surface.
- **Stevens-Johnson syndrome** is characterised by mucocutaneous necrosis with at least two mucosal sites involved. Skin involvement may be limited or extensive. Drugs or combinations of infections or drugs are the main associations. Epithelial necrosis with few inflammatory cells is seen on histopathology. The extensive necrosis distinguishes Stevens-Johnson syndrome from erythema multiforme. Stevens-Johnson syndrome may have features overlapping with toxic epidermal necrolysis including a prodromal illness.
- **Toxic epidermal necrosis** which is usually drug-induced, is an acute severe similar disease characterised by extensive skin and mucosal necrosis accompanied by systemic toxicity. On histopathology there is full thickness epidermal necrosis with subepidermal detachment.

**Management**

- Early recognition and call for help
- Full supportive care to maintain haemodynamic equilibrium

**Complications**

- Mortality rates are 5-12% with SJS and >30% with TEN with death often due to sepsis, electrolyte imbalance or multi-system organ failure

**Erythema multiforme****Stevens-Johnson syndrome**



## **Acute meningococcaemia**

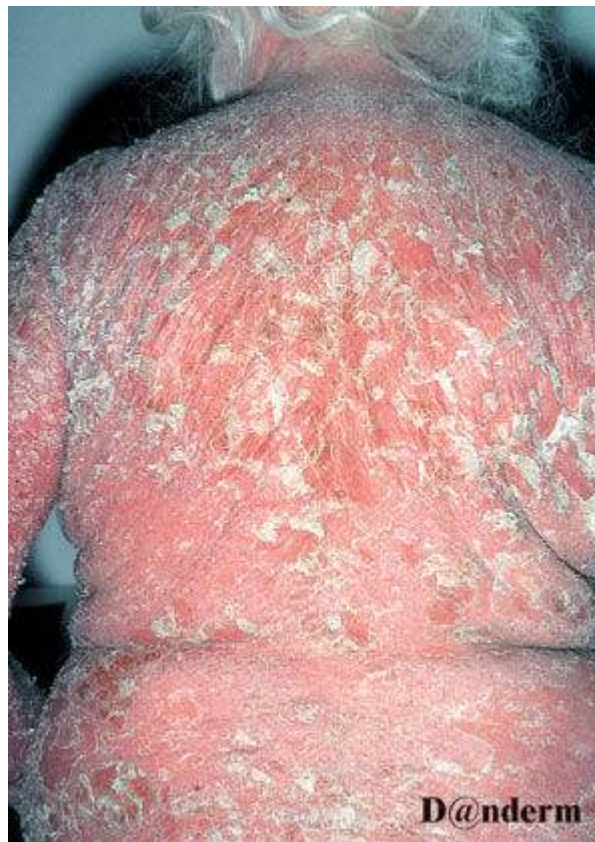- Description**
- A serious communicable infection transmitted via respiratory secretions; bacteria get into the circulating blood
- Cause**
- Gram negative diplococcus *Neisseria meningitides*
- Presentation**
- Features of meningitis (e.g. headache, fever, neck stiffness), septicaemia (e.g. hypotension, fever, myalgia) and a typical rash
  - Non-blanching purpuric rash on the trunk and extremities, which may be preceded by a blanching maculopapular rash, and can rapidly progress to ecchymoses, haemorrhagic bullae and tissue necrosis
- Management**
- Antibiotics (e.g. benzylpenicillin)
  - Prophylactic antibiotics (e.g. rifampicin) for close contacts (ideally within 14 days of exposure)
- Complications**
- Septicaemic shock, disseminated intravascular coagulation, multi-organ failure and death

*Further reading: Hart CA, Thomson APJ. Meningococcal disease and its management in children.*

*BMJ 2006;333:685-690 (<http://www.bmj.com/cgi/content/full/333/7570/685>)*

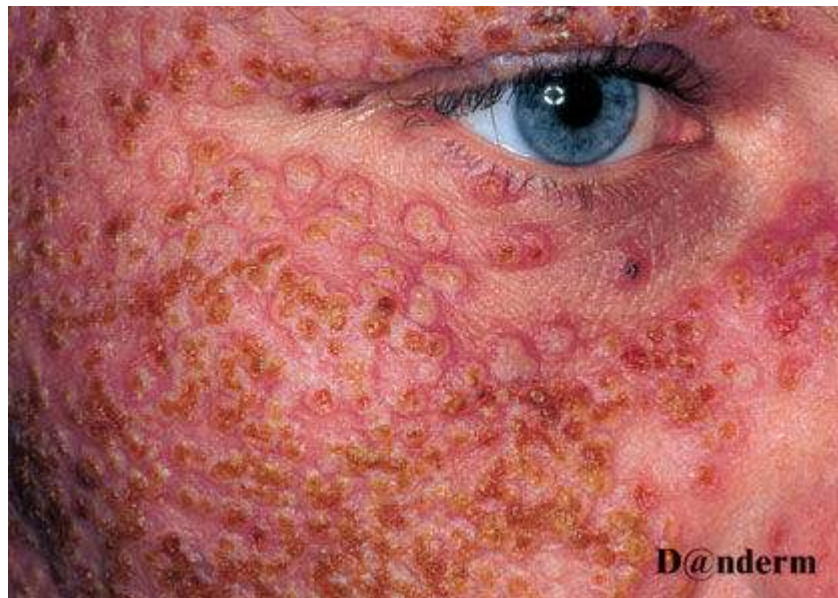**Erythroderma ('red skin')**

<b>Description</b>	<ul style="list-style-type: none"> <li>● Exfoliative dermatitis involving at least 90% of the skin surface</li> </ul>
<b>Causes</b>	<ul style="list-style-type: none"> <li>● Previous skin disease (e.g. eczema, psoriasis), lymphoma, drugs (e.g. sulphonamides, gold, sulphonylureas, penicillin, allopurinol, captopril) and idiopathic</li> </ul>
<b>Presentation</b>	<ul style="list-style-type: none"> <li>● Skin appears inflamed, oedematous and scaly</li> <li>● Systemically unwell with lymphadenopathy and malaise</li> </ul>
<b>Management</b>	<ul style="list-style-type: none"> <li>● Treat the underlying cause, where known</li> <li>● Emollients and wet-wraps to maintain skin moisture</li> <li>● Topical steroids may help to relieve inflammation</li> </ul>
<b>Complications</b>	<ul style="list-style-type: none"> <li>● Secondary infection, fluid loss and electrolyte imbalance, hypothermia, high-output cardiac failure and capillary leak syndrome (most severe)</li> </ul>
<b>Prognosis</b>	<ul style="list-style-type: none"> <li>● Largely depends on the underlying cause</li> <li>● Overall mortality rate ranges from 20 to 40%</li> </ul>

**Erythroderma**

**Eczema herpeticum (Kaposi's varicelliform eruption)**

- Description**
- Widespread eruption - serious complication of atopic eczema or less commonly other skin conditions
- Cause**
- Herpes simplex virus
- Presentation**
- Extensive crusted papules, blisters and erosions
  - Systemically unwell with fever and malaise
- Management**
- Antivirals (e.g. aciclovir)
  - Antibiotics for bacterial secondary infection
- Complications**
- Herpes hepatitis, encephalitis, disseminated intravascular coagulation (DIC) and rarely, death



**Eczema herpeticum**

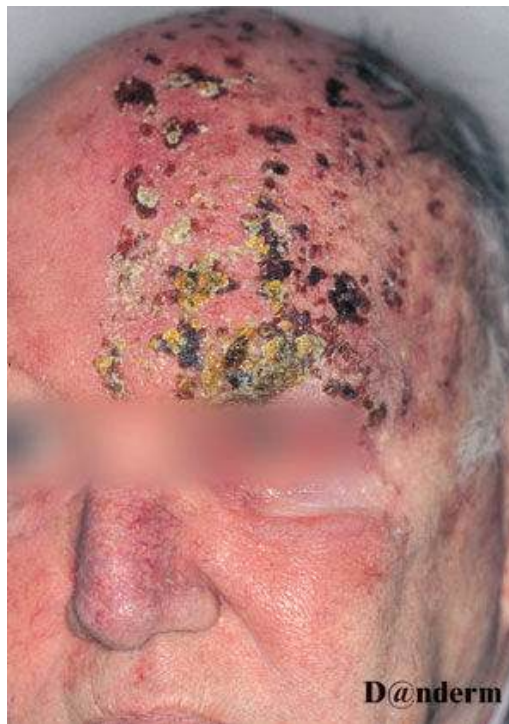## **Necrotising fasciitis**

- Description**
- A rapidly spreading infection of the deep fascia with secondary tissue necrosis
- Causes**
- Group A haemolytic streptococcus, or a mixture of anaerobic and aerobic bacteria
  - Risk factors include abdominal surgery and medical co-morbidities (e.g. diabetes, malignancy)
  - 50% of cases occur in previously healthy individuals
- Presentation**
- Severe pain
  - Erythematous, blistering, and necrotic skin
  - Systemically unwell with fever and tachycardia
  - Presence of crepitus (subcutaneous emphysema)
  - X-ray may show soft tissue gas (absence should not exclude the diagnosis)
- Management**
- Urgent referral for extensive surgical debridement
  - Intravenous antibiotics
- Prognosis**
- Mortality up to 76%

*Further reading: Hasham S, Matteucci P, Stanley PRW, Hart NB. Necrotising fasciitis. BMJ 2005;330:830-833 (<http://www.bmj.com/cgi/content/full/330/7495/830>)*

## Skin Infections / Infestations

- The normal skin microflora and antimicrobial peptides protect the skin against infection. However, when there is skin damage, microorganisms can penetrate resulting in infection.
- There are 3 main types of skin infections according to their sources: bacterial (e.g. staphylococcal and streptococcal), viral (e.g. human papilloma virus, herpes simplex (*see page 34*) and herpes zoster (*see below*)), and fungal (e.g. tinea (*see page 39 & 40*), candida (*see page 39 & 40*) and yeasts). Infestations (e.g. scabies (*see page 58 & 59*), cutaneous leishmaniasis) can also occur.



Herpes zoster (shingles) infection due to varicella-zoster virus affecting the distribution of the ophthalmic division of the fifth cranial (trigeminal) nerve  
 Note: Examination for eye involvement is important

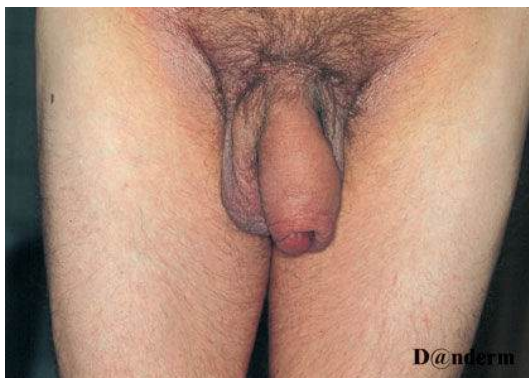### Learning outcomes:

Ability to describe the presentation, investigation and management of:

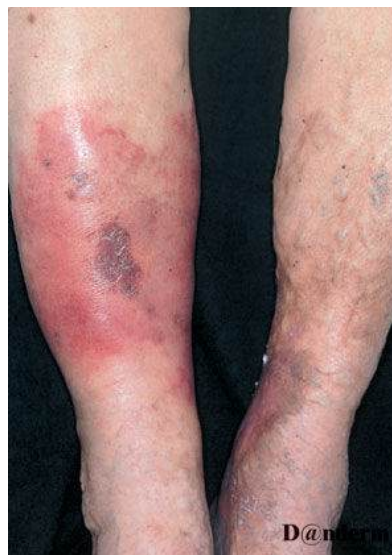- cellulitis and erysipelas
- staphylococcal scalded skin syndrome
- superficial fungal infections

**Erysipelas and Cellulitis**

- Description**
- Spreading bacterial infection of the skin
  - **Cellulitis** involves the deep subcutaneous tissue
  - **Erysipelas** is an acute superficial form of cellulitis and involves the dermis and upper subcutaneous tissue
- Causes**
- Streptococcus pyogenes and Staphylococcus aureus
  - Risk factors include immunosuppression, wounds, leg ulcers, toeweb intertrigo, and minor skin injury
- Presentation**
- Most common in the lower limbs
  - Local signs of inflammation – swelling (tumor), erythema (rubor), warmth (calor), pain (dolor); may be associated with lymphangitis
  - Systemically unwell with fever, malaise or rigors, particularly with erysipelas
  - **Erysipelas** is distinguished from cellulitis by a well-defined, red raised border
- Management**
- Antibiotics (e.g. flucloxacillin or benzylpenicillin)
  - Supportive care including rest, leg elevation, sterile dressings and analgesia
- Complications**
- Local necrosis, abscess and septicaemia



Cellulitis with elephantiasis of the penis



Erysipelas

## Staphylococcal scalded skin syndrome

### **Description**

- Commonly seen in infancy and early childhood

### **Cause**

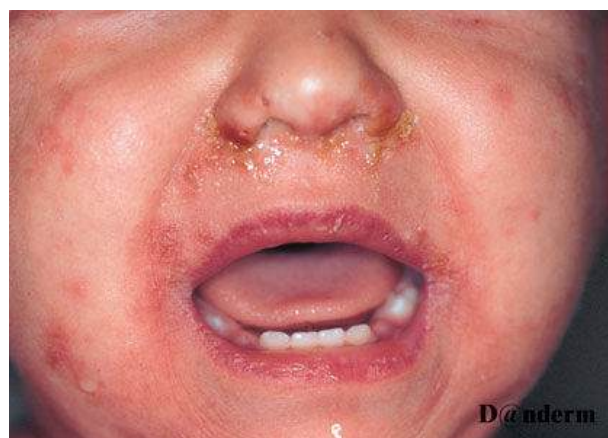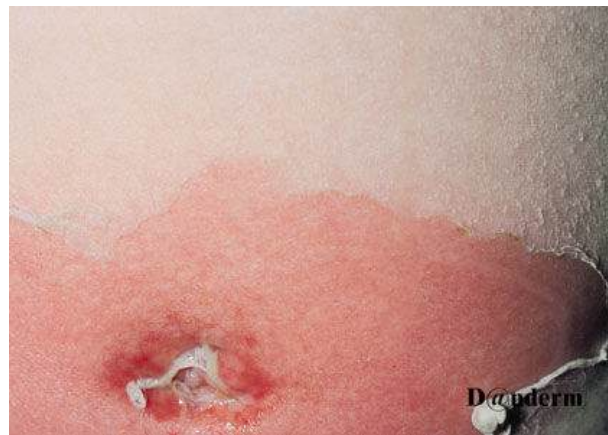- Production of a circulating epidermolytic toxin from phage group II, benzylpenicillin-resistant (coagulase positive) staphylococci

### **Presentation**

- Develops within a few hours to a few days, and may be worse over the face, neck, axillae or groins
- A scald-like skin appearance is followed by large flaccid bulla
- Perioral crusting is typical
- There is intraepidermal blistering in this condition
- Lesions are very painful
- Sometimes the eruption is more localised
- Recovery is usually within 5-7 days

### **Management**

- Antibiotics (e.g. a systemic penicillinase-resistant penicillin, fusidic acid, erythromycin or appropriate cephalosporin)
- Analgesia



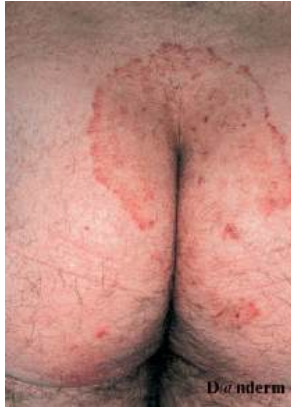**Staphylococcal scalded skin syndrome**

**Superficial fungal infections**

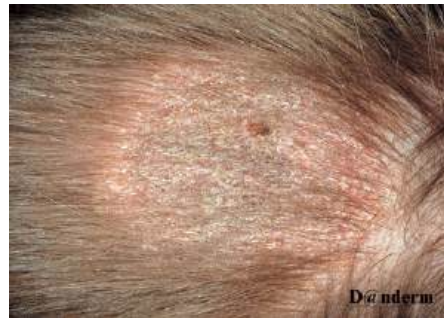- Description**
- A common and mild infection of the superficial layers of the skin, nails and hair, but can be severe in immunocompromised individuals
- Cause**
- Three main groups: dermatophytes (tinea/ringworm), yeasts (e.g. candidiasis, malassezia), moulds (e.g. aspergillus)
- Presentation**
- Varies with the site of infection; usually unilateral and itchy
  - Tinea corporis (tinea infection of the trunk and limbs) - Itchy, circular or annular lesions with a clearly defined, raised and scaly edge is typical
  - Tinea cruris (tinea infection of the groin and natal cleft) – very itchy, similar to tinea corporis
  - Tinea pedis (athlete’s foot) – moist scaling and fissuring in toewebs, spreading to the sole and dorsal aspect of the foot
  - Tinea manuum (tinea infection of the hand) – scaling and dryness in the palmar creases
  - Tinea capitis (scalp ringworm) – patches of broken hair, scaling and inflammation
  - Tinea unguium (tinea infection of the nail) – yellow discolouration, thickened and crumbly nail
  - Tinea incognito (inappropriate treatment of tinea infection with topical or systemic corticosteroids) – Ill-defined and less scaly lesions
  - Candidiasis (candidal skin infection) – white plaques on mucosal areas, erythema with satellite lesions in flexures
  - Pityriasis/Tinea versicolor (infection with *Malassezia furfur*) – scaly pale brown patches on upper trunk that fail to tan on sun exposure, usually asymptomatic
- Management**
- Establish the correct diagnosis by skin scrapings, hair or nail clippings (for dermatophytes); skin swabs (for yeasts)
  - General measures: treat known precipitating factors (e.g. underlying immunosuppressive condition, moist environment)



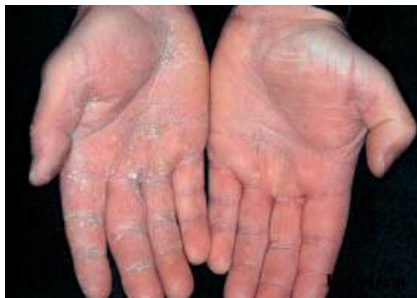- Topical antifungal agents (e.g. terbinafine cream)
- Oral antifungal agents (e.g. itraconazole) for severe, widespread, or nail infections
- Avoid the use of topical steroids – can lead to tinea incognito
- Correct predisposing factors where possible (e.g. moist environment, underlying immunosuppression)



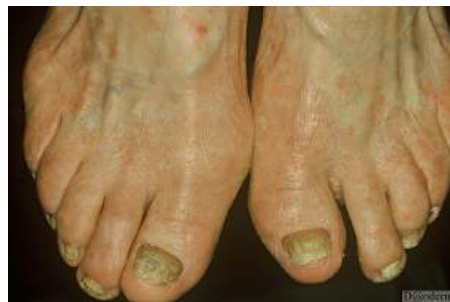**Tinea corporis**



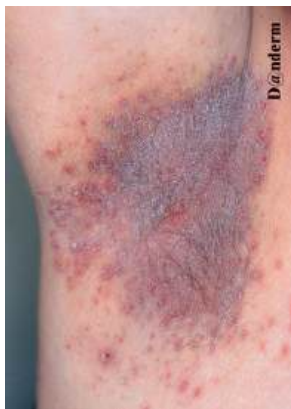**Tinea capitis**



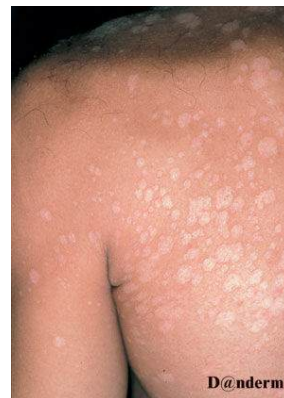**Tinea manuum (right hand)**



**Tinea pedis with associated tinea unguium**



**Candidiasis (right axilla)**



**Pityriasis versicolor**

## Skin Cancer

- Skin cancer is one of the most common cancers.
- In general, skin cancer can be divided into: non-melanoma (basal cell carcinoma and squamous cell carcinoma) and melanoma (malignant melanoma).
- Malignant melanoma is the most life-threatening type of skin cancer and is one of the few cancers affecting the younger population.
- Sun exposure is the single most preventable risk factor for skin cancer.

### Learning outcomes:

#### Ability to recognise:

- basal cell carcinoma
- squamous cell carcinoma
- malignant melanoma

## **Basal cell carcinoma**

### ***Description***

- A slow-growing, locally invasive malignant tumour of the epidermal keratinocytes normally in older individuals, only rarely metastasises

- Most common malignant skin tumour

### ***Causes***

- Risk factors include UV exposure, history of frequent or severe sunburn in childhood, skin type I (always burns, never tans), increasing age, male sex, immunosuppression, previous history of skin cancer, and genetic predisposition

### ***Presentation***

- Various morphological types including nodular (most common), superficial (plaque-like), cystic, morphoeic (sclerosing), keratotic and pigmented
- Nodular basal cell carcinoma is a small, skin-coloured papule or nodule with surface telangiectasia, and a pearly rolled edge; the lesion may have a necrotic or ulcerated centre (rodent ulcer)
- Most common over the head and neck

### ***Management***

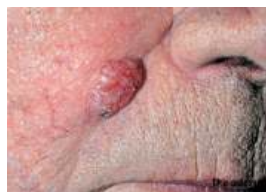- Surgical excision - treatment of choice as it allows histological examination of the tumour and margins
- Mohs micrographic surgery (i.e. excision of the lesion and tissue borders are progressively excised until specimens are microscopically free of tumour) - for high risk, recurrent tumours
- Radiotherapy - when surgery is not appropriate
- Other e.g. cryotherapy, curettage and cautery, topical photodynamic therapy, and topical treatment (e.g. imiquimod cream) - for small and low-risk lesions

### ***Complications***

- Local tissue invasion and destruction

### ***Prognosis***

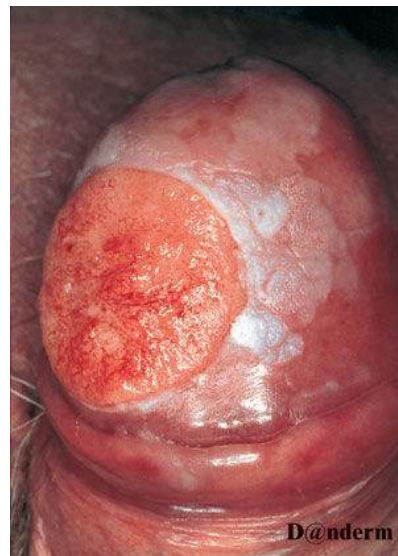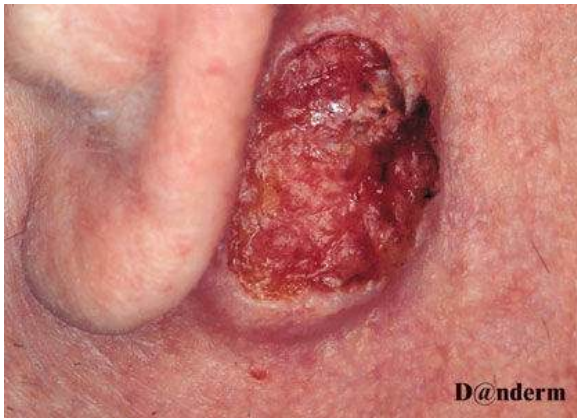- Depends on tumour size, site, type, growth pattern/histological subtype, failure of previous treatment/recurrence, and immunosuppression



**Basal cell carcinoma – nodular type**

**Squamous cell carcinoma**

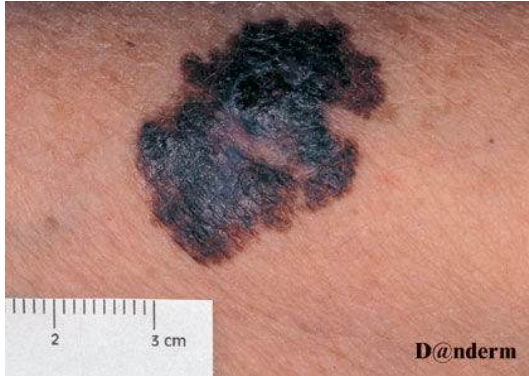- Description**
- A locally invasive malignant tumour of the epidermal keratinocytes or its appendages, which has the potential to metastasise
- Causes**
- Risk factors include excessive UV exposure, pre-malignant skin conditions (e.g. actinic keratoses), chronic inflammation (e.g. leg ulcers, wound scars), immunosuppression and genetic predisposition
- Presentation**
- Keratotic (e.g. scaly, crusty), ill-defined nodule which may ulcerate
- Management**
- Surgical excision - treatment of choice
  - Mohs micrographic surgery – may be necessary for ill-defined, large, recurrent tumours
  - Radiotherapy - for large, non-resectable tumours
- Prognosis**
- Depends on tumour size, site, histological pattern, depth of invasion, perineural involvement, and immunosuppression



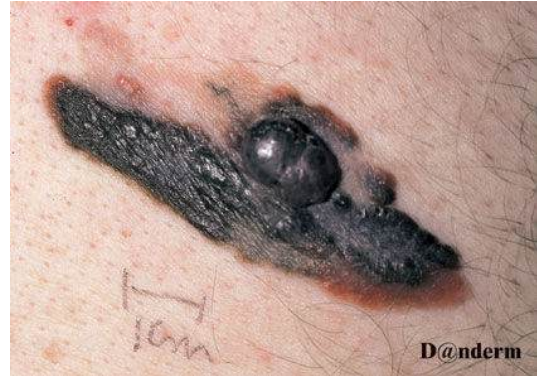Squamous cell carcinoma – adjacent to ear (left) and glans penis (right)

**Malignant melanoma**

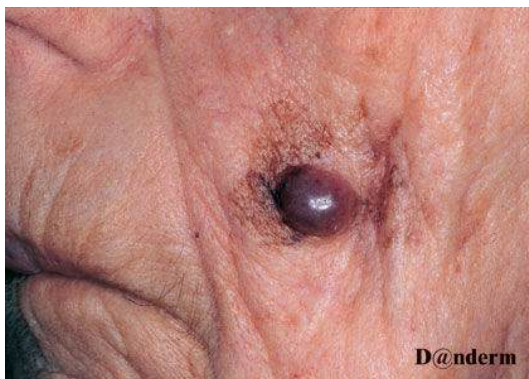- Description**
- An invasive malignant tumour of the epidermal melanocytes, which has the potential to metastasise
- Causes**
- Risk factors include excessive UV exposure, skin type I (always burns, never tans), history of multiple moles or atypical moles, and family history or previous history of melanoma
- Presentation**
- The '**ABCDE Symptoms**' rule (*\*major suspicious features*):
    - Asymmetrical shape\*
    - Border irregularity
    - Colour irregularity\*
    - Diameter > 6mm
    - Evolution of lesion (e.g. change in size and/or shape)\*
    - Symptoms** (e.g. bleeding, itching)
  - More common on the legs in women and trunk in men
- Types**
- Superficial spreading melanoma – common on the lower limbs, in young and middle-aged adults; related to intermittent high-intensity UV exposure
  - Nodular melanoma - common on the trunk, in young and middle-aged adults; related to intermittent high-intensity UV exposure
  - Lentigo maligna melanoma - common on the face, in elderly population; related to long-term cumulative UV exposure
  - Acral lentiginous melanoma - common on the palms, soles and nail beds, in elderly population; no clear relation with UV exposure
- Management**
- Surgical excision - definitive treatment
  - Radiotherapy may sometimes be useful
  - Chemotherapy for metastatic disease
- Prognosis**
- Recurrence of melanoma based on Breslow thickness (thickness of tumour): <0.76mm thick – low risk, 0.76mm-1.5mm thick – medium risk, >1.5mm thick – high risk
  - 5-year survival rates based on the **TNM** classification (primary Tumour, regional Nodes, Metastases): stage 1 (**T** <2mm thick, **N0**, **M0**) - 90%, stage 2 (**T** >2mm thick, **N0**, **M0**) – 80%, stage 3 (**N** ≥ 1, **M0**) – 40- 50%, and stage 4 (**M** ≥ 1) – 20-30%



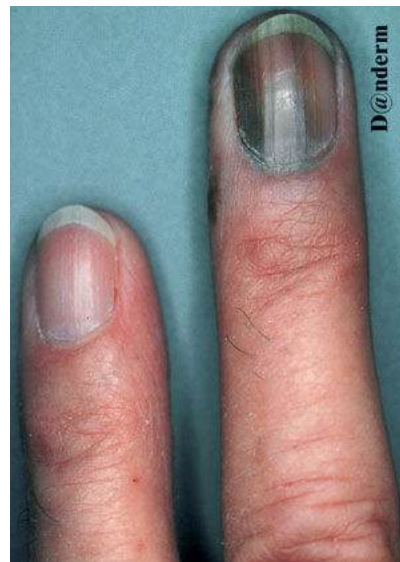**Superficial spreading melanoma**



**Nodular melanoma**



**Lentigo maligna melanoma**



**Acral lentiginous melanoma**

## Inflammatory Skin Conditions

- Eczema, acne and psoriasis are chronic inflammatory skin disorders that follow a relapsing and remitting course. There are many types of eczema but we shall just consider atopic eczema here.
- These skin disorders are not infectious.
- Management is aimed at achieving control and not providing a cure.
- Complications are mainly due to the psychological and social effects.
- Patient education is important in these chronic skin conditions and should concentrate on providing information about the nature of condition, aims of treatment and the available treatment options.

### Learning outcomes:

**Ability to describe the presentation, demonstrate assessment, formulate a differential diagnosis, instigate investigation and discuss how to provide continuing care of:**

- atopic eczema
- acne
- psoriasis

**Atopic eczema*****Description***

- Eczema (or dermatitis) is characterized by papules and vesicles on an erythematous base
- **Atopic eczema** is the most common type - usually develops by early childhood and resolves during teenage years (but may recur)

***Epidemiology***

- 20% prevalence in <12 years old in the UK

***Causes***

- Not fully understood, but a positive family history of atopy (i.e. eczema, asthma, allergic rhinitis) is often present
- A primary genetic defect in skin barrier function (loss of function variants of the protein filaggrin) appears to underlie atopic eczema
- Exacerbating factors such as infections, allergens (e.g. chemicals, food, dust, pet fur), sweating, heat and severe stress

***Presentation***

- Commonly present as itchy, erythematous dry scaly patches
- More common on the face and extensor aspects of limbs in infants, and the flexor aspects in children and adults
- Acute lesions are erythematous, vesicular and weepy (exudative)
- Chronic scratching/rubbing can lead to excoriations and lichenification
- May show nail pitting and ridging of the nails

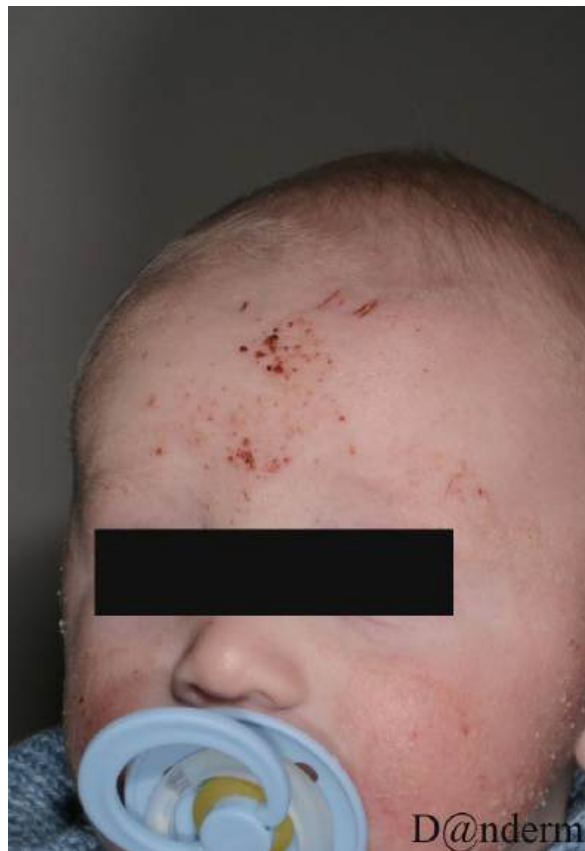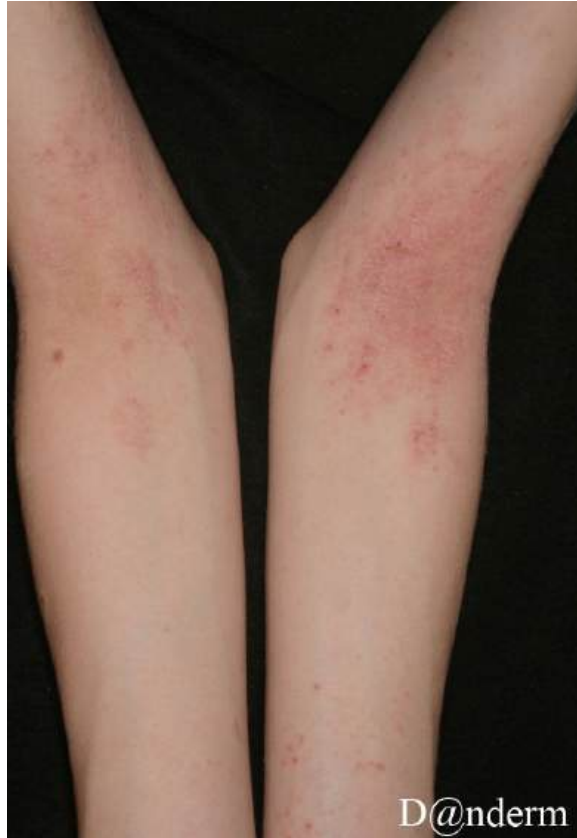***Management***

- General measures - avoid known exacerbating agents, frequent emollients +/- bandages and bath oil/soap substitute
- Topical therapies – topical steroids for flare-ups; topical immunomodulators (e.g. tacrolimus, pimecrolimus) can be used as steroid-sparing agents
- Oral therapies - antihistamines for symptomatic relief, antibiotics (e.g. flucloxacillin) for secondary bacterial infections, and antivirals (e.g. aciclovir) for secondary herpes infection
- Phototherapy and immunosuppressants (e.g. oral prednisolone, azathioprine, ciclosporin) for severe non-responsive cases

***Complications***

- Secondary bacterial infection (crusted weepy lesions)
- Secondary viral infection - molluscum contagiosum (pearly papules with central umbilication), viral warts and eczema herpeticum (*see page 34*)





**Atopic eczema**

Further reading: NICE guidelines. Atopic eczema in children, Dec 2007. <http://www.nice.org.uk/Guidance/CG57>

**Acne vulgaris****Description**

- An inflammatory disease of the pilosebaceous follicle

**Epidemiology**

- Over 80% of teenagers aged 13- 18 years

**Causes**

- Hormonal (androgen)
- Contributing factors include increased sebum production, abnormal follicular keratinization, bacterial colonization (*Propionibacterium acnes*) and inflammation

**Presentation**

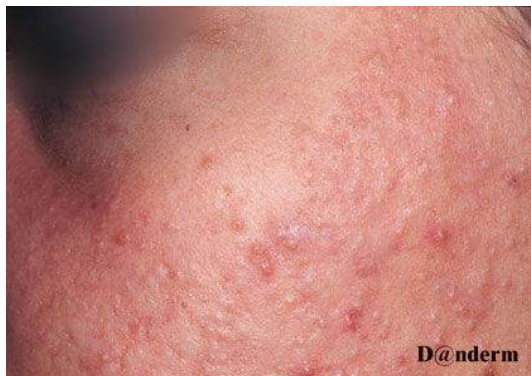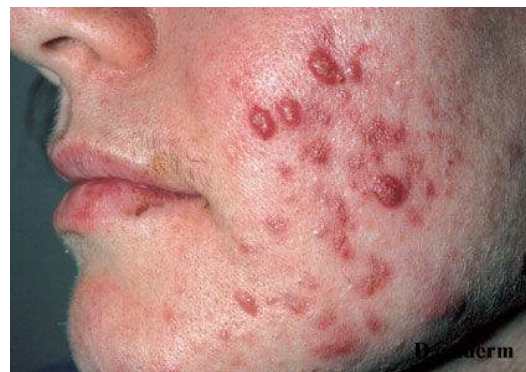- Non-inflammatory lesions (mild acne) - open and closed comedones (blackheads and whiteheads)
- Inflammatory lesions (moderate and severe acne) - papules, pustules, nodules, and cysts
- Commonly affects the face, chest and upper back

**Management**

- General measures - no specific food has been identified to cause acne, treatment needs to be continued for at least 6 weeks to produce effect
- Topical therapies (for mild acne) - benzoyl peroxide and topical antibiotics (antimicrobial properties), and topical retinoids (comedolytic and anti-inflammatory properties)
- Oral therapies (for moderate to severe acne) - oral antibiotics, and anti-androgens (in females)
- Oral retinoids (for severe acne)

**Complications**

- Post-inflammatory hyperpigmentation, scarring, deformity, psychological and social effects

**Comedones****Papules and nodules**

## Psoriasis

### **Description**

- A chronic inflammatory skin disease due to hyperproliferation of keratinocytes and inflammatory cell infiltration

### **Types**

- Chronic plaque psoriasis is the most common type
- Other types include guttate (raindrop lesions), seborrhoeic (naso-labial and retro-auricular), flexural (body folds), pustular (palmar-plantar), and erythrodermic (total body redness)

### **Epidemiology**

- Affects about 2% of the population in the UK

### **Causes**

- Complex interaction between genetic, immunological and environmental factors
- Precipitating factors include trauma (which may produce a Köebner phenomenon), infection (e.g. tonsillitis), drugs, stress, and alcohol

### **Presentation**

- Well-demarcated erythematous scaly plaques
- Lesions can sometimes be itchy, burning or painful
- Common on the extensor surfaces of the body and over scalp
- Auspitz sign (scratch and gentle removal of scales cause capillary bleeding)
- 50% have associated nail changes (e.g. pitting, onycholysis)
- 5-8% suffer from associated psoriatic arthropathy - symmetrical polyarthritis, asymmetrical oligoarthritides, lone distal interphalangeal disease, psoriatic spondylosis, and arthritis mutilans (flexion deformity of distal interphalangeal joints)

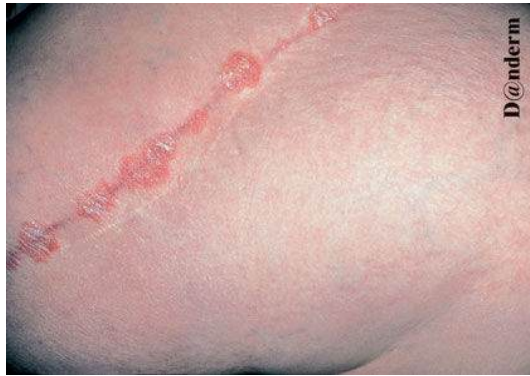### **Management**

- General measures - avoid known precipitating factors, emollients to reduce scales
- Topical therapies (for localised and mild psoriasis) - vitamin D analogues, topical corticosteroids, coal tar preparations, dithranol, topical retinoids, keratolytics and scalp preparations
- Phototherapy (for extensive disease) - phototherapy i.e. UVB and photochemotherapy i.e. psoralen+UVA
- Oral therapies (for extensive and severe psoriasis, or psoriasis with systemic involvement) - methotrexate, retinoids, ciclosporin, mycophenolate mofetil, fumaric acid esters,

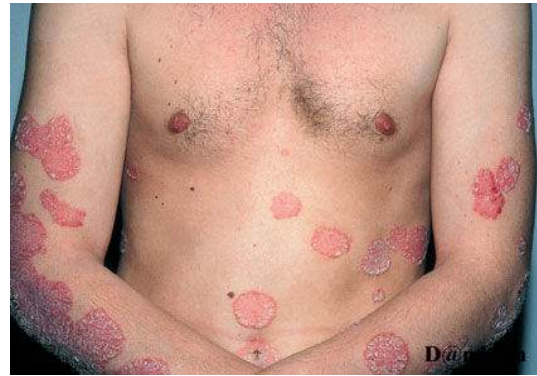and biological agents (e.g. infliximab, etanercept, efalizumab)

**Complications**

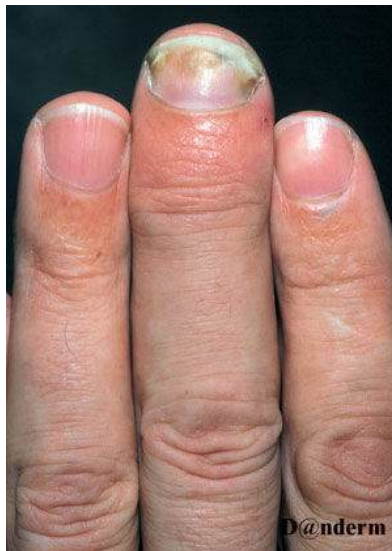- Erythroderma (see page 33), psychological and social effects



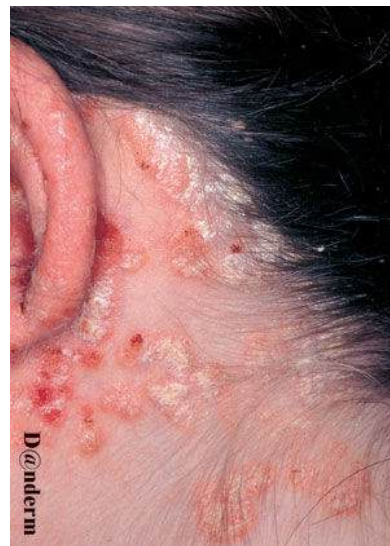**Köebner phenomenon**



**Plaque psoriasis**



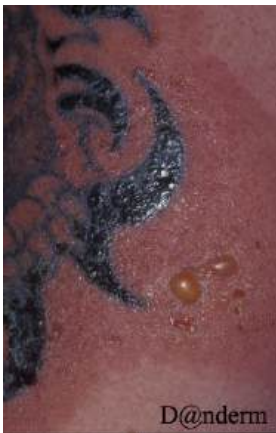**Nail changes and arthropathy**



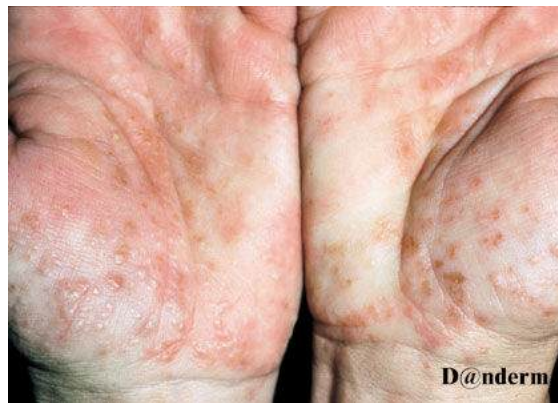**Scalp involvement**

## Blistering Disorders

- In general, blistering skin disorders can be divided into: immunobullous diseases (e.g. bullous pemphigoid, pemphigus vulgaris), blistering skin infections (e.g. herpes simplex) and other (e.g. porphyria cutanea tarda).
- The fragility of blisters depends on the level of split within the skin – an intra-epidermal split (a split within the epidermis) causes blisters to rupture easily; whereas a sub-epidermal split (a split between the epidermis and dermis) causes blisters to be less fragile.
- The common causes of blisters are impetigo (*see below*), insect bites, herpes simplex infection (*see page 34*), herpes zoster infection (*see page 36*), acute contact dermatitis, pompholyx (vesicular eczema of the hands and feet, *see below*) and burns.
- Bullous pemphigoid (*see page 53*) and pemphigus vulgaris (*see page 54*) are uncommon conditions due to immune reaction within the skin.



**Bullous impetigo in a new tattoo**



**Pompholyx**

### Learning outcomes:

1. Ability to recognise common causes of blisters
2. Ability to recognise:
  - Bullous pemphigoid
  - Pemphigus vulgaris

**Bullous pemphigoid*****Description***

- A blistering skin disorder which usually affects the elderly

***Cause***

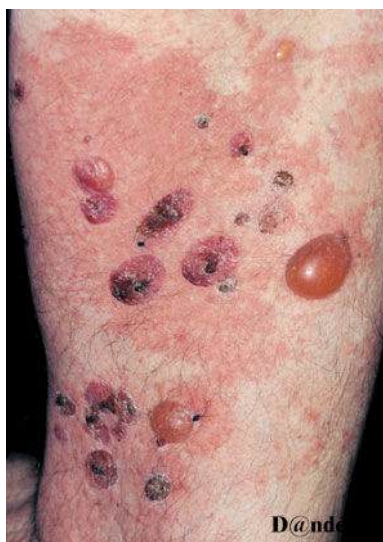- Autoantibodies against antigens between the epidermis and dermis causing a sub-epidermal split in the skin

***Presentation***

- Tense, fluid-filled blisters on an erythematous base
- Lesions are often itchy
- May be preceded by a non-specific itchy rash
- Usually affects the trunk and limbs (mucosal involvement less common)

***Management***

- General measures – wound dressings where required, monitor for signs of infection
- Topical therapies for localised disease - topical steroids
- Oral therapies for widespread disease – oral steroids, combination of oral tetracycline and nicotinamide, immunosuppressive agents (e.g. azathioprine, mycophenolate mofetil, methotrexate, and other)

**Bullous pemphigoid**

## Pemphigus vulgaris

### **Description**

- A blistering skin disorder which usually affects the middle-aged

### **Cause**

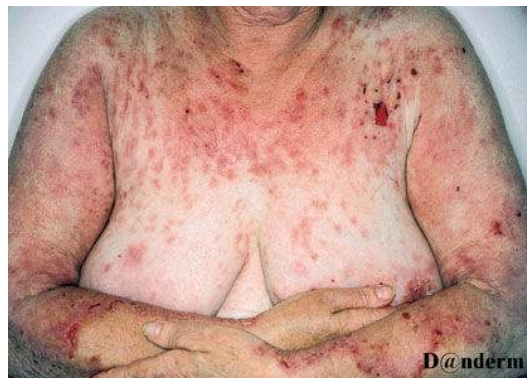- Autoantibodies against antigens within the epidermis causing an intra-epidermal split in the skin

### **Presentation**

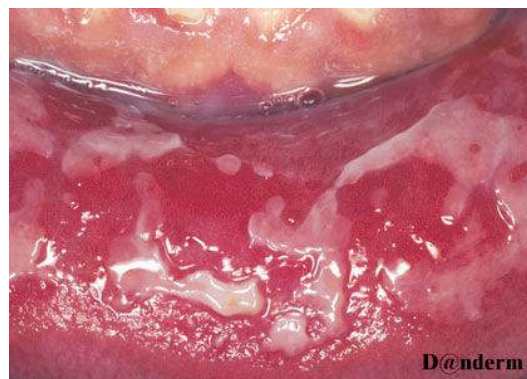- Flaccid, easily ruptured blisters forming erosions and crusts
- Lesions are often painful
- Usually affects the mucosal areas (can precede skin involvement)

### **Management**

- General measures – wound dressings where required, monitor for signs of infection, good oral care (if oral mucosa is involved)
- Oral therapies – high-dose oral steroids, immunosuppressive agents (e.g. methotrexate, azathioprine, cyclophosphamide, mycophenolate mofetil, and other)



**Pemphigus vulgaris**



**Pemphigus vulgaris affecting the oral mucosa**

## Common Important Problems

- There are several commonly-encountered skin problems in clinical practice. Below are some of the important differential diagnoses for each of these presentations.
- Clinical exposure is the key to achieve competence in diagnosing, investigating and managing these skin problems.

### Learning objectives:

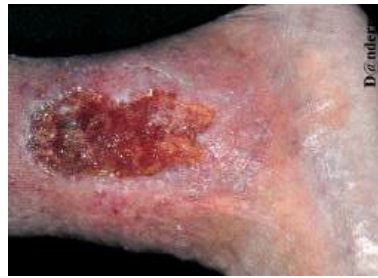**Ability to formulate a differential diagnosis, describe the investigation and discuss the management in patients with:**

- chronic leg ulcers
- itchy eruption
- a changing pigmented lesion
- purpuric eruption
- a red swollen leg

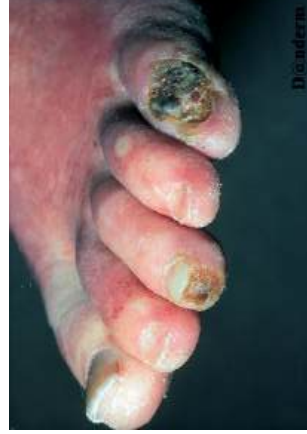

### Chronic leg ulcers

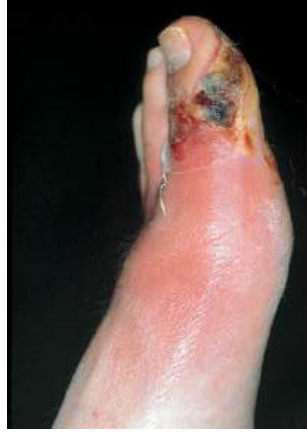- Leg ulcers are classified according to aetiology. In general, there are three main types: venous, arterial and neuropathic ulcers. Other causes include vasculitic ulcers (purpuric, punched out lesions), infected ulcers (purulent discharge, may have systemic signs) and malignancy (e.g. squamous cell carcinoma in long-standing non-healing ulcers).
- In clinical practice, there can be mixture of arterial, venous and/or neuropathic components in an ulcer.



Venous ulcer



Arterial ulcer



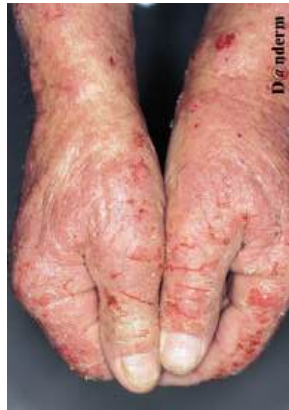Neuropathic ulcer

Chronic leg ulcers

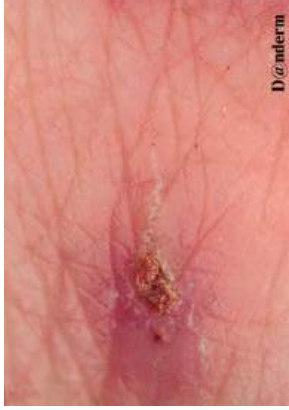	Venous ulcer	Arterial ulcer	Neuropathic ulcer
<b>History</b>	<ul style="list-style-type: none"> <li>- Often painful, worse on standing</li> <li>- History of venous disease e.g. varicose veins, deep vein thrombosis</li> </ul>	<ul style="list-style-type: none"> <li>- Painful especially at night, worse when legs are elevated</li> <li>- History of arterial disease e.g. atherosclerosis</li> </ul>	<ul style="list-style-type: none"> <li>- Often painless</li> <li>- Abnormal sensation</li> <li>- History of diabetes or neurological disease</li> </ul>
<b>Common sites</b>	<ul style="list-style-type: none"> <li>- Malleolar area (more common over medial than lateral malleolus)</li> </ul>	<ul style="list-style-type: none"> <li>- Pressure and trauma sites e.g. pretibial, supramalleolar (usually lateral), and at distal points e.g. toes</li> </ul>	<ul style="list-style-type: none"> <li>- Pressure sites e.g. soles, heel, toes, metatarsal heads</li> </ul>
<b>Lesion</b>	<ul style="list-style-type: none"> <li>- Large, shallow irregular ulcer</li> <li>- Exudative and granulating base</li> </ul>	<ul style="list-style-type: none"> <li>- Small, sharply defined deep ulcer</li> <li>- Necrotic base</li> </ul>	<ul style="list-style-type: none"> <li>- Variable size and depth</li> <li>- Granulating base</li> <li>- May be surrounded by or underneath a hyperkeratotic lesion (e.g. callus)</li> </ul>
<b>Associated features</b>	<ul style="list-style-type: none"> <li>- Warm skin</li> <li>- Normal peripheral pulses</li> <li>- Leg oedema, haemosiderin and melanin deposition (brown pigment), lipodermatosclerosis, and atrophic blanche (white scarring with dilated capillaries)</li> </ul>	<ul style="list-style-type: none"> <li>- Cold skin</li> <li>- Weak or absent peripheral pulses</li> <li>- Shiny pale skin</li> <li>- Loss of hair</li> </ul>	<ul style="list-style-type: none"> <li>- Warm skin</li> <li>- Normal peripheral pulses*</li> <li>*cold, weak or absent pulses if it is a neuroischaemic ulcer</li> <li>- Peripheral neuropathy</li> </ul>
<b>Possible investigations</b>	<ul style="list-style-type: none"> <li>- Normal ankle/brachial pressure index (i.e. ABPI 0.8-1)</li> </ul>	<ul style="list-style-type: none"> <li>- ABPI &lt; 0.8 - presence of arterial insufficiency</li> <li>- Doppler studies and angiography</li> </ul>	<ul style="list-style-type: none"> <li>- ABPI &lt; 0.8 implies a neuroischaemic ulcer</li> <li>- X-ray to exclude osteomyelitis</li> </ul>
<b>Management</b>	<ul style="list-style-type: none"> <li>- Compression bandaging (after excluding arterial insufficiency)</li> </ul>	<ul style="list-style-type: none"> <li>- Vascular reconstruction</li> <li>- Compression bandaging is contraindicated</li> </ul>	<ul style="list-style-type: none"> <li>- Wound debridement</li> <li>- Regular repositioning, appropriate footwear and good nutrition</li> </ul>

### Itchy eruption

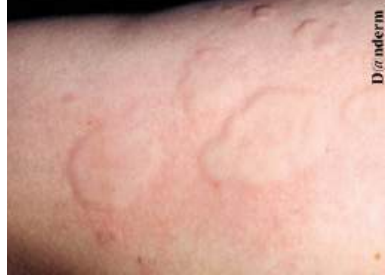- An itchy (pruritic) eruption can be caused by an inflammatory condition (e.g. eczema), infection (e.g. varicella), infestation (e.g. scabies), allergic reaction (e.g. some cases of urticaria) or an unknown cause, possibly autoimmune (e.g. lichen planus).



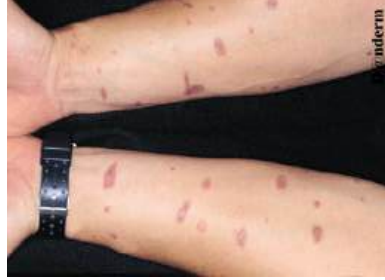Chronic fissured hand eczema



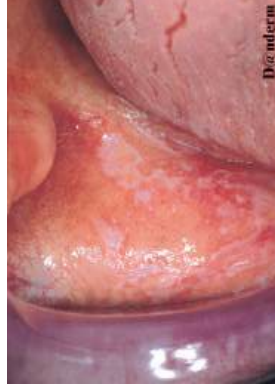
Scabies



Urticaria



Lichen planus



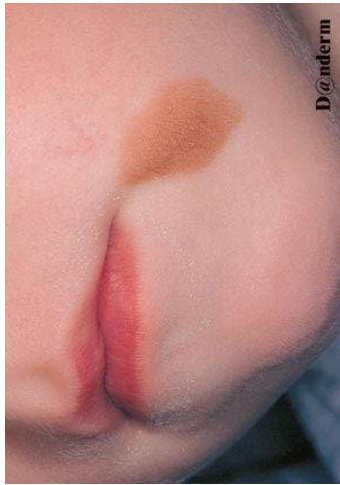Wickham's striae

**Itchy eruption**

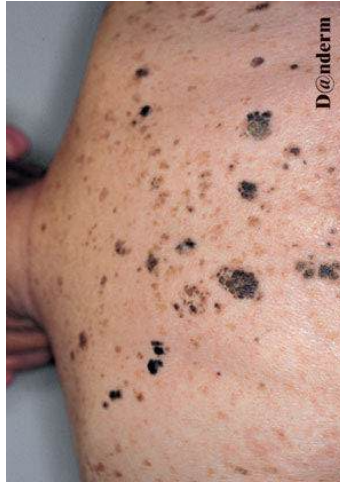	<b>Eczema</b>	<b>Scabies</b>	<b>Urticaria</b>	<b>Lichen planus</b>
<b>History</b>	<ul style="list-style-type: none"> <li>- Personal or family history of atopy</li> <li>- Exacerbating factors (e.g. allergens, irritants)</li> </ul>	<ul style="list-style-type: none"> <li>- May have history of contact with symptomatic individuals</li> <li>- Pruritus worse at night</li> </ul>	<ul style="list-style-type: none"> <li>- Precipitating factors (e.g. food, contact, drugs)</li> </ul>	<ul style="list-style-type: none"> <li>- Family history in 10% of cases</li> <li>- May be drug-induced</li> </ul>
<b>Common sites</b>	<ul style="list-style-type: none"> <li>- Variable (e.g. flexor aspects in children and adults with atopic eczema)</li> </ul>	<ul style="list-style-type: none"> <li>- Sides of fingers, finger webs, wrists, elbows, ankles, feet, nipples and genitals</li> </ul>	<ul style="list-style-type: none"> <li>- No specific tendency</li> </ul>	<ul style="list-style-type: none"> <li>- Forearms, wrists, and legs</li> <li>- Always examine the oral mucosa</li> </ul>
<b>Lesion</b>	<ul style="list-style-type: none"> <li>- Dry, erythematous patches</li> <li>- Acute eczema is erythematous, vesicular and exudative</li> </ul>	<ul style="list-style-type: none"> <li>- Linear burrows (may be tortuous) or rubbery nodules</li> </ul>	<ul style="list-style-type: none"> <li>- Pink wheals (transient)</li> <li>- May be round, annular, or polycyclic</li> </ul>	<ul style="list-style-type: none"> <li>- Violaceous (ilic) flat-topped papules</li> <li>- Symmetrical distribution</li> </ul>
<b>Associated features</b>	<ul style="list-style-type: none"> <li>- Secondary bacterial or viral infections</li> </ul>	<ul style="list-style-type: none"> <li>- Secondary eczema and impetigo</li> </ul>	<ul style="list-style-type: none"> <li>- May be associated with angioedema or anaphylaxis</li> </ul>	<ul style="list-style-type: none"> <li>- Nail changes and hair loss</li> <li>- Lacy white streaks on the oral mucosa and skin lesions (Wickham's striae)</li> </ul>
<b>Possible investigations</b>	<ul style="list-style-type: none"> <li>- Patch testing</li> <li>- Serum IgE levels</li> <li>- Skin swab</li> </ul>	<ul style="list-style-type: none"> <li>- Skin scrape, extraction of mite and view under microscope</li> </ul>	<ul style="list-style-type: none"> <li>- Bloods and urinalysis to exclude a systemic cause</li> </ul>	<ul style="list-style-type: none"> <li>- Skin biopsy</li> </ul>
<b>Management</b>	<ul style="list-style-type: none"> <li>- Emollients</li> <li>- Corticosteroids</li> <li>- Immunomodulators</li> <li>- Antihistamines</li> </ul>	<ul style="list-style-type: none"> <li>- Scabicide (e.g. permethrin or malathion)</li> <li>- Antihistamines</li> </ul>	<ul style="list-style-type: none"> <li>- Antihistamines</li> <li>- Corticosteroids</li> </ul>	<ul style="list-style-type: none"> <li>- Corticosteroids</li> <li>- Antihistamines</li> </ul>

**A changing pigmented lesion**

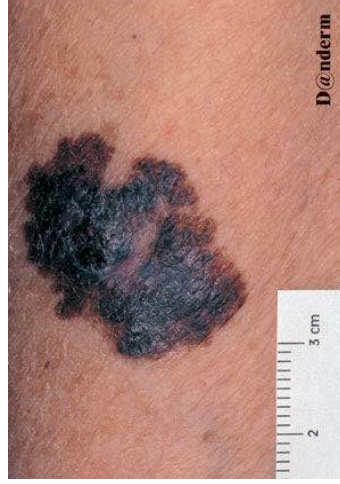- A changing pigmented lesion can be benign (e.g. melanocytic naevi, seborrhoeic wart) or malignant (e.g. malignant melanoma).



**Congenital naevus**



**Seborrhoeic keratosis**



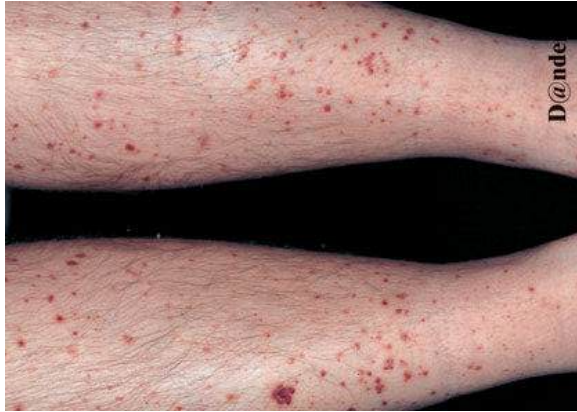**Malignant melanoma**

**A changing pigmented lesion**

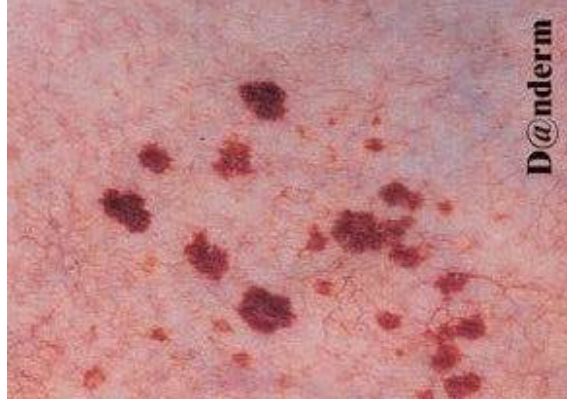	Benign		Malignant
	Melanocytic naevi	Seborrheic wart	Malignant melanoma
<b>History</b>	<ul style="list-style-type: none"> <li>- Not usually present at birth but develop during infancy, childhood or adolescence</li> <li>- Asymptomatic</li> </ul>	<ul style="list-style-type: none"> <li>- Tend to arise in the middle-aged or elderly</li> <li>- Often multiple and asymptomatic</li> </ul>	<ul style="list-style-type: none"> <li>- Tend to occur in adults or the middle-aged</li> <li>- History of evolution of lesion</li> <li>- May be symptomatic (e.g. itchy, bleeding)</li> <li>- Presence of risk factors</li> </ul>
<b>Common sites</b>	<ul style="list-style-type: none"> <li>- Variable</li> </ul>	<ul style="list-style-type: none"> <li>- Face and trunk</li> </ul>	<ul style="list-style-type: none"> <li>- More common on the legs in women and trunk in men</li> </ul>
<b>Lesion</b>	<ul style="list-style-type: none"> <li>- Congenital naevi may be large, pigmented, protuberant and hairy</li> <li>- Junctional naevi are small, flat and dark</li> <li>- Intradermal naevi are usually dome-shape papules or nodules</li> <li>- Compound naevi are usually raised, warty, hyperkeratotic, and/or hairy</li> </ul>	<ul style="list-style-type: none"> <li>- Warty greasy papules or nodules</li> <li>- 'Stuck on' appearance, with well-defined edges</li> </ul>	<ul style="list-style-type: none"> <li>- Features of <b>ABCDE</b>:  <b>A</b>symmetrical shape  <b>B</b>order irregularity  <b>C</b>olour irregularity  <b>D</b>iameter &gt; 6mm  <b>E</b>volution of lesion</li> </ul>
<b>Management</b>	<ul style="list-style-type: none"> <li>- Rarely needed</li> </ul>	<ul style="list-style-type: none"> <li>- Rarely needed</li> </ul>	<ul style="list-style-type: none"> <li>- Excision</li> </ul>

### Purpuric eruption

- A purpuric eruption can be thrombocytopenic (e.g. meningococcal septicaemia, disseminated intravascular coagulation, idiopathic thrombocytopenic purpura) or non-thrombocytopenic e.g. trauma, drugs (e.g. steroids), aged skin, vasculitis (e.g. Henoch-Schönlein purpura).
- Platelet counts and a clotting screen are important to exclude coagulation disorders.



**Henoch-Schönlein purpura**



**Senile purpura**

Purpuric eruption

	<b>Meningococcal septicaemia</b>	<b>Disseminated intravascular coagulation</b>	<b>Vasculitis</b>	<b>Senile purpura</b>
<b>History</b>	<ul style="list-style-type: none"> <li>- Acute onset</li> <li>- Symptoms of meningitis and septicaemia</li> <li>- Extremities</li> </ul>	<ul style="list-style-type: none"> <li>- History of trauma, malignancy, sepsis, obstetric complications, transfusions, or liver failure</li> <li>- Spontaneous bleeding from ear, nose and throat, gastrointestinal tract, respiratory tract or wound site</li> <li>- Petechiae, ecchymoses, haemorrhagic bullae and/or tissue necrosis</li> <li>- Systemically unwell</li> </ul>	<ul style="list-style-type: none"> <li>- Painful lesions</li> <li>- Dependent areas (e.g. legs, buttocks, flanks)</li> <li>- Palpable purpura (often painful)</li> <li>- Systemically unwell</li> </ul>	<ul style="list-style-type: none"> <li>- Arise in the elderly population with sun-damaged skin</li> <li>- Extensor surfaces of hands and forearms</li> <li>- Such skin is easily traumatised</li> <li>- Non-palpable purpura</li> <li>- Surrounding skin is atrophic and thin</li> <li>- Systemically well</li> </ul>
<b>Common sites</b>				
<b>Lesion</b>	<ul style="list-style-type: none"> <li>- Petechiae, ecchymoses, haemorrhagic bullae and/or tissue necrosis</li> <li>- Systemically unwell</li> </ul>	<ul style="list-style-type: none"> <li>- Bloods (a clotting screen is important)</li> <li>- Treat the underlying cause</li> <li>- Transfuse for coagulation deficiencies</li> <li>- Anticoagulants for thrombosis</li> </ul>	<ul style="list-style-type: none"> <li>- Bloods and urinalysis</li> <li>- Skin biopsy</li> <li>- Treat the underlying cause</li> <li>- Steroids and immunosuppressants if there is systemic involvement</li> </ul>	<ul style="list-style-type: none"> <li>- No investigation is needed</li> <li>- No treatment is needed</li> </ul>
<b>Associated features</b>				
<b>Possible investigations</b>	<ul style="list-style-type: none"> <li>- Bloods</li> <li>- Lumbar puncture</li> </ul>			
<b>Management</b>	<ul style="list-style-type: none"> <li>- Antibiotics</li> </ul>			



**A red swollen leg**

- The main differential diagnoses for a red swollen leg are cellulitis, erysipelas, venous thrombosis and chronic venous insufficiency.

	<b>Cellulitis/Erysipelas</b>	<b>Venous thrombosis</b>	<b>Chronic venous insufficiency</b>
<b>History</b>	<ul style="list-style-type: none"> <li>- Painful spreading rash</li> <li>- History of abrasion or ulcer</li> </ul>	<ul style="list-style-type: none"> <li>- Pain with swelling and redness</li> <li>- History of prolonged bed rest, long haul flights or clotting tendency</li> </ul>	<ul style="list-style-type: none"> <li>- Heaviness or aching of leg, which is worse on standing and relieved by walking</li> <li>- History of venous thrombosis</li> </ul>
<b>Lesion</b>	<ul style="list-style-type: none"> <li>- Erysipelas (well-defined edge)</li> <li>- Cellulitis (diffuse edge)</li> </ul>	<ul style="list-style-type: none"> <li>- Complete venous occlusion may lead to cyanotic discoloration</li> </ul>	<ul style="list-style-type: none"> <li>- Discoloured (blue-purple)</li> <li>- Oedema (improved in the morning)</li> <li>- Venous congestion and varicose veins</li> </ul>
<b>Associated features</b>	<ul style="list-style-type: none"> <li>- Systemically unwell with fever and malaise</li> <li>- May have lymphangitis</li> </ul>	<ul style="list-style-type: none"> <li>- Usually systemically well</li> <li>- May present with pulmonary embolism</li> </ul>	<ul style="list-style-type: none"> <li>- Lipodermatosclerosis (erythematous induration, creating 'champagne bottle' appearance)</li> <li>- Stasis dermatitis (eczema with inflammatory papules, scaly and crusted erosions)</li> <li>- Venous ulcer</li> </ul>
<b>Possible investigations</b>	<ul style="list-style-type: none"> <li>- Anti-streptococcal O titre (ASOT)</li> <li>- Skin swab</li> </ul>	<ul style="list-style-type: none"> <li>- D-dimer</li> <li>- Doppler ultrasound and/or venography</li> </ul>	<ul style="list-style-type: none"> <li>- Doppler ultrasound and/or venography</li> </ul>
<b>Management</b>	<ul style="list-style-type: none"> <li>- Antibiotics</li> </ul>	<ul style="list-style-type: none"> <li>- Anticoagulants</li> </ul>	<ul style="list-style-type: none"> <li>- Leg elevation and compression stockings</li> <li>- Sclerotherapy or surgery for varicose veins</li> </ul>

## Management

- Treatment modalities for skin disease can be broadly categorised into medical therapy (topical and systemic treatments) and physical therapy (e.g. cryotherapy, phototherapy, photodynamic therapy, lasers and surgery).
- Topical treatments directly deliver treatment to the affected areas and this reduces systemic side effects. It is suitable for localised and less severe skin conditions. They consist of active constituents which are transported into the skin by a base (also known as a 'vehicle'). Examples of active ingredients are steroids, tar, immunomodulators, retinoids, and antibiotics. The common forms of base are lotion (liquid), cream (oil in water), gel (organic polymers in liquid, transparent), ointment (oil with little or no water) and paste (powder in ointment).
- Systemic therapy is used for extensive and more serious skin conditions, if the treatment is ineffective topically or if there is systemic involvement. However, they have the disadvantage of causing systemic side effects.

### Learning objectives:

#### Ability to describe the principles of use of the following drugs:

- emollients
- topical/oral corticosteroids
- oral aciclovir
- oral antihistamines
- topical/oral antibiotics
- topical antiseptics

**Emollients**

- Examples** ● Aqueous cream, emulsifying ointment, liquid paraffin and white soft paraffin in equal parts (50:50)
- Quantity** ● 500 grams per tub
- Indications** ● To rehydrate skin and re-establish the surface lipid layer  
● Useful for dry, scaling conditions and as soap substitutes
- Side effects** ● Reactions may be irritant or allergic (e.g. due to preservatives or perfumes in creams)

**Topical/Oral corticosteroids**

- Examples** ● Topical steroids: classified as mildly potent (e.g. hydrocortisone), moderately potent (e.g. clobetasone butyrate (*Eumovate*)), potent (e.g. betamethasone valerate (*Betnovate*)), and very potent (e.g. clobetasol propionate (*Dermovate*))  
● Oral steroids: prednisolone
- Quantity** ● Usually 30 grams per tube (enough to cover the whole body once)
- Indications** ● Anti-inflammatory and anti-proliferative effects  
● Useful for allergic and immune reactions, inflammatory skin conditions, blistering disorders, connective tissue diseases, and vasculitis
- Side effects** ● Local side effects (from topical corticosteroids): skin atrophy (thinning), telangiectasia, striae, may mask, cause or exacerbate skin infections, acne, or perioral dermatitis, and allergic contact dermatitis.  
● Systemic side effects (from oral corticosteroids): Cushing's syndrome, immunosuppression, hypertension, diabetes, osteoporosis, cataract, and steroid-induced psychosis

**Oral aciclovir**

- Examples** ● Aciclovir
- Indications** ● Viral infections due to herpes simplex and herpes zoster virus
- Side effects** ● Gastrointestinal upsets, raised liver enzymes, reversible neurological reactions, and haematological disorders

**Oral antihistamines**

- Examples** ● Classified into nonsedative (e.g. cetirizine, loratadine) and sedative

antihistamines (e.g. chlorpheniramine, hydroxyzine)

- Indications**
- Block histamine receptors producing an anti-pruritic effect
  - Useful for type-1 hypersensitivity reactions and eczema (especially sedative antihistamines for children)
- Side effects**
- Sedative antihistamines can cause sedation and anticholinergic effects (e.g. dry mouth, blurred vision, urinary retention, and constipation)

### Topical/Oral antibiotics

- Examples**
- Topical antibiotics: fusidic acid, mupirocin (*Bactroban*), neomycin
  - Oral antibiotics: penicillins, cephalosporins, gentamicin, macrolides, nitrofurantoin, quinolones, tetracyclines, vancomycin, metronidazole, trimethoprim
- Indications**
- Useful for bacterial skin infections, and some are used for acne
- Side effects**
- Local side effects (from topical antibiotics): local skin irritation/allergy
  - Systemic side effects (from oral antibiotics): gastrointestinal upset, rashes, anaphylaxis, vaginal candidiasis, antibiotic-associated infection such as *Clostridium difficile*, and antibiotic resistance (rapidly appears to fusidic acid)

### Topical antiseptics

- Examples**
- Chlorhexidine, cetrimide, povidone-iodine
- Indications**
- Treatment and prevention of skin infection
- Side effects**
- Local side effects: local skin irritation/allergy

### Oral retinoids

- Examples**
- Isotretinoin, Acitretin
- Indications**
- Acne, psoriasis, and disorders of keratinisation
- Side effects**
- Mucocutaneous reactions such as dry skin, dry lips and dry eyes, disordered liver function, hypercholesterolaemia, hypertriglyceridaemia, myalgia, arthralgia and depression
  - Teratogenicity: effective contraception must be practised one month before, during and at least one month after isotretinoin, but for two years after Acitretin (consult current BNF for further details)

## Practical Skills

- There are four main aspects to focus on in clinical practice:
  - i) Patient education, particularly on the nature of disease, treatment and ways to achieve full compliance and effectiveness, and prevention strategies
  - ii) Effective written communication to general practitioner so that patients care can be continued appropriately
  - iii) Good prescribing skills
  - iv) Good clinical examination and appropriate investigations to facilitate accurate diagnosis
- This section highlights several general points on the important clinical skills in dermatology.

### Learning objectives:

#### 1. Ability to perform the following tasks:

- explain how to use an emollient or a topical corticosteroid
- make a referral
- write a discharge letter
- write a prescription for emollient
- take a skin swab
- take a skin scrape
- measure the ankle-brachial pressure index and interpret the result

#### 2. Describe the principles of prevention in:

- pressure sores
- sun damage and skin cancer

**Patient education****How to use emollients**

- Apply liberally and regularly

**How to use topical corticosteroids**

- Apply thinly and only for short-term use (often 1 or 2 weeks only)
- Only use 1% hydrocortisone or equivalent strength on the face
- Fingertip unit (advised on packaging) – strip of cream the length of a fingertip

**Preventing pressure sores**

- Pressure sores are due to ischaemia resulting from localised damage to the skin caused by sustained pressure, friction and moisture, particularly over bony prominences.
- Preventative measures involve frequent repositioning, nutritional support, and use of pressure relieving devices e.g. special beds

**Preventing sun damage and skin cancer**

- Excessive exposure to UV radiation is the most significant and preventable risk factor for the development of skin cancer (Table 14)
- Skin types I and II are at higher risk of developing skin cancer with excessive sun exposure than other skin types (Table 15)

**Table 14. SMART ways to avoid excessive sun exposure**

---

**S**pend time in the shade between 11am-3pm

**M**ake sure you never burn

**A**im to cover up with a t-shirt, wide-brimmed hat and sunglasses

**R**emember to take extra care with children

**T**hen use Sun Protection Factor (SPF) 30+ sunscreen

---

**Table 15. Skin types**

Skin types	Description
I	Always burns, never tans
II	Always burns, sometimes tans
III	Sometimes burns, always tans
IV	Never burns, always tans

**Written communication****Writing a referral letter***Important points to include:*

- Reason(s) for referral, current presentation, and impact of disease
- Patient's medical and social background
- Current and previous treatment, length of treatment, and response to treatment

**Writing a discharge letter***Important points to include:*

- Reason(s) for admission and current presentation
- Hospital course
- Investigation results
- Diagnostic impression
- Management plan (including treatment and follow-up appointment)
- Content of patient education given

**Prescribing skills****Writing a prescription***General tips:*

- Include drug name, dose, frequency and an intended duration/review date
- 30 grams of cream/ointment covers the whole adult body area
- 1 fingertip unit covers the area of two palms and equals ½ gram

**Prescribing emollients***General tips*

- Emollients come in 500 gram tubs
- In general, ointment-based emollients are useful for dry, scaling skin whereas creams and lotions are for red, inflamed and weeping lesions

**Prescribing topical corticosteroids***General tips*

- Prescribe the weakest potency corticosteroid that is effective
- Use only for short term
- Need to specify the base i.e. cream, lotion or ointment

**Clinical examination and investigations****Taking a skin swab**

- Skin swabs can be taken from vesicles, pustules, erosions, ulcers and mucosal surfaces for microbial culture.
- Surface swabs are generally not encouraged.

**Taking a skin scrape**

- Skin scrapes are taken from scaly lesions by gentle use of a scalpel in suspected fungal infection (to show evidence of fungal hyphae and/or spores) and from burrows in scabies (*see page 59*).

**Measuring ankle-brachial pressure index (ABPI)**

- ABPI is used to identify the presence and severity of peripheral arterial insufficiency, which is important in the management of leg ulcers.
- Measure the cuff pressure of dorsalis pedis or posterior tibial artery using a Doppler and compare it to the pressure of brachial artery.
- The ABPI is measured by calculating the ratio of highest pressure obtained from the ankle to highest brachial pressure of the two arms, and is normally >0.8.
- Inappropriately high reading will be obtained in calcified vessels (often in diabetics).



## Acknowledgements

We wish to acknowledge the following contributors:

- Dr Mark Goodfield, former President (2008-2010) of the British Association of Dermatologists, for writing the Foreword.
- Dr Niels K. Veien for allowing us to use his photographs. All illustrations in this handbook were obtained from "D@nderm" with his permission.
- Dr Susan Burge, retired Consultant Dermatologist, Oxford Radcliffe Hospitals NHS Trust, Professor Peter Friedmann, Emeritus Professor of Dermatology, Southampton General Hospital, and Professor Lesley Rhodes, Professor of Experimental Dermatology, University of Manchester for reviewing and contributing valuable suggestions.
- Mr Kian Tjon Tan, Specialty Registrar in Plastic Surgery, Royal Preston NHS Foundation Trust for contributing the chapter Background Knowledge.
- Dr Yi Ning Chiang, Specialty Doctor in Dermatology, Southport and Ormskirk Hospital NHS Trust for contributing the chapter Common Important Problems.





