

IntechOpen

# Dental Anatomy

*Edited by Bağdagül Helvacioğlu Kivanç*





---

# DENTAL ANATOMY

---

Edited by **Bağdagül Helvacioğlu Kivanç**

## Dental Anatomy

<http://dx.doi.org/10.5772/65542>

Edited by Bağdagül Helvacioğlu Kivanç

### Contributors

Mohammed E Grawish, Nicola Mobilio, Santo Catapano, Letizia Perillo, Abdolreza Jamilian, Fabrizia D'Apuzzo, Alireza Darnahal, Ludovica Nucci, Alex Vargas, Paula Astorga, Tomas Rioseco, Vanessa Paredes, Ignacio Faus, Carlos Bellot-Arcís, José-Luis Gandia, Ana Mora, Fabio Sampaio, Isabela Albuquerque Passos Farias, Dayane Franco Barros Manguiera Leite, Marcel Alves Avelino De Paiva, Antonio De Pádua Cavalcante Da Costa, Ticiane Sidorenko De Oliveira Capote, Suellen Tayenne Pedroso Pinto, Marcelo Brito Conte, Juliana Álvares Duarte Bonini Campos, Marcela De Almeida Gonçalves, Bruno Luis Graciliano Silva, Bağdagül Helvacioğlu Kivanç

### © The Editor(s) and the Author(s) 2018

The rights of the editor(s) and the author(s) have been asserted in accordance with the Copyright, Designs and Patents Act 1988. All rights to the book as a whole are reserved by INTECHOPEN LIMITED. The book as a whole (compilation) cannot be reproduced, distributed or used for commercial or non-commercial purposes without INTECHOPEN LIMITED's written permission. Enquiries concerning the use of the book should be directed to INTECHOPEN LIMITED rights and permissions department ([permissions@intechopen.com](mailto:permissions@intechopen.com)). Violations are liable to prosecution under the governing Copyright Law.



Individual chapters of this publication are distributed under the terms of the Creative Commons Attribution 3.0 Unported License which permits commercial use, distribution and reproduction of the individual chapters, provided the original author(s) and source publication are appropriately acknowledged. If so indicated, certain images may not be included under the Creative Commons license. In such cases users will need to obtain permission from the license holder to reproduce the material. More details and guidelines concerning content reuse and adaptation can be found at <http://www.intechopen.com/copyright-policy.html>.

### Notice

Statements and opinions expressed in the chapters are those of the individual contributors and not necessarily those of the editors or publisher. No responsibility is accepted for the accuracy of information contained in the published chapters. The publisher assumes no responsibility for any damage or injury to persons or property arising out of the use of any materials, instructions, methods or ideas contained in the book.

First published in London, United Kingdom, 2018 by IntechOpen

eBook (PDF) Published by IntechOpen, 2019

IntechOpen is the global imprint of INTECHOPEN LIMITED, registered in England and Wales, registration number:

11086078, The Shard, 25th floor, 32 London Bridge Street

London, SE19SG – United Kingdom

Printed in Croatia

British Library Cataloguing-in-Publication Data

A catalogue record for this book is available from the British Library

Additional hard and PDF copies can be obtained from [orders@intechopen.com](mailto:orders@intechopen.com)

Dental Anatomy

Edited by Bağdagül Helvacioğlu Kivanç

p. cm.

Print ISBN 978-1-78923-510-4

Online ISBN 978-1-78923-511-1

eBook (PDF) ISBN 978-1-83881-247-8

# We are IntechOpen, the world's leading publisher of Open Access books Built by scientists, for scientists

3,650+

Open access books available

114,000+

International authors and editors

118M+

Downloads

151

Countries delivered to

Our authors are among the  
Top 1%

most cited scientists

12.2%

Contributors from top 500 universities



WEB OF SCIENCE™

Selection of our books indexed in the Book Citation Index  
in Web of Science™ Core Collection (BKCI)

Interested in publishing with us?  
Contact [book.department@intechopen.com](mailto:book.department@intechopen.com)

Numbers displayed above are based on latest data collected.  
For more information visit [www.intechopen.com](http://www.intechopen.com)





# Meet the editor



Bağdagül Helvacıoğlu Kıvanç is a dentist, a teacher, a researcher and a scientist in the field of Endodontics. She was born in Zonguldak, Turkey, on February 14, 1974; she is married and has two children. She graduated in 1997 from the Ankara University, Faculty of Dentistry, Ankara, Turkey. She acquired her PhD in 2004 from the Gazi University, Faculty of Dentistry, Department of Endodontics, Ankara, Turkey, and she is still an associate professor at the same department. She has published numerous articles and a book chapter in the areas of Operative Dentistry, Esthetic Dentistry and Endodontics. She is a member of Turkish Endodontic Society and European Endodontic Society.





---

# Contents

---

## **Preface XI**

### **Section 1    Tooth Anatomy    1**

Chapter 1    **Permanent Maxillary and Mandibular Incisors    3**  
Mohammed E. Grawish, Lamyaa M. Grawish and Hala M. Grawish

Chapter 2    **The Permanent Maxillary and Mandibular Premolar Teeth    37**  
Işıl Çekiç Nagaş, Ferhan Eğilmez and Bağdagül Helvacioğlu Kivanç

### **Section 2    Dental Anatomy and Caries    59**

Chapter 3    **Dental Anatomical Features and Caries: A Relationship to be Investigated    61**  
Marcel Alves Avelino de Paiva, Dayane Franco Barros Manguiera Leite, Isabela Albuquerque Passos Farias, Antônio de Pádua Cavalcante Costa and Fábio Correia Sampaio

### **Section 3    Dental Anesthesia    85**

Chapter 4    **Anatomy Applied to Block Anesthesia for Maxillofacial Surgery    87**  
Alex Vargas, Paula Astorga and Tomas Rioseco

### **Section 4    Oral Rehabilitation    107**

Chapter 5    **Treatment Considerations for Missing Teeth    109**  
Abdolreza Jamilian, Alireza Darnahal, Ludovica Nucci, Fabrizia D'Apuzzo and Letizia Perillo

Chapter 6 **Anatomical and Functional Restoration of the Compromised Occlusion: From Theory to Materials 121**

Nicola Mobilio and Santo Catapano

**Section 5 Studies About Dental Anatomy 139**

Chapter 7 **Evaluation of the Anatomy of the Lower First Premolar 141**

Ticiana Sidorenko de Oliveira Capote, Suellen Tayenne Pedroso Pinto, Marcelo Brito Conte, Juliana Álvares Duarte Bonini Campos and Marcela de Almeida Gonçalves

Chapter 8 **A Comparative Study of the Validity and Reproducibility of Mesiodistal Tooth Size and Dental Arch with iTero™ Intraoral Scanner and the Traditional Method 157**

Ignacio Faus-Matoses, Ana Mora, Carlos Bellot-Arcís, Jose Luis Gandia-Franco and Vanessa Paredes-Gallardo

Chapter 9 **Identification of Lower Central Incisors 179**

Marcela de Almeida Gonçalves, Bruno Luís Graciliano Silva, Marcelo Brito Conte, Juliana Álvares Duarte Bonini Campos and Ticiana Sidorenko de Oliveira Capote

---

## Preface

---

Dental anatomy is one of the most important and basic areas of dentistry. Dentists should well know the anatomy of maxillofacial region and the teeth for diagnosis, the relationship between dental anatomy and caries, anesthesia techniques, treatment planning and making a decision about which restorative materials should be used.

This book is a collection of nine chapters divided into five sections.

Section I “Tooth Anatomy” has two chapters. Chapter 1 “Permanent Maxillary and Mandibular Incisors” presents information about function, development of maxillary and mandibular incisors and detailed information about the anatomy of these teeth. Chapter 2 “The Permanent Maxillary and Mandibular Premolar Teeth” presents information about function and detailed morphology of the permanent premolar teeth and is presented in a pointwise and systematic manner.

Section II “Dental Anatomy and Caries” has one chapter. Chapter 3 “Dental Anatomical Features and Caries: A Relationship to be Investigated” *aims to review the influence of dental anatomy on dental caries development while taking into account the recent findings in cariology*. Understanding anatomical dental features is of great importance for guiding oral health hygiene and preventative measures. The development of dental disorders plays an important role in dental caries risk.

Section III “Dental Anaesthesia” has one chapter. Chapter 4 “Anatomy Applied to Block Anaesthesia” presents a clear and concise text, useful for both undergraduate and graduate students and for the dentist and maxillofacial surgeon. Knowledge of the precise topography and distribution area of the trigeminal nerve and its branches is required to provide precise and useful anaesthesia. The most relevant aspects of bone and sensory anatomy, relevant for the realization of regional anaesthetic techniques in the oral and maxillofacial area, are reviewed.

Section IV “Oral Rehabilitation” has two chapters. Chapter 5 “Treatment Considerations for Missing Teeth” presents a detailed text about missing teeth. Missing is one of the most encountered dental anomalies in the practice of dentistry and may affect the self-esteem and social wellbeing of the patients. Hypodontia is most frequently used when describing the phenomenon of congenital missing teeth. Hypodontia is a common problem seen by the general dentist and usually referred to the orthodontist. The aims of the chapter are to determine the prevalence, assess the etiology of hypodontia, diagnose the problem and make a decision about a treatment plan. Chapter 6 “Anatomical and Functional Restoration of the Compromised Occlusion: From Theory to Materials” presents a detailed text about occlusal rehabilitation. In this context, occlusal disorders (attrition, abrasion, erosion), principles of restoring the occlusion, establishing the vertical dimension, choosing the therapeutic posi-

tion, designing the occlusal anatomy and the instruments and restorative materials that are used for restoring the occlusion are discussed.

Section V “Studies about Dental Anatomy” has three chapters: Chapter 7 “Evaluation of the Anatomy of the Lower First Premolar”, Chapter 8 “A Comparative Study of the Validity and Reproducibility of Mesiodistal Tooth Size and Dental Arch with the iTero™ Intraoral Scanner and the Traditional Method” and Chapter 9 “Identification of Lower Central Incisors”.

The themes of this book cover a range of guidance for the anatomy of permanent maxillary and mandibular incisors and premolar teeth, the relationship between dental anatomy and caries, anatomy applied to block anaesthesia, treatment of missing teeth, the restoration of the compromised occlusion and a detailed description of the experience reported by the authors with treatment strategies for anatomical disorders of the teeth. There are three studies about dental anatomy, which have precise results and discussions.

The book is aimed toward dentists and can also be well used in education and research.

**Assoc. Prof. Bağdagül Helvacioğlu Kivanç**

Gazi University Faculty of Dentistry

Department of Endodontics

Ankara, Turkey

---

# Tooth Anatomy

---



---

# Permanent Maxillary and Mandibular Incisors

---

Mohammed E. Grawish, Lamyaa M. Grawish and  
Hala M. Grawish

Additional information is available at the end of the chapter

<http://dx.doi.org/10.5772/intechopen.69542>

---

## Abstract

The permanent incisors are the front teeth that erupt between 6 and 8 years of age. They are eight in number, four upper and four lower, two centrals and two laterals. They have sharp biting surfaces designed for shearing and cutting of food materials into small chewable pieces. They are the teeth most visible to the others during eating, smiling and talking, and thus, they have high aesthetic value for the individuals. The unique characteristics, arch position, function, development and chronological age of each tooth will be highlighted. In addition, the different aspects with their geometric outlines, outlines and surface anatomy of these teeth will be described. A brief explanation about the pulp cavity, tooth socket and normal occlusion for each tooth will be included.

**Keywords:** anatomical feature, mandibular central, mandibular lateral, maxillary central, maxillary lateral, occlusion, pulp cavity, tooth socket

---

## 1. Introduction

Identifying tooth number, size and shape has an important clinical significance in many dental disciplines, particularly pediatric dentistry, orthodontics, restorative dentistry and oral surgery [1]. Mammalian dentition is characterized by heterodonty, in which both the upper and lower teeth are differentiated morphologically into four types: flat, chisel-shaped incisors, conical canines, bicuspid premolars and multicuspid molars in the mesiodistal direction [2]. The dental formula for the permanent dentition in human beings consists of two incisors, a canine, two premolars and three molars in each half of the jaw [3]. There are four incisors per arch, two per quadrant. The first or the central incisor is next to the midline. The second or the lateral incisor is distal to central [4]. The importance of the recognition of morphological and anatomical-functional characteristics of teeth, seeking adaptation to individual conditions, has been acknowledged [5].

---

## 2. General character

1. The word incisor is derived from the Latin word *incidere*, "to cut."
2. They are the front teeth existing in most heterodont mammals.
3. They are located in the premaxilla above and the mandible below.
4. Maxillary incisors exist in the premaxilla; mandibular incisors are the teeth that occlude with them.
5. They are eight in number; four maxillary and four mandibular, two on each side of the middle line, one central and one lateral.
6. The maxillary and mandibular central incisors are the first teeth centralized in both sides of the midline, with the mesial of each one is on contact with the mesial surface of the other.
7. In some individuals, the two maxillary central incisors are separated by a space called diastema.
8. The maxillary and mandibular lateral incisors are the teeth located distally from either maxillary or mandibular central incisors and mesially from either maxillary or mandibular canines.
9. The maxillary central is larger in all dimensions than the maxillary lateral, but the reverse is the true for the mandibular central and lateral.
10. The mesiodistal dimension is greater than the labiopalatal dimension in the maxillary incisors, while the labiolingual dimension is greater than the mesiodistal dimension in mandibular incisors.
11. They developed from four lobes, three labially and one lingually (palatally), the lingual (palatal) lobe being represented by the cingulum. Each labial lobe of the incisor terminates incisally in rounded eminence known as mamelon.
12. Unworn, newly erupted incisors have three small mamelons forming the incisal ridge. These mamelons are worn down with use to flat edge.
13. All incisors except the mandibular central incisor have rounded distoincisor angle compared to the mesioincisor angle as the mandibular central incisor has almost symmetrical anatomy.
14. The geometric outlines of the labial and lingual (palatal) surfaces are trapezoid while those for the proximal surfaces are triangular in shapes.
15. In some instances, they have vertical mesial and distal developmental depressions on the root surfaces to prevent tooth rotation and provide tooth anchorage.
16. The incisal tip from the proximal aspects is on one line with the root apices (root axis) in maxillary incisors, while there is a lingual tilting in mandibular incisors as the incisal tip is lingually positioned in relation to the root apices.



17. Maxillary incisors overlap the mandibular incisors, vertically and horizontally producing what is called overjet and overbite.
18. The mesial surfaces of the maxillary and mandibular central incisors are on one line at the median plane. With the exception of mandibular central incisor, each incisor occludes with two antagonists from the opposite arch.
19. They have lingual (palatal) convergence as the mesiodistal dimension of the lingual (palatal) surface less than the labial one.
20. The eruption date of the incisors ranges from 6 to 9 years. The specific sequence within this range is centrals preceding laterals, and mandibular incisors precede maxillary incisors.
21. They have only one root. The root canal systems of these single-rooted teeth often have three pulp horns and a single root canal. Over 40% of the mandibular incisors have two canals, but only just over 1% has two separate foramina.
22. The socket border of the maxillary central incisor is regular and rounded; its interior is evenly cone-shaped, accommodating the shape of the conical root. The upper lateral incisor socket is smaller in cross section but deeper than the socket of the upper central incisor. Meanwhile, the socket of mandibular central is flattened on its mesial surface and is somewhat concave distally to accommodate the developmental depression on the root. The socket of mandibular lateral is similar to that of central incisor with two variations; the socket is larger and deeper.
23. Anterior superior dental branch that arises from the infraorbital artery supplies maxillary incisors. Incisive branch of the inferior dental artery supplies the mandibular incisors. The infraorbital artery and inferior dental artery are the branches of the maxillary artery which is a terminal branch from the external carotid artery.
24. Anterior superior dental nerve originates from the infraorbital nerve. A branch from the maxillary nerve supplies the maxillary incisors, while the incisive nerve originates from the inferior dental nerve and a branch of the mandibular nerve supplies the mandibular incisors. The maxillary and mandibular nerves are the second and third divisions of the trigeminal nerve.
25. The venous drainage for maxillary incisors is to the anterior superior dental vein, while that for mandibular incisors is to the inferior dental vein. The anterior superior and the inferior dental veins drain to the maxillary vein, to the retromandibular vein and finally to the external jugular vein.
26. The maxillary and mandibular incisors drain the lymph into submental and upper deep cervical lymph nodes.
27. The major function of the incisors is biting, shearing or cutting food material during mastication by their incisal ridges or edges. They play important roles in speech and aesthetic.

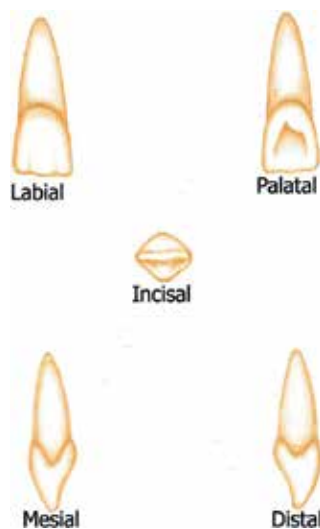
**The mandibular incisors differ from the maxillary ones in the followings:**

28. Mandibular incisors are smaller than maxillary incisors in all dimensions.
29. They have smaller mesiodistal dimension than any other teeth.
30. Their crowns labially are fan-shaped.
31. The mesiolabial and distolabial developmental grooves are less prominent in mandibular incisors.
32. Mandibular incisors have less developed lingual anatomy.
33. Lingual pit and fissure are less common in mandibular incisors compared to maxillary ones.
34. Their contact areas are near the incisal ridges mesially and distally.
35. Attrition occurs on the incisal ridge, labially and not lingually as the maxillary incisors.
36. Their roots are flattened mesiodistally and are longer in proportion to the crown. The roots are frequently grooved on the mesial and distal surfaces with distal groove being more marked.

### **3. Permanent maxillary central incisor**

#### **3.1. Unique characteristics**

This is the most noticeable tooth in the mouth. The general crown size exceeds that of any other incisor in either arch. The mesiodistal crown dimension is the greatest of any anterior tooth. The mesial curvature of cervical line toward the incisal is the greatest of any tooth. The incisal ridge is centralized labiopalatally (see **Figure 1**).



**Figure 1.** Diagram showing the labial, palatal, mesial, distal and incisal aspects of the maxillary permanent central incisor.

### 3.2. Arch position

The maxillary central incisors are the two teeth which are adjacent to the midline in the maxillary arch. They share a mesial contact with each other and have a distal contact with the lateral incisors.

### 3.3. Function

The main function is biting, cutting, incising and shearing the food materials. They also play an important role in the aesthetic and phonetic functions of the human teeth.

### 3.4. Development

It developed from four lobes, three labially and one palatally, the palatal lobe being represented by the cingulum. Each labial lobe of the incisor terminates incisally in rounded eminence known as mamelon [6] (**Table 1**). The mesiodistal and labiopatalal measurements for maxillary permanent central incisor (mm) are shown in **Table 2**.

Appearance of dental organ	5 months intrauterine life (I.U.L.)
Beginning of calcification	3–4 months
Crown completed	4–5 years
Eruption	7–8 years
Root completed	10 years

**Table 1.** Chronology table of maxillary permanent central incisor.

Crown length	Root length	MD at contact area	MD at cervical line	LP at crest of curvature	LP at cervical line	Curvature of CL	
						M	D
10.5	13.0	8.5	7.0	7.0	6.0	3.5	2.5

**Table 2.** Measurements in millimeter of maxillary permanent central incisor.

### 3.5. Labial aspect

#### 3.5.1. Geometric outline

It is trapezoidal in shape with the shortest uneven side toward the cervix and the longest one toward the incisal ridge.

#### 3.5.2. Outlines

**Cervical line:** it is line that demarcates the anatomical crown and the anatomical root. This line is a semicircle and convex root wise. It is found at the center of the tooth aspect and closer to the apex of the root.

**Mesial outline:** is straight or slightly convex from the cervical line to the mesial contact area (the point furthest away from the central axis of the tooth).

**Distal outline:** more convex than the mesial outline.

**Incisal outline:** after the mamelons are worn away, the incisal edge of the maxillary central incisor is straight mesiodistally.

**Contact areas:** the mesial contact is in the incisal third near the mesioincisal angle, while the distal contact is more cervically positioned at the junction between the incisal and middle thirds.

**Angles:** the distoincisor angle is not as sharp as the mesioincisor angle.

**Root:** from this aspect, the root has a cone shape with blunt apex. Although there is a numerous variation between populations, the length of the root is usually longer than the length of the crown by about 3 mm.

### 3.5.3. Surface anatomy

The labial surface is generally convex in mesiodistal and incisocervical dimensions. The convexity is normally greatest in the cervical third (cervical ridge) and tends to be more closely to approach flatness toward the incisal third. The mesiolabial and distolabial developmental grooves that denote the union of the three labial lobes are straight, shallow depressions, which extend from the incisal edge toward the cervical, and fade out, in the middle third. Faint imbrication curved lines (preikymata), which roughly parallel the cemento-enamel junction in the cervical third, are always present in the newly erupted incisors (see **Figure 2**).



**Figure 2.** Labial aspect of maxillary permanent central incisor.

## 3.6. Palatal aspect

### 3.6.1. Geometric outline

It is trapezoidal in shape with the smallest uneven side toward the cervix.

### 3.6.2. Outlines

**Cervical line:** the cervical outline has a slightly greater depth of curvature apically than on the labial surface and is asymmetrical, with its area of maximum curvature offset to the distal.

**Mesial outline:** is similar to its labial counterpart.

**Distal outline:** is similar to its labial counterpart.

**Incisal outline:** the incisal margin is also similar to that of the labial aspect.

**Contact areas:** are similar in position to their labial counterparts.

**Angles:** are similar to their labial counterparts.

**Root:** the root tapers more than the crown toward the palatal side.

### 3.6.3. Surface anatomy

The palatal side of the maxillary central incisor has a smooth rounded convexity, called cingulum near the cervical line, and has a large concavity, called the palatal fossa. Along the mesial and distal sides of the palatal fossa are little elevated linear prominences called marginal ridges. The height of the palatoincisor ridge is raised as well to the height of the marginal ridges. The borders of the palatal fossa are the palatoincisor ridge, incisally; the mesial marginal ridge, mesially; the distal marginal ridge, distally; and the cingulum, cervically. Occasionally, developmental linear grooves are found over the cingulum that extended into the palatal fossa. The mesiodistal dimension of the palatal side is less than of the labial one, and thus, the tooth tapers toward the palatal, accommodating the shape of the dental arch. As a result, the mesial and distal sides of the tooth can be easily seen from the palatal side than the labial one (palatal convergence). Moreover, the tooth cross section at the cervix has a triangular appearance. The sides of the triangle are the labial outline, the mesial outline and the slightly shorter distal outline. On occasion, there may also be a palatal pit located between the cingulum and fossa. This palatal pit may be found near the center of the palatocervical groove, if that structure is present. The palatocervical groove and palatal pit are much more commonly found on maxillary laterals than on maxillary centrals. However, neither structure is a usual finding on the crown of any permanent incisors (see **Figure 3**).



**Figure 3.** Palatal aspect of maxillary permanent central incisor.

## 3.7. Mesial aspect

### 3.7.1. Geometric outline

It is triangular in shape with the wide base at the cervix and narrow apex at the incisal tip.

### 3.7.2. Outlines

**Cervical line:** curves evenly toward the incisal. It exhibits the greatest depth of curvature of any tooth surface in the mouth. The marked curvature of the cervical line also is greater in this aspect compared to the distal one.

**Labial outline:** convex at the cervical one-third representing the cervical ridge then becomes slightly convex to the incisal tip. The incisal tip is on one line with the root apex.

**Palatal outline:** convex at the cervical one-third representing cingulum then becomes concave in the middle one-third, representing the palatal fossa, and then becomes convex again to follow the palatoincisor tip. The entire outline may be described as a shallow “S.”

**Incisal outline:** it is usually pointed or slightly rounded in newly erupted incisors. In teeth with incisal wear, the outline is straight and slopes down from labial to palatal.

**Crest of curvatures:** the labial crest (the point furthest away from the central axis of the tooth) is at the cervical third near the cervical line, while the palatal one is found at the middle of the cervical one-third at the prominence of the cingulum.

Note: the incisal ridge is the projection of enamel on newly erupted teeth, which is the incisal termination of the tooth. In a proximal view, it is normally pointed or slightly rounded. After the tooth enters into occlusion, this ridge becomes blunted and flattened, resulting in a sloping, straight outline from the proximal aspect. This flattened area is termed the incisal edge (**Table 4**).

**Root:** cone-shaped with a rounded blunted end, square at the cervical one-third then gradually tapered to the root apex. The labial outline is convex, while the palatal one is more convex.

### 3.7.3. Surface anatomy

The crown surface is somewhat flattened with the mesial contact located in the incisal third, near the incisal margin, and is centralized labiopallatally. It is roughly ovoid, long incisocervically and narrow labiopallatally. It is the only proximal area in the maxillary arch where mesial surface contacts mesial surface (see **Figure 4**).



**Figure 4.** Mesial aspect of maxillary permanent central incisor.

### 3.8. Distal aspect

#### 3.8.1. Geometric outline

It is triangular in shape.

#### 3.8.2. Outlines

**Cervical line:** the curvature of the cervical line is less distally than mesially.

**Labial outline:** similar to the labial outline of the mesial surface.

**Palatal outline:** similar to the palatal outline of the mesial surface.

**Incisal outline:** the crown appears somewhat thicker at the incisal third.

**Crest of curvatures:** are similar in position to their mesial counterparts.

**Root:** the surface of the root is convex, and does not have a depression.

#### 3.8.3. Surface anatomy

The distal view describes the surface of the tooth distant from the middle line of the face. This side closely resembles the mesial one. A greater part of the tooth surface is seen from this aspect compared to the mesial one as the labial surface of the crown steeped palatally, accommodating the horseshoe shape of the dental arch. Because it contacts the lateral incisor, which is a smaller tooth, the distal contact area is accordingly smaller in size. Its shape is still ovoid, but it is more nearly round than on the mesial. It is also located farther cervically, still in the incisal third, but very near the junction of the incisal and middle thirds (see **Figure 5**).


### 3.9. Incisal aspect

The incisal view of this tooth considers the portion of the tooth visible from the side where the incisal ridge is located. From this angle, only the crown of the tooth is visible, and overall, the



**Figure 5.** Distal aspect of maxillary permanent central incisor.

tooth looks bilateral. The outlines are roughly triangular with the labial surface appears broad and flat, and the palatal surface tapers toward the cingulum. The distance between the mesio-incisal angles to the cingulum is slightly longer than the distance between the distoincisor angles to the cingulum. The incisal edge is centrally situated in a labiopallatal direction. The palatal fossa is seen as broad concavity between the two marginal ridges and incisal to the cingulum [7, 8] (see **Figure 6**).



**Figure 6.** Incisal aspect of maxillary permanent central incisor.

### 3.10. Pulp cavity

#### 3.10.1. Mesiodistal section

The mesiodistal measurement of the pulp chamber is wider compared to the labiopallatal one. The outlines of the pulp cavity follow the general shape of the tooth. If the mamelons are well developed, three definite pulp horns are found at the incisal portion of the tooth. The pulp cavity tapers gradually and evenly along its whole length until the apical constriction of the root is reached. The apical foramen may be located slightly off center to the root tip.

#### 3.10.2. Labiopallatal section

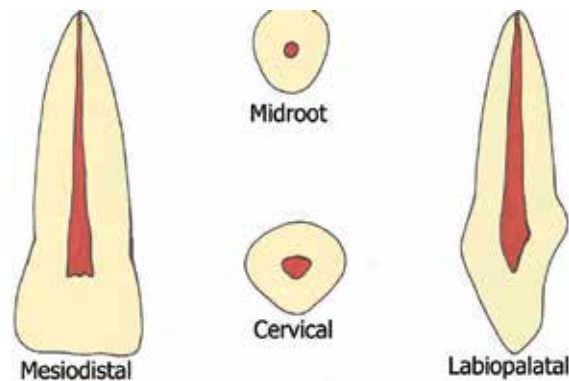
The pulp cavity follows the general outline of the crown and root. The pulp chamber is very narrow in the incisal region. Cervically, the pulp chamber widens to its largest labiopallatal width. Then, the root canal tapers gradually and evenly ending in a constriction at the root tip. The apical foramen may be located a little bit to the palatal or labial aspect of the root, near the very tip of the root.

#### 3.10.3. Cervical cross section

At the cervical level, the pulp cavity mimics the external shape of the tooth. It is the widest in dimension compared to the other cross sections and centralized within the root dentin.

In newly erupted teeth, the outline of the pulp chamber is roughly triangular in shape with the base of this triangle at the labial surface. As the amount of physiologic secondary dentin increases, the pulp cavity becomes more rounded in shape. The root and pulp canal tend to be rounder at midroot level than at the cervical level. The anatomy at the midroot level is essentially the same as that found at the cervical level, just smaller in all dimensions [9] (see **Figure 7**).





**Figure 7.** Pulp cavity for the mesiodistal, labiopalatal, midroot and cervical sections of maxillary permanent central incisor.

### 3.11. Tooth socket

The first socket right or left of the median line is that of the maxillary central incisor. The periphery of the socket often dips down palatally, labially, mesially and distally to accommodate the shape of the root. The central incisor socket is flattened on its mesial surface and is usually somewhat concave distally [10].

### 3.12. Occlusion

Like all upper front teeth and when the mouth is closed, the central incisors are ordinarily positioned labially to the mandibular ones. In some instances, the upper front teeth are positioned palatally to the lower ones and in such case the condition is referred as anterior cross-bite. When the teeth are biting down, the upper central incisors occlude with the lower central and lateral incisors. The contact point of the lower teeth is in the palatal fossa of the upper central incisor about 2 mm cervically from the incisal edge. The anterior open bite occurs when the upper and lower incisors do not contact even when the mouth is fully closed. This incorrect arrangement of teeth may result from some habits, such as thumb sucking. On the other hand, the deep bite occurs when the contact of the lower incisors to the upper incisors is near or completely on the gingiva. When upper anterior teeth are located too far in front of the lower teeth, this is termed as large overjet [11].

### 3.13. Variation

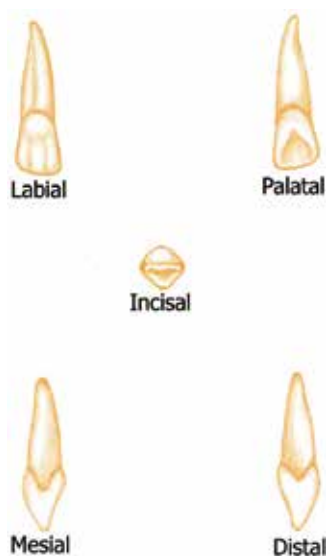
1. Considered to be a common variation in Asian populations, shovel-shaped incisors derive their name from the prominent marginal ridges and the deeper palatal fossa of the teeth. When seen from palatal view, the tooth is said to resemble a shovel.
2. When space exists between maxillary central incisors, the condition is referred to as a diastema. One frequent cause of the space is the presence of a large labial frenum from the upper lip extending near the teeth.

3. The maxillary incisors are the most likely teeth to have a talon cusp, which is an extra cusp on the lingual surface.
4. Also, the permanent maxillary incisors are the most likely teeth to have a dilacerations, which is a sharp curve on a tooth.
5. When the root is exceptionally short, in conjunction with an abnormal contour of the crown, this anomalous condition is referred to as dwarfed root, and the lack of root support may endanger the tooth's longevity in the mouth.
6. In the cases affected by congenital syphilis, a notch forms on the incisal edges of all incisors. When such notch is found, the teeth are described as screwdriver-shaped and they are called Hutchinson's incisors.
7. The alveolar bone between the roots of the two central incisors is occasionally the site of supernumerary teeth or extra teeth, known as mesiodens [1].

## 4. Permanent maxillary lateral incisor

### 4.1. Unique characteristics

The general shape is similar to maxillary central incisor except that they are shorter and narrower. The mesiodistal crown dimension is the smallest of any maxillary teeth. The mesio-incisal and distoincisal angles are more rounded than the corresponding angles of maxillary central incisor. On the palatal aspect, the marginal ridges and cingulum are more prominent. It has the most cervically located contact area of any incisor. Next to third molars, maxillary lateral incisors are the teeth that show most variation in crown size, shape and form (see **Figure 8**).



**Figure 8.** Diagram showing the labial, palatal, mesial, distal and incisal aspects of the maxillary permanent lateral incisor.

## 4.2. Arch position

The maxillary lateral incisor is the tooth located distally from both maxillary central incisors and mesially from both maxillary canines.

## 4.3. Function

Like all the incisors, their function is for shearing or cutting food material during mastication.

## 4.4. Development

It is developed from four lobes, three labially and one palatally, the palatal lobe being represented by the cingulum. Each labial lobe of the incisor terminates incisally in rounded eminence known as mamelon. Mamelons are better seen on the central incisors as compared to the lateral incisors [6] (**Table 3**). The mesiodistal and labiopalatal measurements for maxillary permanent lateral incisor (mm) are shown in **Table 4**.

## 4.5. Labial aspect

### 4.5.1. Geometric outline

It is trapezoidal in shape with the shortest uneven side toward the cervix.

### 4.5.2. Outlines

**Cervical line:** curves in a regular arc apically, with only slightly less depth than in the central incisor.

Appearance of dental organ	5 months I.U.L.
Beginning of calcification	10–12 months
Crown completed	4–5 years
Eruption	8–9 years
Root completed	11 years

**Table 3.** Chronology table of maxillary permanent lateral incisor.

Crown length	Root length	MD at contact area	MD at cervical line	LP at crest of curvature	LP at cervical line	Curvature of CL	
						M	D
9.0	13.0	6.5	5.0	6.0	5.0	3.0	2.0

**Table 4.** Measurements in millimeter of maxillary permanent lateral incisor.

**Mesial outline:** this margin resembles that of the central incisor, but usually is more convex and has a more rounded mesioincisal angle. The contact area is located farther cervically in the incisal third, quite near its junction with the middle third.

**Distal outline:** the distal margin is always more rounded than the distal outline of the central incisor, with a more cervically located contact area. The distoincisal angle is noticeably more rounded than its central incisor counterpart, and also more rounded than its own mesioincisal angle.

**Incisal outline:** the incisal outline resembles the central incisor, but it is not so straight, partially because of the greater rounding of the two incisal angles. It exhibits the greatest rounding of any incisor. The number and prominence of mamelons is variable, but two are the most common finding.

**Contact areas:** the mesial contact at the junction between middle and incisal on-third ewhile the distal contact at the center of the middle third.

**Angles:** the distoincisal angle being more rounded than the mesioincisal angle.

**Root:** the root tapers toward the pointed apex. The root apex is inclined distal to midline. It is narrow mesiodistally than that of maxillary central and usually as long as or somewhat longer than that of the central.

#### 4.5.3. Surface anatomy

The labial surface itself is more convex both mesiodistally and incisocervically than the maxillary central. Labial developmental grooves, and imbrication lines are often present, similar to those of the central incisor but are less prominent. The labial height of contour is located at the cervical third (see **Figure 9**).



**Figure 9.** Labial aspect of maxillary permanent lateral incisor.

## 4.6. Palatal aspect

### 4.6.1. Geometric outline

It is trapezoidal in shape with the smallest uneven side toward the cervix.

#### 4.6.2. Outlines

**Cervical line:** it curves toward the apical, but is offset to the distal.

**Mesial outline:** is similar to its labial counterpart.

**Distal outline:** is similar to its labial counterpart, and the distoincisor angle is much more rounded than the mesioincisor angle.

**Incisal outline:** is similar to the labial aspect.

**Contact areas:** are similar in position to their labial counterparts.

**Angles:** are similar in position to their labial counterparts.

**Root:** the root tapers more than the crown toward the palatal side.

#### 4.6.3. Surface anatomy

The mesial and distal marginal ridges, as well as the cingulum, are relatively more prominent, and the palatal fossa is deeper, when compared to the same structures of the central incisor. A palatocervical groove is a more common finding in maxillary lateral incisors than in central incisors. A palatal pit, near the center of this groove, is also more common, and when present, is a potential site for caries. The palatocervical groove usually originates in the palatal pit and extends cervically, and slightly distally, onto the cingulum. It might be helpful to think of the palatocervical fissure as running in a more or less vertical direction, while the palatocervical groove extends in a roughly horizontal direction (see **Figure 10**).

### 4.7. Mesial aspect

#### 4.7.1. Geometric outline

It is triangular in shape with the wide base at the cervix and narrow apex at the incisal tip.



**Figure 10.** Palatal aspect of maxillary permanent lateral incisor.

#### 4.7.2. Outlines

**Cervical line:** exhibits less depth of curvature than it does on the mesial surface of the central incisor.

**Labial outline:** convex at the cervical one-third representing the cervical ridge then becomes slightly convex to the incisal tip. The incisal tip is on one line with the root apex.

**Palatal outline:** convex at the cervical one-third representing cingulum then becomes concave in the middle one-third, representing the palatal fossa, and then becomes convex again to follow the palatoincisor tip. The entire outline may be described as a shallow "S."

**Crest of curvatures:** the labial crest is at the cervical third near the cervical line, while the palatal one is found at the middle of the cervical one-third at the prominence of the cingulum.

**Incisal outline:** the incisal portion is on one line with root apex.

**Root:** the root appears longer but narrower than that of the central.

#### 4.7.3. Surface anatomy

The crown is shorter, and the labiopalatal measurement of the crown is smaller. The contact area is also similar in shape to the contact of the central incisor. It is found in the incisal third very near the junction of the incisal and middle thirds, centered labiopalatally (see **Figure 11**).

### 4.8. Distal aspect

#### 4.8.1. Geometric outline

It is triangular in shape with the wide base at the cervix and narrow apex at the incisal tip.



**Figure 11.** Mesial aspect of maxillary permanent lateral incisor.

#### 4.8.2. Outlines

**Cervical line:** shows less curvature incisally than on the mesial surface.

**Labial outline:** similar to the labial outline of the mesial surface.

**Palatal outline:** similar to the palatal outline of the mesial surface.

**Crest of curvatures:** are similar in position to their mesial counterparts.

**Incisal outline:** rounded in newly erupted teeth and flat in worn out teeth.

**Root:** the distal surface of the root is slightly more convex than mesial.

#### *4.8.3. Surface anatomy*

The distal surface is smaller and more convex in all dimensions than the mesial surface. The contact area is shorter and not as incisally placed, when compared to the mesial contact. It is normally located at middle of the middle one-third and centered labiopalatally (see **Figure 12**).

### **4.9. Incisal aspect**

In incisal view, this tooth resembles the central incisor to varying degrees. The tooth is narrower mesiodistally than the maxillary central incisor; however, it is nearly as thick labiopalatally. The incisal outline is more rounded labially and palatally than the central incisor. When palatal pit is present; it is located in the depth of the palatal fossa [7, 8] (see **Figure 13**).

### **4.10. Pulp cavity**

#### *4.10.1. Mesiodistal section*


The pulp cavity nearly follows the external shape of the tooth. When viewed from the labial aspect of the tooth, the pulp horns appear to be blunted. The pulp chamber and root canal taper evenly and gradually toward the root apex. In the apical portion, the root often shows a significant curvature.

#### *4.10.2. Labiopalatal section*

The anatomical feature is almost identical to that of the central incisor. Generally, the pulp cavity of the lateral incisor closely resembles the outline form of the crown and the root. The



**Figure 12.** Distal aspect of maxillary permanent lateral incisor.



**Figure 13.** Incisal aspect of maxillary permanent lateral incisor.

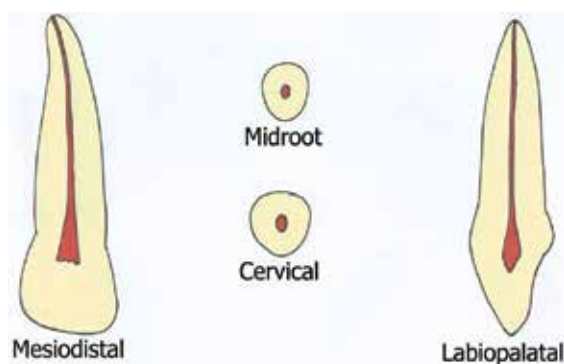
pulp projections are usually well developed and prominent. In the incisal region, the pulp chamber is narrow, and at the cervical level of the tooth it may become very wide. When the cervical enlargement of the pulp chamber is lacking, the root canal tapers slightly to the apical constriction at the root tip. Many of the apical foramina exit on the labial or palatal aspect of the root.

#### 4.10.3. Cervical cross section

The cervical cross section shows the pulp chamber to be centered within the root. The root form of this tooth shows a large variation in shape. The outline form of this tooth may be triangular, oval or round. The pulp chamber generally follows the outline form of the root, but secondary dentin may narrow the canal significantly [9] (see **Figure 14**).

#### 4.11. Tooth sockets

The second socket from the midline is that of the lateral incisor. It is generally conical and egg-shaped, or ovoid, with the widest portion to the labial. It is smaller on cross section, although it is often deeper than the central alveolus. Sometimes, it is curved at the upper extremity [10].



**Figure 14.** Pulp cavity for the mesiodistal, labiopalatal, midroot and cervical sections of maxillary permanent lateral incisor.



#### **4.12. Occlusion**

The upper lateral incisors are usually located labially to the mandibular teeth when the mouth is closed. The upper lateral incisor occludes with the distolabial half of the mandibular lateral and with the mesiolabial inclined plane of the mandibular canine [11].

#### **4.13. Variation**

1. The incisal portion of the cingulum may exhibit a tubercle.
2. Palatocervical fissure may extend all the way onto the root surface from the adjacent cingulum.
3. Distorted crowns and unusual root curvatures are more commonly seen than with any other incisor.
4. A diminutive peg-shaped crown form, which is relatively common, and is due to a lack of development of the mesial and distal portions of the crown.
5. Maxillary laterals sometimes are congenitally missing, that is, tooth buds do not form.
6. The palatal pit of the maxillary lateral may be the entrance site where enamel and dentin have become invaginated in the tooth's pulp cavity, due to a developmental aberrancy called dens in dente [1].

### **5. Permanent mandibular central incisor**

#### **5.1. Unique characteristics**

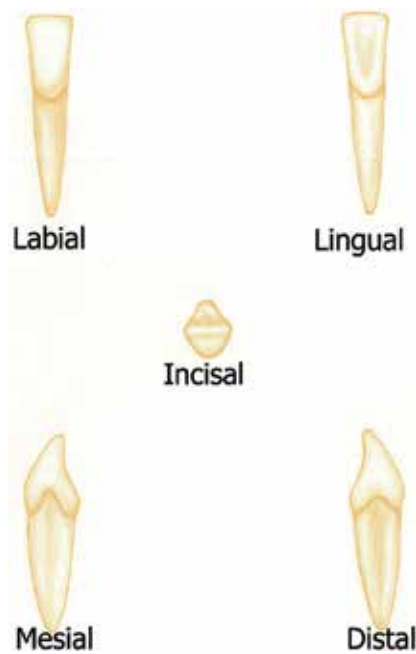
The crown dimensions are the smallest of any tooth, it has bilaterally symmetrical crown, and the line angles are the sharpest of any tooth. The proximal contact areas are at the same level. The incisal edge is lingual to labiolingual bisector. It shows the shallowest labial developmental grooves, smoothest lingual surface contour and the least developed cingulum. As the smallest tooth in the dentition, the mandibular central incisor has only one antagonist. This tooth and the maxillary third molar are the only teeth that have one antagonist (see **Figure 15**).

#### **5.2. Arch position**

It occupies the position adjacent to the midline in each mandibular quadrant. They share a mesial contact area with each other, while the distal contact is with the permanent lateral incisor.

#### **5.3. Function**

These teeth function in biting, cutting, incising and shearing, just as do their maxillary counterparts.



**Figure 15.** Diagram showing the labial, lingual, mesial, distal and incisal aspects of the mandibular permanent central incisor.

**5.4. Development**

It developed from four lobes (three mamelons and one cingulum). Shortly after eruption, mamelons are usually worn away by attrition and the incisal edges of all incisors are straight [6] (**Table 5**). The mesiodistal and labiolingual measurements for mandibular permanent central incisor (mm) are shown in **Table 6**.

Appearance of dental organ	5 months I.U.L.
Beginning of calcification	3–4 months
Crown completed	4–5 years
Eruption	6–7 years
Root completed	9 years

**Table 5.** Chronology table of mandibular permanent central incisor.

Crown length	Root length	MD at contact area	MD at cervical line	LL at crest of curvature	LL at cervical line	Curvature of CL	
						M	D
9.0	12.5	5.0	3.5	6.0	5.3	3.0	2.0

**Table 6.** Measurements in millimeter of mandibular permanent central incisor.

## 5.5. Labial aspect

### 5.5.1. Geometric outline

It is trapezoidal in shape with the shortest uneven side toward the cervix.

### 5.5.2. Outlines

**Cervical line:** the cervical line is symmetrically curved toward the root.

**Mesial outline:** the mesial margin normally tapers evenly toward the cervical part in a nearly straight line.

**Distal outline:** the outline is straight and almost exactly like the mesial outline.

**Incisal outline:** In newly erupted teeth, three mamelons most always be seen. After incisal wear has obliterated the mamelons, the incisal outline is straight, and at right angles to the long axis of the tooth.

**Contact areas:** mesially, the height of contour is associated with the contact area in the incisal third, very close to the incisal margin. The height of contour is also in the incisal third and in the same level, distally.

**Angles:** the mesioincisal angle is quite sharp with a similarly sharp distoincisal angle, normally more so than any of the incisal angles of maxillary incisors.

**Root:** a straight single root, tapering at the apical third. The labial surface is narrow and convex. The mesial and distal outlines are straight down to the apical portion. Its apical third ends in a pointed apex, which tends to curve distally. The root appears longer compared to the crown length.

### 5.5.3. Surface anatomy

The labial surface is generally convex both mesiodistally and incisocervically, but not to the extent of the maxillary incisors, especially the maxillary lateral. However, like the maxillary



**Figure 16.** Labial aspect of mandibular permanent central incisor.

incisors, the convexities are much greater in the cervical third. In fact, in some specimens the labial surface may be quite flat incisal to the height of contour. Developmental grooves and imbrication lines are not normally present. Occasionally, there are very faint grooves which only occur near the incisal margin of the labial surface (see **Figure 16**).

## 5.6. Lingual aspect

### 5.6.1. Geometric outline

It is trapezoidal in shape with the smallest uneven side toward the cervix.

### 5.6.2. Outlines

**Cervical line:** curves evenly toward the root, but is located farther from the incisal ridge than the labial surface counterpart.

**Mesial outline:** closely resembles the mesial outline of the labial aspect.

**Distal outline:** closely resembles the distal outline of the labial aspect.

**Incisal outline:** closely resembles the incisal outline of the labial aspect.

**Contact areas:** are similar in position to their labial counterparts.

**Angles:** are similar to their labial counterparts.

**Root:** is slightly narrower on the lingual side than on the labial side.

### 5.6.3. Surface anatomy

The crown is narrower on the lingual surface (lingual convergence). The lingual surface is relatively smooth, and its structures are generally less prominent than those of the maxillary incisors. There is usually a slight concavity, or lingual fossa, bordered by indistinct marginal ridges on the mesial and distal. There are normally no grooves, fissures or pits on the lingual surface. A cingulum is normally present, although it is not as prominent as in the maxillary incisors. The height of contour is located in the cervical third of the surface, associated with the greatest convexity of the cingulum (see **Figure 17**).

## 5.7. Mesial aspect

### 5.7.1. Geometric outline

It is triangular in shape with the wide base at the cervix and narrow apex at the incisal tip.

### 5.7.2. Outlines

**Cervical line:** there is a marked, even curvature incisally of the cervical margin.



**Figure 17.** Lingual aspect of mandibular permanent central incisor.

**Labial outline:** slopes in a straight to slightly convex line from the incisal ridge to the crest of curvature and is then convex in the remainder of the cervical third.

**Lingual outline:** concave in the incisal two-thirds and convex in the cingulum area, or cervical third.

**Incisal outline:** normally rounded, but can be straight and is located lingual to the center of the root. The profile of the incisal edge has downward inclination toward the labial, which is opposite to the lingual slope of the maxillary incisors. This is due to the wear pattern between the upper and lower incisors.

**Crest of curvatures:** the labial crest is at the cervical third near the cervical line while the lingual one is found at the middle of the cervical third at the prominence of the cingulum.

**Root:** the root outlines are nearly straight from the cervical line to the middle third and then taper to the rounded apex. The mesial surface of the root is flat with a deep longitudinal developmental depression

### *5.7.3. Surface anatomy*

The mesial surface is roughly triangular, or wedge-shaped, like all other anterior teeth. Unlike the maxillary incisors, the crown appears to be slightly offset toward the lingual. The contact area is located about half way from labial to lingual, and in the incisal third, very close to the incisal edge. It has an ovoid shape, which is long incisocervically and narrow labiolingually (see **Figure 18**).

## **5.8. Distal aspect**

### *5.8.1. Geometric outline*

It is triangular in shape.



**Figure 18.** Mesial aspect of mandibular permanent central incisor.

#### 5.8.2. Outlines

**Cervical line:** curves slightly less toward the incisal.

**Labial outline:** similar to the labial outline of the mesial surface.

**Lingual outline:** similar to the lingual outline of the mesial surface.

**Incisal outline:** similar to the incisal outline of the mesial surface. It is located lingual to the center of the root.

**Crest of curvature:** are similar in position to their mesial counterparts.

**Root:** similar to the mesial but with a deeper longitudinal developmental depression and groove at its center.

#### 5.8.3. Surface anatomy

Even the contact area has a similar location, a fact which is unique among incisors (see **Figure 19**).



**Figure 19.** Distal aspect of mandibular permanent central incisor.

## 5.9. Incisal aspect

The most notable features from the incisal aspect are the symmetry of the mesial and distal portions, and the straight incisal edge. Unlike the maxillary central, this tooth is roughly four sided, or diamond-shaped, from this aspect, and the tooth is normally wider labiolingually than mesiodistally. Because the crown is offset toward the lingual, more of the labial surface than the lingual surface is visible from this aspect. Even though the central incisor is described as symmetrical from the incisal aspect, careful scrutiny will reveal that the cingulum is very slightly offset toward the distal, an important feature when attempting to distinguish right from left mandibular central incisors [7, 8] (see **Figure 20**).



**Figure 20.** Incisal aspect of mandibular permanent central incisor.

## 5.10. Pulp cavity

### 5.10.1. Mesiodistal section

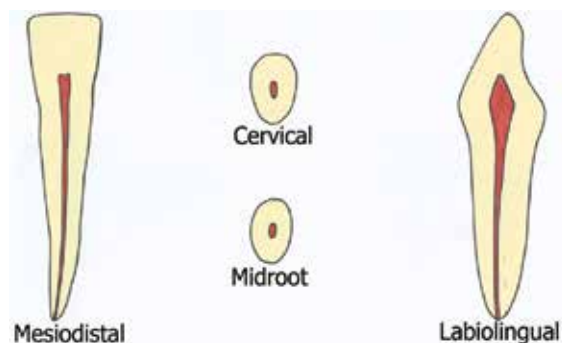The mesiodistal section of the mandibular central incisor demonstrates the narrowness of the pulp cavity. The pulp horns are usually less prominent. The canal also appears narrow, having a gentle taper from the pulp chamber to the apical constriction. The canal may exit at the apex, or mesially or distally to the apex of the root.

### 5.10.2. Labiolingual section

The mandibular central incisor is the smallest tooth in the mouth, but its labiolingual dimension is very large. This tooth usually has one canal, but two canals may be found quite frequently. The pulp chamber may be very small in size, intermediate in size or very large. In the apical 3 or 4 mm of the root, the pulp canal may taper gently to the apex or narrow abruptly. The apical foramen may exit at the root apex or on the labial aspect of the root.

### 5.10.3. Cervical cross section

The cervical cross section demonstrates the proportions of the root dimensions. The mesiodistal dimension is small, whereas the labiolingual dimension is very large, the external shape is variable; some are round, oval or elliptical. Two separate canals may be present, or a dentinal island may make it appear as though two canals are present [9] (see **Figure 21**).



**Figure 21.** Pulp cavity for the mesiodistal, labiolingual, midroot and cervical sections of mandibular permanent central incisor.

### 5.11. Tooth sockets

The central incisor socket is flattened on its mesial surface and is usually somewhat concave distally to accommodate the developmental groove on the root [10].

### 5.12. Occlusion

The labioincisal ridge of the lower central incisor strikes the palatal surface of the upper central incisor at the junction between the incisal and middle thirds. Its mesial outline is in line with the midline and the mesial outline of upper central incisor, while its distal outline is below the junction of the mesial two-thirds and distal thirds of the upper central [11].

### 5.13. Variation

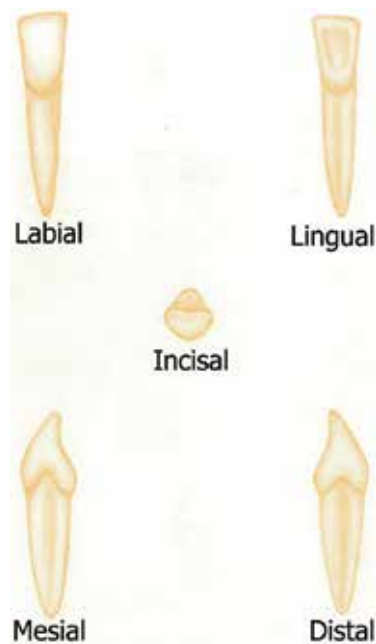
1. There is great variability in the lingual inclination of the labial surface of mandibular central incisor specimens.
2. Anomalies are very rare. Occasionally, a bifurcated root is found which, in mandibular incisors, has labial and lingual locations [1].

## 6. Permanent mandibular lateral incisor

### 6.1. Unique characteristics

The crown of this tooth is similar to that of the mandibular central incisors, but not bilaterally symmetrical. The labial surface has more fan-shaped appearance compared to lower central incisor. The incisal ridge is straight and slopes downward toward the distal. The crown of the mandibular lateral incisor twisted distolingually slightly on its root in order to allow the incisive ridge to follow the curve of the dental arch. The cingulum is shifted to the distal (see **Figure 22**).





**Figure 22.** Diagram showing the labial, lingual, mesial, distal and incisal aspects of the mandibular permanent lateral incisor.

## 6.2. Arch position

The lateral incisors contact mesially with the distal surface of the central incisors and distally with the mesial surface of the canines.

## 6.3. Function

This tooth has the function of incising food as well as aesthetic.

## 6.4. Development

It developed from four lobes (three mamelons and cingulum) [6] (**Table 7**). The mesiodistal and labiolingual measurements for mandibular permanent lateral incisor (mm) are shown in **Table 8**.

## 6.5. Labial aspect

### 6.5.1. Geometric outline

Crown outline is trapezoidal. It has a more fan-shaped appearance from the labial aspect as the cervical portion is narrower, while the incisal portion is wider compared to the mandibular central incisor.

<b>Appearance of dental organ</b>	5 months I.U.L.
<b>Beginning of calcification</b>	3–4 months
<b>Crown completed</b>	4–5 years
<b>Eruption</b>	6–7 years
<b>Root completed</b>	9 years

**Table 7.** Chronology table of mandibular permanent lateral incisor.

Crown length	Root length	MD at contact area	MD at cervical line	LL at crest of curvature	LL at cervical line	Curvature of CL	
						M	D
9.5	14.0	5.5	4	6.5	5.3	3.0	2.0

**Table 8.** Measurements in millimeter of mandibular permanent lateral incisor.

### 6.5.2. Outlines

**Cervical line:** the cervical line is symmetrically curved toward the root.

**Mesial outline:** the mesial outline of the crown is often longer than the distal outline.

**Distal outline:** shorter than the mesial outline.

**Incisal outline:** the incisal ridge is slightly wider mesiodistally. The incisal ridge slopes downward in a distal direction.

**Contact areas:** the distal contact area is more cervically positioned than the mesial contact area. The mesial contact is found at the incisal third, near the incisal ridge. The distal contact is found also at the incisal third, but more cervical to the level of the mesial contact area.

**Angles:** the distoincisor angle of the lower lateral incisor is relatively more rounded and obtuse than the sharp mesioincisor angle of the mandibular central incisor.

**Root:** it is similar to that of the central incisor, but is slightly longer.

### 6.5.3. Surface anatomy

The labial face of the mandibular lateral incisor crown is smooth, with a flattened at the incisal third; the middle third is more convex, narrowing down to the convexity of the root at the cervical portion (see **Figure 23**).

## 6.6. Labial aspect

### 6.6.1. Geometric outline

Crown outline is trapezoid in shape.



**Figure 23.** Labial aspect of mandibular permanent lateral incisor.

#### 6.6.2. Outlines

**Cervical line:** semicircular more curved root wise compared to its labial counterpart. The curvature of cervical line is also offset distally.

**Mesial outline:** closely resembles the mesial outline of the labial aspect.

**Distal outline:** closely resembles the distal outline of the labial aspect.

**Incisal outline:** closely resembles the incisal outline of the labial aspect.

**Contact areas:** are similar in position to their labial counterparts.

**Angles:** are similar in position to their labial counterparts.

**Root:** is slightly narrower on the lingual side than on the labial side.

#### 6.6.3. Surface anatomy

It has faint mesial and distal marginal ridges as well as cingulum, which are less developed. The mesial marginal ridge is longer than the distal marginal ridge. The cingulum is deviated distal to the center of the lingual surface (see **Figure 24**).

### 6.7. Mesial aspect

#### 6.7.1. Geometric outline

It is triangular in shape with the wide base at the cervix and narrow apex at the incisal tip.

#### 6.7.2. Outlines

**Cervical line:** there is a marked, even curvature incisally of the cervical margin.



**Figure 24.** Lingual aspect of mandibular permanent lateral incisor.

**Labial outline:** slopes in a straight to slightly convex line from the incisal ridge to the crest of curvature and is then convex in the remainder of the cervical third.

**Lingual outline:** concave in the incisal two-thirds and convex in the cingulum area, or cervical third.

**Incisal outline:** normally rounded, but can be straight and is located lingual to the center of the root.

**Crest of curvatures:** the labial crest is at the cervical third near the cervical line, while the lingual one is found at the middle of the cervical third at the prominence of the cingulum.

**Root:** the root form is similar to that of the mandibular central incisor, including the presence of developmental depression, mesially.

### 6.7.3. Surface anatomy

The mesial side of the crown is often longer than the distal side; this causes the incisal ridge, which is straight, to slope downward in a distal direction. The mesial contact area centered labiolingually and at the incisal third near the mesioincisal angle, incisocervically (see **Figure 25**).



**Figure 25.** Mesial aspect of mandibular permanent lateral incisor.

## 6.8. Distal aspect

### 6.8.1. Geometric outline

It is triangular in shape.

### 6.8.2. Outlines

**Cervical line:** curves slightly less toward the incisal.

**Labial outline:** similar to the labial outline of the mesial surface.

**Lingual outline:** similar to the lingual outline of the mesial surface.

**Incisal outline:** normally rounded but can be straight and is located lingual to the center of the root.

**Crest of curvature:** is similar in position to their mesial counterparts.

**Root:** the root form is similar to that of the mandibular central incisor, including the presence of developmental depression, distally.

### 6.8.3. Surface anatomy

The distal surface is shorter incisocervically. The distal contact area is more cervical than the mesial one. The concavity immediately above the cervical line on the distal surface of the mandibular lateral incisor is deeper than that of the lower central incisor (see **Figure 26**).

## 6.9. Incisal aspect

The incisal ridge is tilted distally and lingually. The crown of the lower lateral incisor twisted distolingually slightly on its root in order to allow the incisive ridge to follow the curve of the dental arch. The cingulum is shifted to the distal. It is interesting to note that the labiolingual root axes of mandibular central and lateral incisors remain almost parallel in the alveolar process, even though the incisal ridges are not directly in line [7, 8] (see **Figure 27**).

## 6.10. Pulp cavity

### 6.10.1. Mesiodistal section

Similar to that of the mandibular central incisor.

### 6.10.2. Labiolingual section

Similar to that of the mandibular central incisor.



**Figure 26.** Distal aspect of mandibular permanent lateral incisor.



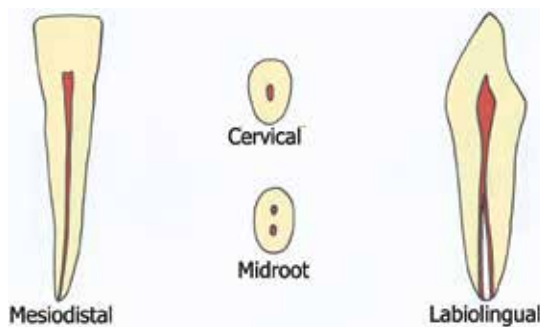
**Figure 27.** Incisal aspect of mandibular permanent lateral incisor.

#### 6.10.3. Cervical cross section

Similar to that of the mandibular central incisor [9] (see **Figure 28**).

### 6.11. Tooth sockets

The socket of the mandibular lateral incisor is similar to that of the central incisor. It usually has the following variations; the socket is larger and deeper to accommodate a larger and longer root [10].



**Figure 28.** Pulp cavity for the mesiodistal, labiolingual, midroot and cervical sections of mandibular permanent lateral incisor.

## 6.12. Occlusion

Labioincisal ridge contacts both maxillary central and lateral incisors at the junction of their incisal and middle thirds. The cingulum is free of contact. The mesial outline is identical with the junction of the distal and middle thirds of maxillary central. The distal outline is centered below maxillary lateral incisor [11].

## 6.13. Variation

Anomalies are rare, but occasionally a bifurcated root is found [1].

## Acknowledgements

Great thanks to Dr Rami Rabie, a postgraduate student in Oral Biology Department, Faculty of Dentistry, Mansoura University, Egypt, and thanks for Rana Ahmed Ezzat Edris, a level 3 student at Faculty of Oral and Dental Medicine, Delta University for Science and Technology, for their valuable contributions providing the original diagrams for the different teeth aspects and different dental pulp sections.

## Author details

Mohammed E. Grawish<sup>1,2\*</sup>, Lamyaa M. Grawish<sup>3</sup> and Hala M. Grawish<sup>3</sup>

\*Address all correspondence to: [grawish2005@yahoo.com](mailto:grawish2005@yahoo.com)

1 Department of Oral Biology, Faculty of Dentistry, Mansoura University, Egypt

2 Department of Oral Biology, Faculty of Oral and Dental Medicine, Delta University for Science and Technology, Gamasa, Mansoura, Egypt

3 Faculty of Oral and Dental Medicine, Delta University for Science and Technology, Gamasa, Mansoura, Egypt

## References

- [1] Brook AH, Jernvall J, Smith RN, Hughes TE, Townsend GC. The dentition: The outcomes of morphogenesis leading to variations of tooth number, size and shape. *Australian Dental Journal*. 2014;**59**(Suppl 1):131-142
- [2] Yamanaka A, Iwai H, Uemura M, Goto T. Patterning of mammalian heterodont dentition within the upper and lower jaws. *Evolution and Development*. 2015;**17**:127-138

- [3] Jussila M, Thesleff I. Signaling networks regulating tooth organogenesis and regeneration, and the specification of dental mesenchymal and epithelial cell lineages. *Cold Spring Harbor Perspectives in Biology*. 2012;**4**:a008425
- [4] Al-Johany SS. Tooth numbering system in Saudi Arabia: Survey. *The Saudi Dental Journal*. 2016;**28**:183-188
- [5] Eugênio OS. *Anatomia e Escultura Dental: Teoria e Prática de Ensino*. São Paulo: Editora Santos; 1995
- [6] Nelson S. *Wheeler's Dental Anatomy, Physiology and Occlusion*. 10th edition. Philadelphia: 15 Saunders; 2014. p 392
- [7] Fuller J, Denely G, Schulein T. *Concise Dental Anatomy and Morphology*. 4th edition. Chicago: Book Medical Publishers Inc; 2001. p 218
- [8] Scheid R, Weiss G. *Woelfel's Dental Anatomy*. 8th edition. Philadelphia: Wolters Kluwer Health; 2012. p. 504
- [9] Vertucci FJ. Root canal anatomy of the human permanent teeth. *Oral Surgery, Oral Medicine, Oral Pathology*. 1984;**58**:589-599
- [10] Saffar JL, Lasfargues JJ, Cherruau M. Alveolar bone and the alveolar process: The socket that is never stable. *Periodontology 2000*. 1997;**13**:76-90
- [11] Hagag G, Yoshida K, Miura H. Occlusion, prosthodontic treatment, and temporomandibular disorders: A review. *Journal of medical and dental sciences*. 2000;**47**:61-66



---

# **The Permanent Maxillary and Mandibular Premolar Teeth**

---

Işıl Çekiş Nagaş, Ferhan Eğilmez and  
Bağdagül Helvacioğlu Kivanç

Additional information is available at the end of the chapter

<http://dx.doi.org/10.5772/intechopen.79464>

---

## **Abstract**

The permanent premolar teeth are placed between the anterior teeth and molars. Eight premolars are found in the permanent dentition, four per arch and two in each quadrant. The main function of premolars is to assist the canines in regard to tear and pierce the food and supplement the grinding of the molars during mastication. The other functions are to support the corners of the mouth reinforce esthetics during smiling and maintain the vertical dimension. Detailed morphology of the permanent premolar teeth is narrated in a pointwise and systematic manner in this chapter.

**Keywords:** teeth, premolars, dental anatomy

---

## **1. Introduction**

The premolars develop from four lobes with the exception of the mandibular second premolar which develops from five lobes. The facial surfaces of the premolars develop from three facial lobes like anterior teeth. Likewise, the lingual surfaces of most premolars develop from one lingual lobe like anterior teeth. While mandibular first premolars develop from four lobes (mesial, distal, buccal, and lingual) just like the anterior teeth and maxillary premolars, mandibular second premolars often develop from five lobes (mesial, buccal, distal, mesiolingual, and distolingual lobes). That is why the term “bicuspid” signifies “two cusps,” widely used to describe premolars, may be inappropriate for this group of teeth since the mandibular premolars may show a variation in the number of cusps from one to three. In anterior teeth, the lingual lobe forms the cingulum of the incisors and canines. However, in premolar teeth, this lobe forms the lingual cusps. The lingual cusps of mandibular premolars are less prominent

---

than the buccal cusps. There are no deciduous premolars. These teeth erupt at the position previously occupied by the deciduous molars.



Timing of teeth eruption can be affected by many factors such as gender, environmental factors and genetic conditions and differs from population to population [1–3]. The agenesis of lower second premolars and maxillary lateral incisors are the most frequent and it could be radiographically documented if the median age of emergence of these teeth was passed [1]. On the other hand, caries in primary molar teeth or early extraction of second primary molar could accelerate the eruption time of permanent premolars [1]. The classic sequences of teeth eruption in the maxillae is as follows: first molar, central incisor, lateral incisor, first premolar, canine, second premolar and second molar whereas in the mandible, central incisor, first molar, lateral incisor, canine, first premolar, second premolar and second molar [2]. In addition, generally, in girls, the maxillary canine can be expected before the second premolar, and the mandibular second premolar can be expected before second molar; in boys both orders are reversed [3].

The detailed descriptions of morphologies of from all aspects, chronology of development, form and function, the common characteristics of the permanent premolar teeth were presented in this chapter. In addition, the major differences between these teeth were given in a pointwise and systematic manner [4–11].

## 2. The permanent maxillary premolars

### 2.1. Permanent maxillary first premolars

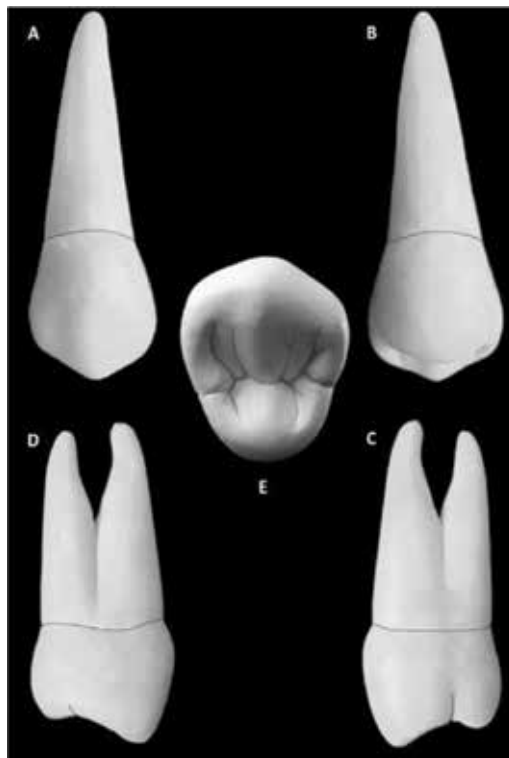
The maxillary first premolar is the fourth permanent tooth from the median line in the maxillary arch, located laterally from both the maxillary canines of the mouth but mesial from both maxillary second premolars. It is the first posterior tooth. Chronologic development of the maxillary first premolar is given in **Table 1**.

In the universal system of notation, the right permanent maxillary first premolar is shown as “#5,” and the left one is shown as “#12.” According to the international notation, the right permanent maxillary first premolar is shown as “14,” and the left one is shown as “24.” Besides, in the Palmer notation, the right permanent maxillary first premolar is symbolized as “,” the left one is symbolized as “.

The image of maxillary first premolar from all aspects is seen in **Figure 1**. A. Buccal, B. Lingual, C. Mesial, D. Distal, E. Occlusal.

Development stage	Years
Initiation of calcification	1 ½–1 ¾ years
Enamel completion	5–6 years
Eruption	10–11 years
Root completion	12–13 years

**Table 1.** Chronologic development of the maxillary first premolar teeth.



**Figure 1.** Maxillary first premolar tooth from different aspects. A. Buccal, B. Lingual, C. Mesial, D. Distal, E. Occlusal.

The buccolingual dimension is higher than the mesiodistal dimension. The buccal, lingual, and distal surfaces of the crown display convexities in different degrees.

#### *2.1.1. Buccal aspect*

The pentagonal or trapezoidal shape of the crown is noticeable from the facial aspect. With this form of the crown, the permanent maxillary first premolar appears to be similar to those of the maxillary canine and second premolar. While the canine has a larger size crown with a more prominent cusp tip, the second premolar has a smaller crown with a less prominent cusp tip. Additionally, the crown is smaller in the cervico-occlusal dimension than any anterior tooth, but larger than that of the second premolar or permanent molars. The greatest mesiodistal width of the crown is about 2 mm less at the cervical region.

The buccal surface is convex with the exception of the developmental depressions. The well-developed middle buccal lobe forms a continuous ridge from the tip of the buccal cusp to the cervical margin. This ridge is called as “buccal ridge” and demarcates the three developmental lobes. Mesiobuccal and distobuccal developmental depressions exist on both mesial and distal sides of the buccal ridge. These depressions divide the occlusal portion of the buccal surface into vertical thirds, consisting of mesiobuccal, distobuccal, and buccal lobes. Mesiobuccal and distobuccal lobes serve to emphasize strong mesiobuccal and distobuccal line angles on the crown. The imbrication lines are in parallel and semicircular forms and also common in the cervical third of the buccal surface.

From this aspect, cervical line of the crown is convex. In addition, the curvature depth is less at the cervical margin of the crown than those of anterior teeth. The crest curvature of the cervical line is almost placed at the center of the root.

The mesial contour of the crown presents a shallow concavity extending from the cemento-enamel junction to the mesial contact area. The highest contour of mesial curvature is at the contact area and located near the junction of the occlusal and middle thirds. The mesial margin of the buccal cusp is lying from the contact area to the tip of the buccal cusp and it creates the mesio-occlusal angle. This margin is less curved and longer than the distal slope of the buccal cusp.

The buccal cusp tip is placed slightly toward the distal. Therefore, unequal two portions are seen at the buccal aspect of the crown of occlusal outlines. A concavity or notch may be observed as a result of the developmental depressions passing over the occlusal margin.

The distal contour of the crown presents more concave and straighter form below the cemento-enamel junction than that of mesial contour. The crest curvature of the distal contact area is located slightly more occlusally.

#### *2.1.2. Lingual aspect*

The tooth is narrower mesiodistally at the lingual than at the buccal. Therefore, the crown converges toward the lingual cusp. The lingual ridge is barely defined. Both the buccal and lingual cusp tips are visible from this aspect, since the lingual cusp is shorter than the buccal cusp. The lingual cusp of the maxillary first premolar is the shortest of the four maxillary premolar cusps.

The lingual portion of the crown is convex and has a spheroidal form. The cervical line at this aspect is regular, with symmetrical curvature toward the root and the crest of curvature is centered on the root. The proximal outlines of the crown at the lingual aspect are convex. These outlines are convex and continuous with the mesial and distal slopes of the lingual cusp. If the tooth presents the severe mesial concavity, the mesial outline may be concave.

The lingual cusp tip is situated well anterior (mesial) to the mid-buccolingual diameter of the crown, so the two cusp tips are not placed on the same axis. This cusp tip is not as sharply pointed as the buccal cusp tip. The mesio-occlusal slope of the lingual cusp is shorter than the disto-occlusal slope.

The developmental depressions, grooves, or pits are normally not found on the lingual surface.

#### *2.1.3. Mesial aspect*

From the proximal aspects, all maxillary posterior teeth are present in trapezoidal geometric form. The buccal cusp is longer than the lingual cusp by 1 mm or occasionally more. Well-marked mesial and distal ridges are seen in both cusps. The mesial surface of the crown displays a concavity toward the cemento-enamel junction. This concavity extends cervically on the mesial surface and joins a deep developmental depression of the root area. This mesial developmental depression is sometimes called "the canine fossa" and located cervically to the mesial contact area. There is a groove called "mesial marginal groove," that is usually present on the mesial

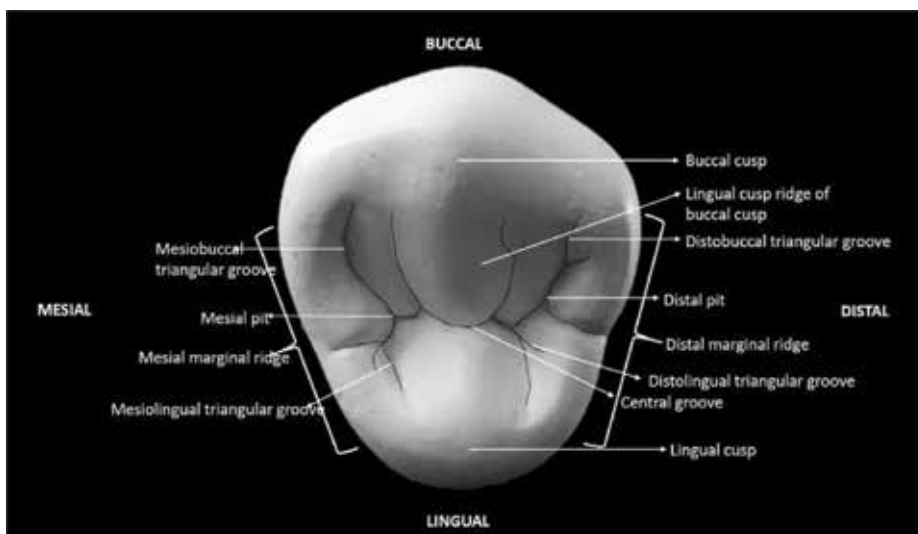
surface of the crown. This groove extends across the mesial marginal ridge from the occlusal surface. Mesial developmental depression and mesial marginal groove are the specific landmarks of maxillary first premolars that help to distinguish the maxillary first premolar tooth from the maxillary second premolar. The facial contour of the crown is convex with the height of contour located at the junction of cervical and middle third. The lingual contour is also convex form of an even arc, with its crest of contour located within the middle third of the crown. The occlusal margin is formed by the mesial marginal ridge. This margin is slightly concave.

#### 2.1.4. Distal aspect

From the distal aspect, a maxillary first premolar tooth is remarkably similar to the mesial view, except this side of the crown is slightly shorter occlusocervically. There are also other differences including the general convexity of the distal surface at all directions. This surface does not exhibit the concavity, which is present on the mesial surface. However, there may sometimes be a flattening in the cervical of the contact area and buccal of the center of the distal surface. Moreover, the curvature of cervical line is occlusally less on the distal than on the mesial. The buccal outline is convex. Buccal crest curvature is in the gingival third. The lingual outline is symmetrically convex with the lingual crest curvature that is in the middle third. The distal marginal ridge is located at a more cervical level. There is normally no deep developmental groove crossing the distal marginal ridge. In the rare instances when it is present, it is shallow and insignificant.

#### 2.1.5. Occlusal aspect

The schematic description of the occlusal table is given in **Figure 2**. From the occlusal aspect, the maxillary first premolar can be described as hexagonal or six-sided figure. This form is made up of the mesiobuccal, mesial, mesiolingual, distolingual, distal, and distobuccal sides.



**Figure 2.** The schematic description of the occlusal table of the maxillary first premolar tooth.

The crown is wider buccolingually than mesiodistally. In addition, the mesiobuccal and distobuccal sides are almost equal, whereas the mesial side is shorter than the distal side, and the mesiolingual side is shorter than the distolingual side.

The outline of the crown at the buccal surface is generally convex. The prominent buccal ridge contributes to this convexity. However, when the buccal developmental depressions are deep, they may create slight concavities in the outline on the mesiobuccal and distobuccal sides of the buccal ridge.

The lingual outline is almost equally convex in semicircular arch form. Mesial and distal margins are relatively straight, and they converge toward the lingual. If the mesial marginal groove is prominent, a dip might be seen in the mesial outline of the crown.

#### 2.1.5.1. Occlusal table components

The cusp ridges and marginal ridges limit the occlusal surface of the maxillary first premolar. Two cusps (buccal and lingual) are placed at the occlusal table. The buccal cusp is generally sharper, longer, and wider than the lingual cusp. On the buccal cusp, the buccal ridge descends from the cusp tip cervically to the buccal surface. The mesial and distal ridges descend from the cusp tip to their respective point angles. The buccal cusp has four inclined planes. These planes are called as mesiobuccal inclined plane, distobuccal inclined plane, mesiolingual inclined plane, and distolingual inclined plane. During the active occlusion, the lingual inclines of the buccal cusps of the maxillary posterior teeth determine the path of the supporting cusps during normal lateral and protrusive working excursions.

The lingual cusp is generally smaller than the buccal cusp. The lingual cusp tip is offset toward the mesial. The lingual cusp ridge extends from the cusp tip lingually to the central area of the occlusal surface. This cusp also presents four cusp ridges and four inclined planes located and named in the same manner as those of the buccal cusp.

The crest of the distal contact area is somewhat buccal to that of the mesial contact area, and the crest of the buccal ridge is somewhat distal to that of the lingual ridge. The crests of curvature represent the highest points on the buccal and lingual ridges and the mesial and distal contact areas. When two triangular ridges join, after traversing the tooth buccolingually, they form a “*transverse ridge*.” The union of the two triangular ridges forms this transverse ridge. In other words, the lingual cusp ridge of the buccal cusp and the buccal cusp ridge of the lingual cusp form the transverse ridge of the occlusal surface.

From the occlusal aspect, close observation reveals that the mesiodistal dimension of the crown is narrower than the buccolingual dimension. The major structures, pits, and grooves are the primary anatomic features. The supplemental grooves are not present in most cases on the occlusal surface of maxillary first premolar teeth. For this reason, the occlusal surface is relatively smooth. A well-defined “*central developmental groove*” divides the surface buccolingually. A “*mesial marginal developmental groove*” extends from the central developmental groove and crosses the mesial marginal ridge and ends on the mesial surface of the crown.

Two developmental grooves connect to the central groove inside the mesial and distal marginal ridges. These grooves are the “*mesiobuccal developmental groove*” and the “*distobuccal developmental*

groove." The connections of the grooves are located at opposite ends of the central developmental groove, and deeply pointed. These grooves usually end in a deep depression in the occlusal surface called the "*mesial*" and "*distal developmental pits*."

The triangular depression that harbors the mesiobuccal developmental groove is located just distal to the mesial marginal ridge and called the "*mesial triangular fossa*." Likewise, the depression in the occlusal surface, just mesial to the distal marginal ridge, is called the "*distal triangular fossa*."

#### 2.1.6. Root

Root contour form of the maxillary first premolar from the buccal aspect still bears a close resemblance to the maxillary canine. However, it is about 3–4 mm shorter than maxillary canine. The maxillary first premolar tooth with two roots presents a smooth and convex lingual root with a blunter root apex than the buccal root apex. The root trunk is flattened at this aspect above the cervical line. The bifurcation of the roots is located near the apical third, with no developmental groove.

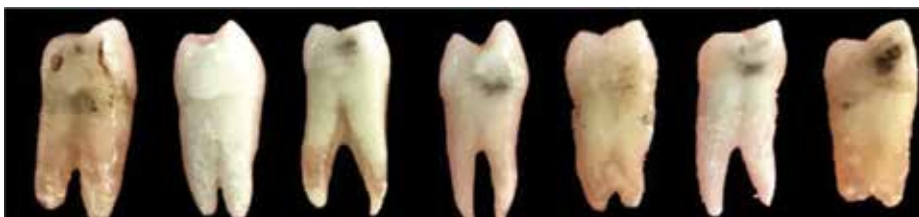The average measurements of the maxillary first premolar are shown in **Table 2**.

The average measurements of the maxillary first premolar (in mm)							
Cervico-occlusal length of crown	Length of root	Mesiodistal diameter of crown	Mesiodistal diameter of crown at cervix	Buccolingual diameter of crown	Buccolingual diameter of crown at cervix	Curvature of cervical line-mesial	Curvature of cervical line-distal
8.5	14.0	7.0	5.0	9.0	8.0	1.0	0.0

**Table 2.** The average measurements of the maxillary first premolar teeth. Variations: The crown and root of this tooth exhibit some variations (**Figure 3**).

## 2.2. Permanent maxillary second premolars

The permanent maxillary second premolar is the fifth tooth from the midline. The maxillary second premolars closely resemble the maxillary first premolar and supplement the latter in function. The maxillary second premolar tooth shares a mesial contact with the maxillary first premolar and a distal contact with the maxillary first molar. This tooth is a succedaneous tooth, replacing the deciduous maxillary second molar. Chronologic development of the maxillary second premolar is given in **Table 3**.



**Figure 3.** The crown and root variations of the maxillary first premolar teeth.

Development stage	Years
Initiation of calcification	2
Enamel completion	6–7
Eruption	10–12
Root completion	12–14

**Table 3.** Chronologic development of the maxillary second premolar teeth.

In the universal system of notation, the right permanent maxillary first premolar is shown as “#4,” and the left one is shown as “#13.” According to the international notation, the right permanent maxillary first premolar is shown as “15,” and the left one is shown as “25.” Besides, in the Palmer notation, the right permanent maxillary first premolar is symbolized as “5┘” while the left one is symbolized as “┘5.”

The crown of the maxillary second premolar has a less angular appearance, giving a more rounded effect than the maxillary first premolar. In addition, the crown is usually smaller in cervico-occlusal and mesiodistal dimensions. It has two cusps of nearly same size. The second premolars also vary from the first premolars in that they generally have single root. Usually, the root length of the maxillary second premolar is almost similar with that of the first premolar. More variations are observed with second premolar teeth.

The image of maxillary second premolar from all aspects is seen in **Figure 4**; A. Buccal, B. Lingual, C. Mesial, D. Distal, E. Occlusal.

#### 2.2.1. Buccal aspect

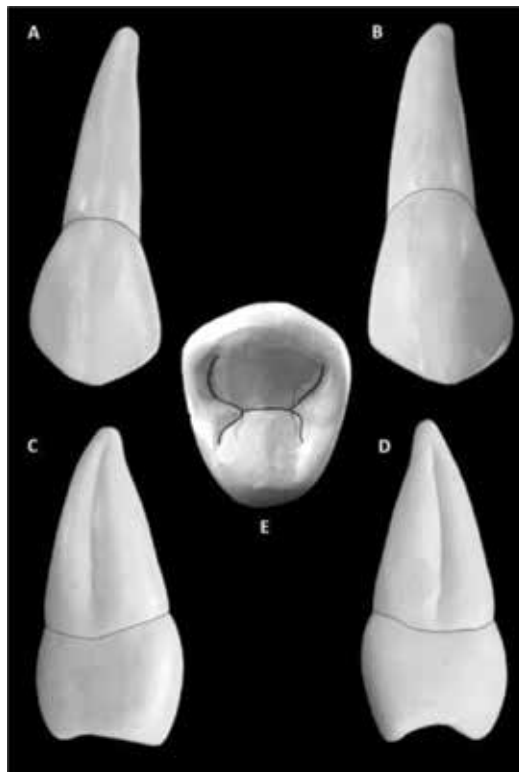
From the buccal view, the crown of the maxillary second premolar has a trapezoidal form. The buccal cusp of the second premolar is not as long as that of the first premolar. In addition, the buccal cusp appears to be less pointed. The mesial outline of the crown is slightly convex from cervix to the point where it joins the mesial slope of the buccal cusp. The distal outline is more convex than the mesial outline. The cervical outline on buccal view is slightly convex and curves in an apical direction. The tooth is thicker at the cervical portion than the maxillary first premolar.

The cusp tip is offset to the mesial; hence, the mesio-occlusal slope of the buccal cusp ridge is slightly shorter than the disto-occlusal slope. The opposite is true for the first premolar. The buccal ridge of the crown may be less prominent than that of the first premolar.

#### 2.2.2. Lingual aspect

The crown of the maxillary second premolar has a trapezoidal form at the lingual aspect. From the lingual view, little variation can be seen except that the lingual cusp is almost having the same length as the buccal cusp. In addition, the lingual cusp tip is not quite so far offset to the mesial. The cervical outlines of the crown at this aspect present that the cervical line is less





**Figure 4.** Maxillary second premolar tooth from different aspects. A. Buccal, B. Lingual, C. Mesial, D. Distal, E. Occlusal.

curved apically than the buccal view. The occlusal outline is formed by the lingual cusp tip and its cusp slopes.

#### *2.2.3. Mesial aspect*

The mesial aspect shows the difference in cusp length between the first and second premolars. The cusps of the second premolar are shorter, with the buccal and lingual cusps more nearly the same length. Greater distance between the cusp tips widens the occlusal surface buccolingually.

Developmental depressions are not seen on the mesial surface of the crown as on the first premolar. The crown surface is convex. A shallow developmental groove appears on the single tapered root. There is no canine fossa or canine groove on this surface. The more equal size of the cusps is also noted. Both the contact area and marginal ridge are found at a slightly more cervical level than on the mesial of the first premolar.

#### *2.2.4. Distal aspect*

The distal view of the second premolars has the same features with the first premolars. Since the distal contact of second premolar is with the first molar, the contact area is slightly larger in

size, when compared to the first premolar. Both the distal contact area and marginal ridge are located at a slightly more cervical level than on the distal of the first premolar. The distal root depression is deeper than the mesial depression on the maxillary second premolar.

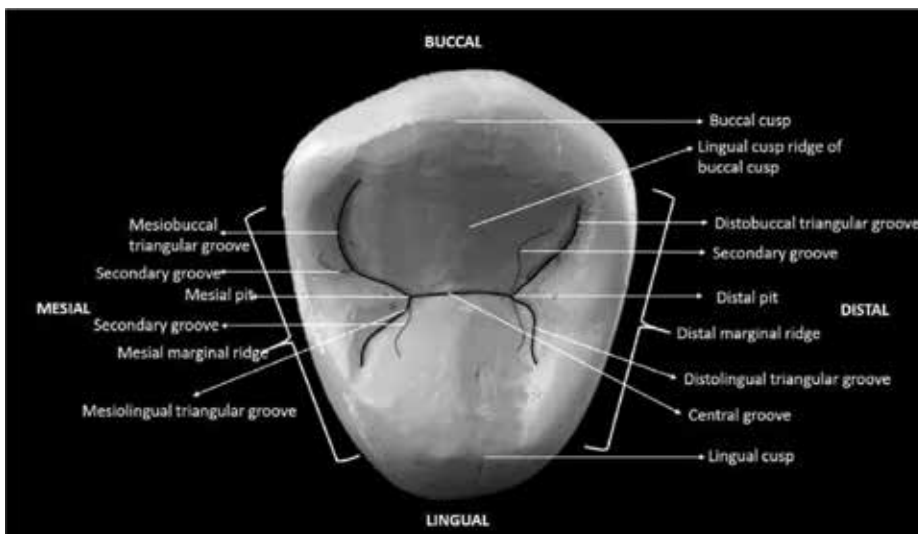
### 2.2.5. Occlusal aspect

The schematic description of occlusal table is given in **Figure 5**. The outline of the crown of the second premolar is more rounded or oval rather than hexagonal shape at this aspect. However, there may be some exceptions about this form. More distance between the cusp tips buccolingually than on the first premolar may be noted. Hence, the lingual cusp is almost as wide as the buccal. The grooves are shorter, shallower, and more irregular than in the first premolar. The central developmental groove is also shorter and more irregular. This groove has numerous supplementary grooves radiating from the central groove. This arrangement gives the occlusal surface a more wrinkled appearance.

### 2.2.6. Root

The root is usually single and shows a longitudinal groove on the mesial and distal surfaces, but may occasionally be double. The distal root depression is deeper than the mesial depression on the maxillary second premolar. Division of the root of the second premolar is rare; in about 15%. Root length is normally as great, or slightly greater than the root structure of the first premolar. The root is wider buccolingually than mesiodistally. It is often deflected slightly to the distal in its apical portion.

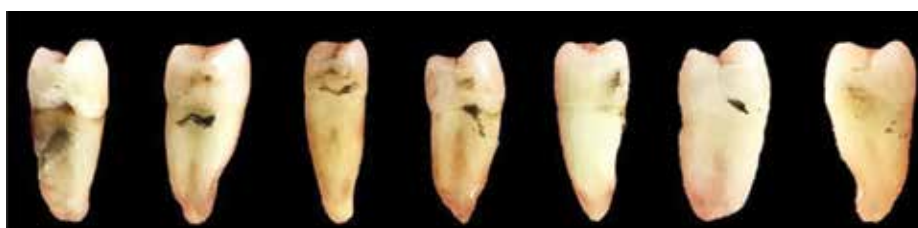The average measurements of the maxillary second premolar are shown in **Table 4**.



**Figure 5.** The schematic description of occlusal table of the maxillary second premolar tooth.

The average measurements of the maxillary second premolar (in mm)							
Cervico-occlusal length of crown	Length of root	Mesiodistal diameter of crown	Mesiodistal diameter of crown at cervix	Buccolingual diameter of crown	Buccolingual diameter of crown at cervix	Curvature of cervical line-mesial	Curvature of cervical line-distal
8.5	14.0	7.0	5.0	9.0	8.0	1.0	0.0

**Table 4.** The average measurements of the maxillary second premolar teeth. Variations: The crown and root of this tooth also exhibit variations and anomalies (**Figure 6**).





**Figure 6.** The crown and root variations of the maxillary second premolar teeth.

### 3. The permanent mandibular premolars

#### 3.1. Permanent mandibular first premolars

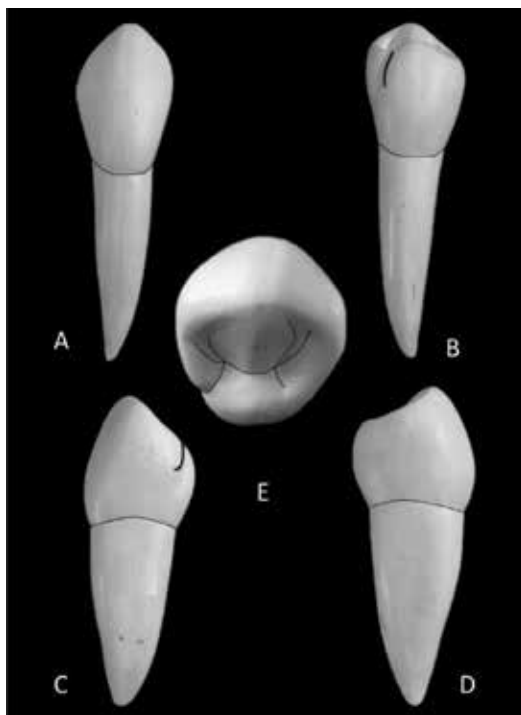
Chronologic development of the permanent mandibular first premolar is given in **Table 5**.

In the universal system of notation, the right permanent mandibular first premolar is shown as “#28,” and the left one is shown as “#21.” According to the FDI notation, the right permanent mandibular first premolar is shown as “44,” and the left one is shown as “34.” Additionally, in the Palmer notation, the right permanent mandibular first premolar is symbolized as “,” the left one is symbolized as “.

The image of mandibular first premolar from all aspects is given in **Figure 7**. A. Buccal, B. Lingual, C. Mesial, D. Distal, E. Occlusal.

Development stage	Years
Initiation of calcification	1 ¾–2 years
Enamel completion	5–6 years
Eruption	5–6 years
Root completion	10–13 years

**Table 5.** Chronologic development of the mandibular first premolar teeth.



**Figure 7.** Mandibular first premolar tooth from different aspects. A. Buccal, B. Lingual, C. Mesial, D. Distal, E. Occlusal.

### 3.1.1. Buccal aspect

The mandibular first premolar is similar to a mandibular canine and second premolar from buccal aspect. It has nearly same buccolingual measurement as a canine and has a sharp buccal cusp. The occlusocervical dimension of this tooth is less than all anterior teeth. However, this dimension is greater than that of the second premolar or any molar.

The buccal surface of mandibular first premolar is convex both occlusogingivally and mesiodistally. The crown is inclined lingually, and therefore, the tip of the buccal cusp is situated on the vertical axis of the root. The buccal height of contour is in the cervical third level of the surface. There is well-developed middle buccal lobe (buccal ridge) between the developmental depressions in mesiobuccal and distobuccal sides. The mesial cusp ridge is shorter than the distal cusp ridge.

The contour of the mesial margin is concave from the contact area to the cervical line joining the mesio-occlusal slope to create the mesio-occlusal angle. The outline continuing from the contact area to the cusp is convex. The height of contour (mesial contact area) is in the middle third at the center of the crown cervico-occlusally.

The distal margin is slightly shorter than mesial margin. In addition, the outline is concave from the contact area to the cervical line and the contact area is broader than the mesial contact

area. The height of contour (distal contact area) is approximately at the same level with the mesial contact area.

The buccal cervical line is slightly curved toward the apex and in comparison with the anterior teeth; the depth of curvature is less than that of the anterior teeth.

The buccal cusp tip divides the occlusal outline into two portions, the mesio-occlusal and disto-occlusal slopes, or mesial and distal cusp ridges. The disto-occlusal cusp ridge is longer than mesio-occlusal, moving the sharp cusp tip toward the mesial. Besides, both of the ridges are slightly concave.

### 3.1.2. *Lingual aspect*

Since the lingual cusp is smaller and shorter than buccal cusp, the buccal section of the occlusal surface could be seen from the lingual aspect. In addition, the crown is narrower mesiodistally on the lingual surface than on the buccal surface. Therefore, most of the mesial and distal parts could be seen from this aspect. This surface is convex in all directions and no ridge is present as seen on the buccal aspect. The lingual height of contour is in the middle third level of the surface.

The most characteristic feature of this tooth is the mesiolingual developmental groove between mesial marginal ridge and lingual cusp.

Since the lingual surface is shorter than buccal surface, both margins are shorter in lingual surface than buccal surface. Different from other teeth, mesial marginal ridge of mandibular first premolar teeth is shorter than distal marginal ridge. Additionally, mesial contact area is more cervically located than distal contact area.

The lingual cervical line is slightly curved toward the apex and narrower than buccal cervical line.

The lingual cusp tip and ridges are approximately at same level with the occlusal surface. Both of cusp tips are mesially offset, and the lingual cusp tip is in alignment with the buccal triangular ridge. There are mesial and distal occlusal fossae on each sides of occlusal surface.

### 3.1.3. *Mesial aspect*

Similarly with all the mandibular posterior teeth, the crown is in rhomboidal shape from the mesial aspect. While the buccal cusp is centered over the root, the lingual cusp tip is aligned with the lingual border of the root.

The buccal outline is convex starting from the cervical line to the buccal cusp tip. In addition, the height of contour is in the cervical third of the crown.

When compared with the buccal outline, this outline has more convexity. This margin is shorter than buccal margin. The lingual height of contour is at the middle third of crown. The “*mesiolingual developmental groove (mesial marginal groove)*” is visible from mesial aspect near the lingual margin.

The cervical line is slightly curved about 1 mm toward the occlusal surface. The occlusal outline is a concave arc inclining lingually. In addition, the buccal section of the transverse ridge is sloping to the lingual direction at an approximately  $45^\circ$  angle.

### 3.1.4. Distal aspect

Similarly with the mesial aspect, the crown is in rhomboid shape. Additionally, buccal/lingual margins are similar. While there is no distolingual developmental groove, there is a distal marginal groove in this aspect of mandibular first premolar.

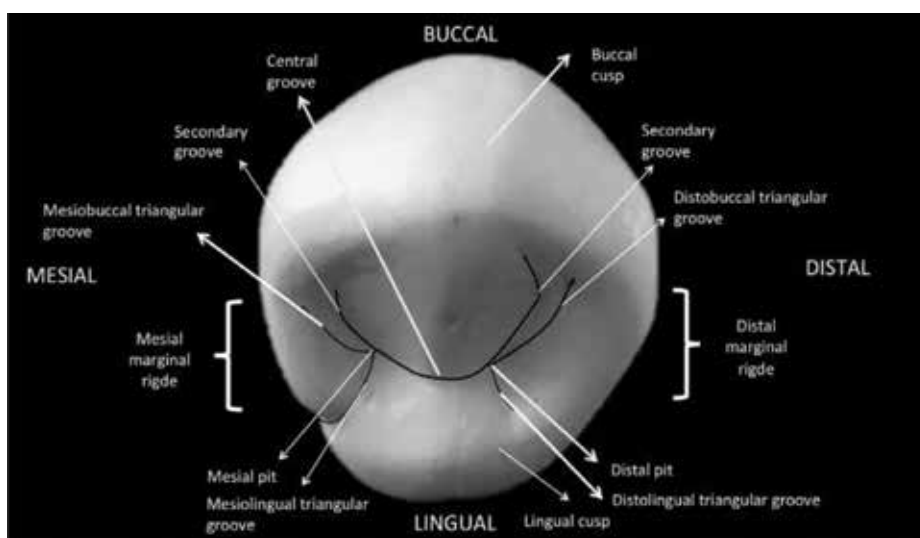
The cervical line on the distal surface has less curvature than mesial cervical curvature (less than 1 mm). The distal contact area is wider than the mesial contact area, since the contact tooth is second premolar.

The distal marginal ridge is not sloping lingually as the mesial. It is in a horizontal position, making the ridge perpendicular to the long axis of the tooth. It is located more occlusally than mesial marginal ridge.

### 3.1.5. Occlusal aspect

The schematic description of the occlusal table is given in **Figure 8**. The shape of the crown is rhomboid or like a diamond. Since the crown is lingually inclined, from this aspect, most of the buccal surface could be seen. The difference between buccolingual and mesiodistal dimension is approximately 0.5 mm. The cusp tip is in the mesial half, and therefore, the distal half is a little bit larger than the mesial half.

The buccal margin has a pronounced convexity. This outline is also convex. However, it is shorter than the buccal outline. It continues up to the mesiolingual developmental groove.



**Figure 8.** The schematic description of the occlusal table of the mandibular first premolar tooth.

The mesial marginal ridge has an angle less than 90° at the point that it connects with the mesiobuccal cusp ridge.

The convexity of the distal outline is more apparent than the mesial outline. It forms a right angle where it meets with the distobuccal cusp ridge.

#### 3.1.5.1. Occlusal table components

Mandibular first premolar has two cusps, a buccal and a lingual. The buccal cusp is the functional cusp, and it is larger than the lingual cusp. Additionally, the buccal cusp tip is slightly mesial to the center and located at the buccal half of the occlusal surface. The lingual cusp is very small and is like a tubercle. It is the nonfunctional cusp as it is a mandibular tooth. The crown converges lingually. The cusp has four cusp ridges as follows: *“mesiobuccal, distobuccal, mesiolingual and distolingual.”*

The *“buccal and lingual triangular ridges”* form the *“transverse ridge”* in the central groove area.

*“Mesial and distal marginal ridges”* are well-developed marginal ridges. Mesial marginal ridge is shorter and is interrupted by mesiolingual developmental groove. The distal marginal ridge is more prominent and joins with the distolingual cusp ridge.

*“Mesial and distal fossae”* are present on the occlusal surface. They are boarded by the transverse ridge, the marginal ridges, and the mesial and distal cusp ridges of the two cusps. While the mesial fossa is linear in shape with the mesial developmental groove, the distal fossa is more circular.

The *“central developmental groove”* connects the *“mesial pit”* to the *“distal pit.”* *“Mesiobuccal triangular groove”* extends from mesial pit in a mesiobuccal direction. Similarly, *“mesiolingual triangular groove”* extends from the mesial pit in a mesiolingual direction. *“Mesiolingual developmental groove”* is between mesial marginal ridge and mesiolingual cusp ridge. Similarly, with the mesial grooves, *“distobuccal triangular developmental groove”* extends from distal pit in a distobuccal direction, and *“distolingual triangular developmental groove”* has a distolingual direction starting from distal pit.

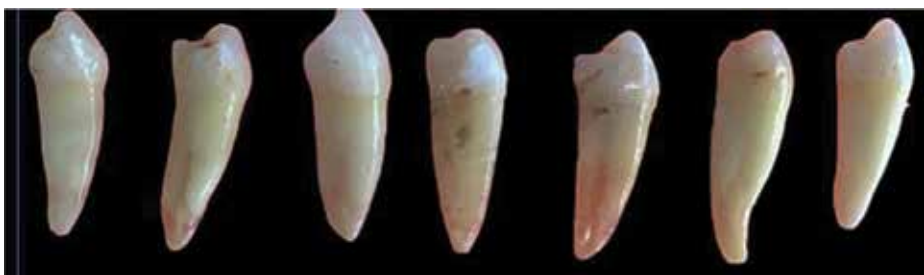#### 3.1.6. Root

In general, a mandibular first premolar has a single and straight root with a sharp apex. The root tapers from cervical to the apical region and is often curved distally. Rarely, a buccal and a lingual root or two buccal and one lingual root are present. The buccolingual section is wider than mesiodistal section. The height of contour of buccal surface is in the center of the root. The root is approximately 3 or 4 mm shorter than that of the mandibular canine. From the mesial aspect, the root is in a tapered form from the cervical line to the apical region. Despite the convexity in mesial and distal surfaces, longitudinal grooves are present in these surfaces, mostly deepest one in the mesial surface. The lingual surface is much narrower than buccal surface allowing most of the mesial and distal surfaces of the root to be seen. The convexity of distal surface is more prominent than mesial surface.

The average measurements of the mandibular first premolar are shown in **Table 6**.

The average measurements of the mandibular first premolar (in mm)							
Cervico-occlusal length of crown	Length of root	Mesiodistal diameter of crown	Mesiodistal diameter of crown at cervix	Buccolingual diameter of crown	Buccolingual diameter of crown at cervix	Curvature of cervical line-mesial	Curvature of cervical line-distal
8.5	14.0	7	5	7.5	6.5	1	0



**Table 6.** The average measurements of the mandibular first premolar teeth. Variations: The crown and root of this tooth exhibit some variations (**Figure 9**).



**Figure 9.** The crown and root variations of the mandibular first premolar teeth.

### 3.2. Permanent mandibular second premolar

Chronologic development of the mandibular second premolar is given in **Table 7**.

In the universal system of notation, the right permanent mandibular second premolar is shown as “#29,” and the left one is shown as “#20.” According to the FDI notation, the right permanent mandibular second premolar is shown as “45,” and the left one is shown as “35.” Furthermore, in the Palmer notation, the right permanent mandibular second premolar is symbolized as “” while the left one is symbolized as “.

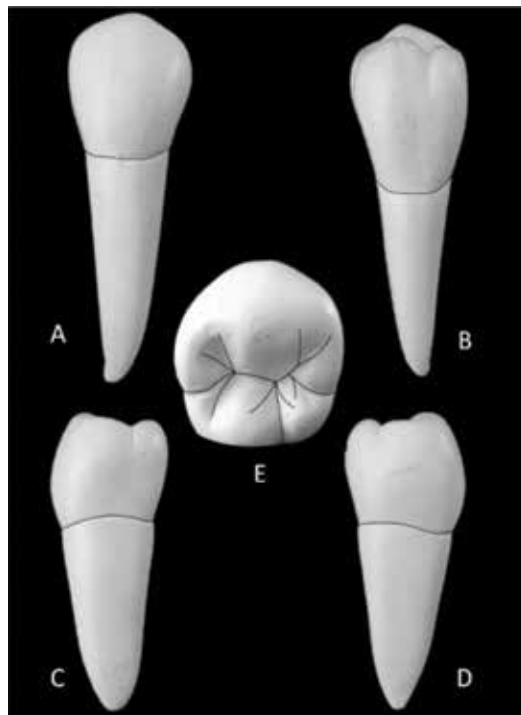
The image of mandibular second premolar from all aspects is seen in **Figure 10**. A. Buccal, B. Lingual, C. Mesial, D. Distal, E. Occlusal.

The mandibular second premolar is the fifth permanent tooth from the median line in the mandibular arch, located between the mandibular first premolars and first molars. Since the occlusal table is broader and similar to that of posterior teeth, this tooth has a function more like a molar.

Development stage	Years
Initiation of calcification	2.25–2.5 years
Enamel completion	6–7 years
Eruption	11–12 years
Root completion	13–14 years

**Table 7.** Chronologic development of the mandibular second premolar teeth.





**Figure 10.** Mandibular second premolar tooth from different aspects. A. Buccal, B. Lingual, C. Mesial, D. Distal, E. Occlusal.

Despite the similarities in general form of the second premolar with the first premolar, there are differences between them except buccal surface. There are two common forms: three-cusp type ("Y" groove pattern) exhibiting two lingual cusps and two-cusp type ("U" and "H" groove pattern).

#### *3.2.1. Buccal aspect*

Considering the buccal aspect, a mandibular second premolar has a larger crown and longer root than first premolar. The buccal cusp is not so long and not as sharp as first premolar. The cusp tip is approximately at the center of the tooth in mesiodistal direction, therefore the distobuccal and mesiobuccal slopes are equal in dimension.

The buccal surface is convex. Furthermore, mesial and distal outlines are convex except near the cervical region. The mesiobuccal and distobuccal cusp ridges are not angulated too much.

The contact areas in mesial and distal regions are situated at the middle third. Since the distal contact is a molar tooth, the distal contact area is broader than mesial contact. Additionally, the height of contour is similar to that of first premolar.

#### *3.2.2. Lingual aspect*

Since there are two different forms of mandibular second premolar, the lingual aspect of a second premolar has some variations. The lingual surface is convex and smooth. In addition, it

is slightly narrower and shorter than the buccal surface. However, this surface is wider and longer than that of first premolar. The mesial, distal, and cervical outlines are similar to first premolar. The lingual cusps are as high as buccal cusp; therefore, small part or none of the occlusal surface could be seen. The height of contour of the lingual surface is found approximately at the occlusal third of the crown.

#### 3.2.2.1. *Two-cusp type*

Two cusps—a buccal and a lingual—are present in this form. While no lingual groove exists in the lingual surface, a lingual depression could be found in the distal portion.

#### 3.2.2.2. *Three-cusp type*

In this type, there are mesiolingual and distolingual cusps, where the first one is the wider and the longer one. Distolingual cusp is often sharper than mesiolingual cusp. There is a “*lingual groove*” between the lingual cusps extending to the lingual surface.

#### 3.2.3. *Mesial aspect*

From the mesial aspect, the shape is rhomboidal like the proximal aspect of all mandibular posterior teeth. Besides, mesial surface is convex except the concavity situated near the gingival region.

This tooth is not inclined lingually as much as the first premolar. Therefore, the tip of the buccal is not centered over the root, usually located at the junction of the buccal and middle thirds. Besides, the lingual cusp is in alignment with the lingual surface of the root.

The buccal surface is more curved than lingual surface. The buccal height of contour is found slightly occlusal of the cervical line, and lingual height of contour is approximately at the occlusal third.

The mesial marginal ridge lies horizontally and is perpendicular to the long axis of the tooth. Additionally, it is located more occlusally than distal marginal ridge. Therefore, limited part of the occlusal surface is visible. There is no mesiolingual developmental groove.

The cervical line has a slight occlusal curvature.

In two-cusp type, while no lingual groove exists in the lingual surface, a lingual depression could be found in the distal portion. In three-cusp type, only the mesiolingual cusp could be seen from this aspect.

#### 3.2.4. *Distal aspect*

In three-cusp type, both of the mesiolingual and distolingual cusps are visible from this aspect. The distal surface is also convex and similar to the mesial surface except some differences:

- The distal marginal ridge is more concave and cervically located than mesial marginal ridge. Therefore, this surface is shorter than mesial occlusocervically. The occlusal surface could be seen from this aspect to a certain extent.

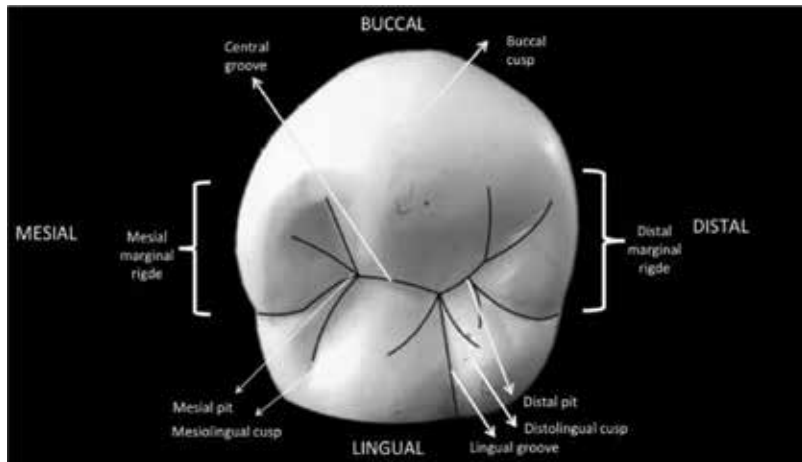
- The distal contact area is located similarly with the mesial contact. Since the distal contact is with the first molar, it is wider buccolingually than mesial contact area.

### 3.2.5. Occlusal aspect

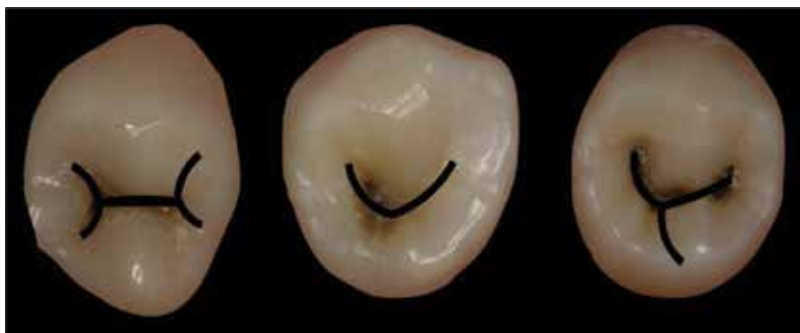The schematic description of the occlusal table is given in **Figure 11**. There are two common forms for the occlusal morphology of the mandibular second premolar. In both types of second premolars, there is “central groove” extending between mesial pit and distal pit.

#### 3.2.5.1. Three-cusp type

Three-cusp type is the more common and square-shaped one. It has a “Y” groove pattern (**Figure 12A**). The variation of groove patterns is presented in **Figure 12**. A. “H” groove pattern, B. “U” groove pattern, C. “Y” groove pattern.



**Figure 11.** The schematic description of the occlusal table of the mandibular second premolar tooth.



**Figure 12.** The variations of groove patterns of the mandibular second premolar tooth. A. “H” groove pattern, B. “U” groove pattern, C. “Y” groove pattern.

This type of mandibular second premolar has three cusps in the following order from largest to smallest: the buccal cusp, the mesiolingual cusp, and the distolingual cusp.

In both of the arches at the occlusal aspect, the tooth becomes narrower toward the lingual half and the distal half. However, three-cusp second premolars are an exception that the crown is wider in the lingual and distal half than the buccal and mesial half.

In three-cusp type, “*mesiolingual triangular groove, mesiobuccal triangular groove, mesial marginal groove, distolingual triangular groove, distobuccal triangular groove and distal marginal groove*” exist. Each of the cusps has “*mesial and distal cusp ridges*” and “*a triangular ridge*” connecting the cusp tip with the center of the occlusal surface. There are “*mesial and distal triangular fossae*.” Mesial triangular fossa originates from “*mesial pit*.” Distal triangular fossa originates from “*distal pit*.” The “*central pit*” is in the center of the occlusal surface in the three-cusp type.

There are three deep developmental grooves (mesial developmental groove, distal developmental groove, and lingual developmental groove) connecting at the central pit. “*Mesial developmental groove*” extends from the central pit to the mesial triangular fossa. “*Distal developmental groove*” runs from the central pit to the distal triangular fossa. “*Lingual developmental groove*” is lying between two lingual cusps.

### 3.2.5.2. Two-cusp type

Two-cusp type is more rounded and has a “*U*” or “*H*” groove pattern (**Figure 12B and C**). The buccal cusp is larger than lingual cusp. No central pit and lingual developmental groove exists. The buccal and lingual cusp triangular ridges connect and create a “*transverse ridge*.”

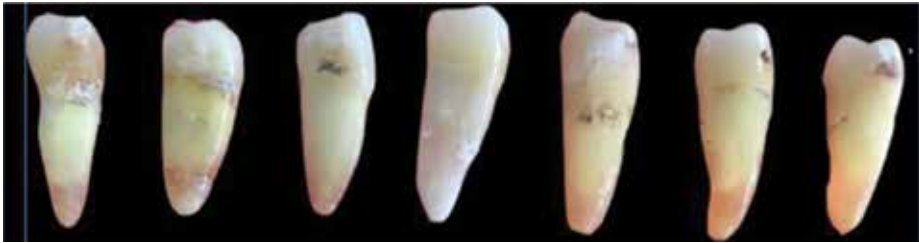### 3.2.6. Root

A mandibular second premolar has a single and tapered root having a curvature to the distal side. When compared with first premolar, the root is wider and longer than that of first premolar. The apex is inclined to distal side. Buccal surface is convex. There are longitudinal grooves on the proximal sides. In distal aspect, the longitudinal grooves are in the middle third. However, longitudinal depression is rarely seen on the mesial surface. The lingual surface is slightly convex and narrower than buccal surface. Some part of the mesial and distal sides of this tooth might be seen from this aspect.

The average measurements of the mandibular second premolar are shown in **Table 8**.

The average measurements of the mandibular second premolar (in mm)							
Cervico-occlusal length of crown	Length of root	Mesiodistal diameter of crown	Mesiodistal diameter of crown at cervix	Buccolingual diameter of crown	Buccolingual diameter of crown at cervix	Curvature of cervical line-mesial	Curvature of cervical line-distal
8	14.5	7	5	8	7	1	0

**Table 8.** The average measurements of the mandibular second premolar teeth. Variations: The crown and root of this tooth also exhibit some variations (**Figure 13**).



**Figure 13.** The crown and root variations of the mandibular second premolar teeth.

#### **4. The differences between maxillary and mandibular premolars**

There are several general characteristics, which aid in differentiating the maxillary premolars from other posterior teeth and mandibular premolars. The maxillary first and second premolars appear more alike than mandibular premolars. However, maxillary first premolar crowns are generally larger than the second premolars. In addition, in the mandible, the first premolar is considerably smaller than those. From mesial and distal aspects, mandibular premolar crowns appear to be tilted lingually relative to their roots, whereas maxillary premolar crowns are aligned more directly. Maxillary premolars possess two cusps of nearly equal size. The mandibular premolars may have more than two cusps, and the lingual cusps are normally less prominent than the facial cusps. The buccal cusp is longer than the lingual cusp/cusps in all premolar teeth. This difference is the most prominent for mandibular first premolars and the least prominent for maxillary second premolars. The maxillary first premolar frequently has two root branches, whereas the other premolars have one root.

#### **Author details**

Işıl Çekiç Nagaş<sup>1</sup>, Ferhan Eğilmez<sup>1</sup> and Bağdagül Helvacioğlu Kivanç<sup>2\*</sup>

\*Address all correspondence to: [bagdagulkivanc@gmail.com](mailto:bagdagulkivanc@gmail.com)

1 Department of Prosthodontics, Faculty of Dentistry, Gazi University, Ankara, Turkey

2 Department of Endodontics, Faculty of Dentistry, Gazi University, Ankara, Turkey

#### **References**

- [1] Almonaitiene R, Balciuniene I, Tutkuvienė J. Standards for permanent teeth emergence time and sequence in Lithuanian children, residents of Vilnius city. *Stomatologija*. 2012;**14**(3): 93-100

- [2] Kochhar R, Richardson A. The chronology and sequence of eruption of human permanent teeth in Northern Ireland. *International Journal of Paediatric Dentistry*. 1998;**8**(4):243-252
- [3] Almonaitiene R, Balciuniene I, Tutkuvienė J. Factors influencing permanent teeth eruption. Part one—general factors. *Stomatologija*. 2010;**12**(3):67-72
- [4] Scott JH, Symons NBB. *Introduction to Dental Anatomy*. 9th ed. New York: Butter & Tanner Ltd; 1982
- [5] Sicher H, Du Brul EL. *Sicher's Oral anatomy*. 7th ed. Mosby co. St. Louis; 1980
- [6] Berkovitz BKB, Holland GR, Moxham BJ. *Color Atlas & Textbook of Oral Anatomy Histology and Embryology*. 2nd ed. Mosby co. St. Louis; 1992
- [7] Brand RW, Isselhard DE. *Anatomy of Oral structures*. 7th ed. Mosby co. St. Louis; 2003
- [8] Scheid RC, Weiss G. *Woelfel's Dental Anatomy and Its Relevance to Dentistry*. 8th ed. China: Lippincott Williams and Wilkins; 2012
- [9] Nelson SJ. *Wheeler's Dental Anatomy, Physiology and Occlusion*. 10th ed. China: Elsevier Health Sciences; 2014
- [10] Fuller JL, Denehy GE, Schuelein TM. *Concise Dental Anatomy and Morphology*. 4th ed. USA: Univ of Iowa Office of State; 2001
- [11] Rashmi GS. *Textbook of Dental Anatomy, Physiology and Occlusion*. 1st ed. New Delhi: Jaypee Brothers Medical Publishers Ltd; 2014

---

## Dental Anatomy and Caries

---





---

## **Dental Anatomical Features and Caries: A Relationship to be Investigated**

---

Marcel Alves Avelino de Paiva,  
Dayane Franco Barros Manguiera Leite,  
Isabela Albuquerque Passos Farias,  
Antônio de Pádua Cavalcante Costa and  
Fábio Correia Sampaio

Additional information is available at the end of the chapter

<http://dx.doi.org/10.5772/intechopen.71337>

---

### **Abstract**

Dental caries is a multifactor disease affecting a significant number of people throughout the world. However, in recent decades the widespread availability of fluoride and other preventive measures have resulted in a decline in the prevalence of caries among children and young adults. Currently, it is accepted that most carious dental lesions are restricted to specific anatomical sites. The aim of this chapter is to review the influence of dental anatomy on dental caries development while taking into account recent findings in cariology. Occlusal fissures in the first permanent molar are generally the first sites in the permanent dentition to develop caries. An increased risk of caries is also found in proximal contacting surfaces between two adjacent teeth. Moreover, a partially erupted tooth, which does not participate in mastication, is also at risk for caries since it may provide a more favorable environment for bacterial accumulation than a fully erupted tooth. Bacterial biofilm on the tooth is frequently a high risk caries environment. Understanding anatomical dental features is of great importance for guiding oral health hygiene and preventive measures. Finally, the development of dental disorders plays an important role in dental caries risk.

**Keywords:** bacterial biofilm, dental anatomy, dental caries, dental morphology, tooth surfaces

---

## 1. Introduction

Dental caries affects a significant number of populations throughout the world as a multifactor disease that is by and large regarded as the most common chronic disease worldwide [1]. It is estimated that 90% of dental problems are due to caries. However, the prevalence of dental caries is variable and may be linked to cultural aspects, education level, income, and dietary habits.

The disease known as dental caries is generally defined as a “localized destruction of susceptible dental hard tissues by acidic by-products from bacterial fermentation of dietary carbohydrates” [1]. In this definition, two important etiological factors are presented: dietary carbohydrates and bacterial fermentation both need clarification concerning their *modus operandi*, and “localized destruction” of dental hard tissues is also a matter to be studied.

A remarkable study on diet and prevalence involving dental caries is performed 60 years ago by Gustafsson and co-workers [2]. Apart from the present perspectives concerning ethical issues when conducting clinical trials, the Vipeholm study clearly showed that dental caries are strongly tied to the availability of refined sugar. This was particularly evident for sugar intake between meals. It is important to point out that at the time, the scientific community was skeptical concerning the preventive effects of reductions of sugar intake on the formation of caries [3]. The idea that caries is not only a sugar-driven disease, but actually is a sugar-disease, has been strongly defended [4]. Assuming this hypothesis, certain researchers regard dietary sugars as the main cause for the development and establishment of caries.

In addition to sugar, the development of caries is clearly dependent on dental plaque activity. Recent advances regarding the process of dental decay have indicated that so-called “dental plaque” is in fact a “dental biofilm” [5]. The dental biofilm concept supports the idea of an organized microbial community. Thus, a change in nomenclature is not just toward a new name, but represents true conceptual modifications in several aspects. Today, bacterial biofilm is regarded as a sort of microcosm of bacteria and fungi both living and competing within a complex matrix. In order to support this point of view, caries is no longer seen as related to a single bacterium species. For many years, *Streptococcus mutans* the most relevant sugar-fermenting, acidogenic species was regarded as the main causative agent of dental caries. However, recent investigations have shown that dental caries are related to a significant and diverse ecosystem and surprisingly, *S. mutans* is just a small fraction of the bacterial community [5]. It is also important to consider that in most situations, the microorganisms of the dental biofilm are not pathogenic. In fact, certain bacteria are necessary since a “healthy” biofilm forms naturally on teeth and helps to avoid colonization by exogenous species. If refined sugar is available, bacterial acid production increases resulting in an immediate pH drop. Demineralization takes place in an acidic environment. Frequent cariogenic challenges result in mineral loss and development of carious lesions. Bacterial acid production and its consequences for the delicate balance between de- and re-mineralization had generally been assumed to be ecological phenomena [5, 6]. However, as already noted, it is the communal life itself as formed by these multiple microorganisms that collectively promotes carious lesion development.

Though dental caries is ubiquitous in many populations of the world, there is an evident decline in the prevalence of caries in many countries. This was quickly observed in industrialized and developing nations. The main reasons for this decline in caries is related to two factors: (a) the widespread use of fluoridated products, particularly through the effective introduction of fluoride in toothpastes and (b) individual commitment to oral hygiene habits, in other words, more people maintain reasonably good levels of oral hygiene throughout their lives [7, 8]. Yet surprisingly, in many countries where declines in caries were observed, sugar intake remained stable [9, 10].

The prevalence of dental caries is frequently measured by epidemiological indexes such as the DMFT. This index quantifies dental caries based on the number of carious or decayed (D), missing (M), or filled (F), teeth (T). The DMFT index does not provide information regarding carious attack severity, nor does it provide useful information concerning the surfaces of teeth where carious lesions occur. Therefore, the epidemiological index DMFS (decayed, missing, and filled by surface), and other forms of measurement have been proposed [11].

This decline in caries has raised certain interesting challenges for dental professionals. For many individuals of the same age, the progression of carious lesions is no longer as fast as previously recorded. Thus, simply recording caries as a cavitated lesion is no longer the study or clinical assessment end point. Further, there is now confusion in the terminology used in many studies dealing with caries (e.g., “caries diagnosis” versus “carious lesions detection”) [11, 12].

Dental caries can be scored in various levels of severity ranging from white spot lesions to full cavitation. Caries diagnosis can be considered a multiple step procedure, starting with identification of the candidate lesion (caries detection), followed by assessment of lesion severity, and finally, determination of lesion activity [12]. These are the main components guiding the establishment of an appropriate treatment plan (operative or non-operative) for contemporary primary or secondary caries management. Caries risk assessment, diagnosis, and synthesis (combining and interpreting findings) are considered to be the chief domains in Cariology, and the basis of clinical decision-making [13].

Currently, all research in dental caries prevention, development or treatment should on one hand, consider the influence of fluoride on the general decline in caries, and on the other hand evaluate the most relevant etiological factors. A third point concerning preventing dental caries must also be considered: a good understanding of dental anatomy. Complete recovery of tooth function can only be achieved if a good knowledge of dental anatomy is applied. In addition, the science of dental anatomy is also important for understanding carious risk to a specific tooth, or to specific areas within the mouth [14].

Dental caries is a disease mediated by biofilm and pH that affects people from all over the world. Sugar intake patterns are also important and may explain why some people have more caries than others. Caries may also affect socially vulnerable individuals more than those who can afford to maintain oral hygiene habits. As caries disproportionately affect certain groups of individuals, the same is true for certain groups of teeth. Why do caries affect molars more than incisors? Why are caries more prevalent in occlusal surfaces as compared to free and smooth surfaces? This is where dental anatomy and caries meet. The aim of this chapter is to review certain features of dental anatomy and their influence on the progression of dental caries.

## 2. Principles of cariology: dental caries reviewed

Cariology is generally known as the study of dental caries or tooth decay. Yet for many dental students, cariology is not a true clinical science, since it is (at least in most cases) presented only at the beginning of the undergraduate course, or merely as a research project. However, recent developments provide new perspectives to this field. Cariology is not confined to dental caries alone. Cariology includes research in dental hard tissues, dental wear (erosive/non-erosive), and dental hard tissue disorders [13]. This wider view of cariology opens new perspectives in dental education and research, being a strong motive for improving diagnostic skills, while treating and preventing carious lesions in more effective ways [15, 16].

### 2.1. Dental caries

Dental caries is ubiquitous worldwide. It is a sugar-driven, biofilm-dependent, multifactor disease, and in many aspects a dynamic process. The continuous presence of pathogenic oral biofilms is the main etiological factor for demineralization and as stated before, certain reports give emphasis to dietary sugars as the main cause for dental caries [4, 17–19]. However, other etiological factors cannot be neglected [20]. For instance, the presence of sugar alone on a free biofilm dental surface will not result in dental caries. Dental caries results from a shift in local environment acidity promoted by microbial metabolism on a tooth surface. Mineral loss on a tooth surface is so subtle in the beginning that even very sensitive techniques are unable to indicate when a carious dental lesion has started. Frequent mineral losses eventually become a pit or a small cavitation [21].

The major factors involved in the dental caries mechanism are well understood. Presently, it is accepted that dental biofilms play a central role in dental caries. Dental caries appear on the tooth only where dental biofilms are found. It is also true that demineralization is provoked by microorganism produced acids, and the degree of mineral loss is directly modulated by both the presence and activity of these dental biofilms. Demineralization can be interrupted or reverted toward remineralization (a mineral recovery process) when the biofilm is either partial or totally removed [22]. This is a time-dependent complex process not a single event. Dental caries is always described as a chronic and progressive demineralization of hard tissues that occurs in tooth surfaces underneath a microorganism layer.

The pathogenesis of dental caries is driven by the establishment of a dental biofilm and formation of an acidogenic environment [20–24]. Frequent de-mineralization events due to repeated cycles of lactic acid production will eventually cause severe dissolution of the tooth enamel or dentin. As a result, white spots begin to appear underneath pathogenic biofilms. In most cases, the process takes several months, but it can occur in few weeks if the tooth surface is exposed to extreme cariogenic challenges. Interestingly, just as the microbial composition of dental biofilms can shift as driven by diet, or through biofilm removal (oral hygiene), the microbial community can also vary from site-to-site within the mouth, as between individuals.

Clinical microbiology studies have demonstrated that Mutans streptococci, especially *S. mutans*, are more prevalent in children who have experienced dental caries during childhood [21]. Yet not all children who develop caries are colonized with Mutans streptococci. The observations provide a clear indication that dental caries are a result of a very complex

process influenced by the interplay of many variables such as oral microbiota, saliva, dietary patterns, and oral hygiene habits [25, 26]. The most recent consensus is that microbial diversity appears to be lower in diseased than in healthy individuals and may reflect the ecological pressure of lowered environmental pH [27].

In addition to the differences in microbial patterns between healthy and disease individuals, a recent observation in children showed that biofilms also differ according to the site of the tooth [28]. In other words, the environmental pH within dental biofilms can differ according to its location on the tooth. This scenario supports observations that dental morphology contributes to pathogenic biofilm development at certain tooth sites, and since salivary enzymes reach free-surface biofilms more easily than those located in dental fissures; the relationship becomes even more complex. Yet, it can be concluded that for dental caries there are predilection sites.

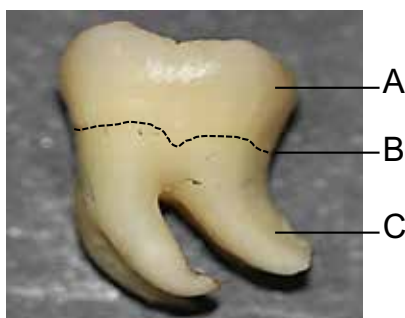
### 3. Dental morphology

Human dental anatomy presents many instances of biologic variation, and for future dental educational planning a greater number of examples of dental morphology variation should be used. The use of natural teeth for teaching is very important, but natural images can also help [29]. A simple investigation into the external morphology of the human tooth clearly shows three distinct parts:

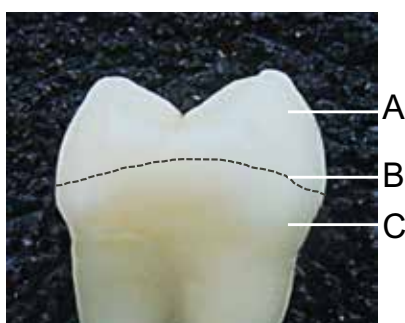
- a. Crown: the top part of the tooth covered in its external layer with enamel tissue. It is the only part you can normally see when someone is smiling, though a small part of it may be covered by the gums. The shape of the tooth's crown determines its function. The incisors and canine teeth are very sharp and chisel-shaped for cutting; premolars and molars have two or more cusps for grinding. The coronal part of the human tooth is composed of two hard tissues: enamel and dentin, this includes the dental pulp, located in the crown.
- b. Gumline: this is the part of the tooth between the crown and the root. It is where the gums meet the crown and the cemento-enamel junction is located. This line (also known as the cervical line) is easily visible to the naked eye due to the color difference between enamel and cementum.
- c. Root: this is the part of the tooth that is embedded in the bone. The root of a tooth makes up about two-third of its whole structure. It is covered with cementum.

These three parts of human teeth play distinct functions within the oral cavity (**Figure 1**). Their anatomical features, size, and shapes are directly related to their ability to tear and crush the food. Incisor and canine crowns have four surfaces and a ridge (a linear elevation on the surface of a tooth), whereas premolar and molar crowns have five surfaces. The surfaces are named according to their positions and functions. Interestingly, teeth exposed to very strong masticatory forces require greater support area. This explains why molars have three roots, whereas incisors have only one. In the oral environment, biting and chewing are very complex phenomena which are also connected to the form, size, and shape of the teeth [30, 31].

Human teeth present anatomical details related to their specific function during mastication, with depressions, elevations, concavities, and convexities. From the perspective of anatomical features, the crown of a tooth can be classified as having retentive and non-retentive areas.



**Figure 1.** Dental tooth major anatomical parts. (A) Crown; (B) cervical line; (C) root.



**Figure 2.** The equatorial line of a tooth. (A) Non-retentive area; (B) equatorial line; (C) retentive area.

The line that separates these areas is called the equatorial line. This is an imaginary line that can be drawn by circling the most convex surfaces of a tooth: the lingual, buccal, and proximal (**Figure 2**).

Considering homologous teeth, the equatorial and occlusal molar areas (surfaces close to equatorial lines) are on average larger in males than in females, though equatorial and occlusal outlines of homologous left and right molars within both sex, and arch (maxillary and mandibular) are similar, being without size and shape differences [32].

The vestibular (buccal) and lingual contour heights (curvature crest) are important to divert and prevent food from getting stuck in the gingival sulcus. The crest curvature is the anatomical point on tooth crown where a parallel line drawn toward the middle-root axis line touches the greatest convexity (protuberance). Contact areas between two teeth are known as proximal contour heights. The possibility of food impaction at these points is a matter of concern. In healthy individuals or in most cases, points of contact between any tooth and any adjacent tooth change with time. In young persons, the contact points of recently erupted teeth are true contact points. In adults, after many years of small and frequent movements, the tooth surfaces can be flattered because of mastication. It has been estimated that in an adult mouth of 40 years of age, approximately 10 mm of enamel have been worn off due to the contact area wear [30, 31].

Certain major anatomical features encountered when studying dental morphology are presented in **Table 1**.

Anatomical features	Definition
Cusp	Elevation or mound on the crown that makes up a divisional part of the occlusal surface of the tooth
Tubercle	Smaller elevation on some portion of the crown produced by an extra formation of enamel
Cingulum	Also known as “girdle” (Latin) is the lingual lobe of an anterior tooth. It makes up the bulk of the cervical third of the lingual surface. Its convexity mesiodistally resembles a girdle encircling the lingual surface at the cervical third
Ridge	Linear elevation on the surface of a tooth and is named according to its location (e.g., buccal ridge, incisal ridge, marginal ridge). Marginal ridges are those rounded borders of the enamel that form the mesial and distal margins of the occlusal surfaces of premolars and molars and the mesial and distal margins of the lingual surfaces of the incisors and canines
Sulcus	Long depression or valley in the surface of a tooth between ridges and cusps. A sulcus has a developmental groove at the junction of its inclines
Groove	Linear channel or sulcus
Fossa	Depression on the tooth surface
Embrasures	Open spaces between teeth and around a contact (e.g., occlusal (incisal) embrasures, buccal and lingual embrasures and gingival embrasures)

*Source:* Adapted from Scheid and Weiss [30] and Stanley and Major [29].

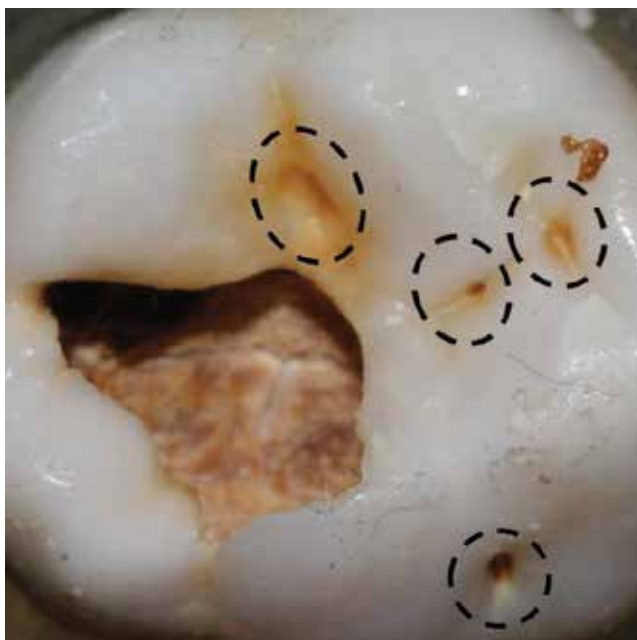**Table 1.** Some major anatomical characteristics and features of human dental teeth.

A complete description of dental features can be found in publications specifically concerning tooth anatomy. The difference between teeth groups, differences in nomenclature and detailed descriptions for each human tooth type are beyond the scope of this chapter. Further information on this topic can be found elsewhere [30, 31].

## 4. Dental anatomy and caries

Klein and Palmer were the first investigators to clearly describe relationships between dental caries and the various morphological tooth types [32, 33]. Their work provided the very useful information that mandibular molars were much more susceptible to carious attack than mandibular canines and incisors. Although it seems obvious currently, this information was collected when most American cities had a high prevalence of caries, and the upper incisors were frequently affected by carious lesions. For that time, these relationships were somewhat obscure. Today, it seems evident that occlusal surface irregularities can facilitate biofilm development and eventually result in carious lesions.

Depressions and grooves in the teeth are always anatomical points of concern for dental caries (**Figure 3**). For the clinician, great individual variation is found in the occlusal areas of the teeth, yet these occlusal areas and proximal contact points are generally the main focus of clinical examinations. The sulci of human teeth are generally V-shaped, and though in most cases, the toothbrush bristles can remove a good portion of biofilms in this area, certain debris and microbial biofilm will remain attached to the deeper parts of the sulcus.



**Figure 3.** Tooth depressions are always anatomical points for dental caries.

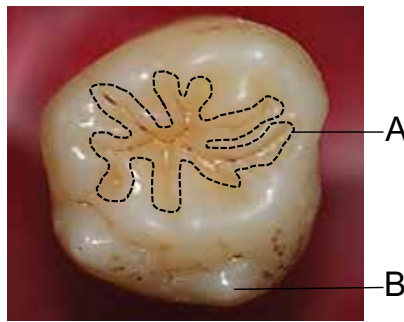
Certain researchers use the term “groove-fossa system” (**Figure 4A**) when describing depressions in the occlusal part of a tooth that is vulnerable to dental caries [34]. This is of particular importance in Pedodontics for identifying risk areas for caries in deciduous teeth and first permanent molars. The pit formed by junction of developmental grooves is a very interesting anatomical feature in the molar occlusal surface; a very “tricky” area for dental caries on the occlusal surface.

Hidden caries is a term used to describe occlusal dentine caries that are missed upon visual examination [35]. In most hidden caries cases, a tiny open cavity is located between grooves. Basically, the point occurs at the convergence of occlusal surface ridges that terminate at a central point in the bottom of the depression. It is a junction of grooves, also regarded as a small physiological-anatomical depression, and easy to verify as an attractive location for bacterial growth. As a result of constant deep demineralization, a cavity can appear below the resistant enamel. In general, its opening (aperture of the lesion) corresponds to a small pit formed in the central fossa between the triangular ridge and the transverse ridge [35].

The fifth cusp in the upper molars (also known as the Carabelli trait) is frequently observed during dental examination. It has received many different names such as: Carabelli trait, Carabelli tubercle, molar tubercle, enamel elevation, fifth cusp, accessory cusp, mesiopalatal prominence, and tuberculum anomalum [36]. It is less prevalent in Asians, but is most common in Europeans 85% or White Caucasians. Carious lesions are also frequently observed at this site (**Figure 4B**).

A very special landmark on mandibular first molars is the mesiobuccal groove. It is a sort of sulcus that stretches from the occlusal surface to the buccal surface, and is frequently





**Figure 4.** (A) The “groove-fossa system” of a posterior tooth. (B) The accessory cusp in an upper molar tooth.

neglected during dental exams. Although sometimes rather shallow, this narrow groove can harbor a small but active bacterial community which can easily provoke cavitation.

Microbial colonization is expected in areas where food impaction is frequent. Thus, all proximal areas below the contact point are favorable sites for food retention, biofilm development and caries. The truth is that together, all of the teeth groups (incisors, canines, premolars and molars) work harmonically toward breaking down food. After a good meal, it is evident that the anatomical features of the teeth have worked together harmonically for biting, crushing, and chewing foodstuffs. However, the shapes of the teeth and their position in the oral cavity may reveal certain gaps where food can accumulate. Other variables must also be considered such as the health status of the gums and the period of tooth eruption.

Normal tooth eruption, development and dental occlusion patterns reveal broad variations. However, certain common events are expected such as slow and irregular eruption of first molars in children and third molar eruption in adolescents and adults. The morphology of a tooth and its eruption time may carry a certain importance for the development of dental caries. Due to favorable conditions for plaque accumulation (biofilm formation), erupting teeth are more likely to develop dental caries. Further, there is also strong evidence that tooth anatomy may affect the likelihood of caries formation. Yet, how deep is the connection between these variables?

A very interesting study investigated the morphology of erupting third mandibular human molars including histological caries features and whether the morphology of interlobal grooves influences specific microorganism viability [37]. A total of 116 buccolingual sections of 22 teeth were examined, and the mesiodistal interlobal groove was classified as either “fissure-like” or “groove-like”. “Fissures” were less prone to caries than “grooves”. Viable microorganisms were seen at the entrance as well as in the interiors of the “grooves”. In “fissures” viable microorganisms were primarily observed at the entrance, while in the interiors microorganisms were less viable or dead. The authors concluded that the internal morphology of interlobal grooves influences bacterial growth conditions, and determines locations for caries progression within a groove-fossa system.

The formation of a microbial biofilms on teeth is enhanced by natural retention factors, which can also render removal by means of oral hygiene more difficult. Certain relevant retention

factors for biofilms on the cervical third and roots include: supra- and subgingival calculi; cementoenamel junctions and enamel projections; furcation entrances and irregularities; cervical and root surface caries; and tooth crowding in the arch. [38].

Without proper brushing and flossing, microbial biofilms and tartar can build up at the gum-line, leading to gingivitis and gum disease. If the margin of the gum tissue that surrounds the teeth wears away, the root surface is exposed and caries are likely to develop. This is called gum recession, a complex process where the gums pull back and the gum line changes. When gum recession occurs, “pockets” or gaps form between the teeth and the gum line. Under this influence, the teeth can be severely damaged, and may ultimately result in tooth loss.

Human teeth present a varied and complex morphology with bases in the innumerable anatomical characteristics provided for by their grooves, fissures, and sulci. Certain teeth unexpectedly reveal risk areas in subtle and hidden structures. For instance, the lingual pit in lateral upper incisors must often be restored due to caries, for in addition to its own morphology; the tooth has its neighboring tooth creating the embrasures and contact points; an antagonist tooth that can force food and debris toward the grooves, fissures, and sulci. Finally, the cervical third of the proximal surface is surrounded by the gums. This is a very special area where open smooth surfaces may also present dental caries, a spot where biofilms are not linked to any specific anatomical feature. Microbial biofilms can form and develop in many anatomical tooth sites or even on free smooth surfaces (cervical third) when conditions are favorable. **Table 2** presents the predilection sites for dental caries by tooth group.

For an experienced dentist, the most common locations of dental caries, presented in **Table 2** are obvious. Nevertheless, the examination process for detecting dental caries needs to be carefully performed even by experienced professionals. It is not rare that a white spot (demineralization area indicating initial caries) is neglected during dental examination. This is the reason for removal of all dental plaque (biofilms) prior any dental examination. Dental caries forms in sites of biofilm

Tooth groups	Risk areas for dental caries
Incisors	All cervical third (particularly free smooth surfaces close to the gum line) Mesial and distal surfaces (below contact point) Lingual pit (lingual surface of lateral incisors)
Canines	All cervical third (particularly free smooth surfaces close to the gum line) Mesial and distal surfaces
Pre molars	All cervical third (particularly free smooth surfaces close to the gum line) Mesial and distal surfaces (below contact point) Sulci Fissures and grooves Triangular fossa (occlusal surface)
Molars	All cervical third (particularly free smooth surfaces close to the gum line) Mesial and distal surfaces (below contact point) Sulci (including sulcus close to Carabelli trait) Fissures and grooves (including the mesio-buccal groove) Triangular fossa (buccal and occlusal surfaces) Central fossa

**Table 2.** Risk areas for dental caries at each tooth group.

stagnation and these sites can frequently remain hidden from sight. Another fundamental condition is the proper light source and the aid of compressed air for dehydrating the tooth surface.

Factors affecting caries detection can vary if the dental examination is in a child, an adolescent or an adult. First, carious lesions can either be visualized at early stages or as a cavitated lesion; second, during childhood, mixed dentition can be a confounding factor; a third variable is related to the different diagnostic tools (e.g., probes, radiographs). Finally, carious locations can also vary with age, for instance, carious lesions can be found in unexpected sites. In young children, dental plaque (biofilm) can easily accumulate underneath and close to the gum line of upper incisors due to extensive bottlefeeding.

When comparing differences between deciduous and permanent teeth, dental caries progression is faster in deciduous teeth because deciduous tooth enamel is less mineralized than permanent tooth enamel. The chemical composition of the enamel is another factor in rapid deciduous caries progression because the total carbonate content is significantly higher in deciduous teeth [77].

In the following sections, classification of dental caries based on their locations is presented. It is important to point out that this approach is only a general guideline for a better understanding of this topic. The limitation of such an approach is related to the lack of clinical information, which would provide even better comprehension about the development of the carious lesions.

#### **4.1. Occlusal caries**

In the permanent dentition, occlusal fissures and grooves on the first permanent molar are generally the first sites to develop caries [39]. In fact, all depressions in the occlusal surface can be regarded as predilection sites for dental caries. The same is not true for primary dentition since early childhood caries (ECC), a typical condition of deciduous incisor smooth surfaces often occurs. It is estimated that occlusal caries account for most of the carious lesions in children aged 8–15 years. The general distribution of occlusal lesions seems to be concentrated in the first and second permanent molars, prevalent in all age groups. Since 1965, certain investigations have supported the view that occlusal molars surfaces are the most caries susceptible [40–42]. A good listing by rank shows the most susceptible surfaces for caries (from the most susceptible to the less susceptible), distributed as follows: occlusal surface of the four first molars > occlusal surface of the lower second molars > occlusal surface of the upper second molars > mesial surface of the upper first molars [41].

Since occlusal surfaces are present only in pre-molars and molars, the development of biofilms on these sites is related to pressed and packed debris and biofilms upon fissures, grooves, and sulci. The clinical appearance of carious lesions varies significantly, and discoloration in these occlusal depressions may be either white or dark [43, 44]. These discolorations can remain even after the tooth is extracted.

As to dental treatment for occlusal caries, the threshold for operative treatment is still a matter of debate [39]. A recent study supports the view that younger dentists are more reluctant to remove hard tooth tissues. Types of dental material are also converging; composites are replacing amalgams or other filling materials [40]. It must be noted that on the whole, development

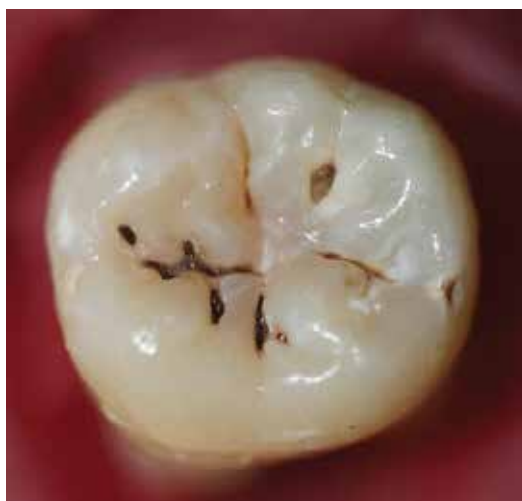of carious lesions has lessened due to both fluoride exposure and accessibility to oral hygiene procedures. Caries risk assessment may help determine whether drilling of an occlusal fissure or choosing a non-invasive treatment is more appropriate. In both cases, a good understanding of premolar and molar occlusal morphology is needed (**Figure 5**).

#### 4.2. Interproximal caries

Different from occlusal surfaces, the process for detecting proximal carious lesions is hampered by natural variations in dental morphology and their relations to the adjacent teeth. Proximal lesions develop between contacting proximal surfaces (just below the contacting point) of two adjacent teeth. Proximal lesions are hard to visualize during the clinical exam, and if not detected during the initial stages, radiographs and tooth separation often reveal their presence. Evidence of a proximal lesion in one tooth raises significant concerns since the neighboring tooth in most cases is also affected. Proximal lesions do eventually appear clinically as opaque areas on buccal and lingual surfaces [45–47].

It is estimated that at least 40% of proximal carious lesions are missed during dental examinations and are allowed to continue growing. Tightly contacting proximal surfaces between teeth create detection and treatment difficulties, even for experienced clinicians. Recent techniques have been developed to facilitate penetration of low-viscosity resins into the porous lesion body of enamel caries. Infusion of a highly fluid unfilled light-cured resin known as “resin infiltration system” is particularly useful for treating incipient proximal lesions [48].

Many dental professionals do not consider single tooth proximal surface dental morphology by itself as a predilection for caries. However, a recent study concluded that morphologies

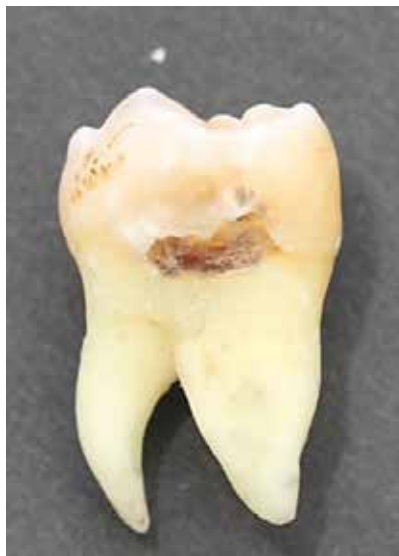

**Figure 5.** Occlusal caries.

of proximal surfaces are important for primary molar teeth [49]. In this study, 52 young children (3–4 year-olds) were followed for 1 year. The morphology of the distal surfaces of the first molar teeth and the mesial surfaces of the second molar teeth ( $n = 208$ ) were scored in four categories: concave-concave; concave-convex; convex-concave; and convex-convex. Radiographs were used to monitor proximal caries, and the results showed risk of developing caries is increased if both surfaces are concave. It is important to point out that proximal surfaces of permanent and primary molar teeth may be convex or concave in the buccolingual direction as well as in the occluso-cervical direction [49, 50].

When teaching dental anatomy, apart from the fact that two neighboring teeth can create a favorable site for caries development, proximal surfaces are generally presented without any special anatomical characteristic. In addition to shape (convex or concave) another point to consider is how wide is the space between teeth if any? If the contact point is actually an open space between the teeth (broad contact area), a significant drop in the likelihood of caries formation is expected. Researchers have evaluated whether the risk of proximal caries in posterior primary teeth is higher when interproximal contact points are closed, or if they are open [51]. Data concerning known risk factors and indicators for caries were also investigated. The findings for young children (24–72 months) showed the odds for caries were significantly increased when such contact points were closed.

For detection of proximal caries, and as adjuncts in the process, bitewing radiographs remain state-of-the-art. However, a good number of caries detected by radiographs (lesions extended to the outer dentine) can be intact on enamel surfaces [52]. Since carious lesions are directly dependent on the continuous presence of active microorganisms, a reasonable approach is to monitor caries using a series of bitewing radiographies [53] (**Figure 6**).



**Figure 6.** Interproximal caries below the contacting point.

### 4.3. Buccal and lingual caries

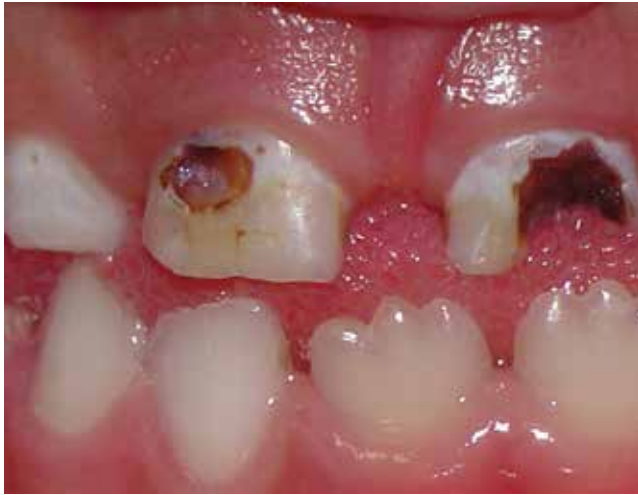In opposition to occlusal surfaces that are rich in fissures and grooves, there is no favorable anatomical environment for complex organized microorganism microcosms on the smooth tooth surface, dental biofilms on free smooth surfaces have a different evolution as compared to occlusal surfaces, and carious lesions on smooth surfaces of the teeth and can be detected in early stages. The challenge for “early colonizing microorganisms” is high since the morphology does not help, and shear forces are constantly taking cells away. It has been observed that during the first few hours of biofilm formation, early colonizers of the tooth surface predominantly consist of beneficial microorganisms (*Actinomyces* and *Streptococci* species) [54, 55]. Later, the first subsequent proliferation is largely due to microbial mass increase during early plaque formation which is modulated by nutrition and the impact of serum proteins that emanate from gingival sulcus [55]. Thus, any free smooth surfaces prone to caries are mainly restricted to areas below the equatorial line, in other words, restricted to the cervical third and close to the gum line (Table 1).

Normal tooth contours provide constant protection from the influence of direct salivary flow and from the masticatory function of the cervical third. Thus certain stagnation of mass may take place and demineralization can create surface roughness providing more attachment points. Further, certain surface characteristics such as hydrophobicity and chemical charge can modulate the number of microorganisms in “mature” biofilm [56]. It must be pointed out that if over-contouring of the tooth is present more food retention is likely to occur, and as a result, a more pathogenic biofilm will be established.

In summary, microbial adherence to rough surfaces takes place easily due to occlusal surface pits and grooves. Though on free smooth surfaces, the reduced influence of shear forces creates difficulties for microbial adherence; initial attachment and subsequent development of a biofilm cannot generally be avoided altogether. Tiny irregularities in the surface caused by the demineralization enhance the development of the biofilms in these areas, particularly on the cervical third close to the gum line and on root surfaces [57].

Dental caries in early childhood are a challenge for many dentists since dental caries often begin during the first year of life. Early childhood caries (ECC) begins soon after dental eruption, developing on smooth surfaces, and progressing rapidly; having a lasting detrimental impact on dentition. Carious lesions in children may be found on either the buccal or lingual surfaces of the teeth and, in certain cases, on both [58].

Clinically, dental caries on smooth surfaces appear as white spots (opaque areas) in the enamel, reflecting demineralization or loss of minerals in the tissue subsurface. Oral prophylaxis and drying the tooth surface are crucial procedures for detecting the lesion. Their appearance can be characterized by several factors such as the depth of the lesion. Yet the carious lesion on a free smooth surface is easily observed extending in a half-moon shape following the gum line [38, 59, 60] (Figure 7).



**Figure 7.** Severe buccal caries in upper incisors.

## **5. Dental caries and other conditions**

### **5.1. Dental caries in partially erupted tooth**

Dental cariologists have placed great efforts into identifying the human tooth surfaces at risk. Since susceptibility of a tooth surface to caries can vary over time, the task is not simple. In general, it is accepted that the period of peak susceptibility for caries occurs at about 4 years from eruption of the tooth. Carlos and Gittelsohn [40] found that the probability of a carious lesion is greatest during the second post-eruptive year (in the second permanent molars), but for other teeth the period of maximum carious attack is reached about 2 years afterwards. Another study recently concluded that carious susceptibility variations do exist, and the most vulnerable sites are those surfaces with pits and fissures, followed by proximal surfaces [42].

There is no doubt that susceptibility to caries is partially influenced by the period of tooth eruption, information particularly relevant if the patient is a child with mixed dentition. When the tooth is partially erupted, the so-called “groove-fossa system” is under greater attack. There is also great evidence that oral hygiene of the occlusal surface of partially erupted teeth is fundamental for a proper prevention of dental caries [12, 34, 61].

Partially erupted teeth do not participate fully in mastication and for this reason offer more favorable environments for bacterial accumulation than fully erupted teeth [34]. As might be expected, it has been observed that the amount of biofilm accumulated on the occlusal surfaces in partially erupted molars is higher than in fully erupted molars [62]. Due to the fact that the lower and upper third molars are the most commonly enclosed teeth; pericoronitis associated with bad oral hygiene and smaller self-cleansing area, leads to accumulation of food and microorganisms that cannot be cleaned with normal brushing and flossing, causing

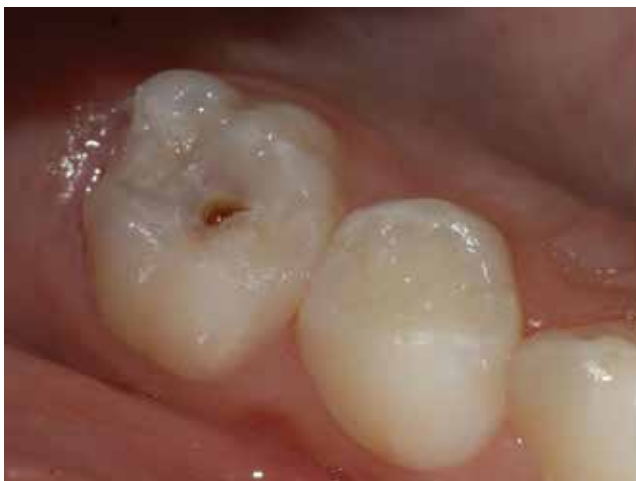the development of caries [61]. Removing dental biofilm in partially erupted molars is more difficult than in fully erupted molars [62, 63].

Eventually, the tooth reaches the occlusal plan and masticatory forces help remove parts of the biofilm. This phenomenon can partially explain why most occlusal lesions tend to cease when teeth reach the occlusal plan. However, for certain individuals, a significant proportion of their carious lesions remain active and in need of proper management [64].

The presence of a partially erupted third molar can also create risks for caries. It is estimated that the prevalence of carious lesions on mandibular second molars due to the presence of a third partially erupted molar can reach up to 39% [65]. Mandibular third molars are the most frequently impacted teeth, a condition that is defined when the tooth does not reach the occlusal plane, even after root formation reaches two-thirds. Impacted third molars tend to accumulate biofilm against the distal surfaces of second molars, thereby creating the risk of distal cervical caries. A recent study has shown that second molars adjacent to absent third molars are at the lowest risk of developing caries and periodontal disease; whereas, second molars adjacent to soft tissue impacted third molars are at the greatest risk [66]. Thus, when a partially erupted mandibular third molar is not removed, good oral hygiene becomes essential to avoid caries [67]. The most important variables when considering caries risk in the second mandibular molar due to a partially erupted third molar are eruption status, type of angulation, and the nature of tooth contact between the molars. Such factors can be used as predictors to indicate the likelihood of developing caries on the second mandibular molar [67]. Otherwise, if recurrent dental caries occur on the second molar, the third molar must be prophylactically removed [68] (**Figure 8**).

## 5.2. Dental disorders and caries

Dental disorders in hard tissues are seldom presented and discussed during classes teaching dental anatomy. Most instructors are concerned solely with teaching the normal morphology



**Figure 8.** Dental caries developed during eruption process in second deciduous molar.



of the teeth. However, observation of dental abnormalities may lure students to acquire problem-solving skills. For instance, first molar and incisor morphologies can be explored together, in spite of the fact that they belong to different groups of teeth. With these teeth, the reason for a combined lecture comes from a common and frequently encountered condition observed by pediatric dentists: molar incisor hypomineralization (MIH). MIH is defined as a qualitative enamel defect of systemic origin. The terminology of MIH was introduced 16 years ago (2001) in order to describe enamel hypomineralization of systemic origin affecting one or more of the first permanent molars that are frequently associated with affected incisors [69].

In certain countries, the prevalence of MIH is regarded as very low (~2%), yet it has reached almost 40% in others. The high variance in recording MIH reflects difficulties in detecting and defining potential etiological factors [70–72]. The treatment for MIH is mainly restoration using Glass Ionomer Cement, and monitoring for defect associated caries. The probability of success is found to be high, mainly in single-surface tooth restorations. Complete removal of the affected areas (occlusal surfaces in molars and buccal surfaces in incisors) should generally be postponed. The reason for such delay in more invasive treatments is related to awaiting better conditions or when a child understands enough to cooperate with complex rehabilitation and treatment procedures [73].

MIH is just one of many tooth disorders that can be explored in dental anatomy courses. Developmental dental disorders may range from abnormalities in dental lamina demarcation to tooth germ anomalies (numbers, size, and shape), to abnormalities in the growth of the dental hard tissues (structure). Restricted to the enamel, certain developmental defects may manifest in two major conditions: enamel hypoplasia or opacity. The etiologies for dental anomalies vary substantially; they can be congenital or idiopathic, inherited or acquired [74]. A deeper understanding of dental anomalies is important because they can affect color, shape, and tooth structure. As a result, dental morphology can also be affected, which may increase the risk for dental caries [75]. Taking all dental anomalies into account, most of them have clinical significance: as to esthetics, malocclusion, and to the more costly development of dental decay and oral diseases [76]. Further, most dental anomalies such as germination, fusion, and dens invaginatus lead to clinical problems, and thus remain relevant to investigations regarding potential changes in dental morphology, potentially causing difficulties in speech and mastication, temporomandibular joint pain and/or dysfunction, malocclusion, periodontal problems and increased susceptibility to caries [74].

## 6. Conclusions

It is widely recognized that knowledge of dental anatomy is fundamental to any branch of dentistry. Dental anatomy is primarily concerned with the shape, morphology, and appearance of teeth. Teaching dental anatomy comprises studies of crown contours, roots, and pulp chambers together in their relationships with other structures in the oral cavity [77–80]. Thus, dental anatomy is directly and easily linked to dental occlusion, forensic dentistry, and cariology. Yet the link between dental morphology and cariology is seldom explored.

There is constant concern to provide dental anatomy courses which are more relevant to clinical practice. Dental caries are certainly an important topic linking these fields, and topics in cariology can easily be introduced during dental anatomy sessions. Problem-based learning (PBL) is likely a good pedagogical approach for attracting students with a more active and enthusiastic learning path.

There are many reasons to avoid conventional lecture-based courses in dental anatomy. When learning dental anatomy, clinical expertise is probably the main goal for most students, and dental caries when integrated together with dental morphology is certainly an intellectually stimulating topic.

Reviewing the influence of dental anatomy on the development dental caries and taking into account recent findings in Cariology is beneficial for dental clinicians and anatomists.

## Author details

Marcel Alves Avelino de Paiva, Dayane Franco Barros Manguiera Leite, Isabela Albuquerque Passos Farias, Antônio de Pádua Cavalcante Costa and Fábio Correia Sampaio\*

\*Address all correspondence to: fcsampa@gmail.com

Federal University of Paraiba, João Pessoa, Brazil

## References

- [1] Selwitz RH, Ismail AI, Pitts NB. Dental caries. *Lancet*. 2007;**396**:51-59. DOI: 10.1016/S0140-6736(07)60031-2
- [2] Gustafsson BE, Quensel C-E, Swenander Lanke L, Lundqvist C, Grahnen H, Bonow BE, Krasse B, The Vipeholm Dental Caries Study. The effects of different levels of carbohydrate intake in 436 individuals observed for five years. *Acta Odontologica Scandinavica*. 1954;**11**:232-364
- [3] Krasse B. The Vipeholm dental caries study: Recollections and reflections 50 years later. *Journal of Dental Research*. 2001;**80**:1785-1788. DOI: 10.1177/00220345010800090201
- [4] Sheiham A, James WPT. Diet and dental caries the pivotal role of free sugars reemphasized. *Journal of Dental Research*. 2015;**94**:1341-1347. DOI: 10.1177/0022034515590377
- [5] Marsh PD. Microbial ecology of dental plaque and its significance in health and disease. *Advances in Dental Research*. 1994;**8**:263-271. DOI: 10.1177/08959374940080022001
- [6] Takahashi N, Nyvad B. Ecological hypothesis of dentin and root caries. *Caries Research*. 2016;**50**:422-431. DOI: 10.1159/000447309
- [7] Baelum V, Fejerskov O. How big is the problem? Epidemiological features of dental caries. In: Fejerskov O, Nyvad B, Kidd E, editors. *Dental Caries: The Disease and its Clinical Management*. 3rd ed. Oxford: Wiley-Blackwell; 2015. p. 21-45

- [8] Bratthall D, Hänsel-Petersson G, Sundberg H. Reasons for the caries decline: What do the experts believe? *Journal of Oral Science*. 1996;**104**:416-425. DOI: 10.1111/j.1600-0722.1996.tb00104.x
- [9] Roncalli AG, Sheiham A, Tsakos G, de Araújo-Souza GC, Watt RG. Social factors associated with the decline in caries in Brazilian children between 1996 and 2010. *Caries Research*. 2016;**50**:551-559. DOI : 10.1159/000442899
- [10] Lagerweij MD, van Loveren C. Declining caries trends: Are we satisfied? *Current Oral Health Reports*. 2015;**2**:212-217. DOI: 10.1007/s40496-015-0064-9
- [11] Topping GV, Pitts NB. Clinical visual caries detection. *Monographs in Oral Science*. 2009;**21**:15-41. DOI: 10.1159/000224210
- [12] Pitts NB, Zero DT, Marsh PD, Ekstrand K, Weintraub JA, Ramos-Gomez F, Tagami J, Twetman S, Tsakos G, Ismail A. Dental caries. *Nature Reviews Disease Primers*. 2017;**25**:17030. DOI: 10.1038/nrdp.2017.30
- [13] Schulte AG, Buchalla W, Huysmans MC, Amaechi BT, Sampaio F, Vougiouklakis G, Pitts NB. A survey on education in cariology for undergraduate dental students in Europe. *European Journal of Dental Education*. 2011;**15**:3-8. DOI: 10.1111/j.1600-0579.2011.00708.x
- [14] Çolak H, Dülgergil ÇT, Dalli M, Hamidi MM. Early childhood caries update: A review of causes, diagnoses, and treatments. *Journal of Natural Science, Biology, and Medicine*. 2013;**4**:29-38. DOI: 10.4103/0976-9668.107257
- [15] Sampaio FC, Rodrigues JA, Bönecker M, Groisman S. Reflection on the teaching of cariology in Brazil. *Brazilian Oral Research*. 2013;**27**:195-196. DOI: 10.1590/S1806-83242013000300001
- [16] Perry S, Burrow MF, Leung WK, Bridges SM. Simulation and curriculum design: A global survey in dental education. *Australian Dental Journal*. 2017;**19**:1-11. DOI: 10.1111/adj.12522
- [17] Sheiham A, James WP. A new understanding of the relationship between sugar, dental caries and fluoride use: Implications for limits on sugars consumption. *Public Health Nutrition*. 2014;**17**:2176-2184. DOI: 10.1017/S136898001400113X
- [18] Moynihan P, Kelly S. Effect on caries of restricting sugars intake: Systematic review to update WHO guidelines. *Journal of Dental Research*. 2014;**93**:8-18. DOI: 10.1177/0022034513508954
- [19] Sheiham A, James WP. A reappraisal of the quantitative relationship between sugar intake and dental caries: The need for new criteria for developing goals for sugar intake. *BMC Public Health*. 2014;**14**:863. DOI: 10.1186/1471-2458-14-863
- [20] Zero DT. Sugars—The arch criminal? *Caries Research*. 2004;**38**:277-285. DOI: 10.1159/000077767
- [21] Kidd EAM, Fejerskov O. What constitutes dental caries? Histopathology of carious enamel and dentin related to the action of cariogenic biofilms. *Journal of Dental Research*. 2004;**83**:C35. DOI: 10.1177/154405910408301S07

- [22] Fejerskov O. Concepts of dental caries and their consequences for understanding the disease. *Community Dentistry and Oral Epidemiology*. 1997;**25**:5-12. DOI: 10.1111/j.1600-0528.1997.tb00894.x
- [23] Fejerskov O. Changing paradigms in concepts on dental caries: Consequences for oral health care. *Caries Research*. 2004;**38**:182-191. DOI: 10.1159/000077753
- [24] Simón-Soro A, Mira A. Solving the etiology of dental caries. *Trends in Microbiology*. 2015;**23**:76-82. DOI: 10.1016/j.tim.2014.10.010
- [25] Nyvad B, Crielaard W, Mira A, Takahashi N, Beighton D. Dental caries from a molecular microbiological perspective. *Caries Research*. 2013;**47**:89-102. DOI: 10.1159/000345367
- [26] Benítez-Páez A, Belda-Ferre P, Simón-Soro A, Mira A. Microbiota diversity and gene expression dynamics in human oral biofilms. *BioMed Central Genomics*. 2014;**15**:311. DOI: 10.1186/1471-2164-15-311
- [27] Sanz M, Beighton D, Curtis MA, Cury J, Dige I, Dommisch H, Ellwood R, Giacaman R, Herrera D, Herzberg MC, Konen E, Marsh PD, Meyle J, Mira A, Molina A, Mombelli A, Quirynen M, Reynolds E, Shapira L, Zaura E. Role of microbial biofilms in the maintenance of oral health and in the development of dental caries and periodontal diseases. Consensus report of group 1 of the Joint EFP/ORCA workshop on the boundaries between caries and periodontal disease. *Journal of Clinical Periodontology*. 2017;**44**:S5-S11. DOI: 10.1111/jcpe.12682
- [28] Richards VP, Alvarez AJ, Luce AR, Bedenbaugh M, Mitchell ML, Burne RA, Nascimento MM. The microbiome of site-specific dental plaque of children with different caries status. *Infection and Immunity*. 2017;**19**:1-11. DOI: 10.1128/IAI.00106-17
- [29] Stanley JN, Major A Jr. *Wheeler's Dental Anatomy, Physiology, and Occlusion*. 9th ed. St. Louis: Elsevier; 2010; 368 p
- [30] Scheid RC, Weiss G. *Woelfel's Dental Anatomy*. 8th ed. Philadelphia: Lippincott Williams & Wilkins; 2012; 504 p
- [31] Ferrario VF, Sforza C, Tartaglia GM, Colombo A, Serrao G. Size and shape of the human first permanent molar: a Fourier analysis of the occlusal and equatorial outlines. *American Journal of Physical Anthropology*. 1999;**108**:281-294. DOI: 10.1002/(SICI)1096-8644(199903)108:3<281::AID-AJPA4>3.0.CO;2-#
- [32] Macek MD, Beltrán-Aguilar ED, Lockwood SA, Malvitz DM. Updated comparison of the caries susceptibility of various morphological types of permanent teeth. *Journal of Public Health Dentistry*. 2003;**63**:174-182. DOI: 10.1111/j.1752-7325.2003.tb03496.x
- [33] Klein H, Palmer CE. Studies on dental caries. XI. Comparison of the caries susceptibility of the various morphological types of permanent teeth. *Journal of Dental Research*. 1941;**20**:203-216
- [34] Carvalho JC, Thylstrup A, Ekstrand KR. Results after 3 years of non-operative occlusal caries treatment of erupting permanent first molars. *Community Dentistry and Oral Epidemiology*. 1992;**20**:187-192. DOI: 10.1111/j.1600-0528.1992.tb01713.x

- [35] Ricketts D, Kidd E, Weerheijm K, de Soet H. Hidden caries: What is it? Does it exist? Does it matter? *International Dental Journal*. 1997;**47**:259-265. DOI: 10.1002/j.1875-595X.1997.tb00786.x
- [36] Sadatullah S, Odusanya SA, Mustafa A, Abdul Razak P, Abdul Wahab M, Meer Z. The prevalence of fifth cusp (Cusp of Carabelli) in the upper molars in Saudi Arabian School Students. *International Journal of Morphology* 2012;**30**:757-760. DOI: <http://dx.doi.org/10.4067/S0717-95022012000200066>
- [37] Ekstrand KR, Bjørndal L. Structural analyses of plaque and caries in relation to the morphology of the groove-fossa system on erupting mandibular third molars. *Caries Research*. 1997;**31**:336-348. DOI: 10.1159/000262416
- [38] Wolf HF, Hassell TM. *Color Atlas of Dental Hygiene*. 15th ed. Stuttgart: Thieme; 2006; 351 p
- [39] Ekstrand KR, Ricketts DN, Kidd EA. Occlusal caries: Pathology, diagnosis and logical management. *Dent Update*. 2001;**28**:380-387. DOI: 10.12968/denu.2001.28.8.380
- [40] Carlos JP, Gittelsohn AM. Longitudinal studies of the natural history of caries. II. A life-table study of caries incidence in the permanent teeth. *Archives of Oral Biology*. 1965;**10**:739-751
- [41] Hannigan A, O'Mullane DM, Barry D, Schäfer F, Roberts AJ. A caries susceptibility classification of tooth surfaces by survival time. *Caries Res*. 2000;**34**:103-108. DOI: 16576
- [42] Batchelor PA, Sheiham A. Grouping of tooth surfaces by susceptibility to caries: A study in 5-16 year-old children. *BMC Oral Health*. 2004;**28**:1-6. DOI: 10.1186/1472-6831-4-2
- [43] Kakudate N, Sumida F, Matsumoto Y, Yokoyama Y, Gilbert GH, Gordan VV. Patient age and Dentists' decisions about occlusal caries treatment thresholds. *Operative Dentistry*. 2014;**39**:473-480. DOI: 10.2341/13-141-C
- [44] Kopperud SE, Tveit AB, Opdam NJ, Espelid I. Occlusal caries management: Preferences among dentists in Norway. *Caries Research*. 2016;**50**:40-47. DOI: 10.1159/000442796
- [45] Abu El-Ela WH, Farid MM, Mostafa MSE-D. Intraoral versus extraoral bitewing radiography in detection of enamel proximal caries: An ex vivo study. *Dento Maxillo Facial Radiology*. 2016;**45**:20150326. DOI: 10.1259/dmfr.20150326
- [46] Haak R, Wicht MJ, Noack MJ. Conventional, digital and contrast-enhanced bitewing radiographs in the decision to restore approximal carious lesions. *Caries Research*. 2001;**35**:193-199. DOI: 10.1159/000047455
- [47] Hintze H, Wenzel A, Danielsen B. Behaviour of approximal carious lesions assessed by clinical examination after tooth separation and radiography: a 2.5-year longitudinal study in young adults. *Caries Research*. 1999;**33**:415-422. DOI: 16545
- [48] Meyer-Lueckel H, Bitter K, Paris S. Randomized controlled clinical trial on proximal caries infiltration: Three-year follow-up. *Caries Research*. 2012;**46**:544-548. DOI: 10.1159/000341807

- [49] Cortes A, Martignon S, Qvist V, Ekstrand KR. Approximal morphology as predictor of approximal caries in primary molar teeth. *Clinical Oral Investigations*. 2017;**22**:1-9. DOI: 10.1007/s00784-017-2174-3
- [50] Almer Nielsen L, Madsen DB. Selektiv brug af bitewingundersøgelse til diagnostik af approksimal caries i primære molarer. *Tandlægebladet*. 2005;**109**:370-374
- [51] Allison PJ, Schwartz S. Interproximal contact points and proximal caries in posterior primary teeth. *Pediatric Dentistry*. 2003;**25**:334-340
- [52] Pitts NB, Rimmer PA. An in vivo comparison of radiographic and directly assessed clinical caries status of posterior approximal surfaces in primary and permanent teeth. *Caries Research*. 1992;**26**:146-152. DOI: 10.1159/000261500
- [53] Pretty IA, Ekstrand KR. Detection and monitoring of early caries lesions: A review. *European Archives of Paediatric Dentistry*. 2016;**17**:13-25. DOI: 10.1007/s40368-015-0208-6
- [54] Heller D, Helmerhorst EJ, Gower AC, Siqueira WL, Paster BJ, Oppenheim FG. Microbial diversity in the early in vivo-formed dental biofilm. *Applied and Environmental Microbiology*. 2016;**82**:1881-1888. DOI: 10.1128/AEM.03984-15
- [55] Kolenbrander PE, London J. Adhere today, here tomorrow: Oral bacterial adherence. *Journal of Bacteriology*. 1993;**175**:3247-3252
- [56] Whittaker CJ, Klier CM, Kolenbrander PE. Mechanisms of adhesion by oral bacteria. *Annual Review of Microbiology*. 1996;**50**:513-552. DOI: 10.1146/annurev.micro.50.1.513
- [57] Nyvad B, Fejerskov O. Scanning electron microscopy of early microbial colonization of human enamel and root surfaces in vivo. *Scandinavian Journal of Dental Research*. 1987;**95**:287-296
- [58] American Academy on Pediatric Dentistry. American Academy of Pediatrics. Policy on early childhood caries (ECC): Classifications, consequences, and preventive strategies. *Pediatric Dentistry*. 2008;**38**:40-43
- [59] Roopa KB, Pathak S, Poornima P, Neena IE. White spot lesions: A literature review. *Journal of Pediatric Dentistry*. 2015;**3**:1-7. DOI: 10.4103/2321-6646.151839
- [60] Denis M, Atlan A, Vennat E, Tirlet G, Attal JP. White defects on enamel: Diagnosis and anatomopathology: Two essential factors for proper treatment (part 1). *International Orthodontics*. 2013;**11**:139-165. DOI: 10.1016/j.ortho.2013.02.014
- [61] Carvalho JC. Caries process on occlusal surfaces: Evolving evidence and understanding. *Caries Research*. 2014;**48**:339-346. DOI: 10.1159/000356307
- [62] Zenkner JE, Alves LS, de Oliveira RS, Bica RH, Wagner MB, Maltz M. Influence of eruption stage and biofilm accumulation on occlusal caries in permanent molars: A generalized estimating equations logistic approach. *Caries Research*. 2013;**47**:177-182. DOI: 10.1159/000345076
- [63] Oliveira RS, Zenkner JEDA, Maltz M, Rodrigues JA. Effectiveness of a standardized treatment protocol for children with active non-cavitated occlusal lesions on erupting

- permanent molars. *International Journal of Paediatric Dentistry*. 2015;**25**:393-398. DOI: 10.1111/ipd.12141
- [64] Alves LS, Zenkner JEA, Wagner MB, Damé-Teixeira N, Susin C, Maltz M. Eruption stage of permanent molars and occlusal caries activity/ arrest. *Journal of Dental Research*. 2014;**93**:114S-119S. DOI: 10.1177/0022034514537646
- [65] Syed KB, Alshahrani FS, Alabsi WS, Alqahtani ZA, Hameed MS, Mustafa AB, Alam T. Prevalence of distal caries in mandibular second molar due to impacted third molar. *Journal of Clinical and Diagnostic Research: JCDR*. 2017;**11**:ZC28. DOI: 10.7860/JCDR/2017/18582.9509
- [66] Nunn ME, Fish MD, Garcia RI, Kaye EK, Figueroa R, Gohel A, et al. Impacted third molars increase the risk for caries and periodontal pathology in neighboring second molars. *Journal of Evidence-Based Dental Practice*. 2014;**14**:89-90. DOI: 10.1016/j.jebdp.2014.04.026
- [67] Toedtling V, Coulthard P, Thackray G. Distal caries of the second molar in the presence of a mandibular third molar—A prevention protocol. *British Dental Journal*. 2016;**221**:297-302. DOI: 10.1038/sj.bdj.2016.677
- [68] McArdle LW, Fraser MD, Judith J. Distal cervical caries in the mandibular second molar: An indication for the prophylactic removal of third molar teeth? Update. *The British Journal of Oral & Maxillofacial Surgery*. 2014;**52**:185-189. DOI: 10.1016/j.bjoms.2013.11.007
- [69] Weerheijm KL, Jälevik B, Alaluusua S. Molar–incisor hypomineralisation. *Caries Research*. 2001;**35**:390-391. DOI: 47479
- [70] Wogelius P, Haubek D, Poulsen S. Prevalence and distribution of demarcated opacities in permanent 1st molars and incisors in 6 to 8-year-old Danish children. *Acta Odontologica Scandinavica*. 2008;**66**:58-64. DOI: 10.1080/00016350801926941
- [71] Silva MJ, Scurrah KJ, Craig JM, Manton DJ, Kilpatrick N. Etiology of molar incisor hypomineralization—A systematic review. *Community Dentistry and Oral Epidemiology*. 2016;**44**:342-353. DOI: 10.1111/cdoe.12229
- [72] Allazzam SM, Alaki SM, ElMeligy OA. Molar incisor hypomineralization, prevalence, and etiology. *International Journal of Dentistry*. 2014;**234508**:2014. DOI: 10.1155/2014/234508
- [73] Fragelli CM, Souza JF, Jeremias F, R de C C, Santos-Pinto L. Molar incisor hypomineralization (MIH): Conservative treatment management to restore affected teeth. *Brazilian Oral Research*. 2015;**29**:1-7. DOI: 10.1590/1807-3107BOR-2015.vol29.0076
- [74] Shrestha A, Marla V, Shrestha S, Maharjan IK. Developmental anomalies affecting the morphology of teeth—A review. *RSBO Rev Sul-Brasil de Odont*. 2015;**12**:68-78
- [75] Caufield PW, Li Y, Bromage TG. Hypoplasia-associated severe early childhood caries—A proposed definition. *Journal of Dental Research*. 2012;**91**:544-550. DOI: 10.1177/0022034512444929
- [76] Jahanimoghadam F. Dental anomalies: An update. *Advances in Human Biology*. 2016;**1**:112-118. DOI: 10.4103/2321-8568.195316

- [77] Goldberg M. Deciduous tooth and dental caries. *Annals of Pediatrics and Child Health*. 2017;**5**:1120
- [78] Moretto SG, Anfe TEA, Nagase DY, Kuguimiya RN, Lago ADN, Freitas PM, Oda M, Vieira GF. Theoretical knowledge versus practical performance in dental sculpting—preliminary study *Clinical and Laboratorial Research in Dentistry*. 2014;**20**:82-87. DOI: <http://dx.doi.org/10.11606/issn.2357-8041.v20i2p82-87>
- [79] Manjunatha BS. *Textbook of Dental Anatomy and Oral Physiology*. 1st ed. Delhi: Jaypee; 2013. DOI: 10.5005/jp/books/11841
- [80] Siéssere S, Vitti M, de Sousa LG, Semprini M, Regalo SC. Educational material of dental anatomy applied to study the morphology of permanent teeth. *Brazilian Dental Journal*. 2004;**15**:238-242. DOI: S0103-64402004000300014



---

## Dental Anesthesia

---



---

# **Anatomy Applied to Block Anesthesia for Maxillofacial Surgery**

---

Alex Vargas, Paula Astorga and Tomas Rioseco

Additional information is available at the end of the chapter

<http://dx.doi.org/10.5772/intechopen.69545>

---

## **Abstract**

Anatomy is a basic knowledge that every clinician must have; however, its full management is not always achieved and gaps remain in daily practice. The aim of this chapter is to emphasize the most relevant aspects of head and neck anatomy, specifically related to osteology and neurology for the application of regional anesthesia techniques. This chapter presents a clear and concise text, useful for both undergraduate and graduate students and for the dentist and maxillofacial surgeon. The most relevant aspects of the bone and sensory anatomy relevant for the realization of regional anesthetic techniques in the oral and maxillofacial area are reviewed, including complementary figures and tables. The anatomy related to the techniques directed to the three major branches of the trigeminal nerve (ophthalmic nerve, maxillary nerve, and to the branches of the mandibular nerve) will be approached separately.

**Keywords:** clinical anatomy, anatomy for anesthesia, maxillofacial surgery

---

## **1. Introduction**

Anatomy is a basic knowledge that every clinician must have; however, its full management is not always achieved and gaps remain in daily practice. Knowledge of the precise topography and distribution area of the trigeminal nerve and its branches is required to provide precise and useful anesthesia. Even more, during diverse types of surgery, it is very important to know the distribution area of the trigeminal nerve in order to predict the anesthetic area and avoid pain.

The aim of this chapter is to emphasize the most relevant aspects of head and neck anatomy, specifically related to osteology and neurology, for the application of regional anesthesia techniques.

---

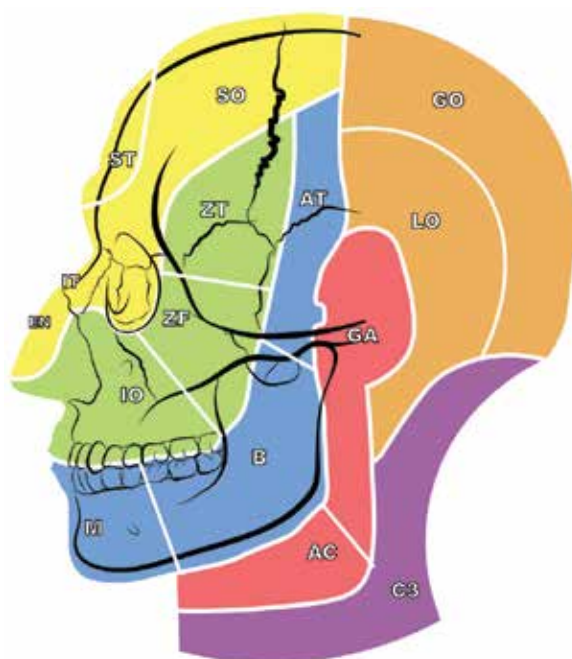
This text includes the most relevant aspects of the bone and sensory anatomy, relevant for the realization of regional anesthetic techniques in the oral and maxillofacial area.

## 2. General principles

The maxilla has fine external and porous corticals, with thickening in certain areas that generally do not reach thicknesses greater than 1 mm. This allows that anesthetic solution deposited through the buccal vestibules infiltrate into the maxillary bone, anesthetizing the maxillary teeth and their adjacent tissues (periodontium and gingival mucosa). However, the thickness of the palatal corticals is much greater, impeding the same infiltrative effect. This forces us to consider anesthetic block of the nerve trunks before they are introduced to the maxilla, for most effective anesthetic and of more extensive sectors.

For its part, the jaw usually has a greater thickening even of all its cortical, reaching easily the 3 mm (basilar rim reaches thicknesses of up to 5 mm) [1]. These anatomical characteristics of the mandible should be considered to decide the anesthetic technique to be used, the latency time, and the required anesthetic concentration.

After the respective trigeminal branches are introduced into the maxilla and jaw and emit the branches that innervate the dental tissues, the terminal branches emerge into the skin and innervate the specific areas of the face, giving rise to the different trigeminal dermatomes [2] (see **Figure 1**).



**Figure 1.** The major sensory dermatomes of the head and neck. B, buccal nerve; EN, external (dorsal) nasal nerve; IO, infraorbital nerve; IT, infratrochlear; ST, supratrochlear nerve; M, mental nerve; SO, supraorbital nerve; Zf, zygomatofacial nerve; ZT, zygomaticotemporal nerve. Adapted from: Simplified Facial Rejuvenation. 1st ed. Heidelberg: Springer; 2008.

### 3. Ophthalmic division

The ophthalmic nerve (V1) is the smallest of the three divisions of the trigeminal nerve. The V1 branches into the frontal, nasociliary, and lacrimal nerves as it approaches the superior orbital fissure. It supplies branches to the cornea, ciliary body, and iris; to the lacrimal gland and conjunctiva; to the upper part of the mucous membrane of the nasal cavity; and to the skin of the eyelids, eyebrow, forehead, and upper lateral nose.

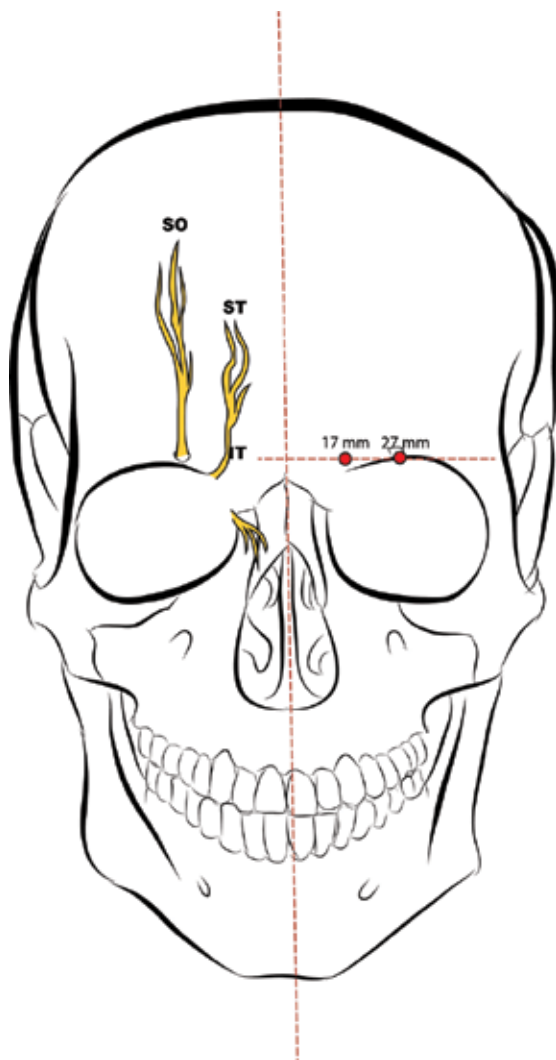
- a. The frontal nerve is the largest division of the branches of the V1, courses outside and superolateral, and divides into the supratrochlear and supraorbital nerves within the orbit. The supratrochlear nerve supplies the conjunctiva and the skin of the upper eyelid and ascends dividing into branches to supply the skin of the lower forehead near the midline. The supraorbital nerve courses between the levator palpebrae muscle and orbital roof and exited the supraorbital notch or foramen; it innervates the upper eyelid, the mucous membrane of the frontal, the galea aponeurosis, and the orbicularis oculi. It ascends to the forehead, dividing into a smaller medial and a lateral branch, which supply the skin of the scalp nearly as far back as the lambdoid suture.
- b. The nasociliary nerve is more deeply placed in the orbit. The sensory root from the nasociliary nerve passes to the globe through the short ciliary nerves and conveys sensation to cornea and globe. At the level of the fissure, the nasociliary nerve gently ascends to reach the medial part of the orbit, where it gives rise to the anterior and posterior ethmoidal nerves and infratrochlear nerve. The anterior ethmoidal nerve gives off two branches, the internal nasal and external nasal nerves. The internal nasal nerve innervates the mucous membrane of the anterior part of the nasal septum and the lateral wall of the nasal cavity. The external nasal branch innervates the skin over the apex and the *ala* of nose. The posterior ethmoidal nerve supplies the ethmoidal and sphenoidal sinuses. The infratrochlear nerve gives sensitive innervation to the skin of the eyelids and bridge of the nose, conjunctiva, and also to the skin of the lacrimal sac and caruncle.
- c. The lacrimal nerve is the smallest of the three division of the V1 and conveys sensation from the area in front of the lacrimal gland.

Anesthetic considerations:

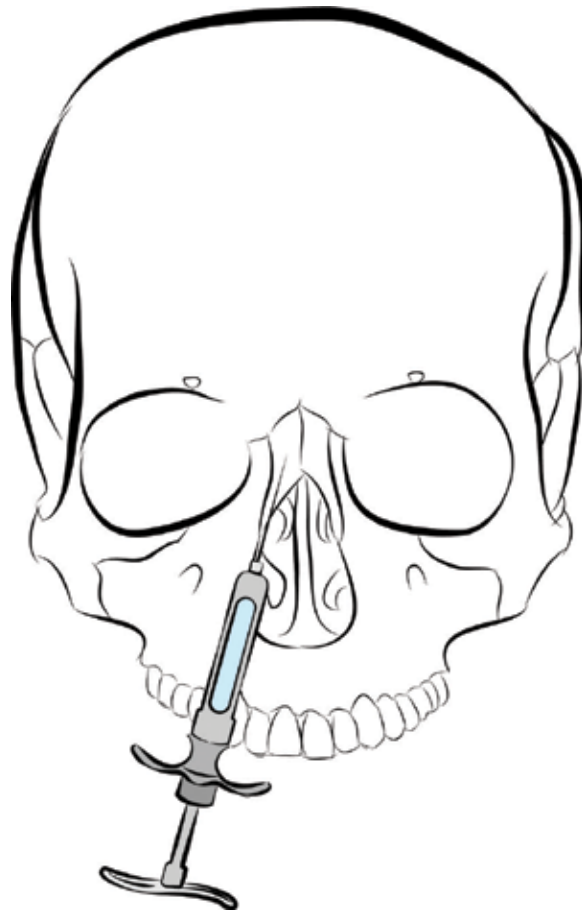
- The anesthetic block of the first division of the trigeminal nerve is useful for the execution of procedures on the territories innervated by the terminal branches.
- The supraorbital, supratrochlear, and infratrochlear nerves can be easily anesthetized through the location of the supraorbital notch or foramen (see **Figure 2**).
- The supraorbital foramen is located 29 mm lateral to the midline (25–33 mm) and 5 mm below the upper margin of the supraorbital rim (range, 4–6 mm) [3]. This supraorbital notch is readily palpable in most patients and when injecting this area, it is prudent to use the free hand to palpate the orbital rim to prevent inadvertent injection into the globe. The supratrochlear nerve is located medial to the supraorbital nerve at the supraorbital rim and emerges between the trochlea and the supraorbital foramen located 16 mm lateral to

the midline (range, 12–21 mm) and 7 mm below the upper margin of the supraorbital rim (range, 6–9 mm) [3]. The infratrochlear nerve can be blocked injecting local anesthetic solution at the junction of the orbit and the nasal bones.

- The external nasal nerve emerges 5–10 mm from the nasal midline at the osseous junction of the inferior portion of the nasal bones (the distal edge of the nasal bones) and can be blocked subcutaneously at the osseous-cartilaginous junction of the distal nasal bones (see **Figure 3**).



**Figure 2.** Points to anesthetic block of the supraorbital and supratrochlear nerves. Adapted from: *Simplified Facial Rejuvenation*. 1st ed. Heidelberg: Springer; 2008.



**Figure 3.** Anesthetic block of external nasal branches.

#### **4. Maxillary division**

The maxillary nerve (V2), the intermediate division of the trigeminal nerve, is purely sensory in function. The V2 gives innervation to all structures in and around the maxillary bone and the mid-facial region, including the skin of the mid-facial regions, the lower eyelid, side of the nose, and upper lip; nasopharyngeal mucosa, maxillary sinus, soft and hard palate, palatine tonsil, maxillary teeth, and periodontal tissues [3].

The maxillary nerve leaves the endocranium through the foramen rotundum, located in the greater wing of the sphenoid bone, to enter the pterygopalatine fossa (PPF).

The PPF is a pyramidal space located between the pterygoid bone posteriorly, the perpendicular plate of the palatine bone anteromedially, and maxilla anterolaterally. It opens

laterally into the medial part of the infratemporal fossa through the pterygomaxillary fissure and superiorly through the medial part of the inferior orbital fissure into the orbital apex. The fossa also communicates posterolaterally with middle cranial fossa through the foramen rotundum, posteromedially with foramen lacerum through the vidian canal, medially with the nasopharynx through the palatovaginal canal, inferomedially with the oral cavity through the palatine foramina, and medially with nasal cavity through the sphenopalatine foramen.

The V2, after entering the PPF, gives off ganglionic branches to the pterygopalatine ganglion (PPG). It then deviates laterally just beneath the inferior orbital fissure, giving rise to the zygomatic nerve and posterosuperior alveolar nerve.

Anesthetic considerations:

- The zygomatic nerve enters the orbit through the inferior orbital fissure, where it divides into zygomaticotemporal and zygomaticofacial nerves. These nerves give innervation to the skin on the temporal area and on the prominence of the cheek, respectively (see **Figure 1**).
- The zygomaticofacial nerve is blocked by injecting the inferior lateral portion of the orbital rim, and the zygomaticotemporal nerve is blocked by placing the needle on the concave surface of the posterior lateral orbital rim (see **Figure 4**).

In the posterior aspect of the maxillary tuberosity, one to three small holes, 1–2 mm in diameter, can be clearly seen, which are located between 10 and 25 mm above the alveolar rim and behind the second or at the height of the third upper molar. These holes are continued with small ducts or grooves that run through the posterolateral wall of the maxillary sinus until reaching the dental apices. It contains the posterosuperior alveolar vessels and nerves; it is destined to the superior molars, premolars, and neighboring tissues.

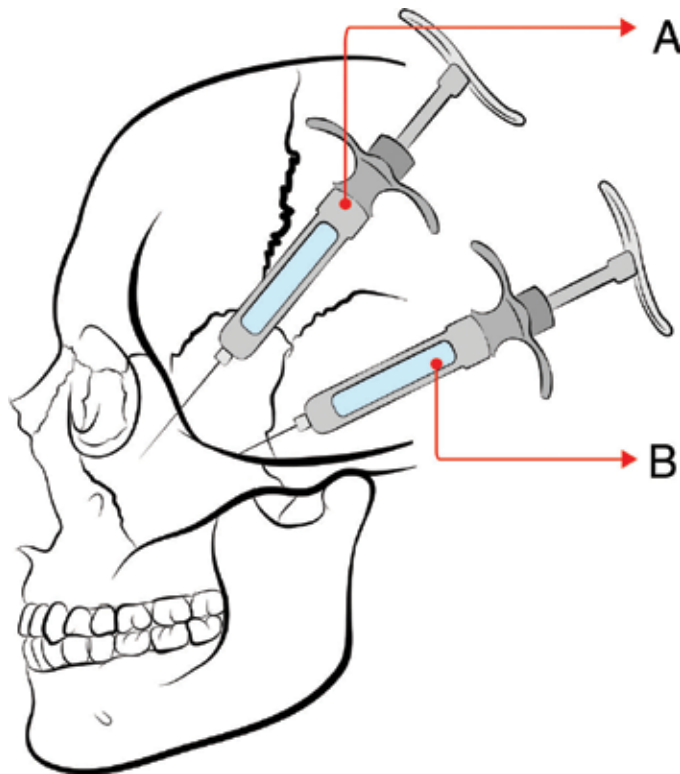
The posterior superior alveolar nerve arises from the maxillary nerve before penetrating into the infraorbital canal in the PPF and descends anteriorly and inferiorly to pierce the infratemporal surface of the maxillary sinus (see **Figure 5**). After entering the maxillary sinus, the nerves pass forward under the mucosa of the maxillary sinus, supplying afferent innervation to these membranes. It also supplies a branch to the upper gum and the adjoining part of the cheek [3].

The middle superior alveolar nerve leaves the infraorbital nerve (ION) in the infraorbital groove, the posterior part of the infraorbital canal. It runs down and forward in the lateral wall of the maxillary sinus and ends in small branches which link up with the superior dental plexus, supplying small rami to the upper premolar teeth [4] and first molar (**Table 1**).

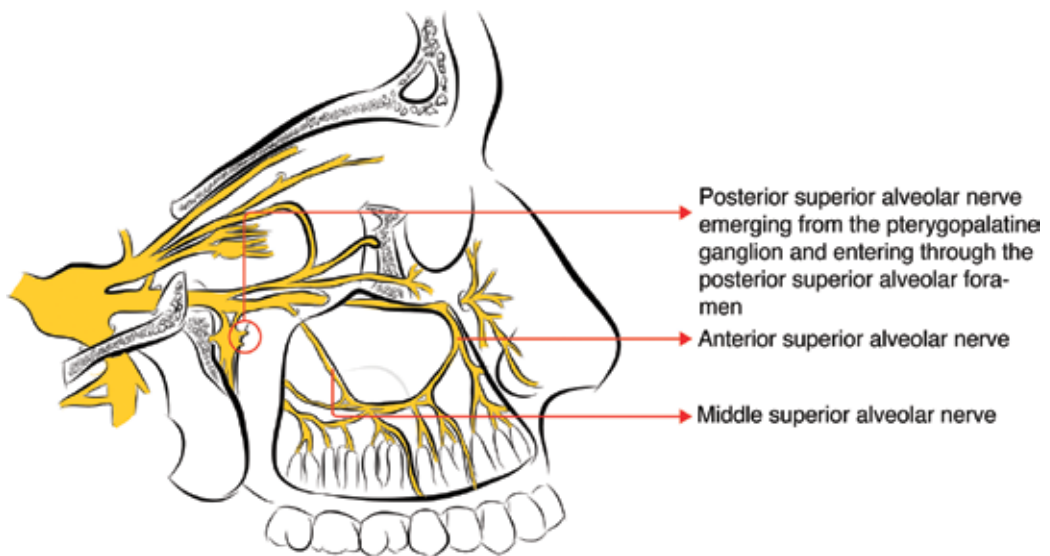
The pterygopalatine ganglion gives rise to: from the lower surface the greater and lesser palatine nerves; from the medial surface the sphenopalatine nerve and pharyngeal branch; and from the superior surface the orbital branch.

The palatine nerves are distributed over much of the roof of the mouth, the soft palate, the amygdala, and the nasal mucosa. The major palatine nerve descends through the greater palatine canal, which begins at the lower end of the PPF, it passes through this duct, and inside, it





**Figure 4.** Image showing the needle directions for block technique of (A) zygomaticofacial nerve and (B) zygomaticotemporal nerve (copyright of authors).



**Figure 5.** Image showing the posterior superior alveolar nerve anatomy entering at maxillary bone, true 3–4 holes in the tuberosity (copyright of authors).

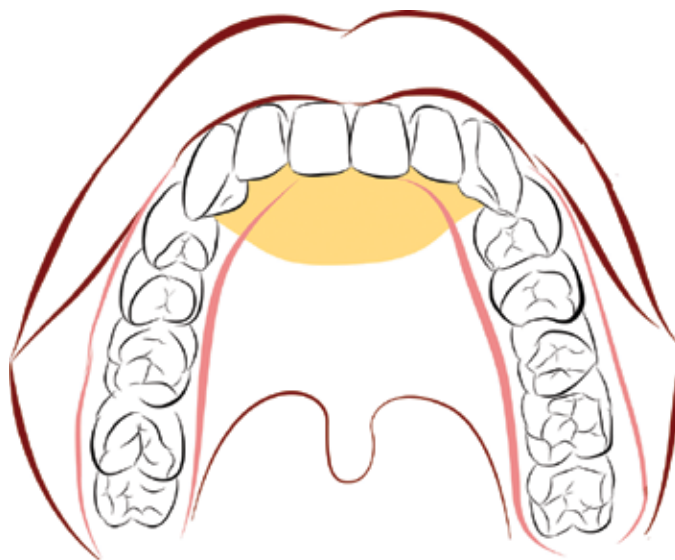
Anesthetized nerves	<ul style="list-style-type: none"> <li>Posterior superior alveolar nerve (local anesthetic reaches the nerve at its one to three entry holes in the posterior aspect of the maxillary tuberosity)</li> </ul>
Anesthetized areas	<ul style="list-style-type: none"> <li>Pulp of the superior molar dental pieces (excepting the mesiobuccal root of the maxillary first molar, which can be innervated by superior middle alveolar nerve or by the Auerbach plexus)</li> <li>Vestibular gingival mucosa and periodontium of the abovementioned dental pieces</li> <li>Vestibular layer of the alveolar ridge</li> </ul>
Anatomical references	<ul style="list-style-type: none"> <li>2 cm cephalic to the alveolar ridge</li> <li>2 cm ventral to the maxillary tuberosity</li> </ul>
Patient/operator position	<ul style="list-style-type: none"> <li>Maxillary occlusal plane positioned perpendicularly to the floor</li> <li>Operator positioned from 9 to 10 o'clock</li> </ul>
Local anesthetic volume required	1.8 mL
Needle required	<ul style="list-style-type: none"> <li>Short or long needle, 25 G</li> </ul>
Needle direction	<ul style="list-style-type: none"> <li>From caudal to cephalic in 45°</li> <li>From lateral to medial</li> <li>From ventral to dorsal, without loss contact with tuberosity bone</li> </ul>
Needle puncture depth	15 mm

**Table 1.** Posterior superior alveolar nerve block technique.

runs down, forward, and inward, and appears in the mouth through the major palatine foramen of the maxillary. It communicates with the filaments of the nasopalatine nerve, a branch of the sphenopalatine nerve [3].

The lesser palatine nerves, after leaving the PPF, descend and appear in the mouth through a lesser palatine foramen in the palatine bone and give branches to the uvula, tonsil, and soft palate. These nerves anastomose with branches of the glossopharyngeal nerve to form a tonsillar plexus around the palatine tonsil [3].

The nasopalatine nerve, the largest of the nasal branches of the PPG, travels through the sphenopalatine foramen, located just below the sphenoid sinus, enters into the nasal cavity and reaches the nasal septum. It then runs anteroinferiorly between the periosteum and mucous membrane of the nasal septum, supplies a few filaments to the nasal septum, exits the nasal



**Figure 6.** Image showing the palatal mucosal area innervated by nasopalatine nerve (copyright of authors).

cavity through the incisive foramen, and ends by supplying the mucosa of the anterior part of the hard palate [3] (see **Figure 6**).

Other nasal branches include medial and lateral posterior superior nasal nerves. The lateral posterior superior nasal branches innervate the mucosa of the posterior part of the superior and middle nasal conchae and the lining of the posterior ethmoidal sinuses. The medial posterior superior nasal branches supply the mucosa of the posterior part of the roof and of the nasal septum.

The anterior palatine canal, also called nasopalatine, presents a Y-shape and is formed by the union of two lateral canals excavated in the palatine apophyses of the jaws, one to each side of the nasal septum, in the anterior area of the nasal floor, where they converge in one. With a top-down and back-to-front direction, its total length varies between 8 and 20 mm. Its mouth end in the palate is made through a depression or fovea, the anterior palatine foramen or incisor foramen, which may have an oval, triangular, rectangular, or racket shape, with a major axis of approximately 1 cm and a width of 5 mm. While the nasal holes that initiate this duct are located approximately 15–20 mm behind the piriform notch, the incisive foramen is located between 4 and 10 mm behind the alveolar ridge, under a thickening of the palatal mucosa, called the incisive papilla (**Table 2**).

The palatine canal, which leads to the descending palatine artery, a venous vessel and the major palatine nerve, it is an access route to the pterygomaxillary fossa from the oral cavity. The maxillary nerve block via the greater palatine canal technique will anesthetize all the terminal branches of the maxillary nerve with a single injection.

Anesthetized nerves	<ul style="list-style-type: none"> <li>Nasopalatine nerve bilaterally (both side nerves confluence in the midline forming the incisive papilla)</li> </ul>
Anesthetized areas	<ul style="list-style-type: none"> <li>Palatine mucosa from canine to canine</li> <li>Underlying hard tissues (mucoperiosteum)</li> </ul>
Anatomical references	<ul style="list-style-type: none"> <li>Incisal papilla, located in the midline 5 mm posterior to the inter-incisal space between superior central incisors</li> </ul>
Patient/operator position	<ul style="list-style-type: none"> <li>Maxillary occlusal plane positioned perpendicularly to the floor</li> <li>Operator positioned from 9 to 10 o'clock</li> </ul>
Local anesthetic volume required	0.5 mL
Needle required	<ul style="list-style-type: none"> <li>Short needle, 25 G</li> </ul>
Needle direction	<ul style="list-style-type: none"> <li>From caudal to cephalic in 75°</li> <li>Ventral to dorsal</li> </ul>
Needle puncture depth	10 mm

**Table 2.** Nasopalatine nerve block technique.

The greater palatine canal is formed by the union of two excavated channels, one in the maxilla and another in the vertical sheet of the palatal bone. From the palate, its direction is outward, backward, and upright (inclinations of 5–10°, 15–20°, and 60–70°, respectively), with a length varying between 10 and 22 mm, depending on the facial biotype.

The greater palatine canal emerges onto the oral cavity through the greater palatine foramen. This foramen has an oval shape, with a larger diameter that can easily reach 5 mm. It is located in the angle that forms the horizontal portion of the palatine bone and the inner side of the maxillary alveolar ridge. In the soft tissues that cover it, a mild depression is observed, and this is an important aspect that can help in the appropriate location of the foramen for anesthetic purposes. Its posterior border lies approximately 1 cm in front of the hook of the pterygoid process and 5–6 mm in front of the border between hard and soft palate, which translates clinically as a change in the coloration of the palatal mucosa. The location of the palatine foramen in relation to the molars varies with age and individual characteristics, being able to be in front or distal to the third molar or—less frequently—between this and the second molar [4]; in young individuals who do not yet have the third molar, it is located in front of the distal side of the second; and in children less than 12 years old, it is usually in front of the distal face of the first molar (Table 3).

After entering the PPF, the V2 then turns medially as the infraorbital nerve (ION), passing through the inferior orbital fissure to enter the infraorbital groove, from where the anterior

Anesthetized nerves	<ul style="list-style-type: none"> <li>• Maxillary division of the trigeminal nerve and all of its branches (local anesthetic reaches the maxillary nerve at the pterygopalatine fossa)</li> </ul>
Anesthetized areas	<ul style="list-style-type: none"> <li>• Pulp of dental pieces of the ipsilateral hemimaxilla</li> <li>• Periodontium and alveolar bone related to the abovementioned dental pieces</li> <li>• Palatine mucosa of the ipsilateral hemimaxilla</li> <li>• Skin of the ipsilateral lower eyelid, lateral wall of the nasal pyramid, cheek, and superior lip without crossing the midline</li> </ul>
Anatomical references	<ul style="list-style-type: none"> <li>• 10 mm medial to the distal surface of the second molar</li> <li>• Alternatively, 15 mm lateral to the palate midline can be used as reference (useful in the edentulous patient, where dental references are lost)</li> <li>• 3.5 mm anterior to the limit between soft palate and hard palate</li> </ul>
Patient/Operator position	<ul style="list-style-type: none"> <li>• Cervical hyperextension, maxillary occlusal plane positioned perpendicularly to the floor</li> <li>• Maximum mouth opening</li> <li>• Operator positioned from 9 to 10 o'clock</li> </ul>
Local anesthetic volume required	1.8 mL
Needle required	<ul style="list-style-type: none"> <li>• Long needle, 25 G</li> </ul>
Needle direction	<ul style="list-style-type: none"> <li>• From caudal to cephalic</li> <li>• From ventral to dorsal</li> <li>• From medial to lateral</li> </ul>
Needle puncture depth	30–35 mm

**Table 3.** Maxillary nerve block technique via the greater palatine canal.

and middle superior alveolar nerves arise. The long axis of the infraorbital canal is directed forward, down, and medially through its canal lying progressively below the floor of the orbit and in the roof of the maxillary sinus, until it emerges in the face through the infraorbital foramen.

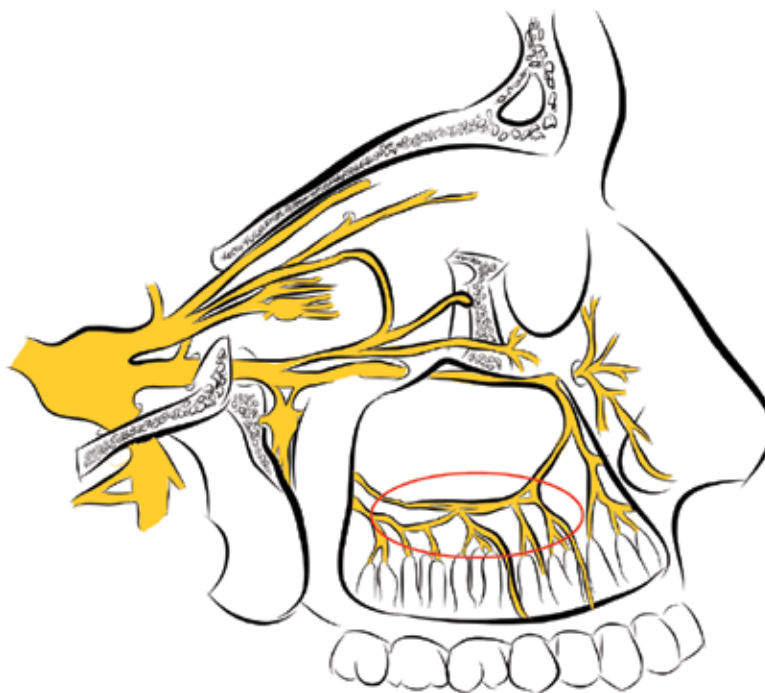
The anterior superior alveolar nerve leaves the lateral side of the ION just prior to the infraorbital exit through the foramen. It traverses the canal in the anterior wall of maxillary sinus and divides into branches supplying incisor and canine teeth. In the absence of middle superior alveolar nerves, which happens in approximately 70% of cases [4], the anterior superior

alveolar nerve emits a few posterior branches, which join with branches of the posterior superior alveolar nerve to form a nervous plexus also called the Auerbach dental plexus, which is distributed through the lateral wall of the maxillary sinus and innervates the premolars and the mesiobuccal root of the first molar [1] (see **Figure 7**).

The infraorbital nerve (ION) is the terminal branch of the maxillary nerve, and after emerging onto the face, it divides onto its terminal branches: inferior palpebral, nasal, and superior labial branches [5], which supply the skin and conjunctiva of the lower eyelid, the lateral skin of the nose, the movable part of the nasal septum and vestibule of the nose, the skin over the cheek and upper lip, and the related oral mucosa [5].

The infraorbital notch or foramen is the facial or anterior opening of the infraorbital canal. In a generally oval shape, its major axis is oblique downward and outward, with a maximum length of 6 mm. Due to the final orientation of the infraorbital canal, the foramen has a superior cutting edge, which is notorious, whereas its lower border is imperceptible, being confused with the anterior aspect of the maxilla, which at this point forms the canine fossa.

The infraorbital foramen is single in 90–97% of the cases [4]. Several authors have also described the presence of an accessory infraorbital foramen through which a branch of the ION passes. A recent systematic review showed that the frequency of skulls containing the



**Figure 7.** Image showing the anatomical alternative with Auerbach's plexus (circle) (copyright of authors).

accessory infraorbital foramen ranged from 0.8 to 27.3%, with a mean frequency of  $16.9 \pm 8.6\%$ , being more frequent in left side of the skull [6]. This is important because a partial nerve blockade during anesthesia can lead to an insufficient blockage of the ION.

In a study by Hu et al. [5], the accessory infraorbital foramen was found in 14% of the cases, and the nerve component that exited through the accessory infraorbital foramen was either the inferior palpebral branch, or the external nasal branch.

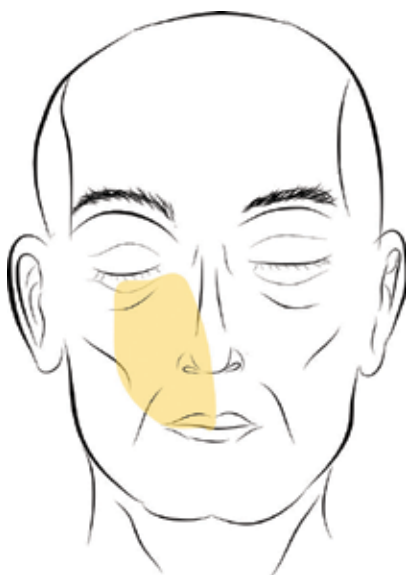The topography of both the canal and the infraorbital foramen is of special importance in the practice of anesthesia of the anterior superior alveolar nerves and the infraorbital nerve branches.

To properly locate the infraorbital foramen, we must consider that *it* is normally located within 1 cm of the inferior border of the orbital rim [3, 7].

In the lateral sense, it is located at the junction of the inner third and the middle third of the infraorbital rim. It also corresponds to an imaginary vertical line drawn downward from the supraorbital notch, joining the infraorbital and mental foramen.

A successful infraorbital nerve block will anesthetize the infraorbital cheek, the lower palpebral area, the lateral nasal area, and superior labial regions (see **Figure 8**).

The aforementioned infraorbital nerve blocks provide anesthesia to the lateral nasal skin but do not provide anesthesia to the central portion of the nose. An external nasal nerve of the block will supplement nasal anesthesia by providing anesthesia over the area of the cartilaginous nasal dorsum and tip (**Table 4**).



**Figure 8.** Image showing area innervated by infraorbital nerve (copyright of authors).

Anesthetized nerves	<ul style="list-style-type: none"> <li>• Anterior superior alveolar nerve</li> <li>• Middle superior alveolar nerve</li> <li>• Infraorbital nerve and its branches: <ul style="list-style-type: none"> <li>• Inferior palpebral nerve</li> <li>• Lateral nasal nerve</li> <li>• Superior labial nerve</li> </ul> </li> </ul>
Anesthetized areas	<ul style="list-style-type: none"> <li>• Pulp of dental pieces including from central incisors to second premolars</li> <li>• Gingival mucosa vestibular to the abovementioned dental pieces</li> <li>• Wing of the nose skin</li> <li>• Inferior eyelid</li> <li>• Ipsilateral superior lip</li> </ul>
Anatomical references	<ul style="list-style-type: none"> <li>• Union of internal third and lateral two-thirds of the inferior orbital rim</li> <li>• Intraoral technique: bottom of the oral vestibule in relation with the ipsilateral first premolar</li> </ul>
Patient/operator position	<ul style="list-style-type: none"> <li>• Maxillary occlusal plane positioned perpendicularly to the floor</li> <li>• Operator positioned from 9 to 10 o'clock</li> </ul>
Local anesthetic volume required	0.9–1.2 mL
Needle required	<ul style="list-style-type: none"> <li>• Long needle, 25 G for intra-oral technique</li> <li>• Short needle, 25 G for extra-oral technique</li> </ul>
Needle direction	<ul style="list-style-type: none"> <li>• From ventral to dorsal</li> <li>• From medial to lateral</li> <li>• From caudal to cephalic</li> </ul>
Needle puncture depth	16 mm for intraoral technique

**Table 4.** Infraorbital nerve block technique.

## 5. Mandibular division

The mandibular division (V3) is the largest branch of the trigeminal nerve. It supplies the teeth and gums of the mandible, the skin in the temporal region, part of the auricle, the lower lip, and the lower part of the face. The V3 also contains motor fiber to innervate the muscle of mastication, the mylohyoid, the anterior belly of the digastric muscle, tensor veli palatini, and tensor tympani muscle [1].

The V3 is made up of two roots: a large, sensory root, which proceeds from the lateral part of the trigeminal ganglion and emerges almost immediately through the foramen ovale of the sphenoid bone and a small motor root that passes below the trigeminal ganglion and unites



with the sensory root just outside the foramen ovale. This trunk it later splits into a small anterior and a large posterior division.

Branches from the anterior division provide motor innervation to the muscles of mastication, and sensory innervation to the mucous membrane of the cheek and buccal mucous membrane of the molars.

The anterior division of V3 runs under the lateral pterygoid and then emerges between its two heads to become the buccal nerve, the only sensory component of the anterior division. Under the lateral pterygoid, this nerve gives off several motor branches; the deep temporal nerves, the masseter, and lateral pterygoid nerves.

At the level of the occlusal plane of the mandibular molars, the buccal nerve crosses in front of the anterior border of the ramus and enters the cheek through the buccinator muscle. It gives innervation to the skin of the cheek, the buccal gingiva of the mandibular molars, and the mucobuccal fold in that region [1].

The posterior division of V3 gives rise to sensory branches and one motor branch. It descends downward and medially to the lateral pterygoid muscle, at which point it branches into the auriculotemporal, lingual, and inferior alveolar nerves.

The auriculotemporal nerve provides sensitive innervation to the skin over the helix and tragus of the ear, the external auditory meatus, the posterior portion of the temporomandibular joint, and the skin over the temporal region.

The lingual nerve provides general sensation to the anterior two-thirds of the tongue and sensory innervation to the mucous membranes of the floor of the mouth and the lingual gingiva of the mandible.

The inferior alveolar nerve descends medial to the lateral pterygoid muscle and lateroposterior to the lingual nerve, to the region between the sphenomandibular ligament and the medial surface of the mandibular ramus, where it is introduced into the mandibular canal at the level of the mandibular foramen. Immediately before the inferior alveolar nerve enters the mandibular foramen gives off a motor branch, the mylohyoid nerve, which supplies the mylohyoid muscle and anterior belly of the digastric muscle. Nevertheless, some fibers of the mylohyoid nerve could enter into mandibula through the retromandibular foramina and provide innervation to premolar, canine, and incisor teeth [4, 8].

The inferior alveolar nerve travels anteriorly through the mandibular canal and gives off branches to the teeth, which may form a plexus between the trunk of the nerve and the roots of the teeth. The dental branches of the inferior alveolar nerve supply the molar, premolar, canine, and incisors teeth. The inferior alveolar nerve emerges in the mental foramen where it divides into the terminal branches: the incisive and mental nerve.

The mental nerve, pure sensory, leaves the interior of the mandible to supply the skin of the chin and lower lip, the mucosa of the lip, and the adjacent gum.

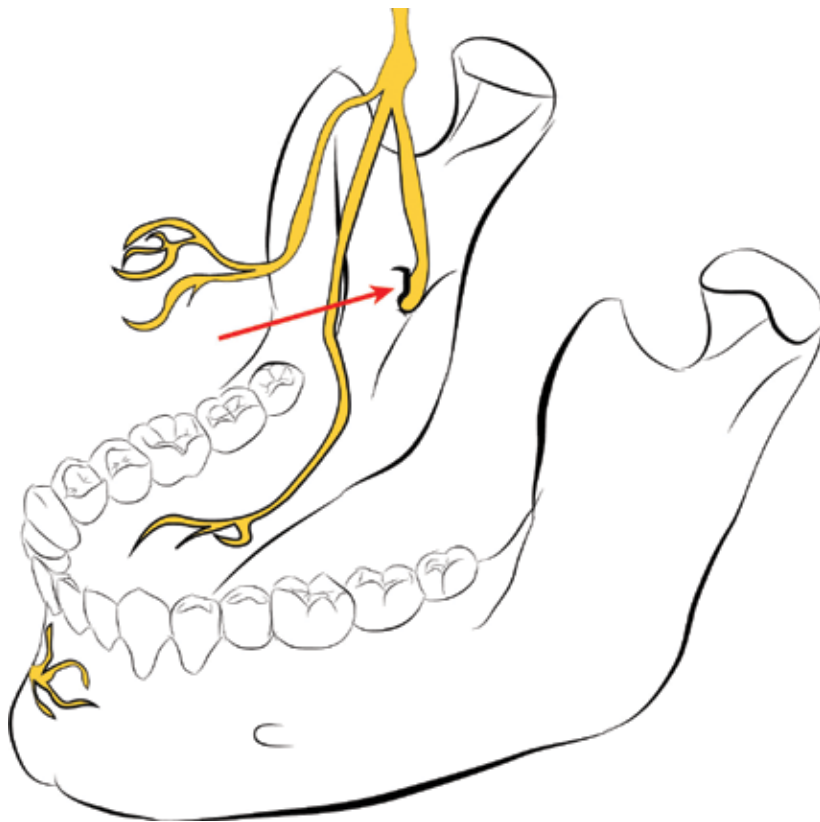
A continuation of the mandibular canal, the mandibular incisive canal, is a normal structure that typically extends closer to the mandibular midline after the mental nerve emerges

through the mandibular foramen [9, 10]. The mandibular incisive nerve travels within this canal and forms a nerve plexus via dental branches to supply innervation to first bicuspid, canine, and lateral and central incisors.

Given that the mandibular bone is very thick, an anesthetic technique with successful nerve block of the V3 branches requires knowledge of the location of the mandibular bone repairs that allows the deposition of the anesthetic in areas close to the nerve trunks before they enter or after they leave the mandibular canal.

The mandibular foramen is located in the medial surface of the mandibular ramus and is the entrance to the mandibular canal, excavated in the thickness of the mandible. This foramen acquires relevance in oral surgery since it is a critical point for the nerve block anesthesia of the inferior alveolar nerve. It has the appearance of a wide cleft, limited from the anterior side by a bony plate called the lingula of the mandible or spine of spix [8] (see **Figure 9**).

The lingula can be palpated through the mucosa of the oral cavity. It shows the way, where one should point the needle, when anesthetizing the inferior alveolar nerve [8].



**Figure 9.** Image showing distribution of buccal, lingual, and inferior alveolar nerves at mandibular lingula or spine of spix level (arrow) (copyright of authors).

The location of the inferior alveolar foramen would be equidistant from the four edges of the mandibular ramus, although it is usually observed closer to the mandibular notch and to the posterior edge of the mandibular ramus [8]. In the vertical direction, the distance between the hole and the occlusal plane is correlated with the patient's age: as the individual grows, the mandibular foramen moves cranially and positions itself in the center of the corpus [8]. In very young individuals, the mandibular foramen is located approximately at the level of the occlusal plane [11].

In the mentioned foramen, the nerve lies anteriorly and medially to the inferior alveolar artery. Such a configuration occurs in 60% of the cases. In 20%, the nerve is located laterally, and in 10%, posteriorly to the artery. In 10%, the nerve is placed independently to the artery [8] (Table 5).

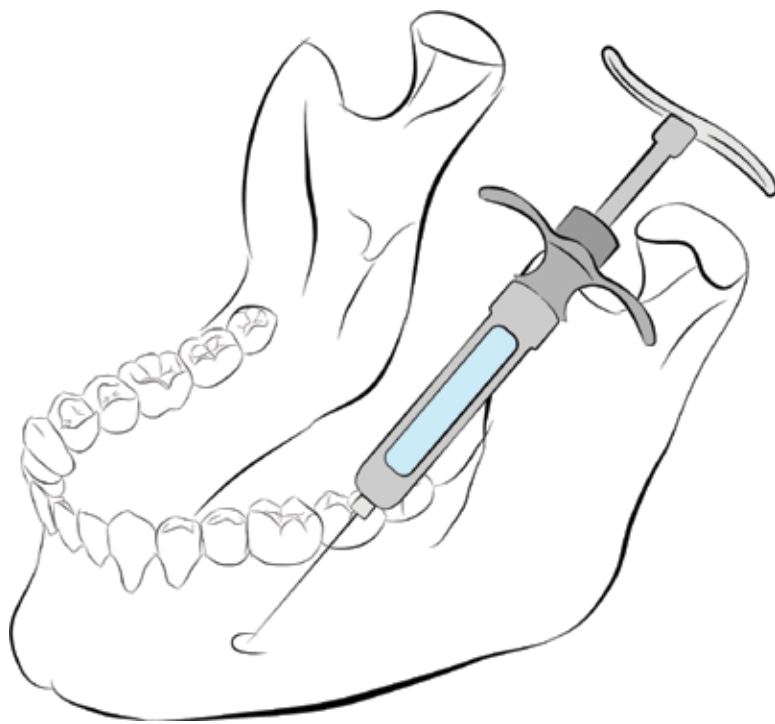
Anesthetized nerves	<ul style="list-style-type: none"> <li>• Inferior alveolar nerve (local anesthetic reaches the nerve at its entry to the mandibular canal through the inferior alveolar foramen, in the medial surface of the mandibular ramus)</li> <li>• Buccal nerve</li> <li>• Lingual nerve</li> </ul>
Anesthetized areas	<ul style="list-style-type: none"> <li>• Pulp of the dental pieces of the ipsilateral hemimandible</li> <li>• Vestibular and lingual mucoperiosteum of the ipsilateral hemimandible</li> <li>• Anterior two-thirds of the tongue</li> <li>• Floor of the mouth mucosa</li> <li>• Skin of the ipsilateral inferior lip and chin</li> </ul>
Anatomical references	<ul style="list-style-type: none"> <li>• 1 cm dorsal to the anterior edge of the mandibular ramus</li> <li>• Pterygomandibular raphe (clinical manifestation of the pterygomandibular ligament)</li> <li>• 1 cm cephalic to the mandibular occlusal plane</li> </ul>
Patient/operator position	<ul style="list-style-type: none"> <li>• Mandibular occlusal plane positioned parallel to the floor while the patient makes a maximal mouth opening</li> <li>• Operator positioned from 9 to 10 o'clock for the left hemimandible block (right-handed operator)</li> <li>• Operator facing the patient for the right hemi-mandible block (right-handed operator)</li> </ul>
Local anesthetic volume required	1.5 mL
Needle required	<ul style="list-style-type: none"> <li>• Long needle, 25 G</li> </ul>
Needle direction	<ul style="list-style-type: none"> <li>• From ventral to dorsal</li> <li>• From medial to lateral (placing the body of the syringe in contact with the contralateral corner of mouth)</li> </ul>
Needle puncture depth	20–25 mm

**Table 5.** Inferior alveolar, buccal, and lingual nerve block techniques.

The mandibular canal travels through the thickness of the mandible; first, close to the medial surface and then maintained equidistant and, at the anterior end, approach the external osseous table. The mental canal has an upward, backward, and lateral outward direction at an angle of  $45^\circ$  to the mandibular bone plane. As a consequence of this, the mental foramen regularly rounded and with a diameter of 3–5 mm has an acute lower anteroinferior border, whereas the posterosuperior half is confused with the bone plane of the mandibular body. The mental foramen may usually be found on the vertical line drawn downward from the supraorbital notch and lies below the level of premolar teeth (see **Figure 10**).

The mental foramen has many anatomical variations not only in its size and shape but also in its location and direction of the opening [9]. In a study by Kqiku et al. [12], the most common position of the mental foramen investigated—using anatomical dissection—was between the first and second mandibular premolars in 37.75% of the cases and 27.5% in line with the long axis of the second mandibular premolar.

These anatomical dispositions require that the approach of the mental foramen for anesthetic purposes consider the direction of the needle from back to front and from top to bottom. In an anteroposterior sense, the location of the mental foramen is in front of the second premolar or between both premolars, at a height—in the young adult—equidistant between the basilar border and the alveolar ridge (**Table 6**).



**Figure 10.** Image showing the needle direction for a successful mental anesthesia (copyright of authors).

Anesthetized nerves	<ul style="list-style-type: none"> <li>• Mental nerve, terminal branch of the inferior alveolar nerve</li> </ul>
Anesthetized areas	<ul style="list-style-type: none"> <li>• Pulp of the dental pieces from inferior second premolar to inferior central incisor</li> <li>• Vestibular mucoperiosteum of the abovementioned dental pieces</li> <li>• Skin of the ipsilateral inferior lip and chin</li> </ul>
Anatomical references	<ul style="list-style-type: none"> <li>• Almost bottom of the oral vestibule (more precise in the lip internal face), puncture site located between the apices of the inferior first and second premolars</li> </ul>
Patient/operator position	<ul style="list-style-type: none"> <li>• Mandibular occlusal plane positioned parallel to the floor, mandibular rest position</li> <li>• Operator facing the patient, approximately positioned at 8 o'clock</li> </ul>
Local anesthetic volume required	0.6 mL
Needle required	<ul style="list-style-type: none"> <li>• Short or long needle, 25 or 27 G</li> </ul>
Needle direction	<ul style="list-style-type: none"> <li>• From dorsal to ventral</li> <li>• From cephalic to caudal</li> <li>• From lateral to medial</li> </ul>
Needle puncture depth	23–25 mm

**Table 6.** Mental nerve block technique.

Branches of the cervical plexus could provide an additional innervation of the mandibular region. The great auricular nerve arises from the cervical plexus and provides sensory innervation of the skin over the parotid gland, the mastoid process, and the outer ears. Consequently, a separate infiltration of the great auricular may be needed to achieve total analgesia of the mandibular region when conventional anesthesia fails [4].

## Author details

Alex Vargas\*, Paula Astorga and Tomas Rioseco

\*Address all correspondence to: [avardix@gmail.com](mailto:avardix@gmail.com)

Medicine Faculty, Pontificia Universidad Catolica de Chile, Santiago, Chile

## References

- [1] Malamed SF. Techniques of regional anesthesia in dentistry. In: Duncan L, editor. Handbook of Local Anesthesia. 4th ed. St. Louis: Mosby; 1997. pp. 116-243

- [2] Niamtu III J. Local anesthetic blocks of the head and neck. In: Shiffman MA, Mirrafati SJ, Lam SM, Cueteaux CG, editors. *Simplified Facial Rejuvenation*. 1st ed. Heidelberg: Springer; 2008. pp. 29-44
- [3] Joo W, Yoshioka F, Funaki T, Mizokami K, Rhoton AL. Microsurgical anatomy of the trigeminal nerve. *Clinical Anatomy*. 2014;**27**(1):61-88. DOI: 10.1002/ca.22330
- [4] Rodella LF, Buffoli B, Labanca M, Rezzani R. A review of the mandibular and maxillary nerve supplies and their clinical relevance. *Archives of Oral Biology*. 2012;**57**(4):223-334. DOI: 10.1016/j.archoralbio.2011.09.007
- [5] Hu KS, Kwak J, Koh KS, Abe S, Fontaine C, Kim HJ. Topographic distribution area of the infraorbital nerve. *Surgical and Radiologic Anatomy*. 2007;**29**(5):383-388. DOI: 10.1007/s00276-007-0227-z
- [6] Martins-Júnior PA, Pereira C, De Maria M, Matias L, Henriques J, Miranda MR. Analysis of anatomical characteristics and morphometric aspects of infraorbital and accessory infraorbital foramina. *Journal of Craniofacial Surgery*. 2017;**28**(2):528-533
- [7] Ercikti N, Apaydin N, Kirici Y. Location of the infraorbital foramen with reference to soft tissue landmarks. *Surgical and Radiologic Anatomy*. 2016;**1**:1-6
- [8] Lipski M, Tomaszewska IM, Lipska W, Lis GJ, Tomaszewski KA. The mandible and its foramen: Anatomy, anthropology, embryology and resulting clinical implications. *Folia Morphologica*. 2013;**72**(4):285-292
- [9] Juodzbaly G, Wang H-L, Sabalys G. Anatomy of mandibular vital structures. Part II: Mandibular canal and inferior alveolar neurovascular bundle in relation with dental implantology. *Journal of Oral & Maxillofacial Research*. 2010;**1**(1):e2
- [10] Greenstein G, Tarnow D. The mental foramen and nerve: Clinical and anatomical factors related to dental implant placement: A literature review. *The Journal of Periodontology*. 2006;**77**(12):1933-1943
- [11] Epars J-F, Mavropoulos A, Kiliaridis S. Changes in the location of the human mandibular foramen as a function of growth and vertical facial type. *Acta Odontologica Scandinavica*. 2015;**73**(5):375-379
- [12] Kqiku L, Sivic E, Weiglein A, Städtler P. Position of the mental foramen: An anatomical study. *Wiener Medizinische Wochenschrift*. 2011;**161**(9-10):272-273

---

## Oral Rehabilitation

---





---

# Treatment Considerations for Missing Teeth

---

Abdolreza Jamilian, Alireza Darnahal,  
Ludovica Nucci, Fabrizia D'Apuzzo and  
Letizia Perillo

Additional information is available at the end of the chapter

<http://dx.doi.org/10.5772/intechopen.69543>

---

## Abstract

Specific terms are used to describe the nature of tooth agenesis. Hypodontia is most frequently used when describing the phenomenon of congenitally missing teeth. Many other terms to describe a reduction in the number of teeth appear in the literature: oligodontia, anodontia, aplasia of teeth, congenitally missing teeth, absence of teeth, agenesis of teeth and lack of teeth. The term hypodontia is used when one to six teeth, excluding third molars, are missing, and oligodontia when more than six teeth are absent (excluding the third molars). The long-term management of hypodontia in the aesthetic zone is a particularly challenging situation. Although there are essentially two distinct approaches to manage this problem, that is space closure or opening for prosthetic replacements, implant or autotransplantation. These patients often manifest with many underlying skeletal and dental problems and a multidisciplinary approach for management of this condition is recommended. Two treatment approaches including space closure and space reopening are described in details in this chapter.

**Keywords:** hypodontia, missing teeth, implant, orthodontic space closure, space reopening

---

## 1. Introduction

Missing is one of the most dental anomalies in practice of dentistry and they may affect the self-esteem and social well-being of the patients. This condition is often complicated by dental anomalies associated with hypodontia such as impacted teeth, microdontia, delayed eruption and taurodontism. Hypodontia reportedly affects between 3 and 8% of the population. Hypodontia is a common problem seen by the general dentist and is usually referred to the orthodontist [1, 2]. Agenesis means that a dental bud fails to develop or is not present at birth.

This problem leaves an empty space in the arch which causes plentiful problems. Specific terms have been used to describe the nature of tooth agenesis.

- Anodontia is named complete absence of teeth.
- Hypodontia means missing teeth, but usually less than six teeth.
- Oligodontia or partial anodontia is defined absence of six or more teeth.

Anodontia and oligodontia are rare; however, hypodontia is relatively a common problem. Many other terms are also used to describe a reduction in the number of teeth in the literature such as aplasia of teeth, agenesis of teeth, absence of teeth, lack of teeth and congenitally missing teeth [3, 4].

The aims of this chapter are as follows:

- To determine the prevalence of hypodontia
- To assess the etiology of hypodontia
- To diagnose the problem
- To plan the treatment
- To decide the open or close space in the dentition

## 2. Prevalence of hypodontia

Hypodontia in primary dentition arises in 0.1–0.9% of the population, with equal frequencies in both males and females. This problem is more common in the upper jaw and it is frequently related with the upper lateral incisor in the primary dentition. As a general rule, when the primary tooth is missing, its permanent counterpart will be missing [1]. Hypodontia in the permanent dentition occurs with equal rate in the upper and lower arches and usually affects the third molar. The type of agenesis in dentition and prevalence of missing vary with racial and ethnic groups. However, females are more frequently affected [2]. Prevalences of hypodontia vary between 1.6 and 9.6% across the world with exclusion of the third molars. Prevalence of agenesis differs between continents and races. The occurrence of missing permanent teeth, excluding the third molar is 3.4% in Swiss, 4.4% in the USA, 6.1% in Sweden, 8% in Finland and 9.6% in Austria with exclusion of third molar. Japanese people have the highest rates of agenesis both in primary and permanent dentition. Australian Aborigines and African Blacks might have a low rate of missing teeth. The rate of agenesis in Indians has been reported less than 1% [3, 4]. The prevalence of third molar missing has been reported of 9–37% [2]. Hall [5] reported that upper lateral incisors are the most agenesis teeth (not including third molars). Missing of the upper lateral incisor is also related to anomalies such as agenesis of other permanent teeth, undersized maxillary lateral incisors (peg laterals), palatally position of canines and distal displacement of lower second premolars [6–8]. Agenesis may arise in isolation, or as part of a syndrome. Dental anomalies, especially hypodontia, have frequently been found in children who also have cleft lip and cleft palate or a syndrome [9–11].

### 3. Etiology of hypodontia

Heredity and familial distribution are two of the possible factors associated with congenitally missing teeth. Shapira, et al. stated [12], 'Congenital partial anodontia appears to be the result of one or more point mutations in a closely linked polygenic system, most often transmitted in an autosomal dominant pattern incomplete penetrance and variable expressivity'. Genetics has a crucial role in hypodontia, as confirmed by the studies on monozygotic twins. The pattern of agenesis can differ between monozygotic twins, this issue possibly pointing to additional underlying mechanisms such as epigenetic factors, which might be implied occurrence of two anomalies simultaneously [13]. Genetic, epigenetic and environmental factors contribute to the development of hypodontia. It has been shown that genetics has a predominant role in the etiology of missing teeth [14]. Infection, trauma and drugs, as well as genes associated with syndromes play a crucial role in hypodontia. Agenesis may be an isolated condition or a dental appearance of special syndromes such as cleft lip and palate [9, 15, 16] and ectodermal dysplasia [17]. The isolated one can follow autosomal recessive, dominant, or X-linked patterns of inheritance [18]. Some studies showed that some anomalies such as bimaxillary retrusion, mandibular prognathism, decreased maxillary jaw size and reduced vertical facial dimension in patients affected with hypodontia [19, 20]. In hereditary cases, missing has greater incidence when the dental germ is developing after the adjacent tissues have closed the space needed for the tooth development. Other scientists reported that delays in tooth development and reductions in tooth size correlate with agenesis [21]. Both of these might agree with the terminal reduction theory. Moreover, it has also been reported that anterior agenesis may depend more on genes while posterior missing might be sporadic [22].

### 4. Diagnosis

Dental agenesis is categorized according to the number of missing teeth, less than three and six missing teeth are defined as mild and moderate, respectively. Clinical evaluation, radiographic and dental cast examinations are required for proper diagnosis. The third molar germ calcification initiates at the age of about 7.5 and in very few people, it starts at the age 9.5. Thus, by including patients younger than 9, researchers might overestimate the missing of the third molars. This might explain the high occurrence of agenesis in third molars which has been reported by some studies.

### 5. Treatment plan

Treatment needs an interdisciplinary approach including operative dentistry, paediatric dentistry, orthodontics and prosthodontics. Early extraction of primary canines might guide the eruption of the permanent canine into the proper position in cases with missing maxillary

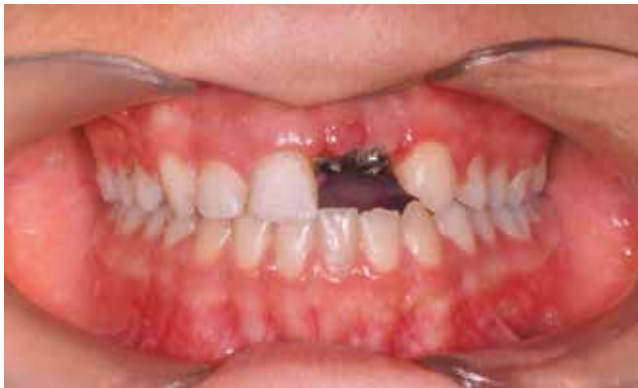lateral and impaction of upper canine. The amount of crowding, type of malocclusion, facial profile, age of the patient, periodontal conditions, bone volume in alveolar process, vertical or horizontal growth pattern, craniofacial morphology and the number of missing teeth should be considered in treatment plan. There are two treatment plans that include space reopening or space closing. Space can be reopened for implant insertion, auto transplantation and prosthetic restoration. Another treatment plan is space closing which can be done by fixed orthodontics.

## 6. Space closure versus space opening

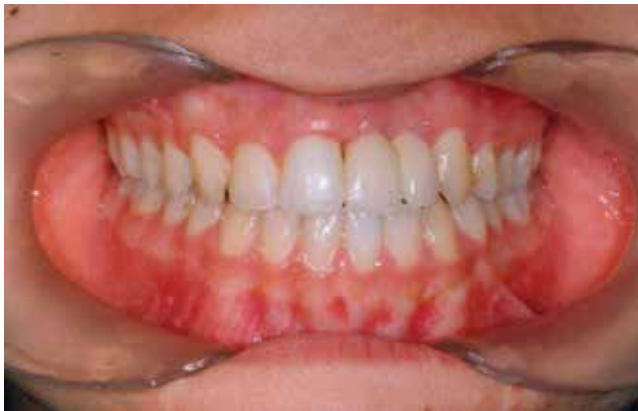Missing of maxillary incisors during the teenage years is a severe problem and often requires a challenging treatment plan. There are several solutions for treatment of lacking maxillary incisors including crown and bridge, resin bonded bridgework, removable partial dentures, osseointegrated implants, auto transplantation, orthodontic space closure [23–27]. Each of these methods has their own advantages and disadvantages; however, opening the space followed by implant insertion and space closure are the most common treatment options for tooth replacement. Implant insertion is an optimal treatment plan with obtaining an ideal occlusion and the indisputable advantage of avoiding any damage to the adjacent teeth [23, 28].

Space closing by mesial movement of the posterior teeth is a vital approach and it provides major satisfactory aesthetic and functional long-term results. Moreover; the result of space closure and all of the changes in the long term will be natural. It is clear that when implant or any prostheses are used, some changes could happen in the presence of a foreign body [26, 29, 30]. On the other hand, shorter and easier orthodontic treatment by implant insertion makes the space opening a favourable treatment approach for replacing missing teeth. Nevertheless, opening the space and implant insertion have some disadvantages. Implant insertion is contraindicated in growing patients. Implant must be postponed until the growth is ceased. If the implant is used at about 18 years of age, the neighbouring teeth and surrounding alveolar bone may continue to erupt. This eruption results in infraocclusion of the implant site. There will be a big discrepancy in vertical dimension between the gingival margin of the implanted tooth and the gingival margin of the neighbouring teeth. This side effect may appear in few years after implant insertion in young adult patients and the implant becomes submerged [31–34]. In patients where maxillary and mandibular incisors are not in contact with each other, the amount of extrusion might be 0/2–0/3 mm per year. Implant acts like an ankylosed teeth and its status cannot change in contrast to their adjacent teeth; thus, small displacement of neighbouring teeth after implant insertion can cause aesthetic complications [35–37]. Infra-positioned implant results in an unlevelled of gingival margins. This issue is a problematic challenge especially in patients with a high smile line. Thus, it is better not to use implant in cases with ‘gummy smile’ or vertical growth pattern patients [26]. Furthermore, it has been reported that more than 50% of single-implant crowns at 4-year follow-ups have some

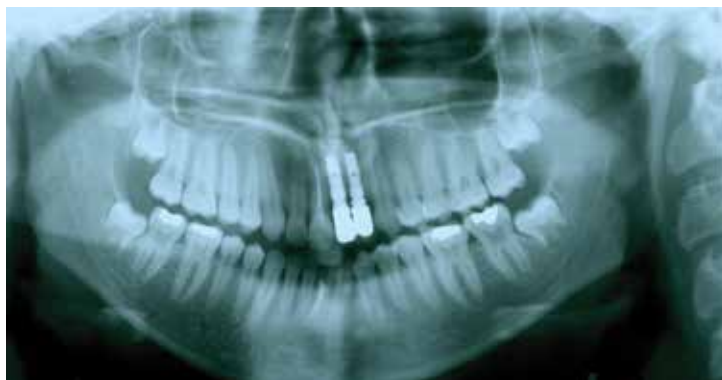extent of blue colouring of the gingiva [38]. Some other side effects such as bleeding on probing, gingivitis, increased probing depth, periodontitis, Peri-implantitis and progressive loss of marginal bone support of the implant, have also been shown in cases with implant insertion [36, 39–41]. Besides, the most problematic issue of the space opening is that the teenagers must wait many years after completion of orthodontic treatment for implant insertion. During this interim phase, the patients must use temporary crowns or restorations that often causes many difficulties and displacements both on implant site and adjacent teeth. On the other hand, orthodontic space closure is a practical and safe procedure that could achieve better long-term results. Moreover, none of the stated drawbacks have been found in orthodontic space closure [29, 42, 43]. Nevertheless, orthodontic space closure has its own disadvantages. Concerns may be related to the complexity of treatment, the risk for reopening of space, increased functional force on the first premolar roots [44]. Attempts for closing the space of upper incisors will tend to retract the anterior teeth, which may be favourable in class II division I malocclusion with maxillary protrusion. Space closure in the maxillary arch may well provide reduction of an increased overjet. However, space closing may be undesirable in class III malocclusion with maxillary deficiency. Moreover, space closure of a missing upper lateral incisor results in the canine being displaced mesially into contact with the central incisor. In this case, the canine is more prominent, wider and darker than the lateral incisor. Canine can be reshaped by selective grinding of the cusp tip and it needs rebuilding by composite materials like lateral incisor. In cases with increased overjet or crowding extraction of the contralateral lateral incisor may help to maintain symmetry and correct the dental midline. Space reopening is usually the best treatment option where orthodontic treatment does not need to use the space to relieve the crowding. In this case, any attempt to close the space results in an unfavourable effect. The major disadvantage of space reopening is that it requires a foreign body such as permanent prosthesis or implant. The optimal space required for the prosthesis or implant is usually determined by two factors. The first one is occlusion and the second is aesthetic. Ideal overjet and overbite must be provided along with good Class I malocclusion at the end of the treatment. A maxillary lateral incisor should be two thirds of the width of the maxillary central incisor. Providing of these conditions may be difficult due to anchorage problems associated with reduced numbers of teeth in hypodontia patients. In cases with extensive space or early loss of teeth which have resulted in alveolar atrophy, space closure will not be desirable. The position of the roots of the neighbouring teeth should be estimated radiographically in space opening cases. Therefore, not only adequate space must be provided for replacement of the crown but also the roots of neighbouring teeth should be parallel or slightly divergent to create adequate space for implant insertion [45, 46]. **Figures 1–3** show a patient immediately after implant insertion and **Figures 4–6** show the same patient after 5 years. However, these images illustrate that some changes such as infraocclusion and periodontal problems can be seen in implant site after 5 years. **Figures 7 and 8** show a patient with missing both maxillary lateral incisors treated by orthodontic space closure. **Figures 9 and 10** show the same patient 5 years after completion of treatment. These pictures demonstrate that the dentition, periodontal status have not been changed after 5 years in space closure.



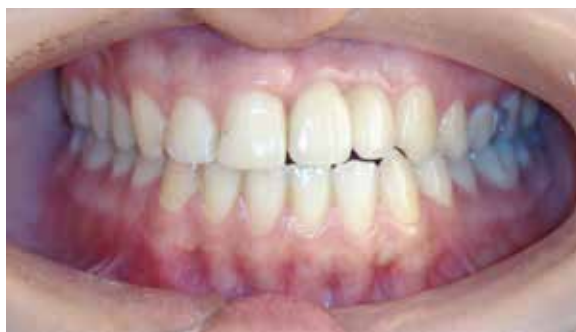**Figure 1.** A patient immediately after implant abutment insertion.



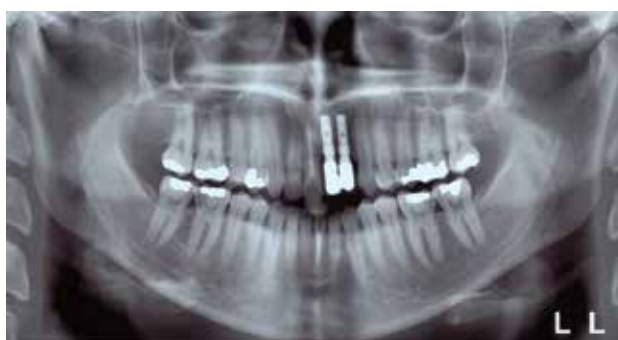**Figure 2.** A patient immediately after implant insertion.



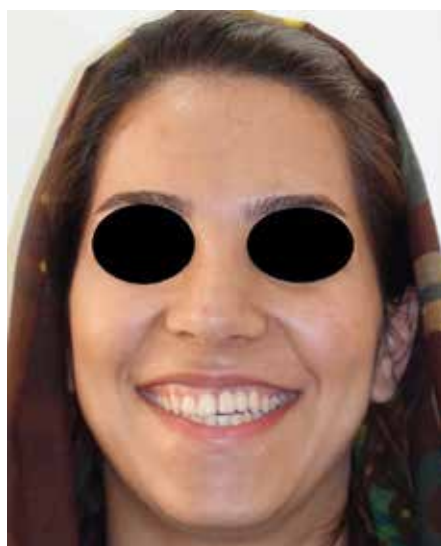**Figure 3.** OPG (Orthopantomogram) of the same patient.



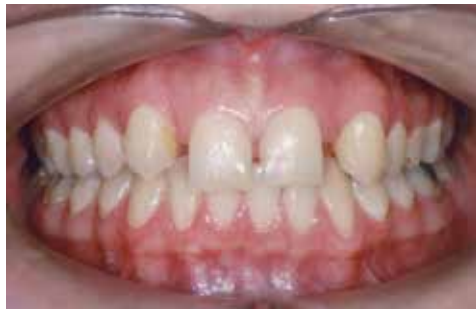**Figure 4.** Same patient after 5 years.



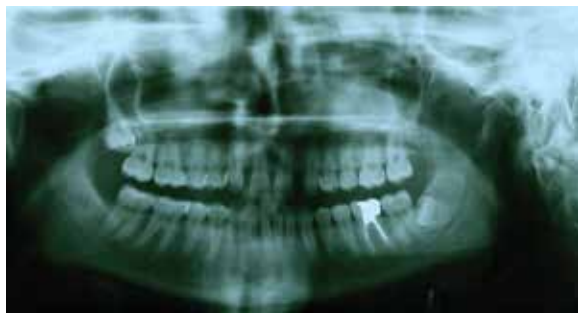**Figure 5.** OPG of the same patient after 5 years.



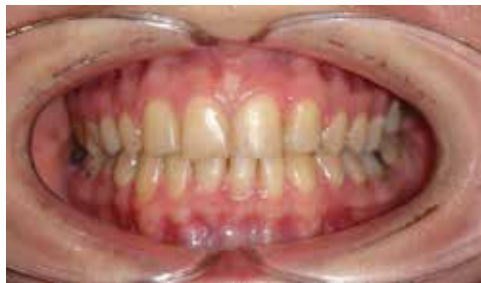**Figure 6.** Frontal view of the patient after 5 years.



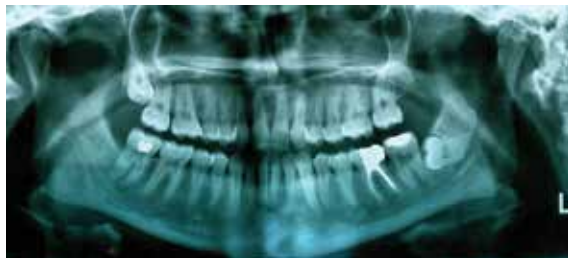**Figure 7.** A patient with missing maxillary lateral incisors.



**Figure 8.** OPG of the patient with missing maxillary incisors.



**Figure 9.** Same patient 5 years after orthodontic space closure.



**Figure 10.** OPG of the same patient 5 years after orthodontic space closure.



## 7. Conclusion

The main advantage of the space closure to implants can be followed as:

- The whole treatment can be finished immediately after completion of orthodontics in space closure cases. This issue is a vital interest for teenager patients.
- Better long-term aesthetic results can be provided in space closure due to lack of infraocclusion, blue colouring of the gingiva and periodontal problems.
- Gingivitis, periodontitis, and other periodontal problems will not occurring space closure because the tooth has displaced along with its surrounding tissues and its bone.
- Use of other prosthetic replacement for the missing incisor by partial denture or bonded bridges could require further treatments to substitute the restorations.
- Orthodontic space closure will decrease the financial charge for the patient.

## Author details

Abdolreza Jamilian<sup>1\*</sup>, Alireza Darnahal<sup>2</sup>, Ludovica Nucci<sup>3</sup>, Fabrizia D'Apuzzo<sup>3</sup> and Letizia Perillo<sup>3</sup>

\*Address all correspondence to: [info@jamilian.net](mailto:info@jamilian.net)

1 Department of Orthodontics, Tehran Dental Branch, Craniomaxillofacial Research Center, Islamic Azad University, Tehran, Iran

2 Tehran Dental Branch, Craniomaxillofacial Research Center, Islamic Azad University, Tehran, Iran

3 Multidisciplinary Department of Medical-Surgical and Dental Specialties, Second University of Naples, Naples, Italy

## References

- [1] Polder BJ et al. A meta-analysis of the prevalence of dental agenesis of permanent teeth. *Community Dentistry and Oral Epidemiology*. 2004;**32**(3):217-226
- [2] Jamilian A et al. Hypodontia and supernumerary and impacted teeth in children with various types of clefts. *American Journal of Orthodontics and Dentofacial Orthopedics*. 2015;**147**(2):221-225
- [3] Vastardis H. The genetics of human tooth agenesis: New discoveries for understanding dental anomalies. *American Journal of Orthodontics and Dentofacial Orthopedics*. 2000;**117**(6):650-656
- [4] Jamilian A, Perillo L, Rosa M. Missing upper incisors: A retrospective study of orthodontic space closure versus implant. *Progress in Orthodontics*. 2015;**16**:2

- [5] Hall RK. Congenitally missing teeth—A diagnostic feature in many syndromes of the head and neck. *Journal of the International Association of Dentistry for Children*. 1983;**14**(2):69-75
- [6] Aasheim B, Ogaard B. Hypodontia in 9-year-old Norwegians related to need of orthodontic treatment. *Scandinavian Journal of Dental Research*. 1993;**101**(5):257-260
- [7] Guttal KS et al. Frequency of developmental dental anomalies in the Indian population. *European Journal of Dentistry*. 2010;**4**(3):263-269
- [8] Carter NE et al. The interdisciplinary management of hypodontia: Orthodontics. *British Dental Journal*. 2003;**194**(7):361-366
- [9] Muller TP et al. A survey of congenitally missing permanent teeth. *Journal of the American Dental Association*. 1970;**81**(1):101-107
- [10] Garib DG et al. Agenesis of maxillary lateral incisors and associated dental anomalies. *American Journal of Orthodontics and Dentofacial Orthopedics*. 2010;**137**(6):732 e1-6; discussion 732-3
- [11] Peck S, Peck L, Kataja M. Concomitant occurrence of canine malposition and tooth agenesis: Evidence of orofacial genetic fields. *American Journal of Orthodontics and Dentofacial Orthopedics*. 2002;**122**(6):657-660
- [12] Shapira Y, Lubit E, Kuftinec MM. Hypodontia in children with various types of clefts. *Angle Orthodontist*. 2000;**70**(1):16-21
- [13] Jamilian A, Showkatbakhsh R, Boushehry MB. The effect of tongue appliance on the nasomaxillary complex in growing cleft lip and palate patients. *Journal of the Indian Society of Pedodontics and Preventive Dentistry*. 2006;**24**(3):136-139
- [14] Jamilian A, Nayeri F, Babayan A. Incidence of cleft lip and palate in Tehran. *Journal of the Indian Society of Pedodontics and Preventive Dentistry*. 2007;**25**(4):174-176
- [15] Graber LW. Congenital absence of teeth: A review with emphasis on inheritance patterns. *Journal of the American Dental Association*. 1978;**96**(2):266-275
- [16] Backman B, Wahlin YB. Variations in number and morphology of permanent teeth in 7-year-old Swedish children. *International Journal of Paediatric Dentistry*. 2001;**11**(1):11-7
- [17] Mirabella AD, Kokich VG, Rosa M. Analysis of crown widths in subjects with congenitally missing maxillary lateral incisors. *European Journal of Orthodontics*. 2012;**34**(6):783-787
- [18] Srivastava D et al. Use of anterior maxillary distraction osteogenesis in two cleft lip and palate patients. *National Journal of Maxillofacial Surgery*. 2015;**6**(1):80-83
- [19] Jamilian A et al. Cleft sidedness and congenitally missing teeth in patients with cleft lip and palate patients. *Progress in Orthodontics*. 2016;17:14
- [20] Lexner MO et al. Anomalies of tooth formation in hypohidrotic ectodermal dysplasia. *International Journal of Paediatric Dentistry*. 2007;**17**(1):10-18

- [21] Ahmad W et al. A locus for autosomal recessive hypodontia with associated dental anomalies maps to chromosome 16q12.1. *American Journal of Human Genetics*. 1998;**62**(4):987-991
- [22] Tavajohi-Kermani H, Kapur R, Sciote JJ. Tooth agenesis and craniofacial morphology in an orthodontic population. *American Journal of Orthodontics and Dentofacial Orthopedics*. 2002;**122**(1):39-47
- [23] Endo T et al. Hypodontia patterns and variations in craniofacial morphology in Japanese orthodontic patients. *Angle Orthodontist*. 2006;**76**(6):996-1003
- [24] Goya HA et al. An orthopantomographic study of hypodontia in permanent teeth of Japanese pediatric patients. *Journal of Oral Science*. 2008;**50**(2):143-150
- [25] Galluccio G, Pilotto A. Genetics of dental agenesis: Anterior and posterior area of the arch. *European Archives of Paediatric Dentistry*. 2008;**9**(1):41-45
- [26] Rupp RP, Dillehay JK, Squire CF. Orthodontics, prosthodontics, and periodontics: A multidisciplinary approach. *General Dentistry*. 1997;**45**(3):286-289
- [27] Ghassemi M et al. Orthodontic treatment after autotransplantation. *Angle Orthodontist*. 2011;**81**(4):721-725
- [28] Zachrisson BU, Stenvik A, Haanaes HR. Management of missing maxillary anterior teeth with emphasis on autotransplantation. *American Journal of Orthodontics and Dentofacial Orthopedics*. 2004;**126**(3):284-288
- [29] Zachrisson BU, Rosa M, Toreskog S. Congenitally missing maxillary lateral incisors: Canine substitution. *Point*. *American Journal of Orthodontics and Dentofacial Orthopedics*. 2011;**139**(4):434, 436, 438 passim
- [30] Showkatbakhsh R, Jamilian A. Opening or closing space for replacing upper incisors. Two case reports. *Revista Española de Ortodoncia*. 2010;**40**:181-185
- [31] Zachrisson BU. Planning esthetic treatment after avulsion of maxillary incisors. *Journal of the American Dental Association*. 2008;**139**(11):1484-1490
- [32] Nordquist GG, McNeill RW. Orthodontic vs. restorative treatment of the congenitally absent lateral incisor—Long term periodontal and occlusal evaluation. *Journal of Periodontology*. 1975;**46**(3):139-143
- [33] Robertsson S, Mohlin B. The congenitally missing upper lateral incisor. A retrospective study of orthodontic space closure versus restorative treatment. *European Journal of Orthodontics*. 2000;**22**(6):697-710
- [34] Bernard JP et al. Long-term vertical changes of the anterior maxillary teeth adjacent to single implants in young and mature adults. A retrospective study. *Journal of Clinical Periodontology*. 2004;**31**(11):1024-1028
- [35] Kuijpers MA, de Lange J, van Gool AV. Maxillofacial growth and dental implants in the maxillary anterior region. *Nederlands Tijdschrift Voor Tandheelkunde*. 2006;**113**(4):130-133

- [36] Jemt T et al. Changes of anterior clinical crown height in patients provided with single-implant restorations after more than 15 years of follow-up. *International Journal of Prosthodontics*. 2006;**19**(5):455-461
- [37] Spear FM, Mathews DM, Kokich VG. Interdisciplinary management of single-tooth implants. *Seminars in Orthodontics*. 1997;**3**(1):45-72
- [38] Oesterle LJ, Cronin RJ Jr. Adult growth, aging, and the single-tooth implant. *International Journal of Oral & Maxillofacial Implants*. 2000;**15**(2):252-260
- [39] Thilander B, Odman J, Lekholm U, Orthodontic aspects of the use of oral implants in adolescents: A 10-year follow-up study. *European Journal of Orthodontics*. 2001;**23**(6):715-731
- [40] Chang M et al. Implant supported single-tooth replacements compared to contralateral natural teeth. Crown and soft tissue dimensions. *Clinical Oral Implants Research*. 1999;**10**(3):185-194
- [41] Dueled E et al. Professional and patient-based evaluation of oral rehabilitation in patients with tooth agenesis. *Clinical Oral Implants Research*. 2009;**20**(7):729-736
- [42] Fransson C et al. Extent of peri-implantitis-associated bone loss. *Journal of Periodontology*. 2009;**36**(4):357-363
- [43] Paolantonio M et al Clinical, microbiologic, and biochemical effects of subgingival administration of a Xanthan-based chlorhexidine gel in the treatment of periodontitis: A randomized multicenter trial. *Journal of Periodontology*. 2009;**80**(9):1479-1492
- [44] Rosa M, Zachrisson BU. Integrating space closure and esthetic dentistry in patients with missing maxillary lateral incisors. *Journal of clinical orthodontics*. 2007;**41**(9):563-73; quiz 424
- [45] Thordarson A, Zachrisson BU, Mjor IA. Remodeling of canines to the shape of lateral incisors by grinding: A long-term clinical and radiographic evaluation. *American Journal of Orthodontics and Dentofacial Orthopedics*. 1991;**100**(2):123-132
- [46] Czochrowska EM et al. Outcome of orthodontic space closure with a missing maxillary central incisor. *American Journal of Orthodontics and Dentofacial Orthopedics*. 2003;**123**(6):597-603

---

# **Anatomical and Functional Restoration of the Compromised Occlusion: From Theory to Materials**

---

Nicola Mobilio and Santo Catapano

Additional information is available at the end of the chapter

<http://dx.doi.org/10.5772/intechopen.69544>

---

## **Abstract**

Many conditions can alter the occlusal interface, from tooth wear to tooth loss. The masticatory system is constituted by many components that can influence each other like muscles, joints, teeth and nervous system. This implies that (a) every change at occlusal level makes the other components to adapt and (b) an occlusal alteration may be the effect of an alteration occurred on muscles or joints. Keeping this in mind, traditional principles of occlusal rehabilitation are analysed, and the choice of the restorative materials is discussed.

**Keywords:** dental ceramics, freedom in centric, lithium disilicate, masticatory system, occlusal morphology, occlusion

---

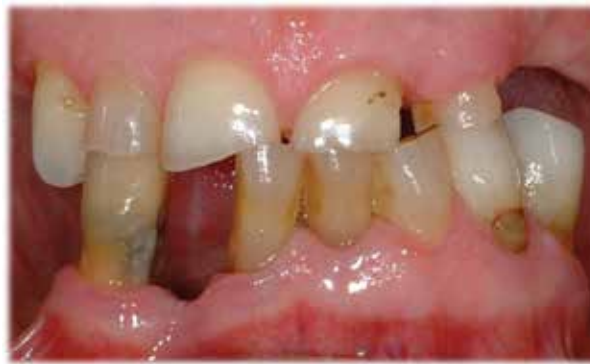## **1. Introduction: Occlusal disorders**

Many conditions or pathologies can affect dental tissues and therefore alter the occlusal interface, like dental caries, trauma and tooth wear. The latter one indicates the surface loss of dental hard tissue from causes other than developmental ones, dental caries and trauma [1]. It is a very complex phenomenon, including processes of different origin such as erosion, attrition and abrasion [1, 2]. Wear is a normal physiologic process and occurs throughout life, being part of the aging process [2]. A degree of tooth wear is considered unavoidable [3]. Problems arise if the rate of loss or the degree of destruction becomes excessive, exceeding the physiological mechanisms designed to compensate for it (e.g. formation of secondary dentin and eruption process [4]). In this manner, it may cause functional or aesthetic problems or sensitivity for the patient [5], or it is likely to prejudice the survival of the teeth [6] or it reaches a level at which restorations are indicated [2]. Furthermore, wear could lead

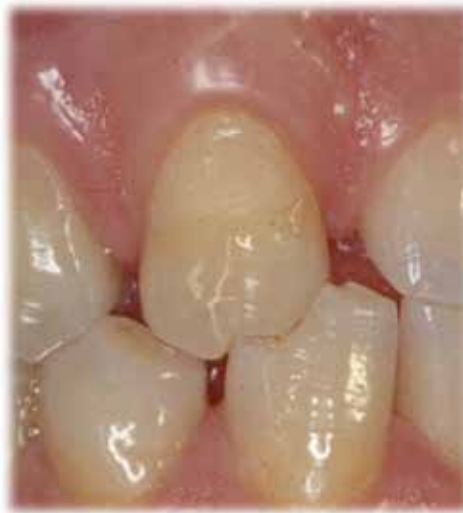to poor masticatory function with a concomitant reduction in quality of life and possible deterioration of systemic health [7]. Such a wear is called *pathological* (**Figure 1**) [8]. With increasing life expectancy and more people keeping their natural dentition into old age, the problems associated with tooth wear are likely to place greater demands upon dental professionals [1].

### 1.1. Attrition

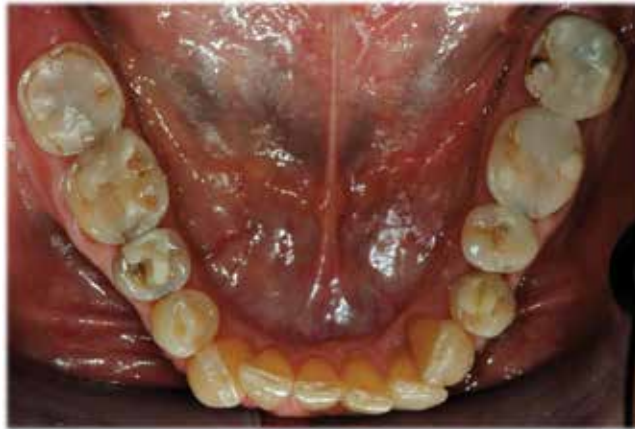Attrition is the physical wear of tooth against tooth, which means that (a) it is strictly related to occlusal relationship and (b) only tooth surfaces that make contact with each other can be described as having attrition (**Figure 2**) [9]. Regarding the mechanism of action, attrition is



**Figure 1.** Extensive, pathological tooth wear due to attrition.



**Figure 2.** Dental attrition is strictly limited to occlusal/incisal surfaces.

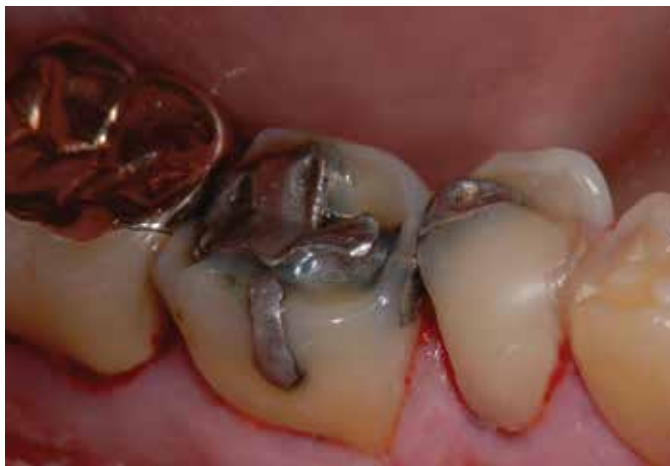

**Figure 3.** Dental abrasion may involve the entire dental surface.

a two-body wear process. The exact prevalence of attrition is unclear primarily because of differing assessment criteria [5, 6]. Data from literature vary greatly [9]. However, we certainly know that some para-functional activities can contribute greatly towards attrition [10]. Among these, grinding teeth during sleep or awake can dramatically accelerate tooth attrition. Also, the presence of restoring material harder than dental tissues may intensify the rate of attrition.

## 1.2. Abrasion

Abrasion is the physical wear of the tooth surface by something other than another tooth, like foods and toothbrush. It affects the entire tooth surface rather than just the occlusal contact area (Figure 3).



**Figure 4.** Dental erosion typically does not involve restorations.

### 1.3. Erosion

Erosion is the result of chemical dissolution by acids, excluding chemicals produced by bacteria. Acids may be exogenous (acid foods and beverage- lemon, cola, etc.) or endogenous (gastric reflux or vomit). Typically, restorations are not affected (**Figure 4**).

## 2. Restoring the occlusion: not just teeth

In restoring the occlusion, it is fundamental to keep in mind that the masticatory system is constituted by different components such as occlusal interface, masticatory muscles, temporomandibular joints (TMJs) and nervous system (central and peripheral, motor and sensory). All the components can influence each other. This statement has two implications. First of all, a change in occlusion will have consequences on the rest of masticatory system that needs to be adapted. In physiological condition, the system has the ability to adapt to changes, like any other biological systems [11]. As dentists, we act on occlusion, but de facto, we act on the entire masticatory system. On the other hand, that means that alterations in one of the other components of the system may be pointed out as occlusal alteration. For example, in the case of muscle pain, it was shown that the distribution of occlusal contacts changes [12]. In that study, an experimental muscle pain was induced in masseter in healthy subjects. Even if the number of occlusal contacts did not change, the distribution did. After the pain resolution, the distribution of contacts returned to baseline. In other words, muscle pain (and, more generally, facial pain) influences muscle activity in a specific way, altering the position of the mandible and, as a consequence, the occlusion. This is consistent with the so-called 'pain-adaptation model' [13]. Accepting this model has important practical consequences, first of all, the end of 'occlusal adjustment' as therapy for muscle pain. For decades, in fact, it was assumed that the so-called occlusal interferences were the most frequent cause of masticatory muscle pain: the masticatory muscles would be enrolled to eliminate the occlusal disturbances and this 'hyperactivity' would cause muscle pain. Of course, eliminating the occlusal interferences would stop the muscle activity and, so, the pain. On the contrary, as demonstrated, the 'occlusal alterations' can be the effect rather than the cause of muscle pain; touching the occlusion of a suffering patient may result in an irreversible and a useless damage. This aspect is confirmed also in treating patients with muscle pain; they often complain that their teeth 'no longer fit together properly' [14].

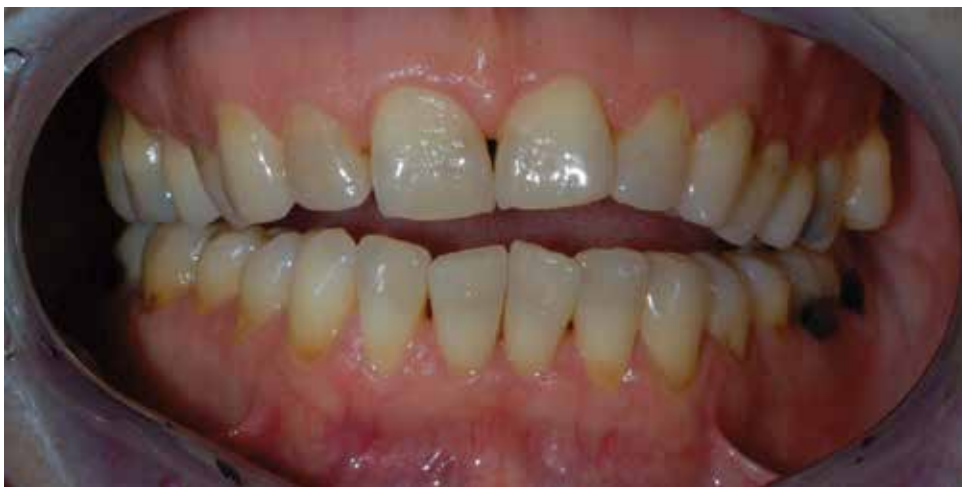The second clinical implication regards the establishing of intermaxillary relationship; to correctly establish the position during rehabilitation, the masticatory system is needed not to be in pain. Otherwise, the pain would alter the muscle activity and, consequently, the jaw position, leading to an error in the choice of horizontal relationship (see below). This may happen regardless of the technique used to achieve the centric position. Obrez and Stohler [15] found a difference in the position of the apex of the Gothic arch (i.e. the centric position) before and after a muscle pain was experimental induced in the masseter. The difference disappeared after the pain resolution. So, any registration of maxillomandibular relationship, and thus any occlusal rehabilitation, cannot be achieved until the pain condition has been resolved.



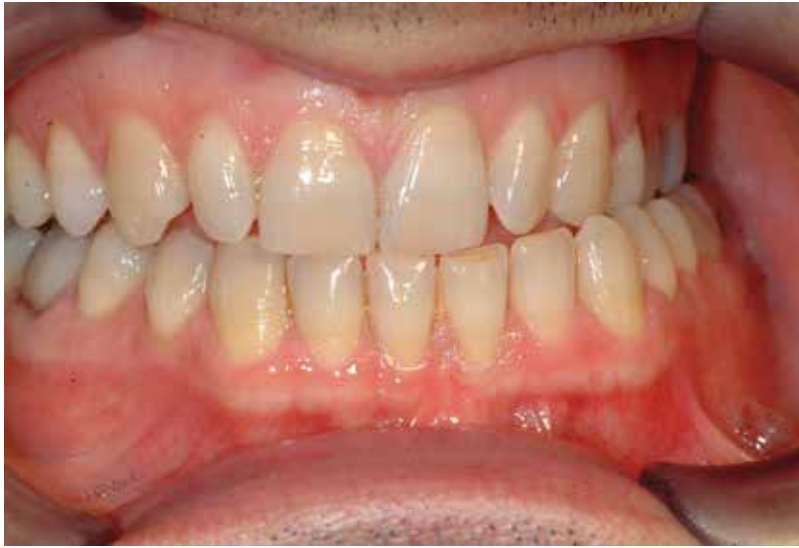Also, an alteration at TMJ level may be firstly seen at occlusal level. In the case of TMJ inflammation, a swelling of synovial space may occur, resulting in the excessive intracapsular fluid. This phenomenon may cause a so-called acute malocclusion, which is a premature contact of anterior teeth with disclusion of the posterior teeth [16]. The malocclusion disappears after resolution of TMJ inflammation. Also, chronic pathologies affecting TMJ may lead to secondary malocclusion, though it develops slowly and can be easily underestimated. Such a scenario happened in a patient suffering of systemic rheumatoid arthritis with a bilateral TMJ involvement. The massive erosion of both mandibular condyles leads to a secondary, progressive anterior open bite (**Figure 5**).

The following case represents the best example of the diagnostic error that may result from looking just at the occlusion, forgetting the other components of the masticatory system. The patient showed a facial asymmetry with a left cross-bite (**Figure 6**). Many clinicians proposed to him to orthodontically and/or orthodontically correct the cross-bite. The clinical examination showed left buccal wear facets that were incompatible with the cross-bite. Dental casts were able to get the maximum intercuspation, so an obstacle in the contralateral TMJ was hypothesized. Indeed CT exam showed a mass in the right TMJ (**Figure 7**). The histological examination resulted in osteoma of the glenoid fossa that was surgically removed restoring the occlusion without any other occlusal therapy (**Figure 8**) [17]. The former was certainly an extreme case, but it suggests that a joint problem may cause an altered centric. So it is always necessary to evaluate not only masticatory muscles but also TMJs. More extensively, whenever you need to completely rehabilitate the occlusion, it is an essential overall assessment of the masticatory system and not only of the dental condition.

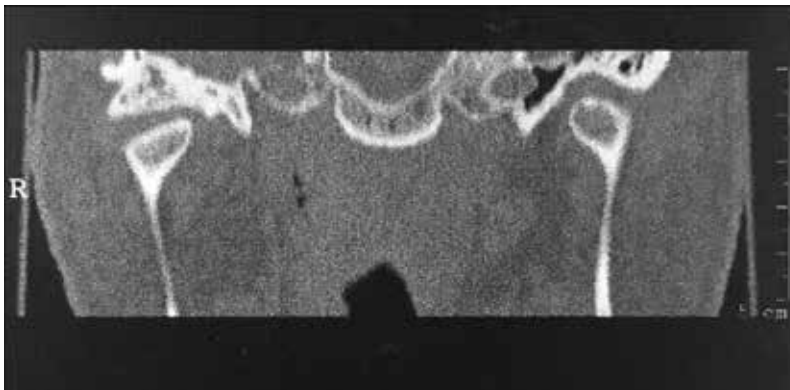
The term ‘neuroplasticity’ refers to the adaptive ability of the brain to undergo structural and functional changes throughout the life. These changes are fundamental for the acquisition of



**Figure 5.** Anterior open bite due to degenerative arthritis of mandibular condyles.

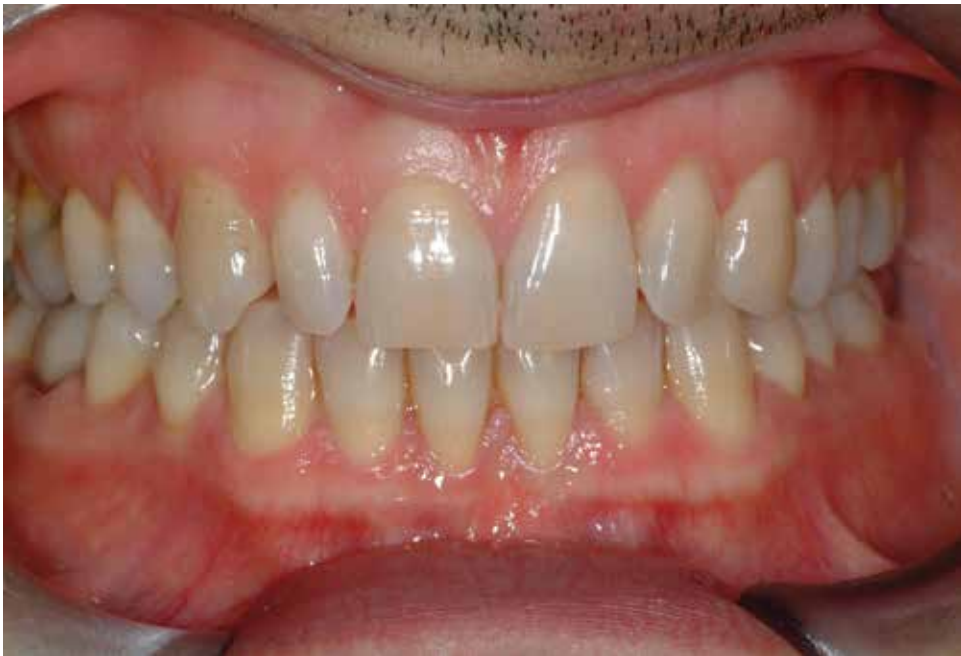

**Figure 6.** Left cross bite.



**Figure 7.** CT scan showing a mass in the right glenoid fossa dislocating the mandibular condyle.

motor skills, memory, development of the central nervous system (CNS), learning and adaptation resulting from nerve trauma or other sensory changes. The CNS is a plastic system: neuroplasticity allows us to survive to environmental challenges. Luraschi et al. [18] found that, after the insertion of a new complete denture, the CNS responded with the activation of cerebral cortical areas that were previously silent (showed with functional magnetic resonance imaging); after a period of 3 months they returned to baseline. In other words, cortical neuroplastic changes occur in association with adaptation to changes at occlusal level. These findings lead to a fascinating perspective on explaining why some subjects easily adapt to changes while others failed [19].



**Figure 8.** Resolution of left cross bite after surgical removal of the osteoma in the right TMJ.

### **2.1. The principles of restoring the occlusion**

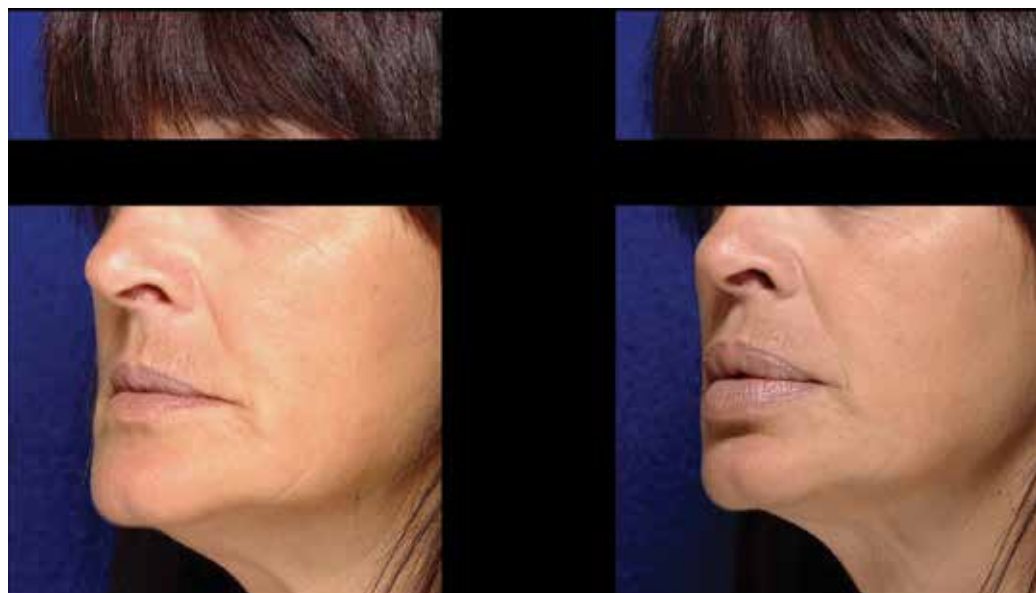Many years passed since Beyron enunciated his principles to achieve what he poetically called 'occlusal harmony' [20, 21]. These principles included:

- acceptable vertical dimension of occlusion (VDO) with acceptable interocclusal distance
- stable jaw relationship with bilateral contact in retrusive closure
- freedom in the retrusive range with maximum intercuspation slightly and straight in front of the retruded contact position
- axial occlusal contacts on the posterior teeth
- no interference in eccentrics movements

Even if little or no evidence was provided over the years for supporting those principles, they are inspired, now as then, by common sense, appearing wise and cautious, and, in the authors' opinion, they are still valid.

### **2.2. Establishing the vertical dimension**

Restoring the occlusion very often means restoring the vertical dimension. The vertical dimension of occlusion (VDO) is defined as the distance measured between two points when the



**Figure 9.** The same patient before (on the left) and after restoring the correct vertical dimension.

occluding members are in contact with each other [22]. Many methods have been described to establish the correct VDO. These methods are often combined to achieve the best result. However, even if some methods pretend to be more 'scientific' or 'validated' than others, establishing the VDO remains a clinical manoeuvre, in which the clinician's personal talent and experience play a crucial role.

For establishing the correct VDO, we employ three consecutive methods such as rest position, phonetics and aesthetics. We usually start from the physiological rest position of the jaw [22], when the head is in an upright position, there is no dental contact, antagonist muscles (jaw elevators and depressors) are balanced and the mandibular condyles are in a non-forced position in the glenoid fossa. In this position, an 'interocclusal distance' of few millimetres is present, i.e. antagonist teeth are not occluding. If during rest position, antagonist teeth are in contact, the VDO may be too high and it needs to be reduced.

The rest position is the starting point to determine the new VDO, but it must be combined with other functional aspects, first of all with phonetics. If the VDO is incorrect, phonetics may be negatively affected. Pound established that the key to the ideal relationship between antagonist anterior teeth for achieving clarity of speech was the 'S position'. The 'S position' is defined as the most forward position the mandible ever assumes during speech and it is the closest to contact of any teeth during a speech [23]. The 'S position' limits the possibility of increasing VDO, as an excessive VDO will cause antagonist teeth contact during 'S' sounds.

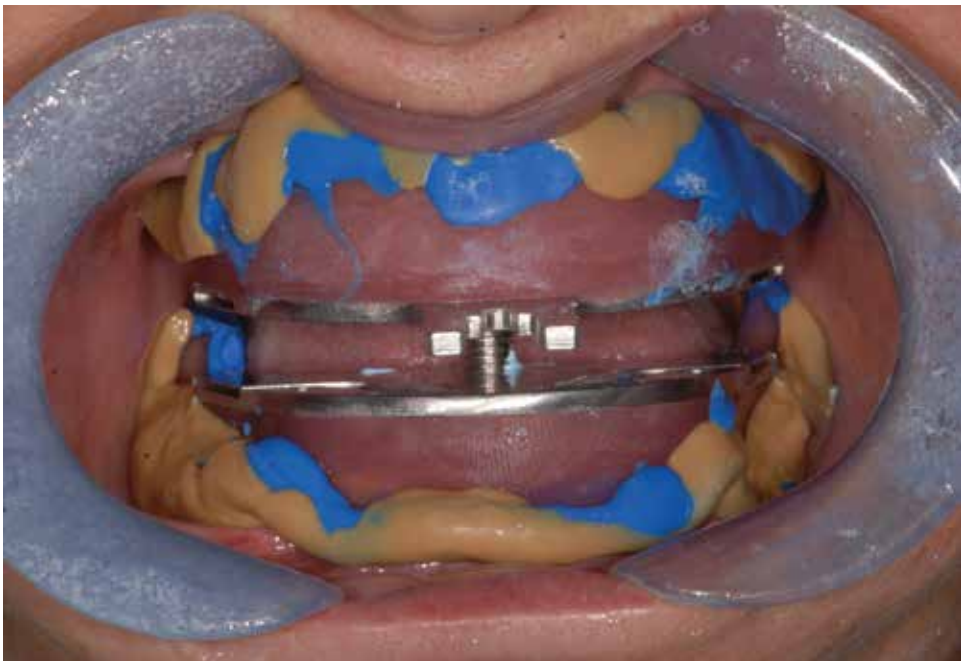
The final aspect to consider is aesthetics. The dimension of the lower third influences the overall appearance of the patients' face, so aesthetic considerations have a key role in defining VDO. Restoring the lost VDO may give several years back to the patient, removing the old appearance that the lost teeth and the lost dimension usually cause (**Figure 9**).

### 2.3. Choosing the 'therapeutic position'

In case of gross occlusal alteration, it is necessary to choose a therapeutic position of the mandible in which the new 'centric occlusion' is created. Few arguments have been debated in the past and present of dentistry, like the choice of therapeutic position. Independently from the 'philosophy' that guides you, the definitions of centric and the method to assess it are closely related, and so the consequent occlusal morphology. Some authors prefer to actively guide the jaw in the centric relation, and various manoeuvres have been described [24]. Other authors prefer not to 'force' the jaw in a specific position. One 'not guided' method consists in choosing a retruded functional position as shown by tracing the border mandibular movement on the horizontal plane. This method, called 'central bearing point', was initially created for complete denture rehabilitation, but it may be adapted to every clinical situation. A pivot traces jaw movements on a plate, designing the so-called 'Gothic arch' (**Figure 10**). The apex of the Gothic arch represents, in this approach, the centric relation (**Figure 11**). This centric relation may be chosen as reference position in creating the new centric occlusion, ensuring a 'freedom in centric' as explained below.

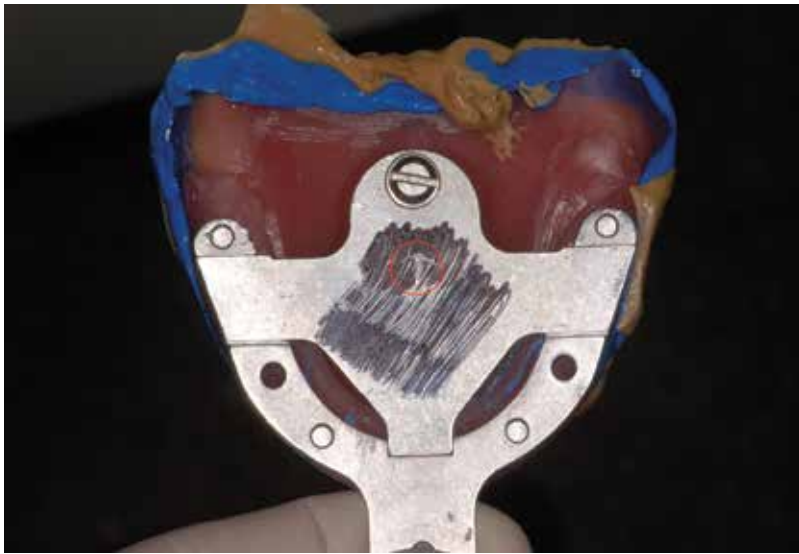### 2.4. Designing the occlusal anatomy

Old studies showed that functional movements do not occur in a single position, but in an 'area' around the centric occlusion [25]. This is the biological premise for the so-called '*freedom in centric*' in which there is a degree of freedom in centric movements starting from the central fossa of the occlusal surface [26]. This concept avoids interference on posterior teeth during functional movements, that is, one of Beyron's principles.



**Figure 10.** Central bearing point technique applied on edentulous patient.





**Figure 11.** Gothic arch tracing.

In restoring a single tooth or few teeth, the rest of occlusion is the best guide to design the occlusal anatomy and the restored tooth needs to be integrated in the existing occlusion, without introducing interferences in centric occlusion or eccentric movements. On the contrary, when extensive occlusal reconstructions are needed, reference points need to be derived from the structure other than residual occlusion. These reference points are the other component of the masticatory system that limits functional movements. In particular, the TMJ anatomy influences mandibular dynamics. Changes in occlusion made regardless of TMJ anatomy may introduce occlusal interferences during movements. For these reasons, it is fundamental to record some particular parameters to which the occlusion morphology is conformed. The most important (and the most used) parameters are as follows (a) the protrusive condyle path and (b) the immediate mandibular lateral translation (also known as immediate side shift), which influence both anterior guidance and dimension of the posterior cusps in the protrusive and lateral movements, respectively.

## 2.5. Which instruments are needed?

In an extensive occlusal restoration, it is necessary to work on patient's master casts that are mounted on an **articulator** that best reproduces hinge axis. In such a way, we can be reasonably sure that each occlusal change made on articulator will result in the same occlusal change on the patient's mouth. In order to do that, it is necessary to use a **face bow**, a calliper-like instrument that records the spatial relationship of the maxillary (or mandibular) arch to some anatomic reference point or points and then transfer this relationship to the articulator [22].

There are different types of articulator; the most frequently used are the **semi-adjustable** ones that represent an optimal compromise between the non-adjustable articulators, inevitably

inaccurate because they cannot be combined to a face bow, and fully adjustable articulators, more precise but also more complex to use. If you are well aware of those that are the principles that must be applied, you can equally get a good result even using a less complex and precise tool.

After recording the hinge axis, the two parameters that are usually recorded are as follows:

- a. The protrusive condylar path. The functional part is represented by the intermediate segment, used to calculate the angle to be set in the articulator,
- b. The immediate side shift on the horizontal plane that is the movement of the not working condyle that guides the lateral movement.


These two parameters are dependent on the anatomy of the glenoid fossa and influence the anterior guidance and the occlusal morphology of the cusps of the posterior teeth during eccentric movements.

## 2.6. Which restorative materials are used?

The ability of some dental materials to adhere to dental tissues has dramatically changed the modern dentistry, modifying operative protocols, techniques and even treatment plans. 'New' glass-ceramics like lithium disilicate combine good mechanical properties with excellent aesthetic results. The strong point of this ceramics is adhesive cementation on the tooth, a property that stronger polycrystalline ceramics like zirconia are lacking of. Indeed, the surface of lithium disilicate may be etched by hydrofluoric acid that dissolves the glass matrix to increase surface energy and, consequently, bond strength to dental tissues. Such a surface treatment is impossible on zirconia because no glass matrix is present. The clinical consequence is the use of lithium disilicate for producing indirect restorations with no mechanical retention and resistance form. An *in vitro* study [27] was conducted to compare the retention of lithium disilicate crowns cemented using two different cementation systems: (a) a glass-ionomer cement (GIC) and (b) a self-curing luting composite resin. Adhesive cementation with luting composite showed failure load three times higher than conventional cementation with GIC. Furthermore, crowns cemented with luting composite most often failed by fracture; otherwise, crowns cemented with glass-ionomer cement most often failed by decementation. These results suggest a completely different biomechanical behaviour between the two luting procedures; the ceramic crown is etched and cemented by a luting composite resin cement become part of the tooth. The new system crown-cement-tooth has a resistance equal to the inner tensile strength of an intact tooth.

The interface between tooth, luting composite and lithium disilicate surface was qualitatively evaluated using a scanning electron microscope (SEM). SEM analysis showed the three layers with no interruptions (**Figure 12**); by increasing the enlargement the interface did not change [28].

An *in vitro* study was conducted to compare the fracture resistance of human teeth restored with lithium disilicate only restorations, with and without a retention and resistance form.



**Figure 12.** SEM evaluation (800×) of the (from left to right) tooth-luting composite-ceramic interface.

The fracture test (**Figure 13**) showed no difference between the groups, revealing that if adequate adhesive procedures (using etching ceramic like lithium disilicate) are applied, traditional concepts of tooth preparation (retention form, resistance form, ferrule effect) are no longer required for the mechanical resistance of restored teeth.

Because of its capacity to adhere to dental tissues, lithium disilicate may be used to restore the lost anatomical and functional form of the teeth. This property is combined with excellent optical properties and very good mechanical properties that make this material the first choice to restore single anterior and posterior teeth, with total or partial restorations. It may also be used for realizing anterior 3-unit bridges. Even if its use for implant prosthesis is not generally recommended, a screw-retained implant crown realized by lithium disilicate has recently been described [29]. For higher load-bearing situation, like long-span bridges or complete arch rehabilitation, other materials, like polycrystalline ceramics or traditional porcelain-fused-on-metals (PFM) are suggested. However, no real adhesion to dental tissues can be achieved with these materials.

Some concerns in using ceramics for restoring teeth regard its impact on tooth wear. In fact, dental materials may be worn by enamel or they may cause aggressive wear of enamel [7]. Holding the other factors constant, variation in enamel wear rate is related to the coefficient of friction (which is a function of the material) and type of wear mechanism [7]. Ideally, a restoration should have wear resistance similar to that of enamel [30]. The average wear rate on occlusal contact areas is about  $29 \mu\text{m}/\text{year}$  for molars and about  $15 \mu\text{m}/\text{year}$  for premolars [30]. The attrition of restoration is of clinical importance only if it deviates from the physiological attrition of enamel [31]. Too hard materials dramatically accelerate wear of antagonist enamel



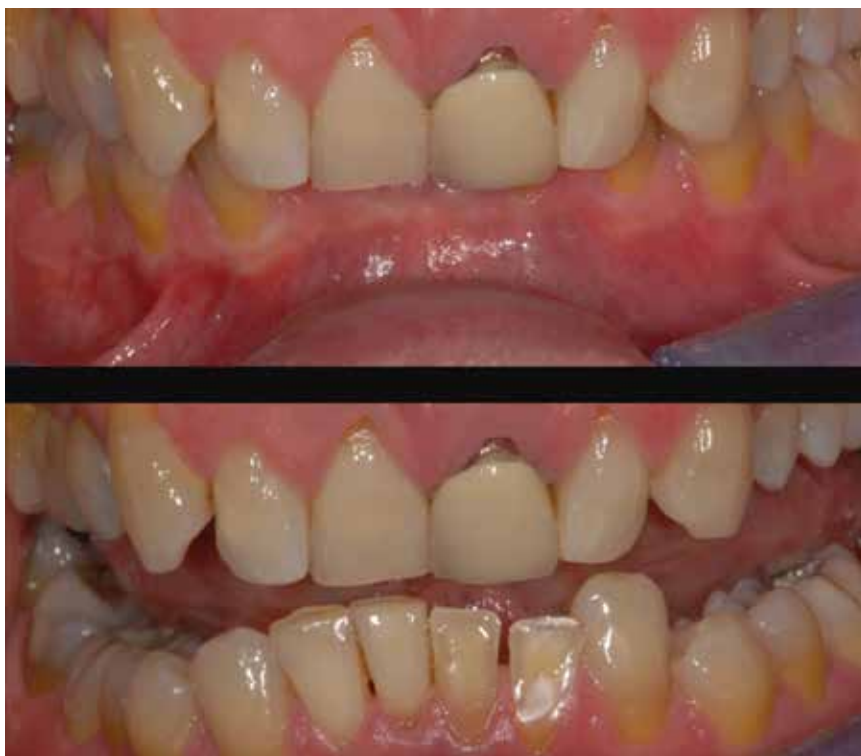

**Figure 13.** Fracture test of natural tooth restored with lithium disilicate restoration.

(**Figure 14**). For example, the enamel-ceramic combination wears more than the enamel-enamel combination and both wear more than enamel-amalgam combination [7].

Among the various dental materials, composite resins have a particular behaviour as many variables that derive from their composition directly influence their wear resistance. Composites consist of filler particles dispersed in a brittle polymer. The size, shape and hardness of the fillers, the quality of the bonding between the fillers and the polymer matrix and the extent of polymerization of the polymer matrix influence the wear characteristics of the composite. Furthermore, the composition of the material influences physical parameters such as flexural strength, fracture toughness, hardness, modulus of elasticity and curing depth, all of which may influence the wear [32].

In general, composite resins are susceptible to abrasive and fatigue wear [33]. The mean occlusal contact wear of composite materials ranges from 60 to 200  $\mu\text{m}$ , depending on the material, attributing lower wear rates for composite resin launched in the mid-1990s compared



**Figure 14.** A ceramic crown on left upper central incisor, associated to deep bite, caused an augmented wear due to attrition of antagonist teeth.

to those that were launched at the end of the 1980s or beginning of the 1990s. However, the range of wear may vary considerably within the same material [34]. The latest composite resins, with smaller fillers, do not show excessive wear. Many variables related to the composition of composite resins influence wear resistance. Composite resins with small particles are more wear resistant than those with large particles [35, 36]; composites with more than 48% volume of fillers have a higher wear resistance [37] the filler inter-particle spacing of less than 0.10–0.43  $\mu\text{m}$  is needed to protect the resin matrix from wear [37]. Experimental non-aged composites show similar wear regardless of the degree of conversion (DC) [37], and some commercial 7-days-aged composite resins with high DC show less wear than composites with lower DC [38]. There is some correlation between DC and hardness, but composite resins with high values for hardness do not necessarily have a high resistance to abrasive wear [39].

### 3. Conclusion

As dental clinician, we act every day on the occlusal interface. Being the masticatory system constituted by different components that influence each other, we must keep in mind that

every change at one level will have consequences on the others. For this reason, altering or restoring the occlusion must consider the anatomical limits of muscles and joints, and the adaptive capacity of the nervous system. There are few basic principles that need to be fulfilled in occlusal rehabilitation, and an anatomical face bow and a semi-adjustable articulator represent useful tools to achieve the treatment goals.

The use of materials that can be adhesively fixed to dental tissues should be preferred. These include both glass-ceramics and composite resins. Ceramics present better mechanical and optical properties, but their high hardness may increase tooth wear due to attrition, especially when grinding habits are present. In these cases, the use of composite resin may be preferred.

## Author details

Nicola Mobilio\* and Santo Catapano

\*Address all correspondence to: [nicola.mobilio@unife.it](mailto:nicola.mobilio@unife.it)

Dental School, Dental Clinic, University of Ferrara, Ferrara, Italy

## References

- [1] Hattab FN, Yassin OM. Etiology and diagnosis of tooth wear: A literature review and presentation of selected cases. *International Journal of Prosthodontics*. 2000;**13**:101-107
- [2] Bartlett D, Phillips K, Smith B. A difference in perspective-the North American and European interpretations of tooth wear. *International Journal of Prosthodontics*. 1999;**12**:401-408
- [3] Barbour ME, Rees GD. The role of erosion, abrasion and attrition in tooth wear. *The Journal of Clinical Dentistry*. 2006;**17**:88-93
- [4] Litonjua LA, Andreana S, Bush PJ, Cohen RE. Tooth wear: Attrition, erosion, and abrasion. *Quintessence International*. 2003;**34**:435-446
- [5] Bishop K, Kelleher M, Briggs P, Joshi R. Wear now? An update on the ethology of tooth wear. *Quintessence International*. 1997;**28**:305-313
- [6] Kelleher M, Bishop K. Tooth surface loss: An overview. *British Dental Journal*. 1999;**186**:61-66
- [7] DeLong R. Intra-oral restorative materials wear: Rethinking the current approaches: How to measure wear. *Dental Materials*. 2006;**22**:702-711
- [8] Russell MD. The distinction between physiological and pathological attrition: A review. *Journal of the Irish Dental Association*. 1987;**33**:23-31
- [9] Smith BG, Bartlett DW, Robb ND. The prevalence, etiology and management of tooth wear in the United Kingdom. *Journal of Prosthetic Dentistry*. 1997;**78**:367-372

- [10] Seligman DA, Pullinger AG, Solberg WK. The prevalence of dental attrition and its association with factors of age, gender, occlusion, and TMJ symptomatology. *Journal of Dental Research*. 1988;**67**:1323-1333
- [11] Sessle BJ. Biological adaptation and normative values. *International Journal of Prosthodontics*. 2003;**16**(Suppl):72-73; discussion 89-90
- [12] Mobilio N, Catapano S. Effect of experimental jaw muscle pain on occlusal contacts. *Journal of Oral Rehabilitation*. 2011;**38**:404-409
- [13] Lund JP, Donga R, Widmer CG, Stohler CS. The pain-adaptation model: A discussion of the relationship between chronic musculoskeletal pain and motor activity. *Canadian Journal of Physiology and Pharmacology*. 1991;**69**:683-6894
- [14] Obrez A, Türp JC. The effect of musculoskeletal facial pain on registration of maxillo-mandibular relationships and treatment planning: A synthesis of the literature. *Journal of Prosthetic Dentistry*. 1998;**79**:439-445
- [15] Obrez A, Stohler CS. Jaw muscle pain and its effect on gothic arch tracings. *Journal of Prosthetic Dentistry*. 1996;**75**:393-398
- [16] Okeson JP. *Bell's Orofacial Pains: The Clinical Management of Orofacial Pain*. 6th ed. Chicago, IL: Quintessence; 2005. p. 592
- [17] Mobilio N, Zanetti U, Catapano S. Glenoid fossa osteoma resulting in a progressive mal-occlusion: A case report. *Journal of Orofacial Pain*. 2010;**24**:313-318
- [18] Luraschi J, Korgaonkar MS, Whittle T, Schimmel M, Müller F, Klineberg I. Neuroplasticity in the adaptation to prosthodontic treatment. *Journal of Orofacial Pain*. 2013;**27**:206-216
- [19] Avivi-Arber L, Lee JC, Sessle BJ. Dental occlusal changes induce motor cortex neuroplasticity. *Journal of Dental Research*. 2015;**94**:1757-1764
- [20] Beyron H. Optimal occlusion. *Dental Clinics of North America*. 1969;**13**:537-554
- [21] Beyron H. Occlusion: Point of significance in planning restorative procedures. *Journal of Prosthetic Dentistry*. 1973;**30**:641-652
- [22] The glossary of prosthodontic terms. *Journal of Prosthetic Dentistry*. 2005;**94**:10-92
- [23] Pound E. Let/S/be your guide. *Journal of Prosthetic Dentistry*. 1977;**38**:482-489
- [24] Dawson PE. *Evaluation, Diagnosis and Treatment of Occlusal Problems*. St Louis, MO: Mosby; 1989
- [25] Pameijer JH, Glickman I, Roeber FW. Intraoral occlusal telemetry. 3. Tooth contacts in chewing, swallowing and bruxism. *Journal of Periodontology*. 1969;**40**:253-258
- [26] Schuyler CH. Freedom in centric. *Dental Clinics of North America*. 1969;**13**:681-686
- [27] Mobilio N, Fasiol A, Mollica F, Catapano S. Effect of different luting agents on the retention of lithium disilicate ceramic crowns. *Materials*. 2015;**8**:1604-1611

- [28] Mobilio N, Fasiol A, Catapano S. Qualitative evaluation of the adhesive interface between lithium disilicate, luting composite and natural tooth. *Annali Di Stomatologia*. 2016;**7**:1-3
- [29] Mobilio N, Catapano S. The use of monolithic lithium disilicate for posterior screw-retained implant crowns. *Journal of Prosthetic Dentistry*. 2017;903-906
- [30] Lambrechts P, Braem M, Vuylsteke-Wauters M, Vanherle G. Quantitative in vivo wear of human enamel. *Journal of Dental Research*. 1989;**68**:1752-1754
- [31] Lambrechts P, Braem M, Vanherle G. Buonocore memorial lecture. Evaluation of clinical performance for posterior composite resins and dentin adhesives. *Operative Dentistry*. 1987;**12**:53-78
- [32] Heintze SD, Zappini G, Rousson V. Wear of ten dental restorative materials in five wear simulators – results of a round robin test. *Dental Materials*. 2005;**21**:304-317
- [33] Powers JM, Sakaguchi RL. *Craig's Restorative Dental Materials*. 13th ed. India: Elsevier; 2006
- [34] Heintze SD. How to qualify and validate wear simulation devices and methods. *Dental Materials*. 2006;**22**:712-734
- [35] Zantner C, Kielbassa AM, Martus P, Kunzelmann KH. Sliding wear of 19 commercially available composites and compomers. *Dent Mater*. 2004;**20**:277-285
- [36] Turssi CP, Ferracane JL, Vogel K. Filler features and their effects on wear and degree of conversion of particulate dental resin composites. *Biomaterials*. 2005;**26**:4932-37
- [37] Condon JR, Ferracane JL. In vitro wear of composite with varied cure, filler level, and filler treatment. *J Dent Res*. 1997;**76**:1405-1411
- [38] Knobloch LA, Kerby RE, Seghi R, van Putten M. Two-body wear resistance and degree of conversion of laboratory-processed composite materials. *Int J Prosthodont*. 1999;**12**:432-438
- [39] Turssi CP, De Moraes Purquerio B, Serra MC. Wear of dental resin composites: Insights into underlying processes and assessment methods—a review. *J Biomed Mater Res B Appl Biomater*. 2003;**65**:280-285



---

## Studies About Dental Anatomy

---





---

# Evaluation of the Anatomy of the Lower First Premolar

---

Ticiana Sidorenko de Oliveira Capote,  
Suellen Tayenne Pedroso Pinto,  
Marcelo Brito Conte,  
Juliana Álvares Duarte Bonini Campos and  
Marcela de Almeida Gonçalves

Additional information is available at the end of the chapter

<http://dx.doi.org/10.5772/intechopen.71038>

---

## Abstract

This chapter provides information about the lower first premolars. This tooth is considered to be one of the most complex teeth and the dentistry graduation students usually have difficulties in identifying it. The aim of this chapter is to present a detailed morphological study of extracted lower first premolars. One hundred lower first premolars, belonging to the collection of the Laboratory of Anatomy of the Department of Morphology of the São Paulo State University (UNESP), School of Dentistry, Araraquara, SP, Brazil, were evaluated. Nine measurements were performed through direct observation without any instruments. Other 20 measurements were made by photographs and they were analyzed by the Image Tool 3.0 program. According to the results, it was concluded that most of the teeth presented the following features such as one lingual cusp; the distal occlusal pits were wider than the mesial occlusal pits; an enamel bridge linking the buccal and lingual cusps; the grooves in the lingual surface that emerged from the mesial and distal occlusal pits were absent, and where the grooves were present, they emerged from the mesial occlusal pit; one rectilinear root with no root grooves and where the root groove was present, it was observed in the mesial surface.

**Keywords:** dental anatomy, lower first premolar, morphometric, tooth morphology, teeth

---

## 1. Introduction

The lower first premolar is considered to be one of the most complex teeth. During the practical classes of Dental Anatomy, we can see some students with difficulties in the identification of the first premolars. Probably this is due to the wide anatomic variations present in those teeth.

---

There are few studies in which researchers performed standardized measures and provided more detailed information about the lower first premolars.

The lower first premolar is the smallest of all premolars. It has a very characteristic crown that differs from the other teeth, mainly due to its buccal cusp, which is disproportionately larger than the lingual cusp. The buccal surface of the crown is strongly inclined toward the lingual side and the buccal cusp is about two times larger than the lingual cusp [1].

Being smaller than the buccal cusp, the lingual cusp may be so small to become a single tubercle. Between the two cusps, buccal and lingual, there is a principal groove, whose concavity is directed toward the buccal surface [1, 2].

An enamel bridge may also be present linking the buccal and lingual cusps [3], which separates the principal groove in two pits, the mesial occlusal pit (MOP) and the distal occlusal pit (DOP) [4]. According to Madeira and Rizzolo [5], the distal occlusal pit is the largest, and between both occlusal pits (mesial and distal), the distal one is the closest to the lingual surface.

Usually, the tooth has only one root [1, 4]. The mesial and distal longitudinal grooves of the root are shallow and the root apex is rarely divided [4].

The aim of this chapter is to present a detailed morphological study of extracted lower first premolars.

## 2. Methodology

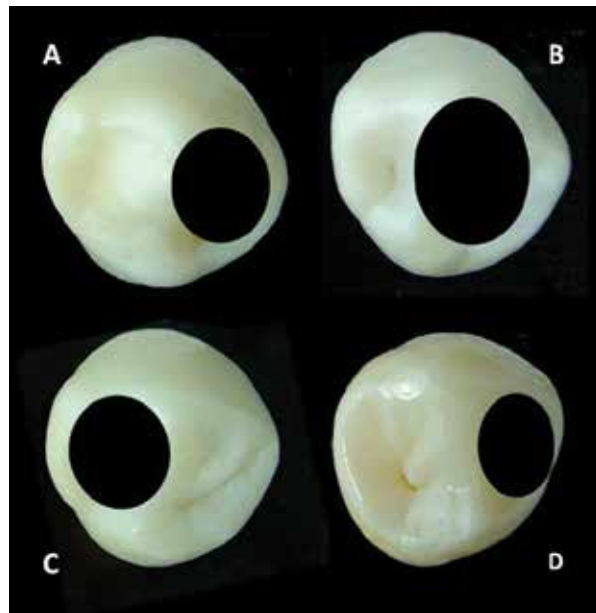
This project was approved by the Ethics Committee of the School of Dentistry of Araraquara, São Paulo State University (UNESP) (CAAE 17513313.6.0000.5416).

One hundred lower first premolars with no information about gender and age were evaluated, and they belong to the collection of the Laboratory of Anatomy of the Department of Morphology of the São Paulo State University (UNESP), School of Dentistry, Araraquara. The teeth were cleaned with dental instruments and solutions of hydrogen peroxide and ammonium hydroxide. The teeth were stored dry, without any solutions, in glass containers. Those teeth are routinely used in the dental anatomy classes.

For identifying the proximal surfaces, a previous study was done to determine the criteria of their identification.

Nine measurements were performed through direct observation without any instruments:

- Mesial occlusal pit (MOP): 1 = discreet, 2 = small, 3 = medium, 4 = large (**Figure 1**).
- Distal occlusal pit (DOP): 1 = discreet, 2 = small, 3 = medium, 4 = large (**Figure 1**).
- Presence/absence of groove in the lingual surface that emerged from the mesial occlusal pit (G-MOP).
- Presence/absence of groove in the lingual surface that emerged from the distal occlusal pit (G-DOP).



**Figure 1.** Classification of occlusal pits. (A) Discreet occlusal pit; (B) small occlusal pit; (C) medium occlusal pit and (D) large occlusal pit.

- Number of lingual cusps (LC).
- Number of dental roots (DR).
- Region of root bifurcation or trifurcation: 0 = absent, 1 = cervical third, 2 = middle third, 3 = apical third.
- Presence/absence of root grooves in the mesial surface (MG-R).
- Presence/absence of root grooves in the distal surface (DG-R).

Other measures were made by photographs and they were analyzed by the Image Tool 3.0 program, which allowed the measurements of dimension, angle and area.

Prior to the photographs, some points were registered in the teeth to facilitate some measurements through the use of the Image Tool program such as signaling of the distal surface, apex of the cusps, limits of the mesial and distal longitudinal edges of all cusps, point of largest dimension of the mesial and distal marginal ridges, contour of the mesial and distal longitudinal edge of the buccal cusp and contour of the cervical line (**Figures 3, 6 and 7**).

The teeth were photographed on the occlusal, buccal, lingual, mesial and distal surfaces. For standardization of the photographs, a digital camera (FujiFilm FinePix S7000) was positioned on a stand. In each photograph, a ruler was photographed for calibration of the images and the measurements were made using the Image Tool 3.0 program. The calibration was made in millimeters. For the occlusal photographs, the teeth were fixed in a device elaborated by

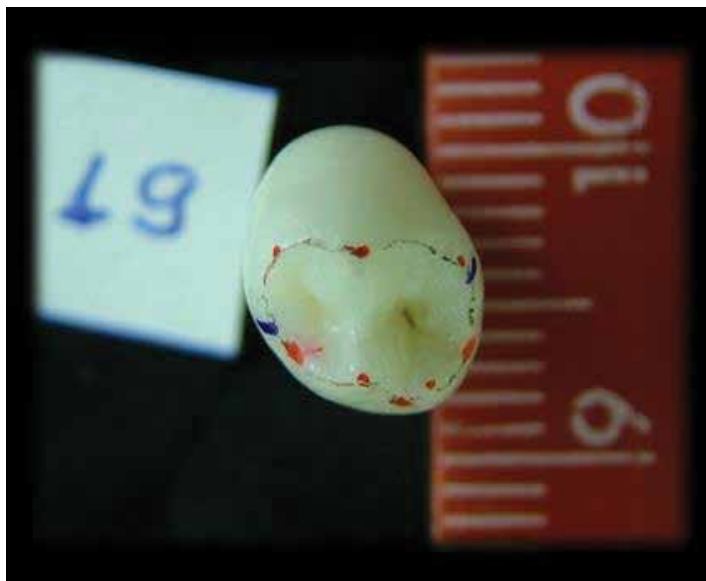
Prof. Dr. Hélio Ferraz Porciúncula, a retired adjunct professor of Anatomy of the School of Dentistry of Araraquara, São Paulo State University (UNESP) (**Figure 2**).

*Photograph of occlusal surface (Figure 3):*

- Measurement of the mesial longitudinal edge of the buccal cusp (MLE-BC).
- Measurement of the distal longitudinal edge of the buccal cusp (DLE-BC).



**Figure 2.** Metallic device where the teeth were fixed for occlusal photographs.



**Figure 3.** Occlusal surface photograph.

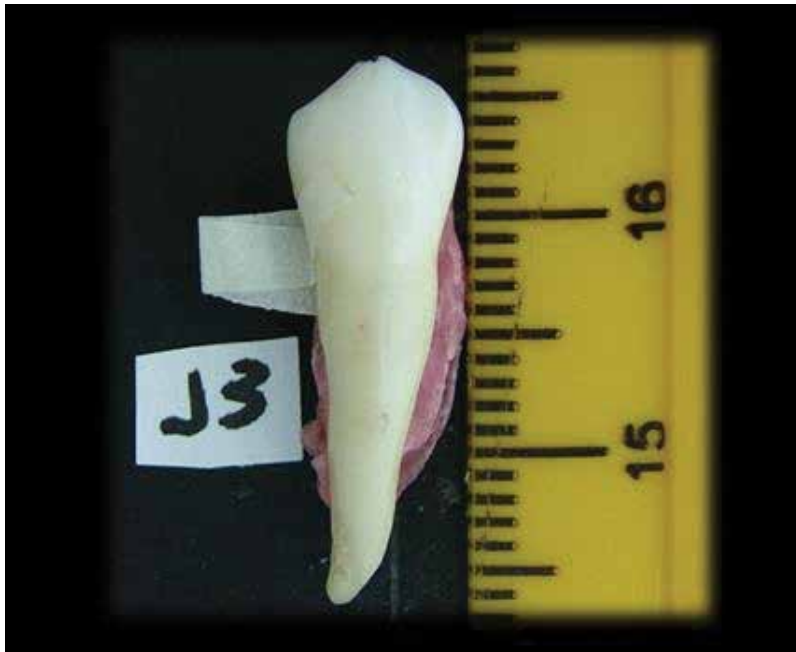- Measurement of the mesial longitudinal edge of the lingual cusp (MLE-LC): presence of only a lingual cusp located in the middle third (MLE-LC0), presence of a lingual cusp located in the mesial third (MLE-LC1) and presence of a lingual cusp located in the distal third (MLE-LC2).
- Measurement of the distal longitudinal edge of the lingual cusp (DLE-LC): presence of only a lingual cusp located in the middle third (DLE-LC0), presence of a lingual cusp located in the mesial third (DLE-LC1) and presence of a lingual cusp located in the distal third (DLE-LC2).
- Measurement of the buccolingual dimension of the occlusal surface (BL-O): measurement between the buccal and lingual surfaces made from the buccal cusp apex to the lingual cusp apex.
- Measurement of the mesiodistal dimension of the occlusal surface (MD-O): measurement between the mesial and distal marginal ridges on the occlusal surface in the region of greatest dimension.
- Measurement of the buccolingual dimension of the mesial marginal ridge (BL-MMR).
- Measurement of the buccolingual dimension of the distal marginal ridge (BL-DMR).
- Measurement of the mesiodistal dimension of the enamel bridge (M-PE): when it was present, a mesiodistal measurement was performed between the two surfaces that limit the enamel bridge and coincide with the margin of the occlusal pits.
- Position of the enamel bridge: absent, mesial, middle and distal position (P-PE).
- Presence/absence of the mesiodistal groove crossing the enamel bridge (G-PE).
- Measurement of the distance from the mesial occlusal pit to the buccal surface (MOP-MLE): a measurement made from the center of the mesial occlusal pit to the mesial longitudinal edge.
- Measurement of the distance from the distal occlusal pit to the buccal surface (DOP-DLE): a measurement made from the center of the distal occlusal pit to the distal longitudinal edge.

*Photograph of buccal surface (Figure 4):*

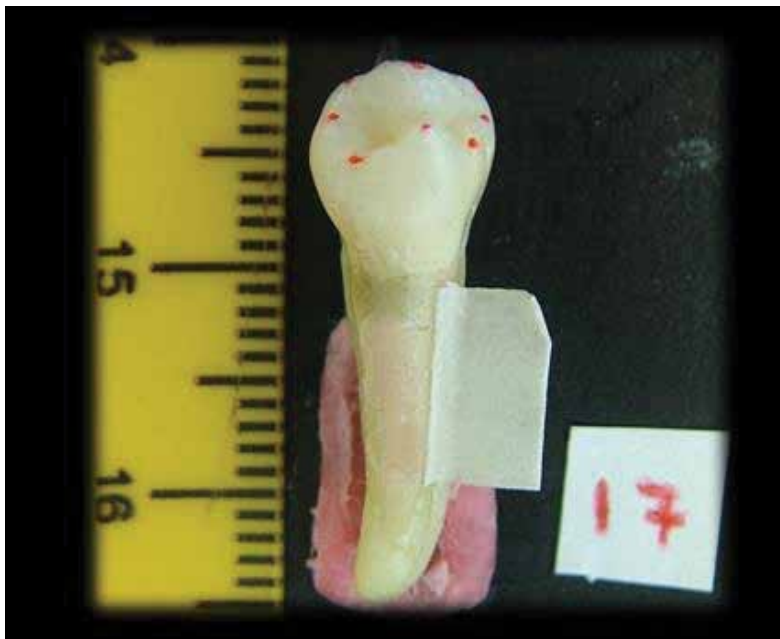- Measurement of the cervical-occlusal dimension of the crown (CO-BS): measurement of the buccal cusp apex to the most cervical region of the cervical line, made on the buccal surface.
- Measurement of the root length (RL): measurement of the most cervical region of the cervical line up to the root apex, made on the buccal surface.
- Measurement of the mesiodistal dimension of the root (MD-R): measurement made between the mesial and distal root surfaces in the dental cervix, made on the buccal surface.
- Measurement of the deviation of the root apex from the long axis of the crown (DRA): measurement of the angle formed between the long axis of the tooth and the root apex.

*Photograph of lingual surface (Figure 5):*

- Measurement of the cervical-occlusal dimension of the lingual surface (CO-LS): measurement from the apex of the highest lingual cusp to the most cervical region of the cervical line, made on the lingual surface.



**Figure 4.** Buccal surface photograph.



**Figure 5.** Lingual surface photograph.

*Photograph of mesial surface (Figure 6):*

- Measurement of the cervical-occlusal dimension of the mesial surface (CO-MS): measurement from the cervical line of the crown in the middle third to the mesial marginal ridge.
- Measurement of the buccolingual dimension of the root (BL-R): measurement between the buccal and lingual surfaces of the root in the dental cervix, made on the mesial surface.

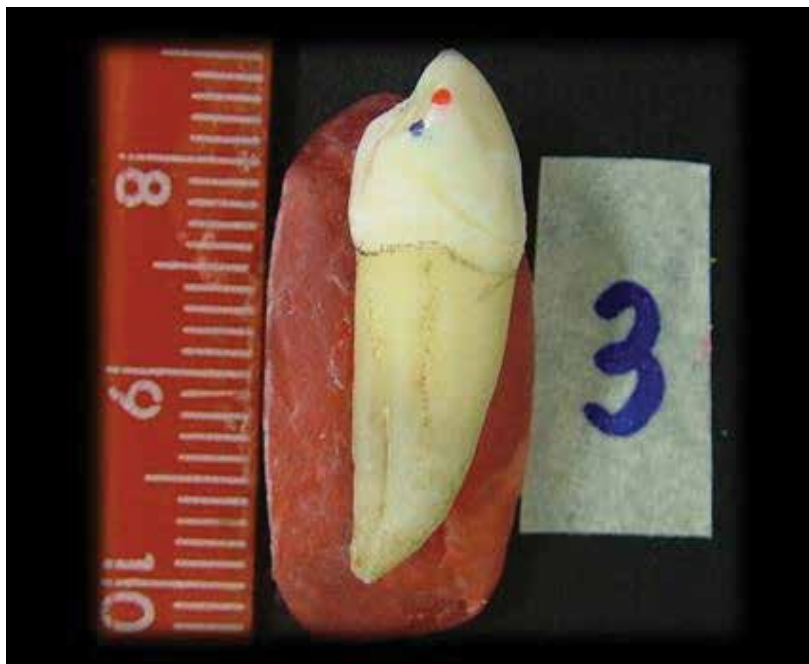*Photograph of distal surface (Figure 7):*

- Measurement of the cervical-occlusal dimension of the distal surface (CO-DS): measurement from the cervical line of the crown in the middle third to the distal marginal ridge.

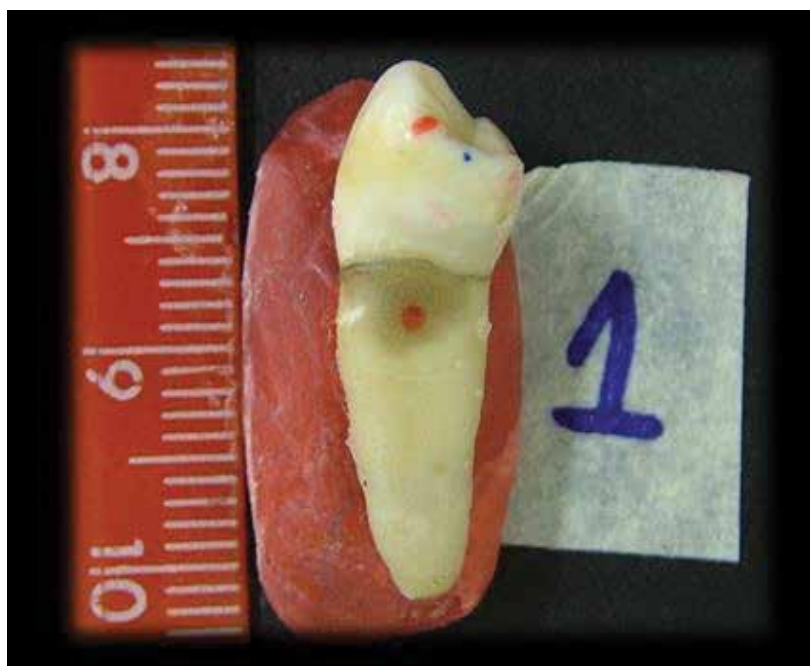The measurement of total tooth length (TL) will be obtained by adding the cervical-occlusal dimension of the crown (CO-C) to the root length measurement (RL).

## 2.1. Statistical analysis

The analyses were made by a qualified examiner. For reproducibility analysis, the teeth were analyzed in duplicate, with an interval of at least 7 days between the analyses. From the 100 teeth, which constituted the sample, 30 teeth were randomly selected. The reproducibility was estimated using intraclass correlation coefficient (ICC).



**Figure 6.** Mesial surface photograph.



**Figure 7.** Distal surface photograph.

From the two evaluations (initial and after the interval) performed to obtain the reproducibility, the measurements obtained from the initial evaluation were considered to compose the sample, since the other teeth were evaluated only once.

Descriptive statistics was performed.

The comparisons of interest were estimated using Kruskal-Wallis and Dunn's tests. An association study between mesial occlusal pits (MOP) and distal occlusal pits (DOP) was performed using Fisher's exact test. The level of significance was 5%.

### 3. Results

**Table 1** shows intraexaminer reproducibility performed in two different times. From the seven evaluated parameters, six presented "excellent" agreement and one presented "satisfactory" agreement (intraclass correlation coefficient, ICC).

**Tables 2–7** present the frequencies of the anatomical features evaluated through direct observation of the teeth.

From the first 100 evaluated lower first premolars, 97% were uniradicular and only three teeth (3%) presented a apical third bifurcation.



Anatomical features	ICC	p
MOP-MLE	0.647	<0.001
BL-DMR	0.953	<0.001
MLE-BC	0.799	<0.001
BL-O	0.886	<0.001
MD-O	0.876	<0.001
CO-C	0.958	<0.001
MD-R	0.821	<0.001

**Table 1.** Reproducibility of measurements performed by one examiner in two different times.

	Frequency	%
MOP		
Discreet	20	20
Small	63	63
Medium	15	15
Large	2	2
DOP		
Discreet	6	6
Small	24	24
Medium	43	43
Large	27	27
Total	100	100

**Table 2.** Distribution of mesial and distal occlusal pits (MOP and DOP).

	Frequency	%
G-MOP		
Absent	58	58
Present	42	42
G-DOP		
Absent	70	70
Present	30	30
Total	100	100

**Table 3.** Frequency of the grooves in the lingual surface that emerged from mesial and distal occlusal pits (G-MOP and G-DOP).

Number of lingual cusps	Frequency	%
1	78	78
2	19	19
3	3	3
Total	100	100

**Table 4.** Frequency of the number of lingual cusps.

	Frequency	%
MG-R		
Absent	61	61
Present	39	39
DG-R		
Absent	92	92
Present	8	8
Total	100	100

**Table 5.** Frequency of grooves in the mesial and distal root surfaces (MG-R and DG-R).

Enamel bridge position	Frequency	%
Absent	6	6
Mesial	47	47
Middle	45	45
Distal	2	2
Total	100	100

**Table 6.** Frequency of the enamel bridge position.

Mesiodistal groove crossing the enamel bridge	Frequency	%
Absent	50	50
Present	50	50
Total	100	100

**Table 7.** Frequency of the mesiodistal groove crossing the enamel bridge.

**Table 8** shows the frequency of the measurements made through the photographs and the use of the Image Tool 3.0 program.

Regarding the number of lingual cusps, 78 teeth presented only one cusp. From those, 25 teeth showed the lingual cusp positioned in the mesial third, 37 teeth showed that it is positioned

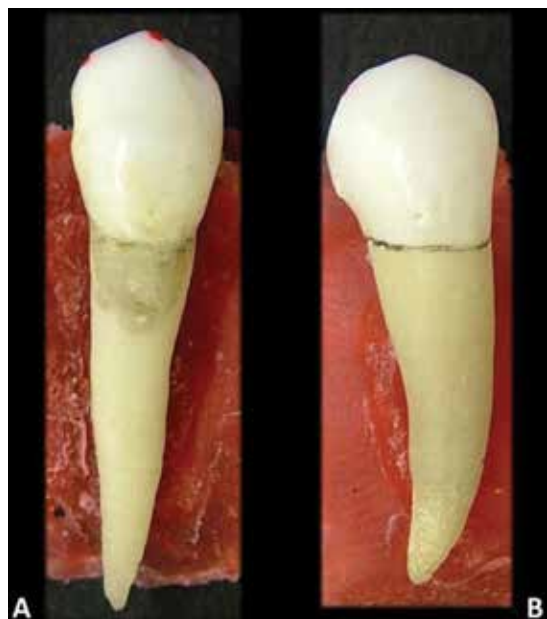in the middle third and 16 teeth showed that it is positioned in the distal third. Nineteen teeth presented two cusps and only three teeth presented three lingual cusps.

From the 100 lower first premolars, 70 presented a rectilinear root, without any angulation of the root apex. Thirty teeth (30%) presented deviation of the root apex or the apical third, varying from 16.67 to 172.47°, with a mean of 153.16°, being 26 with a distal deviation and 4 presenting a mesial deviation of the apical third (**Figure 8**).

Only two teeth presented MOP with score 4 (large), which were not considered for the statistical analysis.

Anatomical feature	n	Mean	Standard deviation
MLE-BC	100	3.75	0.557
DLE-BC	100	3.81	0.563
MLE-LC0	40	0.90	1.185
DLE-LC0	40	1.00	1.326
MLE-LC1	47	1.04	1.230
DLE-LC1	47	1.10	1.337
MLE-LC2	37	0.71	1.081
DLE-LC2	37	0.63	0.899
BL-O	100	4.81	0.940
MD-O	100	7.08	0.761
BL-MMR	100	3.29	0.957
BL-DMR	100	3.76	0.854
M-PE	100	3.09	1.026
MOP-MLE	100	1.89	0.424
DOP-DLE	100	2.12	0.433
CO-BS	100	8.34	0.901
CO-LS	100	5.59	0.842
CO-MS	100	5.33	0.682
CO-DS	100	5.21	0.608
RL	100	14.43	1.971
BL-R	100	7.21	0.701
MD-R	100	5.36	0.578
TL	100	22.85	1.888
DRA	30	153.16	29.692

**Table 8.** Frequency of the measurements obtained by the use of photographs and the Image Tool program.



**Figure 8.** Lower first premolars with a rectilinear root (A) and with a distal deviation (B).

The relation between MOP and MOP-MLE was analyzed. It was verified that the dimension of MOP-MLE was statistically related to the size of MOP ( $p = 0.037$ ; Kruskal-Wallis followed by Dunn’s test), that is, the higher the MOP, the higher the MOP-MLE was.

Statistical analysis showed that there was no statistically significant relation between DOP and DOP-DLE ( $p = 0.486$ ; Kruskal-Wallis), as well as there was no significant relation between BL-MMR and MOP ( $p = 0.769$ ); BL-DMR and DOP ( $p = 0.07$ ); MOP-MLE and DOP-DLE ( $p = 0.075$ ); BL-MMR and BL-DMR ( $p = 0.947$ ).

According to **Table 9**, there was a significant association between MOP and DOP ( $p = 0.007$ ; Fisher’s exact). It may be noted that the distal occlusal pits were usually higher when compared to the mesial occlusal pits.

DOP						
MOP	1	2	3	4	Total	p
1	5	3	8	5	20	0.007
2	1	20	27	15	63	
3	0	1	7	7	15	
Total	6	24	42	26	98	

**Table 9.** Distribution of the size of the mesial occlusal pits according to the size of the distal occlusal pits.

## 4. Discussion

In this study, we evaluated the anatomical features of the lower first premolar because it is considered one of the most complex teeth and the dentistry graduation students usually have difficulties in identifying it. According to Kraus and Furr [6], the lower first premolar shows an extremely wide range of morphologic variability.

There was no information about gender and age related to the teeth analyzed in this study. This is a limitation of this study because it was not possible to make associations between the measurements and those criteria.

The methodology was elaborated to cover the most of the anatomical structures of the lower first premolar for a detailed characterization of it. In order to do that, the classification of the pits, the way photographs were taken and the measurements made through the program Image Tool 3.0 were standardized.

Besides the anatomy books, there are practically no studies that describe the lower first premolars fully in detail. As those teeth have a wide anatomical variation and the dentistry students have difficulties in identifying them, this study sought to improve the information already known about those teeth, by facilitating the teaching-learning process in the dental anatomy.

The results presented in this chapter showed that the widest occlusal pit was the distal one. According to Figún and Garino [7], even though the occlusal pits are irregularly arranged, the distal pit is the widest one. Some authors [1, 2, 4] reported that the distal occlusal pit is the widest one [5, 8] but they did not mention whether there were differences between the occlusal pits.

The groove from the mesial occlusal fossa frequently continues to the lingual surface of the tooth [4, 5]. In our study, the grooves in the lingual surface that emerged from mesial and distal occlusal pits were usually absent. When the groove was present, it emerged, more frequently, from the mesial occlusal pit. According to Pagano et al. [8], there are some different situations related to the occlusal grooves such as grooves from the distal occlusal pit, short grooves from the mesial and distal occlusal pits or mesiolingual groove crossing the mesial marginal ridge.

Regarding the number of lingual cusps, most of the evaluated teeth had only one lingual cusp. This characteristic is in agreement with other studies [1–5].

Regarding the dimension of the total length of the lower first premolars, Della Serra and Ferreira [1] cited a variation from 17.0 to 27 mm and Sicher and Dubrul [4] reported a similar variation (18.5–27 mm). According to Picosse [2], the mean length of the lower first premolars in men was 21.97 mm and in women, it was 22.47 mm. In the present study, the total length of the evaluated teeth ranged from 19 to 28 mm, with a mean length of 22.85 mm.

In this study, we evaluated the cervical-occlusal measurement of the crown on the buccal surface (CO-BS) and the lingual surface (CO-LS). The mean values were 8.34 mm (ranging from 7 to 10 mm) and 5.59 mm (ranging from 2 to 8 mm), respectively. Sicher and Dubrul [4] also

made the same evaluation and reported values from 7.5 to 11 mm for the length of the dental crown in the buccal surface and 5 to 5.8 mm in the lingual surface. Picosse [2] reported a mean value of 8.69 mm for men and 7.40 mm for women, for the length of dental crown, whereas Della Serra and Ferreira [1] cited a variation from 6.2 to 11 mm.

Regarding the mesiodistal dimension of the dental crown, we found in the literature a variation from 6.0 to 8.0 mm [4], 5.5 to 8.5 mm [1] and a maximum value of 6.87 mm [2]. In the present study, the same measurement ranged from 6 to 9 mm with a mean value of 7.08 mm.

Observing the size of the mesial and distal longitudinal edges of the buccal cusp, there was similarity between them. Although, Picosse [2] reported that the distal edge is slightly larger and more inclined.

In this study, it was verified that the distal marginal ridge was frequently larger than the mesial marginal ridge. This feature may contribute for the largest buccolingual dimension of the distal surface, besides the wider distal occlusal pit observed in the lower first premolars. Figun and Garino [7] also verified that the distal segment is the largest portion of the occlusal surface, and the mesial segment presents a large slope and a small dimension. Pagano et al. [8] reported that the occlusal surface presents a large/moderate reduction of the mesiolingual segment; the convex lingual surface is continuous with the contact surface and a large buccolingual dimension of the distal surface.

According to Madeira and Rizzolo [5], the buccal and lingual cusps are almost always linked by an enamel bridge. Some authors also mentioned the constant presence of the enamel bridge [1, 4]. A similar situation was verified in this study. The enamel bridge was absent only in 6% of the teeth; it was present 47% in the mesial third and 45% in the middle third.

The mesiodistal groove crossing the enamel bridge was present in 50% of the teeth. The literature did not report the percentage of the presence of this groove. It is reported that some lower first premolars may have the enamel bridge being crossed by a mesiodistal groove [1, 4, 5].

A large variation in the root canal morphology is reported in the literature, especially in lower premolars [9]. The lower first premolars are prone to variations in their internal anatomy, which may have different number of roots and root canals [10]. In the present study, 97% of the teeth were uniradicular and only three teeth (3%) presented a apical third bifurcation. Bernardino et al. [11] observed four lower first premolars (3.2%) presenting three roots and 123 (96.8%) being uniradicular from a sample of 127 teeth. According to the authors, lower first premolars with three roots can be considered a rare anatomical variation. The incidence of a three-rooted lower first premolar is approximately 0.2% [12]. It was verified that the root was rectilinear, without any angulation in 70% of the teeth. Della Serra and Ferreira [1] reported that the root was rectilinear in 47.5% of the cases. Therefore, according to Madeira and Rizzolo [5], the root curves a little to distal direction in a buccal view. Our results showed that, when there is a deviation of the root apex, it is usually to distal direction.

The root grooves were absent in most of the evaluated teeth and, when present, they were usually observed in the mesial surface, in agreement with the observations of Madeira and

Rizzolo [5], who reported the presence of shallow longitudinal grooves and sometimes almost imperceptible ones in the mesial surface of the root. Differently from them, Picosse [2] reported that the mesial and distal radicular grooves were always present.

It was observed that the buccolingual dimension of the root was larger than the mesiodistal dimension. This feature is in agreement with Sicher and Dubrul [4], who reported that the mesiodistal dimension is slightly smaller than the buccolingual dimension.

## 5. Conclusion

According to the results, it was concluded that the lower first premolars usually presented the following features:

- Only one lingual cusp.
- An enamel bridge linking the buccal and lingual cusps.
- Distal occlusal pits wider than the mesial occlusal pits.
- The grooves in the lingual surface that emerged from the mesial and distal occlusal pits were absent, and when the grooves were present, they emerged from the mesial occlusal pit.
- One rectilinear root with no root grooves.
- When the root groove was present, it was observed in the mesial surface.

## Author details

Ticiana Sidorenko de Oliveira Capote<sup>1\*</sup>, Suellen Tayenne Pedroso Pinto<sup>1</sup>, Marcelo Brito Conte<sup>1</sup>, Juliana Álvares Duarte Bonini Campos<sup>2</sup> and Marcela de Almeida Gonçalves<sup>1</sup>

\*Address all correspondence to: [ticiana@foar.unesp.br](mailto:ticiana@foar.unesp.br)

1 Department of Morphology, School of Dentistry, São Paulo State University (UNESP), Araraquara, São Paulo, Brazil

2 Department of Food and Nutrition, Faculty of Pharmaceutical Sciences, São Paulo State University (UNESP), Araraquara, São Paulo, Brazil

## References

- [1] Della Serra O, Ferreira FV. Anatomia dental. 3rd ed. São Paulo: Artes Médicas; 1981. 334p
- [2] Picosse M. Anatomia dentária. 4th ed. São Paulo: Sarvier; 1977. 294p

- [3] Girón G, Gómez P, Morales L, León M, Moreno F. Rasgos morfológicos y métricos dentales coronales de premolares superiores e inferiores en escolares de tres instituciones educativas de Cali, Colombia. *International Journal of Morphology*. 2009;**27**(3):913-925
- [4] Sicher H, Dubrul E. *Anatomia Oral*. 8th ed. Porto Alegre: Artes Médicas; 1991. 390p
- [5] Madeira MC, Rizzolo RJC. *Anatomia do dente*. 8th ed. São Paulo: Sarvier; 2016. 169p
- [6] Kraus BS, Furr ML. Lower first premolars part I. a definition and classification of discrete morphologic traits. *Journal of Dental Research*. 1953;**32**(4):554-564
- [7] Figún ME, Garino RR. *Anatomia odontológica funcional e aplicada*. 2nd ed. Porto Alegre: Artmed; 2003. 532p
- [8] Pagano JL, Carbó RAR, Ramón A. *Anatomía dentaria*. Buenos Aires: Mundi; 1965. 664p
- [9] Dotto SR, Pagliarin CML, Carvalho MGP, Travassos RMC, Rosa RA. Endodontic treatment of mandibular premolar with three radicular conducts—Case report. *Revista de Endodontia Pesquisa e Ensino Online*. 2007;**3**(6):1 Available from: [http://w3.ufsm.br/endodontiaonline/artigos/\[REPEO\]%20Numero%206%20Artigo%201.pdf](http://w3.ufsm.br/endodontiaonline/artigos/[REPEO]%20Numero%206%20Artigo%201.pdf)
- [10] Endo MS, Tomazoli ATP, Queiroz AF, de Morais CAH, Pavan NNO. Tratamento endodôntico de primeioprémolar inferior com três canais: relato de caso. *Archives of Health Investigation*. 2017;**6**(2):85-88
- [11] Bernardino Junior R, Lucas BL, Borges DP, Souza AC. Three-rooted first lower premolar: A case report. *Bioscience Journal*. 2007;**23**(4):104-107
- [12] Cleghorn BM, Christie WH, Dong CC. Anomalous mandibular premolars: A mandibular first premolar with three roots and a mandibular second premolar with a C-shaped canal system. *International Endodontic Journal*. 2008;**41**(11):1005-1014



---

# **A Comparative Study of the Validity and Reproducibility of Mesiodistal Tooth Size and Dental Arch with iTero™ Intraoral Scanner and the Traditional Method**

---

Ignacio Faus-Matoses, Ana Mora,  
Carlos Bellot-Arcís, Jose Luis Gandia-Franco and  
Vanessa Paredes-Gallardo

Additional information is available at the end of the chapter

<http://dx.doi.org/10.5772/intechopen.70963>

---

## **Abstract**

**Introduction:** The introduction of intraoral scanning offers an alternative for measuring mesiodistal tooth sizes.

**Objectives:** To evaluate the validity and reproducibility of dental measurements performed on 3D digital study models using an intraoral scanner and compare them with measurements obtained using the traditional method.

**Materials and methods:** The study was approved by the Ethics Committee. The sample comprised 60 patients selected applying the following inclusion criteria: teeth erupted from first molar to first molar, no disorders in the number or shape, and no prosthetic restorations. A digital impression was taken of each patient using an intraoral scanner and plaster study models were fabricated from alginate impressions. The dental arches were measured using the two methods. OrthoCad™ computer software was used to measure the digital models, whereas a digital Vernier caliper was used to measure the physical models.

**Results:** Reproducibility of the 3D digital models obtained with the intraoral scanner was good. The validity of the digital measurements was excellent.

**Conclusions:** The measurement of mesiodistal tooth sizes using the scanner is an excellent alternative to traditional methods. But statistically significant differences may occur in dental arch dimensions, as the intraoral scanning method tends to overestimate measurements compared with the traditional method.

**Keywords:** 3D models, dental casts, intraoral scanner, iTero, reproducibility

---

## 1. Introduction

Orthodontic study models have always played a crucial role as a diagnostic register that provides information in the three spatial planes. Correct diagnosis and treatment planning will always rely on the data obtained from models and traditional plaster models remain the “Gold Standard” for dental measurement.

As the intraoral scanner has evolved, it has gained in importance in the quest to eliminate physical models of patients and replace them with virtual models. In the early days of scanning, models were produced by means of extraoral laser scanning or cone beam computerized tomography (CBCT) [1]. Today, some dental clinics possess intraoral scanners that make it possible to obtain digital models directly from the patient with no need to scan physical models.

Digital models have several advantages over conventional models, although the traditional models produce excellent results in terms of precision and fit providing the clinician has sufficient experience and the impression-taking techniques are adequate and performed correctly. But, there is always a potential for error that may be reflected in the working model produced.

Technical error, a badly chosen impression tray, badly mixed impression materials, or dimensional changes to materials (for example, the expansion of setting plaster) can all contribute to an accumulation of small errors that may affect the finished model. This points to the need for a technique capable of overcoming these problems and the solution might be the use of intraoral scanners that generate digital models.

In 2013, some authors [2] published a number of different research papers that compared manual, silicon, and digital (using the iTero® intraoral scanner) impression-taking techniques performed by experienced clinicians and second-year undergraduates who not yet experienced in impression techniques. The results showed that for inexperienced clinicians, the digital technique with intraoral scanner was easier to use and obtained better clinical results in less time, and so proved more efficient.

But, other researchers [3] have found that although patients prefer intraoral scanning as an impression technique, alginate impression is actually faster. The study used Cerec® Omnicam and LAVA C.O.S® scanners, and the patients were children aged between 10 and 17 years attending the clinic for orthodontic treatment.

Meanwhile, other researchers [4] found that impressions taken with an intraoral scanner, in this case the iTero®, were faster than conventional techniques using silicon.

In addition, digital techniques can overcome other problems such as patient discomfort, the impossibility of rectifying error once the physical impression has been taken, and the inconvenience of storing space-consuming materials and working models.

Nevertheless, the conventional technique currently in use does offer certain advantages over digital techniques, at least for the time being: for the experienced clinician, they are relatively simple to perform and are more economical in terms of initial outlay (although this may even out in the long term).

This table lists the main advantages and disadvantages of the digital technique using intraoral scanner.

Advantages	Disadvantages
1. Clean process	1. Learning curve
2. Patient comfort	2. Initial economic outlay
3. Eliminates possibility of impression taking error	3. Only captures features that are visible
4. Possibility of correcting the impression without repeating data registration	4. Technique limited to partial cases
5. Acts as a communication tool with the laboratory	5. Unsupported by sufficient scientific and clinical evidence
6. Communication/marketing tool with patient	6. Some systems are closed
7. Space-saving	

In 2014, some authors [5] claimed that digital models were being used for diagnostic purposes by 76% of North American orthodontists. According to a number of authors [6–11], digital models elaborated from scanned extraoral models have been shown to be a valid technique for taking orthodontic measurements, and although the published research reveals some discrepancies, Jacob et al. argue that these do not appear to be clinically relevant. The literature includes several articles [12–14], including a systematic review [15] about the reproducibility and validity of measurements taken from 3D study models, most of which used table-top or extraoral scanners to register data from conventional impressions, CBCTs, or plaster models. But little research has been published on intraoral scanners. Some authors [16–18] showed how digital models may be valid and reproducible, although differences have been found between the different scanners assayed.

Some authors [16] compared intraoral scanning with the conventional manual technique, using the Cadent IOC® intraoral scanner with OrthoCad® measurement software. Conventional impressions and scans were taken from 30 patients, and linear measurements were taken of mesiodistal dental distances to calculate the Bolton ratio for each patient. Although the study identified statistically significant differences between the techniques, it was concluded that these were not clinically relevant; in other words, although differences were found, they were minimal and the models obtained from intraoral scans were clinically valid and reproducible.

In 2013, other authors [1] published a study to determine the validity, accuracy, and reproducibility of measurements taken from digital models generated directly with an intraoral scanner, in this case the 3 M Lava C.O.S<sup>®</sup>. In addition to linear measurements, they also calculated the Bolton ratio. The 3 M scanner was found to be valid, exact, and reproducible for obtaining plaster models, and although it produced significantly different measurements for calculating the Bolton ratio, the authors did not consider these clinically relevant, as they were always less than 1.5 mm. They also registered the time required to perform the two techniques and affirmed that this decreased significantly as the clinician's experience increased.

In 2015, other authors [18] published an article comparing intraoral (iTero<sup>®</sup> and Lythos<sup>®</sup>), extraoral scanners (Ortho Insign<sup>®</sup>), and traditional measurements, in this case *in vitro* using dissected mandibles to compare the validity and reproducibility of the methods. They measured the mesiodistal diameters of premolars, canine height, intercanine and intermolar distance, and arch length. It was found that the three scanners provided valid and reproducible measurements compared with manual measurement, although it was clear that intraoral scanners tended to systematically underestimate measurements.

In 2016, other authors [19] investigated the accuracy of different intraoral scanners (Trios<sup>®</sup>, iTero<sup>®</sup>, E4D<sup>®</sup> Dentist and Zfx IntraScan<sup>®</sup>) for measuring mesiodistal sizes and intermolar and intercanine distance, in the presence of archwires and brackets, concluding that the apparatus did not present a clinical scanning difficulty, but that there were differences between the four scanners, TRIOS<sup>®</sup> and iTero<sup>®</sup> obtaining the most accurate results.

In 2016, some authors [20] published a literature review that included six different intraoral scanners. Although the study models produced using the scanners were valid and reproducible as intra- and inter-arch measurements taken manually, the patients preferred the conventional impression technique because it required less time to perform.

The leading scanners available on the market today [21] (CEREC<sup>®</sup>, Lavas C.O.S system<sup>®</sup>, iTero<sup>®</sup>, E4D<sup>®</sup> y TRIOS<sup>®</sup>) show varying characteristics in terms of their functional principles, light sources, the use or non-use of powder applications, operating processes, and dedicated software.

1. The CEREC<sup>®</sup> 1 scanner (Sirona<sup>®</sup>, Bensheim, Germany) was introduced in 1987 and was the first intraoral scanner on the market. The system is based on the principle of light triangulation, whereby the intersection of three light beams determines each point in space. Dental surfaces can refract light and so reduce scanning precision; for this reason, it is necessary to apply a layer of titanium dioxide powder to disperse light uniformly, reduce reflection, and so ensure scanning accuracy. At present, the most widely used version of the CEREC<sup>®</sup> scanner is the product's fourth generation, named the CEREC<sup>®</sup> AC Bluecam. This scanner's capture method differs from its predecessors as it uses a blue LED diode light source. According to the manufacturer, the CEREC<sup>®</sup> AC Bluecam scanner captures one quadrant of the digital impression per minute and its antagonist quadrant in a few seconds. The most innovative CEREC<sup>®</sup> system is the CEREC<sup>®</sup> AC Omnicam, launched in 2012, with a continuous capture system in which uninterrupted data acquisition generates a 3D model, unlike the CEREC<sup>®</sup> Bluecam that registers individual images one at a time. The CEREC<sup>®</sup> Omnicam can be used for taking either the impression of an

individual tooth, a quadrant, or a complete arch, whereas the CEREC® Bluecam can only be used to capture a single tooth or quadrant. The CEREC® Omnicam's other key features include image capture in natural color and powder-free scanning, which is particularly useful when scanning large areas [22]. When performing an intraoral scan, the dentist holds the scanner and points it towards the area to be scanned. The camera must be placed a few millimeters from the dental surface or even lightly touching it. Moreover, it is possible to interrupt the scanning process and resume it at any moment. The CEREC® Omnicam system has also introduced a new movement detection feature to ensure that data capture and precision are accurate, so the camera stops working whenever it detects camera shake or any movement that might compromise precision [23].

2. The Lava C.O.S® intraoral scanner (Chairside Oral Scanner; 3M® Espe, Seefeld, Germany) was invented in 2006, entered the market in 2008, and works on the principle of active wavefront sampling. The system uses three sensors that capture clinical images from different viewpoints simultaneously and generate surface "patches" processed with the help of an algorithm to visualize a three-dimensional virtual model. It captures 20 images per second, covering some 10,000 data items in each scan. The huge amount of data obtained and processed with algorithms involves a large number of images that contribute to a high-quality image of great accuracy [24]. The Lava C.O.S® has the smallest capture point of all the scanners on the market, with a width of only 13.2 mm. The scanner uses a visible blue light source and a laptop computer connected to an easy-to-use touch screen. Like the CEREC® AC Bluecam system, the Lava C.O.S® also requires the use from a fine titanium dioxide powder applied to the tooth to ensure adequate scanning. The scanning procedure is as follows [22, 25]: after cleaning and drying the patient's mouth, a fine, even layer of powder is applied to the dental surfaces. During scanning, the capture point must be moved from the posterior teeth towards the anterior sector taking care to capture both the buccal and lingual tooth surfaces. The Lava C.O.S® produces images simultaneously to scanning so that, if required, any area can be rescanned. As the resulting scans are examined by the clinician, if it is necessary to extend the scan area, he/she only has to carry on scanning and the dedicated software will merge all additional scan data automatically. When one arch has been scanned, then the same procedure is repeated for the antagonist arch. Then, the patient is asked to occlude to register the articulation between the upper and lower arches and merge the data for both arches in occlusion. Although it uses its own working computer files, it might be said that the Lava C.O.S® is a semi-open data system [23] as it is compatible with other systems.
3. The iTero® scanner (Cadent Inc.® Carlstadt, NJ, USA) appeared on the market in 2007 and was later taken over by the North American Align Technologies® in 2014. The scanner captures tooth surface data with the use of optical laser scanning based on the principle of parallel confocal scanning [26]. According to some authors [27], in the course of a single scan, it can capture up to 100,000 laser light points at 300 different focal depths on the tooth surface. These focal depths are defined by differences of approximately 50 microns each, allowing the system to obtain precise information about the surface topography. Thanks to this capture technology, the iTero® can scan intraoral structures without the need for powder application [23]. Initially, the system used a red light source for data

capture and required a computer, mouse, keyboard, and monitor, as well as the scanner itself. But, the latest versions offer updated hardware of a smaller size that is easier to use due to the introduction of a touchscreen, which has eliminated the use of the keyboard. As described by some authors [28], the iTero takes a photograph of each area of the tooth surface from different viewpoints—occlusal, vestibular, lingual—and of the interproximal points of adjacent teeth; if it detects any sudden movement, the system will automatically request a rescan of the area. Afterwards images must be captured at a 45° angle to the buccal and lingual surfaces of the antagonist teeth and, if necessary, the patient's occlusion can be captured positioning the scanner on the vestibular surface of the occluded arches, whereby the system will generate a model of the occlusion. The iTero® is an open system that produces SLT files (Standard Triangle Language), a standard file type for working with 3D models in many different fields, including dentistry, architecture, and engineering.

4. The E4D (D4D Technologies® Richardson, TX, USA) works on the principle of optical coherence tomography and confocal laser scanning microscopy. This uses a red laser as light source whose microcrystals vibrate 20,000 times per second. Laser technology traps images from all angles creating a library of images that are then processed by the system's software to produce a virtual 3D model in only a few seconds. This system does not require powder applications to the teeth. As well as the intraoral scanner, the apparatus includes a pedal, computer, and monitor. To perform a scan, the clinician holds the scanner over the tooth while pressing down on the pedal; as soon as the image appears on the monitor, the pedal can be released and the scanner moved on to the next area to be scanned. The scanner must be positioned at a certain distance from the tooth and for this rubber points are supplied that rest on the teeth and keep the scanner at an equal distance throughout the procedure. In this way, a series of images are captured from different viewpoints, which the system's software automatically converts into a digital model. Unlike the other systems described above, occlusal relationships are not registered by data capture from a vestibular viewpoint with the teeth in occlusion but by using an impression material placed on the teeth that the patient bites on and which are scanned afterwards. The scanner detects the impression material and the adjacent teeth, and from this information together with the digital models already generated configures a virtual model of the occlusion. Data captured can be exported in the system's own format or in "open" STL format, although an annual fee is charged for the SLT service.
5. The TRIOS® scanner (3D Shape, © Copenhagen, Denmark) was developed in 2010 and became available in 2011. The system works on the principle of ultrafast optical sectioning and confocal microscopy. Some 3000 images per second are generated reducing any influence of relative movement between the scan point and the tooth. By analyzing all the images captured, the system constructs a 3D digital model instantly, which also reflects the shape and colors of the teeth and gums. Like the iTero, ® the E4D®, and the TRIOS® scanners, it does not need powder application to perform the scanning process. The TRIOS® is relatively simple to use; the dentist holds the scan point at a distance of 2–3 cm from the tooth and 3D models of both teeth and gums are generated instantly while the

operator moves the device over the tooth surfaces. When both arches have been scanned, a scan of the patient in occlusion must be captured from the buccal viewpoint; the system then adapts the data from both arches to produce a coordinated model of the complete occlusion. The TRIOS® comprises two separate parts, the TRIOS Cart® and TRIOS Pod®. The TRIOS Pod® is a transportable scanner that offers better mobility and flexibility and is compatible with other computers including the iPad®. In either case—TRIOS Pod® or TRIOS Cart®—the clinician can choose between the system's standard version and full color version. The TRIOS® is an open system that generates 3D digital models from STL files or its own system's files.

A wide variety of intraoral scanners are currently available. They can be classified in terms of the technology used for image capture, as each scanner employs a different working method to construct a digital model, based on multiple photo or video capture by laser, red laser, or blue light. Scanning may require applications of titanium oxide powder to eliminate reflections that would otherwise impede data registering, as in the case of the 3 M® or the Bluecam de Cerec® systems. A system may be "closed," in which case the work flow only proceeds via the manufacturer's own services, or "open," generating STL files that can be processed by any design software.

## 2. Objectives

1. To analyze intra-examiner and inter-examiner reproducibility of both measurement methods.
2. To evaluate the validity of intraoral scanning in comparison with the manual method, considered the "Gold Standard."

## 3. Materials and methods

The initial sample consisted of 102 individuals of both sexes who sought orthodontic treatment from the Master's Program in Orthodontics at the University of Valencia.

The inclusion criteria applied were as follows:

- Patients in permanent dentition from first molar to first molar at the moment of data registration.
- Good quality study models available, both physical and digital.
- Patients presenting minor occlusal restorations that did not visibly compromise the mesial faces of teeth.
- Patients presenting malocclusions with rotations, diastemas and overcrowding.

Exclusion criteria were as follows:

- Patients wearing fixed prostheses that could present alterations to the original points of contact or that could produce possible bias in the models obtained due to differences in light reflections during scanning.
- Patients presenting disorders in the number of teeth, agenesis, extractions, or supernumerary teeth.
- Patients presenting major dental destruction, fractures, or attrition that could alter the mesiodistal diameters of teeth.

The final sample included 60 individuals of both sexes, 26 men and 34 women, with an average age of 33.6 years (ranging from 16.3 to 62.7 years).

All patients underwent intraoral scanning. Then, alginate impressions were taken and subsequently cast in plaster (**Figure 1**).

### 3.1. Manual measurement method

All measurements were performed with a digital Vernier caliper, with the exception of arch length, which was measured with a brass wire (**Figure 1**).

### 3.2. Direct measurements

- Teeth sizes (TS)
- Upper (UICD) and lower intercanine distance (LICD)
- Upper (UIMD) and lower intermolar distance (LIMD)
- Upper (UAL) and lower arch length (LAL)

### 3.3. Indirect measurements

After taking the measurements listed above, the following values were calculated that constituted indirect measurements:

- Upper (UD) and lower discrepancy (LD)
- Bolton anterior (BOLTON AR) and overall ratio (BOLTON OR) [29, 30]



**Figure 1.** Plaster casts, digital Vernier caliper to performed all measurements and brass wire to measure arch length.



### 3.4. Intraoral scan measurement method

The iTero® intraoral scanner was used to scan dental arches, capturing image data directly from each patient's mouth. This scanner acquires tooth surface data by means of optical laser scanning based on the principle of parallel confocal scanning (**Figure 2**).

The scans were performed by two clinicians trained for this purpose and calibrated identically.

As soon as the patient's teeth had been scanned, the files were sent via the Internet from the scanner to the database [www.mycadent.com](http://www.mycadent.com) or [www.myaligntech.com](http://www.myaligntech.com), downloading the digital model in STL format using OrthoCAD® software, whose reliability and reproducibility have been confirmed [6, 12, 16, 31, 32] to analyze the visualizations of each patient's occlusion.

### 3.5. Direct measurements

- Teeth sizes (TS)
- Upper (UICD) and lower intercanine distance (LICD)
- Upper (UIMD) and lower intermolar distance (LIMD)
- Upper (UAL) and lower arch length (LAL)

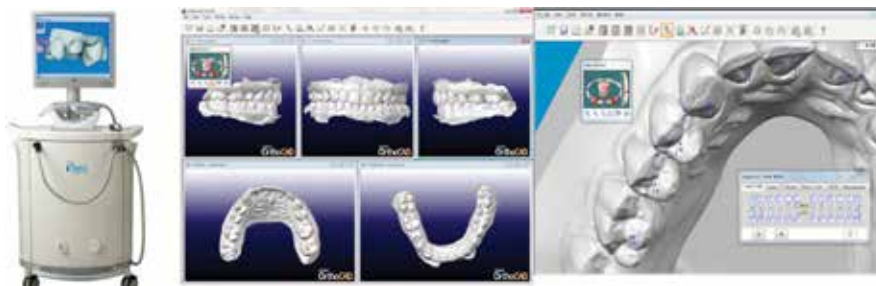
### 3.6. Indirect measurements

After taking the measurements listed above, the following values were calculated that constituted indirect measurements:

- Upper (UD) and lower discrepancy (LD)
- Bolton anterior (BOLTON AR) and overall ratio (BOLTON OR)

### 3.7. Statistical analysis

Firstly, the Dahlberg formula, the coefficient of variation (CV), and the intraclass correlation coefficient (ICC) were used to estimate intra- and inter-examiner reproducibility of the methods. The main evaluator repeated all measurements by means of both methods (intraoral



**Figure 2.** iTero® intraoral scanner and digital dental casts.

scanner and manual measurement), whereas a second evaluator performed the same two sets of measurements of the whole sample. Normality of all differences in intra- and inter-examiner measurements was compared using the Kolmogorov-Smirnov and Shapiro-Wilk tests, with results that confirmed reproducibility for most variables ( $p > 0.05$ ). Mean values obtained at the first and second sets of measurements by the first examiner using both methods were compared using a paired sample t-test. The same statistical test was applied to compare mean values obtained for each parameter by the two methods in order to evaluate the validity of intraoral scanning.

Secondly, to evaluate the validity of the intraoral scanning method, the results obtained by the two methods were compared using a regression model, which estimated the confidence intervals of regression coefficients. The significance level was set at 5% ( $p < 0.05$ ).

## 4. Results

### 4.1. Intraoral scan intra- and inter-examiner reproducibility

Section 4.1 examines intra- and inter-examiner reproducibility of the scanning method using the Itero intraoral scanner as presented in **Tables 1** and **2**.

### 4.2. Validity of intraoral scanning compared with manual measurement

Section 4.2 investigates the validity of intraoral scanning in comparison with manual measurement (considered the “Gold Standard”) by means of two analyses:

The first analysis compares average values obtained for each parameter using the two methods to determine whether the intraoral scanning method can be considered valid. When average values vary between methods, this might suggest a possible systematic error as presented in **Table 3**. The second analysis grouped the measurements obtained for each parameter, applying a regression model to check for the absence of bias and also any lack of linearity in order to accept or reject the validity of intraoral scanning (**Table 4** and **Figure 3**). Six linear regression models were estimated to define the linear correlations between measurements obtained using the scanner and measurements obtained manually: (1) teeth sizes (TS); (2) intercanine (ICD) and intermolar distances (IMD); (3) arch length (AL); (4) discrepancy (D); (5) Bolton ratios (BOLTON); and (6) all measurements together.

#### 4.2.1. Model 1: teeth sizes (TS)

The following graph brings together 1440 pairs of measurements corresponding to 24 teeth and 60 individuals. The continuous blue line is the model’s estimated regression line, whereas the dotted line is the main diagonal, whereby the horizontal coordinates are equal to the vertical, representing perfect agreement between the two methods. The two lines literally overlap, pointing to the validity of the measurement method using the intraoral scanner (**Figure 3**).

**Intraoral scan intra-examiner reproducibility**

	Main examiner differences between first and second		Confidence interval (CI) 95%		p-value	D	Dahlberg CV (%)	ICC
	Mean	SD	Lower limit	Upper limit				
TS 16	-0.05	0.31	-0.12	0.03	0.233	0.15	1.48	0.89
TS 15	-0.06	0.23	-0.13	0.00	0.065	0.13	1.96	0.94
TS 14	-0.06	0.27	-0.13	0.01	0.113	0.15	2.07	0.83
TS 13	-0.04	0.39	-0.13	0.06	0.398	0.18	2.34	0.86
TS 12	-0.11	0.54	-0.25	0.03	0.133	0.27	3.94	0.83
TS 11	-0.01	0.31	-0.09	0.07	0.865	0.15	1.72	0.91
TS 21	0.03	0.50	-0.09	0.16	0.605	0.24	2.84	0.80
TS 22	-0.09	0.31	-0.18	-0.01	0.034*	0.17	2.52	0.91
TS 23	-0.07	0.27	-0.15	0.00	0.064	0.15	2.02	0.92
TS 24	-0.08	0.46	-0.20	0.04	0.169	0.23	3.33	0.71
TS 25	-0.19	0.89	-0.42	0.04	0.108	0.46	6.69	0.53
TS 26	-0.08	0.39	-0.19	0.02	0.105	0.20	1.98	0.80
TS 36	-0.11	0.39	-0.20	-0.01	0.033*	0.20	1.83	0.88
TS 35	-0.09	0.35	-0.19	0.00	0.048*	0.18	2.55	0.81
TS 34	-0.09	0.31	-0.16	-0.01	0.036*	0.16	2.29	0.84
TS 33	-0.06	0.27	-0.13	0.01	0.098	0.14	2.03	0.91
TS 32	-0.07	0.31	-0.16	0.01	0.092	0.17	2.85	0.81
TS 31	0.00	0.27	-0.07	0.07	0.923	0.13	2.40	0.84
TS 41	-0.06	0.27	-0.12	0.01	0.098	0.13	2.44	0.80
TS 42	-0.03	0.35	-0.11	0.06	0.517	0.16	2.64	0.79
TS 43	-0.09	0.31	-0.16	-0.01	0.018*	0.14	2.11	0.89
TS 44	-0.03	0.31	-0.12	0.05	0.420	0.16	2.20	0.84
TS 45	-0.07	0.31	-0.15	0.01	0.094	0.16	2.25	0.89
TS 46	-0.08	0.31	-0.16	0.00	0.069	0.16	1.52	0.92
UICD	-0.21	0.93	-0.46	0.03	0.085	0.48	1.47	0.97
LICD	-0.30	1.16	-0.59	0.00	0.052	0.59	2.44	0.94
UIMD	0.06	1.08	-0.21	0.34	0.643	0.52	1.06	0.97
LIMD	-0.15	1.47	-0.53	0.23	0.428	0.72	1.69	0.91
UAL	-0.61	1.51	-1.01	-0.22	0.004**	0.85	1.21	0.94

**Intraoral scan intra-examiner reproducibility**

	Main examiner differences between first and second		Confidence interval (CI) 95%		p-value	D Dahlberg (mm)	CV (%)	ICC
	Mean	SD	Lower limit	Upper limit				
LAL	-0.86	2.21	-1.43	-0.29	0.004**	1.22	1.98	0.85
UD	0.07	2.52	-0.58	0.72	0.827	1.21	1.25	0.85
LD	-0.28	2.63	-0.96	0.40	0.408	1.29	1.78	0.73
BOLTON AR	-0.16	1.94	-0.66	0.34	0.521	0.94	1.19	0.83
BOLTON OR	-0.01	1.36	-0.36	0.34	0.954	0.65	0.71	0.82

Main examiner differences, confidence interval (CI) 95%, t-test (p-value), Dahlberg (D), coefficient of variation (CV), and intraclass correlation coefficient (ICC).

Tooth sizes (TS), upper (UICD) and lower intercanine distance (LICD), upper (UIMD) and lower intermolar distance (LIMD), upper (UAL) and lower arch length (LAL), upper (UD) and lower discrepancy (LD), and Bolton anterior (BOLTON AR) and overall ratio (BOLTON OR).

\*p < 0.05.

\*\*p < 0.01.

**Table 1.** Intraoral scan intra-examiner reproducibility.

**Intraoral scan inter-examiner reproducibility**

	Main examiner differences between first and second		Confidence interval (CI) 95%		p-value	Dahlberg (D, mm)	CV (%)	ICC
	Mean	SD	Lower limit	Upper limit				
TS 16	0.04	0.41	-0.11	0.19	0.565	0.14	1.44	0.93
TS 15	-0.06	0.58	-0.27	0.15	0.536	0.20	2.92	0.91
TS 14	0.03	0.55	-0.17	0.23	0.738	0.19	2.62	0.80
TS 13	-0.04	0.44	-0.20	0.12	0.583	0.15	1.96	0.95
TS 12	-0.02	0.38	-0.16	0.12	0.758	0.13	1.94	0.97
TS 11	0.00	0.33	-0.12	0.12	1.000	0.11	1.27	0.97
TS 21	0.00	0.36	-0.13	0.13	1.000	0.12	1.43	0.96
TS 22	-0.11	0.52	-0.29	0.08	0.214	0.19	2.81	0.94
TS 23	0.01	0.33	-0.11	0.13	0.859	0.12	1.53	0.97
TS 24	-0.03	0.38	-0.17	0.11	0.647	0.14	1.95	0.92
TS 25	-0.12	0.41	-0.27	0.03	0.104	0.16	2.41	0.94

Intraoral scan inter-examiner reproducibility								
	Main examiner differences between first and second		Confidence interval (CI) 95%		p-value	Dahlberg (D, mm)	CV (%)	ICC
	Mean	SD	Lower limit	Upper limit				
TS 26	0.07	0.47	-0.09	0.24	0.373	0.17	1.65	0.89
TS 36	-0.11	0.66	-0.35	0.13	0.326	0.24	2.18	0.85
TS 35	-0.09	0.38	-0.23	0.05	0.193	0.15	2.06	0.89
TS 34	-0.02	0.36	-0.15	0.11	0.735	0.12	1.72	0.93
TS 33	0.01	0.44	-0.15	0.17	0.891	0.15	2.16	0.92
TS 32	0.03	0.44	-0.13	0.19	0.685	0.15	2.59	0.88
TS 31	-0.02	0.44	-0.18	0.14	0.780	0.15	2.79	0.90
TS 41	-0.03	0.49	-0.21	0.15	0.713	0.17	3.15	0.81
TS 42	0.08	0.30	-0.03	0.19	0.137	0.12	2.00	0.91
TS 43	-0.07	0.25	-0.16	0.02	0.111	0.10	1.44	0.97
TS 44	-0.02	0.47	-0.19	0.15	0.801	0.16	2.29	0.90
TS 45	-0.13	0.74	-0.40	0.14	0.311	0.27	3.64	0.70
TS 46	0.12	0.63	-0.11	0.35	0.265	0.23	2.09	0.84
UICD	-0.36	1.23	-0.81	0.09	0.105	0.49	0.69	0.99
LICD	-0.53	2.82	-1.56	0.50	0.275	1.04	1.69	0.95
UIMD	-0.02	3.20	-1.19	1.15	0.970	1.10	1.29	0.88
LIMD	-0.27	4.24	-1.82	1.28	0.703	1.47	1.56	0.66
UAL	-0.27	3.29	-1.47	0.93	0.622	1.14	3.47	0.90
LAL	-0.93	3.72	-2.29	0.43	0.157	1.44	5.87	0.70
UD	-0.49	2.44	-1.38	0.40	0.245	0.91	1.82	0.94
LD	-0.04	3.40	-1.28	1.20	0.944	1.17	2.71	0.77
BOLTON AR	0.30	2.44	-0.59	1.19	0.464	0.86	1.10	0.89
BOLTON OR	-0.03	1.45	-0.55	0.50	0.904	0.49	0.53	0.92

Main and second examiner differences, confidence interval (CI) 95%, t-test (p-value), Dahlberg (D), coefficient of variation (CV), and intraclass correlation coefficient (ICC).

Tooth sizes (TS), upper (UICD) and lower intercanine distance (LICD), upper (UIMD) and lower intermolar distance (LIMD), upper (UAL) and lower arch length (LAL), upper (UD) and lower discrepancy (LD), and Bolton anterior (BOLTON AR) and overall ratio (BOLTON OR).

**Table 2.** Intraoral scan inter-examiner reproducibility.

	Differences intraoral scan and manual		Confidence interval (CI) 95%		p-value
	Mean	SD	Lower limit	Upper limit	
TS 16	-0.16	0.46	-0.28	-0.04	0.011*
TS 15	-0.06	0.50	-0.18	0.07	0.342
TS 14	0.08	0.35	-0.02	0.17	0.100
TS 13	0.03	0.35	-0.05	0.12	0.420
TS 12	0.08	0.50	-0.05	0.21	0.201
TS 11	0.03	0.31	-0.05	0.11	0.509
TS 21	-0.01	0.39	-0.10	0.09	0.864
TS 22	0.01	0.50	-0.12	0.14	0.854
TS 23	-0.09	0.39	-0.19	0.01	0.075
TS 24	-0.15	0.58	-0.29	0.00	0.042*
TS 25	0.07	0.46	-0.04	0.19	0.209
TS 26	0.07	0.39	-0.04	0.17	0.191
TS 36	0.07	0.35	-0.03	0.16	0.154
TS 35	0.04	0.39	-0.06	0.14	0.447
TS 34	0.02	0.39	-0.08	0.12	0.649
TS 33	-0.03	0.43	-0.13	0.08	0.613
TS 32	0.02	0.35	-0.07	0.11	0.698
TS 31	-0.03	0.23	-0.10	0.03	0.328
TS 41	-0.06	0.31	-0.14	0.02	0.159
TS 42	0.00	0.31	-0.09	0.08	0.907
TS 43	-0.07	0.31	-0.15	0.01	0.090
TS 44	0.10	0.35	0.00	0.19	0.037*
TS 45	0.02	0.39	-0.09	0.12	0.751
TS 46	0.13	0.39	0.04	0.23	0.007**
UICD	0.02	1.63	-0.39	0.44	0.906
LICD	-0.34	2.25	-0.91	0.24	0.244
UIMD	-0.44	2.25	-1.02	0.14	0.131
LIMD	0.09	2.13	-0.46	0.64	0.745
UAL	0.58	2.01	0.06	1.10	0.029*
LAL	0.97	3.83	-0.02	1.96	0.054
UD	0.59	1.86	0.11	1.07	0.017*
LD	0.97	3.60	0.03	1.90	0.044*

	Differences intraoral scan and manual		Confidence interval (CI) 95%		p-value
	Mean	SD	Lower limit	Upper limit	
BOLTON AR	-0.46	2.56	-1.12	0.20	0.163
BOLTON OR	0.32	1.86	-0.17	0.80	0.194

CI 95% and t-test (p-value).

Tooth sizes (TS), upper (UICD) and lower intercanine distance (LICD), upper (UIMD) and lower intermolar distance (LIMD), upper (UAL) and lower arch length (LAL), upper (UD) and lower discrepancy (LD), and Bolton anterior (BOLTON AR) and overall ratio (BOLTON OR).

\*p < 0.05.

\*\*p < 0.01.

**Table 3.** Differences between intraoral scan and manual method.


Linear regression model intraoral scan/manual method	R <sup>2</sup>	Dependent (CI 95%)	Constant (CI 95%)
Model 1: TS	0.968	0.995 (0.982–1.008)	0.043 (–0.059 to 0.144)
Model 2: ICD and IMD	0.871	0.900 (0.809–0.991)	7.348 (1.363–13.33)
Model 3: AL	0.979	0.978 (0.952–1.005)	0.644 (–0.371 to 1.659)
Model 4: D	0.548	0.690 (0.525–0.854)	–0.449 (–1.250 to 0.351)
Model 5: BOLTON	0.949	1.034 (0.971–1.098)	–3.014 (–8.423 to 2.396)
Model 6: All measurements	0.998	1.000 (0.997–1.002)	0.073 (–0.005 to 0.150)

Value R<sup>2</sup> and dependent and constant confidence interval (CI) 95%. Teeth sizes (TS), intercanine distances (ICD), intermolar distances (IMD), arch length (AL), discrepancy (D), and Bolton ratios (BOLTON).

**Table 4.** Six linear regression models between intraoral scan and manual method.

#### 4.2.2. Model 2: intercanine (ICD) and intermolar distances (IMD)

This model represents 240 pairs of measurements. The graph shows two lines almost super-imposed over one another, which are compatible with the hypothesis of agreement between measurements and so the validity of the scanning method (**Figure 3**).



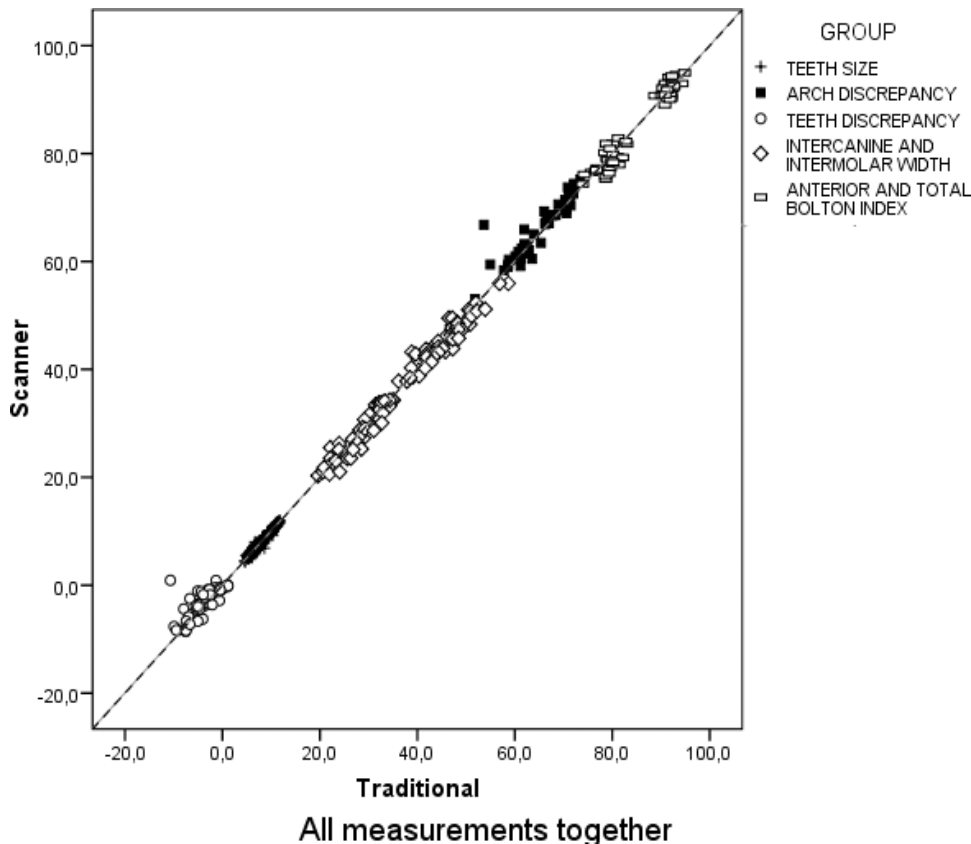
**Figure 3.** Five linear regression models using the scanner vs. traditional method: (1) teeth sizes; (2) intercanine and intermolar width; (3) arch discrepancy; (4) teeth discrepancy; and (5) anterior and total Bolton index.

4.2.3. Model 3: arch length (AL)

The model represents 120 pairs of arch length measurements. The linear regression line lies above the theoretical line  $y = x$ , indicating a slight differences in the dependent variable. This outcome coincides with the analysis described above, that arch length measurements were overestimated by the scanning method (**Figure 3**).

4.2.4. Model 4: discrepancies (D)

The model represents 120 pairs of measurements. The regression line is above the main diagonal coinciding with the analysis described above that arch length measurements were overestimated by the scanning method. Given that discrepancy was calculated as the difference between arch length and the sum of a series of tooth sizes and as the validity of tooth size measurement has already been established, the discrepancy must be the outcome of imprecise arch length measurements (**Figure 3**).



**Figure 4.** Linear regression models using the scanner vs. traditional method for all the measurements together.



#### 4.2.5. Model 5: anterior and overall Bolton ratios

For Bolton ratios, the graph shows the two lines almost coinciding, which is compatible with the hypothesis of agreement between sets of measurements and so the validity of the measurement method with intraoral scanning.

Intervals of the dependent and constant included 1 and 0, respectively, and so the validity of the measurement method with scanner was accepted (**Figure 3**).

#### 4.2.6. Model 6: all parameters together

As a synthesis of all the data, this estimated model combined measurement data for all parameters obtaining almost perfect correlation ( $R^2 = 0.998$ ), although this was not sufficient to accept the validity of the scanner. However, on the basis of the values of the dependent and constant and their respective intervals, it may be concluded that the measurement method using the intraoral scanner is generally valid, in spite of sporadic differences in arch length measurement and oseodental discrepancy (**Figure 4**).

## 5. Discussion

Section 4.1 examined intra- and inter-examiner reproducibility of the scanning method using the Itero intraoral scanner.

**Regarding intra-examiner reproducibility of the scanning method using the Itero intraoral scanner**, as other authors have found [11, 16, 18, 20], all the data obtained could be interpreted as highly reproducible. However, for arch length measurement, some bias occurred between the repeated sets of measurements. *Regarding teeth sizes (TS)*, it was seen that the closer to zero the mean mesiodistal size and standard deviation, the more reproducible the measurement method. A tendency to register higher values in the second set of measurements of dental sizes was noted for most values (negative differences). In 2013, some authors [1] argued that differences of less than 0.2 mm in tooth sizes could be considered clinically insignificant, although these differences are statistically significant. The coefficients of variation (CV) for most tooth sizes were below 2.5% and considered very good. Intraclass correlation coefficients (CCI) for all tooth sizes pointed to a very good level of intra-examiner reproducibility, as confirmed by other authors [11, 16, 18, 20]. *Regarding intercanine (ICD) and intermolar distances (IMD) and arch length (AL)*, greater differences were found in arch lengths than in intercanine and intermolar distances, these results being similar to those of Jacob et al. [18]. Likewise, other authors [33] affirmed that, although statistically significant, errors of less than 0.20 mm are not clinically significant. These results are similar to studies by Naidu et al. [16] and Grünheid et al. [17]. Arch length, intercanine, and intermolar distance measurements showed very low CV, all below 2%, indicating good reproducibility. Finally, CCIs were over 0.70, coinciding with other author [34] who considered that CCIs over 0.75 signified excellent

reproducibility; in other words, the present study obtained slightly lower CCIs pointing to a fairly high level of reproducibility. *Regarding Anterior and overall Bolton ratio (BOLTON A,O)*, all data demonstrated high reproducibility.

*Regarding inter-examiner reproducibility of the scanning method using the Itero intraoral scanner*, all the data obtained could be interpreted as highly reproducible. In fact, intra-examiner analysis did not detect any loss of reproducibility between sets of measurements, which shows that the measurement methods compared function independently of the examiner performing them.

*Regarding teeth sizes (TS)*, mean differences showed a tendency to be negative. However, all confidence intervals for mean differences contained a zero; in other words, any bias, when it existed, was unappreciable in statistical terms. Dahlberg error, D, showed values below 0.25 mm for most dental size measurements, a finding that concurs with Wiranto et al. [1]. All tooth sizes except one were below 3.5%. Intraclass correlation coefficients presented values above 0.65 in all cases, whereas values above 0.90 were not unusual, indicating fairly high reproducibility.

*Regarding intercanine (ICD) and intermolar distance (IMD) and arch length (AL)*, values remained below 1.50 mm, an acceptable range, showing quite low coefficients of variance. *Regarding anterior and overall Bolton ratio (BOLTON A, O)*, Bolton ratios were found to be below 1 mm. In a study by Wiranto et al. [1], differences reached 1.5 mm using the LAVA C.O.S intraoral scanner, but the authors considered that, although statistically significant, these differences were clinically insignificant. In relative terms, the CV was below 3.0% for most parameters.

Section 4.2 investigated the validity of intraoral scanning in comparison with manual measurement (considered the “Gold Standard”) by means of two analyses.

**The first analysis compared** average values obtained for each parameter using the two methods to determine whether the intraoral scanning method can be considered valid. Regarding teeth sizes, almost no differences were found, and the few systematic errors identified were the exception rather than the rule. Slight variations also occurred in a study by some authors [16], in which the authors explained by the fact that rotations present in round-shaped teeth, such as upper molars, premolars or canines, mean that for the intraoral scanning method, there is no physical barrier for positioning the measurement points, leading to statistically significant variations in comparisons of the two methods.

For intercanine and intermolar distances, similar results were obtained with both methods.

But, for arch length measurement, statistical analysis detected significant differences between scanning and manual measurement, whereby the scanning method overestimated dimensions. So, comparing the arch length measurements obtained manually with those obtained by scanning, neither the dependent variable could be accepted as 1 nor the constant as 0. In other words, the scanner overestimated arch length and even more so when measuring individuals with smaller arch dimensions. Some authors [35] also observed significant differences in data obtained for this variable in their comparison of measurements taken from plaster models and from digital models, whereby digital models overestimated arch length. This was somewhat similar to others [13], who compared measurements taken from digital models obtained using a tabletop scanner with measurements taken from plaster models.

Some authors [36] attributed these variations to the difficulty of measuring 3D models on a 2D computer screen. Others [7] made a similar argument, affirming that interpreting anatomical structures to determine arch length from a 2D visualization of a digital model is much more complex than measuring a physical model. This was also pointed out by others [1].

The second analysis grouped the measurements obtained for each parameter, applying six regression models. In this model, tooth sizes made up 720 of 1020 pairs (70.5%) representing considerable weight, a situation that coincides with observations made by some authors [18, 33].

## 6. Conclusions

The intra- and inter-examiner reproducibility of both methods can be qualified as high, both in terms of systematic components and random error, although the manual method showed itself to be slightly more reproducible than intraoral scanning.

- The overall validity of intraoral scanning is acceptable for measuring dental parameters in comparison with the manual method or “Gold Standard.”
- The maximum agreement between the two methods was obtained when measuring mesiodistal tooth sizes, whereas the minimum agreement was obtained in arch length measurement and oseodental discrepancies, whereby intraoral scanning tended to overestimate measurements compared with the manual method.

## Author details

Ignacio Faus-Matoses, Ana Mora, Carlos Bellot-Arcís, Jose Luis Gandia-Franco and Vanessa Paredes-Gallardo\*

\*Address all correspondence to: [vanessa.paredes@uv.es](mailto:vanessa.paredes@uv.es)

Orthodontic Department, Dentistry University, University of Valencia, Spain

## References

- [1] Wiranto MG, Engelbrecht WP, Tutein Nolthenius HE, Van Der Meer WJ, Ren Y. Validity, reliability, and reproducibility of linear measurements on digital models obtained from intraoral and cone-beam computed tomography scans of alginate impressions. *American Journal of Orthodontics and Dentofacial Orthopedics*. 2013;**143**(1):140-147
- [2] Lee SJ, Macarthur RX IV, Gallucci GO. An evaluation of student and clinician perception of digital and conventional implant impressions. *The Journal of Prosthetic Dentistry*. 2013;**110**(5):420-423

- [3] Burhardt L, Livas C, Kerdijk W, Van der Meer WJ, Ren Y. Treatment comfort, time perception, and preference for conventional and digital impression techniques: A comparative study in young patients. *American Journal of Orthodontics and Dentofacial Orthopedics*. 2016;**150**(2):261-267
- [4] Lee SJ, Gallucci GO. Digital vs. conventional implant impressions: Efficiency outcomes. *Clinical Oral Implants Research*. 2013;**24**(1):111-115
- [5] Keim RG, Gottlieb EL, Vogels DS III, Vogels PB. JCO study of orthodontic diagnosis and treatment procedures, part1: Results and trends. *Journal of Clinical Orthodontics*. 2014;**48**: 607-630
- [6] Stevens DR, Flores-Mir C, Nebbe B, Raboud DW, Heo G, Major PW. Validity, reliability, and reproducibility of plaster vs digital study models: Comparison of peer assessment rating and Bolton analysis and their constituent measurements. *American Journal of Orthodontics and Dentofacial Orthopedics*. 2006;**129**:794-803
- [7] Leifert MF, Leifert MM, Efstratiadis SS, Cangialosi TJ. Comparison of space analysis evaluations with digital models and plaster dental casts. *American Journal of Orthodontics and Dentofacial Orthopedics*. 2009;**136**(1):16.e1-16.e4 discussion 16
- [8] Fleming PS, Marinho V, Johal A. Orthodontic measurements on digital study models compared with plaster models: A systematic review. *Orthodontics & Craniofacial Research*. 2011;**14**:1-16
- [9] Sousa MV, Vasconcelos EC, Janson G, Garib D, Pinzan A. Accuracy and reproducibility of 3-dimensional digital model measurements. *American Journal of Orthodontics and Dentofacial Orthopedics*. 2012;**142**:269-273
- [10] Kim J, Heo G, Lagravère MO. Accuracy of laser-scanned models compared to plaster models and cone-beam computed tomography. *The Angle Orthodontist*. 2014;**84**:443-450
- [11] Patzelt SB, Lamprinos SS, Att W. The time efficiency of intraoral scanners: An in vitro comparative study. *Journal of the American Dental Association (1939)*. 2014;**145**:542-551
- [12] Costalos PA, Sarraf K, Cangialosi TJ, Efstratiadis S. Evaluation of the accuracy of digital model analysis for the American Board of Orthodontics objective grading system for dental casts. *American Journal of Orthodontics and Dentofacial Orthopedics*. 2005;**128**(5):624-629
- [13] Rheude B, Sadowsky PL, Ferriera A, Jacobson A. An evaluation of the use of digital study models in orthodontic diagnosis and treatment planning. *The Angle Orthodontist*. 2005;**75**:300-304
- [14] Torassian G, Kau CH, English JD, Powers J, Bussa HI, Marie Salas-Lopez A, Corbett JA. Digital models vs plaster models using alginate and alginate substitute materials. *The Angle Orthodontist*. 2010;**80**(4):474-481
- [15] De Luca Canto G, Pachêco-Pereira C, Lagravere MO, Flores-Mir C, Major PW. Intra-arch dimensional measurement validity of laser- scanned digital dental models compared with the original plaster models: A systematic review. *Orthodontics & Craniofacial Research*. 2015;**18**:65-76

- [16] Naidu D, Scott J, Ong D, Ho CT. Validity, reliability and reproducibility of three methods used to measure tooth widths for Bolton analyses. *Australian Orthodontic Journal*. 2009;**25**:97-103
- [17] Grünheid T, McCarthy SD, Larson BE. Clinical use of a direct chairside oral scanner: An assessment of accuracy, time, and patient acceptance. *American Journal of Orthodontics and Dentofacial Orthopedics*. 2014;**146**:673-682
- [18] Jacob HB, Wyatt GD, Buschang PH. Reliability and validity of intraoral and extraoral scanners. *Progress in Orthodontics*. 2015;**16**:38
- [19] Jung YR, Park JM, Chun YS, Lee KN, Kim M. Accuracy of four different digital intraoral scanners: Effects of the presence of orthodontic bracket. *International Journal of Computerized Dentistry*. 2016;**19**(3):203-215
- [20] Aragon MLC, Pontes LF, Bichara LM, Flores-Mir C, Normando D. Validity and reliability of intraoral scanners compared to conventional gypsum models measurements: A systematic review. *European Journal of Orthodontics*. 2016;**38**(4):429-434
- [21] Ting-Shu S, Jian S. Intraoral digital impression technique: A review. *Journal of Prosthodontics*. 2015;**24**(4):313-321
- [22] Birnbaum NS, Aaronson HB, Steven C, Cohen B. 3D digital scanners: A high-tech approach to more accurate dental impressions. *Inside Dentistry*. 2009;**5**:70-74
- [23] Galhano GA, Pellizer EP, Mazaro JV. Optical impression system for CAD-CAM restorations. *The Journal of Craniofacial Surgery*. 2012;**23**:e575-e579
- [24] Syrek A, Reich G, Ranftl D, Klein C, Cerny B, Brodesser J. Clinical evaluation of all-ceramic crowns fabricated from intraoral digital impressions base don the principle of active wavefront sampling. *Journal of Dentistry*. 2010;**38**:553-559
- [25] Birnbaum NS, Aaronson HB. Dental impressions using 3D digital scanners: Virtual becomes reality. *The Compendium of Continuing Education in Dentistry*. 2008;**29**:494-496, 498-505
- [26] Garg AK. Cadent iTero's digital system for dental impressions: The end of trays and putty? *Dental Implantology Update*. 2008;**19**:1-4
- [27] Kachalia PR, Geissberger MJ. Dentistry a la carte: In-office CAD-CAM technology. *Journal of the California Dental Association*. 2010;**38**:323-330
- [28] Glassman S. Digital impressions for the fabrication of aesthetic ceramic restorations: A case report. *Practical Procedures & Aesthetic Dentistry*. 2009;**21**:60-64
- [29] Bolton WA. Disharmony in tooth size and its relation to the analyses and treatment of malocclusion. *The Angle Orthodontist*. 1958;**28**(3):113-130
- [30] Bolton WA. The clinical application of a tooth-size analysis. *American Journal of Orthodontics*. 1962;**48**:504-529

- [31] Zilberman O, Huggare JÅV, Parikakis KA. Evaluation of the validity of tooth size and arch width measurements using conventional and three-dimensional virtual orthodontic models. *The Angle Orthodontist*. 2003;**73**(3):301-306
- [32] Okunami TR, Kusnoto B, BeGole E, Evans CA, Sadowsky C, Fadavi S. Assessing the American Board of Orthodontics objective grading system: Digital vs. plaster dental casts. *American Journal of Orthodontics and Dentofacial Orthopedics*. 2007;**131**(1):51-56
- [33] Akyalcin S, Cozad BE, English JD, Colville CD, Laman S. Diagnostic accuracy of impression-free digital models. *American Journal of Orthodontics and Dentofacial Orthopedics*. 2013;**144**:916-922
- [34] Fleiss JL. *Statistical Methods for Rates and Proportions*. New York: Wiley; 1981
- [35] Mullen SR, Martin CA, Ngan P, Gladwin M. Accuracy of space analysis with emodels and plaster models. *American Journal of Orthodontics and Dentofacial Orthopedics*. 2007;**132**:346-352
- [36] Schirmer UR, Wiltshire WA. Manual and computer-aided space analysis: A comparative study. *American Journal of Orthodontics*. 1997;**112**:676-680

---

## Identification of Lower Central Incisors

---

Marcela de Almeida Gonçalves,  
Bruno Luís Graciliano Silva, Marcelo Brito Conte,  
Juliana Álvares Duarte Bonini Campos and  
Ticiana Sidorenko de Oliveira Capote

Additional information is available at the end of the chapter

<http://dx.doi.org/10.5772/intechopen.71341>

---

### Abstract

Unlike the other teeth, the permanent lower central incisors have great symmetry between the proximal surfaces, being difficult to distinguish them. It was intended to facilitate the study of the anatomy of the lower central incisor for dentistry students, that this study searched for a better way to differentiate the third quadrant element (31) from the fourth quadrant element (41). The purpose of this chapter was to evaluate 100 permanent lower central incisors of the didactic collection of the Discipline of Anatomy of the Department of Morphology of the School of Dentistry of Araraquara - UNESP and to verify the presence of correlation between the some anatomical features. Besides, it was evaluated if there was difference between 31 and 41. It was verified that the systematic methodology used for the evaluation of the incisors in this study facilitated the identification of the teeth. There was no statistically significant difference between the measurements of 31 and 41. Distinguishing the right from the left central incisor is difficult, even for experienced practitioners. We could observe that the measurements do not facilitate the identification of teeth of different quadrants. Therefore, the anatomical features are relevant for the study of the dental anatomy in the identification of the lower central incisors.

**Keywords:** dental anatomy, lower central incisor, dental crown, dental root, tooth morphology

---

### 1. Introduction

In dentistry, it is essential to have a wide knowledge of the dental anatomy. The study of basic anatomical characteristics combined with the extensive knowledge about the richness

---

of details present in a single tooth is the factor that can differentiate a high-level dentist from other professionals.

In esthetic procedures, where there is a great need to know the morphology of each tooth, we have the anterior dental teeth acting as protagonists. Incisors and canines are the group of teeth that require most attention of dentists, since alterations in their anatomical structures are easy to perceive.

In this chapter, there is a search for a better understanding of the external shape and appearance of one of these components: the permanent lower central incisors.

It is already known that, unlike the other teeth, the permanent lower central incisors have their mesial surface shorter or equal compared to the distal surface (if observed by their free surfaces), converging to the cervix of the teeth [1]. Although being almost equal to the proximal surfaces, the distal one is more convex and with a clearer configuration. The mesial surface, on the other hand, is smaller (at least in weary teeth) and less inclined than the distal surface [1]. However, there is great symmetry between both surfaces of the permanent lower central incisor, with a tendency to parallelism, being difficult to distinguish the proximal surfaces [2]. Another feature that hinders the identification of the proximal surfaces is the intersection of the incisal margin with the mesial and distal margins of the proximal surfaces. This intersection occurs at almost right, very little rounded, or not rounded angles [2, 3].

The deciduous lower central incisor differs from the deciduous lower lateral incisor mainly because of the size, since the lateral incisor is larger than the central incisor. This difference in size is, in many people, more pronounced in deciduous than in permanent teeth [4].

The teeth that may be confused with the permanent lower central incisors during the individual study in dental anatomy classes are the permanent lower lateral incisors. However, the lower lateral incisor is slightly larger in all dimensions [2]. Its crown is not symmetrical bilaterally as the one of the central incisor [5]. Its proximal surfaces present greater convergence to the cervix, and the mesial surface is slightly higher than the distal one [1, 2, 5]. The almost right angles observed on the permanent lower central incisors are not present on the lateral incisors, but they have a distoincisor angle more rounded and obtuse [1, 2, 5]. The most significant difference between the permanent lower incisors is the projection of the distoincisor angle to the lingual surface of the lateral incisors, because the incisal edge is rotated to the distal-lingual direction. The cingulum, located on the lingual surface, also accompanies the edge rotation, with its greater prominence slightly distal. With respect to the roots, the lower lateral incisors present them longer, more robust, and with deeper grooves, with the apex angled to distal [2, 5].

Due to the absence of sufficient wear to alter the dental structure, in newly erupted teeth, the mesial surface is still larger than the distal one, although this condition is transient and, over time, the situation is reversed, since wear is more pronounced in the mesial part of the incisal margin [1, 2].

According to Madeira and Rizzolo [2], the cervical line describes a very closed curve, which extends incisally up to one-third of the length of the crown and is even more closed on the mesial side.



It was intended to facilitate the study of the anatomy of the lower central incisor for dentistry students that this study searched for a better way to differentiate the third quadrant element (31—permanent left lower central incisor) from the fourth quadrant element (41—permanent right lower central incisor).

This chapter had as a purpose to evaluate permanent lower central incisors of the didactic collection of the Discipline of Anatomy, Department of Morphology, School of Dentistry of Araraquara, São Paulo State University (UNESP) and to verify the presence of correlation between the structures mentioned below: proximal surface with the smallest cervical-incisal dimension, mesio-incisal and disto-incisal angles, cervical line on the proximal surfaces, the flattest proximal surface in the cervix region, root grooves, and root apex, intending to identify the proximal surfaces by those structures. Measurements of the cervical-incisal dimension of the crown, the root length, mesio-distal dimension of the crown and root, buccolingual dimension of the crown and root, and total tooth length were made. Besides, it was evaluated whether there was difference between 31 and 41.

## 2. Methodology

This project was approved by the Ethics Committee of the School of Dentistry of Araraquara, São Paulo State University (UNESP) (CAAE 61522516.2.0000.5416).

One hundred permanent lower central incisors, with no information about sex and age, were evaluated, and those belong to the collection of the Laboratory of Anatomy of the Department of Morphology of the São Paulo State University (UNESP), School of Dentistry, Araraquara were evaluated. The teeth were cleaned with dental instruments and solution of hydrogen peroxide and ammonium hydroxide. The teeth were stored dry, without any solutions, in glass containers. Those teeth are routinely used in the dental anatomy classes.

The proximal faces were randomly determined with the letters A and B, and the following structures were evaluated by visual method:

1. Proximal surface with the smallest cervical-incisal dimension: A, B, or W (without identification, when no difference was observed between A and B).
2. The most pointed incisal angle: A, B, or W.
3. The greatest curvature of the cervical line: A, B, or W.
4. The flattest proximal surface in the cervix region: A, B, or W.
5. Surface with less deep root groove or a more convex surface: A, B or S.
6. Angulation of the root apex: A, B, or R (rectilinear).

Each tooth was identified by a number. The teeth were evaluated by two experienced anatomy professors who checked, at the same time, the classifications and reached a consensus.

From the evaluated features, the teeth were identified as 31 or 41 by the sum of the features observed in each surface, their association, and the most striking structures. The professors also classified the identification of the incisors as easy, moderate difficulty, and difficult, and they noted which features were considered to make the identification.

Subsequently, measurements were made on the same teeth by a single examiner using a digital caliper (Mitutoyo® Sul Americana LTDA).

The following measurements were performed:

- Measurement of the cervical-incisal dimension of the crown (CIC): measurement from the cervical line to the incisal edge made on the buccal surface.
- Measurement of the root length (RL): measurement of the most cervical region of the cervical line up to the root apex made on the buccal surface.
- Measurement of the mesio-distal dimension of the crown (MDC): measurement on the incisal edge of the crown made on the buccal surface.
- Measurement of the mesio-distal dimension of the root (MDR): measurement between the mesial and distal root surfaces in the dental cervix made on the buccal surface.
- Measurement of the buccolingual dimension of the crown (BLC): measurement between the buccal and lingual surfaces of the crown in the dental cervix made on the mesial surface.
- Measurement of the buccolingual dimension of the root (BLR): measurement between the buccal and lingual surfaces of the root in the dental cervix made on the mesial surface.

The measurement of total tooth length (TL) was obtained by the sum of the cervical-incisal dimension of the crown (CIC) and the measurement of the root length (RL).

Descriptive statistics was performed. The t-test was applied to evaluate the relation between the right lower first premolars and the left lower first premolars. A correlation study was performed using the Pearson correlation coefficient ( $r$ ) among the six evaluated features.

### 3. Results

**Table 1** presents the mean, the minimum, and maximum values of the measurements made on 31 and 41. There was no statistically significant difference between the measurements made on 31 and 41 ( $p > 0.05$ ; t-test; **Table 1**).

As there was no significant difference between 31 and 41, the measurements were presented together, without considering the sides.

The mean, the minimum, and maximum values of the measurements of all evaluated lower central incisors are shown in **Table 2**.

Measurements	31	41	p
<b>CIC</b>			
Minimum	10.6	7.9	
Maximum	15.7	11.3	
Mean	9.4	9.3	0.4315
<b>RL</b>			
Minimum	10.6	8.5	
Maximum	15.7	15.1	
Mean	12.9	12.5	0.2167
<b>MDC</b>			
Minimum	4.4	4.7	
Maximum	6.3	5.9	
Mean	5.4	5.3	0.5
<b>MDR</b>			
Minimum	3.1	3.1	
Maximum	4.5	5.6	
Mean	3.5	3.6	0.8224
<b>BLC</b>			
Minimum	4.7	5.0	
Maximum	7.0	6.7	
Mean	5.8	5.8	0.8035
<b>BLR</b>			
Minimum	4.6	4.8	
Maximum	6.7	6.5	
Mean	5.7	5.7	0.5133
<b>TL</b>			
Minimum	19.4	16.7	
Maximum	26.2	24.8	
Mean	22.2	21.8	0.1366

**Table 1.** Mean, minimum, and maximum values of the measurements (mm) made on 31 and 41.

From the 100 permanent lower central incisors, one was not classified as 31 or 41, because the two professors considered more appropriate not to classify it due to the features presented of the tooth and the difficulty in identifying it.

**Table 3** shows the frequency of the anatomical features observed on the lower inferior central incisors.

	N	Minimum	Maximum	Mean
CIC	100	7.6	11.7	9.3
RL	100	8.5	15.7	12.7
MDC	100	4.4	6.3	5.3
MDR	100	3.1	5.6	3.6
BLC	100	4.7	7.4	5.8
BLR	100	4.6	6.7	5.7
CTD	100	16.7	26.2	22.0

**Table 2.** Mean, minimum, and maximum values of the measurements (mm) made on the lower central incisors.

Anatomical features	Frequency	%
<b>Proximal surface with the smallest cervical-incisal dimension</b>		
Mesial	57	57.6
Distal	28	28.3
Without identification	14	14.1
Total	99	100
<b>The most pointed incisal angle</b>		
Mesial	55	55.6
Distal	22	22.2
Without identification	22	22.2
Total	99	100
<b>Proximal surface with the greatest curvature of the cervical line</b>		
Mesial	51	51.5
Distal	23	23.2
Without identification	25	25.3
Total	99	100
<b>The flattest proximal surface</b>		
Mesial	65	65.7
Distal	17	17.2
Without identification	17	17.2
Total	99	100
<b>Surface with less deep root groove or a more convex surface</b>		
Mesial	74	74.7
Distal	15	15.2

Anatomical features	Frequency	%
Without identification	10	10.1
Total	99	100
<b>Angulation of the root apex</b>		
Mesial	6	6.1
Distal	35	35.4
Rectilinear	58	58.6
Total	99	100

**Table 3.** Frequency of the anatomical features observed on the lower inferior central incisors.

## 4. Discussion

The professors verified that the most pointed incisal angle did not show reliability in the selection of the features for the identification of the proximal surfaces. Therefore, it was not included in the sum of the features for decision making. According to Madeira and Rizzolo [2], the incisal angles are almost right, very little rounded, or not rounded.

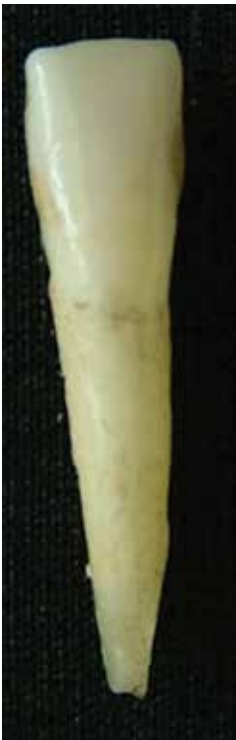Thirty-one teeth were considered easy to identify by the anatomy professors, 22 were considered moderate difficulty, and 46 teeth were considered difficult to classify.

From the 31 teeth considered easy to classify, 19 incisors were identified by adding and associating 4 features, 8 by 3 features, and 4 by 5 features. From the 22 teeth considered with moderate difficulty, 13 were identified by 3 features, 7 by 2 features, and 2 by 4 features. From the difficult teeth, 29 incisors were identified by 2 features, 8 by 3 features, 2 by 4 features, and 7 teeth only by 1 feature.

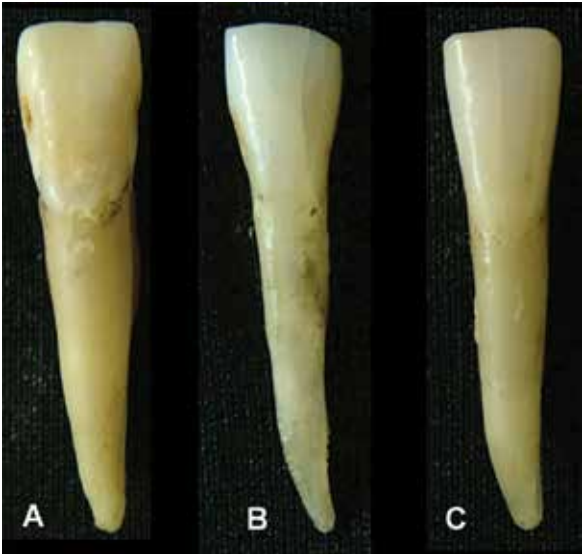
From the teeth considered easy, most of them were chosen by adding the shortest proximal surface feature to the root features (surface with less deep root groove or a more convex surface and the angulation of the root apex), associated or not to the proximal surface with a cervical line with the greatest curvature, or a flatter proximal surface. Therefore, it was verified that the more items found which characterize a certain proximal surface according to the literature, the easier it becomes to identify them. Only five teeth from the 31 considered easy to identify, the shortest proximal surface did not help the identification of the proximal surfaces, and no root features were observed for the identification of four incisors.

The identification of the teeth became more difficult, when one or more features were contrary to the others or when it was not possible to verify differences between the surfaces. Therefore, the professors took into account the most striking elements.

The mesial surface presented the smallest cervical-incisal dimension in 57 teeth (**Figures 1 and 2**), followed by the distal surface (28), and 14 incisors the incisal edge was rectilinear, with mesial and distal surfaces with similar cervical-incisal dimension (**Figure 2 and Table 3**). The



**Figure 1.** Tooth 31 presenting the mesial surface with smaller cervical-incisal dimension compared to the distal surface.



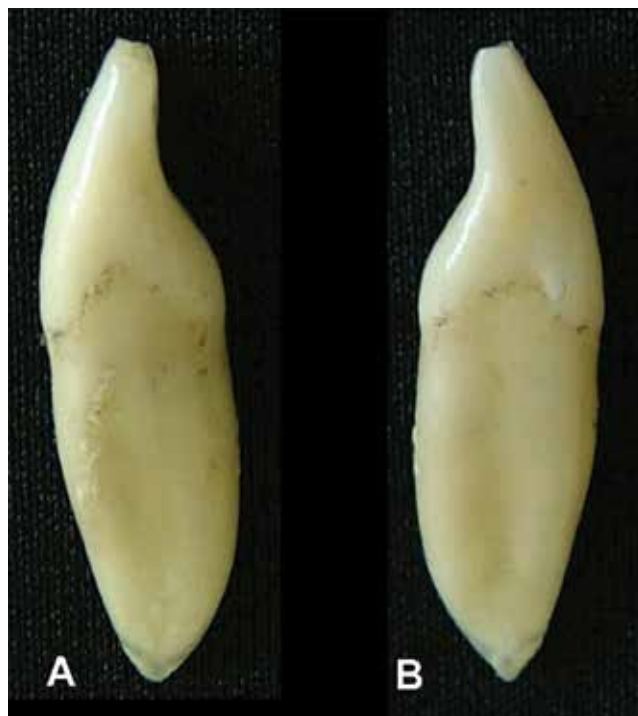
**Figure 2.** Permanent lower central incisors. (A) Rectilinear incisal edge, (B) incisor with the distal surface with smaller cervical-incisal dimension, and (C) incisor with the mesial surface with smaller cervical-incisal dimension.

mesial edge of the buccal surface is usually smaller than the distal one (the inverse of what is observed on the other teeth) because the wear is more pronounced on the mesial half of the incisal edge [1, 6]. Due to the wear, a beveled shape is identified in the incisal edge of the mesial surface, which extends through the buccal surface [1, 2, 7]. The incisal edge is rectilinear and obliquely directed, from top to bottom, in the disto-mesial direction (at least in the teeth with certain wear); the mesial angle becomes more obtuse and the distal one becomes more acute [1]. Possibly, due to the presence of wear, it was observed in the present study that the most pointed incisal angle was the mesial one (55 incisors; **Table 3**). Pagano et al. [7] reported that the mesial and distal angles are slightly rounded or acute, with no significant differences between them.

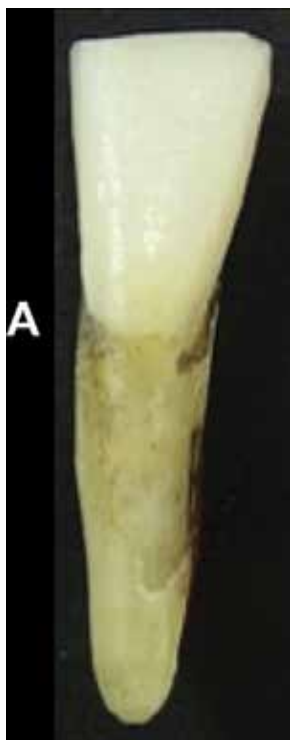
The cervical line presents a greatest curvature on the mesial surface according to Madeira and Rizzolo [2]. This feature was verified in 51.5% of the teeth in this study (**Figure 3**; **Table 3**).

According to Picosse [6], the distal edge of the buccal surface is more angled, but it is difficult to notice. Della Serra and Ferreira [1] reported that the mesial surface is smaller and less inclined than the distal one. In the present study, it was observed that the distal surface was more inclined compared to the mesial surface, this being the flattest one (65.7%) (**Figure 4** and **Table 3**).

Regarding the root grooves, the authors have reported that the lower central incisors have evident longitudinal grooves, the distal groove being the deepest one [2–4, 8]. In the present



**Figure 3.** Permanent lower central incisors. (A) The cervical line presents a greatest curvature on the mesial surface. (B) The cervical line presents a smaller curvature on the distal surface.



**Figure 4.** Permanent lower central incisor. (A) Mesial surface is flatter than the distal surface in the cervix region.

study, it was observed that the distal groove was the deepest one in many teeth. The mesial surface of the roots presented less deep grooves or a more convex surface (74.7%). However, the deepest groove was the mesial one on 15 teeth, and no difference was observed between the surfaces on 10 incisors (**Table 3**). According to Picosse [6], some teeth present the grooves so evident that they can separate the root, partially or totally, into two buccal and lingual segments. This feature described by Picosse [6] was not observed in any lower incisors of this study. Sanchez et al. [9] evaluated the presence of root concavities in the lower central incisors, improving the knowledge of tooth root morphology to result in a correct instrumentation and subsequent success in periodontal treatment. The authors observed that these concavities were present in 100% of the sample and were deeper and wider in the distal surface than in the mesial surface of the root. This feature coincides with the presence of deeper root grooves in the distal surface, already reported in the literature and also found in this study (**Figure 5**).

With the objective of understanding the morphology of the grooves present in the proximal surfaces of the roots of the upper and lower anterior teeth and its effect on the loss of periodontal insertion, Kaur et al. [10] evaluated 300 proximal surfaces of 150 teeth. The prevalence of proximal root grooves was 86.67%. The prevalence of grooves on maxillary teeth was 43.42% and on mandibular teeth was 56.67%. In mandibular teeth, it was 88% for mandibular central incisor, 90% for mandibular lateral incisor, and 80% for mandibular canines. Of the



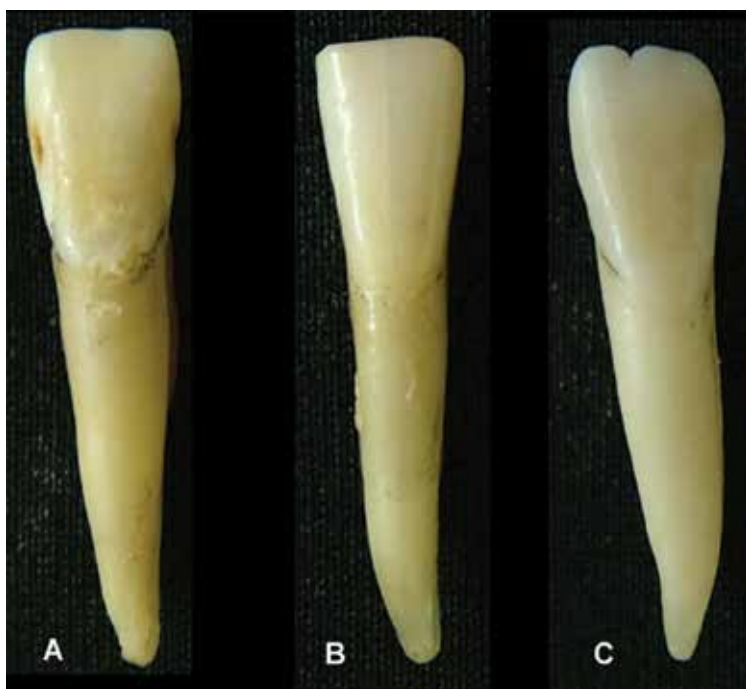


**Figure 5.** Permanent lower central incisor. (A) Mesial surface with a shallow root groove and (B) distal surface with a deeper root groove.

total 300 surfaces that were examined, 228 had grooves, of which 110 (48.24%) were mesial and 118 (51.75%) were distal. The mean width for maxillary central incisor and mandibular incisors was seen to be 1.97 mm and 2.20 mm, respectively. It was observed that the loss of periodontal insertion was higher in teeth that had root grooves than those that did not had grooves, and teeth with deeper grooves presented greater loss. The observations made in the study also support the hypothesis that proximal root grooves when present play a significant role in the loss of attachment.

Madeira and Rizzolo [2] describe the root of the lower central incisor as rectilinear, with no angulation. However, anatomical variation is observed in teeth and also in other anatomical structures. In this study, the root was rectilinear in 58.6% of the lower central incisors; in 35.4%, the root apex was angled to distal, which would not be an uncommon situation; and in 6.1%, there was a mesial inclination of the root apex (**Figure 6** and **Table 3**). According to Della Serra and Ferreira [1], the root inclines to the distal approximately one degree, as well as for Figun and Garino [8], who reported that there is a slight radicular deviation to the distal side. Della Serra and Ferreira [1] cited a study in which rectilinear roots were observed in 66.7% of the lower central incisors, 12.5% presented an angled distal root apex, 2% presented an angled mesial root apex, and in 18.8%, the root apices were inclined to the buccal side. In the present study, no inclination to the buccal side of the root apex was observed.

In this study, we evaluated the measurement of the cervical-incisal dimension of the crown (CIC). The mean value was 9.3 mm (ranging from 7.6 to 11.7 mm; **Table 2**). Della Serra and Ferreira [1] cited a variation from 6.7 to 11.5 mm, and Woelfel and Scheid [5] found a minimum



**Figure 6.** Permanent lower central incisor. (A) Rectilinear root, (B) root apex angled to distal, and (C) root apex angled to mesial.

value of 6.3 mm and a maximum value of 11.6 mm (mean 8.8 mm). The same result (8.8 mm) was found by Figun and Garino [8]. Sicher [11] reported a mean of 9.4 mm for the length of the dental crown. According to Picosse [6], the mean of the dental crown length of the lower central incisors in men was 8.51 mm, and in women, it was 7.95 mm. These results are lower than those found in our study and in the other reported studies.

Regarding the measurement of the root length (RL), the mean value was 12.7 mm (ranging from 8.5 to 15.4 mm; **Table 2**). Others authors reported a range from 8.8 to 16 mm [1], from 7.7 to 17.9 mm (mean value of 12.6 mm) [5], and 11.9 mm [8]. Picosse [6] verified that the mean of the root length was 12.27 mm in men and 12.65 in women. Sanchez et al. [9] measured the root length both on the distal and mesial surfaces. The authors found a mean value of  $13.88 \pm 1.4$  mm on the distal surface and  $13.76 \pm 1.5$  mm on the mesial surface, with no statistically significant difference between them. Besides we have made the same measurement on the buccal surface of the root, our results as well as those cited by Sanchez et al. [9] are within the standards.

Observing the mesio-distal dimension of the dental crown (MDC), we found in the literature a variation from 5.0 to 6.5 mm [1]; 4.4 to 6.7 mm [5]; and a maximum value of 6.87 mm [2]. In the present study, the same measurement ranged from 4.4 to 6.3 mm, with a mean value of 5.3 mm (**Table 2**). A mean value of 5.4 mm for the mesio-distal distance of the lower central incisors was cited by some authors [6, 8, 11].

It was observed that the mean value of the measurement of the mesio-distal dimension of the root (MDR) was 3.6 mm (ranging from 3.1 to 5.6 mm) (**Table 2**). Similar values were observed by Woelfel and Scheid [5] (mean value of 3.5 mm, ranging from 2.7 to 4.6 mm) and 3.9 mm by Sicher [11].

The buccolingual dimension of the crown (BLC) ranged from 4.7 to 7.4 mm (mean value of 5.8 mm; **Table 2**). In the literature, it was found a range from 6 to 8 mm [1] and from 4.8 to 6.8 mm, with a mean value of 5.7 mm [5].

A mean value of 5.7mm (ranging from 4.6 to 6.7mm, **Table 2**) was observed regarding the buccolingual dimension of the root (BLR). A dimension of 5.9 mm was cited by Sicher [11] and 5.4 mm (ranging from 4.3 to 6.5 mm) by Woelfel and Scheid [5]. According to Picosse [6], the mean of the maximum buccolingual dimension of the lower central incisors was 5.7 mm in men and 5.46 in women. Figún and Garino [8] found a buccolingual distance of 6 mm.

The measurement of total tooth length (TL) ranged from 16.7 to 26.2 mm (mean value of 22 mm) (**Table 2**). Others authors reported a range from 15.5 to 27.5 mm [1], from 16.6 to 26.7 mm (mean value of 20.8 mm) [5], 21.4 mm [11], 20.7 mm [8], and 20.78 mm in men and 20.6 mm in women [6].

According to Picosse [6], the mean of the measurements of the lower central incisors was higher in men than in women, except for the measurement of the root length. In our study, there was no information about sex and age. This is a limitation of this study because it was not possible to make associations between the measurements and those criteria.

The Pearson correlation coefficient between six anatomical features (21 possible associations) observed in the lower central incisors showed a weak positive correlation between the features: 1 and 2 ( $r = 0.366$ ,  $p = 0.0001$ ), 1 and 3 ( $r = 0.327$ ,  $p = 0.0016$ ), 1 and 4 ( $r = 0.347$ ,  $p = 0.0004$ ), 1 and 5 ( $r = 0.412$ ,  $p < 0.0001$ ), and 2 and 5 ( $r = 0.309$ ,  $p = 0.0018$ ) and weak negative for 2 and 6 ( $r = -0.419$ ,  $p < 0.0001$ ). The other associations were not significant. Therefore, it was verified that the evaluated features do not repeat in the same way in all incisors, demonstrating anatomical variation. Some patterns described in the literature were confirmed, but the percentage of anatomical variations was high for all studied features.

This makes the study of the lower central incisor quite difficult, especially for the first-year Dentistry graduation student. The lower central incisor is the smallest and most symmetrical tooth of the permanent dentition. Its anatomical elements, such as grooves and ridges, are the least evident [2].

The purpose of this study was to verify features that could facilitate the identification of the proximal surfaces of the lower central incisor. It was verified that the standard anatomical features described in the literature could not be observed in all teeth. However, the observation of the mentioned anatomical features, the sum of the features, the association of them, and the observation of the most striking structures consist of a method that assists in the identification of the permanent lower central incisors.

## 5. Conclusion

It was verified that the evaluated anatomical features do not repeat in the same way in all lower central incisors, demonstrating the presence of anatomical variation. However, the systematic methodology used for the evaluation of the incisors in this study facilitated the identification of the teeth. Therefore, the observation of the anatomical features mentioned in the literature, the sum and the association of the features, and the observation of the most striking structures are methods that facilitated to differentiate the third quadrant element (31—permanent left lower central incisor) from the fourth quadrant element (41—permanent right lower central incisor).

It was verified that there was no statistically significant difference between the measurements of 31 and 41. Distinguishing the right from the left central incisor is difficult, even for experienced practitioners. We could observe that the measurements do not facilitate the identification of teeth of different quadrants. Therefore, the anatomical features are relevant for the study of the dental anatomy in the identification of the lower central incisors.

## Author details

Marcela de Almeida Gonçalves<sup>1\*</sup>, Bruno Luís Graciliano Silva<sup>1</sup>, Marcelo Brito Conte<sup>1</sup>, Juliana Álvares Duarte Bonini Campos<sup>2</sup> and Ticiania Sidorenko de Oliveira Capote<sup>1</sup>

\*Address all correspondence to: marcelagoncalves@foar.unesp.br

1 Department of Morphology, School of Dentistry, São Paulo State University (UNESP), Araraquara São Paulo, Brazil

2 Department of Food and Nutrition, Faculty of Pharmaceutical Sciences, São Paulo State University (UNESP), Araraquara, São Paulo, Brazil

## References

- [1] Della Serra O, Ferreira FV. Anatomia dental. 3rd ed. São Paulo: Artes Médicas; 1981. p. 334
- [2] Madeira MC, Rizzolo RJC. Anatomia do dente. 8th ed. São Paulo: Sarvier; 2016. 169p
- [3] Sicher H, Tandler J. Anatomía para dentistas. 2nd ed. Editorial Labor S.A: Barcelona-Madrid; 1950. p. 463
- [4] Sicher H, Dubrul E. Anatomia Oral. 8th ed. Artes Médicas: Porto Alegre; 1991. p. 390
- [5] Woelfel JB, Scheid RC. Anatomia dental: sua relevância para a odontologia. 5th ed. Rio de Janeiro: Guanabara Koogan; 2000. p. 319
- [6] Picosse M. Anatomia dentária. 4th ed. São Paulo: Sarvier; 1977. p. 294

- [7] Pagano JL, Carbó RAR, Ramón A. Anatomía dentaria. Buenos Aires: Mundi; 1965. p. 664
- [8] Figún ME, Garino RR. Anatomia odontológica funcional e aplicada. 2nd ed. Porto Alegre: Artmed; 2003. p. 532
- [9] Sanchez PRL, Storrer CM, Romito GA, Pustiglioni FE. Morphometric study of length and grooves of lower central incisors roots. South Brazilian Dentistry Journal. 2009;**6**(2):169-175
- [10] Kaur S, Gupta R, Dahiya P, Kumar M. Morphological study of proximal root grooves and their influence on periodontal attachment loss. Journal of Indian Society of Periodontology. 2016;**20**(3):315-319
- [11] Sicher H. Anatomia Oral. 2nd ed. Rio de Janeiro: Livraria Atheneu; 1955. p. 563

*Edited by Bağdagül Helvacioğlu Kivanç*

Dental Anatomy is one of the most important and basic areas of dentistry. This book is a collection of nine chapters divided into five sections as follows:

Chapter 1: “Permanent Maxillary and Mandibular Incisors”

Chapter 2: “The Permanent Maxillary and Mandibular Premolar Teeth”

Chapter 3: “Dental Anatomical Features and Caries: A Relationship to be Investigated”

Chapter 4: “Anatomy Applied to Block Anaesthesia”

Chapter 5: “Treatment Considerations for Missing Teeth”

Chapter 6: “Anatomical and Functional Restoration of the Compromised Occlusion:  
From Theory to Materials”

Chapter 7: “Evaluation of the Anatomy of the Lower First Premolar”

Chapter 8: “A Comparative Study of the Validity and Reproducibility of Mesiodistal  
Tooth Size and Dental Arch with the iTero™ Intraoral Scanner and the Traditional  
Method”

Chapter 9: “Identification of Lower Central Incisors”

The book is aimed toward dentists and can also be well used in education and research.

Published in London, UK

© 2018 IntechOpen  
© icefront / iStock

**IntechOpen**

