Progress Report

Xin Chen

We have accomplished the following quarterly research goals that we promised in the proposal.

<u>Quarter 1, Develop a miniature MRgFUS tissue ablation system including the 3D positioning and immobilization device compatible to microPET, 7T MRI and small animal irradiation.</u>

We developed a small MR compatible spherically-focused ultrasound applicator (Fig 1,a), purchased a micropositioner from SmarArc Gmbb in Germany (Fig 1,c), and integrated with the computer-programmable RF generator (Fig 1,d). To verify the acoustic performance of the new transducer, we measured the relative acoustic pressure squared (Fig 1, b).

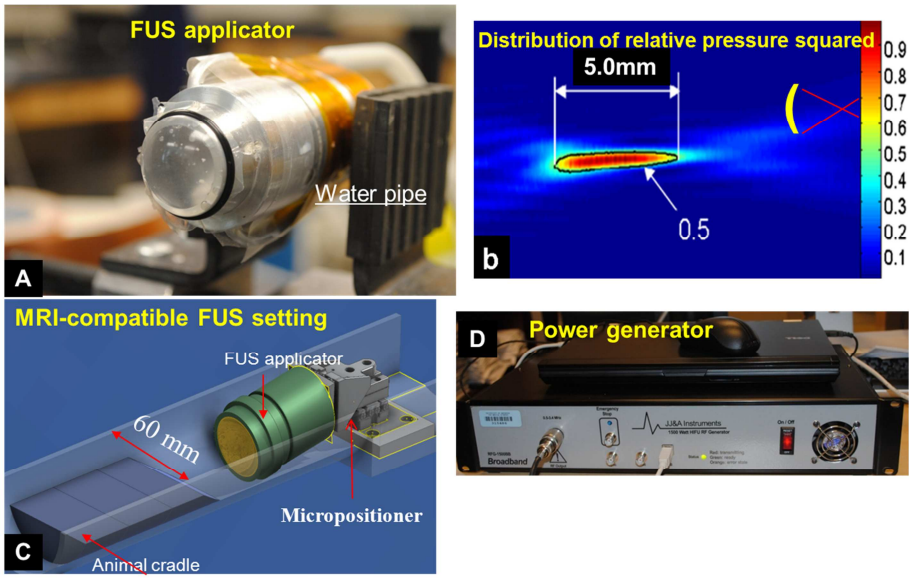

The characteristics and parameters of the transducer:
(1). Recommended work frequency is 2.88 MHz + - 0.01 MHz. (2). This HIFU transducer was built with spherical PZT element with OD = 19 mm and thickness 0.7 mm. The PZT element is covered by Aluminum layer (alloy 6061). (3). Focal distance of the transducer is 31 mm. It is distance between its focal spot and outer surface of the Aluminum layer over the PZT element. (4). The transducer has water cooling system. Aluminum cone at the frontal surface of the transducer has length 15 mm. Hence, focal spot of the transducer is ahead of this cone at distance 16 mm.

The parameters of the micropositioner: (1). Range of movement: 20mm; (2) resolution of movement: 20micro meter. (3). Remotely controlled from outside of the MR room; (4) MR compatible materials;

Quarter 2: Develop the methodology and technology for the combination of PET and MRI to detect and co-register hypoxic regions in small animal tumors.

We have accomplished these tasks successfully. We can register the MRI and PET to identify the targets for ablations, as shown in Fig 2

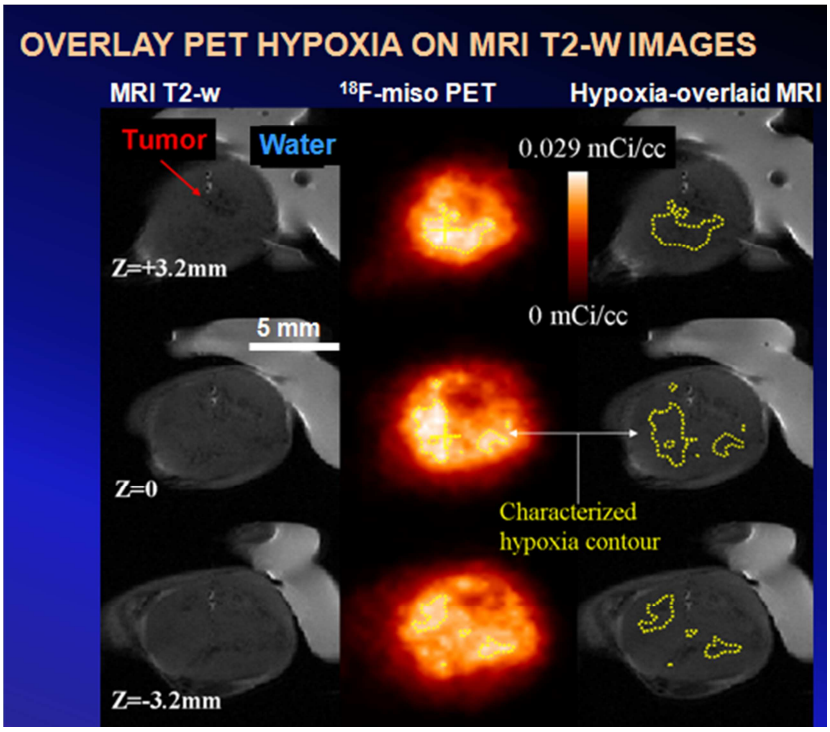

Fig 2. Coregistration between PET and MRI.

In addition to finish the scheduled tasks, we evaluated the PET measurement by comparing with the interstitial Oxylite measurements, as shown in figure 3.

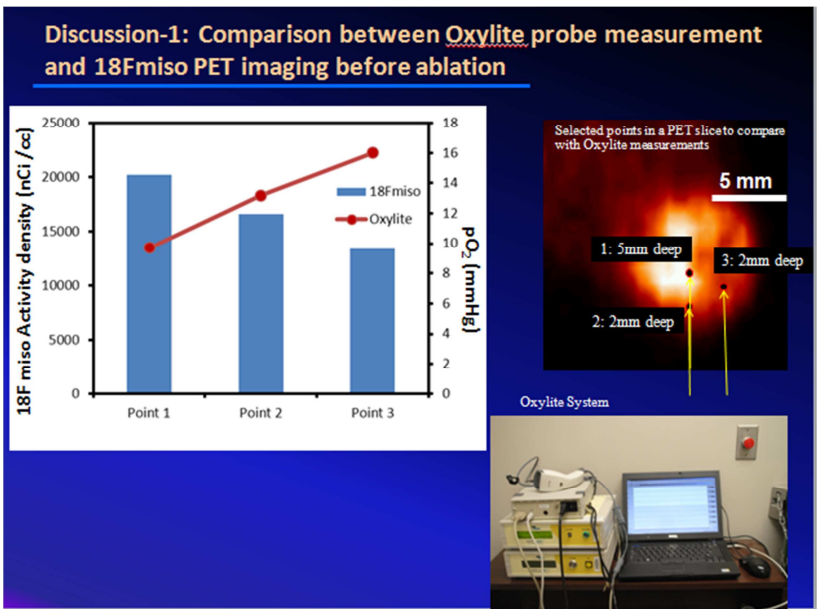

Fig 3: Comparison between Oxylite probe measurement and 18Fmiso PET imaging before ablation.

We also acquired the PET images before and after the ablations. The comparison demonstrated a significant impact of the ablation on the PET-measured hypoxia information, as shown in figure 4. We put it as a discussion because more data will be needed before making any conclusions.

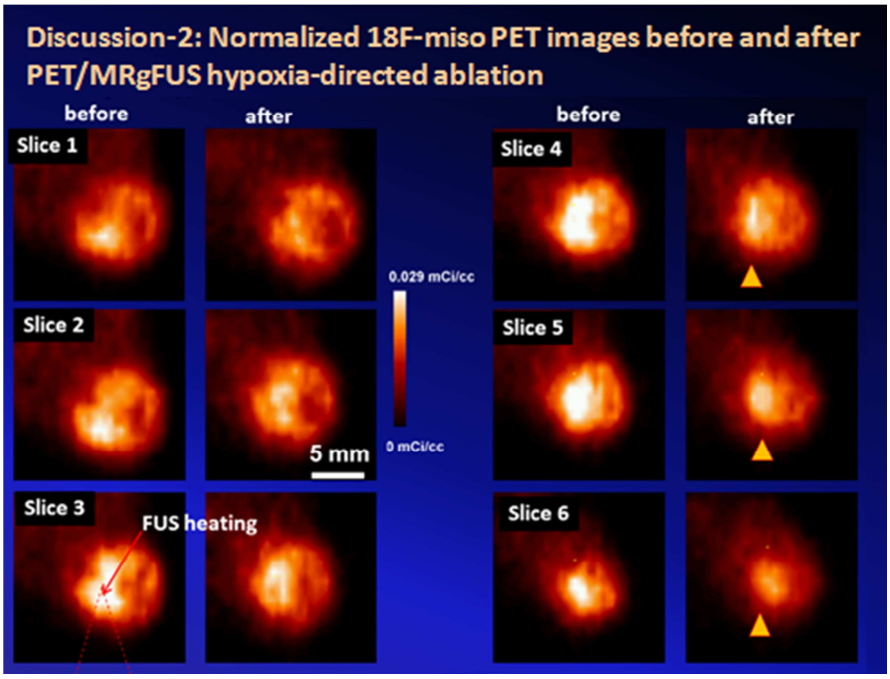

Fig.4. Comparison between PET images before and after ablations.