

UNIVERSITY OF PORT HARCOURT  
COLLEGE OF NATURAL AND APPLIED SCIENCE  
FACULTY OF SCIENCE  
DEPARTMENT OF ANIMAL AND ENVIRONMENTAL BIOLOGY

SEMINAR REPORT  
ON  
MYIASIS INFESTATION AND ITS APPLICATION IN MAGGOT  
THERAPY

PRESENTED

BY

ONYEYAFORO EMMANUEL  
U2014/5550078

COURSE TITLE: SEMINAR

COURSE CODE: AEB 481.2

COORDINATOR(S): PROF. (MRS) F.O. NDUKA,  
DR. U.I DANIEL

SUPERVISOR: DR. MRS. EZE

MAY, 2018

## DEDICATION

I dedicate this Seminar Project to God Almighty, my creator, my strong pillar, my source of inspiration, wisdom, knowledge and understanding. He has been the source of my strength throughout this research and on His wings only have I soared.

## ACKNOWLEDGEMENT

The success and the final outcome of this project required a lot of assistance from many people and I am extremely privileged to have got all these along in my project.

On this note, I wish express my profound gratitude to my parents Mr. and Mrs. A.O Onyeyaforo for their love, encouragement and financial support which made me complete this project duly. To my supervisor Dr. Mrs. Eze, I owe deep gratitude for the constructive criticism, corrections, inputs and encouragement which aided the successful completion of this work.

I am particularly grateful to my departmental lecturers, the course coordinator and assistant; Prof. (Mrs) F.O. Nduka and Dr. U.I Daniel respectively for their moral support and availing themselves throughout the period of this project for questions.

I will not forget to remember my friends Hannah, Uduak Harry, Chisom and Glory; you made things easier for me in a distinct way. Lastly, to all who I might forgot to mention here, thanks for being there for me at all times.

## ABSTRACT

*This essay represents a decision to wade through the vortex of arguments on the modality 'myiasis infestation and its role in maggot therapy'. The maggots of the green bottle fly, **Lucilia sericata**, have been crawling around the world for about two hundred million years. Following the evolution of man, a relationship developed between these maggots and the wounds of man. An acceptable sort of myiasis was born. In the last decade, the level of evidence recording successful outcomes of clinically applied and artificially induced myiasis on wounds using this medicinal maggot has expanded greatly. And as modern and advanced technology helps science to unlock more doors, we are able to gain a clearer picture of the molecules and biochemical pathways by which maggots exert their effects; studies which hopefully will enrich our understanding of the clinical effects observed. The following commentary exacts such new developments and summarizes our current thinking on maggot / larval therapy.*



## TABLE OF CONTENT

Title Page	i	
Dedication	ii	
Acknowledgement	iii	
Abstract	iv	
Table of Content	v	
Introduction		1
History of Myiasis		2
Causative Agents	3	
Epidemiology	4	
Pathophysiology	5	
Prognosis	11	
Treatment	11	
Prevention/Control	12	
Application of Myiasis in Maggot Therapy	13	
General Mechanism of Action	15	
Medical Uses	18	
Conclusion	19	
Recommendations	19	
References	20	

## INTRODUCTION

Myiasis can be defined as the invasion of the organs and tissues of human or vertebrate animals with dipterous larvae belonging to the family *Calliphoridae* (Rohela et al. 2006). It is a parasitic infestation of the body of a living mammal by certain species of fly larvae (maggots) which grow on the host while feeding on host's tissue. It's so common in poverty stricken communities and countries prevailing at the same scale at which it affects humans to animals. Though flies are commonly attracted to open wounds, urine and faeces, some can create an infestation even on unbroken skin via vector agents of the arthropod phylum. These infestations present a severe and continual problem for animals due to their inability to react effectively to the causes and effects leading to economic loss in livestock industries worldwide. *Lucilia sericata*, the common bottle green fly of the family *Calliphoridae* fastidiously related to Myiasis infestation in human increases its prevalence in rural tropical regions where its activities cause parasitic infestation and often may require medical attention for surgically removal. But the bright side of this infection is its service as an eye opener to doctors and physicians who apply the kinetics of this infection which gave rise to maggot/larval therapy; a method of removing dead cells and bacterial from an unhealing wound.

## HISTORY OF MYIASIS

Frederick William Hope coined the term 'myiasis' in 1840 to refer to diseases resulting from dipterous larvae as opposed to those caused by other insect larvae (the term for this was scholechiasis). Hope described several cases of myiasis from Jamaica caused by unknown larvae, one of which resulted in death. Often, a history of traveling to a tropical country or existence of a previous wound is noted in the concerns of the infestation. In one study, the average time from exposure to diagnosis was 6 weeks. Patients complain of boil-like lesions usually on exposed areas of the body, like the scalp, face, forearms, and legs. Lesions can be painful, pruritic, and tender, and patients often have the sense of something moving under the skin. Sometimes, patients also complain of fever or swollen glands. In the cases of ophthalmomyiasis, patients complain of severe eye irritation, redness, foreign body sensation, pain, lacrimation, and swelling of the eyelids. In the cases of nasal myiasis, patients present with epistaxis, foul smell, passage of worms, facial pain, nasal obstruction, nasal discharge, headache, dysphagia, and sensation of foreign body in the nose.

## CAUSATIVE AGENTS

Myiasis causing flies may be grouped into two categories as follows:

- Obligate parasitic flies
- facultative parasitic flies

**Obligate parasitic flies** require the ingestion of living tissue in order to complete their lifecycles while the **facultative parasitic** ones feeds exclusively on dead tissues.

The causative agents of Myiasis include the larvae of the Dipteran orders of fly species. Over hundred species of diptera has been reported to cause human myiasis and some of the most common ones includes:-

- *Dermatobia hominis* (human botfly) causes furuncular myiasis.
- *Lucilia sericata* (bottle green fly) causes wound myiasis
- *Cordylobia anthropophaga* (tumbu fly) also causes furuncular myiasis.
- *Cochliomyia hominivorax* (American bush fly) and *lawrenci*  
*emmanuencium* (Roman gutter fly) causes abscess and wound myiasis respectively
- *Hypoderma bovis* (infested cattle fly) and *Gasterophilus intestinalis* (infested horses fly) both cause creeping (migratory) myiasis.
- *Oestrus ovis* (sheep botfly) causes ophthalmomyiasis.

## EPIDEMIOLOGY

Myiasis is uncommon in the United States, and any cases reported are usually imported cases of myiasis from travelers returning from tropical destinations. However, reported incidence rates are increasing among individuals from non endemic countries who have traveled to tropical destinations or engage in outdoor activities. Myiasis is a worldwide infestation with seasonal variation, the prevalence of which is related to the latitude and life cycle of the various species of flies. Its incidence is higher in the tropics and subtropics of Africa and the Americas. The flies responsible prefer a warm and humid environment and so are restricted to the summer months in the temperate zones, while living year-round in the tropics. *Dermatobia hominis*, also known as human or tropical botfly, is endemic to tropical Mexico, South America, Central America, and Trinidad, while *Cordylobia anthropophaga* (tumbu fly) is endemic to sub-Saharan Africa.

Race: Myiasis is not prevalent in any particular race.

Sex: No sex predilection exists for myiasis.

Age: Myiasis may occur at any age.

## PATHOPHYSIOLOGY

The pathophysiology of the human infection differs depending on the type of fly and its mode of infestation.

- ***Dermatobia hominis*** (Human botfly) - furuncular myiasis

This type is endemic to tropical southeast Mexico, South America, Central America, and Trinidad. The adult fly resembles a bumblebee. It is short lived and survives for little more than a week. It does not feed and is infrequently seen. The life cycle of the botfly is unique, as the female, egg-bearing fly catches a blood-sucking arthropod, usually a mosquito midflight and attaches her eggs to its abdomen (means of transportation known as phoresy). When the mosquito takes a blood meal from a warm-blooded animal, the local heat induces the eggs to hatch and drop to the skin of the host and enter painlessly through the bite of the carrier or some other small trauma. Once deposited in the skin, the larvae start out as small and fusiform and later become pyriform to ovoid as they reach full development at lengths of 15-20 mm.

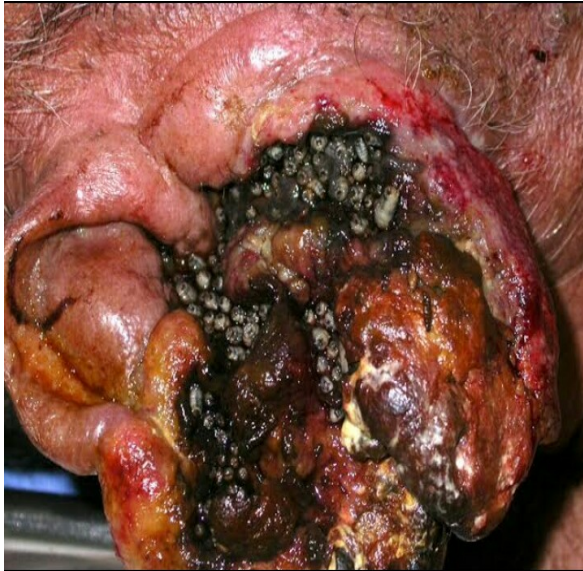

Fig. 1: Myiasis of the skin

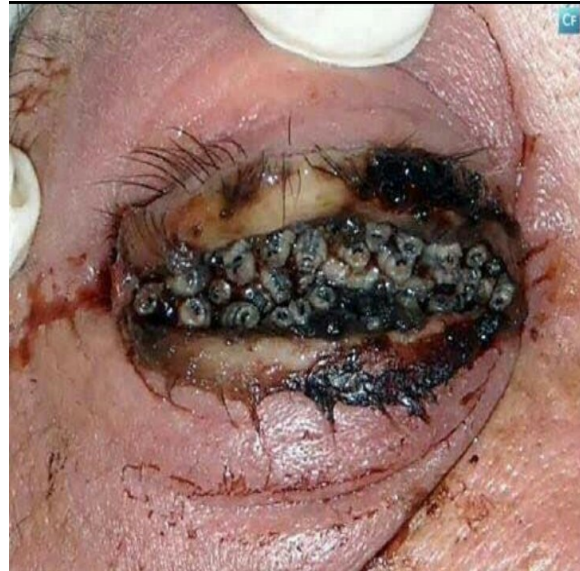


Fig. 2: Ophthalmomyiasis

- *Cordylobia anthropophaga* (tumbu fly) - Furuncular myiasis

This type is endemic to sub-Saharan Africa. The adult fly is about the size of a housefly but stockier. It prefers shade and is most active in the early morning and afternoon. It is attracted by the odor of urine and feces. The females lay their eggs on dry, sandy soil or on damp clothing hung out to dry. The eggs hatch in 1-3 days and can survive near the soil surface or on clothes for up to 15 days waiting for contact with a suitable host. Activated by heat, such as the body heat of the potential host, they are capable of penetrating the unbroken skin with sharp mandibles. [5] They become fusiform to ovoid and reach a length of 13-15 mm. Their larval stage is shorter than that of the human botfly

and is completed in 9-14 days.

- ***Hypoderma bovis/Gasterophilus intestinalis*** - Creeping/migratory myiasis

The adult fly of the *Hypoderma* genus is large and hairy and resembles a bumblebee. Normal hosts for the larvae of this fly are deer, cattle, and horses. Humans are abnormal hosts, in which the parasite is unable to complete its development. Human infections usually occur in rural areas where cattle and horses are raised. In animals, the fly attaches the eggs to the hairs. The larvae hatch, penetrate the skin, and wander extensively through the subcutaneous tissues, eventually locating under the skin of the back, where they produce the furuncular lesions. In humans, the larvae migrate rapidly (as much as 1 cm/h) and erratically through the subcutaneous tissues, producing intermittent, painful swelling over the months. The larvae may emerge spontaneously from the furuncles or die within the tissues. In the rare case, the larvae are seen invading the orbit, pharyngeal region, and spinal canal.

The larvae of the *Gasterophilus* genus are usually gastrointestinal (*Gasterophilus intestinalis*) or nasal (*Gasterophilus nasalis*) parasites of horses. In humans, the young larvae burrow in the skin and wander intradermally, creating narrow, tortuous, erythematous, and linear lesions with intense pruritus. Lesions usually advance 1-30 cm/d. [6] Death of the larvae terminates the infection in 1-2 weeks



without sequelae.

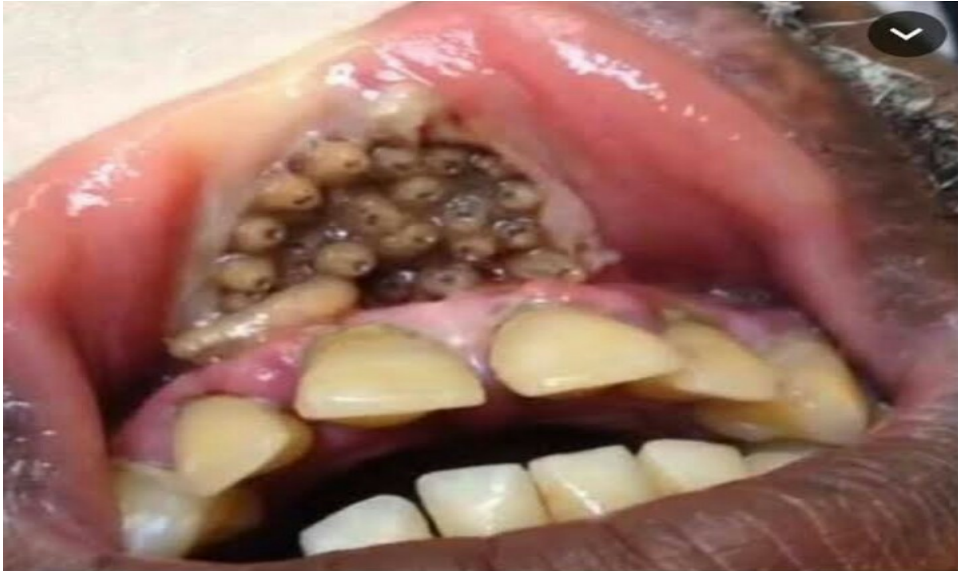

Fig.

3:

Myiasis of the Mouth

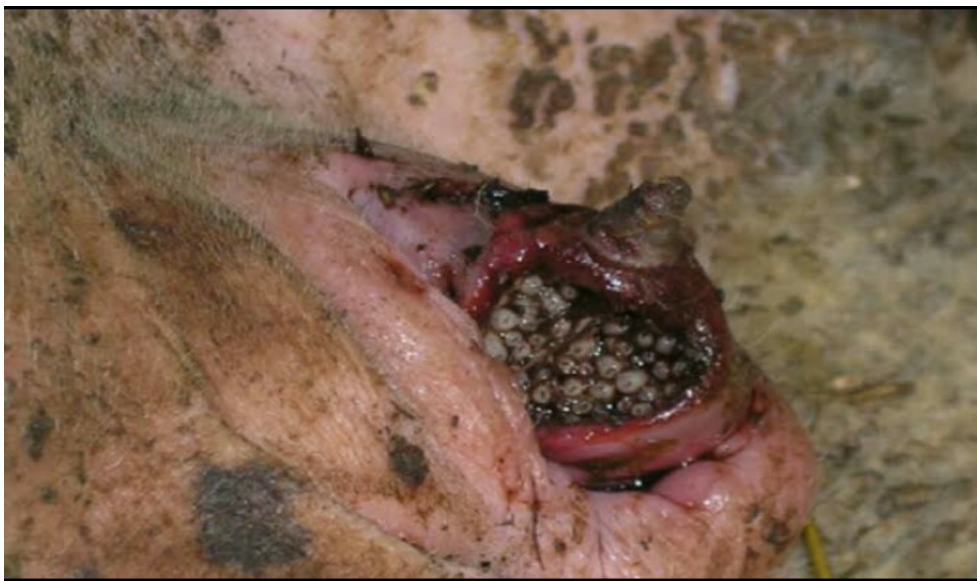

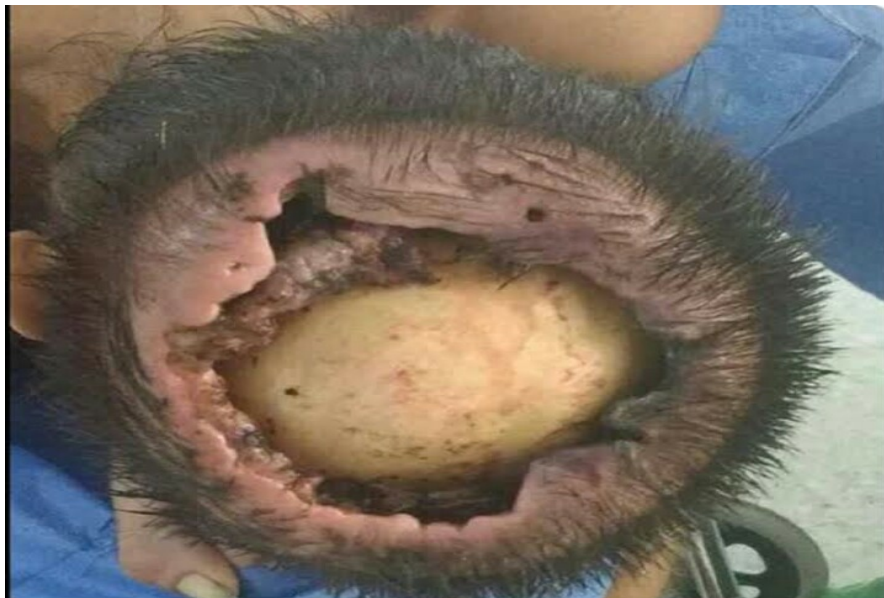Fig. 4: Anal Myiasis in Pigs

- *Cochliomyia hominivorax/Lucilia sericata* (blow fly) – wound myiasis.

The adult flies are rather stocky flies and metallic blue-green top purplish black in color. The larvae are pinkish, fusiform, and strongly segmented. Female flies deposit the eggs near poorly managed wounds and the larvae feed on necrotic tissue. Flies may be dispersed by natural agents such as tornados and hurricanes.

- **Posttraumatic myiasis**

Patients who are victims of facial trauma or extensive scalp injury can develop extensive intracranial maggot infestation causing meningitis and encephalitis if not properly managed within a reasonable period of time.



**Fig. 5: Posttraumatic Myiasis**

## NASAL MYIASIS

In nasal myiasis, examination of the nose (rhinoscopy) reveals an edematous, ulcerated mucous membrane filled with necrotic material and crawling maggots. Patients may have septal perforation or palatal perforation or both. Erosion of the bridge of the nose and adjacent area of the face can also be seen as well as orbital cellulitis and diffuse cellulitis of the face. In a smaller number of patients, examination reveals extensive ulceration of the tonsils and the posterior pharyngeal wall due to maggots.

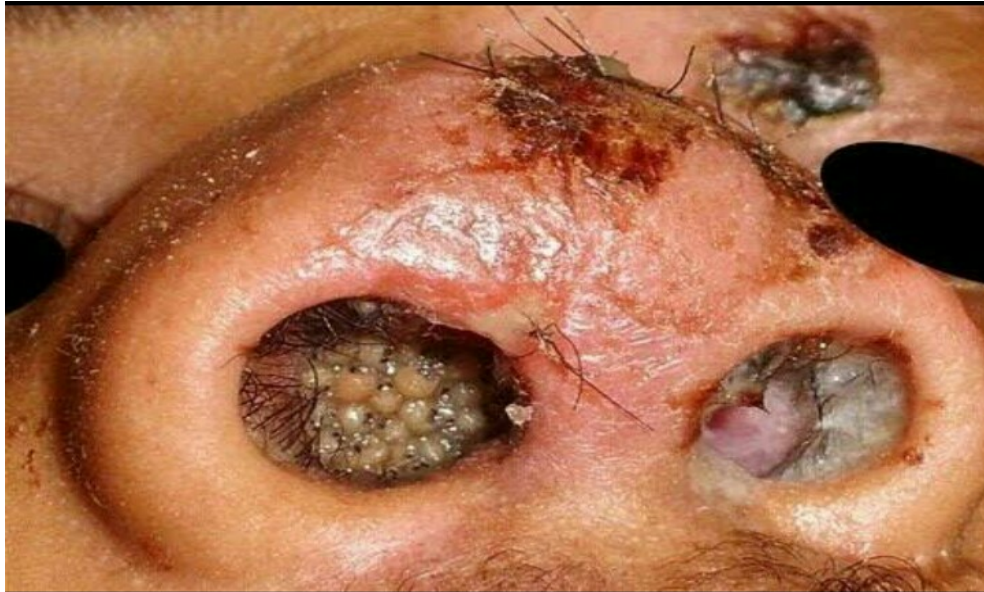

Fig. 6: Nasal Myiasis

## PROGNOSIS

Myiasis is a self-limited infestation with minimal morbidity in the vast majority of cases. The major reasons for treatment are reduction of pain and psychological relief. Once the larva has emerged or has been removed, the lesions rapidly resolve. However, larvae such as *C. hominivorax* (cause of wound myiasis) can infest around orifices of the head and may burrow into brain tissue. Complications include infections such as cellulitis. Cases of neonatal fatal cerebral myiasis, caused by the penetration of larva through the fibrous portion of the fontanel have also been reported.

## TREATMENT

Depending on the location of the larval infestation, dermatologists (wound and furuncular myiasis), ophthalmologists (ophthalmomyiasis), or otorhinolaryngologists (oral, facial, nasal myiasis) may need to be consulted. Ways of treating myiasis includes:

- OCCLUSION/SUFFOCATION APPROACHES

This non-invasive approach includes placing petroleum jelly, liquid paraffin, beeswax or heavy oil, or bacon strips over the central punctum and has been used to coax the larvae to emerge spontaneously head-first over the course of several hours, at which time, tweezers (or forceps) aid in the capture. This approach takes advantage of the larva's oxygen requirements, encouraging it to

exit on its own.

- **SURGICAL REMOVAL WITH LOCAL ANESTHESIA**

The skin lesion is locally anesthetized with lidocaine and excised surgically followed by primary wound closure. Furthermore, care should be taken to avoid lacerating the larva because retained larval parts may precipitate foreign body reaction.

- **SYSTEMIC/TOPICAL IVERMECTIN**

An alternative treatment for all types of myiasis is oral ivermectin or topical ivermectin (1% solution), proven especially helpful with oral and orbital myiasis.

## **PREVENTION/CONTROL**

Individuals traveling to rural endemic areas should be covered at all times with long-sleeved shirts, pants, and hats. At night, sleeping on raised beds, in screened rooms, or under a mosquito net is appropriate.

Insect repellents are also recommended. Clothing should be hot-ironed and dried appropriately to remove any residual eggs in areas endemic to tumbu flies. Patients with any type of wound should not be permitted to sleep outside and, if in an indoor or hospital environment, the windows should never be opened, unless properly screened.

## APPLICATION OF MYIASIS IN MAGGOT THERAPY

Maggot therapy is a type of biotherapy involving the introduction of live disinfected maggots (fly larvae) into the non-healing skin and soft tissue wound(s) of a human or animal for the purpose of cleaning out the necrotic tissues within a wound and disinfection. Maggot therapy is essentially an artificially induced myiasis performed in a controlled environment by experienced medical practitioners. Maggots are photophobic and will naturally move into the deep crevices that may be beyond the reach of a surgeon's scalpel. They have been known for centuries to help heal wounds. Military surgeons noted that soldiers whose wounds became infested with maggots had better outcomes than those not infested.

Maggots are fly larvae or immature flies, not all species of flies are safe and effective as medicinal maggots. The larvae of *Lucilia sericata*, the common green bottle, is therefore the most appropriate species for this application. They are facultative parasites feeding only on dead tissues and unable to ingest or significantly damage healthy human tissue.

Kingdom: *Animalia*

Phylum: *Arthropoda*

Class: *Insecta*

Order: *Diptera*

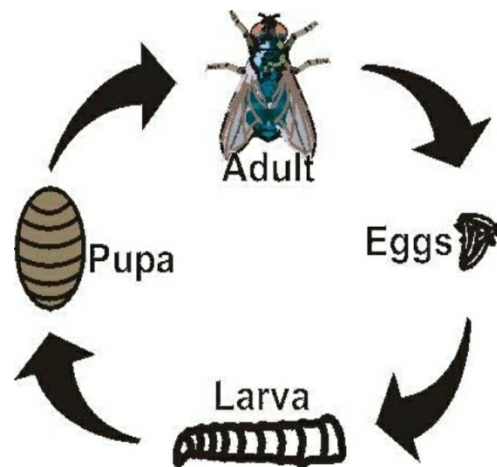
Family: *Calliphoridae*

Genus: *Lucilia*



Species: *L. sericata*

**Fig. 7: *Lucilia sericata***



**Fig. 8: Lifecycle of *L. sericata***



## GENERAL MECHANISM OF ACTION

After the extraction and culture of the fly's eggs to form maggot, the maggots are sterilized and introduced to a patient's wound for the therapy to commence.

The application of maggot involves four main action pathways which are;

- Debridement
- Disinfection (Antimicrobial activity)
- Stimulation of healing
- Biofilm inhibition and eradication

## DEBRIDEMENT

In maggot therapy, large numbers of small maggots consume necrotic tissue far more precisely than is possible in a normal surgical operation, and can debride a wound in a day or two. The area of a wound's surface is typically increased with the use of maggots due to the undebrided surface not revealing the actual underlying size of the wound. They derive nutrients through a process known as "extracorporeal digestion" by secreting a broad spectrum of proteolytic enzymes that liquefy necrotic tissue, and absorb the semi-liquid emanating from the wound within a few days. In an optimum wound environment maggots molt twice, increasing in length from 1–2 mm to 8–10 mm, and in girth, within a



period of 48–72 hours by ingesting necrotic tissue, leaving a clean wound free of necrotic tissue when they are removed.

## **DISINFECTION OF WOUND**

Secretions from maggots believed to have broad-spectrum antimicrobial activity include allantoin, urea, phenylacetic acid, phenylacetaldehyde, calcium carbonate, proteolytic enzymes, and many others. In vitro studies have shown that maggots inhibit and destroy a wide range of pathogenic bacteria including methicillin-resistant *Staphylococcus aureus* (MRSA).

## **STIMULATION OF HEALING**

Application of maggot therapy exhibited a significantly shorter time to granulation, and to overall healing of lesions. The presence of poorly perfused tissue in the impairment of wound healing has always been a clinical obstacle.

## **BIOFILM INHIBITION AND ERADICATION**

Restrains the microorganisms as well as bacteria that might still be present on the surface of the lesion or wound, thereby increasing more the chances of total eradication of the a wound.

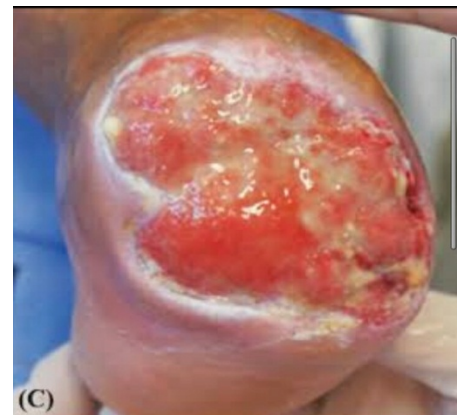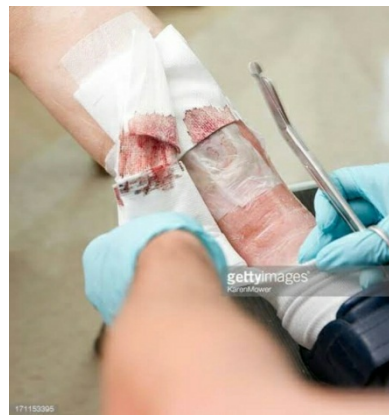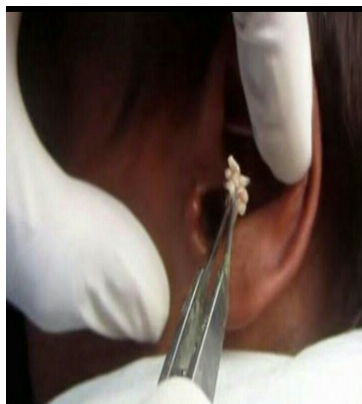


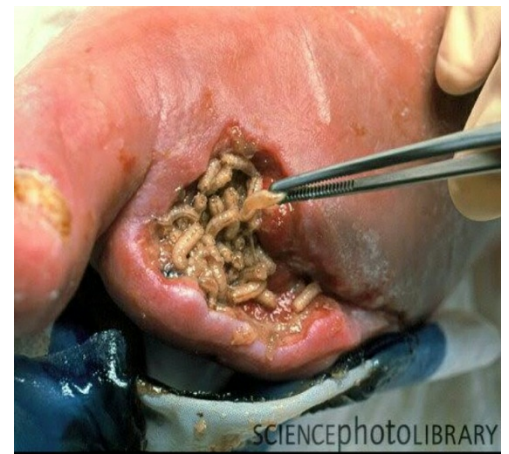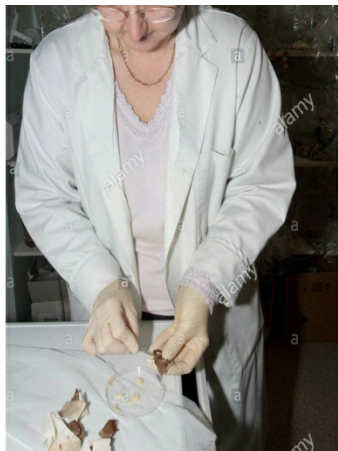Fig. 9

Fig. 10

Fig. 11

Fig. 12

Fig. 13

Fig. 14

Fig. 9: Maggot Culturing processes

Fig. 10: Medical maggot ready for use

Fig. 11: Application of maggot to wounds

Fig. 12: Application of maggot to wounds

Fig. 13: Dressing of wounds after application

Fig. 14: Maggot debrided wound

## MEDICAL USES

The American Medical Association and Centers for Medicare and Medicaid Services recently clarified the reimbursement guidelines to the wound care community for medicinal maggots. Maggot therapy has been used as a purposeful way to treat the following:-

- Diabetic foot ulcers
- Chronic Ulcers
- Non healing necrotic and soft tissue wounds
- Pressure ulcers
- Venous statis ulcers
- Neuropathic foot ulcers
- Chronic Osteomyelitis

## CONCLUSION

Though the effect of myiasis by obligate larvae of parasitic flies is very critical in some cases, the larvae of *Lucilia sericata* has thrown a good light of importance on myiatic studies and its general application for the benefit of man and the society at large through maggot debridement therapy.

## RECOMMENDATIONS

- This therapy is good for diabetic patients having necrotic lesion rather than total amputation of limbs.
- Proves useful in health areas and situations where antibiotics fail.
- It is particularly helpful with chronic osteomyelitis.

## REFERENCES

- Costa DC, Pierre-Filho Pde T, Medina FM, Mota RG, Carrera CR. Use of oral ivermectin in a patient with destructive rhino-orbital myiasis. *Eye*. 2005 Sep. 19(9):1018-20. [Medline].
- Diaz JH. The epidemiology, diagnosis, management, and prevention of ectoparasitic diseases in travelers. *J Travel Med*. 2006 Mar-Apr. 13(2):100-11. [Medline].
- Huntington, T. E.; Voigt, David W.; Higley, L. G. (January 2008). "Not the Usual Suspects: Human Wound Myiasis by Phorids". *Journal of Medical Entomology*. 45 (1): 157-159. doi:10.1603/0022-2585(2008)45[157:NTUSHW]2.0.CO;2. PMID 18283957.
- James, WD, Berger, TG, Elston, DM. Myiasis. *Andrews' Diseases of the Skin*. 11th ed. Elsevier; 2011. 438.
- Maier H, Hönigsmann H. Furuncular myiasis caused by *Dermatobia hominis*, the human botfly. *J Am Acad Dermatol*. 2004 Feb. 50(2 Suppl):S26-30. [Medline].
- Otranto, Domenico (2001). "The immunology of myiasis: parasite survival and host defense strategies". *Trends in Parasitology*. 17 (4): 176-182. doi:10.1016/S1471-4922(00)01943-7. PMID 11282507.
- Richards, O. W.; Davies, R.G. (1977). *Imms' General Textbook of Entomology: Volume 1: Structure, Physiology and Development Volume 2: Classification and Biology*. Berlin: Springer. ISBN 0-412-61390-5.
- Sherman, R. A. (March 2009). "Maggot therapy takes us back to the future of wound care: new and improved maggot therapy for the 21st century". *J Diabetes Sci Technol*. 3 (2): 336-344.
- Sherman, RA, Hall, MJR, Thomas, S (2000). "Medicinal Maggots: An ancient

remedy for some contemporary afflictions". *Annual Review of Entomology*. 45: 55–81. doi:10.1146/annurev.ento.45.1.55. PMID 10761570.

Sun, Xinjuan; Jiang, Kechun; Chen, Jingan; Wu, Liang; Lu, Hui; Wang, Aiping; Wang, Jianming (2014). "A systematic review of maggot debridement therapy for chronically infected wounds and ulcers". *International Journal of Infectious Diseases*. 25: 32–7. doi:10.1016/j.ijid.2014.03.1397 (<https://doi.org/10.1016%2Fj.ijid.2014.03.1397>)?

Terterov S, Taghva A, MacDougall M, Giannotta S. Posttraumatic human cerebral myiasis. *World Neurosurg*. 2010 May. 73(5):557-9. [Medline]